The British Association of Gynaecological Pathologists



Dr Imen Ben Salha

Consultant Histopathologist (gynaecological pathology), University College London Hospitals NHS foundation trust.
Educational supervisor.

The British Association of Gynaecological Pathologists

Gynae Mock Exam

The British Association of Gynaecological Pathologists

Speaker disclosures

Choose one

I have no financial conflicts of interest to disclose

Frozen section (FRCPATH part 2)

- 6 cases to be viewed in 2 x 20-minute stations (3 cases per station) before meeting with a pair of examiners in a 20-minute station.
- Candidates should make notes, to form the basis for face-to-face discussion with 2 examiners who will expect a discussion consistent with the report given to the requesting surgeon.
- This section is marked on the basis of discussion with the examiners only and not a candidate's written preparatory notes.
- Each case is marked to a pre-determined marking scheme.

Frozen section of ovarian tumours

- Intraoperative frozen section (FS) gives rapid histological analysis, allowing clinical decision for a staging operation in cases suspicious of ovarian cancer
- Surgeons can perform or avoid the full surgical staging procedure depending on the results.

Case 1

Clinical history:

Female 60 years

100mm solid cystic ovarian mass ?malignant.

Frozen section

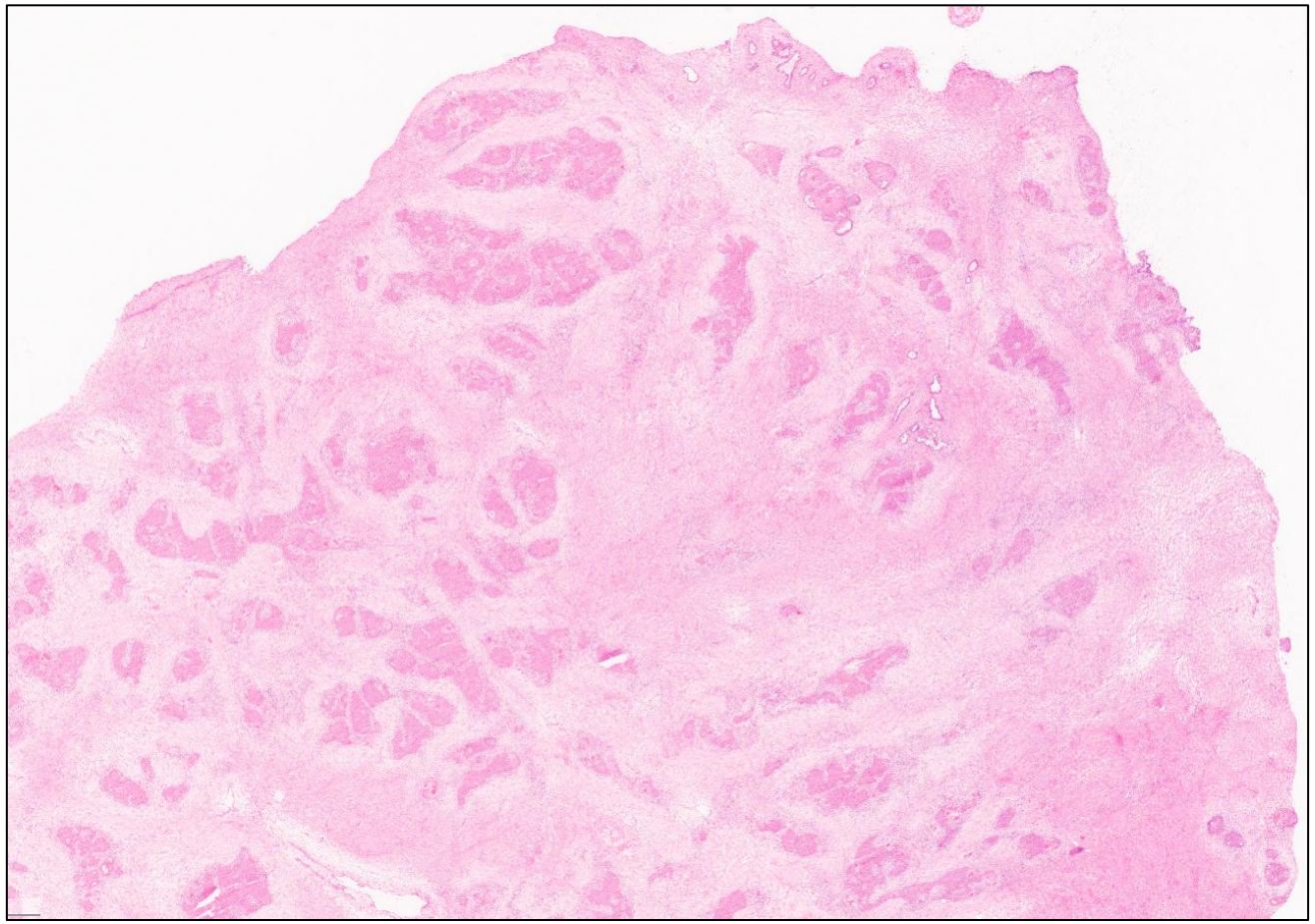

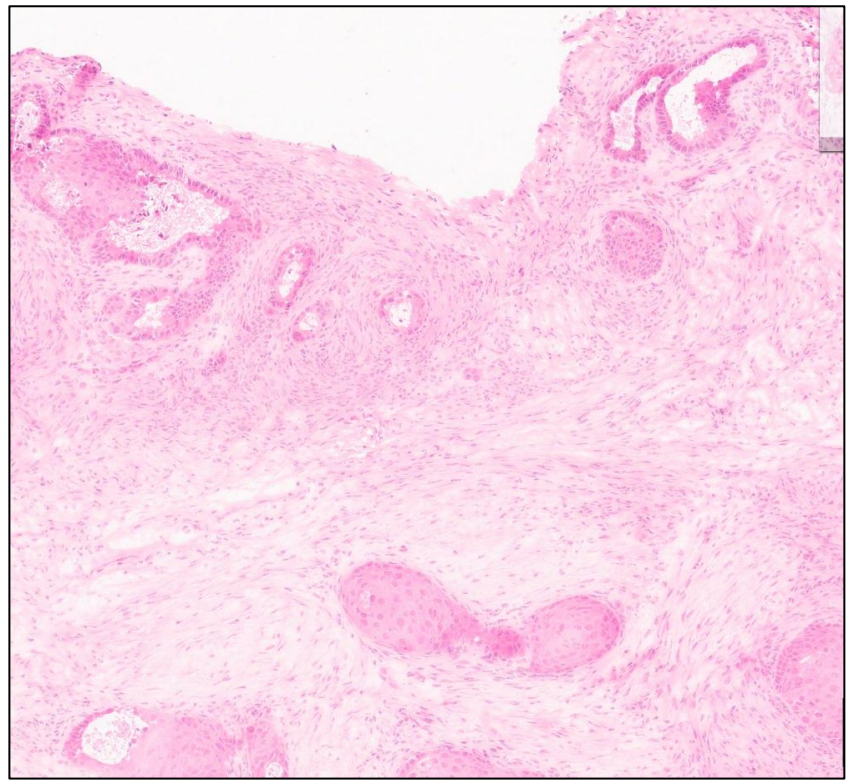

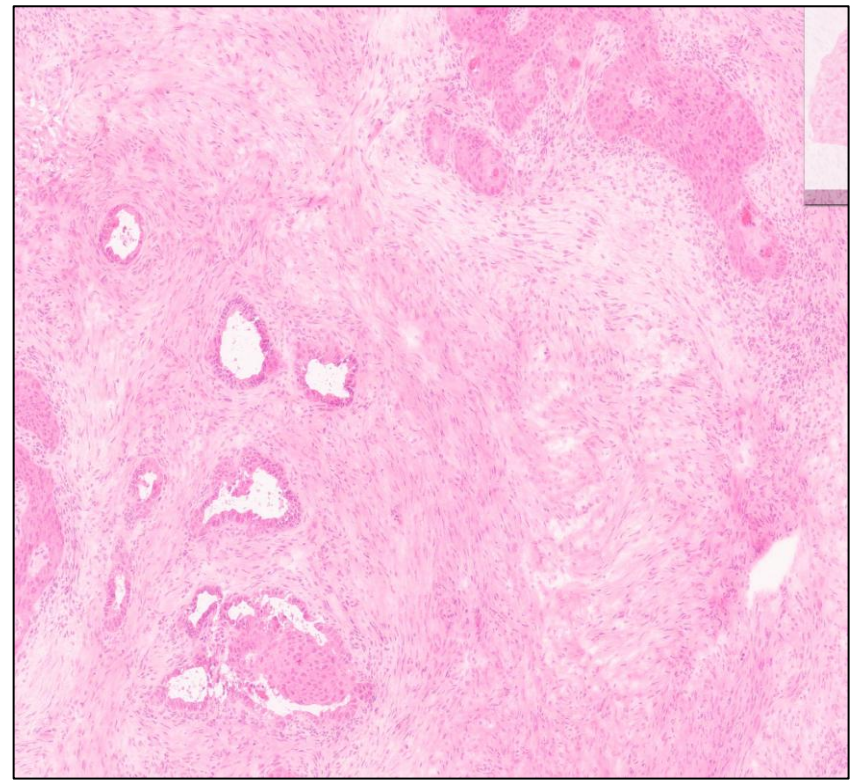

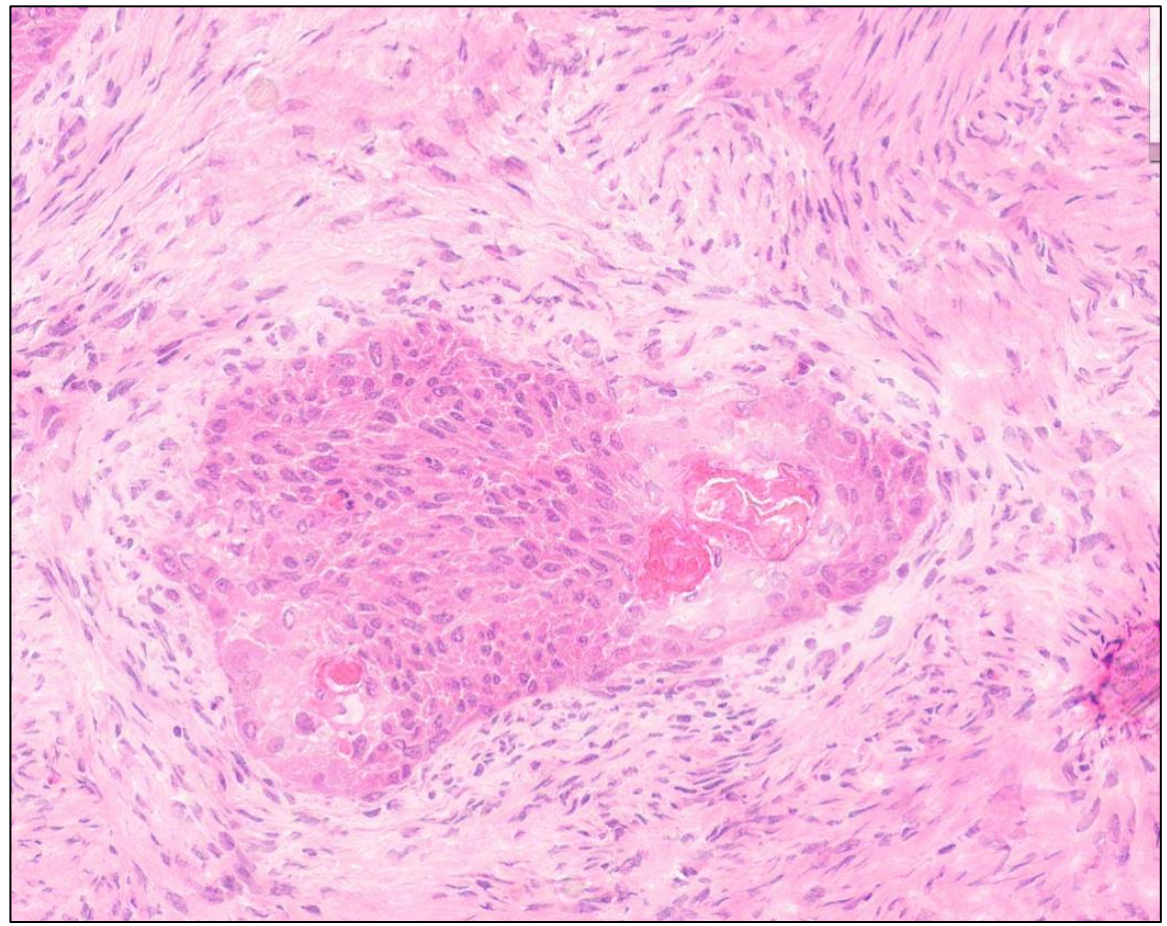

Paraffin sections

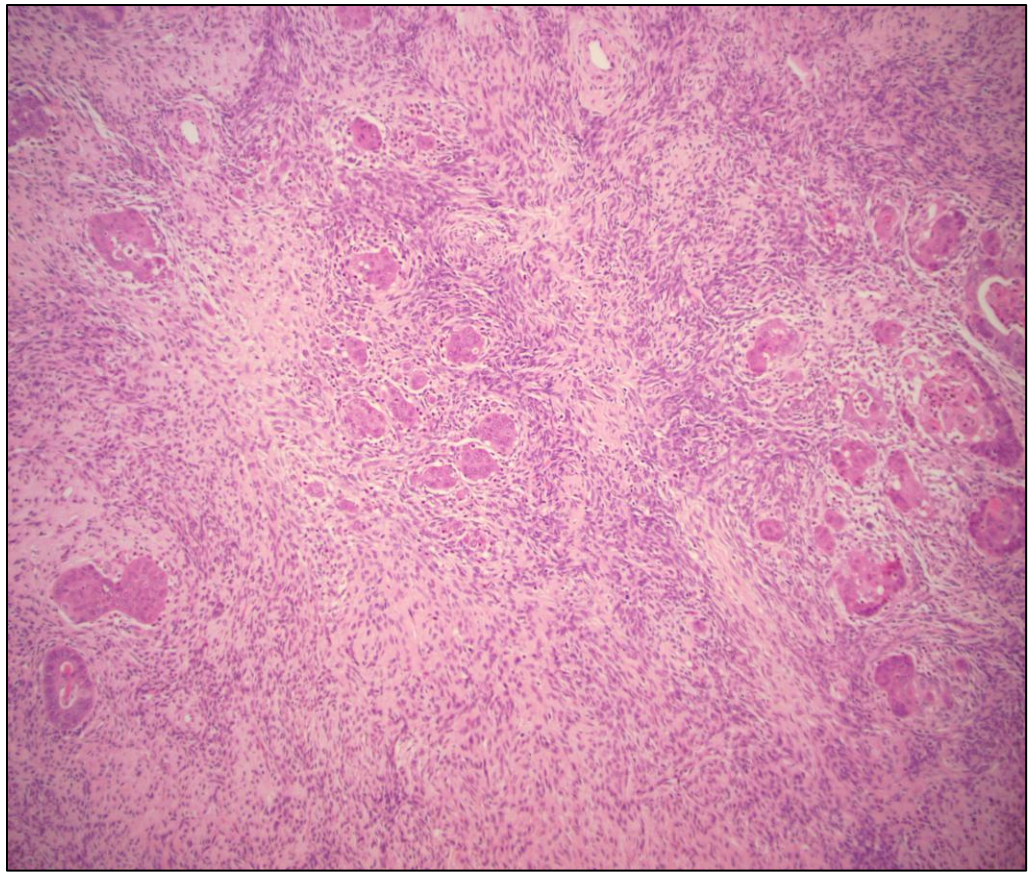

Squamous morula admixed with glandular structures (HE x10)

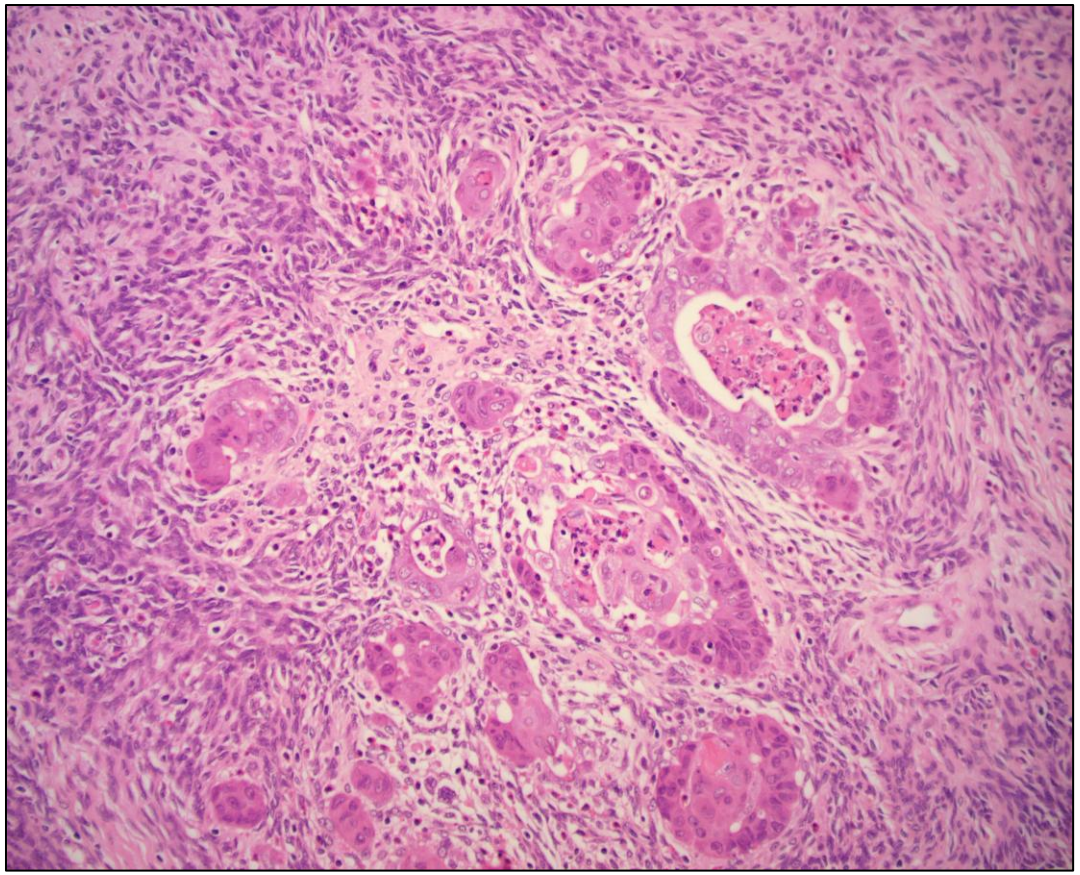

Squamous morula admixed with glandular structures (HE x20)

Paraffin sections

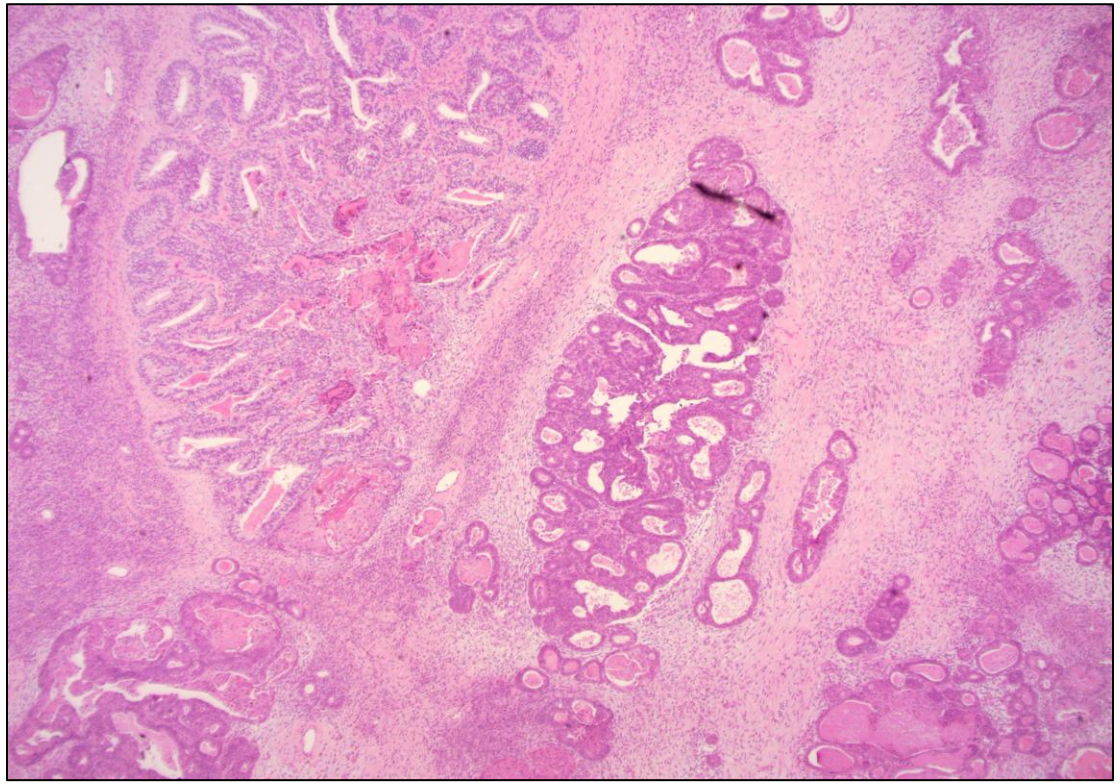

Glandular structures and squamous morula (HE X10)

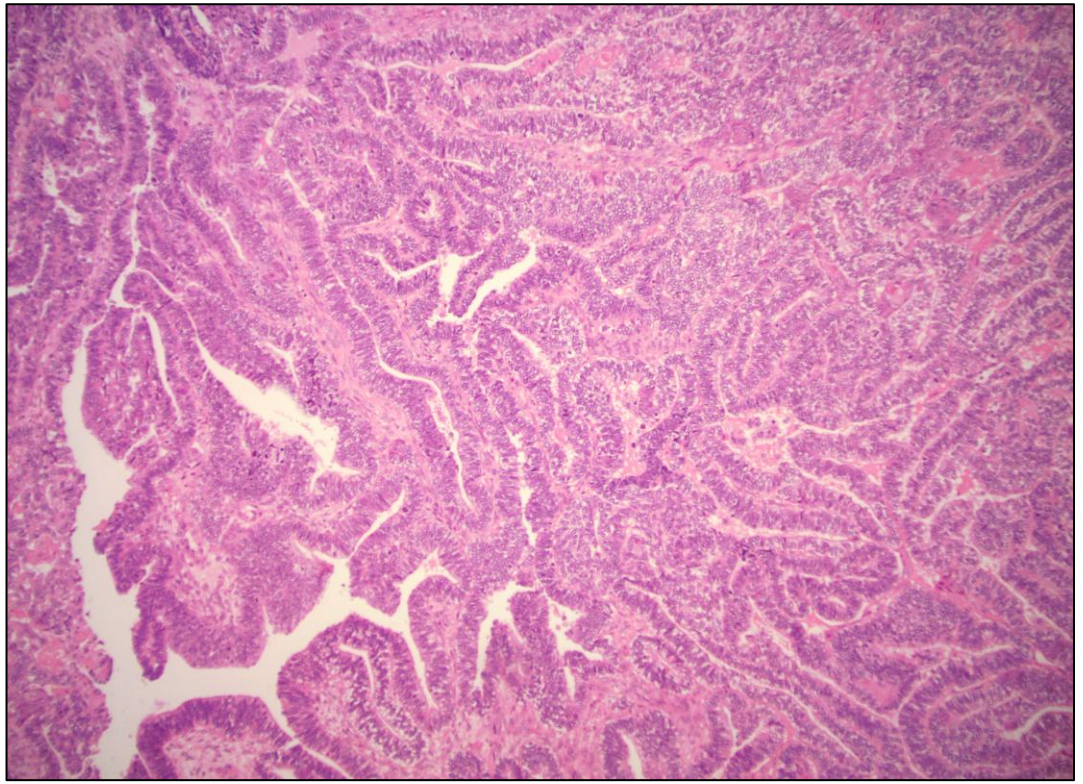

Purely glandular component(HE X20)

Immunohistochemistry

- CK7+,ER+, PR+, p53 wild type
- PTEN preserved, PAX2 lost
- Positive MLH1, PMS2, MSH2 and MSH6
- CDX2 + within squamous morula

Diagnosis

- Endometrioid adenocarcinoma , grade 2
- Capsule defect was present
- No endometriosis was seen
- Uterus, cervix, and contralateral fallopian tube and ovary: Clear
- Bilateral pelvic lymph nodes and para-caval lymph nodes: Clear of malignancy
- FIGO stage 1C1

Discussion

- Confident diagnosis of malignant (carcinoma)
- Confirmation of subtype: Recognising morphological features of endometrioid adenocarcinoma
- Primary gynaecological malignancy. Excluding metastasis (implication on management)
- Comment on endometriosis
- Capsule status (staging)
- Does the patient have an endometrial tumour? Is it primary ovarian?

Case 2

- Clinical history:

Female 42 years

60mm ovarian mass, C/S solid with yellowish areas.

FROZEN SECTION

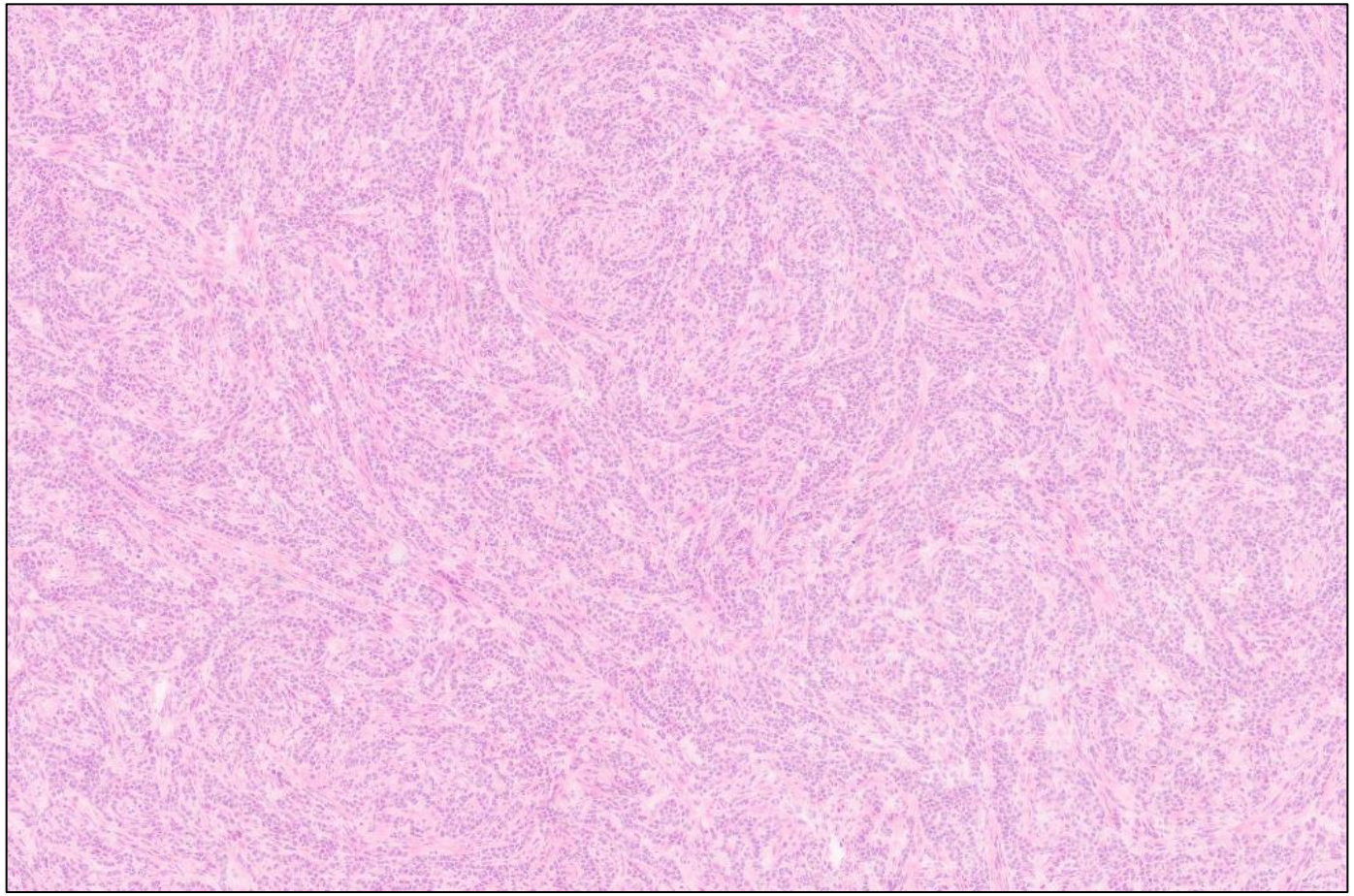

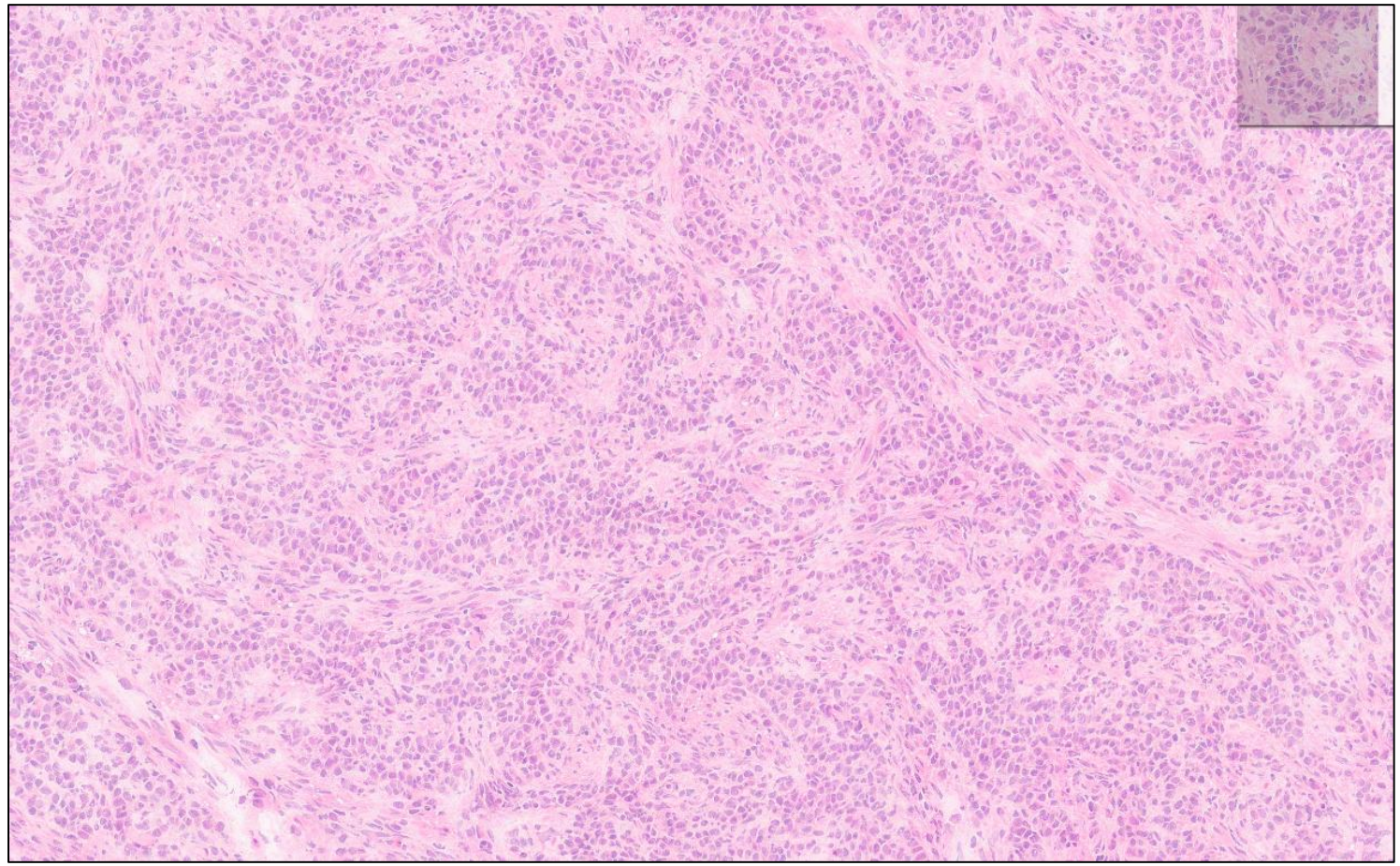

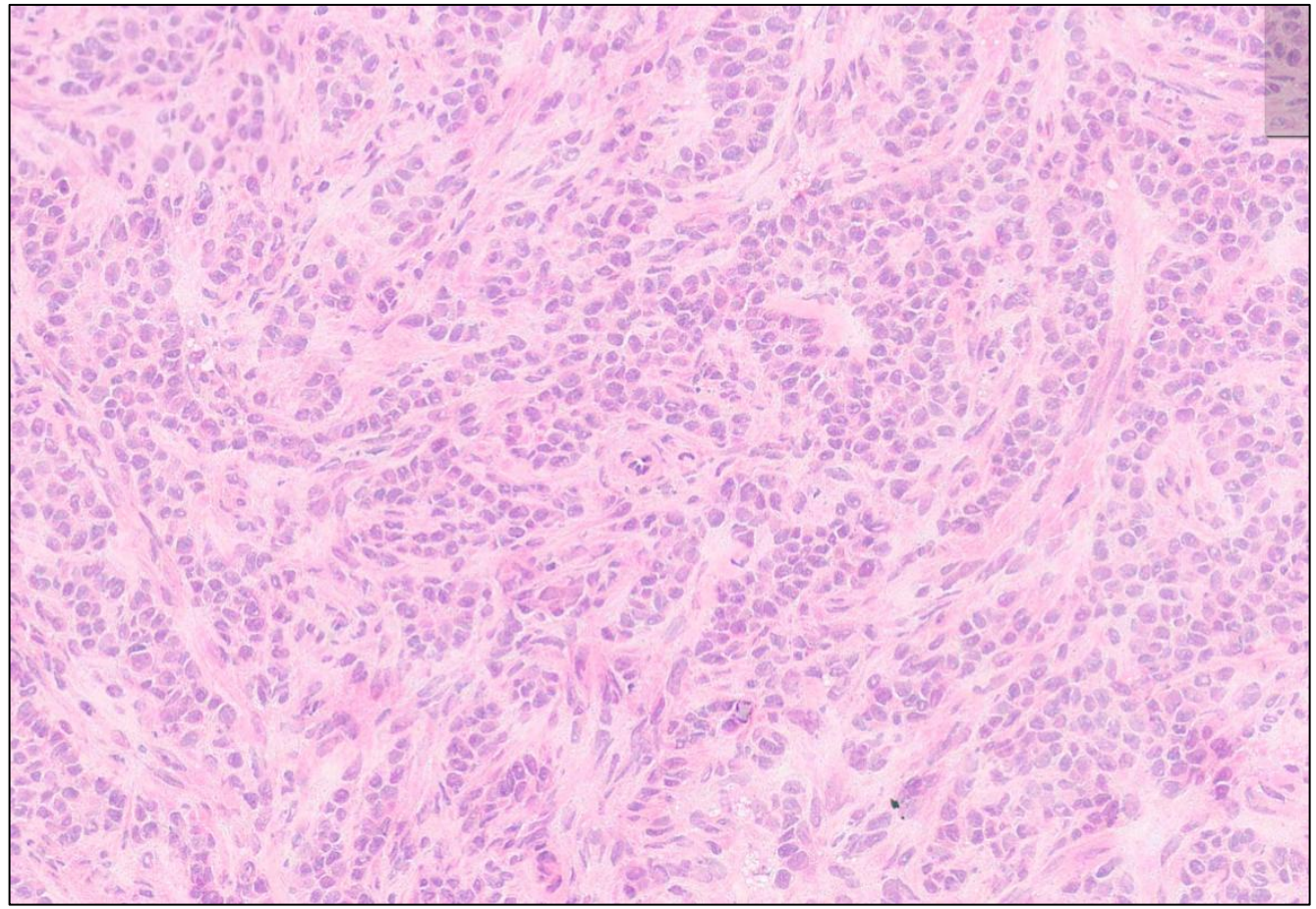

Paraffin Sections

Trabecular pattern
(HE x10)

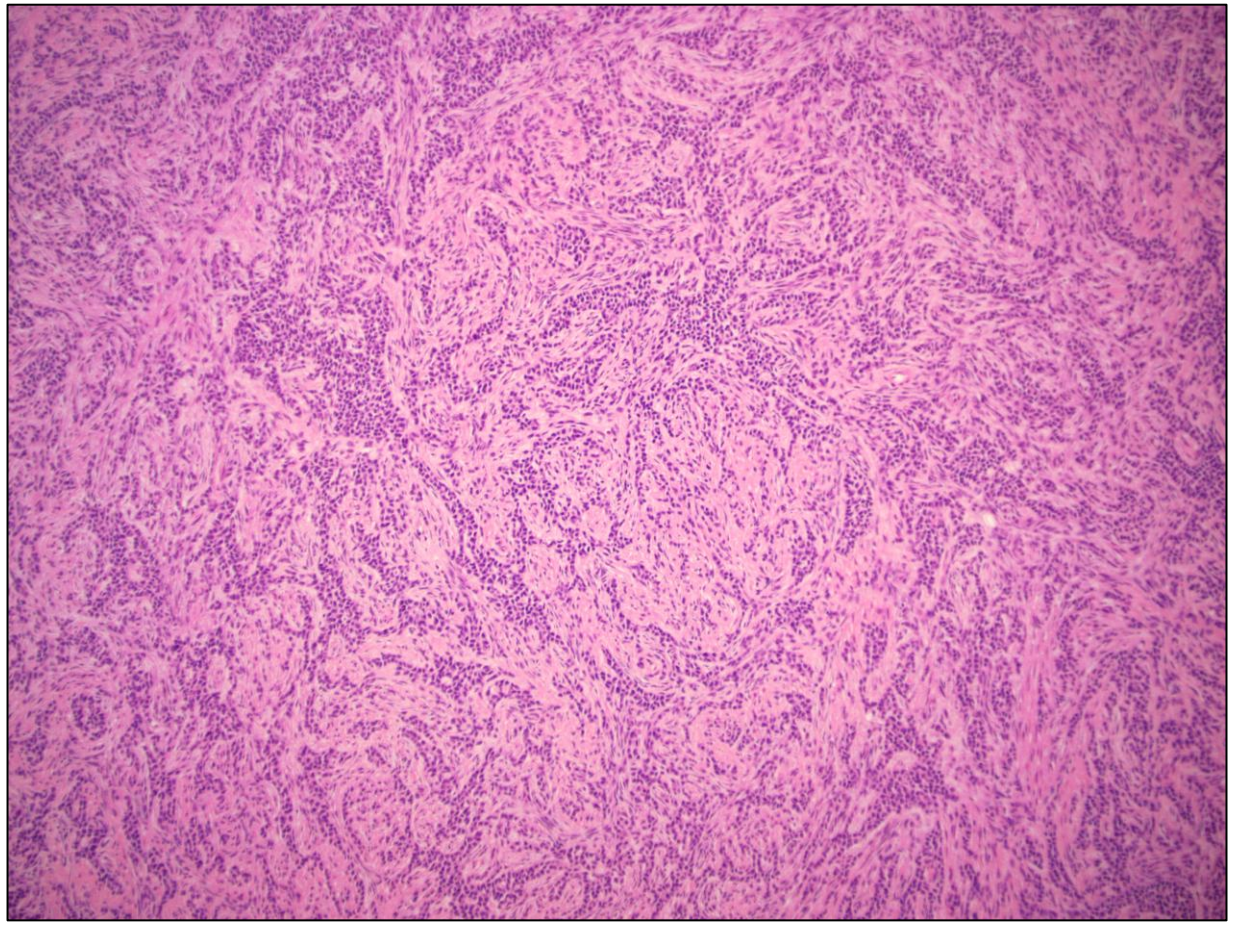

High N/C ratio
with nuclear grooves
(HE, X40)

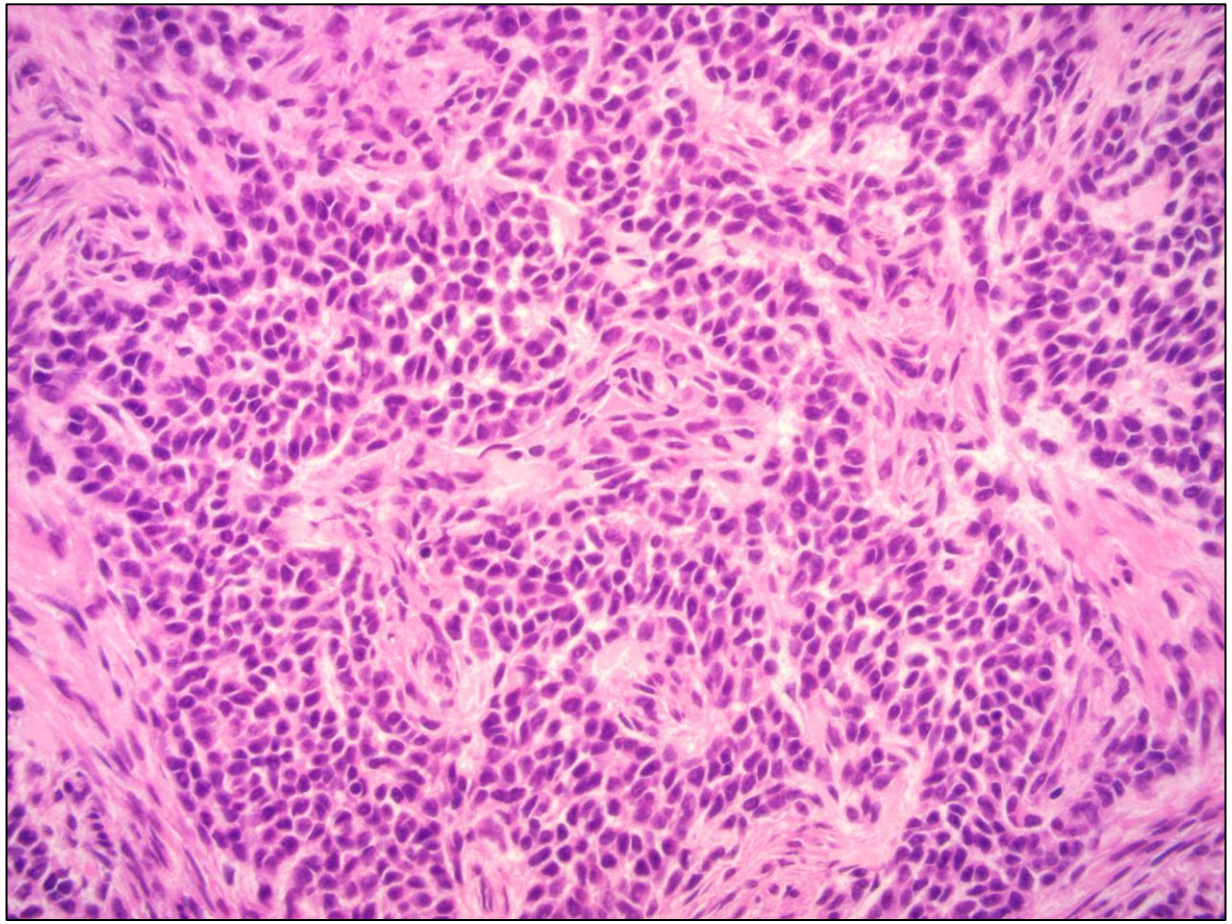

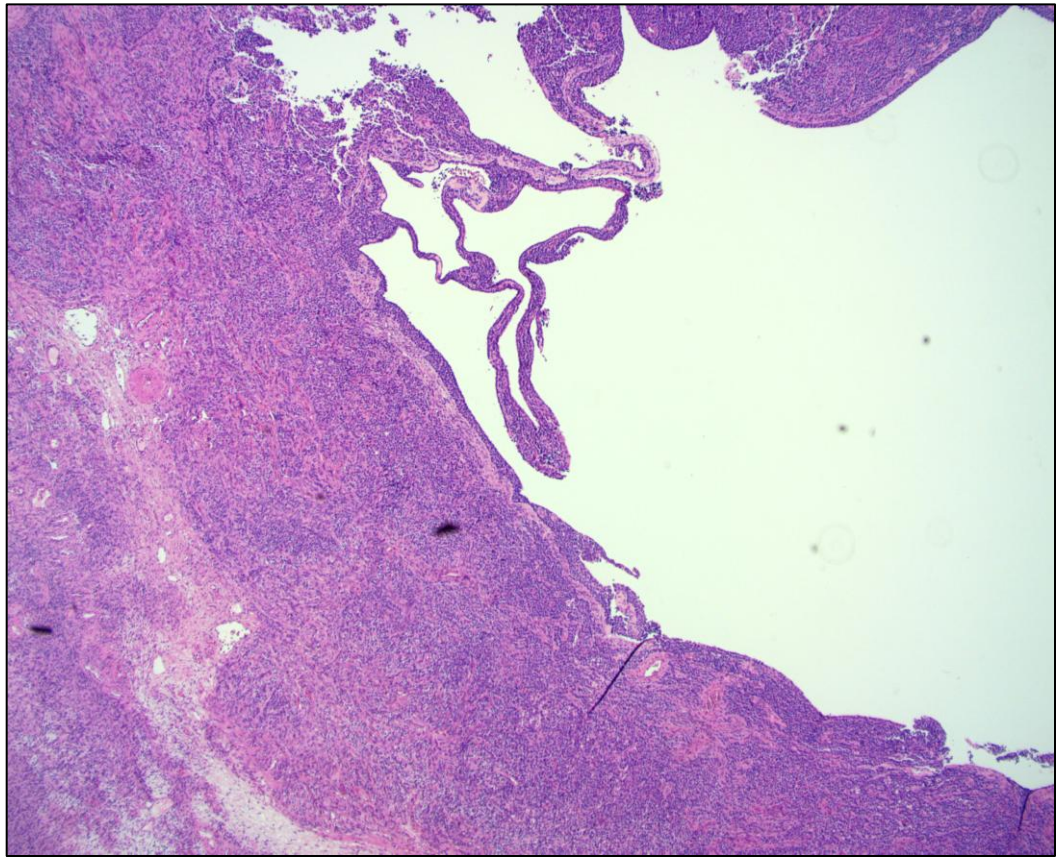

Diffuse pattern and cystic change, HE (X4)

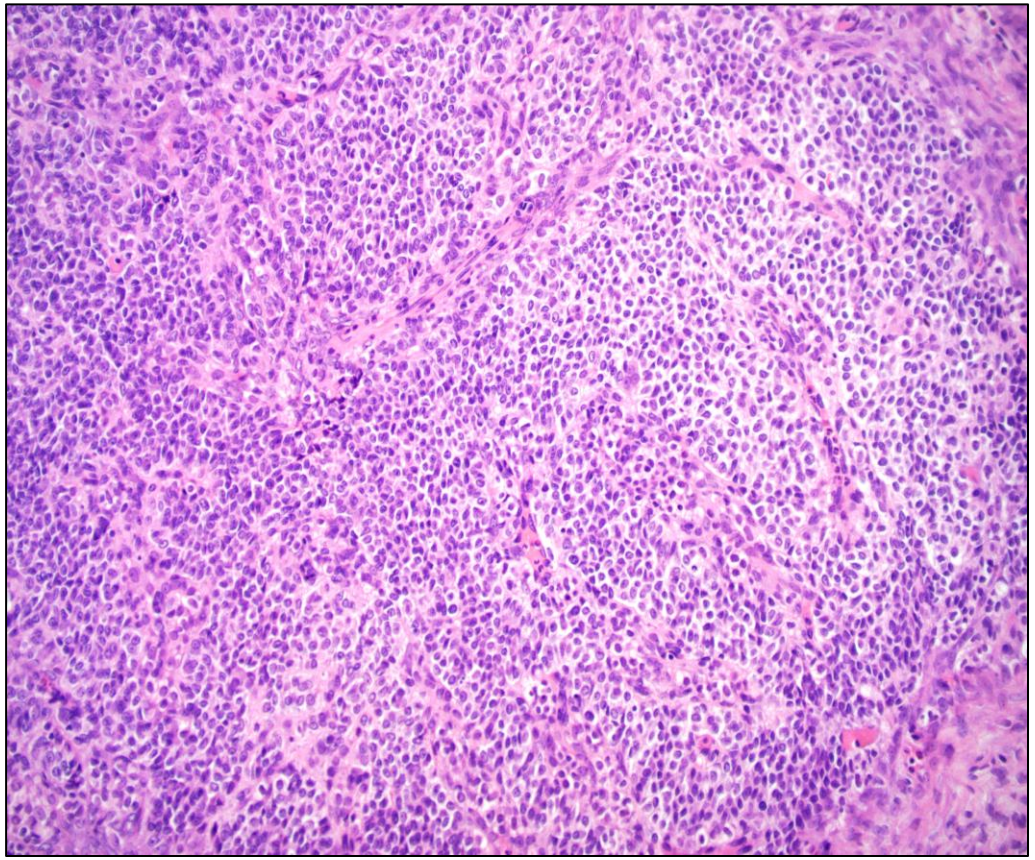

Diffuse pattern , HE (X20)

Reticulin stain, X20

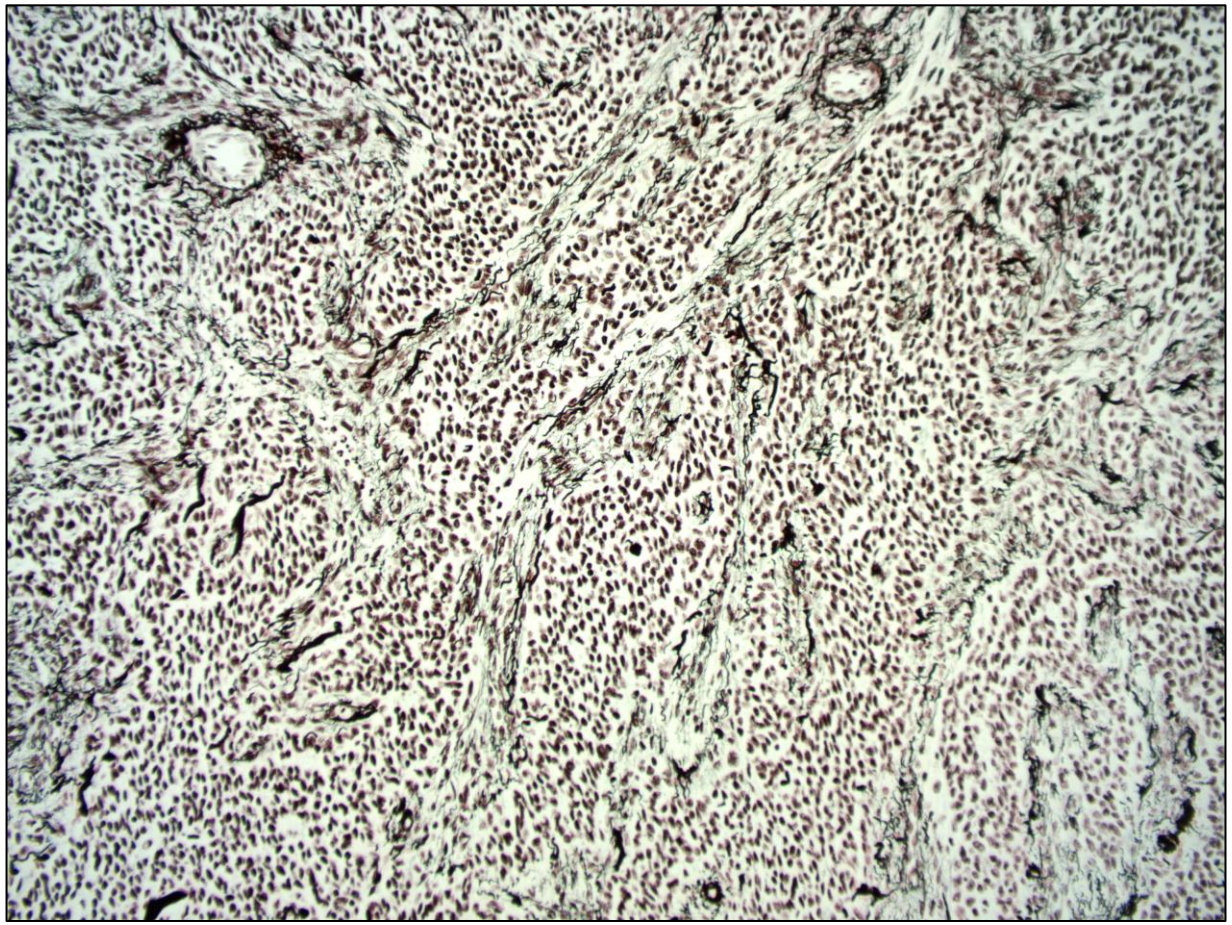

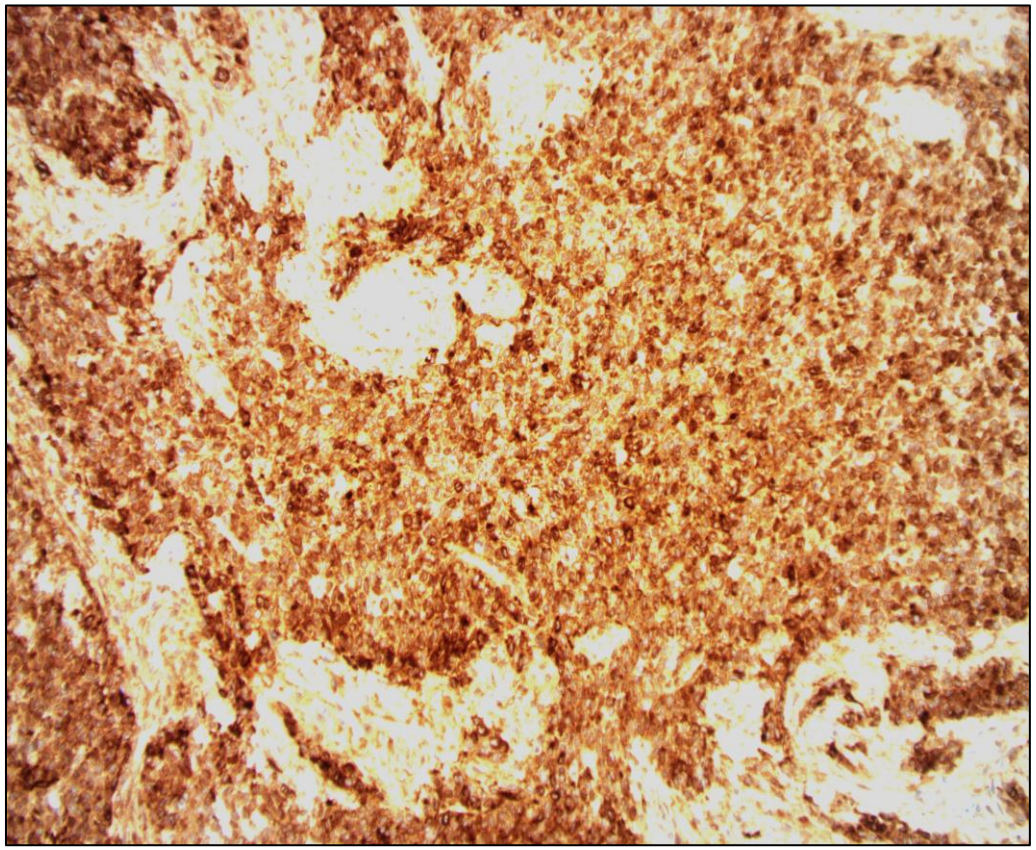

Inhibin X20

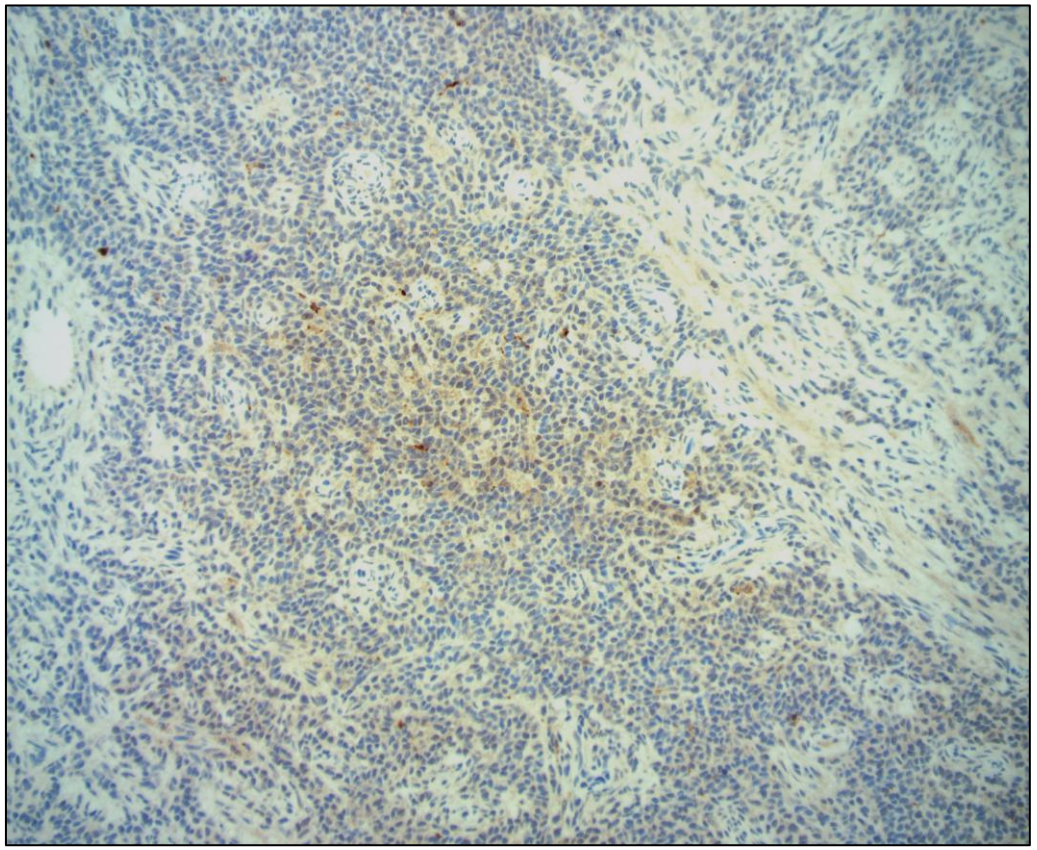

Calretinin X20

Diagnosis

- Adult granulosa cell tumour (cells arranged in cords and trabeculae with areas of diffuse growth and cystic change)
- Intact capsule
- Fallopian tube: Intact. No malignancy
- Uterus, cervix, contralateral fallopian tube and ovary: Clear
- Omentum and peritoneal biopsies: Clear
- FIGO stage IA

Discussion

- Confident diagnosis of sex cord stromal tumour
- Recognising features of adult granulosa cell tumour, AGCT (trabecular pattern of growth and cell morphology)
- Diffuse pattern of growth can be challenging. Differential diagnosis includes cellular , mitotically active fibroma.
- Capsule status
- Macroscopic appearance can be very helpful in reaching a confident diagnosis of AGCT
- ? Did the patient present any symptoms related to oestrogenic or androgenic manifestations
- Molecular test: FOXL2 mutation

- Possible association with endometrial hyperplasia and endometrioid adenocarcinoma. Thorough examination of uterus macroscopically and sampling of endometrium.



Architectural patterns in AGCT

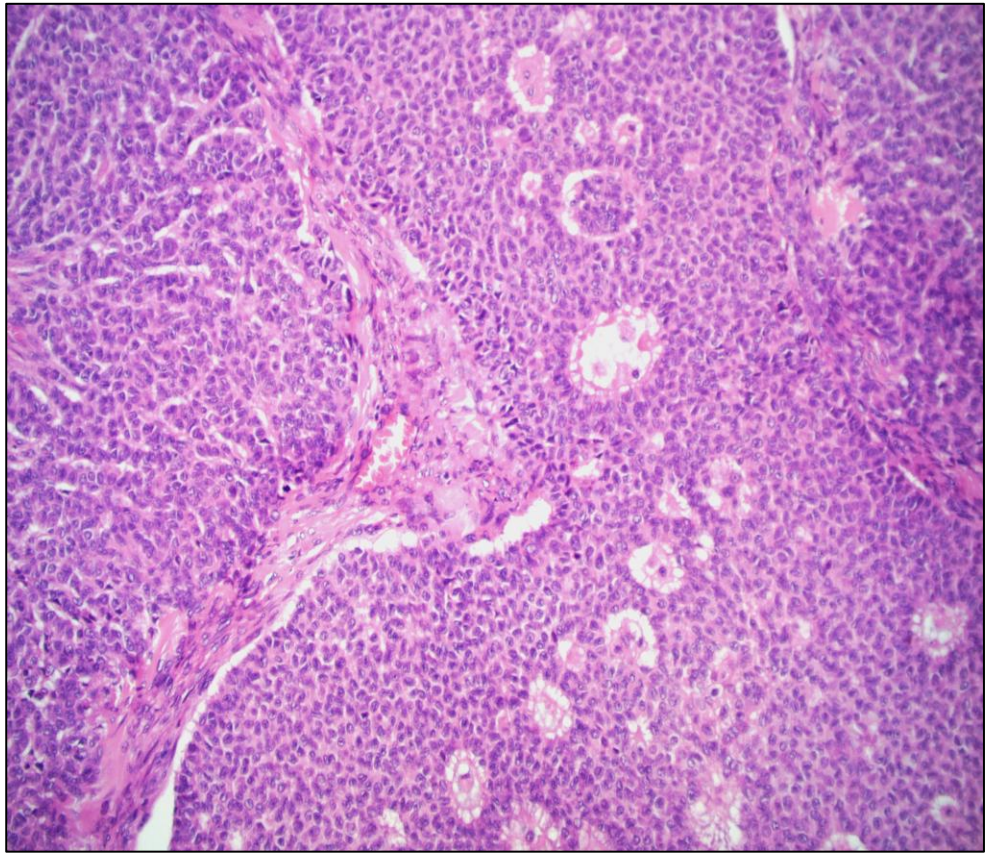

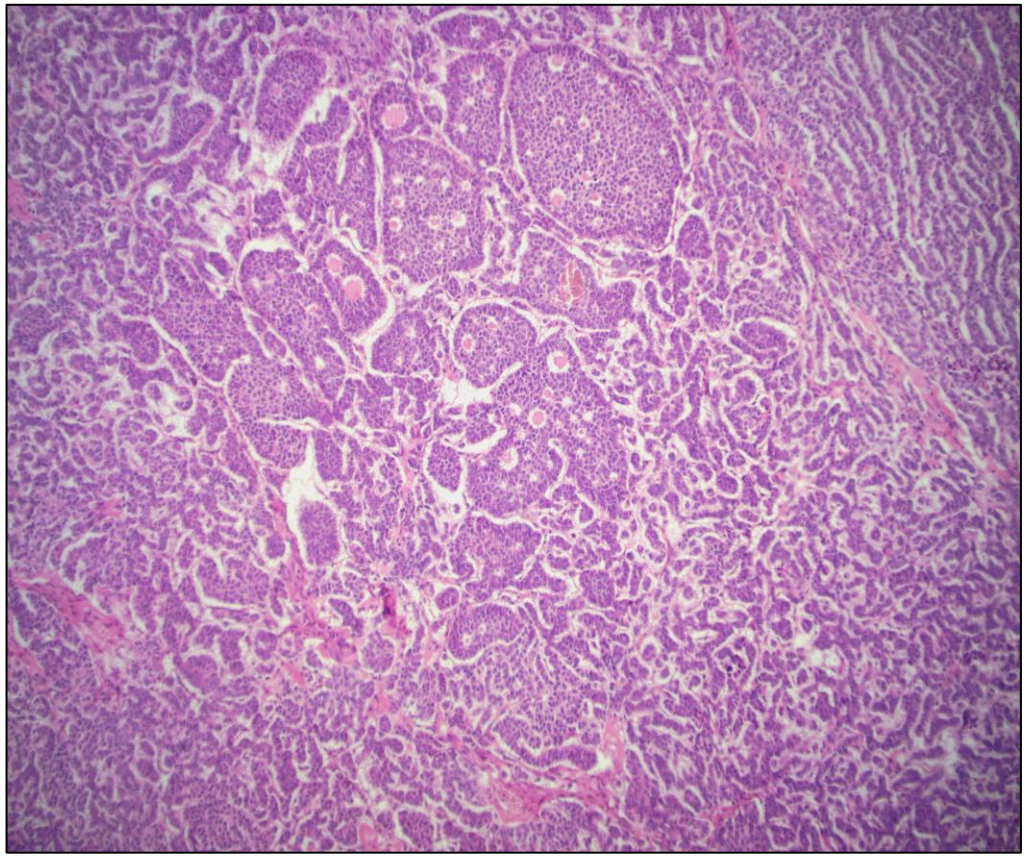

Case 3

Female 52 years

180mm solid cystic ovarian mass.

Frozen section

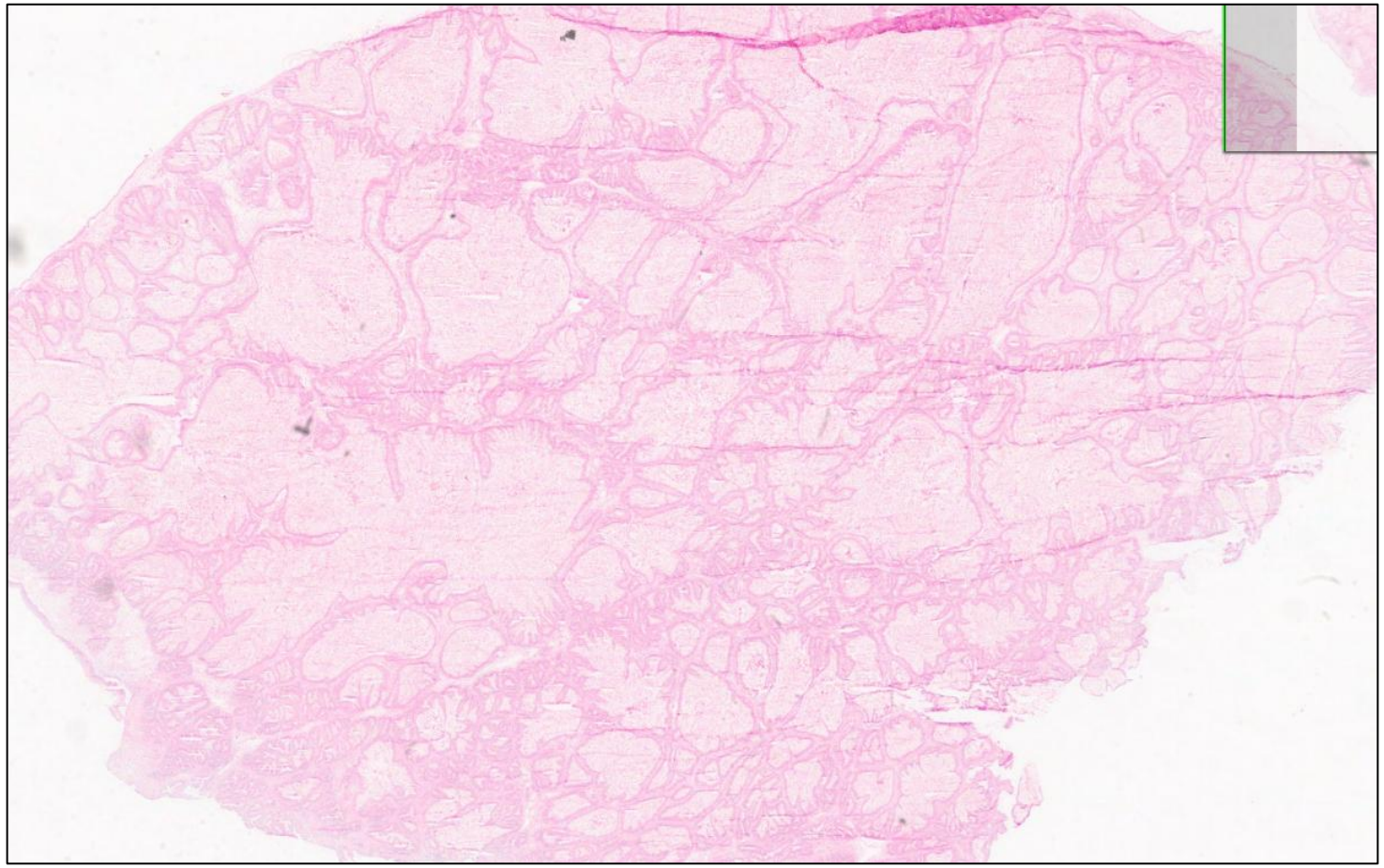

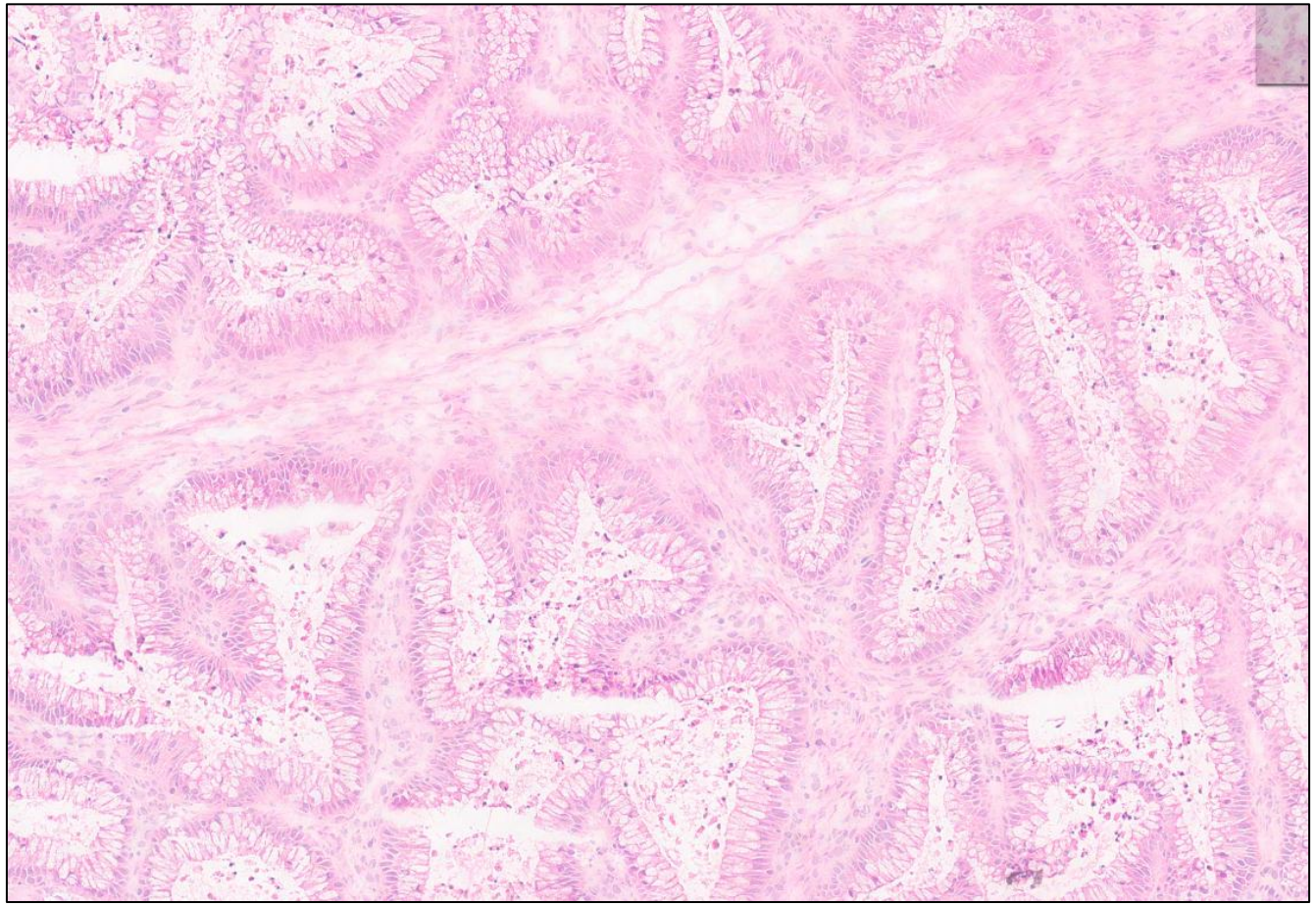

Paraffin sections

Cysts lined by gastrointestinal type epithelium showing variable degrees of stratification and tufting with mild cytological atypia.

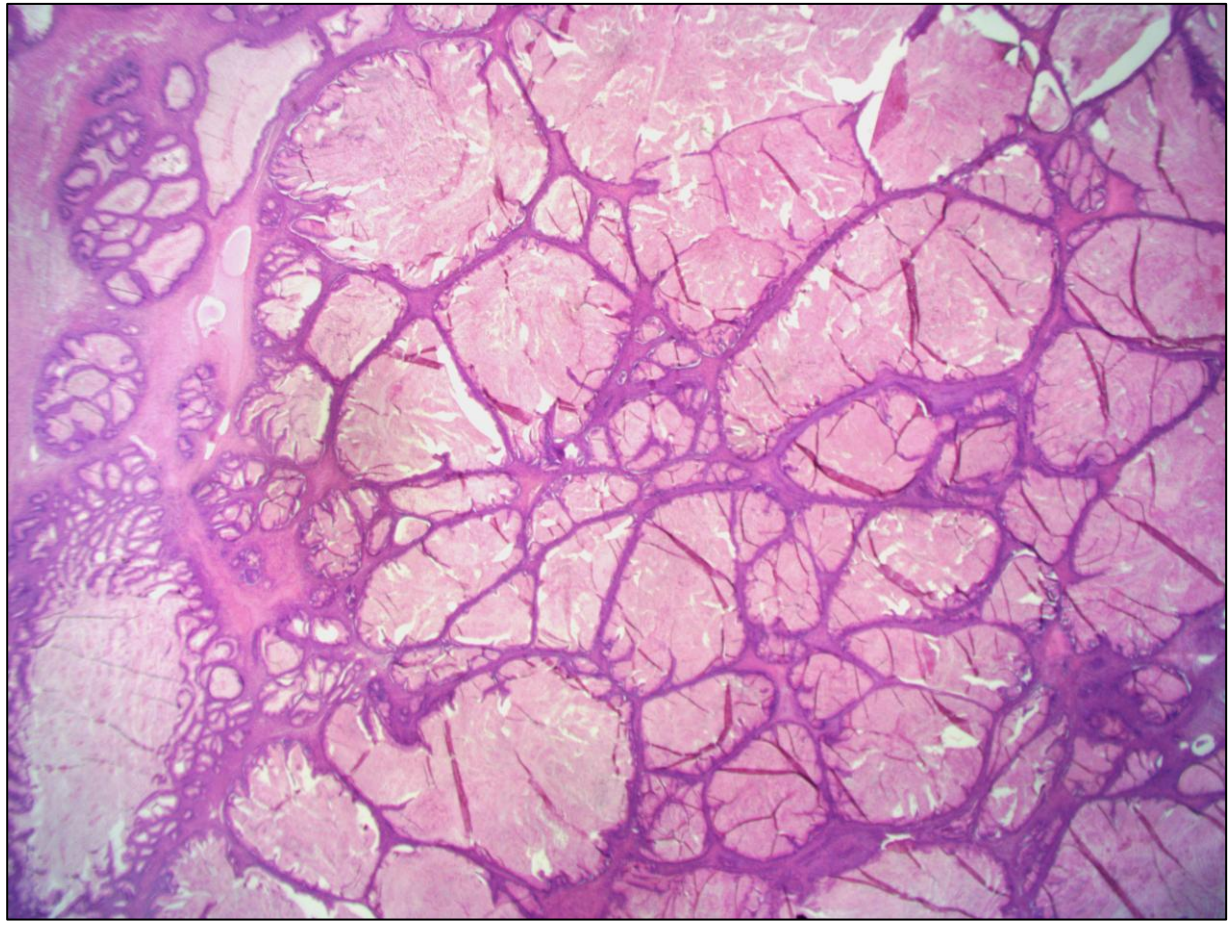

HE X1.25

HE X10

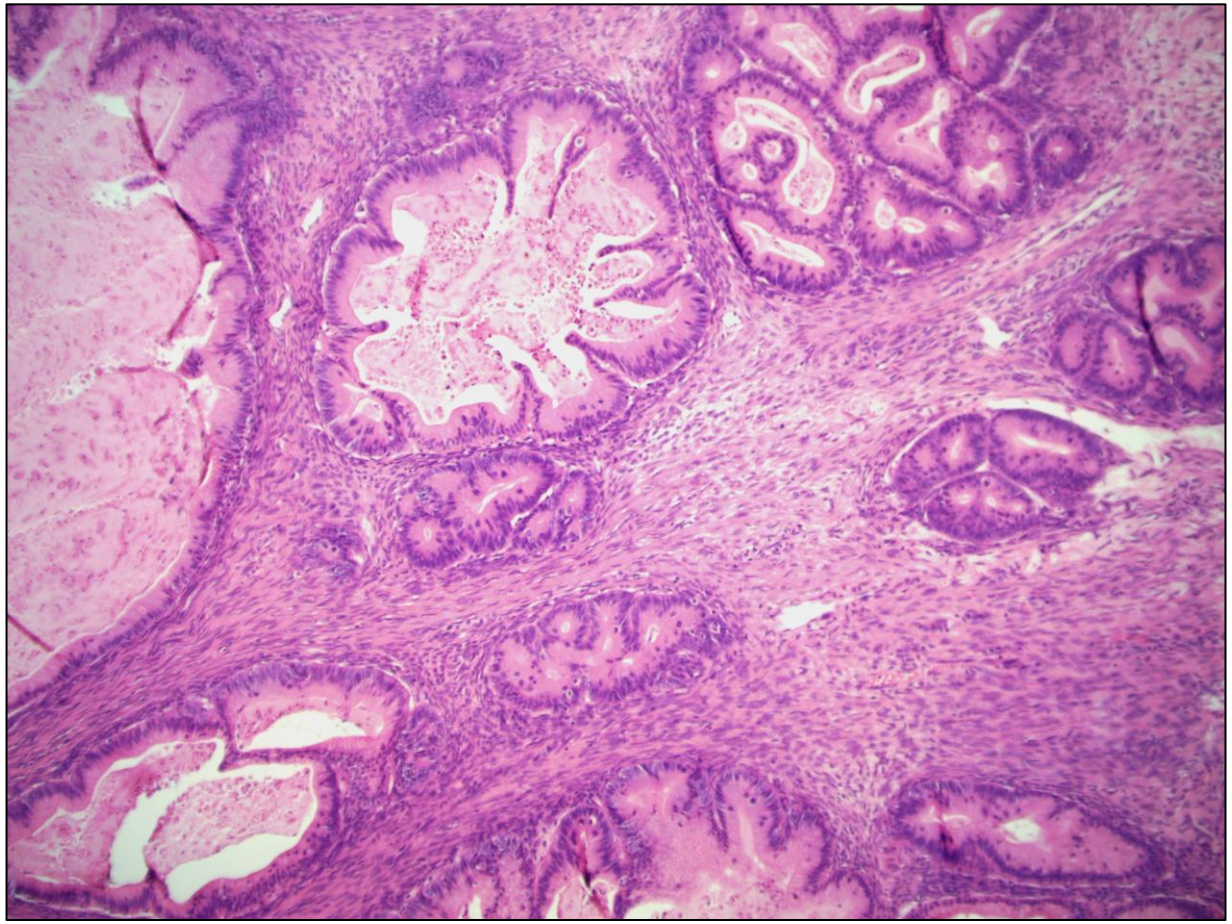

HE X40

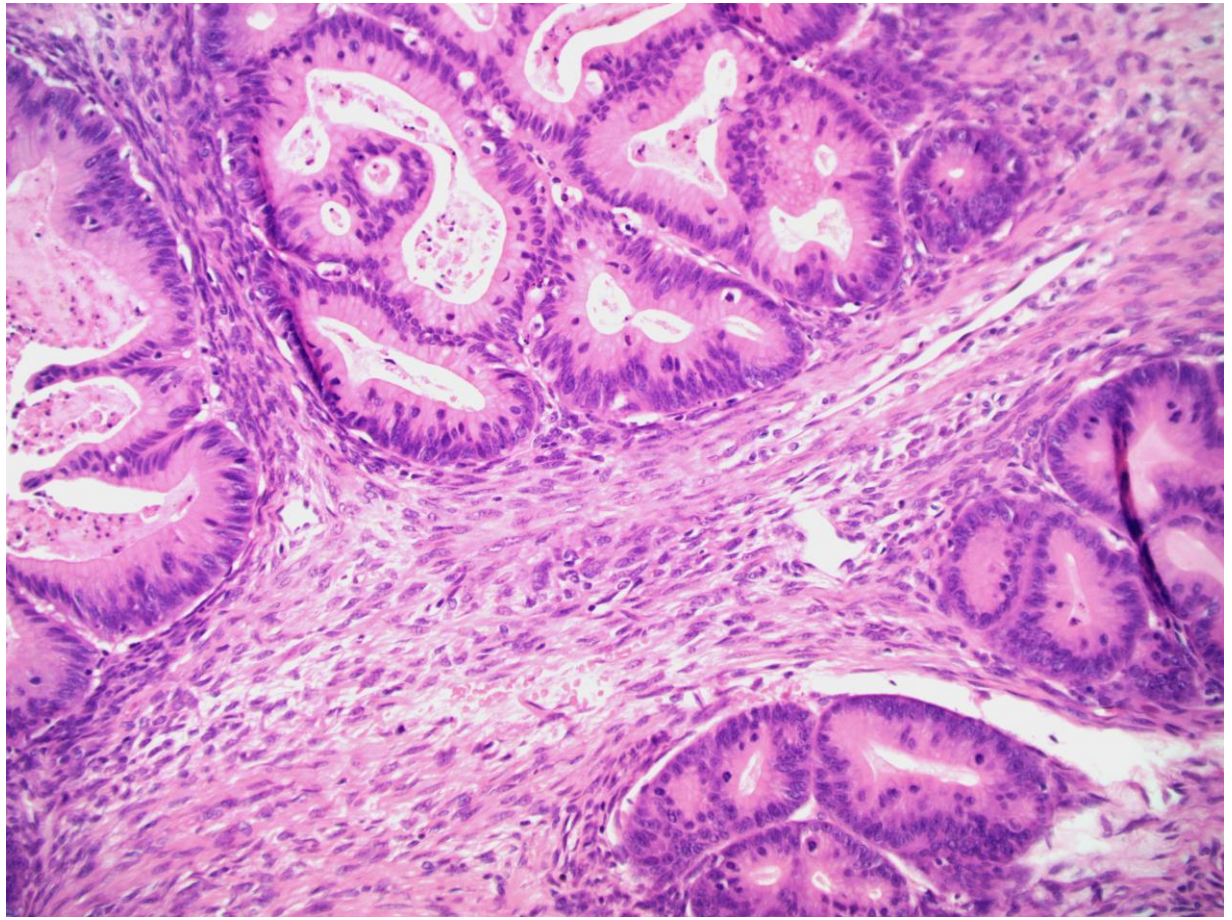

Immunohistochemistry

- CK7+, CK20+, CDX2+. Weak patchy positivity for Pax8
- ER-, PR-, p16-
- SMAD4+, SATB2-

Diagnosis

- Borderline mucinous tumour
- Capsule intact
- Uterus, cervix, contralateral fallopian tube and ovary: Clear
- Omental biopsy and peritoneal biopsies: Clear
- In our centre we use the terminology “Borderline at least” in some of the cases
- FIGO stage 1A

Discussion

- Adequate sampling (2 blocks/cm)
- Look for invasion: Two patterns: Expansile and stromal destructive.
- Immunohistochemistry on paraffin section is necessary to support the diagnosis of ovarian borderline mucinous tumour as metastasis from GI and pancreato-biliary tract can morphologically mimic borderline mucinous tumour
- Clinical pathological correlation is required
- Is the tumour bilateral?
- Any history of extra-gynaecological malignancy ?

Thank you