The British Association of Gynaecological Pathologists

Lecturer – Dr Baljeet Kaur

- Dr Baljeet Kaur is a consultant Gynae-pathologist and leads the regional pathology services for Trophoblastic disease unit and Malignant Ovarian Germ Cell Tumour service (MOGCT) based at Charing Cross Hospital .
- She has been an invited speaker at various national and international meetings and has published widely on Trophoblastic diseases.
- She is co-author of GTD chapter in WHO, WHO Classification of Tumours 2020 and ICCR Gestational trophoblastic neoplasia dataset.
- She is the key pathologist in ISSTD (International Society for the Study of Trophoblastic Diseases), EOTTD (European Organisation for Treatment of Trophoblastic Disease) and European network for rare adult solid Cancer (EURACAN).
- Baljeet has a large national and international referral practice and receives over 600 consult cases for her expert opinion.



The British Association of Gynaecological Pathologists

Everyday Dilemmas in Gynaecological Pathology

Title : **Endometrial case based discussion**

Dr. Baljeet Kaur

Consultant Histopathologist

North West London Pathology

Imperial College NHS Trusts, London, UK

Date :07/03/25

The British Association of Gynaecological Pathologists

Speaker disclosures

- ❑ I have no financial conflicts of interest to disclose

Case History

- 62 years female
- Ovarian cytoreductive surgery
- Previous endometrial biopsy : grade-1 endometrioid adenocarcinoma
- Imaging: large right ovarian mass - clinical concern of two tumours (one endometrial and one ovarian).
- Surgery : Uterus, cervix, fallopian tube and ovary (specimen A), rectosigmoid serosa (specimen B), sigmoid mesentery (specimen C), epiploic (specimen D), transverse colon (specimen E), transverse mesentery (specimen F), omentum (specimen G), lesser omentum (specimen H), small bowel mesentery (specimen J), caecum (specimen K), para- aortic lymph node (specimen L) and right hemicolectomy (specimen M).

Macroscopic description

Uterus, cervix, fallopian tube and ovary measured 140 x 75 x50 mm and weigh 562 g.

Left ovary had a maximum dimension of 20 mm and showed several surface deposits. The left fallopian tube appeared normal.

The right ovary was 90 mm in maximum dimension and the right tube was not externally identified due to adhesions of peritoneum and omentum. Cut surface of the right ovary appeared abnormal with multiple cystic and solid tumour nodules on the surface.

The uterus showed a tumour involving the entire cavity extending close to the surface with multiple surface deposits on the uterine serosa. Paracervical tumour nodularity with adherent fatty tissue stuck to the posterior surface of the parametrium was noted.



Courtesy :Dr. Eleanor Jaynes (University Hospital Southampton)

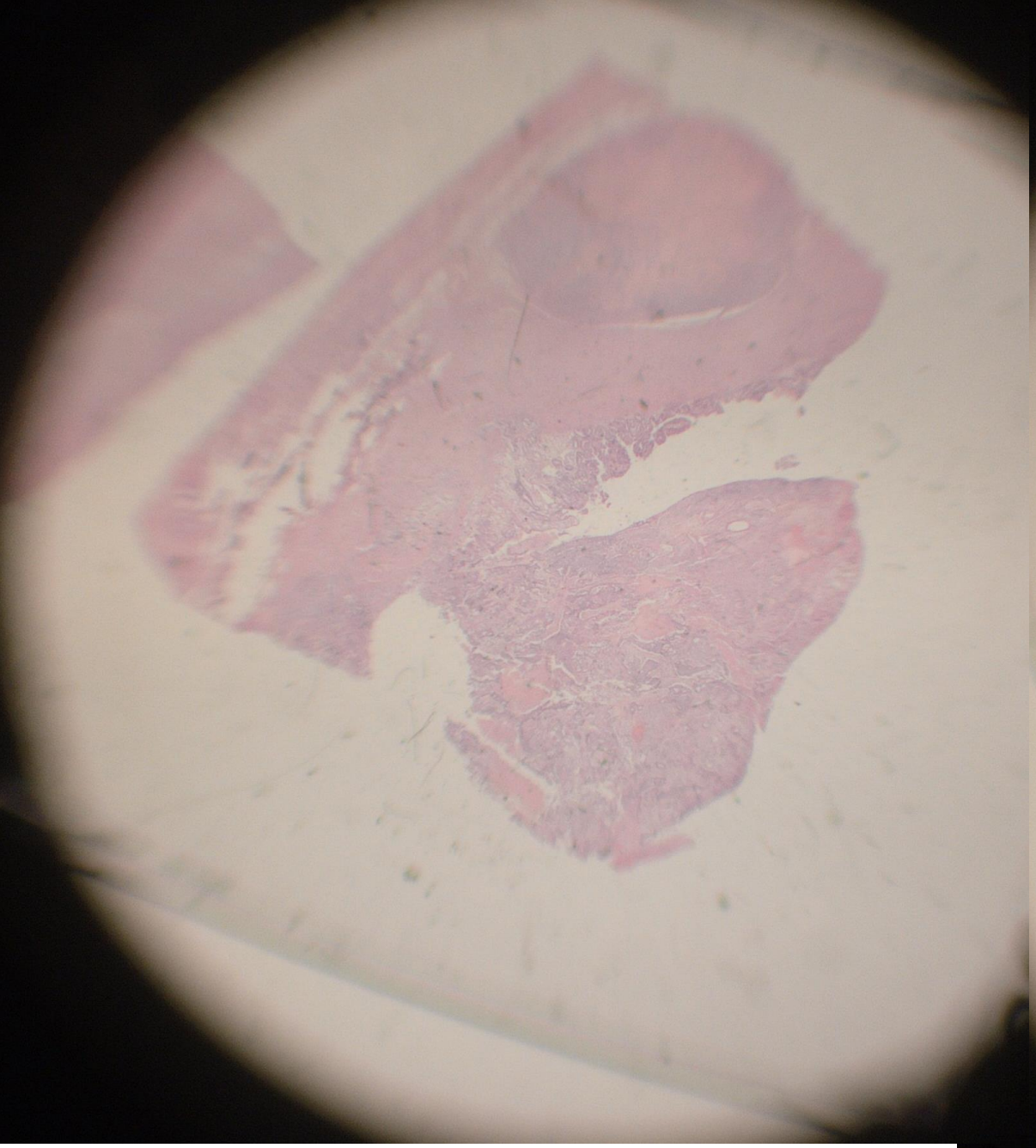
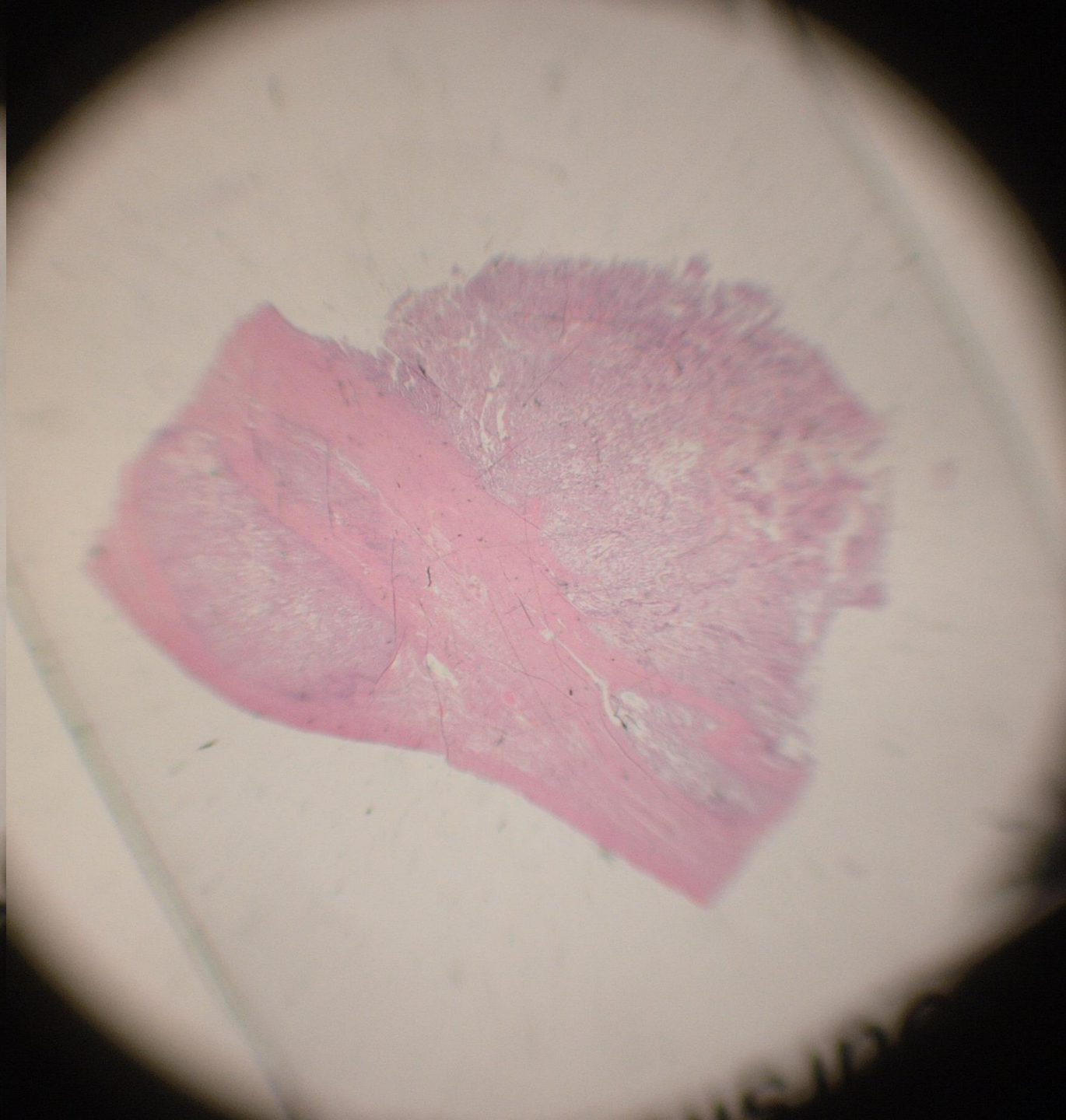

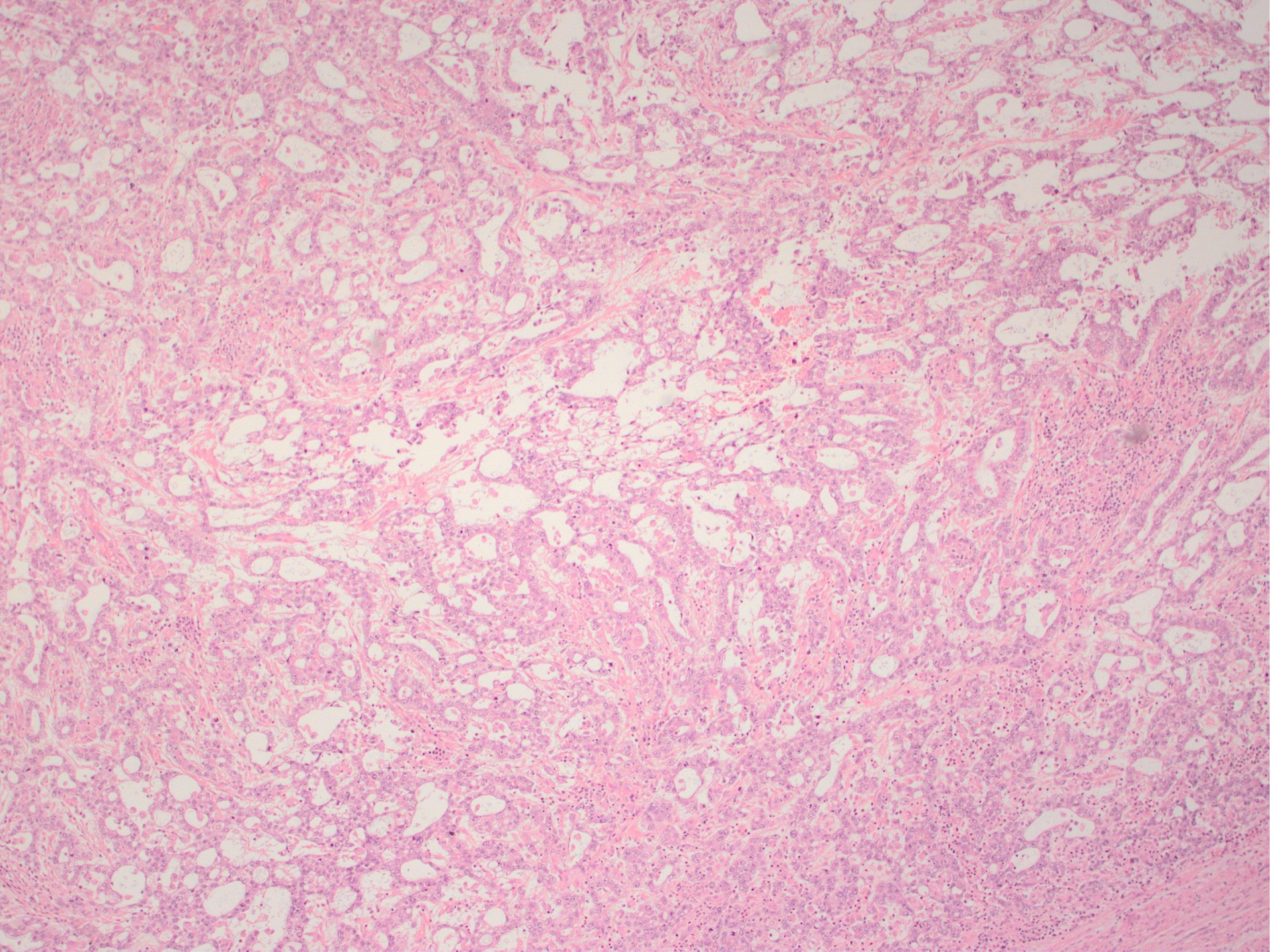

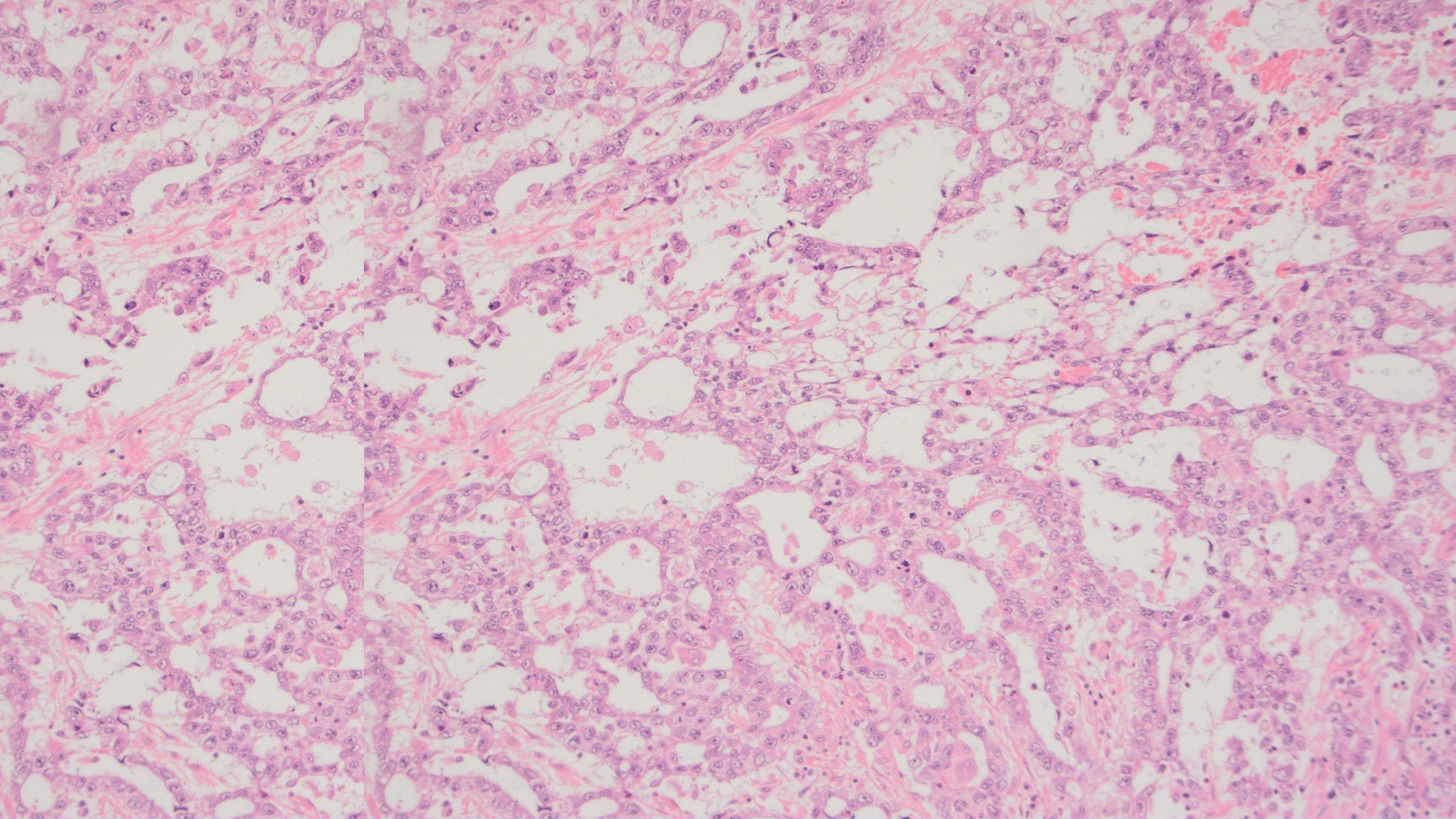

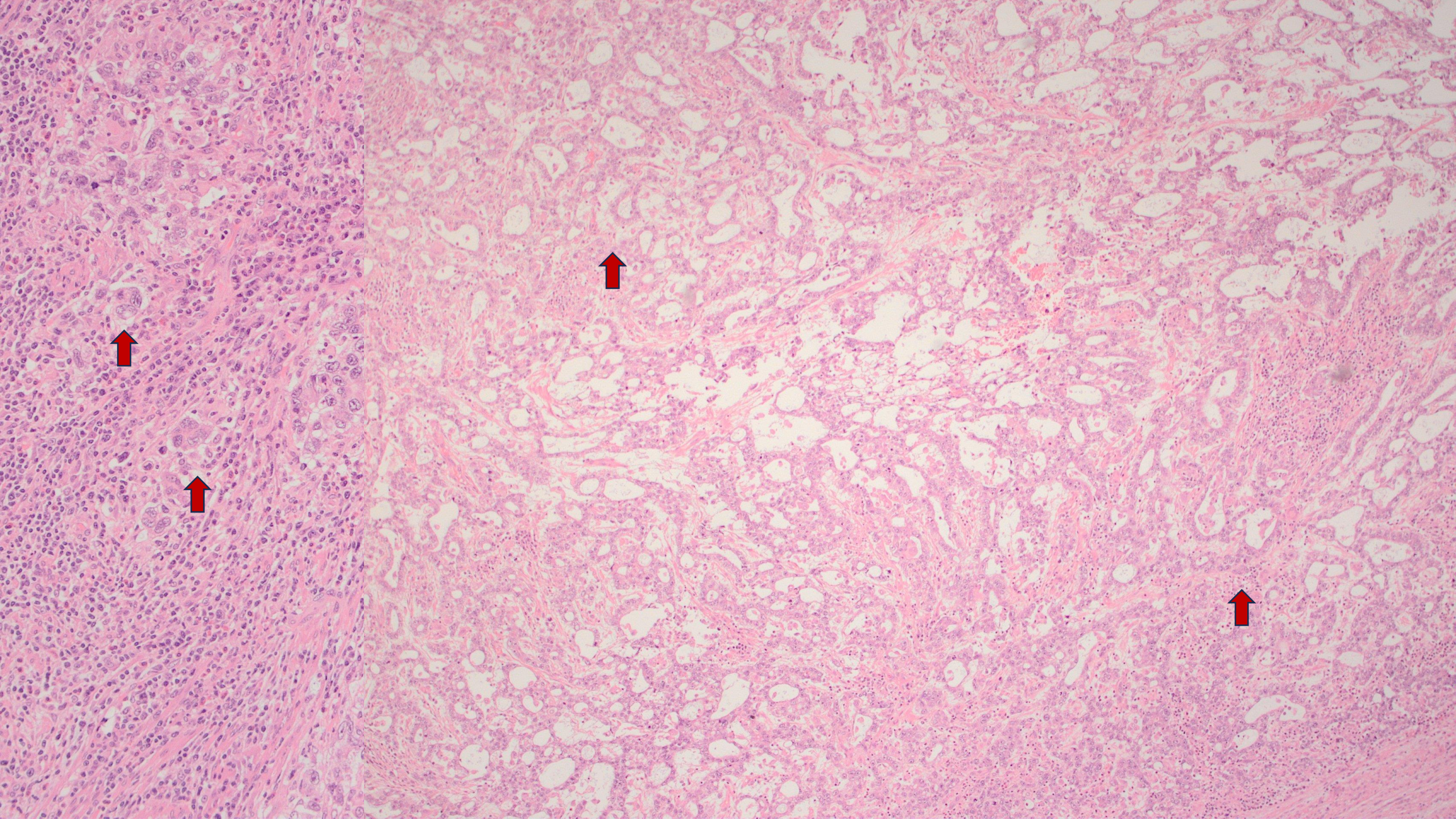

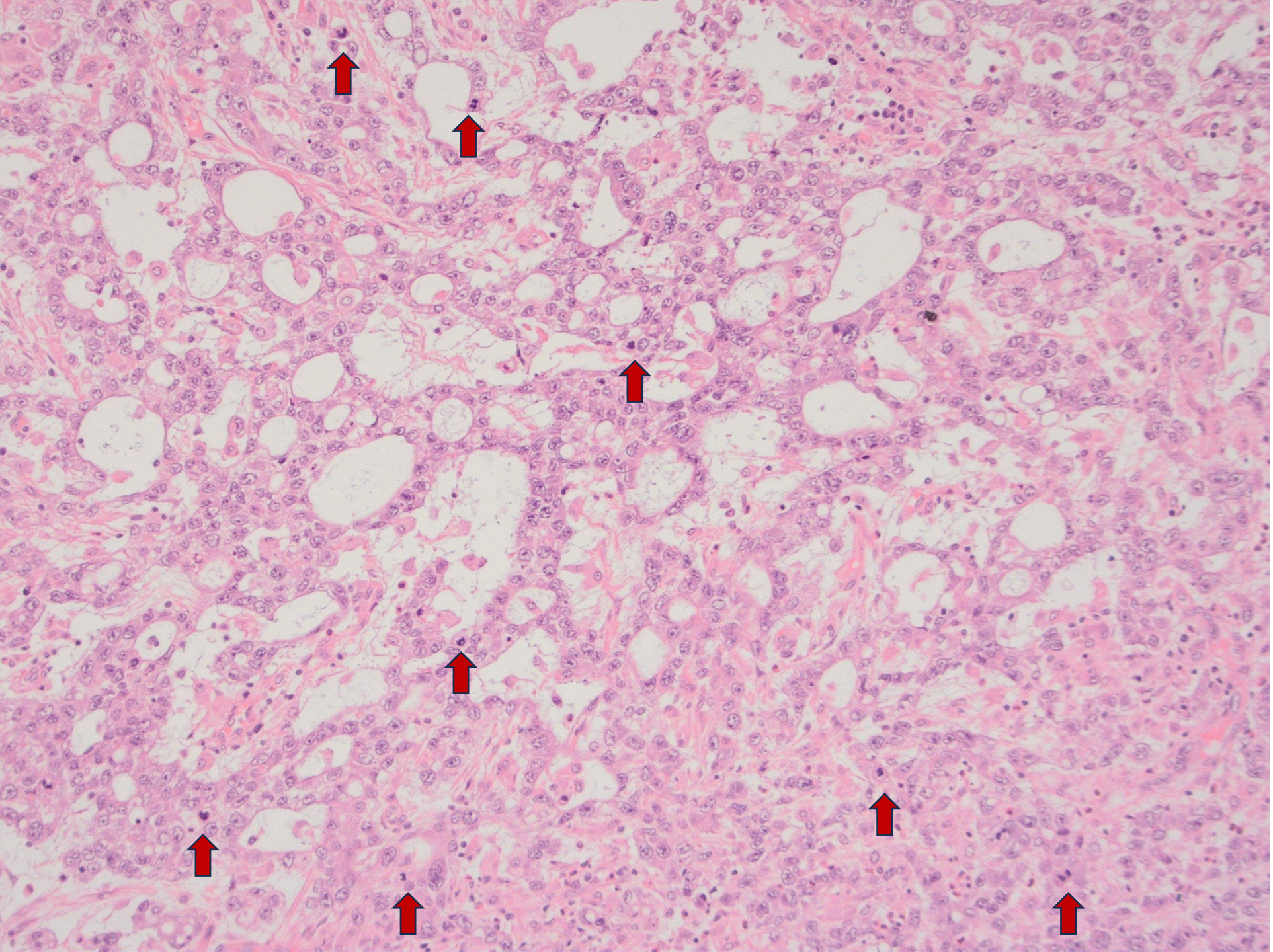

Surface Nodules

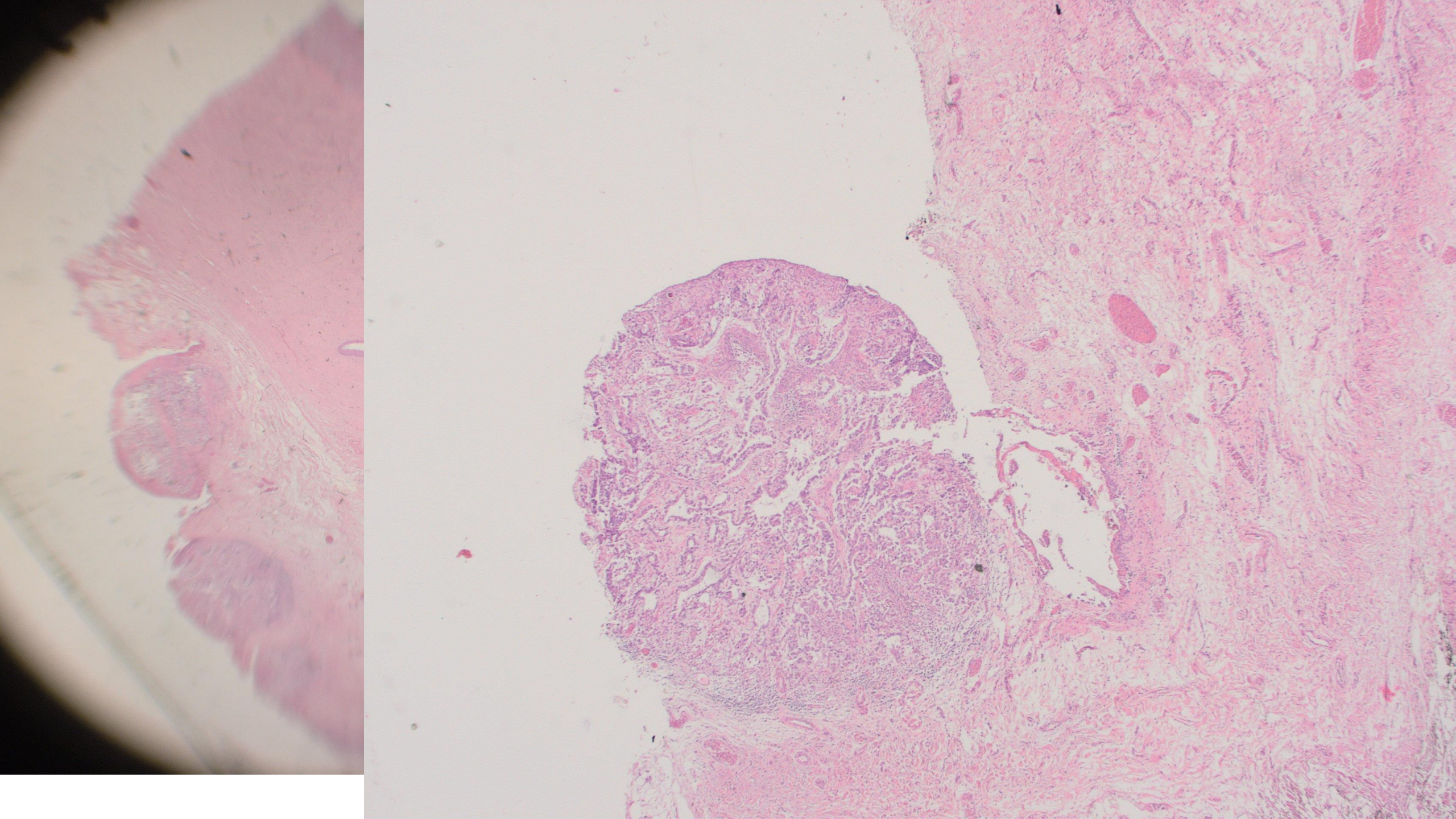

Right Ovary



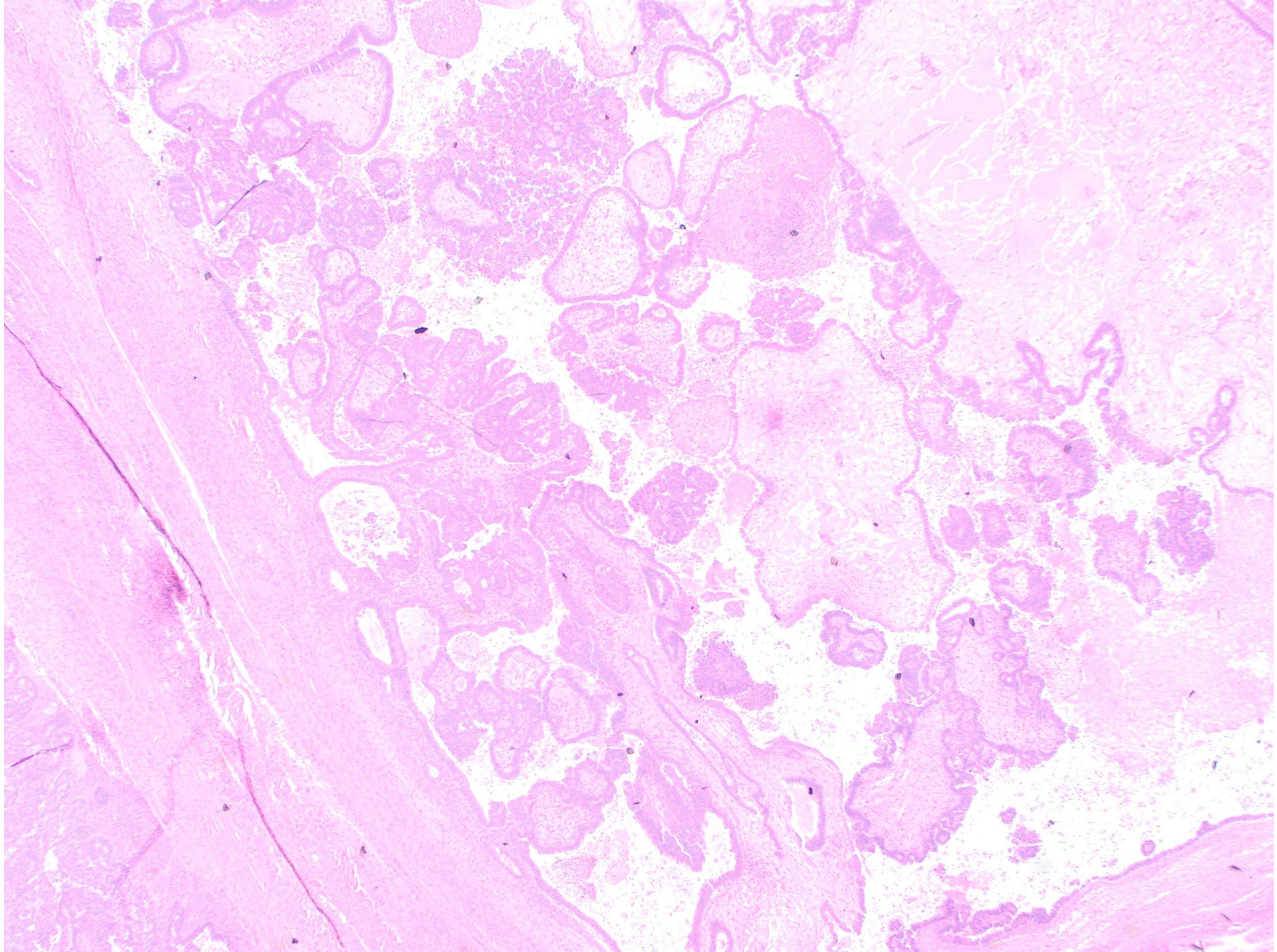

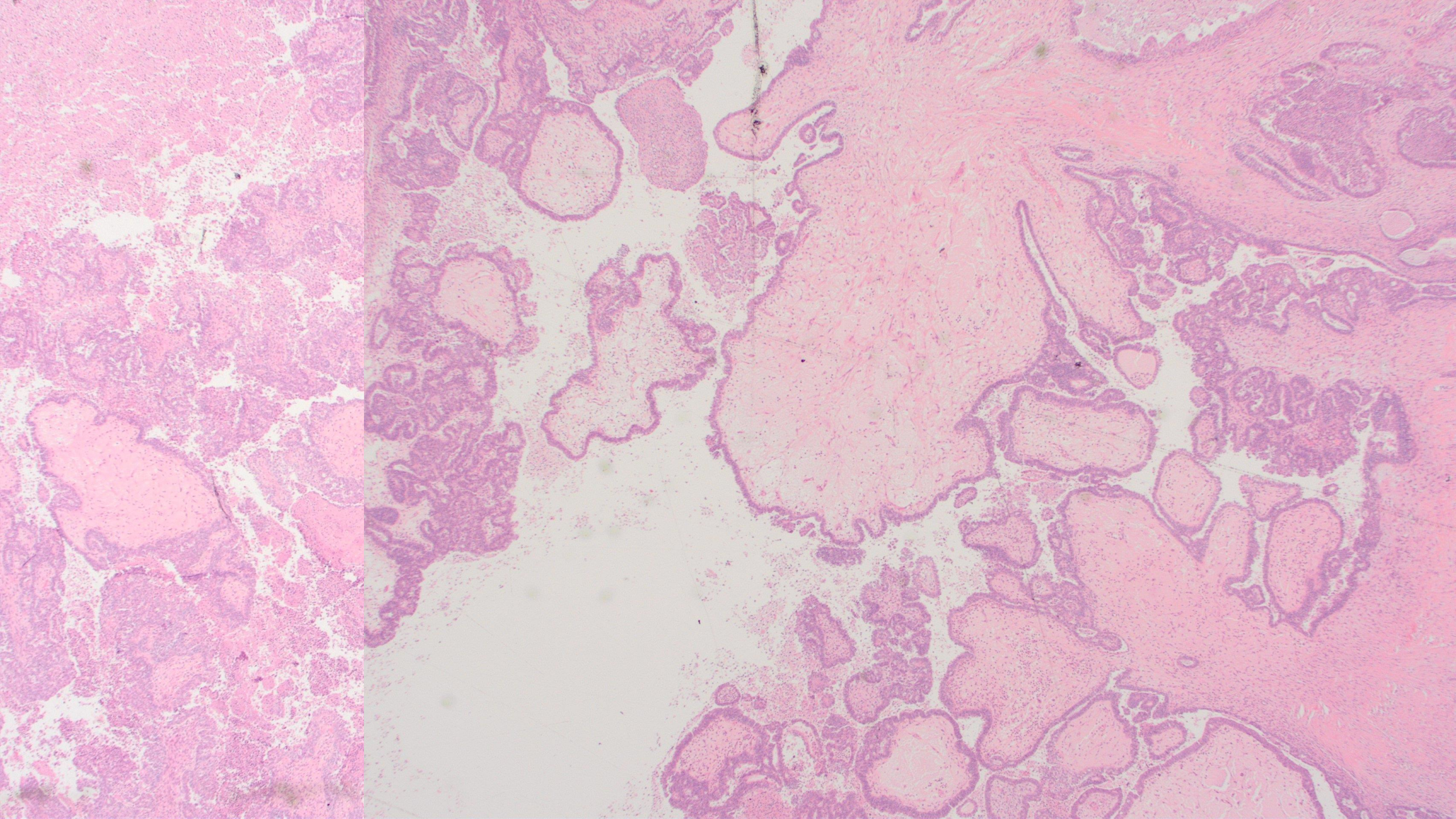

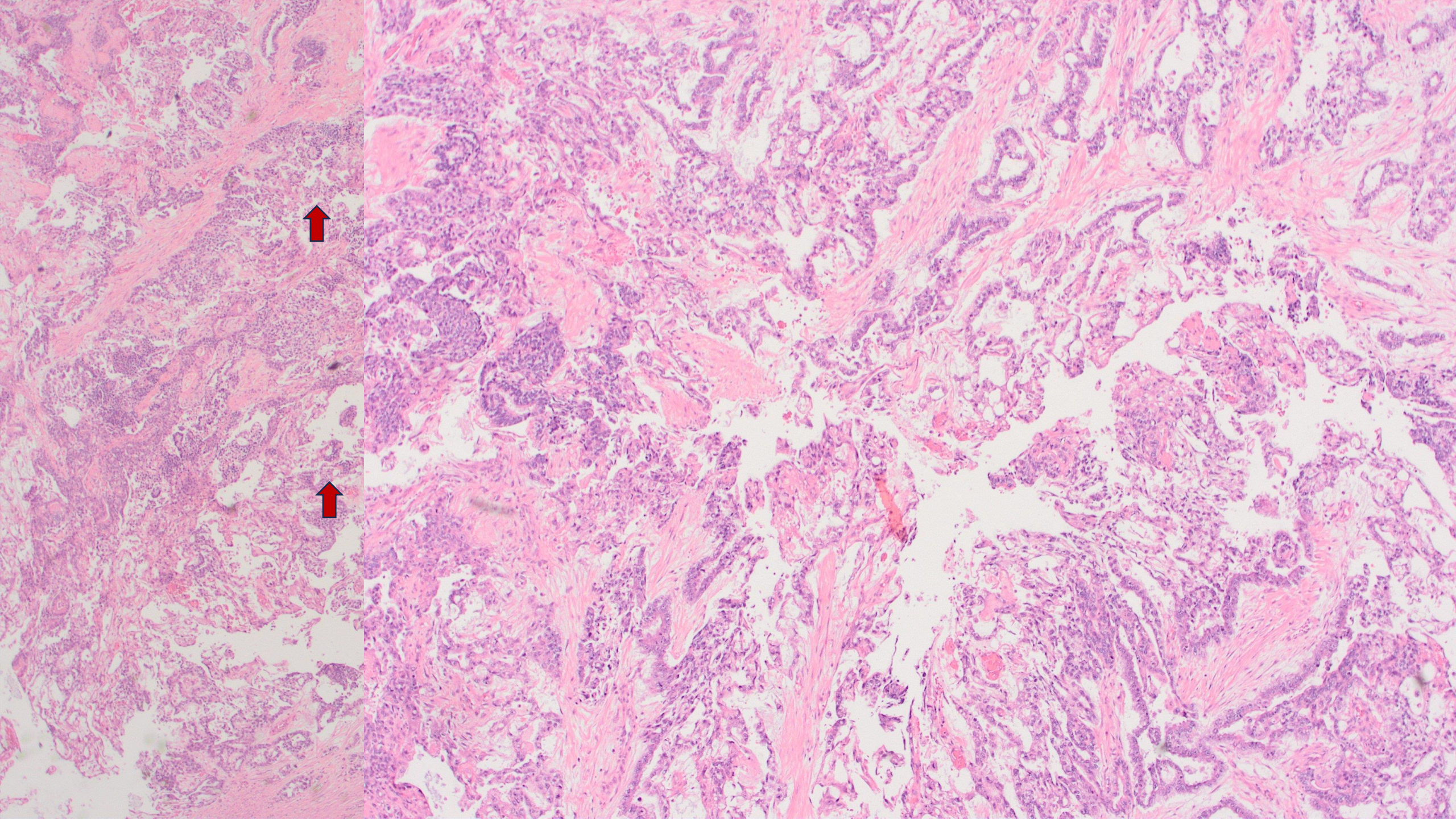

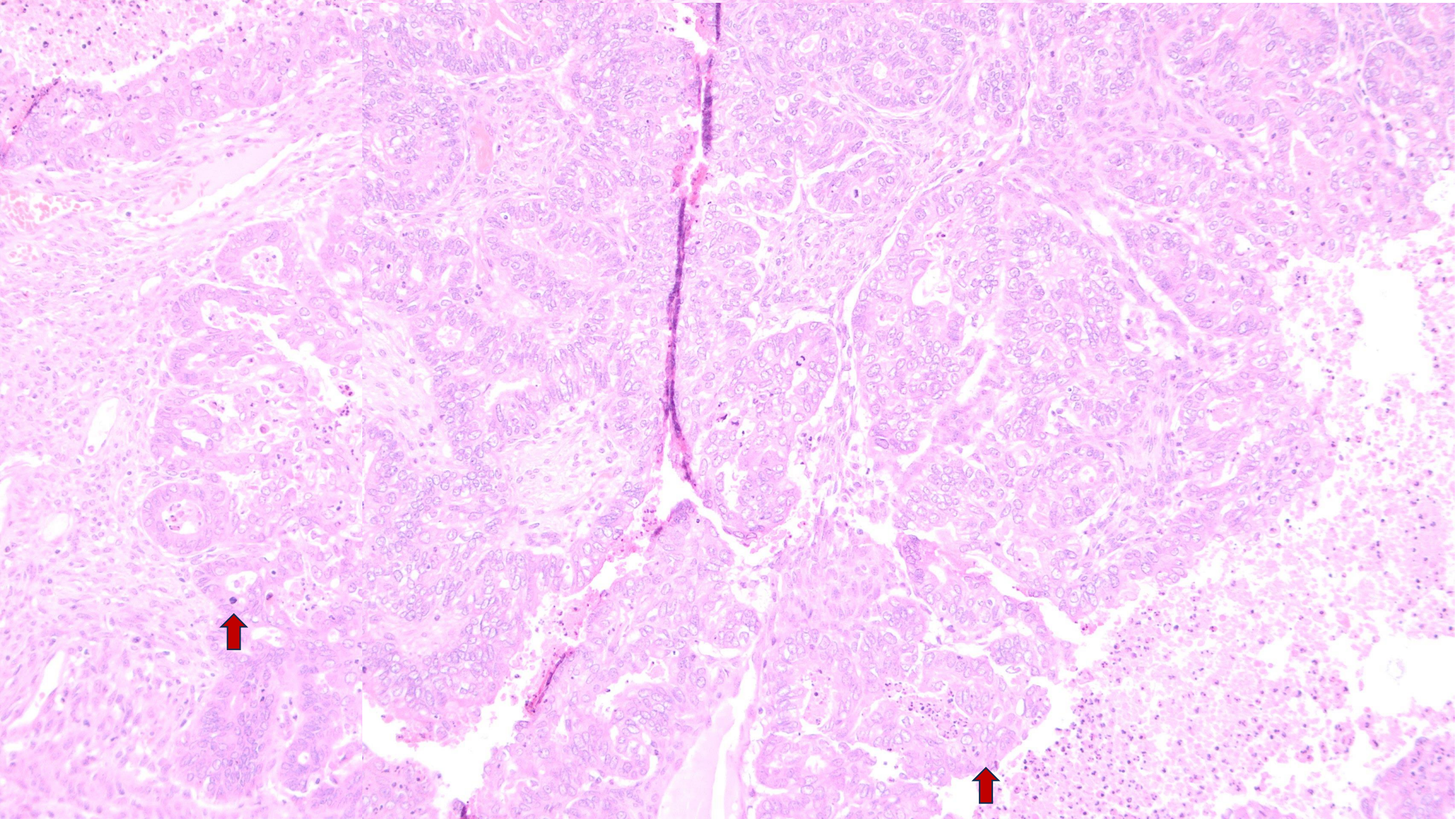

Morphological Diagnosis?

POLL-1

1. High grade serous carcinoma/ Carcinosarcoma
2. Endometroid carcinoma
3. Clear cell carcinoma
4. Mesonephric carcinoma
5. Germ cell Tumour

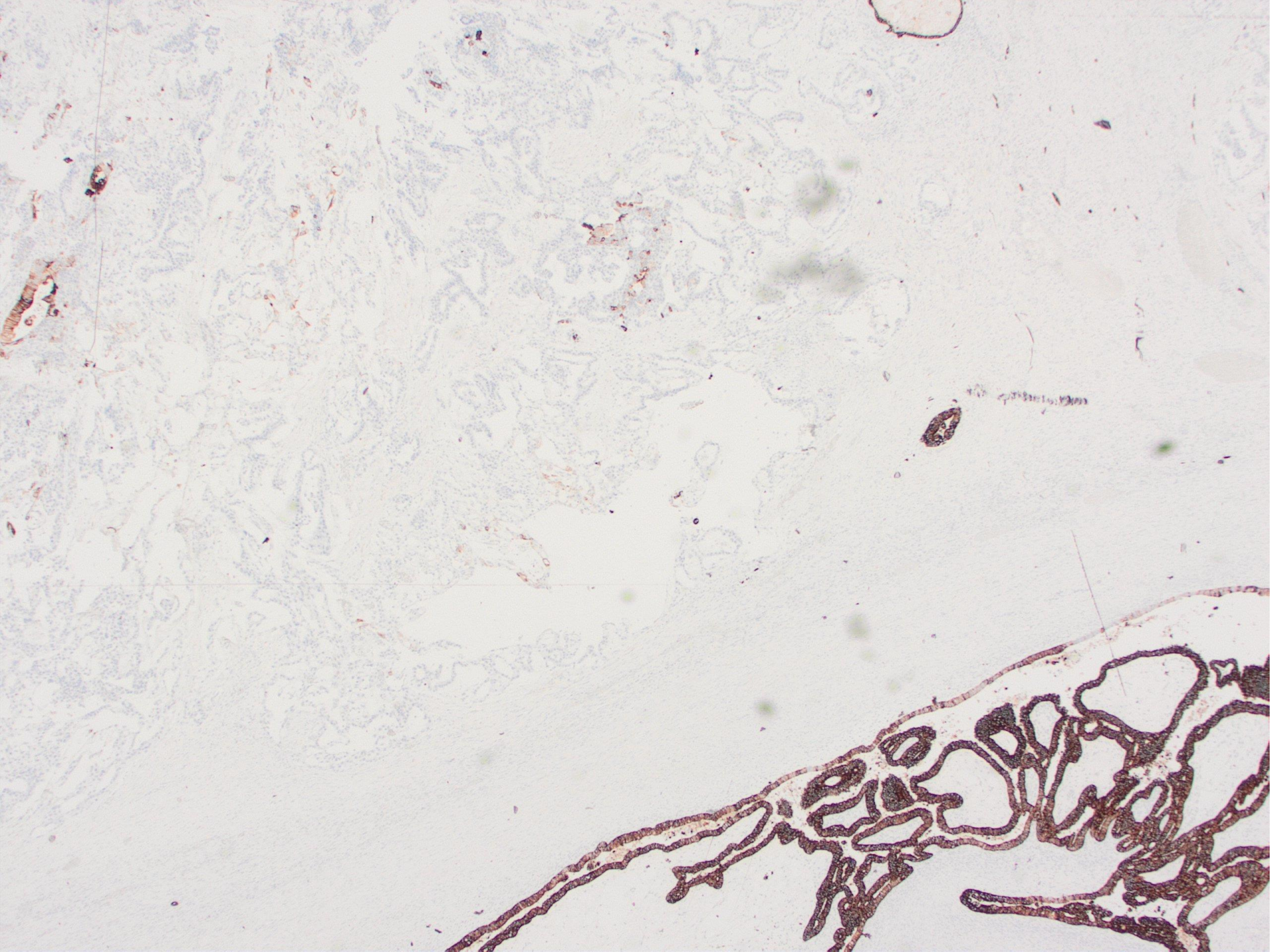

CK7

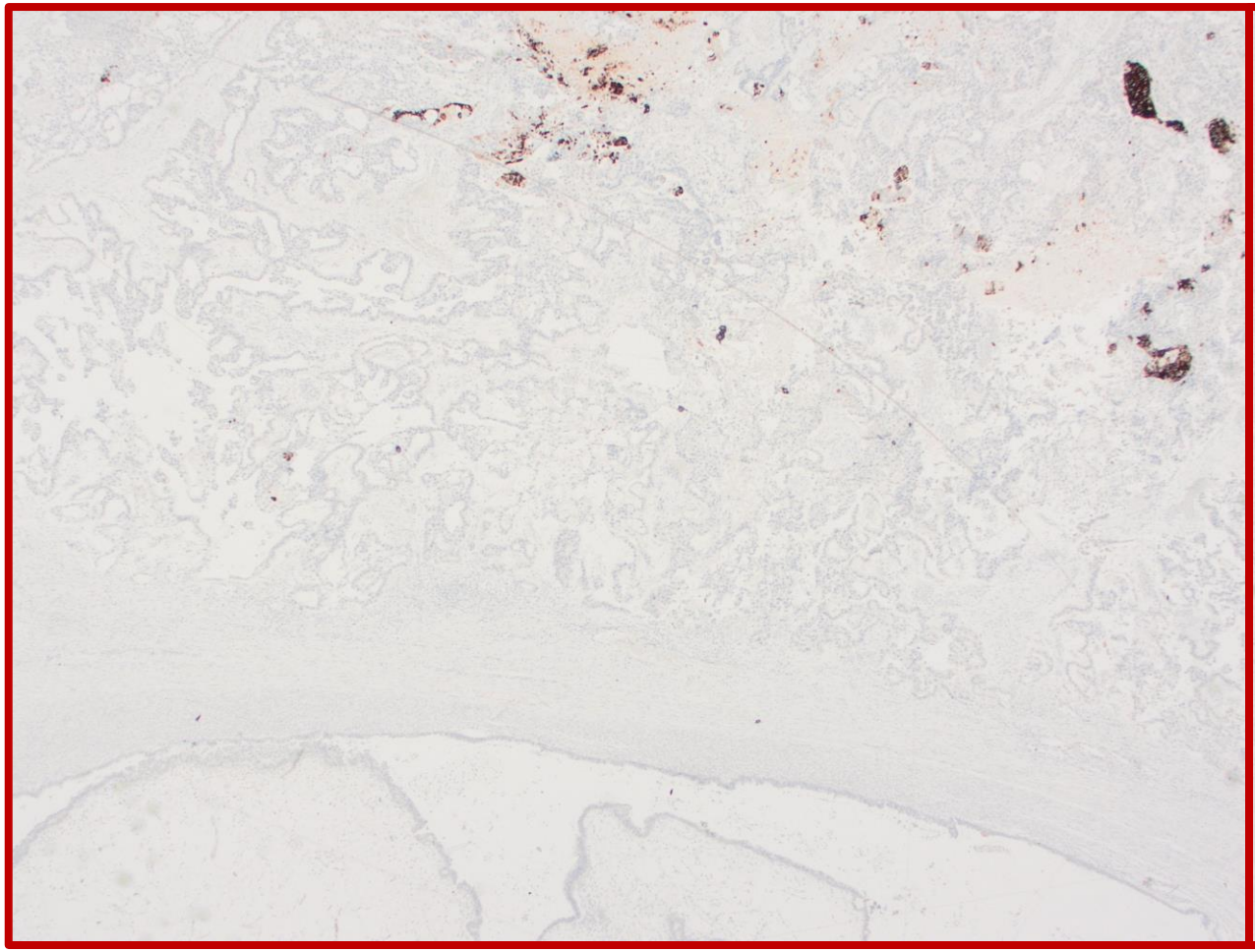

CK20

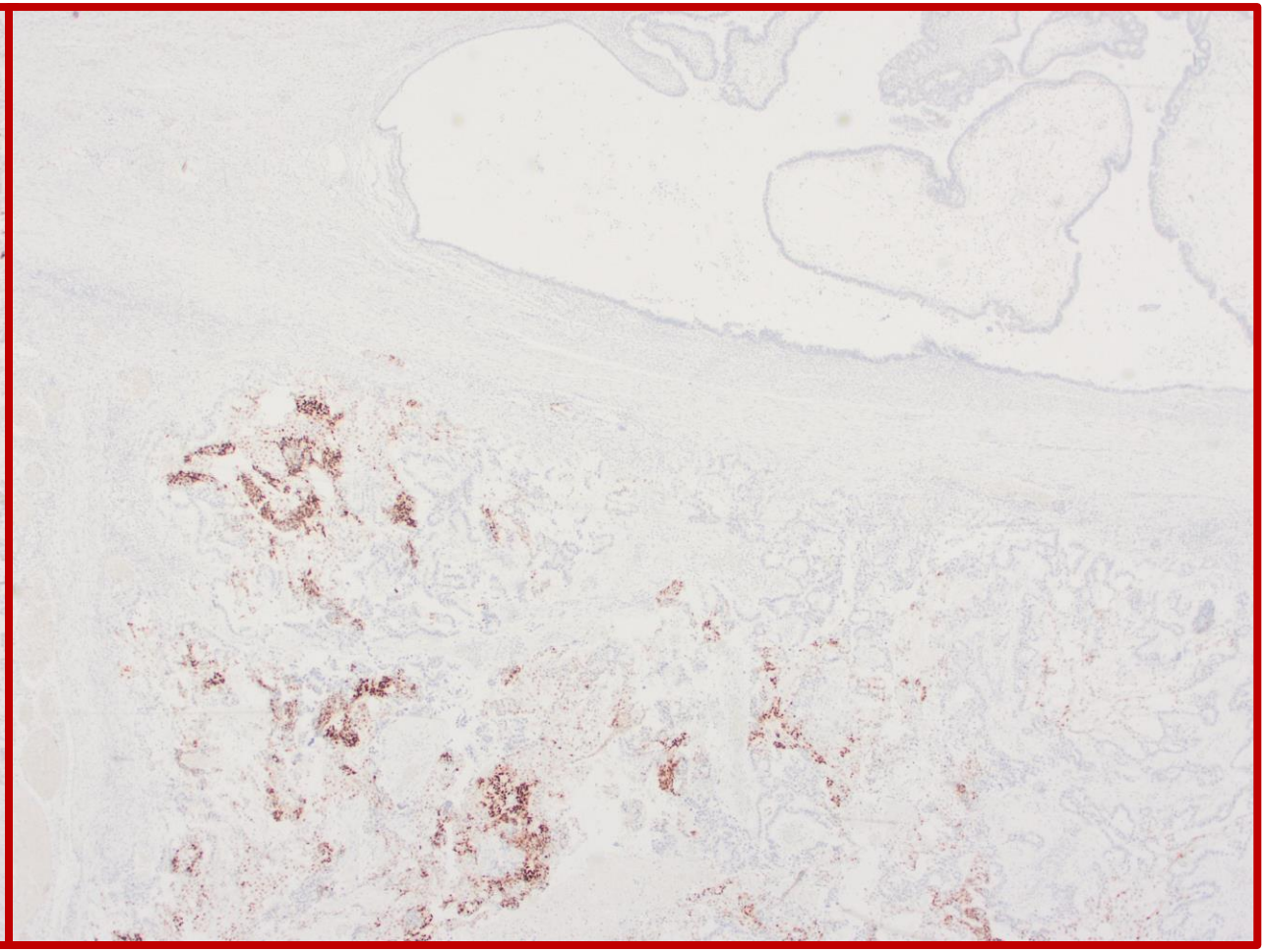

CDX-2

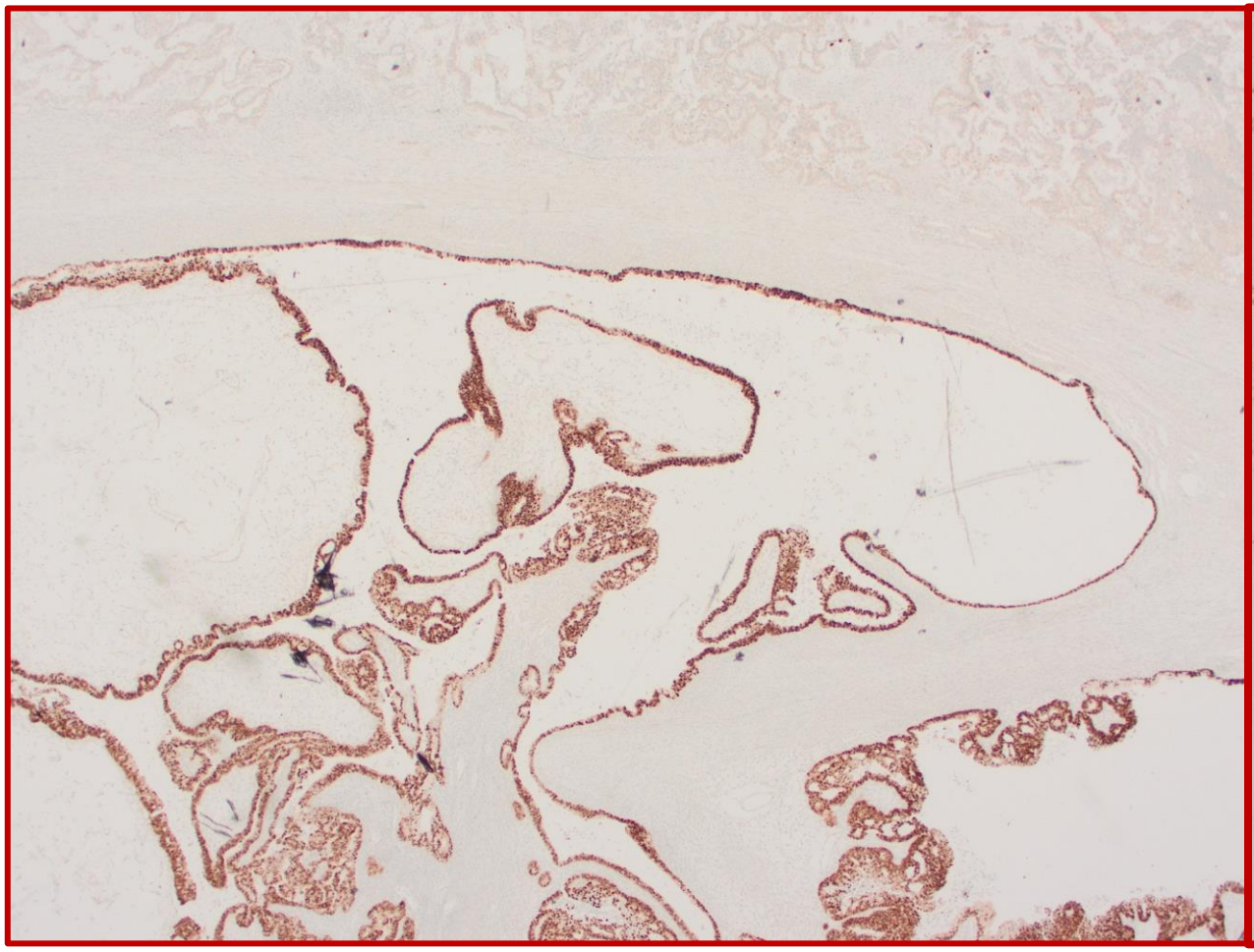

Pax-8

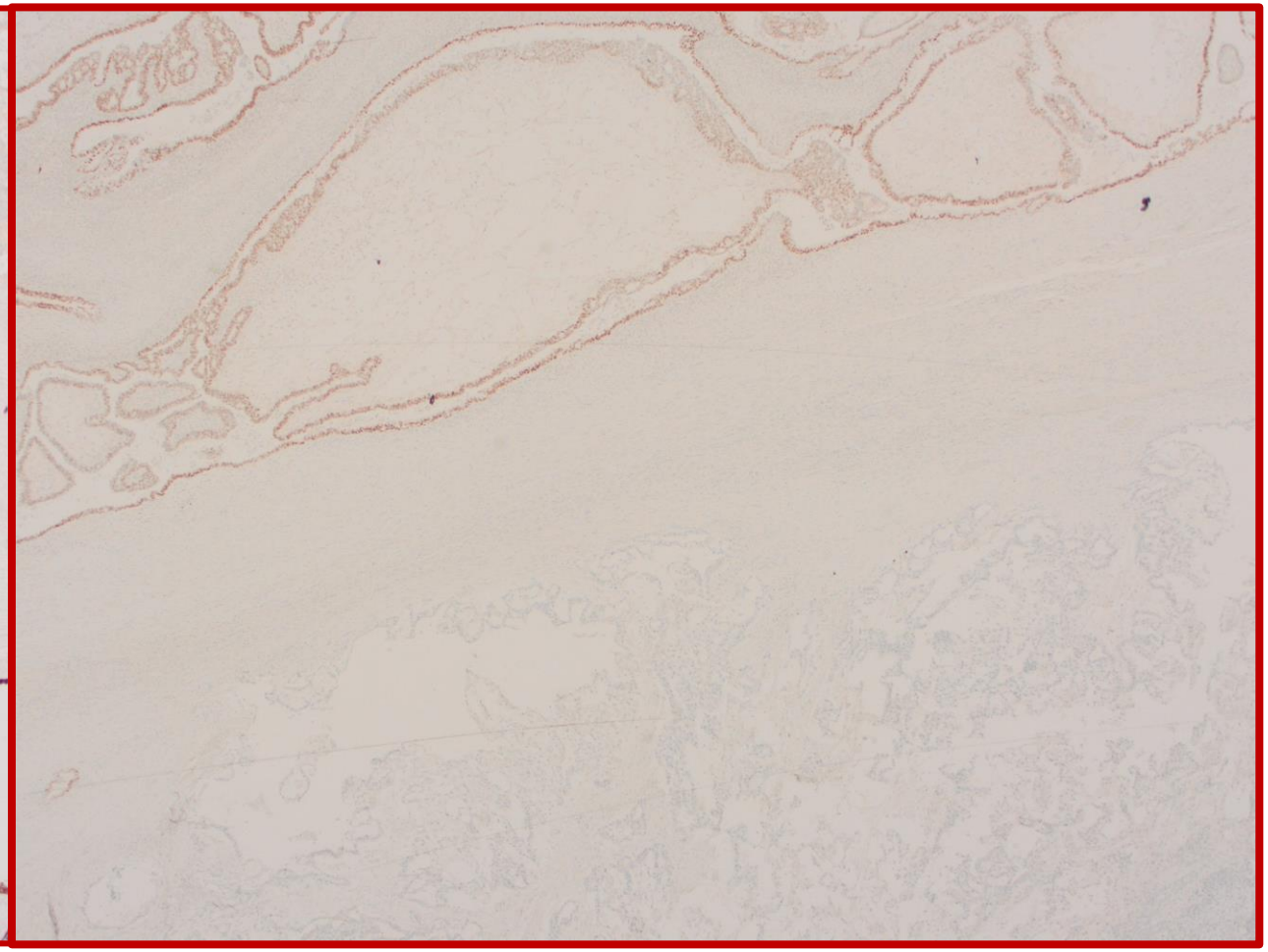

ER

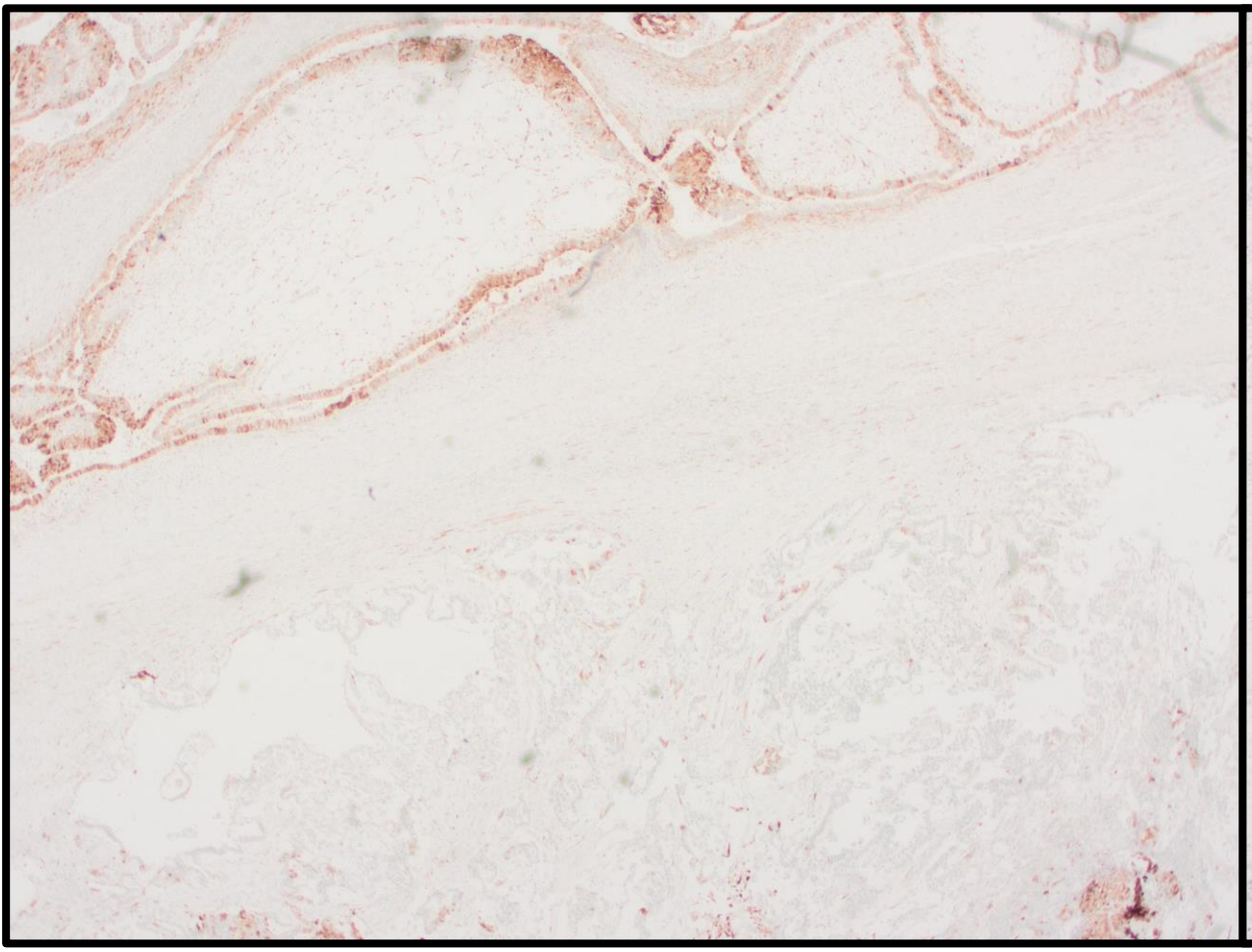

P16

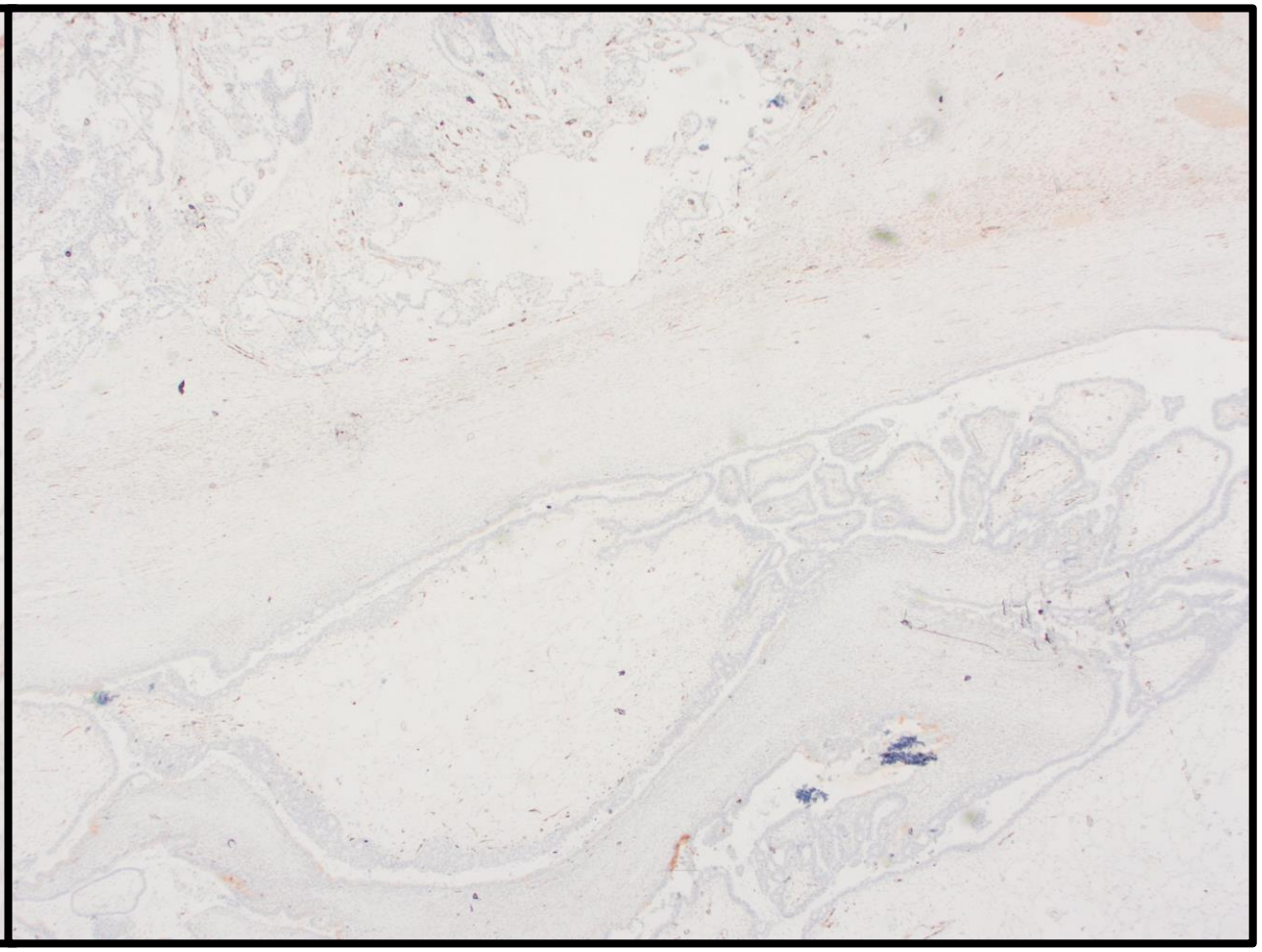

WT-1

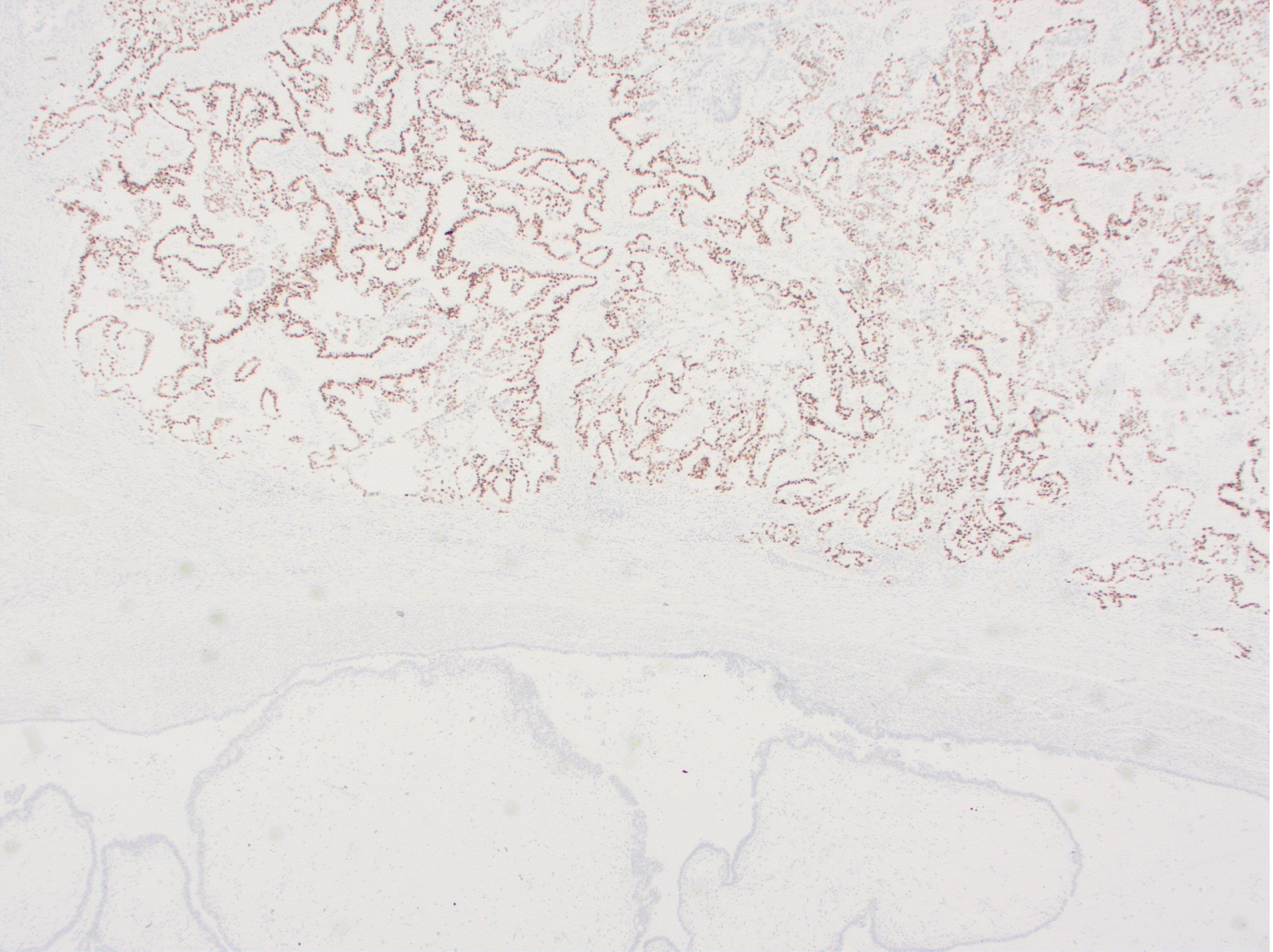

SALL-4

Summary

Tumour with low grade and High-grade areas

- Low grade Positive :CK7,PAX-8, ER
  Negative for- WT-1
- High Grade Positive : SALL-4, GLYPICAN-3, focal CK20, CDX-2
  Negative for: CK7, P16 mosaic. P53- wild type

Both Components Negative for TTF-1, GATA-3, AMACR, calretinin, CD-30, D2-40, OCT3/4, PR, vimentin and WT-1. P 53 is wild type.

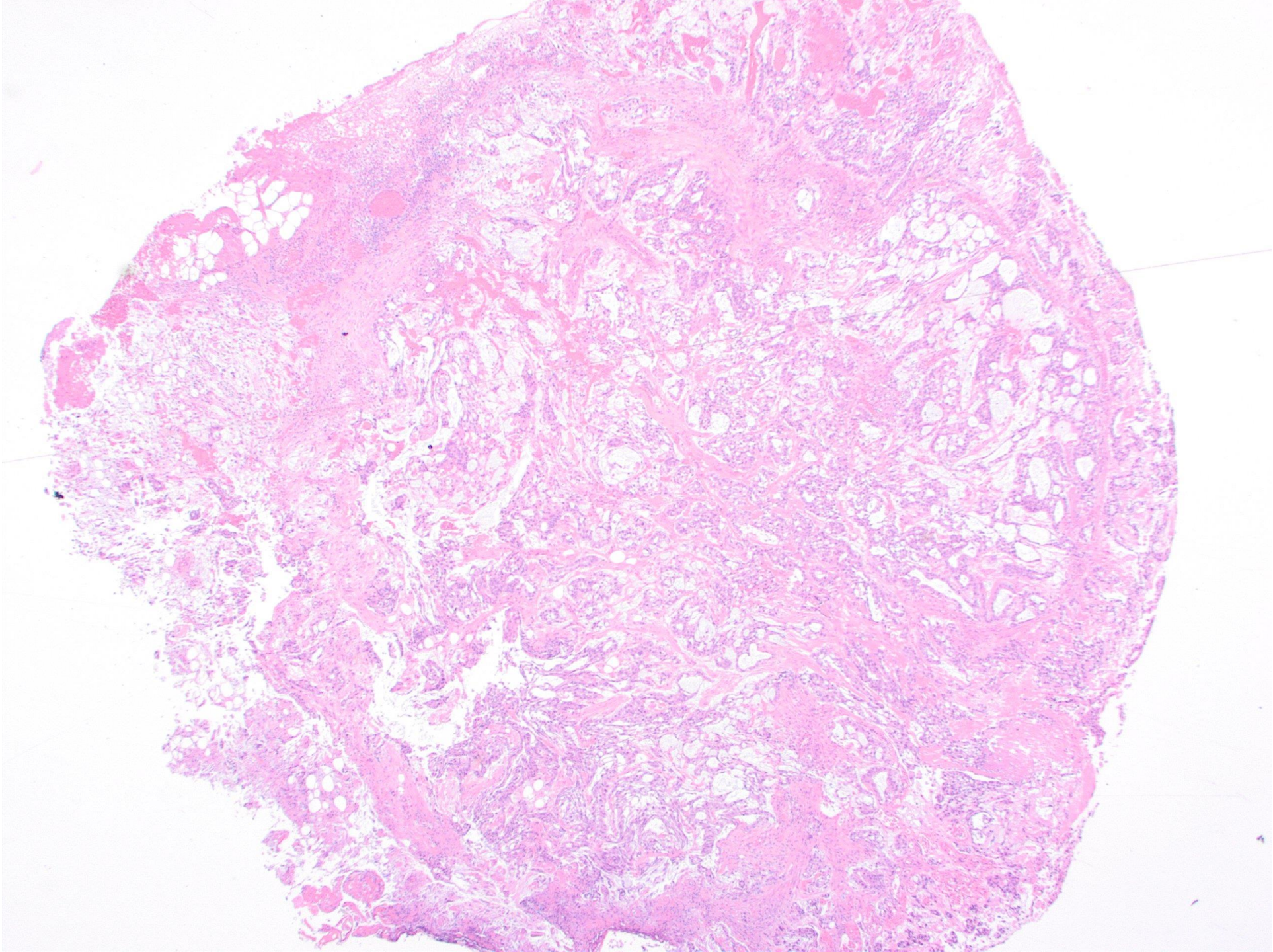

Fallopian Tube

Diagnosis?

POLL-2

Are uterine and ovarian tumour the same tumour or they are different tumours?

1. They are the same tumour
2. Two different tumours

Diagnosis?

POLL-3

What will I do next?

1. More IHC
2. Molecular studies
3. More sampling
4. Levels
5. Show to a colleague

Further sections from the uterus

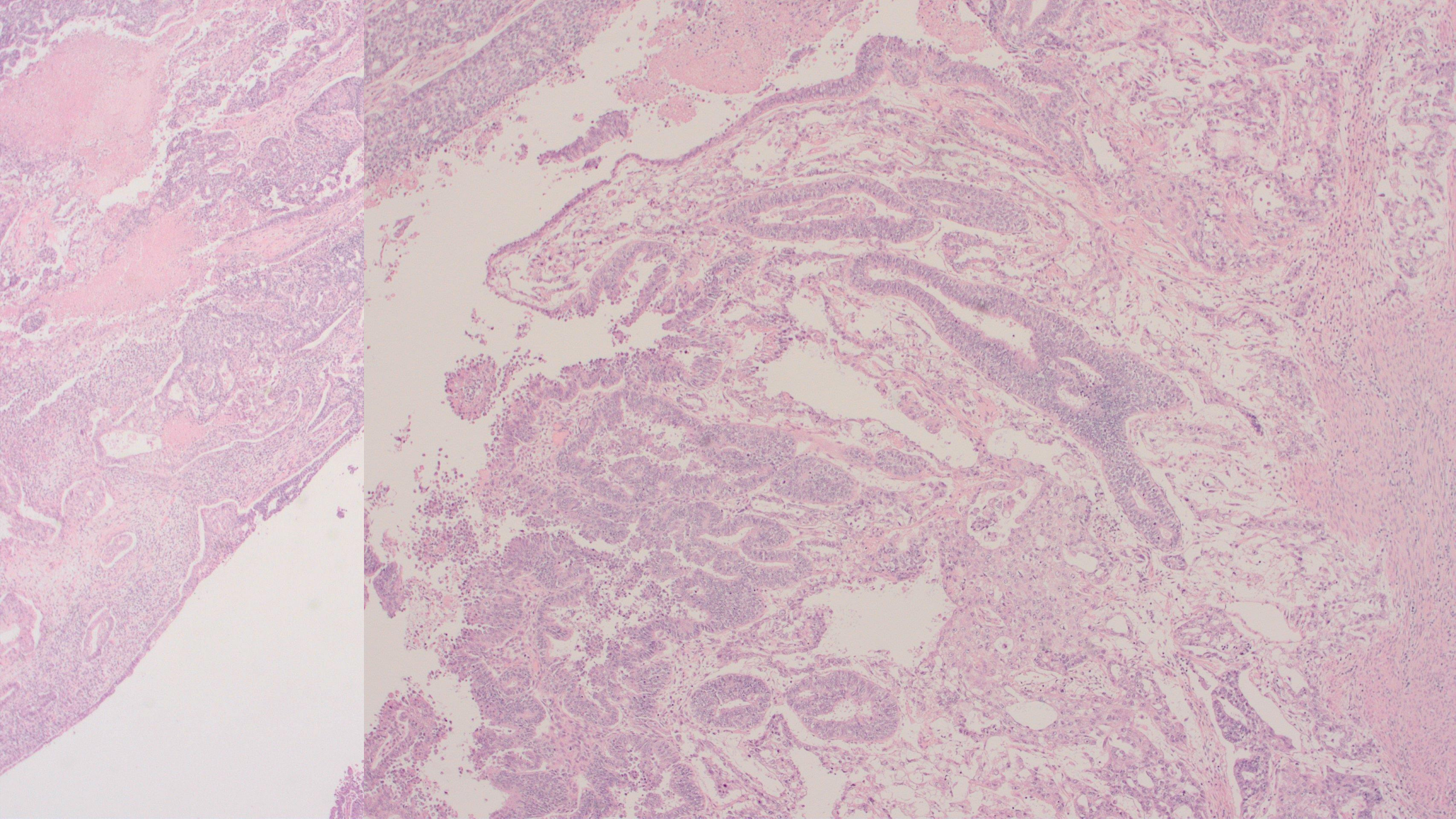

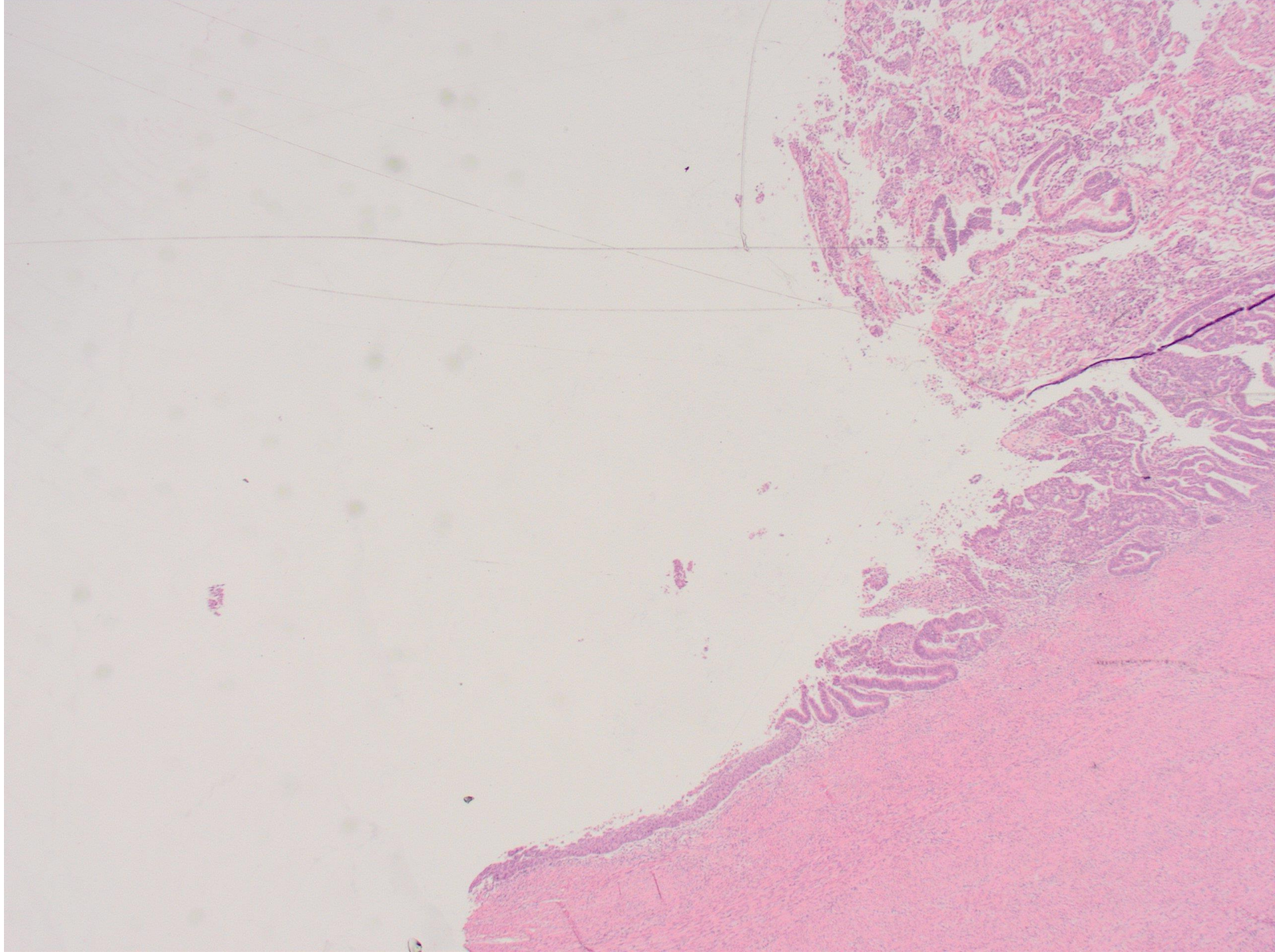

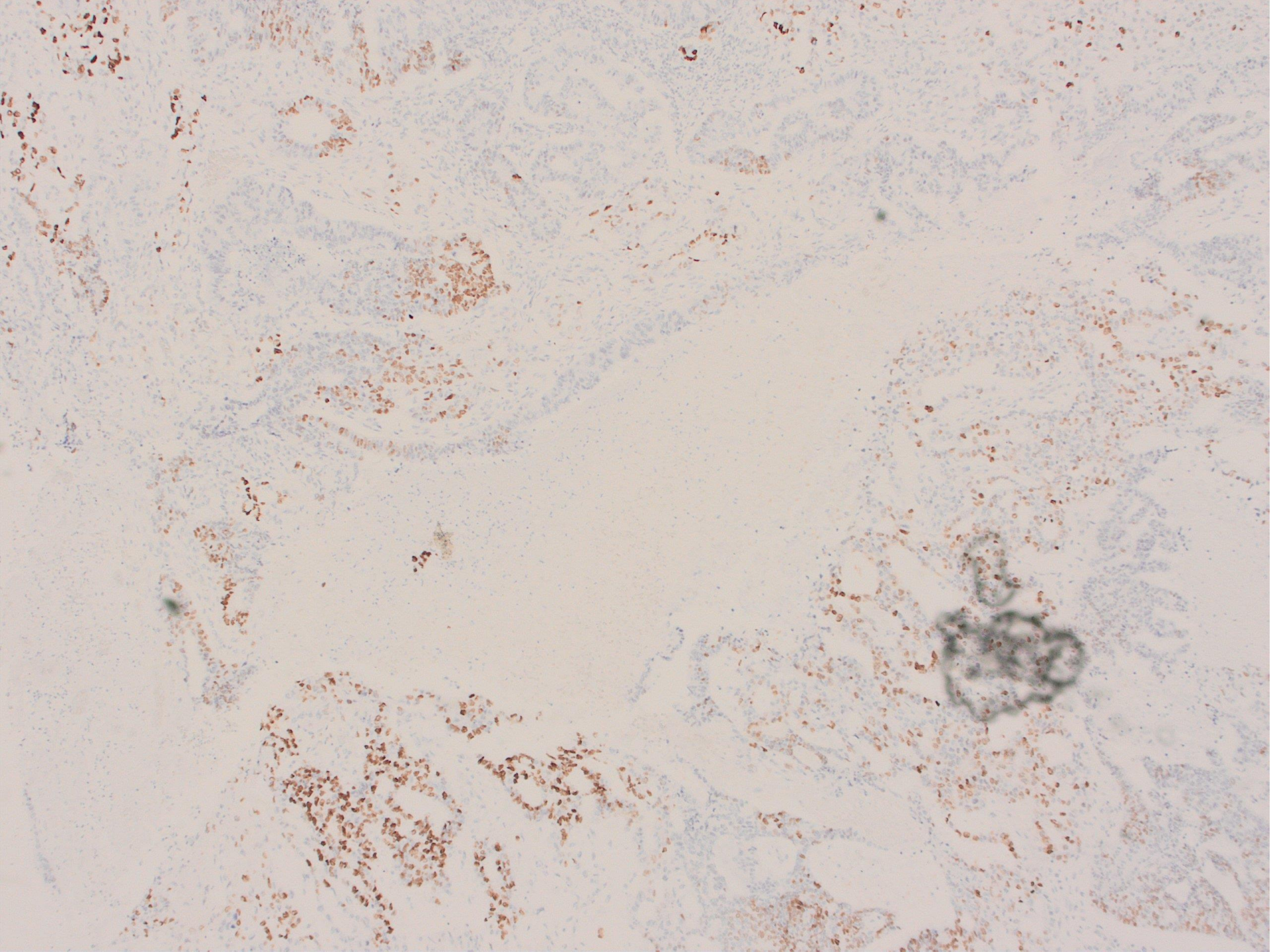

SALL-4

Diagnosis?

POLL-4

This is a

1. Primary uterine tumour with mets to ovaries and elsewhere
2. Primary ovarian tumour with mets to uterus and elsewhere
3. Extrauterine/ extra ovarian tumour
4. Don’t know

Summary



- 62 years female
- Previous endometrial biopsy : grade-1 endometrioid adenocarcinoma
- Uterus showed a tumour involving the entire cavity extending close to the surface with multiple surface deposits on the uterine serosa. Paracervical tumour nodularity with adherent fatty tissue stuck to the posterior surface of the parametrium was noted.
- Bilateral ovarian tumour (2cm and 9cm), showed several surface deposits

Summary



Tumour with low grade and High-grade areas

- Low grade Positive :CK7,PAX-8, ER
  Negative for- WT-1
- High Grade Positive : SALL-4, GLYPICAN-3, focal CK20, CDX-2
  Negative for: CK7, P16 mosaic. P53- wild type

Both Components Negative for TTF-1, GATA-3, AMACR, calretinin, CD-30, D2-40, OCT3/4, PR, vimentin and WT-1. P 53 is wild type.

Diagnosis

- Somatically derived YST arising on the background of Endometroid carcinoma

PATHOLOGY OF THE UPPER GENITAL TRACT: ORIGINAL ARTICLES

Ovarian Yolk Sac Tumors in Older Women Arising From Epithelial Ovarian Tumors or With No Detectable Epithelial Component

Roth, Lawrence M. M.D.; Talerman, Aleksander M.D.; Levy, Tally M.D.; Sukmanov, Oleg M.D.; Czernobilsky, Bernard M.D.

Author Information

International Journal of Gynecological Pathology 30(5):p 442-451, September 2011. | *DOI:* 10.1097/PGP.0b013e3182164386

1. rare in older women
2. often have elevated serum levels of α-fetoprotein
3. Endometrioid carcinoma is the most common putative precursor
4. 4 cases of YST in postmenopausal women. Of the 3 cases with an identified epithelial component
5. Although a precursor epithelial ovarian neoplasm, typically a malignancy (somatic carcinoma), is usually identified, no precursor neoplasm was observed in 1 of our cases and in 5 cases from the literature.
6. We believe that YSTs in older women, whether or not an epithelial component is detected histologically, constitute a single entity that is distinct from YSTs in younger patients and should be treated aggressively.
7. Neoplasms with a YST component in older women are less responsive to the chemotherapy currently used for ovarian germ cell tumors; therefore, adjuvant therapy should include platinum-based chemotherapy designed to treat both epithelial ovarian cancer and germ cell tumors.
8. Of the 24 reported cases, including our own, 17 died of neoplasms within 25 months and another was living with disease at 2 months. However, 2 more recent patients treated aggressively with platinum-based chemotherapy designed to treat both epithelial and germ cell tumor components with stage 1 disease are living and have been disease free >1 year after operation.

Histopathology

Histopathology 2016, **69**, 739–751. DOI: 10.1111/his.13021

Yolk sac tumours of the female genital tract in older adults derive commonly from somatic epithelial neoplasms: somatically derived yolk sac tumours

Tamara McNamee, Stephen Damato[1] & W Glenn McCluggage

18 yolk sac tumours (YSTs) of the female genital tract (17 ovary, one uterus) in patients aged 40 years or over

Six patients had pure YST, two were associated with immature teratoma (one withan endometrioid adenocarcinoma) and in 11 ther ewas an epithelial neoplasm comprising high-gradeserous carcinoma (HGSC) (n = 5), clear cell carcinoma (n = 1), borderline clear cell adenofibroma(n = 1), endometrioid adenocarcinoma (n = 2), serous tubal intra-epithelial carcinoma (n = 1) and large-cell neuroendocrine carcinoma (n = 1).

YST exhibited predominantly glandular morphology, closely mimicking an epithelial neoplasm.

In only five cases was a diagnosis of YST suggested by the referring pathologist. Other referral diagnoses for the YST component included high-grade serous carcinoma (HGSC), endometrioid adenocarcinoma, clear cell carcinoma, metastatic intestinal adenocarcinoma, Sertoli cell tumour, Sertoli–Leydig cell tumour, malignant germ cell tumour (not otherwise specified),carcinosarcoma and neuroendocrine carcinoma

In the ovarian patients, the stages were FIGO stageIA (four cases), IC (four cases), IIB (one case), IIIA(one case), IIIB (one case), IIIC (five cases) and IVB(one case). The uterine patient was FIGO stage IVB

Histopathology

Histopathology 2016, **69**, 739–751. DOI: 10.1111/his.13021

Yolk sac tumours of the female genital tract in older adults derive commonly from somatic epithelial neoplasms: somatically derived yolk sac tumours

Tamara McNamee, Stephen Damato[1] & W Glenn McCluggage

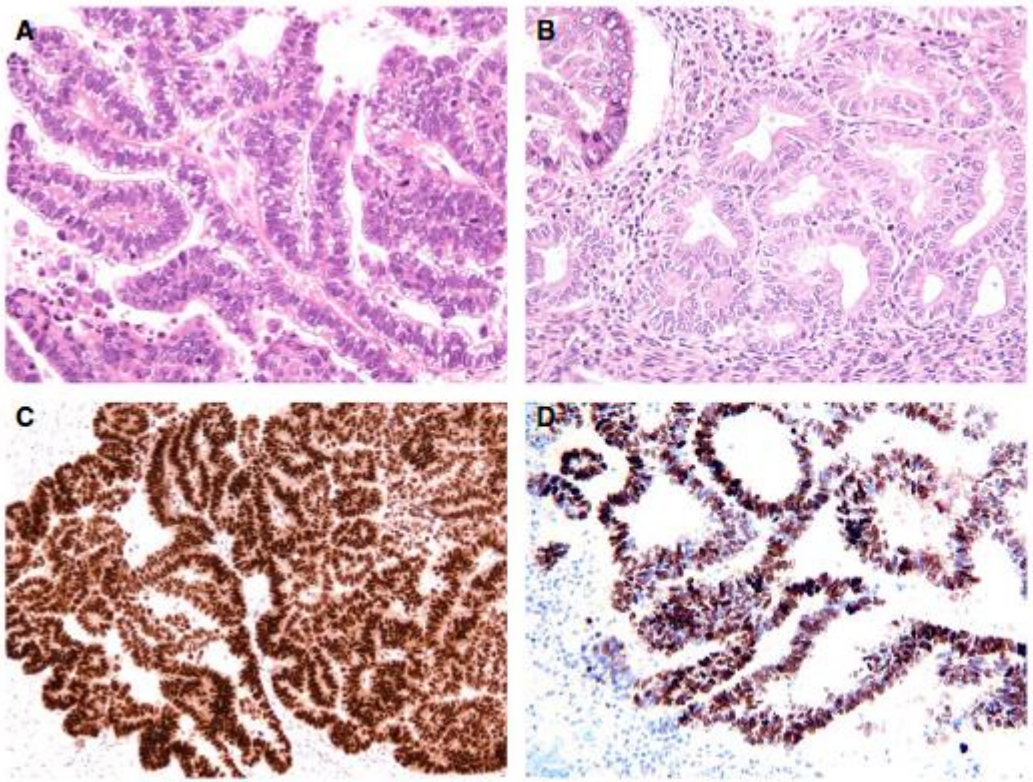

Figure 6. Uterine case (case 18) with glandular and papillary yolk sac tumour component (**A**) and small focus of endometrioid adenocarcinoma (**B**). The yolk sac tumour component is positive with SALL4 (**C**) and CDX2 (**D**).

2 cases showed IT component

Histopathology

Original Article

Germ cell tumour growth patterns originating from clear cell carcinomas of the ovary and endometrium: a comparative immunohistochemical study favouring their origin from somatic stem cells

Francisco F Nogales, Jaime Prat, Maolly Schuldt, Nelly Cruz-Viruel, Baljeet Kaur, Emanuela D'Angelo, Xavier Matias-Guiu, August Vidal, W Glenn McCluggage, J Wolter Oosterhuis

First published: 06 November 2017 | https://doi.org/10.1111/his.13426 | Citations: 18

12 cases (11 ovarian and one uterine) exhibiting a mixture of glandular YST and clear cell tumour
Somatically derived malignant stem cells in Mullerian clear cell tumours behave as genetically engineered iPSCs (induced pluripotent stem cells) and give rise to components resembling all the components of GCT
These showed lack of 12p gain

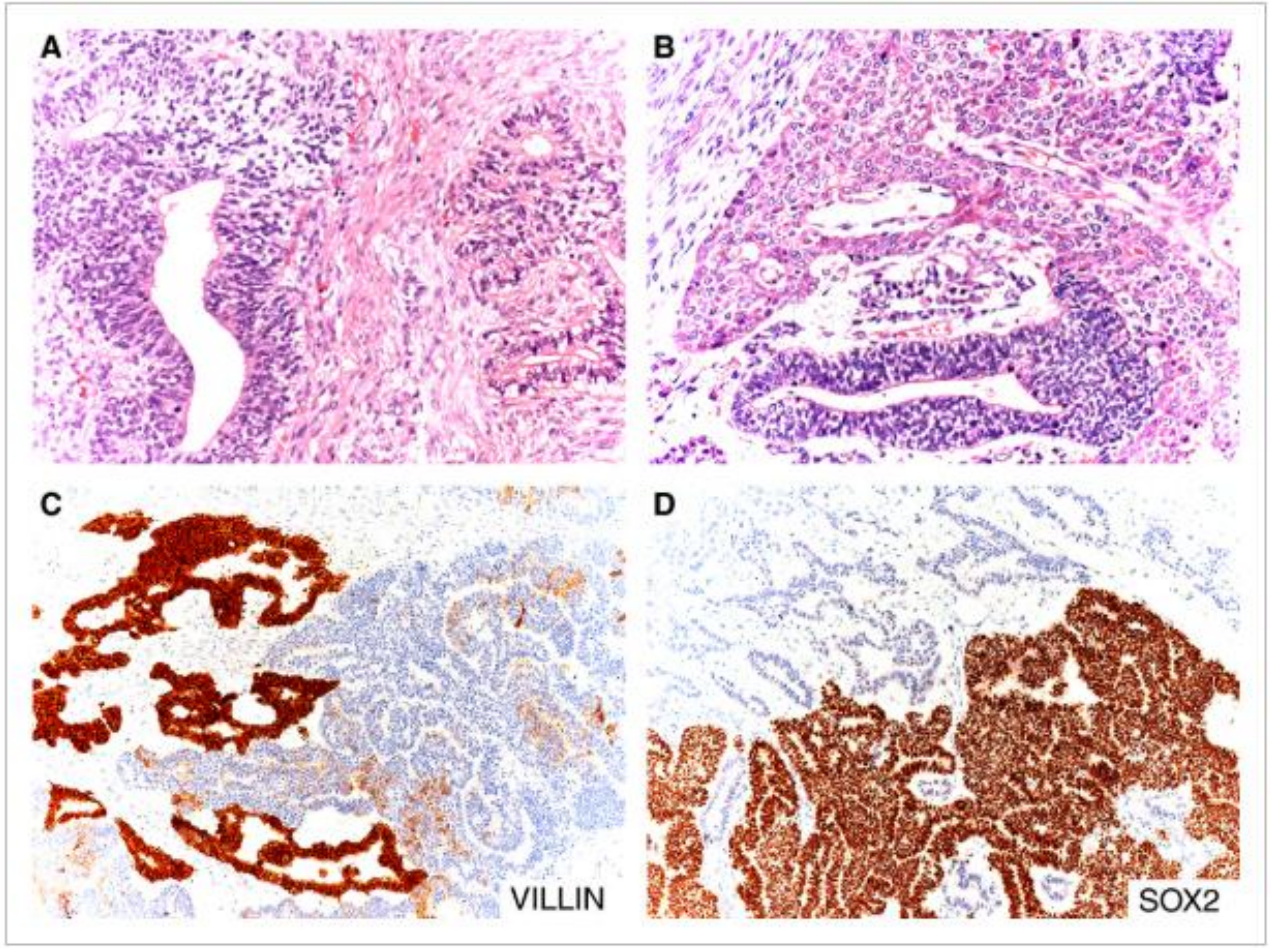

Figure 3

Open in figure viewer | PowerPoint

Case 9: simultaneous endodermal and neural differentiations (**A**). A neuroepithelial rosette (left) faces foci of glandular yolk sac tumour (right) (**B**). Hepatoid tissue (top) merges with a neuroepithelial rosette (bottom centre). Glandular yolk sac tumours (YST) is identified by its villin expression (**C**) while neuropithelium expresses SOX2 (**D**).

Histopathology

Original Article

Germ cell tumour growth patterns originating from clear cell carcinomas of the ovary and endometrium: a comparative immunohistochemical study favouring their origin from somatic stem cells

Francisco F Nogales ✉, Jaime Prat, Maolly Schuldt, Nelly Cruz-Viruel, Baljeet Kaur, Emanuela D'Angelo, Xavier Matias-Guiu, August Vidal, W Glenn McCluggage, J Wolter Oosterhuis

First published: 06 November 2017 | https://doi.org/10.1111/his.13426 | Citations: 18

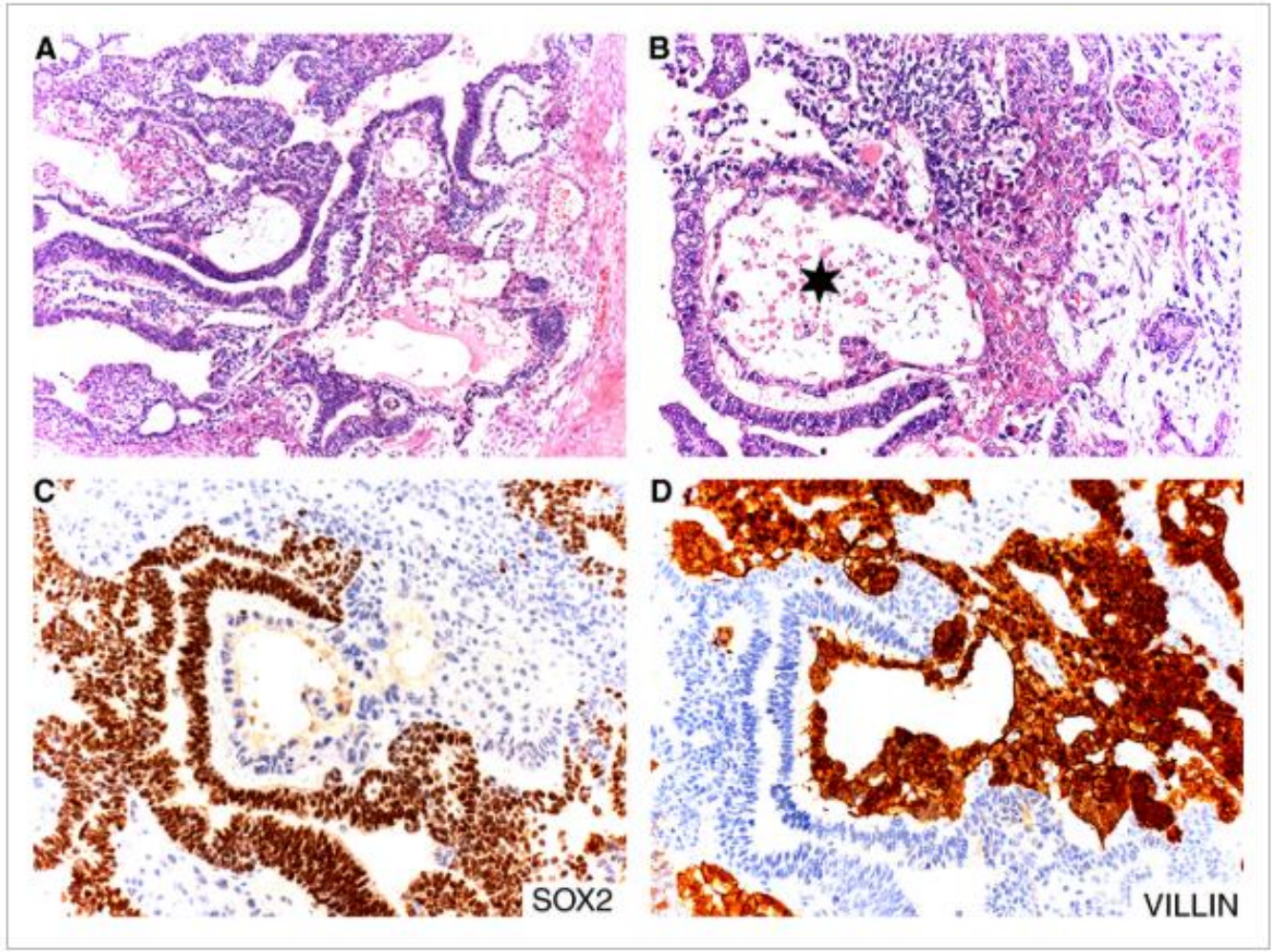

Figure 4

Open in figure viewer | PowerPoint

Case 11: organoid association of endodermal and neurogenic structures forming embryoid-like bodies (**A**, **B**) with a primitive vitelline cavity (asterisk) surrounded by a neuroectodermal plate expressing SOX2 while the yolk sac lining reveals a strong stain for villin (**D**).

Histopathology

Original Article

Germ cell tumour growth patterns originating from clear cell carcinomas of the ovary and endometrium: a comparative immunohistochemical study favouring their origin from somatic stem cells

Francisco F Nogales ✉, Jaime Prat, Maolly Schuldt, Nelly Cruz-Viruel, Baljeet Kaur, Emanuela D'Angelo, Xavier Matias-Guiu, August Vidal, W Glenn McCluggage, J Wolter Oosterhuis

First published: 06 November 2017 | https://doi.org/10.1111/his.13426 | Citations: 18

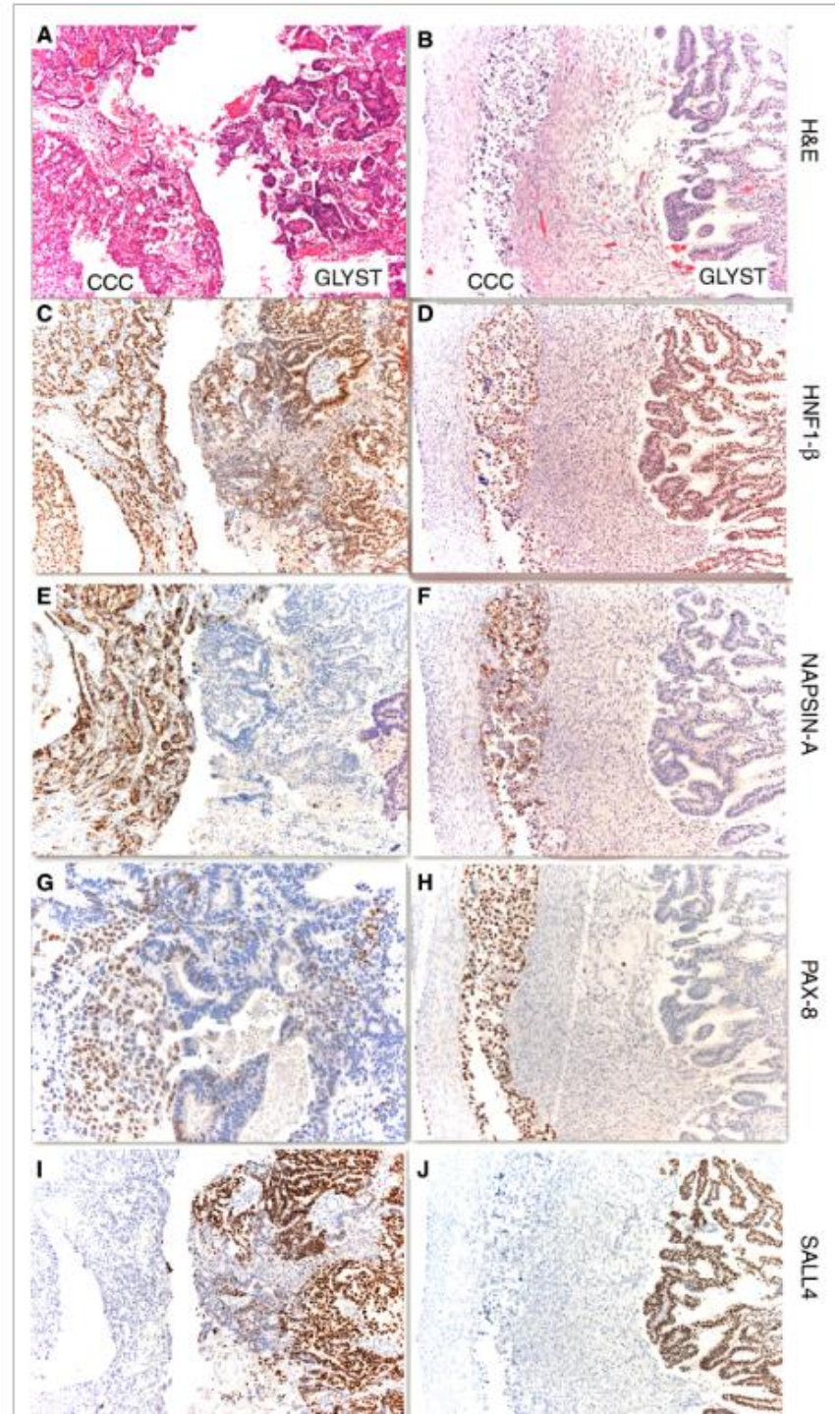

ORIGINAL ARTICLES

Yolk Sac Tumor in Extragonadal Pelvic Sites

Still a Diagnostic Challenge

Ravishankar, Sanjita MD; Malpica, Anais MD; Ramalingam, Preetha MD; Euscher, Elizabeth D. MD

Author Information

The American Journal of Surgical Pathology 41(1):p 1-11, January 2017. | *DOI:* 10.1097/PAS.0000000000000722

Clinicopathologic features of 15 cases

Primary sites were as follows: uterus (11), vagina (1), vulva (1), bladder (1), and peritoneum (1).

7 patients presented at FIGO stage IIIor IV.

The following histologic patterns were observed: microcystic/reticular (7), glandular (8), solid (8), papillary (5), and hepatoid (1).

Schiller-Duval bodies were seen in only 3 (23%) cases.

Eight cases (46%), all uterine primaries, had associated somatic components

Immunoperoxidase studies : SALL4,12/12; CDX2, 10/12; a fetoprotein, 7/14; glypican-3, 9/10; cytokeratin 20, 5/9 (rare cells); cytokeratin 7, 3/12 (nondiffuse);PAX8, 2/9 (variable expression).

Follow-up from 5 to 86 months was available for 13 patients: 5 died of disease, 6 are alive with disease, and 2 have no evidence of disease.

EGYST arising in the female pelvis of peri/postmenopausal patients may be associated with a somatic component and represent either somatically derived YST or YST differentiation within a somatic carcinoma.

The benefit of germ cell appropriate chemotherapy in somatically derived EGYST is less clear.

Somatic Origin

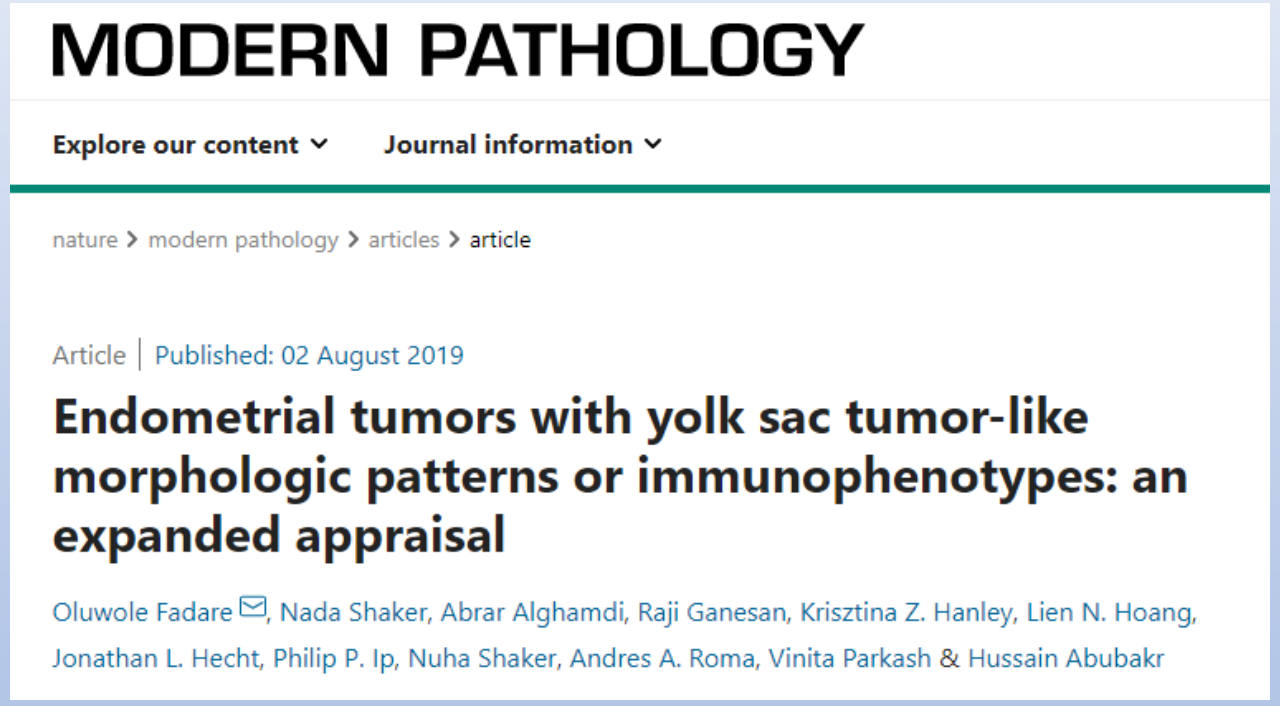

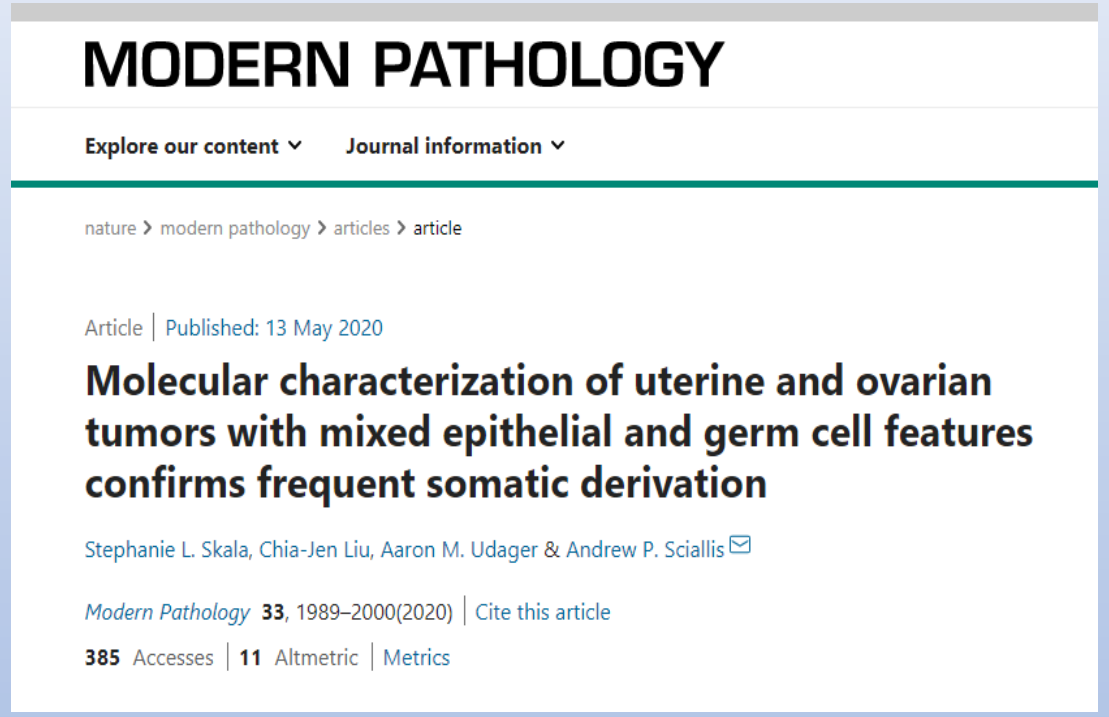

It has been postulated that this phenomenon represents a form of retro differentiation in carcinomas, and that yolk sac tumor-like areas possibly originated from spontaneously induced pluripotent stem cells. The diagnostic term “somatically derived yolk sac tumors” has been proposed for such tumors.

NGS and FISH findings in a series of gynecologic “germ cell tumors” from women >35 years old (8 patients)
i(12p) seen in 3 cases and polysomy seen in 2 cases
Identical mutations were seen in the yolk sac tumor-like and endometrioid components of each case

Histopathology



Volume77, Issue5
November 2020
Pages 788-797

Original Article

Malignant tumours of the uterus and ovaries with Mullerian and germ cell or trophoblastic components have a somatic origin and are characterised by genomic instability

Andres M Acosta, Lynette M Sholl, Paola D Cin, Brooke E Howitt, Christopher N Otis, Marisa R Nucci

Nine MMGC/T from three institutions were studied

The different components of MMGC/T have a clonal origin, given their almost identical mutational profiles.

FISH studies performed on the YST components of six cases demonstrated either trisomy (two of six) or polysomy (four of six) of chromosome 12 but absence of i(12p)

Take Home message

- There is no single marker that will make a definitive diagnosis of EGYST.
- High index of suspicion based on the recognition of histologic features and a panel of immunoperoxidase stains is often required.
- YST and somatic carcinoma may have overlapping histologic and immunohistochemical features that can further contribute to a diagnostic pitfall.
- CK20 and CDX-2 positivity may mimic metastatic colorectal carcinoma
- As both prognosis and management of YST differ significantly from somatic tumors, accurate diagnosis is essential

NIHR | Imperial Biomedical Research Centre

ecmc

CANCER RESEARCH UK | IMPERIAL CENTRE

NHS North West London Pathology

Acknowledgements

- Dr. Eleanor Jaynes (University Hospital Southampton)
- BRC Imperial



707

Thank You