The British Association of Gynaecological Pathologists

Lecturer – Prof W Glenn McCluggage



I am a consultant Histopathologist in Belfast Health and Social Care Trust, Belfast and an Honorary Professor in Gynaecological Pathology of Queen's University of Belfast. I have published over 680 papers in peer reviewed journals, including original publications and many invited editorials and reviews. I am on the Editorial Board of several major pathology journals (Modern Pathology, Human Pathology, Advances in Anatomic Pathology, International Journal of Gynecological Pathology, Virchows Archives), a member of the International Advisory Board of Journal of Clinical Pathology and associate editor of Histopathology. I am past President of International Society of Gynecological Pathologists and was previously secretary of this society. Previously I was President of the British Association of Gynaecological Pathologists. I have an extremely busy referral practice and receive numerous consultation cases from all over the world. I have been invited to lecture at numerous national and international meetings. I have authored or coauthored the various Royal College of Pathologists datasets in United Kingdom on reporting of gynaecological malignancies and have chaired the ICCR (International Collaboration on Cancer Reporting) panels developing international guidelines for reporting endometrial, ovarian, cervical, vulval and vaginal carcinomas. I am also the ICCR series champion for gynaecological neoplasms. I have been part of the last four World Health Organization (WHO) groups formulating the classification of Tumours of the Female Genital Tract and am one of the editors on the upcoming 2025/2026 WHO Classification.

The British Association of Gynaecological Pathologists

BAGP 21ST ANNUAL MEETING

- ENDOMETRIAL CARCINOMA: LESSONS FROM REFERRAL PRACTICE
- W GLENN MCCLUGGAGE
- 5/6/2025

The British Association of Gynaecological Pathologists

Speaker disclosures

I have undertaken some paid work for GSK

LAYOUT OF TALK

- Some general comments about referral practice and referring cases
- Some endometrial cases with lessons

REFERRAL CASES

- It is a 2-way street with “gains” and “pains” on both sides
- Very rewarding for referral pathologist (interesting cases; can gather together case series for collaborative studies; learning experience)
- Considerable amount of work for each case
- Very rewarding for referring pathologist (hopefully correct answer; learning experience)
- Many things can make it easier for both “referral” and “referring” pathologist

WHEN REFERRING CASES- DO

- Email the pathologist beforehand to see whether they can review the case and advise what material to send (now almost everyone does this)
- Send a referral letter detailing the reason for referring the case; include name and DOB of patient, biopsy number (may be multiple biopsy numbers- detail these)
- Get the name and address of the pathologist correct
- Send copy of report stating that you have referred the case (this will include useful information regarding gross description/ block key; pathologist needs to know origin of slides)
- Provide an email and postal address to email and send the report
- Send the relevant material together with blocks or blank slides (needed for further work; keeping material; cutting blank sections)
- Acknowledge receipt of emailed report
- Provide follow-up/ clinical details if asked by referring pathologist
- Provide details of any follow-up specimens or opinions
- Provide details of any further ancillary studies

WHEN REFERRING CASES- DON'T

- Send lots of unnecessary slides
- Hound the pathologist and ask for a report by a certain date (for MDT/ tumour board meeting etc)
- Get your secretary to email or ring regarding the report
- Send to multiple different pathologists at once
- Send the case because you are going on leave or because it is Christmas

CASE 1: SOME DOGMAS ARE NOT ALWAYS TRUE

- F 70
- Postmenopausal bleeding
- Endometrial biopsy

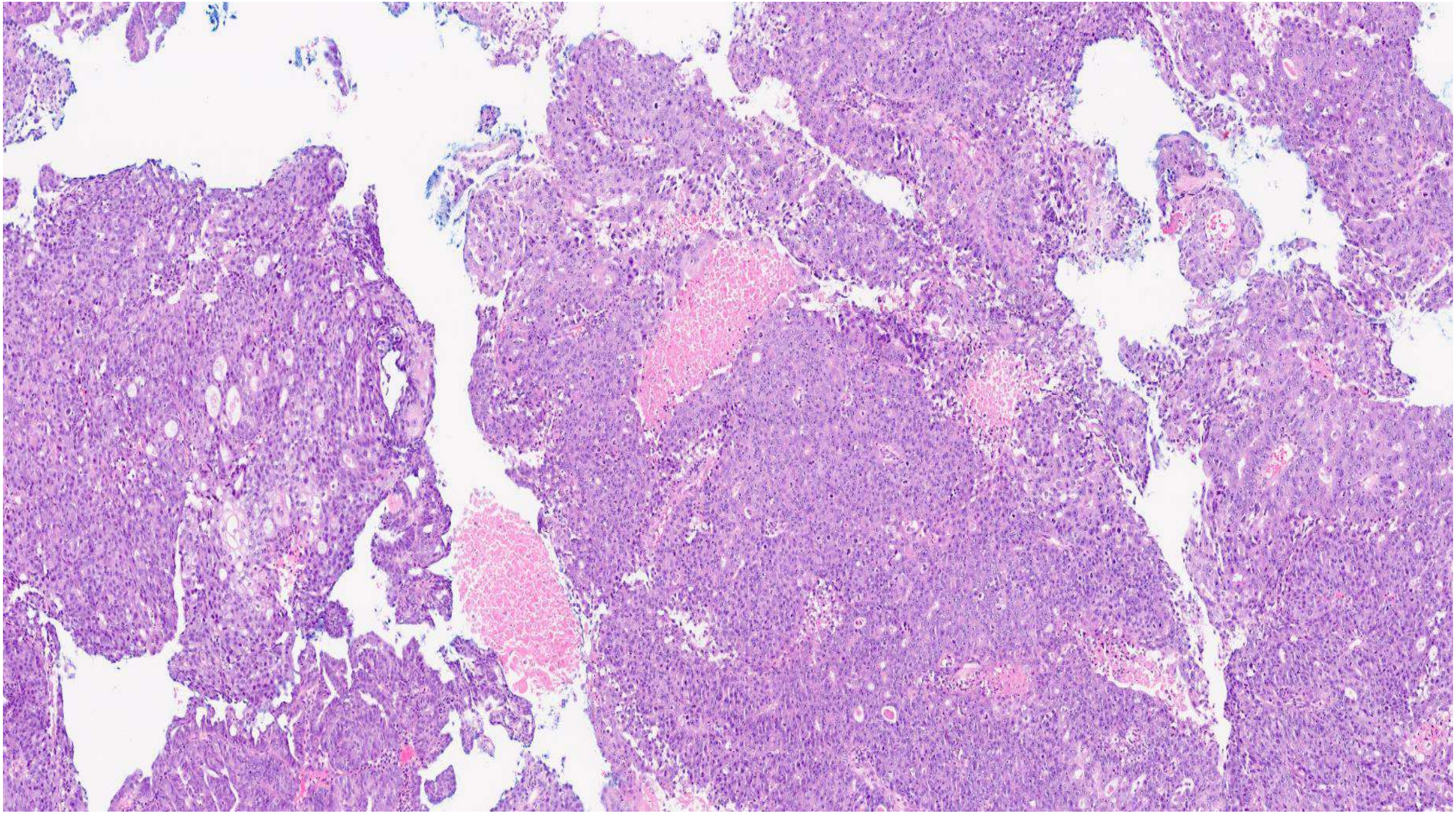

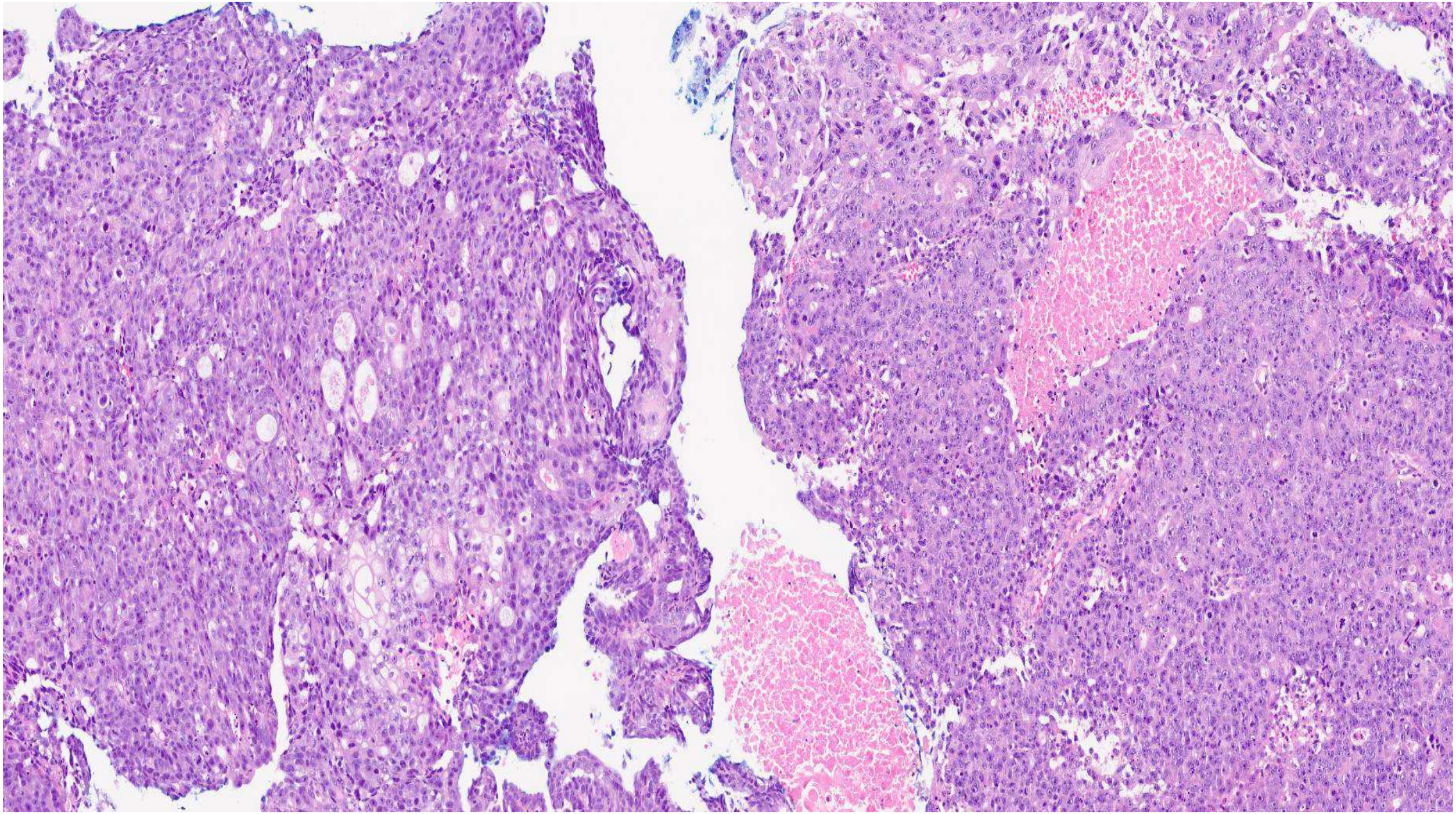

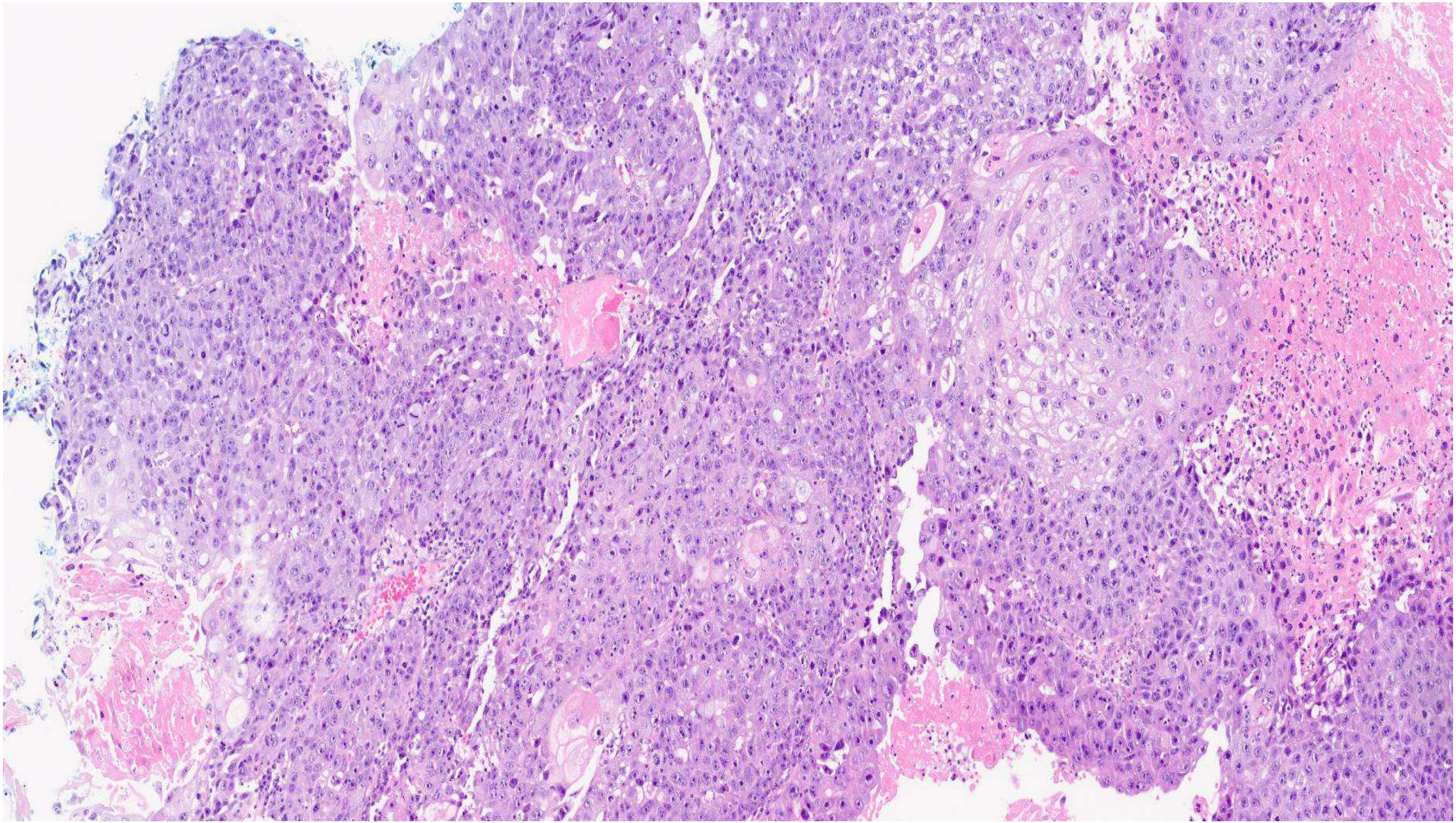

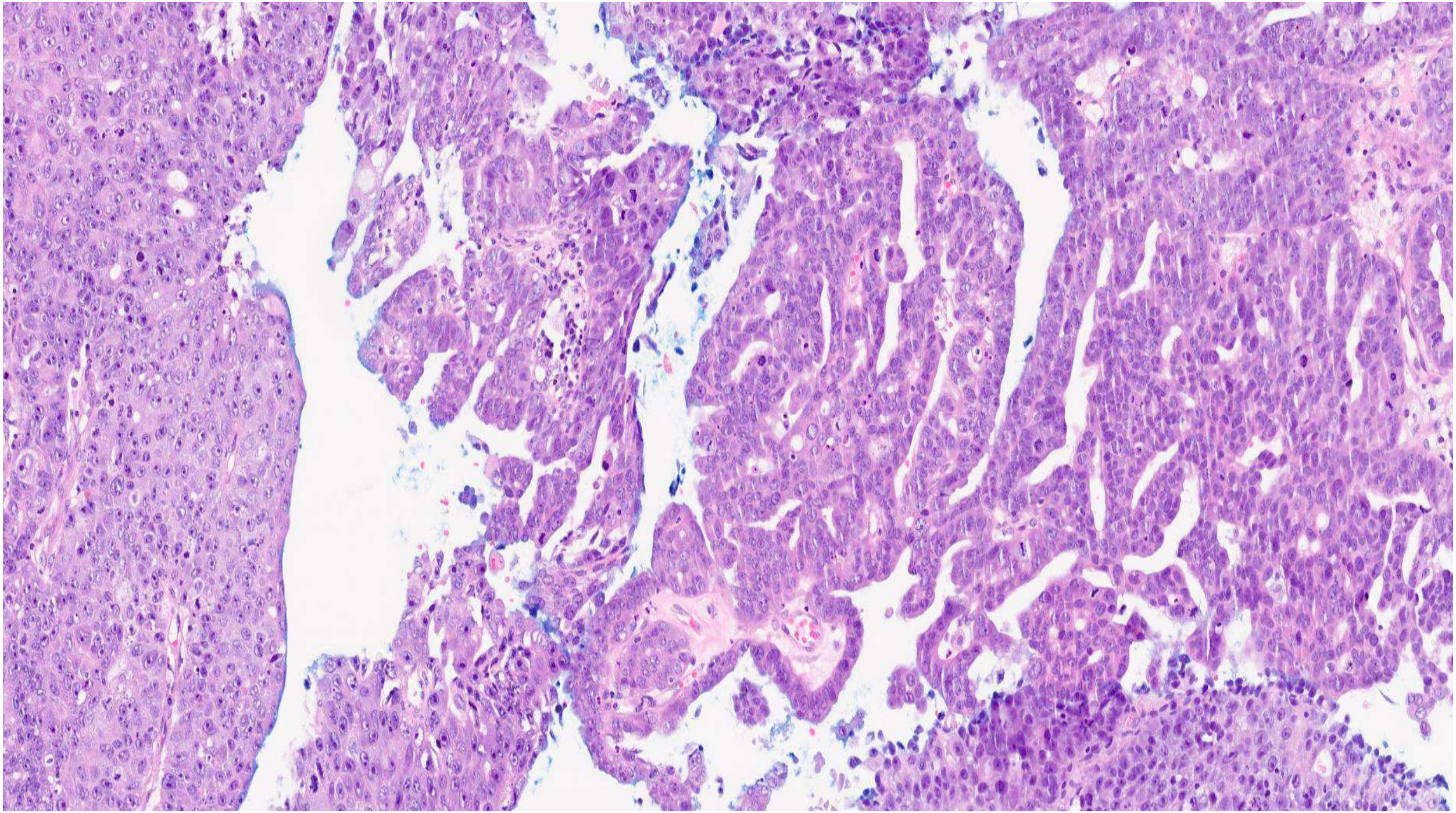

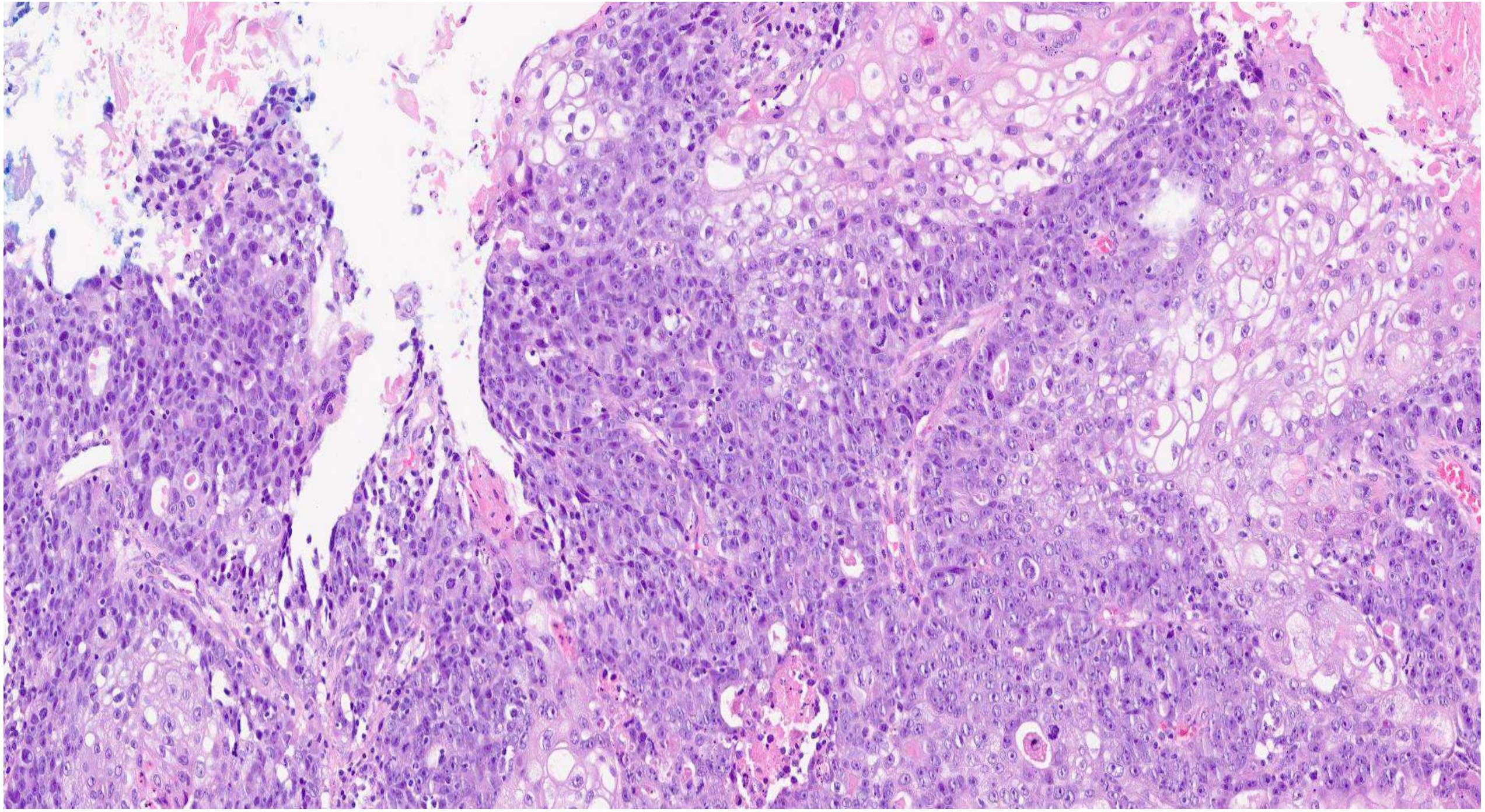

FAVOURED DIAGNOSIS ON MORPHOLGY

- Grade 3 endometrioid adenocarcinoma

IMMUNOHISTOCHEMISTRY

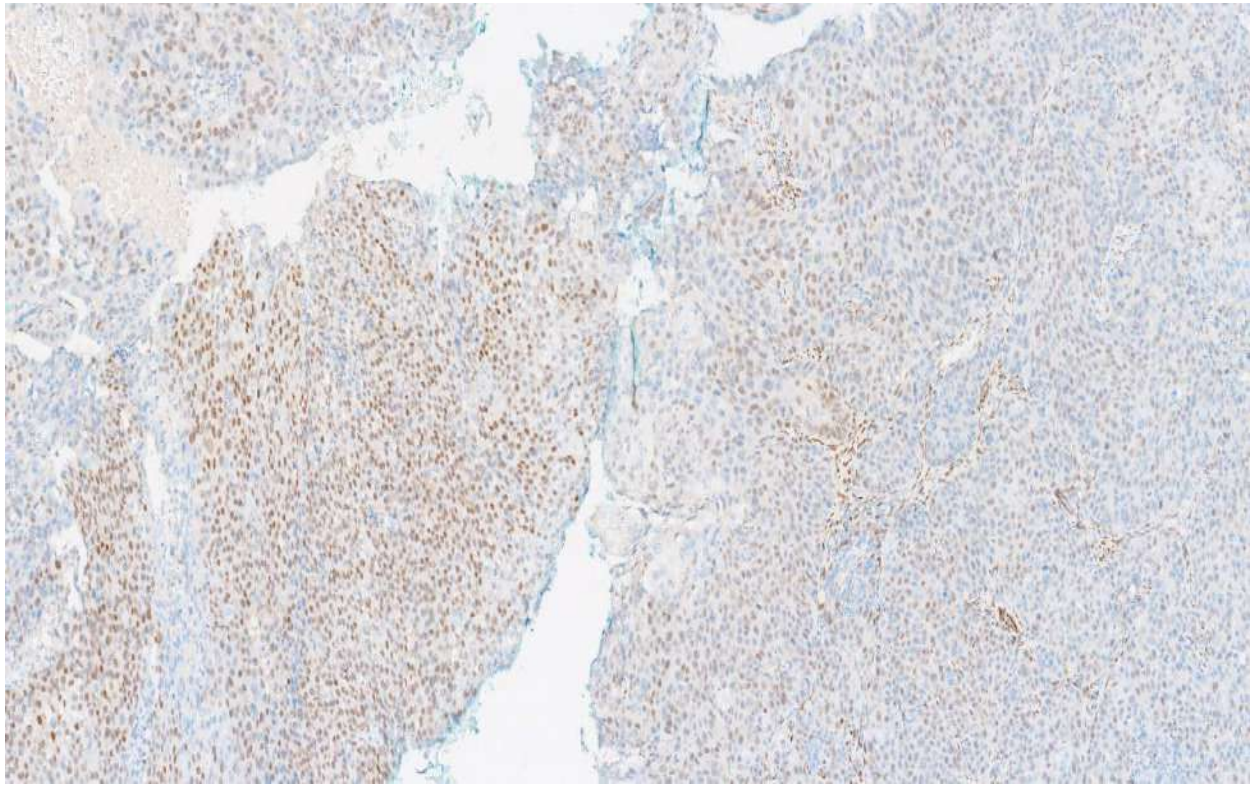

ER

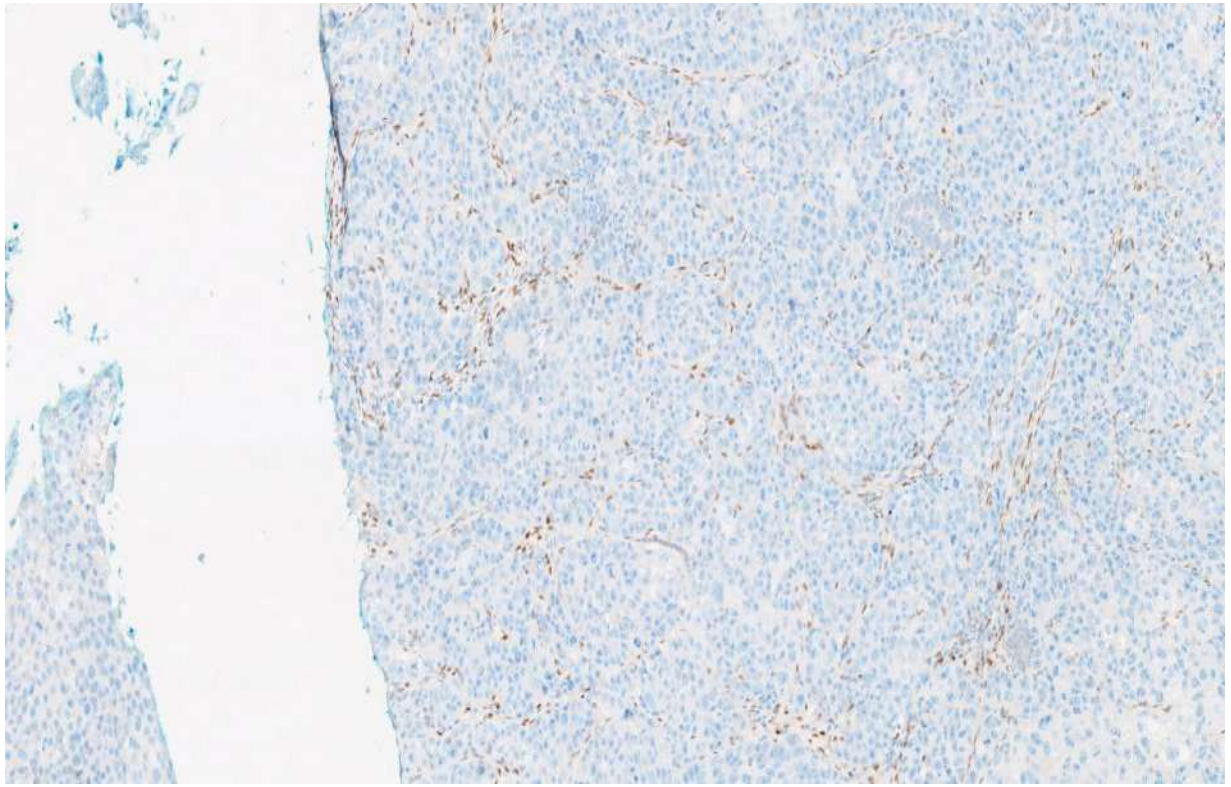

PR

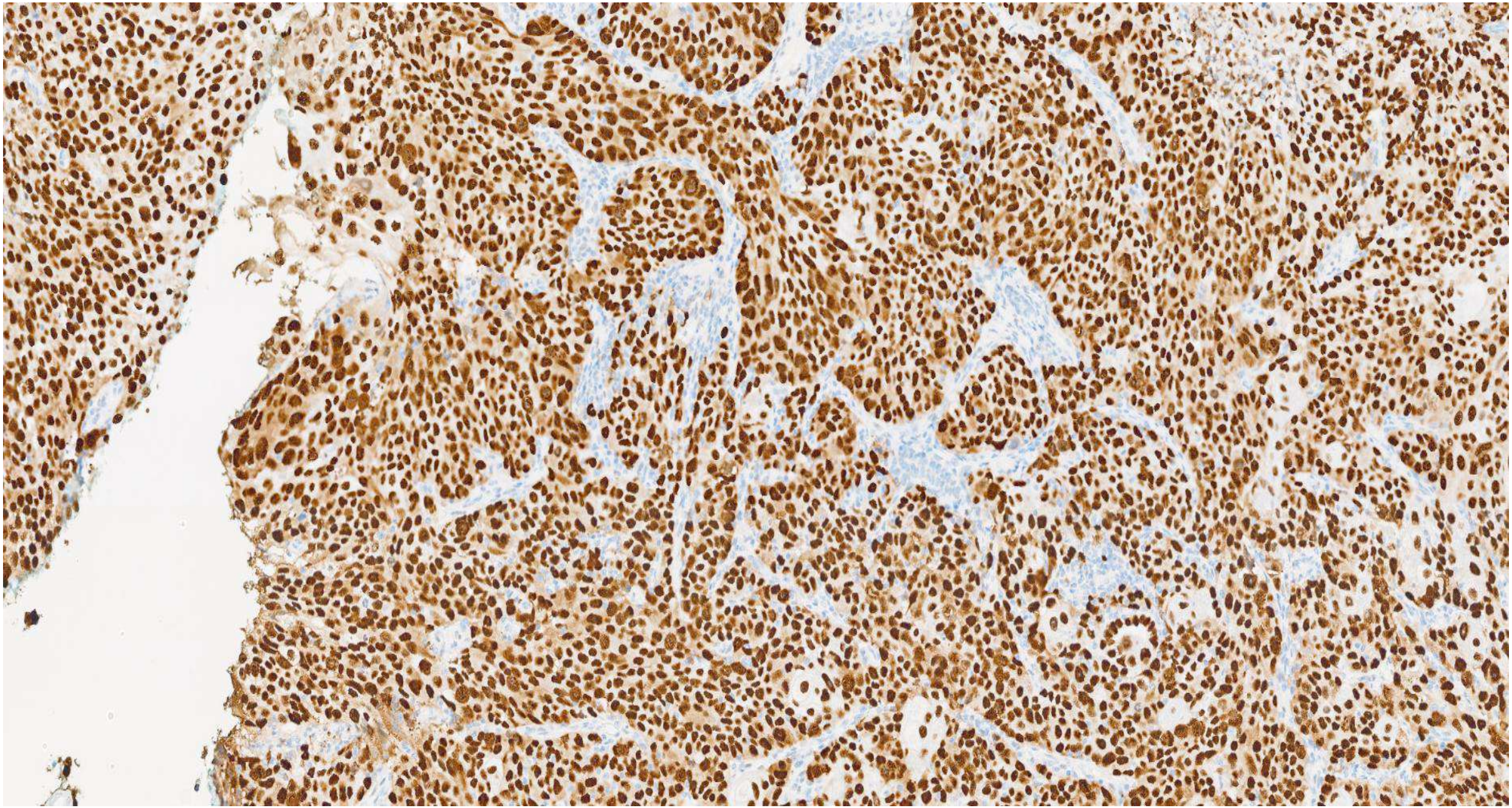

p53

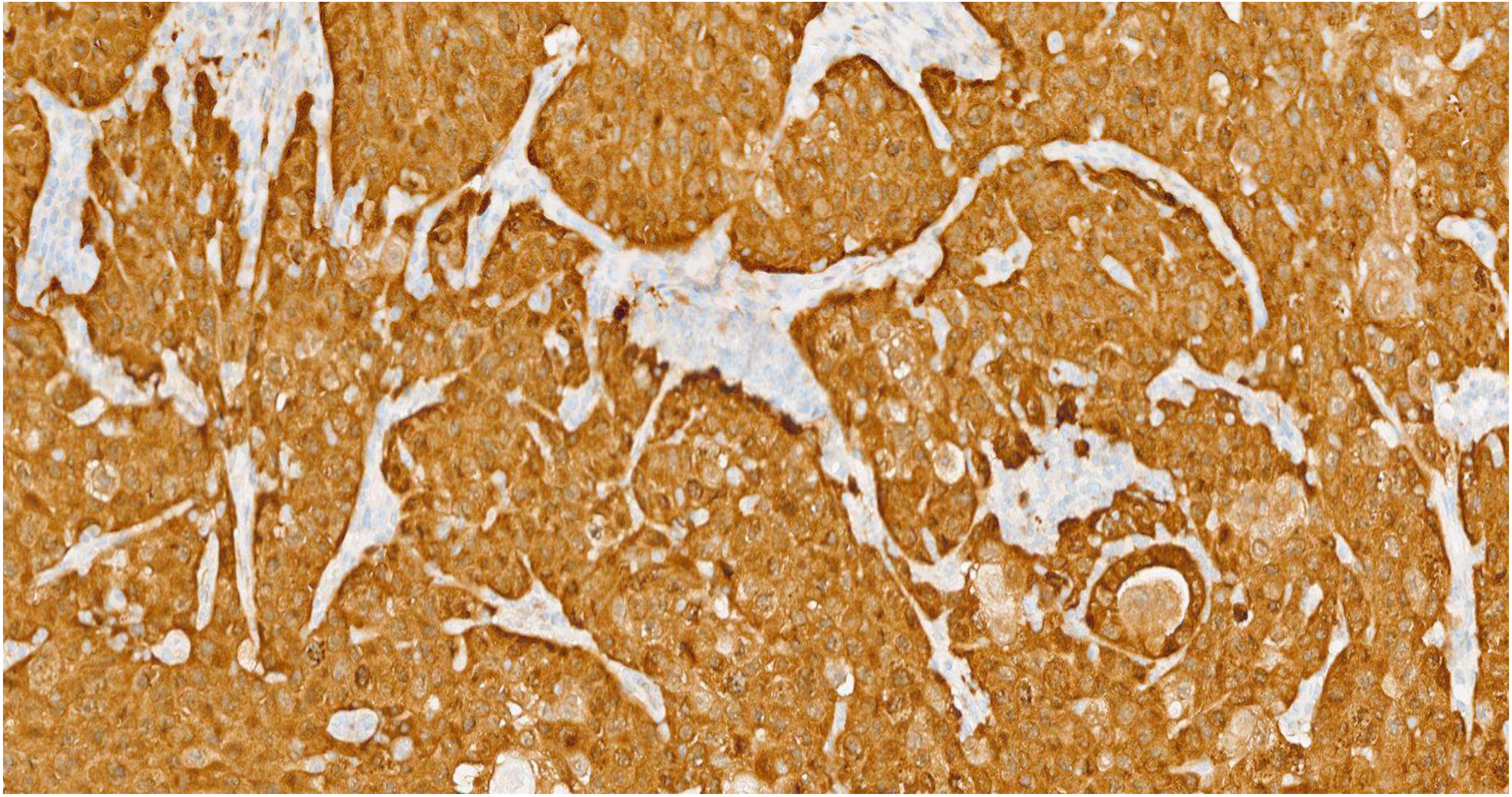

p16

P16 IN ENDOMETRIAL CARCINOMAS

- Diffuse block-type positivity in about 2/3 serous carcinomas
- Endometrioid adenocarcinomas (and other morphological types) almost never block-type positivity, although can be quite diffuse (even grade 3, although I think occasional exceptions)
- Many consider that mutation-type p53 together with block-type p16 pathognomonic of serous carcinoma in uterine corpus adenocarcinoma

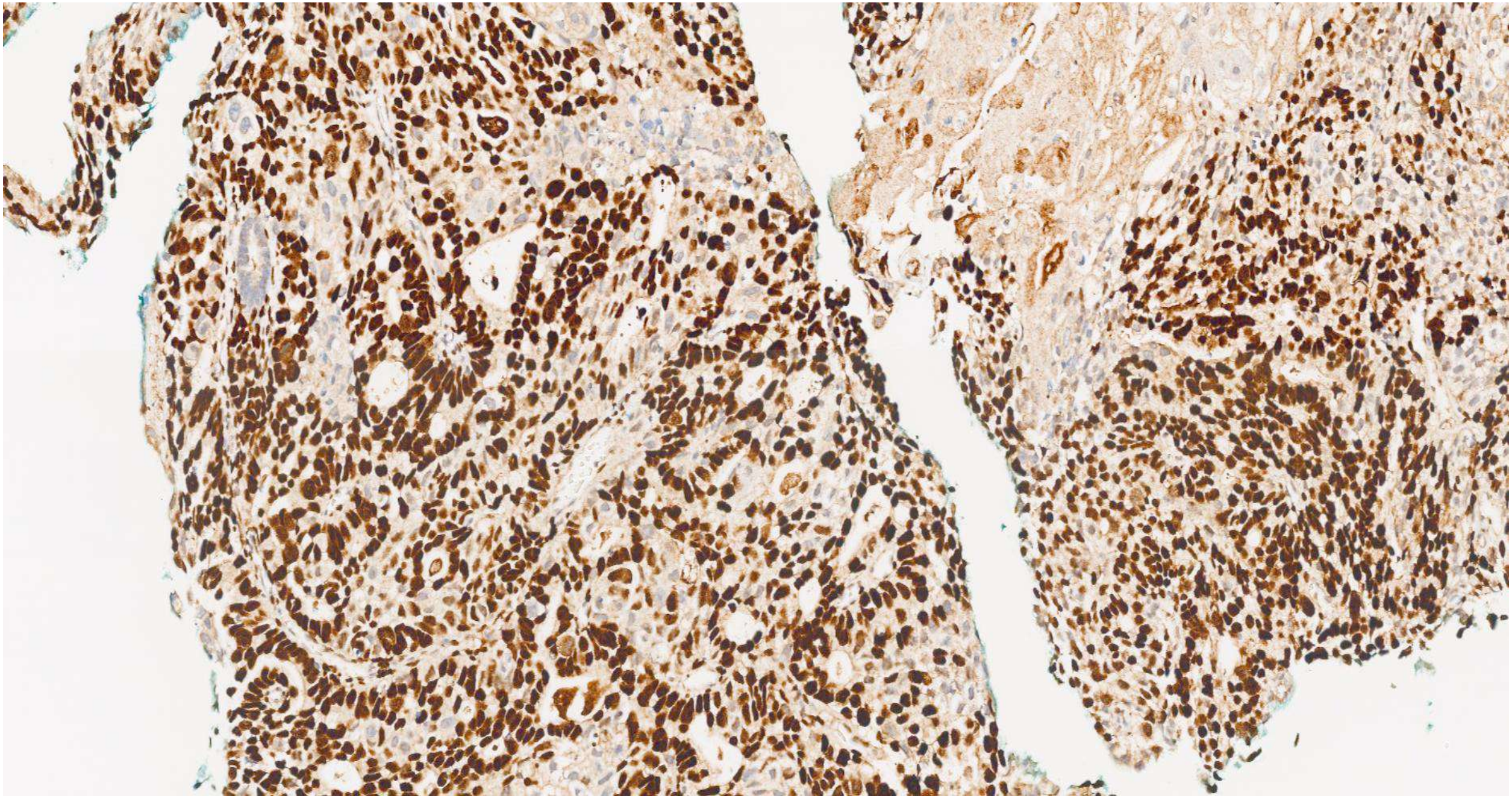

WT1

? DIAGNOSIS

- ? Grade 3 endometrioid adenocarcinoma
  - Squamous elements; predominantly solid and glandular architecture architecture in favour (soft pointer)
- ? Serous carcinoma
  - Block-type p16 in favour
  - Diffuse WT1 in favour
  - Relatively weak and focal ER and negative PR in favour

MY DIAGNOSIS

- Serous carcinoma with squamous elements
- No adnexal tumour on subsequent hysterectomy
- NGS- *TP53* mutation; no other mutations more characteristic of endometrioid adenocarcinoma

HIGH-GRADE SEROUS NEOPLASIA IN ENDOMETRIUM AND TUBE/ OVARY

- WT1 more likely to be positive in tubo-ovarian HGSC (95%) than endometrial serous carcinoma
- if WT1 negative, doubt whether tubo-ovarian HGSC
- PMID: 25033726 (44% of endometrial serous carcinomas WT1 positive)

DOGMA

- Serous carcinomas do not contain squamous elements; squamous elements in an endometrial carcinoma are pathognomonic of endometrioid adenocarcinoma or carcinosarcoma
- I have seen squamous elements in a few endometrial serous carcinomas and tubo-ovarian HGSCs

CASE 2: NOT ALL ADENOCARCINOMAS WITH CLEAR CELLS ARE CLEAR CELL CARCINOMA

- F 60
- Postmenopausal bleeding

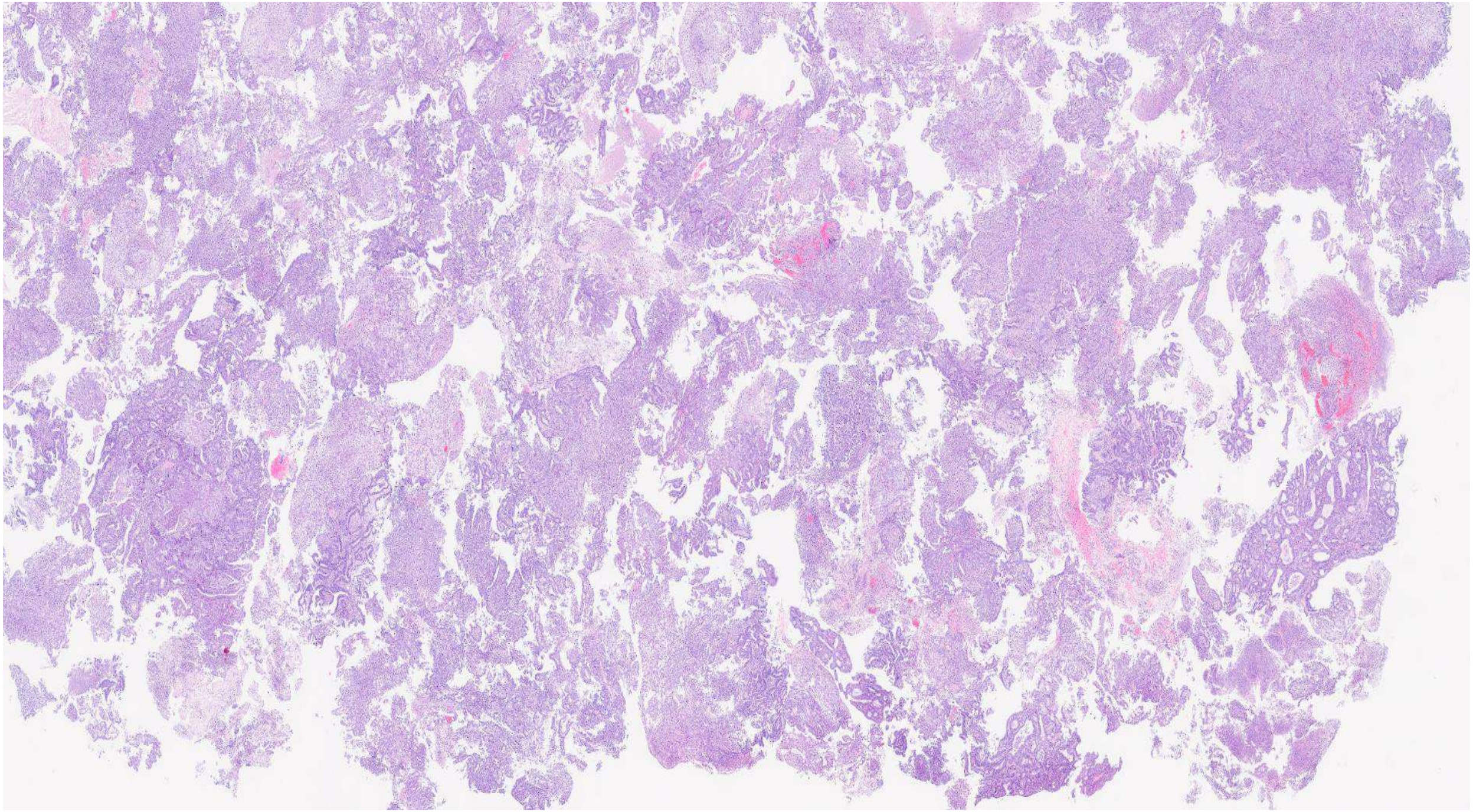

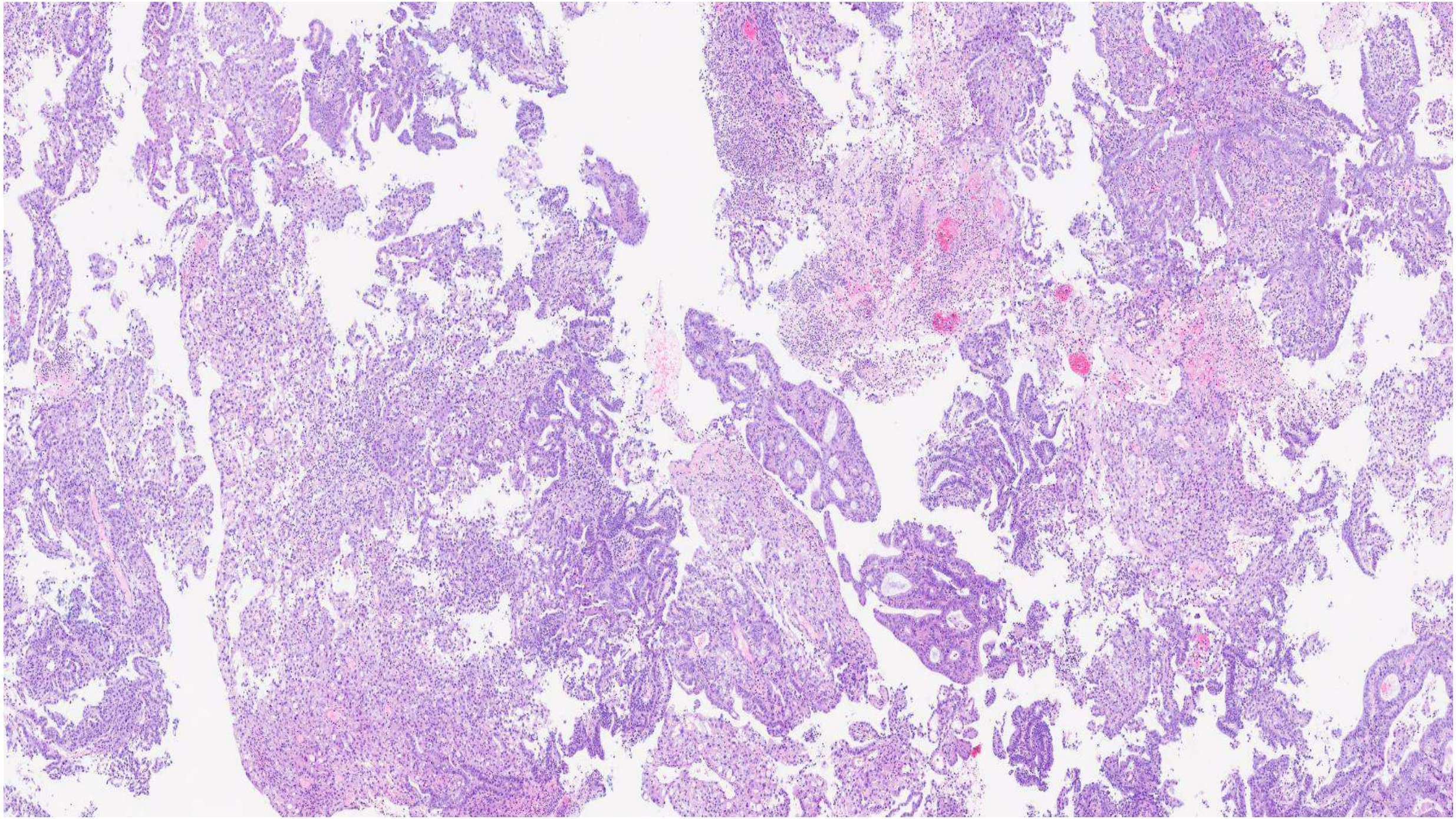

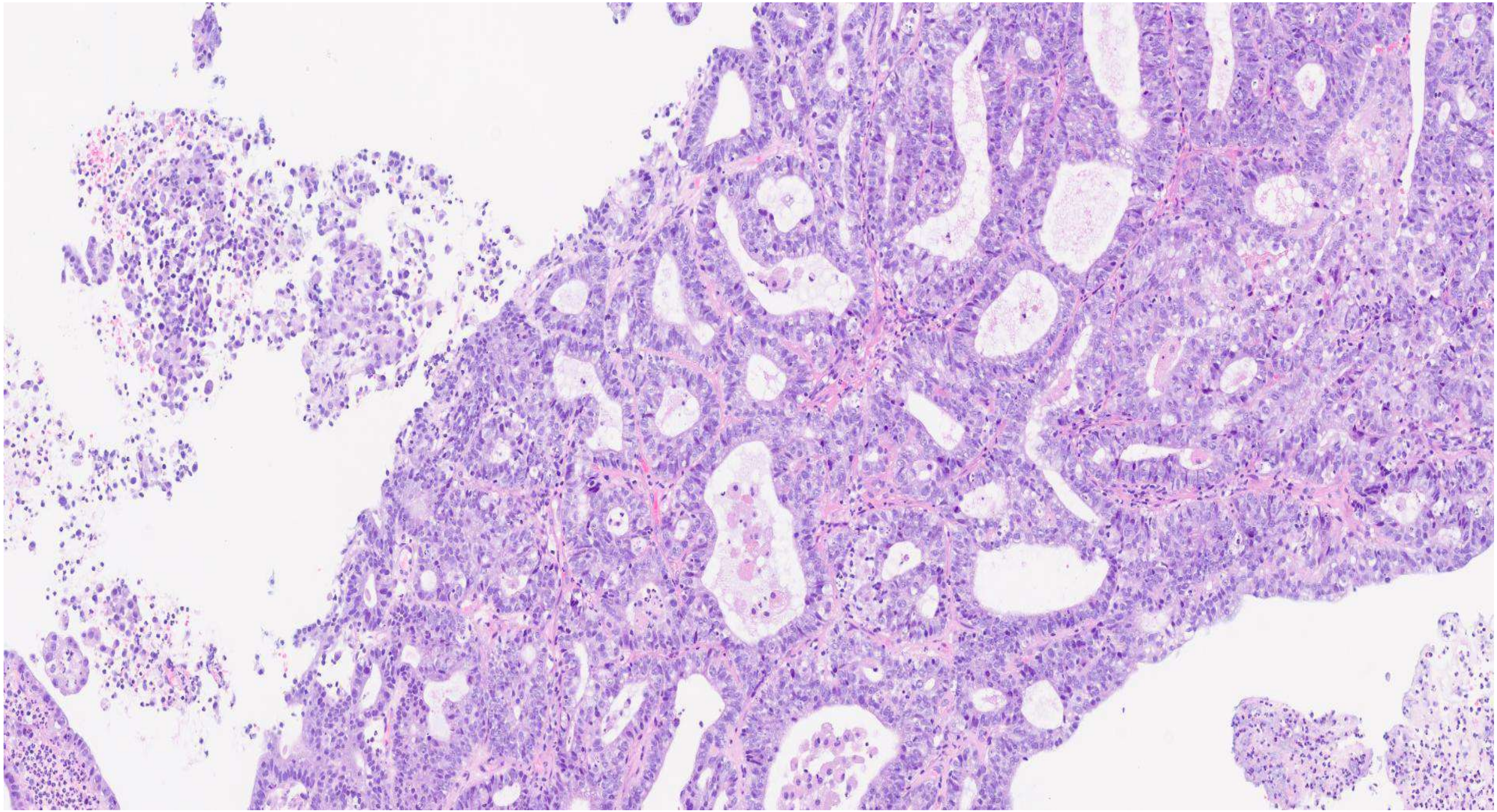

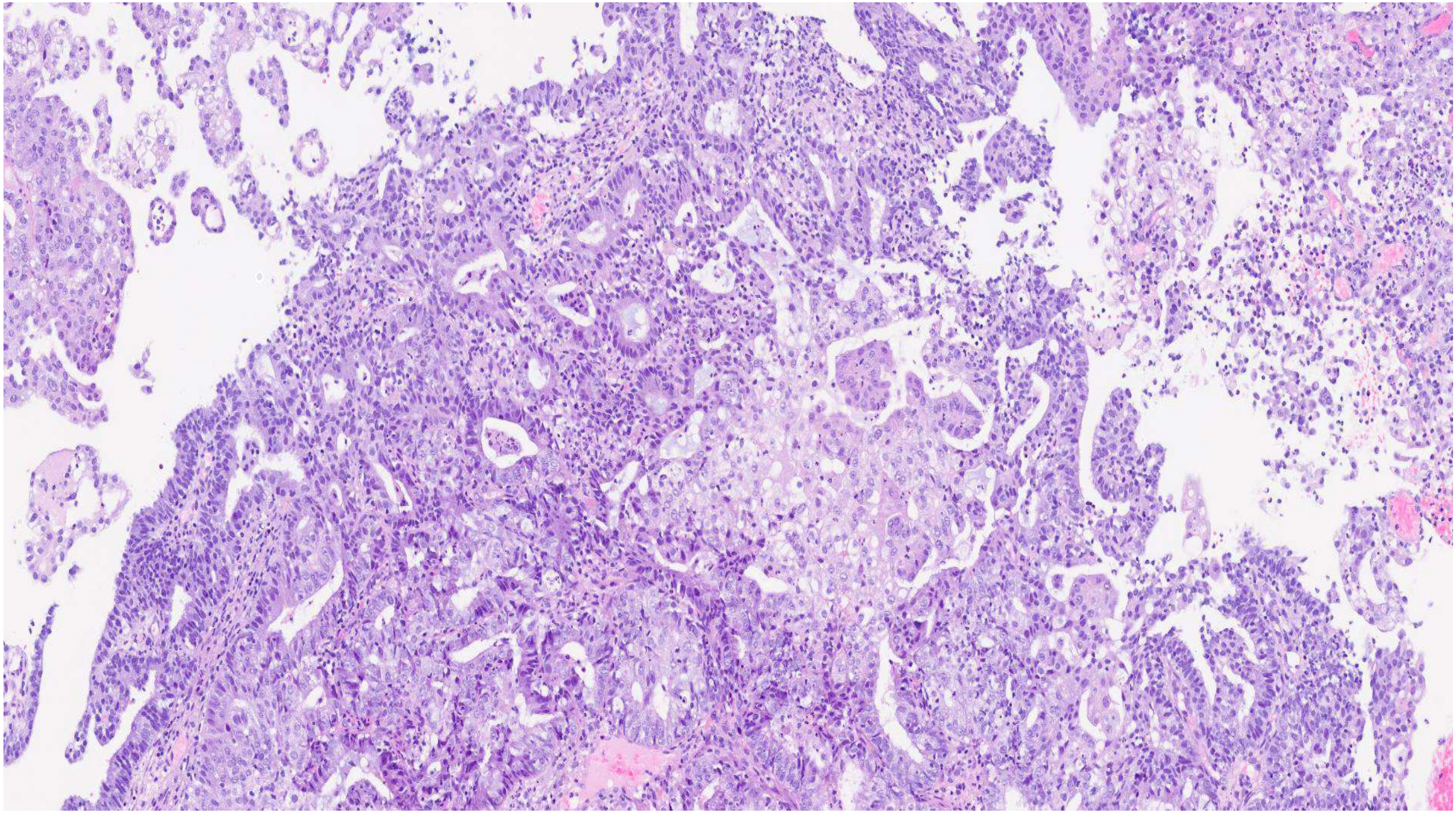

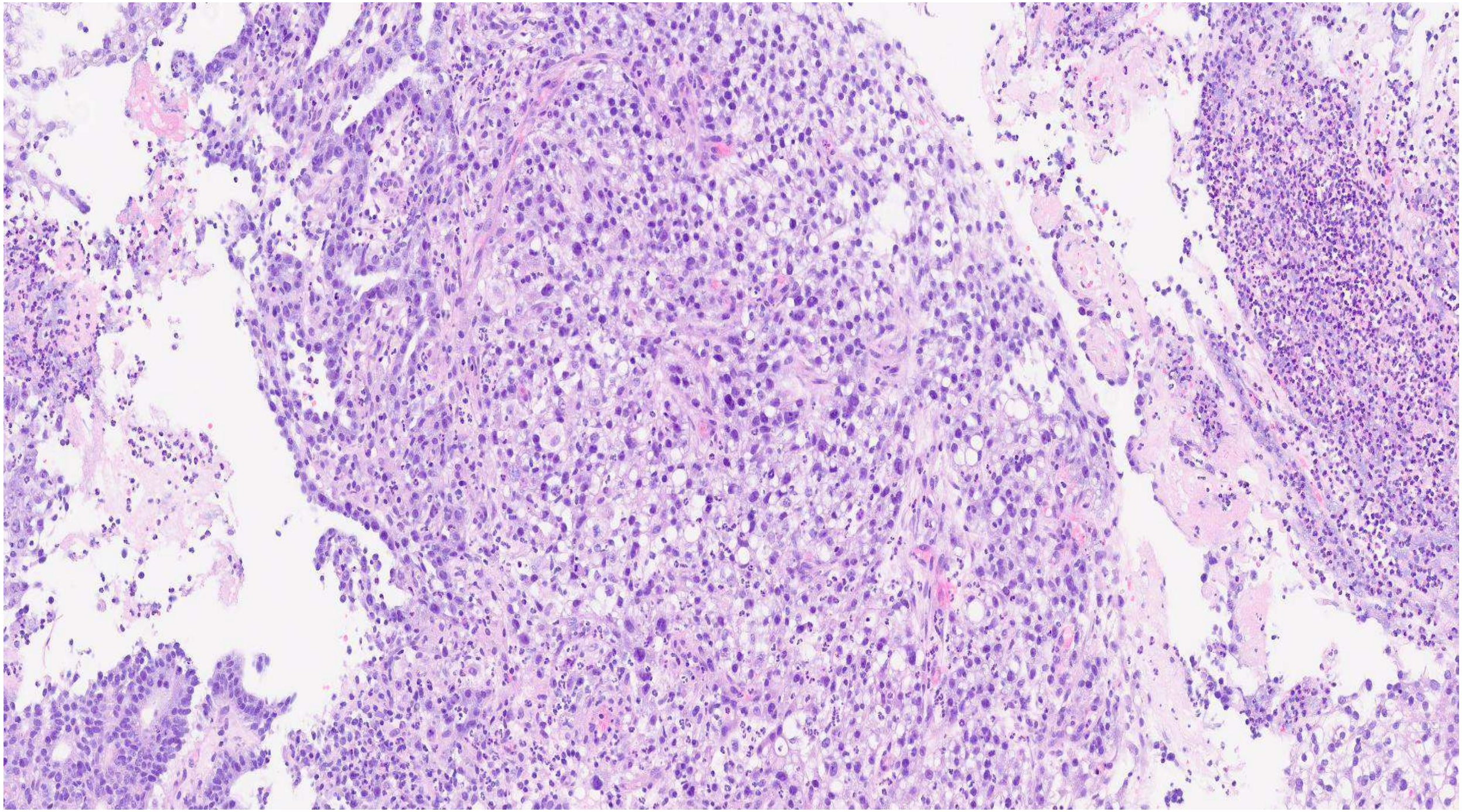

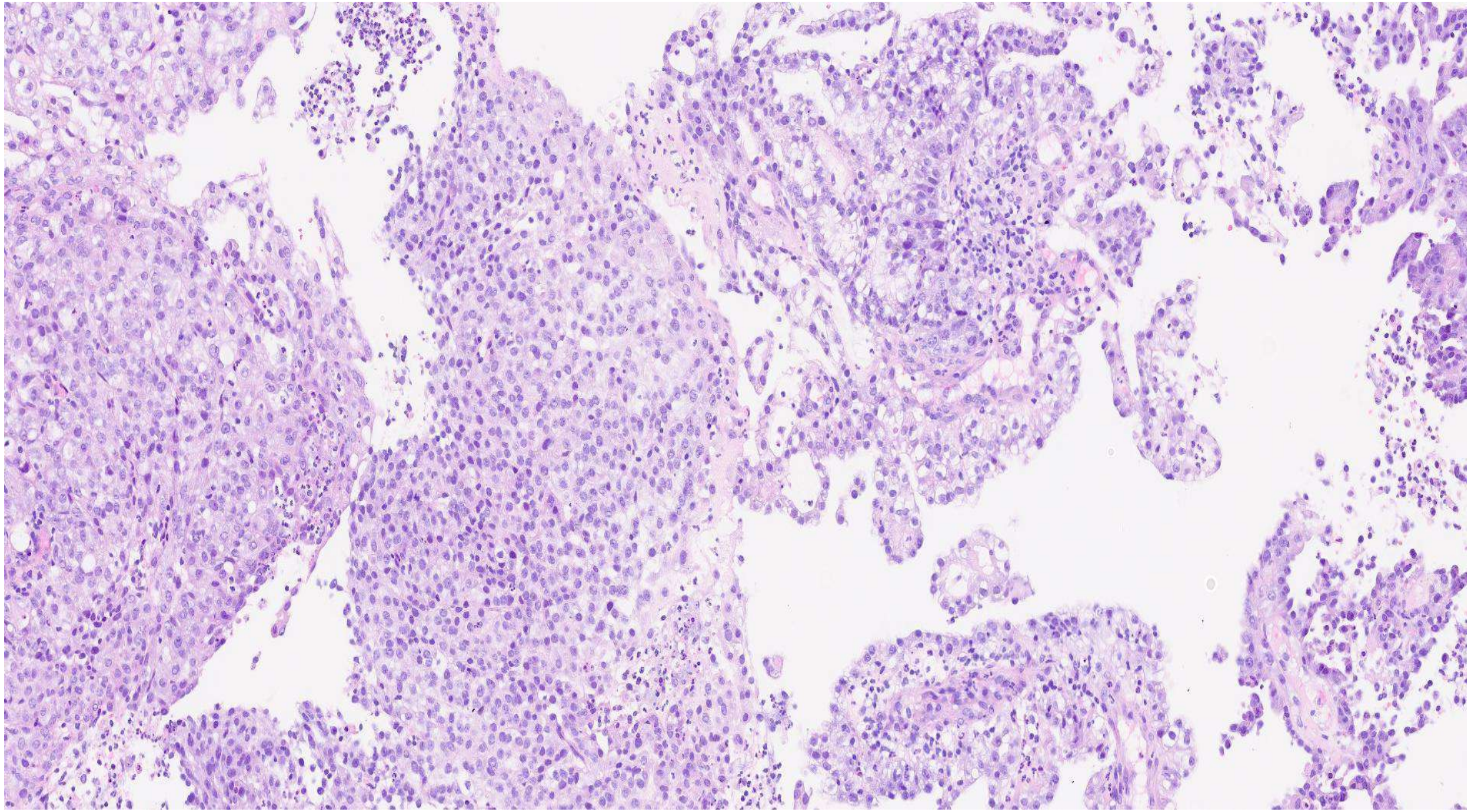

IMMUNOHISTOCHEMISTRY

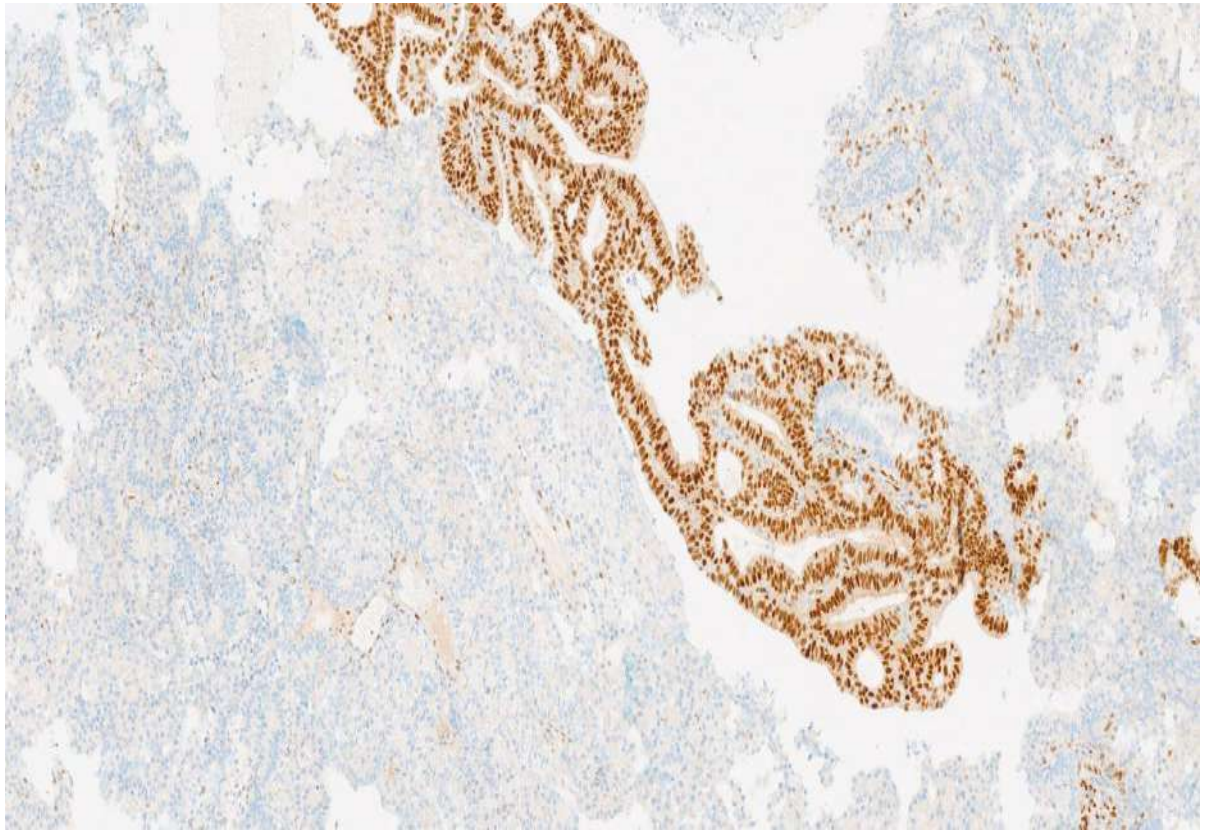

ER

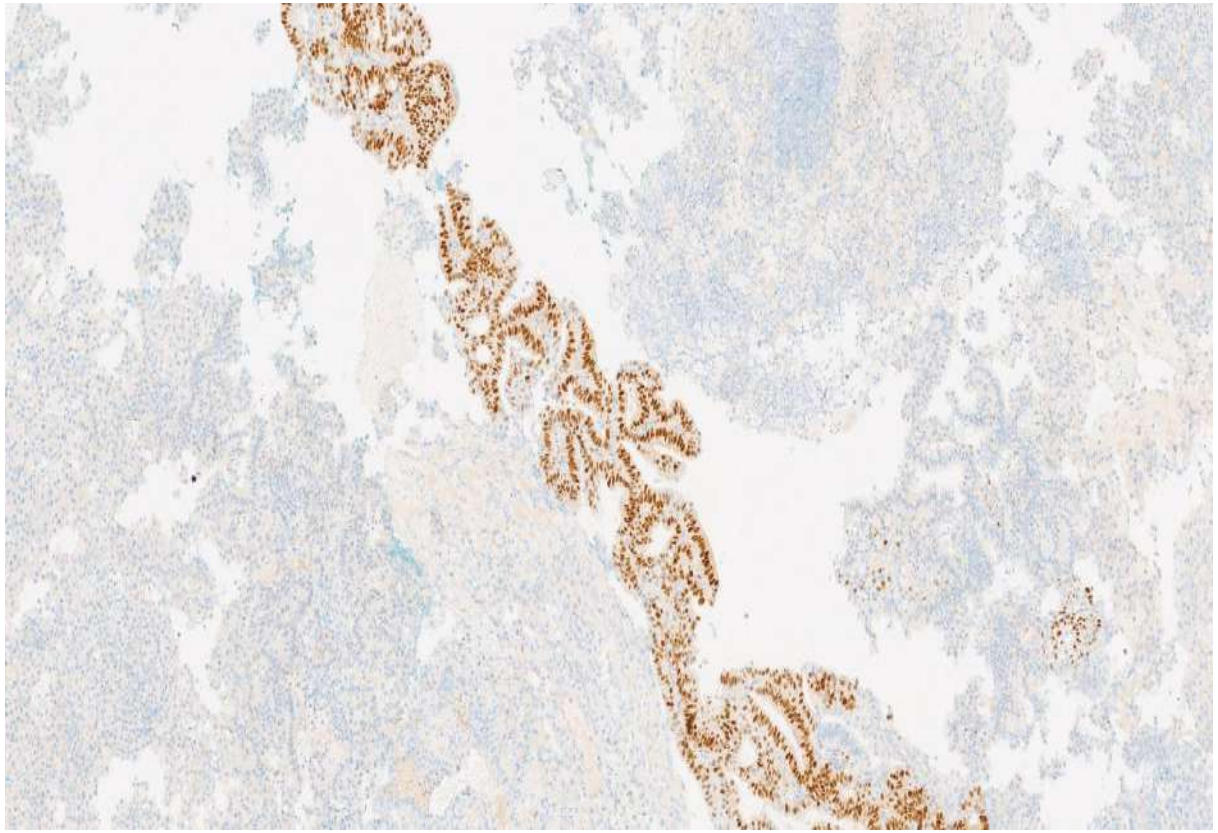

PR

IMMUNOHISTOCHEMISTRY- p53

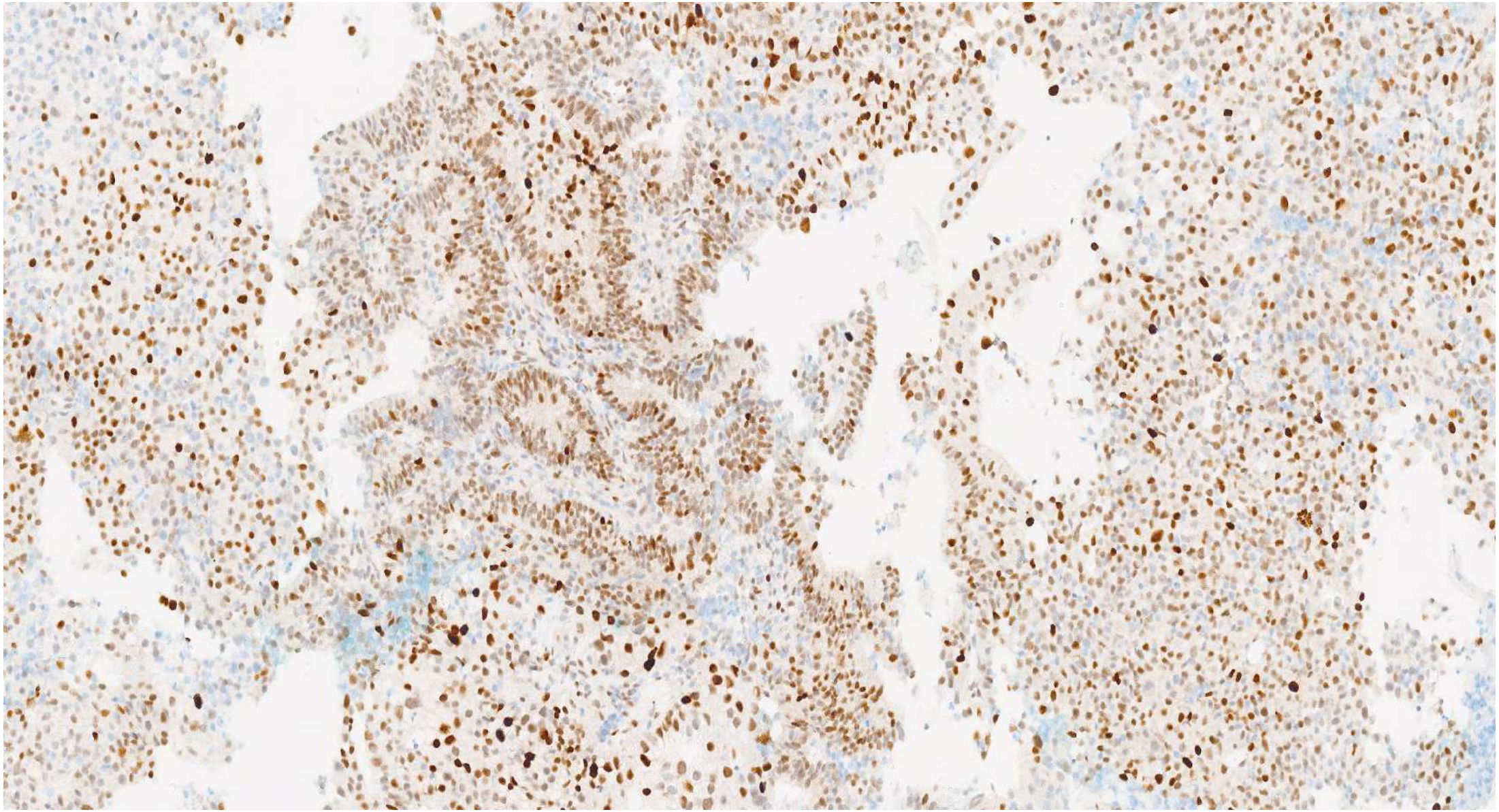

IMMUNOHISTOCHEMISTRY- NAPSIN A

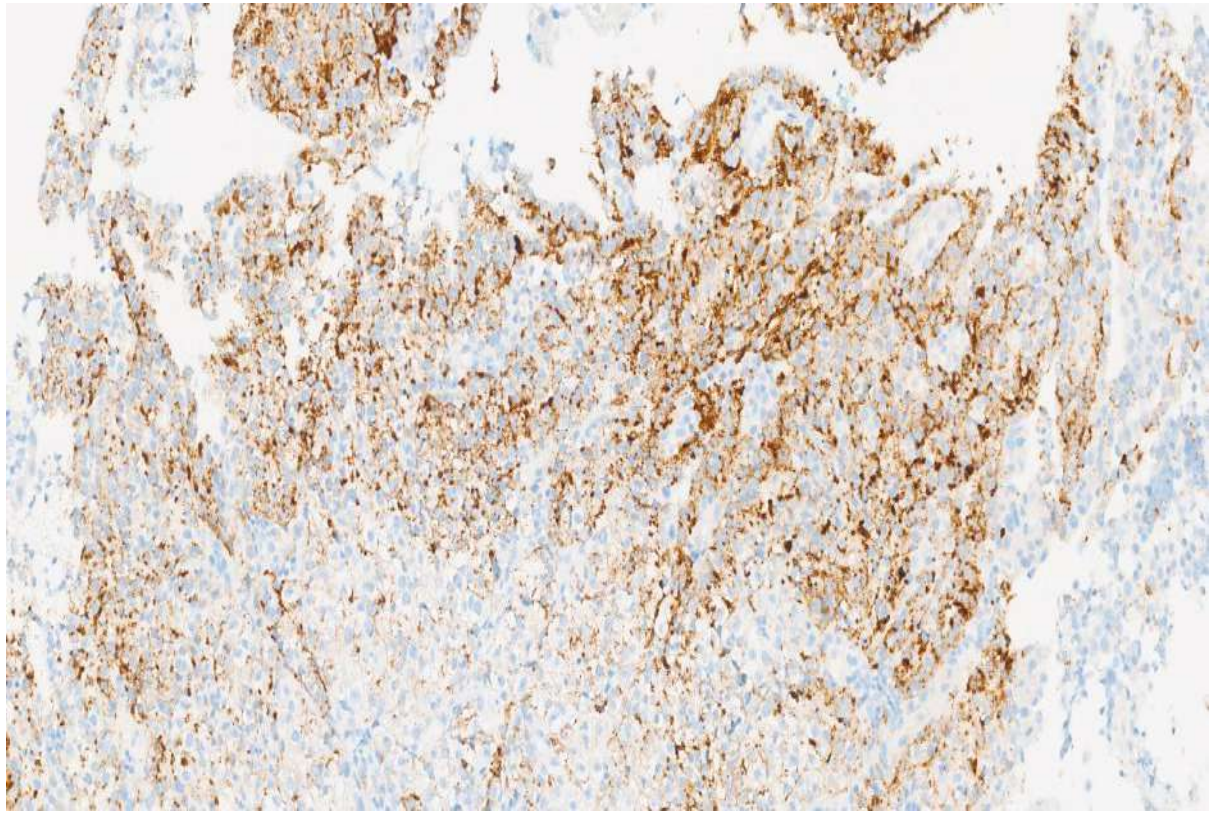

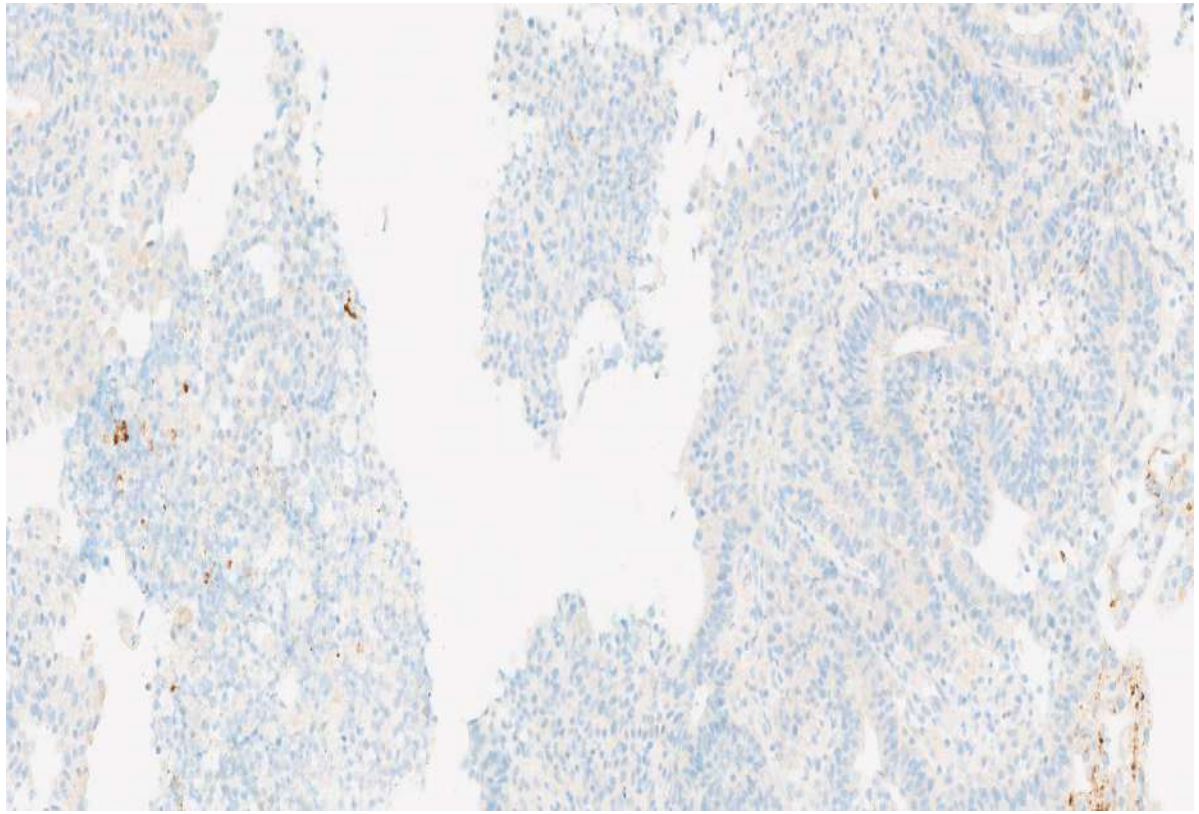

IMMUNOHISTOCHEMISTRY- HNF 1 BETA

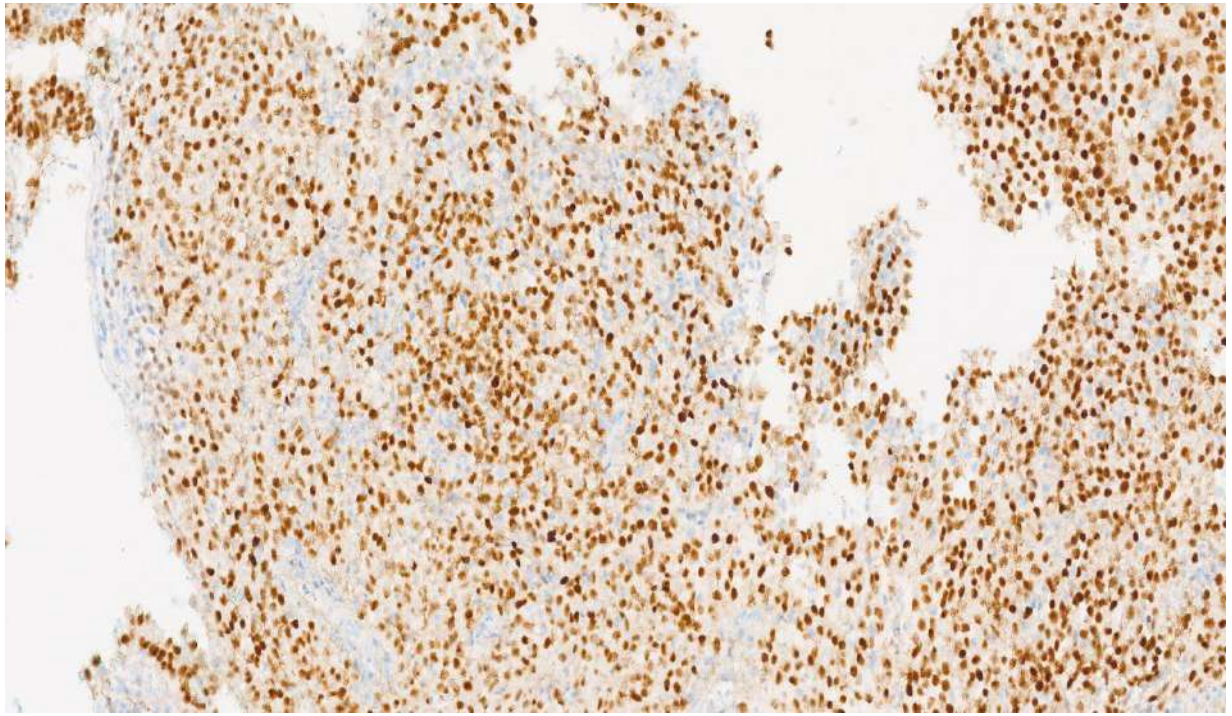

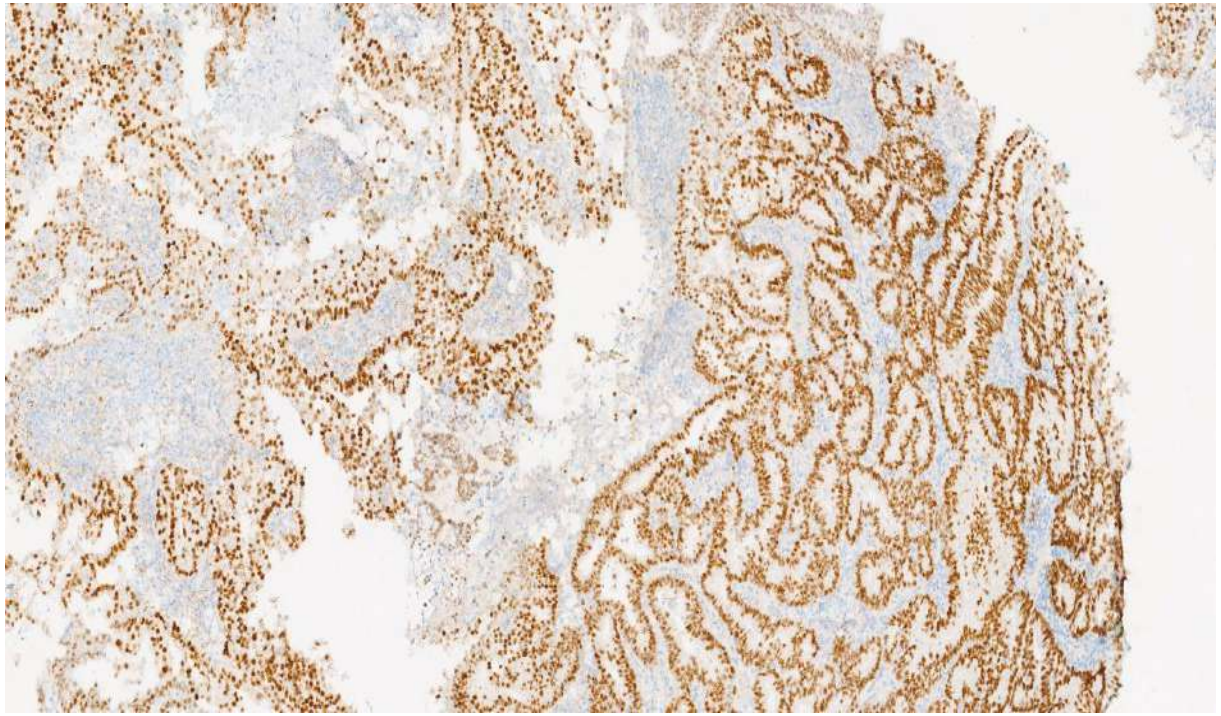

IMMUNOHISTOCHEMISTRY

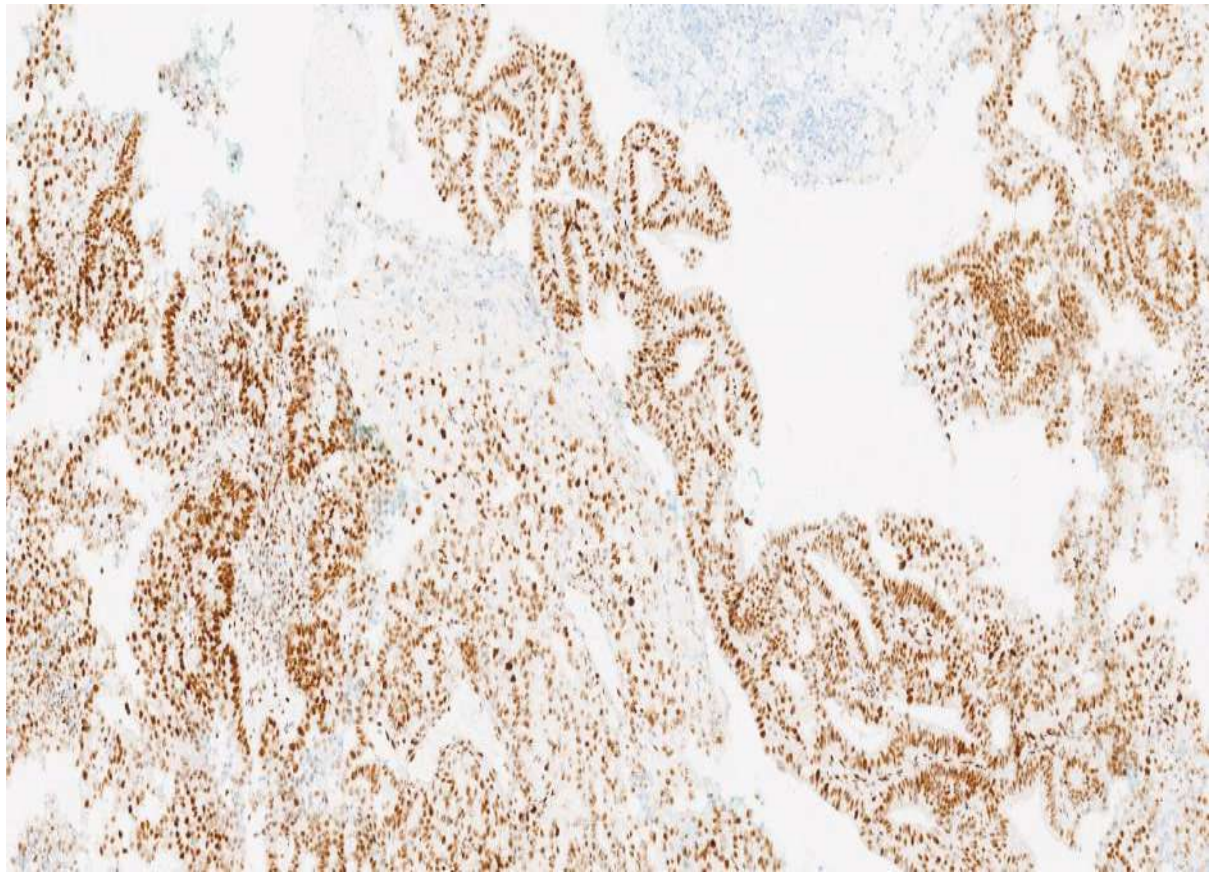

MLH1

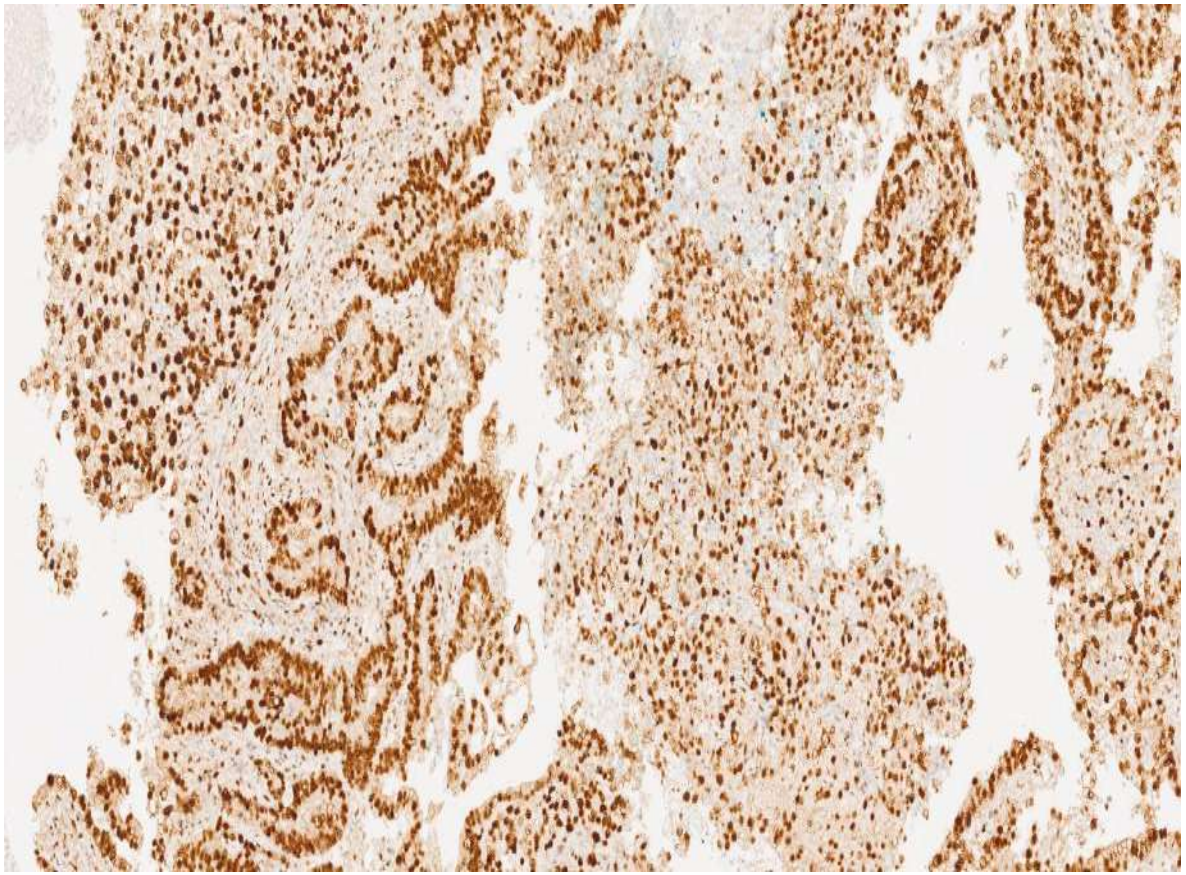

PMS2

IMMUNOHISTOCHEMISTRY

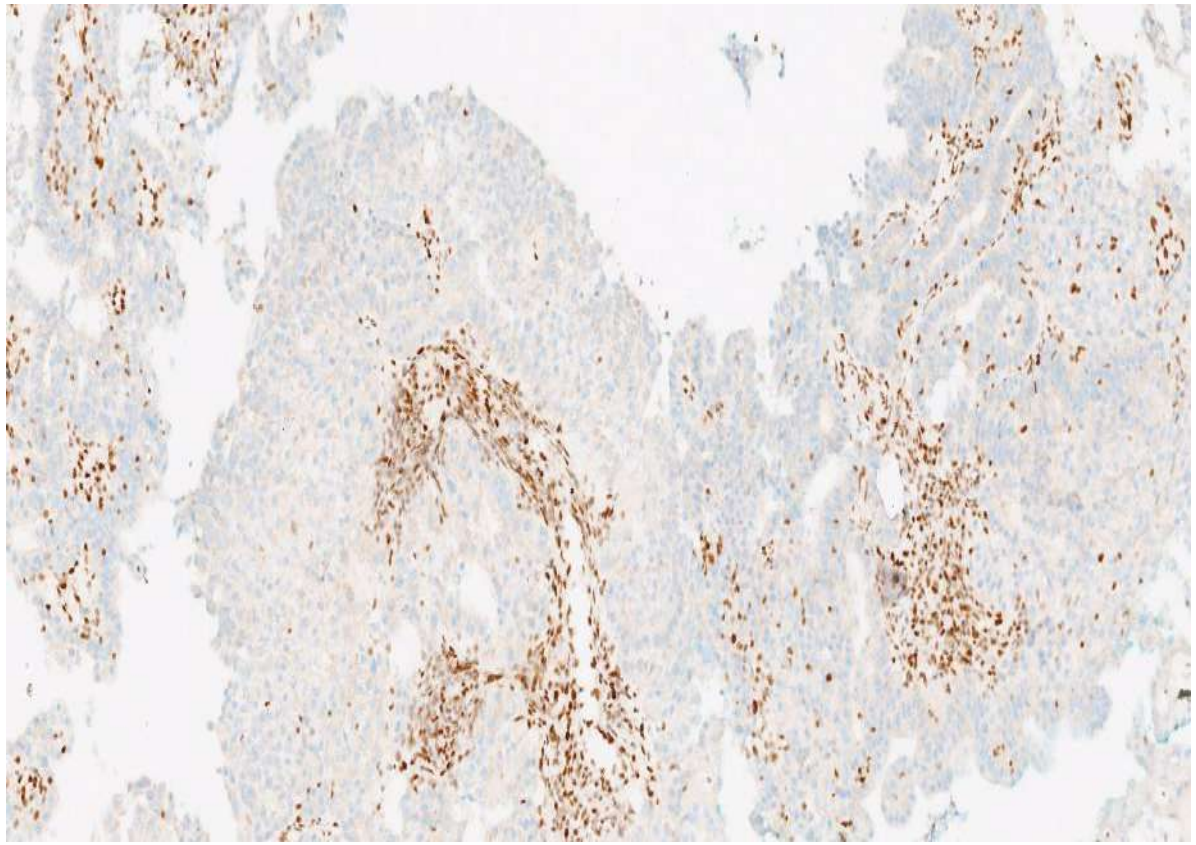

MSH2

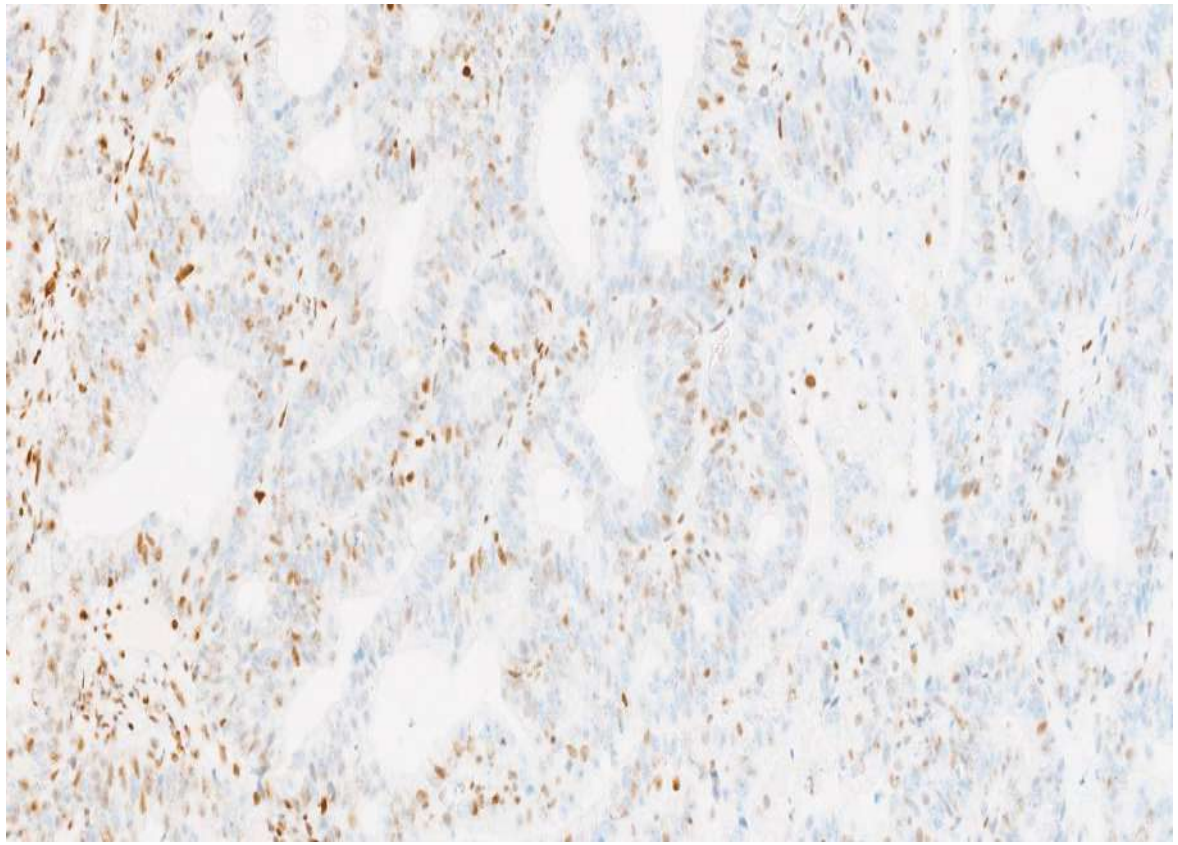

MSH6

DIAGNOSIS

- Mixed endometrioid and clear cell carcinoma
- Automatically grade 3
- MMR deficient/MSI/hypermutated TCGA molecular group

PMID 30550482

International Journal of Gynecological Pathology
38:S25–S39, Lippincott Williams & Wilkins, Baltimore
Copyright © 2018 by the International Society of Gynecological Pathologists

Other

Issues in the Differential Diagnosis of Uterine Low-grade Endometrioid Carcinoma, Including Mixed Endometrial Carcinomas: Recommendations from the International Society of Gynecological Pathologists

Joseph T. Rabban, M.D., M.P.H., C. Blake Gilks, M.D., Anais Malpica, M.D., Xavier Matias-Guiu, M.D., Khush Mittal, M.D., George L. Mutter, M.D., Esther Oliva, M.D., Vinita Parkash, M.D., Brigitte M. Ronnett, M.D., Paul Staats, M.D., Colin J.R. Stewart, M.D., and W. Glenn McCluggage, M.D.

Summary: This article provides practical recommendations developed from the International Society of Gynecological Pathologists Endometrial Carcinoma Project to address 4 issues that may arise in the diagnosis of uterine corpus low-grade endometrioid carcinoma: (1) The distinction between atypical hyperplasia and low-grade endometrioid carcinoma. (2) The distinction between low-grade endometrioid carcinoma and serous carcinoma. (3) The distinction between corded and hyalinized or spindle cell variants of low-grade endometrioid carcinoma and carcinosarcoma. (4) The diagnostic criteria for mixed endometrial carcinomas, a rare entity that should be diagnosed only after exclusion of a spectrum of tumors including morphologic variants of endometrioid carcinoma, dedifferentiated endometrial carcinoma, carcinosarcoma, and endometrial carcinomas with ambiguous morphology. **Key Words:** Endometrial cancer—Atypical hyperplasia—Serous carcinoma—Mixed carcinoma.

ISGyP RECOMMENDATIONS: MIXED ENDOMETRIAL CARCINOMAS

- Usually mixed endometrioid and serous or mixed endometrioid and clear cell
- Stresses that these are uncommon (more common than in ovary) and that rigorous criteria should be used for diagnosis
- Stresses that should only be diagnosed after exclusion of morphological variants of pure endometrioid, serous and clear cell carcinoma, dedifferentiated carcinoma, carcinomas with ambiguous features, carcinosarcomas
- Mixed endometrial carcinomas- don’t need any minimum percentage of minor component (WHO 2014- 5%; WHO 2020- amended to reflect ISGyP recommendations)
- Immunohistochemistry recommended and each component should have expected immunophenotype
- List each type of carcinoma and percentage of each component
- Automatically high-grade
- Mixed endometrioid and clear cell often associated with MMR abnormalities

ENDOMETRIOID CARCINOMA WITH CLEAR CELL CHANGE

- This is a difficult area (endometrium and ovary)
- Clear cell change may involve squamous or glandular elements
- Secretory variant of endometrioid carcinoma (subnuclear and/ or supranuclear vacuolation)
- May result in misdiagnosis as clear cell carcinoma or component of clear cell carcinoma
- Clear cells areas in endometrioid carcinomas are often positive with HNF1 beta (very non-specific marker which is positive in many carcinomas) and rarely may be Napsin A positive

SECRETORY ENDOMETRIOID CARCINOMA

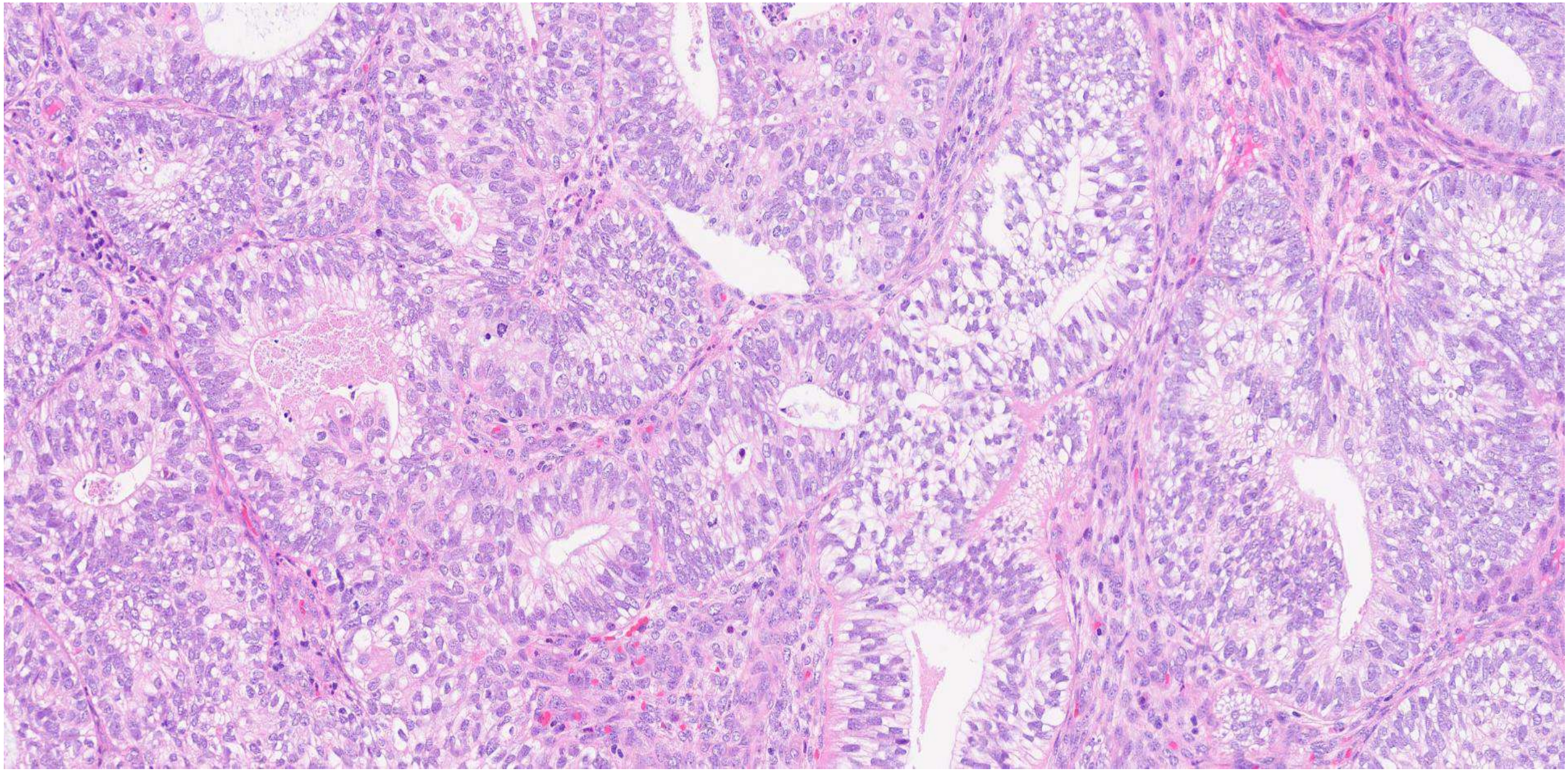

CLEAR CELL CHANGE IN SQUAMOUS ELEMENTS IN ENDOMETRIOID CARCINOMA

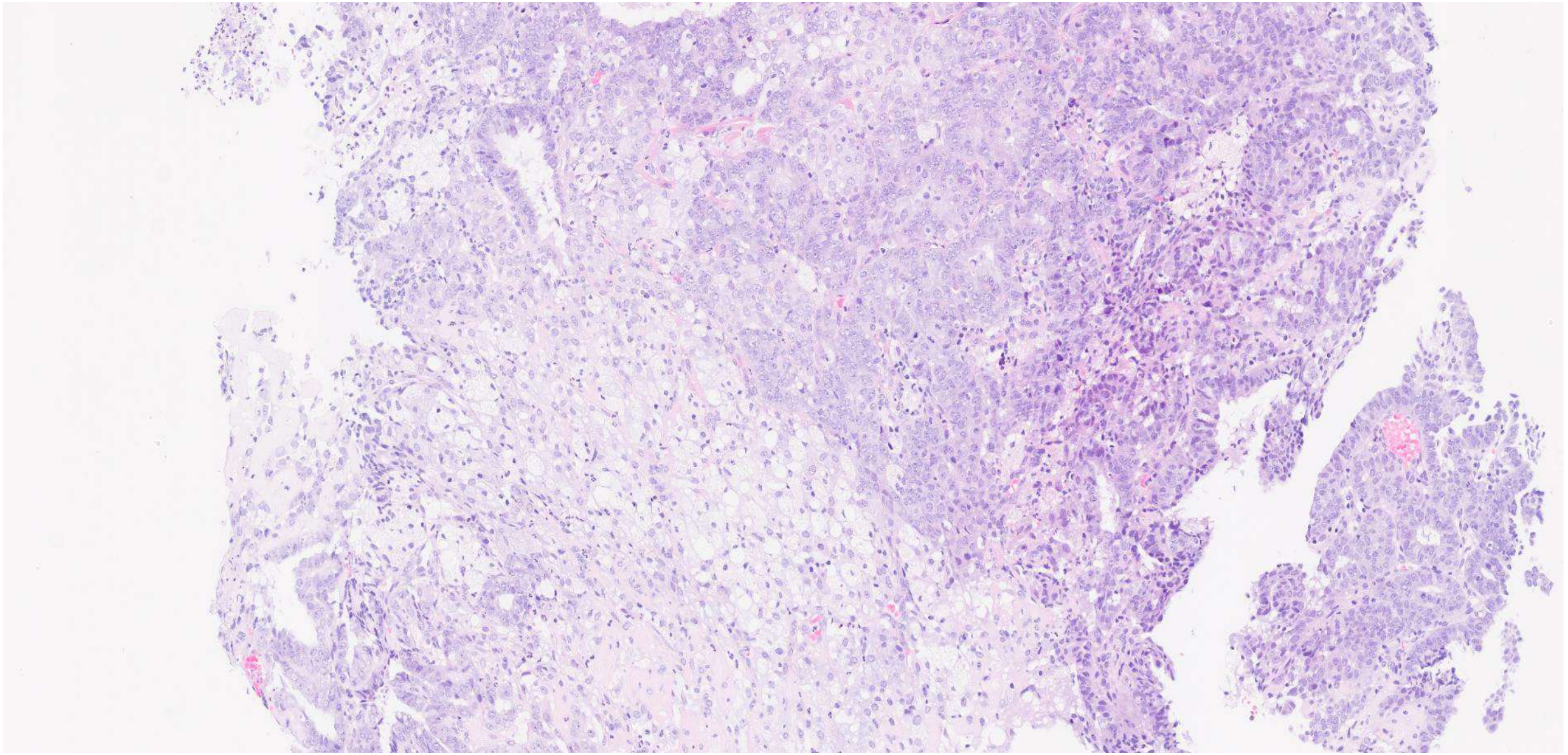

ENDOMETRIOID CARCINOMA WITH CLEAR CELL CHANGE

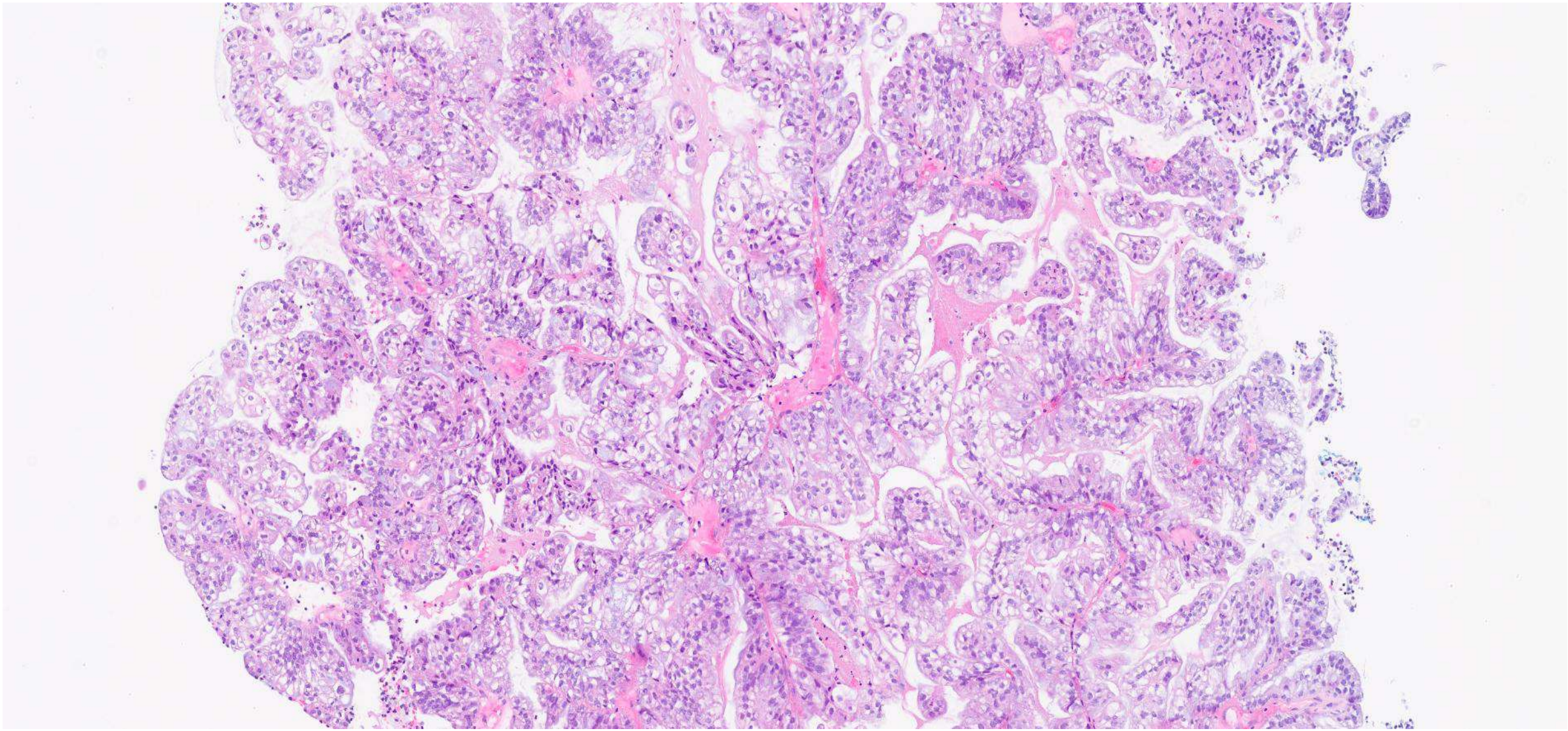

ENDOMETRIOID CARCINOMA WITH CLEAR CELLS

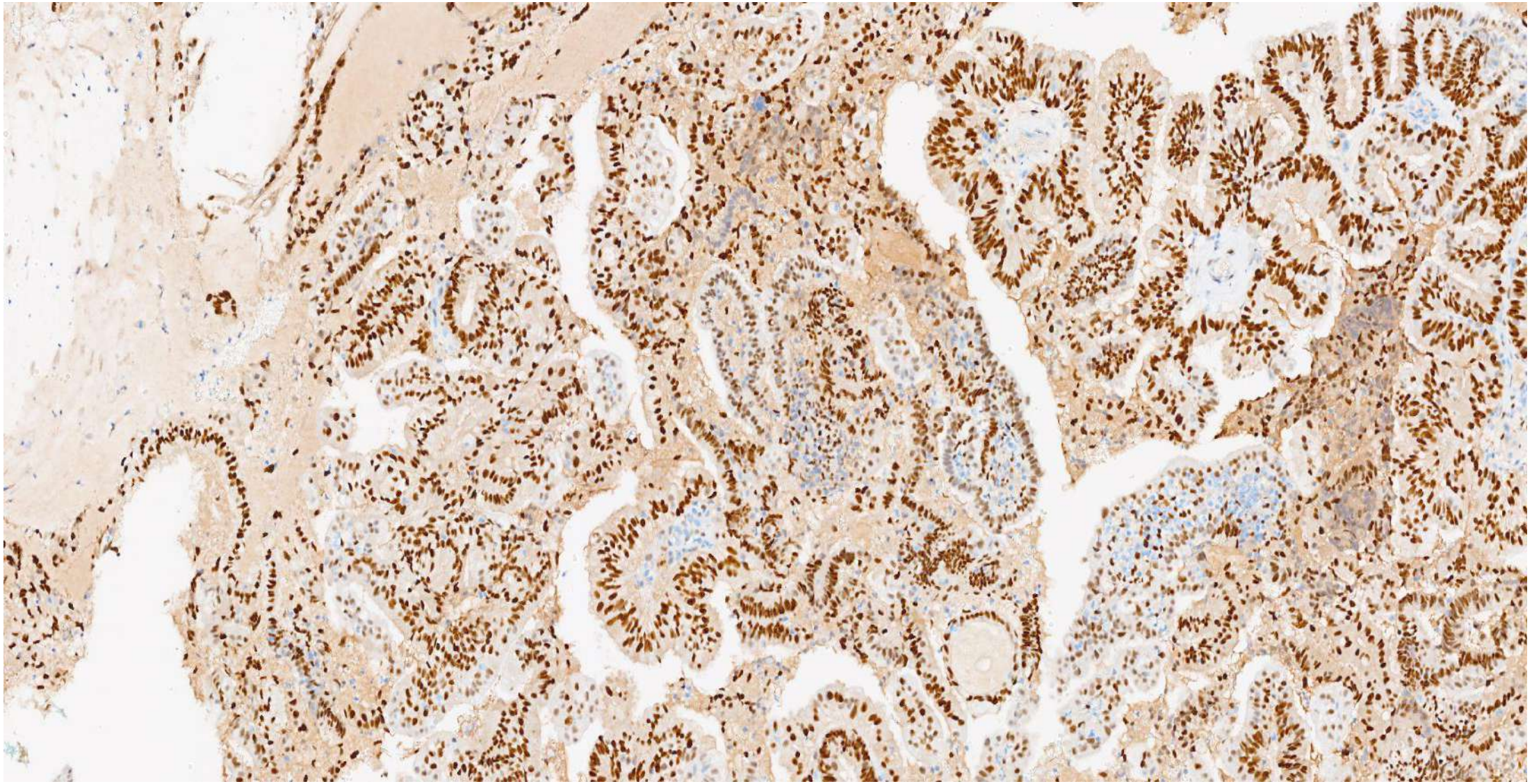

ER

ENDOMETRIOID CARCINOMA WITH CLEAR CELLS

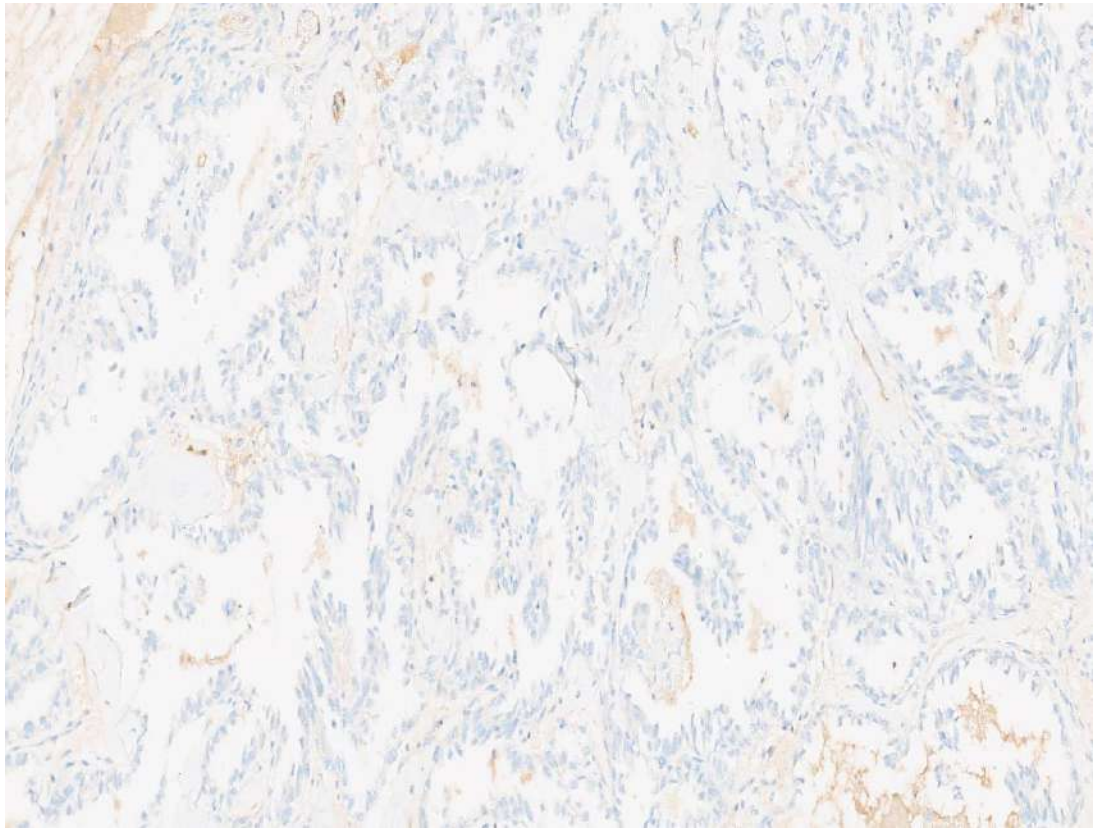

Napsin A

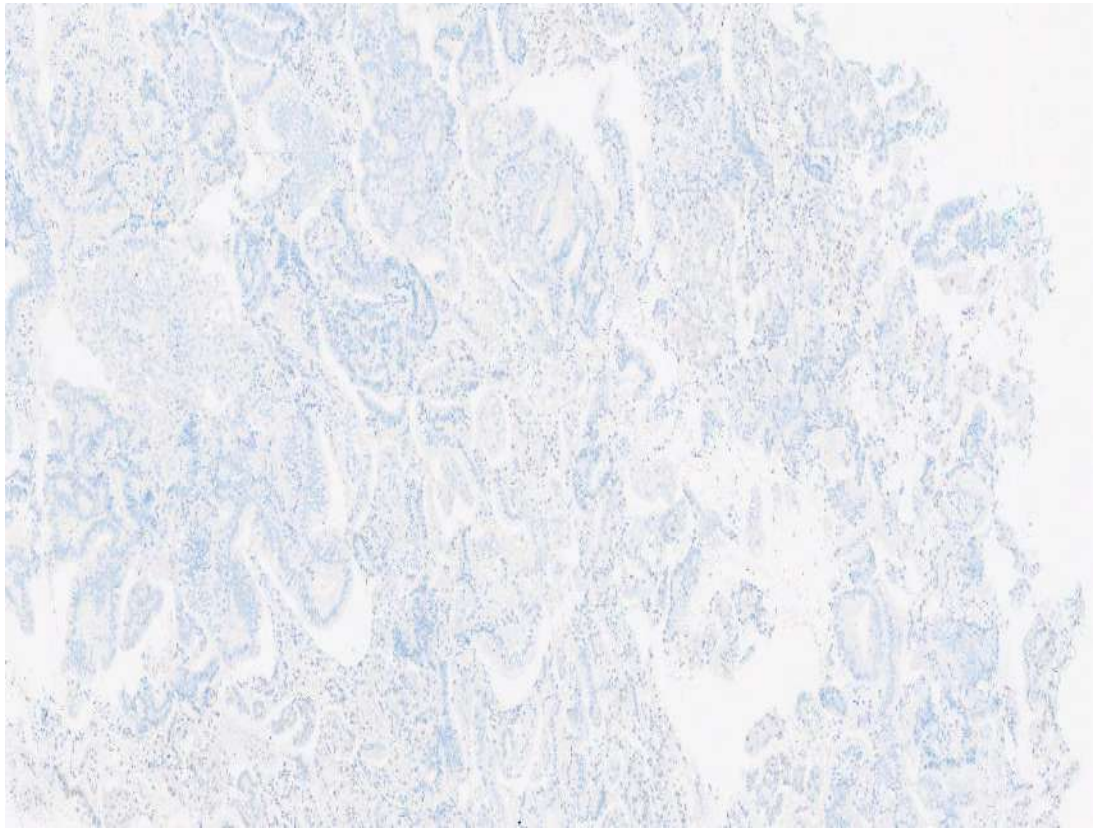

HNF1 beta

ENDOMETRIOID CARCINOMA WITH CLEAR CELLS

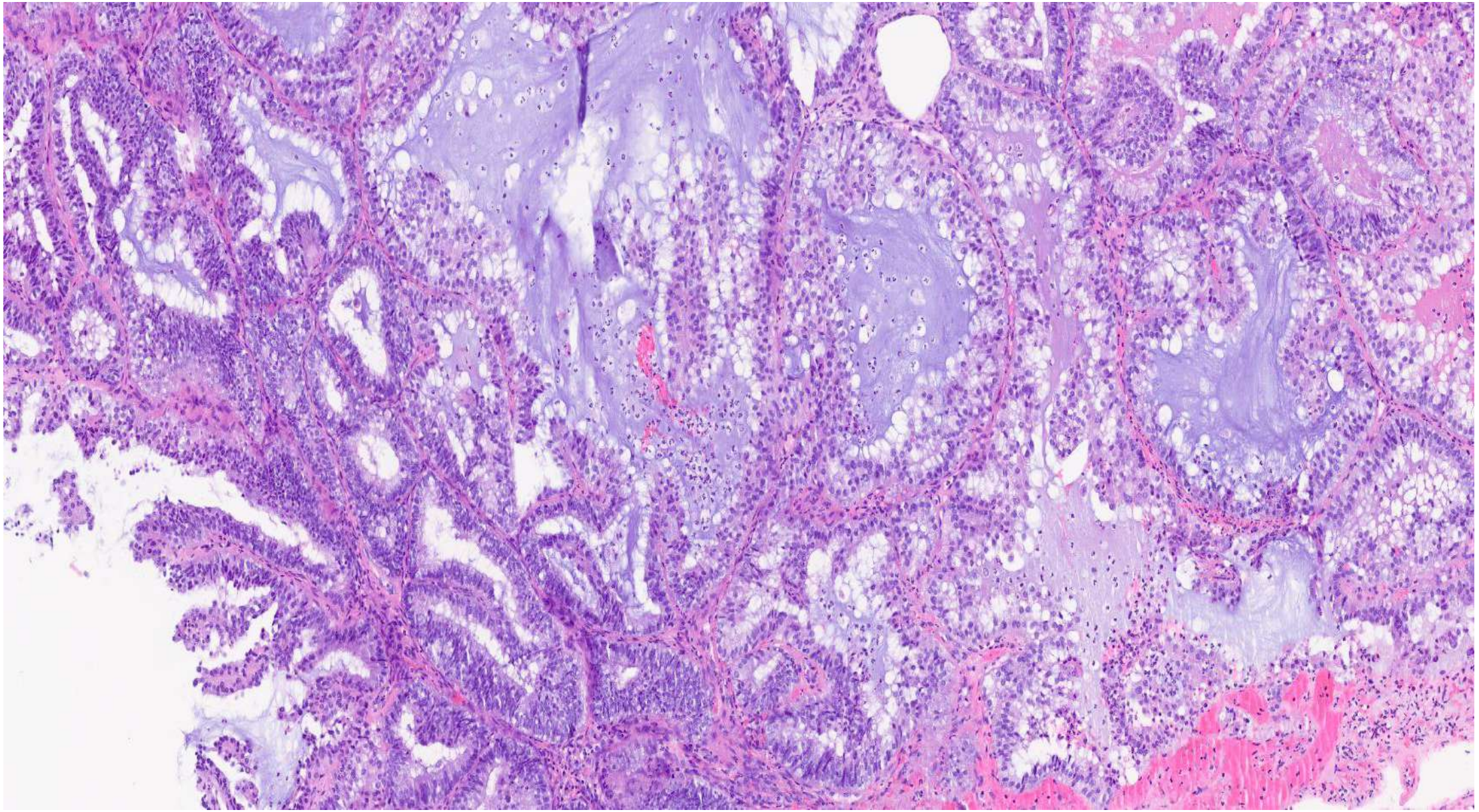

ENDOMETRIOID CARCINOMA WITH CLEAR CELLS

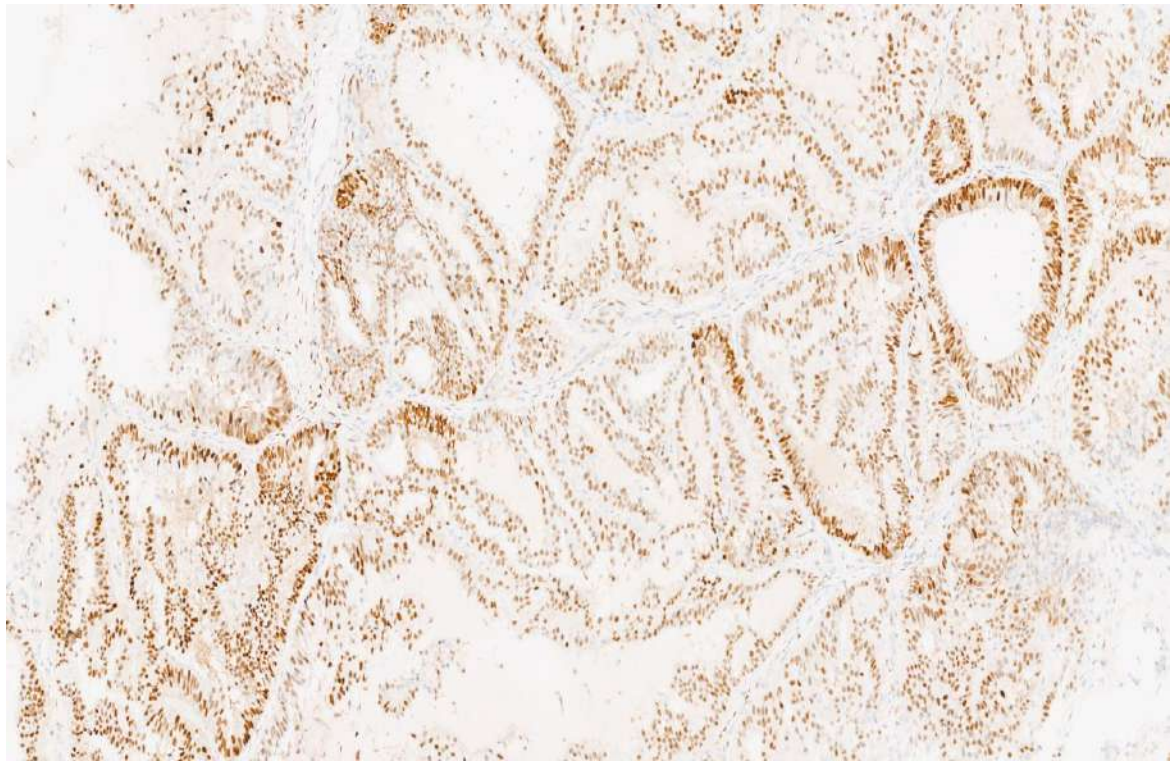

ER

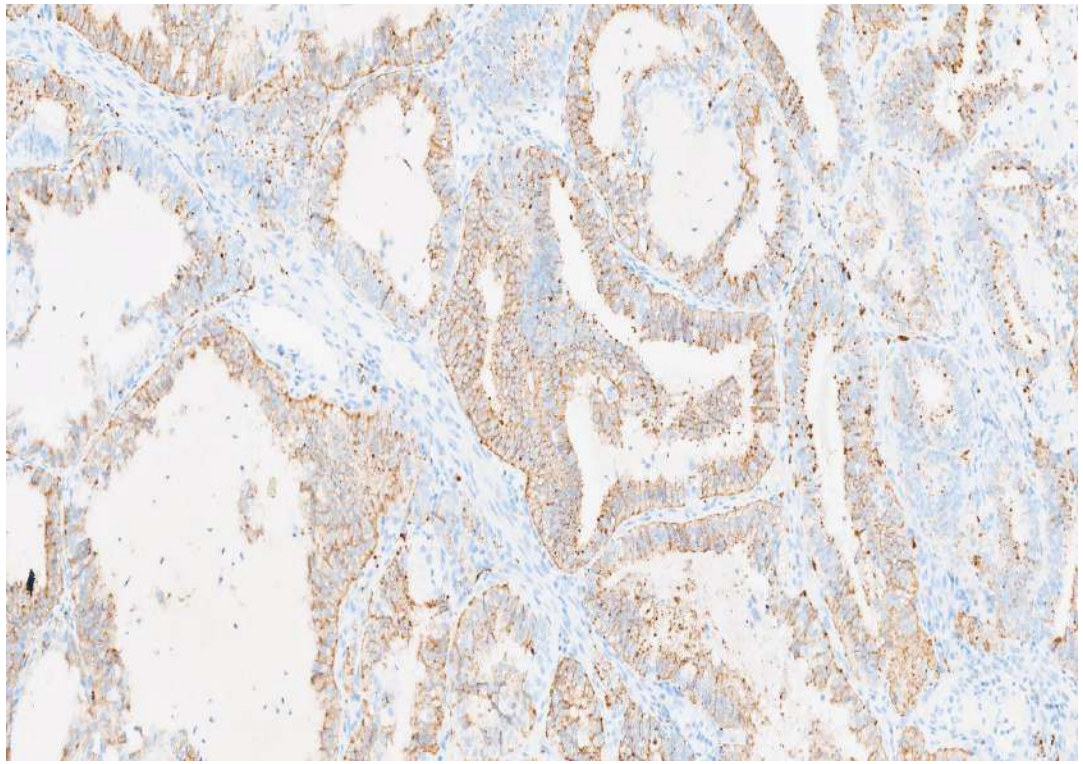

Napsin A

MIXED ENDOMETRIOID AND CLEAR CELL CARCINOMA

- Have high threshold before making diagnosis
- Endometrioid carcinoma with clear cells is much more likely to be a pure endometrioid adenocarcinoma than a mixed endometrioid and clear cell carcinoma
- “Hold-out” for 2 separate morphologies and immunophenotypes

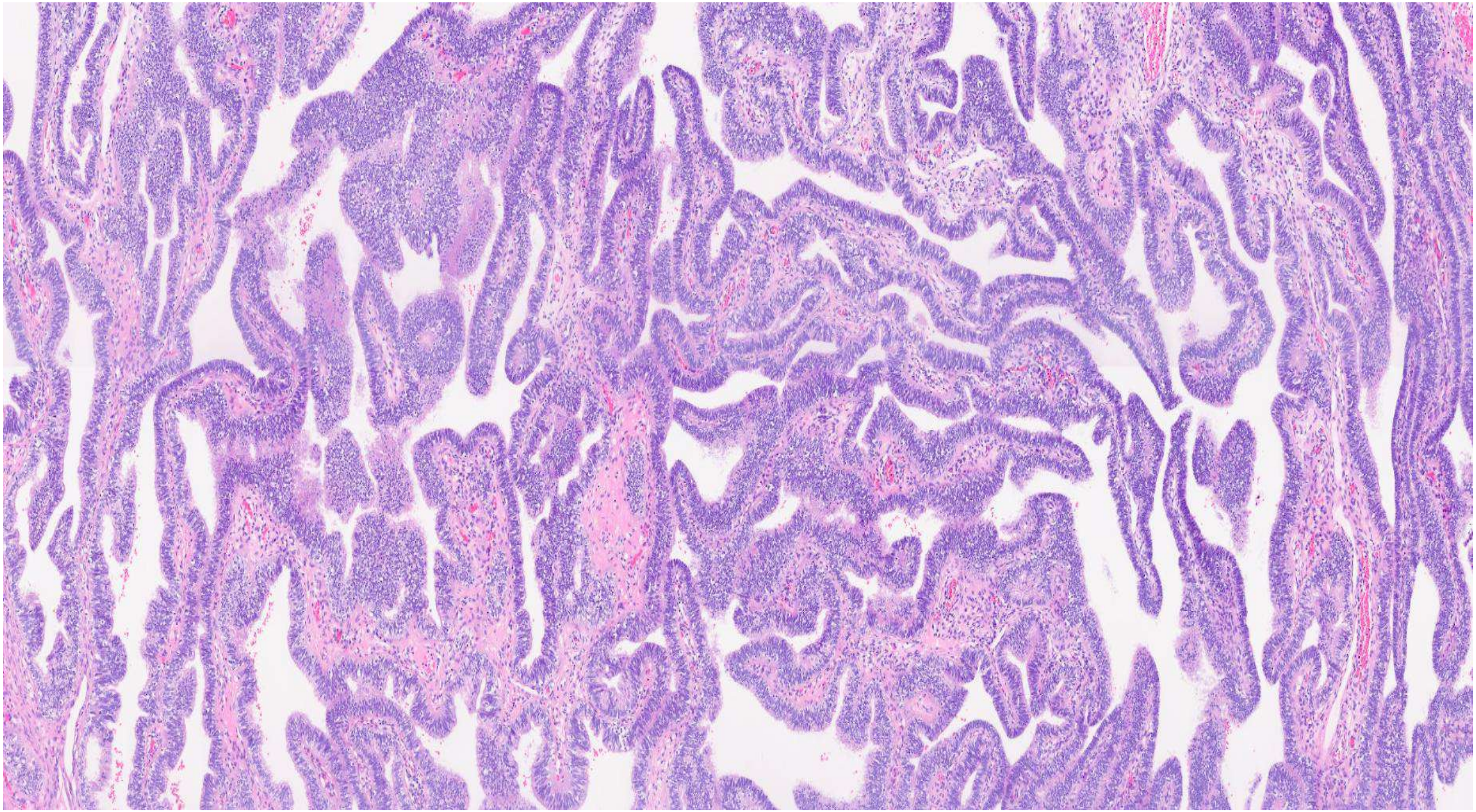

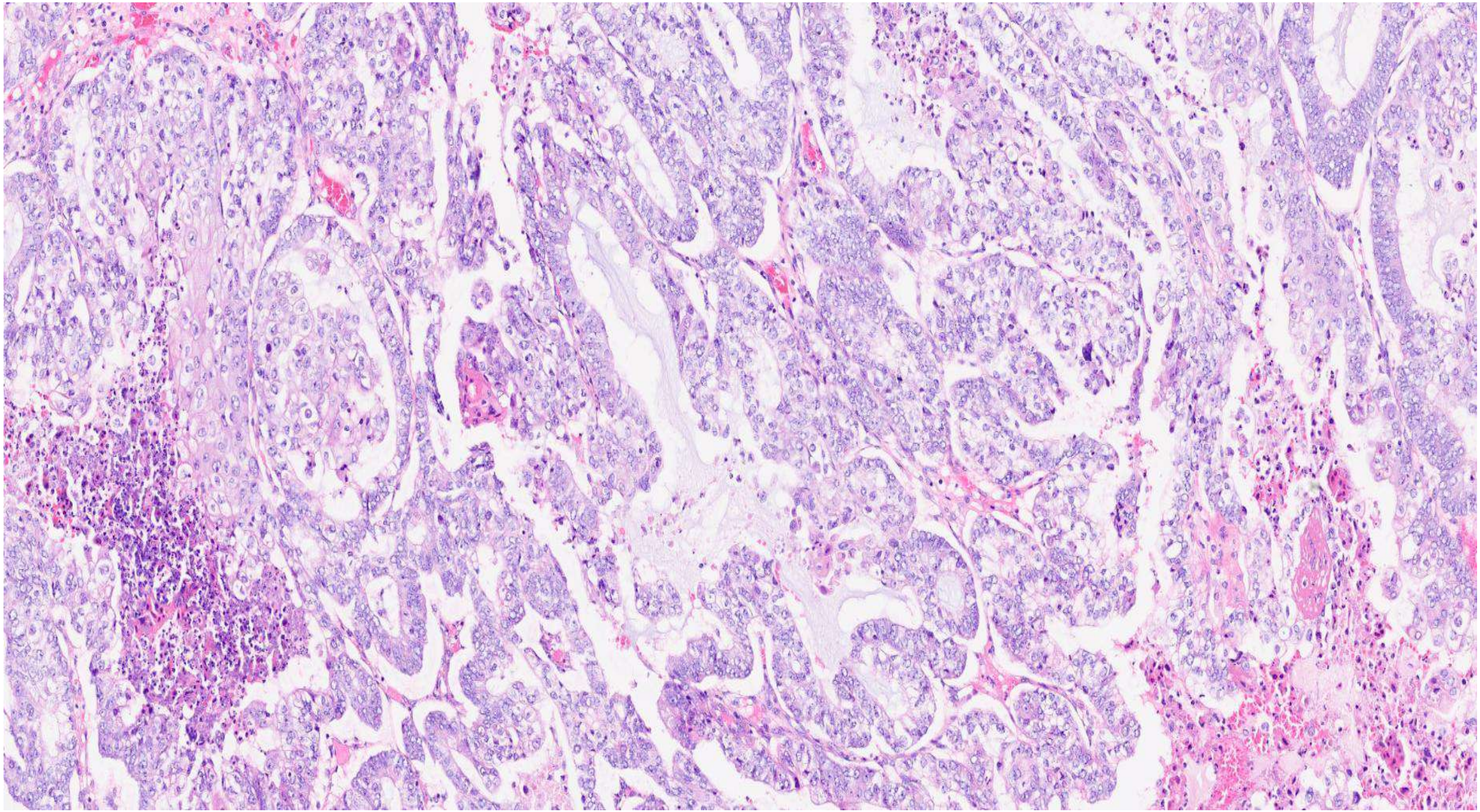

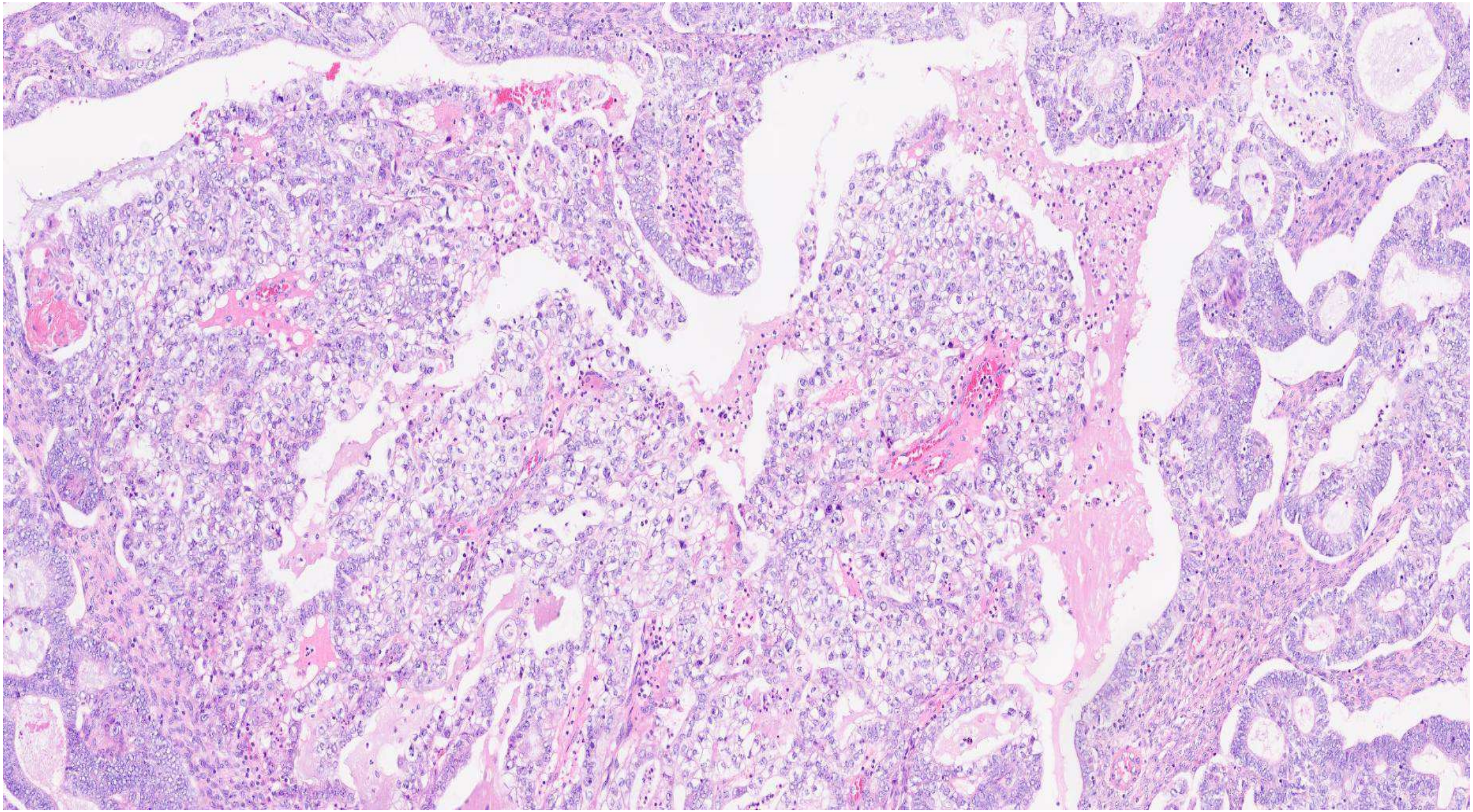

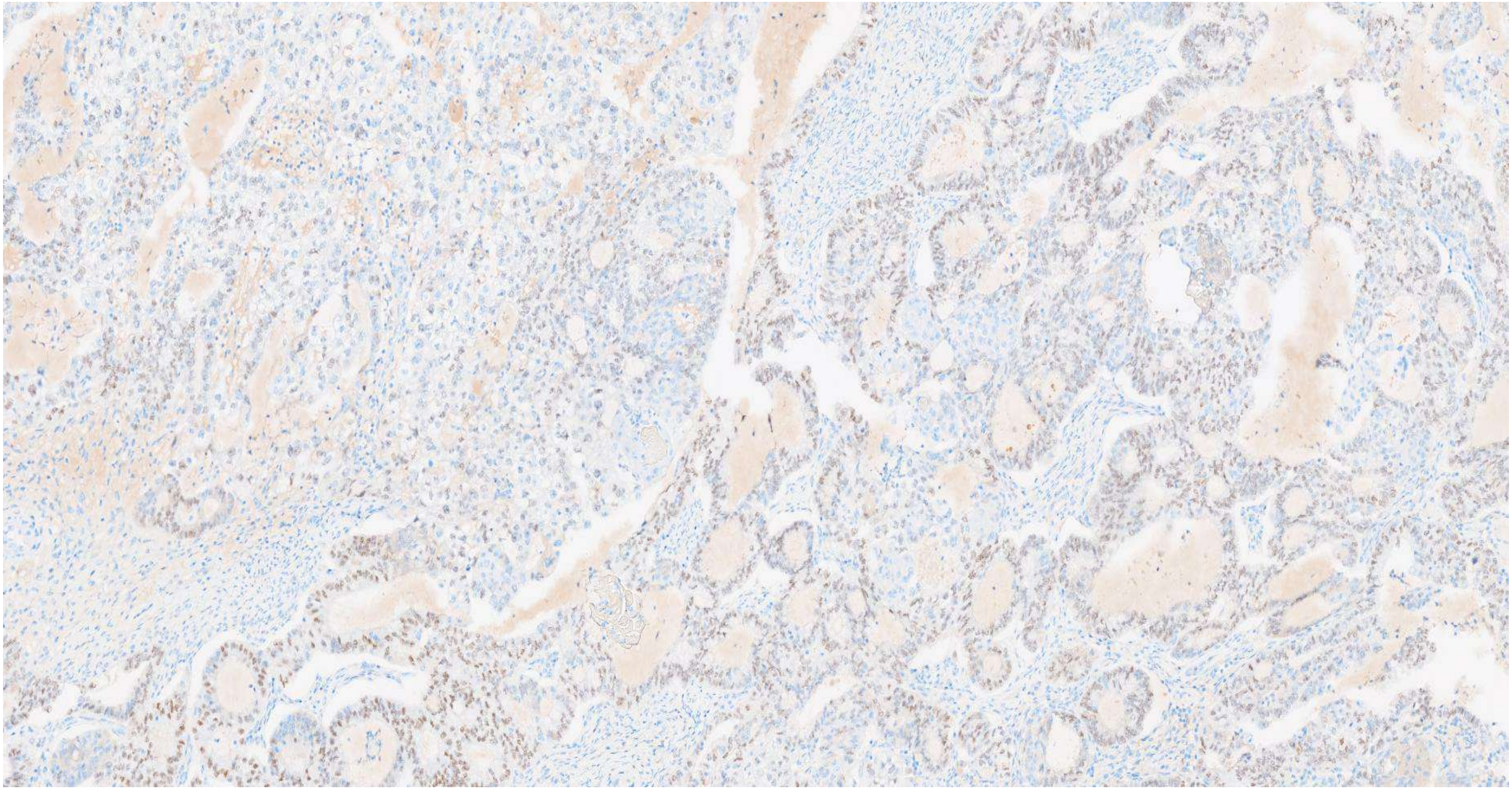

ER

FURTHER IMMUNOHISTOCHEMISTRY

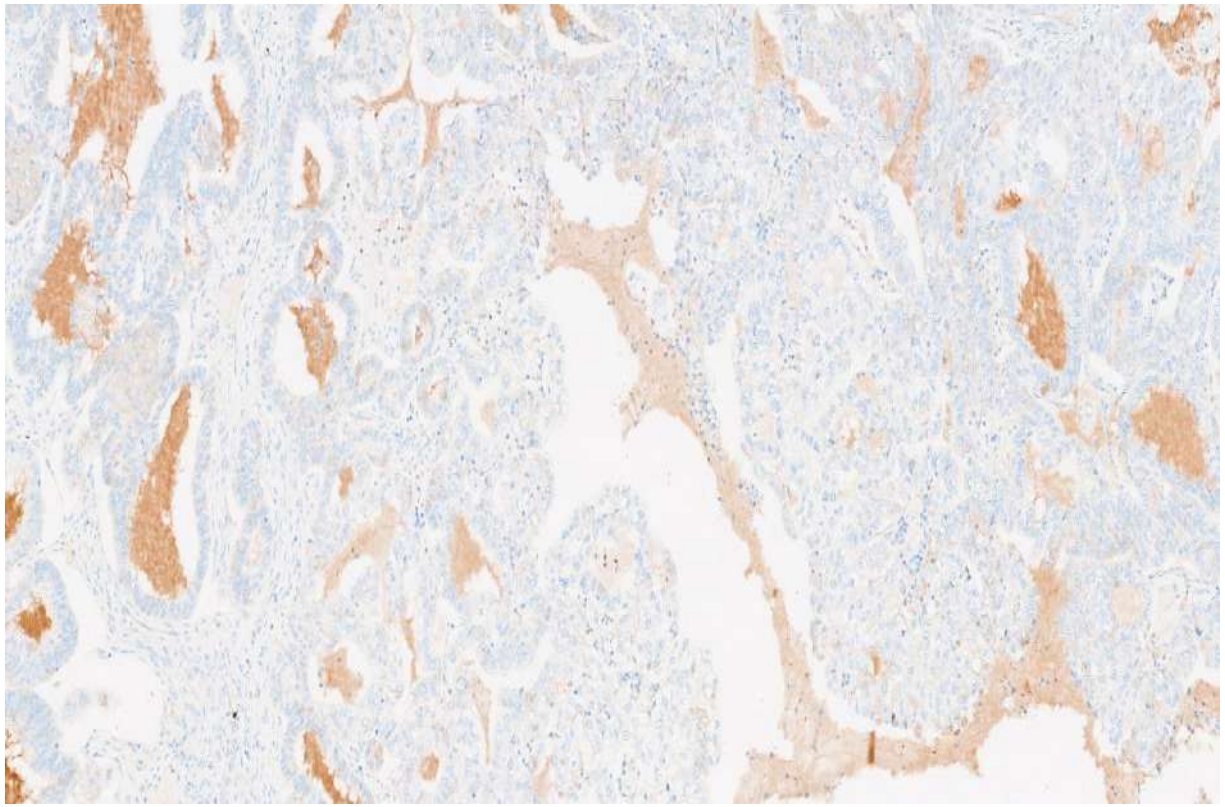

NAPSIN A

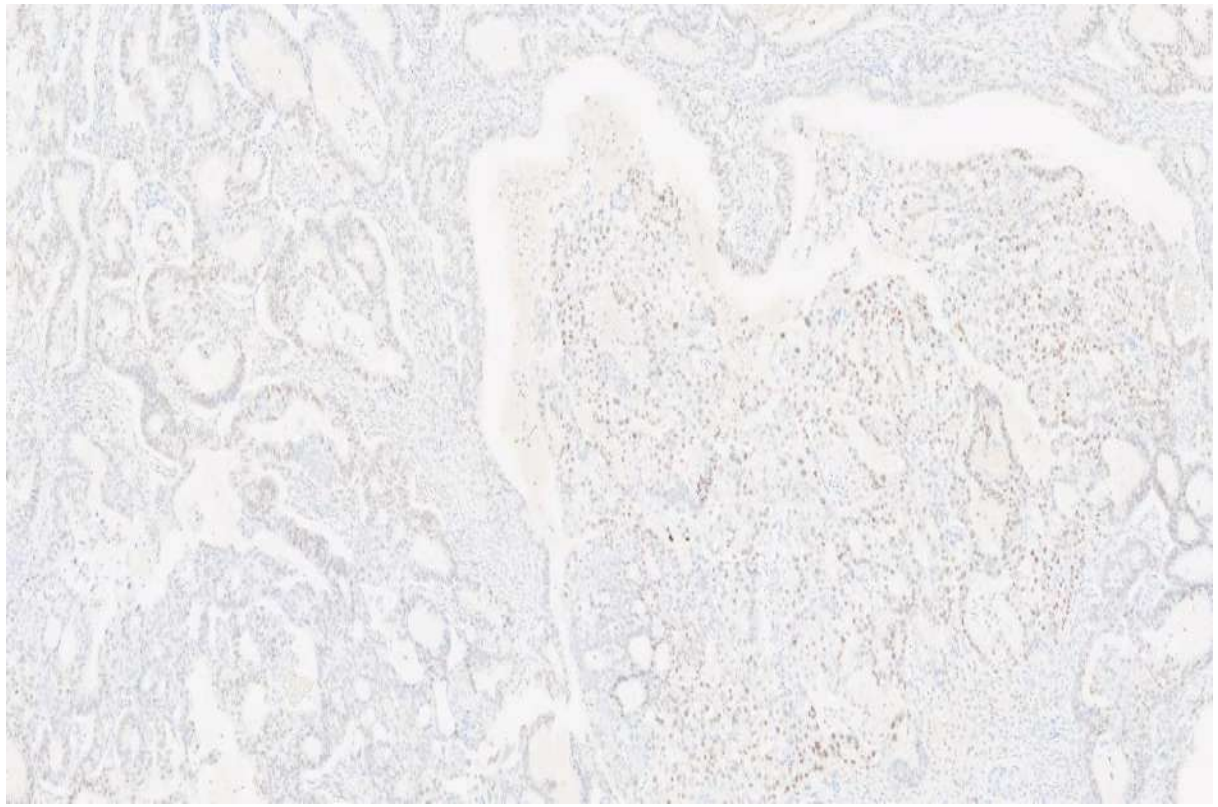

HNF 1 BETA

SEROUS CARCINOMA WITH CLEAR CELLS

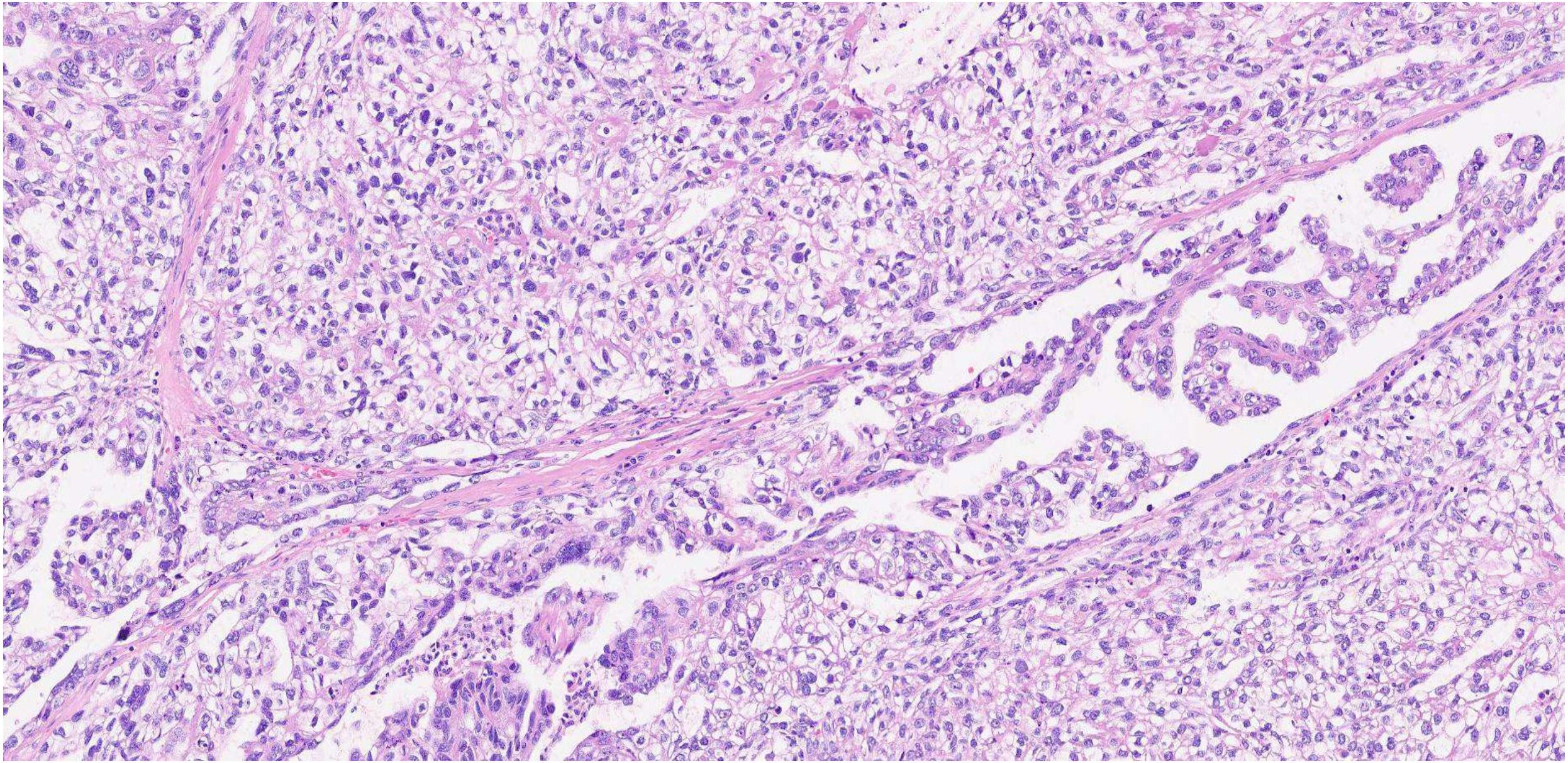

SEROUS CARCINOMA WITH CLEAR CELLS

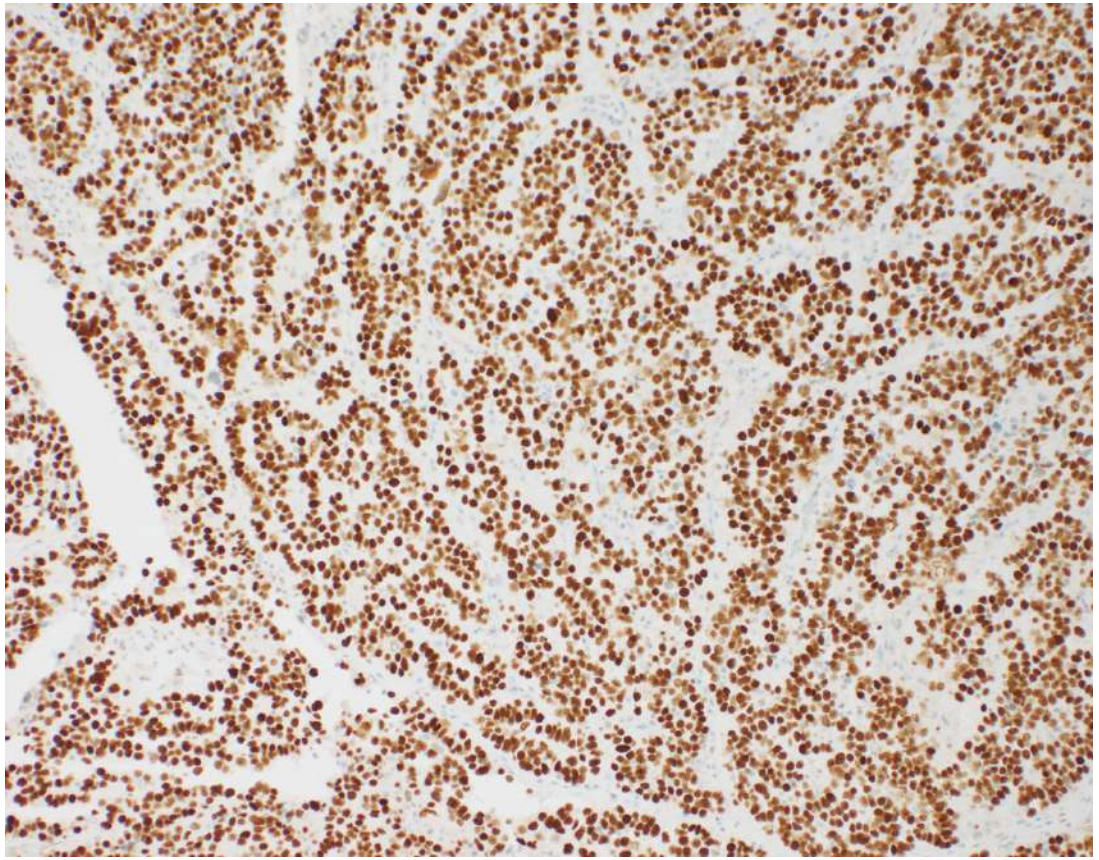

p53

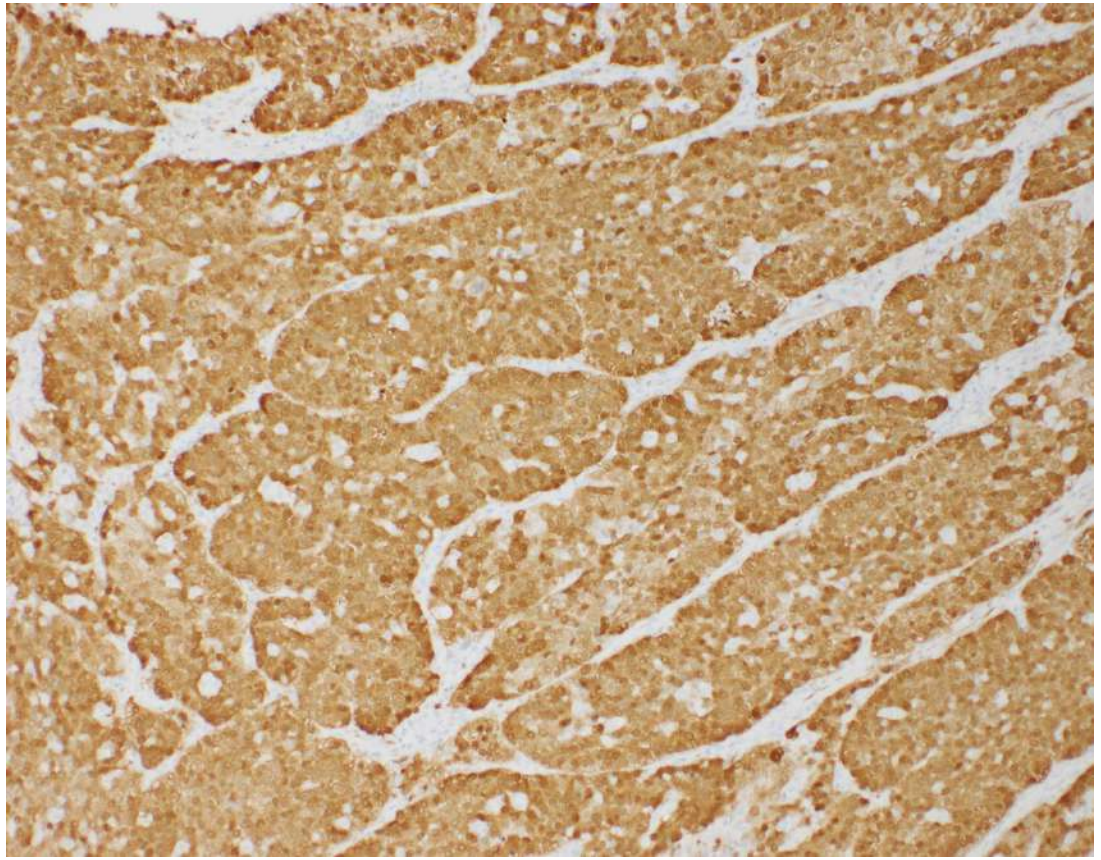

p16

CASE 3: BEWARE ER NEGATIVE LOW-GRADE ENDOMETRIOID ADENOCARCINOMAS

- F 66
- Postmenopausal bleeding
- Original diagnosis: grade 1 endometrioid adenocarcinoma with mucinous differentiation

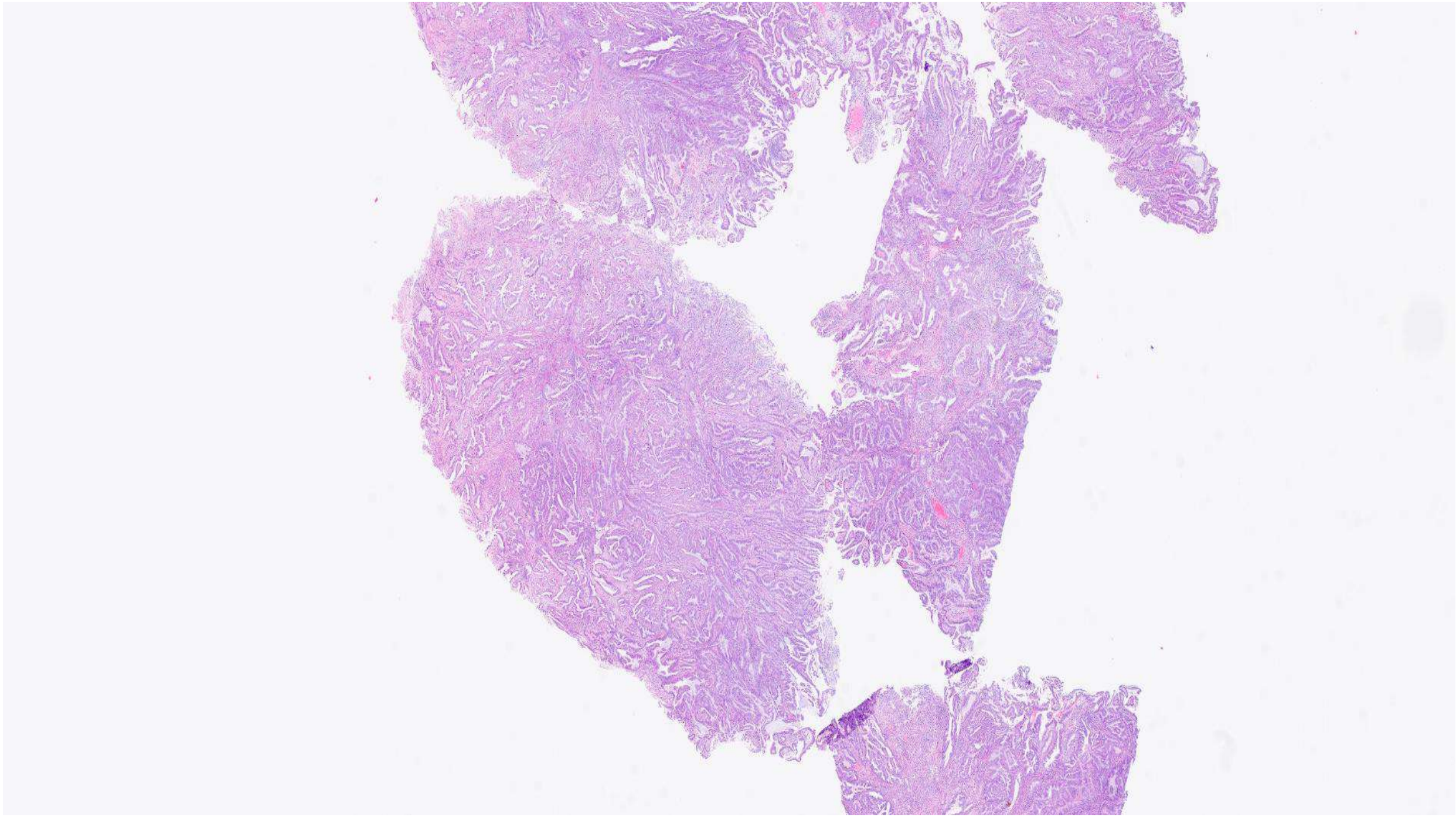

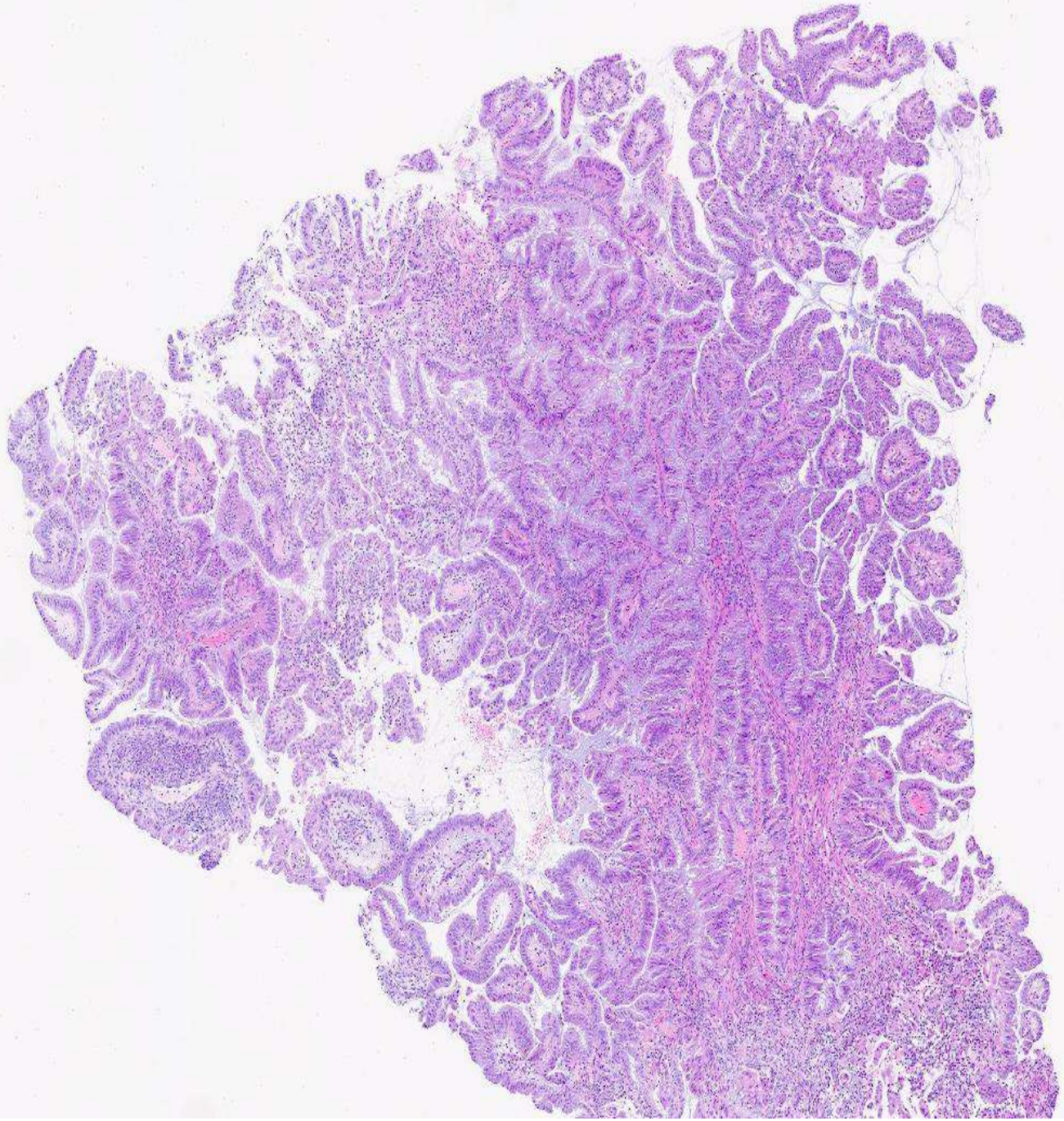

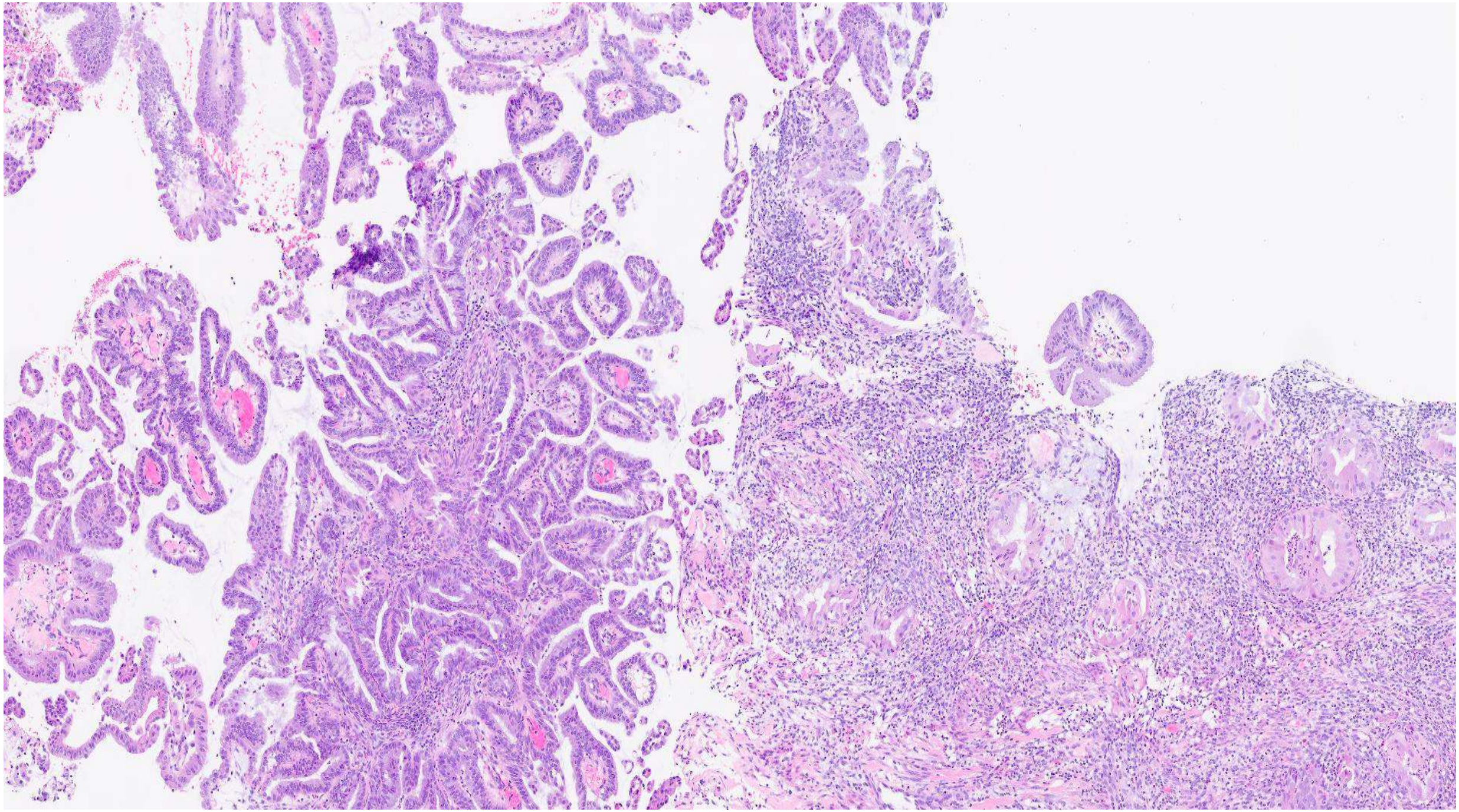

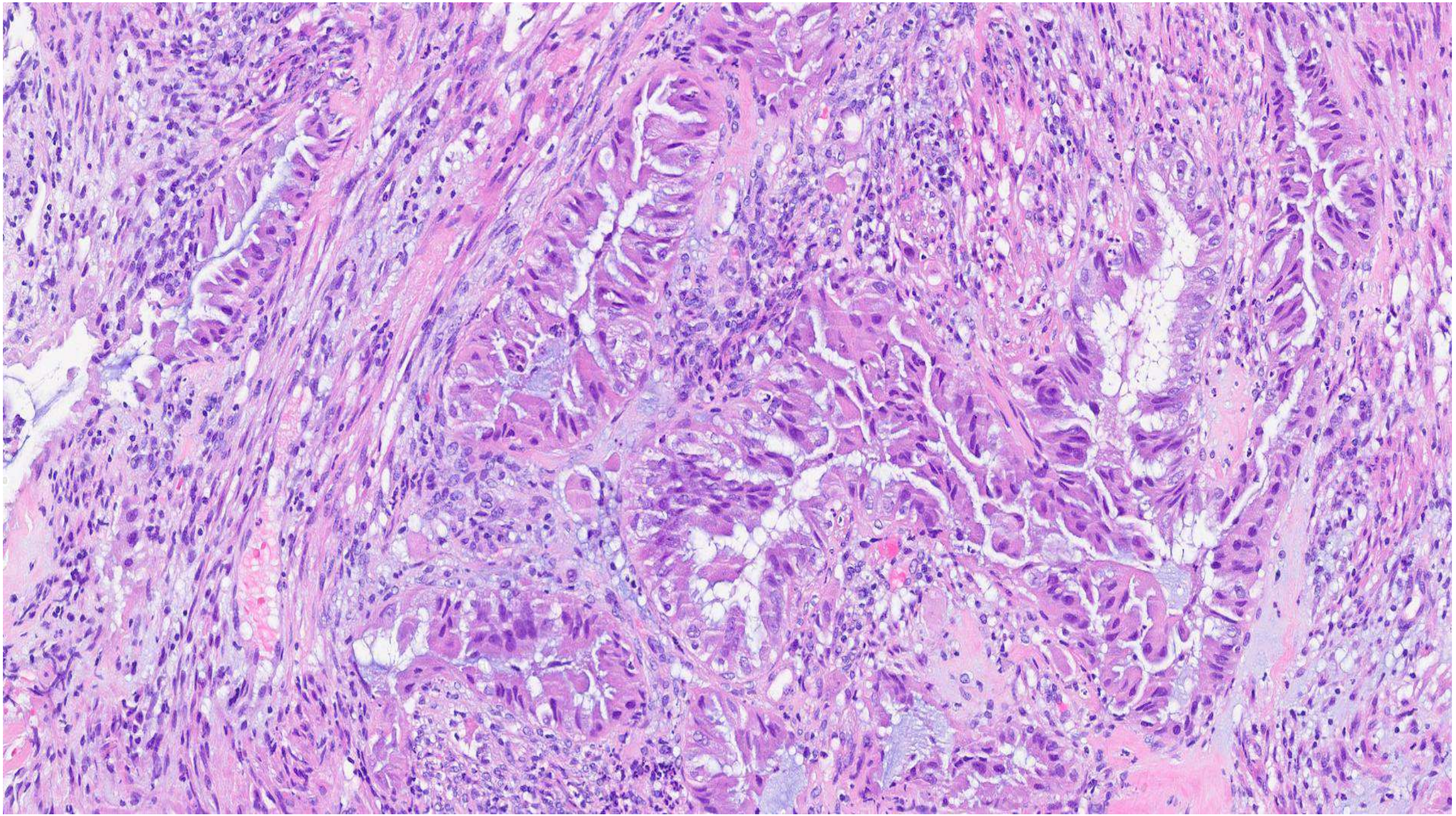

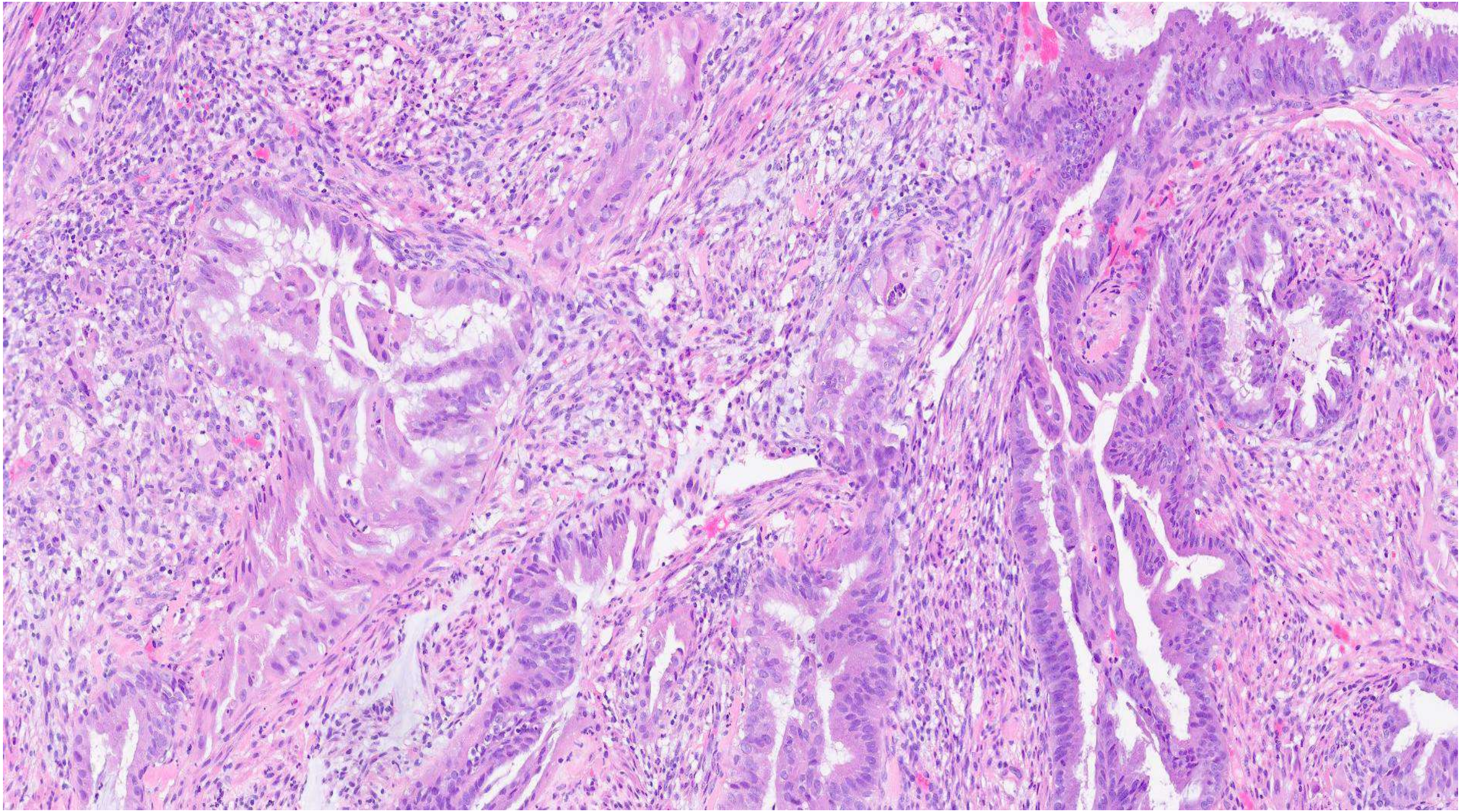

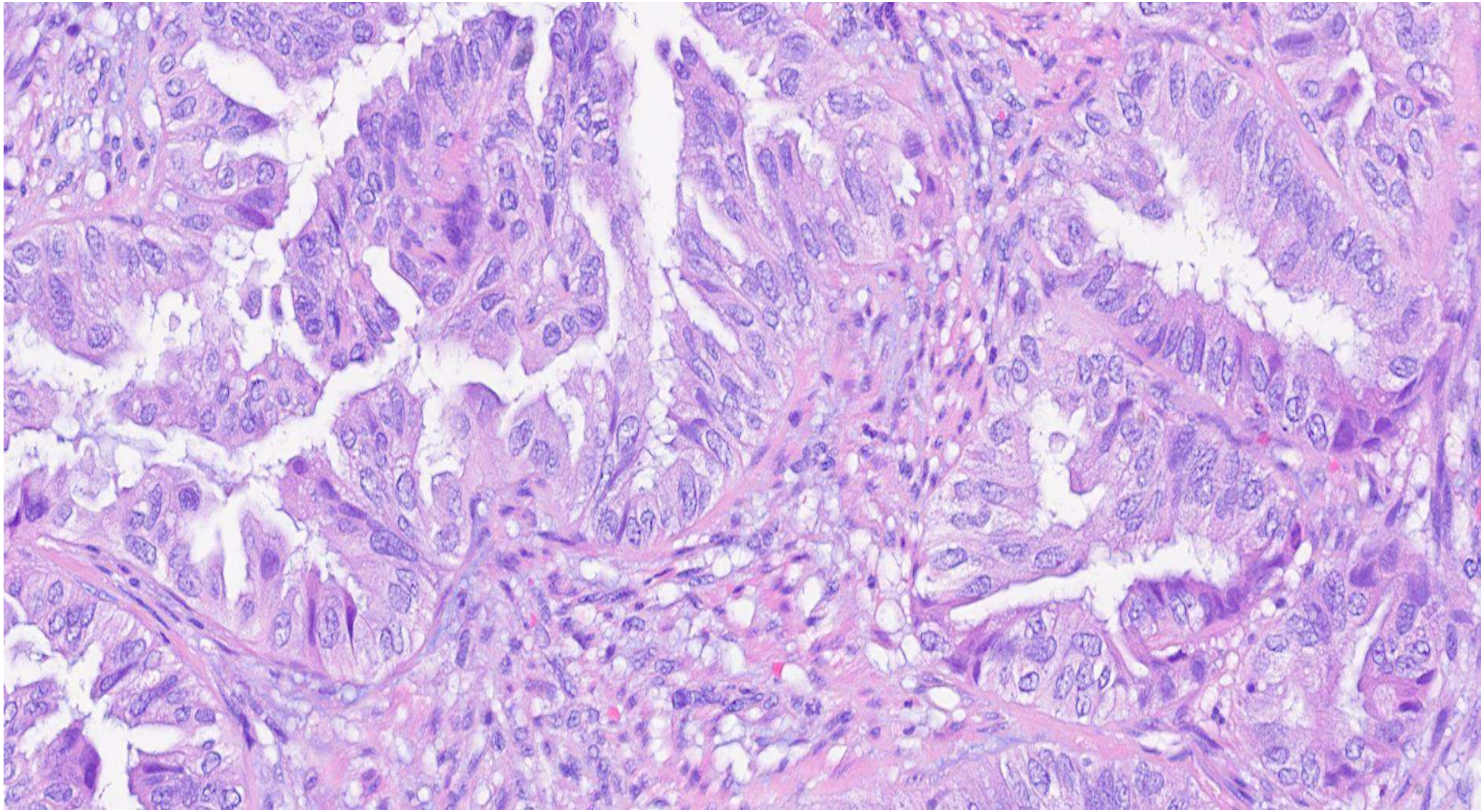

IMMUNOHISTOCHEMISTRY

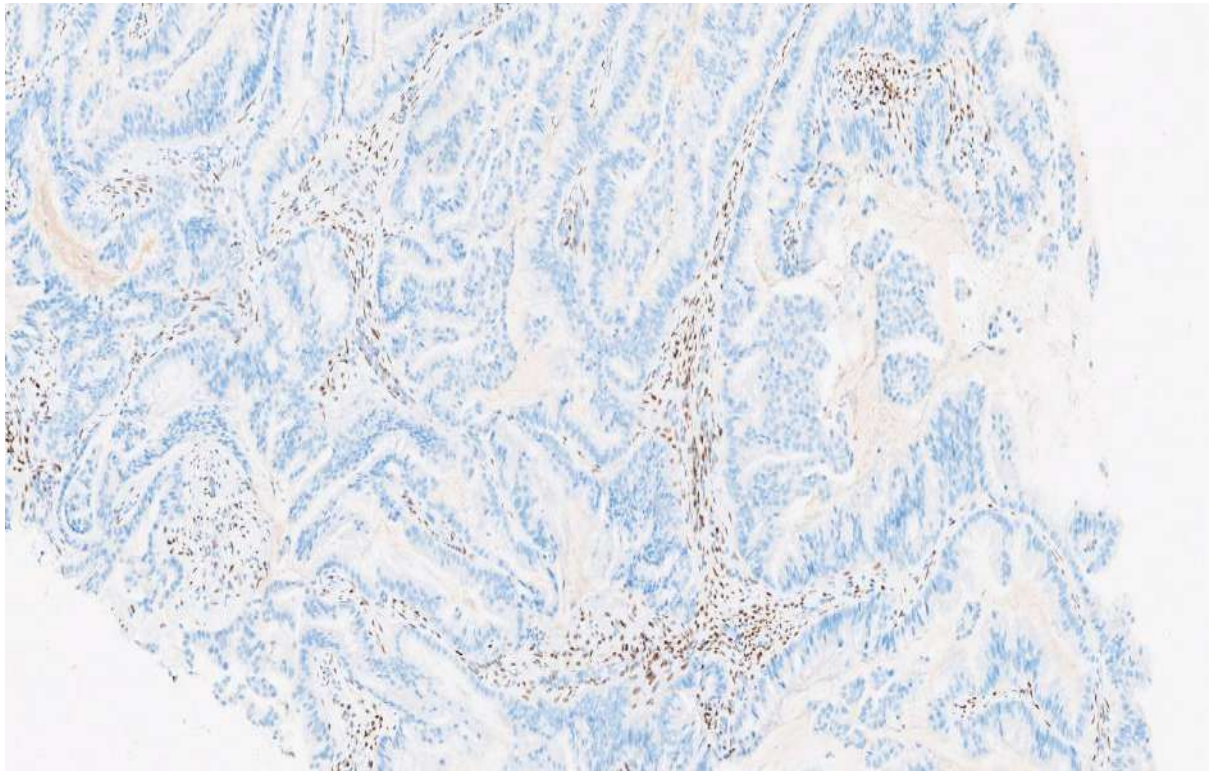

ER

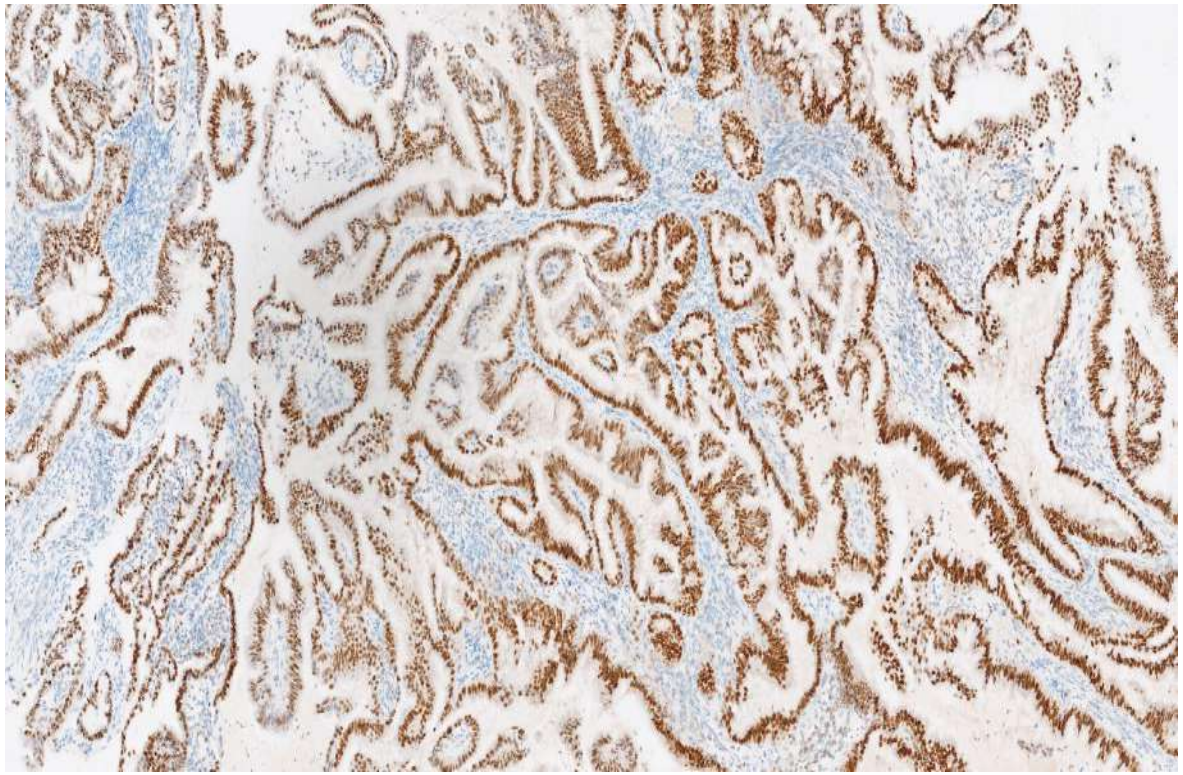

p53

IMMUNOHISTOCHEMISTRY

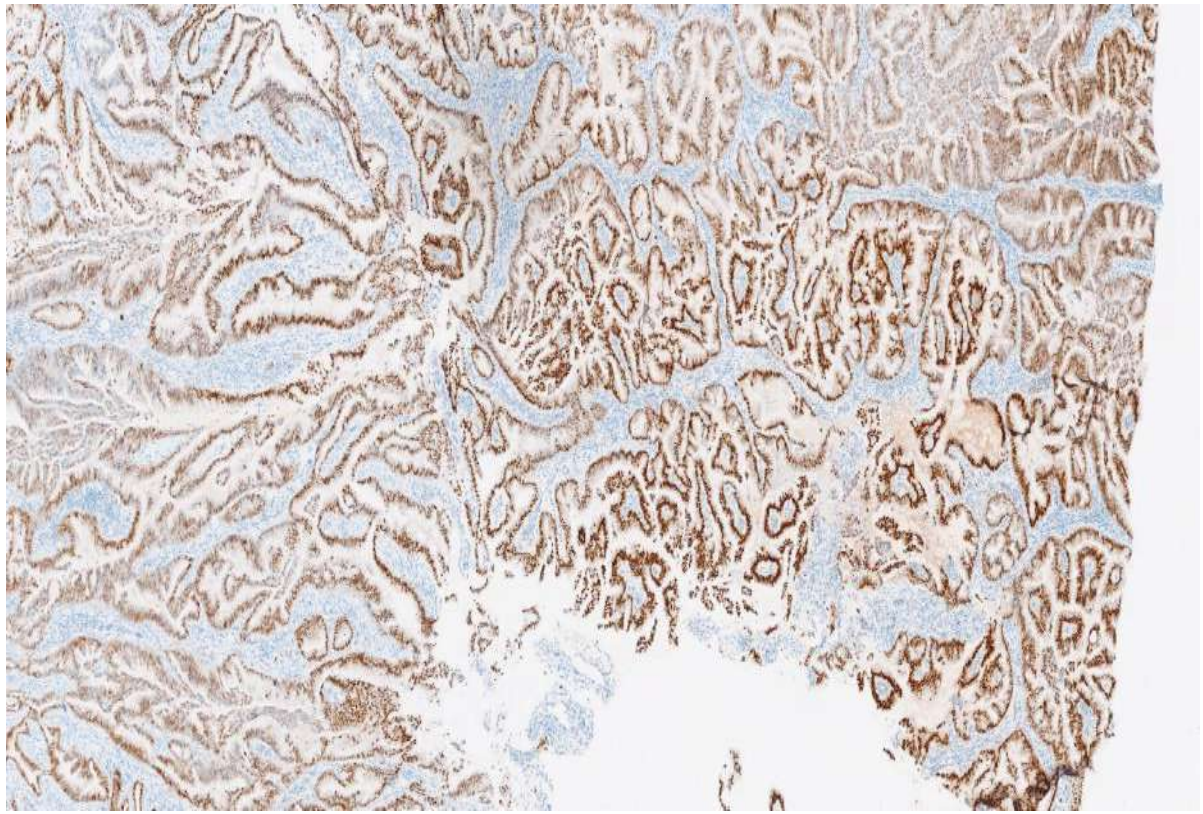

PAX8

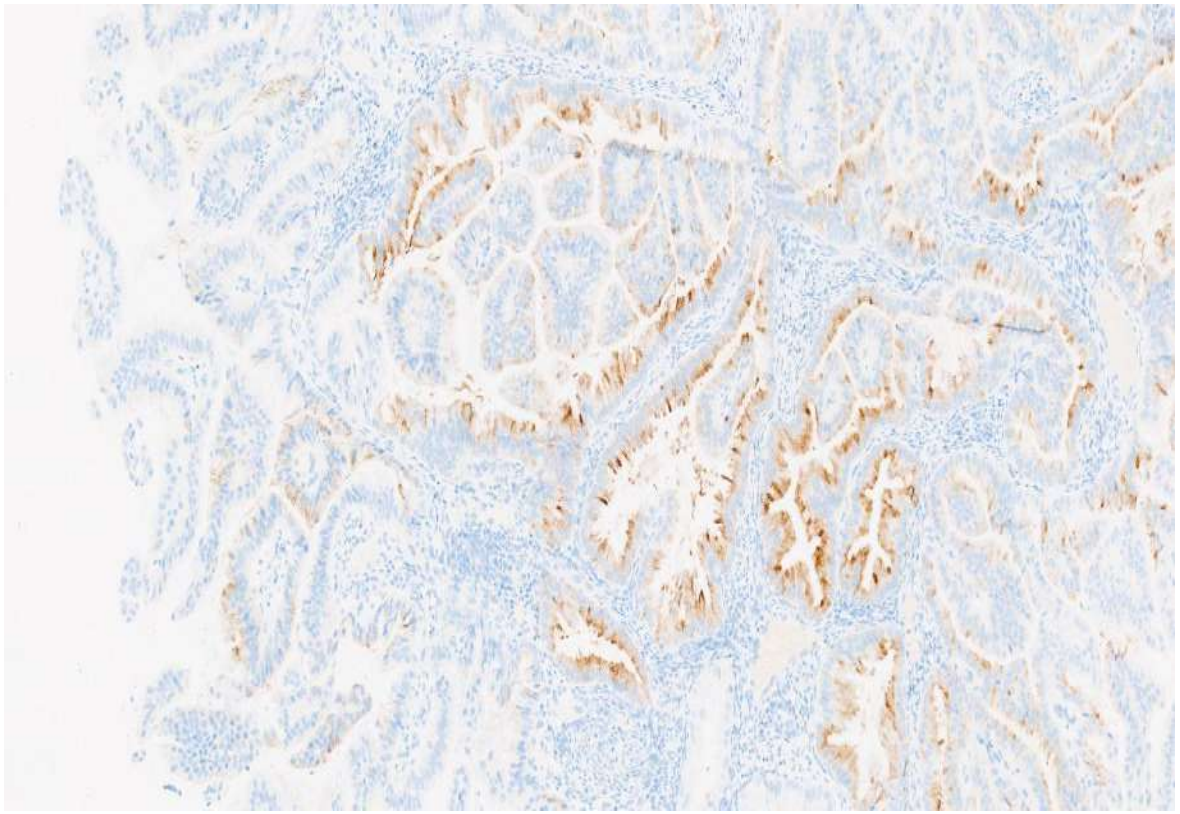

MUC6

IMMUNOHISTOCHEMISTRY

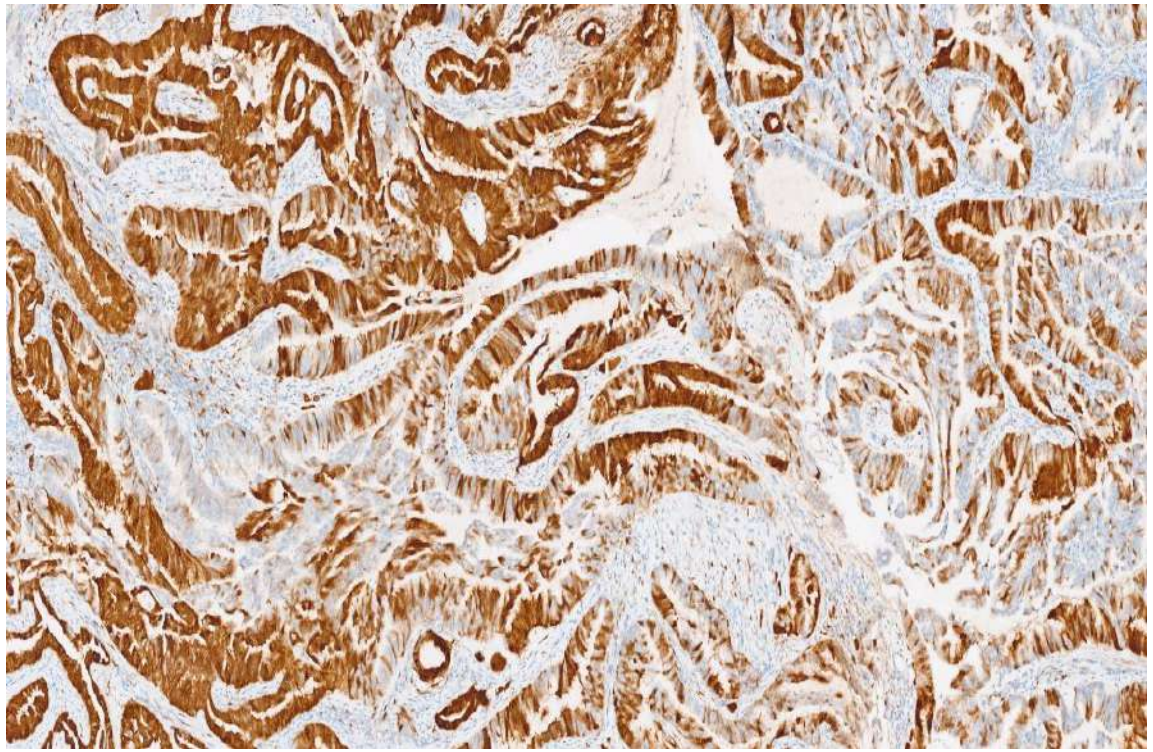

p16

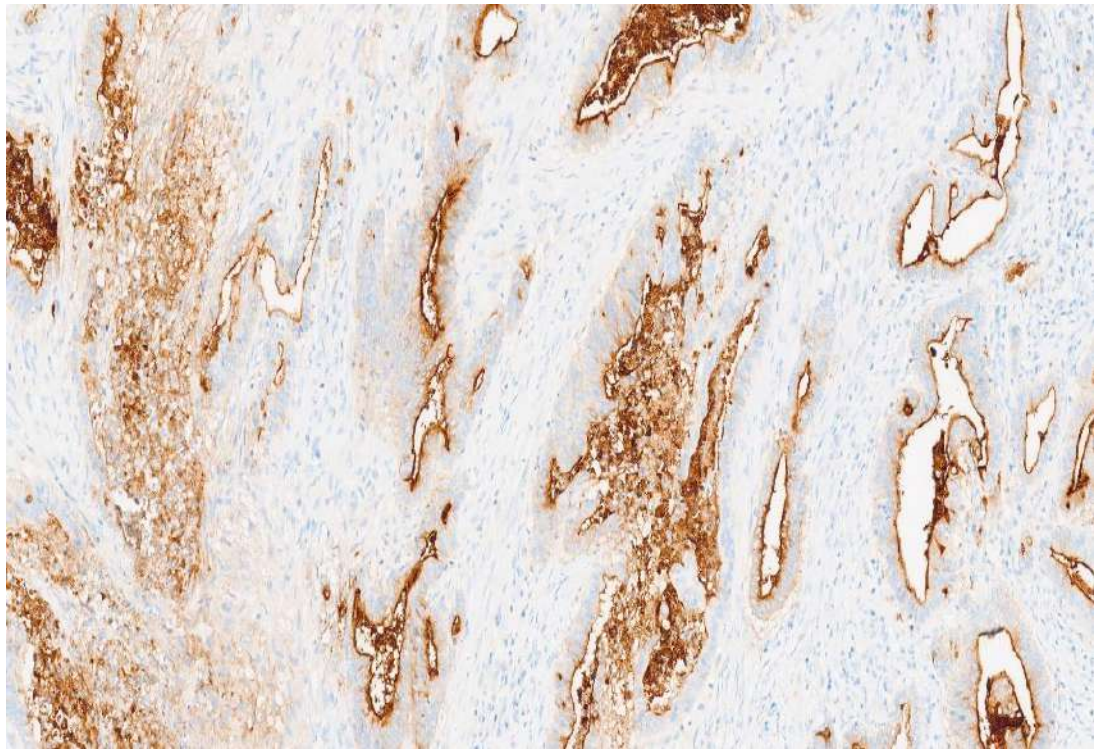

CEA

IMMUNOHISTOCHEMISTRY- CDX2

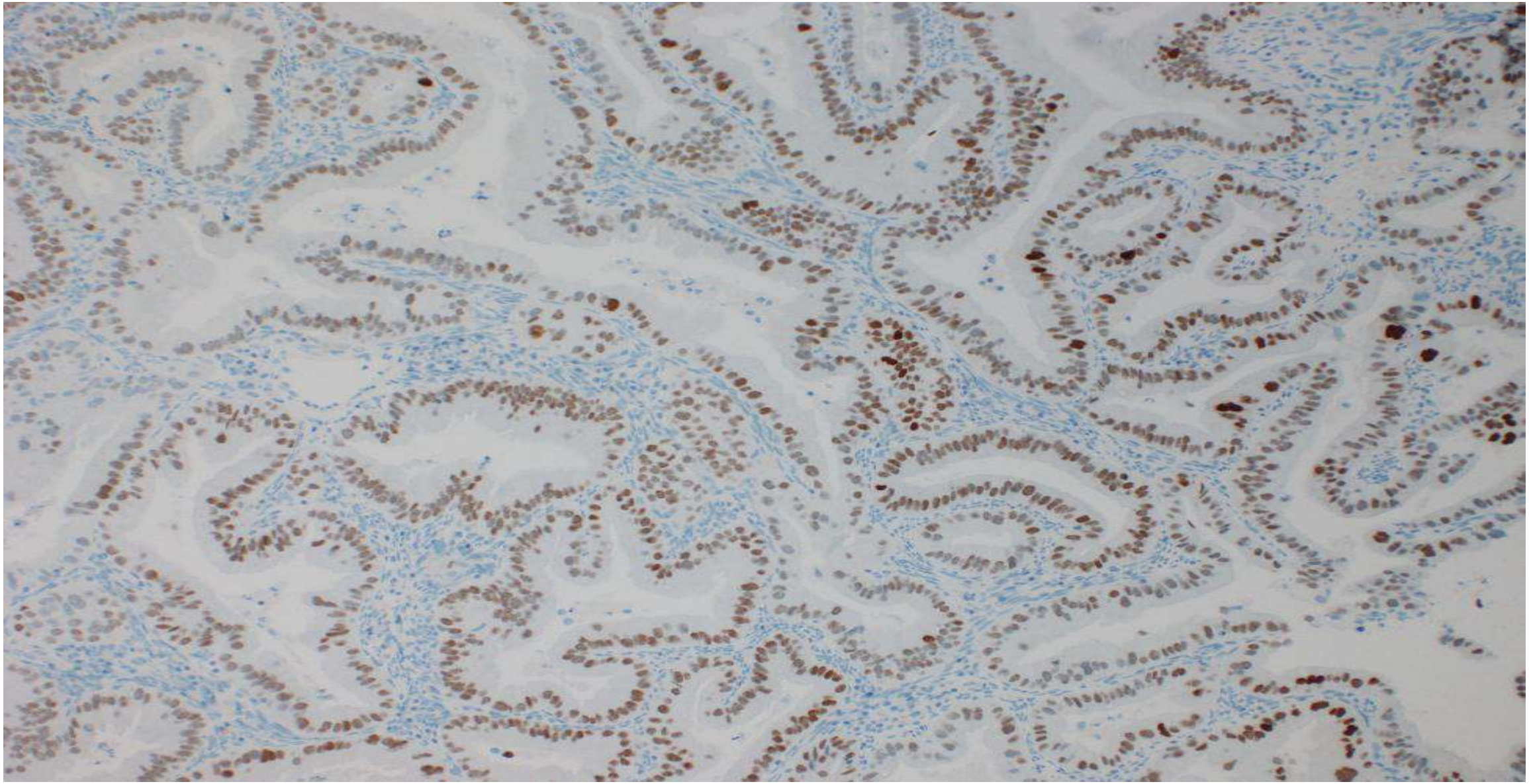

DIAGNOSIS

- Gastric/ gastrointestinal-type mucinous adenocarcinoma of endometrium
- *P53* abnormal TCGA molecular group (MMR proficient; no *POLE* mutation)

WHO 2020 CLASSIFICATION OF ENDOMETRIAL CARCINOMAS

- ENDOMETRIOID ADENOCARCINOMA
- SEROUS CARCINOMA
- CLEAR CELL CARCINOMA
- UNDIFFERENTIATED AND DEDIFFERENTIATED CARCINOMA
- MIXED CARCINOMA
- MESONEPHRIC ADENOCARCINOMA
- SQUAMOUS CELL CARCINOMA
- **MUCINOUS CARCINOMA, INTESTINAL TYPE**
- MESONEPHRIC-LIKE ADENOCARCINOMA
- CARCINOSARCOMA

WHO 2020- ENDOMETRIAL MUCINOUS CARCINOMA

- Endometrioid carcinoma with any amount of mucinous differentiation now just termed endometrioid carcinoma (can say in comment that exhibits mucinous differentiation); these are usually ER/ PR positive
- Old 50% rule for mucinous carcinoma no longer applies
- In endometrium- category of mucinous carcinoma now reserved for gastric/ gastrointestinal/ intestinal type carcinomas; identical to situation in ovary
- As in cervix, gastric-type is the well-established term but gastrointestinal-type is more appropriate (some cases exhibit overt intestinal differentiation with goblet cells)

ENDOMETRIOID CARCINOMA WITH MUCINOUS DIFFERENTIATION

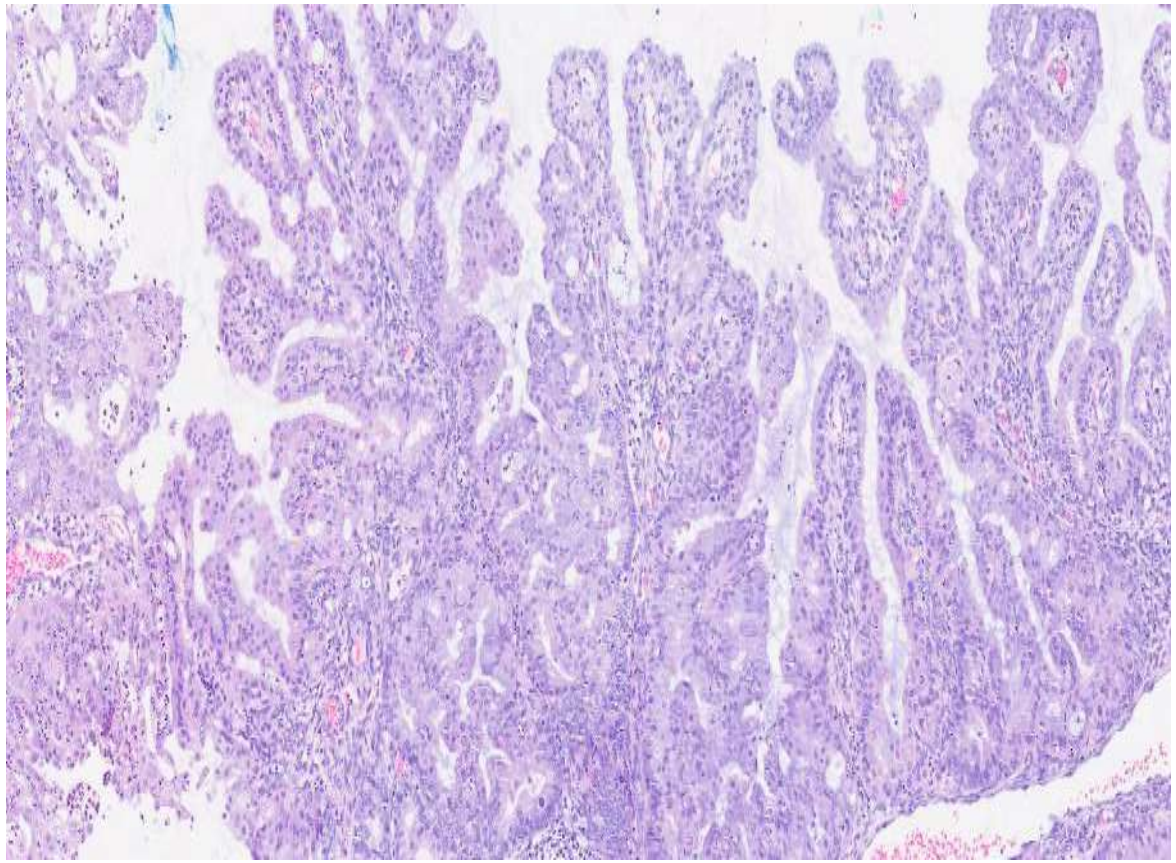

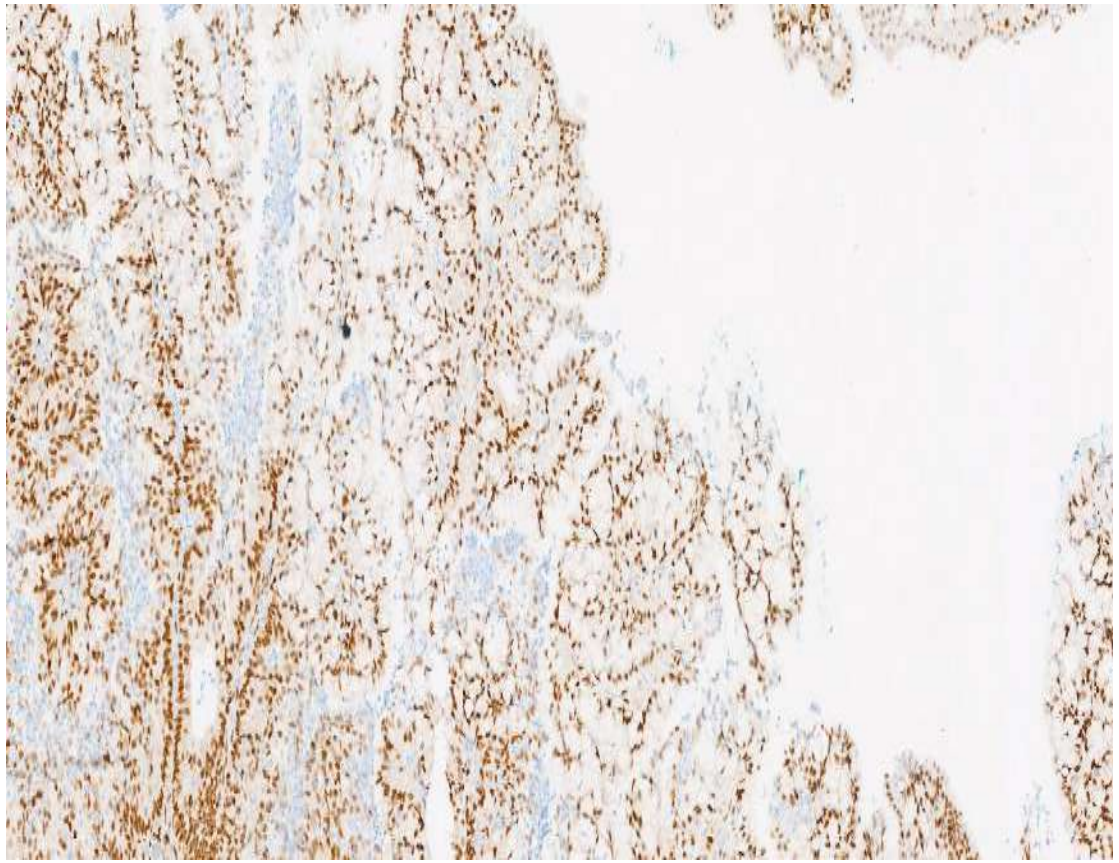

ER

PMID 31567280

ORIGINAL ARTICLE

Endometrial Gastric (Gastrointestinal)-type Mucinous Lesions

Report of a Series Illustrating the Spectrum of Benign and Malignant Lesions

Richard Wing-Cheuk Wong, FRCPA, Angela Ralte, FRCPath,† Katherine Grondin, MD, PhD,‡ Karen L. Talia, FRCPA,§ and W. Glenn McCluggage, FRCPath‖*

PMID 40066786

ORIGINAL ARTICLE

Primary Endometrial Gastric (Gastrointestinal)-type Mucinous Adenocarcinoma

A Detailed Clinicopathologic and Molecular Analysis of 27 Cases

Harsimar Kaur, MBBS,† Lawrence Hsu Lin, MD, PhD,*‡ David L. Kolin, MD, PhD,* Andre Pinto, MD,§ Carlos Parra-Herran, MD,* Mark Catherwood, MD,‖ Koen Van de Vijver, MD, PhD,¶ Natalia Buza, MD,† W. Glenn McCluggage, FRCPath,# and Marisa R. Nucci, MD**

PMID 40066786

- May be of all 4 TCGA molecular types
- Usually in older women (median age=69.5 y; range=42 to 87 y)
- Claudin-18 is a more specific marker for gastric-type differentiation than MUC6
- PAX8 negative in almost half of cases
- Frequently harbour mutations in *TP53, KRAS* and *PIK3CA*
- Often present at advanced stage with aggressive clinical behaviour
- Can have deceiving low grade morphology
- FIGO grading does not accurately reflect biologic behaviour and these tumours should be considered high grade even with well differentiated glandular morphology
- None of patients had Peutz Jeghers syndrome

PMID 38477341

Histopathology

Histopathology 2024, **85**, 20–39. DOI: 10.1111/his.15174

REVIEW

Gastric-type glandular lesions of the female genital tract excluding the cervix: emerging pathological entities

Richard W-C Wong,[1,#] Karen L Talia[2,#] & W Glenn McCluggage[3]

[1]*Department of Pathology, United Christian Hospital, Kwun Tong, Hong Kong,* [2]*Department of Pathology, Royal Children's Hospital and Royal Women's Hospital, Melbourne, Australia and* [3]*Department of Pathology, Belfast Health and Social Care Trust, Belfast, UK*

CASE 4: SOMETIMES MORPHOLOGY AND IMMUNOHISTOCHEMISTRY CANNOT DO IT ALL

- F 35
- Radiology- large myometrial-based uterine mass
- Underwent endometrial biopsy which was reported as undifferentiated carcinoma
- Radiology showed stage IV disease with peritoneal and liver deposits and external iliac node involvement
- Treated with 3 cycles of carbotaxol and paclitaxel
- Did not respond and case was sent for review

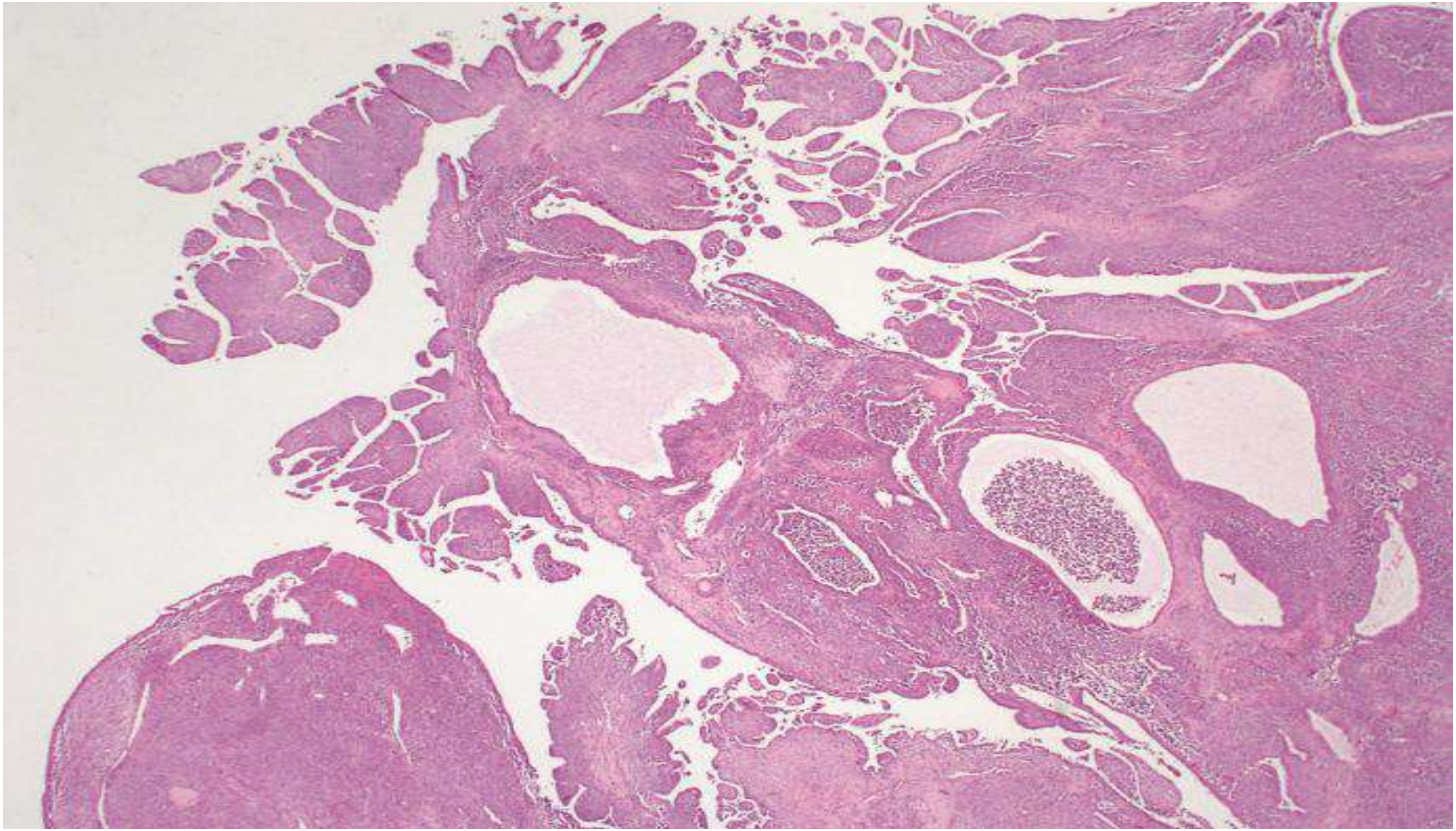

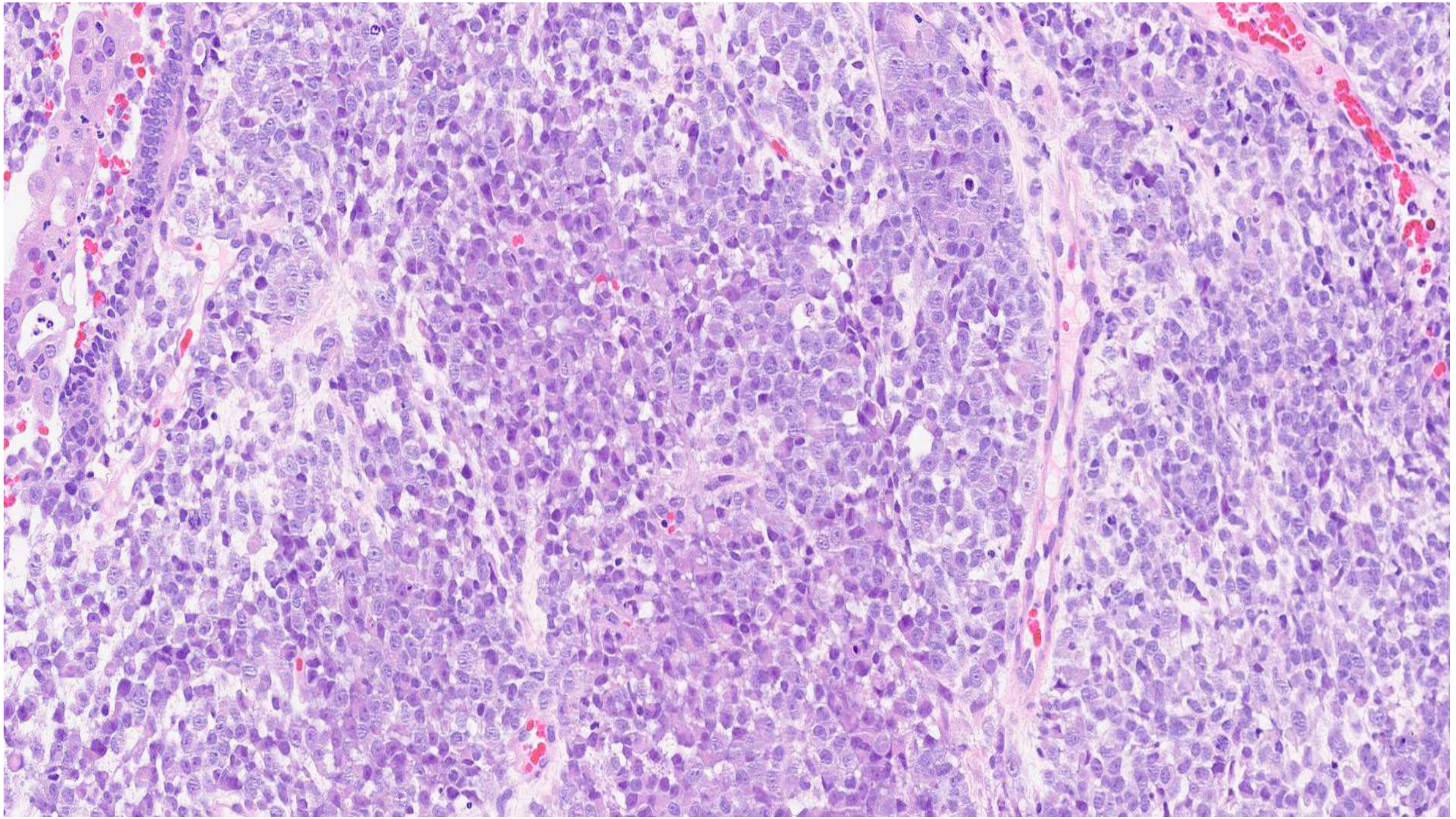

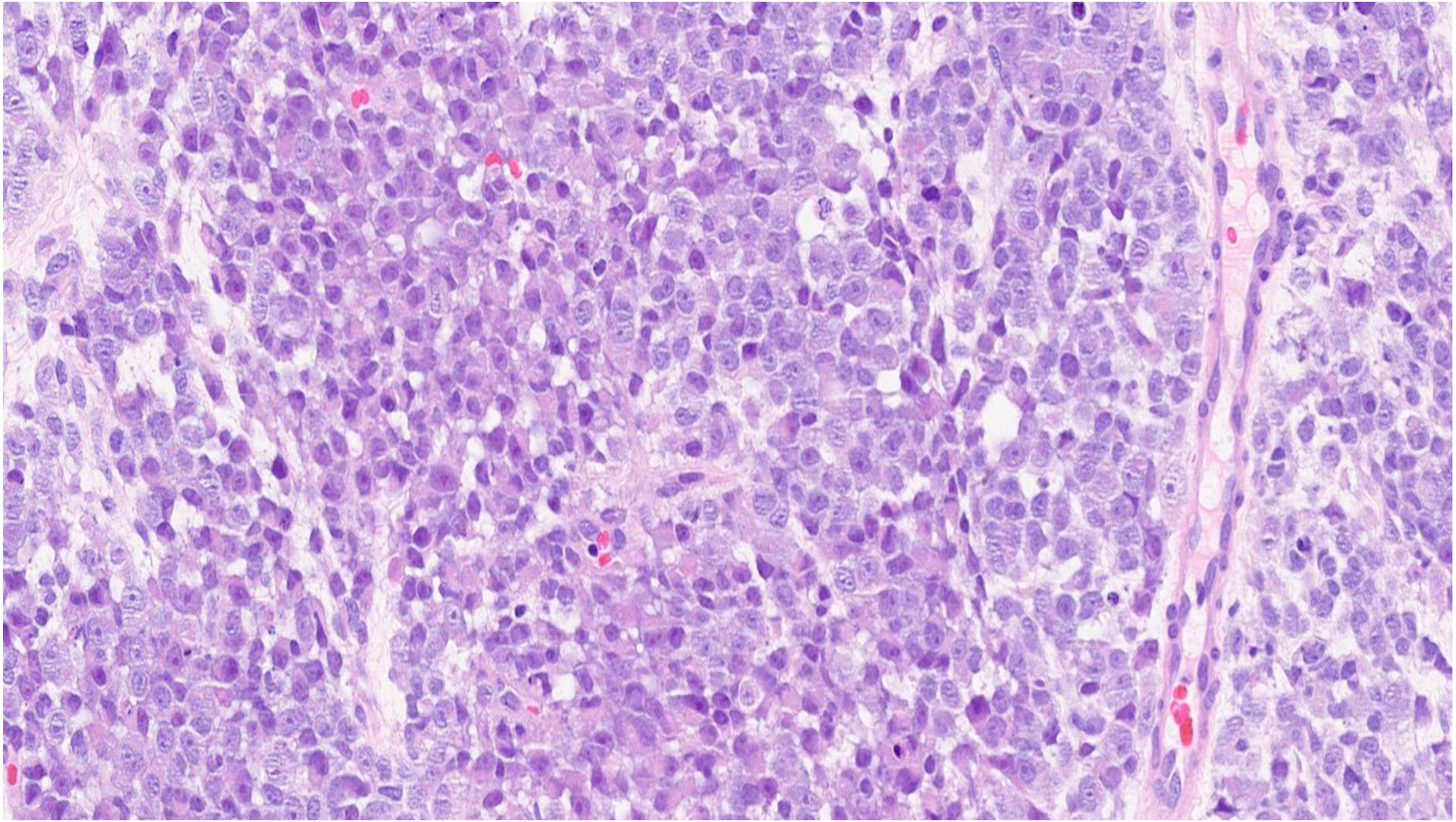

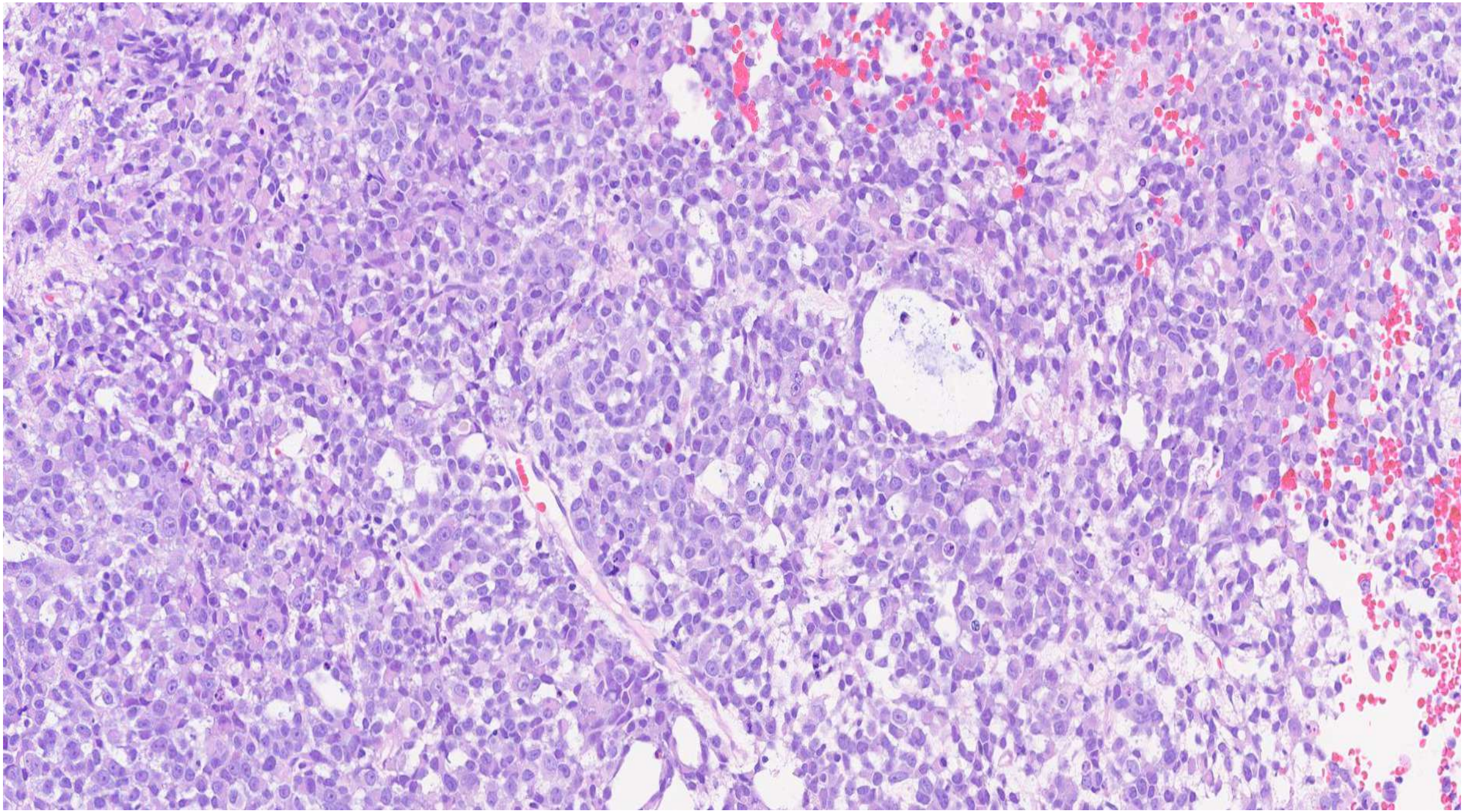

IMMUNOHISTOCHEMISTRY

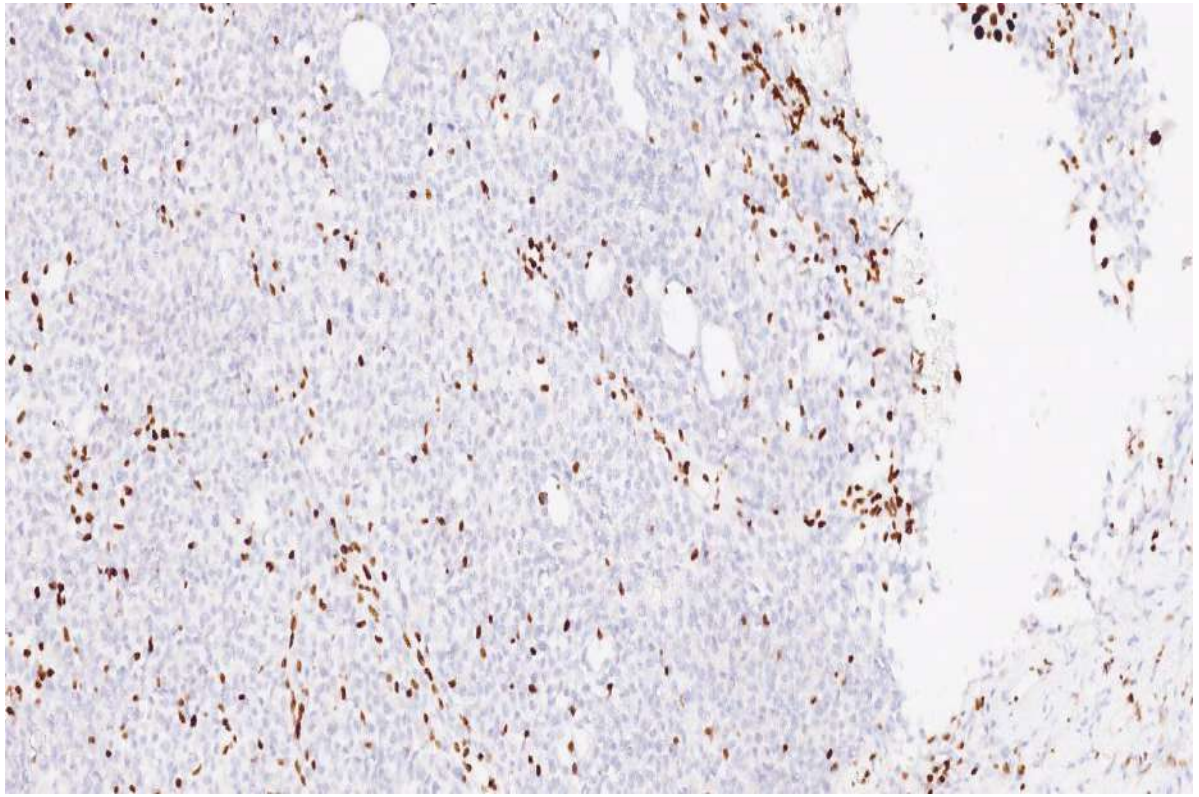

SMARCA4

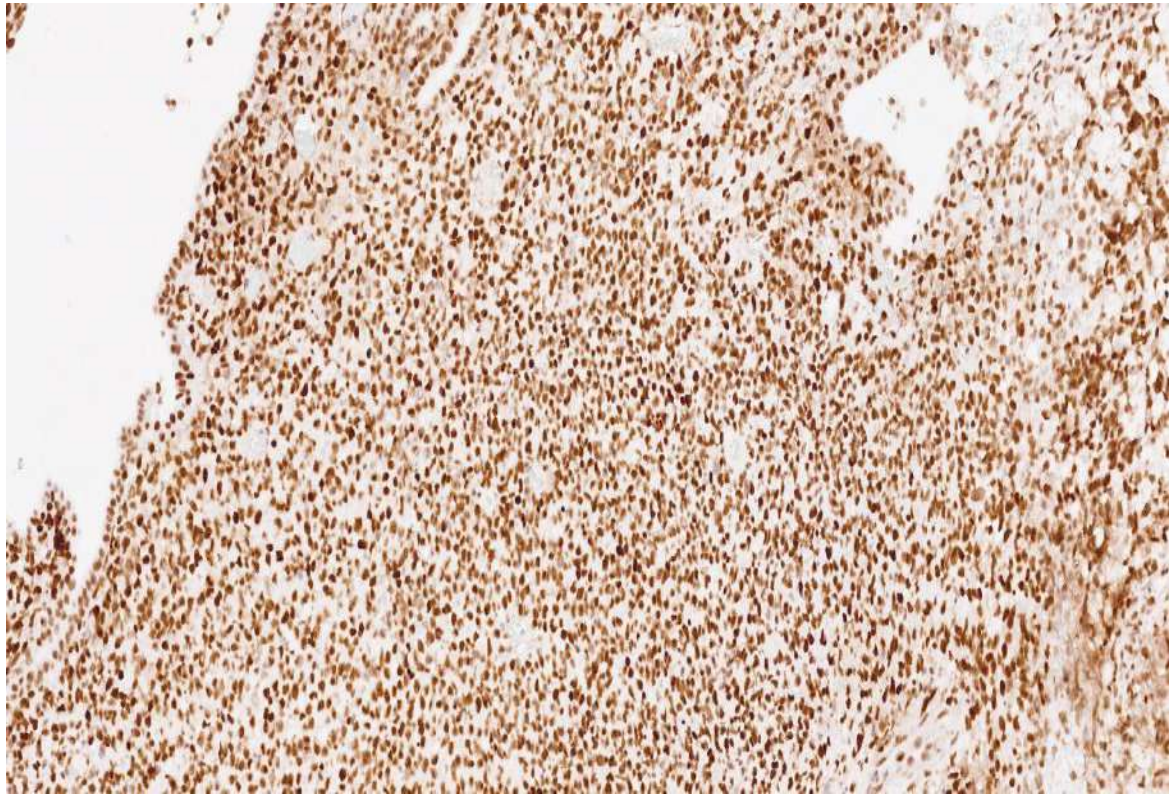

SMARCB1

OTHER IMMUNOHISTOCHEMISTRY AND MOLECULAR

- EMA (occasional cells positive) and p16 focal
- MMR retained
- ER, PR, broad spectrum, cyclin D1, CD10, neuroendocrine markers negative
- p53 wild-type
- NGS- *SMARCA4* mutation present
- NGS- no MSI; no *PTEN, CTNNB1, TP53, PIK3CA* mutations

DIFFERENTIAL DIAGNOSIS

- SMARCA4 deficient undifferentiated endometrial carcinoma
- SMARCA4 deficient undifferentiated uterine sarcoma

PMID 29700418

Modern Pathology
https://doi.org/10.1038/s41379-018-0049-z

ARTICLE

SMARCA4-deficient undifferentiated uterine sarcoma (malignant rhabdoid tumor of the uterus): a clinicopathologic entity distinct from undifferentiated carcinoma

David L. Kolin[1] · Fei Dong[2] · Michele Baltay[2] · Neal Lindeman[2] · Laura MacConaill[2] · Marisa R. Nucci[1] · Christopher P. Crum[1] · Brooke E. Howitt[1,3]

Received: 13 December 2017 / Revised: 25 January 2018 / Accepted: 4 February 2018
© United States & Canadian Academy of Pathology 2018

SMARCA4-DEFICIENT UTERINE SARCOMA

- 3 papers (PMID 29700418, 31954538, 31567195)
- Atypical epithelioid cells with scant or abundant cytoplasm, sometimes with rhabdoid morphology; indistinguishable from SCCOHT (typical or large cell variant)
- Sometimes “phyllodes-like” architecture resulting in consideration of adenosarcoma- entrapped normal glands
- SMARCA4 immunohistochemical loss and *SMARCA4* mutations
- One patient had germline *SMARCA4* mutation and daughter had SCCOHT

SMARCA4 UNDIFFERENTIATED SARCOMA: DIFFERENCES FROM SMARCA4 UNDIFFERENTIATED CARCINOMA

- MAY BE VIRTUALLY IMPOSSIBLE ON BIOPSY: MAY MAKE DIFFERENCE TO MANAGEMENT
- Sarcoma- predominantly myometrial based
- Sarcoma- younger patients but significant overlap
- Sarcoma- no low-grade endometrioid component
- Sarcoma- more aggressive- median survival of 7 months
- Sarcoma- no expression of epithelial markers
- Sarcoma- MMR proficient
- Sarcoma- few other molecular events/ monogenic (similar to SCCOHT; different than undifferentiated carcinoma where other molecular are generally present)

CURRENT CASE- FEATURES IN FAVOUR OF CARCINOMA

- Focal expression of EMA

CURRENT CASE- FEATURES IN FAVOUR OF SARCOMA

- Radiology (myometrial-based mass)
- Phyllodes-like architecture
- No low-grade endometrioid component (but only biopsy)
- MMR proteins retained
- NGS- no MSI; no *PTEN, CTNNB1, TP53, PIK3CA* mutations

CASE 5: THERE ARE NEW ENTITIES OUT THERE AND EVERYONE WANTS TO DIAGNOSE THEM BUT THERE ARE ALWAYS EXCEPTIONS

- F 45
- Prior hysterectomy and BSO for endometriosis
- Nodule on anterior abdominal wall

PMID: 35384888

Histopathology

Histopathology 2016, **68**, 1013–1020. DOI: 10.1111/his.12895

Hormone receptor-negative, thyroid transcription factor 1-positive uterine and ovarian adenocarcinomas: report of a series of mesonephric-like adenocarcinomas

Marie McFarland, Charles M Quick[1] & W Glenn McCluggage

MESONEPHRIC-LIKE ADENOCARCINOMAS- PMID 35384888

- Uterine corpus or ovarian neoplasms
- Morphologically essentially very similar/ identical to cervical mesonephric adenocarcinomas
- Admixture of architectural patterns (small tubules/ glands, sometimes with eosinophilic colloid-like secretions; dilated glands; papillary; solid; spindled)
- Cytology- atypical, angulated, clear vesicular nuclei, often with overlapping (papillary thyroid-like)
- Lack of squamous or mucinous differentiation
- Immunohistochemistry- PAX8 positive; ER/ PR “flat” negative (occasionally focally positive); TTF1, GATA3 often diffuse; p53 wild-type; CD10, calretinin variably positive; WT1 negative; p16 focal or negative
- MMR retained
- Recommend to call “mesonephric-like” adenocarcinomas
- Later found that *KRAS* mutations are very common (sometimes also *PIK3CA*)

PMID: 40279981

Gynecologic Oncology 197 (2025) 57–65

Contents lists available at ScienceDirect

Gynecologic Oncology

journal homepage: www.elsevier.com/locate/ygyno



Mesonephric-like adenocarcinoma of the female genital tract: Pathologic diagnosis, clinical outcomes, and novel therapeutics

Kari L. Ring [a,*], Anne M. Mills [b], Brooke E. Howitt [c], Rachel N. Grisham [d], Elizabeth D. Euscher [e], Hyun-Soo Kim [f], Ann H. Klopp [g], David L. Kolin [h], W. Glenn McCluggage [i], Jelena Mirkovic [j], Kay J. Park [k], Eliane Aoun [l], Chika Awujo [l], Ji Son [l], Samuel C. Mok [l], Sammy Ferri-Borgogno [l], David S. Hong [m], Lien Hoang [n], Amir A. Jazaeri [l], Jeffrey A. How [l], Karen H. Lu [o]

Table 1
Expert consensus statements for pathologic diagnosis of MLA.

General
• A diagnosis of MLA should only be made on the basis of the characteristic morphology with a supportive immunophenotype
• Specialist review should be considered in cases which do not exhibit a classical morphology with supportive immunophenotype
Morphology
• An admixture of different architectural patterns is a characteristic morphological feature of MLA which is seen in most, but not all, cases. Patterns include tubular, glandular, papillary, solid/diffuse, retiform and glomeruloid
• MLA is characterized by nuclei which are atypical (but usually not markedly pleomorphic) and which are clear and vesicular, and sometimes overlapping (papillary thyroid carcinoma-like) with occasional grooves
• In addition to the presence of characteristic mesonephric-like histology, ciliated, mucinous and squamous differentiation should be absent
• If squamous and/or mucinous differentiation are present and cannot be attributed to a morphologically and immunohistochemically distinct endometrioid component (i.e. a confirmed mixed tumor), the tumor should not be diagnosed as MLA
Immunohistochemistry
• If appropriate morphology is present, a front-line panel of TTF1, GATA3, ER, and PR should be performed to help support the diagnosis.
• TTF1 and/or GATA3 should be positive
o Expression of only one of GATA3 and TTF1 is required for diagnosis; however, if a single marker is positive and it is only focally expressed, additional staining, molecular testing and/or specialist review should be considered.
o TTF1 and GATA3 often have an inverse staining pattern, but it is not required
• The extent of ER and PR is typically <10 % but can be ≥10 % in the context of an otherwise classic MLA. Neither ER nor PR expression should be diffuse.
• MMR proteins should be intact and p53 should be wild-type
• If not already part of reflex testing, these markers should be performed as part of the MLA work-up
• In the setting of ambiguous/uncertain morphology/immunohistochemistry results, additional helpful markers include:
o CD10: Luminal staining supports MLA
o PAX2: Loss of nuclear expression argues against MLA
o PAX8: Absence of diffuse expression argues against MLA
o SOX17: negative or focal expression supports MLA
• Calretinin lacks sensitivity and specificity for MLA, and should not be used in this differential
• In mixed tumors, extent of staining should be based on the suspected MLA component alone (i.e. not averaged across different histotype components)
Molecular
• In cases where the morphology or immunohistochemistry is not classical but MLA is considered, molecular testing should be performed
• MLA do not harbor *TP53* or *POLE* pathogenic mutations and are microsatellite stable (MSS); thus they are classified as TCGA-NSMP molecular subgroup of endometrial carcinomas. Although the TCGA classification was defined and validated in endometrial tumors, for MLA, the same molecular criteria apply in extrauterine MLA
• A *KRAS*/*NRAS* canonical activating mutation (in the context of a TCGA-NSMP molecular class for endometrial tumors) is supportive of a MLA, although not specific
• Other genes commonly mutated in gynecologic carcinomas, such as *PIK3CA* and *ARID1A*, may also be altered in a subset of MLA
• Copy number alterations may be moderate to high in MLA, and frequently include chromosome 1q gains

HOW TO DIAGNOSE MLA?

- RISK OF UNDERDIAGNOSIS AND OVERDIAGNOSIS
- “New” entity so everyone wants to diagnose
- Always exceptions but in general should not diagnose if squamous elements present (unless mixed tumour)
- Should doubt diagnosis if MMR deficient/ MSI-H or p53 mutation-type staining/ *TP53* mutation
- Need to see a compatible morphology, including cytology
- If characteristic MLA morphology is present, a front-line panel of TTF1, GATA3, ER, and PR should be done to help support the diagnosis
- TTF1 and/or GATA3 should be positive
- ER and PR expression should be “limited”
- Doubt diagnosis if PAX8 not diffuse and strong
- ? Value of SOX17 and PAX2
- In non-classical cases, molecular testing (*KRAS/ NRAS*) and/ or specialist review may be valuable

CASE 5: THERE ARE NEW ENTITIES OUT THERE AND EVERYONE WANTS TO DIAGNOSE THEM BUT THERE ARE ALWAYS EXCEPTIONS

- F 45
- Prior hysterectomy and BSO for endometriosis
- Nodule on anterior abdominal wall

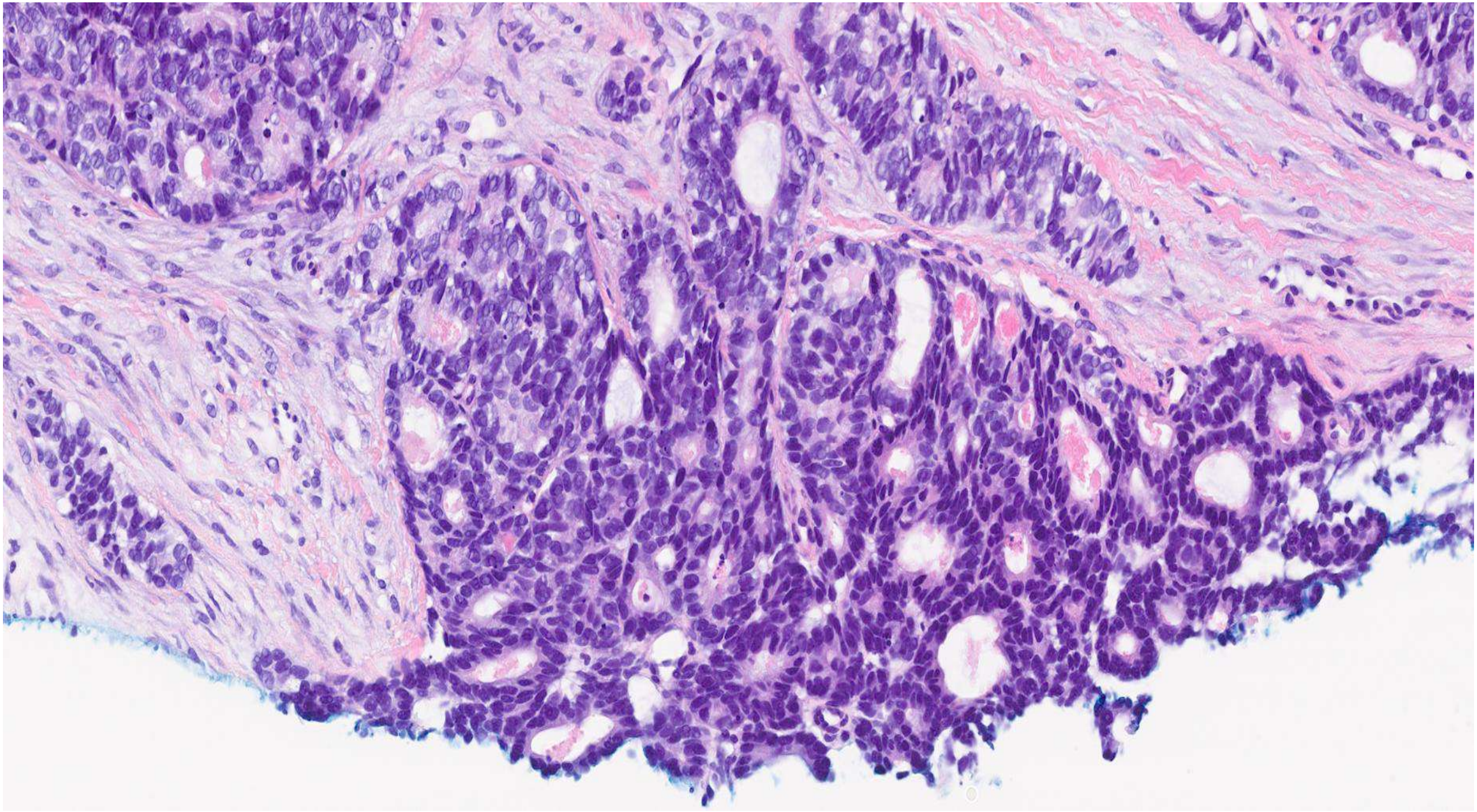

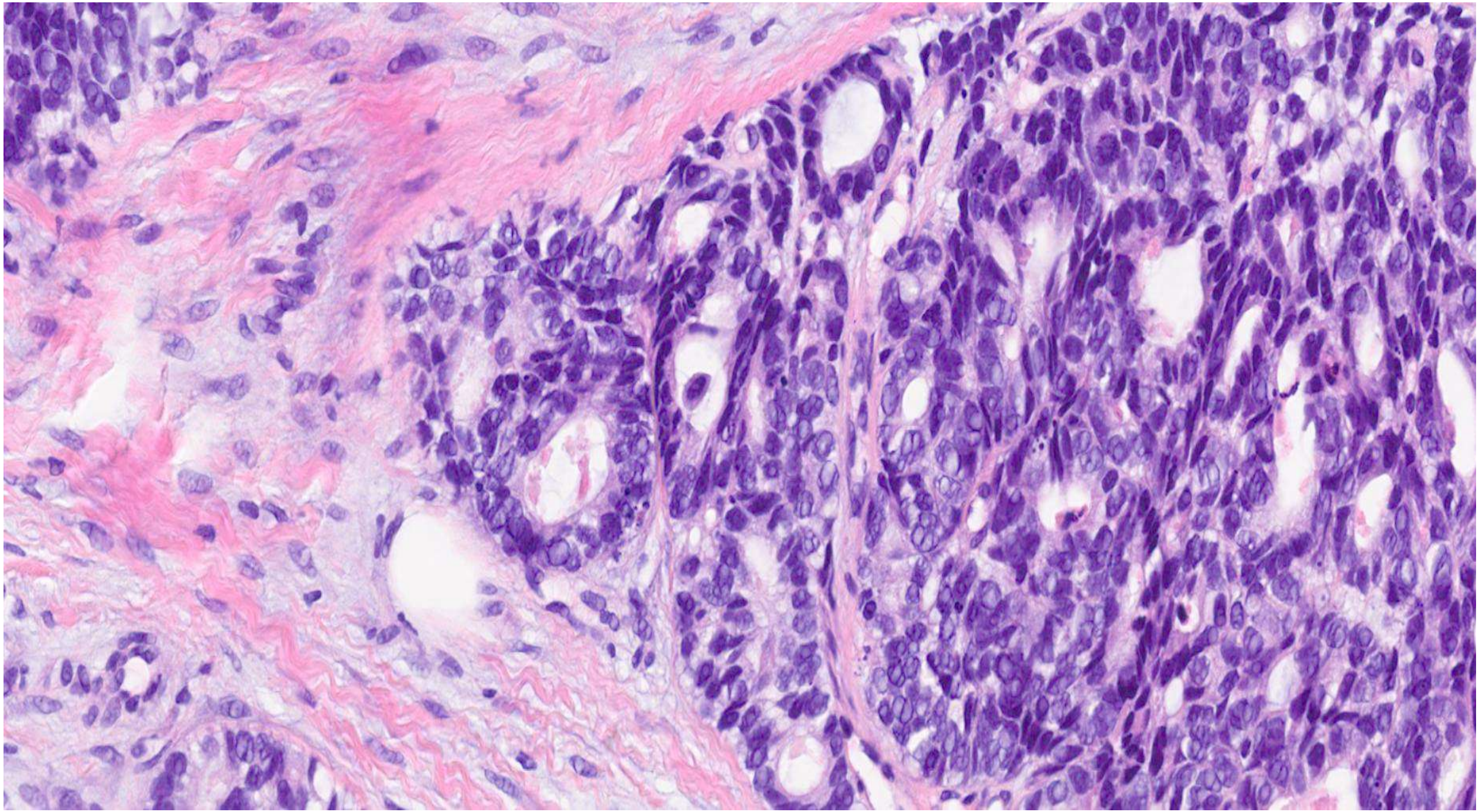

TTF1

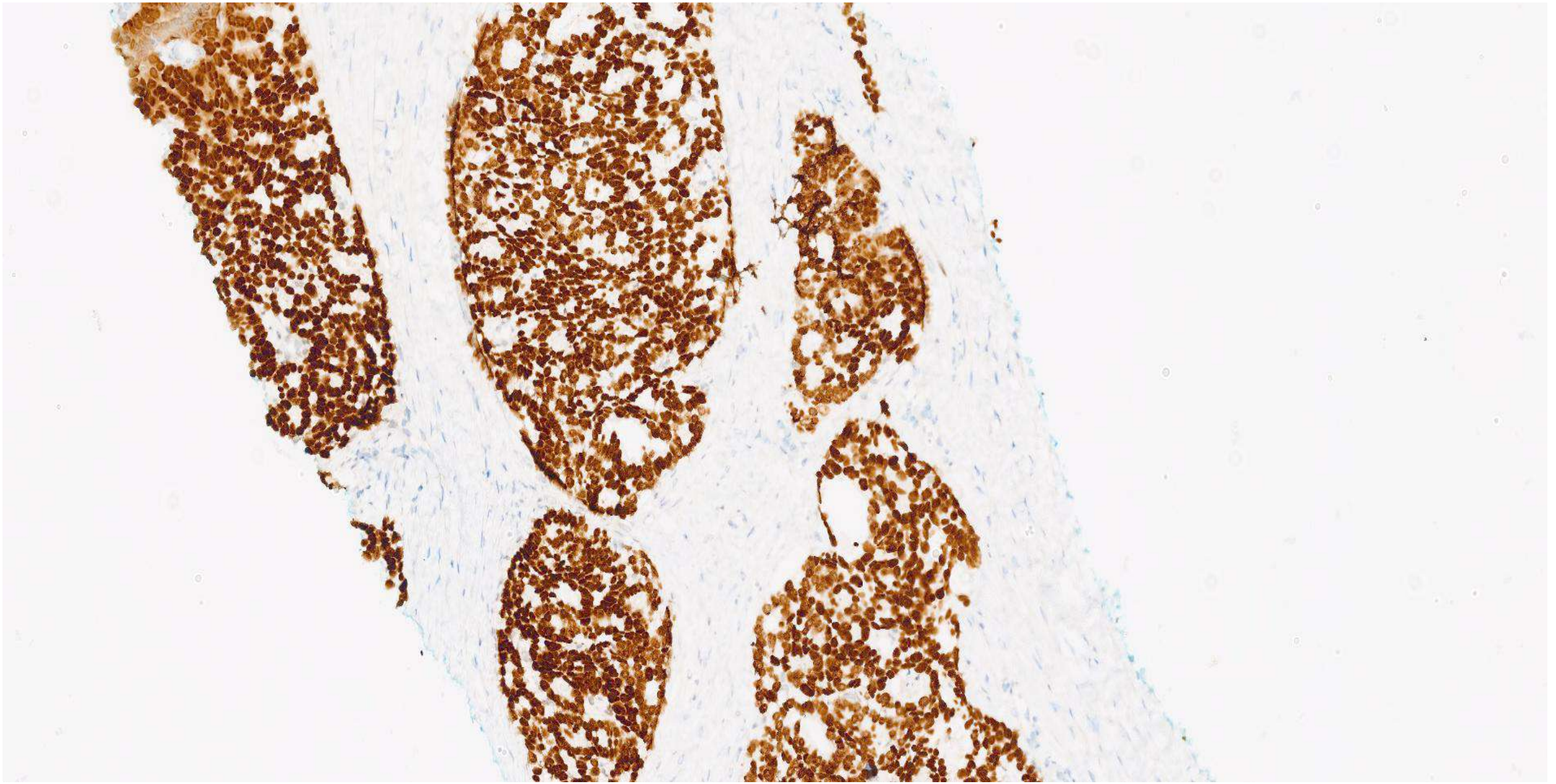

GATA3

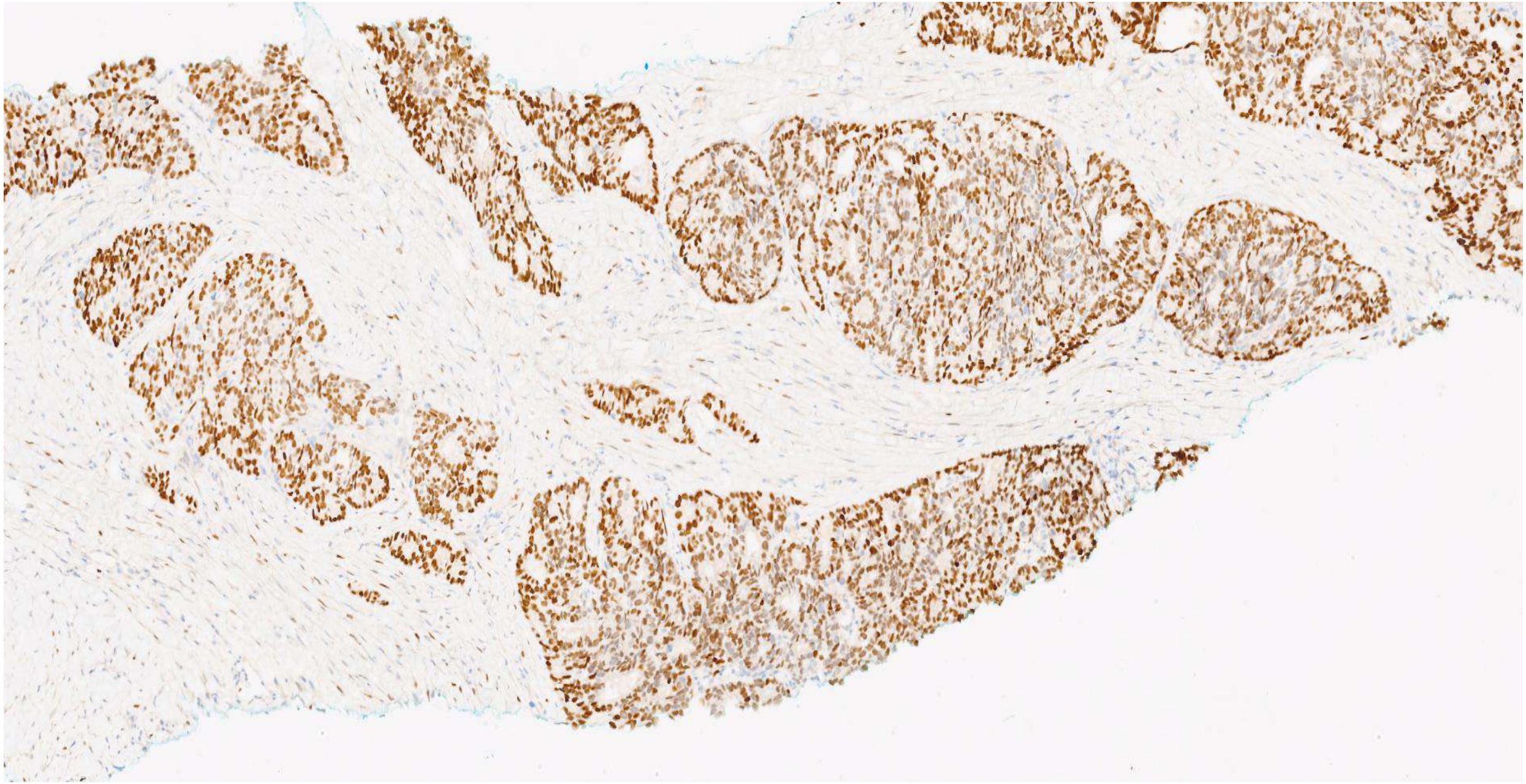

CD10

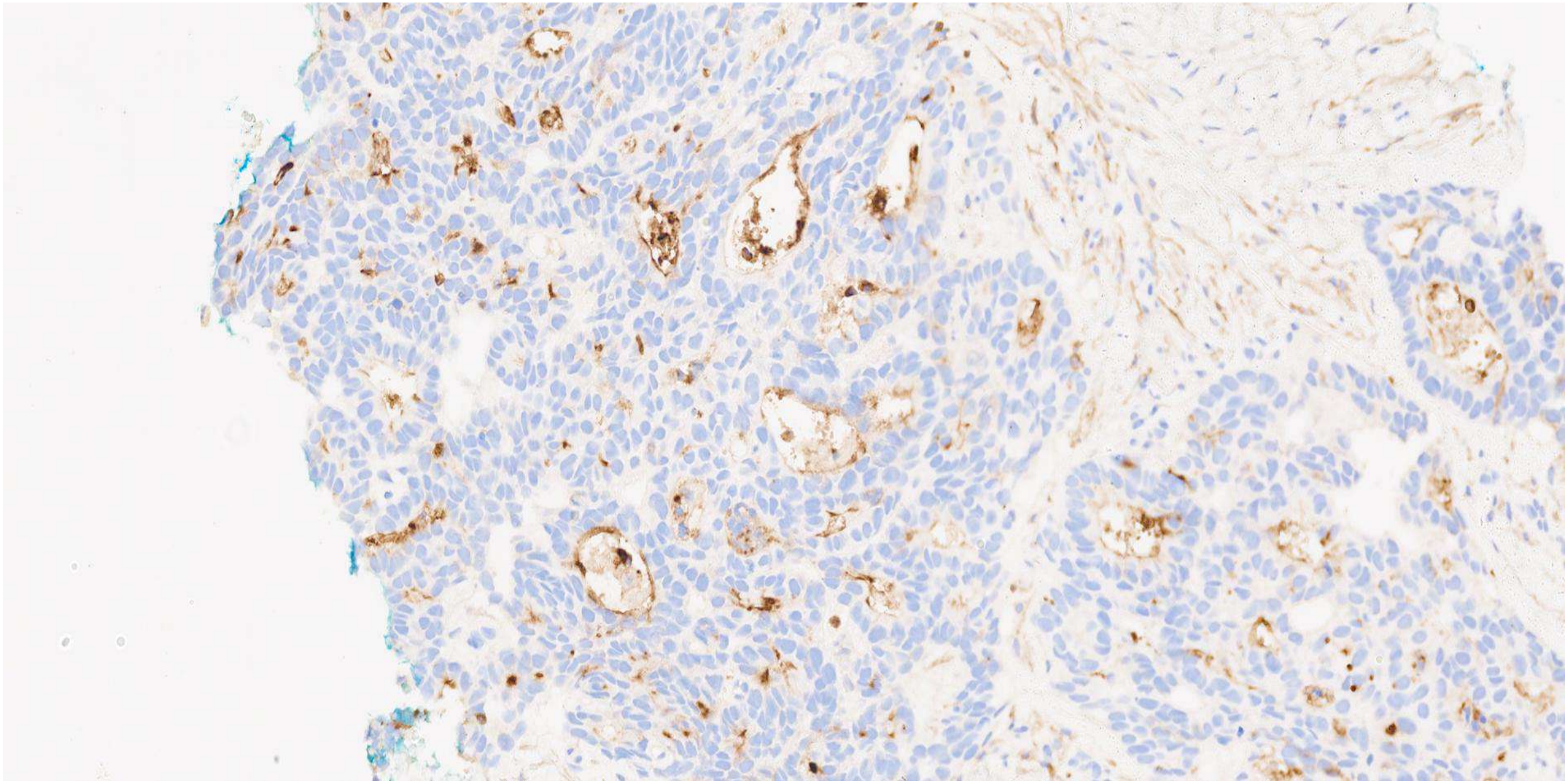

FURTHER IMMUNOHISTOCHEMISTRY AND MOLECULAR

- MMR immunohistochemistry retained
- PAX8 diffuse
- p53 wild-type
- NGS- *KRAS* and *PIK3CA* mutations

ER

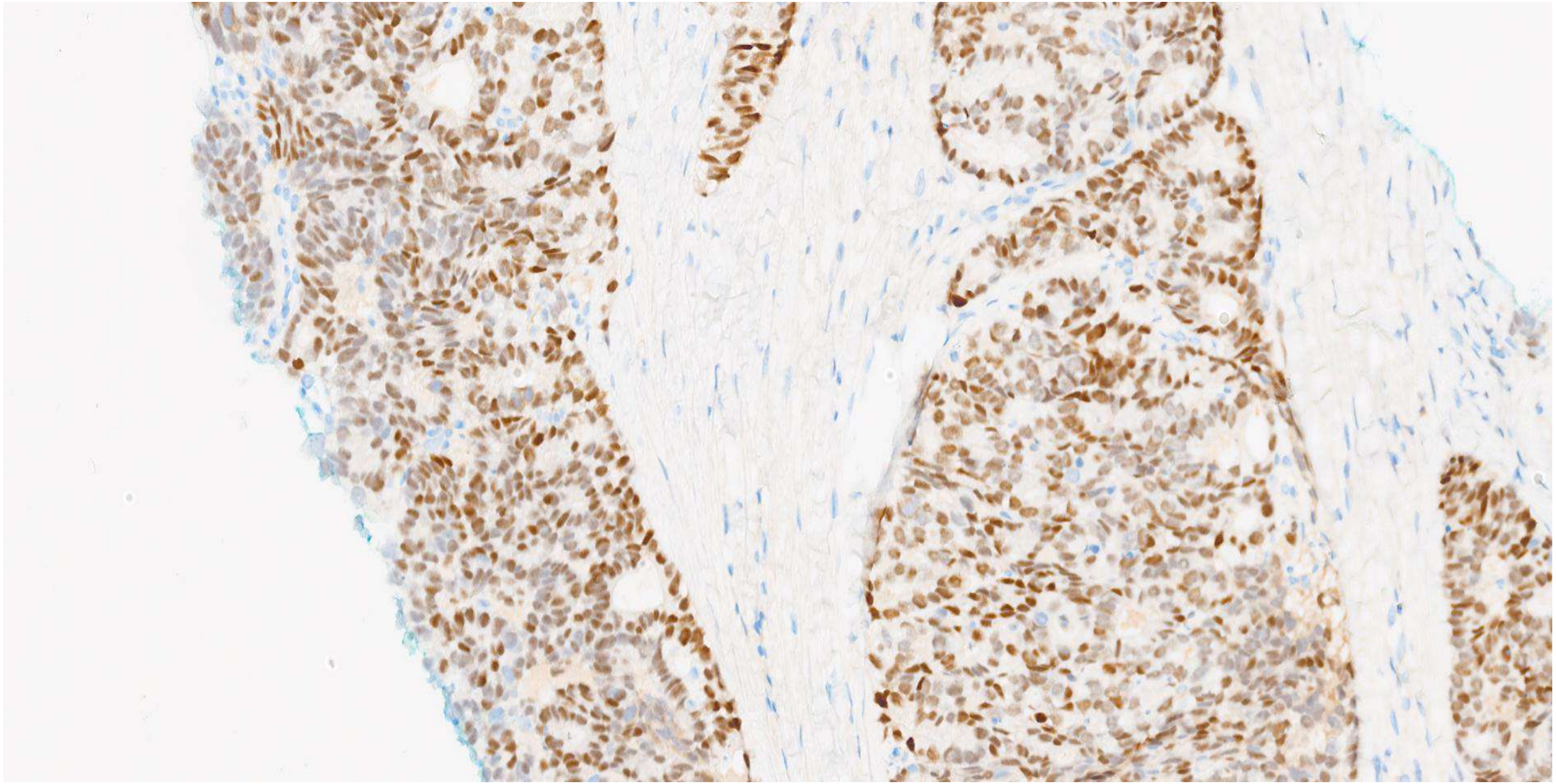

RISK OF “OVERDIAGNOSIS” OF MLA: ENDOMETRIOID CARCINOMA

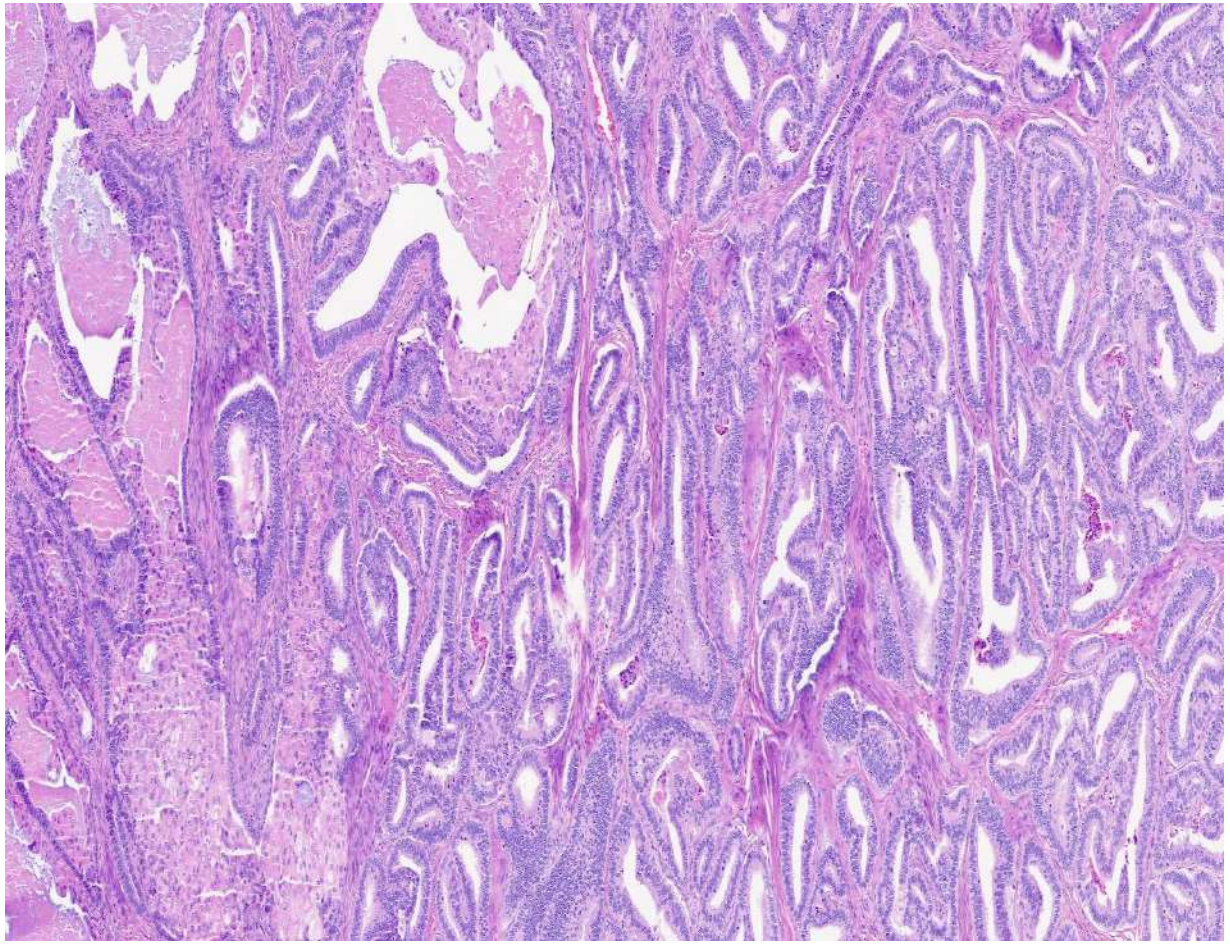

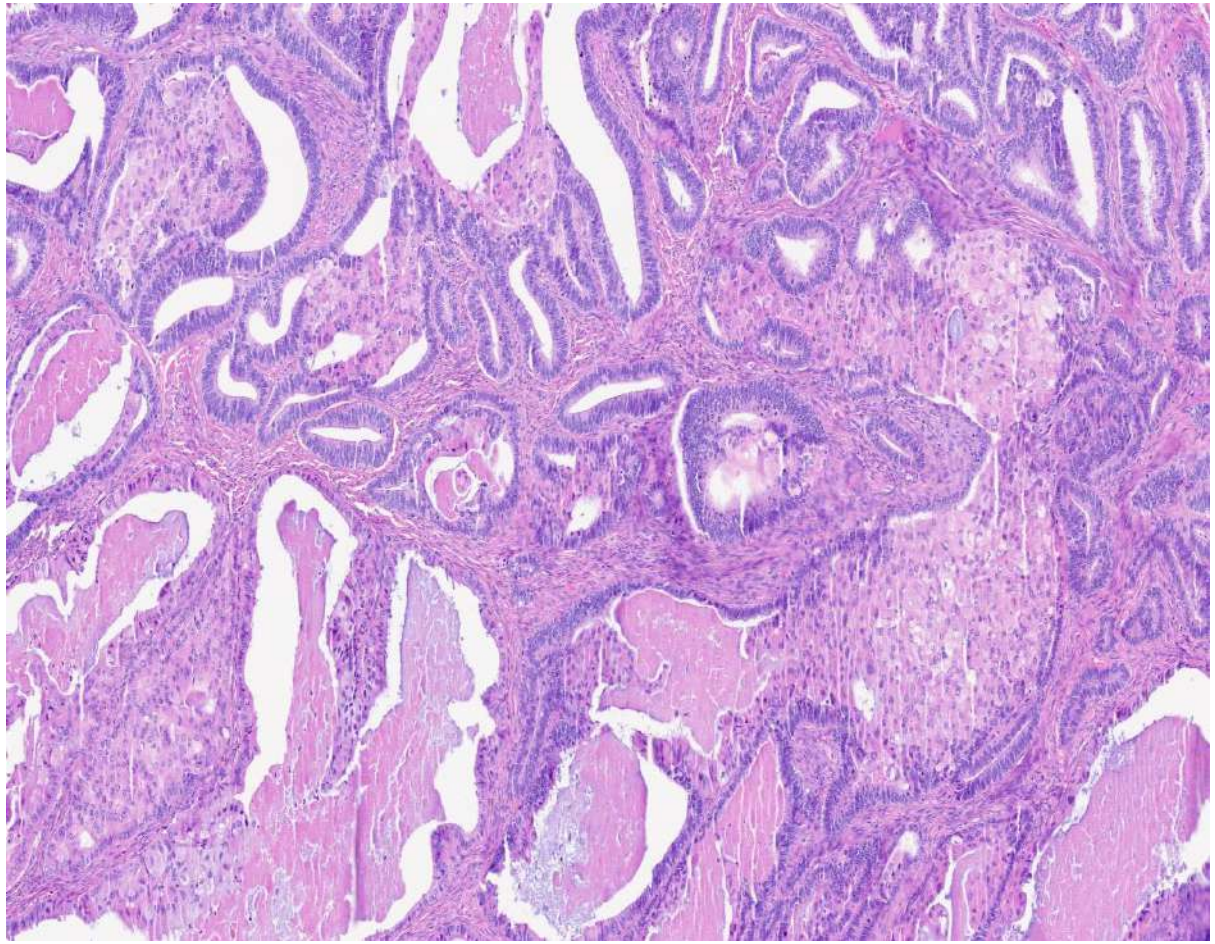

RISK OF “OVERDIAGNOSIS” OF MLA

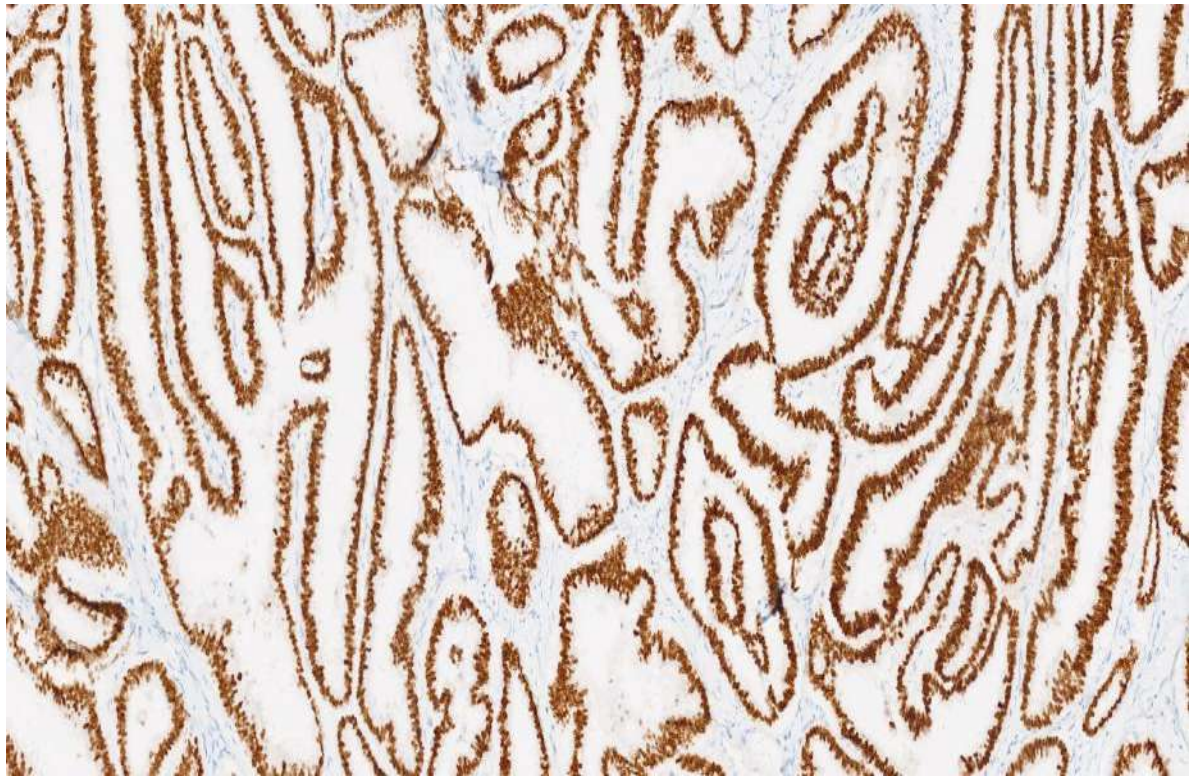

TTF1

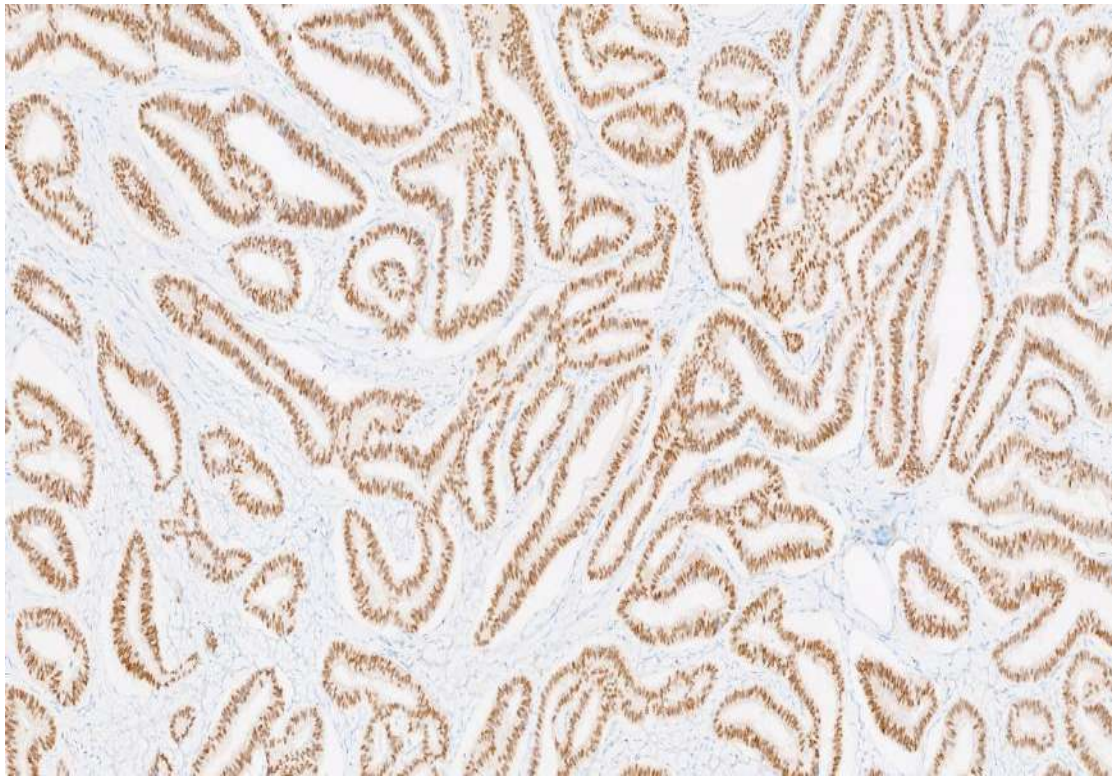

GATA3

RISK OF “OVERDIAGNOSIS” OF MLA: CLEAR CELL CARCINOMA

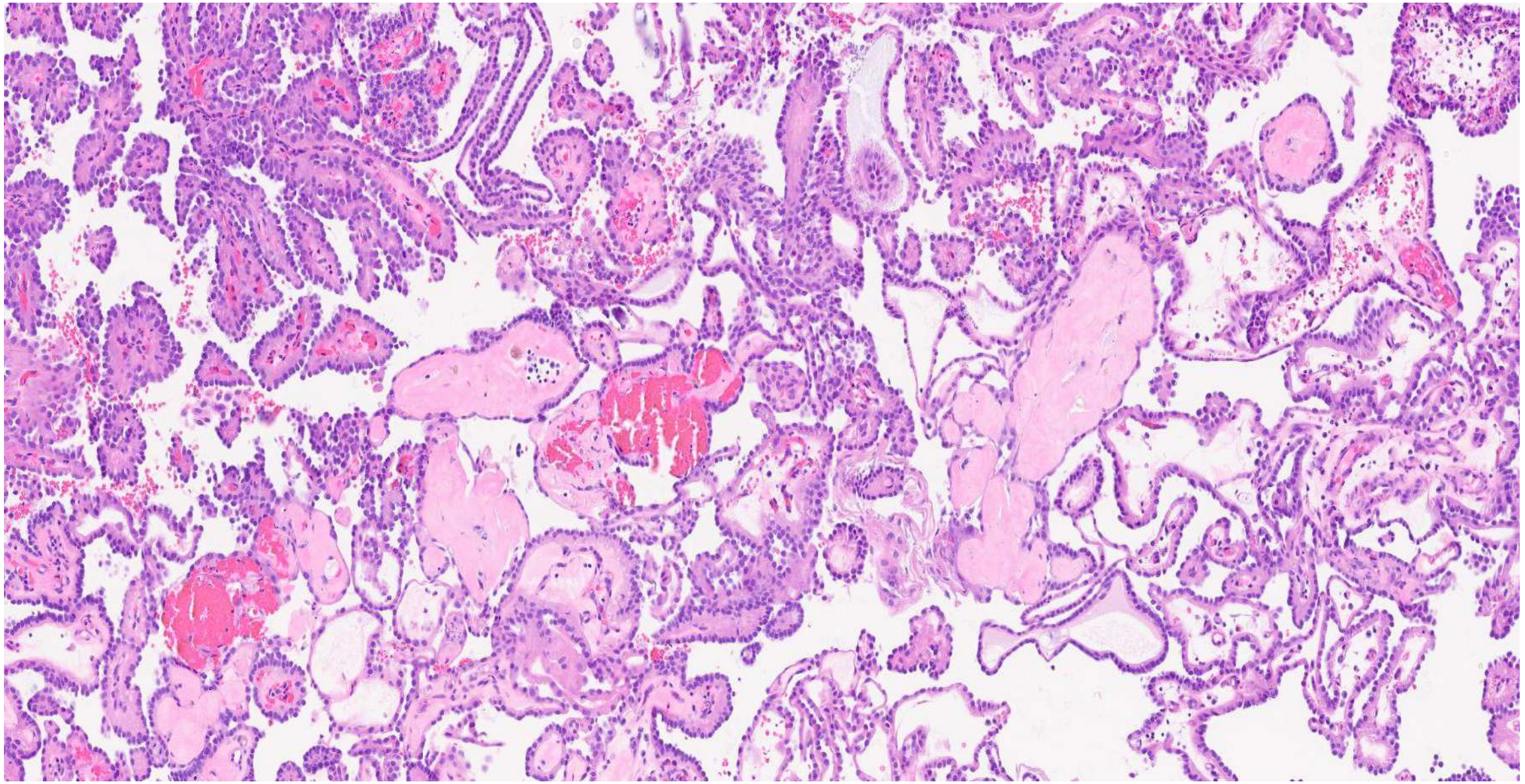

TTF1

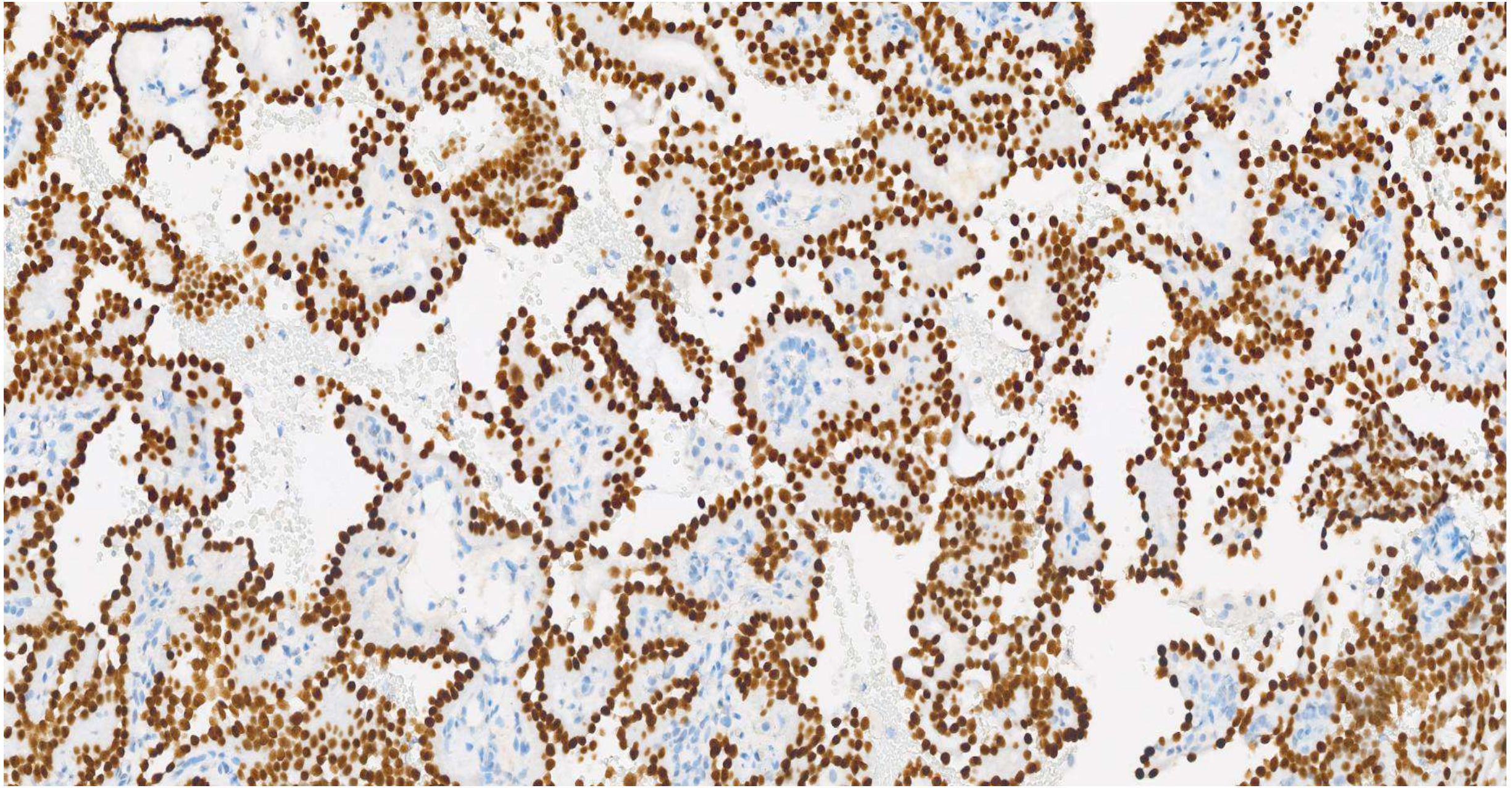

GATA3

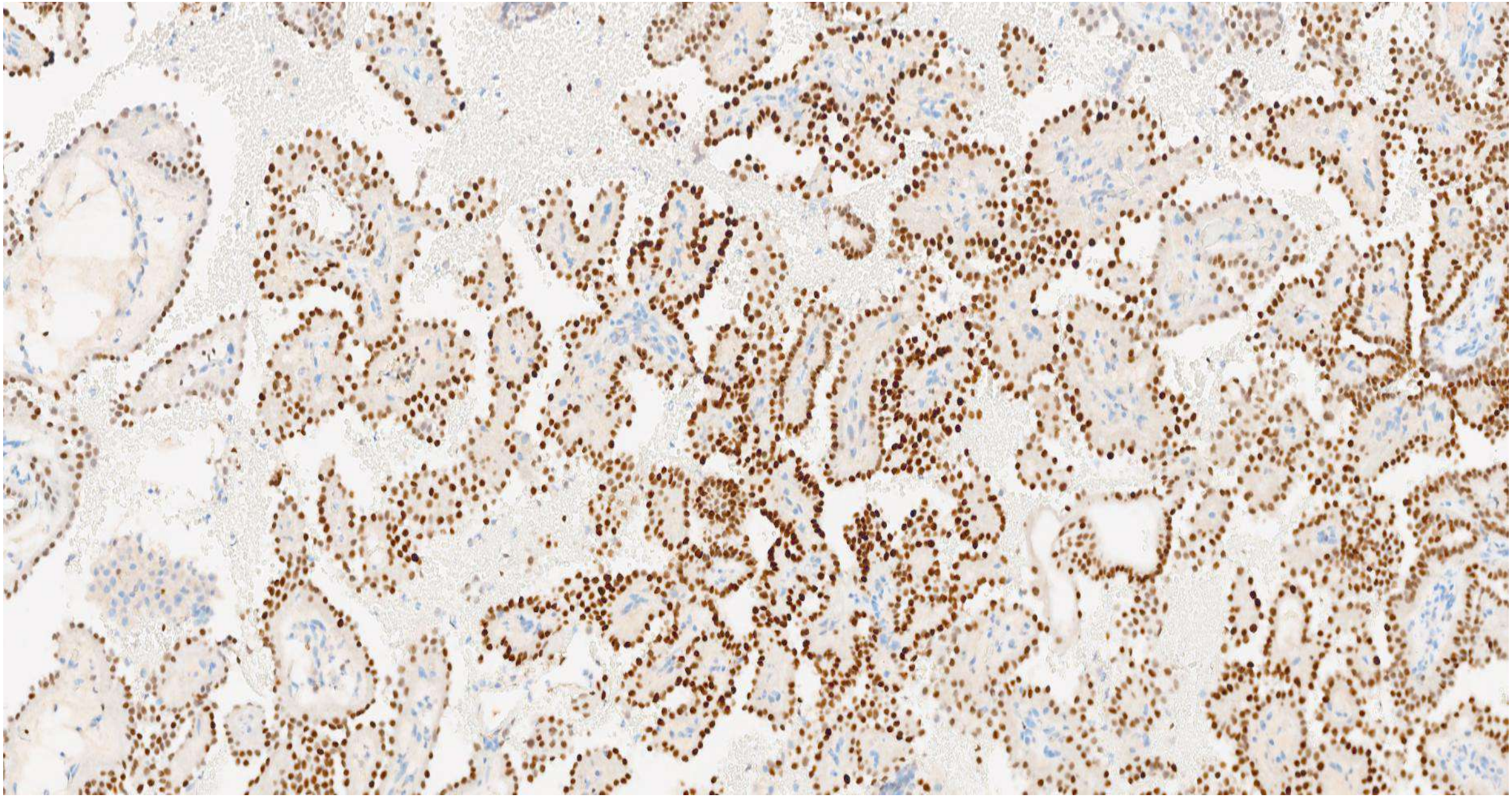

NAPSIN A

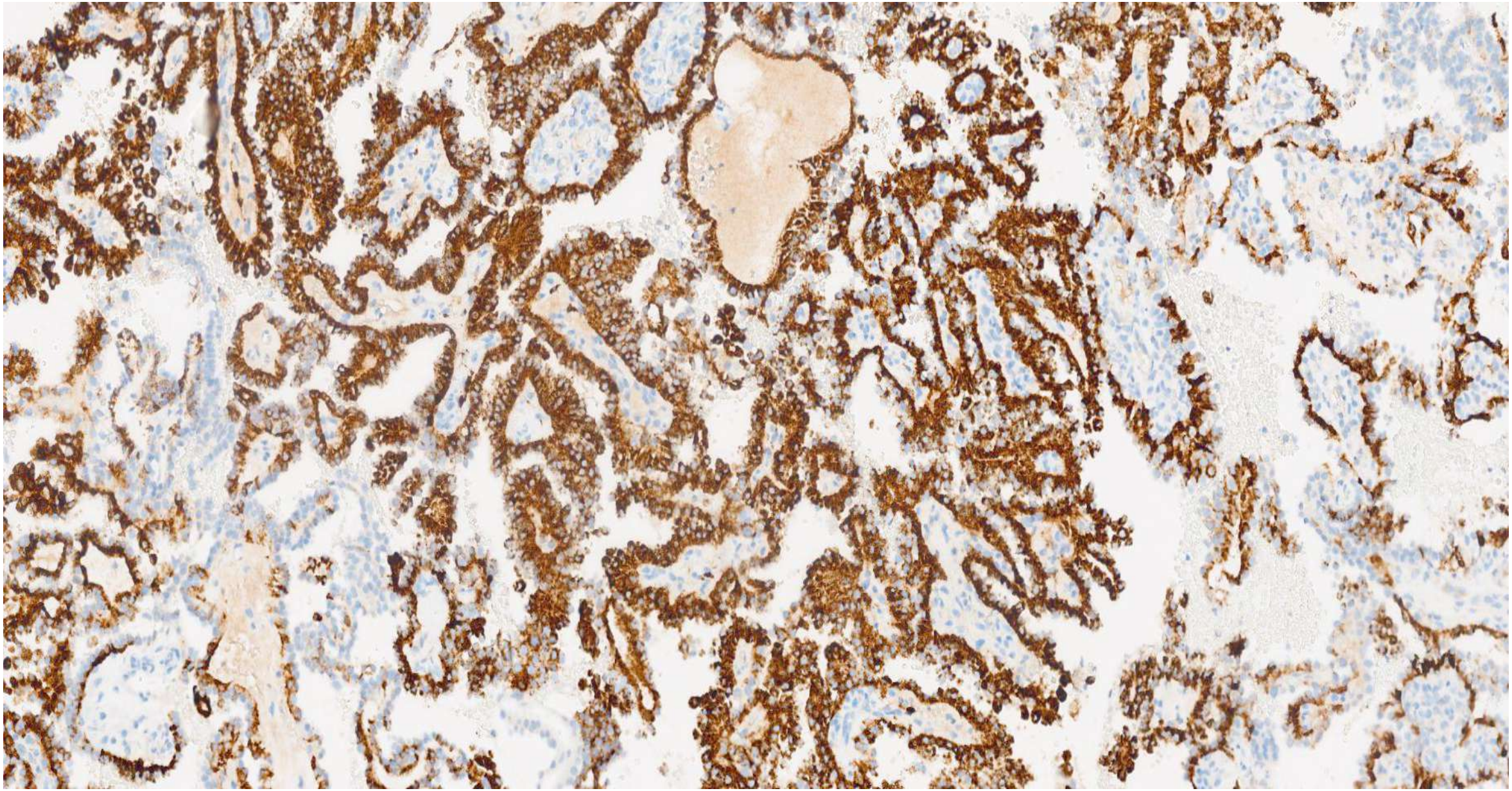

HNF 1 beta

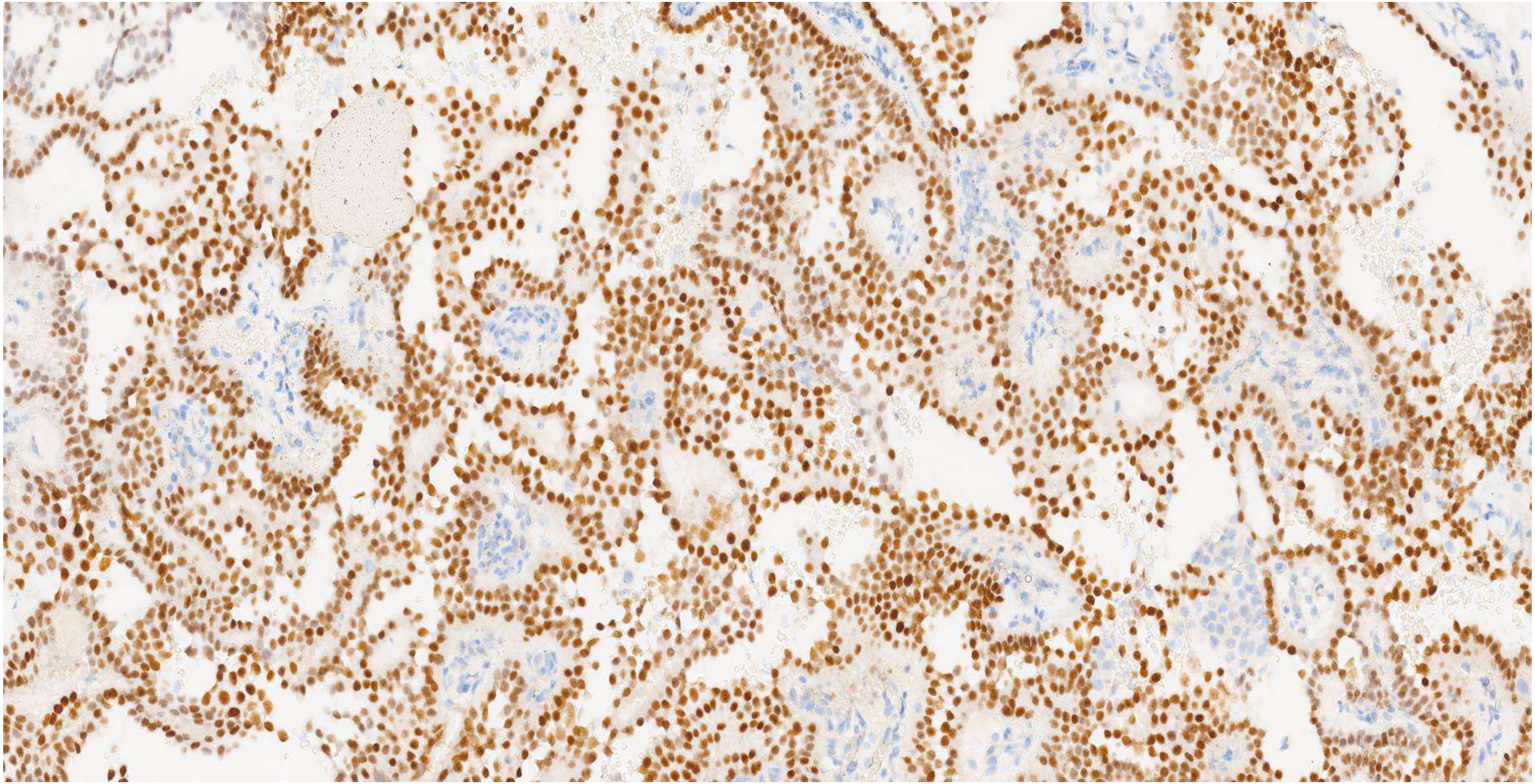

PMID 40377328: ANOTHER LESSON – NO MARKER IS TOTALLY SPECIFIC OR SENSITIVE

ORIGINAL ARTICLE

Napsin-A Expression in Mesonephric and Mesonephric-like Adenocarcinomas: Implications for Distinction From Clear Cell Carcinoma

Jelena Mirkovic, MD, PhD,† Ekaterina Olkhov-Mitsel, PhD,† Sharon Nofech-Mozes, MD,*† Oluwole Fadare, MD,‡ and W. Glenn McCluggage, FRCPath§*

CASE 6: SOME ENTITIES BECOME “LESS PREVALENT” OVER TIME

- F 55
- Hysterectomy for endometrial carcinoma; biopsy diagnosed as neuroendocrine carcinoma

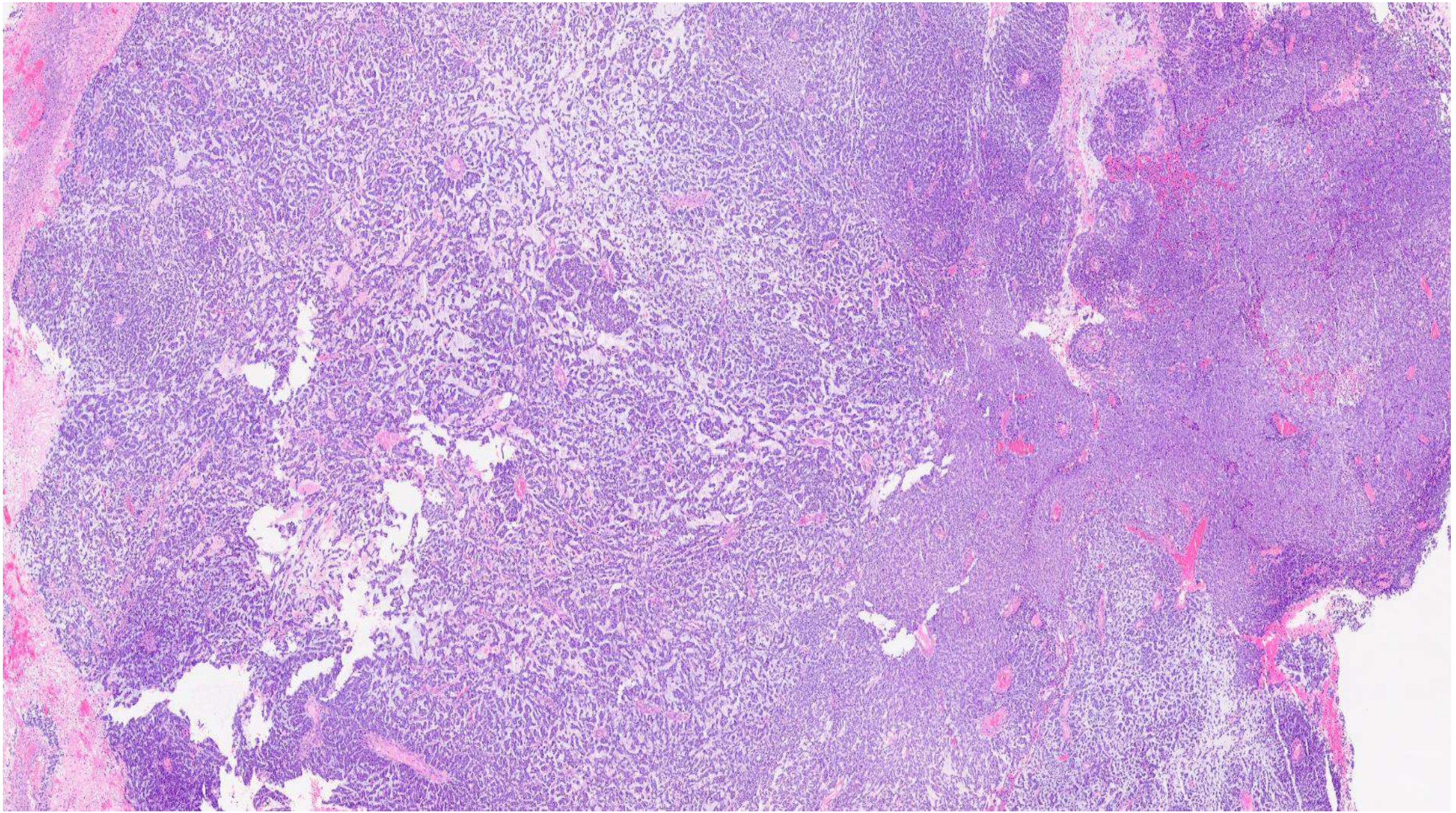

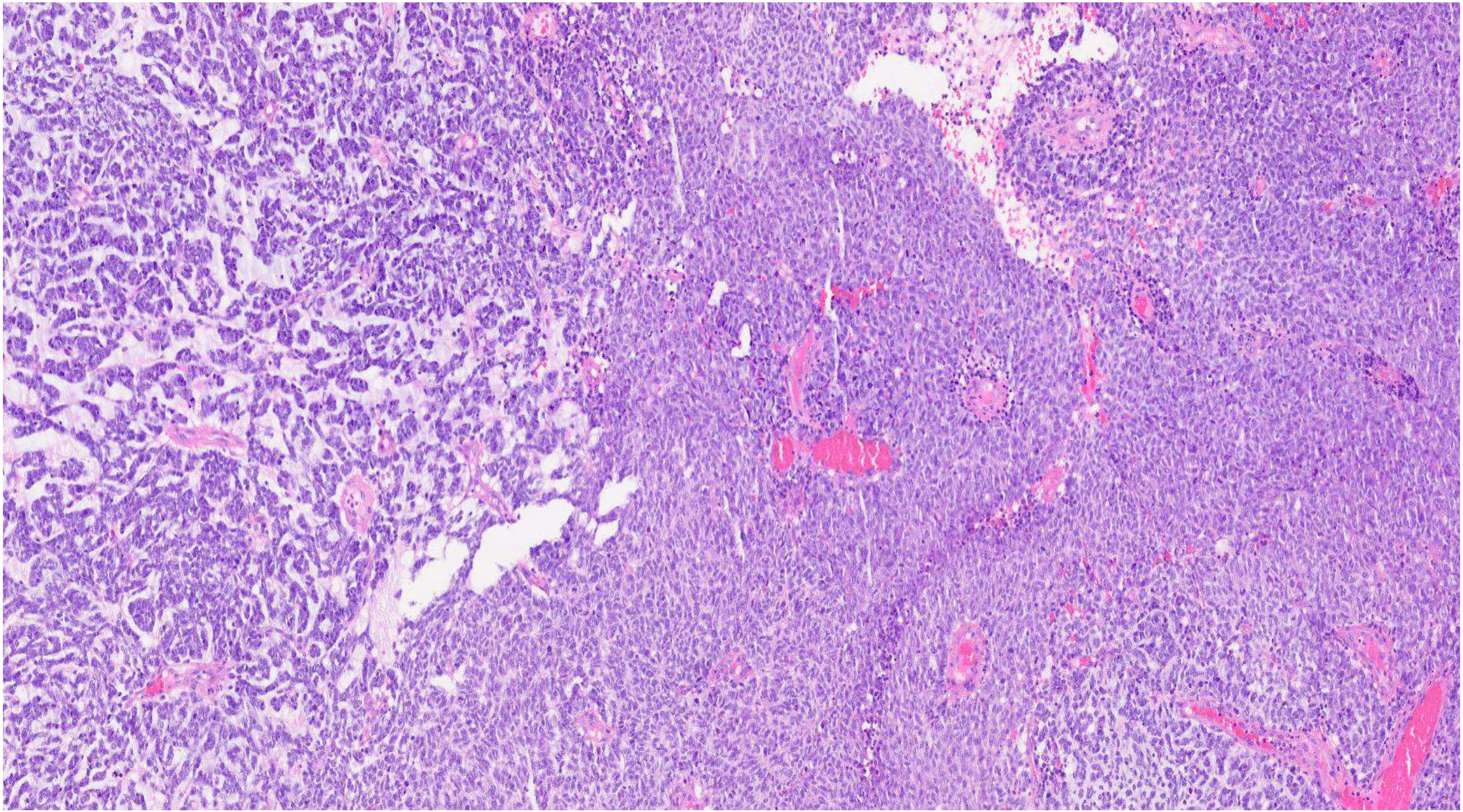

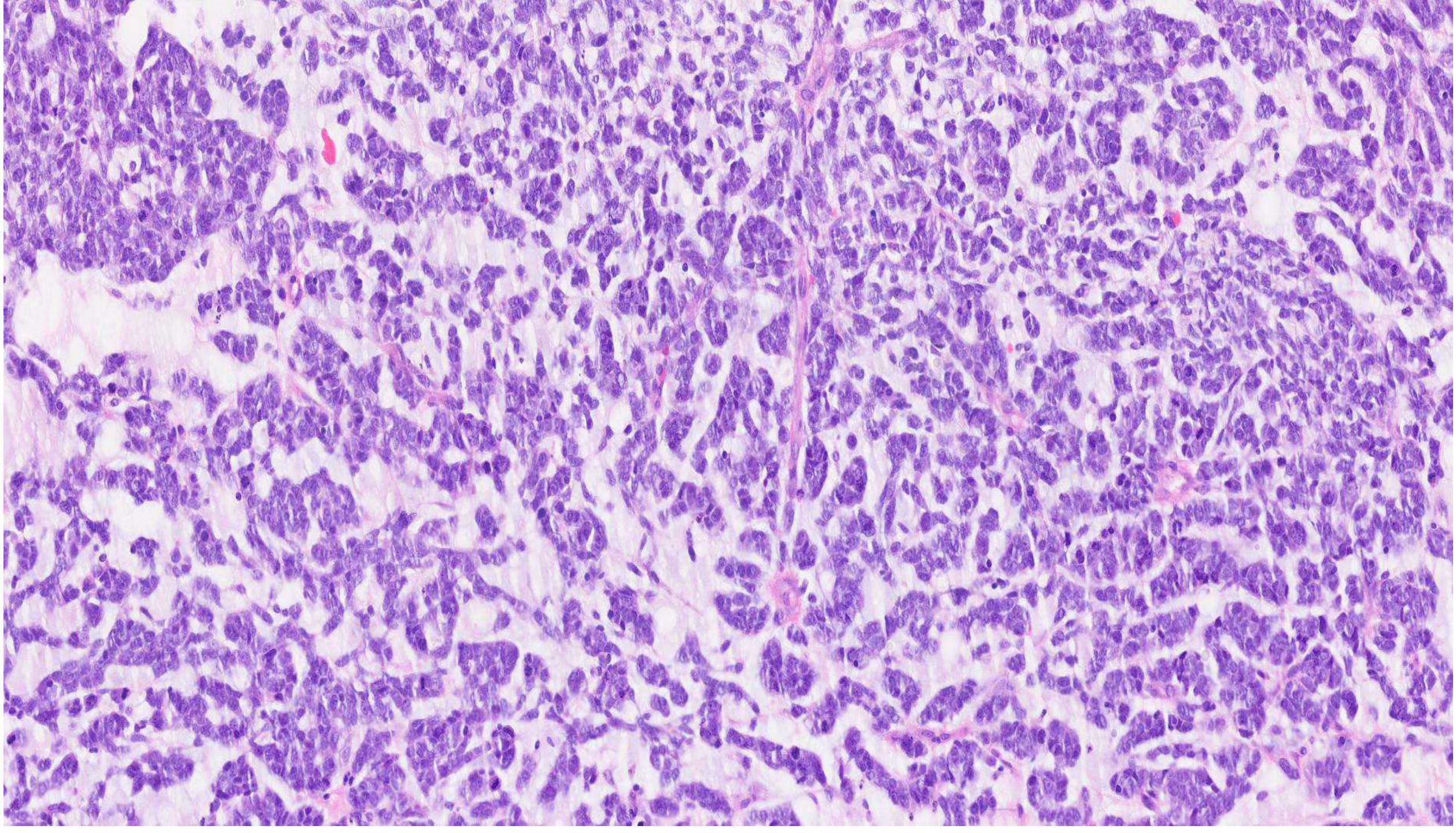

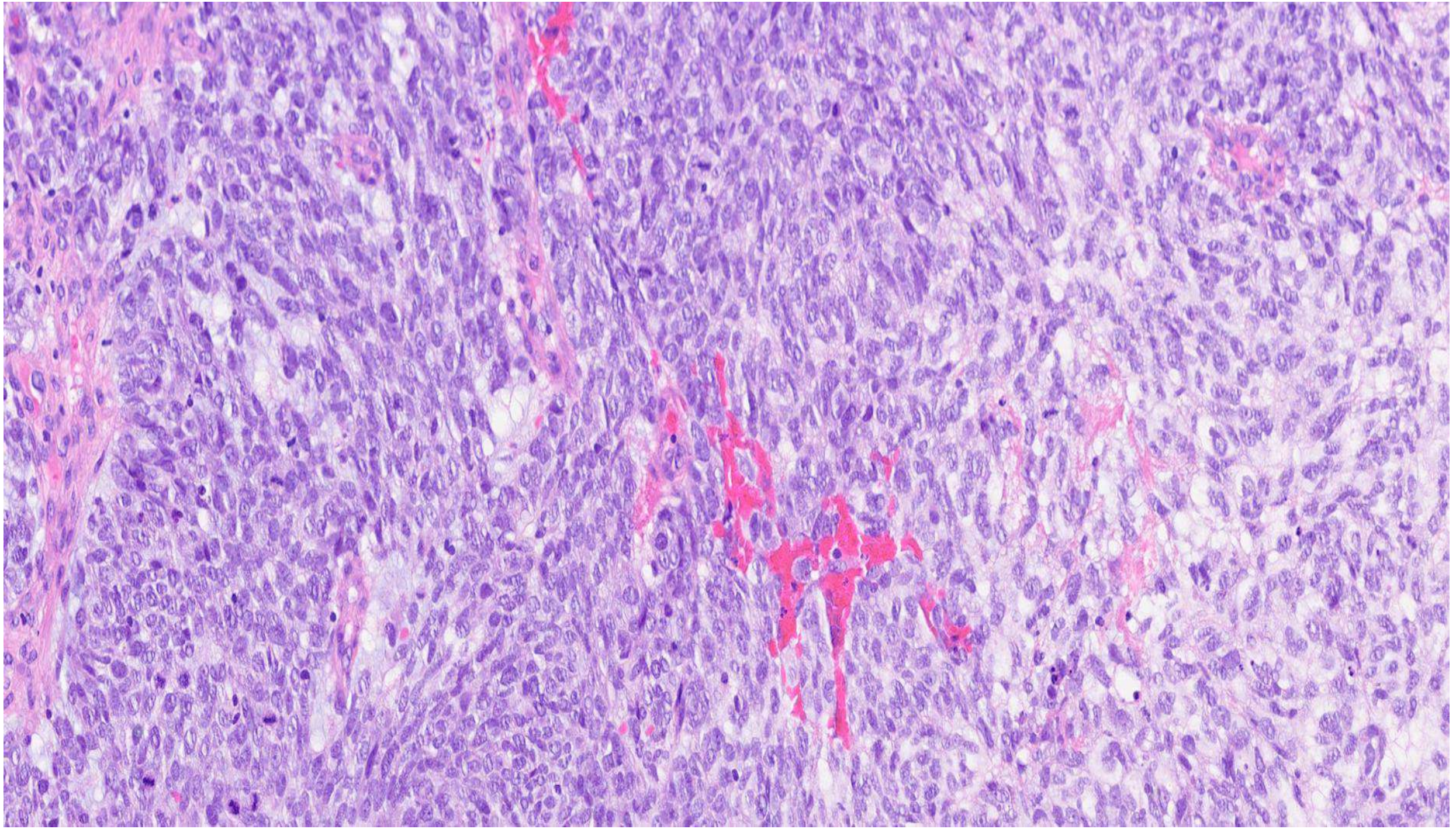

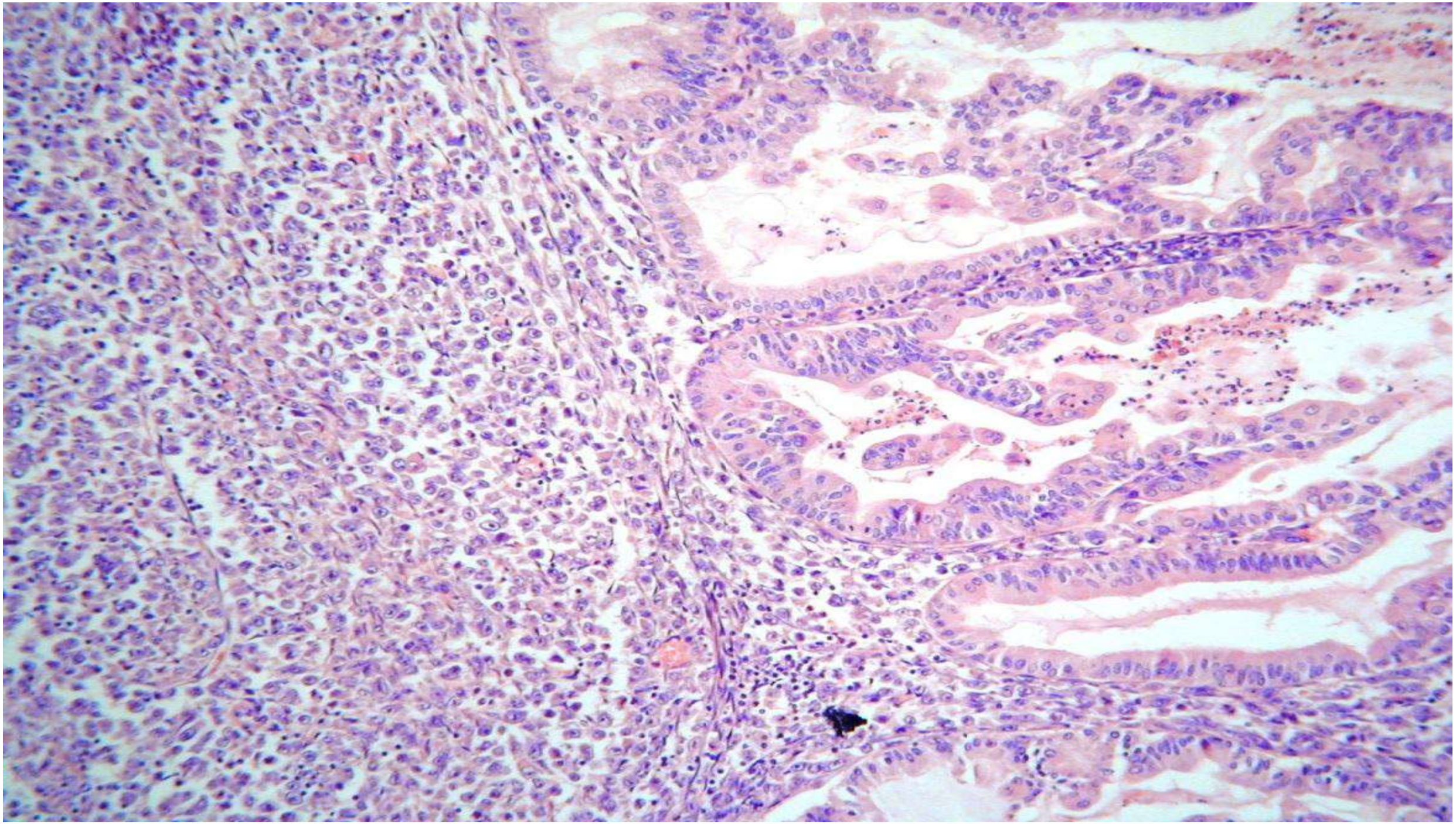

IMMUNOHISTOCHEMISTRY

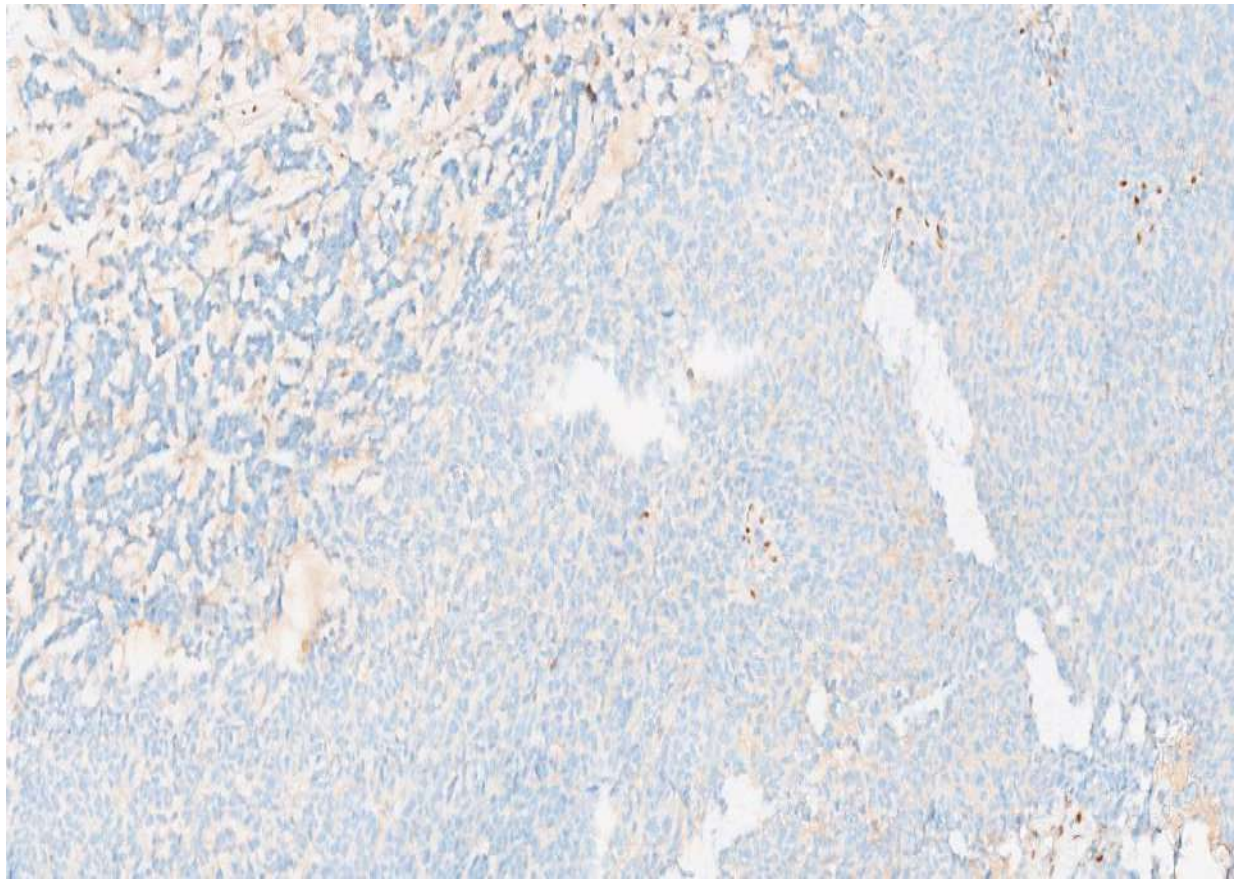

ER

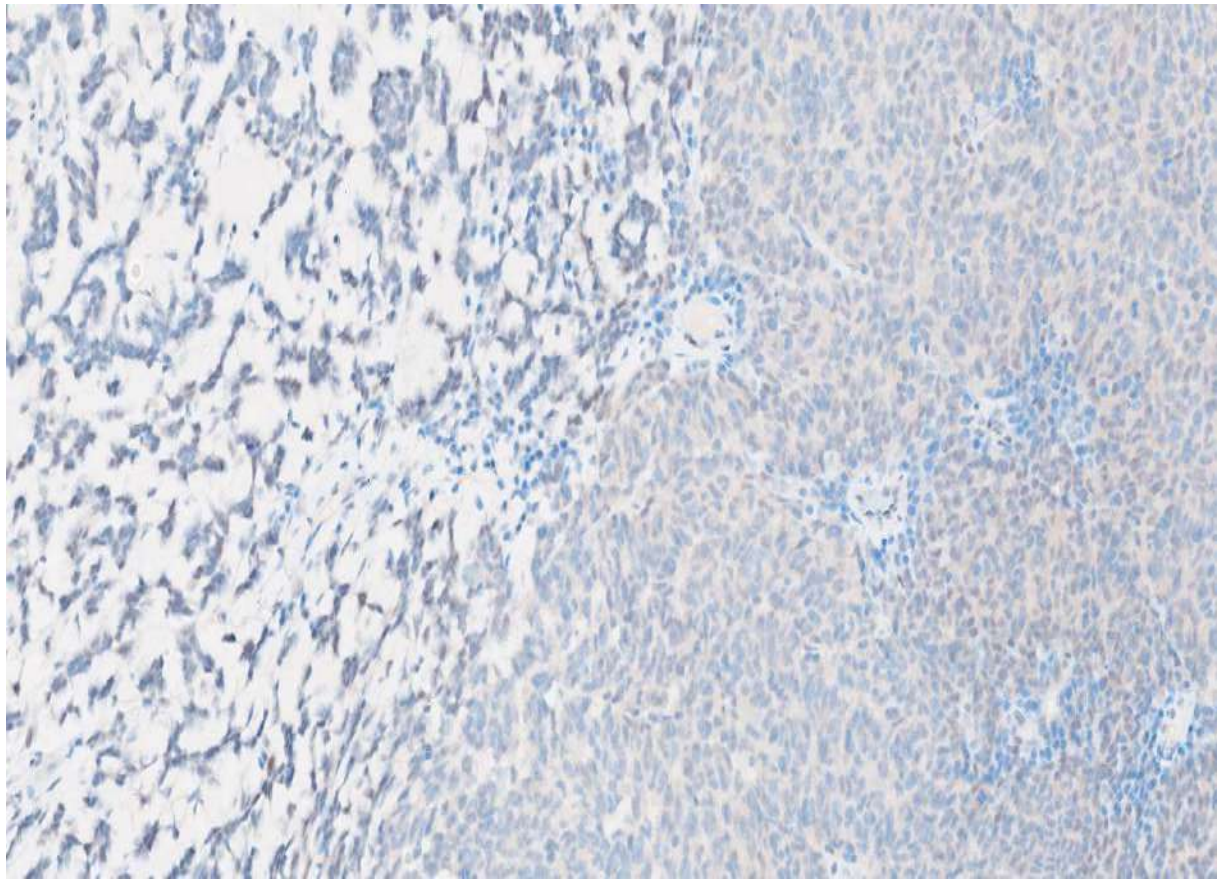

PAX8

IMMUNOHISTOCHEMISTRY

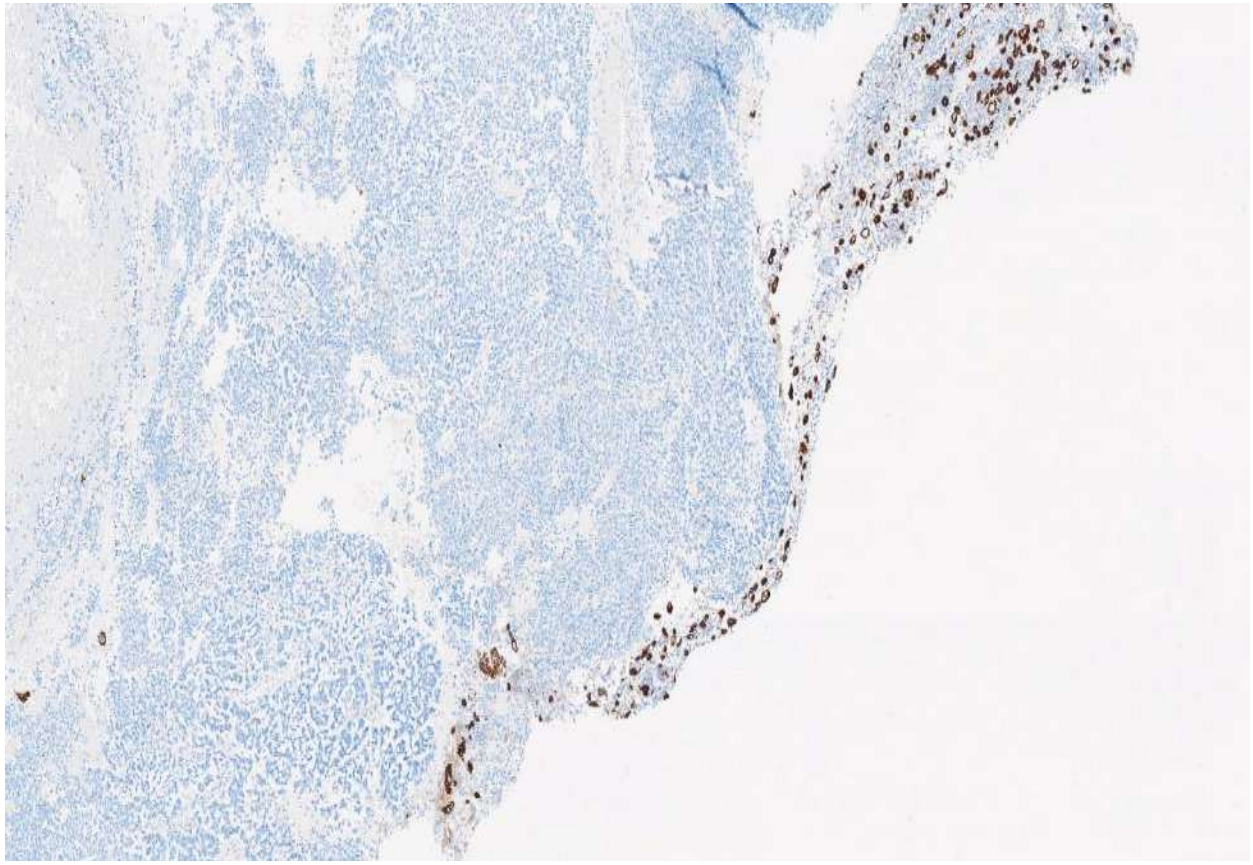

AE1/3

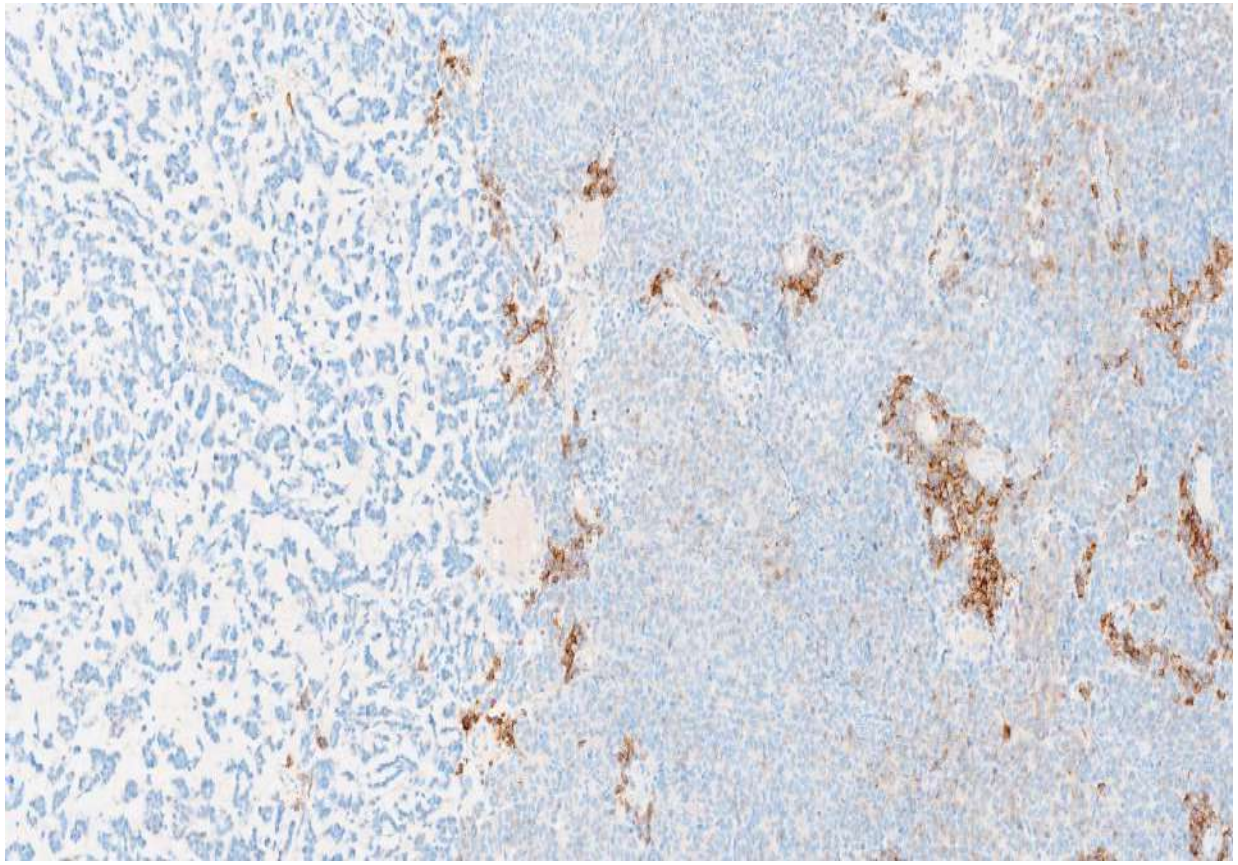

EMA

IMMUNOHISTOCHEMISTRY

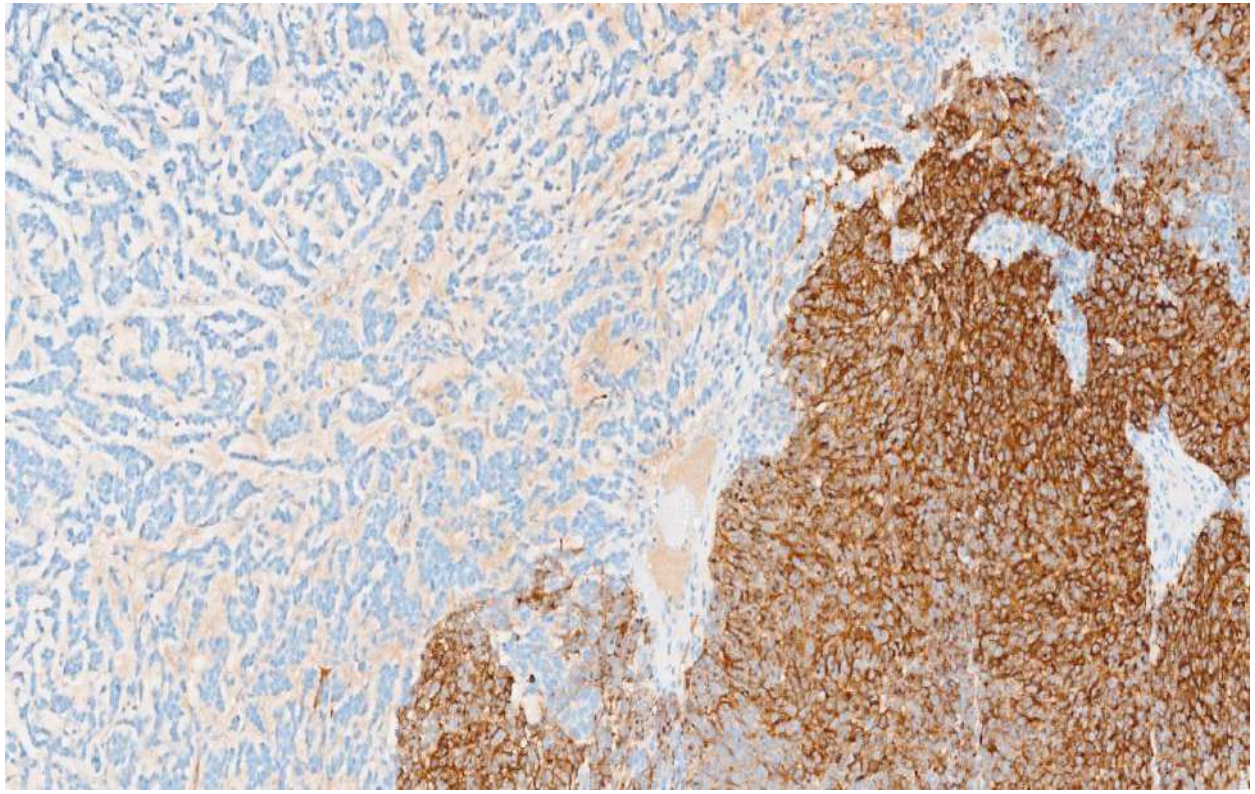

chromogranin

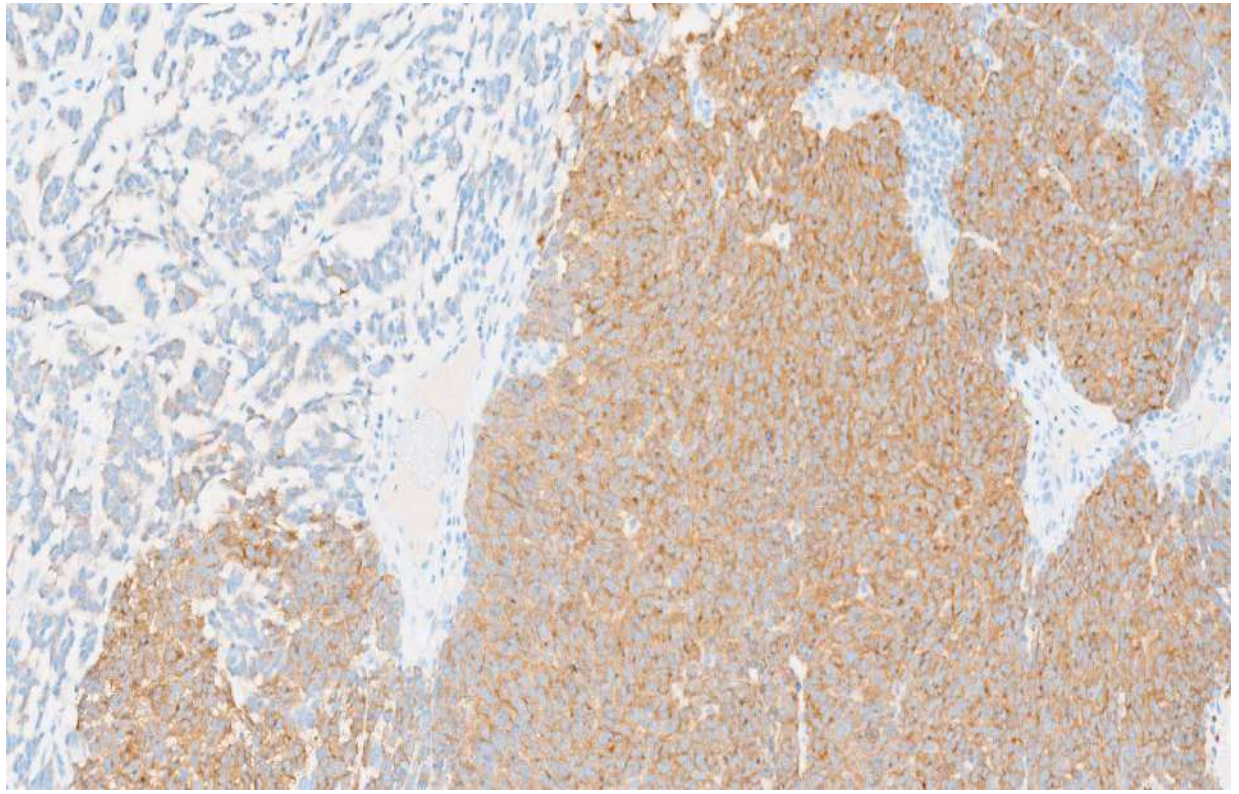

synaptophysin

IMMUNOHISTOCHEMISTRY

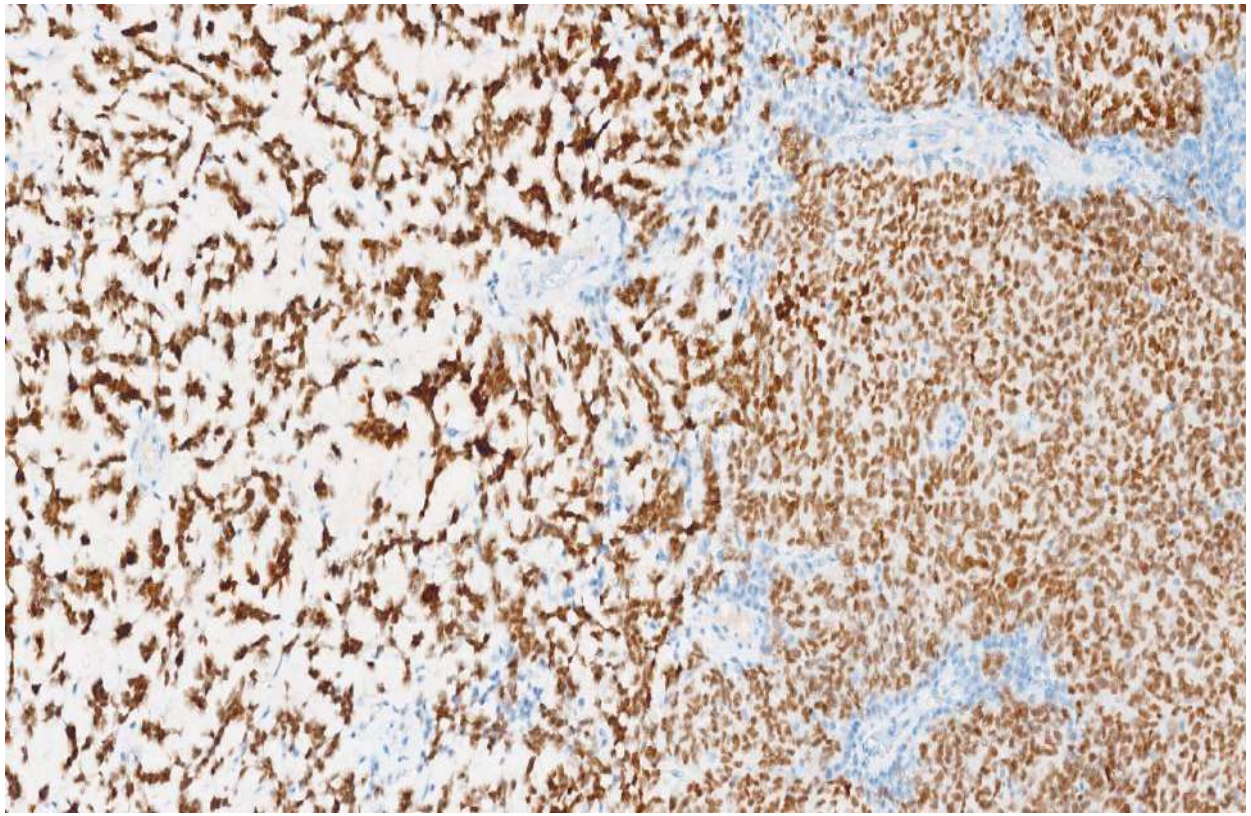

TTF1

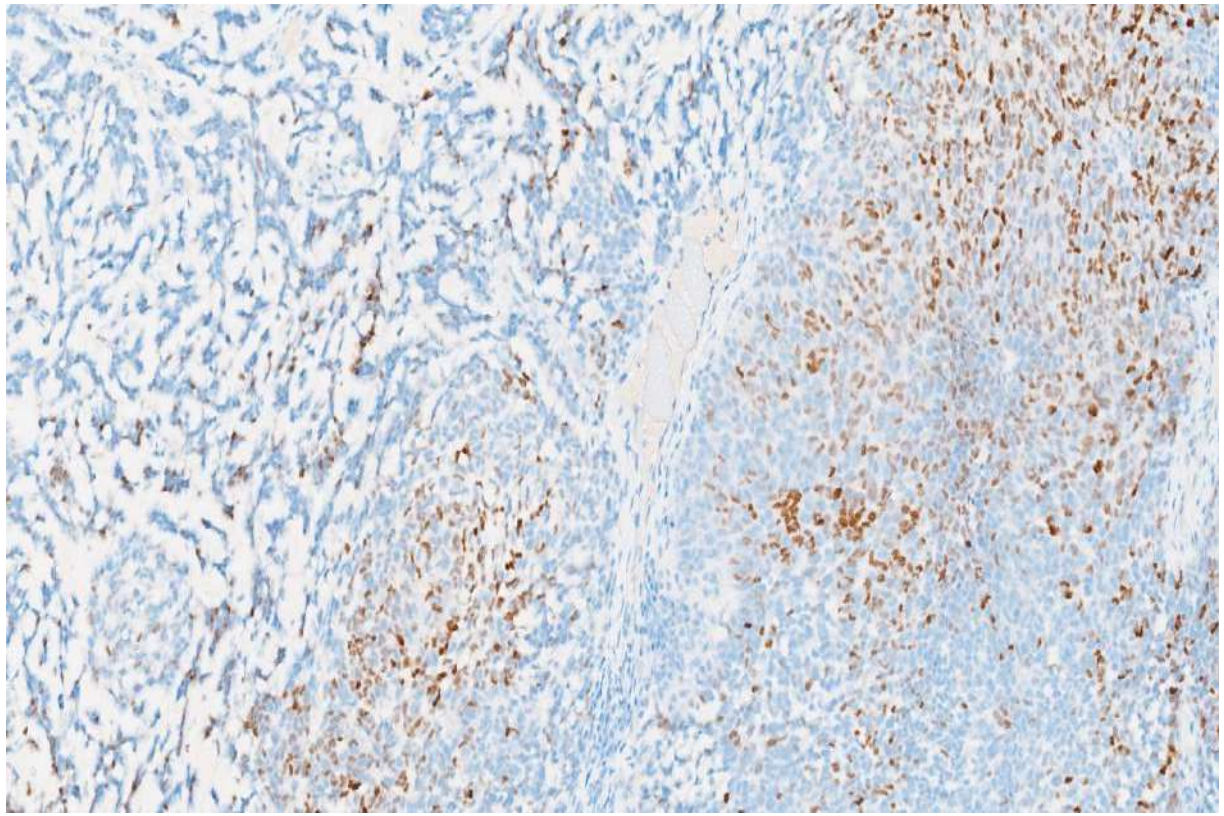

INSM1

ORIGINAL DIAGNOSIS

- Neuroendocrine carcinoma (admixed with endometrioid adenocarcinoma)

IMMUNOHISTOCHEMISTRY

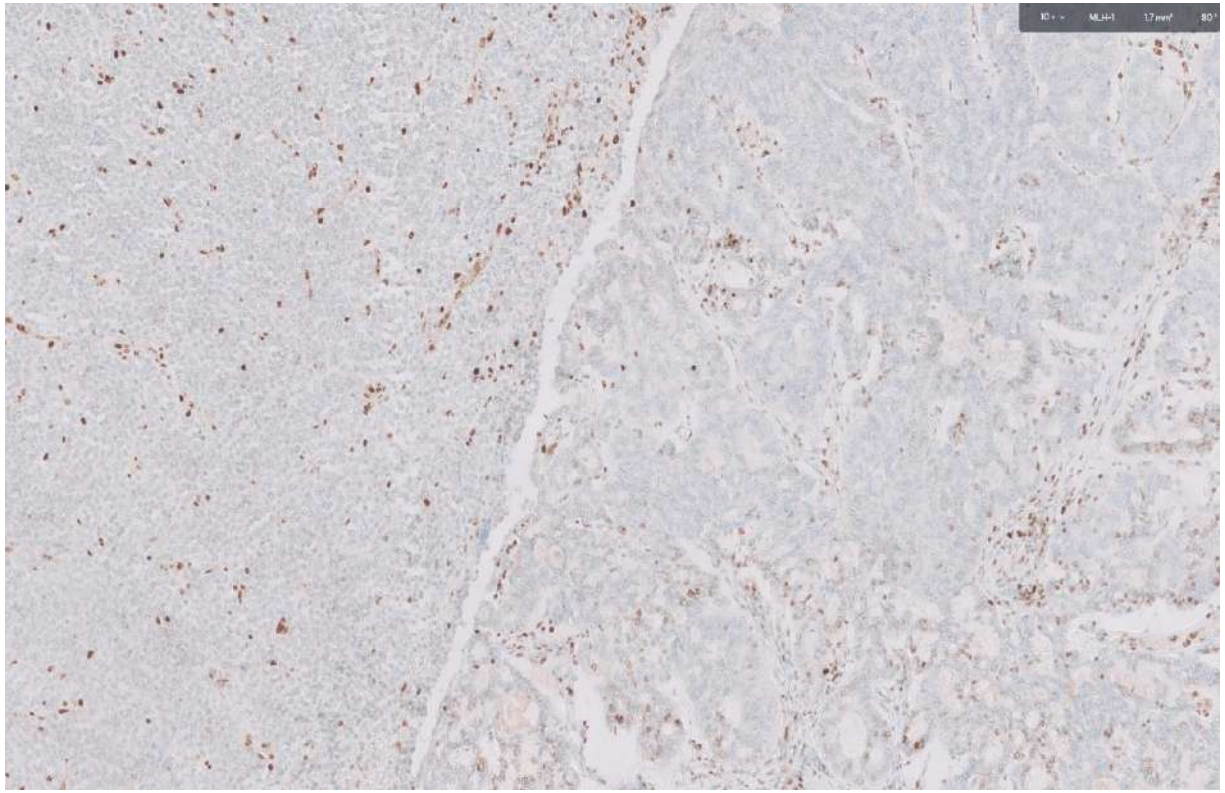

MLH1

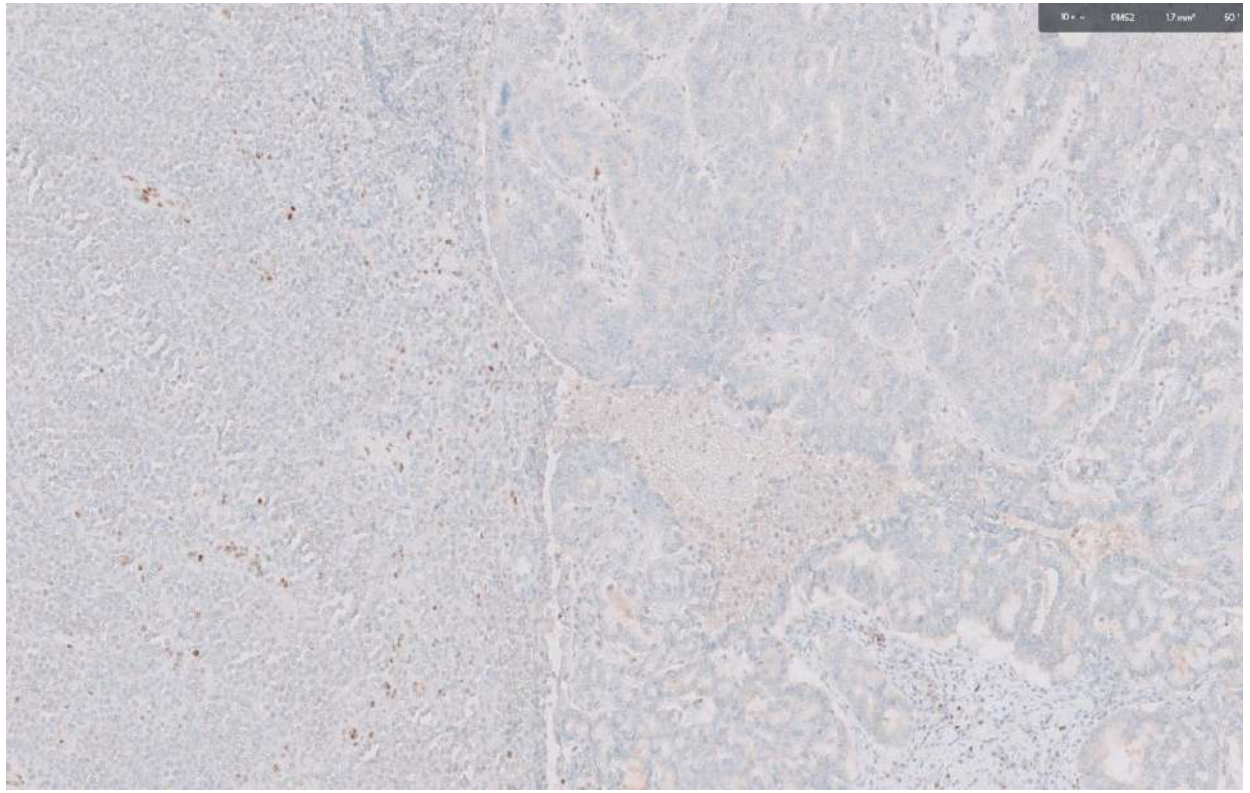

PMS2

SMARCA4 (BRG1)

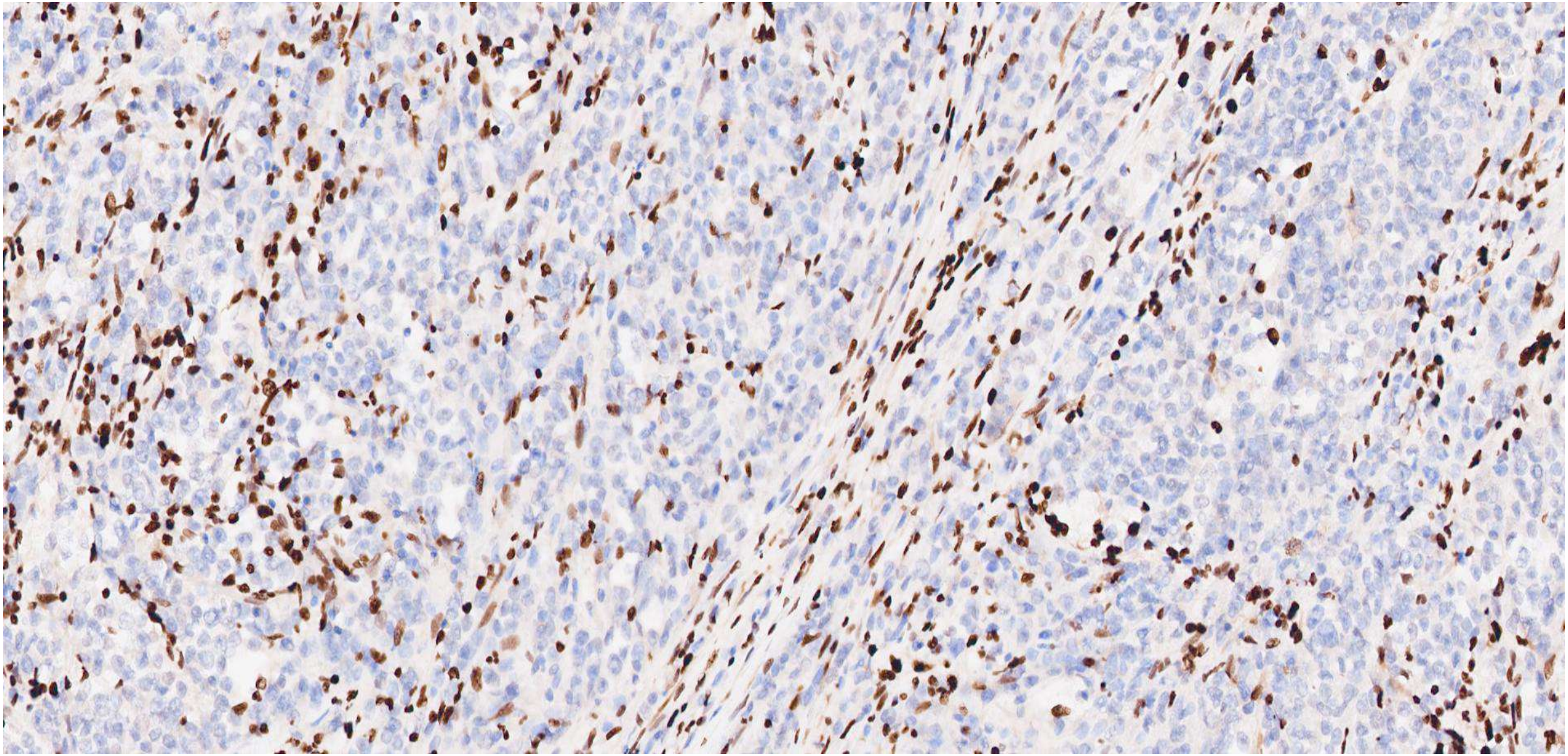

DIAGNOSIS: DEDIFFERENTIATED ENDOMETRIAL CARCINOMA

- Mixed endometrioid and undifferentiated carcinoma
- Previously these were sometimes diagnosed as neuroendocrine carcinomas

IMMUNOHISTOCHEMISTRY- UNDIFFERENTIATED CARCINOMA

- cytokeratin and EMA staining may be very focal, although typically strong (ADVISE TO PERFORM MORE THAN ONE EPITHELIAL MARKER)
- neuroendocrine marker positivity (usually less than 10% according to WHO 2020 but may be more) not uncommon
- usually negative or focal/ mosaic p16 and wild-type p53
- ER, PR, PAX8, E-cadherin, claudin 4- often negative
- often loss of MMR proteins (33-70%); usually also lost in low-grade endometrioid component; most often get loss of MLH1/PMS2- usually secondary to MLH1 methylation
- CD34 sometimes positive
- cyclin D1 sometimes diffusely positive

CYCLIN D1 IN UNDIFFERENTIATED CARCINOMA- PMID 25871469

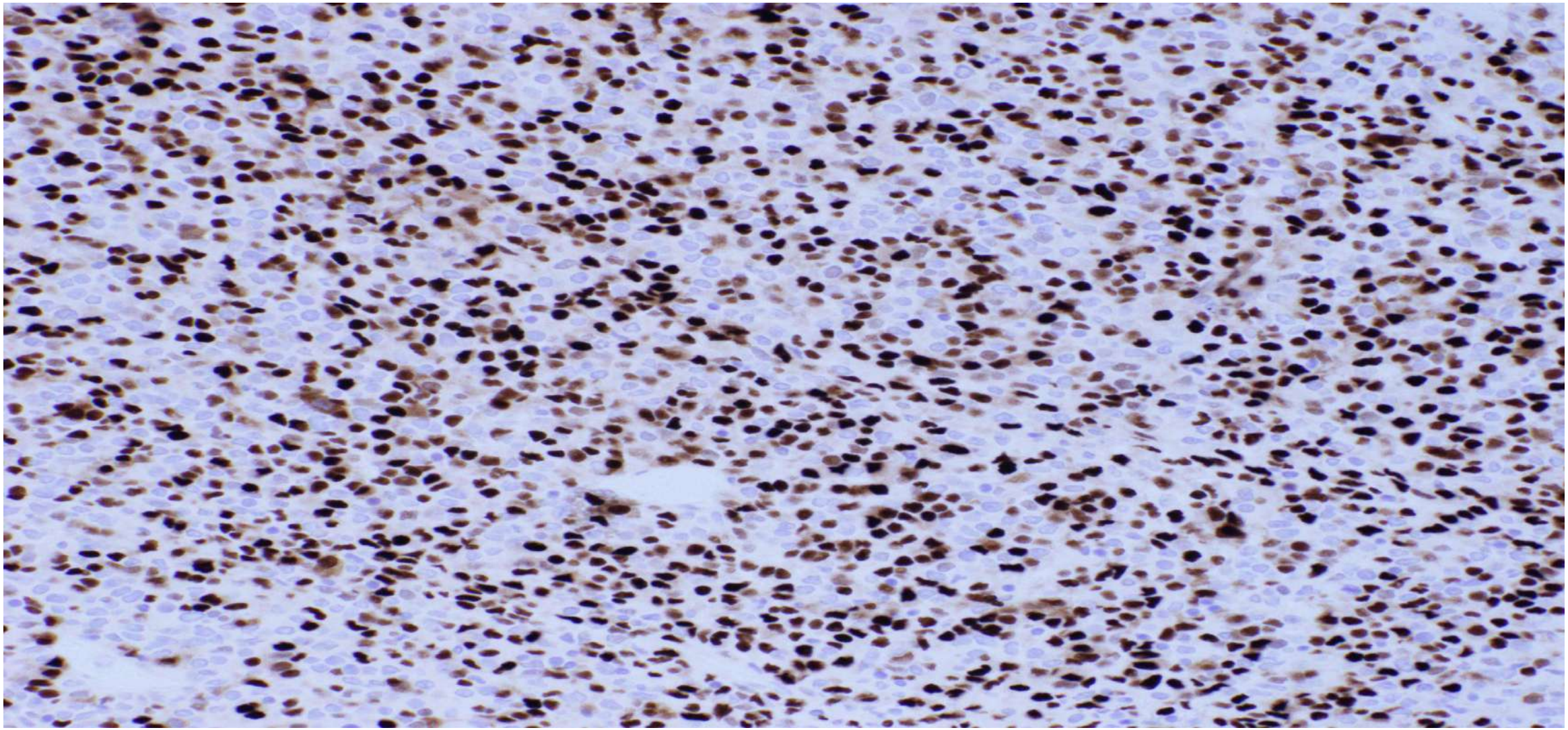

SWI-SNF MARKERS IN UNDIFFERENTIATED CARCINOMA

- often (up to 70%) loss of SWI-SNF complex proteins (**SMARCA4/ BRG1** or SMARCB1/ INI1 or combined **ARID1A and ARID1B**; may get SMARCA2 loss in combination with SMARCA4); quite specific for undifferentiated carcinoma amongst uterine corpus epithelial neoplasms since almost always retained in other high-grade endometrial carcinomas
- SWI-SNF markers usually retained in low-grade endometrioid component (loss plays a role in dedifferentiation; mutation is secondary/ progression event and MSI/ MMR deficiency may facilitate this- hypermutated/ MSI in TCGA)

PMID 35394077

Histopathology

Histopathology 2022, **81**, 44–54. DOI: 10.1111/his.14639

Endometrial neuroendocrine carcinoma and undifferentiated carcinoma are distinct entities with overlap in neuroendocrine marker expression

Basile Tessier-Cloutier,[1] Eun-Young Kang,[2] Deepu Alex,[1,3] Colin J R Stewart,[4] W Glenn McCluggage,[5] Martin Köbel[2] & Cheng-Han Lee[6,7]

[1]Department of Pathology and Laboratory Medicine, University of British Columbia, [3]Department of Pathology and Laboratory Medicine, BC Cancer, Vancouver, BC, [2]Department of Pathology and Laboratory Medicine, University of Calgary, Calgary, [6]Department of Laboratory Medicine and Pathology, Royal Alexandra Hospital, [7]Department of Laboratory Medicine and Pathology, University of Alberta, Edmonton, AB, Canada, [4]Department of Histopathology, King Edward Memorial Hospital and School for Women's and Infants' Health, University of Western Australia, Perth, WA, Australia and [5]Department of Pathology, Belfast Health and Social Care Trust, Belfast, UK

Date of submission 7 January 2022
Accepted for publication 2 March 2022
Published online *Article Accepted* xx-xx-xx

HISTOPATHOLOGY 2022;81;44-54- PMID 35394077

- 44 SWI-SNF deficient UDEC/ DDEC and 15 endometrial NEC
- 75% UDEC/ DDEC expressed at least 1 neuroendocrine marker; 41% expressed more than 1 neuroendocrine marker
- Neuroendocrine marker expression in UDEC/ DDEC typically focal- average 17%, 4% and 8% for synaptophysin, chromogranin, CD56 respectively
- Corresponding figures for NEC were 73%, 40% and 62% respectively
- All NEC showed intact SWI-SNF (except for 1 with isolated ARID1A loss)
- 38 of 44 UDEC/ DDEC had abnormal MMR (mostly MLH1/ PMS2 loss); all NEC had intact MMR
- **CONCLUSION- there is frequent but typically focal NEC expression in SWI-SNF deficient UDEC/ DDEC**
- **CONCLUSION- NECs typically express 2 or more neuroendocrine markers with diffuse expression in at least 1**
- **CONCLUSION- SWI-SNF markers may be useful in distinguishing between UDEC/ DDEC and NEC**

PMID 26945341: 8 OF 18 CASES MMR DEFICIENT

HHS Public Access
Author manuscript
Am J Surg Pathol. Author manuscript; available in PMC 2018 June 13.

Published in final edited form as:
Am J Surg Pathol. 2016 May ; 40(5): 577–586. doi:10.1097/PAS.0000000000000633.

Neuroendocrine Carcinoma of the Endometrium: A Clinicopathologic Study of 25 Cases

Cady E. Pocrnich, MD, FRCPC, **Preetha Ramalingam, MD**, **Elizabeth D. Euscher, MD**, and **Anais Malpica, MD**
Department of Pathology, The University of Texas, MD Anderson Cancer Center, Houston, Texas

ENDOMETRIOID CARCINOMA RESEMBLING PILOMATRIX CARCINOMA- PMID 33811207

International Journal of Gynecological Pathology
00:1–6, Lippincott Williams & Wilkins, Baltimore
Copyright © 2021 by the International Society of Gynecological Pathologists

Original Article

FIGO Grade 3 Endometrioid Adenocarcinomas With Diffusely Aberrant β-Catenin Expression: An Aggressive Subset Resembling Cutaneous Pilomatrix Carcinomas

Paul Weisman, M.D., Kay J. Park, M.D., and Jin Xu, M.D.

PILOMATRIX CARCINOMA-LIKE ENDOMETRIOID CARCINOMA: PMID 33811207

- Originally reported in uterus but also occur in ovary
- Strong morphological and immunohistochemical similarity to cutaneous pilomatrix carcinoma
- Solid basophilic cells with prominent necrosis and “shadow” cells
- Morphological variant of grade 3 endometrioid carcinoma
- Typically aberrant nuclear and cytoplasmic beta-catenin staining and often CDX2 positive
- Loss of ER, PR and PAX8
- **Often neuroendocrine marker positivity (especially synaptophysin)**
- Also sometimes (not always) focal conventional low-grade endometrioid component
- Aggressive behaviour and may present with metastatic disease with no conventional low-grade endometrioid component
- Some are MMR deficient; some are NSMP
- MAY BE MISDIAGNOSED AS UNDIFFERENTIATED CARCINOMA, **NEUROENDOCRINE CARCINOMA**, SQUAMOUS CELL CARCINOMA (these may all contain a component of low-grade endometrioid carcinoma and are often hormone receptor and PAX8 negative)

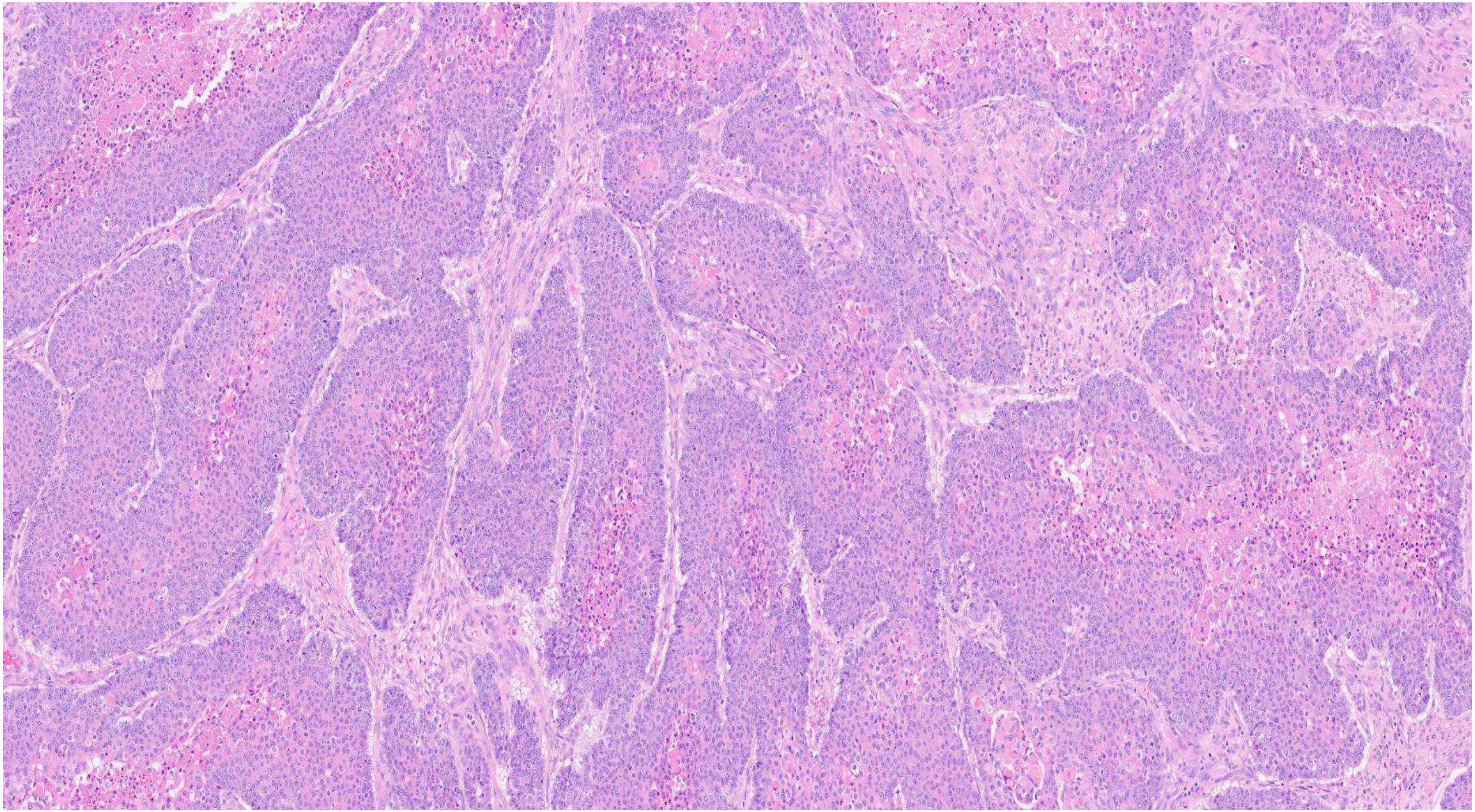

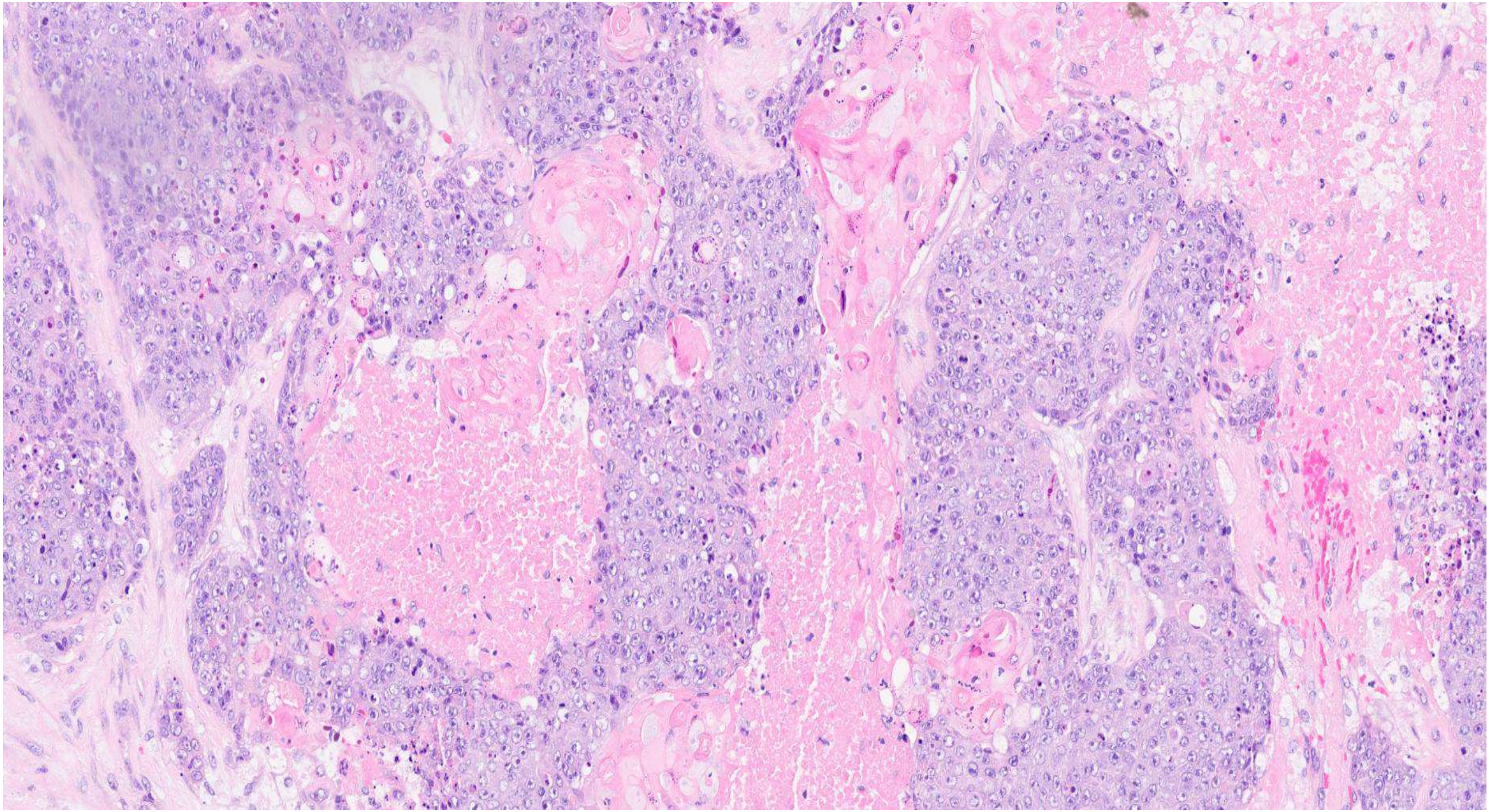

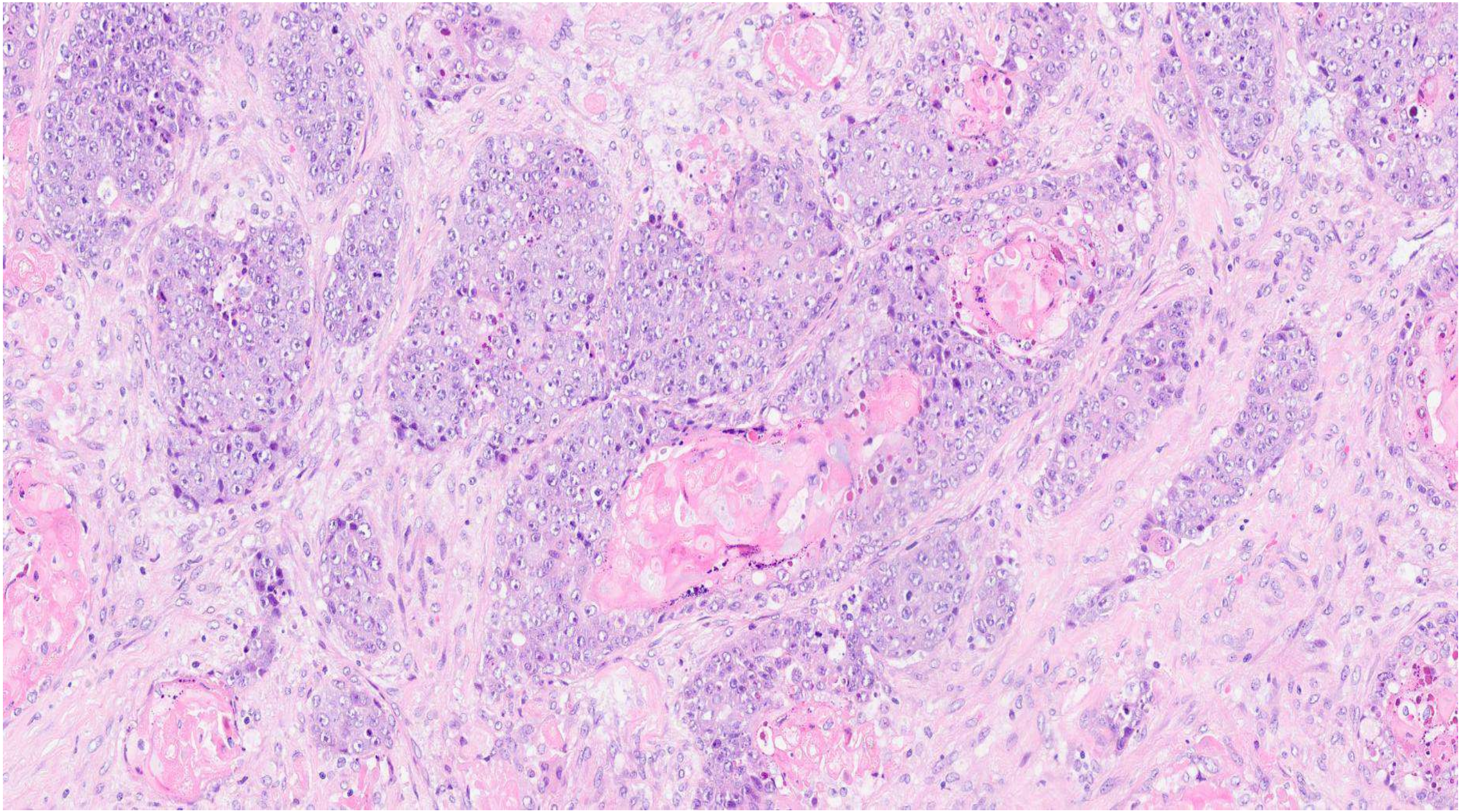

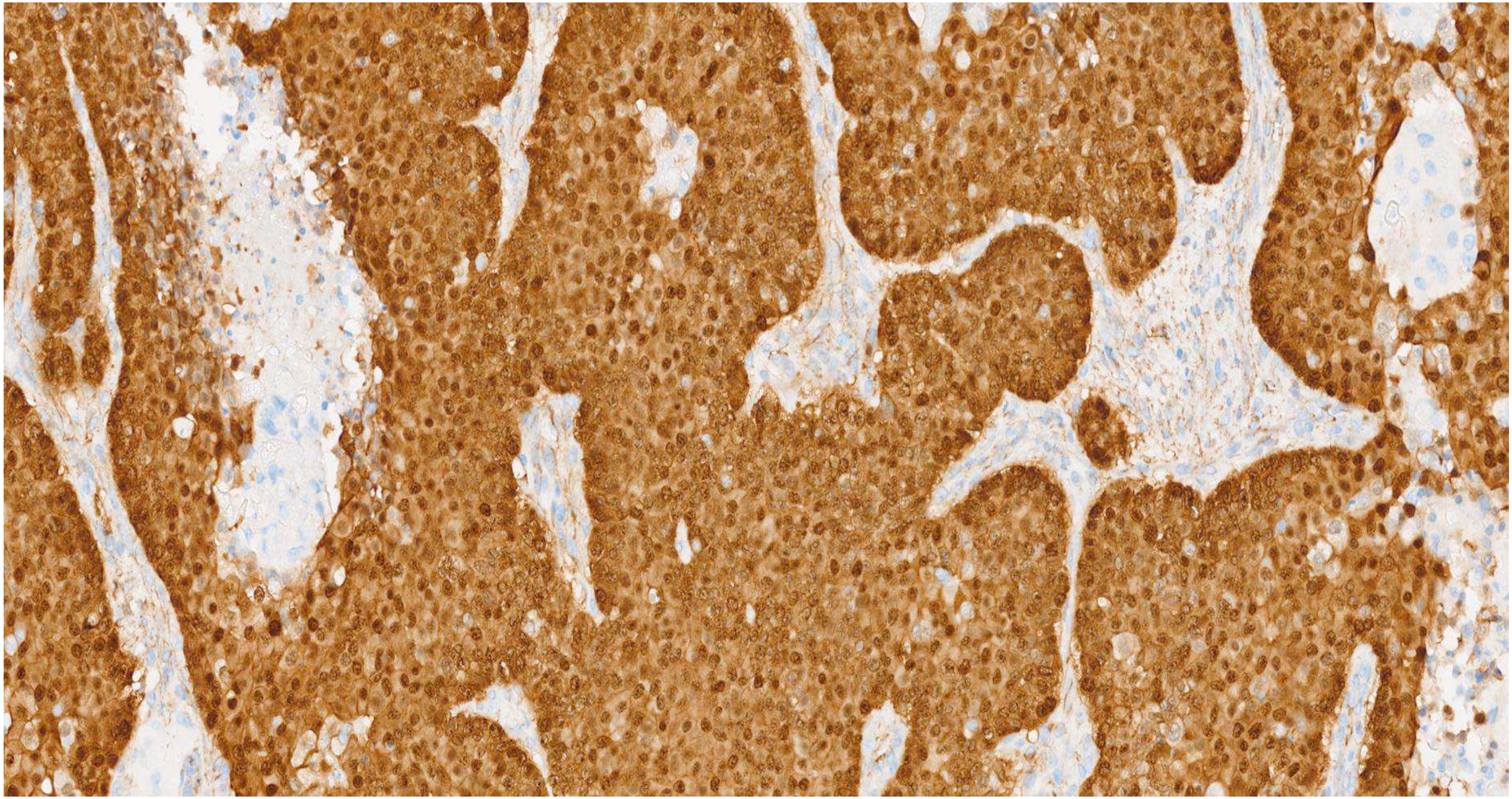

Beta- catenin

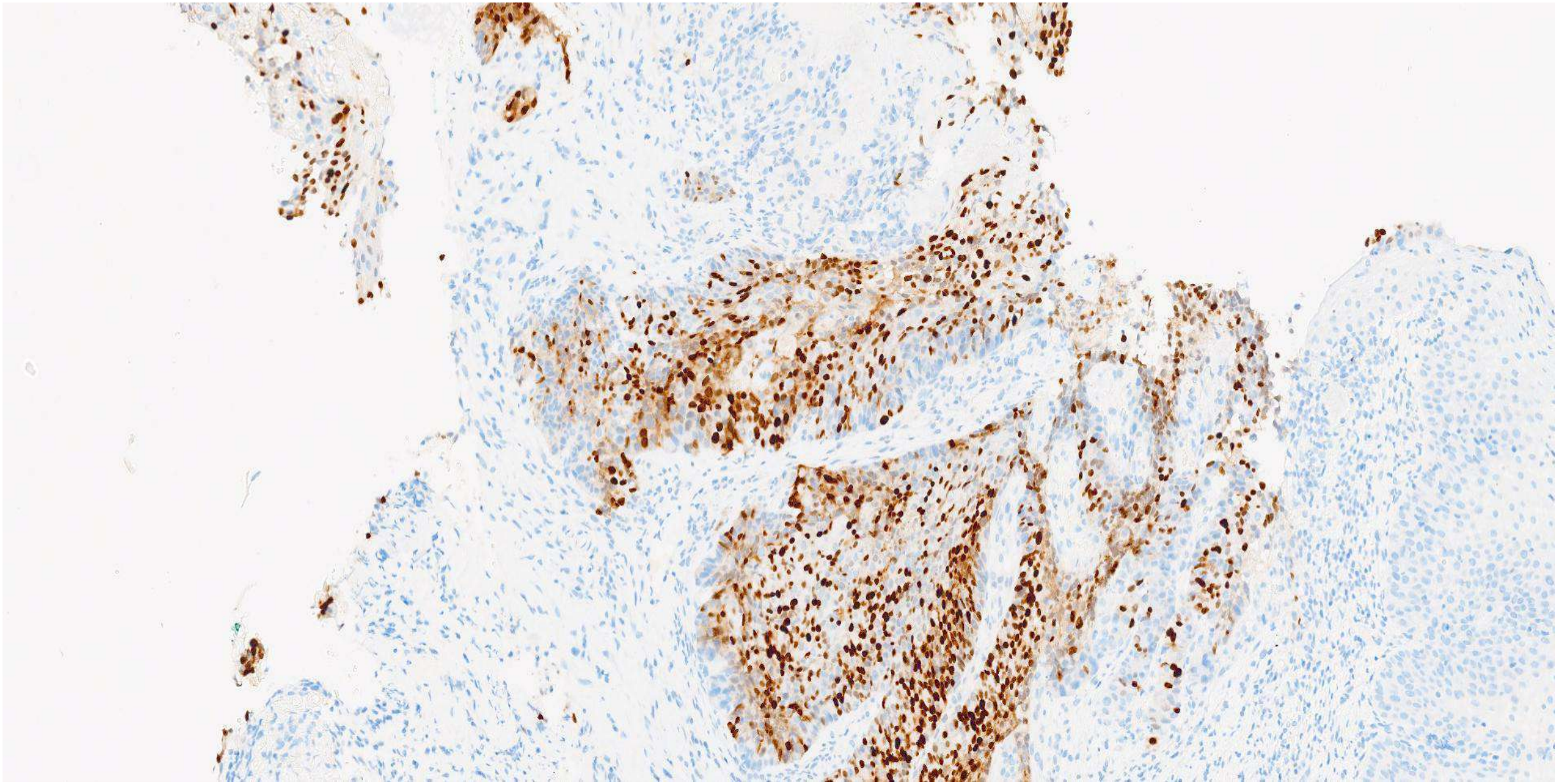

CDX2

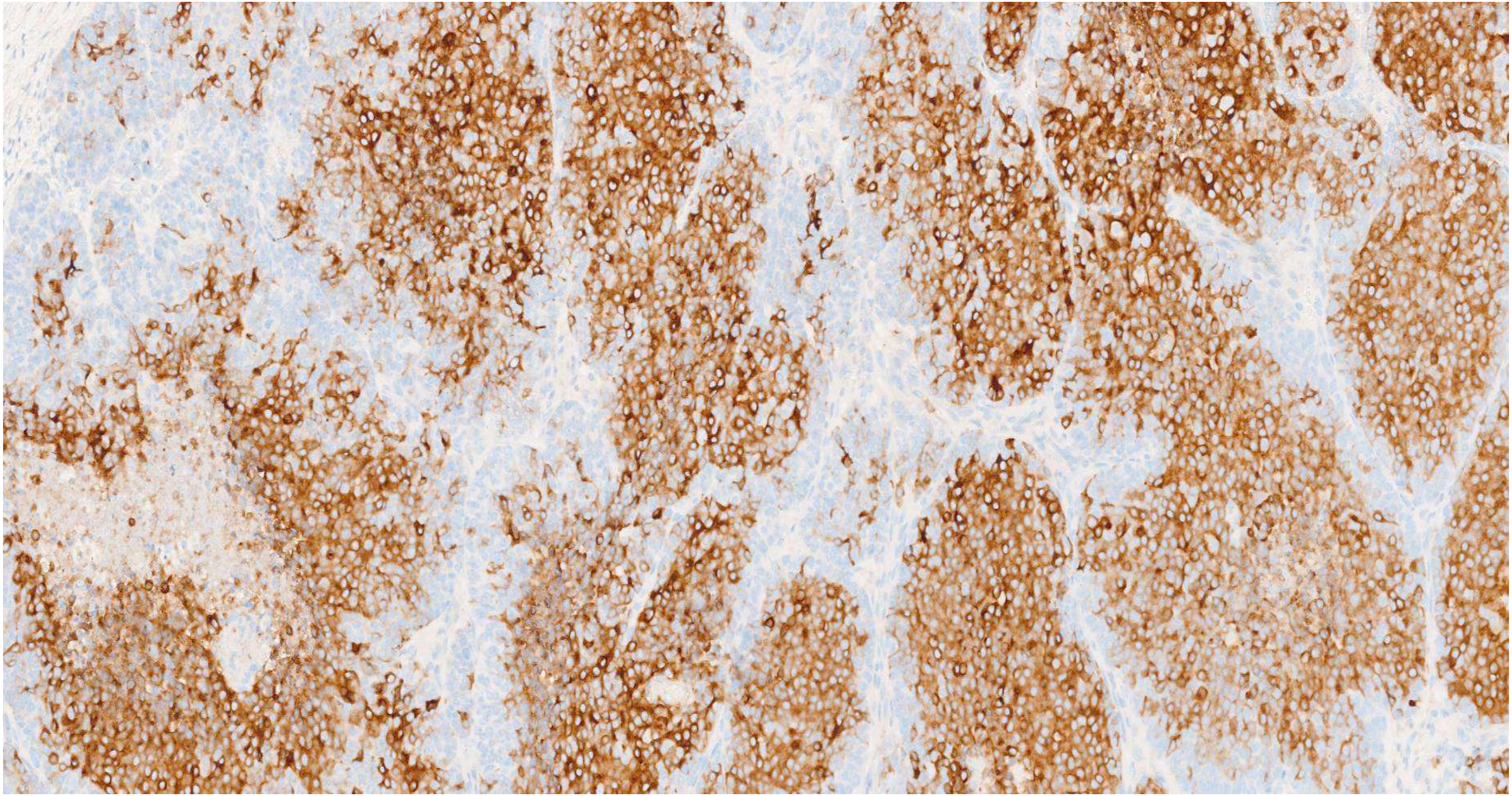

synaptophysin

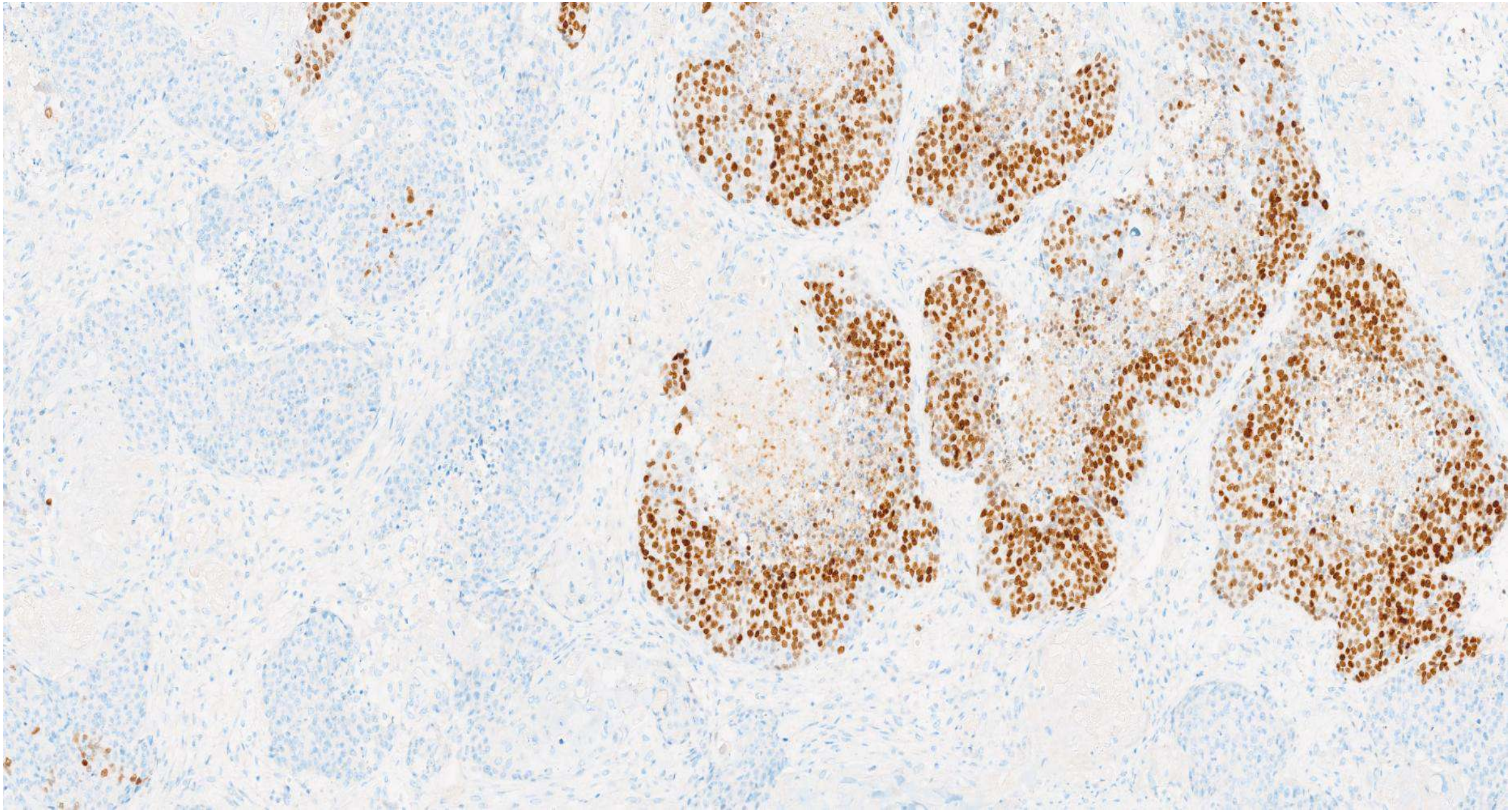

TTF1

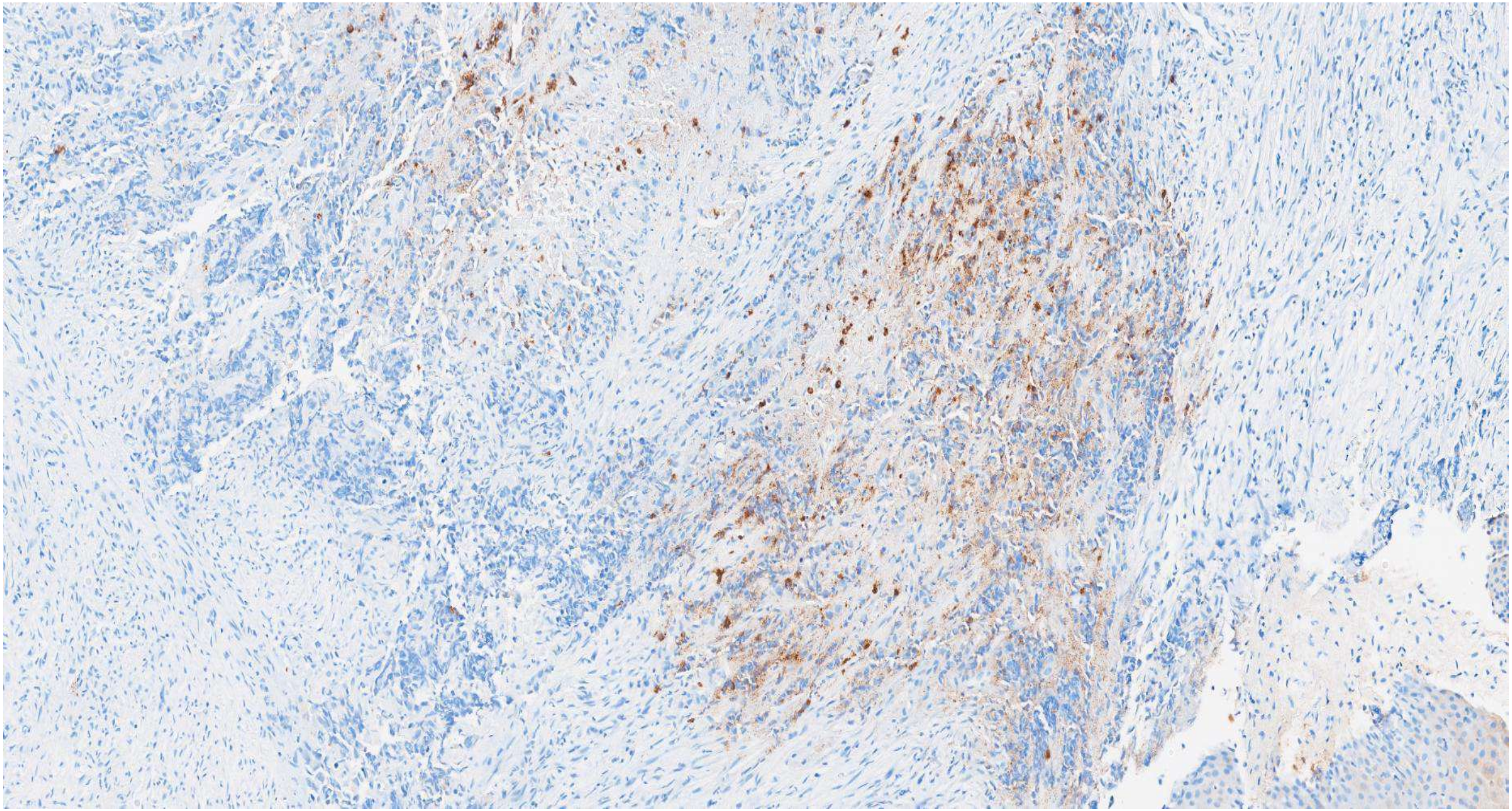

chromogranin

PMID 31040050. Pathology 2019;51;369-374

Pathology (June 2019) **51(4)**, pp. 369–374

ANATOMICAL PATHOLOGY

Expression of neuroendocrine markers in non-neuroendocrine endometrial carcinomas

AUGUST W. MORITZ[1], MATTHEW P. SCHLUMBRECHT[2], MEHRDAD NADJI[1], ANDRE PINTO[1]

[1]Department of Pathology, University of Miami Miller School of Medicine, Miami, FL, United States; [2]Department of Obstetrics and Gynecology, Division of Gynecological Oncology, University of Miami Miller School of Medicine, Miami, FL, United States

ENDOMETRIOID CARCINOMA- ABERRANT NEUROENDOCRINE MARKER EXPRESSION

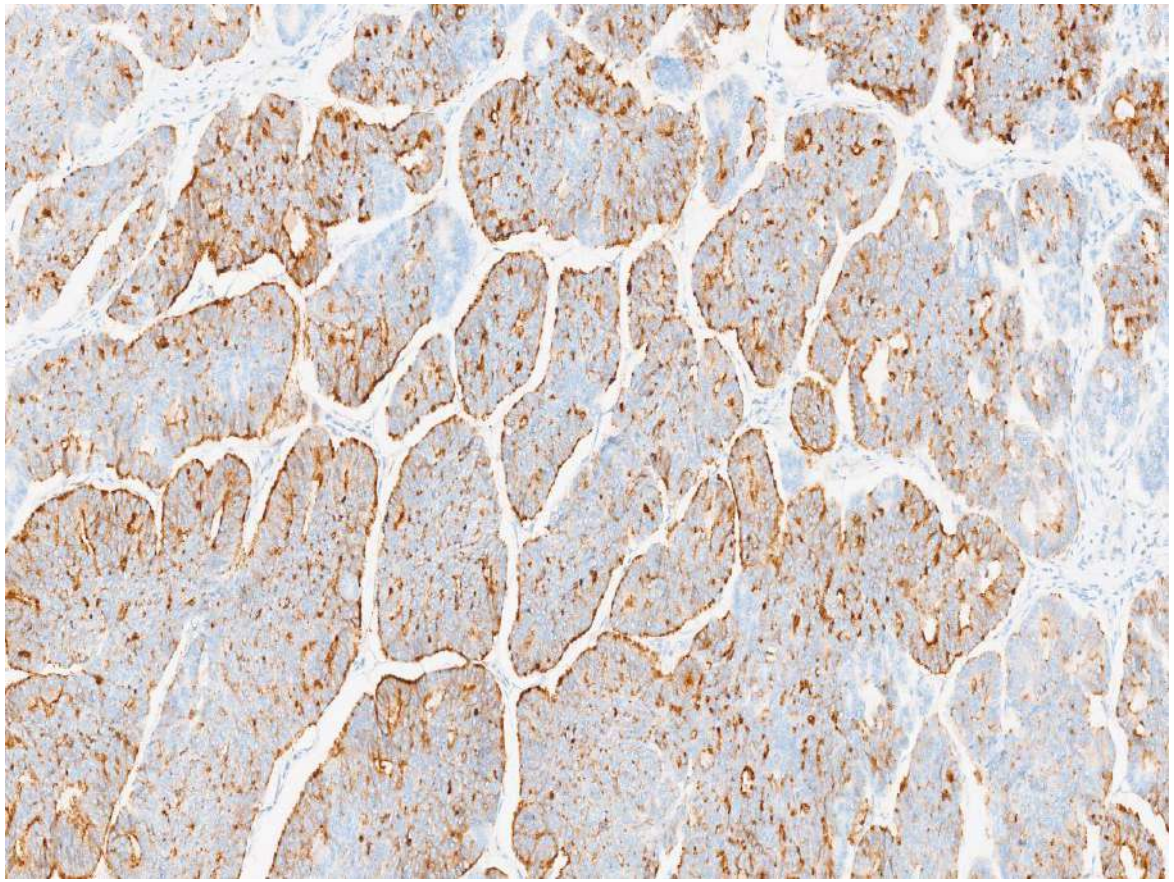

chromogranin

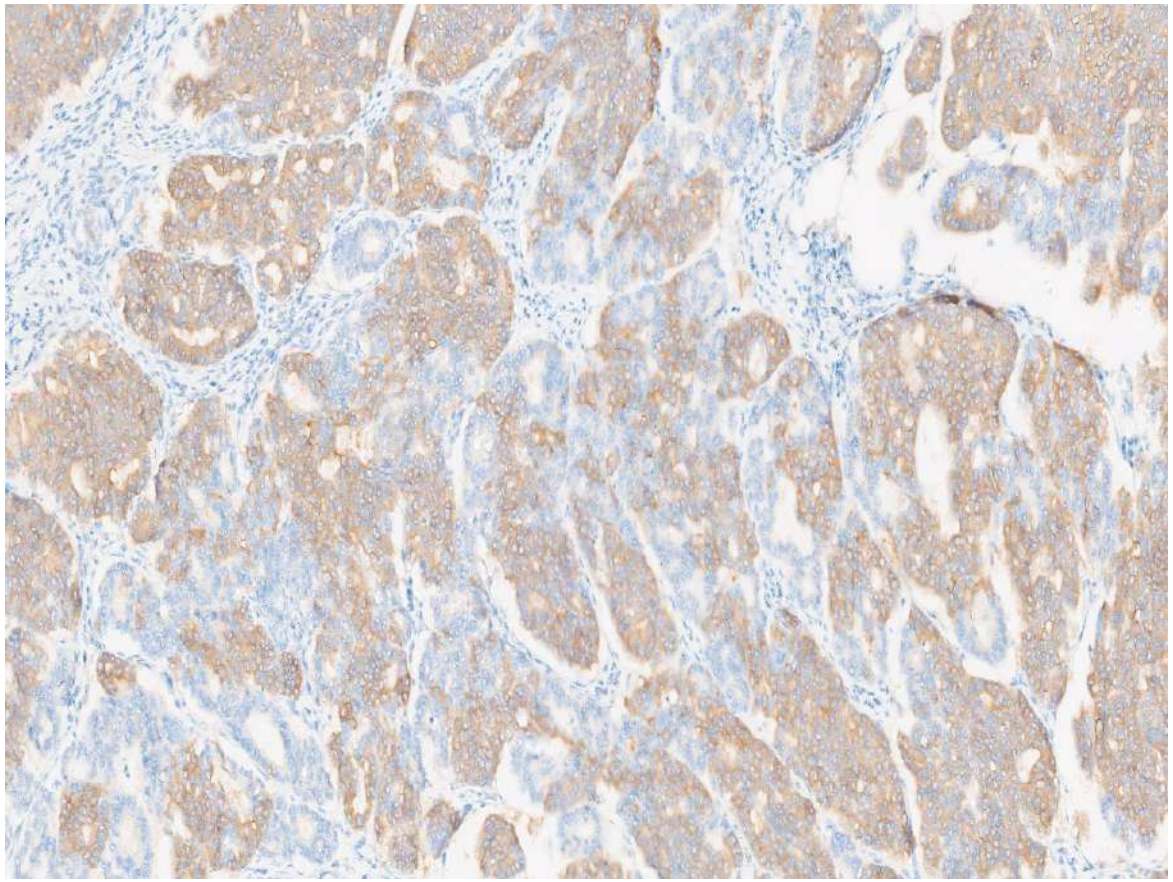

synaptophysin

NEUROENDOCRINE CARCINOMAS OF THE ENDOMETRIUM ARE VERY RARE

- Get occasional SCNEC: prototypical neuroendocrine carcinoma
- Beware before diagnosing LCNEC
  - Make sure morphology is incompatible (many carcinomas can be positive with neuroendocrine markers)
  - Exclude undifferentiated carcinoma
  - Exclude pilomatrix-like endometrioid adenocarcinoma

THANK YOU