The British Association of Gynaecological Pathologists

Lecturer – Dr Kay Park

Dr. Park completed her Anatomic and Clinical Pathology residency at NY Presbyterian Hospital, Weill Cornell Medical Center where she also completed a Gynecologic Pathology fellowship. She then went on to the Oncologic Surgical Pathology fellowship at Memorial Sloan Kettering Cancer Center, after which was Chief Fellow at MSK. She stayed on as staff and has been at MSK for 17 years. Her main area of research interest is cervical pathology, particularly cervical adenocarcinomas. She has published on non-HPV associated cervical adenocarcinomas and was the lead author for these entities in the 2020 WHO Classification of Female Genital Tumours. She was also involved in the Pattern Classification System for cervical adenocarcinoma, spearheaded by Dr. Elvio Silva.
Dr. Park was the program director of the oncologic pathology fellowship at MSK for 6 years and is currently the Chair of Memorial Sloan Kettering's Graduate Medical Education Committee.



LECTURE

Endocervical adenocarcinomas – diagnostic dilemmas

The British Association of Gynaecological Pathologists

- Endocervical Adenocarcinoma – Diagnostic Dilemmas
- Kay Park, MD
- Memorial Sloan Kettering Cancer Center, NY, NY USA
- June 9, 2022

The British Association of Gynaecological Pathologists

Speaker disclosures

- ❑ I have no financial conflicts of interest to disclose

Endocervical Adenocarcinomas Diagnostic Dilemmas

Kay J. Park, MD

Attending Pathologist

Memorial Sloan Kettering Cancer Center



@KayParkMD
@ISGynP
@IJGynP

Overview

Subtype

Benign vs. pre-invasive vs. invasive

Pattern Classification

Staging

(measuring tumor size and DOI)



SUBTYPE

WHO Classification of Endocervical AdCa

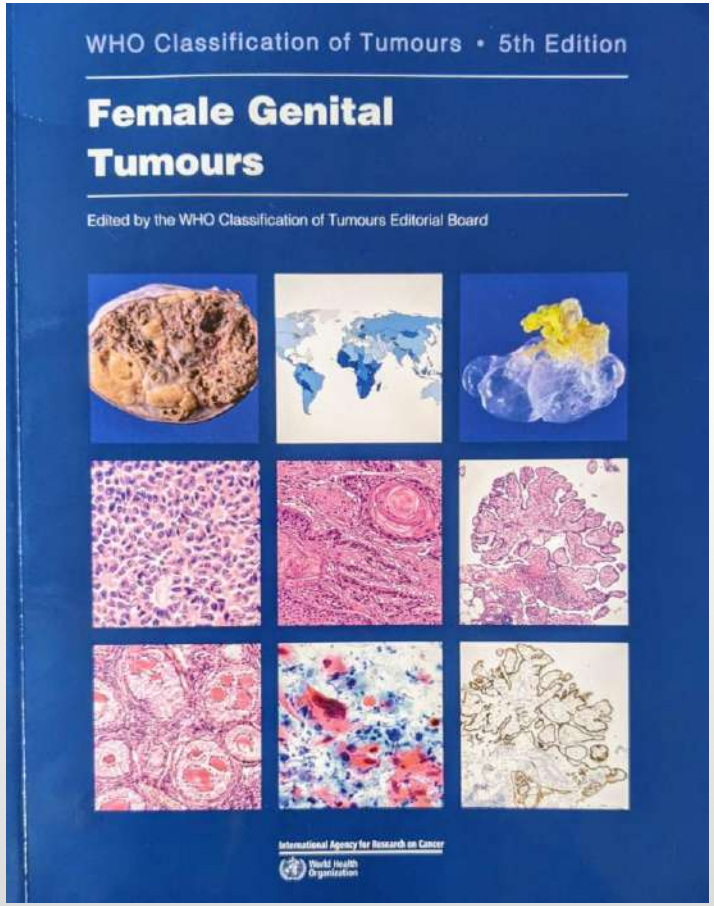

Adenocarcinomas

- Adenocarcinoma in situ, HPV-associated
- Adenocarcinoma, HPV-associated

- Adenocarcinoma in situ, HPV-independent
- Adenocarcinoma, HPV-independent, **gastric** type
- Adenocarcinoma, HPV-independent, **clear cell** type
- Adenocarcinoma, HPV-independent, **mesonephric** type
- Other adenocarcinomas
  - **Endometrioid**
  - Serous

Typing Endocervical Adenocarcinoma Difficult Differentials

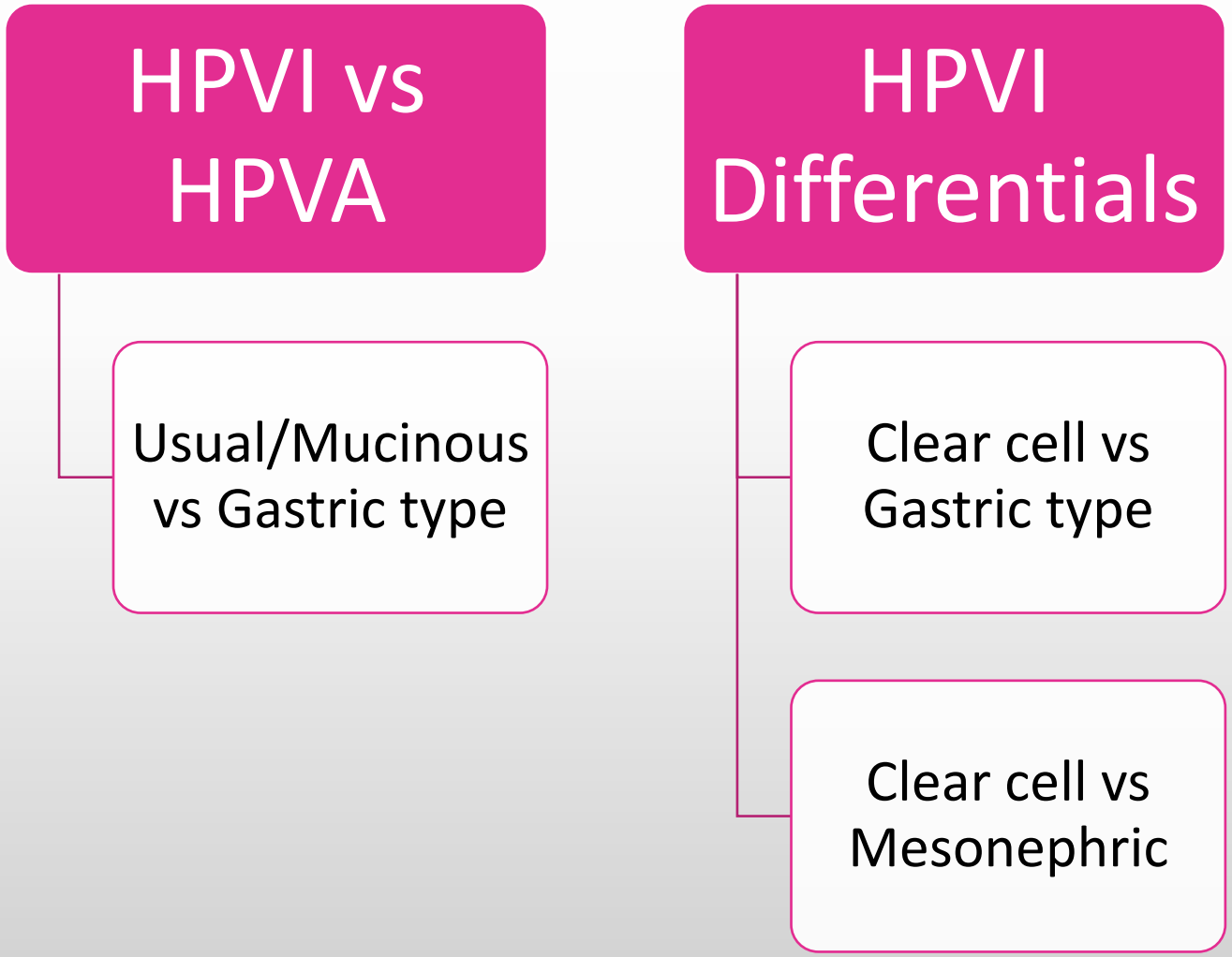

IECC

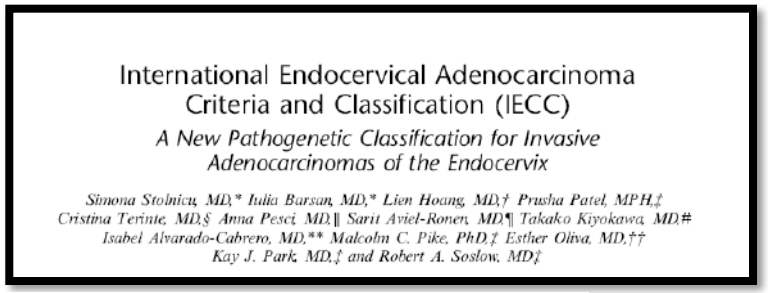

International Endocervical Adenocarcinoma Criteria and Classification (IECC)

A New Pathogenetic Classification for Invasive Adenocarcinomas of the Endocervix

Simona Stolnicu, MD, Iulia Barsan, MD,* Lien Hoang, MD,† Prusha Patel, MPH,‡ Cristina Terinte, MD,§ Anna Pesci, MD,‖ Sarit Aviel-Ronen, MD,¶ Takako Kiyokawa, MD,# Isabel Alvarado-Cabrero, MD,** Malcolm C. Pike, PhD,‡ Esther Oliva, MD,†† Kay J. Park, MD,‡ and Robert A. Soslow, MD‡*

Am J Surg Pathol • Volume 42, Number 2, February 2018

HPVA

(HPV Associated)

Apical mitotic figures and apoptotic bodies at scanning magnification

If features not seen at scanning, cursory exam at 200x to detect additional cases

Subcategorized based on cytoplasmic features

(to provide continuity with pre-existing classification schemes)

Usual, mucinous, etc.

HPVI

(HPV Independent)

No easily identifiable mitotic activity and apoptotic bodies at scanning mag

Focal or equivocal HPVA features at 200x – limited HPVA, tentatively classified as NHPVA

Subclassified based on published criteria defining morphologically, etiologically and phenotypically unified diagnostic entities

Gastric type, clear cell, mesonephric, etc.

Usual type

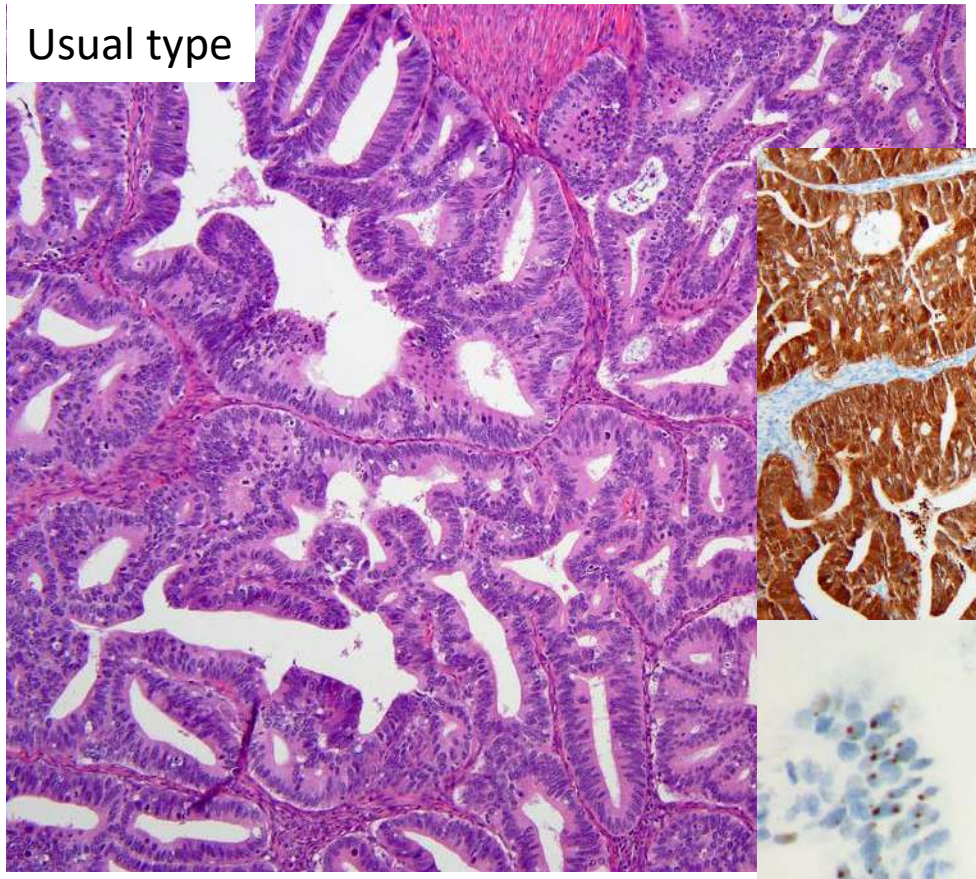

Mucinous intestinal



p16

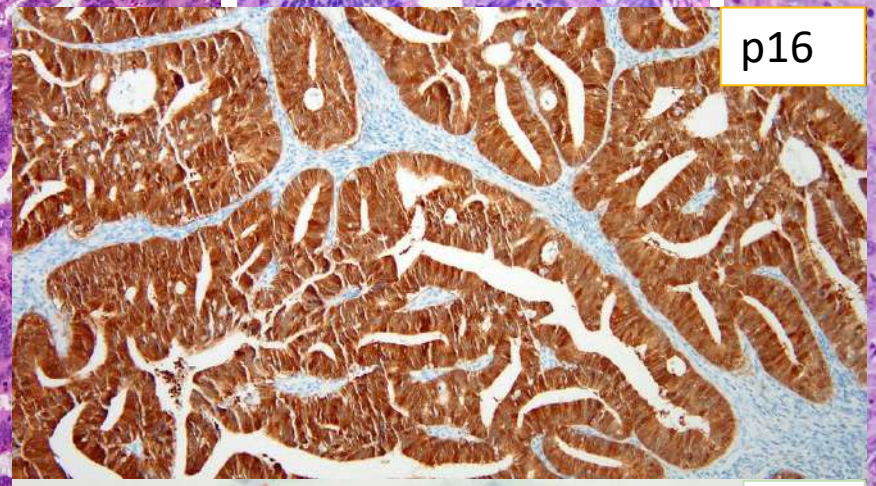

HPV

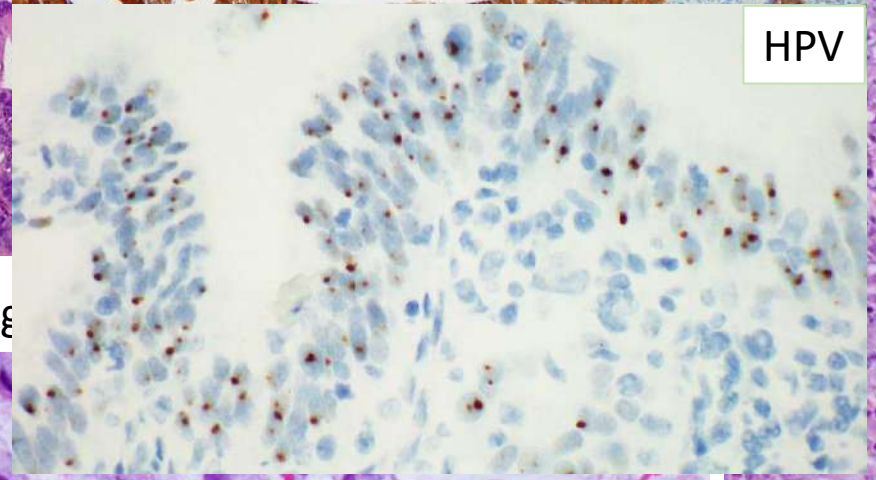

Invasive stratified mucinous carcinoma

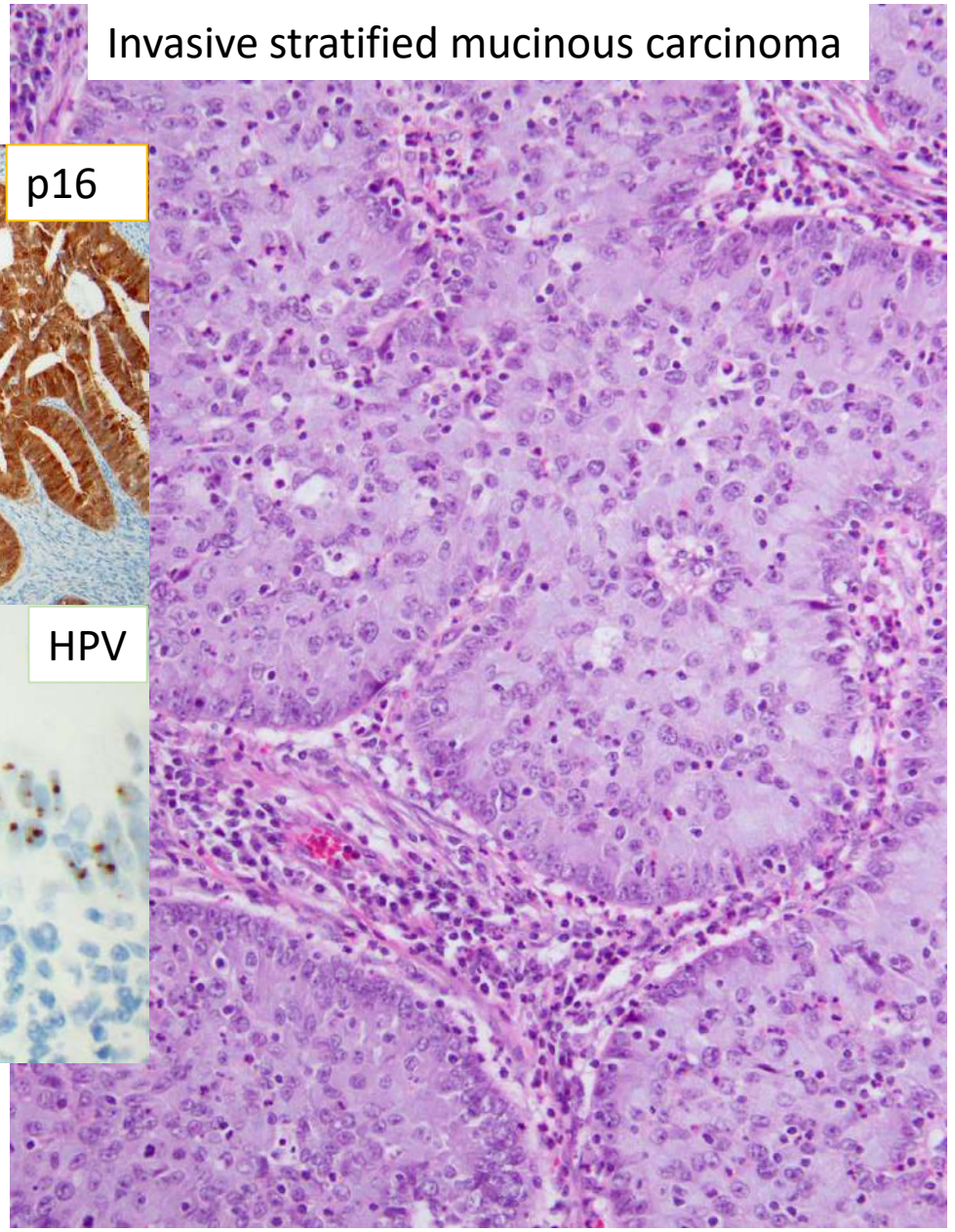

Mucinous NOS

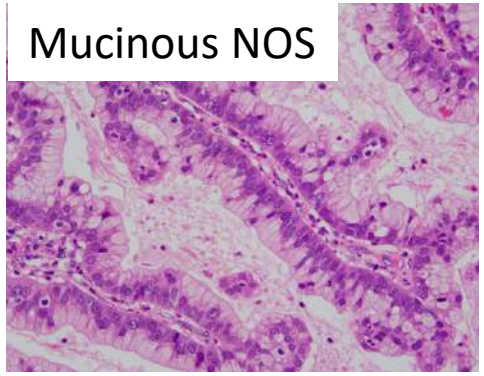

Mucinous sig

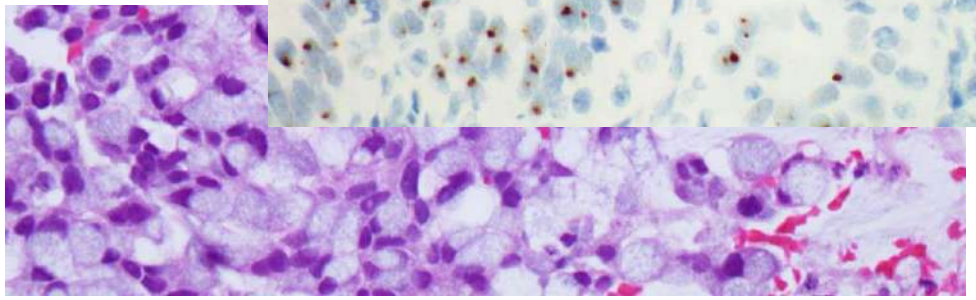

Gastric type
Voluminous clear , foamy or eosinophilic cytoplasm

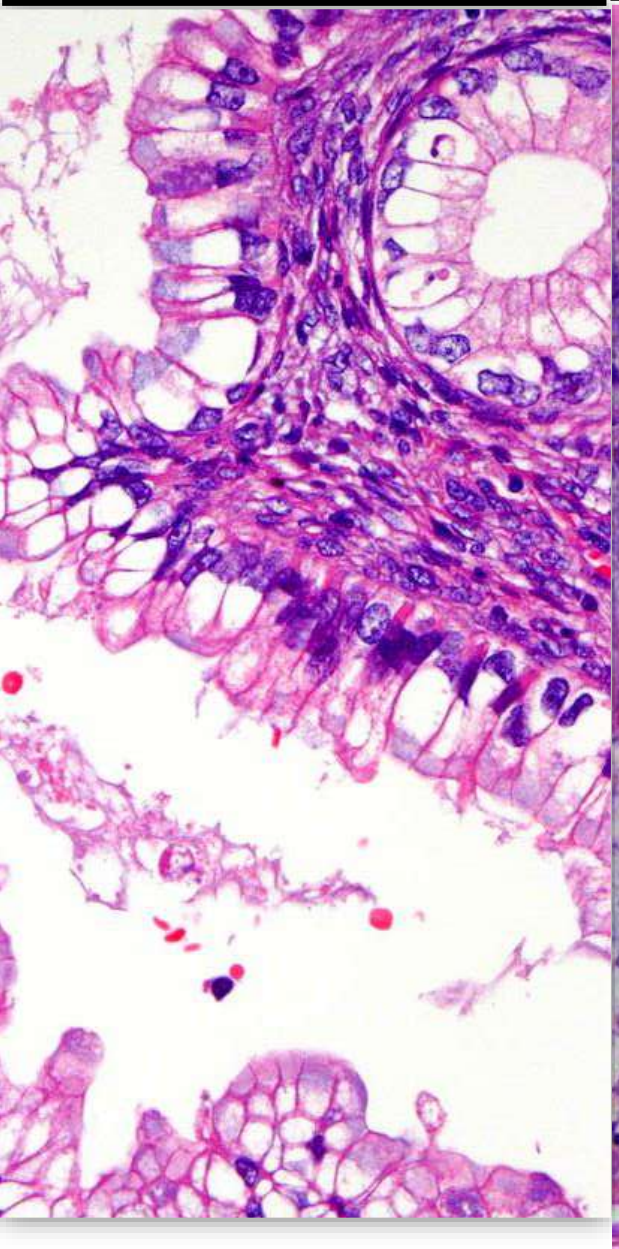

Clear cell
Clear cell morphology, mimics excluded

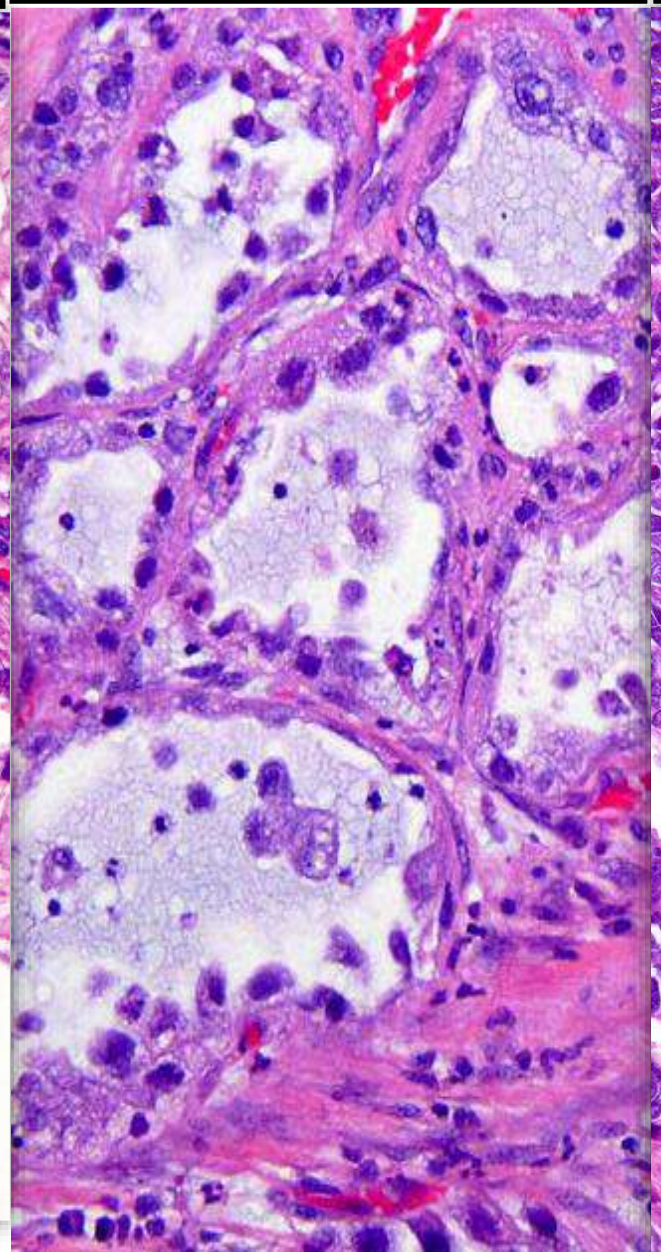

Mesonephric
Resembles mesonephric remnants with variable morphology

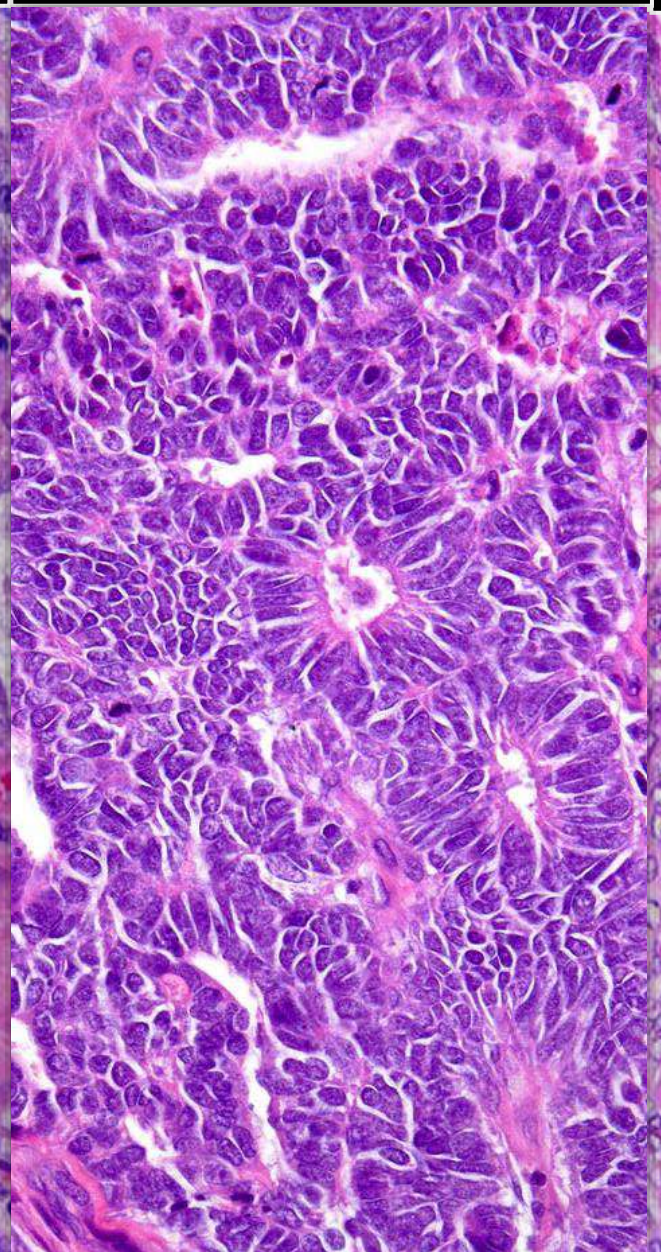

Endometrioid
Cervix primary with “confirmatory endometrioid features”

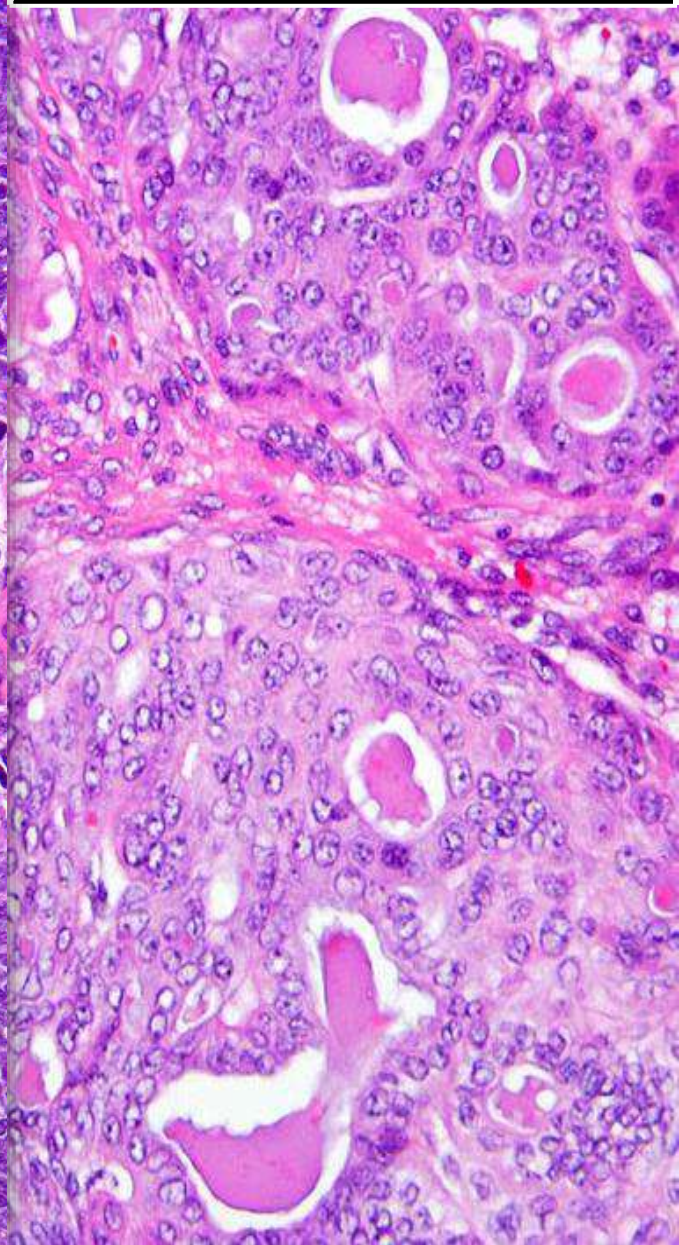

Case 1

43 y.o. history of cervical cancer with abdominal metastases

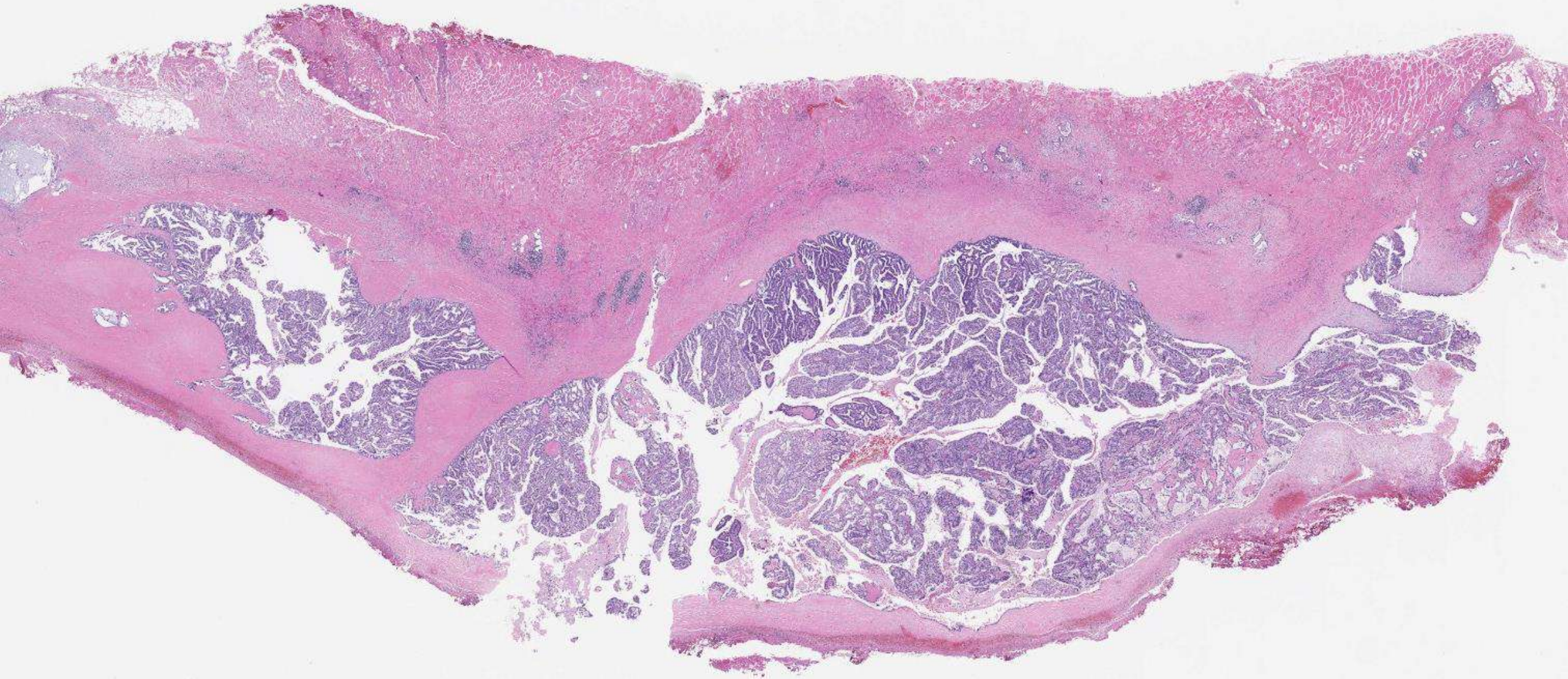

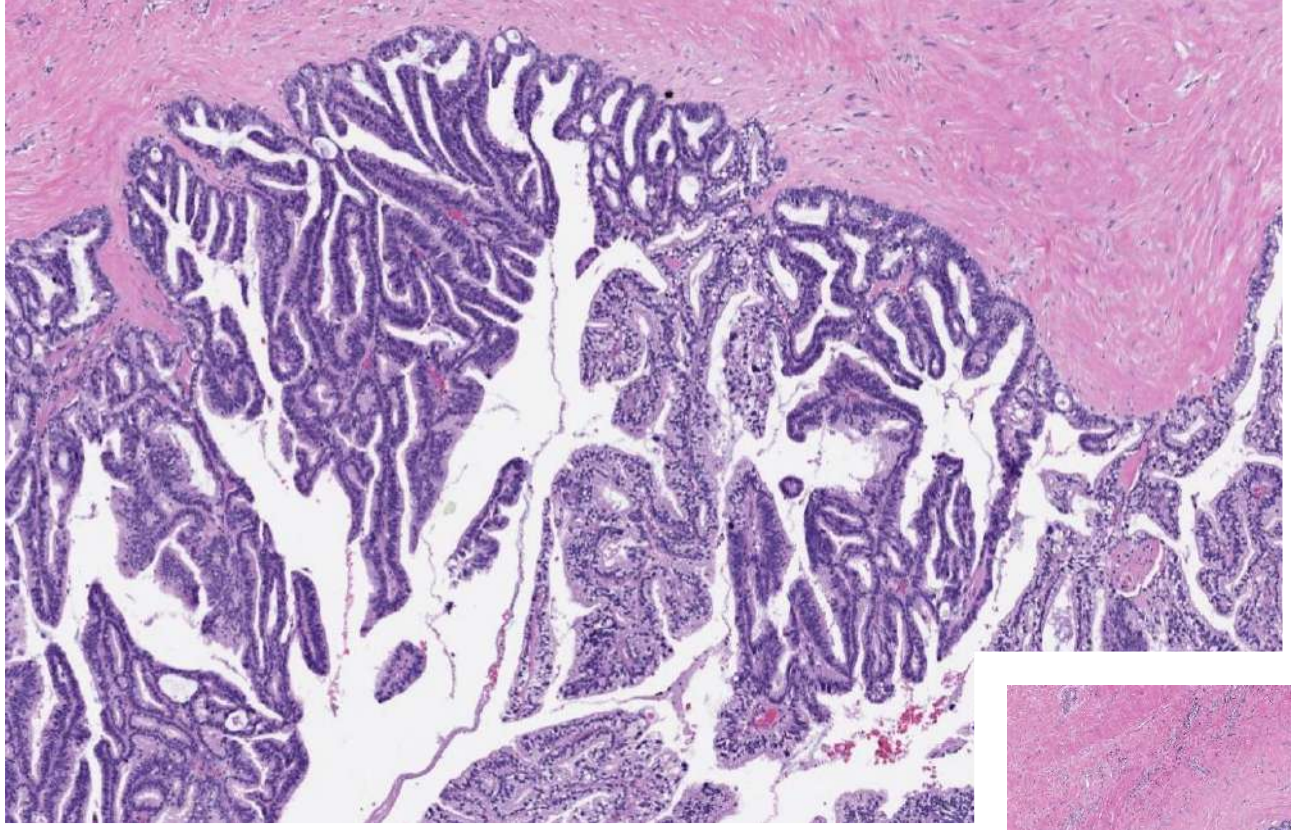

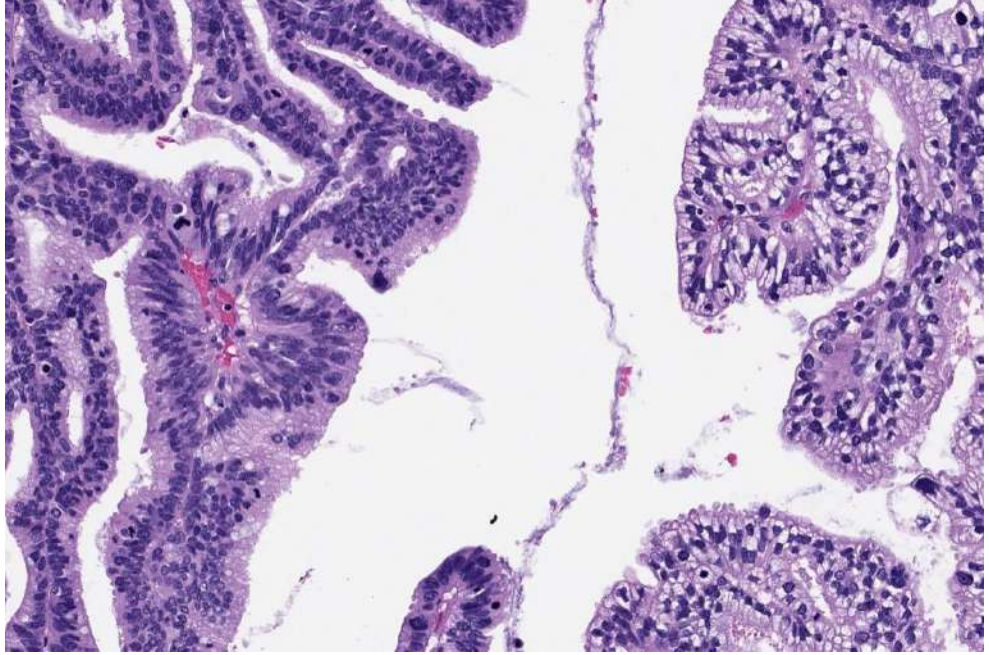

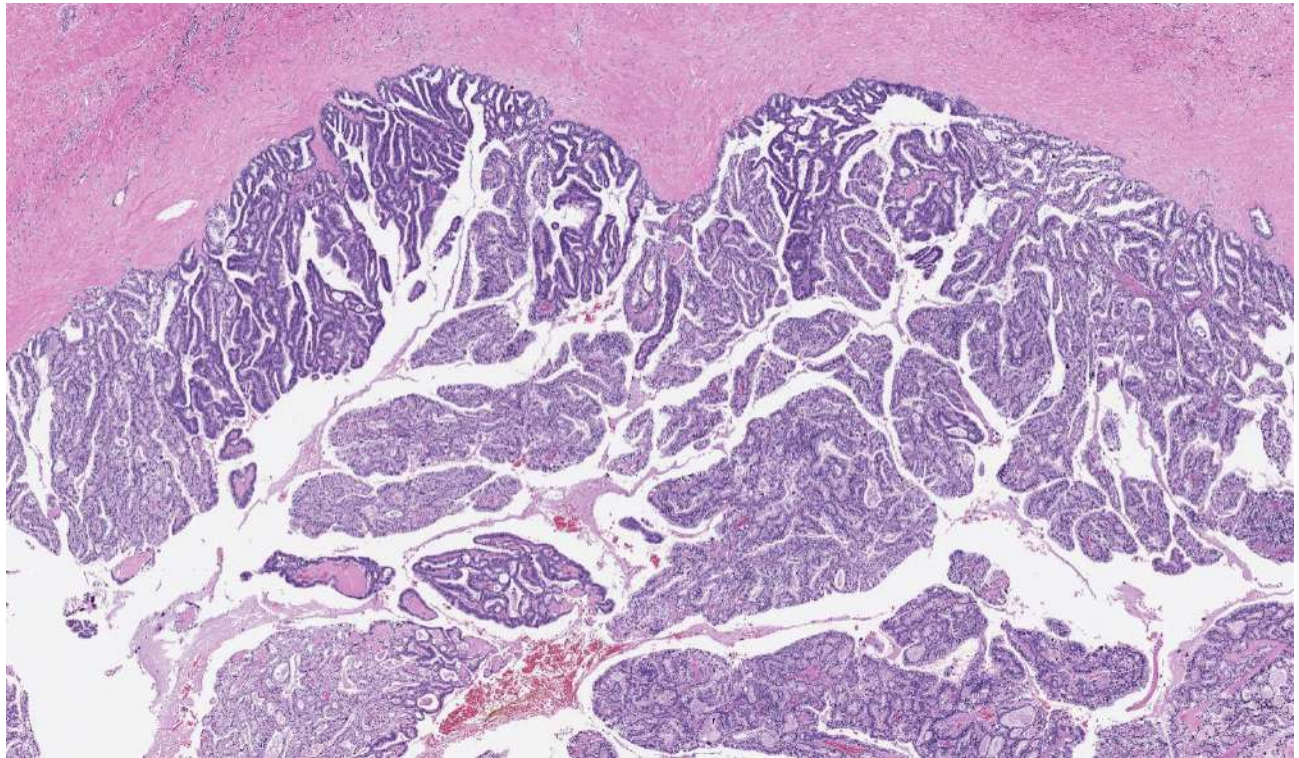

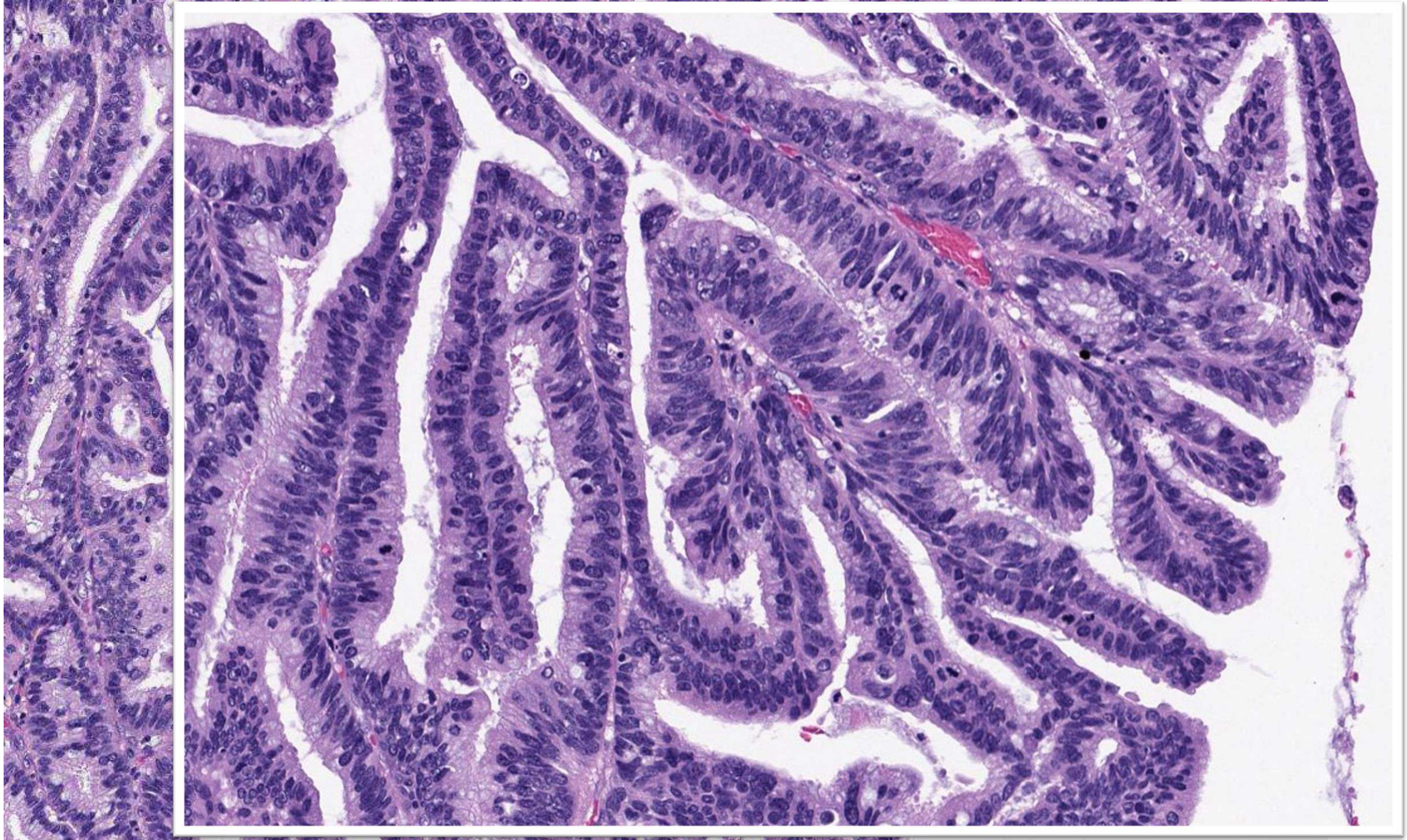

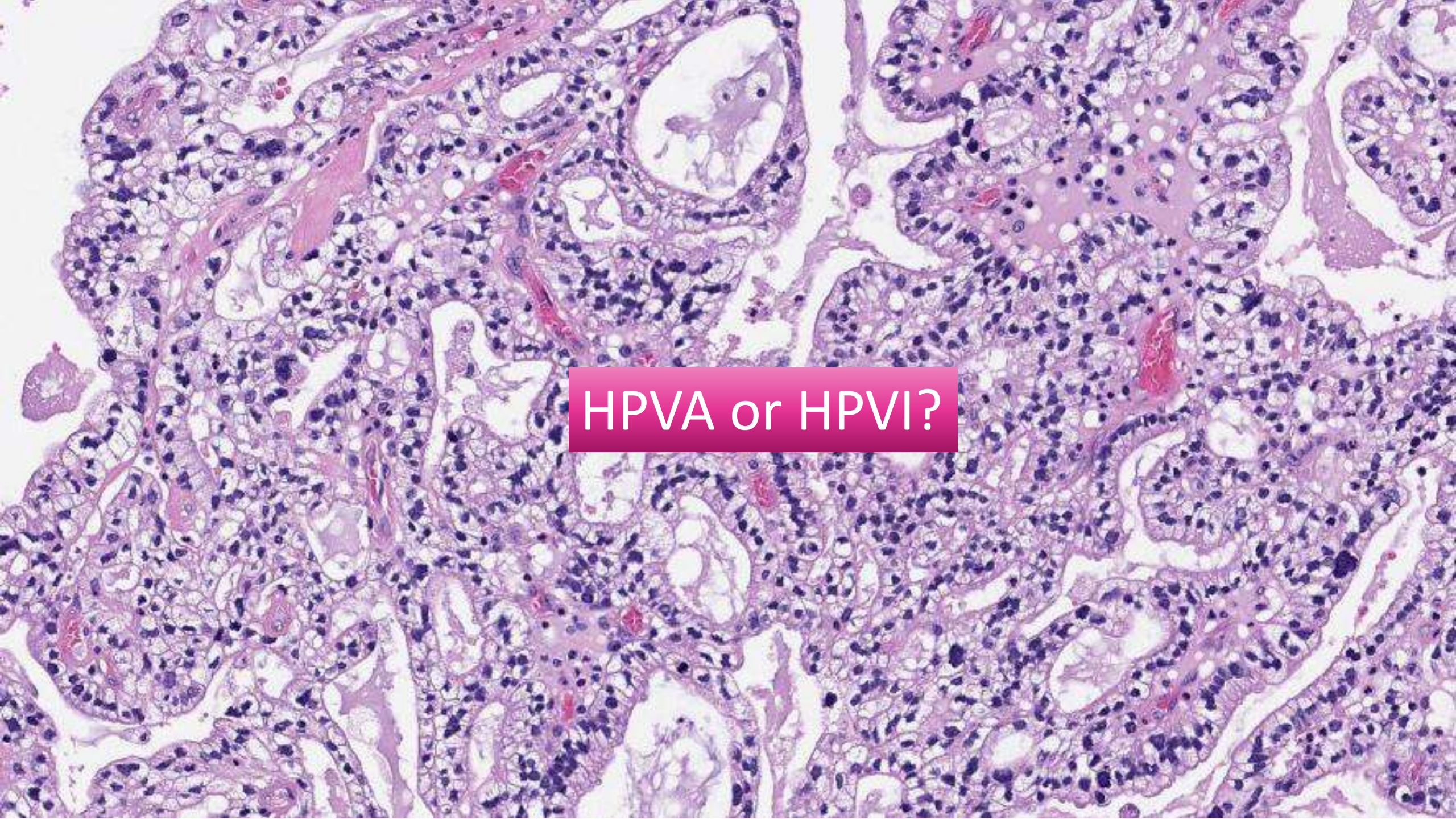
HPVA or HPVI?

HPV in situ hybridization

HPVA Adenocarcinoma with areas mimicking gastric type

p16

Case 2

60 year old with postmenopausal bleeding

ECC

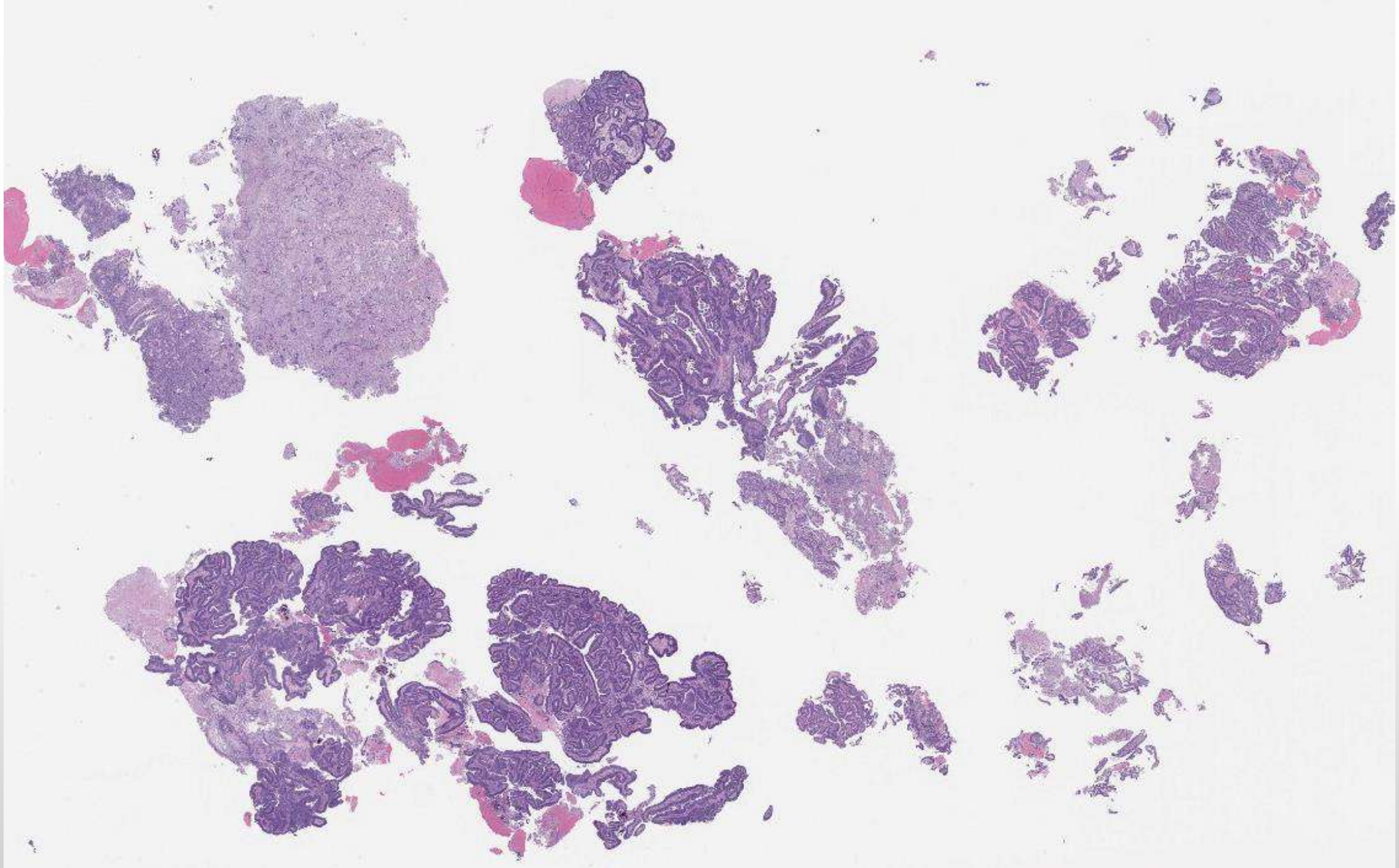


HPV and p16 Negative
Gastric type mimicking HPVA

Case 3

55 year old with Pap showing adenocarcinoma, HPV+

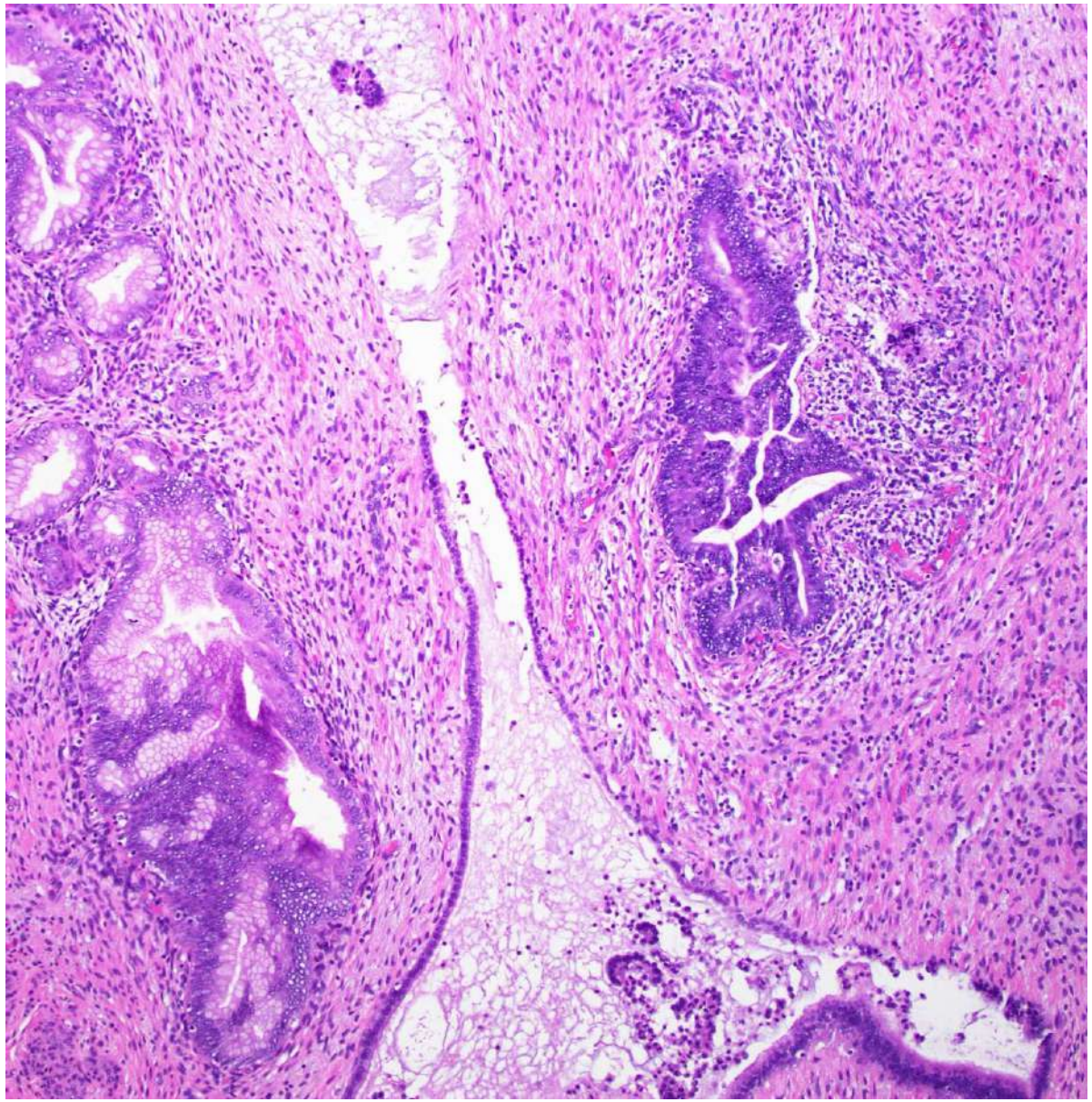

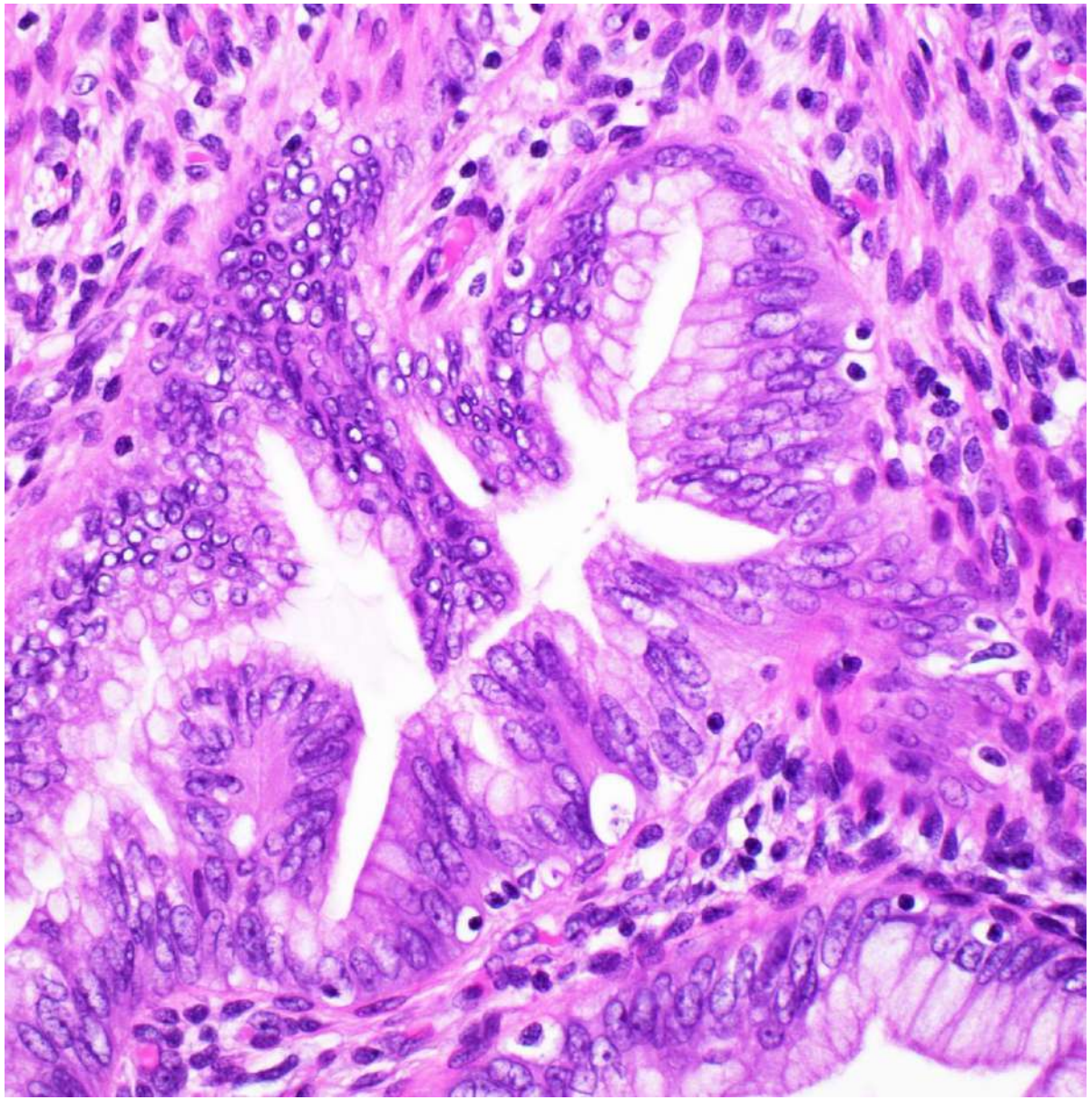

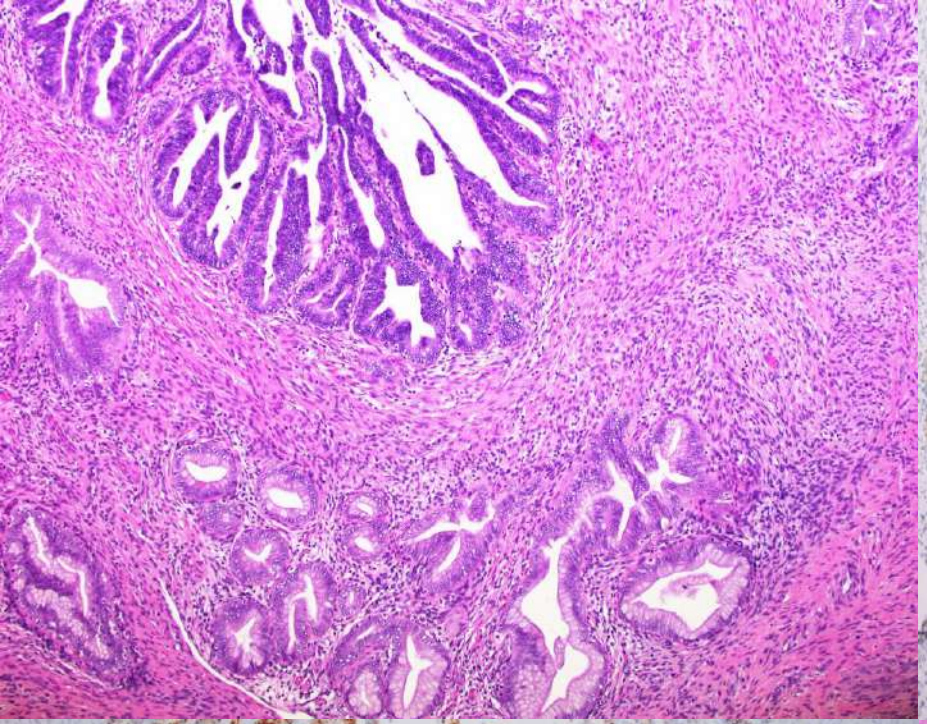



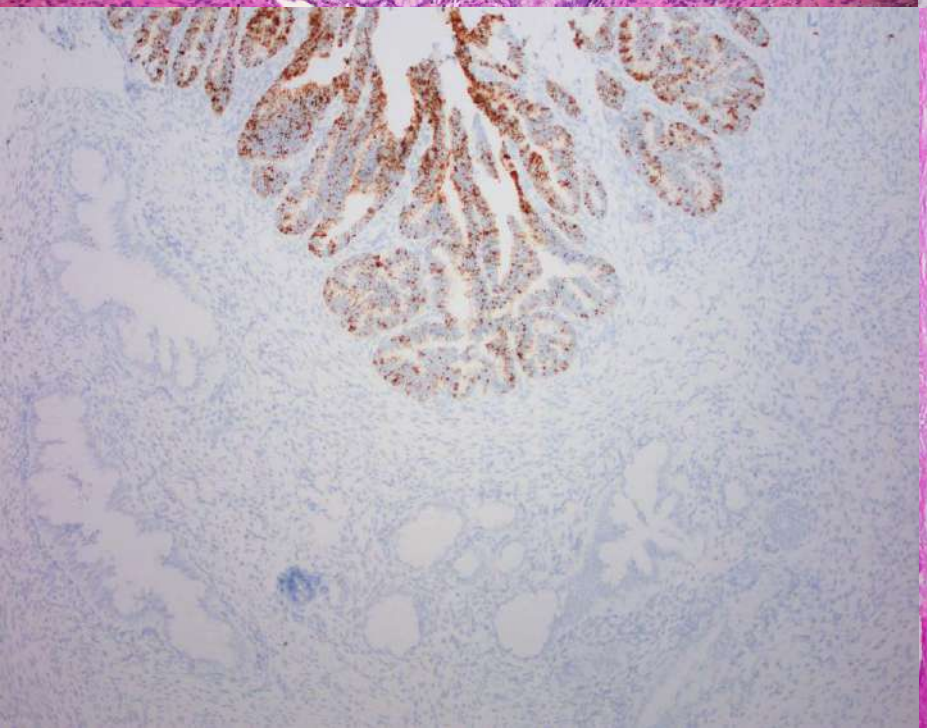

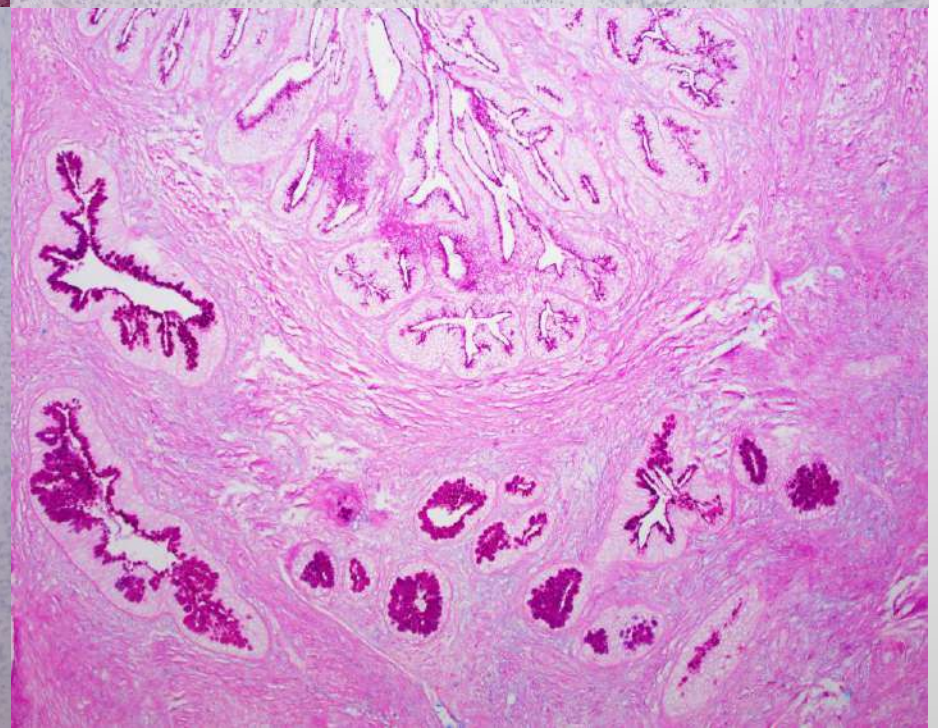

HPV+
adenocarcinoma
in
Pre-existing gastric
metaplasia/LEGH/
aLEGH

Take home points

- HPVA adenocarcinoma can mimic gastric type
- Gastric type can mimic HPVA
- HPVA and HPVI glandular neoplasia can co-exist!
- Morphology is usually enough but can be overlapping
- P16 is usually but not always helpful
- HPV ISH is very helpful
- PAS/Ab highlights gastric type mucin but it can still be involved by HPV+ neoplasia

Adenocarcinoma Sutyping

Case 4

44 year old with atypical glands on Pap

DDx
Clear cell carcinoma
Mesonephric carcinoma
Gastric type

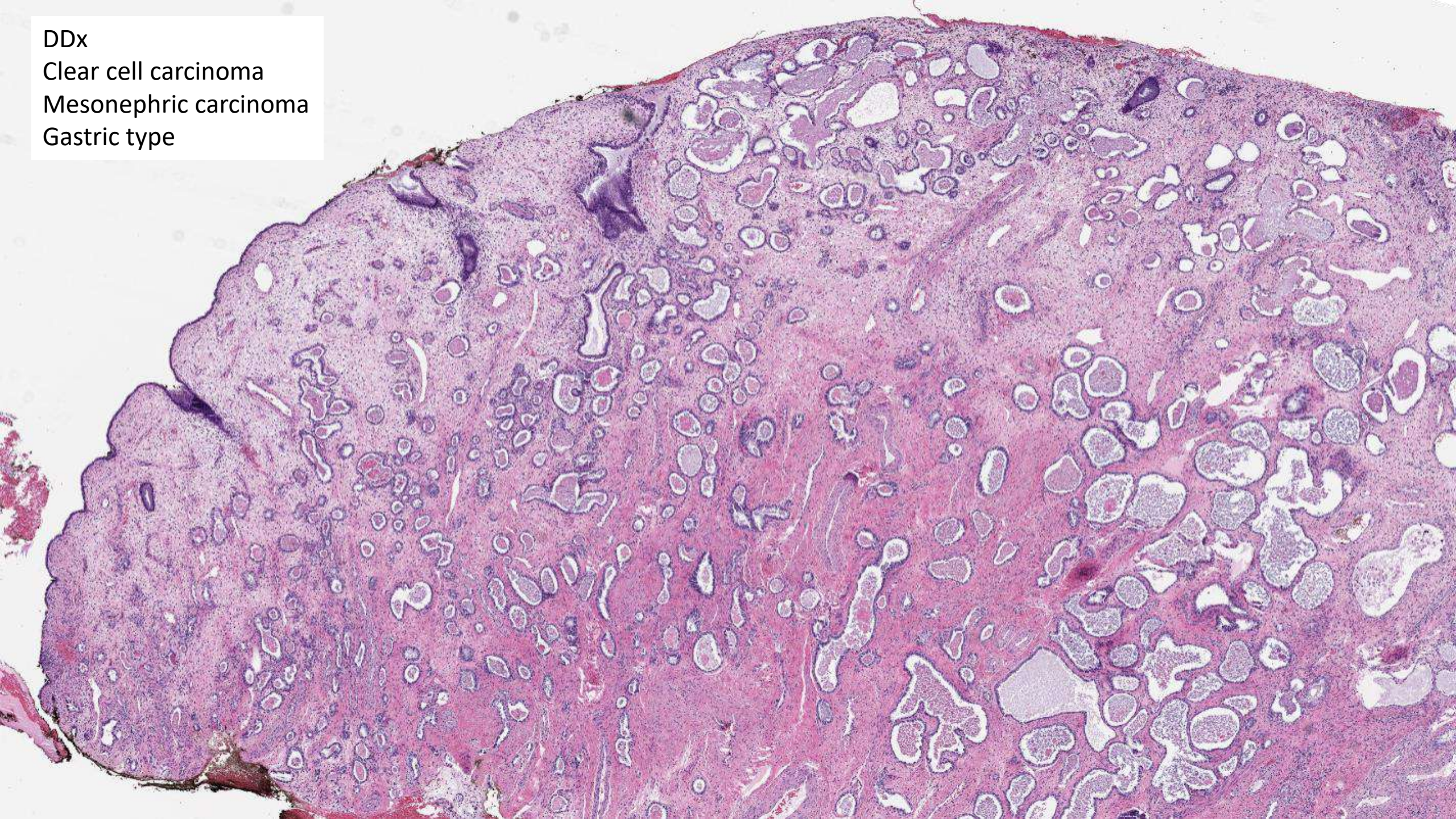

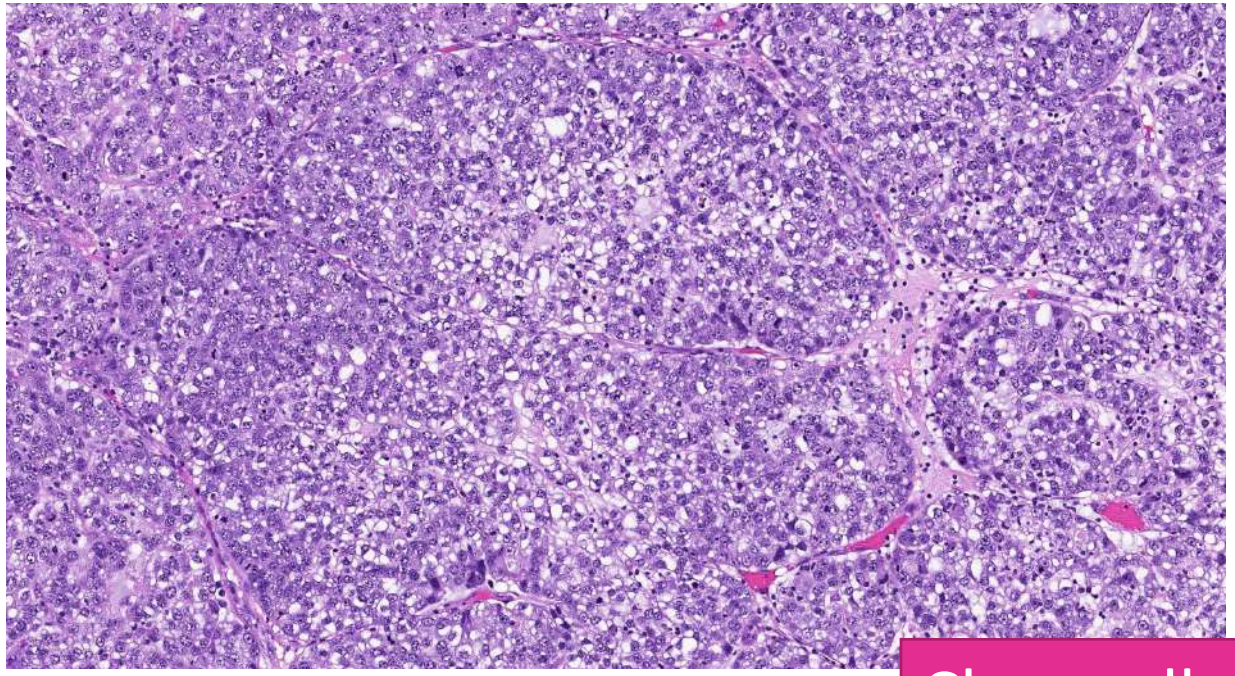
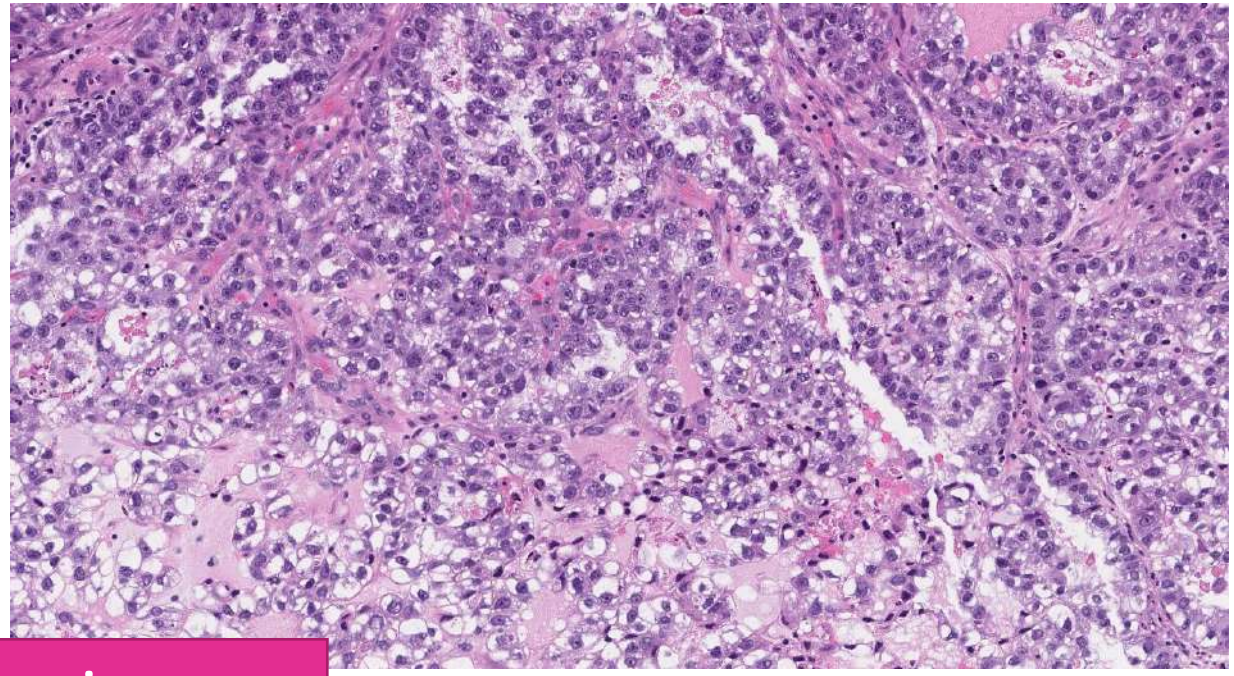

Clear cell carcinoma

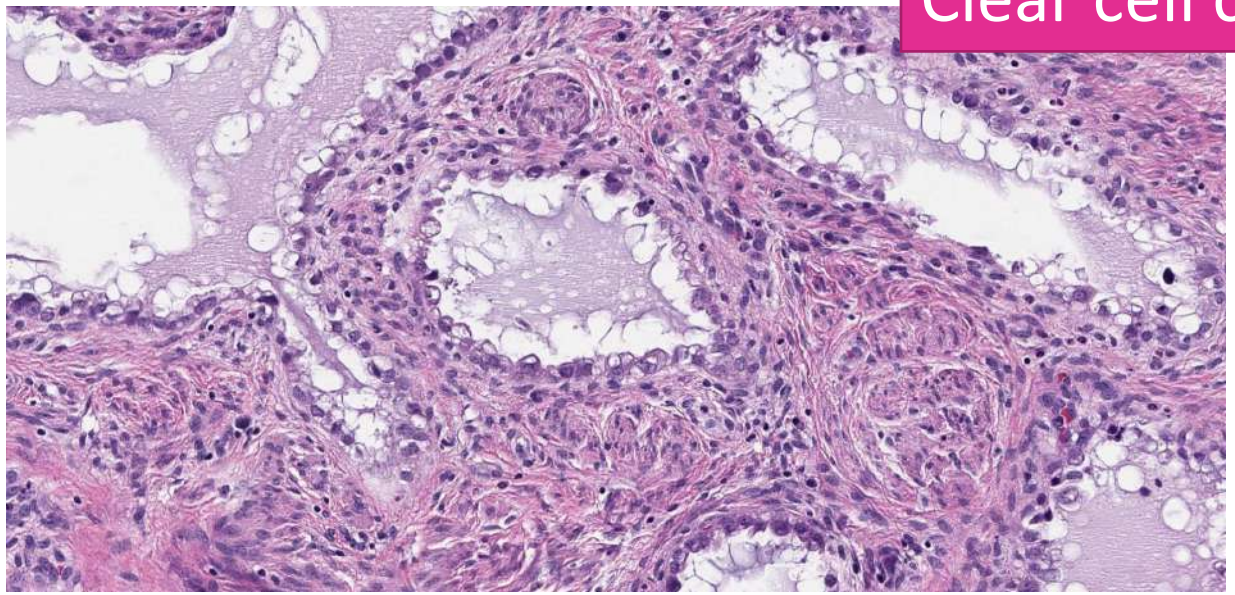
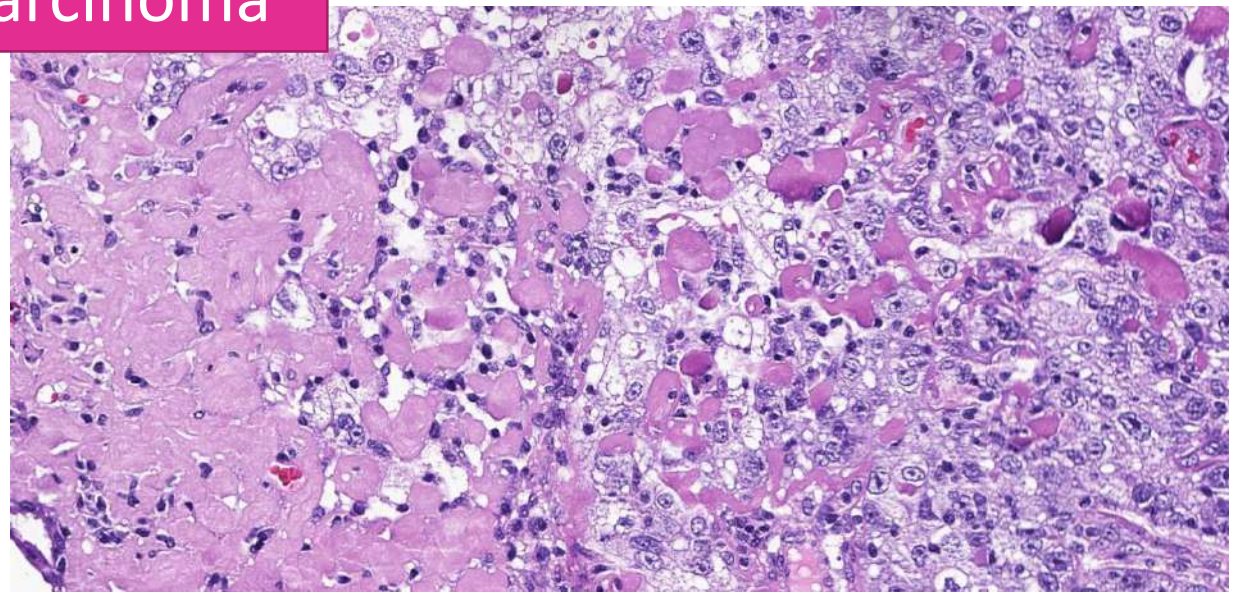

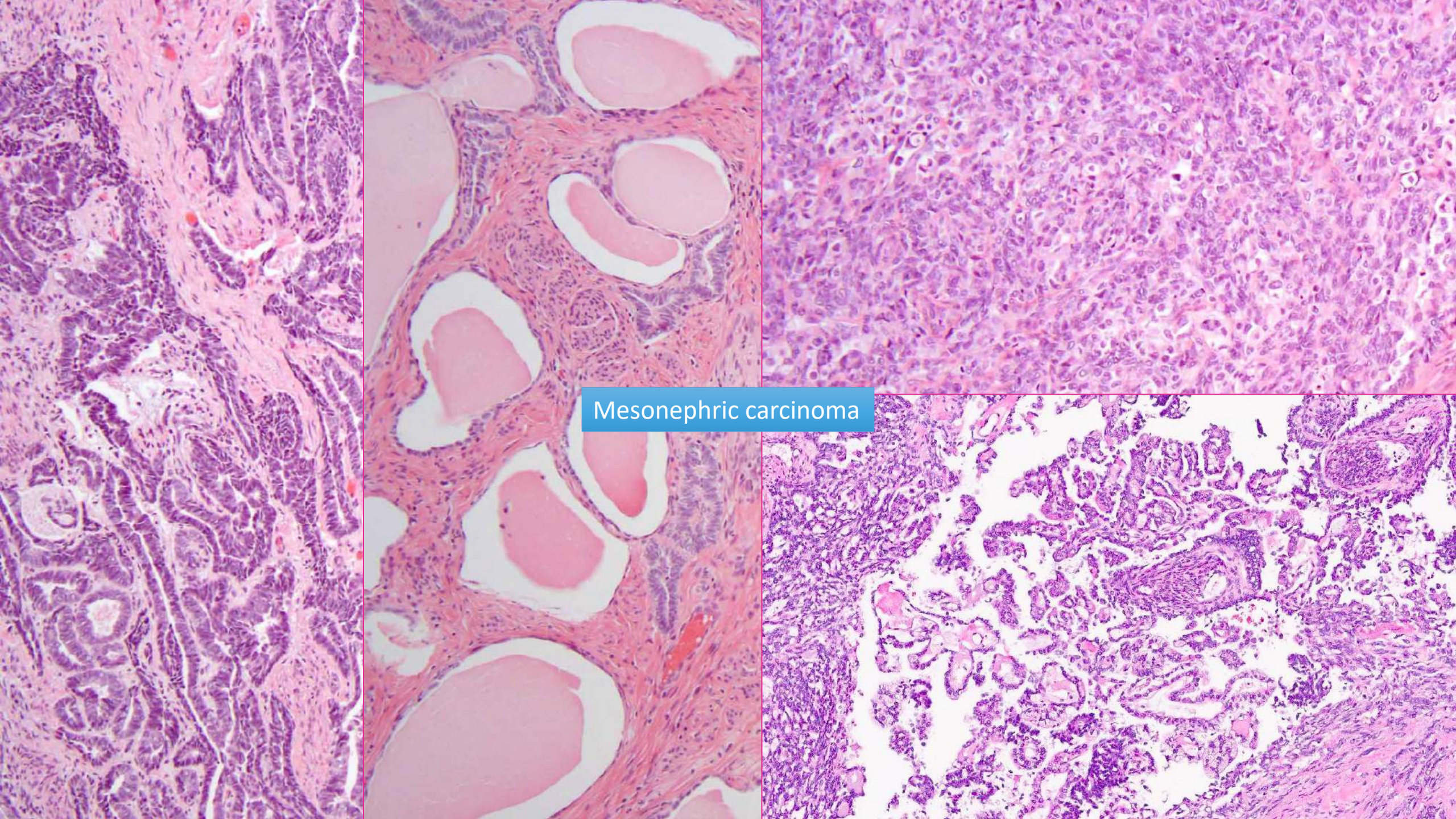
Mesonephric carcinoma

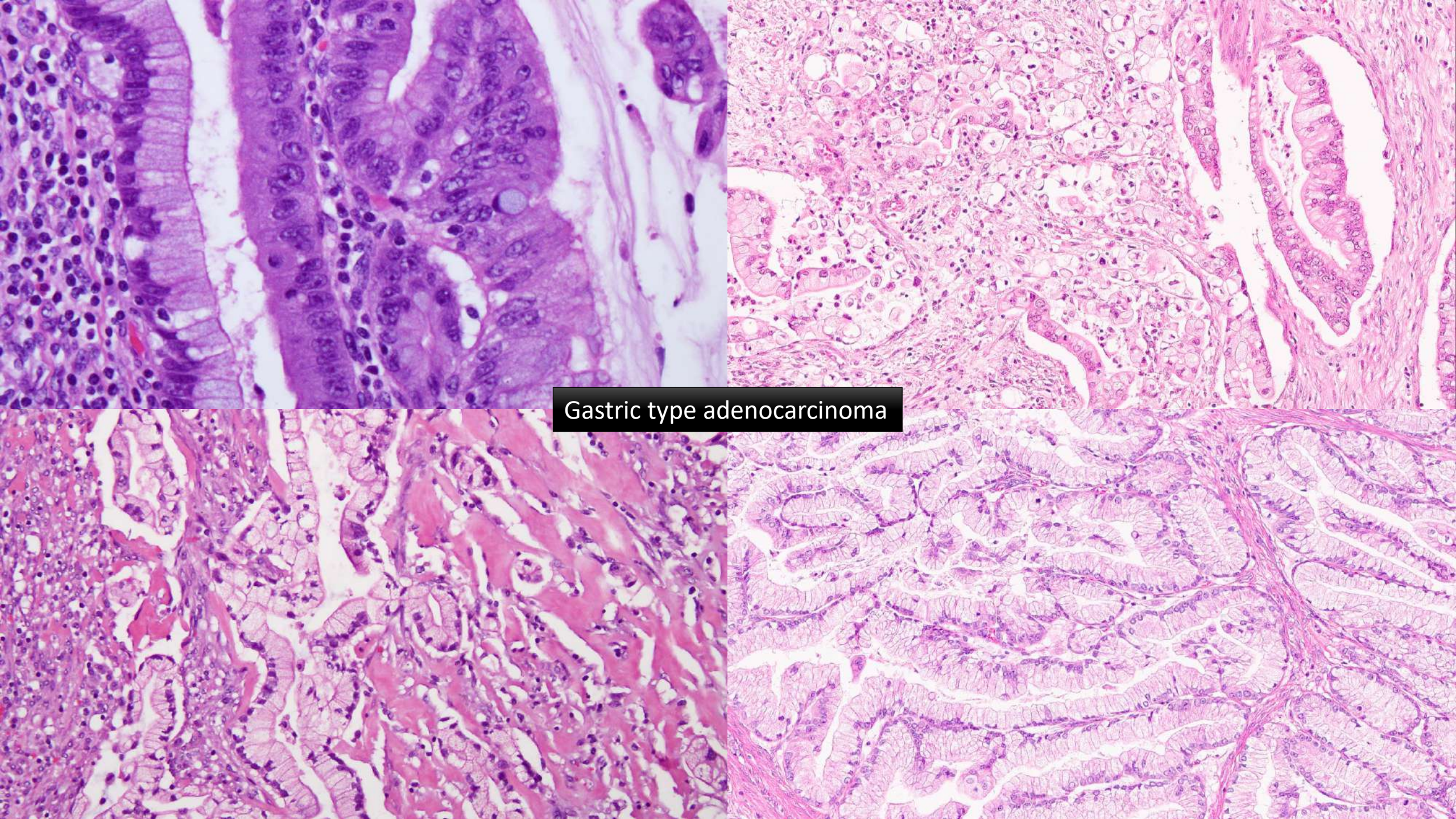
Gastric type adenocarcinoma

Classic morphology in well sampled specimen

- CCC: hobnail, papillary, solid, glycogen (not mucin)
- Mesonephric: morphologic heterogeneity, tubular, eosinophilic secretions, PTC-like nuclei, spindling
- Gastric: mucin, tall columnar, lobular, goblet cells

Ancillary studies

NOT HELPFUL

- P16
- ER/PR
- PAX8
- TTF1
- HNF1beta

HELPFUL

- GATA3
- Napsin A
- Racemase (AMACR)
- p53

Ancillary tests

- p16
- HPV-ISH

→ HPVA vs. HPVI

- Napsin-A
- Racemase
- HNF1-beta
- ER/PR

→ Clear cell carcinoma

- GATA3
- TTF-1
- CD10

→ Mesonephric carcinoma

- p53 → Aberrant in ~50% Gastric type; differentiate from serous metastasis
- PAS-Ab
- Mucicarmine

→ Gastric/pyloric mucin (PAS dominant)

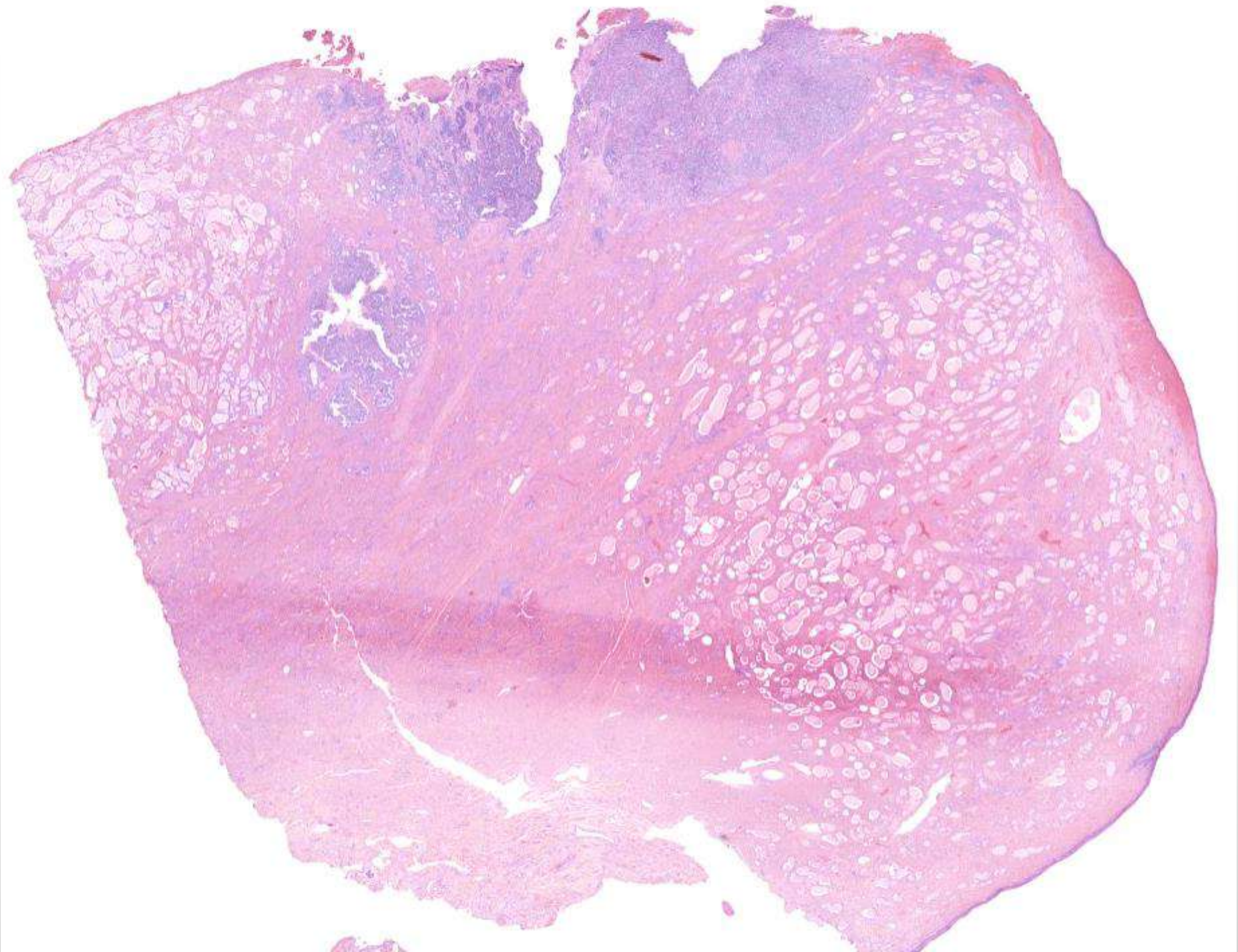

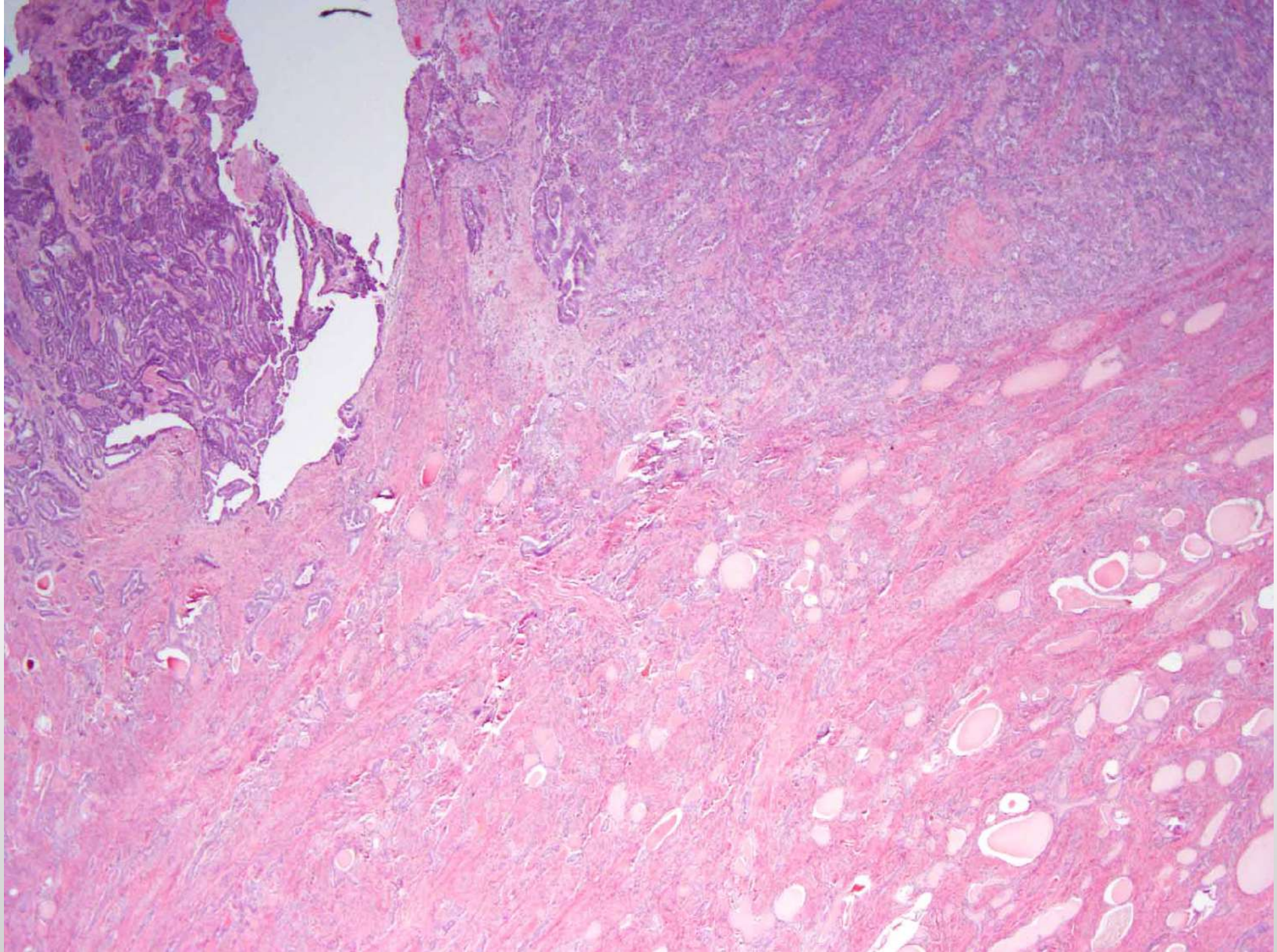

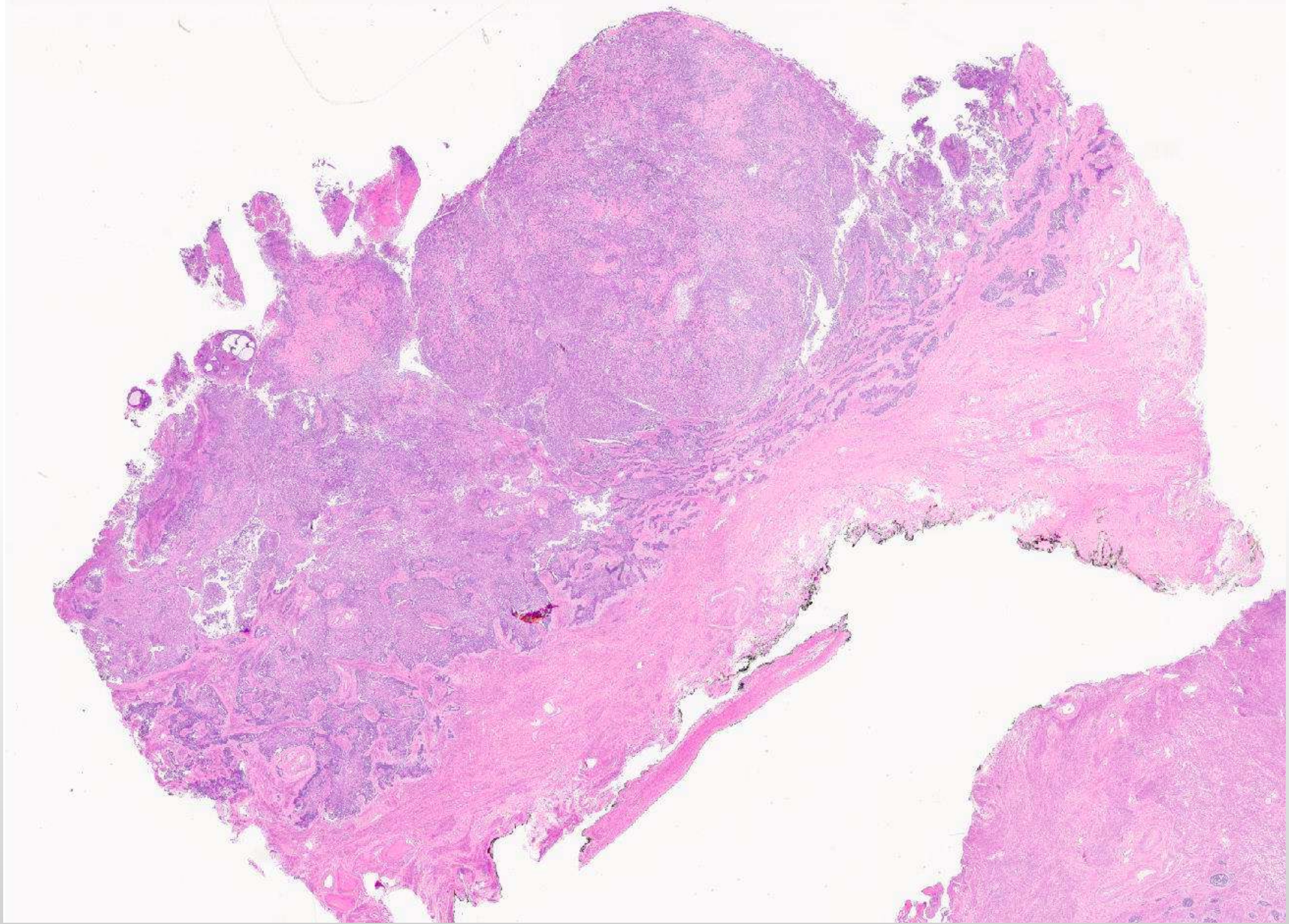

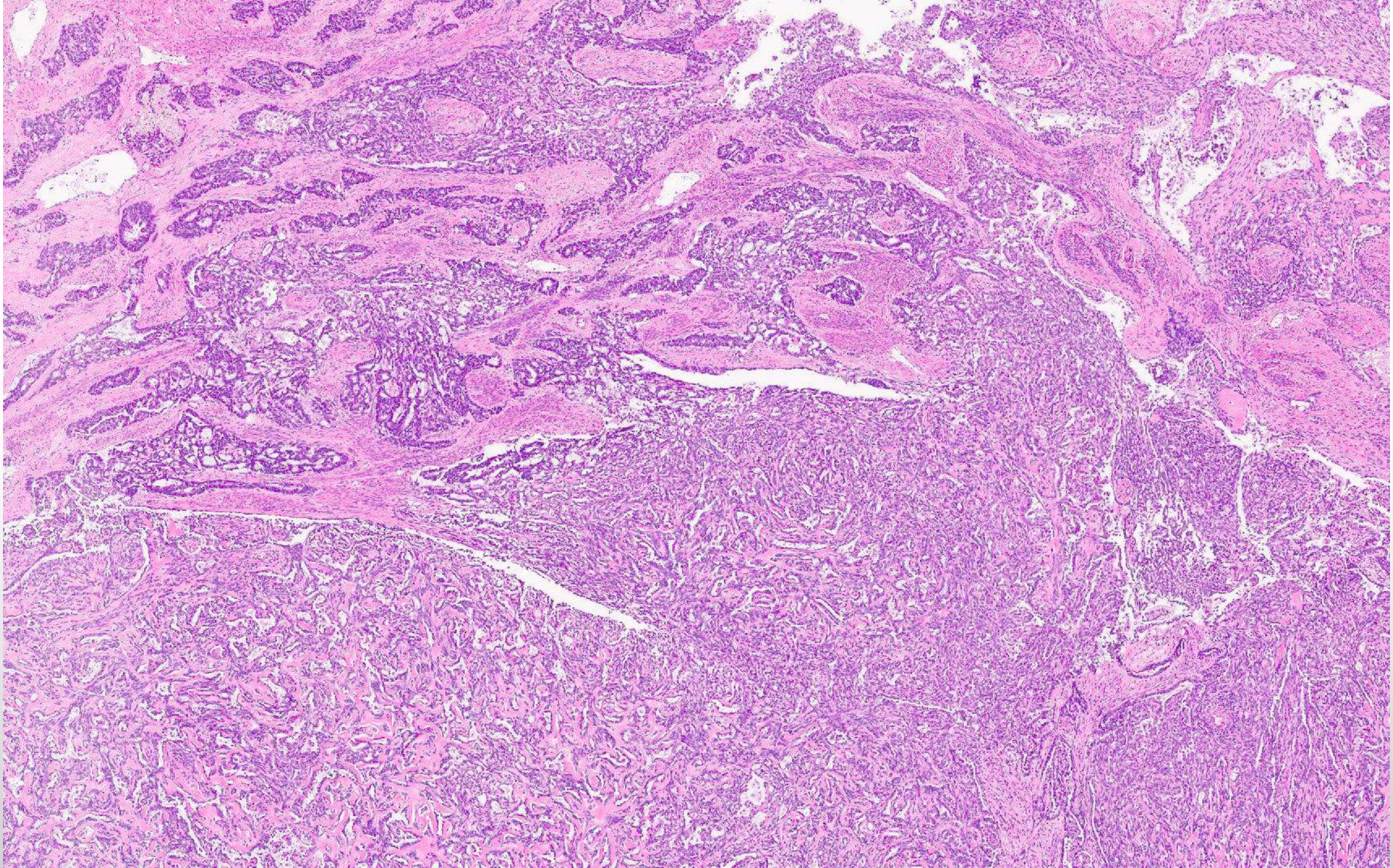

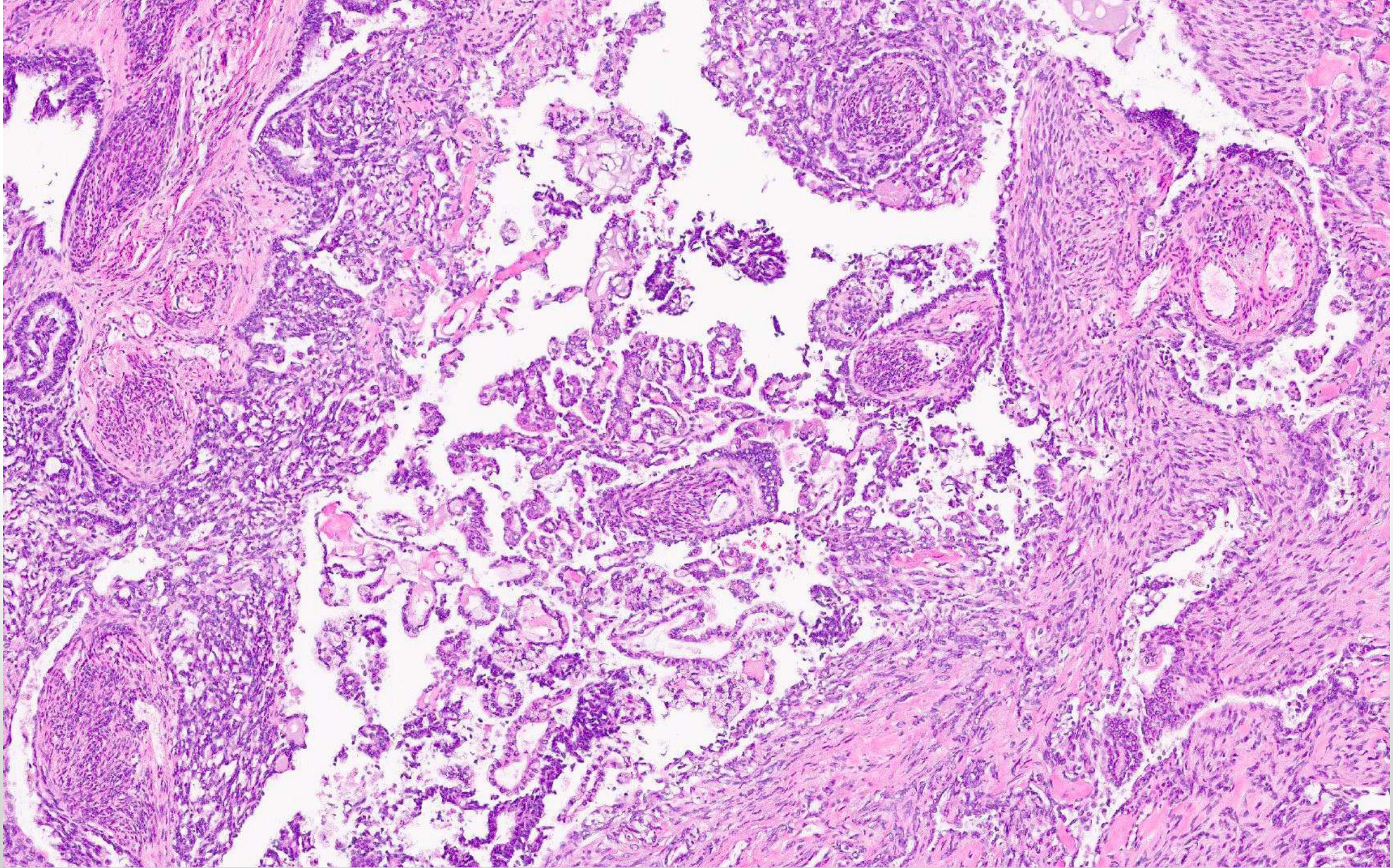

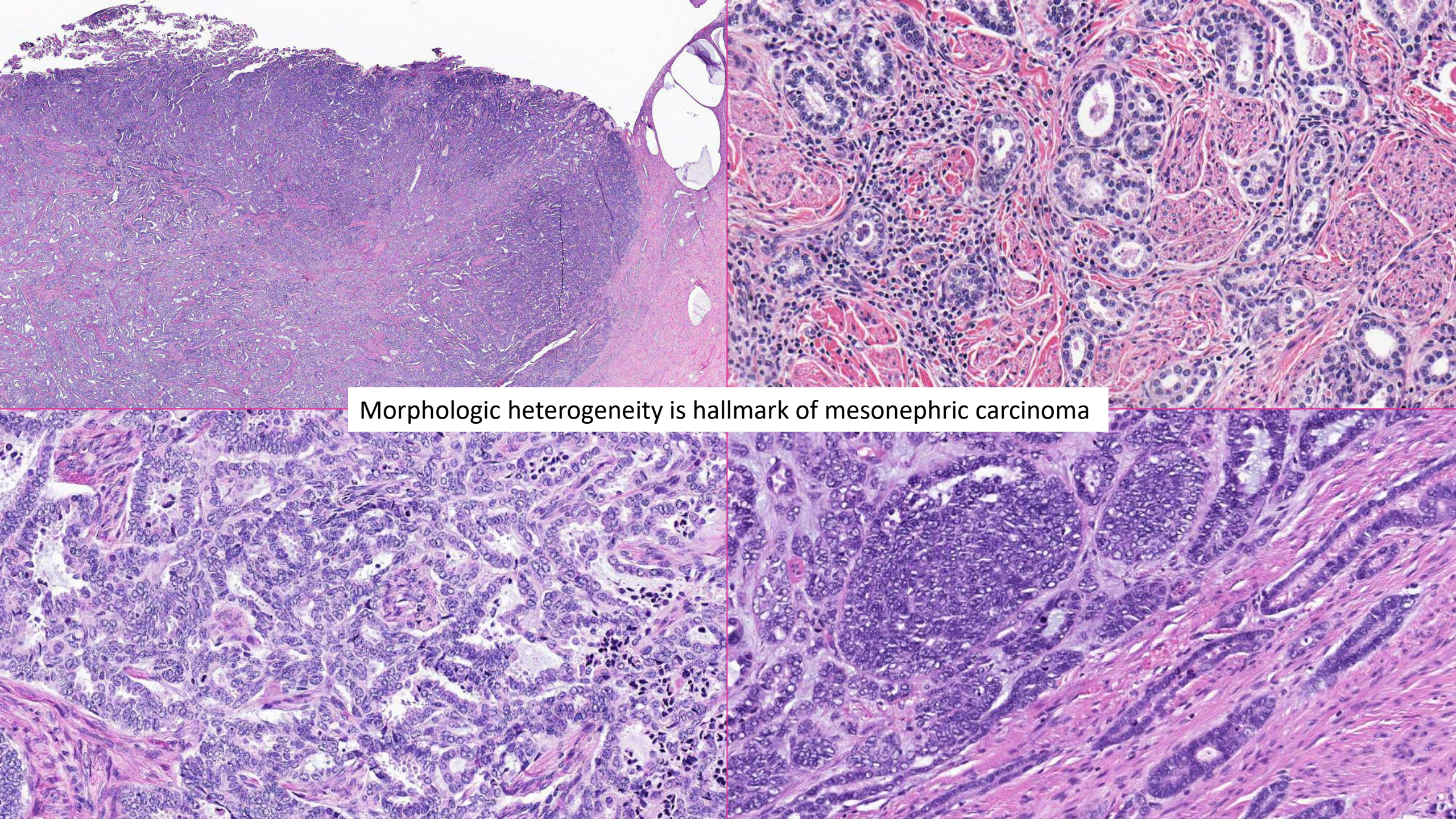
Morphologic heterogeneity is hallmark of mesonephric carcinoma

Benign vs. Pre-invasive vs. Invasive

Benign vs. AIS/CGIN (HPV+) vs. aLEGH/gAIS (HPV-)

aLEGH/gAIS vs. Invasive gastric type adenocarcinoma

Case 5

23 year old with atypical glands on Pap

Positive for HPV (non-16/18)

Cone

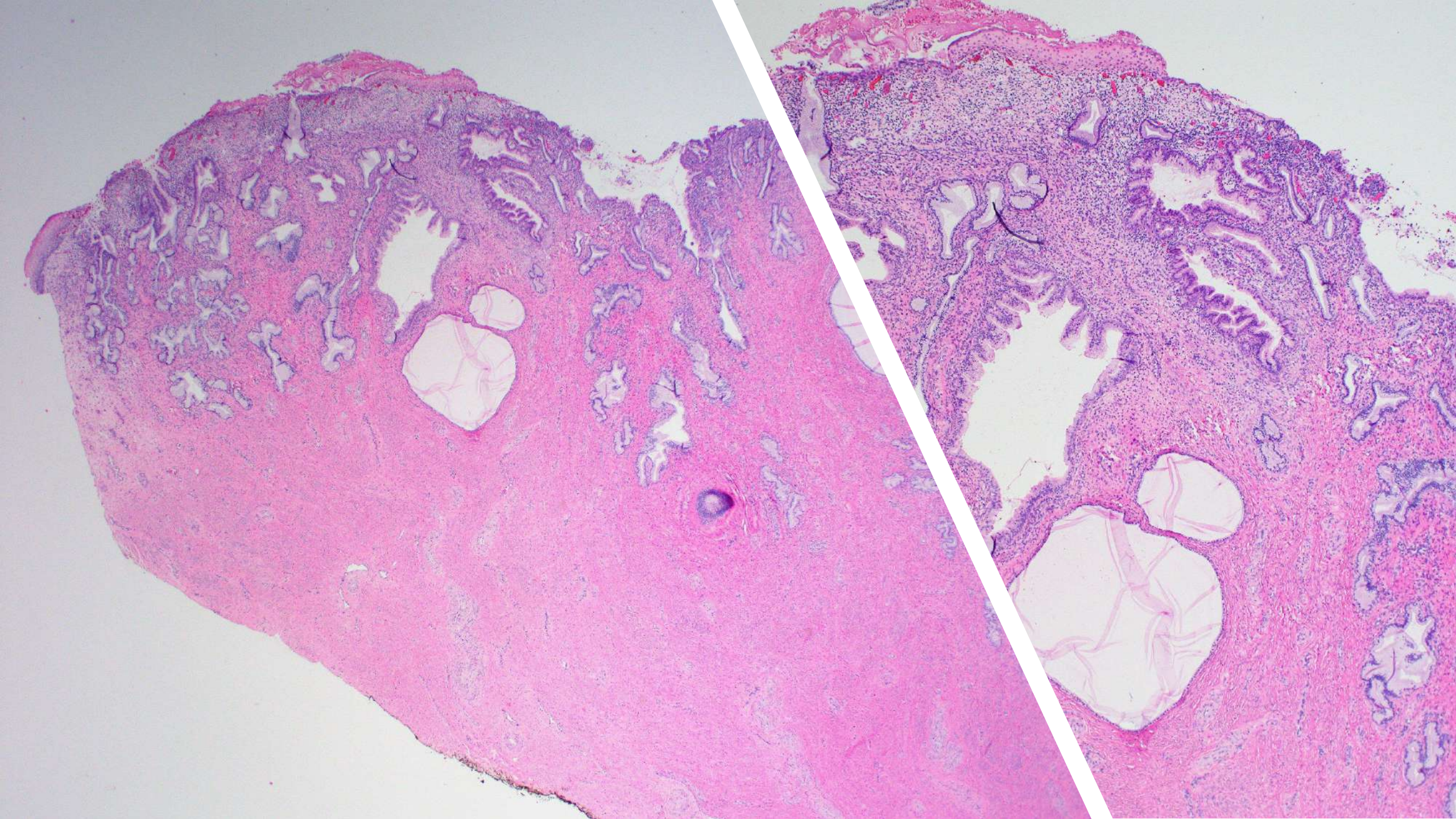

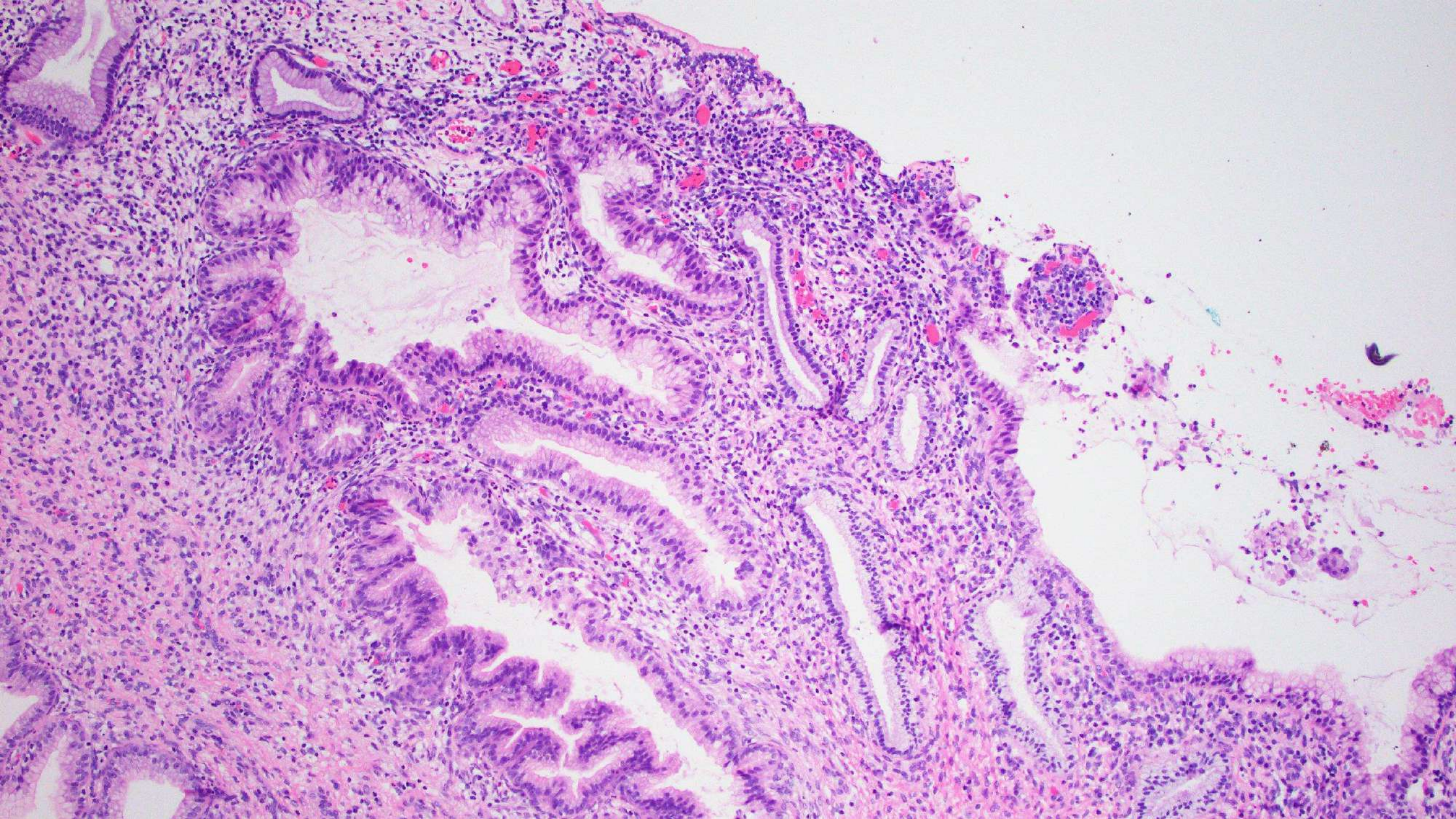

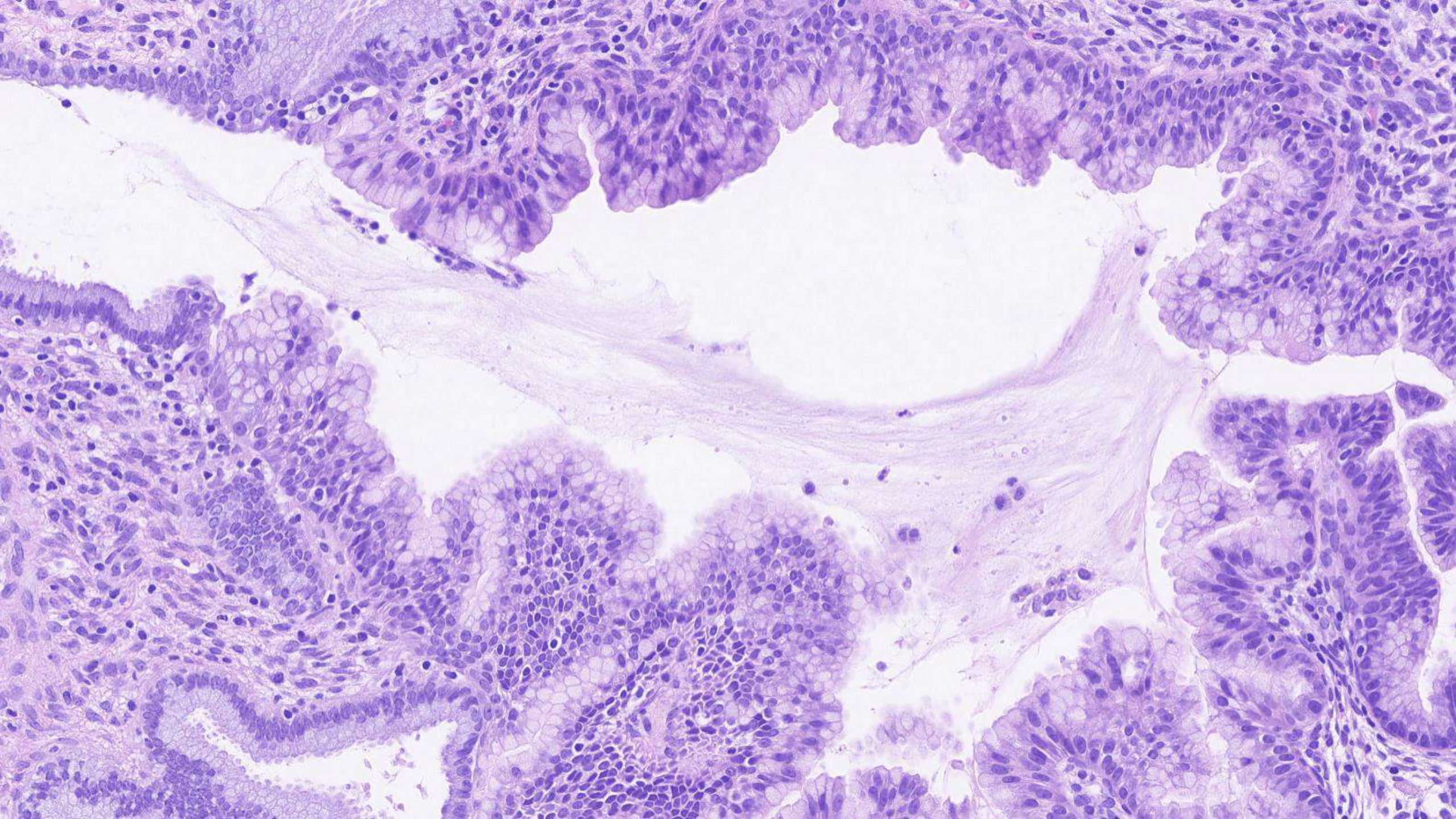

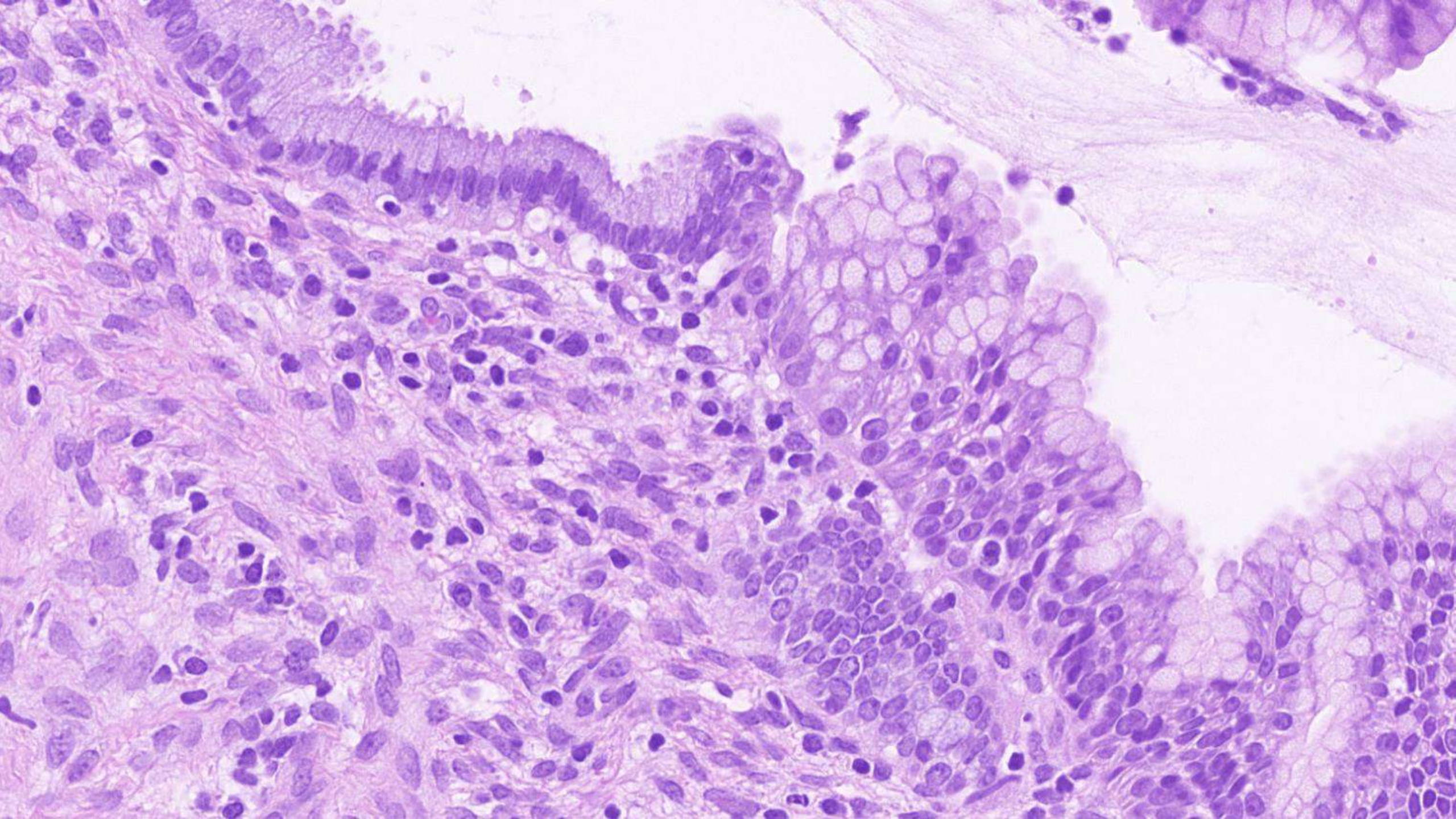

Question from submitting pathologist: Is this gastric type AIS?

IHC

- P16 negative
- p53 wild type
- HPV negative

Conclusion: not HPV associated

- Is it gastric type mucin?
- Is it neoplastic?

Ancillary studies (normal vs gAIS)

Helpful

- CA-IX
- PAS/AB
- p53 (sometimes)
- ER/PR
- PAX2

Not helpful

- p16

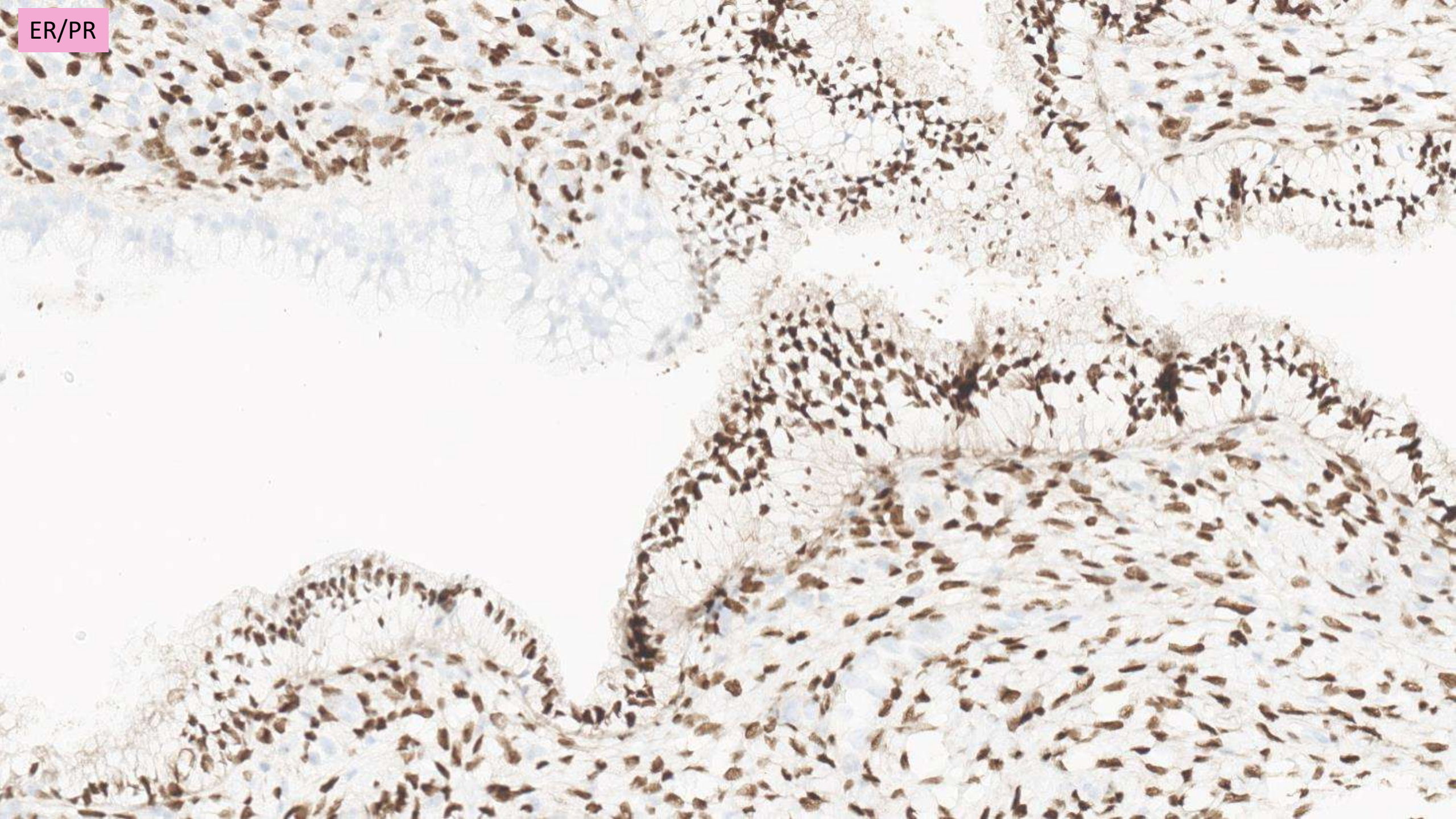
ER/PR

CA-IX

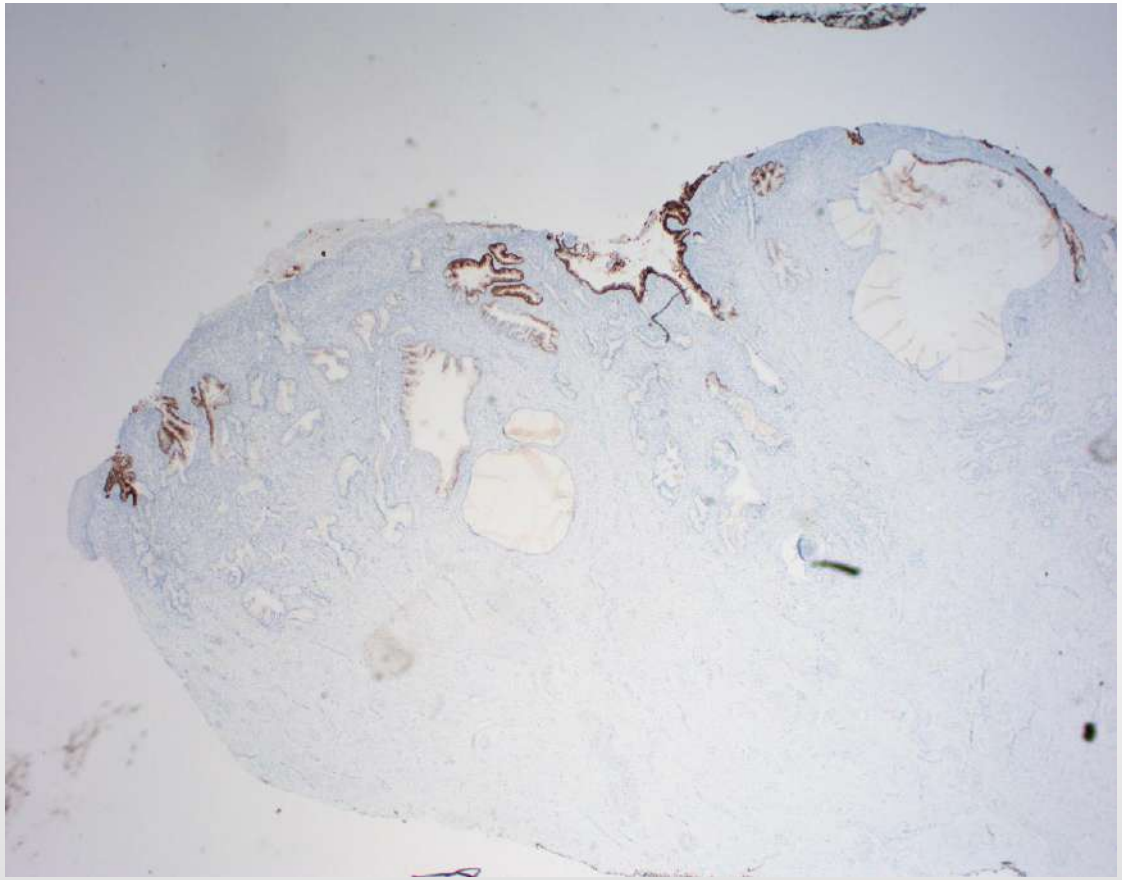

PAS-AB

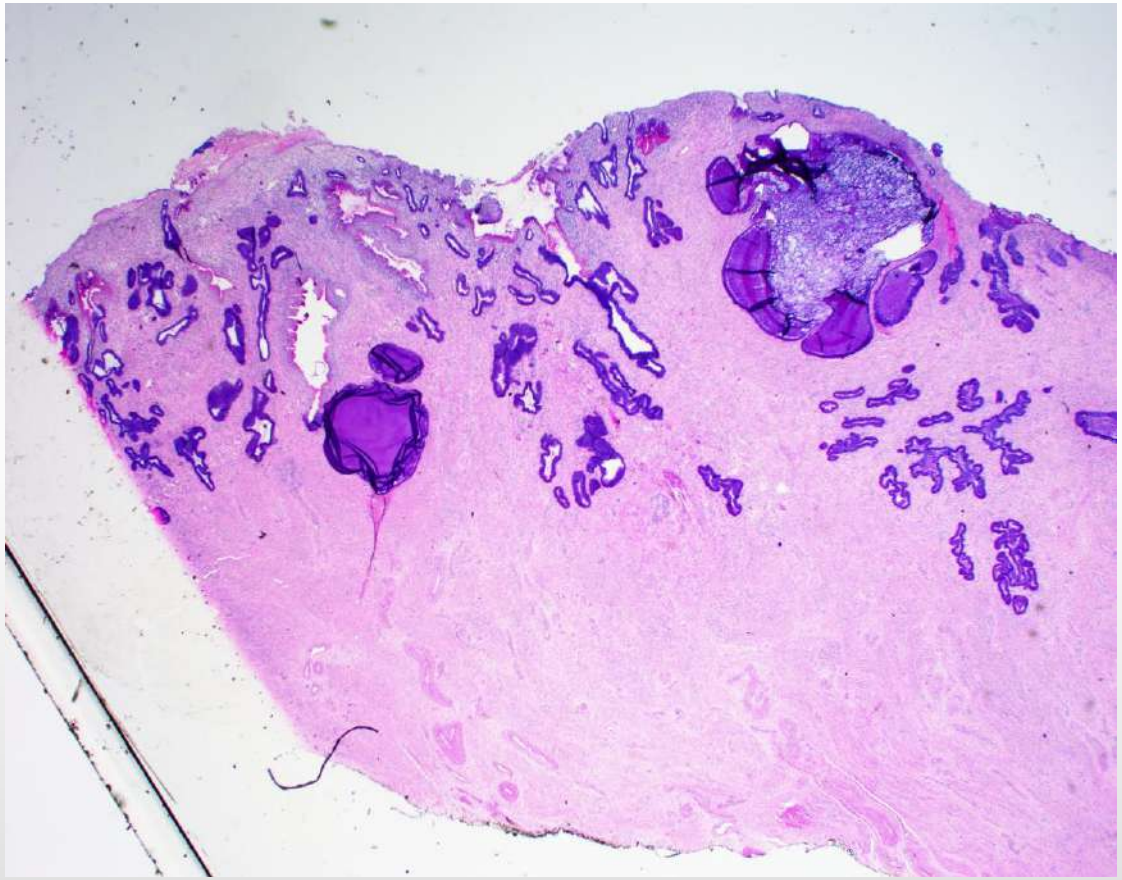

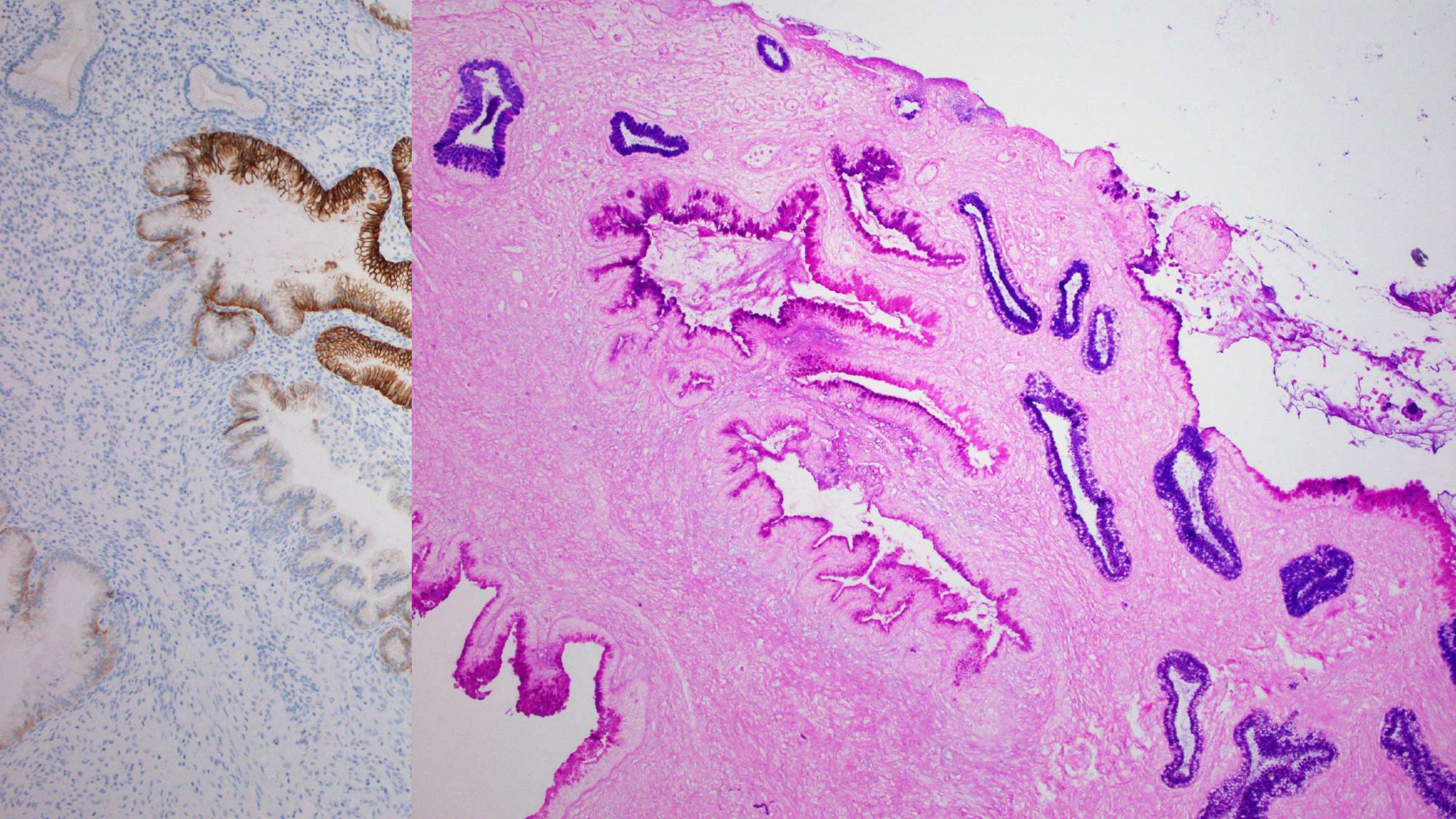

CA-IX

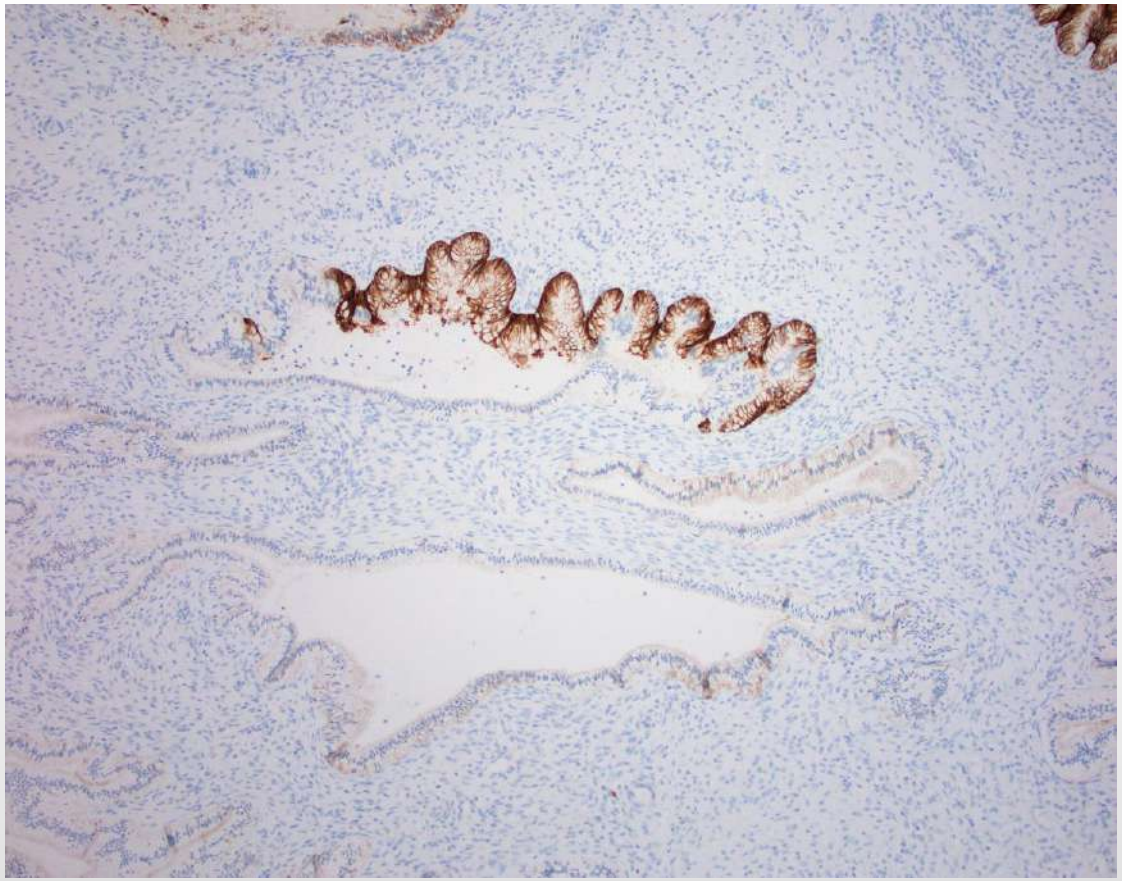

PAS-AB

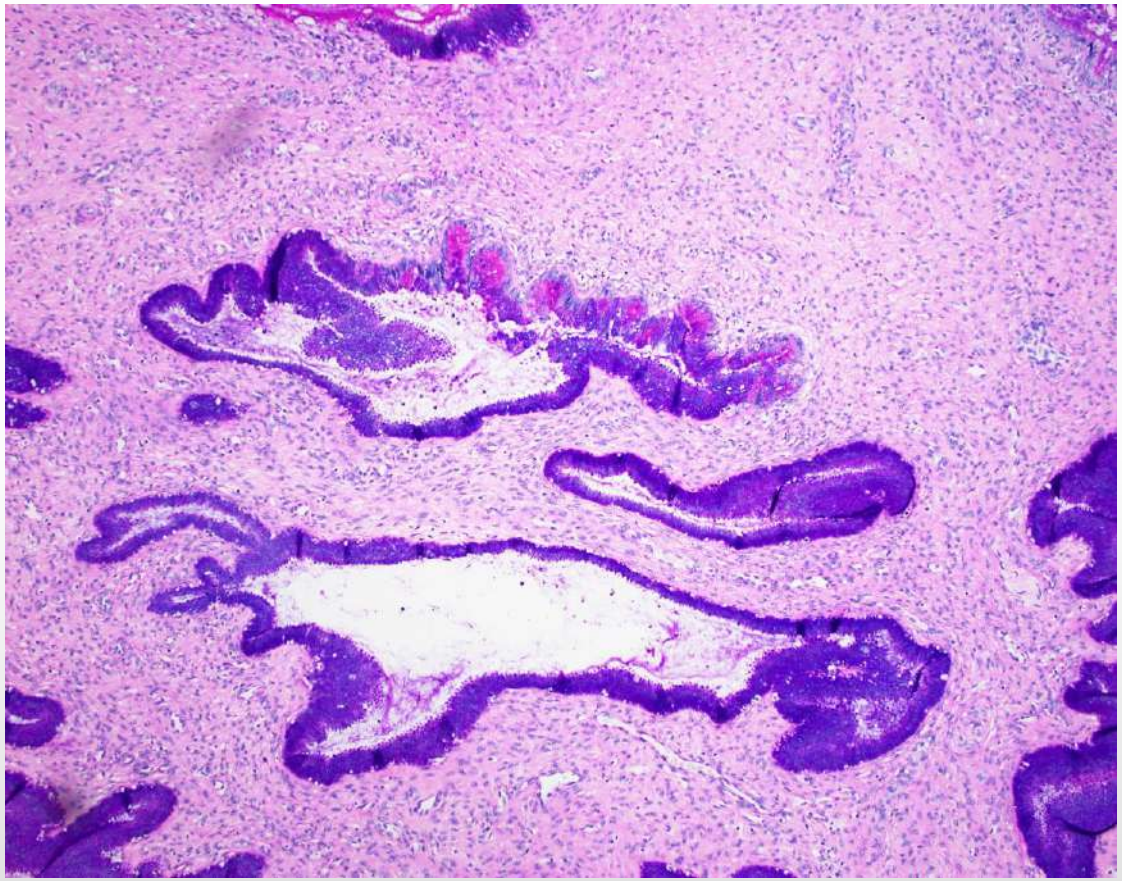

CA-IX

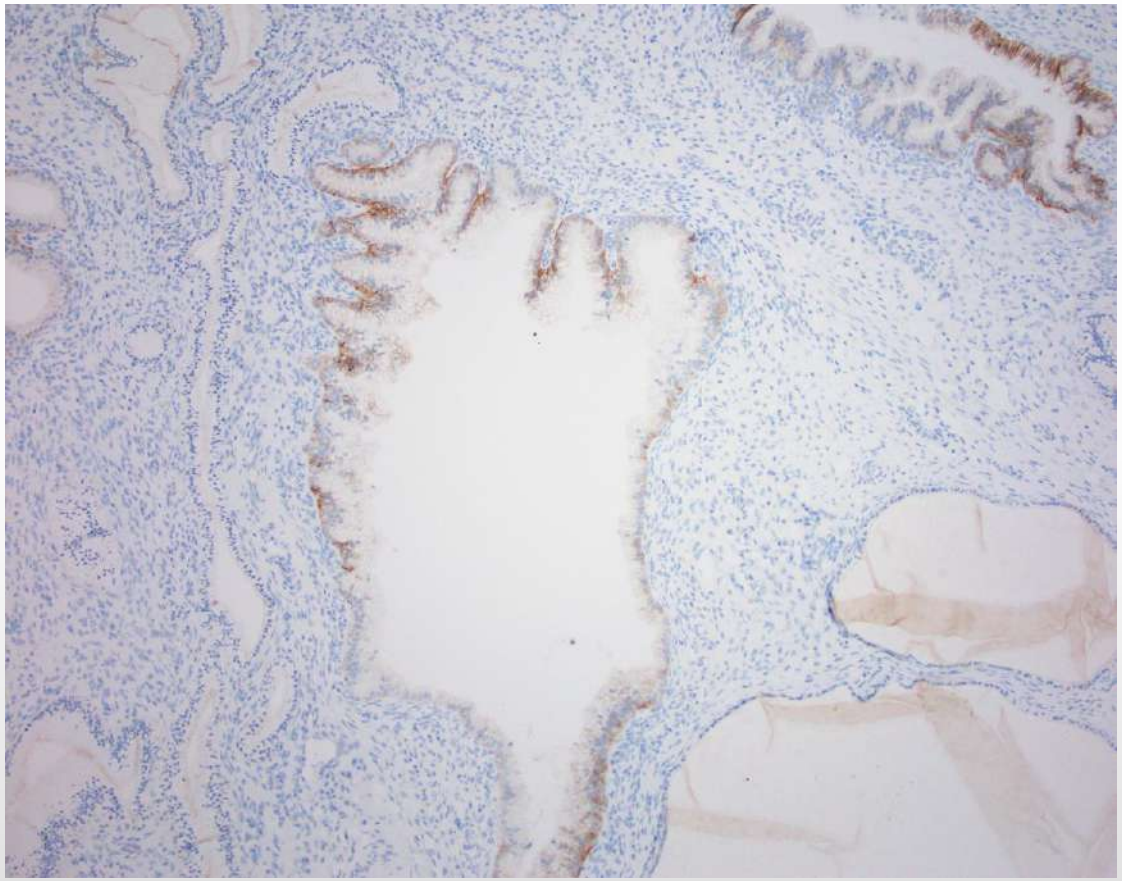

PAS-AB

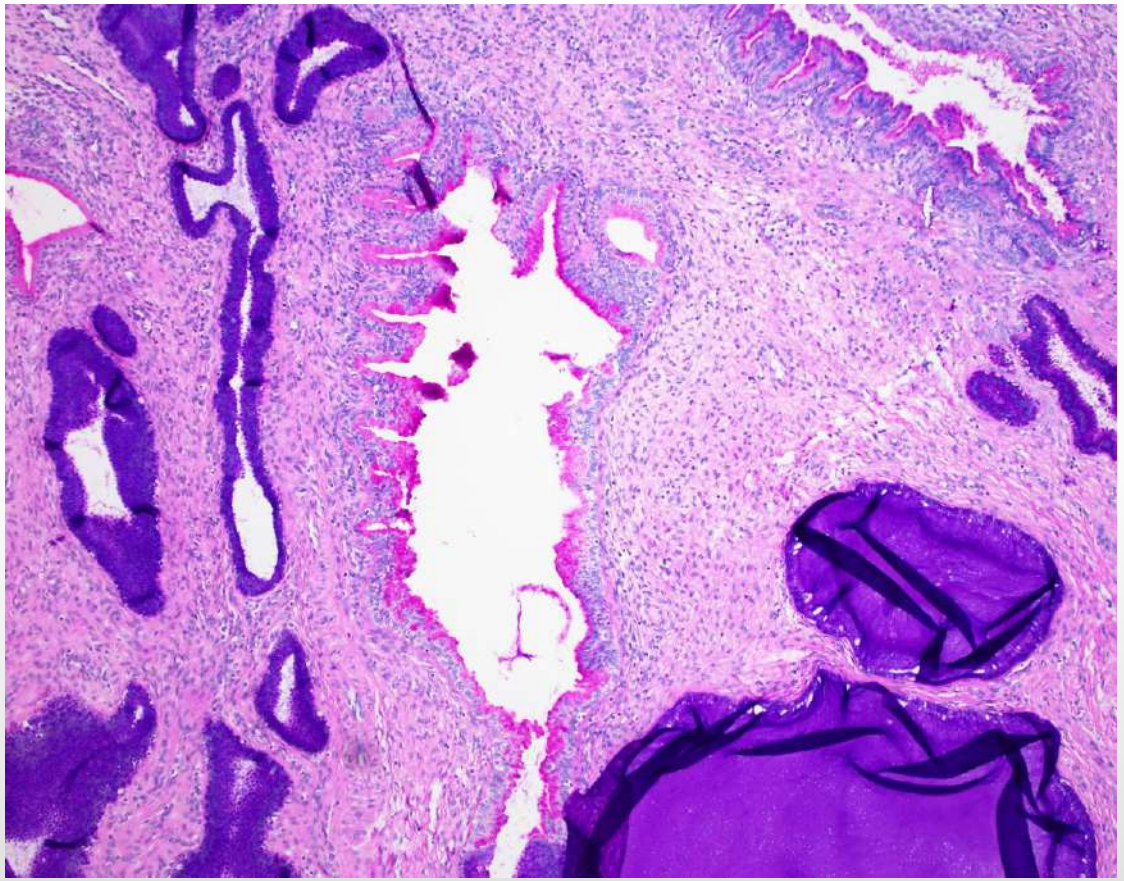

Gastric type adenocarcinoma in situ

gAIS

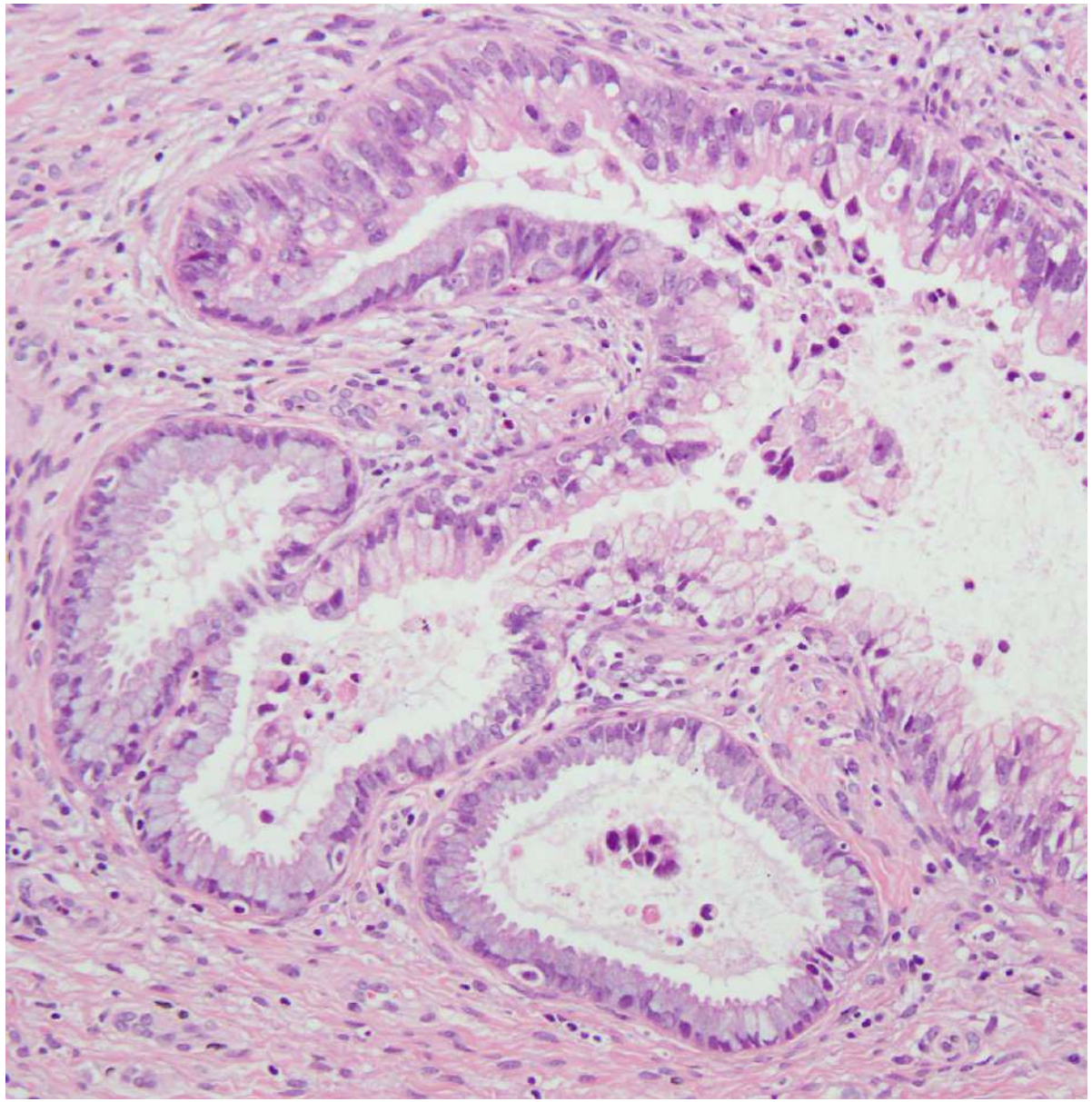

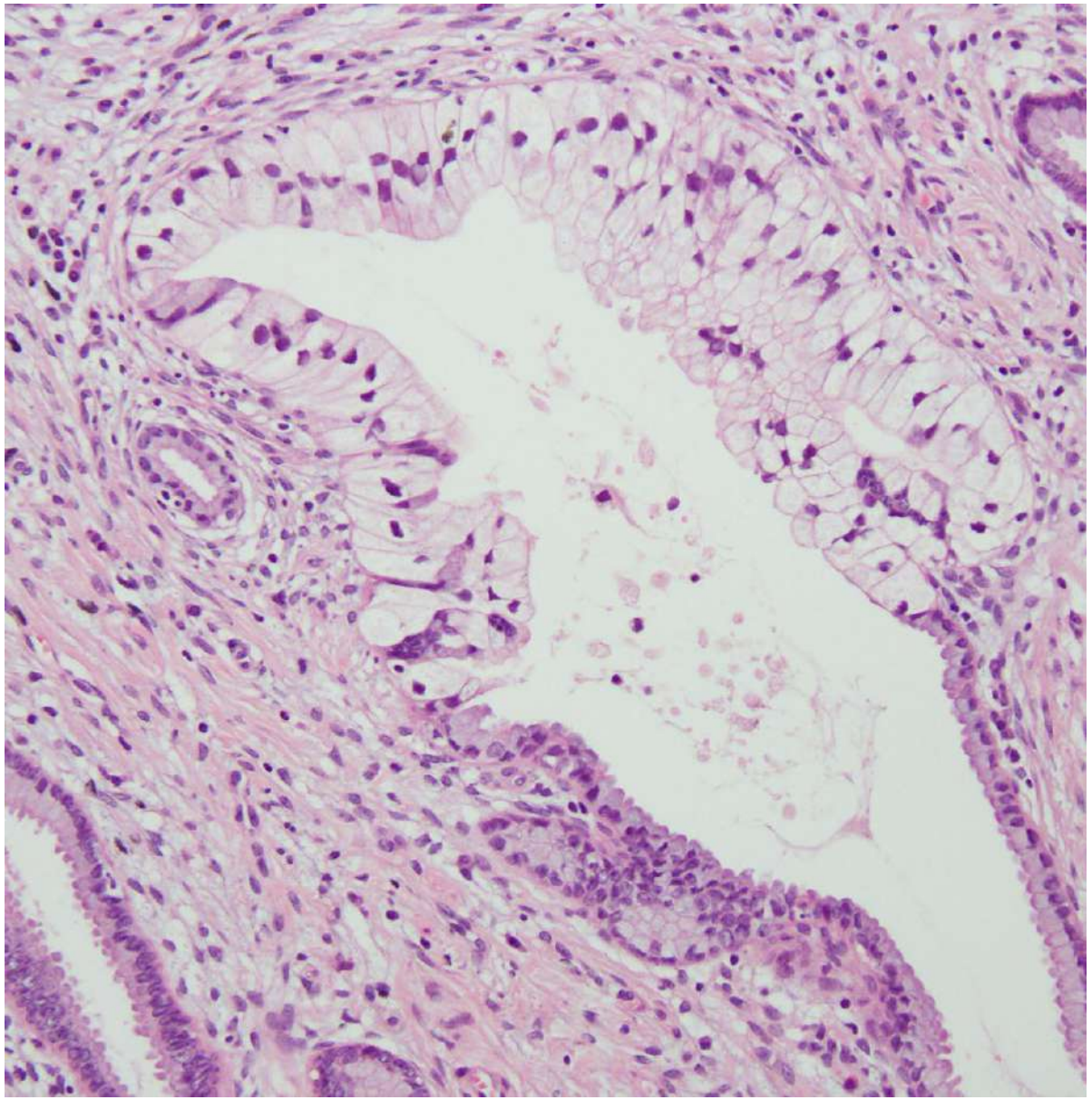

gAIS

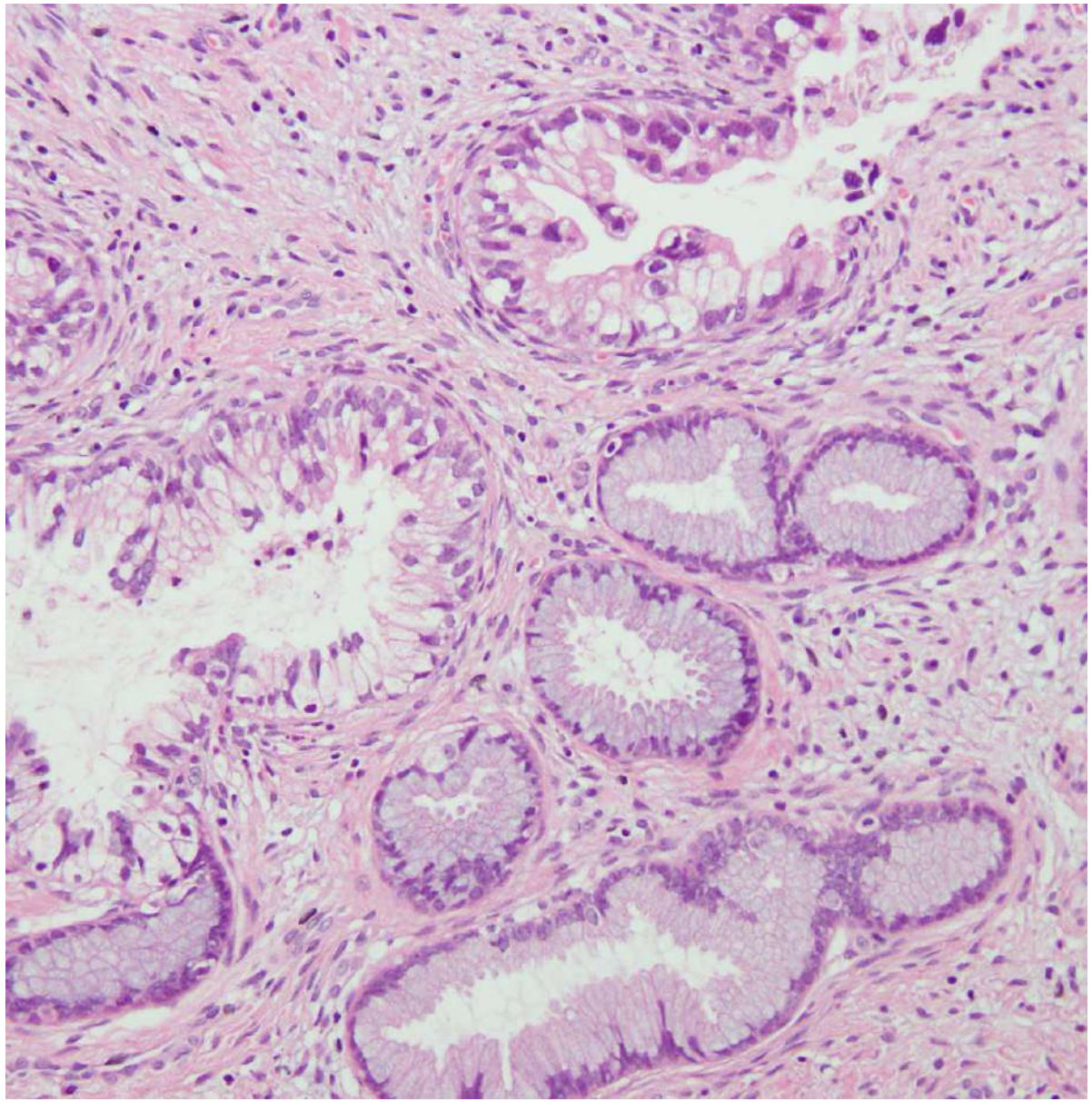

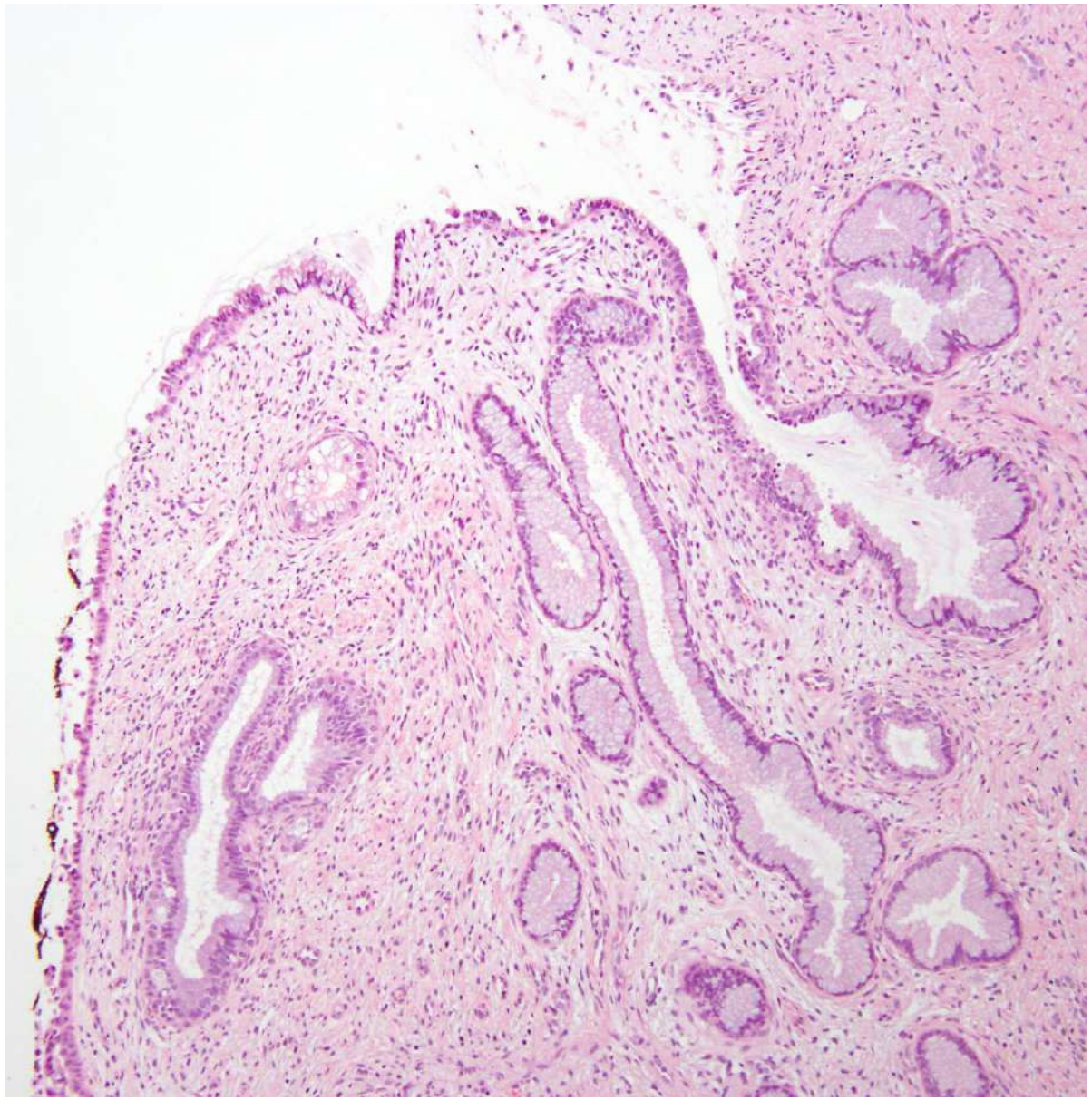

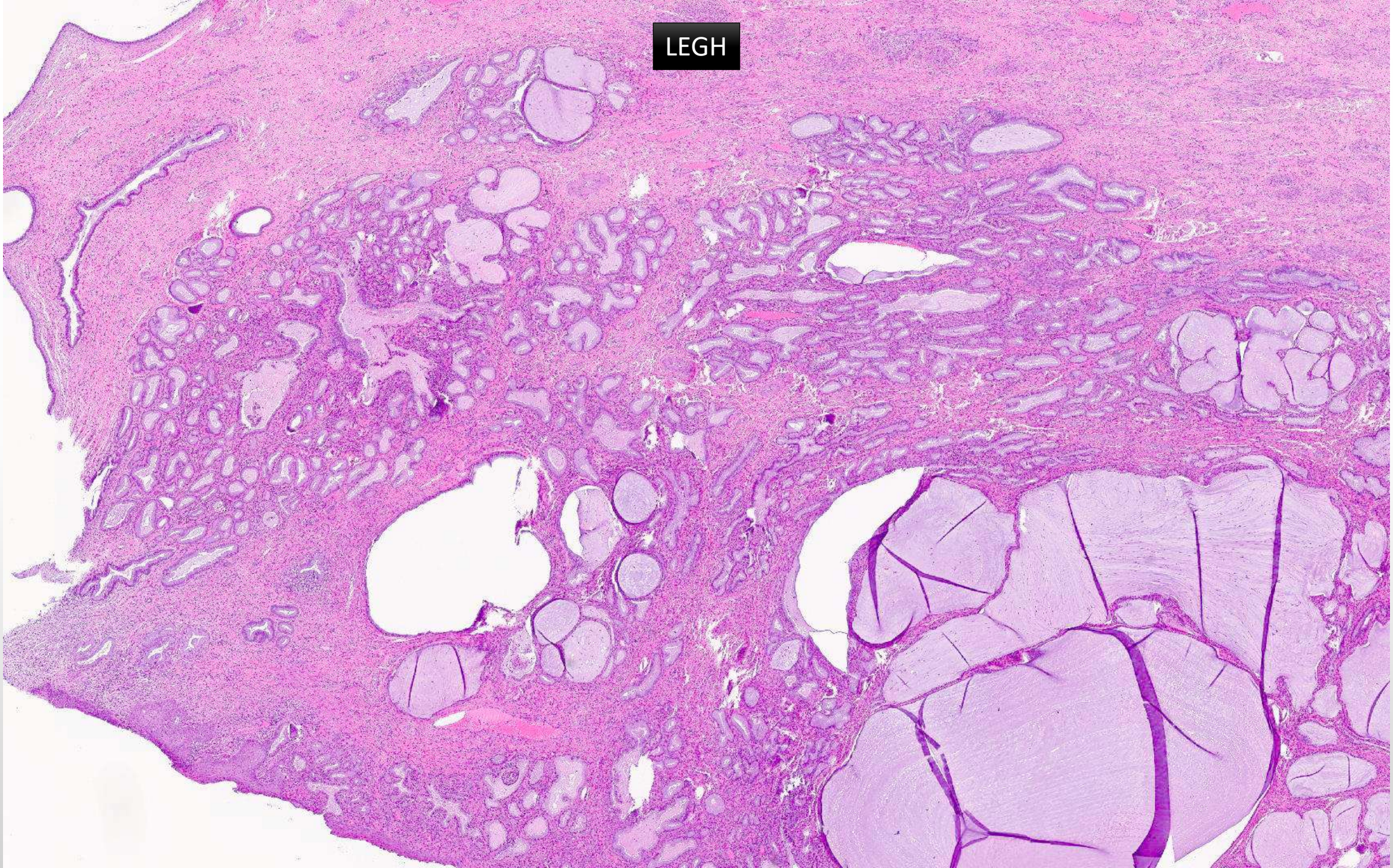
LEGH

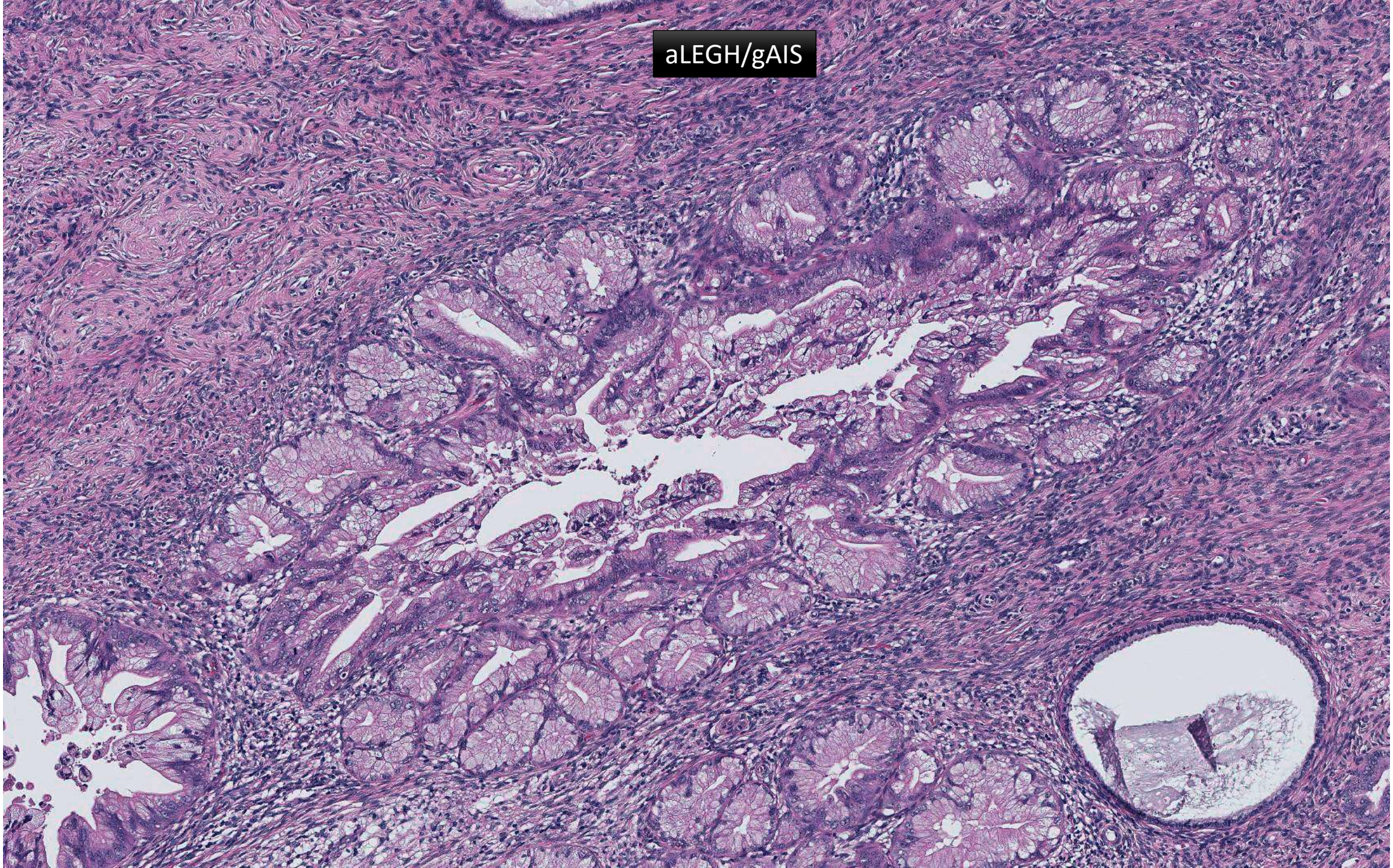
aLEGH/gAIS

Gastric type Adenocarcinoma In situ vs. Invasive

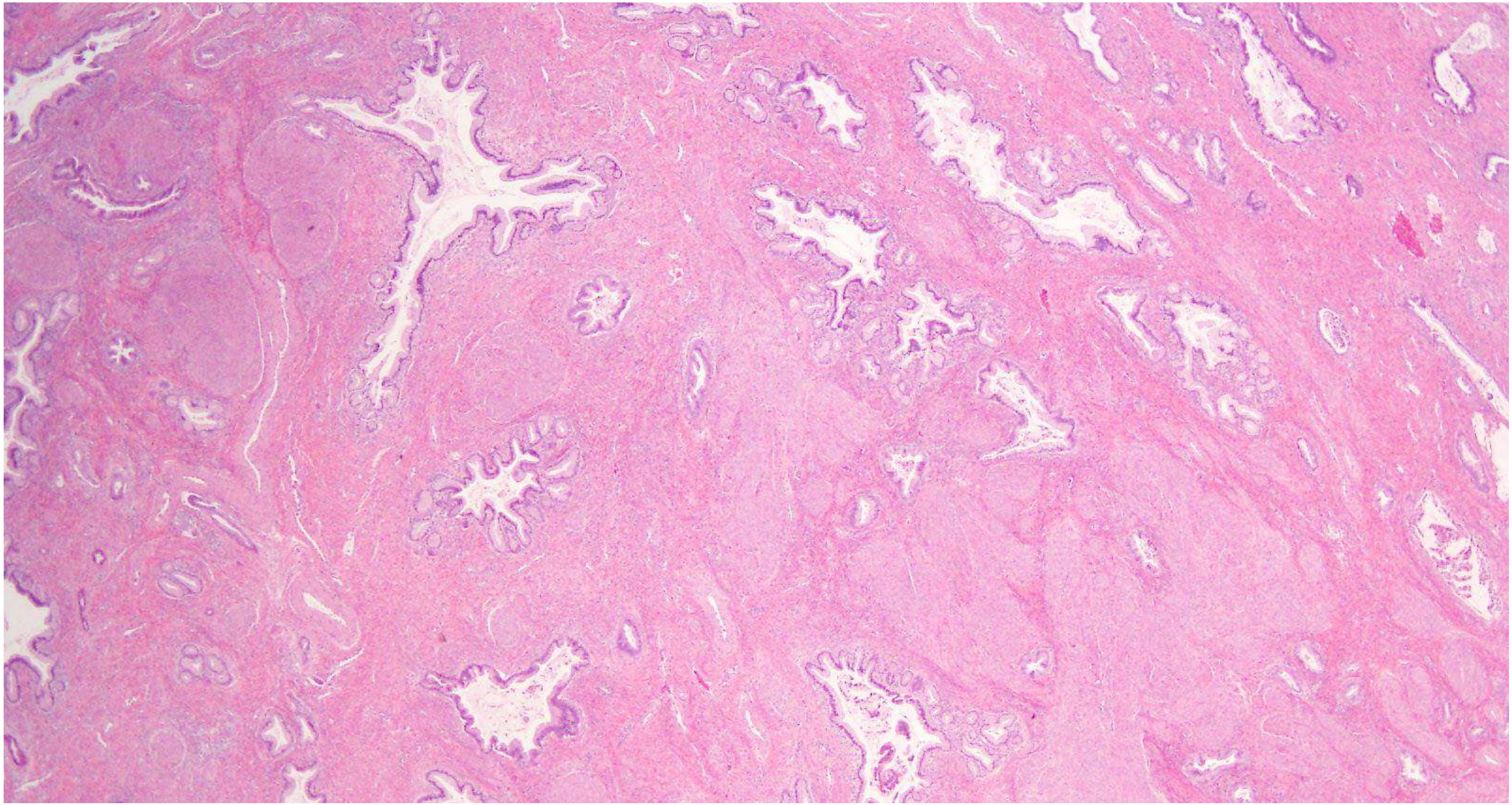

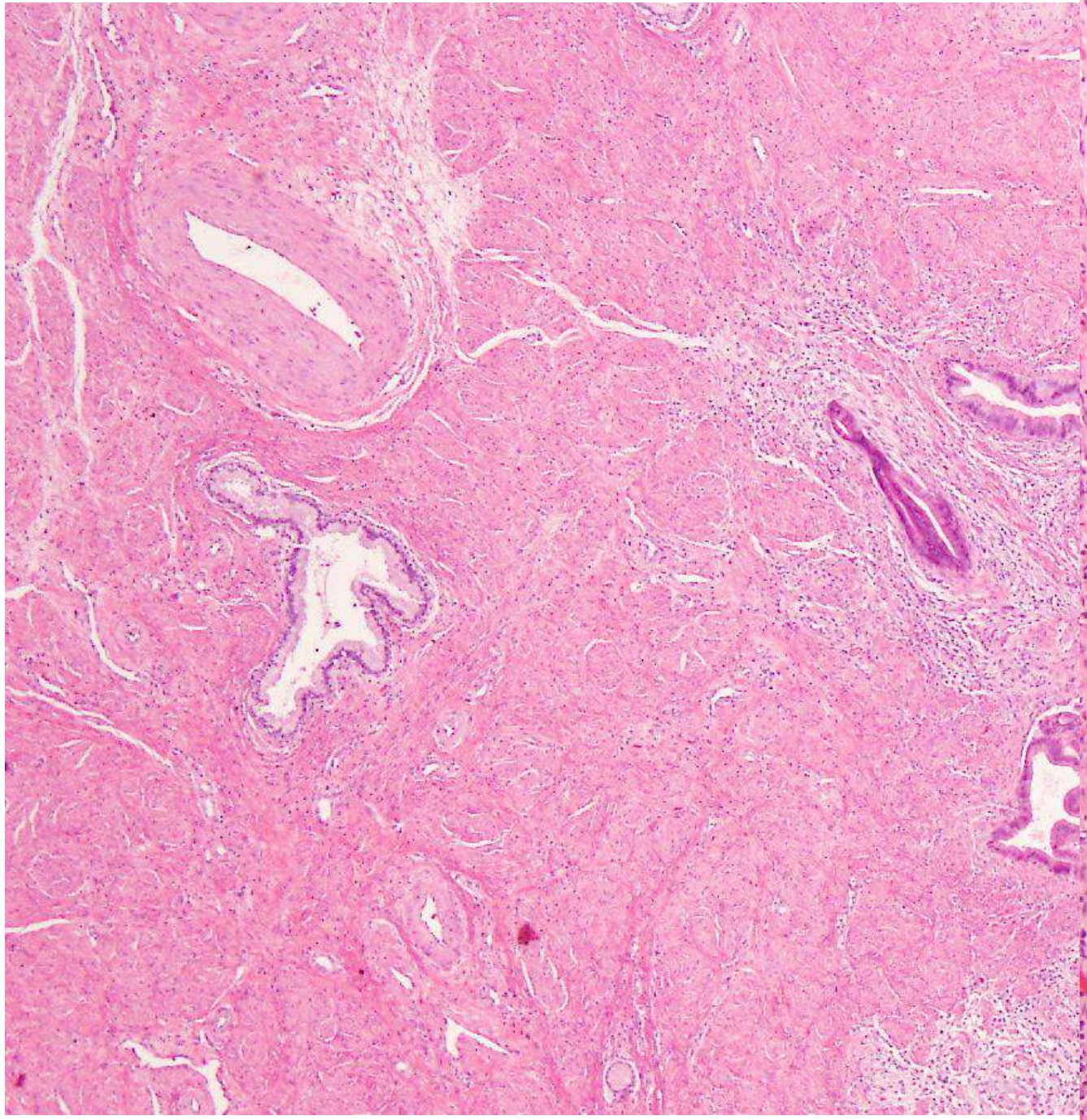

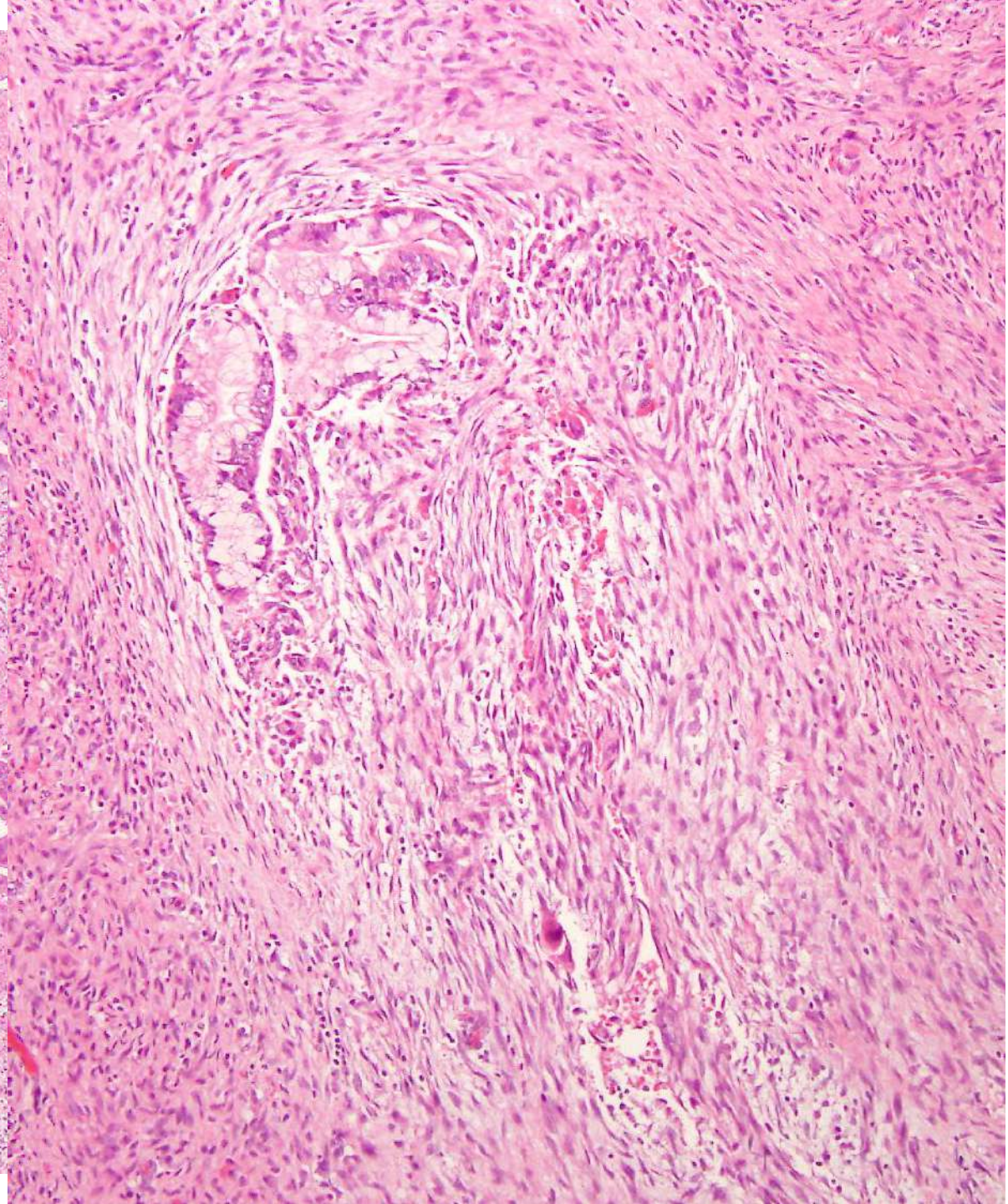

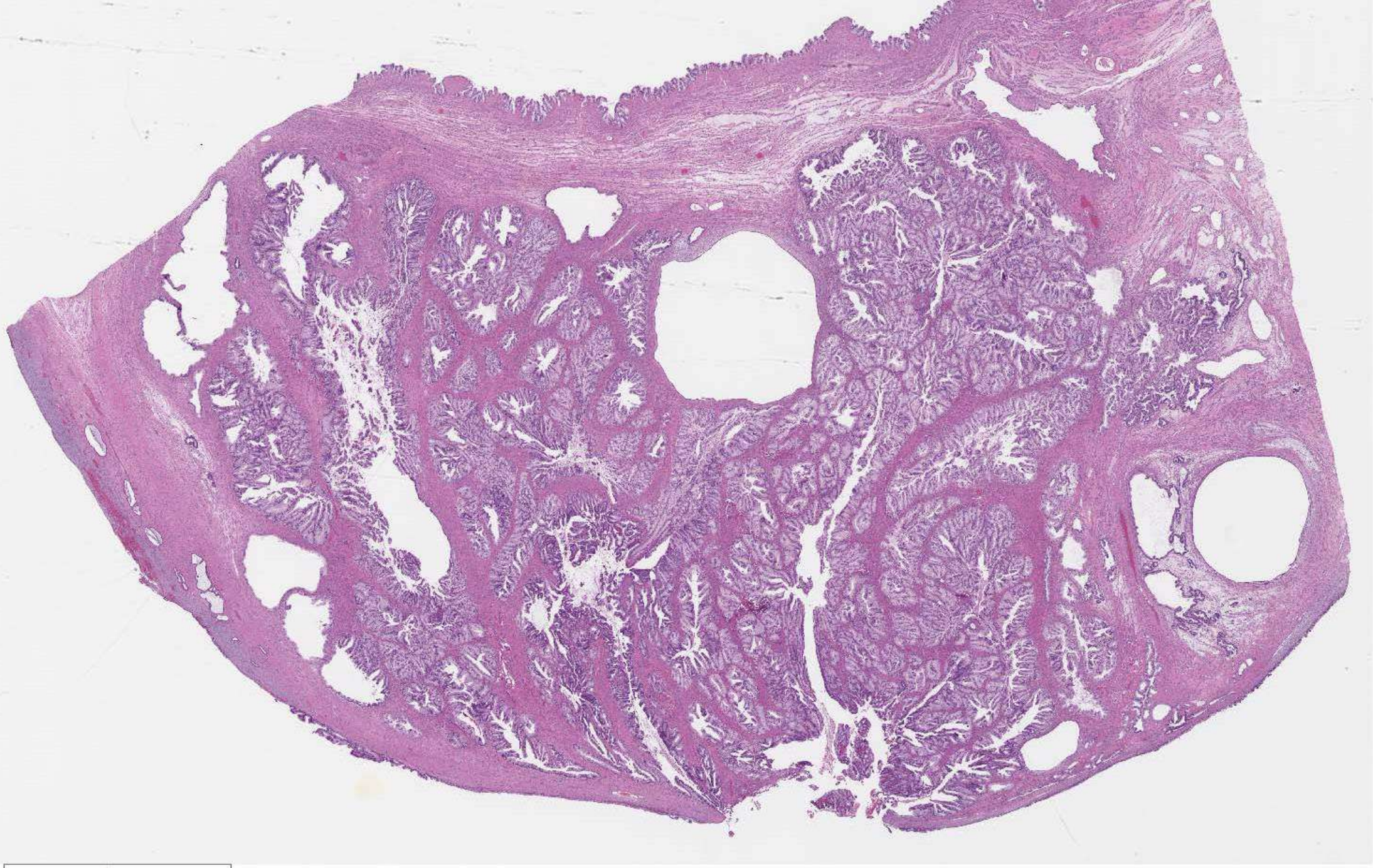
4mm

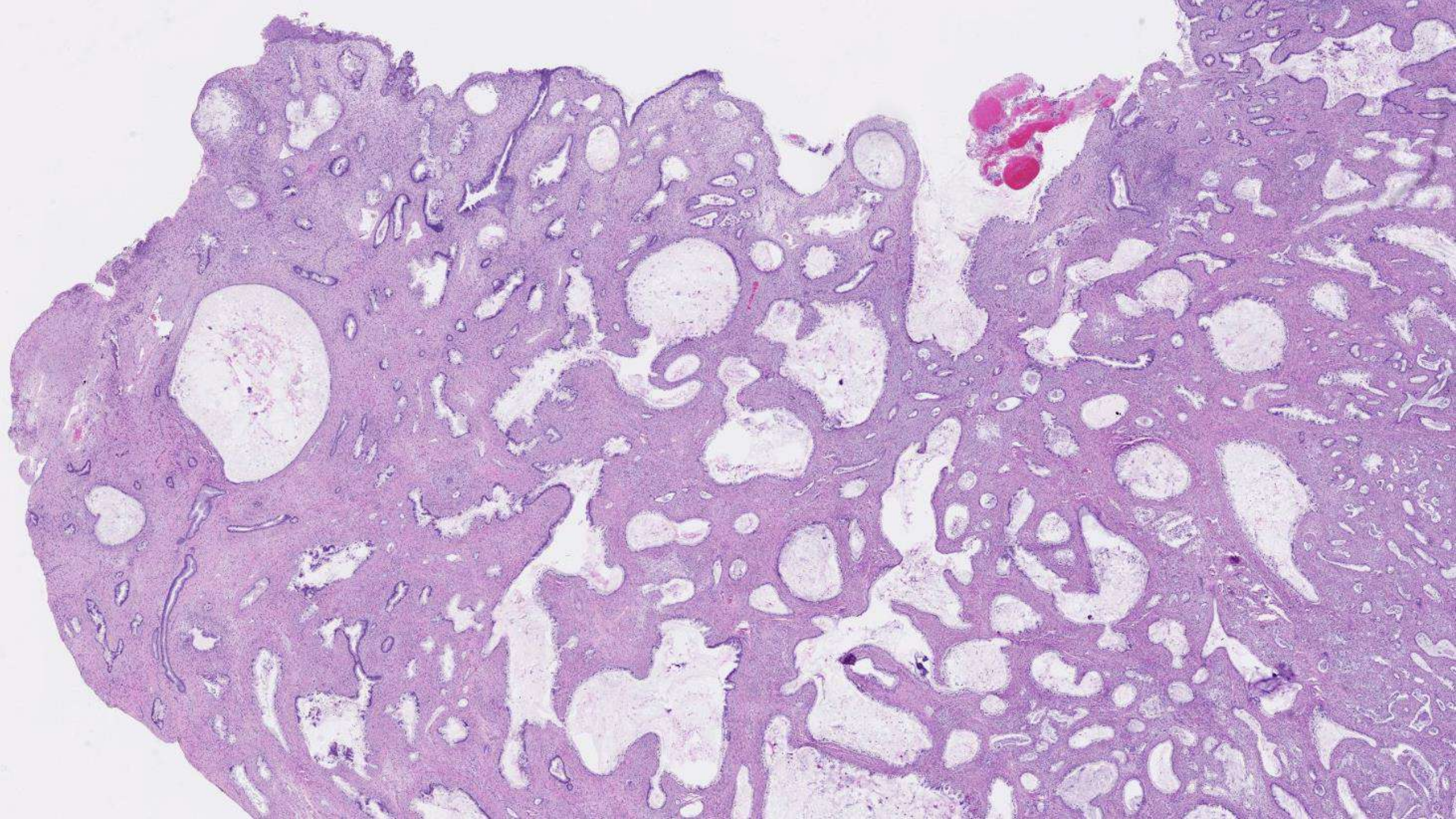

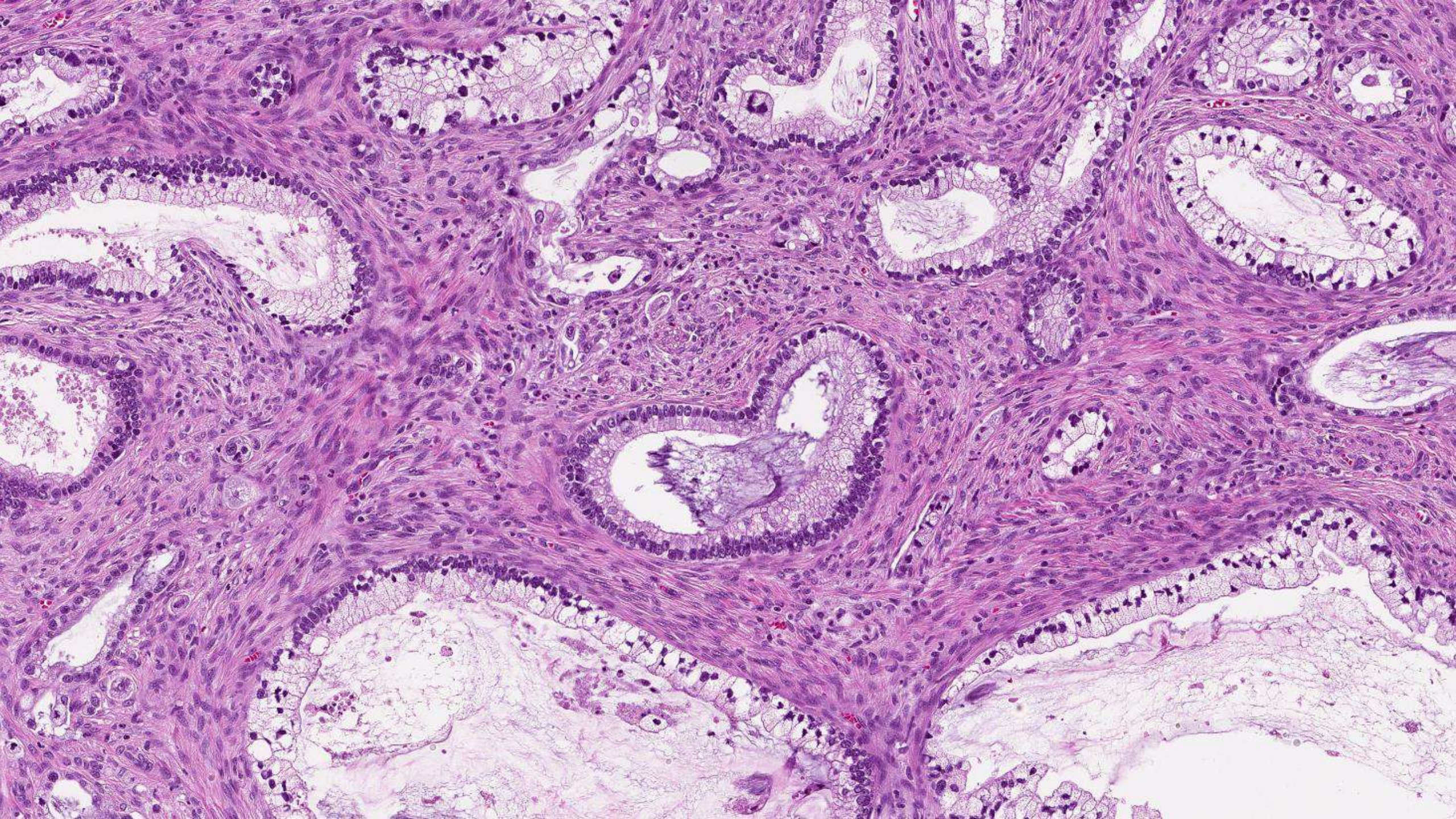

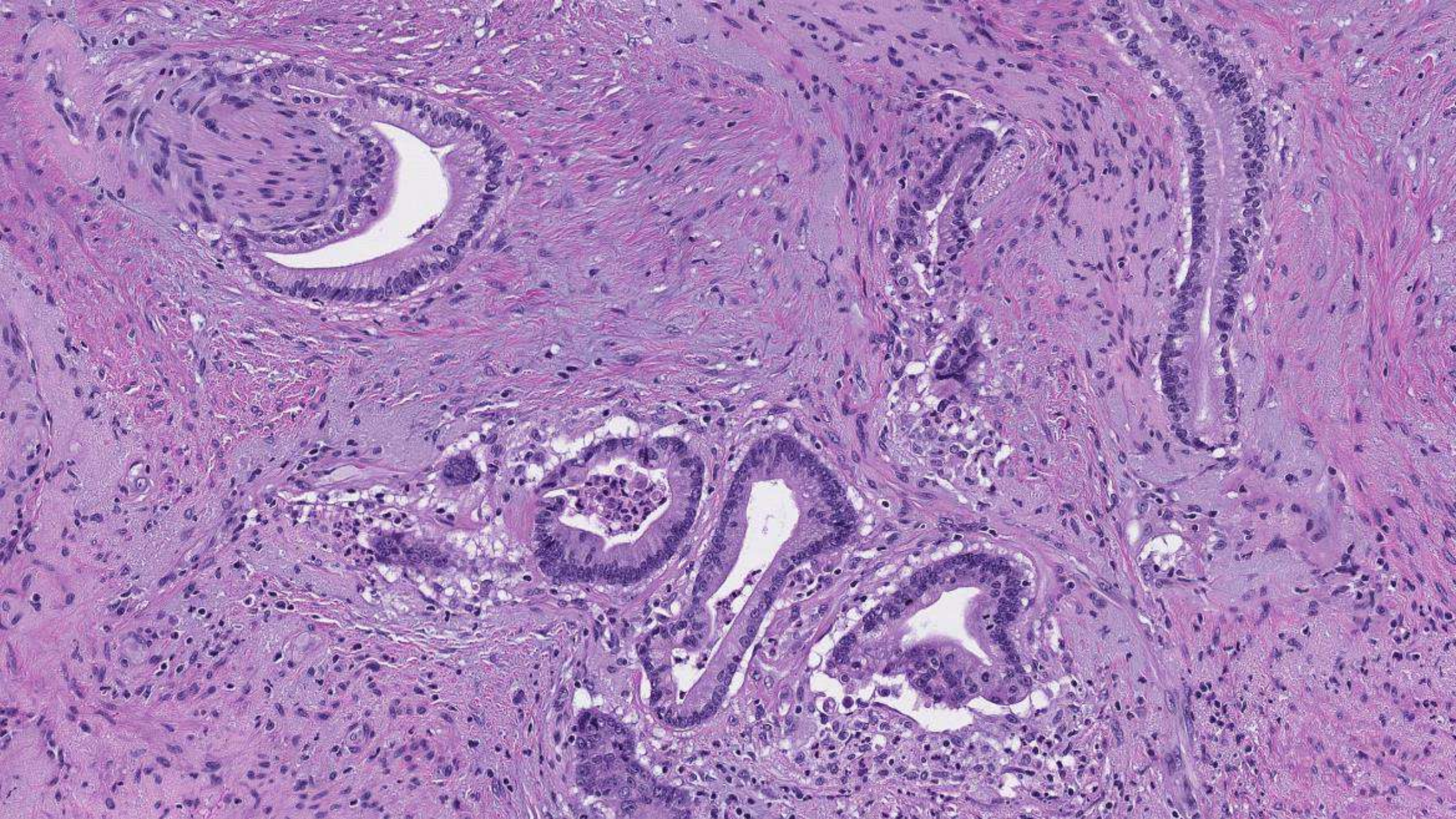

Ancillary studies

- No IHC to distinguish in situ from invasive
- At least focal stromal desmoplasia with invasion, single cells, clusters
- Deep infiltration with irregularly shaped glands
- Gland proliferation beyond pre-existing normal glands
- Remember to extensively sample the cervix!

Pattern Classification

AIS vs. Pattern A

Pattern A vs. Pattern B

Pattern B vs. Pattern C

Pattern A vs. Pattern C

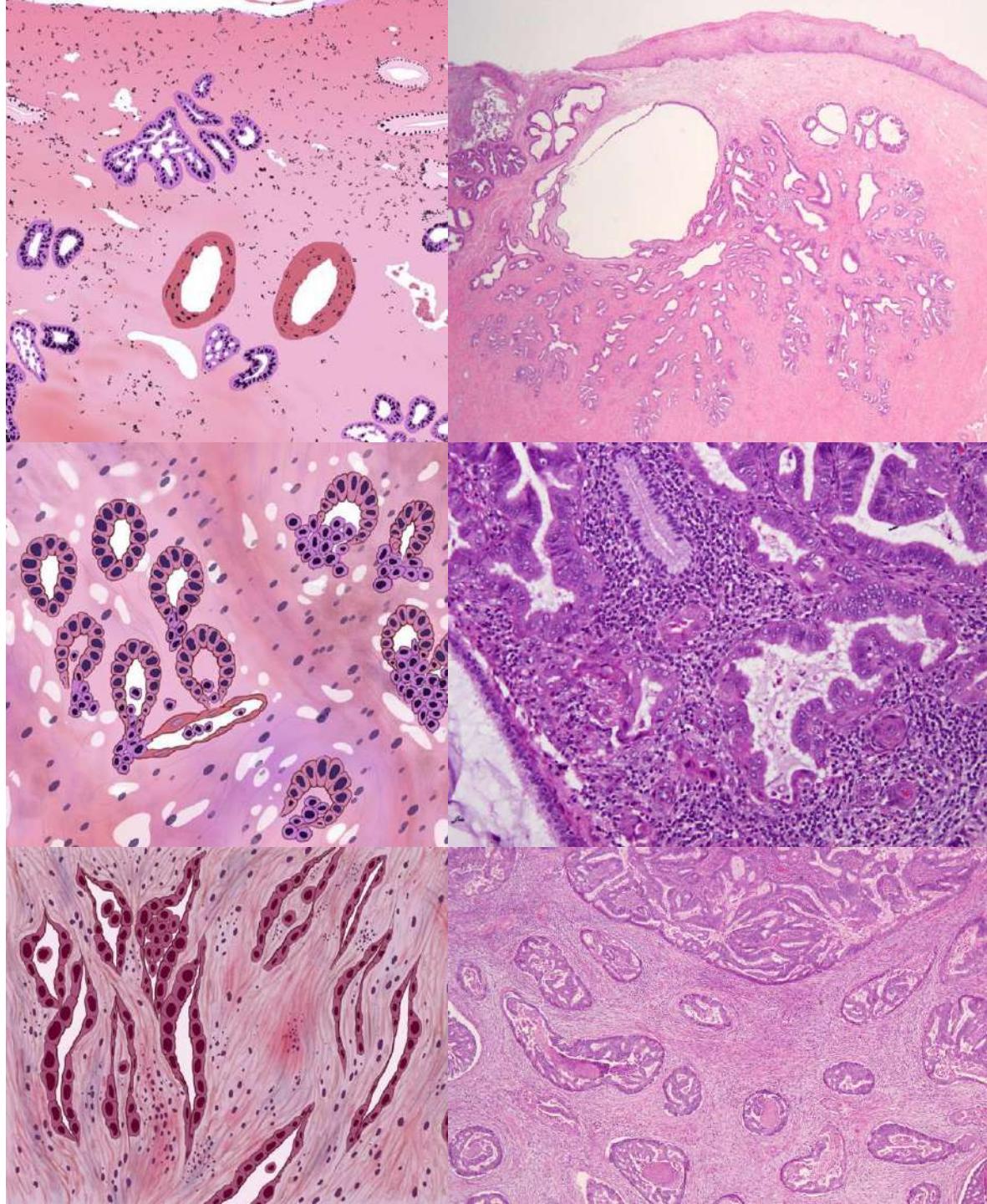

Why is Pattern Classification Important?

What is the clinical application?

Early stage carcinoma only

- Stage IA1, IA2, IB1
- Original study was all about the lymph nodes

All about the lymph nodes

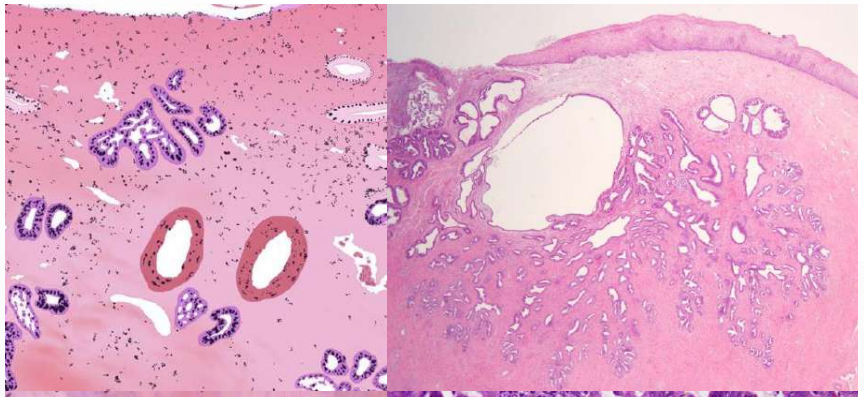

Pattern A

0% lymph node metastases

0% recurrence

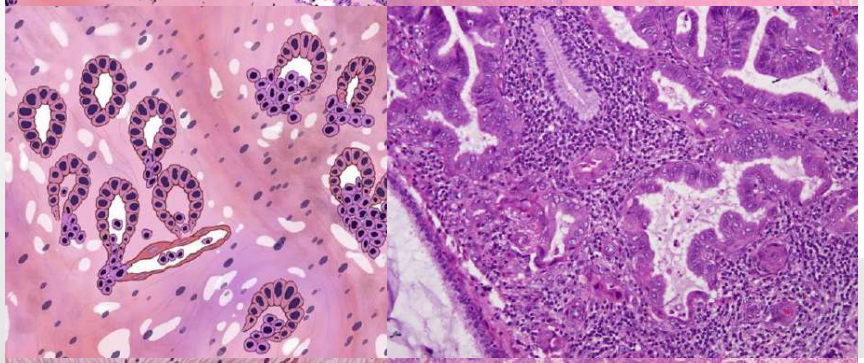

Pattern B

8% with lymph node metastases

2% recurrence

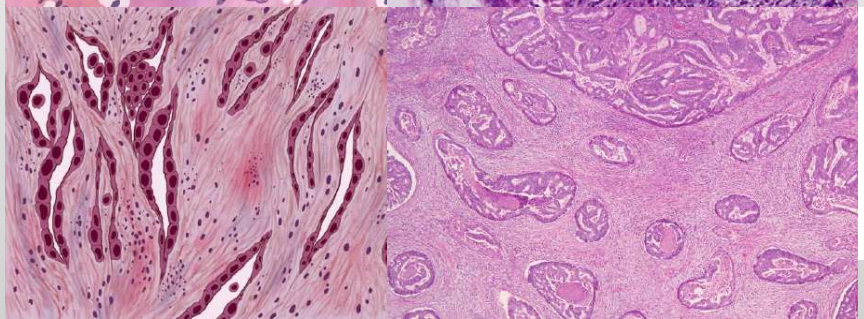

Pattern C

24% lymph node metastases

21% recurrence

Early stage carcinoma only

- Stage IA1, IA2, IB1
- Original study was all about the lymph nodes
- In early stage UEA:
  - Pattern A and pattern B without LVI have similar excellent overall and recurrence free survival
  - IB1 Pattern B with LVI has similar OS as Pattern C

Good prognosis
Pattern A
Pattern B without LVI

Bad (worse) prognosis
IB1 Pattern B with LVI
Pattern C

Clinical correlation of lymphovascular invasion and Silva pattern of invasion in early-stage endocervical adenocarcinoma: proposed binary Silva classification system PMID: 35501168

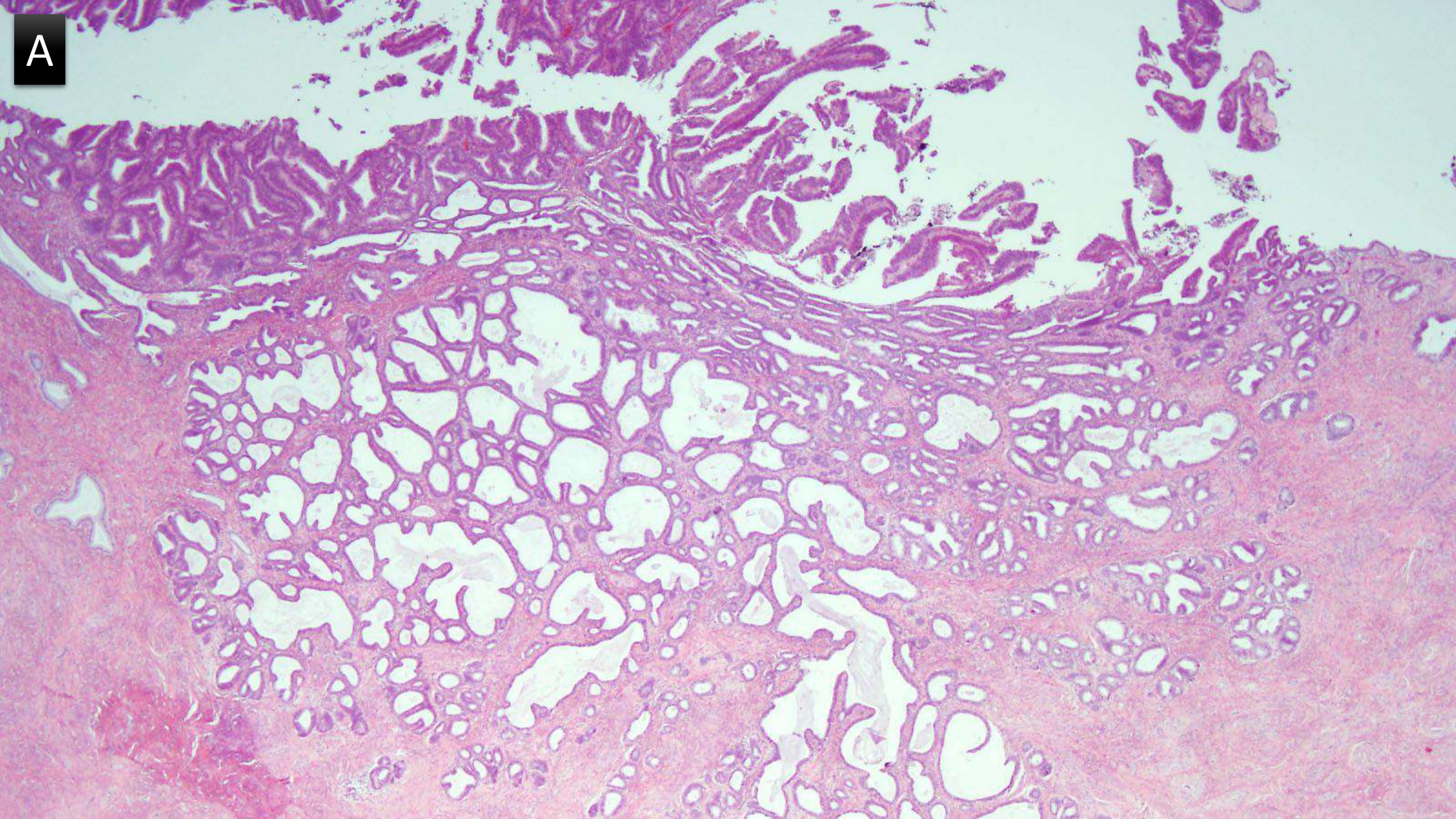
A

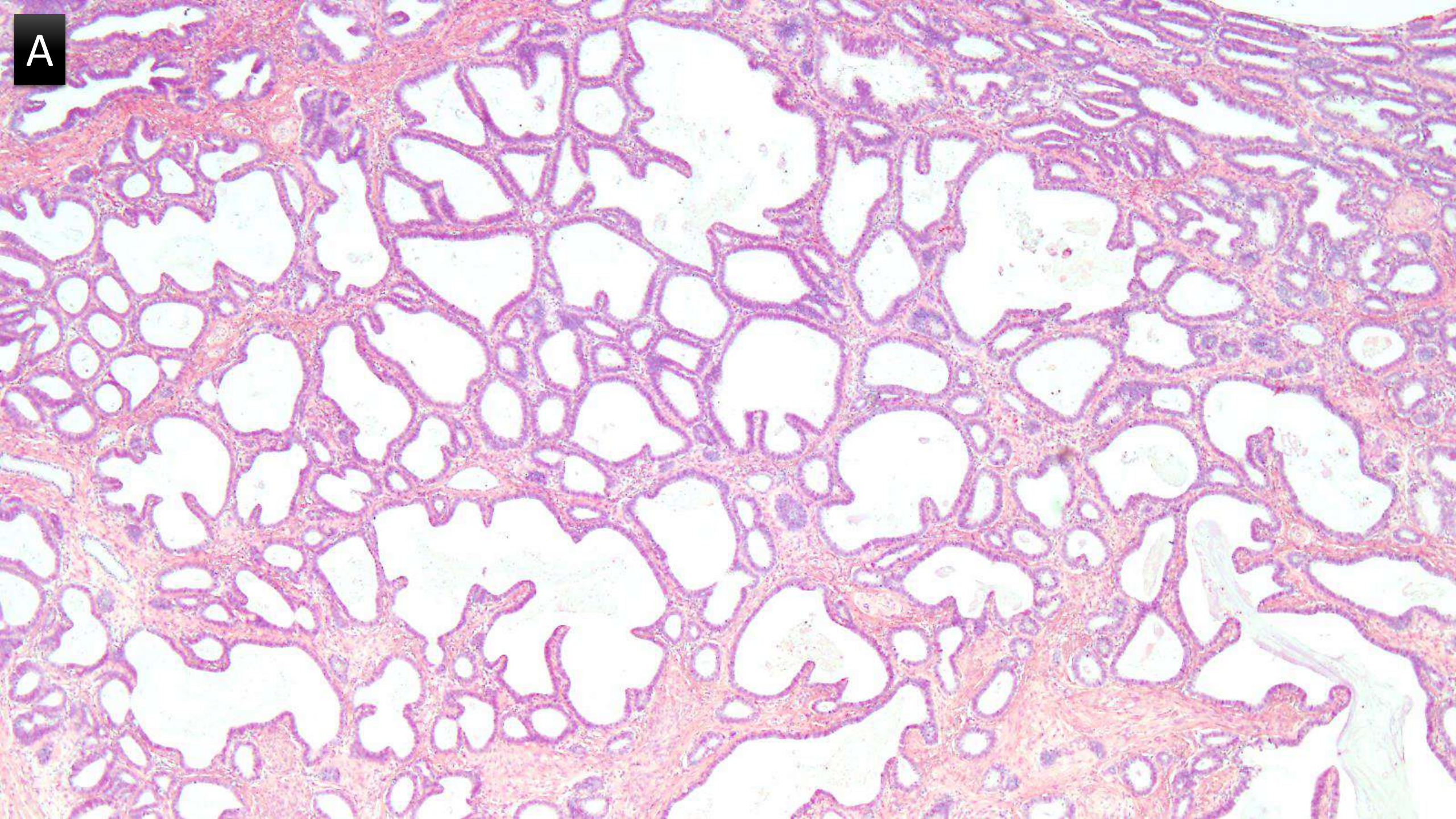
A

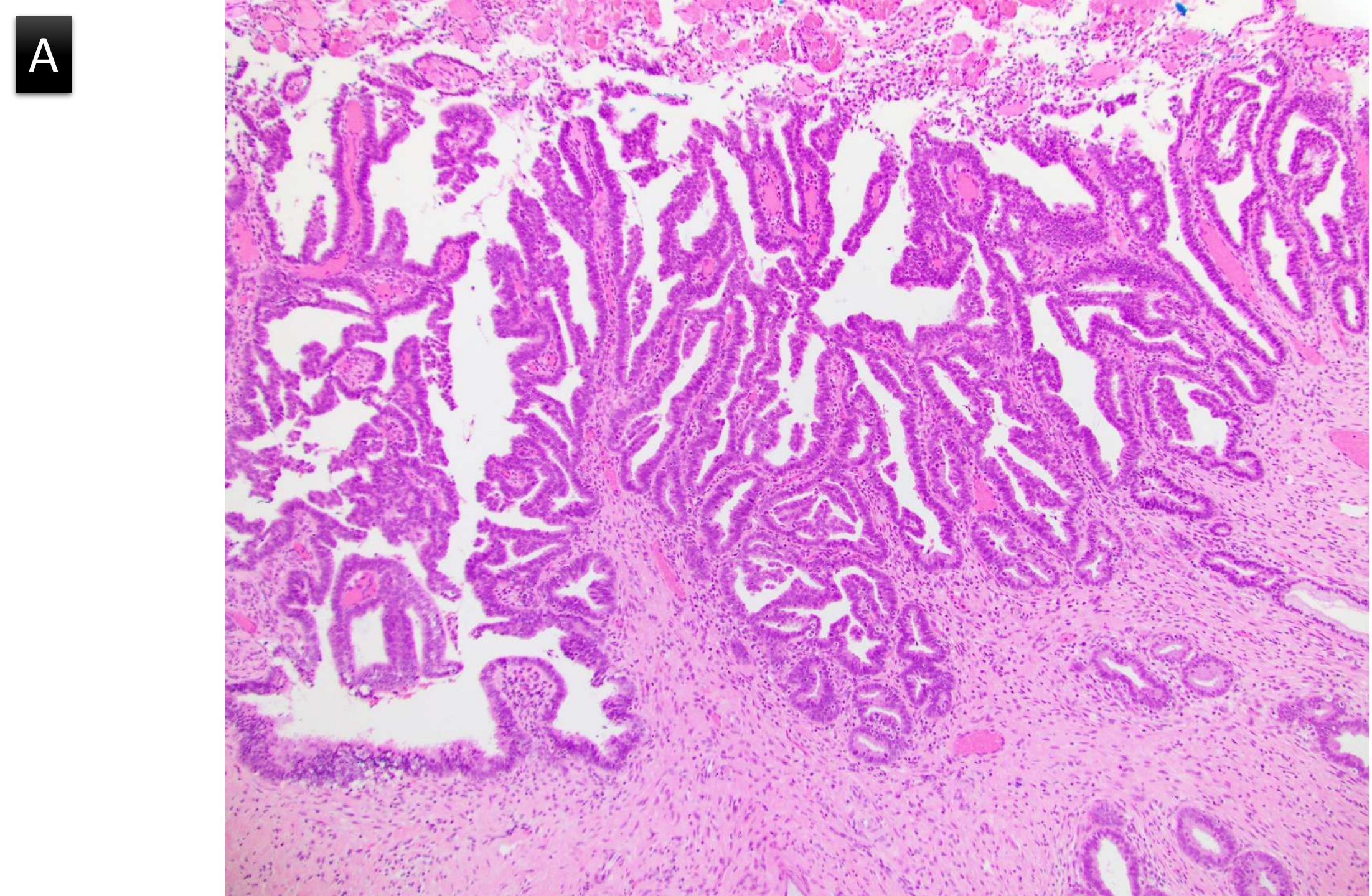
A

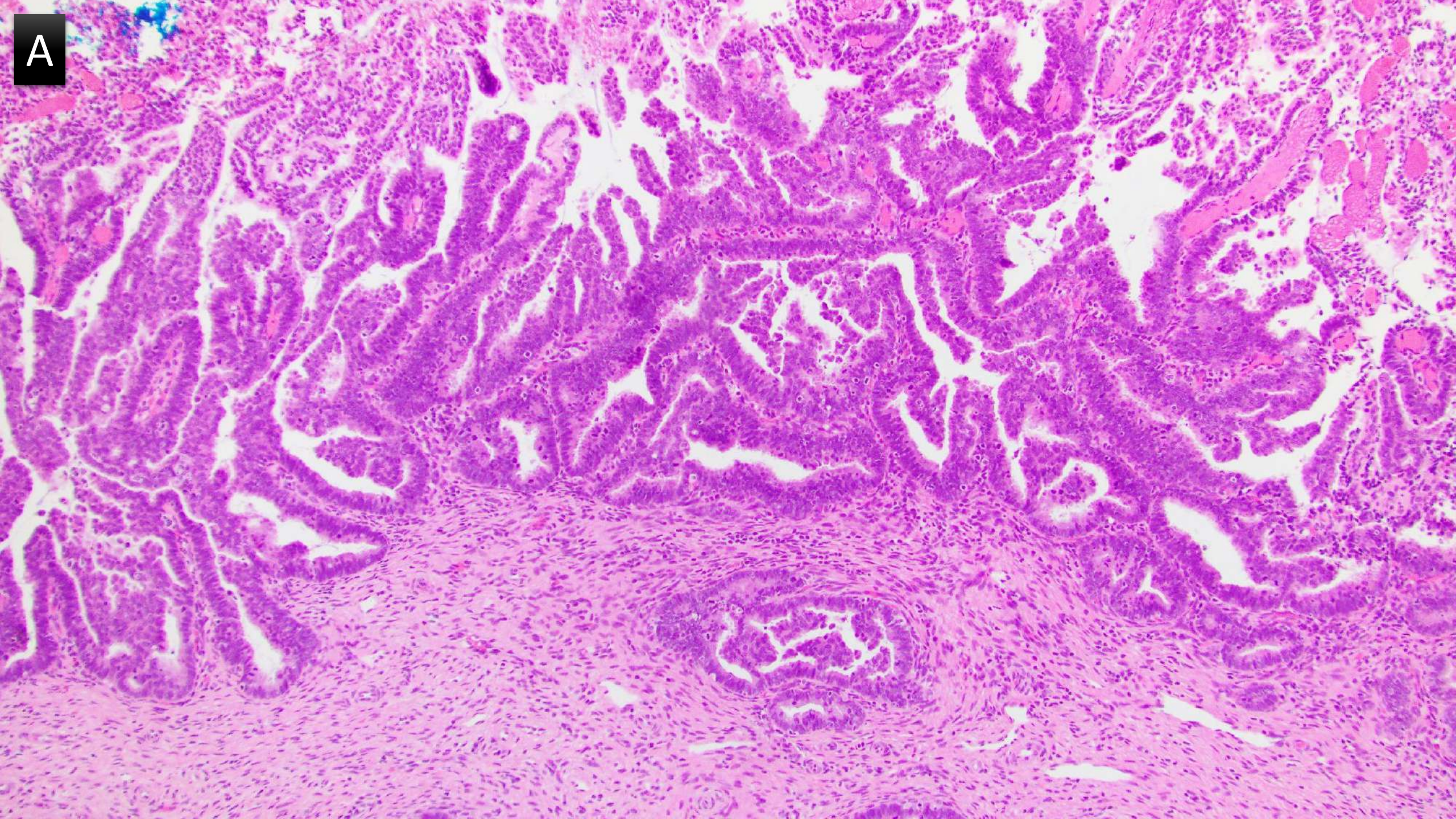
A

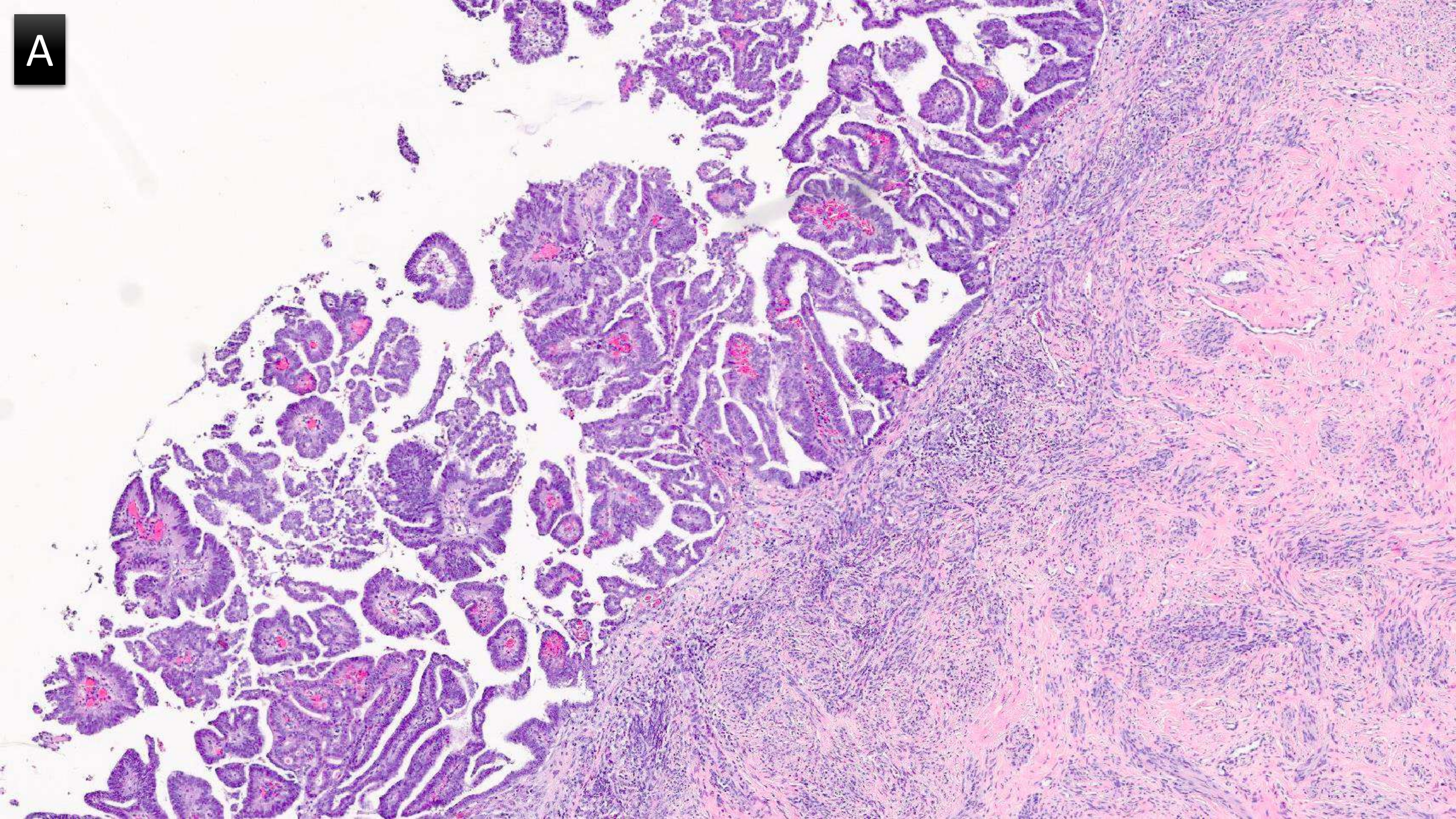
A

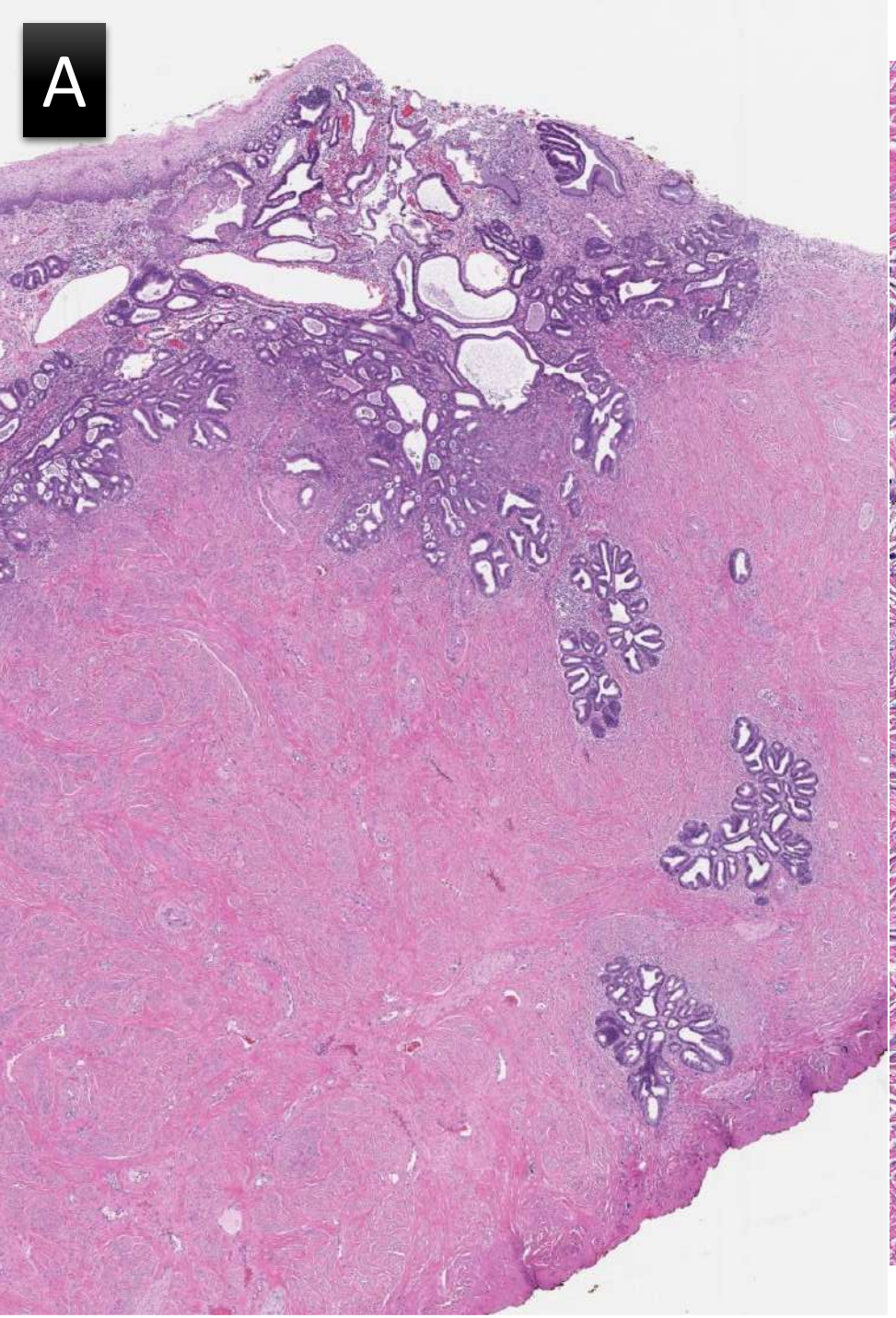
A

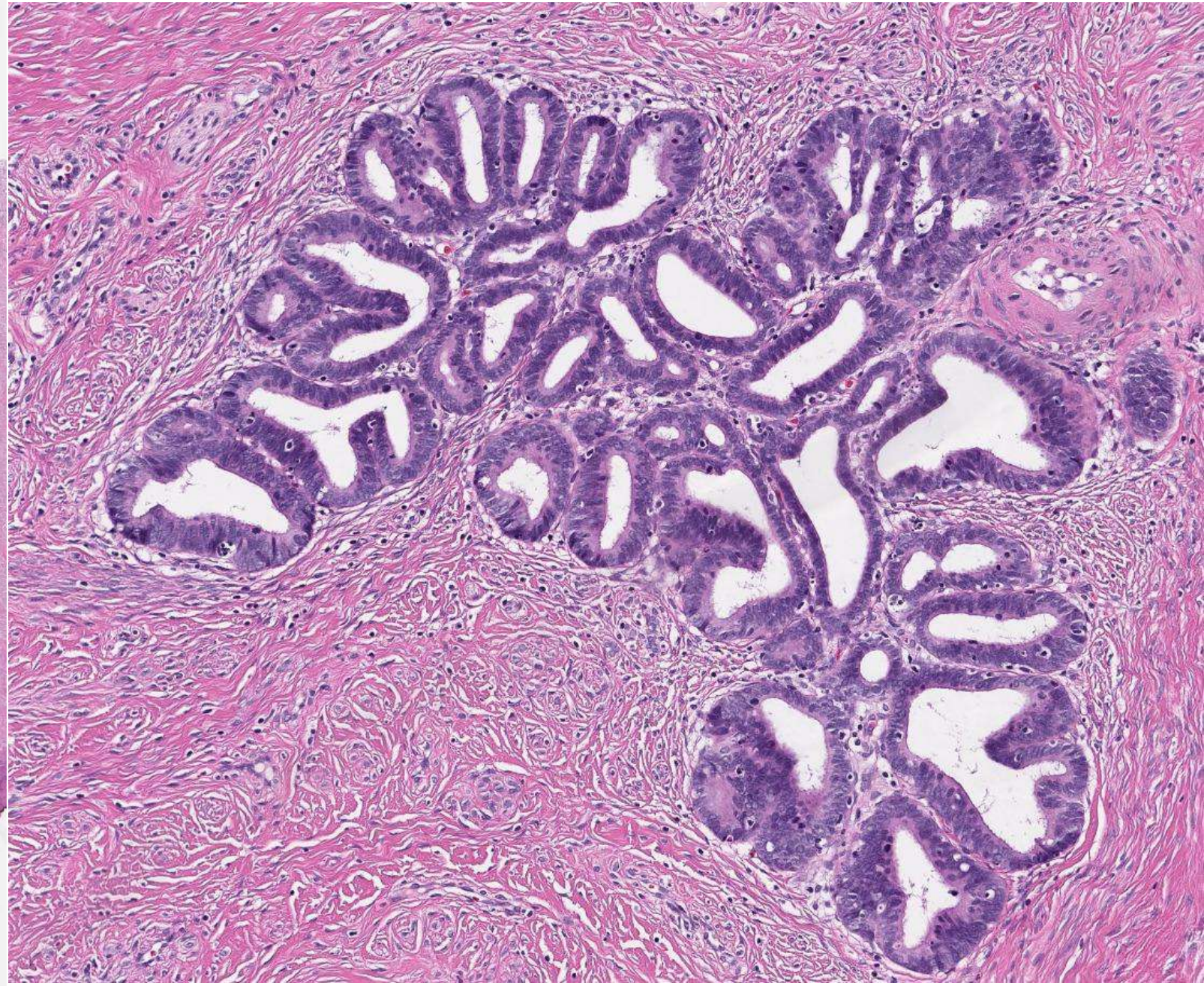

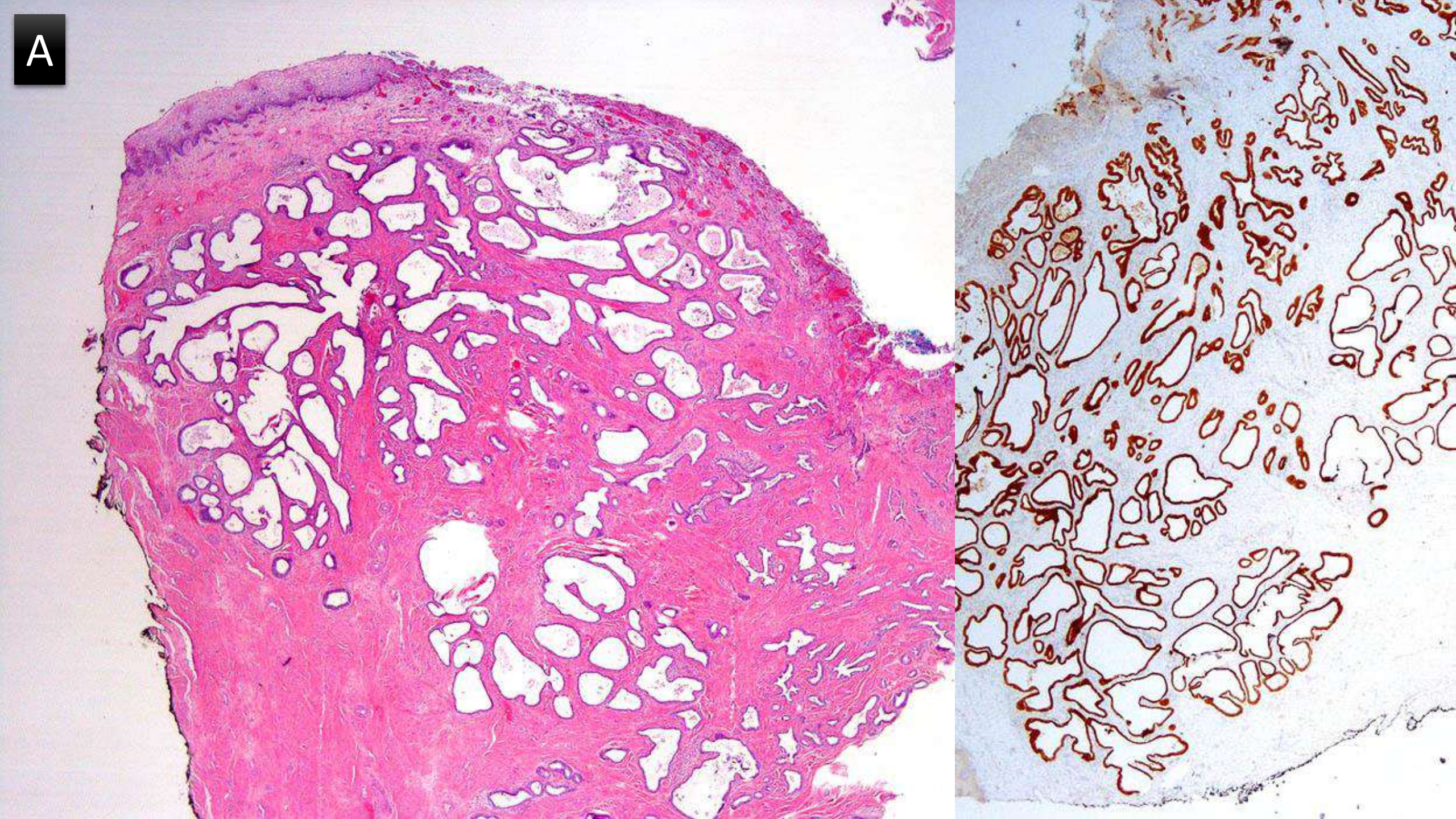
A

A (or AIS?)

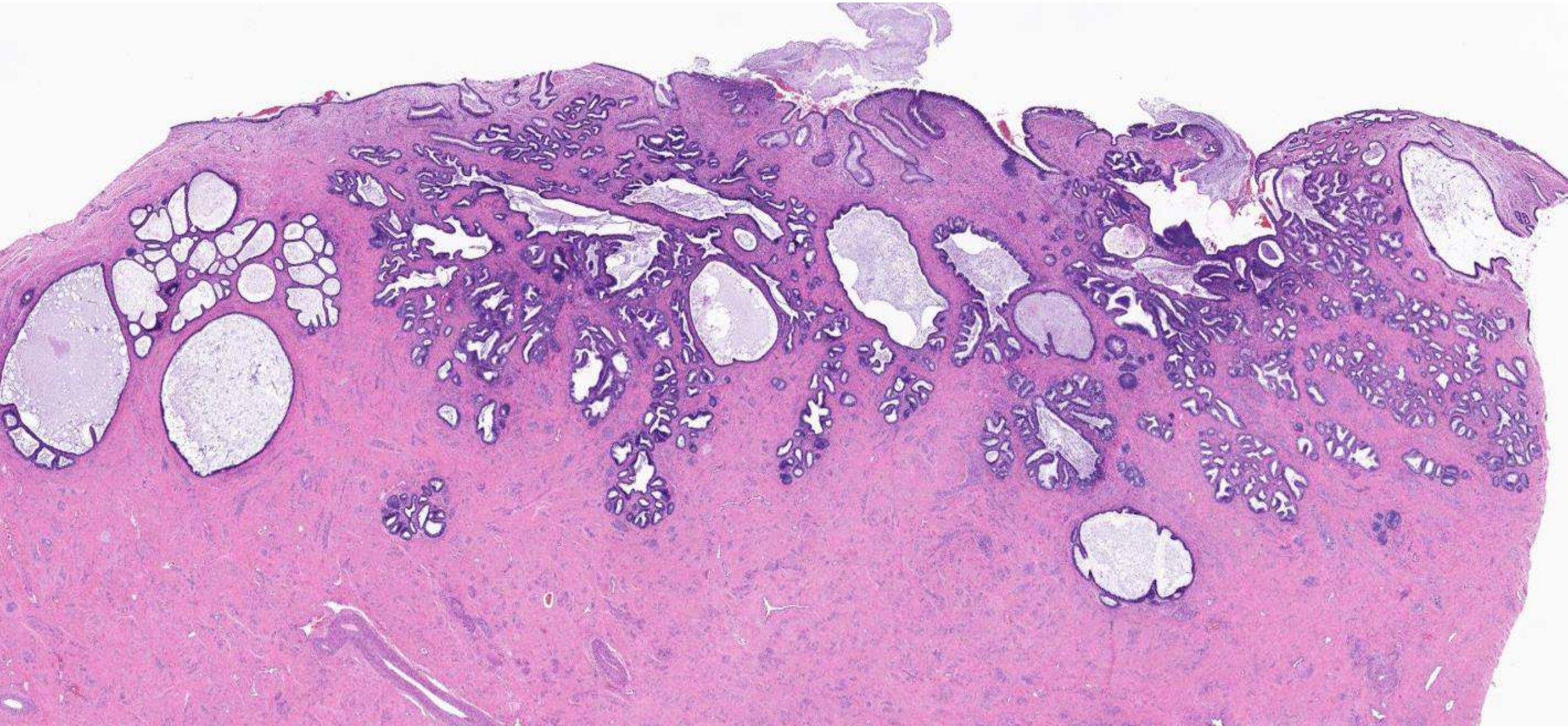

A

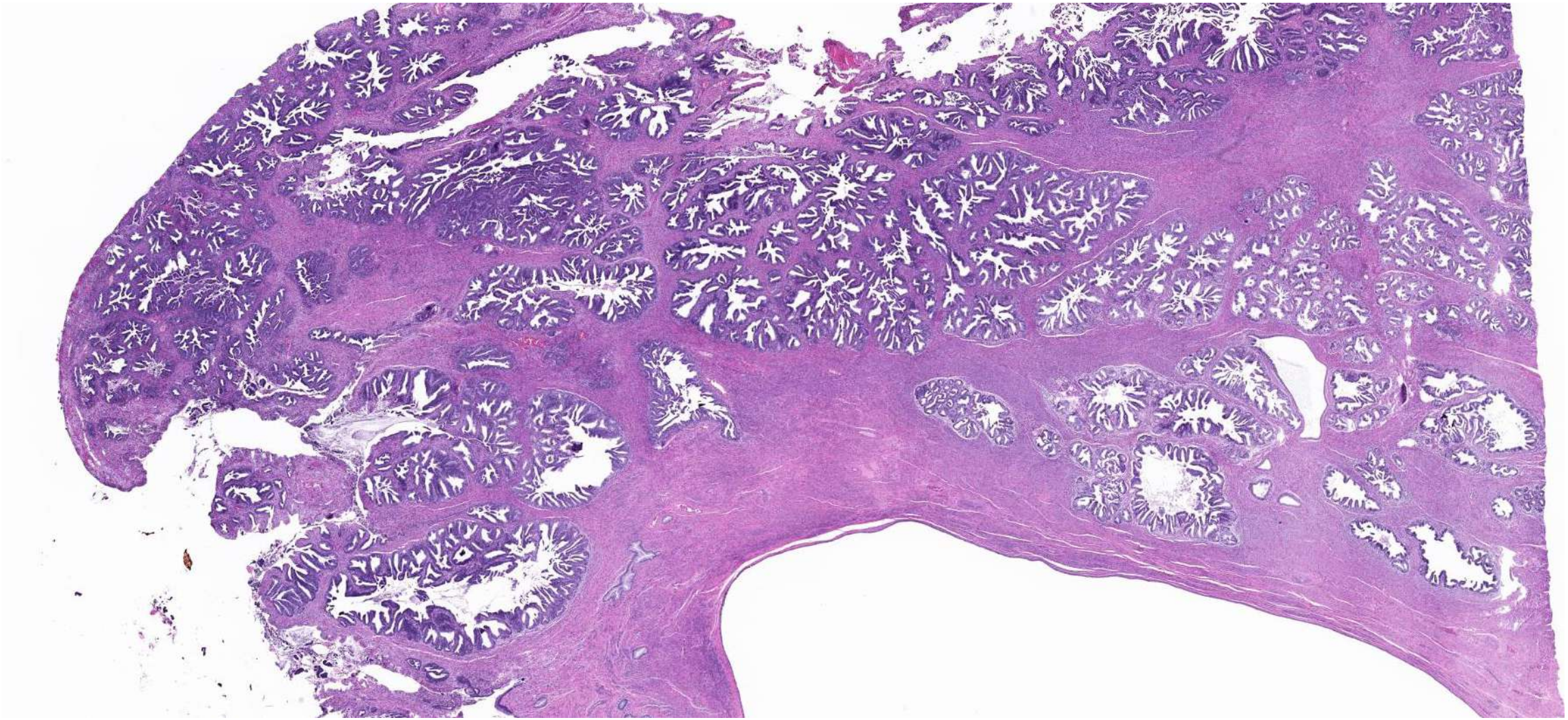

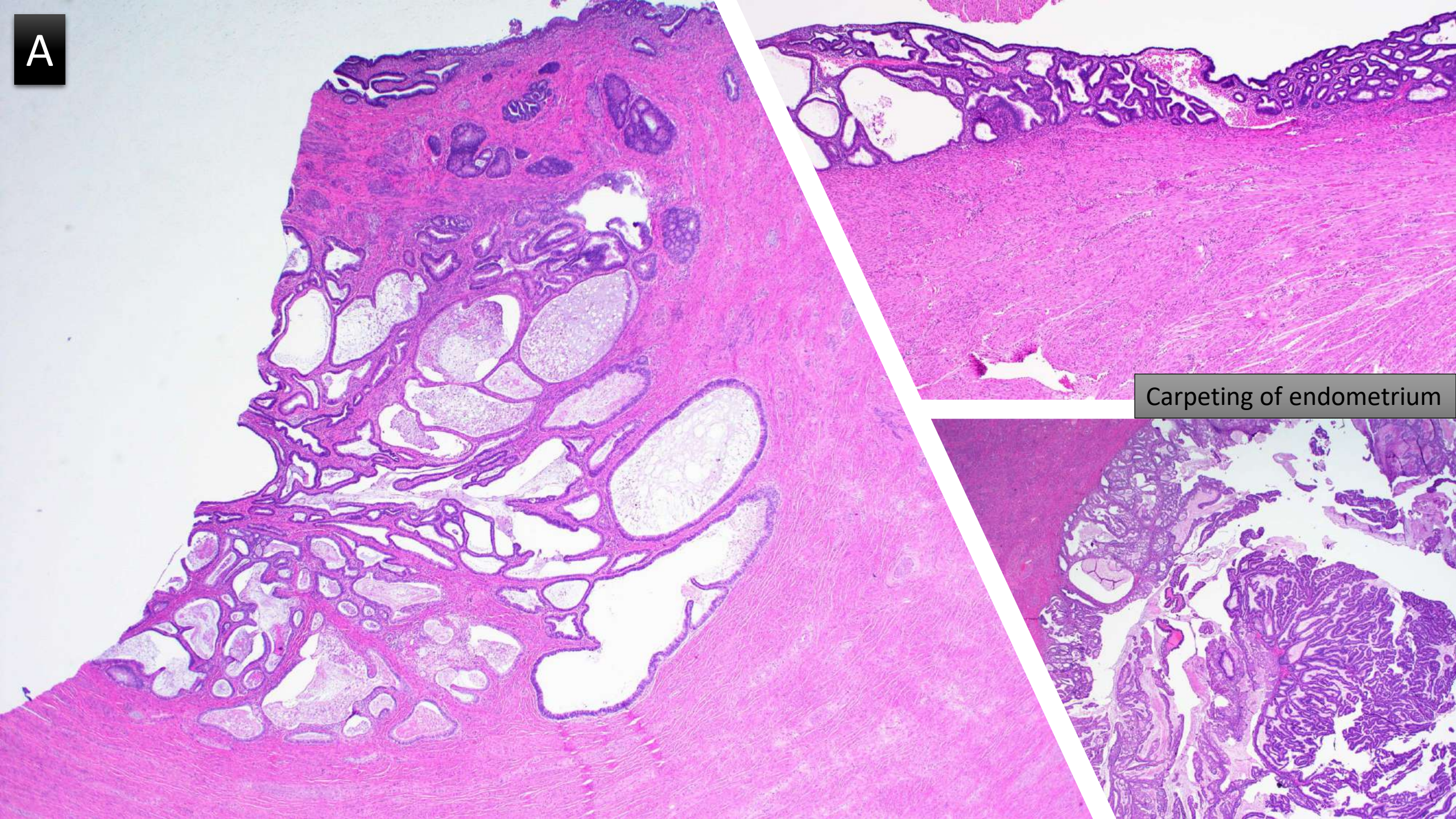
A
Carpeting of endometrium

Ovarian metastasis years later

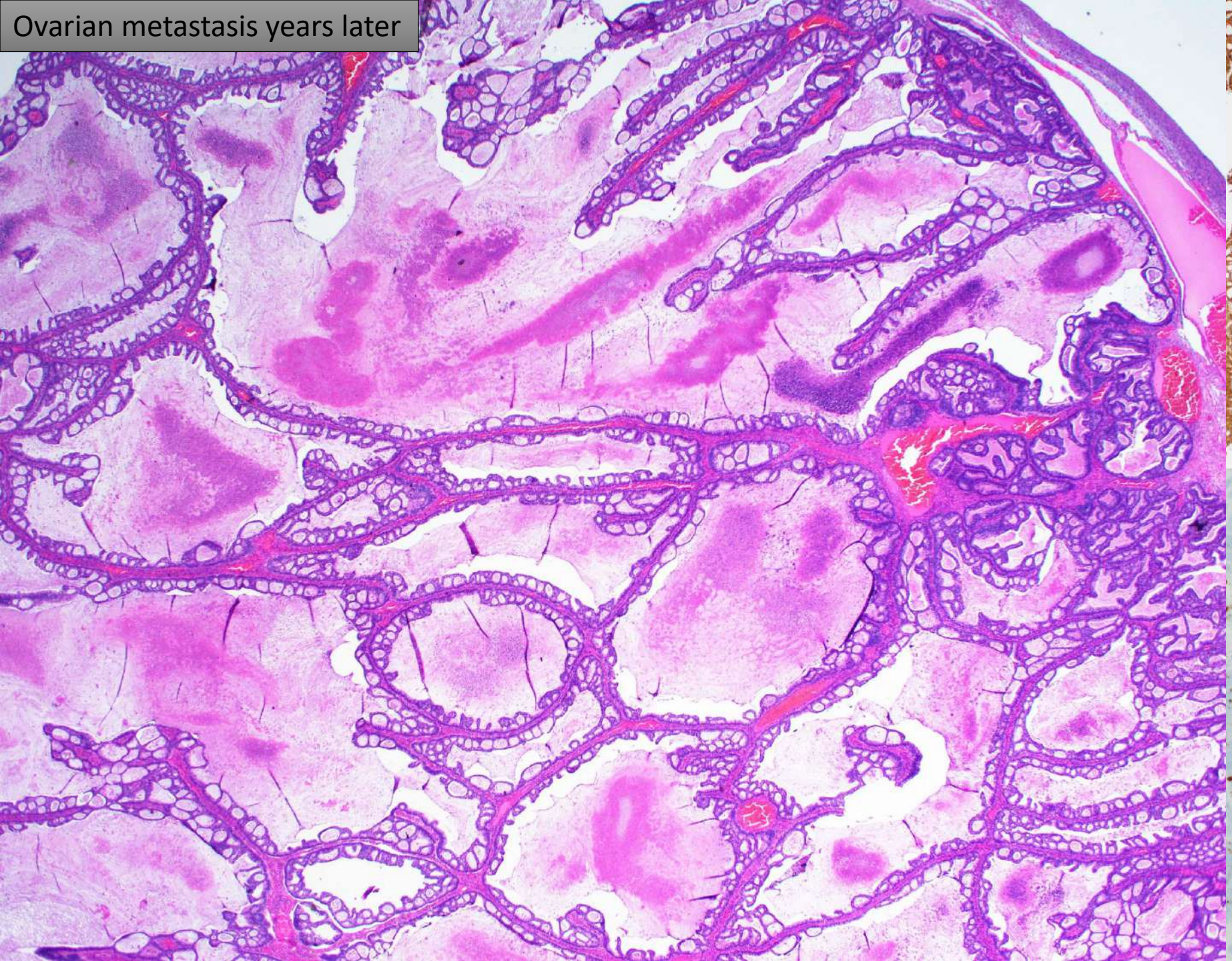

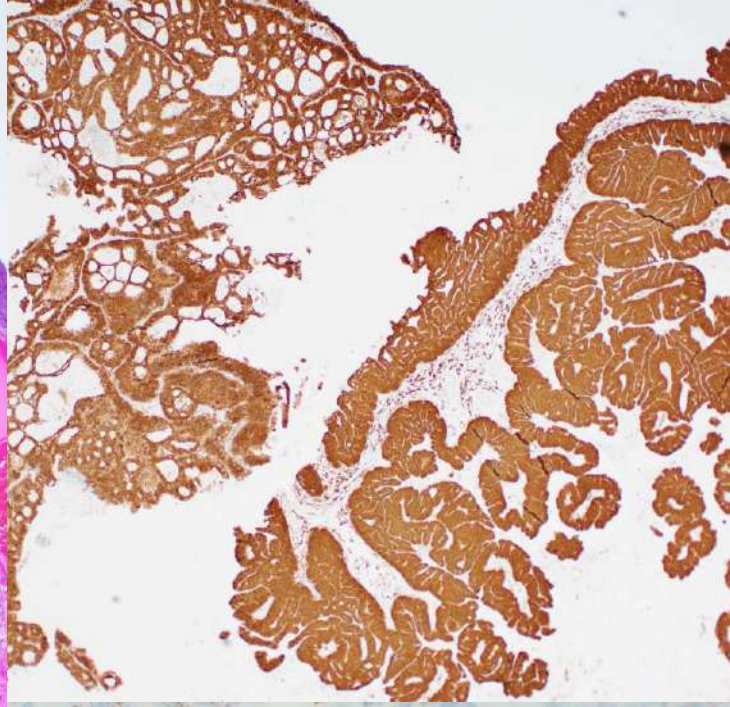

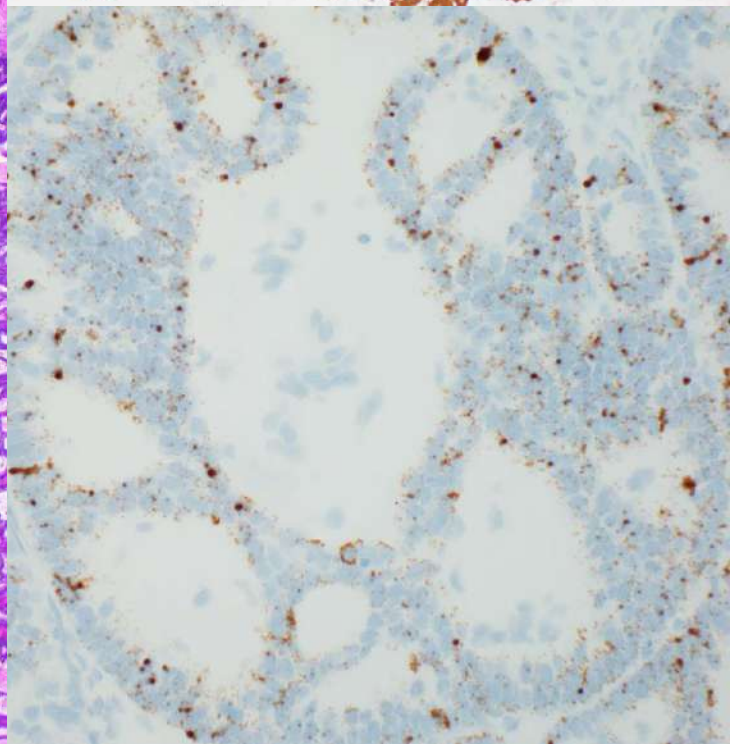

Clinical, Morphologic, and Molecular Features Associated With Ovarian Metastases From Pattern A Endocervical Adenocarcinomas

Jacqueline Feinberg, MD, Anjelica Hodgson, MD,† Nadeem R. Abu-Rustum, MD,*‡ Kara Long Roche, MD,*‡ and Kay J. Park, MD†*

(*Am J Surg Pathol* 2022;46:509–518)

TABLE 1. Clinical and Pathologic Features of Pattern A EAs With Ovarian Metastases

Patient No.	Age (y)	Presenting Symptoms	Initial Surgery	EA Subtype	Cervical Tumor Size (mm)
Synchronous ovarian metastases					
1	36	Ovarian mass	Open total hysterectomy, BSO, appendectomy, omentectomy, peritoneal biopsies	Mucinous intestinal	16
2	41	Endometrial "simple hyperplasia," ovarian mass, ascites	Open total hysterectomy, BSO, appendectomy, omentectomy, peritoneal biopsies, LND	Usual	At least 12
3	58	Postmenopausal bleeding, ovarian mass, ascites	Open total hysterectomy, BSO, right hemicolectomy, peritoneal biopsies	Mucinous intestinal	At least 25
4	41	Ovarian mass, remote history of abnormal Pap	Open total hysterectomy, BSO, omentectomy, LND	Mucinous NOS	22
Metachronous ovarian metastases					
5	38	Abnormal Pap	Robotic-assisted laparoscopic radical hysterectomy, LND	Usual	Carcinoma in endometrial curettings only
6	31	Abnormal Pap	Laparoscopic simple trachelectomy converted to hysterectomy, BS	Mucinous intestinal	At least 15
7	37	Abnormal Pap	Robotic-assisted laparoscopic total hysterectomy, BS, SLN biopsies	Mucinous NOS	9
8	38	Abnormal Pap	Open total abdominal hysterectomy	Usual	NA

BS indicates bilateral salpingectomy; BSO, bilateral salpingo-oophorectomy; LND, lymph node dissection; LUS, lower uterine segment; NA, not applicable; NOS, not otherwise specified; SLN, sentinel lymph node.

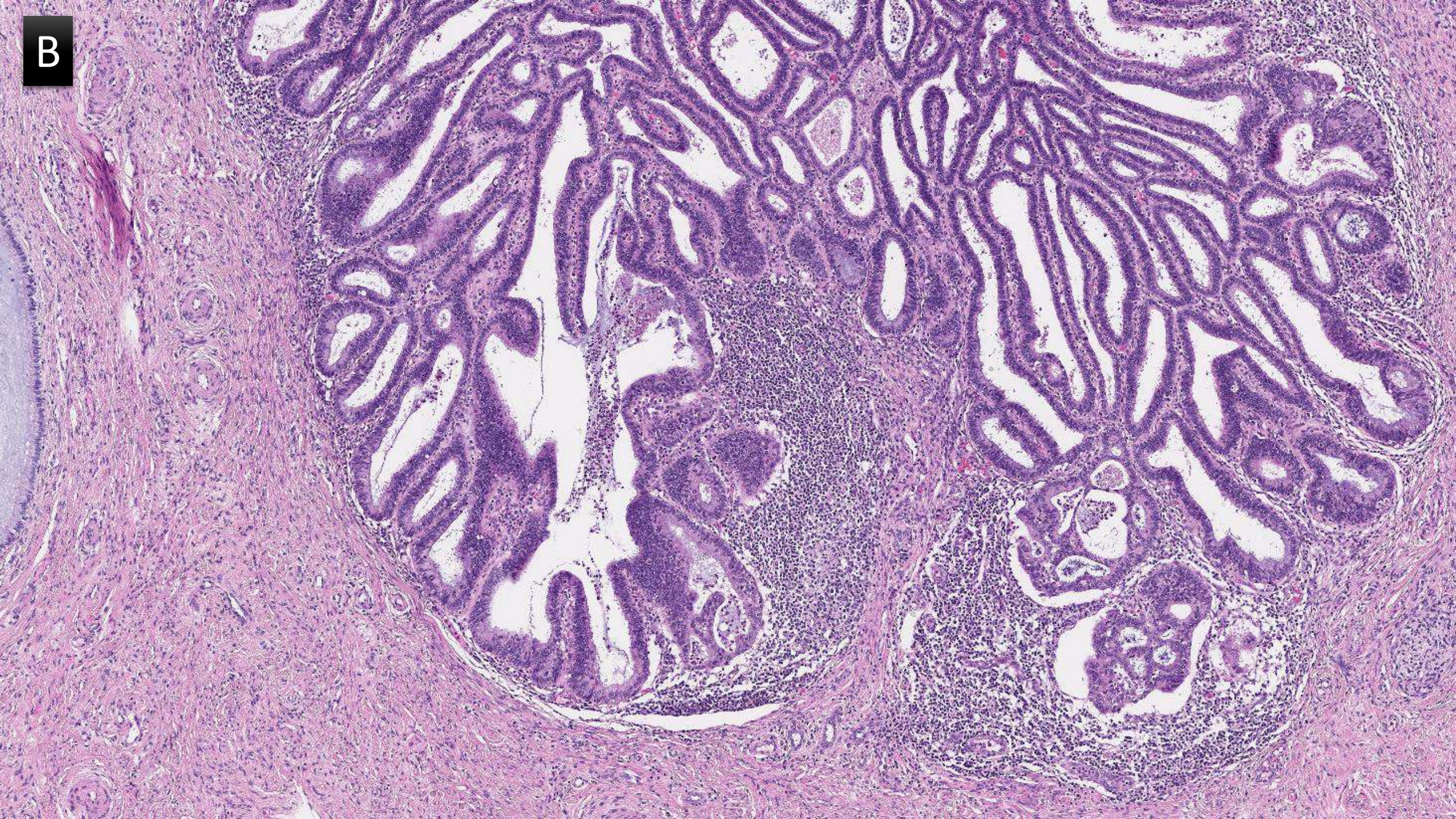
B

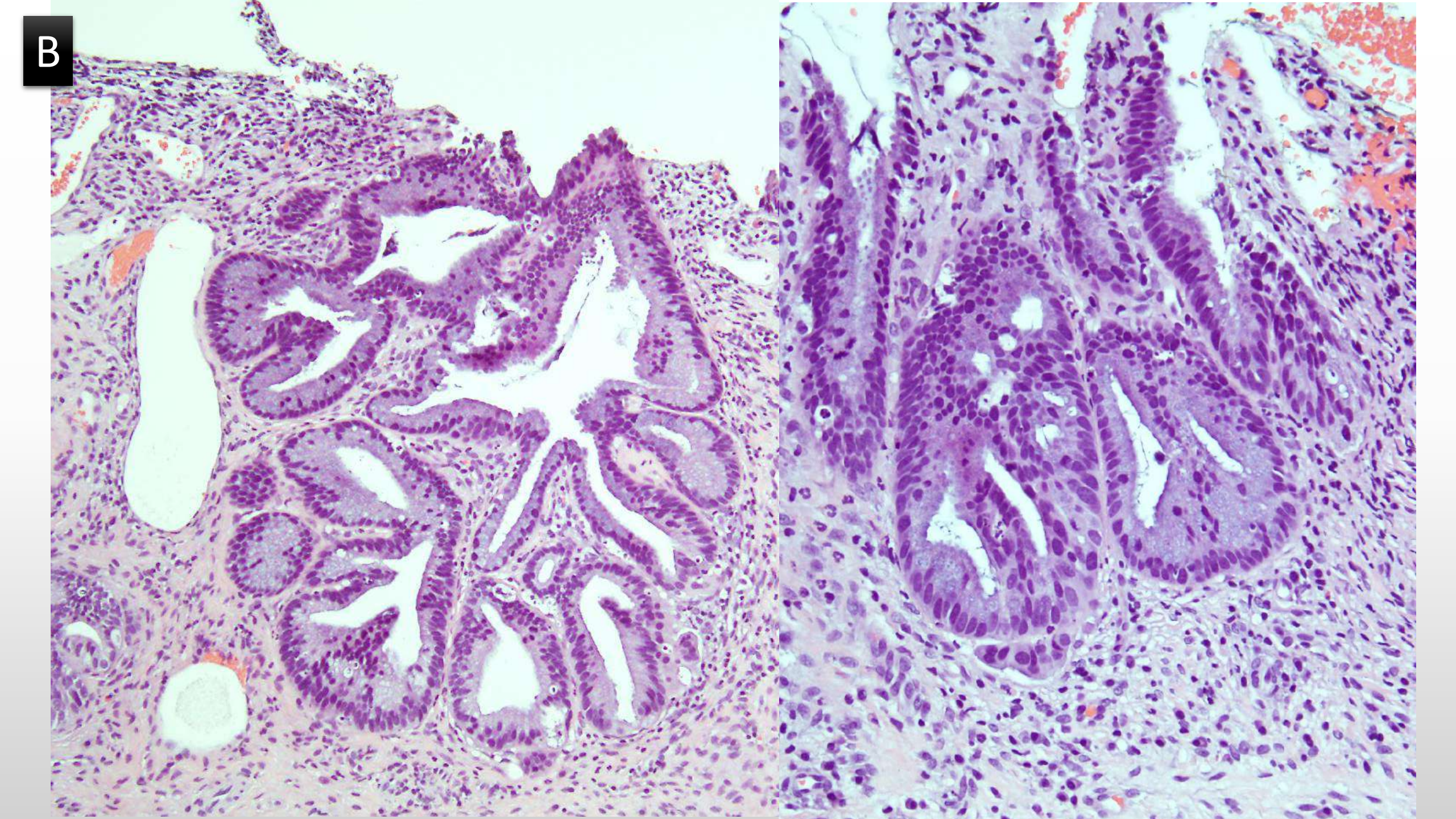
B

B

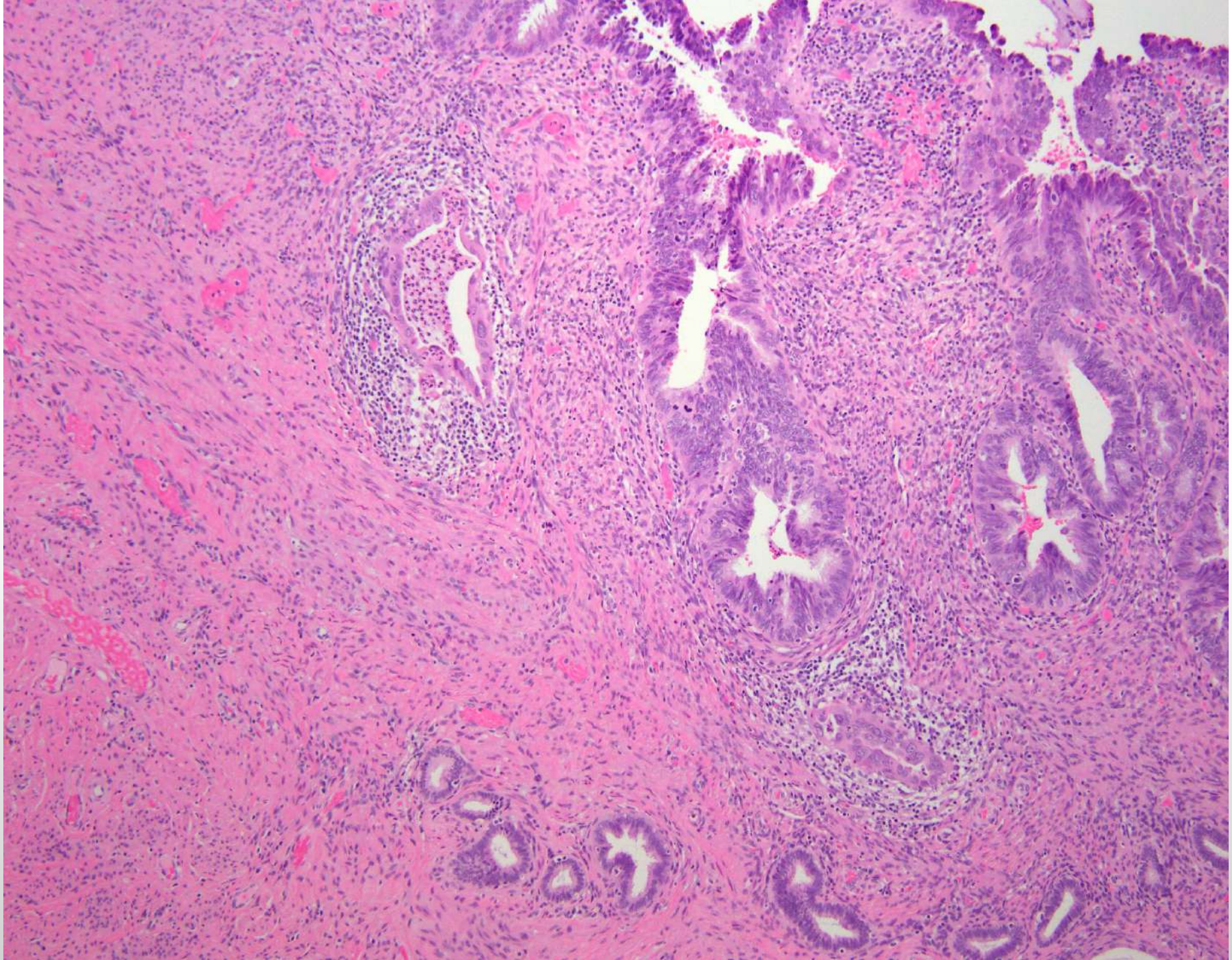

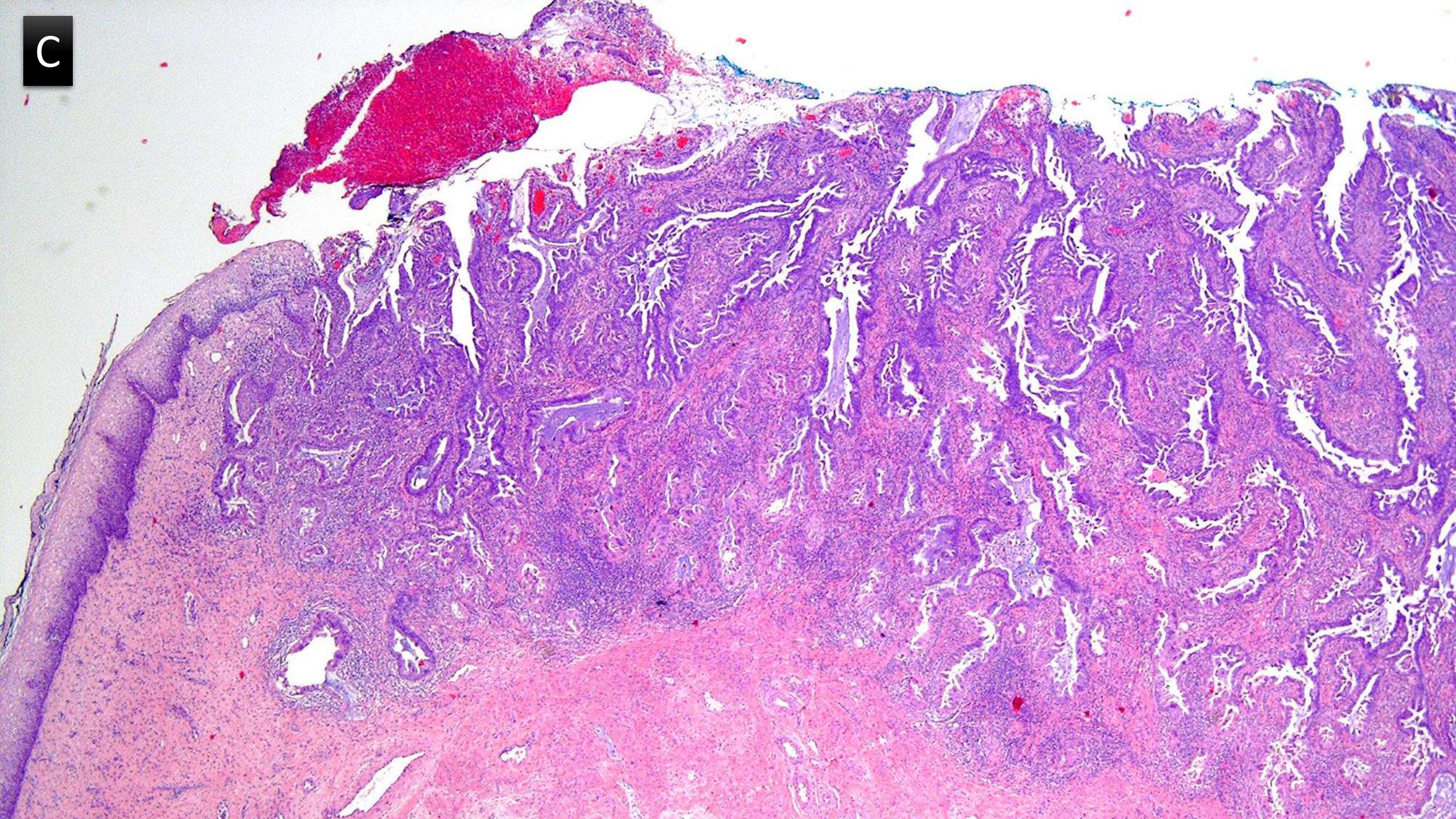
C

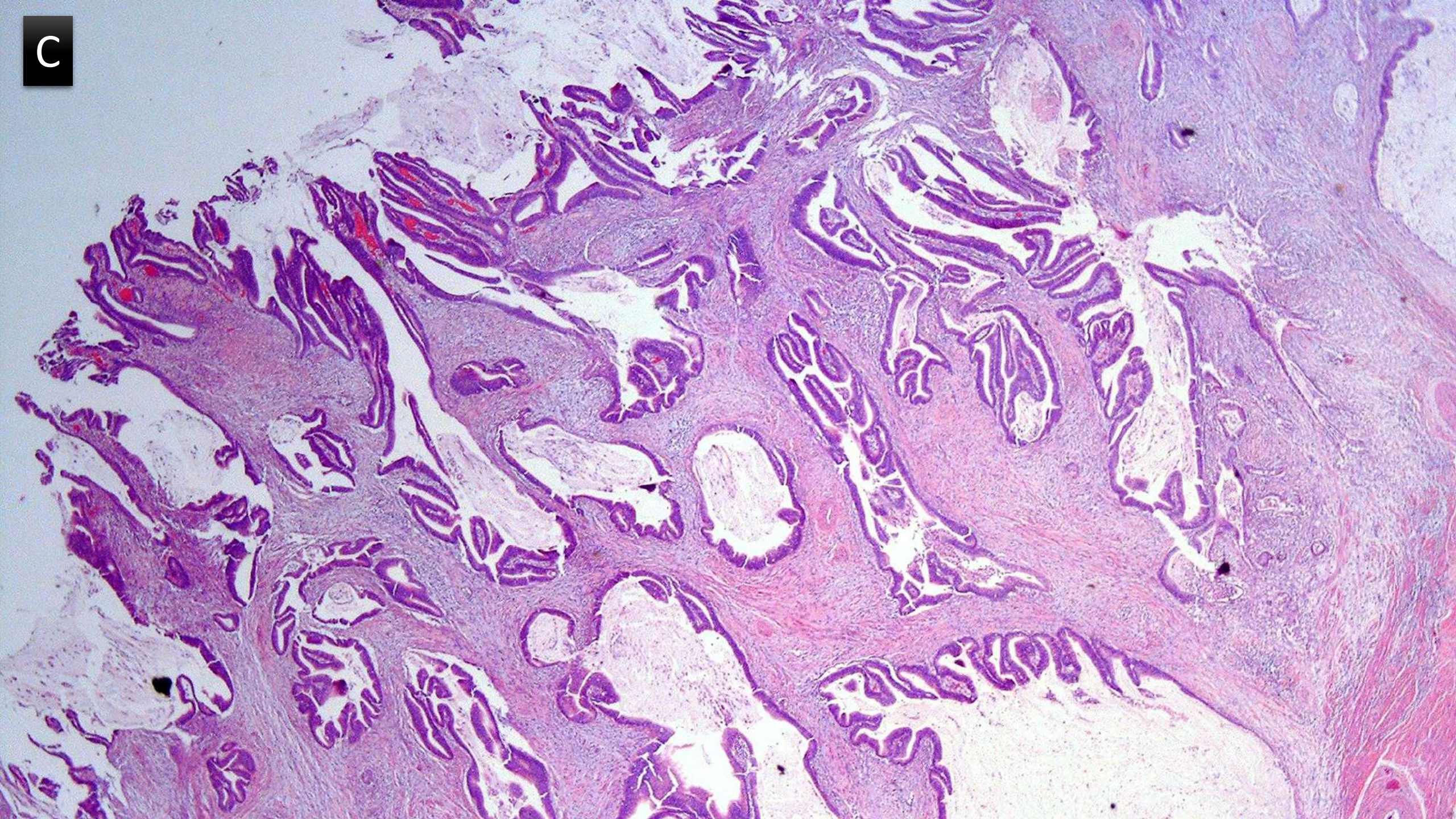
C

C

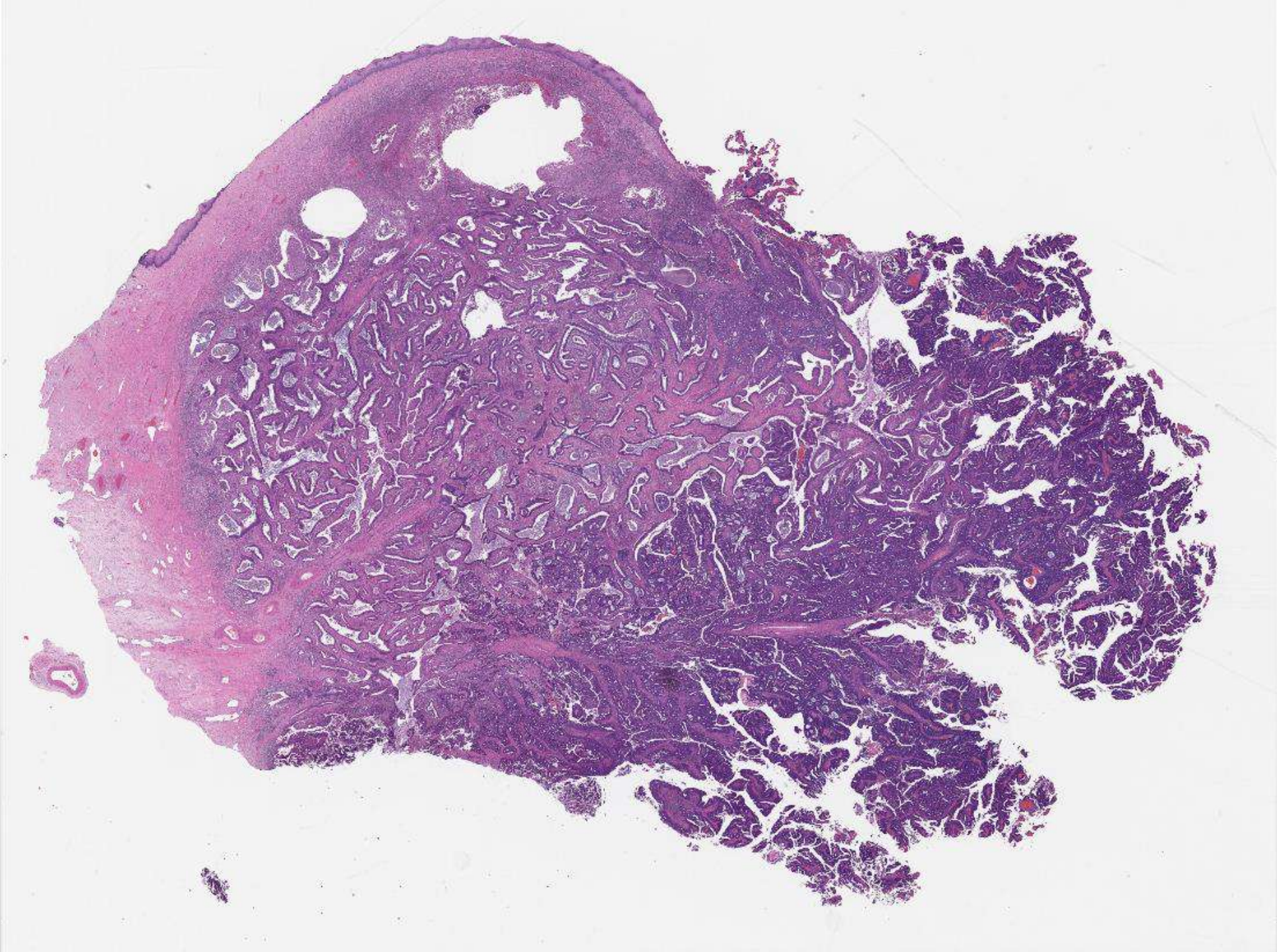

C

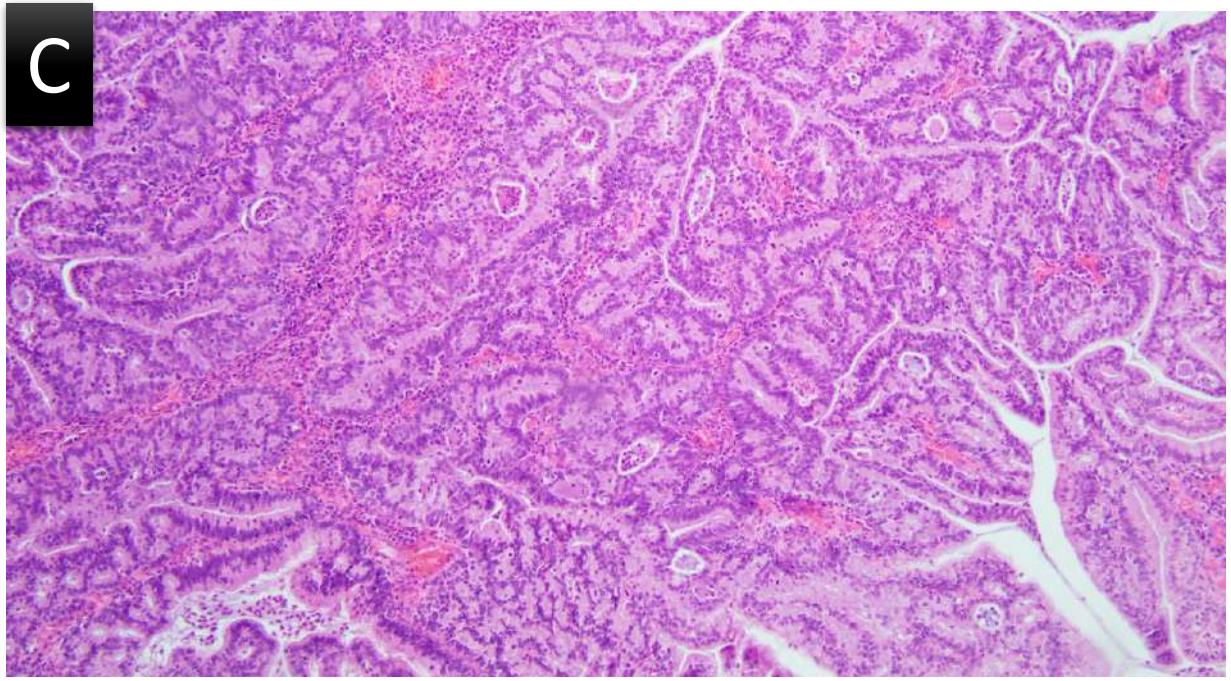

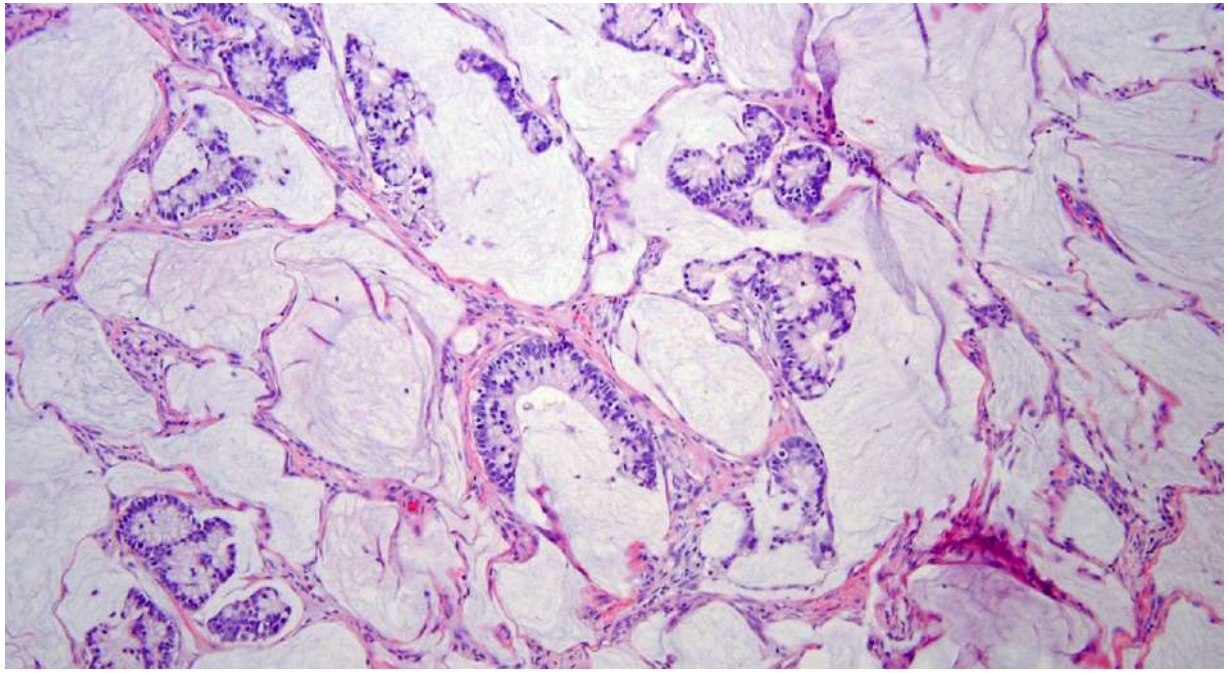

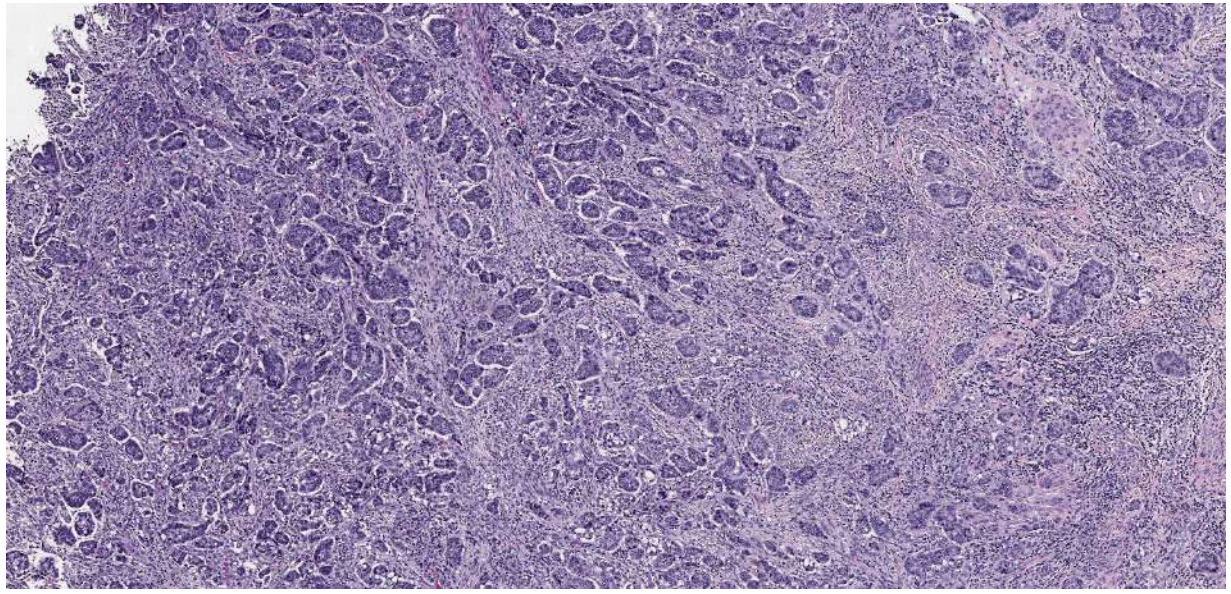

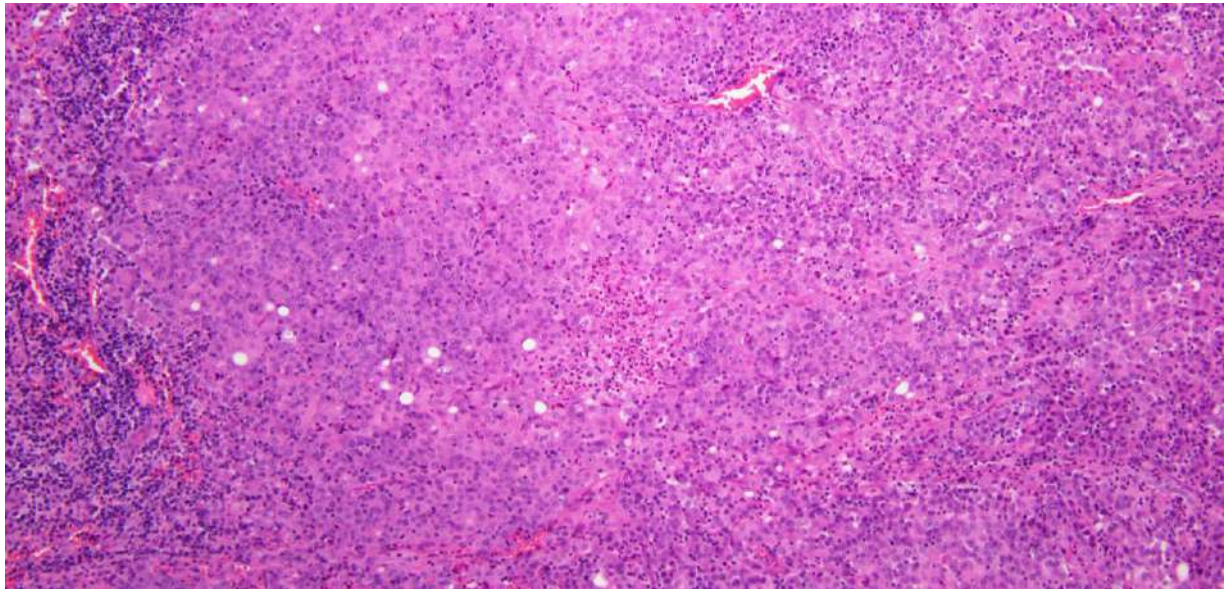

AIS vs. Pattern A

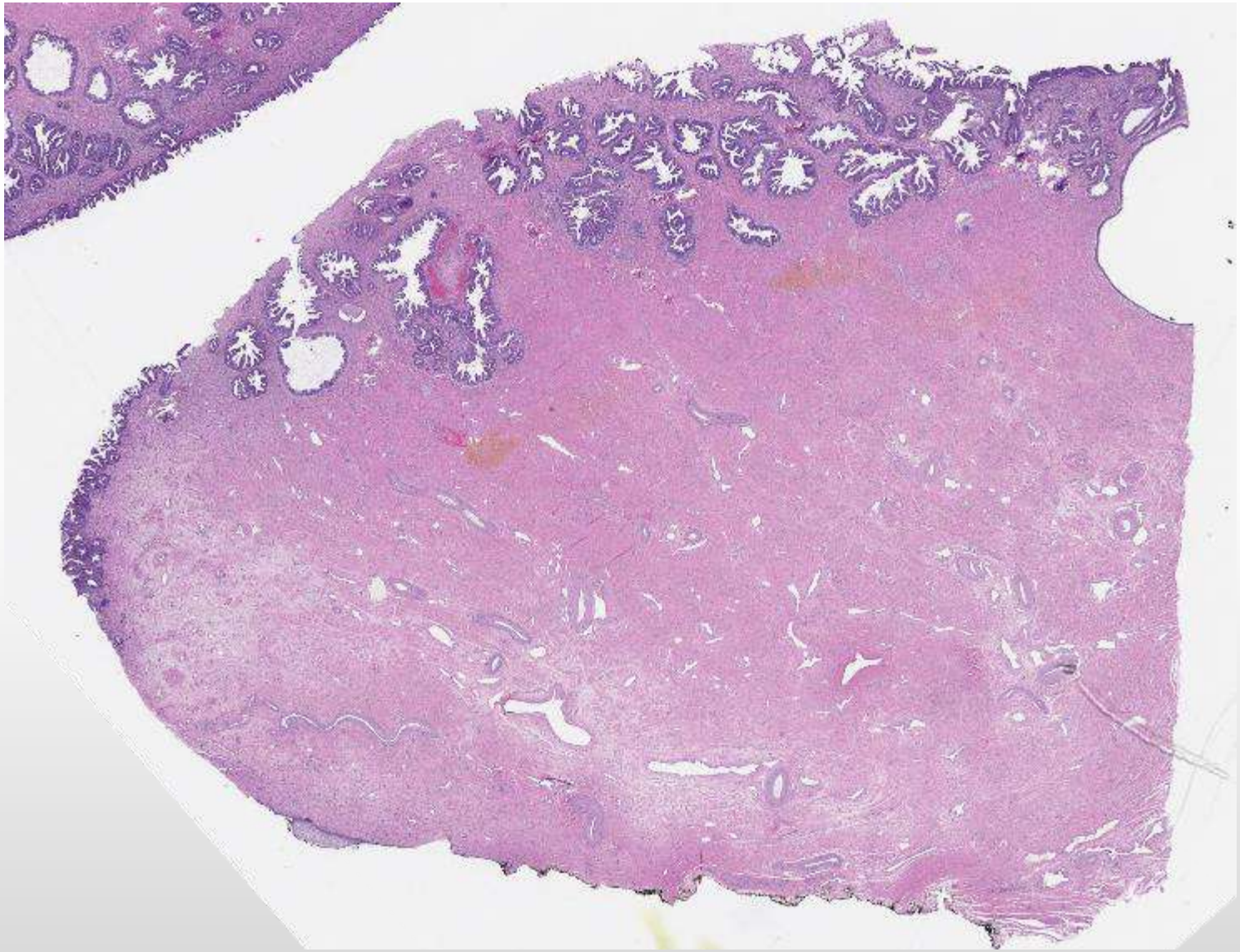

Pattern A vs. Pattern B

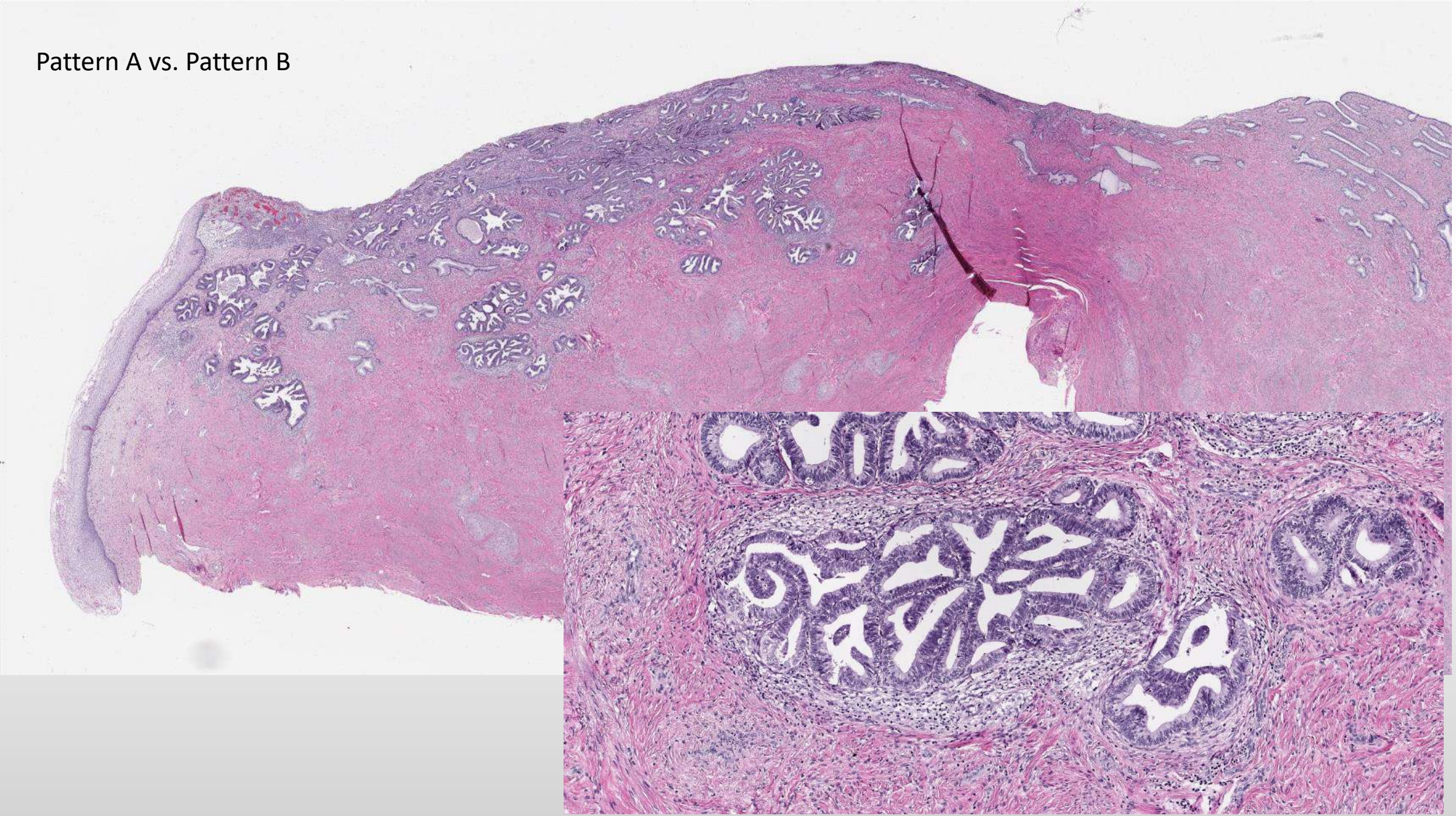

Pattern A vs. Pattern C



Pattern A vs. Pattern C

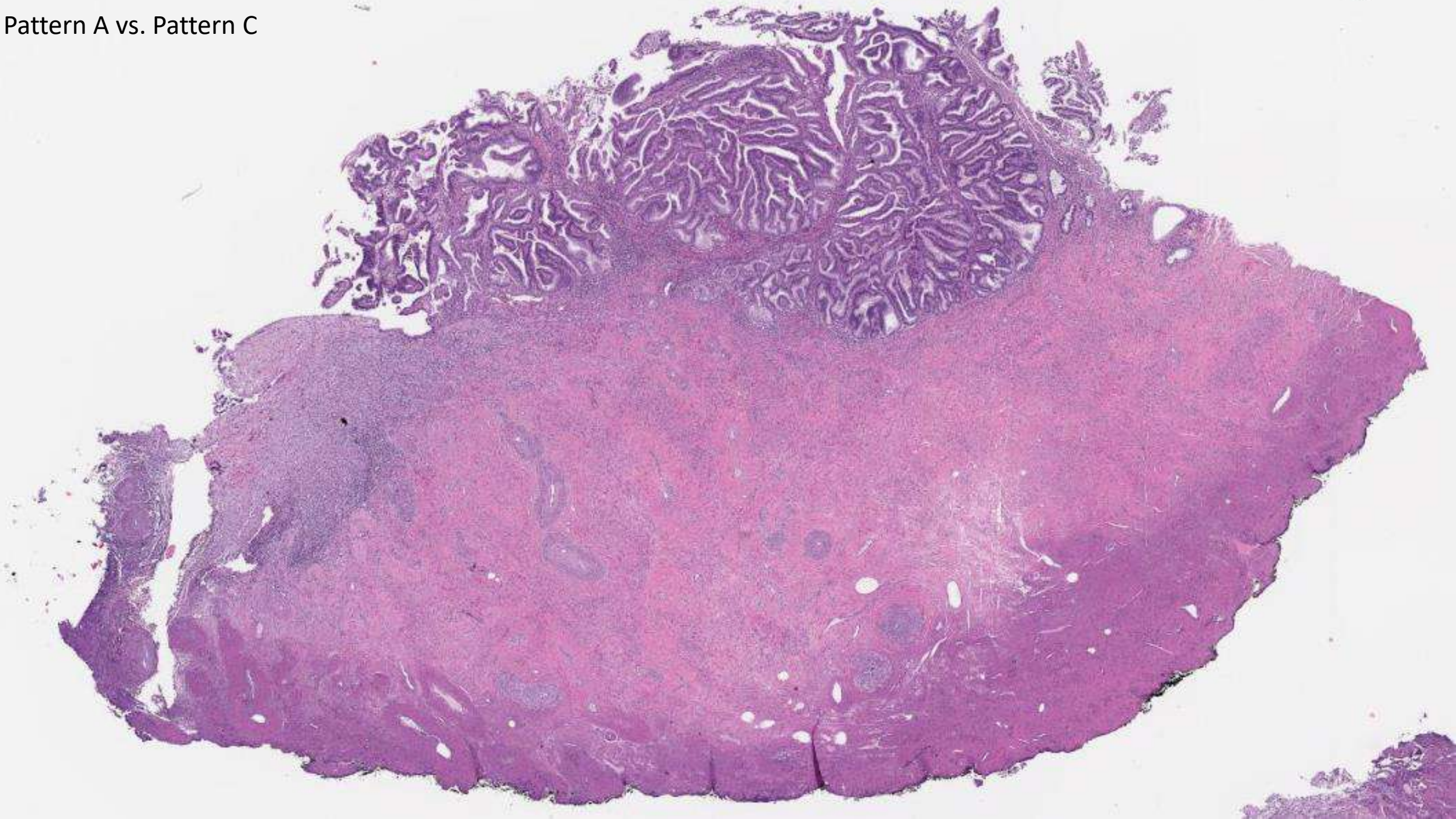

Staging adenocarcinomas

Staging Adenocarcinomas

- Newest FIGO Stage 2018
- Removed horizontal extent as part of stage for *microscopic tumors only*
- ICCR recommendations – still report horizontal extent
- Measuring DOI
  - Exophytic tumors
  - No stromal invasion

Case 6

56 year old with adenocarcinoma on ECC

Gynecologist saw a 1.2 cm red, raised lesion

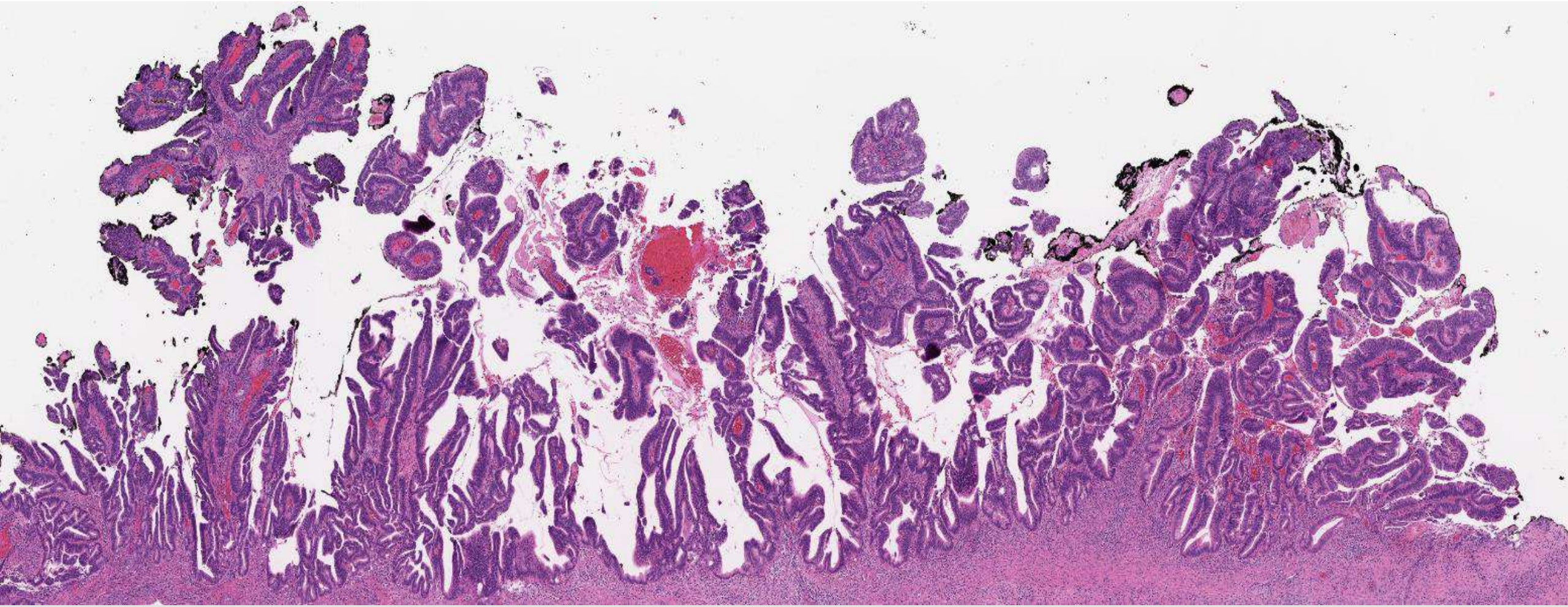

2018 FIGO Staging
Cervix uteri

DOI: 10.1002/ijgo.12969

CORRIGENDUM

WILEY GYNECOLOGY OBSTETRICS FIGO

Corrigendum to "Revised FIGO staging for carcinoma of the cervix uteri" [Int J Gynecol Obstet 145(2019) 129–135]

The authors regret to note a number of errors in Box 1. The '-' in measurement cut-offs was erroneously placed in 12 instances in Stages I and II. The corrected version of Box 1 is given below; corrected notations of measurement are shown in bold type. Micrometastases have been included in Stage IIIC.

Box 1

Stage I:

The carcinoma is strictly confined to the cervix (extension to the corpus should be disregarded).

- IA Invasive carcinoma that can be diagnosed only by microscopy with maximum depth of invasion ≤5 mm[a]
  - **IA1** Measured stromal invasion ≤3 mm in depth
  - **IA2** Measured stromal invasion >3 mm and ≤5 mm in depth
- IB Invasive carcinoma with measured deepest invasion >5 mm (greater than stage IA); lesion limited to the cervix uteri with size measured by maximum tumor diameter[b]
  - **IB1** Invasive carcinoma >5 mm depth of stromal invasion and ≤2 cm in greatest dimension
  - **IB2** Invasive carcinoma >2 cm and ≤4 cm in greatest dimension
  - **IB3** Invasive carcinoma >4 cm in greatest dimension

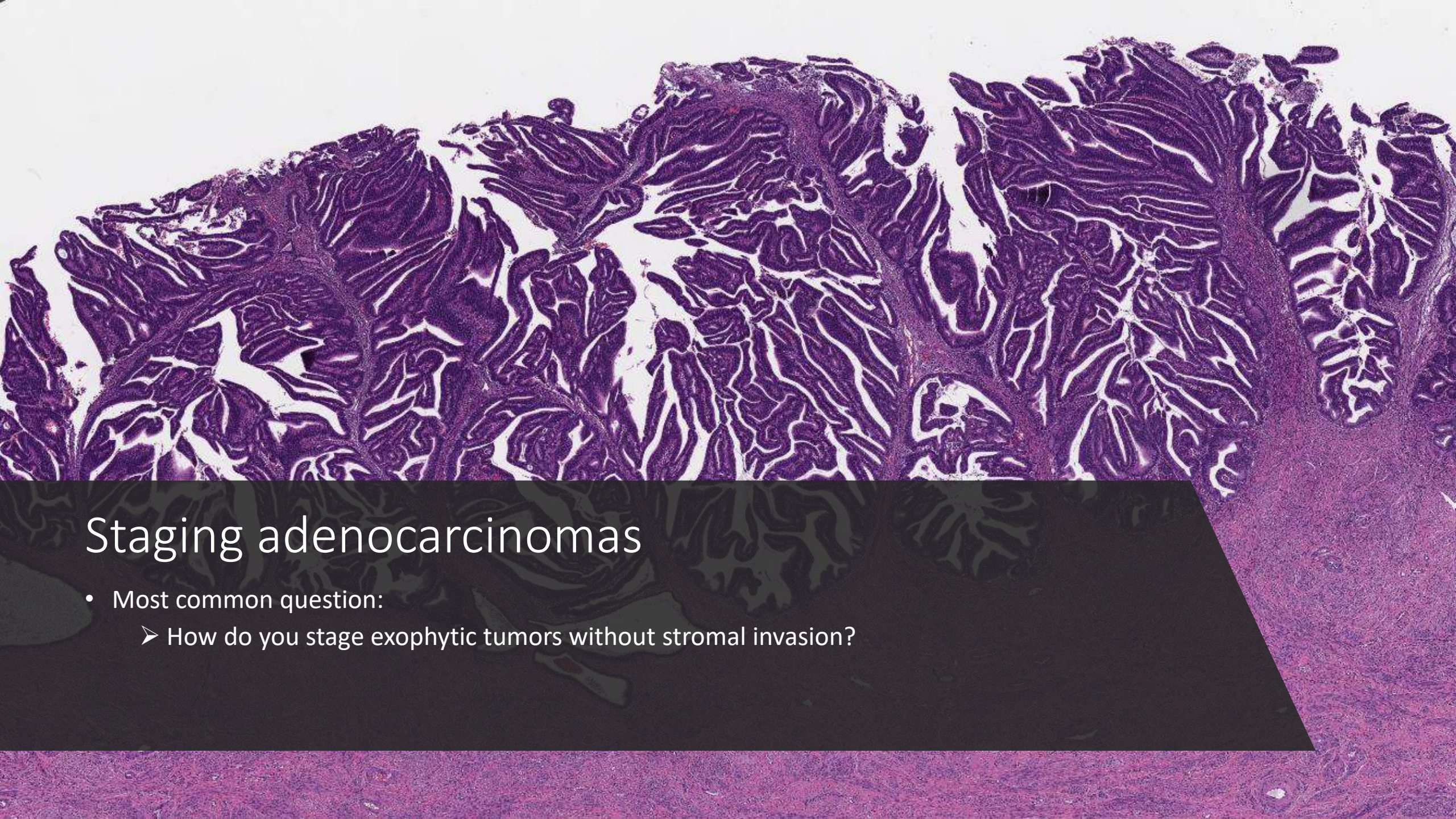

Staging adenocarcinomas

- Most common question:
  - How do you stage exophytic tumors without stromal invasion?

Algorithm for staging (pathologically)

- Must be completely removed with negative margins
- Is it grossly visible?
  - Yes – IB (stage on largest tumor size)
    - IB1: <=2 cm
    - IB2: >2 cm, <=4 cm
    - IB3: >4 cm
  - No – what is horizontal extent?
    - >2 cm → at least stage IB
    - <=2 cm → what is depth of invasion?
      - Stage based on DOI

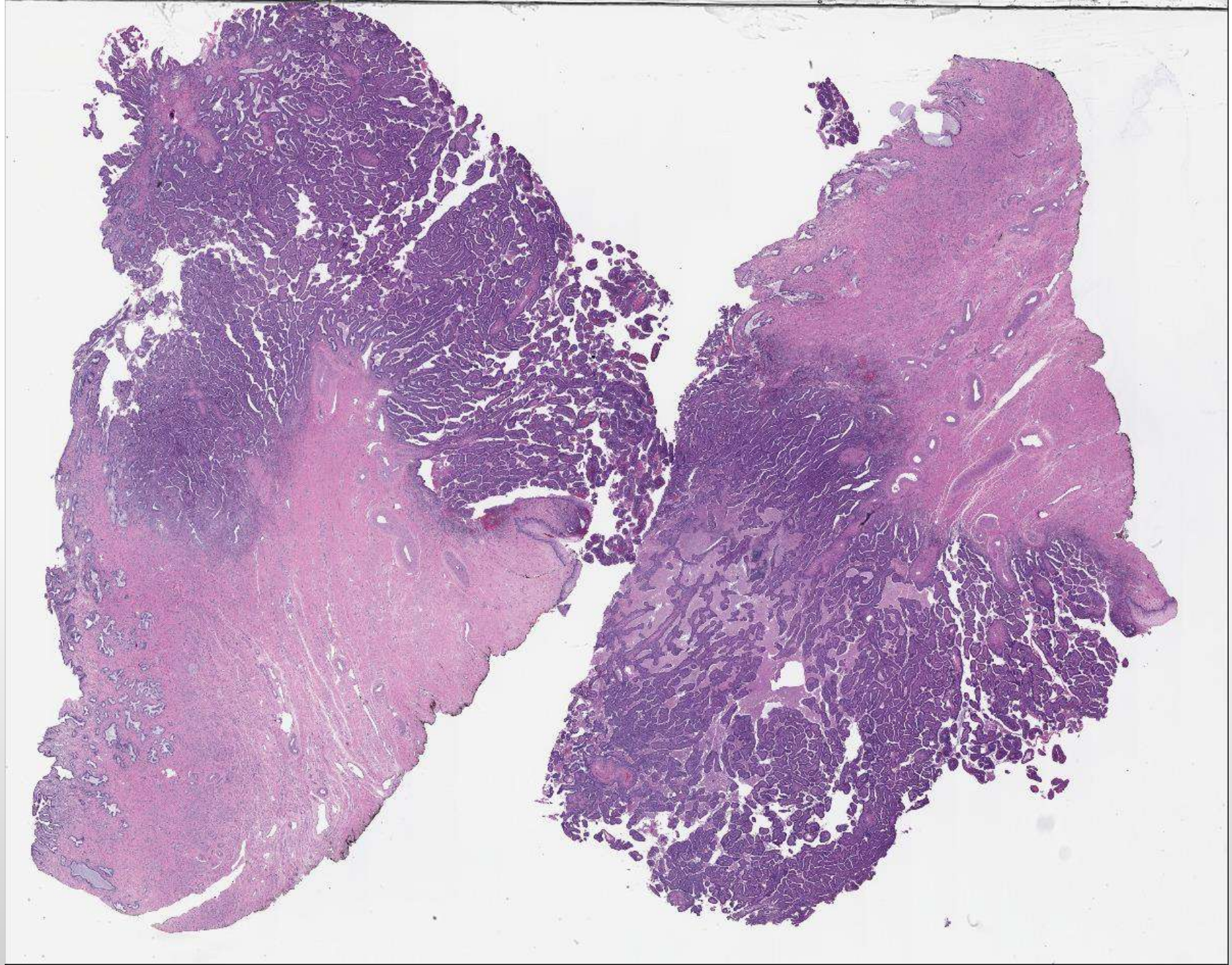

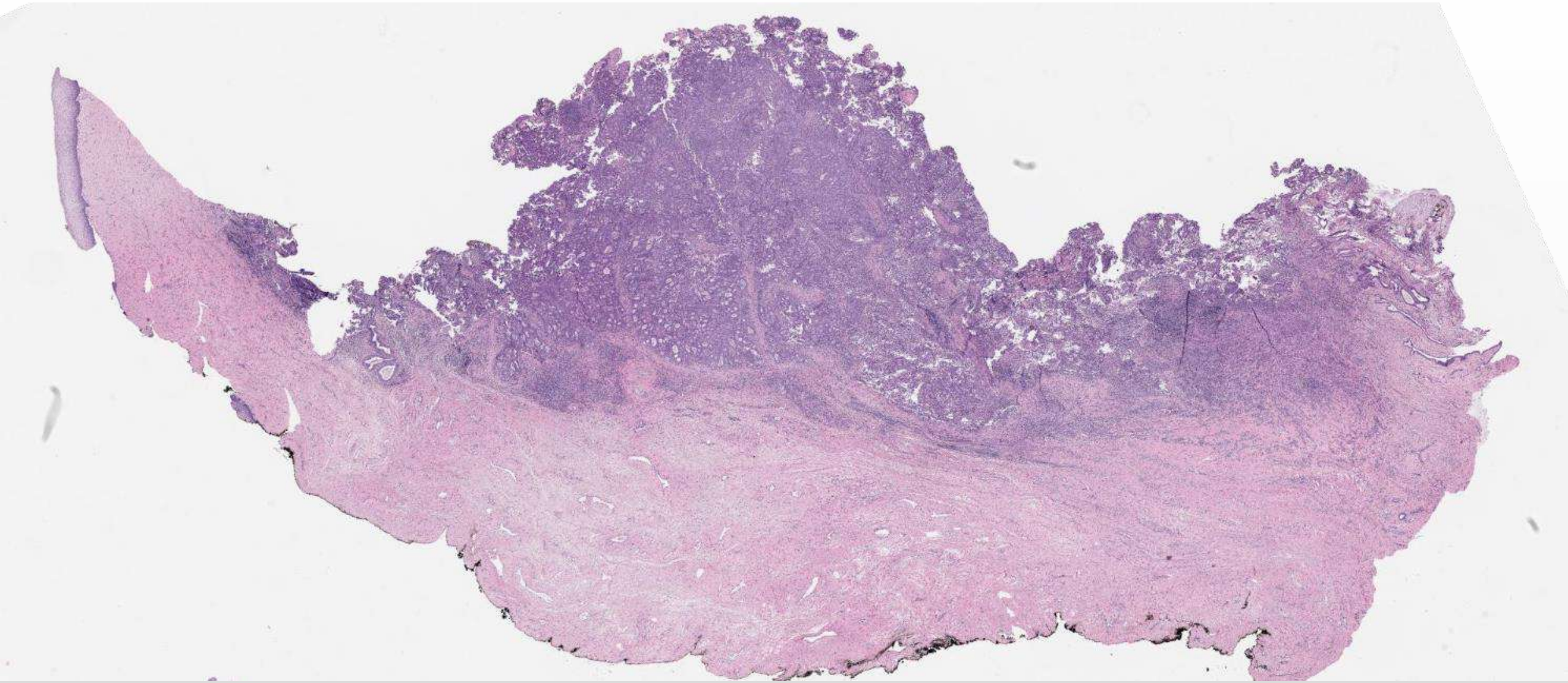

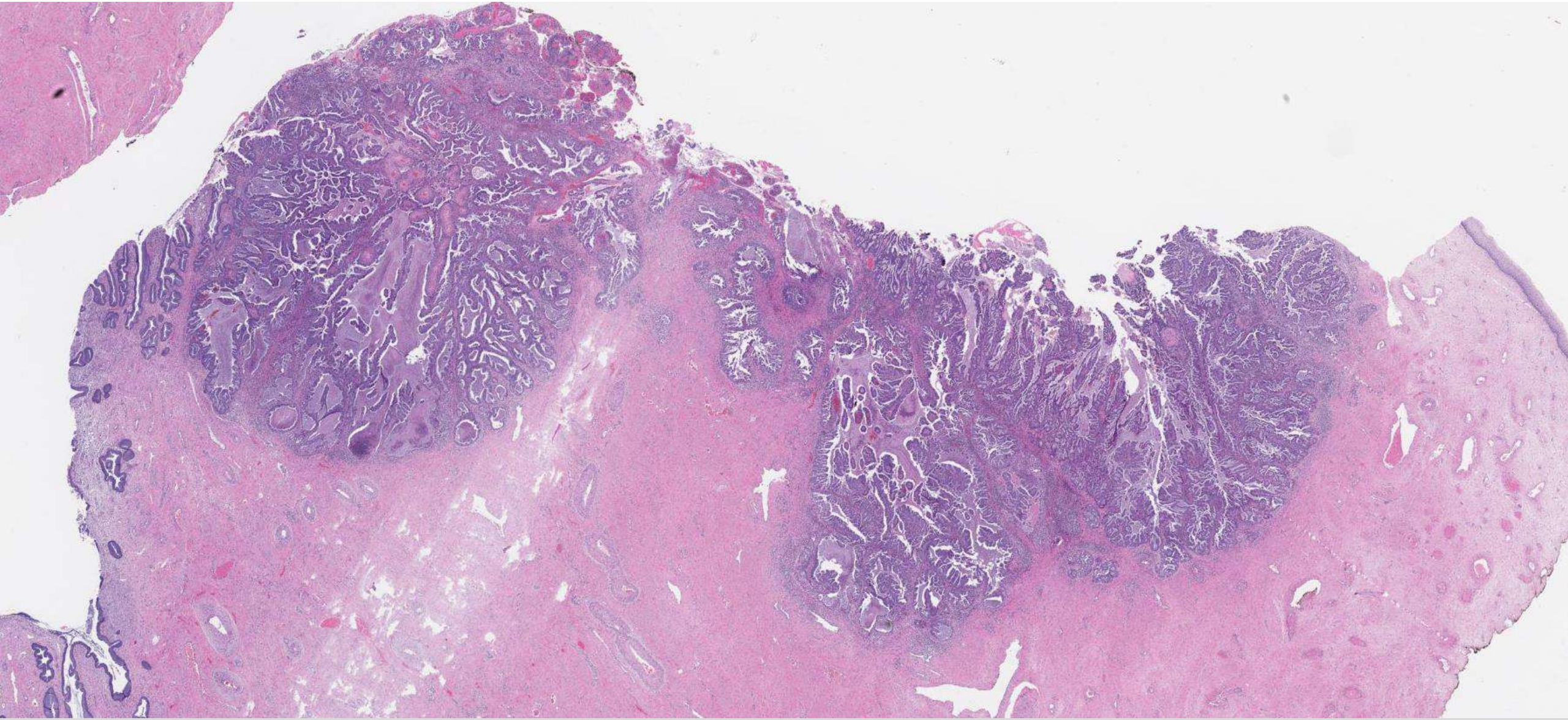

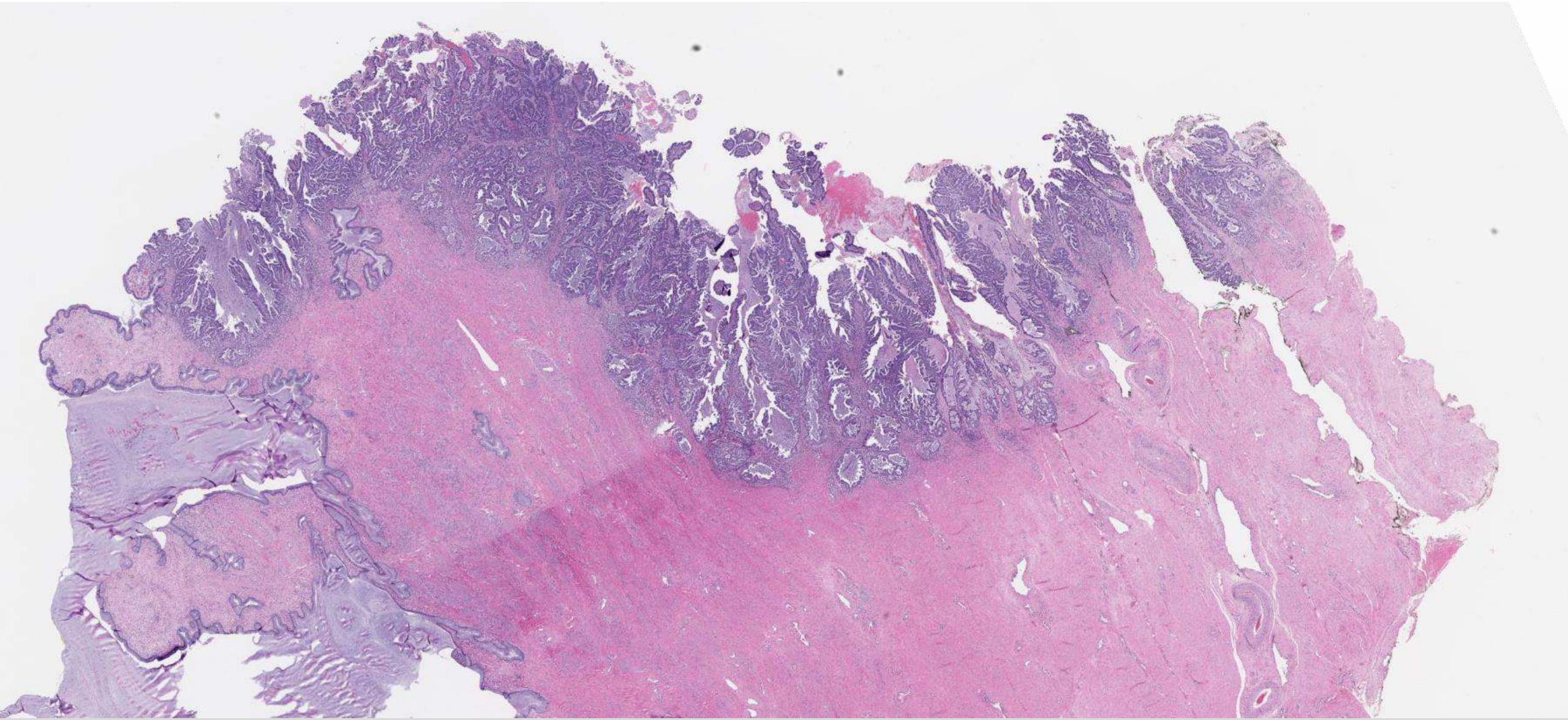

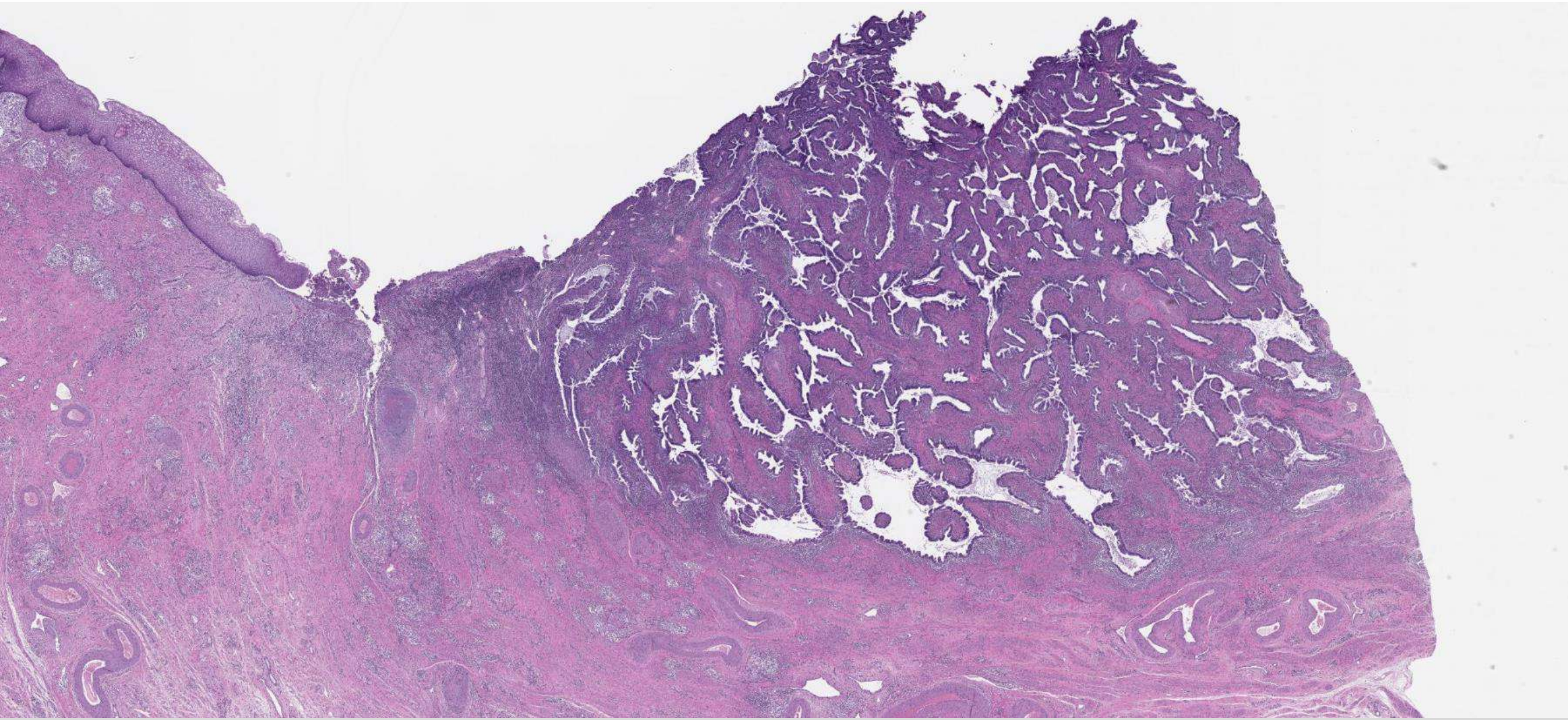

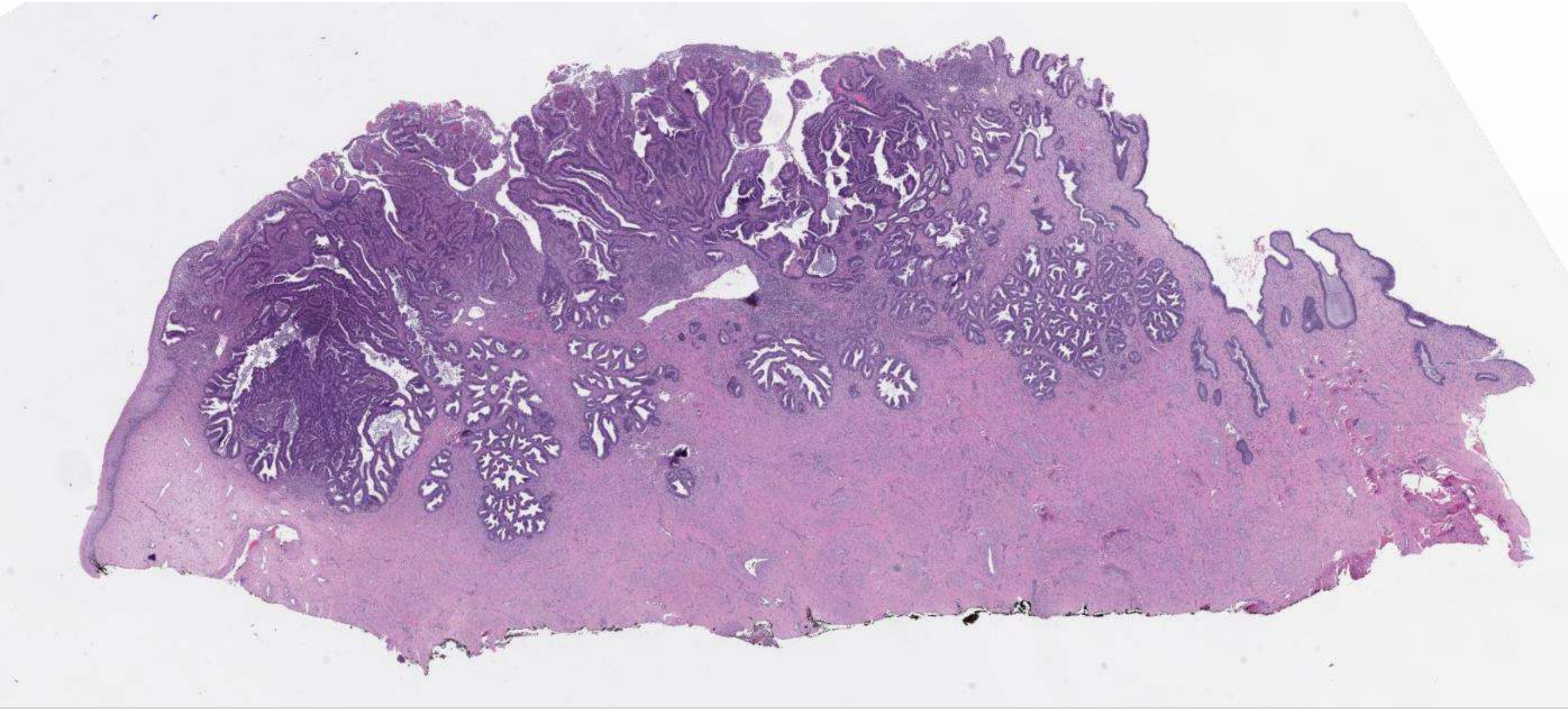

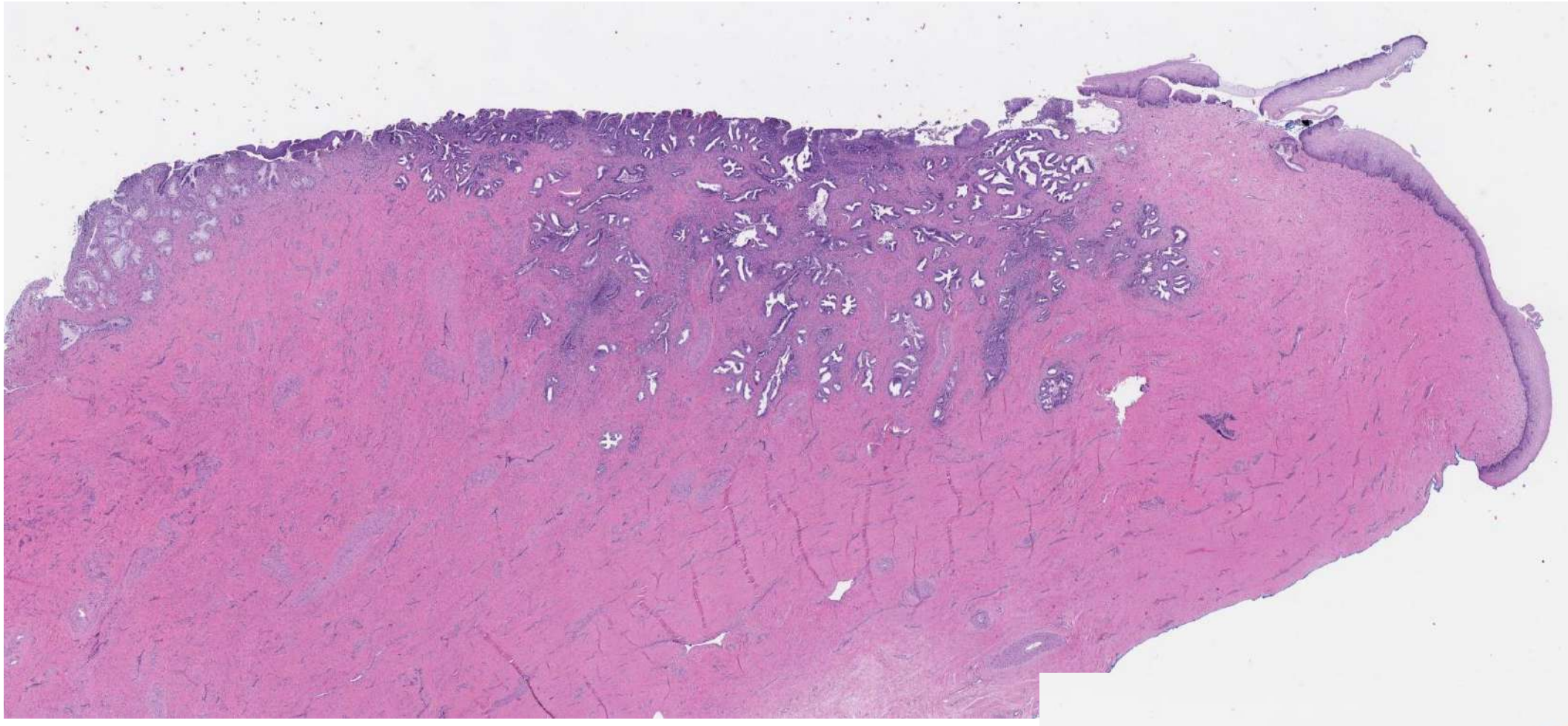

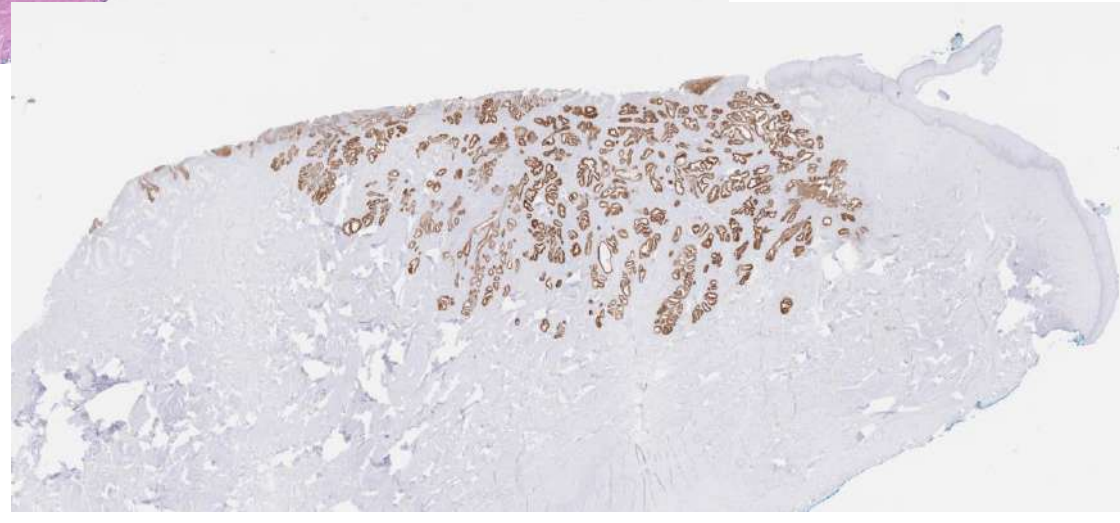

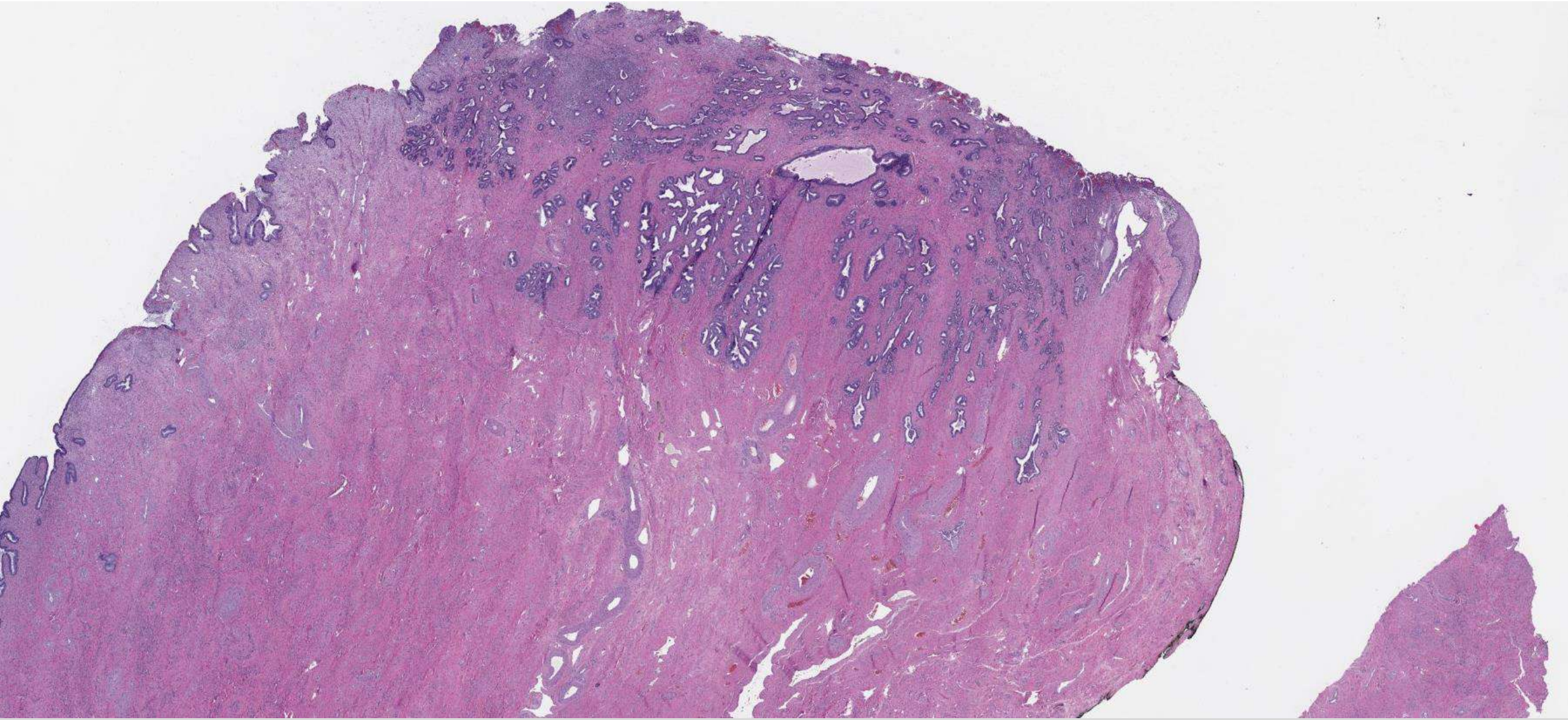

Algorithm for staging (pathologically)

- Must be completely removed with negative margins
- Is it grossly visible?
  - Yes – IB (stage on largest tumor size)
    - IB1: <=2 cm
    - IB2: >2 cm, <=4 cm
    - IB3: >4 cm
  - No – what is horizontal extent?
    - >2 cm → at least stage IB
    - <=2 cm → what is depth of invasion?
      - Stage based on DOI

Summary

Subtyping endocervical adenocarcinoma

How to distinguish benign from gAIS

How to distinguish gAIS from invasive gastric type adenocarcinoma

Pattern classification

Staging