NHS Cervical Screening Programme

NHS
Cancer Screening Programmes

Histopathology Reporting in Cervical Screening – an Integrated Approach

NHSCSP PUBLICATION NO 10 (SECOND EDITION)

SEPTEMBER 2012

HISTOPATHOLOGY REPORTING IN CERVICAL SCREENING – AN INTEGRATED APPROACH

Second edition

NHSCSP Publication No 10
September 2012

Published by
NHS Cancer Screening Programmes
Fulwood House
Old Fulwood Road
Sheffield
S10 3TH

Tel: 0114 271 1060
Fax: 0114 271 1089
Email: info@cancerscreening.nhs.uk
Website: www.cancerscreening.nhs.uk

© NHS Cancer Screening Programmes 2012

The contents of this document may be copied for use by staff working in the public sector but may not be copied for any other purpose without prior permission from NHS Cancer Screening Programmes. The report is available in PDF format on the NHS Cancer Screening Programmes website.

ISBN 978-1-84463-082-0

Typeset by Prepress Projects Ltd (www.prepress-projects.co.uk)
Printed by Henry Ling Ltd

This publication is dedicated to the late
Professor Harold Fox

CONTENTS

CONTRIBUTORS viii

FOREWORD ix

PREFACE xi

1 CERVICAL SQUAMOUS NEOPLASIA: PRECURSORS, TUMOURS, AND BENIGN MIMICS 1

1.1 Terminology and grading 1
1.2 Morphological features of CIN 1
1.3 FIGO stage I cervical squamous carcinoma 6
1.4 Classification and grading system for cervical squamous carcinoma 11
1.5 Benign mimics of CIN 16

2 CERVICAL GLANDULAR NEOPLASIA: PRECURSORS, TUMOURS, AND BENIGN MIMICS 23

2.1 Introduction 23
2.2 CGIN 23
2.3 SMILE 27
2.4 Early invasive adenocarcinoma 28
2.5 Cervical adenocarcinoma (including variants) 30
2.6 Benign glandular mimics of CGIN and adenocarcinoma 38

3 UNCOMMON CERVICAL TUMOURS 49

3.1 Introduction 49
3.2 Neuroendocrine tumours 49
3.3 Adenosquamous carcinoma 52
3.4 Glassy cell carcinoma variant of adenosquamous carcinoma 52
3.5 Adenoid cystic carcinoma 53
3.6 Adenoid basal carcinoma 53
3.7 Mixed epithelial and mesenchymal tumours 54
3.8 Mesenchymal tumours 55
3.9 Haematopoietic lesions 55
3.10 Melanocytic neoplasms 56
3.11 Miscellaneous tumours and metastases 56

4 COLPOSCOPY: INDICATIONS FOR COLPOSCOPIC REFERRAL, METHODS OF TREATMENT AT COLPOSCOPY, AND FOLLOW-UP OF HISTOLOGICALLY CONFIRMED PREINVASIVE AND INVASIVE DISEASE 57

4.1 Introduction 57
4.2 Referral guidelines for colposcopy 57
4.3 Management of cellular changes 58
4.4 Documentation of colposcopic examination and information required when submitting specimens for histology 59
4.5 Treatment of CIN 59
4.6 Treatment of early-stage invasive disease 60
4.7 Other methods of treating CIN and early-stage invasive disease: hysterectomy and trachelectomy 60
4.8 Management of patients after primary treatment 61
4.9 The colposcopy MDTM 62

5 CERVICAL CYTOLOGY: FOLLOW-UP PROTOCOLS AND HPV TRIAGE 65

5.1 Management of low-grade cytological changes 65
5.2 Follow-up after treatment for CIN 66
5.3 Follow-up after treatment for CGIN 66
5.4 Follow-up after treatment for invasive cervical cancer 67

6 AUDIT AND QUALITY ASSURANCE IN HISTOPATHOLOGY 69

6.1 Introduction 69
6.2 Quality assurance 69
6.3 Audit 70
6.4 Histology/cytology correlation 71
6.5 MDTMs 72
6.6 Histology reporting 73

7 CANCER REGISTRIES: THEIR ROLE IN CANCER REGISTRATION AND DATA COLLECTION, AND THEIR RELATIONSHIPS WITH OTHER NATIONAL ORGANISATIONS 75

7.1 Cancer registration 75
7.2 Cancer registries 75
7.3 Role of cancer registries 76
7.4 UKACR 77
7.5 The process of data collection 77
7.6 Information collected by registries 77
7.7 Legal background to cancer registration and confidentiality 78
7.8 Uses of cancer registration information 79
7.9 The NCIN 80
7.10 Cancer registries and gynaecological cancer 80
7.11 Relationship between registries and QARC 80
7.12 Developments in the role of cancer registries 80

APPENDIX 1: REPORTING PROFORMAS 83

RCPath datasets for histological reporting of cervical neoplasia (3rd edition) 83

APPENDIX 2: WORLD HEALTH ORGANIZATION HISTOLOGICAL CLASSIFICATION OF TUMOURS OF THE UTERINE CERVIX AND ACCOMPANYING SNOMED CODES 86

APPENDIX 3: HPV TRIAGE AND TEST OF CURE PROTOCOL 88

APPENDIX 4: TNM AND FIGO STAGING OF CERVICAL TUMOURS 89

APPENDIX 5: HANDLING OF SPECIMENS SENT FOR HISTOLOGICAL EXAMINATION 91

Cervical punch/wedge biopsies 91
Cone biopsy and LLETZ 91
Processing/staining 92
Radical trachelectomy 93
Hysterectomy 94

APPENDIX 6: INFORMATION ABOUT CANCER REGISTRIES 98

English regional registries 99
Scotland, Wales, and Northern Ireland 100
National Registry of Childhood Tumours 100
Sources of cancer registration data 101

REFERENCES 103

CONTRIBUTORS

Lynn Hirschowitz *Consultant Pathologist, Birmingham Women's NHS Foundation Trust*	Editor Lead author, Chapter 1 Coauthor, Appendix 5
Alex Albus *Data Flows Project Manager, Trent Cancer Registry*	Coauthor, Chapter 7
Laurence Brown *Consultant Pathologist, Leicester Royal Infirmary*	Lead author, Appendix 5 Coauthor, Chapter 2
Nagindra Das *Gynaecological Oncologist, Royal Cornwall Hospital*	Lead author, Chapter 4
Raji Ganesan *Consultant Pathologist, Birmingham Women's NHS Foundation Trust*	Lead author, Chapter 6 Coauthor, Chapter 2
C Simon Herrington *Professor of Pathology, Division of Cancer Research, University of Dundee*	Coauthor, Chapter 1
Tito Lopes *Gynaecological Oncologist, Royal Cornwall Hospital*	Coauthor, Chapter 4
W Glenn McCluggage *Professor of Pathology, Royal Group of Hospitals, Belfast*	Lead author, Chapters 2 and 3
David Meechan *Director, Trent Cancer Registry*	Coauthor, Chapter 7
Naveena Singh *Consultant Pathologist, Barts and the London NHS Trust*	Coauthor, Chapter 1 Coauthor, Appendix 5
John HF Smith *Consultant Histopathologist and Cytopathologist, Director, East Pennine Cytology Training Centre*	Lead author, Chapter 5 Coauthor, Chapter 6
Alexandra Thackeray *Deputy Director, Trent Cancer Registry*	Coauthor, Chapter 7
Sue Wild *Information Outputs Officer, Trent Cancer Registry*	Lead author, Chapter 7

FOREWORD

Histopathology reporting plays a vital role in the NHS Cervical Screening Programme (NHSCSP). The many high-quality histopathology services around England make a crucial contribution to the central aim of the NHSCSP: to reduce the incidence of, and mortality from, cervical cancer. However, histopathology also plays a structural role within cervical screening, linking together the various elements of the programme. Biopsies form a clinical 'gold standard', against which findings from cytology and colposcopy are correlated, and are therefore critical to multidisciplinary working. They also function as an important indicator of quality, and are used to audit and monitor the effectiveness of each part of the service.

It is therefore with pleasure that I introduce a new edition of NHSCSP publication number 10, *Histopathology Reporting in Cervical Screening.* The first edition of this publication, written by a working group headed by the late Professor Harold Fox, was heralded as a landmark, not simply because it offered clear clinical guidance about the classification of histological conditions and the handling of specimens, but also because it outlined a new, forward-looking emphasis on data collection and service audit.

The current edition updates this guidance for a new era, with the aim of producing a short, clear, readable text. It is testament to the hard work of its authors that the new version in no way falls short of its predecessor. Advice has been revised in the light of new research, and now includes information about recent advances in immunohistochemistry, that allow pathologists to discriminate with greater certainty between particularly awkward benign mimics and cancer. Additionally, the document contains a far greater number of illustrations than the previous edition, and these are in colour to assist with the identification of difficult cases. New policies and procedures are also explained in detail, most significantly those relating to the new national system of human papillomavirus testing for triage and test of cure.

The authors of this publication have also provided a more rounded view of the relationship of histopathology services to the rest of the cervical screening programme. In later chapters, readers will find sections on cytology and colposcopy, which provide a helpful sense of the way in which different elements of the service work together. Up-to-date guidance on service audit and cancer registration information has also been included, with a view to explaining the way in which data are collected and collated. What becomes clear is that this exercise achieves far more than evidencing the programme's effectiveness and efficiency (important though that is) – the information obtained helps to save more lives by shedding valuable light on the aetiology of cervical cancer, by encouraging future research, and by promoting future improvements to the cervical screening programme.

Julietta Patnick
September 2012

PREFACE

It has been an honour to be entrusted with the editing of this revision of NHSCSP Publication No 10, *Histopathology Reporting in Cervical Screening*. The original publication, which it now replaces, was the product of a working party chaired by the late Professor Harold Fox, which was convened under the auspices of the Royal College of Pathologists (RCPath) and the NHS Cervical Screening Programme. The group's remit was to establish standards and guidelines for the reporting and handling of cervical biopsies arising from the Cervical Screening Programme. The document that resulted not only achieved this but also standardised the data collected by the cancer registries and thereby allowed the accuracy and effectiveness of the screening process to be monitored. I gratefully acknowledge the important foundations that the working party laid down.

However, much has changed since NHSCSP No 10 was published 13 years ago, in 1999. The RCPath Cervical Cancer Dataset and the Fédération Internationale de Gynécologie et d'Obstetrique (FIGO) staging system for cervical carcinoma have been revised, and advances in immunohistochemistry have both facilitated the differentiation of benign mimics from preneoplastic conditions of the cervix (cervical glandular intraepithelial neoplasia in particular) and improved the characterisation of a range of cervical tumours. Working in multidisciplinary teams is now standard practice, and the resulting scrutiny of the screening process has raised the standards of both diagnosis and treatment. The screening programme and colposcopy services have evolved, and, as this document goes to press, human papillomavirus (HPV) triage and 'test of cure' are being rolled out nationally. The revision of NHSCSP No 10 incorporates much of this new information, with the aim of producing a practical handbook that gives an integrated overview of all of the subspecialist elements of the Cervical Screening Programme.

This revision includes many more illustrations than its predecessor, and these are now presented in colour. However, it is not the aim to produce an exhaustive reference book or atlas, and illustrations are therefore used to highlight conditions that are unusual or that present diagnostic difficulty. The chapters describing the histopathological features of cervical squamous and glandular neoplasia have also been expanded to include more detail about preinvasive disease, tumours, and benign mimics, and to provide advice on the use of immunohistochemical markers to assist with the diagnosis of problematic or unusual conditions. In addition, a new chapter on uncommon cervical tumours has been added. This pays particular attention to neuroendocrine tumours, reflecting the clinical importance of recognising this subtype of cervical carcinoma, which carries a particularly poor prognosis.

My brief in producing this publication was to include in one volume 'everything that anyone reporting cervical biopsies for the cervical screening programme needs to know'. The revised publication has therefore been expanded to provide more information for pathologists about the screening process in general. A short chapter on cytology is included for the benefit of those histopathologists reporting on behalf of the NHSCSP, who neither report cervical cytology nor have cytology laboratories affiliated to their pathology laboratories. This provides all of the information relevant to the programme, albeit in an abridged form, including information about follow-up protocols and HPV triage. As histological findings should also be correlated with appearances at colposcopy, a short chapter on the latter has been included to ensure that histopathologists are aware of the indications for colposcopic referral, the methods of treatment available at colposcopy, and the protocols for the follow-up of histologically confirmed preinvasive and invasive disease. Inclusion of these two chapters emphasises the importance of working in multidisciplinary teams – an essential requirement for audit of the screening process.

The chapter on audit and quality assurance has been expanded to include RCPath key performance indicators, NHSCSP standards for laboratories (and pathologists), and guidance on auditing invasive cervical carcinoma, colposcopy, and histopathology reports. Finally, the importance of providing accurate information to cancer registries for the purposes of cancer registration is covered in a separate chapter, which also details the relationships of the registries with other national organisations.

I am grateful to the contributors for their timely and informative submissions and to my husband, Seth Love, who patiently supported me during the many hours of writing and editing and provided particular assistance with the preparation of photomicrographs. I am deeply indebted and sincerely grateful to Dr Kiera Chapman (Policy and Publications Editor, NHSCSP) without whose meticulous help and support this publication would not have been possible. Dr Chapman coped uncomplainingly with my idiosyncrasies and demands, and transformed this publication into something that I hope will enhance the understanding by histopathologists of the different components of the cervical screening programme, and help them to provide the best possible diagnostic service to support it.

Lynn Hirschowitz
September 2012

1 CERVICAL SQUAMOUS NEOPLASIA: PRECURSORS, TUMOURS, AND BENIGN MIMICS

1.1 Terminology and grading

As stated in the previous edition of this publication, the use of existing cervical intraepithelial neoplasia (CIN) terminology for the histological reporting of squamous intraepithelial neoplasia is recommended. The main advantages of the three-tier grading system (CIN1, CIN2, and CIN3) are that it permits direct correlation with the cytological grades of dyskaryosis and that it ensures continuity in the recording, transfer, and storage of coded data to existing local, regional, and national databases. Collection and analysis of these data is necessary to evaluate the effectiveness of the cervical screening programme.

When providing guidance for patient management, the three-tier grading system is of limited value. For practical purposes, patient management is based on a two-tier grading system of low- (CIN1) and high-grade (CIN2 and CIN3) abnormality (see Chapter 4).

Although the histological features of CIN are well described,[1–3] considerable interobserver variability in the grading of CIN exists, particularly in lesions at the lower end of the spectrum.

1.2 Morphological features of CIN

The defining histological features of CIN are nuclear abnormalities, alterations in epithelial maturation, and the presence of mitotic activity.[4]

1.2.1 Nuclear abnormalities

Nuclei are enlarged, of variable size, and show irregularity in their shape and contour. Hyperchromasia and irregular chromatin clumping are present, and the nuclear membrane may be wrinkled. The nuclear : cytoplasmic ratio is increased and the polarity of the nuclei may be altered, giving a disorganised arrangement. The term ‘nuclear atypia’ encompasses this range of nuclear changes.

- Prominent nucleoli are uncommon in preinvasive lesions, whereas they may be prominent in reactive atypia.
- Nuclear atypia is often random and variable in CIN, whereas reactive nuclear atypia is more homogeneous in distribution.
- Neoplastic nuclear atypia correlates closely with alterations in epithelial maturation.

1.2.2 Alterations in epithelial maturation

The term ‘maturation’ tends to be used synonymously with epithelial differentiation in the cervix. As squamous epithelial cells mature, the nuclear : cytoplasmic ratio decreases towards the epithelial surface, so that the cytoplasmic component predominates in superficial cells.

The proportion of the epithelium that shows maturation is one of the features used to grade CIN. There is little or no epithelial maturation in CIN3. Instead, immature and atypical squamous cells extend through the full thickness of the epithelium, so that cells with a high nuclear : cytoplasmic ratio are present at the epithelial surface. In CIN1, by contrast, maturation occurs in the upper two-thirds of the epithelium, and a low nuclear : cytoplasmic ratio is observed in squamous cells towards the surface. However, mild nuclear atypia involving the full thickness of the epithelium is a characteristic of CIN1.

1.2.3 Mitotic activity[5,6]

Normal cervical squamous epithelium shows minimal mitotic activity. When present, it is confined to the parabasal layers. Most, but not all, cases of CIN show increased mitotic activity. Mitoses may be present at all levels of the epithelium, and may appear in the superficial third as the grade of CIN increases. Atypical mitotic figures are seen (Figure 1A); these reflect aneuploidy.

1.2.4 Criteria for the diagnosis of CIN1 (Figure 1B)

Nuclear atypia is essential to the diagnosis of CIN1. Some degree of nuclear abnormality extends through the full thickness of the squamous epithelium, but atypical nuclei are most prominent in the basal third, with cytoplasmic maturation in the upper two-thirds. Normal mitotic figures may be increased, and the presence of abnormal mitoses supports the diagnosis. CIN1 may be identified in immature and atrophic squamous epithelium and is often seen in association with human papillomavirus (HPV) infection. Not all of these criteria for the diagnosis of CIN1 are found in every case.[2,7,8]

1.2.5 Criteria for the diagnosis of CIN2 (Figure 1C)

Nuclear atypia extends through the full epithelial thickness and is more marked than in CIN1. Cytoplasmic maturation is present in the upper third of the epithelium, and mitotic figures (including abnormal forms) are increased throughout; atypical mitotic figures may be common.

1.2.6 Criteria for the diagnosis of CIN3 (Figure 1D)

Maturation may be absent, or confined only to the superficial epithelial layers. Nuclear atypia is severe and distributed through the full epithelial thickness. Mitoses may be numerous and found at all levels of the epithelium, and abnormal forms are frequent.

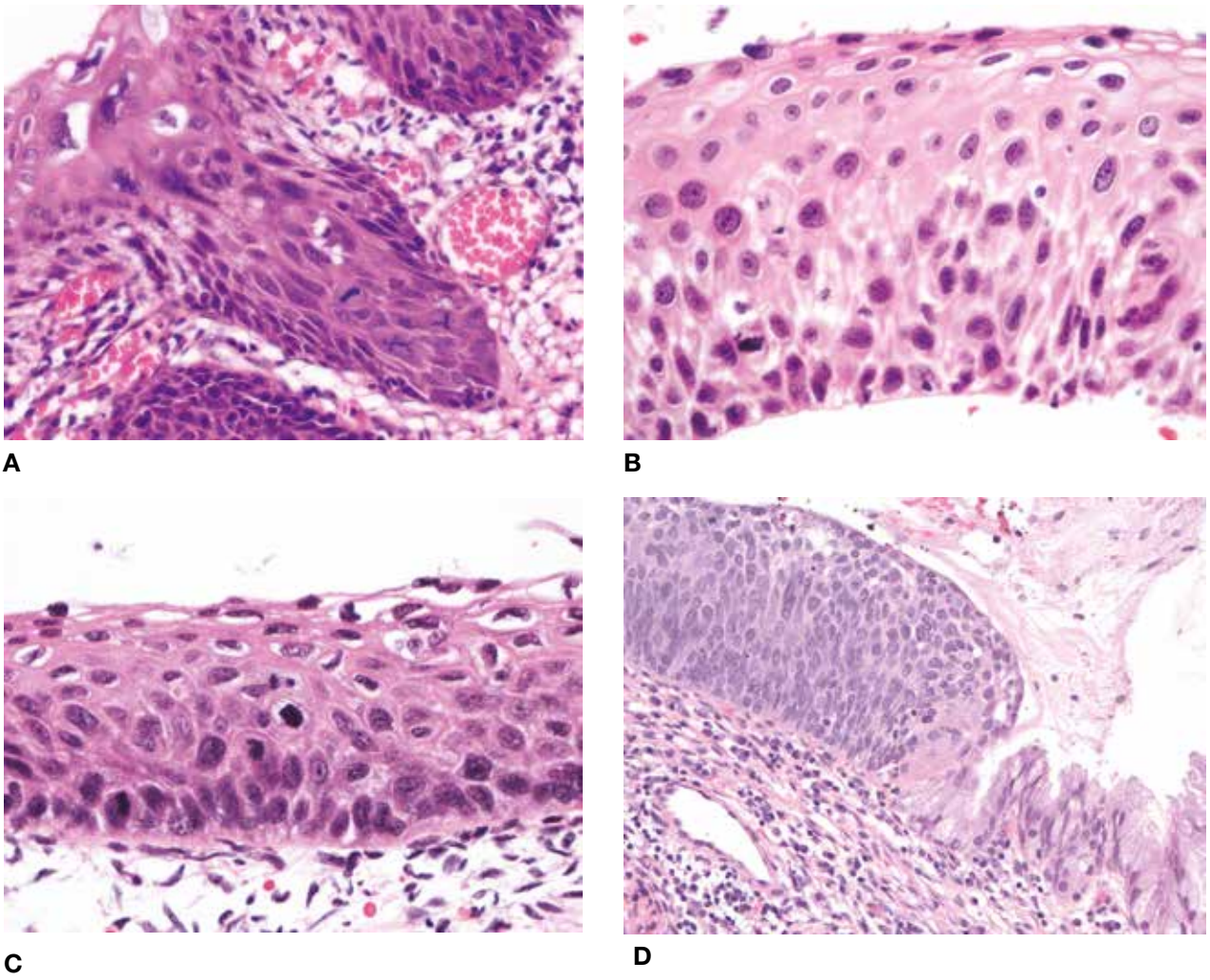

Figure 1 CIN. (A) Mitotic activity is increased in CIN and atypical mitotic figures are seen. (B) In CIN1, nuclear atypia extends through the full thickness of the squamous epithelium, but atypical nuclei are most prominent in the basal third. Cytoplasmic maturation is present in the upper two-thirds of the epithelium, where koilocytosis is also visible. (C) In CIN2, nuclear atypia extends through the full epithelial thickness and is more marked than in CIN1. Cytoplasmic maturation is present in the upper third of the epithelium, where there is also koilocytosis. (D) In CIN3, nuclear atypia is severe and distributed through the full epithelial thickness. Maturation is absent in this example. All staining is standard H&E (haematoxylin and eosin), unless otherwise specified.

1.2.7 Reporting CIN

- Grading of CIN may not be possible in thin, metaplastic epithelium, or where the surface epithelium is incomplete. In these circumstances, even where nuclear atypia is present, a diagnosis of 'ungraded CIN' should be made. If possible, the pathologist should give some indication as to whether the CIN is likely to be of low or high grade to assist with patient management.
- The presence of endocervical crypt involvement should be reported. A complex architecture may sometimes result from extensive involvement of endocervical gland crypts, and here care is needed to avoid misinterpreting near-confluent crypt involvement as invasive squamous carcinoma. When distinguishing between crypt involvement and invasive carcinoma, the rounded crypt profiles of the former are helpful.
- Expansile CIN3 is the term used where there is extensive involvement and expansion of the underlying endocervical glands. There is often central necrosis within the glands replaced by CIN3, and intraepithelial squamous maturation may also be observed. This variant of CIN3 is more likely than others to be associated with early invasion, and it is recommended that levels are performed in such cases to exclude this possibility.[9]
- The grade of CIN in the biopsy or large loop excision of the transformation zone (LLETZ) must be correlated with the grade of dyskaryosis in the cytology report.[10] The cytology findings represent the lowest grade of abnormality that might be expected in the biopsy, and the identification of CIN3 in a woman with a cytological result of low-grade dyskaryosis should not be regarded as failure of the screening programme. Lower grades of CIN may be identified in areas adjacent to squamous mucosa showing higher-grade CIN, and it is therefore helpful for the pathologist to mention all grades of CIN present in the histology report. When issuing the histology report, the pathologist must take care to record all pathological lesions (neoplastic and non-neoplastic) that may be associated with, or account for, the reported cytological changes.[11]
- To ensure that CIN is not overlooked in biopsy material, it is recommended that levels are cut from cervical punch biopsies and cervical biopsies of unspecified type. Three levels are recommended, and routine step-sectioning is not necessary. For cervical cone biopsies, loop biopsies/LLETZ, and cervical wedge biopsies, an initial single level from each block is likely to be sufficient. Deeper levels may be required if the findings in the initial sections do not correlate with the antecedent cervical sample. A single further level has been shown to be adequate for the assessment of specimens in which the surface epithelium or squamocolumnar junction is missing, or where there is a discrepancy with results from the cervical sample.[11,12]
- If a biopsy or excision specimen cannot be assessed because of epithelial loss, electrothermal or crush artefact, this must be stated in the report.
- The use of a standardised reporting proforma for CIN in excisional biopsies is recommended (Appendix 1). Systemised Nomenclature of Medicine (SNOMED) codes must be assigned (Appendix 2).

1.2.8 HPV-associated changes (Figure 2)

The koilocyte is said to be a pathognomonic feature of HPV infection. Koilocytes show variation in nuclear size of at least three-fold,[13] nuclear hyperchromasia, and irregularity of the nuclear membrane, imparting a 'raisinoid' appearance. Perinuclear halos, cytoplasmic clearing, and binucleation are commonly seen, but may also be features of reactive cellular changes, making it difficult to differentiate between the two. However, in koilocytes, the perinuclear halo should be sharply demarcated with a 'hard' edge that results from cytoplasmic membrane thickening.

Additionally, it is important to note that other viral infections can cause, or be associated with, changes similar to those produced by HPV, and that HPV infection may be present in the absence of koilocytes. Other cytological features that are associated with HPV infection are: multinucleation, individual cell keratinisation, parakeratosis, acanthosis, and papillomatosis.[14] HPV-associated features should be carefully and consistently reported in all biopsies. As noted in the previous edition of this document:

- Lesions in which there is only koilocytosis should be reported as 'koilocytosis only'.
- Lesions with all or most of the following should be described as showing 'HPV-associated features': koilocytosis, multinucleation, individual cell keratinisation, parakeratosis, acanthosis, or papillomatosis.
- Lesions with acanthosis, a papillary, exophytic architecture, and/or hyperparakeratotic spiky projections should be reported as 'condyloma acuminatum'.

CIN and koilocytosis often coexist, and CIN should be graded using the criteria described above. However, pathologists should be mindful that nuclear changes may be exaggerated in the presence of HPV infection, and that this can result in an overgrading of CIN.

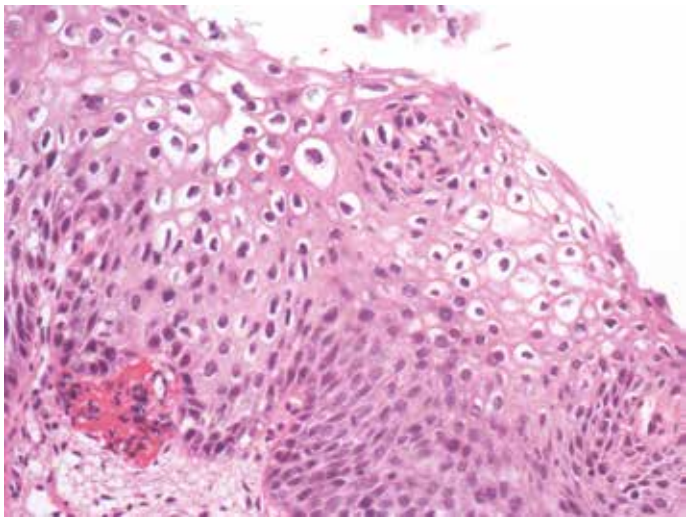

Figure 2 HPV-associated changes. Koilocytes are prominent, characterised by perinuclear halos with cytoplasmic clearing, nuclear hyperchromasia, irregularity of the nuclear membrane, and variation in nuclear size.

1.2.9 Immunoprofile of CIN[15]

Immunohistochemical markers may be helpful in distinguishing CIN from benign mimics (see section 1.5):

- p16 is typically diffusely positive in CIN, due to the presence of high-risk HPV (HR-HPV) infection. Staining is both nuclear and cytoplasmic. Note that lesions associated with low-risk HPV infection are p16 negative or show only focal positivity.
- The MIB1 proliferation index is increased. As the grade of dysplasia increases, so the percentage of MIB1-positive epithelial cells rises, with positive cells seen in the higher levels of the epithelium.[16] MIB1 reactivity may also be helpful for the assessment of cauterised resection margins.[17]
- ProExC (a cocktail of antibodies against topoisomerase II-alpha and minichromosome maintenance 2 proteins) is overexpressed in CIN.[18]

1.2.10 Management[19]

Once a diagnosis of CIN is confirmed histologically, management is as follows:

- CIN1 does not necessarily require treatment, but untreated patients must be followed in primary care or in clinic until regression occurs, treatment is undertaken, or the woman becomes HPV negative.
- Treatment of CIN2 and CIN3 is usually by local excision.
- Although there is a higher incidence of recurrence with endocervical resection margin involvement,[20] women under 50 years old with margin involvement may be followed with colposcopy and cytology, whereas women over 50 years old should be offered treatment (hysterectomy) rather than surveillance.
- Hysterectomy may be performed in older patients and those with other pathology, such as uterine fibroids.

1.3 FIGO stage I cervical squamous carcinoma

1.3.1 Definition and general comments

The term ‘microinvasive carcinoma’ does not appear in the FIGO staging system for cervical cancer and has different connotations in the UK and North America. In most, but not all, institutions in the UK, ‘microinvasive carcinoma’ is applied to FIGO stage IA1 and IA2 tumours, whereas in the United States, the term is synonymous with stage IA1 disease only.[21] The American Society of Gynecologic Oncology (SGO) defines FIGO stage IA tumours by the depth of stromal invasion and also by the absence of lymphovascular invasion. Cancers that invade more than 3 mm, or those invading less than 3 mm with lymphovascular invasion, are classified as FIGO stage IB.[22]

The British Association of Gynaecological Pathologists (BAGP) Working Group therefore recommends using the specific FIGO stage as a descriptor[23] and avoiding the term ‘microinvasive carcinoma’.

1.3.2 Morphological features of stromal invasion (Figure 3)

An obvious infiltrative growth pattern may be evident, even though the carcinoma is small. The following features may be helpful in identifying stromal invasion (pathologists should be mindful that not all of the features of invasion are present in every case):

- The absence or loss of a sharply-defined basement membrane (Figure 3A–C).
- Small, angulated buds of atypical squamous epithelial cells with a more differentiated or 'hypermature' appearance (so-called 'paradoxical' differentiation). The buds arise from surface epithelium with CIN3, or from gland crypts involved by CIN (Figure 3B,C), and it is not uncommon to find several of these. Some may be continuous with the dysplastic epithelium from which they originate, while others may be detached.
- The presence of 'hypermature' squamous cells, which typically have more abundant eosinophilic cytoplasm than the CIN3 from which they arise (Figure 3A–C). The nuclei are pleomorphic and may contain nucleoli or exhibit altered nuclear polarity. The cells may sometimes show dyskeratosis.

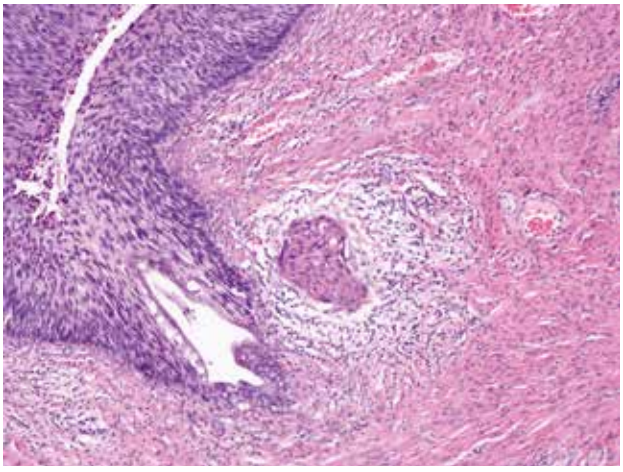

A

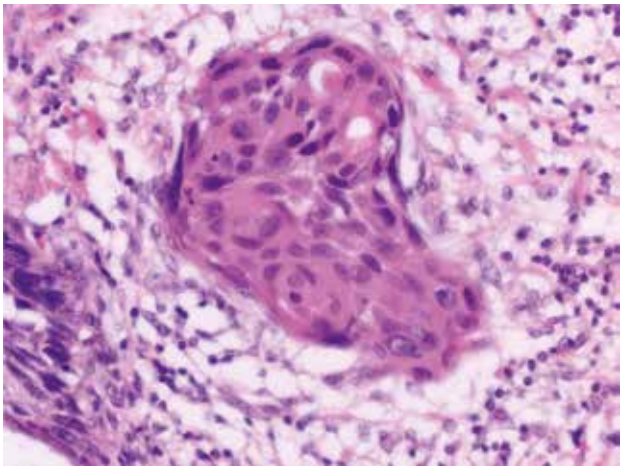

B

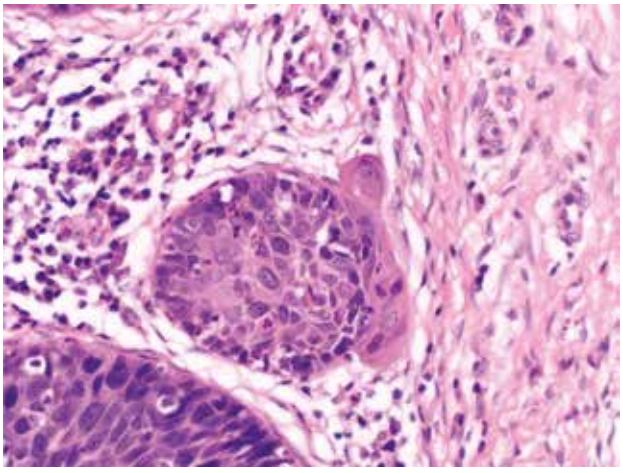

C

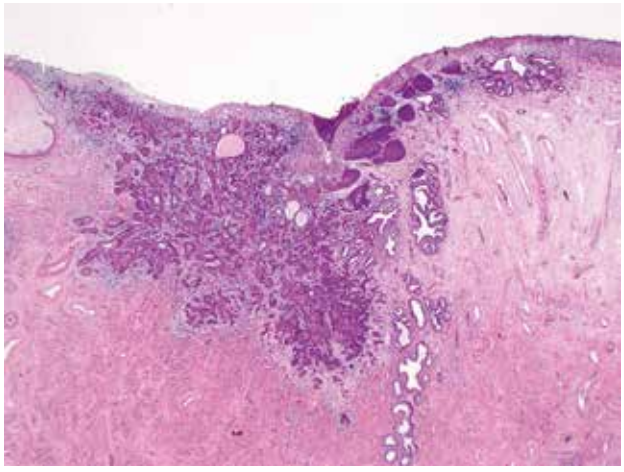

D

Figure 3 Stromal invasion. (A) There is an inflammatory and oedematous stromal reaction around the focus of stromal invasion. (B) The loss of a sharply defined basement membrane and the angulated contour of the invasive focus are more obvious at high magnification. (C) Small buds of atypical squamous epithelial cells have breached the basement membrane of a gland crypt involved by CIN and have a more differentiated or 'hypermature' appearance. (D) Confluent 'spray bud' pattern of stromal invasion, with tiny nests and 'tongues' of hypermature, invasive squamous cells.

- A stromal reaction (Figure 3A–C), which may be inflammatory, oedematous, or desmoplastic.
- Loss of the orderly basal epithelial palisade in the atypical epithelial buds.
- Different patterns of stromal invasion: a 'spray bud' pattern (which comprises tiny nests of hypermature squamous cells), a confluent pattern, and a pattern with invasive 'tongues' (Figure 3D). Clinical outcome is strongly influenced by the depth of invasion but not by the pattern of invasion.[24]

1.3.3 Measurement of stromal invasion (Figure 4)

Two tumour dimensions are required for FIGO staging. However, although FIGO provides guidance on measuring the depth of invasion, it does not specify how to measure width or horizontal spread/ lateral extent.

Tumour volume is said to be the most reliable prognostic factor for early stage tumours,[25–27] but, for practical purposes, measurement of tumours in two dimensions (depth and maximum width) is adequate, as the combination of these measurements gives an indication of volume.[28] As invasion may occur in consecutive sections of a loop or cone biopsy, it is recommended that pathologists measure the horizontal spread not only in an individual section (i.e. across the second dimension of the tumour) but also in adjacent blocks (i.e. in a third dimension) to determine the maximum width of the tumour. This also allows a more accurate estimation of volume.

- **Depth of invasion** must be measured in all cases. This measurement is taken from the base of the epithelium (surface or glandular) from which the carcinoma arises, as specified in the FIGO classification (Figure 4a–c). If there is no obvious epithelial origin, the depth must be measured from the tumour base (the deepest focus of tumour invasion) to the base of the nearest surface epithelium (Figures 4d and 5A).
- **Horizontal spread/width/lateral extent** (Figure 4e) of unifocal tumours must be measured using the section in which the width of the tumour is greatest. The measurement is from one lateral edge of the tumour to the other. The measurement of width is not limited to the confluent component of the tumour (Figure 5B). The frequency of residual neoplasia correlates with the lateral extent of an invasive carcinoma's spread.[29]
- **A third dimension** (Figure 6). Invasive carcinoma can also be measured in three or more consecutive blocks of a loop or cone biopsy and may exceed 7 mm in its third dimension, i.e. the carcinoma may be more than FIGO stage IA2. In such cases, this dimension should be determined by calculating the block thickness from the macroscopic dimensions of the specimen and multiplying this by the number of contiguous blocks through which the invasion extends.
- **Resection margins**. In small, completely excised FIGO stage I tumours, the closest resection margin should be reported. The distance (in millimetres) of the carcinoma and CIN from the closest margin should be provided.

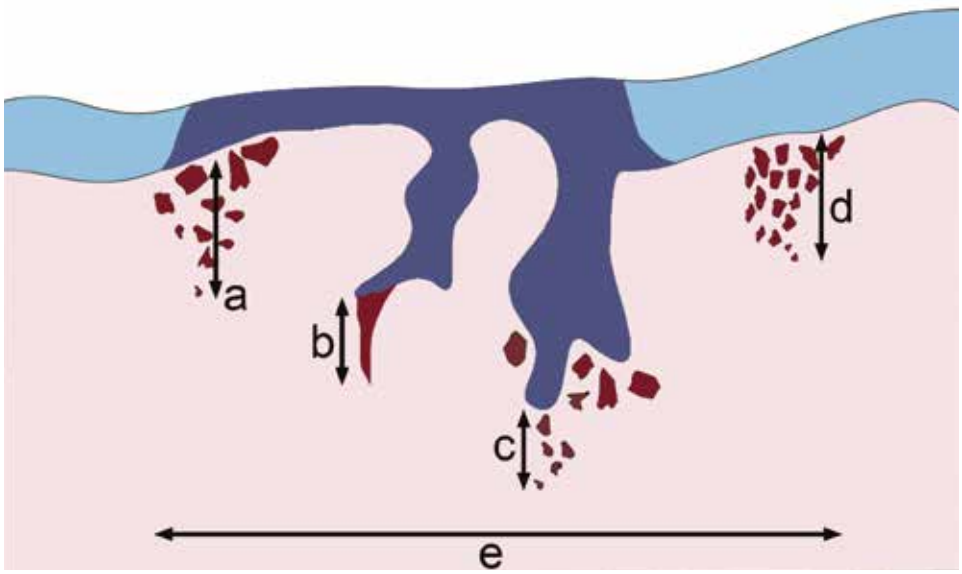

Figure 4 Measurement of stromal invasion. CIN3 with involvement of endocervical gland crypts is represented by the darker blue areas, non-dysplastic squamous epithelium is lighter blue, and dark brown areas indicate foci of stromal invasion. **Depth of invasion:** when invasion originates from the surface epithelium (a) or gland crypts (b and c), the depth of invasion is taken from the base of the epithelium from which the invasive carcinoma arises to the deepest focus of invasion, as specified in the FIGO classification. Measurements are taken in the same way, regardless of whether the invasive foci remain attached to the gland crypt (b) or not (c). Where invasion occurs and no obvious surface (or crypt) epithelial origin is seen, the depth of invasion is measured from the deepest focus of tumour invasion to the base of the nearest non-neoplastic surface epithelium (d). **Maximum horizontal dimension/width** (e): this is measured in the piece of tissue in which the width is greatest (from the edge at which invasion is first seen to the most distant edge at which invasion is identified) in sections where the foci of invasion arise in close proximity to each other, even if those foci are separated by short stretches of normal epithelium.

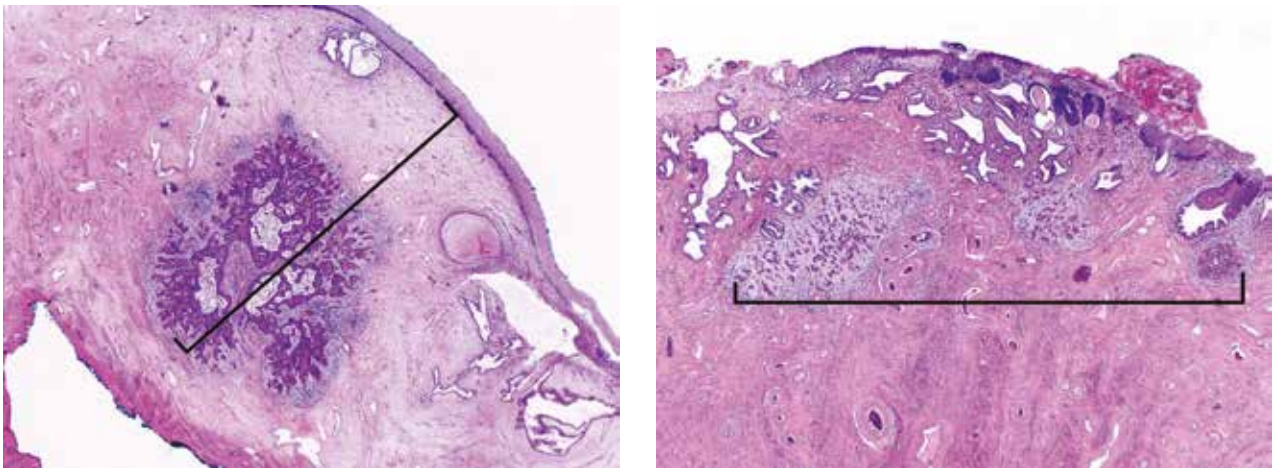

A **B**

Figure 5 Measurement of stromal invasion. (A) If there is no obvious epithelial origin, the depth must be measured from the deepest focus of tumour invasion to the base of the nearest surface epithelium. (B) In this unifocal tumour, the width/lateral extent must be measured from one lateral edge of the tumour to the other. The measurement of width is not limited to the confluent component of the tumour.

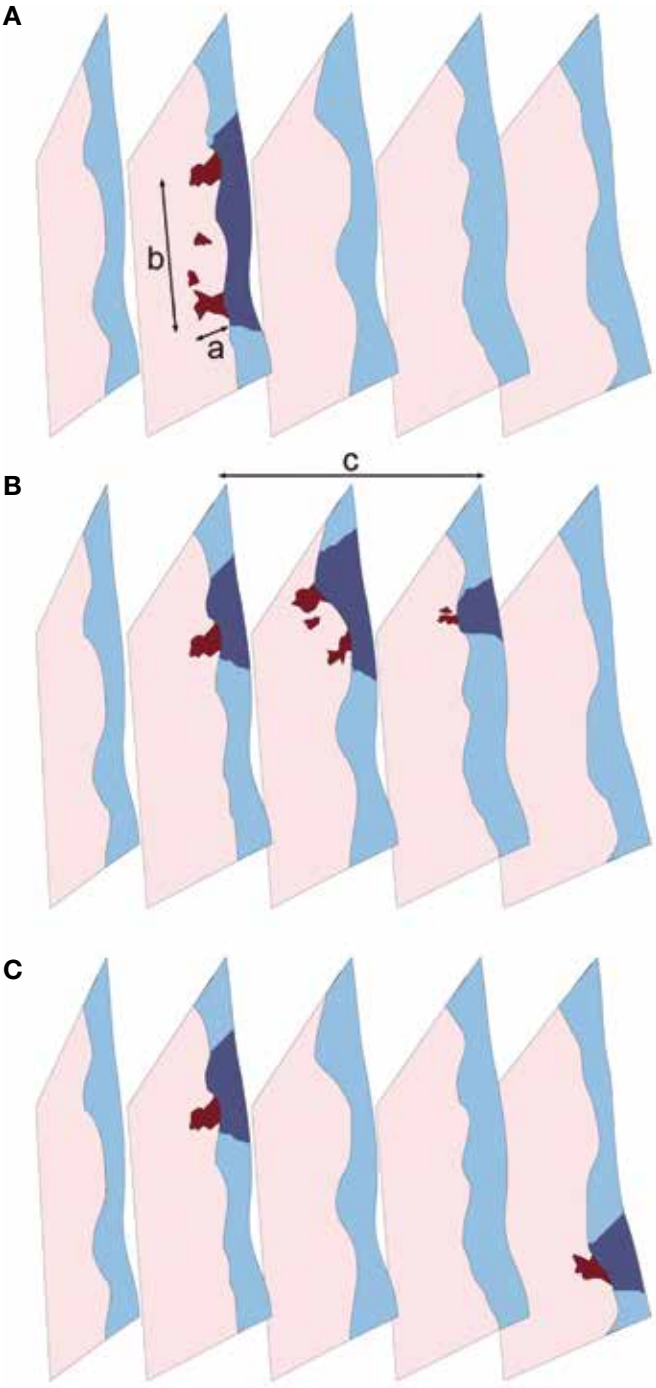

Figure 6 Measurement of stromal invasion: third tumour dimension and multifocal disease. CIN3 with involvement of endocervical gland crypts is represented by the darker blue-coloured areas, non-dysplastic squamous epithelium is lighter blue, and dark brown areas indicate foci of stromal invasion. The depth of invasion (a), and maximum horizontal tumour dimension/ width (b) are measured in unifocal disease (A) as described in section 1.3.3. **Third dimension:** when stromal invasion is present in three or more consecutive blocks of a loop or cone biopsy the third tumour dimension (B) may exceed 7 mm, i.e. the carcinoma may be more than FIGO stage IA2. This dimension is determined by calculating the block thickness (usually 2.5–3.0 mm) from the macroscopic specimen dimensions and multiplying this by the number of sequential blocks through which the invasion extends. **Multifocal disease:** the foci of invasion are separated by blocks of uninvolved cervical tissue (C). The current recommendation is to measure each focus of invasion separately. The multifocal tumour should be staged on the basis of the dimensions of the largest focus, but dimensions of all the invasive foci must be provided. Such cases must be referred for central review and multidisciplinary team discussion.

1.3.4 Multifocal disease (Figure 6)

Cervical carcinoma is caused by HR-HPV infection, which has the potential to produce a field change in the cervical epithelium so that more than one focus of neoplastic transformation may arise. Multifocal stromal invasion can be detected in up to 12% of carcinomas.[30]

It is important not to overstage multiple FIGO stage IA1 or IA2 tumours as FIGO stage IB simply because they arise separately within the same area of field change, as this can lead to inappropriate

treatment. There is no good evidence to support the recommendation that each focus of invasion is measured separately, and the separate dimensions added together to give a single measurement of horizontal tumour spread.[31] Such a method attributes the same biological potential to multiple small tumours (which may be biologically insignificant in their own right) as that ascribed to a large, invasive tumour.

Multifocal disease is diagnosed if foci of invasion are:

- Separated by blocks of uninvolved cervical tissue (levels must be cut to exclude invasion), or
- On separate cervical lips, or
- Situated far apart from each other in the same section.

The individual foci of stromal invasion may be attached to, or discontinuous from, the epithelium from which they arise.

The current recommendation is that each focus of invasion is measured separately and that staging of multifocal tumours is based on the dimensions of the largest focus. However, the pathology report must state clearly that the tumour is multifocal in origin, must provide the dimensions of all of the separate foci of invasion, and must indicate how the FIGO stage has been ascertained. Such cases should to be referred to cancer centres for review, and should be discussed at the multidisciplinary team meeting (MDTM).

1.3.5 Management of early-stage invasive squamous carcinoma

Treatment may be modified according to age, patient wishes, and the need to preserve fertility.

- The recommended treatment of FIGO stage IA1 carcinomas is by local excision with resection margins that are clear of both CIN and invasive disease.[32,33]
- Radical hysterectomy is usually undertaken for FIGO stage IA2 and IB1 carcinomas, although in some institutions, IA2 carcinomas are treated by local excision.
- If fertility preservation is desired, trachelectomy may be considered for FIGO stage IA2 tumours and small stage IB1 carcinomas.

1.4 Classification and grading system for cervical squamous carcinoma

1.4.1 Definition and general comments

The World Health Organization (WHO) classification is used for cervical squamous carcinoma (Appendix 2).[34] Although the WHO recognises several variants of squamous carcinoma, in practice the different variants often overlap. Squamous carcinomas are graded according to the modified Broder's system, which classifies them as well-, moderately-, or poorly-differentiated, based on the degree of nuclear pleomorphism, mitotic activity, and keratinisation observed. However, a weakness of this system is the poor correlation between grade and prognosis.[35] Other grading systems, e.g. Stendahl, or invasive front grading, correlate better with prognosis but are too time-consuming for routine use.[36,37]

All cervical squamous carcinomas, like adenocarcinomas, must be clinically staged according to the revised FIGO system.[38] Lymph node status must be recorded separately or captured within the TNM (tumour, node, metastasis) staging system, depending on local preference.[39]

Almost all squamous carcinomas are HPV related, except for a few reported cases of lymphoepithelioma-like carcinoma in the Asian population, which may be related to Epstein–Barr virus (EBV) infection.[40]

1.4.2 Squamous cell carcinoma (not otherwise specified)

The following features characterise squamous cell carcinoma:

- The cell type, differentiation, and growth pattern vary, and there may be morphological heterogeneity even within individual cases.
- The degree of cytological atypia and keratinisation vary.
- Mitotic activity is usually increased and includes atypical forms.
- The tumour cells infiltrate as anastomosing tracts, nests, groups, compact or irregular sheets, and, in some cases, as cords, trabecular structures, or individual cells.
- In small or early tumours, an in situ component of CIN may be seen. This may create difficulties in differentiating between crypt involvement and invasive tumour nests. A distinguishing feature of invasive tumour nests is the presence of angulated, jagged contours; in contrast, involved crypts tend to have smooth, rounded contours. A desmoplastic stromal response is also a helpful indicator of invasion, as is the presence of lymphovascular and perineural invasion.
- Necrosis may be present, and may be of comedo type.

Immunoprofile:

- Detection of nuclear p63 is useful to confirm the diagnosis in poorly-differentiated tumours.

1.4.3 Squamous cell carcinoma – keratinising

By definition, these tumours require keratin pearl formation for their diagnosis. The pearls comprise concentric whorls of squamous epithelium with central nests of acellular keratin. Individual cell keratinisation (dyskeratosis) can occur, but without squamous pearl formation this is insufficient for a diagnosis of keratinising squamous carcinoma.

Keratinising squamous carcinoma is characterised by:

- Tumour growth in nests and cords.
- Tumour cells that appear large and mature, with moderate amounts of eosinophilic cytoplasm.
- Prominent intercellular bridges.
- Mitotic activity that is less prominent than in the non-keratinising variant.

1.4.4 Squamous cell carcinoma – non-keratinising

No squamous pearls are present, although there may be individual cell keratinisation. Also:

- Tumour growth is usually in sheets, small groups, or nests.
- The tumour cells are large and polygonal in shape, with sharp cell borders. Intercellular bridges are less prominent than in the keratinising type.
- Nuclear pleomorphism may be prominent and mitotic activity brisk.
- Mucin histochemistry is helpful in excluding poorly-differentiated adenocarcinoma. Poorly-differentiated tumours that lack keratinisation or intercellular bridges and contain many mucin-producing cells should be diagnosed as 'poorly-differentiated adenocarcinoma'.[34]

Immunoprofile:

- Pancytokeratin, CK5/6, or p63 may be required to identify poorly-differentiated squamous carcinomas.
- Neuroendocrine markers (synaptophysin, chromogranin, and CD56) can exclude large cell neuroendocrine carcinoma.

1.4.5 Basaloid squamous carcinoma (Figure 7)

These tumours resemble the corresponding tumours of the vulva and vagina. Keratin pearls are not seen, but foci of keratinisation and squamous differentiation may be present. Additionally:

- Tumour growth is in sheets and nests.
- The tumours are composed of small, basaloid cells with scanty cytoplasm.
- Tumour cell nuclei are small and hyperchromatic.
- Mitotic activity is brisk.
- Necrosis is common.

Immunoprofile:

- CK5/6 or p63 can be used in some cases to confirm the diagnosis.
- Neuroendocrine markers (synaptophysin, chromogranin, and CD56) can exclude neuro-endocrine carcinoma.

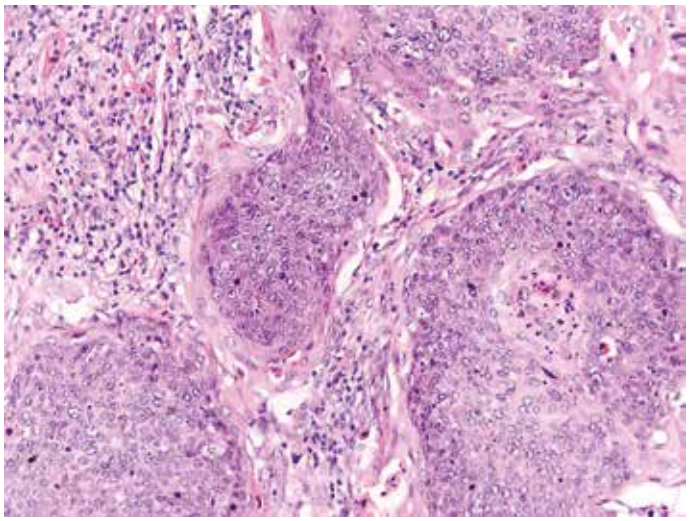

Figure 7 Basaloid squamous carcinoma. The tumour is composed of small, basaloid cells with scanty cytoplasm. Foci of squamous differentiation and keratinisation can be seen in the centre of the basaloid islands.

1.4.6 Verrucous carcinoma

This variant of squamous carcinoma is very rare and typically shows very bland cytological features and a bulky exophytic growth pattern. Appearances are identical to counterparts in the anogenital tract. The tumours occur in older women, are usually associated with HPV 6 infection,[28] and are slow growing and indolent in their behaviour, with a tendency to impinge on local structures rather than to infiltrate them. Correct diagnosis ensures appropriate treatment, which is wide local excision. Lymphadenectomy is not required, nor do these tumours respond to radiotherapy. There is a propensity for local recurrence but not metastasis. Features that may be found include:

- Exophytic growth at the tumour surface, but growth along a broad, 'pushing' invasive front at the base; rete pegs are typically described as 'bulbous'.
- Minimal cytological atypia, even at the pushing front.
- Low mitotic activity (this is basal when present).
- Presence of keratin whorls within the epithelium or on the tumour surface.
- Lack of single cell infiltration or tumour nests.

Exophytic condylomata may resemble verrucous carcinoma. The presence of fibrovascular cores in the papillary projections on the surface of condylomas is a helpful distinguishing feature. A biopsy of sufficiently large size to include the base of the tumour is required for diagnosis.

1.4.7 Warty carcinoma

This uncommon variant of squamous carcinoma, also known as condylomatous squamous carcinoma, resembles the vulval counterpart.[41] The tumours have an exophytic, papillomatous surface and show cytological features of HPV infection.

1.4.8 Papillary squamous carcinoma

This tumour is characterised by a papillary, exophytic architecture. The papillae have fibrovascular cores and are covered by squamous epithelium, in which there is moderate to severe dysplasia, which resembles CIN. This type of carcinoma must be distinguished from other variants of squamous carcinoma with an exophytic, papillary component, for example warty, verrucous, and squamotransitional cell carcinoma.

- Unlike warty squamous carcinoma, papillary carcinoma lacks keratinisation and cytological features of HPV infection, despite an association with HPV 16.[28]
- There may be typical squamous carcinoma underlying the exophytic surface component, and this differentiation distinguishes papillary carcinoma from squamotransitional carcinoma. Superficial biopsies may not provide adequate material for diagnosis.
- Slender papillary projections at the tumour surface distinguish papillary squamous carcinoma from verrucous carcinoma. The former shows features of typical squamous carcinoma in its depths.

1.4.9 Lymphoepithelioma-like carcinoma (Figure 8)

Lymphoepithelioma-like carcinoma most commonly affects younger, Asian women.[42] EBV has been demonstrated in tumours affecting Asian women,[40] but in Caucasian women HPV is more likely to play a role.[43]

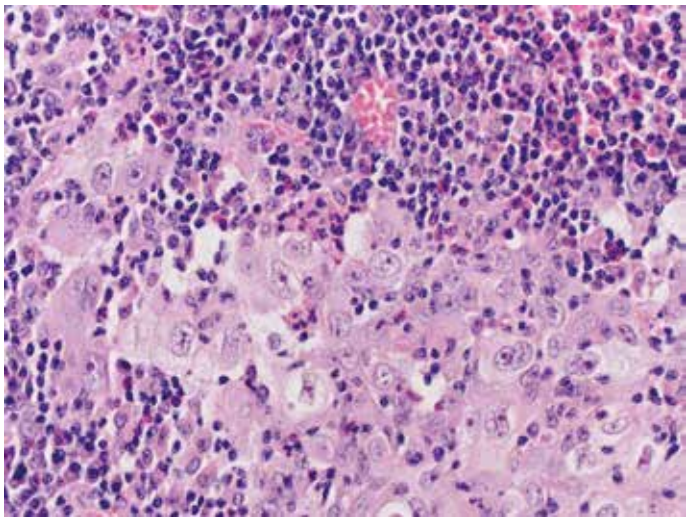

Figure 8 Lymphoepithelioma-like carcinoma. The squamous carcinoma is partly obscured by large numbers of lymphocytes, which infiltrate and erode the nests of carcinoma cells, imparting a syncytial-like appearance.

Lymphoepithelioma-like carcinomas are associated with a favourable prognosis and a low incidence of node metastases.[44] Appearances are similar to the corresponding lymphoepithelioma-like carcinomas of the nasopharynx.

- The malignant squamous element is partly obscured by large numbers of lymphocytes, which infiltrate and erode the groups and nests of carcinoma cells, imparting a syncytial-like appearance to the groups.
- The tumour is composed of cells of uniform appearance with large vesicular nuclei, prominent nucleoli, and moderate amounts of indistinct eosinophilic cytoplasm.
- Most of the infiltrating lymphocytes mark as T cells.

Immunoprofile:

- Staining for cytokeratins can be helpful in diagnosing this carcinoma.

1.4.10 Squamotransitional carcinoma

These rare papillary tumours occur mainly in postmenopausal women. They are potentially aggressive, show varying proportions of squamous and transitional components, and resemble papillary transitional cell tumours of the urinary tract.[45] HR-HPV has been identified in squamotransitional carcinoma.[46] Differentiation from other cervical tumours with a papillary architecture is important (see section 1.4.8). There is a suggestion that squamotransitional carcinomas have a propensity for late metastasis and local recurrence.

- The papillae over the tumour surface have fibrovascular cores, which are covered by multilayered, dysplastic epithelium that may resemble CIN.
- Superficial or deep invasion of the underlying stroma may be present, and deep biopsy is recommended to identify any invasive component and to avoid the potential for misinterpreting superficial biopsies as CIN3 with a papillary architecture.
- There is no evidence of any relationship to transitional metaplasia.[47,48]

Immunoprofile:

- CK7 is usually positive; CK20 is expressed in only a small proportion of cases.[45]

1.5 Benign mimics of CIN

Several non-neoplastic changes can result in histological appearances that resemble CIN. Recognising these can avoid misdiagnosis and unnecessary treatment and ensure correct interpretation of cytological changes.

1.5.1 Squamous metaplasia and immature squamous metaplasia (Figure 9)

This physiological process occurs in the transformation zone and involves the replacement of endocervical glandular epithelium by squamous epithelium, as subcolumnar reserve cells proliferate and undergo squamous differentiation (Figure 9A). When maturation is complete, this epithelium is indistinguishable from that which covers the ectocervix and vagina. Residual columnar cells can persist on the epithelial surface (Figure 9B), even in the presence of CIN (Figure 9C).

However, immature squamous metaplasia differs from its mature counterpart in several respects and can be confused with CIN. It shows the following features:

- Lack of epithelial maturation (the entire thickness of the epithelium is made up of immature, polygonal cells of similar size and shape).
- Bland, round, uniform nuclei with fine chromatin, regular nuclear membranes, and single small nucleoli.
- Nuclear enlargement and an increase in the nuclear : cytoplasmic ratio.
- Variable cellular polarity, without cell crowding or cell disorganisation.
- Infrequent mitoses, which may be present at all levels; atypical forms are not seen.
- Absence of cytoplasmic glycogen.
- Variable presence of columnar cells within the epithelium and over the surface.
- Involvement of both surface and endocervical crypt epithelium.
- A sharp line of demarcation between metaplastic epithelium and neighbouring mature epithelium (this may not be included in all biopsy specimens; Figure 9D).

The diagnosis of CIN should be based on nuclear features of pleomorphism, hyperchromasia, increased mitotic activity, and atypical mitoses; these are not seen in squamous metaplasia.

Immunoprofile:

- Sparse, weak, dot-like staining of occasional nuclei with MIB1 is seen in immature squamous metaplasia (Figure 10A), whereas staining is strong and widespread in CIN.
- Only isolated, irregularly distributed cells are positive for p16 in squamous metaplasia (Figure 10B), whereas strong staining of all cells in the affected zone of the epithelium occurs where CIN is present.

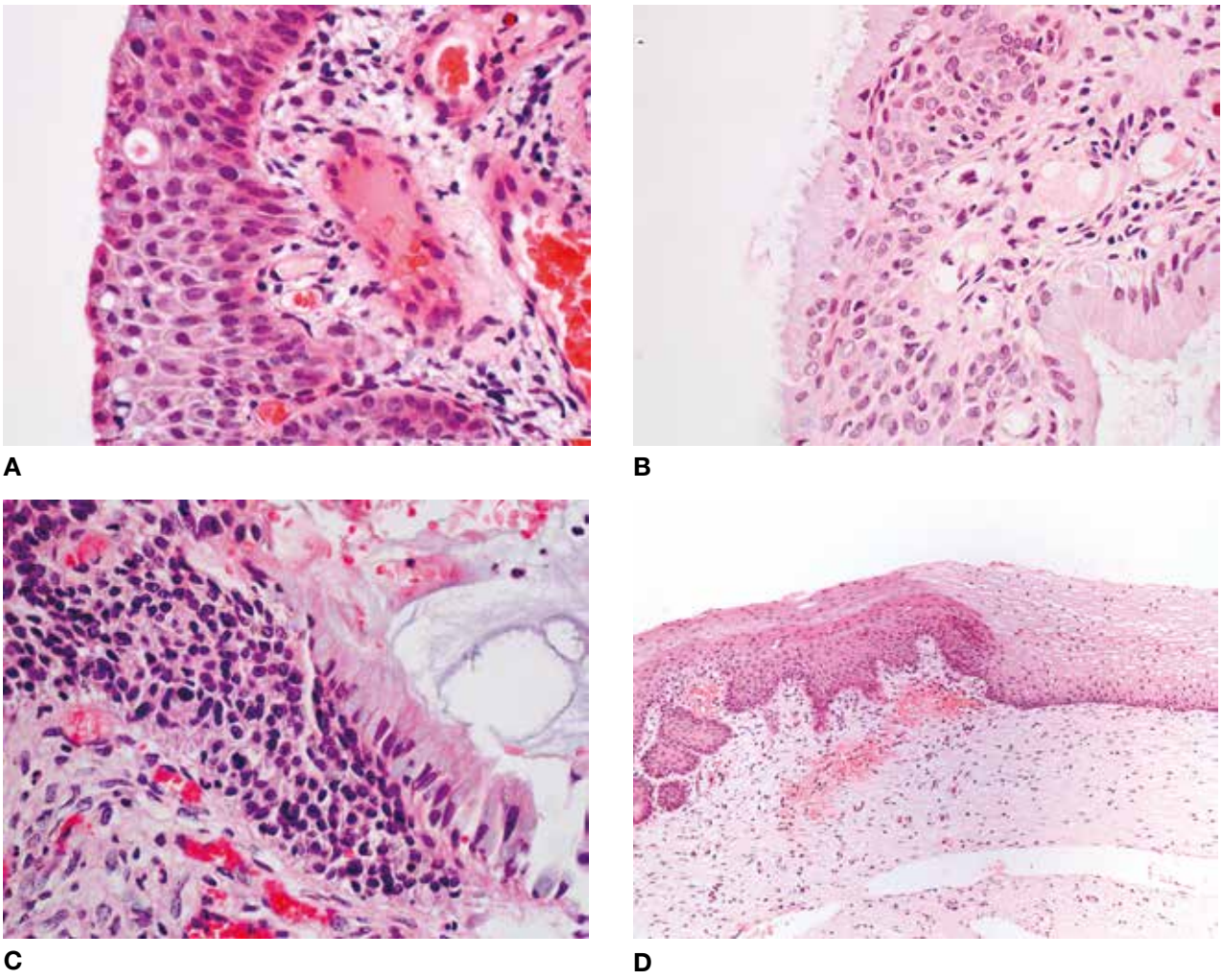

Figure 9 Squamous metaplasia. (A) The subcolumnar reserve cells in the transformation zone proliferate and undergo squamous differentiation as part of a physiological process, which results in the replacement of endocervical glandular epithelium by squamous epithelium. (B) Residual columnar cells can persist on the surface of squamous metaplasia. (C) Residual columnar cells can occasionally persist on the surface of CIN (CIN3 in this case). (D) A line of demarcation between metaplastic epithelium and neighbouring mature epithelium may be seen.

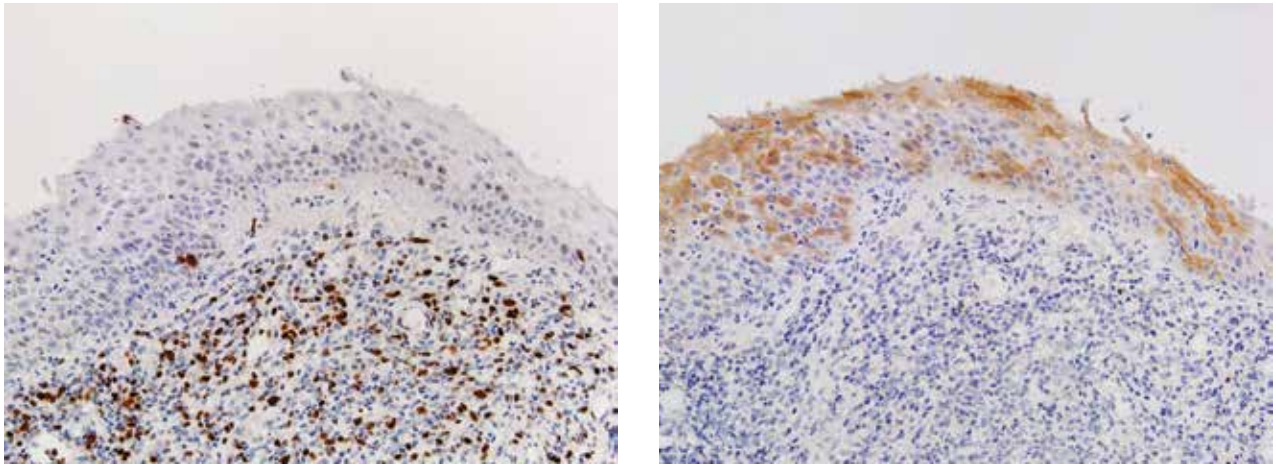

A B

Figure 10 Squamous metaplasia; immunohistochemistry. (A) Ki67 can be detected in only a few cells in the immature squamous metaplastic epithelium, and most of those are labelled only weakly. Note, in contrast, the strong labelling of inflammatory cell nuclei in the underlying stroma. (B) Only some of the epithelial cells express p16.

1.5.2 BCH (Figure 11)

Basal cell hyperplasia (BCH) is a common finding that is usually idiopathic, though it may be associated with pregnancy, inflammation, and healing, as well as with the use of contraceptives, including intrauterine contraceptive devices. The typical histological features are:

- An increase in the thickness of the basal and parabasal layers of the epithelium, with regular replication of the basal epithelial layers.
- Nuclear enlargement with vertical orientation.
- Mild nuclear hyperchromasia but no nuclear pleomorphism.
- Normal differentiation in the upper epithelial layers.
- Low rate of mitotic activity in the basal and parabasal epithelial layers.

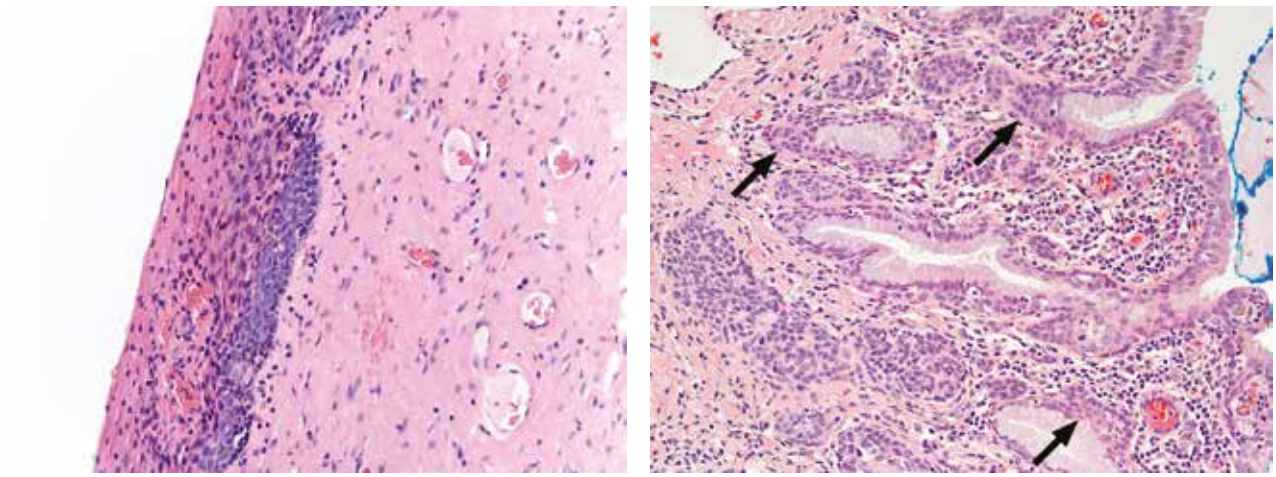

Figure 11 BCH. (A) Regular replication of the basal epithelial layers results in increased thickness of the basal and parabasal layers. (B) BCH may also extend beneath glandular epithelium and endocervical glands (arrows).

These changes must not be misinterpreted as CIN. Due attention must be paid to the lack of nuclear pleomorphism, nuclear atypia, and low levels of mitotic activity in BCH, and to the normal maturation of the upper epithelial layers.

Immunoprofile:

- Only occasional cells express MIB1 and p16 in BCH, whereas strong staining of all of the cells in the zone of BCH and in the overlying epithelium occurs when CIN is present.

1.5.3 Low-oestrogen states and atrophy (Figure 12)

Hypo-oestrogenic states during the menopause and perimenopause, after oophorectomy or pelvic chemoradiation, and during low-oestrogen contraceptive use or treatment with anti-oestrogenic medication, result in squamous epithelial atrophy. This is characterised by:

- A thin epithelium, showing lack of maturation.
- An epithelium composed entirely of basal and parabasal cells with a high nuclear : cytoplasmic ratio.
- Nuclei of uniform size, shape, and distribution with mild nuclear hyperchromasia but no pleomorphism.
- An absence of mitoses.
- The presence, in partial atrophy, of perinuclear haloes (pseudokoilocytosis), mild nuclear hyperchromasia, variation in nuclear size, and multinucleation[13,49] (these changes may be focal or diffuse and have been described as postmenopausal squamous atypia; CIN should not be diagnosed in the absence of the nuclear changes that typify it).

Making the distinction between atrophic changes (including transitional cell metaplasia, see section 1.5.4) and CIN may be difficult, and an erroneous diagnosis of CIN2 or -3 may be considered.

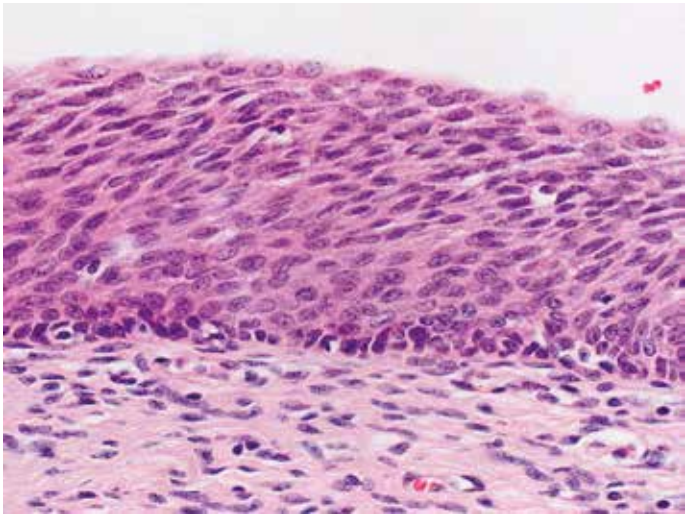

Figure 12 Atrophy. The epithelium is thin, shows lack of maturation, and is composed of basal and parabasal cells with a high nuclear : cytoplasmic ratio.

Immunoprofile:

- A high MIB1 labelling index and diffuse immunoreactivity for p16 are typical of CIN, whereas atrophic epithelium and transitional cell metaplasia are typically p16 negative, and show only scattered parabasal MIB1-positive cells.
- ProExC, a cocktail of antibodies against topoisomerase II-alpha and minichromosome maintenance 2 proteins, marks the nuclei of HPV-infected and neoplastic cells but is negative in atrophic epithelium.[50]

1.5.4 Transitional cell metaplasia

This form of metaplasia usually occurs in postmenopausal women and is considered to be a form of atrophy.[48,51] The change is often widespread and is indicated by:

- A hyperplastic epithelium lacking in maturation.
- Uniform epithelial cells with a high nuclear : cytoplasmic ratio throughout the epithelial thickness.
- Uniform oval to round nuclei, which often show longitudinal grooves and a vertical orientation.
- The absence of mitotic activity, of abnormal nuclear chromatin dispersion, and of pleomorphism.

Immunoprofile:

- A low MIB1 labelling index and negativity for p16 is useful in distinguishing between transitional cell metaplasia and CIN (see section 1.2.9).
- Expression of CK13, CK17, and CK18 is seen in normal urothelium and metaplastic transitional epithelium in the cervix.
- CK20, a marker of terminal urothelial differentiation, is not expressed in transitional metaplasia.[47]

1.5.5 Repair (reactive epithelial changes and regeneration)

Changes caused by repair can occur in squamous and glandular epithelium in response to non-specific acute or chronic inflammation and infection, or in association with uterine prolapse or injury (e.g. a previous biopsy). Both mature and immature squamous epithelium may show these changes, which can be particularly prominent in immature epithelium, where they can be difficult to distinguish from CIN (Figure 13A). Atypia of repair is characterised by the following:

- Inflammatory cells, present in the stroma and epithelium (Figure 13B).
- Nuclei with uniform atypia (i.e. there is no, or minimal, pleomorphism).
- Evenly distributed, or slightly clumped, nuclear chromatin.
- Prominent nucleoli or macronucleoli.
- Basal layer hyperplasia.
- Orderly epithelial maturation with normal-looking cells in the upper layers.
- Increased mitotic activity (in some cases).

Lower levels of mitotic activity, the absence of atypical mitotic figures, and a lack of significant nuclear atypia and pleomorphism are useful for distinguishing atypia of repair from CIN.

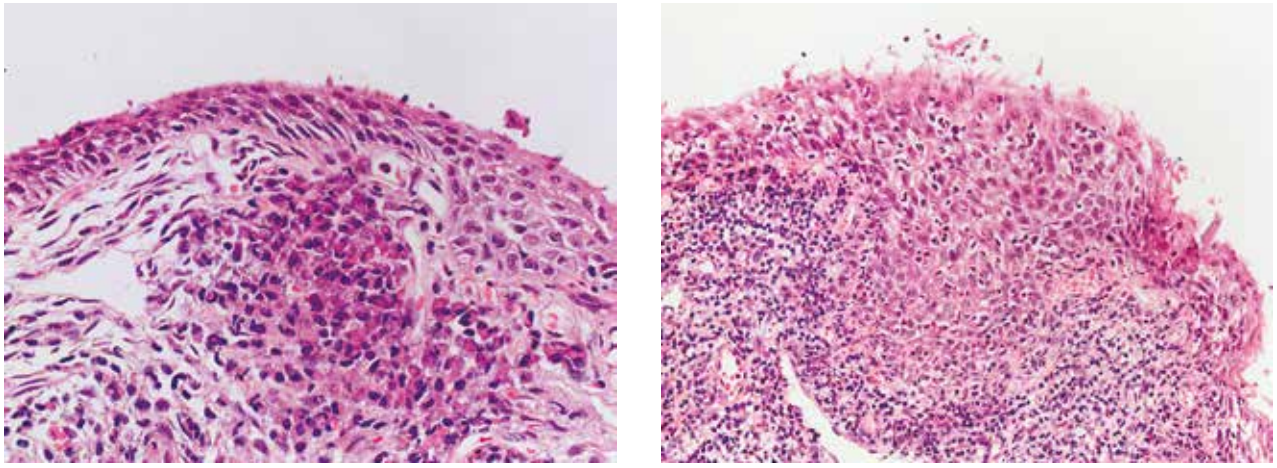

A B

Figure 13 Repair and reactive changes. (A) Thinned epithelium with uniform nuclear atypia but no mitotic activity, and inflammatory cells in the stroma. (B) Uniform nuclear atypia in mature, hyperplastic squamous epithelium, permeated by inflammatory cells.

Immunoprofile:

- p16 expression is widespread in cases of CIN, but only occasional cells express this marker in cases of repair.

1.5.6 Radiation-induced atypia

This may be identified acutely or may be noted many years after irradiation of the cervix. It is accompanied by concomitant stromal changes.

- Acute radiation changes in squamous epithelium include nuclear enlargement and prominent nucleoli, cytoplasmic swelling and vacuolation. Surface ulceration is often present, and stromal oedema, necrosis, and polymorph infiltration can be seen.
- Chronic radiation atypia is characterised by epithelial atrophy, with nuclear enlargement and multinucleation in epithelial cells. The nuclear chromatin often has a 'smudgy' appearance, and mitotic activity is not usually seen. Cytoplasmic vacuolation may persist. Stromal changes include fibrosis with hyalinisation, multinucleation of stromal cells with formation of atypical fibroblasts ('radiation fibroblasts'), and focal calcification. Vascular changes comprise intimal thickening, sclerosis, and atypical endothelial cells. Radiation changes may also be seen in endocervical cells (see section 2.6.14).
- Cervical neoplasia should be diagnosed with extreme caution when there is a history of radiation. The presence of stromal changes and immunohistochemistry can be helpful in distinguishing radiation-induced atypia from CIN.

Immunoprofile:

- Staining with p16 is of limited use because expression may be seen in post-radiotherapy cervical biopsies.[52]
- MIB1 may be helpful and is positive in only isolated cells.

1.5.7 Hyperkeratosis and parakeratosis

Keratinisation of the cervical squamous epithelium is common and usually results from chronic irritation associated with chronic inflammation, prolapse, or use of a pessary or diaphragm. White, thickened epithelium is noted at clinical examination. Histological examination reveals:

- A thick keratin layer over the epithelial surface (hyperkeratosis).
- Pyknotic nuclei (parakeratosis) within the keratin layer.
- Acanthosis with a well-developed granular layer, prominent intercellular bridges, and elongated rete pegs.
- Absence of cytological atypia.
- Presence of accompanying chronic inflammation.
- Absence of koilocytosis, papillomatosis, and other features of condyloma.
- A lack of nuclear changes characterising CIN.

There is no morphological or clinical evidence that this condition is related to cervical neoplasia, but careful evaluation is advised because both CIN and well-differentiated invasive squamous carcinoma can show hyperparakeratosis.

2 CERVICAL GLANDULAR NEOPLASIA: PRECURSORS, TUMOURS, AND BENIGN MIMICS

2.1 Introduction

Premalignant and malignant endocervical glandular lesions are increasing in incidence.[53] In part, this may reflect a relative increase compared with squamous neoplasms, the incidence of which has declined in developed countries as a result of organised cervical screening programmes. However, other evidence suggests that this increase is real and some of this increase may be a result of better recognition of these lesions by pathologists.[53]

- Most, but not all, premalignant and malignant endocervical glandular lesions are associated with HR-HPV infection, most commonly HPV types 16 and 18. Compared with CIN, a greater proportion of endocervical glandular lesions is associated with HPV 18 infection.[54]
- There are many benign endocervical glandular lesions that may mimic premalignant and malignant endocervical glandular lesions, especially when such lesions are florid.[55]
- Immunohistochemistry may be useful in the assessment of endocervical glandular lesions, but results should always be interpreted in conjunction with the histomorphology.[15,56]

2.2 CGIN (Figure 14)

2.2.1 Definition and general comments

Cervical glandular intraepithelial neoplasia (CGIN) is the term used in the UK for endocervical glandular lesions that act as precursors of usual-type endocervical adenocarcinomas (referred to as 'mucinous adenocarcinomas of endocervical type' by the WHO).[34,56]

- CGIN is divided into low and high grades (L-CGIN, H-CGIN) (Figure 14A, B).
- In WHO terminology, L-CGIN corresponds to glandular dysplasia and H-CGIN to adenocarcinoma in situ (AIS).[34,56] The WHO defines AIS as a lesion in which normally situated glands are partly or wholly replaced by cytologically malignant epithelium. Glandular dysplasia is defined by the WHO as a glandular lesion characterised by significant nuclear abnormalities, which are more striking than those of glandular atypia but which fall short of the criteria for AIS.[34]
- H-CGIN is more common than L-CGIN. It is important to recognise that some authorities do not report L-CGIN because the diagnosis is poorly reproducible.
- Mixtures of L-CGIN and H-CGIN may be seen. Indeed, it is uncommon to find L-CGIN in isolation, as it is usually associated with H-CGIN.
- If L-CGIN is diagnosed and H-CGIN is absent, the pathology report should state that management should follow the recommendations for H-CGIN.
- Most examples of CGIN are of so-called 'usual' or 'endocervical' type but variants do occur (see below).
- Although CGIN and CIN occur in patients of a similar age range, CGIN is not as common as CIN and is often colposcopically 'silent'. Most cases of CGIN occur in association with CIN, so that CGIN may be an incidental finding in patients with CIN.

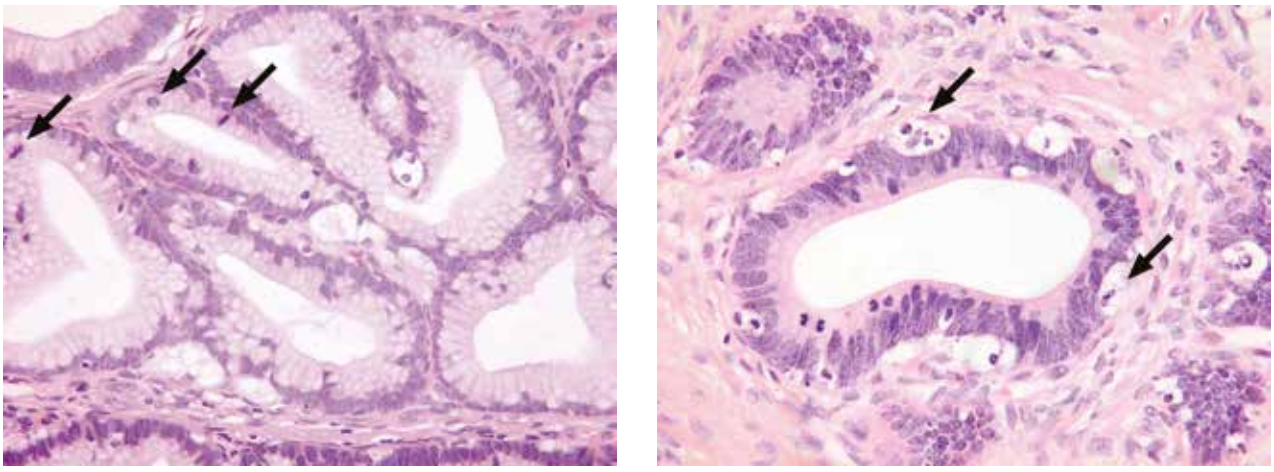

A B

Figure 14 CGIN. (A) Low-grade CGIN. In this area of glandular architectural irregularity, the endocervical glandular cells show mild nuclear atypia and hyperchromasia. Mitotic figures are present (arrows). (B) High-grade CGIN – the endocervical glandular cells show mucin depletion, nuclear stratification, atypia, hyperchromasia, and loss of polarity with mitotic figures and apoptosis. The apoptotic bodies are present in the base/non-luminal aspect of the glands (arrows).

2.2.2 Morphological features of CGIN (usual or endocervical type)

- CGIN usually occurs at, or close to, the transformation zone. An initial clue to its diagnosis is provided by low-power examination, which reveals abnormal, darkly staining glands confined to the normal endocervical glandular field.
- A cribriform architecture (Figure 14C) and intraglandular papillae may be seen. However, when these features are prominent and widespread, a diagnosis of adenocarcinoma should be considered.
- Despite statements to the contrary in the literature, skip lesions and extension high up the endocervical canal are relatively uncommon.
- Often both the surface and crypt epithelium are involved, and there are abrupt transitions between normal and abnormal glandular epithelia, occurring both within and between glands.
- The endocervical glandular cells show mucin depletion, nuclear stratification, atypia, hyperchromasia, and loss of polarity. Mitotic figures, most prominent at the luminal aspect of the glands (Figure 14D), are readily identifiable but can be sparse. Atypical mitoses may be present.
- Apoptotic bodies are a characteristic and relatively constant feature,[57] and are not only more common, but also more numerous than in invasive cervical adenocarcinomas. The apoptotic bodies are usually situated at the non-luminal aspect of the glands (Figure 14B).

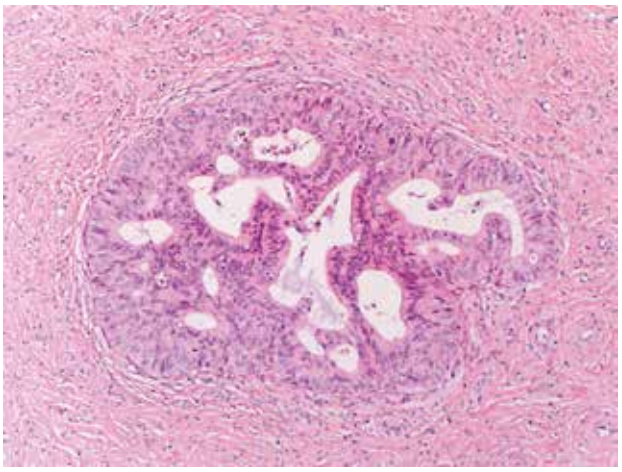

C

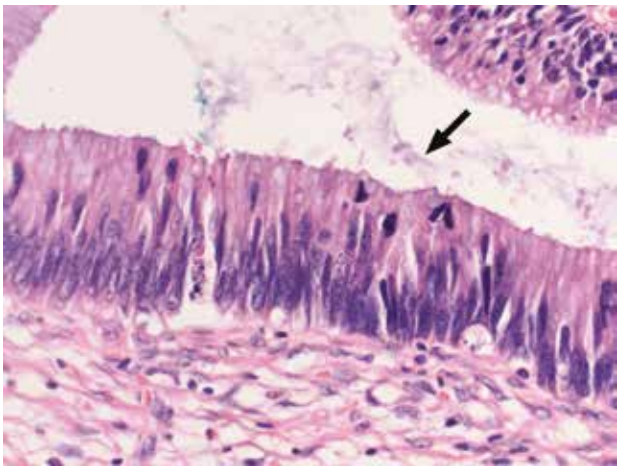

D

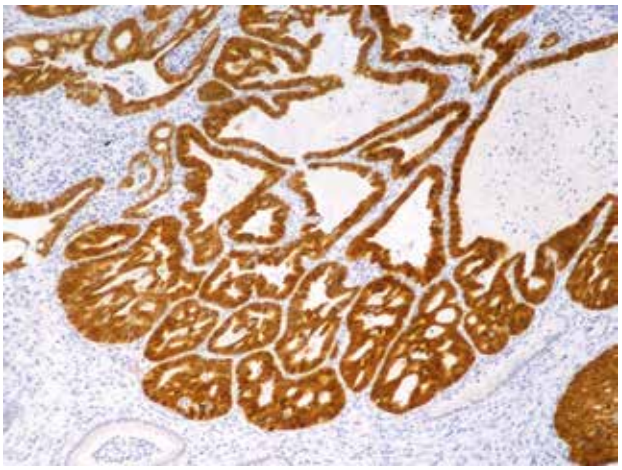

E

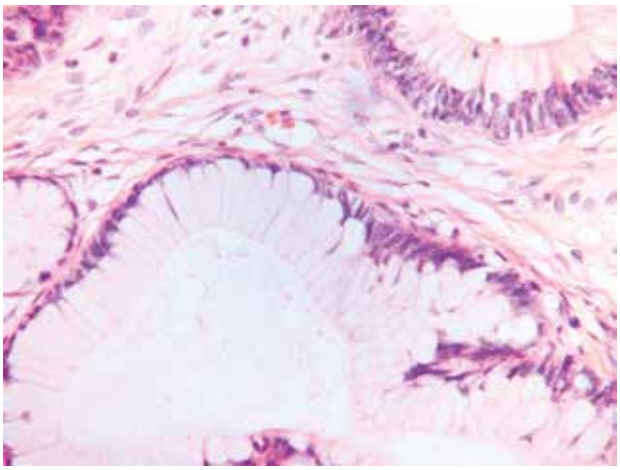

F

Figure 14 CGIN (continued). (C) A cribriform architecture may be seen but should not be prominent or widespread. (D) High-grade CGIN with mitotic figures (arrow). These are most prominent at the luminal aspect of the glands. (E) Diffuse nuclear and cytoplasmic p16 immunopositivity in CGIN is an indicator of HR-HPV. (F) Intestinal CGIN, the most common variant after endocervical-type CGIN, contains goblet cells in the dysplastic endocervical glands.

Immunoprofile of CGIN:

- Diffuse p16 positivity (involving both nuclear and cytoplasmic staining), which is an indicator of HR-HPV (Figure 14E).[15,54,58]
- An MIB1 proliferation index that is usually in excess of 30%, though it may occasionally be lower.[15,58]
- Overexpression of ProExC (a cocktail of antibodies against topoisomerase II-alpha and minichromosome maintenance 2 proteins).[18]
- Negative or focally positive bcl-2 (this may be useful in distinguishing CGIN from tuboendometrial metaplasia (TEM) and superficial endometriosis, both of which are usually diffusely positive for bcl-2).[58]
- Expression of carcinoembryonic antigen (CEA) is often, but not always, present.[15]
- Immunostaining for hormone receptors (ER, oestrogen receptor, and PR, progesterone receptor) is usually negative or focally positive.
- Negative staining for vimentin.

2.2.3 Management

- Treatment tends to be individualised. Affected women are often young, so most cases of CGIN are managed by local excision. Clear margins must be achieved and this may require more than one attempt at local excision with careful subsequent cytological follow-up.[59]
- Hysterectomy may be indicated in older women or patients with other pathology, such as uterine fibroids, but local excision with clear margins should be undertaken prior to this, to ensure that invasion is not present.

2.2.4 Variants of CGIN

There are several variants of CGIN:

- Intestinal type (Figure 14F): this is the most common variant of CGIN after the usual (endocervical) type, with which it tends to be associated. Typically, goblet cells are present in dysplastic endocervical glands, but Paneth cells and/or neuroendocrine cells may also be seen.[60] When intestinal-type epithelium with goblet cells is present in the endocervix, this almost always indicates the presence of a premalignant or malignant endocervical glandular lesion. However, in these cases, nuclear features may be subtle because of nuclear compression by intracytoplasmic mucin globules. 'Benign' intestinal metaplasia rarely exists in the cervix, and intestinal-type CGIN is possibly more likely to be associated with early invasion than the usual endocervical type.[60]

Immunoprofile of intestinal-type CGIN:

- p16 positivity and a high MIB1 proliferation index.
- Usually positive for CK7 and for enteric markers CDX2 and CK20 (indicating a partial enteric or hybrid immunophenotype).

- Endometrioid type: the WHO states that an endometrioid variant of AIS exists, but the authors of this chapter feel that this equates to usual-type CGIN with marked depletion of intracytoplasmic mucin. It is therefore recommended that this diagnosis is avoided.
- Tubal type: occasional examples of CGIN contain cilia, and are referred to as being of tubal type.[61] This variant is uncommon and tends to be associated with usual-type CGIN. It has been proposed that ciliated CGIN may arise from typical or atypical TEM, and atypical TEM remains the main differential diagnosis. The presence of apoptotic bodies is a useful clue, pointing to a diagnosis of ciliated CGIN, but care must be taken to distinguish these from the intraepithelial lymphocytes that are characteristic of TEM.

2.3 SMILE

2.3.1 Definition and general comments

Although stratified mucin-producing intraepithelial lesion (SMILE) is not uncommon, it is not currently included in the WHO classification. SMILE may be a marker of phenotypic instability and is best regarded as a form of reserve cell dysplasia. SMILE has also been considered as a form of stratified CGIN.

- SMILE occasionally occurs in isolation but is usually associated with CGIN and/or CIN.[62]
- Where it occurs alone, SMILE should be managed in the same way as CGIN. This should be stated in the pathology report, so that clinicians ensure adequate local excision with clear margins.
- Where it occurs in isolation and is identified by punch biopsy, the pathology report should state that there is often an association with CIN and/or CGIN.
- The main differential diagnosis is atypical immature squamous metaplasia.

2.3.2 Morphological and immunohistochemical features of SMILE (Figure 15)

- SMILE involves surface and/or crypt epithelium.
- The morphological features overlap with those of CIN and CGIN. SMILE shows stratified epithelium similar to CIN, but with cytoplasmic clearing. Mucin droplets or globules are present throughout the full epithelial thickness (Figure 15A,B). By contrast, in immature squamous metaplasia, mucin is usually confined to the surface layer.
- The stratified epithelial cells show nuclear atypia and hyperchromasia.

Immunoprofile:

- p16 is positive.
- There is a high MIB1 proliferation index
- p63 expression is variable.

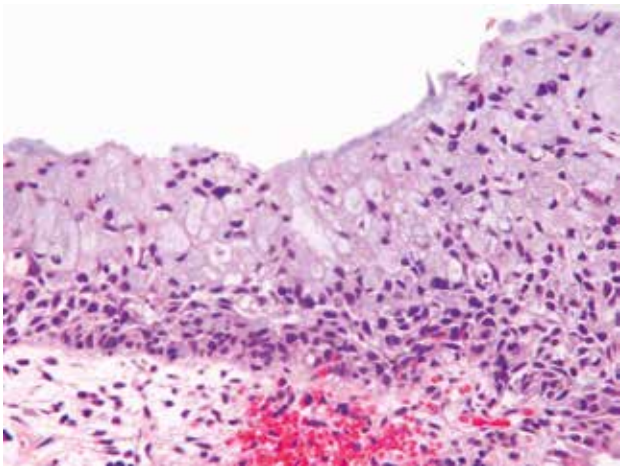

A

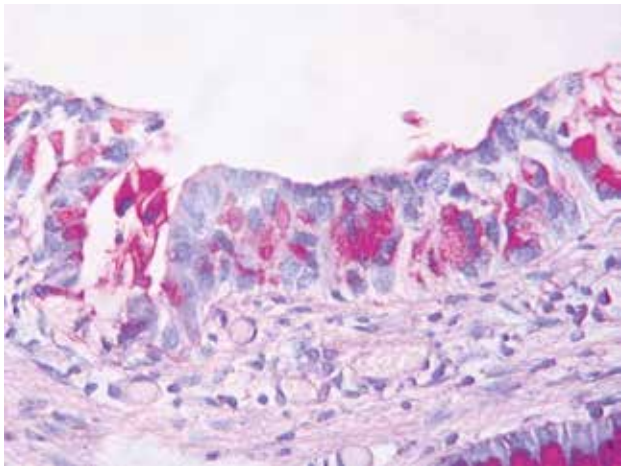

B

Figure 15 SMILE. (A) SMILE shows stratified epithelium similar to CIN, with intraepithelial mucin-secreting cells that extend through the full epithelial thickness. (B) Mucin droplets or globules are present throughout the full epithelial thickness.

2.4 Early invasive adenocarcinoma

2.4.1 Definition and general comments

Although it is more difficult to recognise early invasion in glandular than in squamous lesions, diagnosis of early invasive adenocarcinoma is increasing. This probably reflects both increasing incidence and better recognition by histopathologists. Nonetheless, assessment of early invasion remains problematic and poorly reproducible, partly due to difficulties in distinguishing it from florid CGIN. A specialist opinion may therefore be useful.

As for squamous carcinoma, the term 'microinvasive adenocarcinoma' should not be applied; similarly, 'early invasive adenocarcinoma' is not a specific histological diagnosis. Instead, in both situations, the appropriate FIGO stage should be given.[38]

2.4.2 Morphological features of early invasive adenocarcinoma (Figure 16)

- In some cases, an obvious infiltrative growth pattern is evident (Figure 16A), even though the adenocarcinoma is small.
- In other cases, a diagnosis of invasion is made on the basis of architectural complexity in the glandular field, despite the absence of obvious destructive invasion or a stromal response (Figure 16B).[56,63] Here, there are often papillary, cribriform, and solid growth patterns, which are not usually present in the normal endocervical gland field.
- Early invasive adenocarcinoma (Figure 17) may also be diagnosed when small buds of atypical epithelial cells with more abundant eosinophilic cytoplasm (imparting a so-called 'squamoid appearance') emanate from glands involved by CGIN (Figure 17A,B).[64]
- A stromal inflammatory, oedematous, or desmoplastic response (Figure 17C) is not always apparent (i.e. there can be a so-called 'naked' pattern of invasion). However, these are useful diagnostic features when present.
- The proximity of abnormal glands to thick-walled stromal blood vessels may be helpful in confirming an invasive lesion (Figure 17D).[65]

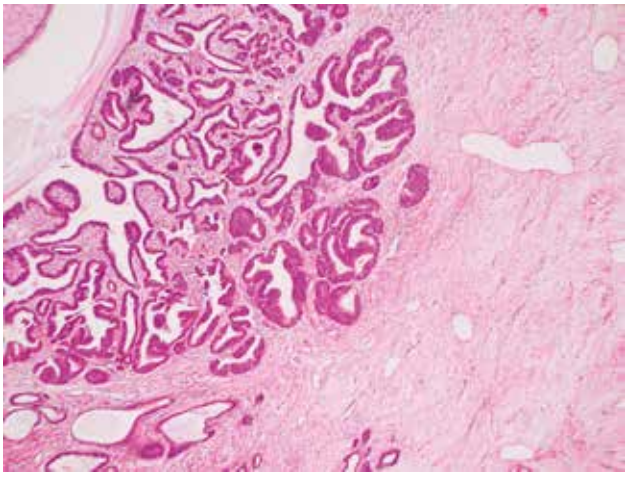

A

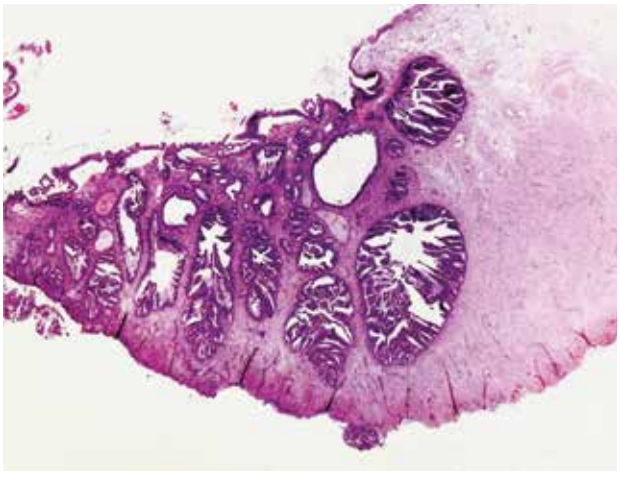

B

Figure 16 Early invasive adenocarcinoma. (A) Small, early invasive adenocarcinoma. This example shows an obvious infiltrative growth pattern despite the tumour size. (B) A diagnosis of invasion can be made on the basis of architectural complexity in the glandular field, even in the absence of obvious destructive invasion or a stromal response.

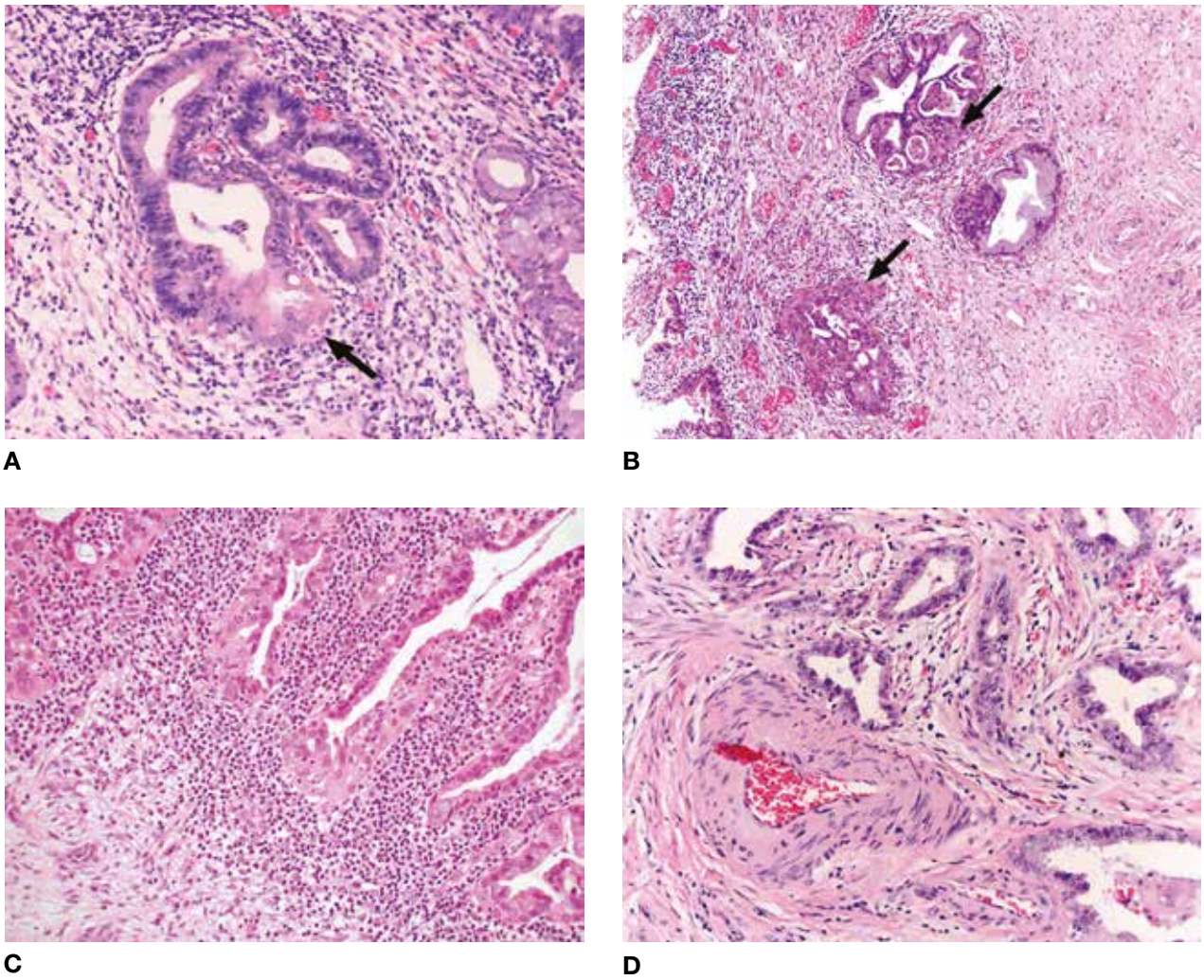

Figure 17 Early invasive adenocarcinoma. (A) Atypical epithelial cells with a squamoid appearance extend from the base of the largest endocervical gland (arrow), and there is an inflammatory host reaction. (B) The invading small buds of atypical squamoid cells (arrows) have evoked a mild inflammatory host reaction. (C) A brisk host inflammatory reaction is seen around foci of early stromal invasion with a squamoid appearance. (D) The proximity of abnormal glands to thick-walled stromal blood vessels helps to confirm an invasive lesion.

2.4.3 Measurement of early invasive adenocarcinoma

Recognition and measurement of early invasive adenocarcinoma is problematic because of difficulties in differentiating between CGIN and foci of early invasion.

- Depth of invasion is measured from the deepest point of invasion to the basement membrane of the surface epithelium or crypt from which the adenocarcinoma arises.
- When a diagnosis of invasion is made on the basis of extreme architectural complexity, measurements should be taken from the tumour surface to the deepest point of the lesion (Figure 18). This is a measure of tumour thickness, rather than of depth of invasion, and may overestimate the latter.
- The horizontal size of the tumour must be measured from one lateral edge to the other.
- The width of the tumour in its third dimension should be calculated by multiplying the number of blocks involved by the thickness of the blocks (block thickness is calculated from the macroscopic dimensions of the specimen).

- In cases of multifocal disease, the principles for measuring multifocal invasion in squamous neoplasms should be applied.
- FIGO stage IA adenocarcinoma cannot be diagnosed in an incompletely excised lesion where there is CGIN or adenocarcinoma at a resection margin.
- In a completely excised small adenocarcinoma, the nearest margin should be reported. The distance (in millimetres) of the adenocarcinoma (and CGIN) from the margin should also be stated.

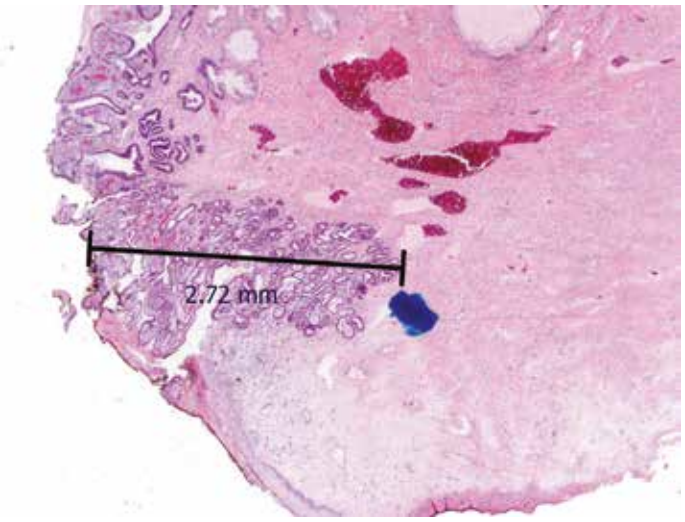

Figure 18 Measurement of tumour thickness. In cases of architectural complexity, where a clearly defined origin is not identified, a measure of tumour thickness should be taken from the tumour surface to the deepest point of invasion.

2.4.4 Management of early invasive adenocarcinoma

Treatment is individualised and modified according to the patient's age and wishes and the desire to preserve fertility.

- There is good evidence that FIGO stage IA1 adenocarcinomas can be safely treated by local excision(s) with clear margins and careful follow-up.[66,67]
- Radical hysterectomy is usually undertaken for FIGO stage IA2 and IB1 adenocarcinoma.
- Trachelectomy is an option for FIGO stage IA2 and small IB1 adenocarcinomas when fertility preservation is desired.
- For FIGO stage IA1 adenocarcinoma, it is important to ensure that local excision of the adenocarcinoma with clear margins is achieved before simple hysterectomy is performed. This avoids the possibility of identifying residual (and possibly more extensive) invasion in the hysterectomy specimen.

2.5 Cervical adenocarcinoma (including variants)

2.5.1 Definition and general comments

Several different morphological subtypes of adenocarcinoma are recognised by the WHO (Appendix 2).[34] The endocervical type of mucinous adenocarcinoma is the most common and accounts for approximately 80% of cervical adenocarcinomas. Most endocervical-type adenocarcinomas are associated with HR-HPV, but some of the other variants are not HPV related.[54] A recently recognised gastric subtype of adenocarcinoma is not currently included in the WHO classification, but is discussed in these guidelines.

It is recommended that cervical adenocarcinomas are graded according to the FIGO system for endometrial adenocarcinomas.[23]

2.5.2 Mucinous adenocarcinoma of endocervical type (usual-type adenocarcinoma)

This subtype is often associated with CGIN and typically has inconspicuous intracytoplasmic mucin. Additionally:

- The nuclei are hyperchromatic.
- Mitoses and apoptotic bodies are typically prominent. Mitoses are often luminal and may be atypical. Apoptotic bodies are basal in location and are found in the epithelium lining the neoplastic glands.
- The gland profiles are complex. Branching, budding, or cribriform growth patterns are seen, and intraluminal or exophytic papillae may be present.
- A stromal desmoplastic, inflammatory, or oedematous response is often, but not invariably, present.
- Some endocervical-type adenocarcinomas may have a so-called 'naked' pattern of invasion, where neoplastic glands 'melt' into the stroma without a desmoplastic response.
- Rare microcystic variants occur, and at low-power these resemble dilated benign glands. They are distinguished from the latter by the presence (alone, or in combination) of focal atypia, a desmoplastic stromal response, significant mitotic and apoptotic activity, and cribriform foci.[68]
- A rare dedifferentiated variant that includes areas resembling lobular breast carcinoma is described.[69]

Immunoprofile:

- Diffuse expression of CK7, CEA, and p16 occurs.
- ER, PR, and vimentin are usually negative.
- A panel of CEA, p16, ER, vimentin, and HPV markers may help to exclude primary endometrial adenocarcinoma of endometrioid type in problematic cases.[15,70–73]

2.5.3 Intestinal type mucinous adenocarcinoma (Figure 19)

This is an uncommon variant of primary cervical adenocarcinoma, and resembles colonic adenocarcinoma. It is probably not associated with HPV infection.

- Some intestinal-type mucinous adenocarcinomas contain goblet cells (Figure 19A) but differ from the adenocarcinomas that arise from intestinal-type CGIN in having an intestinal, rather than an endocervical, immunophenotype (see below).
- 'Dirty' necrosis is often a feature. However, these tumours must be distinguished from colorectal metastasis on the basis of clinical history, pattern of spread, and immunohistochemistry (cervical primary tumours are usually CK7 positive; colorectal metastasis is usually CK7 negative).

Immunoprofile:

- Intestinal-type mucinous adenocarcinoma labels diffusely for CK7, focally or diffusely for CK20 and CDX2 (Figure 19B), and variably for p16.[60]

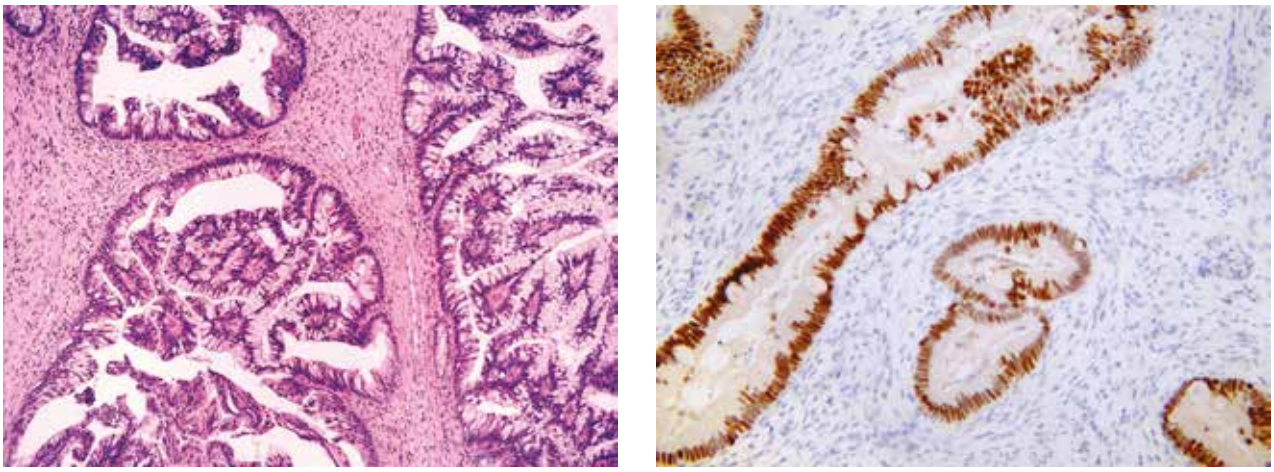

A B

Figure 19 Mucinous adenocarcinoma, intestinal type. (A) This uncommon variant of primary cervical adenocarcinoma resembles colonic adenocarcinoma and contains goblet cells. (B) Strong and diffuse nuclear expression of CDX2.

2.5.4 Signet ring cell mucinous adenocarcinoma (Figure 20)

There are very rare tumours,[74] characterised by the presence of intracellular mucin vacuoles.

- Signet ring cells may be present throughout the tumour or may be a focal component. In the latter case, they are usually present in association with an endocervical-type adenocarcinoma. If the entire neoplasm is composed of signet ring cells, metastasis from the breast, stomach, or elsewhere should be excluded.
- Diathermy can result in signet ring stromal cells similar to those found in this variant of adenocarcinoma, but the nuclei are not atypical and epithelial markers are negative.[75]

Immunoprofile:

- These tumours usually express CK7, CEA, and p16.

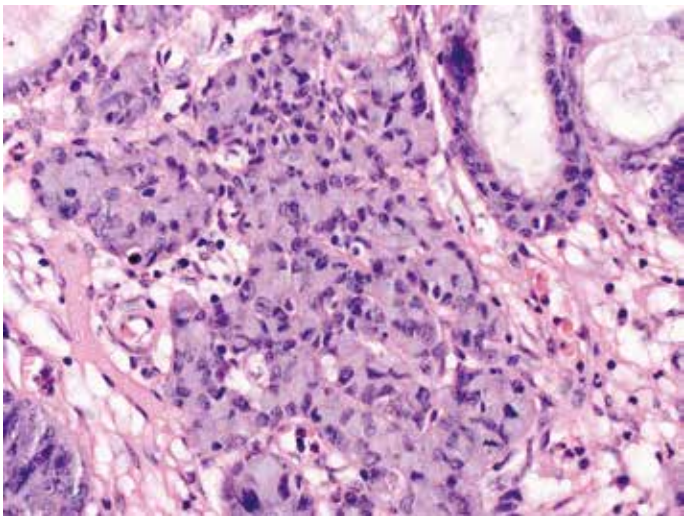

Figure 20 Mucinous adenocarcinoma: signet ring cell type. The presence of intracytoplasmic mucin vacuoles characterises these tumours. In this example, the signet ring cell component is associated with an endocervical-type adenocarcinoma.

2.5.5 Mucinous variant of minimal deviation adenocarcinoma (adenoma malignum) (Figure 21)

These tumours, which account for 1–3% of cervical adenocarcinomas,[76,77] may be associated with Peutz–Jeghers syndrome and profuse vaginal discharge. Most are not HPV related and some probably arise from lobular endocervical glandular hyperplasia.[78] Clinically, the cervix may be normal or enlarged. The poor prognosis of these tumours is probably due to a delay in their diagnosis. Small biopsy specimens are suboptimal for diagnosis.

- Minimal cytological atypia is a characteristic feature; focal atypia may be seen after extensive sampling.
- Mitoses are rare.
- Intracytoplasmic neutral mucin is abundant and stains red with combined Alcian blue and periodic acid–Schiff (PAS); normal endocervical glands stain a purple-violet colour.
- Neuroendocrine cells are often present.
- The gland pattern is abnormal, with loss of the usual lobular architecture. Glands are irregularly spaced and have claw- or crab-shaped profiles.
- Deep stromal invasion is characterised by glands that lie in close proximity to thick-walled stromal blood vessels (this may be a useful diagnostic clue).
- A stromal desmoplastic reaction, and perineural or lymphovascular invasion, facilitate diagnosis.
- The differential diagnosis includes endocervical glandular hyperplasia (laminar or lobular), deep Nabothian cysts and glands, tunnel clusters, endocervicosis, and endocervical adenomyoma.

Immunoprofile:

- These tumours display a pyloric gland immunophenotype (HIK1083 and MUC6 positive).

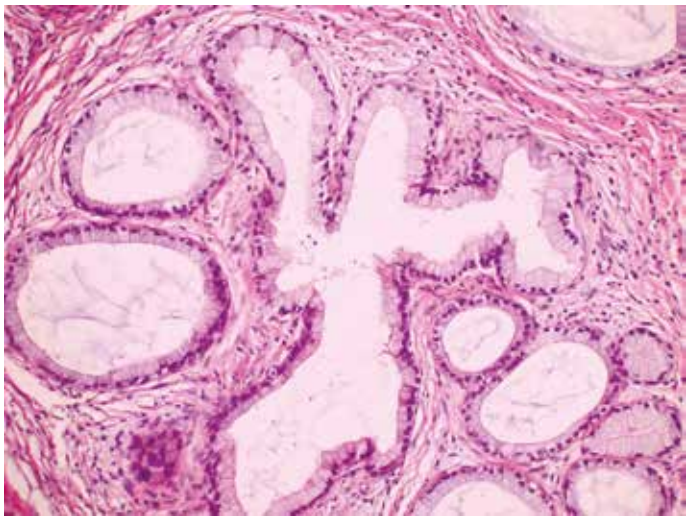

Figure 21 Mucinous adenocarcinoma: minimal deviation variant. Neoplastic glands are irregularly spaced and have abnormal contours. In typical cases, there is minimal cytological atypia.

2.5.6 Villoglandular adenocarcinoma (Figure 22)

This uncommon variant of adenocarcinoma is probably overdiagnosed.[79,80] There is significant interobserver variability in its diagnosis. Diagnosis on the basis of a papillary architecture alone is flawed, as papillary growth may be present in endocervical-type, serous, and other adenocarcinoma variants. Some cases are associated with the use of hormonal preparations. It is widely assumed that these tumours have a good prognosis and that conservative treatment, in the form of local excision, is adequate. However, some cases exhibit deep stromal invasion or lymph node metastasis. Few of the reported case series of villoglandular adenocarcinoma have had sufficient follow-up and caution should be exercised when basing a diagnosis on a superficial biopsy, as a deep, high-grade component may be missed, and such cases are associated with a poor outcome.[81]

- Cytological atypia is mild or moderate at most.
- Mucin production is scanty.
- The tumours may be polypoid or exophytic at macroscopic examination, and are characterised histologically by a fronded growth of thick or thin papillae, which are covered by endocervical-type epithelium.

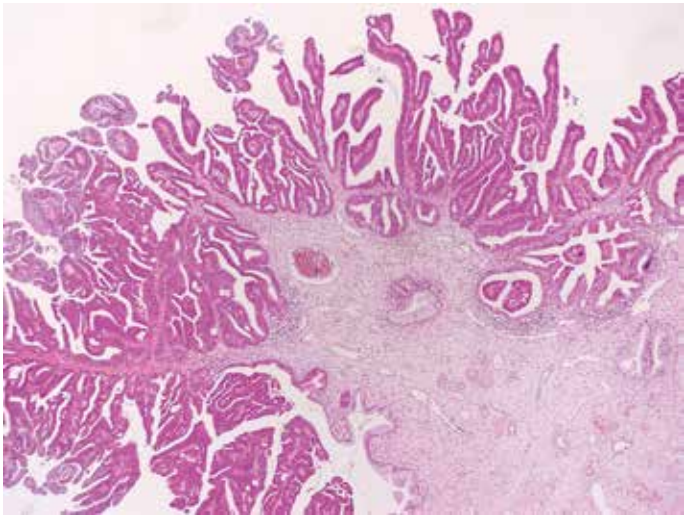

Figure 22 Mucinous adenocarcinoma: villoglandular variant. This exophytic tumour exhibits a fronded growth of papillae, which are covered by mildly dysplastic endocervical-type epithelium. There is no stromal invasion in this example.

2.5.7 Gastric-type cervical adenocarcinoma (Figure 23)

This recently described, uncommon variant of primary cervical adenocarcinoma[82] exhibits gastric differentiation like adenoma malignum, but is characterised by obvious malignant cytological features. The carcinoma is probably not HPV related[83] and may be associated with Peutz–Jeghers syndrome.[84] It probably arises in some cases from lobular endocervical glandular hyperplasia (a benign endocervical glandular lesion that exhibits gastric differentiation). Occasional composite adenocarcinomas, composed of adenoma malignum and gastric-type adenocarcinoma, are reported.[84] These tumours behave aggressively and have a poor prognosis with a propensity for peritoneal dissemination.

- The tumour is often well-differentiated architecturally, with cells that have abundant clear or eosinophilic cytoplasm, with distinct cell borders.
- However, in contrast to adenoma malignum, there is obvious nuclear atypia. It may be that these two types of neoplasm are part of a spectrum of cervical adenocarcinomas exhibiting gastric differentiation.

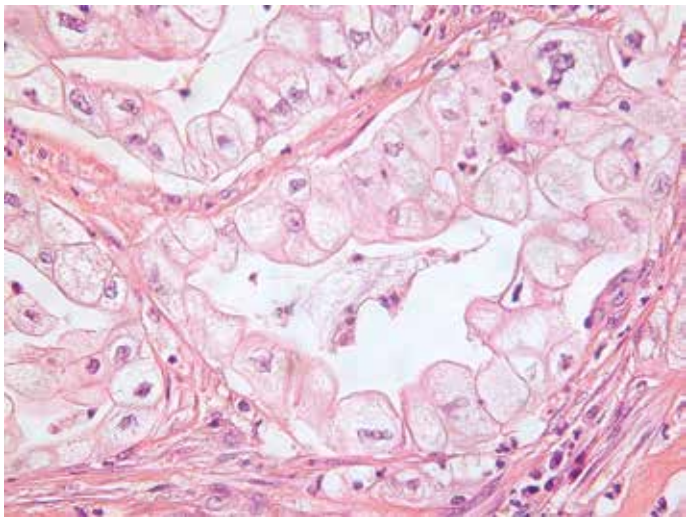

Figure 23 Mucinous adenocarcinoma: gastric type. The tumour cells have abundant clear cytoplasm with sharp cell borders.

Immunoprofile:

- Positive with HIK1083 and MUC6.

2.5.8 Endometrioid adenocarcinoma

Some consider these to account for up to 30% of cervical adenocarcinomas, but most cases are probably endocervical-type adenocarcinomas with intracytoplasmic mucin depletion. The authors consider this to be a rare variant of cervical adenocarcinoma. It is difficult to diagnose unless morphologically bland squamous elements are present (Figure 24).[85]

- The tumours comprise simple or complex glands that are lined by endometrioid-type epithelium with stratified nuclei and minimal intracytoplasmic mucin.
- Spread from a primary tumour in the uterine corpus should be excluded and immunohistochemistry may assist in this regard (see section 2.5.2, immunoprofile box).
- A rare endometrioid subtype of minimal deviation adenocarcinoma exists, and this should be distinguished from cervical involvement by endometrioid endometrial adenocarcinoma, endometriosis, and TEM.

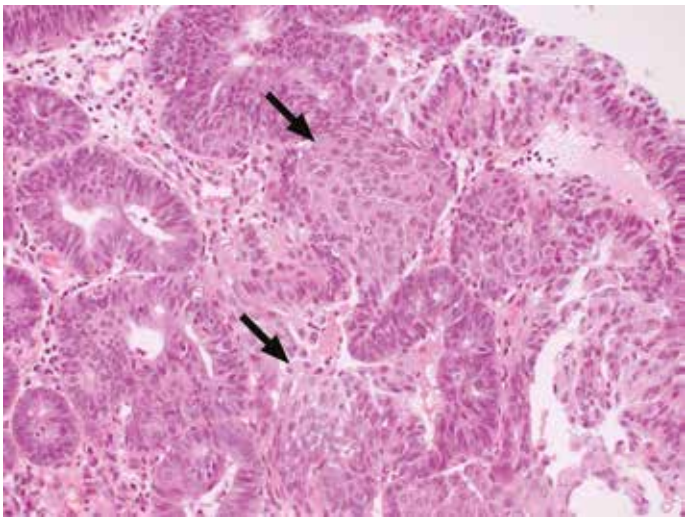

Figure 24 Endometrioid adenocarcinoma. Complex glands are lined by endometrioid epithelium, which shows foci of squamous metaplasia (arrows).

2.5.9 Clear cell adenocarcinoma

Clear cell adenocarcinoma accounts for 2–4% of cervical adenocarcinomas, and shows a bimodal age distribution (at 26 and 71 years).[86] Prior to 1990, it was associated with intrauterine exposure to diethylstilbestrol (DES). Currently, most cases are not linked to DES exposure, and the tumours are not generally HPV related. Tumours are morphologically similar to their vaginal, endometrial, and ovarian counterparts.[87]

- Tumours are composed of clear or hobnail cells.
- Intracytoplasmic mucin and eosinophilic hyaline globules may be present.
- The growth pattern is solid, tubulocystic, or papillary.
- Densely eosinophilic, hyalinised stromal cores are often identified.
- Spread from a primary tumour in the uterine corpus should be excluded, especially in older women.
- The differential diagnoses include mesonephric adenocarcinoma and hyperplasia, microglandular hyperplasia (MGH), Arias–Stella reaction, and yolk sac tumour.

Immunoprofile:

- There are no specific immunohistochemical markers, but negative staining with CD10, calretinin and vimentin may assist in distinguishing this tumour from mesonephric adenocarcinoma.

2.5.10 Serous adenocarcinoma

This tumour type, which is associated with HR-HPV, occurs in a younger age group than uterine serous carcinoma and accounts for approximately 3% of cervical adenocarcinomas.[88] The association with a poor prognosis is controversial, although aggressive behaviour is reported in some cases. Morphologically, these tumours resemble their endometrial, ovarian, and primary peritoneal counterparts.

- The tumour cells show severe cytological atypia.
- Mitotic activity is increased.
- The architecture can be of simple or complex papillary type; detached epithelial buds and psammoma bodies may be present.
- Differential diagnoses include villoglandular adenocarcinoma, papillary variants of endocervical-type adenocarcinoma, and metastasis. Spread from a primary uterine serous tumour should be excluded in older women.

Immunoprofile:

- Staining for p16 is usually positive.[89]
- p53 may be positive or negative.[88]

2.5.11 Mesonephric adenocarcinoma (Figure 25)

- This rare variant[77,90] arises in the lateral wall of the cervix, but this location may not be obvious in large tumours as any quadrant of the cervix can be involved. Mesonephric adenocarcinomas arise from mesonephric remnants, and it can be difficult to distinguish between benign remnants and adenocarcinoma when the former are overgrown by tumour. It has been suggested that these tumours have a propensity for late recurrence and metastasis.
- Tumour cells sometimes show mild nuclear atypia, but severe nuclear atypia may be present.
- The growth pattern is characterised by small, closely packed tubules that are lined by cuboidal or columnar cells.
- An admixture of growth patterns is characteristic, and ductal, retiform, solid, sex cord-like, sarcomatoid, or mixed patterns may be present.
- There are often eosinophilic, colloid-like luminal contents.

The differential diagnosis includes clear cell adenocarcinoma and mesonephric duct (MND) hyperplasia. The latter is not usually associated with a mass. Extension beyond the cervix, significant atypia or mitotic activity, and vascular or perineural infiltration are suggestive of adenocarcinoma.

Immunoprofile:

- AE1/3, CK7, epithelial membrane antigen (EMA), and CD10 may be positive, the latter showing a luminal staining pattern.
- Inhibin, vimentin, and calretinin may be positive, but the immunophenotype is variable and diagnosis should be based on morphology.[91,92]
- ER, PR, and CEA are usually negative, but may be focally positive.

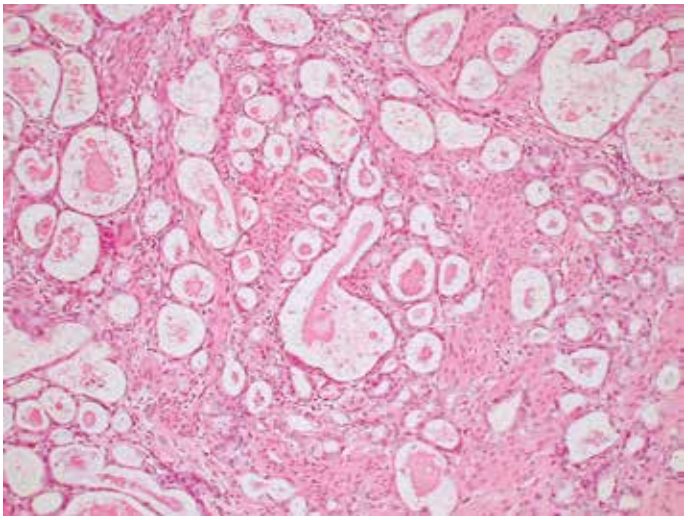

Figure 25 Mesonephric adenocarcinoma. Ductal growth pattern with mild and focally moderate cytological atypia, and eosinophilic intraluminal secretions.

2.6 Benign glandular mimics of CGIN and adenocarcinoma

A wide range of benign endocervical glandular lesions may mimic CGIN or occasionally some of the variants of adenocarcinoma.[55] When benign glandular mimics are 'hyperplastic' or appear florid, the possibility of misdiagnosis increases. The presence of adjacent, more typical appearances may be a clue to the nature of the lesion. Ancillary immunohistochemical studies are useful, but the results must be interpreted in conjunction with histomorphology.

2.6.1 TEM (Figure 26)

Synonyms are tuboendometrioid metaplasia and tubal metaplasia. TEM is a common finding after prior cervical cauterisation or resection.[93–95] However, endometrioid and ciliated epithelium, both of which are present in TEM, can also be a normal finding in the lower uterine segment, and care must therefore be taken to avoid misdiagnosis.

- Involved glands are usually, but not always, located in the superficial third of the cervical stroma. The lining of Nabothian cysts may also be affected.
- Endocervical mucinous epithelium (surface and/or crypt epithelium) is replaced by either endometrioid or ciliated tubal-type epithelium, or, more commonly, by a mixture of the different epithelial subtypes.
- The combination of different cell types (secretory, intercalated, ciliated) results in a heterogenous appearance.
- The epithelium is often infiltrated by lymphocytes, which are surrounded by halos. These may mimic apoptotic bodies.
- There is often pseudostratification, and a mild degree of nuclear atypia.
- Mitotic activity is often present and occasionally conspicuous, especially in those cases with endometrioid differentiation. However, atypical mitoses are absent.
- Apoptotic bodies are usually not present. This may be useful in distinguishing TEM from CGIN, as the latter is characterised by prominent apoptotic bodies.
- Sometimes there is a sharp demarcation between TEM and normal endocervical glands, and this can mimic CGIN.
- There is often stromal condensation and mild hypercellularity surrounding the glands; endometriosis may coexist.

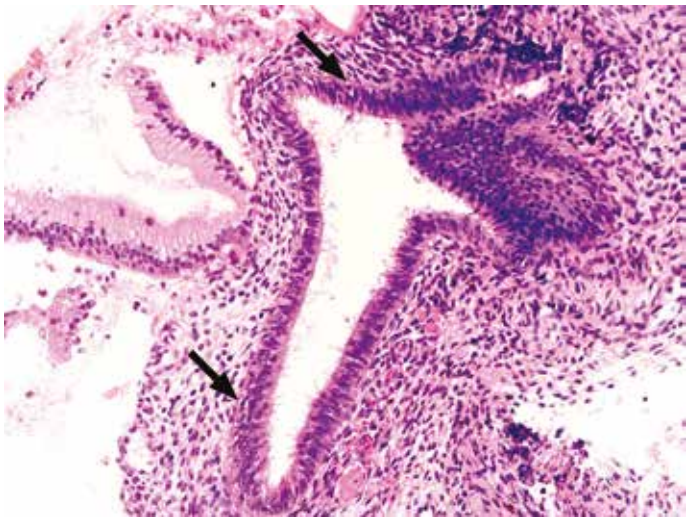

Figure 26 TEM. The crypt epithelium is replaced by a mixture of endometrioid and ciliated tubal-type epithelium. Only isolated basal lymphocytes (arrows) are present in this example.

Immunoprofile:

- MIB1 is usually <30%.
- p16 is negative or patchy.
- bcl-2 is diffusely positive.
- ER and vimentin are positive.
- This immunoprofile contrasts with that of CGIN, in which there is usually a higher MIB1 proliferation index, diffuse positivity with p16, and negative ER, vimentin, and bcl-2.[58,96–98]

2.6.2 Cervical endometriosis

Two types are described: superficial (primary) endometriosis, and deep (secondary) endometriosis.[99]

- Superficial endometriosis is more common than the deep form and often coexists with TEM, resulting in a spectrum of appearances. The location of superficial endometriosis in the cervix is similar to that of TEM, and although this form of endometriosis may occur as a result of implantation, it is often secondary to prior cervical resection or cauterisation. The cytological features are similar to TEM (although the glands are usually more overtly endometrioid in appearance), but a periglandular cuff of endometrial stroma (with or without haemosiderin-laden macrophages) is present at least focally. Occasionally, endometrial stroma without glands is seen (stromal endometriosis).

Immunoprofile:

- Similar to TEM.
- Although endometrial-type stroma may be highlighted by CD10, it should be noted that there is often a rim of CD10-positive stromal cells surrounding normal endocervical glands.[90]

- Deep endometriosis, comprising endometrial glands with surrounding endometrial stroma, is less common than the superficial type and is located in the outer aspect of the cervical stroma, in association with pelvic endometriosis. There is no association with prior cervical resection or cauterisation, and the cause is probably retrograde menstruation.

2.6.3 MGH (Figure 27)

MGH is common in premenopausal women and is associated with hormone use or pregnancy.[100] The lesion is usually focal and microscopic but, when found on the surface of endocervical polyps, it may be diffuse, grossly visible, and sometimes florid. Characteristics include:

- Small, closely packed glands of varying size, sometimes cystically dilated, lined by columnar or cuboidal cells with prominent subnuclear and sometimes supranuclear vacuoles. Intracellular mucin may be present.
- Reserve cell hyperplasia and immature squamous metaplasia can be seen.
- Acute and chronic inflammatory cells are present, including polymorphs and plasma cells, which infiltrate the glands and intervening stroma.

- There may be unusual features, such as solid, corded, or trabecular areas, a reticular pattern, signet ring cells, myxoid stroma, and prominent eosinophilic stromal hyalinisation. These may result in a worrisome morphological appearance, mimicking clear cell carcinoma or signet ring carcinoma. The presence of more typical foci of MGH facilitates diagnosis.[101]
- Significant nuclear atypia is absent, and subnuclear vacuoles are present, both of which help to distinguish MGH from clear cell carcinoma.
- Morphologically similar features may be found on the surface of endometrioid or mucinous adenocarcinomas of the uterine corpus, particularly in small biopsy samples, resulting in diagnostic problems.[102] However, MGH contains subnuclear vacuoles and is vimentin negative, while adenocarcinomas usually lack subnuclear vacuoles, have a clear association with underlying endometrial adenocarcinoma, and are vimentin positive.

Immunoprofile:

- MGH may be CEA positive but has a low MIB1 proliferation index.
- MGH is negative with p16, bcl2, and vimentin.

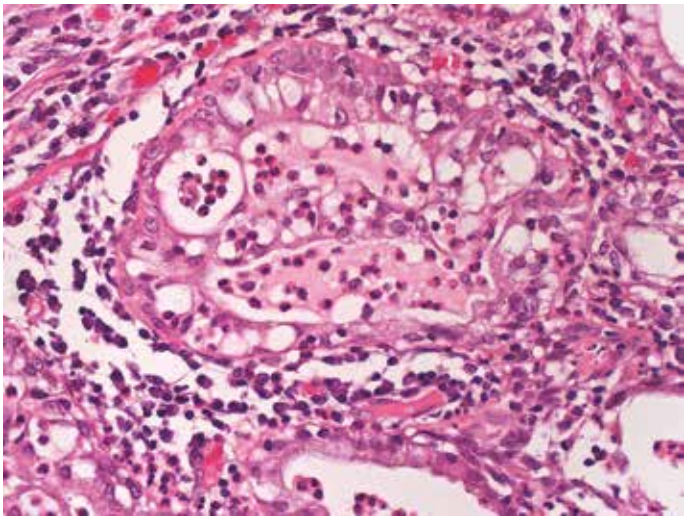

Figure 27 MGH. Closely packed, small glands of varying size, lined by columnar and cuboidal cells, some of which have subnuclear or supranuclear vacuoles. There is reserve cell hyperplasia and inflammatory cell infiltration.

2.6.4 MND remnants and hyperplasia[103]

Remnants of MNDs (Wolffian ducts) may be an incidental finding in cervical resection and hysterectomy specimens.[104] There is no associated mass lesion. MNDs are located in the lateral walls of the cervix, deep in the cervical stroma beneath normal endocervical glands. Where they are hyperplastic, MNDs may involve much of the cervical stroma, may extend close to the surface, and may be admixed with normal endocervical glands. No size cut-off has been defined to distinguish between normal and 'hyperplastic' mesonephric remnants, although a cut-off of 6 mm has been suggested in one study.[104]

- A characteristic linear arrangement is present at low-power examination, often with a central duct and small surrounding tubules, resulting in a lobular appearance (though this may be lost where there is mesonephric hyperplasia).
- The ducts and tubules are lined by either bland cuboidal or low columnar non-ciliated epithelium, with little or no nuclear stratification. The nuclei are bland and mitoses are rare.
- The cytoplasm may be clear or eosinophilic and does not contain mucin.

- Characteristic, densely eosinophilic, PAS-positive luminal material is present. This is often described as colloid-like.
- A pure ductal variant occurs, in which there is an absence of both tubules and lobular architecture. The nuclei are often more hyperchromatic in the ductal variant.
- Diffuse forms of mesonephric hyperplasia may mimic well-differentiated endocervical-type adenocarcinoma or mesonephric adenocarcinoma. Unlike endocervical adenocarcinoma, mesonephric hyperplasia is composed of small tubules with eosinophilic, colloid-like contents. It is mostly found at a deep location, without surface involvement or associated CGIN, and is typified by the absence of intracytoplasmic mucin, a desmoplastic response, nuclear atypia, and mitotic activity. Most mesonephric adenocarcinomas are characterised by a mass lesion and exhibit more obvious destructive stromal invasion and nuclear atypia. Mitotic activity is not always a prominent feature, but vascular or perineural invasion may be present, as may significant extension outside the cervix or into the uterine corpus.

Immunoprofile:

- MND remnants are positive with calretinin and vimentin and show luminal immunoreactivity with CD10.
- ER, PR, and CEA are usually negative, but androgen receptor is positive.[90]

2.6.5 Arias–Stella reaction (Figure 28)

This is usually associated with pregnancy and, less commonly, with the use of hormonal preparations. Changes may be focal and tend to involve superficial (rather than deep) endocervical glands. The morphology is identical to the Arias–Stella reaction in eutopic endometrial glands.[105]

- Endocervical glands are lined by atypical glandular cells, often with hobnail features and clear cytoplasm.
- Occasional mitotic figures may be present.
- Clear cell adenocarcinoma is excluded by the clinical history, the absence of a mass lesion, diffuse nuclear atypia, the presence of mitotic activity, and confinement to the normal gland field.

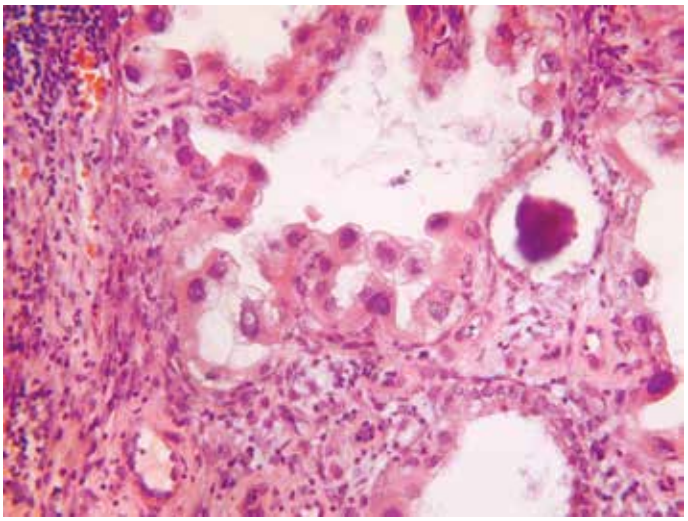

Figure 28 Arias–Stella reaction. The endocervical glands are lined by atypical glandular cells with clear cytoplasm and hobnail features.

2.6.6 Tunnel clusters

These are a common incidental finding, and may result in a gross lesion, though this is rare. Tunnel clusters are thought to develop from the involution of previously hyperplastic endocervical glands. Two variants (types A and B) are recognised, and may coexist.[106] Both have a lobular architecture.

- Type A tunnel clusters are less common and consist of tightly packed, small glands that are lined by columnar, mucinous epithelium. These can be mistaken for a small adenocarcinoma because of a somewhat infiltrative appearance at low power and a slightly cellular surrounding stroma. However, there is no nuclear atypia or mitotic activity.
- Type B tunnel clusters are more common and consist of closely packed, dilated glands that are lined by flattened, mucinous epithelium. These rarely create diagnostic problems, although a microcystic variant of adenocarcinoma, which can resemble type B tunnel clusters, has been described.[68] However, unlike type B clusters, microcystic variants of adenocarcinoma are associated with foci of usual-type adenocarcinoma, and exhibit significant nuclear atypia, mitotic activity, and a stromal desmoplastic response.

2.6.7 Ectopic prostatic tissue (prostatic metaplasia) (Figure 29)

This is likely to represent displaced, peri-urethral Skene's glands (the female equivalent of prostatic glands)[107,108] and is almost always an incidental microscopic finding. Ectopic prostatic tissue is usually located in the superficial or deep stroma of the ectocervix, but occasionally occurs close to the transformation zone.

- The glands of prostatic metaplasia include a mixture of glandular and squamous elements (Figure 29A).
- Typically the glands are double layered and may show papillary or cribriform patterns.
- The cytologically bland squamous elements tend to form central islands in the metaplastic glands.
- Ectopic prostatic tissue may be mistaken for adenoid basal carcinoma, but the latter exhibits peripheral palisading, is prostatic marker negative, and does not contain a double cell layer.

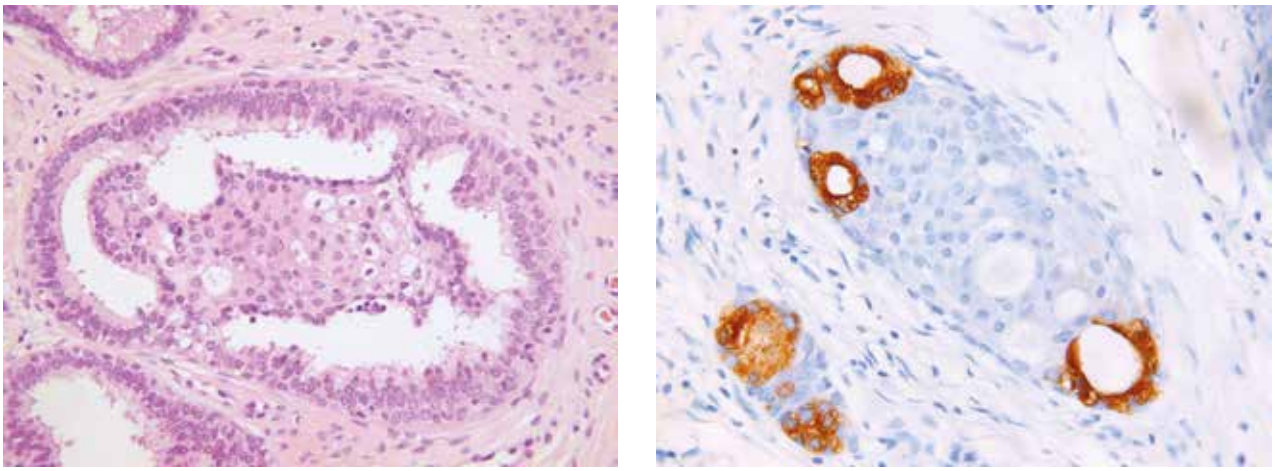

A **B**

Figure 29 Prostatic metaplasia. (A) The glandular lining is double-layered and a cytologically bland squamous component forms a central island in the metaplastic gland. (B) The glandular elements express PSA.

Immunoprofile:

- The glandular elements are usually, but not always, positive for prostatic markers (prostate-specific antigen (PSA) and prostatic acid phosphatase (PrAP) (Figure 29B). Staining may be focal and PrAP is more likely to be positive than PSA.
- The outer cell layer is usually positive with 34βE12.

2.6.8 LEGH (Figure 30)

Lobular endocervical glandular hyperplasia (LEGH) is usually an incidental microscopic finding, but occasionally results in the formation of a mass lesion.[109] The glandular proliferation is typically well demarcated and confined to the inner half of the cervical stroma, comprising a central gland with surrounding hyperplastic lobules, which exhibit gastric or pyloric differentiation.

- There is a tall, columnar, mucinous epithelial lining with no significant atypia or mitotic activity.
- An atypical form has been described (known as atypical LEGH)[78] which is thought to be the precursor of adenoma malignum and gastric-type cervical adenocarcinoma.
- LEGH can be differentiated from adenoma malignum by its superficial location and lobular architecture, and also by the absence of irregular stromal infiltration, desmoplastic response, focal nuclear atypia, and vascular/perineural infiltration.

Immunoprofile:

- LEGH may be positive for HIK1083 and MUC6.

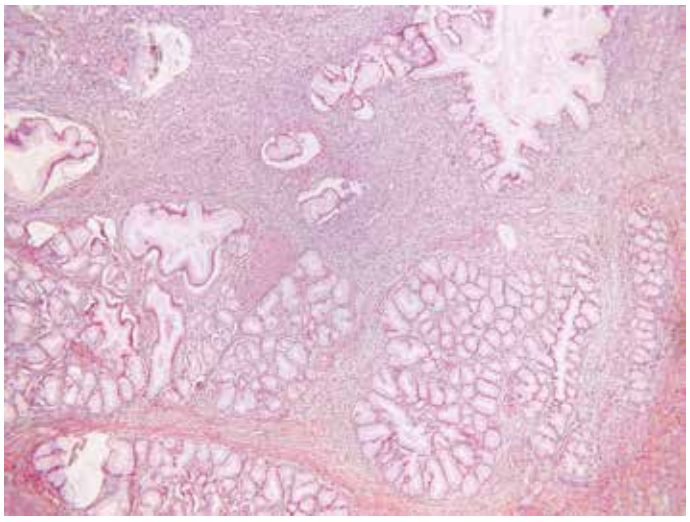

Figure 30 LEGH. The glandular proliferation comprises a central gland with surrounding hyperplastic lobules, which exhibit gastric or pyloric differentiation. The proliferation is typically well demarcated and confined to the inner half of the cervical stroma.

2.6.9 Diffuse laminar endocervical glandular hyperplasia (DLEGH)

This lesion is extremely rare[110] and is an incidental microscopic finding, characterised by diffuse proliferation of evenly spaced endocervical glands that are confined to the inner third of the cervix.

- The glands are sharply demarcated from the underlying stroma and typically form a discrete layer under which a line can be drawn. There is no lobular architecture.
- Associated inflammation may be present, with mild nuclear atypia and periglandular oedema. The latter may mimic a stromal reaction.
- DLEGH is distinguished from adenocarcinoma by its superficial location and the absence of nuclear atypia, mitotic activity, irregular infiltration, and stromal desmoplasia.

2.6.10 Florid cystic endosalpingiosis[111]

The gross appearance is of multiple cysts involving the outer aspect of the cervical wall. The uterine serosa may also be affected, and foci of non-cystic endosalpingiosis are sometimes seen on the external surface of the cervix.

- Histologically, there are multiple dilated glands in the outer aspect of the cervical stroma, and these are lined by ciliated tubal-type cells.
- Psammoma bodies may be present.
- Florid cystic endosalpingiosis is distinguished from TEM by its deep location, and malignancy is excluded by its cystic appearance and ciliation, the lack of atypia, and the absence of mitotic activity.

2.6.11 Endocervicosis[112]

This is the mucinous counterpart of endometriosis. It may be associated with prior Caesarean section, and a mass lesion may be present.

- Glands with a bland mucinous epithelial lining are observed in the outer aspect of the cervix and surrounding tissues.
- Foci of endometrioid or ciliated epithelium (müllerianosis) may be present.
- Mild nuclear atypia is present.
- Perineural involvement has been described.[112]
- Endocervicosis is distinguished from adenoma malignum by its deep location and its lack of superficial cervical stromal involvement.

2.6.12 Endocervical adenomyoma (adenomyoma of endocervical type)[113]

This usually presents as a circumscribed, polypoid lesion, which projects either into the cervical canal (where it may prolapse through the external os), or from the external aspect of the cervix into the pelvis. An intramural location has also been reported. Cystic areas may be visible grossly.

- Histologically, the lesion is composed of cysts and glands with an endocervical mucinous lining. Foci of ciliated, endometrioid, or squamous differentiation can be seen, and there may be mild reactive nuclear atypia.
- The glandular architecture may be lobular and include papillary infoldings.

- The stroma is myomatous (note that minor foci of smooth muscle may be present in the stroma of endocervical polyps).
- The main differential diagnosis is adenoma malignum, which is excluded by the circumscription and polypoid appearance of endocervical adenomyoma. The presence of smooth muscle and of a somewhat lobular architecture, and the lack of a desmoplastic response also distinguish the benign mimic from adenoma malignum.

2.6.13 Deep Nabothian cysts

- Deep Nabothian cysts are cystically dilated endocervical glands, which are often mucin filled. They are located deep in the cervical stroma, sometimes including its outer half,[114] and may impart a suspicious appearance at macroscopic examination, though they do not tend to cause problems histologically.[115]
- The lining epithelium can show TEM.

2.6.14 Radiation effect (Figure 31)

This can occur where there is a history of prior pelvic irradiation.

- Stromal and vascular changes caused by past irradiation are often present.
- The cells lining endocervical glands have enlarged, pleomorphic nuclei, often with smudged chromatin. These may take on a hobnail appearance.
- The cytoplasm tends to be eosinophilic and voluminous, resulting in a low nuclear : cytoplasmic ratio.
- Cytoplasmic vacuolation may be present.
- Mitoses are usually absent.
- Normal cells may be interspersed between pleomorphic cells.
- The cellular pleomorphism may be mistaken for in situ malignancy. However the low nuclear : cytoplasmic ratio, smudged chromatin, and lack of mitotic activity that characterise the radiation effect are helpful in confirming the diagnosis.

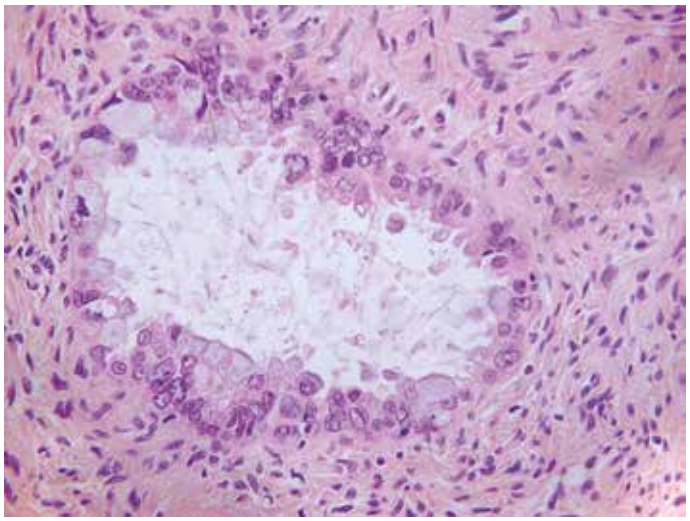

Figure 31 Radiation effect. The nuclei of some of the glandular cells are enlarged and pleomorphic. The cytoplasm is vacuolated and occasional cells have a hobnail appearance.

2.6.15 Inflammatory-associated changes

- These can result in a macroscopic abnormality and may occur on the surface of a polyp.
- Cells can have atypical nuclei (Figure 32), abundant eosinophilic cytoplasm, and a hobnail appearance.
- Multinucleated endocervical cells may be associated with inflammation; these do not indicate viral infection.
- A papillary architecture is often present ('papillary endocervicitis'), as is mild reactive nuclear atypia.
- Numerous lymphocytes, plasma cells, and neutrophils are a constant feature.

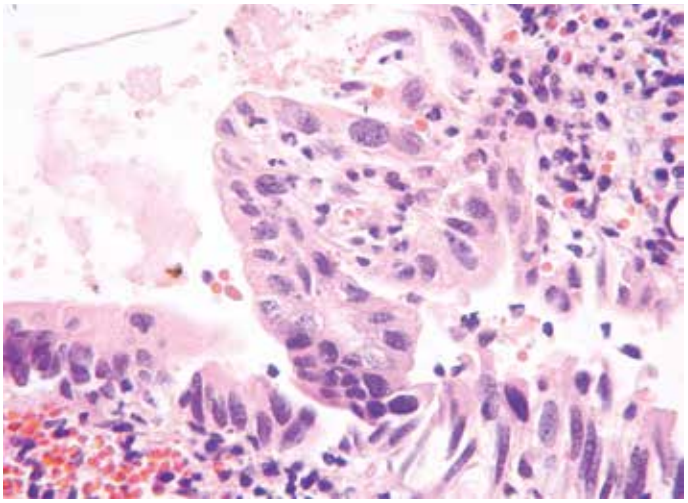

Figure 32 Inflammatory atypia. The cells have atypical nuclei and moderate amounts of eosinophilic cytoplasm. Inflammatory cells are present, and mitoses are absent.

2.6.16 Cautery/electrothermal effect (Figure 33)

This is seen at the margins of cauterised loop biopsies.

- Characteristics include nuclear streaming, stromal homogenisation, and occasionally signet ring stromal cells.[75]
- When severe, the nuclear changes may be misinterpreted as CGIN. It may also be difficult to distinguish electrothermal effects from involvement by CGIN of the endocervical resection margin.
- Immunohistochemistry may be of value in distinguishing cautery effects from CGIN (see section 2.2.2).

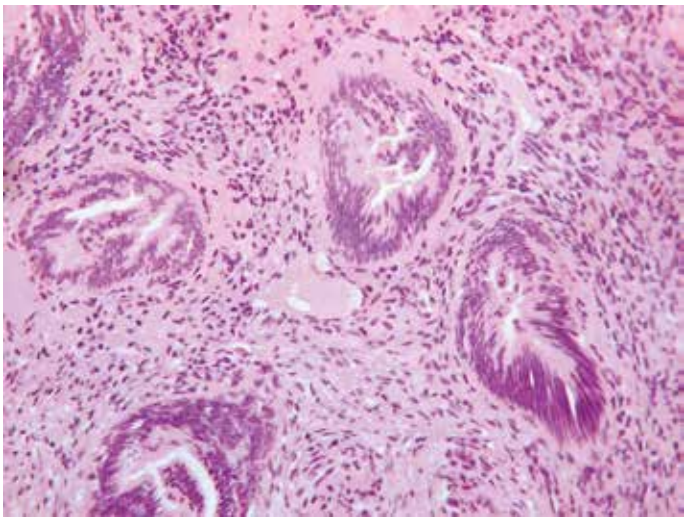

Figure 33 Cautery effect. The epithelial and stromal elements show diffuse basophilia, with nuclear streaming and hyperchromasia. In the endocervical glands, this may be misinterpreted as CGIN.

2.6.17 CMV infection

Cytopathic changes caused by CMV infection may occasionally be identified in the cervix as an incidental finding[116] in patients who are immunocompetent. The finding is of no clinical significance.

- The changes affect endocervical cells and, less commonly, endothelial cells.
- Typical CMV inclusions are present, though these are often only found focally in a few cells (Figure 34).
- Fibrin thrombi may be seen in vessels.

Immunoprofile:

- The diagnosis is confirmed by positive staining with antibodies against CMV.

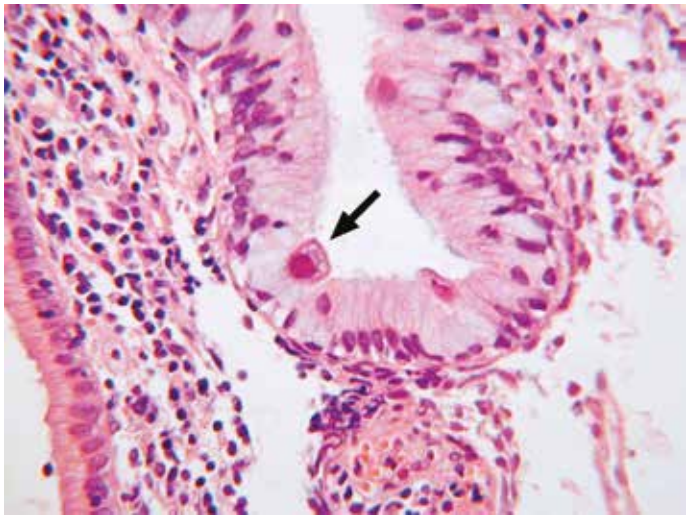

Figure 34 Cytomegalovirus (CMV) infection. Typical CMV inclusion in an endocervical epithelial cell (arrow).

2.6.18 Changes secondary to recent endometrial sampling (atypical reactive proliferation)

When the cervix is examined in hysterectomy specimens soon after an endometrial curette or biopsy[117] has been taken (usually for endometrial carcinoma) there may be cytoarchitectural changes in endocervical glands at the cervical surface. When these are florid, they can raise concerns about endocervical neoplasia or glandular involvement by endometrial carcinoma; however, awareness of the existence of benign, sampling-related changes will avert misdiagnosis. Changes include:

- Nuclear stratification and multilayering.
- Mild nuclear atypia.
- Hobnail cell changes, and a micropapillary architecture.

3 UNCOMMON CERVICAL TUMOURS

3.1 Introduction

Apart from squamous carcinomas and adenocarcinomas, most cervical neoplasms are uncommon or rare. The most frequently diagnosed of these rare tumours are the neuroendocrine neoplasms, especially the small cell neuroendocrine carcinomas. Mixed epithelial and mesenchymal neoplasms (mixed müllerian tumours) also occur but are much less common in the cervix than in the uterine corpus. Pure mesenchymal neoplasms (especially smooth muscle tumours) occur in the cervix, as do rare lymphoid and melanocytic lesions, and metastases from other primary sites.

3.2 Neuroendocrine tumours

3.2.1 Definition and general comments

- The WHO classifies neuroendocrine tumours as carcinoid tumours, atypical carcinoid tumours, and small and large cell neuroendocrine carcinomas (SCNEC and LNEC, respectively).[34]
- Of these rare subtypes, SCNEC is the most common, followed by LCNEC. Carcinoid and atypical carcinoid tumours are rare and are morphologically identical to the corresponding neoplasms in other organs.[118–124]
- The term 'SCNEC' should be used rather than 'small cell carcinoma', to avoid confusion between small cell neuroendocrine carcinoma and the small cell variant of squamous carcinoma.
- SCNEC and LCNEC are HPV-related neoplasms. They are most commonly associated with HPV types 16 and 18.[122,124]
- Cervical neuroendocrine carcinomas may be associated with premalignant or malignant endocervical glandular lesions. Foci of CIN or squamous carcinoma are also occasionally present.
- Occasionally, areas of SCNEC and LCNEC may be admixed with other types of neoplasm (Figure 35).
- SCNEC and LCNEC are aggressive cervical neoplasms with a propensity for widespread systemic metastasis; even neoplasms with a minor component of SCNEC or LCNEC may behave aggressively.
- Since management differs from other morphological subtypes of cervical carcinoma, accurate diagnosis is imperative.

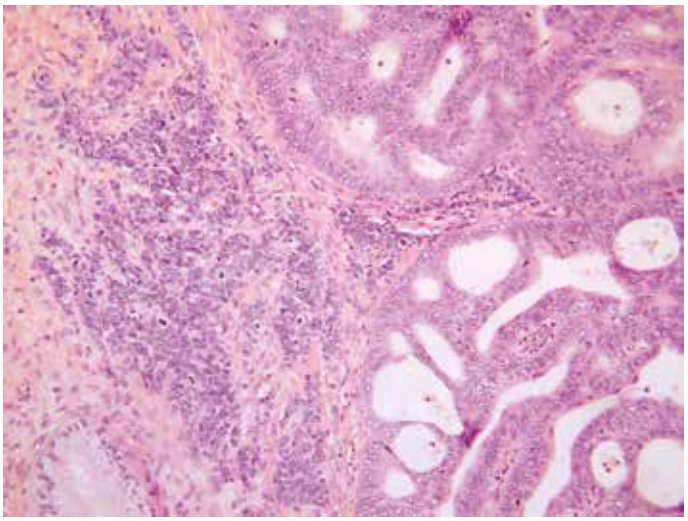

Figure 35 Combined tumour. SCNEC (left of field) is associated with a moderately-differentiated endocervical adenocarcinoma.

3.2.2 Morphological features of small cell neuroendocrine carcinomas (Figure 36)

- SCNEC is composed of a monotonous population of cells with ovoid or slightly spindled hyperchromatic nuclei (Figure 36A), often exhibiting moulding. The cells have scanty cytoplasm. There is usually abundant mitotic and apoptotic activity.
- There may be extensive crush artefact, nuclear fragmentation, and necrosis (Figure 36B).
- A diffuse growth pattern usually predominates, but nests, trabeculae, and rosette-like structures are sometimes present.

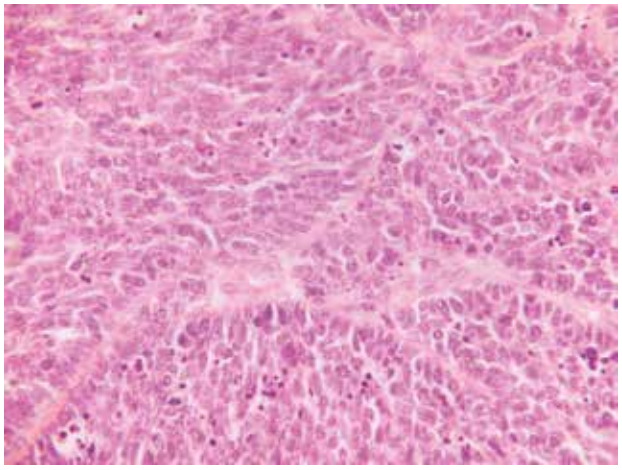

A

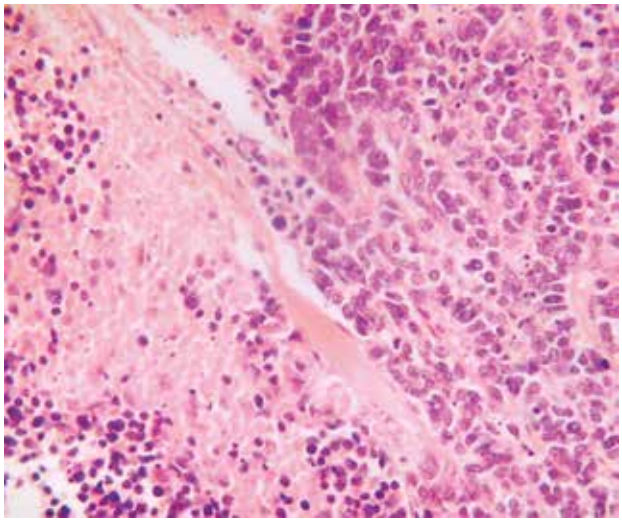

B

Figure 36 SCNEC. (A) A monotonous population of small cells that have ovoid or spindled hyperchromatic nuclei and scanty cytoplasm. There is abundant mitotic activity and apoptosis. (B) Tumour necrosis and abundant apoptotic activity.

3.2.3 Morphological features of LCNECs (Figure 37)

- Travis et al.[125] have defined the morphological features of pulmonary LCNEC tumours. Cervical tumours exhibit similar characteristics:
  a) Cells are of large size and polygonal shape, and have a low nuclear : cytoplasmic ratio.
  b) Nuclei show coarse chromatin and prominent nucleoli.
  c) Mitotic activity is in excess of 10 per 10 high-power fields.
  d) There is immunohistochemical or ultrastructural evidence of neuroendocrine differentiation.
- Additionally, insular, nested, trabecular, glandular, and solid growth patterns, often with extensive necrosis, are usually present.
- Nuclear palisading may be seen around the periphery of cell nests.
- Eosinophilic cytoplasmic granules may be present.

LCNEC is probably underdiagnosed and may be misdiagnosed as poorly-differentiated squamous carcinoma or adenocarcinoma. This is more likely if a component of either of the latter is also present.

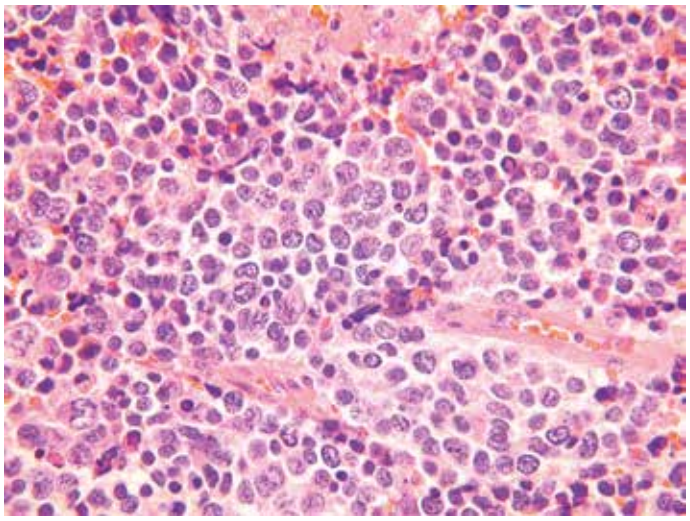

Figure 37 LCNEC. The tumour cells are of large size, have a polygonal shape and scanty, eosinophilic, slightly granular cytoplasm. The nuclei contain coarse, granular chromatin and some have distinct nucleoli.

Immunoprofile of SCNEC and LCNEC:

- SCNEC is variably positive with the neuroendocrine markers chromogranin, CD56, synaptophysin, and PGP9.5. Of these, CD56 and synaptophysin are the most sensitive, but CD56 lacks specificity. Chromogranin is the most specific neuroendocrine marker, but lacks sensitivity, marking only about 50% of these neoplasms as positive.[126]
- A diagnosis of SCNEC can be made in the absence of neuroendocrine marker positivity if the morphological appearances are typical.
- SCNEC may be negative with broad-spectrum cytokeratins or show only focal positive staining (often punctate cytoplasmic staining is seen).
- At present, a diagnosis of LCNEC requires neuroendocrine marker positivity.
- A high percentage of primary cervical SCNEC and LCNEC are TTF1 positive, including some types that show diffuse immunoreactivity. This marker is therefore of no value in excluding metastasis from a primary lung tumour.[126]
- Most SCNEC and LCNEC are diffusely positive with p16, secondary to the presence of HR-HPV.[126]
- Diffuse p63 nuclear positivity is useful in confirming the presence of a small-cell variant of squamous carcinoma, rather than SCNEC. However, occasionally SCNEC and LCNEC exhibit p63 nuclear immunoreactivity.[126–127]
- Some SCNEC and LCNEC are positive with CK7, CK20, neurofilament, or CD99. Such aberrant staining reactions may result in confusion with Merkel cell carcinomas or tumours of the Ewing family.[126]
- Peptide hormones, including adenocorticotrophic hormone, calcitonin, glucagon, and gastrin, have been demonstrated in some tumours.

3.2.4 Management

- Establishing a correct diagnosis of SCNEC or LCNEC is important, because they are managed differently from other morphological subtypes of cervical carcinoma.
- Surgical treatment is not usually undertaken, even if these neoplasms are of small size and clinically and radiologically confined to the cervix.
- Specific chemotherapy, active against neuroendocrine carcinomas, is often given.
- Prophylactic cranial irradiation may be administered.

3.3 Adenosquamous carcinoma (Figure 38)

This accounts for approximately 3.6% of cervical carcinomas.[128]

- Adenosquamous carcinomas are HPV related, and are distinguished from endometrioid adenocarcinoma by the presence of benign squamous elements in the latter and malignant squamous elements in the former.
- Tumours are graded as well-, moderately-, or poorly-differentiated, according to the degree of differentiation seen in the squamous and glandular components.
- The presence of morphological elements of both glandular and squamous type in H&E-stained sections is required for diagnosis.
- Scattered mucin-containing cells may be found in a significant percentage of poorly-differentiated squamous carcinomas, and care must be taken not to misdiagnose these cases as adeno-squamous carcinoma.[129]

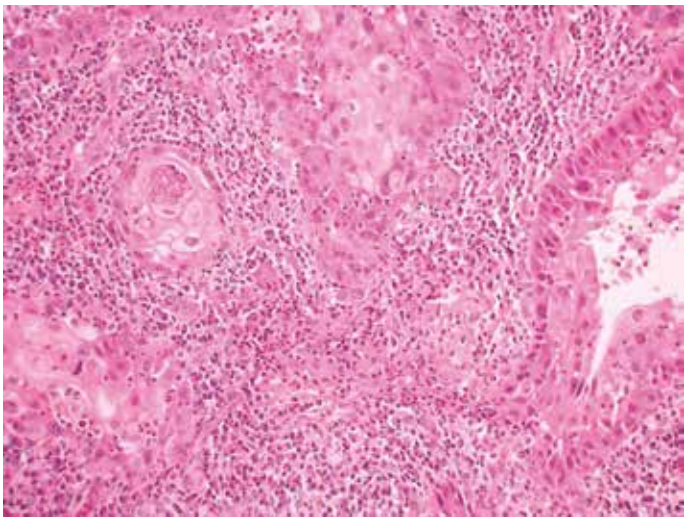

Figure 38 Adenosquamous carcinoma. Both malignant glandular and squamous elements are required for the diagnosis. There is a brisk host inflammatory reaction to the carcinoma in this case.

3.4 Glassy cell carcinoma variant of adenosquamous carcinoma (Figure 39)

These HPV-related tumours account for approximately 1–2% of cervical carcinomas.[130,131] There is significant interobserver variability in their diagnosis. Originally these tumours were thought to have a poor prognosis, but survival rates are similar to those for other poorly-differentiated cervical carcinomas, with tumour stage being an important prognostic factor.

- The tumour cells are typically large, with abundant eosinophilic, finely granular (ground-glass) cytoplasm. Rare single cell keratinisation may be seen.
- The growth pattern is one of nests and sheets.
- An eosinophil-rich inflammatory infiltrate is frequently present.
- Typically there is no associated in situ component of CIN or CGIN.

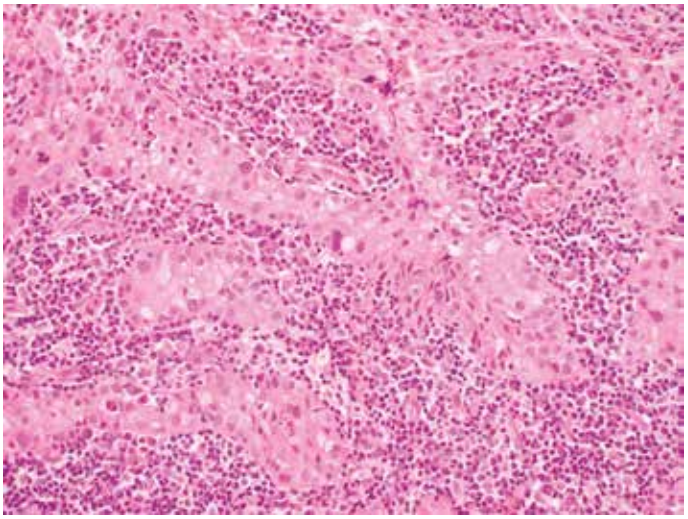

Figure 39 Glassy cell carcinoma variant of adenosquamous carcinoma. The tumour is composed of tracts of large, eosinophilic tumour cells with abundant eosinophilic, 'ground-glass' cytoplasm. The carcinoma is associated with a brisk host inflammatory reaction, which often contains eosinophils, although few are present in this example.

3.5 Adenoid cystic carcinoma

This tumour variant occurs mainly in postmenopausal women, and is similar morphologically to the corresponding salivary gland tumour. It accounts for less than 1% of cervical adenocarcinomas.[132,133] The prognosis is poor.

- Tumour cells are rounded or cuboidal with hyperchromatic nuclei and a high nuclear : cytoplasmic ratio.
- Necrosis is present and mitotic activity is high.
- The architecture is cribriform, but acini, nests, and cords are also seen. There is peripheral palisading of tumour cells, with PAS-positive extracellular hyaline material.
- A solid variant is described, which lacks a cribriform growth pattern. Solid tumour elements are surrounded by abundant PAS-positive hyaline basement membrane material.[134]
- Lymphatic permeation is common.
- The differential diagnosis includes adenoid basal carcinoma, SCNEC, and non-keratinising variants of squamous carcinoma.

3.6 Adenoid basal carcinoma

This is an uncommon tumour that occurs mainly in postmenopausal women (usually without cervical enlargement). It is usually an incidental microscopic finding, unless associated with other variants of cervical carcinoma (in which case, the prognosis is related to the other tumour type and may be poor). In its pure form, however, the prognosis is good and this has led to the designation of such tumours as 'adenoid basal epithelioma'.[135,136]

- The tumour cells are bland, mitotically inactive, and show peripheral palisading.
- The tumour growth is in small infiltrative nests and acini.
- No stromal reaction is seen.
- There may be associated CIN, and other types of carcinoma may be present.
- The tumour is distinguished from adenoid cystic carcinoma by the absence of basement membrane material, necrosis, significant mitotic activity, or vascular invasion.
- The bland nature of the tumour cells and peripheral palisading exclude squamous carcinoma.

3.7 Mixed epithelial and mesenchymal tumours

3.7.1 Carcinosarcoma (Figure 40)

This is a rare primary cervical neoplasm[137] that is characterised morphologically by malignant epithelial and mesenchymal components.

- The epithelial component may be squamous, glandular (of variable subtype), or undifferentiated.
- The stroma may be undifferentiated sarcoma, fibrosarcoma, leiomyosarcoma, or contain heterologous elements (chondrosarcoma or rhabdomyosarcoma).
- It is important to exclude spread from a primary tumour in the uterine corpus.

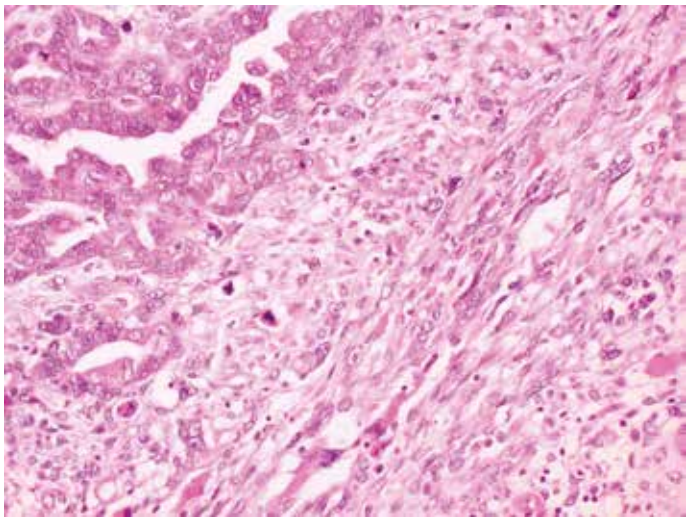

Figure 40 Carcinosarcoma. This tumour contains malignant epithelial and mesenchymal components. The epithelial component comprises moderately-differentiated endocervical-type adenocarcinoma (left side of field) and undifferentiated sarcoma (right of field).

3.7.2 Adenofibroma and adenosarcoma

These are rare primary cervical neoplasms[138] and are more commonly found in the uterine corpus than in the cervix. The tumours are composed of a benign epithelial component and a stromal component, which is either benign (adenofibroma) or malignant (adenosarcoma). Adenofibroma is less common than adenosarcoma; indeed, some doubt the existence of the former.[138]

- Lesions are usually polypoid and project into the cervical canal.
- The low-power architecture is club-like, leaf-like, or phyllodes-like.
- Adenosarcoma is distinguished from adenofibroma by increased cellularity surrounding the epithelial elements (cambium layer), stromal atypia, and mitotic activity in excess of 2 per 10 high-power fields.[34] In practice, however, a diagnosis of adenosarcoma can be made in the absence of this degree of mitotic activity, if the characteristic low-power architecture and cambium layer are present.[138]
- The treatment of choice is hysterectomy, given the risk of recurrence following polypectomy.
- The main adverse prognostic features with adenosarcoma are deep invasion and sarcomatous overgrowth.[138]

3.8 Mesenchymal tumours

This group of tumours is much less common in the cervix than in the uterine corpus. Alongside those discussed separately below, other mesenchymal neoplasms described in the cervix are endometrial stromal neoplasms, uterine tumours resembling ovarian sex cord tumours, inflammatory myofibroblastic tumours, epithelioid sarcomas, and malignant rhabdoid tumours.[139–141]

Alveolar soft-part sarcomas are also reported, and these are more common in the cervix than in the uterine corpus.

3.8.1 Leiomyoma

Leiomyomas are the most common type of mesenchymal tumour found in the cervix.

- Cervical leiomyomas often exhibit a degree of nuclear palisading, reminiscent of a neurilemmoma.
- Leiomyoma variants, similar to those occurring in the uterus, can also arise.

3.8.2 Other mesenchymal tumours

- Leiomyosarcomas occasionally occur as primary cervical neoplasms.
- Embryonal rhabdomyosarcoma (sarcoma botryoides) occurs as a primary cervical neoplasm, usually in women in their late teens and early twenties.[142] It usually presents as a polypoid lesion, which may be removed by polypectomy.
- Superficial myofibroblastoma of the lower female genital tract and may occur as a primary cervical neoplasm.[143,144]

3.9 Haematopoietic lesions

3.9.1 Lymphomas and leukaemias

It is rare to find lymphomas and leukaemias involving the cervix as part of a systemic process.[145,146] Primary cervical lymphomas have occasionally been reported, but strict criteria should be used to exclude spread from elsewhere.

3.9.2 Lymphoma-like lesion

This usually occurs in women of reproductive years,[147] and is composed of a dense infiltrate of lymphoid cells, which may be mistaken for lymphoma. The lesion is usually an incidental microscopic finding, in contrast to lymphoma, which typically forms a mass.

- The lymphoid infiltrate is usually band-like and lies just beneath the surface mucosa, which may be ulcerated.
- The lymphoid population is polymorphic, but significant numbers of blasts may be present.

Immunoprofile:

- Markers show a mixture of B and T lymphoid cells, without evidence of light chain restriction.
- Occasional cases exhibit clonal immunoglobulin heavy chain gene rearrangement, which does not warrant a diagnosis of lymphoma.[148]

3.10 Melanocytic neoplasms

These are uncommon in the cervix, but benign and malignant variants can sometimes occur.

- The most common benign melanocytic lesion is a blue naevus,[148] which usually occurs as an incidental microscopic finding but is occasionally visible macroscopically. Located within the superficial cervical stroma, this subtype of neoplasm consists of S100-positive polygonal and spindle cells containing melanin pigment.
- Malignant melanoma also occurs in the cervix.[149] Before diagnosing primary cervical malignant melanoma, metastasis should be excluded. Adjacent in situ melanoma is useful in confirming a primary cervical neoplasm.

3.11 Miscellaneous tumours and metastases

- Rare miscellaneous neoplasms reported to arise as primary tumours in the cervix include trophoblastic tumours, yolk sac tumours, gliomas, and tumours of the Ewing family.
- Cervical metastases from primary tumours arising at anatomical sites other than the uterine corpus are uncommon. It is not uncommon for endometrial adenocarcinomas to spread to the cervix, usually by direct extension.
- Breast carcinoma, especially of lobular type, may metastasise to the cervix and tends to show a typical Indian file growth pattern, which provides a clue to its provenance.

Metastases from primary ovarian, peritoneal, and pancreatic tumours have been reported, and these may mimic primary cervical adenocarcinoma and CGIN.[150]

4 COLPOSCOPY: INDICATIONS FOR COLPOSCOPIC REFERRAL, METHODS OF TREATMENT AT COLPOSCOPY, AND FOLLOW-UP OF HISTOLOGICALLY CONFIRMED PREINVASIVE AND INVASIVE DISEASE

4.1 Introduction

This chapter provides a brief overview of the indications for colposcopy referral and the importance and consequences of histological diagnosis for the management of women within the NHS Cervical Screening Programme (NHSCSP). Detailed colposcopy guidance and programme management are covered in *Colposcopy and Programme Management* (NHSCSP Publication No 20)[19] and *HPV Triage and Test of Cure: Draft Implementation Guidance* (NHSCSP Good Practice Guide No 3).[151]

4.2 Referral guidelines for colposcopy

Direct referral for colposcopic examination now takes place in most laboratories that participate in the NHSCSP.

4.2.1 Direct referral to colposcopy following abnormal cytology

Colposcopic referral following cytology should take place in the following situations:

- Where one test shows high-grade dyskaryosis, ?invasion, or worse.
- On the occurrence of a third consecutive sample with an inadequate result.
- After one test shows borderline changes (including borderline change in endocervical cells) and the woman tests positive for HR-HPV (HPV triage).
- After one test shows low-grade dyskaryosis and the woman is positive for HR-HPV (HPV triage).

The 62-day cancer pathway applies where:

- Any test shows high-grade dyskaryosis.
- Any sample shows possible invasion.
- Any test shows ?glandular neoplasia.
- There is an abnormal or suspicious appearance of the cervix.

In England, urgent colposcopic referral (within 2 weeks) is required for any sample showing possible invasion, any test reported as ?glandular neoplasia, and any abnormal or suspicious appearance of the cervix.

Where direct referral is not active, all women with a high-grade cytology result (moderate, severe, ?invasive, glandular) who are referred by GPs must be referred urgently, via the 2-week pathway.

Women with borderline or low-grade changes should normally be seen within 6 weeks. All treatment should be completed within 18 weeks for those who do not have cancer.

4.2.2 Previous treatment for CIN

If a woman tests positive for HR-HPV following treatment for any grade of CIN, she should be re-referred for colposcopic assessment. This applies irrespective of whether the cytology result is normal, low grade, or borderline (HPV test of cure).

4.2.3 Cases presenting with symptoms

Women presenting with symptoms (post-coital bleeding especially in women over 40 years old; intermenstrual bleeding, and persistent vaginal discharge) should be referred for gynaecological examination and thence for colposcopy if cancer is suspected.

4.3 Management of cellular changes

4.3.1 Colposcopically directed biopsies of the cervix

These are taken from areas of abnormality that are identified at colposcopic examination:

- In women with low-grade cytological changes, who have an abnormal transformation zone.
- In women with high-grade cytological changes, if excisional treatment is not performed at that visit for other reasons.

Additionally:

- All women should have diagnostic biopsies performed prior to undergoing ablative treatment, irrespective of cytology results.
- Directed biopsies should not be considered definitive if a glandular lesion or invasive disease is suspected.
- Multiple biopsies are recommended, as they result in improved diagnostic accuracy.[152]
- The reasons for not performing a biopsy must be recorded.

4.3.2 Excisional biopsy

Excisional biopsies are recommended:

- When high-grade cytological changes are reported, and a high-grade abnormality is confirmed at colposcopy.
- When a lesion extends into the endocervical canal.

Treatment after directed biopsies must take cytological and colposcopic findings into consideration.

4.4 Documentation of colposcopic examination and information required when submitting specimens for histology

Women who undergo colposcopic assessment should have the following information clearly documented in their hospital notes:

- The reason for referral, or the grade of the cytological changes.
- The adequacy of colposcopic examination (i.e. whether or not the squamocolumnar junction was fully visualised) and documentation of whether the upper limit of any cervical lesion was seen.
- The colposcopic features and overall impression of the cervical lesion, especially if there is a suspicion of invasive disease.
- The presence or absence of endocervical and vaginal extension.

When submitting a specimen for histological examination, the colposcopist should provide all relevant clinical details on the request form, the grade of the cytological changes, and colposcopic findings for the histopathologist who will be examining the specimen.

4.5 Treatment of CIN

Women with high-grade disease (CIN2 or CIN3), or persistent low-grade disease (CIN1), should be offered treatment to prevent progression to cancer.[153] Treatment is usually conservative and involves excisional or ablative/destructive techniques. There is no single conservative technique (excisional or ablative) for treating and eradicating CIN that is more efficacious and therefore preferable.

4.5.1 Treatment modalities

There are two main types:

- Excisional techniques:
  - LLETZ is the most common treatment modality used in England.
  - Other excisional techniques, such as NETZ (needle excision of the transformation zone), CO_2 laser, or cold knife conisation are sometimes used.

- Ablative techniques:
  - Cold coagulation.
  - Cryocautery.
  - Laser vaporisation.

4.5.2 Use of ablative techniques

Ablative techniques should only be used:

- Where diagnostic biopsies have been carried out to confirm the nature of the lesion.
- When the entire transformation zone is visualised.
- Where there is no evidence of a glandular abnormality or invasive disease.
- When there is no major discrepancy between cytology and histology.

Cryocautery should only be used for low-grade CIN, and a double freeze–thaw–freeze technique must then be employed in all cases. However, it should be borne in mind that clearance of CIN3 is poor with this technique.[154]

4.5.3 Standards for excisional treatment

- The specimen should be removed as a single sample in ≥80% of cases.
- For ectocervical squamous lesions, tissue to a depth of >7 mm should be removed.
- For glandular lesions, tissue to a depth of >10 mm above the squamocolumnar junction should be excised.

4.6 Treatment of early-stage invasive disease

In cases of early-stage (stage IA) invasive disease, excisional treatment may be offered and is considered to be adequate.

4.7 Other methods of treating CIN and early-stage invasive disease: hysterectomy and trachelectomy

4.7.1 Hysterectomy

Hysterectomy is usually performed for cervical intraepithelial abnormalities when further local excisional or ablative therapy is not possible, when there are other clinical indications to undertake a hysterectomy, or when the patient declines conservative management options.

4.7.2 Radical trachelectomy

Radical trachelectomy is a management option for early cervical cancer (tumours less than 20 mm in size) in women who wish to conserve their uterus to retain fertility.

- Trachelectomy specimens should be examined by a specialist gynaecological pathologist or a pathologist with a special interest in gynaecological pathology.
- Assessment of the endocervical resection margin[23] is of particular importance in such cases, and the use of a standardised reporting proforma is recommended. Frozen section examination may be required.[155]

4.7.3 Resection margins in hysterectomy and trachelectomy

- The status of resection margins is important when assessing the risk of residual disease. The use of standardised histology reports or templates for reporting excisional biopsies ensures detailed and consistent documentation of this information (see Appendix 1).[23,156]
- When resection margins are involved, further management will depend upon a combination of histological and clinical parameters.

4.8 Management of patients after primary treatment

4.8.1 Post-treatment surveillance

Women who have been treated for CIN are at a higher risk of recurrent intraepithelial disease and cervical cancer than women in the general population.[157]

- Post-treatment surveillance is aimed at the early identification of residual or recurrent disease, thereby preventing progression to cancer.
- Histological findings in the excised specimen guide the subsequent management of women within the NHSCSP. The nature of the intraepithelial lesion, and the status of resection margins in the loop biopsy specimen, are especially important.

4.8.2 Management after local excision

- HPV test of cure will be applied to all women attending their first post-treatment follow-up appointment or cytology test, irrespective of the grade of treated CIN. HPV tests will also be performed on all women currently in annual follow-up after treatment for CIN (wherever they are in the 10-year surveillance process), thereby allowing some of them to return to routine recall (see section 4.8.3).
- If a woman fails to attend for colposcopy after having been treated for CIN, and returns to the care of her GP *before* her first follow-up cervical cytology sample, she should still be included in the test of cure protocol.
- High-grade CIN with involved resection margins, especially the endocervical margin, is associated with a higher risk of persistent or recurrent disease. Further treatment is usually recommended for women over the age of 50 with involved endocervical resection margins.[158]

4.8.3 Test of cure protocols

Test of cure applies to women who have been treated for CIN. They will be offered cytology and HPV testing 6 months after treatment.

- All women who have normal, borderline, or low-grade cytology results, and who are HR-HPV negative, will be invited for their next cytology test in 3 years, regardless of their age. If their 3-year cytology report is negative, they revert to their normal recall pattern (i.e. every 5 years for women over 50, or every 3 years for women aged 25–49).
- Women with normal, borderline, or low-grade dyskaryosis who are HR-HPV positive are re-referred to colposcopy.
- Women with high-grade dyskaryosis (moderate or worse) are referred to colposcopy, whatever their age.

The test of cure protocol does not apply to CGIN.

- Because women who have been treated for CGIN are at higher risk of developing recurrent disease than those treated for high-grade CIN, 10 years of cytological follow-up are required. The first sample should be taken 6 months after treatment. If it is negative, then cytology should be repeated at 12 months, and then annually for the subsequent 9 years (minimum standard).
- Incompletely excised, high-grade CGIN requires further treatment.

4.8.4 Management after ablative treatment

- Follow-up is cytological and follows the test of cure protocol (see above), irrespective of the method of treatment employed for the CIN.

4.8.5 Management after hysterectomy for CIN

- If the CIN is completely excised, vaginal vault cytology at 6 and 18 months after a hysterectomy is required.
- If the excision status is uncertain, or CIN is incompletely excised, follow-up depends on the grade of the CIN in the hysterectomy specimen. Vault cytology is required at 6 and 12 months for low- and high-grade CIN. If both follow-up vault smears are negative in patients who have had incomplete excision of low-grade CIN, these patients can be discharged. However, according to existing guidance, a further nine annual vault cytology samples are required for high-grade CIN. Clinicians may wish to consider a triple approach with colposcopy, cytology, and an HPV test in these circumstances, *although this is not part of the cervical screening programme, and the treating clinician must make robust arrangements for the follow-up of such patients*.
- CIN that extends to the cervical resection margins, or vaginal intraepithelial neoplasia (VaIN) at vaginal resection margins is associated with a higher likelihood of persistent disease. Retreatment may be needed in the event of persistent or recurrent disease at cytological follow-up.

4.8.6 Management after trachelectomy

- There is no standard follow-up protocol, but it is recommended that patients who have undergone this form of treatment as part of conservative management for cervical cancer should remain under the care and guidance of the gynaecological oncologist who carried out the treatment. In view of the lack of available evidence on long-term follow-up, and bearing in mind the risk of recurrent cytological changes, follow-up with cytology and colposcopy is recommended. MRI may also be carried out as part of the follow-up.
- Cytology samples taken after trachelectomy may be difficult to interpret and should be assessed by an experienced gynaecological cytopathologist. Specialist review of abnormal post-trachelectomy cytology may be required before deciding upon further treatment.

4.9 The colposcopy MDTM

Meetings of the colposcopy multidisciplinary team are an important component of the national cervical screening programme and are essential to the provision of high-quality, integrated patient care. Not only are these meetings educational, they are also essential to the provision of advice about patient management, audit, and quality assurance within the local screening programme.

- The group should have a minimum core membership of the lead gynaecological pathologist, lead cytologist, and lead colposcopist and should also include the Hospital-Based Programme Co-ordinator (HBPC) for cervical screening.
- Each colposcopist should attend at least 50% of the meetings.
- The MDTM should occur no less than every 2 months to ensure timely management of both problematic patients and cases with discordant results.[159]

- There should be clear guidelines defining which cases are referred to, and discussed at, the MDTM. It is difficult to be prescriptive in this matter, especially in the light of varying local workload and practices,[11] but discussion of the following cases is recommended:
  - All cytology results in which abnormal glandular cells are reported, including the subsequent histology from these cases.
  - All invasive cytology results and their subsequent histology.
  - All cases in which there is a mismatch of at least two grades between cytology, colposcopy, or histology.[160]
- The outcome of multidisciplinary team reviews should be fed back to the clinician with responsibility for care of the patient.
- Regular audit of referral, treatment proposals, and patient outcomes after MDTM review is recommended.

5 CERVICAL CYTOLOGY: FOLLOW-UP PROTOCOLS AND HPV TRIAGE

Standardisation of follow-up after the identification of cytological changes or histological confirmation of preinvasive disease is essential for an efficient and cost-effective cervical screening programme. It is important to ensure compliance with all follow-up recommendations, and unscheduled cervical samples are therefore discouraged. These guidelines have been modified to take into account the implementation of HPV triage and 'test of cure' protocols (see Appendix 3).[151]

5.1 Management of low-grade cytological changes

5.1.1 Changes to guidance

Until recently, NHSCSP guidance recommended that all women with persistent borderline changes in squamous cells, as well as those presenting for the first time with low-grade dyskaryosis, should be referred for colposcopy.[19] However, evidence has shown that triage of such women by HR-HPV testing is more sensitive, though slightly less specific, for the detection of high-grade CIN.[161,162]

- The results of the NHSCSP liquid-based cytology (LBC) HPV pilot[163] suggest that although HPV triage decreases the number of repeat cytology tests and reduces the time taken to return women to routine recall, it results in an increase in referrals to colposcopy.
- HPV triage is not only feasible and acceptable to women, but the results of an economic analysis concluded that it was cost-effective in terms of quality of service and life-years saved.[164,165]

5.1.2 Sentinel Site study

In 2007 the Sentinel Site study was initiated to determine the feasibility of national roll-out of HPV triage, to evaluate the rates of referral to colposcopy, and to determine the positive predictive value of this approach.[166]

- HPV-positive rates were 53.7% in women with borderline cytology, and 83.9% in women with low-grade dyskaryosis.
- Among the six study sites, the HPV-positive rates ranged from 34.8% to 73.3% for borderline cytology, and 73.4% to 91.6% for low-grade dyskaryosis.
- In the single site using both LBC technologies, there were no differences in HPV-positive rates between the two technologies.
- The positive predictive value of an HPV test was 16.3% for CIN2 or worse, and 6.1% for CIN3 or worse.
- It was concluded that triaging women with low-grade cytological changes using HPV testing would allow approximately one-third of these women to return immediately to routine recall. Immediate referral for colposcopy avoids the need for repeat cytology in the remaining group. Variation in HPV-positive rates will result in differing colposcopy workloads.[151]
- It has now been recommended that HPV triage of low-grade cytological changes be implemented throughout the NHSCSP. Implementation guidance is available.[151,167]

5.2 Follow-up after treatment for CIN

5.2.1 Previous guidance

- Previous NHSCSP guidance recommended that women who had been treated for a low-grade histological abnormality (HPV-related changes/CIN1) required follow-up cytology at 6, 12, and 24 months after treatment. If all results were negative, these women reverted to screening at the routine interval.[19]
- Women who were treated for high-grade CIN (CIN2 or CIN3) required 6- and 12-month follow-up cytology, and annual cytology for the subsequent 9 years, before returning to screening at the routine interval.[19]

5.2.2 HPV testing: new guidance

HPV test of cure was introduced throughout the NHSCSP on 1 April 2012.[167]

- Evidence suggests that HPV test of cure is more sensitive, albeit slightly less specific, than cytology when used to follow up women treated for low- and high-grade CIN.[161,162,168]
- HPV test of cure uses HR-HPV testing to assess a woman's risk of having residual or recurrent disease after treatment of CIN.
- Results from the Sentinel Site Study show that using HPV test of cure enables 80% of women to revert to routine recall 6 months after treatment (instead of having up to 10 years of annual cytology follow-up). Women return for two or three routine cytology tests in the 10 years after treatment, depending on their age.
- Results also show that these women are at very low risk of recurrent cervical neoplasia.[166]
- Women who are HPV positive, or who have abnormal cytology, will be referred back to colposcopy, and then followed up according to national guidelines.[19]

Implementation of HPV testing for triage and 'test of cure' is predicted to result in approximately 350 000 fewer cytology samples per annum in the NHSCSP.[169]

5.2.3 HPV testing modalities

- There are a number of HR-HPV testing modalities available in the UK.
- The NHSCSP have performed a comparative analysis of the CE-marked* tests to assess their suitability for use within the screening programme and their performance in relation to the accepted Digene Hybrid Capture 2 test marketed by QIAGEN. Details of those considered appropriate for use in the NHSCSP for HPV triage are available on the intranet: www.cspnhs.org.uk.

5.3 Follow-up after treatment for CGIN

Because women who have been treated for CGIN are at higher risk of developing recurrent disease than those treated for high-grade CIN, 10 years of cytological follow-up are required. The first sample should be taken 6 months after treatment. If it is negative, then cytology should be repeated

*The CE (Conformité Européenne) label denotes that a product is compliant with European Union legislation and can be freely moved within the European market. It can be applied to in vitro diagnostic medical devices, such as HPV tests.

at 12 months, and then annually for the subsequent 9 years (minimum standard). Ideally, however, 6-monthly samples should be taken for the first 5 years, followed by annual samples for a further 5 years (best practice).[1]

5.4 Follow-up after treatment for invasive cervical cancer

The management of women who have been treated for cervical cancer is outside the responsibility of the NHSCSP. In most situations, follow-up will be determined by the patient's gynaecological oncologist. However, guidance for the follow-up of FIGO stage IA1 cervical cancer that has been treated conservatively can be found in NHSCSP Publication No. 20.[19]

6 AUDIT AND QUALITY ASSURANCE IN HISTOPATHOLOGY

6.1 Introduction

Histopathology plays a key role in the screening process. A high-quality histopathology service ensures the provision and maintenance of a high-quality screening programme.

Histopathology is essential for multidisciplinary audit of different components of the NHSCSP. Biopsies form the 'gold standard' for monitoring the efficiency and accuracy of the screening process, allowing correlation of histological findings with cytology and colposcopy. Consequently, working in multidisciplinary teams is important for audit and management of patients.

6.2 Quality assurance

6.2.1 Laboratories

All laboratories that provide histopathology and cytology services for the NHSCSP must:

- Be accredited by Clinical Pathology Accreditation (UK) Ltd, or another body accrediting to an equivalent standard (see EL(97)83, *Cervical Screening Programme: Achieving Quality Standards in Laboratories*).[170]
- Be fully compliant with the recommendations laid out in *Achievable standards, Benchmarks for reporting, and Criteria for evaluating cervical cytopathology* (NHSCSP Publication No 1) and *Quality Assurance Guidelines for the Cervical Screening Programme* (NHSCSP Publication No 3).[171,172]
- Participate in the UK National External Quality Assurance Scheme for Cellular Pathology Technique.
- Participate in the UK National External Quality Assurance Scheme for Immunocytochemistry (if this is a component of the laboratory repertoire).

6.2.2 Histopathologists

Histopathologists who report biopsy and resection specimens that emanate from the cervical screening process must:

- Participate in external quality assessment (EQA) schemes of a general or specialist nature (e.g. the National Gynaecological Pathology EQA scheme).
- Participate in the Royal College of Pathologists (RCPath) continuing professional development scheme (CPD).
- Undergo annual appraisal.
- Participate in audit, and contribute to the audit processes that are integral to the performance and monitoring of the NHSCSP.
- Work with professional colleagues in local, regional, and national networks, using the expertise of specialist gynaecological pathologists to assess problematic cases.
- Comply with, and monitor, key performance indicators proposed by the RCPath.[173]

6.3 Audit

Any variation in practice identified as a result of audit should be discussed in a formal professional forum. Remedial action must be taken and re-audit carried out to complete the audit cycle. Any changes that are implemented as a result of audit should be critically reviewed to ensure that a beneficial result has been achieved.

6.3.1 Histology/cytology correlation

- The cervical biopsy (punch or loop) should explain the cytological findings. Histology and cytology must be correlated in every case.
- The cervical cytology findings must always be regarded as the *lowest grade* of abnormality that may be expected in a biopsy. A comment on correlation must be included with every report (see section 1.2.7).

6.3.2 RCPath key performance indicators

Laboratories must be audited on their compliance with these indicators:

- By April 2012, 80% of diagnostic biopsies must be reported, confirmed, authorised, and electronically available to the requestor within 7 calendar days. This target increases to 90% by April 2014.
- By April 2012, 80% of histopathology and diagnostic cytology cases (excluding those histopathology specimens requiring decalcification) must be confirmed, electronically authorised, and available to the requestor within 10 calendar days. This target increases to 90% by April 2014.
- By April 2012, 90% of MDTMs must be attended by a consultant histopathologist, increasing to 95% by April 2014. The consultant histopathologist who attends should be a member of the team reporting the relevant cases; attendance may be defined by a team rota.
- By April 2012, 95% of cases should have undergone an audit of SNOMED or SNOMED-CT (SNOMED clinical terms) Topography, Morphology, and Procedure codes, rising to 100% by April 2014. This will facilitate multidisciplinary team review, electronic communication with cancer registries, and audit of histopathology clinical opinions.
- By April 2012, 90% of cases in which there has been an alteration in the histopathology report should be recorded. This change may be a consequence of MDTM consensus on a refined or altered diagnosis, or may result from another formal histopathological review. A supplementary report (or the addition of a computer code) should be used to document this quality assurance process and its outcome. Cases identified by the pathology service or cancer coordinators for discussion at MDTMs will form the denominator for this key performance indicator. The target will increase to 95% by April 2014.
- By April 2012, 80% of cancer resections must be reported using a template or proforma (including the RCPath cancer dataset). The target increases to 90% by April 2014.

6.3.3 Audit of invasive cervical cancer

The process of auditing cervical cancer is described in detail in the document *Audit of Invasive Cervical Cancers* (NHSCSP Publication No 28).[174]

- The histopathologist who identifies a cervical cancer must notify the HBPC in the Trust where the diagnosis is made.

- The lead histology consultant in the laboratory holding the histological material should instigate the local review process.
- The outcome of the review must be reported to the coordinating HBPC, using the standard forms. Certain cases may require referral to the quality assurance reference centre (QARC) for panel review via the Trust's HBPC.

6.3.4 Audit of colposcopy standards

The content of histopathology reports may be used to monitor colposcopic standards for excisional treatment of cervical lesions.[19]

- The specimen should be removed as a single sample in ≥80% of cases.
- For ectocervical squamous lesions, tissue to a depth of >7 mm should be removed.
- For glandular lesions, tissue to a depth of more than >10 mm above the squamocolumnar junction should be excised.

6.3.5 Audit of histopathology reports

It is considered good practice for a percentage of cases reported as CIN, CGIN, or carcinoma to be reviewed by departmental colleagues to ensure uniformity in the interpretation of diagnostic criteria. Cases should be selected at random. A specific percentage is not recommended, as the proportion will depend on departmental workload and existing review practices, and should take into account the number of cases that are already being reviewed by gynaecological cancer MDTMs.

6.4 Histology/cytology correlation

6.4.1 Histological findings of a grade higher than expected from the cytology result

These may be due to the following:

- Sampling error: persistent undersampling, if established by audit, may reveal substandard sample-taker performance, which can be remedied by re-education or retraining.
- Undergrading of cytological changes in cervical samples.
- A failure to recognise unusual or uncommon forms of dyskaryosis in cervical samples, e.g. high-grade dyskaryosis of 'small' or 'pale' cell type, misinterpretation of crowded groups, or subtle forms of glandular dyskaryosis.[175–177] Persistent failure to recognise uncommon or unusual patterns of dyskaryosis, if established by audit, requires the re-education or retraining of cytology staff.

6.4.2 Histological findings of a grade lower than expected from the cytology result

This may be due to:

- Poor-quality biopsy: loss of surface epithelium or electrothermal artefact may impair histological assessment. Deeper levels should be cut in these cases, but may be of limited value.

- Unrepresentative biopsy material: the colposcopist may not have selected the most appropriate site to biopsy. It is recognised that not all CIN lesions produce a colposcopic abnormality.[178]
- Overinterpretation of cytology: atrophic parabasal cells, histiocytes, degenerate metaplastic cells, endometrial cells, and follicular cervicitis are the most common pitfalls. Cytology review must be carried out, and an explanation of the discrepancy must be sought. Review of both the cytology and the histology by an external pathologist may be necessary. Confirmation of a significant cytological finding that is not explained by a technically satisfactory biopsy must be fed back at the MDTM.
- Removal, during sampling, of all of the abnormal cells (in the case of a small preinvasive lesion), resulting in a genuine negative biopsy.
- Natural disease regression, especially if a significant amount of time has elapsed between the cytology sampling and biopsy. In this situation, HPV testing may provide reassurance.

6.4.3 Histological discrepancies and suspected CGIN

- The limitations of punch biopsies in diagnosing CGIN are recognised.[179–181] A cytological prediction of glandular neoplasia, followed by a negative punch biopsy alone, should not be misinterpreted as a cytology overcall.
- The possibility that abnormal cells originate from elsewhere in the female genital tract must always be considered, and investigated if clinically appropriate.

6.5 MDTMs

6.5.1 Colposcopy MDTM (also referred to as clinicopathological conference)

Clinicopathological correlation is an integral part of the cervical screening programme, and works as a form of integrated quality assurance for cytology, colposcopy, and histopathology services. Attendance should be monitored. The colposcopy MDTM enables:

- Interaction between cytology and histopathology professionals and clinicians, in a manner that impacts significantly on diagnosis and patient management decisions.
- A forum for the education of colposcopists and pathologists, via discussion and decision making on difficult cases, e.g. where patients have significant comorbidity, or where patient choice limits treatment options. Problematic decisions must be documented to explain why management deviated from national guidelines.[182]
- Audit of the frequency with which non-guideline recommended decisions are taken, and collation of the follow-up of such decisions.

Refer to Colposcopy, section 4.9, for details about meeting organisation and case selection.

6.5.2 Gynaecological cancer network MDTMs[181–185]

- Cases of cervical cancer must be discussed at a unit or centre MDTM to optimise patient treatment decisions in the context of radiological and further clinical investigations.
- National guidelines[186] recommend that all women with FIGO stage IA cancers can be managed at units. Those with tumours at a more advanced stage, and all patients with adenocarcinomas, should be referred to cancer centres.

6.6 Histology reporting

Accurate and high-quality histopathology reporting is critical for optimal patient management. Additionally, high-quality histology reports are an important data source for cancer registries, and help to evaluate the effectiveness of screening programmes. It is therefore recommended that:

- Standardised histology reporting proformas (such as the RCPath cancer datasets, Appendix 1) or templates should be used for reporting excisional biopsies and resections with cervical cancer. This ensures consistent documentation of data for audit purposes and for electronic submission to cancer registries.
- All cervical carcinomas must be classified according to the WHO classification of cervical neoplasms (Appendix 2).
- All cervical carcinomas must be staged according to the FIGO system (Appendix 4). Node involvement must be separately specified, or TNM staging may be used for this purpose, depending on local preference.[39]
- All histology reports should be assigned SNOMED Topography and Morphology codes to permit data retrieval and audit.

6.6.1 Report content

- All histopathology reports must include a macroscopic description, which indicates the specimen type, dimensions, and any macroscopic abnormalities (as recommended in Appendix 5).
- In loop or punch biopsies, the microscopy section should specify whether there are any features that impair histological assessment or interpretation, e.g. fragmentation, crush/diathermy artefact, or epithelial loss. A clear distinction must be made between a specimen that fails to identify the source of the abnormal cells in the cytology sample because it is technically unsatisfactory or damaged, and a biopsy that is technically adequate but does not include or identify the lesion.
- The presence of the transformation zone must be confirmed.
- The report must indicate:
  - The presence (or absence) of a preinvasive lesion/s (CIN, CGIN, or SMILE).
  - The grade of CIN or CGIN.
  - The status of the resection margins. Depending on local practice, a measurement of the distance to the closest resection margin (in millimetres) may be provided.
  - HPV-associated changes, including koilocytosis.
  - Correlation of findings with the antecedent/referral cytology test. All pathological lesions and non-neoplastic histological features that may be associated with cytological changes should therefore be included in the histological report.
- RCPath cervical cancer datasets (Appendix 1) are recommended for the reporting of cervical cancers. The cancer type, differentiation, tumour dimensions, presence of lymphovascular and perineural invasion, completeness of excision, relationship to excision planes, and FIGO stage must be reported. Accompanying lymph nodes should be handled according to the guidelines in Appendix 5, and the findings should be included in the final histopathology report.

7 CANCER REGISTRIES: THEIR ROLE IN CANCER REGISTRATION AND DATA COLLECTION, AND THEIR RELATIONSHIPS WITH OTHER NATIONAL ORGANISATIONS

7.1 Cancer registration

Cancer registration involves the systematic collection of information on the incidence and characteristics of malignant neoplasms and specific in situ and non-malignant tumours in a resident population. The process is established worldwide and follows guidelines developed by bodies such as the International Agency for Research on Cancer (IARC) of the WHO, the Union for International Cancer Control (UICC), and the International Association of Cancer Registries (IACR).[187–190]

Cancer registration in England can be traced back to 1929, although complete national coverage was achieved only in 1962.[191] Cancer registration is not a statutory function in the UK, but since January 1993 it has been mandatory for NHS organisations (including Trusts) to provide core data, listed in the cancer registration minimum dataset to the English regional cancer registries (Table 1).

7.2 Cancer registries

- There are eight regional cancer registries in England, and together they provide a complete national cancer registration service. Each registry is responsible for the collection of population-based cancer information for a specific area (see Appendix 6).
- Changes in health administration in 2002 (the abolition of regional offices, and introduction of government offices) resulted in cross-boundary issues for some registries. Where these exist, registries collaborate to collect data and provide analytical services for an area.
- Registries submit data on all newly diagnosed cancers to the National Cancer Registration Team at the Office for National Statistics for the compilation of national cancer statistics.[187–192]
- The collation of cancer registration data in Scotland, Wales, and Northern Ireland is the responsibility of a single national registry in each country, although the Welsh registry also submits data to the Office for National Statistics (see Appendix 6).
- A dedicated National Registry of Childhood Tumours, covering England, Wales, Scotland, and Northern Ireland (since 1993) is provided by the Childhood Cancer Research Group based at the University of Oxford.
- All UK registries submit data annually for the compilation of a national performance monitoring report.[193]
- The November 2010 Department of Health White Paper, *Healthy Lives, Healthy People: Our Strategy for Public Health in England*, proposed that regional cancer registries should become part of an integrated new public health service, Public Health England.[194] The following policy statement, *Healthy Lives, Healthy People: Update and Way Forward*, published in July 2011, and the first *Transforming Public Health Bulletin*, also published in July 2011, confirm that the functions of cancer registries, together with those of other organisations (including the National Cancer Intelligence Network (NCIN), the National Screening Committee, the National Cancer Screening Programmes, and the QARCs) will transfer into Public Health England from April 2013.[195,196]

Table 1 Current core cancer registration dataset for submission to the Office for National Statistics (Source: Office for National Statistics)[187]

Core data items
Record type (new/amendment/deletion)
Identity number (unique)
Patient's name
Patient's previous surname
Patient's address
Postcode
Employment
Sex
NHS number
Marital status
Date of birth
Date of death (if applicable)
Incidence date
Site of primary growth
Type of growth
Behaviour of growth
Multiple tumour indicator
Previous registration details
Basis of diagnosis[a]
Death certificate only indicator[a]
Side (laterality)[a]
Treatment(s) (indicators)[a]
Stage[b]
Grade[b]

a From incidence year 1993 (incidence year).
b From incidence year 1993; phased introduction – initially only for breast and cervix.

7.3 Role of cancer registries

- The main strength of the cancer registration system is that it establishes a means of measuring the level of cancer in a defined, resident population. By collecting information on the number of new cases and calculating incidence rates, which may then be compared between populations, cancer registration information has helped to advance understanding of the aetiology of the disease; for example, assisting researchers in their investigation of links between environmental factors and cancer incidence.[197] Cancer registries are also unique in being able to provide population-based trend data that is detailed enough to allow changes in cancer incidence and survival to be monitored over long periods of time.
- As cancer has become an increasing priority for the NHS, so the demand for cancer registration information has increased. Registries have therefore evolved from their historical role of data collection to provide cancer intelligence services to stakeholders.
- Registries work closely with their local cancer networks, delivering agreed programmes of analytical work to inform the networks' service commissioning and outcome monitoring functions.

- Cancer registries also collaborate with the NCIN, which was launched in June 2008 to fulfil the commitments of the Cancer Reform Strategy.
- *Improving Outcomes: A Strategy for Cancer* affirms the importance of cancer registration information for the planning and commissioning of services, but calls on registries to provide cancer data more promptly and with more comprehensive staging information.[167]

7.4 UKACR

- The United Kingdom Association of Cancer Registries (UKACR) was established in 1992 to provide a hub for cancer registration in the UK. It ensures that registries are regularly informed of national issues and of relevant legislation pertaining to cancer registration and data collection.[193]
- Membership includes cancer charities, as well as all registries throughout the UK and Ireland.
- The Executive Committee and subgroups of the UKACR work to progress cancer registration and the role of registries.
- Registries are part of the international cancer registration community, through membership of the IACR and European Network of Cancer Registries (ENCR).[190,198]

7.5 The process of data collection

- Access to multiple sources of data is essential to ensure the completeness and accuracy of cancer registration information.[197]
- Current sources of data include NHS Trusts, cancer centres, treatment centres, hospices, private hospitals, cancer screening QARCs, other cancer registers, general practices, nursing homes, death certificates, Hospital Episode Statistics (HES), and Cancer Waiting Time (CWT) information.
- In many instances, more than one source of information is available to cancer registries from a single organisation. For example, a single hospital can provide information from its hospital patient administration systems, pathology laboratories, medical records departments, and radiotherapy databases.
- Figure 41 shows the current national cancer registration system, including incoming data sources, flows of information between registries, and provision of data to the Office for National Statistics.[187]
- Registries work to incorporate new routine data sources with those already being received (e.g. patient administration systems, pathology) and now receive an increasing amount of information from MDTMs and the national Radiotherapy Data Set (RTDS).[199] Data from the new, national Systemic Anti-Cancer Therapy (SACT) dataset (submission of which is mandated from April 2012) will also to be received in due course.

7.6 Information collected by registries

- Cancer registries collect information on a set of mandatory registrable conditions, which include all malignant and in situ neoplasms, all neoplasms of uncertain behaviour, some non-malignant conditions, and some neoplasms of unspecified nature.
- The Information Standards Board (ISB) approved an extended Cancer Registration dataset in 2005, as part of the National Cancer Dataset (NCDS).[200] The standard NHS contract for acute hospitals[201] requests that providers supply this information to registries on a regular basis by March 2011. The NCDS is currently under review, with input from the 12 NCIN Site Specific Clinical Reference Groups (SSCRGs). This will result in a new Cancer Outcomes and Services Dataset (COSD), which will be mandatory from January 2013.

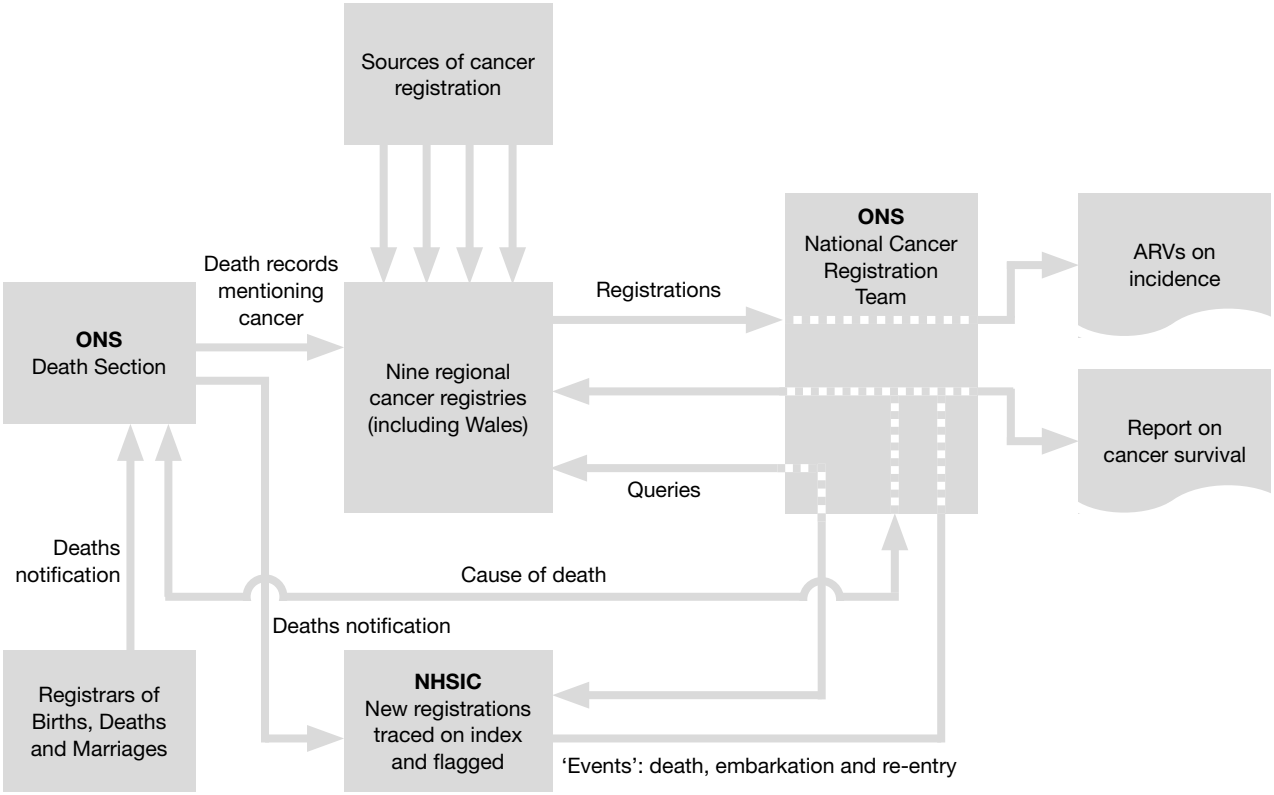

Figure 41 The National Cancer Registration system (Source: Office for National Statistics).[187] ARV: Annual Reference Volume (published annually, series MB1); NHSIC: NHS Information Centre for Health and Social Care; ONS: Office for National Statistics.

- Registries work with their local cancer networks and Trusts to ensure that the full dataset is submitted, and to improve the quality of data. There is a national emphasis on the provision of tumour stage data by Trusts.[201]

Although registries currently supply a subset of data items to the Office for National Statistics, they provide a more comprehensive dataset to the National Cancer Data Repository (NCDR).[202]

7.7 Legal background to cancer registration and confidentiality

- Cancer registries have legal support to allow them to collect and release patient-level data relating to cancer under Section 251 of the NHS Act 2006 (and formerly under Section 60 of the Health and Social Care Act 2001).[203,204]
- Section 251 allows the Secretary of State for Health to set aside the common law duty of confidentiality for medical purposes, where it is not possible to use anonymised information and where seeking individual consent is not practicable. The provisions of Section 60 (Health Service (Control of Patient Information) Regulations 2002 (SI 1438)) continue to have effect under Section 251.[205]
- The Ethics and Confidentiality Committee currently administers powers granted under Section 251, this responsibility having been delegated to the ECC from the National Information Governance Board for Health and Social Care (NIGB). The support given to cancer registries under Section 251 is subject to annual review.[206]

- Cancer registries have rigorous procedures to protect patient confidentiality and to meet the strict requirements of the Data Protection Act 1998 regarding the receipt, secure storage, and transfer of personal information.[207] This includes the following provisions:
  - All releases of data that are patient specific or that may potentially identify patients (such as those for small geographic areas or rare tumour sites) to legitimate third parties are subject to national confidentiality guidelines approved by the UKACR.[193]
  - Data must be provided only to research projects that have been granted full local ethics approval, as well as Ethics and Confidentiality Committee approval.
  - Registries must submit details of all identifiable data releases to the Ethics and Confidentiality Committee (ECC) as part of the annual review of their Section 251 support.
  - All data published in registry reports or on their websites is aggregated.

Although cancer registries do not contact patients directly, an NHS leaflet about the cancer registration system is available to patients at the time of diagnosis, including information about their right to opt out. *About Cancer Registration* was prepared by the UKACR with input from patient groups, and is distributed through local cancer networks. The leaflet, with accompanying 'frequently asked questions', is also available from the UKACR website.[193]

7.8 Uses of cancer registration information

The purposes to which cancer registration data are put generally fall into three categories: service planning, epidemiological research, and primary prevention and clinical outcomes monitoring. Specifically, data from cancer registries are used to:

- Monitor trends in cancer incidence, prevalence, and survival through time, across different areas, and between various social groups.
- Evaluate the effectiveness of cancer prevention and screening programmes (population-based data are used to monitor the effectiveness of the existing NHS Cancer Screening Programmes for breast, cervical, and colorectal cancer, and to inform the design of new programmes).[208]
- Inform service planning by helping to evaluate the quality and outcomes of cancer care, through the provision of comparative data about treatment patterns and outcomes.
- Support the work of cancer genetic counselling services for individuals and families who have a higher risk of developing cancer.
- Evaluate the effect of environmental and social factors on cancer risk, and support investigations into the causes of cancer.
- Support cancer clinical audit programmes at local and national level, including the National Clinical Audit Support Programme's (NCASP) cancer audits.[209]
- Contribute to programmes aimed at reducing inequalities in health outcomes by investigating differences in cancer incidence, survival, and access to treatment between social groups.
- Support recalls of specific groups of cancer patients, for example women who were treated for Hodgkin's disease with radiotherapy who may therefore have an increased risk of developing breast cancer.

Aggregated cancer registration data are readily available from a variety of sources (Appendix 6). Patient-specific and potentially identifiable information releases are subject to national guidelines on confidentiality, and requests should be directed to individual registries (Appendix 6).

7.9 The NCIN

- The NCIN [under the auspices of the National Cancer Research Institute (NCRI)] was established in 2008 after the publication of the Cancer Reform Strategy.[210] It works closely with cancer services in England, Scotland, Wales, and Northern Ireland to improve the quality and availability of cancer data for analysis, publication, and research.
- The NCIN is funded by the Department of Health, NHS National Cancer Action Team, and NCRI partners, including the Medical Research Council and cancer charities.
- The NCIN is a network of UK-wide partner organisations (the cancer registries, the NHS and health departments, cancer charities, research funders, statistical and analytical organisations, and others interested in using information to improve outcomes for cancer patients) and is coordinated by a small central team.[211]
- Specialist clinical input into the NCIN is provided by twelve SSCRGs. These groups advise on putting the available data to best use and propose future changes to the collection and analysis of cancer data to improve clinical outcomes. An example of the work of SSCRGs is the current review of the Cancer Outcomes and Services Dataset (previously the National Cancer Dataset).[200]
- The role of the NCIN in improving data quality, making data more accessible, and reducing duplication is acknowledged in *Improving Outcomes: A Strategy for Cancer*.[167]
- In April 2013, the NCIN will become part of Public Health England.

7.10 Cancer registries and gynaecological cancer

The regional cancer registries each have at least one site-specific lead, whose role is to support the NCIN SSCRGs through the delivery of agreed programmes of analytical work. Trent Cancer Registry is the lead registry for gynaecological cancers, supporting the National Gynaecological SSCRG.[212] The analytical support provided includes the production of an annual data briefing on an agreed topic and an annual data quality and completeness report.

Trent also provides analytical support to the NHSCSP through a funded programme of work.

7.11 Relationship between registries and QARCs

Supporting quality assurance of the NHSCSP is an important part of the cancer registries' role. The relationships between registries and regional QARCs are formalised in Service Level Agreements.

This relationship should be strengthened when the functions of these organisations are brought together under the umbrella of Public Health England, from April 2013.[195–196]

7.12 Developments in the role of cancer registries

The two main challenges currently facing registries are to reduce the time between collection and publication of data, and to improve the completeness of the available information on tumour stage.

- The quality of cancer data available to commissioners is high. However, processing and validating the information causes a delay which makes the published data less useful (see the 2010 National Audit Office report, *Delivering the Cancer Reform Strategy*).[213]

- As part of their contracts, cancer registries must submit registrations for all newly diagnosed cases to the Office for National Statistics for compilation of national-level data. It has been acknowledged that differences in working methods contribute to variations in timeliness between registries. The eight English registries are therefore moving towards more consistent methods of working, using a single, nationally agreed database system, and implementing a phased reduction in the turnaround time for processing.[193] This will be further strengthened by the move to Public Health England.
- Historically, details about tumour stage have been inconsistently supplied to registries. With some types of tumour, deriving an accurate stage from information supplied in a pathology report has proven to be time-consuming and challenging for registry staff. This has led to a situation where registries have recorded better staging data for some tumour sites than others. There is now a commitment to staging all tumours to consistent standards.
- The *Operating Framework for the NHS in England 2011/12* emphasises the importance of obtaining good-quality staging data to assess the impact of earlier diagnosis on survival rates.[214] The document also reiterates that providers are expected to submit information about tumour stage as part of their cancer registration dataset. The report of the Public Accounts Committee, *Delivering the Cancer Reform Strategy*, published in March 2011, recommends that staging data should be provided in a complete and timely manner in at least 70% of cases in each region by the end of 2012.[215]

APPENDIX 1: REPORTING PROFORMAS

RCPath dataset for histological reporting of cervical neoplasia (3rd edition)

Reporting proforma for cervical cancer in excisional cervical biopsies

Surname: ..... Forenames: ..... Date of birth: .....

Patient identifier (CHI/NHS no): ..... Hospital: ..... Hospital no: .....

Date of receipt: ..... Date of reporting: ..... Report no: .....

Pathologist: ..... Surgeon: .....

Description of specimen and core macroscopic items

Wedge ☐ Cone ☐ Loop ☐ Biopsy of cervix: …….. mm × …….. mm and ……. mm thick/deep

Number of fragments received, measurement of each and block designation:

.....

.....

Core microscopic items

Invasive malignancy:

Type: Squamous carcinoma ☐ Adenosquamous carcinoma ☐ Adenocarcinoma ☐

Neuroendocrine carcinoma ☐ Other ☐ (specify…….....)

Differentiation/grade:

Well/Grade 1 ☐ Moderate/Grade 2 ☐ Poor/Grade 3 ☐ Not assessable/GX ☐ N/A ☐

Distribution of invasive component: Unifocal ☐ Multifocal ☐

Tumour size: Maximum horizontal dimension ……..... mm

Maximum thickness/depth of invasion (delete as appropriate) …….... mm

Are invasive foci present in three or more sequential slices of tissue*: Yes ☐ No ☐

Excision status: Incomplete ☐ Complete ☐ Not assessable ☐

If complete excision, distance to closest resection margin: ..... mm

Specify margin: ectocervical/endocervical/deep radial

Other features

CIN (cervical intraepithelial neoplasia):	Present ☐	Absent ☐	
Grade:	CIN1 ☐	CIN2 ☐	CIN3 ☐
CGIN (cervical glandular intraepithelial neoplasia):	Present ☐	Absent ☐	
Grade:	Low ☐	High ☐	
SMILE (stratified mucin-producing intraepithelial lesion):	Present ☐	Absent ☐	

Excision margins: (specify whether involved by CIN, CGIN or SMILE)

Ectocervical resection margin:	Clear ☐	Involved by CIN ☐	CGIN ☐	SMILE ☐	Not assessable ☐
Endocervical resection margin:	Clear ☐	Involved by CIN ☐	CGIN ☐	SMILE ☐	Not assessable ☐
Deep lateral/radial resection margin:	Clear ☐	Involved by CIN ☐	CGIN ☐	SMILE ☐	Not assessable ☐

Lymphovascular space invasion: Present ☐ Absent ☐

***Note:** If invasive foci are seen in three or more sequential sections of tissue, the third dimension of the lesion (which is not routinely measured) may exceed 7 mm (i.e. more than stage IA)

Provisional pathological FIGO stage **SNOMED codes: T …… M ……**

Signature of pathologist: ..... Date: ……..

RCPath dataset for histological reporting of cervical neoplasia (3rd edition)

Reporting proforma for cervical cancer in hysterectomy specimens

Surname: ..... Forenames: ..... Date of birth: .....

Patient identifier (CHI/NHS no):..... Hospital:..... Hospital no: .....

Date of receipt:..... Date of reporting: ..... Report no: .....

Pathologist: ..... Surgeon: .....

Description of specimen and core macroscopic items

Vaginal cuff: present ☐ absent ☐ length …..… mm diameter ……. mm

Dimensions of uterus: length ……. mm transverse …… mm anteroposterior ……. mm

Adnexa: Present ☐ Absent ☐

Normal ☐ Abnormal (specify) …….

No tumour seen ☐ Maximum dimensions of tumour: ……. mm × ……. mm

Position of cervical tumour: Anterior ☐ Posterior ☐ Right ☐ Left ☐ Circumferential ☐

Ectocervix ☐ Endocervix ☐

Macroscopic involvement of vagina: Yes ☐ No ☐

Macroscopic involvement of parametria: Yes ☐ No ☐

Macroscopic involvement of paracervical tissues: Yes ☐ No ☐

Core microscopic items

Type: Squamous carcinoma ☐ Adenosquamous carcinoma ☐ Adenocarcinoma ☐

Neuroendocrine carcinoma ☐ Other ☐ (specify…….…..)

Differentiation/grade: Well/Grade 1 ☐ Moderate/Grade 2 ☐ Poor/Grade 3 ☐

Not assessable/GX ☐ Not applicable ☐

Tumour size: Maximum horizontal dimension ……..... mm

Thickness/depth of invasion (delete as appropriate) ……. mm

Minimum thickness of uninvolved cervical stroma (minimum tumour-free rim): ……... mm

Position of this: …….....

Closest radial resection margin (include paracervical tissue thickness): …….. mm

Position of this: …….....

Vaginal involvement: Yes ☐ No ☐ Distance from distal vaginal epithelial margin: ……. mm

Position of this: …….....

Paracervical involvement: Yes ☐ No ☐ If involved: Left ☐ Right ☐

Parametrial involvement: Yes ☐ No ☐ If involved: Left ☐ Right ☐

Lymphovascular invasion: Yes ☐ No ☐

CIN: Present ☐ Absent ☐ Grade 1/2/3

CGIN: Present ☐ Absent ☐ Grade: low/high

SMILE: Present ☐ Absent ☐

Pelvic nodes: (pelvic group includes obturator, internal, external and common iliac nodes)

	Right	Left
Total number		
Number involved		

Extranodal spread: Yes ☐ No ☐

Para-aortic nodes: Positive ☐ Negative ☐ Not sampled ☐

Total number of nodes ☐ Number of positive nodes ☐

Extranodal spread: Yes ☐ No ☐

Other tissues and organs	Normal	Abnormal (describe)
Endometrium	☐	☐
Myometrium	☐	☐
Right adnexum	☐	☐
Left adnexum	☐	☐

Provisional pathological FIGO stage* .....……

*Correlate with previous cone/loop specimen/s – final staging may follow MDT review)

SNOMED codes: **T …….. M ……..**

T …….. M ……..

Signature of pathologist: …….....…… Date: ……..

APPENDIX 2: WORLD HEALTH ORGANIZATION HISTOLOGICAL CLASSIFICATION OF TUMOURS OF THE UTERINE CERVIX AND ACCOMPANYING SNOMED CODES

Tumour class	Code
Epithelial tumours	
Squamous tumours and precursors	
Squamous cell carcinoma, not otherwise specified	8070/3
Keratinising	8071/3
Non-keratinising	8072/3
Basaloid	8083/3
Verrucous	8051/3
Warty	8051/3
Papillary	8052/3
Lymphoepithelioma-like	8082/3
Squamotransitional	8120/3
Early invasive (microinvasive) squamous cell carcinoma	8076/3
Squamous intraepithelial neoplasia	
Cervical intraepithelial neoplasia (CIN3)	8077/2[a]
Squamous cell carcinoma in situ	8070/2
Glandular tumours and precursors	
Adenocarcinoma	8140/3
Mucinous adenocarcinoma	8480/3
Endocervical	8482/3
Intestinal	8144/3
Signet ring cell	8490/3
Minimal deviation	8480/3
Villoglandular	8262/3
Endometrioid adenocarcinoma	8380/3
Clear cell adenocarcinoma	8310/3
Serous adenocarcinoma	8441/3
Mesonephric adenocarcinoma	9110/3
Early invasive adenocarcinoma	8140/3
Adenocarcinoma in situ	8140/2
Glandular dysplasia	
Other epithelial tumours	8015/3
Adenosquamous carcinoma	8560/3
Glassy cell carcinoma variant	8015/3
Adenoid cystic carcinoma	8200/3
Adenoid basal carcinoma	8098/3
Neuroendocrine tumours	
Carcinoid	8240/3
Atypical carcinoid	8249/3

Tumour class	Code
Small cell carcinoma	8041/3
Large cell neuroendocrine carcinoma	8013/3
Undifferentiated carcinoma	8020/3
Mesenchymal tumours and tumour-like conditions	
Leiomyosarcoma	8890/3
Endometrioid stromal sarcoma, low grade	8931/3
Undifferentiated endocervical sarcoma	8805/3
Sarcoma botryoides	8910/3
Alveolar soft-part sarcoma	9581/3
Angiosarcoma	9120/3
Malignant peripheral nerve sheath tumour	9540/3
Leiomyoma	8890/0
Genital rhabdomyoma	8905/0
Mixed epithelial and mesenchymal tumours	
Carcinosarcoma (malignant müllerian mixed tumour)	8980/3
Adenosarcoma	8933/3
Wilms' tumour	8960/3
Adenofibroma	9013/0
Adenomyoma	8932/0
Melanocytic tumours	
Malignant melanoma	8720/3
Blue naevus	8780/0
Miscellaneous tumours	
Tumours of germ cell type	
Yolk sac tumour	9071/3
Dermoid cyst	9084/0
Mature cystic teratoma	9080/0
Lymphoid and haematopoetic	
Malignant lymphoma (specify type)	9590/3
Leukaemia (specify type)	9800/3
Secondary tumours	

a In the UK, the preferred SNOMED code for CIN3 is 74008.

Data from the IARC Screening Group webpages: http://screening.iarc.fr/atlasclassifwho.php (accessed 18 January 2012).

APPENDIX 3: HPV TRIAGE AND TEST OF CURE PROTOCOL

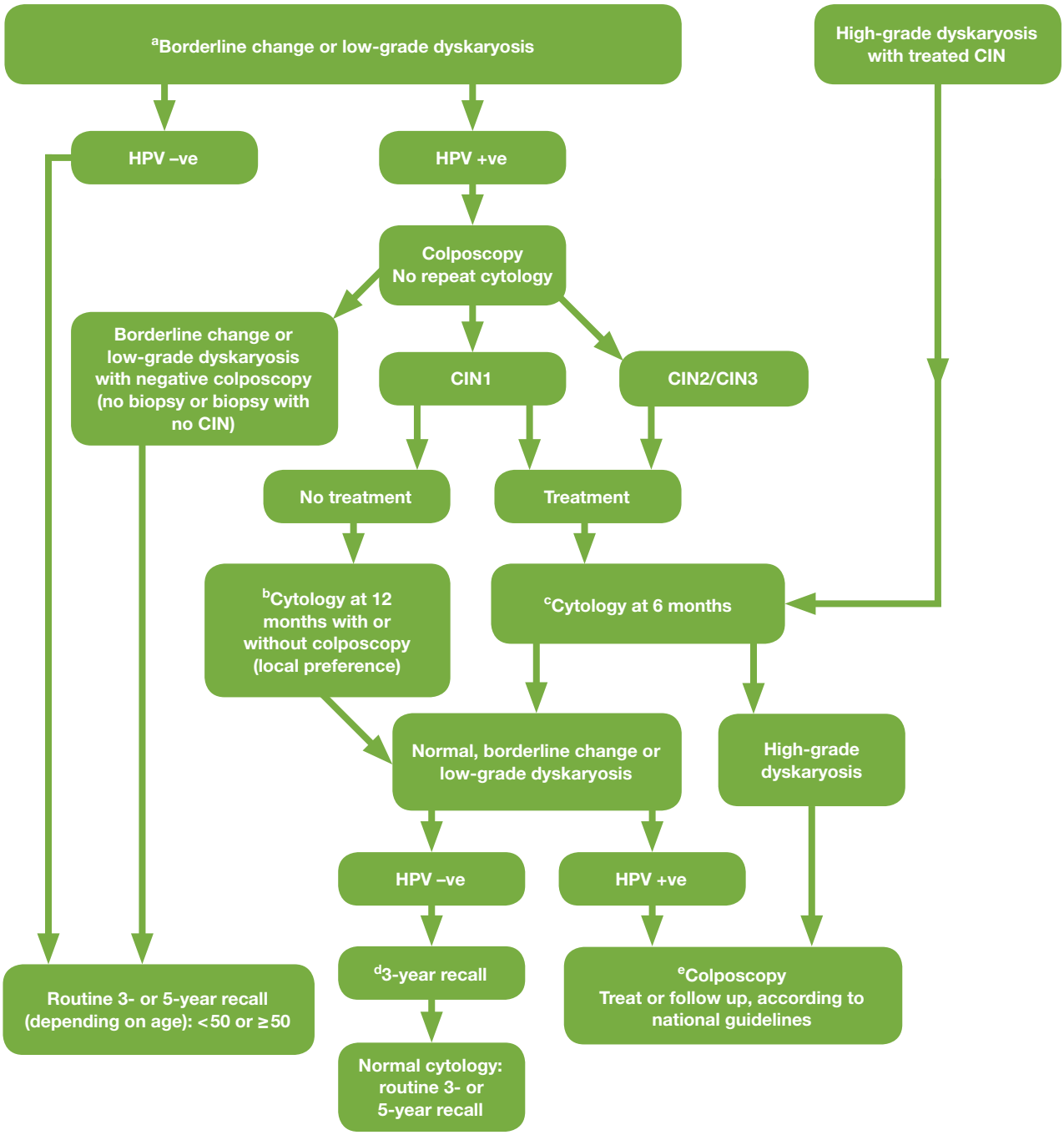

NOTES: This flow chart has been updated for the sake of clarity and to incoporate the revised British Society for Clinical Cytology (BSCC) terminology for abnormal cervical cytology.

(a) If sample is unreliable/inadequate for the HPV test, refer cases showing borderline change and low-grade dyskaryosis for 6-month repeat cytology. Where repeat cytology reports as negative/borderline/low-grade, retest for HPV. If the HPV test is negative, return to routine recall. If the HPV test is positive, refer the woman for colposcopy. All cases of high-grade dyskaryosis should be referred to colposcopy. (b) Follow-up of 12-month cytology should follow normal NHSCSP protocols. (c) Women in annual follow-up after treatment for CIN are eligible for the HPV test of cure at their next screening test. (d) Women ≥50 who have normal cytology at 3 years will then return to 5-yearly routine recall. Women who reach 65 must still complete the protocol and must comply with other national guidance. (e) Women referred due to borderline, low-grade, or normal cytology, who are HR-HPV positive, and who then have a satisfactory and negative colposcopy, can be recalled in 3 years.

APPENDIX 4: TNM AND FIGO STAGING OF CERVICAL TUMOURS

TNM categories	FIGO stages	Description
TX		Primary tumour cannot be assessed
T0	[a]	No evidence of primary tumour
T1	I	Tumour confined to cervix (extension to corpus should be disregarded)
T1a[b]	IA	Invasive carcinoma diagnosed only by microscopy. Stromal invasion with a maximal depth of 5.0 mm measured from the base of the epithelium and a horizontal spread of 7.0 mm or less[c]
T1a1	IA1	Measured stromal invasion 3.0 mm or less in depth and 7.0 mm or less in horizontal spread
T1a2	IA2	Measured stromal invasion more than 3.0 mm and not more than 5.00 mm with a horizontal spread of 7.0 mm or less[d]
T1b	IB	Clinically visible lesion confined to the cervix or microscopic lesion greater than T1a/IA2
T1b1	IB1	Clinically visible lesion 4.0 cm or less in greatest dimension
T1b2	IB2	Clinically visible lesion more than 4.0 cm in greatest dimension
T2	II	Tumour invades beyond uterus but not to pelvic wall or to lower third of vagina
T2a	IIA	Tumour without parametrial invasion
T2a1	IIA1	Clinically visible lesion 4.0 cm or less in greatest dimension
T2a2	IIA2	Clinically visible lesion more than 4.0 cm in greatest dimension
T2b	IIB	Tumour with parametrial invasion
T3	III	Tumour extends to pelvic wall, involves lower third of vagina, causes hydronephrosis or non-functioning kidney[e]
T3a	IIIA	Tumour involves lower third of vagina
T3b	IIIB	Tumour extends to pelvic wall, causes hydronephrosis or non-functioning kidney
T4	IVA	Tumour invades mucosa of the bladder or rectum, or extends beyond true pelvis[f,g]
M1	IVB	The cancer has spread to distant organs
N1		Regional

a FIGO no longer includes stage 0 (Tis).
b All macroscopically visible lesions even with superficial invasion are T1b/1B.
c Vascular space involvement, venous or lymphatic, does not affect classification.
d Invasion is limited to a measured stromal invasion with a maximal depth of 5.0 mm and a horizontal extension of not greater than 7.0 mm. Depth of invasion should not be greater than 5.00 mm taken from the base of the epithelium of the original tissue – superficial or glandular. The depth of invasion should always be reported in millimetres, even in those cases with 'early (minimal) stromal invasion' (~1 mm).
e On rectal examination, there is no cancer-free space between the tumour and the pelvic wall. All cases with hydronephrosis or non-functioning kidney are included, unless they are known to be due to another cause.

f Bullous oedema is not sufficient to classify a tumour as T4.
g Invasion of bladder or rectal mucosa should be biopsy-proven according to FIGO.

Rules for TNM Classification
The classification applies only to carcinomas. There should be histological confirmation of the disease. The following are the procedures for assessing T, N, and M categories:

T categories: clinical examination and imaging.*
N categories: clinical examination and imaging.
M categories: clinical examination and imaging.

*The use of diagnostic imaging techniques to assess the size of the primary tumour is encouraged but is not mandatory. Other investigations, e.g. examination under anaesthesia, cytoscopy, sigmoidoscopy, and intravenous pyelography, are optional and no longer mandatory.

Rules for FIGO classification
The FIGO stages are based on clinical staging. Some stage I subdivisions require histological examination of the cervix. (TNM stages are based on clinical and/or pathological classification.)

Anatomical subsites
1. Endocervix (C53.0)
2. Exocervix (C53.1)

Regional lymph nodes
The regional lymph nodes are the paracervical, parametrial, hypogastric (internal iliac, obturator), common and external iliac, presacral, and lateral sacral nodes. Para-aortic nodes are not regional.

N – Regional lymph nodes
NX: Regional lymph nodes cannot be assessed.
N0: No regional lymph node metastasis.
N1: Regional lymph node metastasis.

M – Distant metastasis
M0: No distant metastasis
M1: Distant metastasis (includes inguinal lymph nodes and intraperitoneal disease except metastasis to pelvic serosa). It excludes metastasis to vagina, pelvic serosa, and adnexa.

pTNM Pathological classification
The pT and pN categories correspond to the T and N categories.
pN0: Histological examination of a pelvic lymphadenectomy specimen will ordinarily include six or more lymph nodes. If the lymph nodes are negative, but the number ordinarily examined is not met, classify as pN0.

APPENDIX 5: HANDLING OF SPECIMENS SENT FOR HISTOLOGICAL EXAMINATION[11]

Cervical punch/wedge biopsies

These are taken to confirm/exclude the presence of CIN, CGIN, and SMILE. The biopsies are usually received fixed in formalin and are 4–7 mm in their greatest dimension and 2–4 mm thick. The surgeon/colposcopist may mount the specimen on paper to provide optimal orientation.[216]

The following information should be recorded:

- The number of fragments.
- The colour and consistency of the biopsies.
- The size of each fragment in three dimensions, measured in millimetres: for mucoid samples with unmeasurably small tissue fragments, an aggregate measurement may be given in three dimensions, or the size given as volume in millilitres.

When taking blocks:

- Process all the tissue as received.
- Specimens that are greater than 5 mm may be bisected along their long axis, perpendicular to the mucosal surface. (If this is done, it should be recorded).
- For wedge biopsies, identify the squamocolumnar junction where possible, and slice perpendicularly to this. (If this is done, it should be recorded).

When processing/staining:

- Use standard H&E.
- Remember that small biopsies may not detect CIN3.[217]
- Consider cutting levels to visualise the epithelium; levels are also needed in cases where the histology does not match the colposcopic appearance or cytology.[9]
- Excision margins cannot be assessed in small diagnostic biopsies.

Cone biopsy and LLETZ

Cone/LLETZ (loop) biopsies are carried out on women with abnormal cytology samples, or following a positive punch biopsy. The biopsy can be diagnostic or therapeutic. Large loop diathermy is most commonly used, and is favoured as a procedure because of reduced levels of bleeding, improved healing, and relative preservation of cervical epithelium at the expense of artefact at the resection margins. Additionally, loop diathermy can be performed as an outpatient procedure, without a general anaesthetic.

Electrothermal artefact may nonetheless impair histological diagnosis and render the assessment of resection margins difficult,[218] especially in cases of glandular neoplasia. To avoid this, 'cold knife' cone biopsy is a preferred procedure for assessing glandular lesions of the cervix, especially after a diagnostic biopsy.

Intact cone or loop biopsies are roughly conical in shape. The specimen may arrive free in the specimen pot, or it may be orientated and/or pinned to a cork board. It may be opened at one end

(giving a U-shape) or opened and drawn out into a flattened, curved specimen. Alternatively, it may be received as multiple loop fragments, e.g. superficial, deeper/'top-hat', or marginal fragments.

On receipt, the following should be recorded:

- Measurements of the intact central loop/cone biopsy in three dimensions (anteroposterior, side-to-side, and thickness).
- Measurements of flat/opened loop biopsy in three dimensions (noting which dimension is being measured).
- For multiple loop biopsies, the number of pieces, with the smallest and largest measured in the maximum dimension where the sample is small, or in three dimensions where it is larger.
- The colour, consistency, and presence of any surface lesions.

When blocking a specimen, the following general advice should be followed:

- For intact central loop/cone biopsies, all slices must be blocked sequentially (if radially sliced, block 1 is 1 o'clock, and so on).
- Consider the use of ink where the identification of margins is difficult. For example, inking the ectocervical rim can be useful when orientating individual slices in the presence of a large ectropion. However, this is not always necessary.
- Note that opening or probing an intact loop/cone biopsy may damage the surface epithelium.[219]
- When sectioning intact central loop/cone biopsies, two possible methods should be considered:
  - Slicing serially in the sagittal and parasagittal plane at 2–3 mm intervals,[11,220] from one edge to the other (beginning at the 3 or 9 o'clock edge), perpendicular to the transverse axis of the external os. This allows assessment of tumour volume in small lesions and avoids the problems of interpretation that may arise when a loop/cone specimen is sectioned radially, resulting in blocks of variable thickness.
  - Sampling radially, in wedge-shaped slices. This allows mapping of a lesion if desired[221] (although mapping is not usually necessary).
- Opened loop biopsies should be processed in sequential transverse slices (and blocks).
- Fragments (e.g. superficial, deep/'top-hat', or marginal) should be processed in designated sequential cassettes.

Procedure for blocking a loop:

- In all cases, the whole loop must be submitted.
- Begin by placing the surface to be cut face down in the cassette. (Instead of placing samples with the cut face down, some centres embed the outer (curved) surface of the first and last (edge) slices of the loop, with the outer edge face down for sectioning.)
- Ensure that each subsequent slice is placed in a sequential cassette, with the cut faces orientated similarly, to allow assessment and measurement of invasive lesions. The opposite face can be marked with ink to assist the microtomist.
- Each piece of tissue should be placed in a single cassette.[219] *Placing multiple pieces in one cassette makes it impossible to measure the horizontal size of any small invasive lesion, thereby compromising accurate staging. This practice should be avoided.*
- Block each marginal/edge slice on its cut surface.

Processing/staining

- Use standard H&E. A single full-face section is required from each block.[219]
- Examine further levels if invasive disease is suspected on the basis of the cytological, colposcopic, or histological features.[9]

- If the surface epithelium or squamocolumnar junction is missing, or there is a discrepancy between the histological and cytological findings, a single further level is usually adequate.[12]
- Histochemistry and immunohistochemistry may be required to determine tumour subtype.

Radical trachelectomy[222,223]

This procedure is usually performed for early-stage cervical cancers, where preservation of fertility is desired. The following structures are usually included with trachelectomy specimens:

- Cervix.
- Parametrium.
- Vaginal cuff.
- Pelvic lymphadenectomy (this may be removed in a separate surgical procedure).

Record:

- The structures included, and whether the specimen can be orientated. In most cases the surgeon will place a suture at the 12 o'clock position to assist orientation; this should be encouraged. The peritoneum is present posteriorly, often taking a triangular shape with the apex pointing downwards. There is usually no peritoneum over the anterior surface of vaginal trachelectomies, but a small amount may be present in specimens excised abdominally. Where the anterior and posterior aspects of a specimen are difficult to identify, this should be clearly recorded.
- The height/length, lateral, and anteroposterior dimensions in millimetres.
- The length of the vaginal cuff as a range (with maximum and minimum dimensions, as this usually varies around the circumference); also, the positions of the maximum and minimum lengths.
- The presence of any macroscopic abnormality: residual tumour, biopsy defect/scar, or other lesions.
- The dimensions of the residual tumour, biopsy defect, or other lesion(s), and the distance of the residual tumour from the proximal, distal, and radial resection margins.

When taking blocks:

- The parametrial margins should be inked. Using a standard protocol of Right (gReen) and Left (bLue or yeLlow) helps to maintain orientation after slicing, as does use of a different colour to mark the anterior aspect.
- The specimen should be blocked in its entirety. Block taking will vary according to local preferences and the nature of the individual specimen (see below).
- There is often a large central circumferential biopsy defect and no macroscopically visible residual tumour.
- Where residual tumour is clearly visible, the blocks should be taken in such a way that it is possible to measure tumour position and distance relative to margins (proximal, vaginal, cervical stromal (tumour-free stromal rim), and parametrial).

Blocks should be taken in a standard way for all other cases (i.e. when there is no residual visible tumour) and should also be taken to sample the remaining tissue after the tumour has been assessed. The following methods are recommended:

- The specimen is inked according to local protocols.
- The specimen is sliced in parallel, horizontal slices of 2–3 mm thickness, including cervix and attached parametrial tissues in continuity, starting from the upper end and stopping 10–15 mm above the external os, taking care not to slice through the vaginal fornices.

- The lower part of the specimen, comprising the ectocervix and attached vaginal cuff, are sliced in the same way as a cone biopsy (see above).
- Each slice is processed in a separate cassette.
- The proximal/upper margin (first slice) is embedded to allow examination of the superior surface. All transverse slices are embedded similarly, with the superior surface forming the cutting face of the block.
- Each slice may have to be bisected, or cut into three or four pieces, to fit into a cassette in a way that preserves all surgical margins. Large blocks can be used if preferred. No tissue should be trimmed or discarded
- Alternatively, take one sagittal slice through the length of the trachelectomy, leaving right and left hemicervices with parametrial and vaginal tissues attached. The vertical slice is processed as anterior and posterior portions of cervix and vagina, and the remaining specimen is then handled according to the advice given above.
- For specimens that are smaller than 10–15 mm in their vertical dimension, processing as a cone or LLETZ may be preferable.

Processing/staining:

- Use standard H&E.
- Cut a full-face single section from each block.[219]
- If the surface epithelium is missing or sections are incomplete, consider cutting further levels.
- Histochemistry and immunohistochemistry may be necessary to subtype tumours.

Hysterectomy

Type of hysterectomy

Simple hysterectomy
- May be performed in cases where persistent abnormal cytology has been reported, after therapeutic conisation or loop excision of an earlier cervical lesion, or for persistent cytological changes where the transformation zone cannot be visualised colposcopically (because of cervical stenosis or scarring from previous cervical loop biopsies or conisation).
- CIN may be an incidental finding when simple hysterectomy has been performed for other clinical reasons. When the uterus has already been opened and sampled before the cervical lesion was detected, two standard cervical blocks may already have been taken. In such cases, block the remaining cervical tissue to examine the entire transformation zone. This will ensure that the whole lesion has been processed, exclude an invasive component, and allow assessment of resection margins.

Radical hysterectomy
- Is performed for histologically confirmed cervical carcinoma and includes the parametria, vaginal cuff, and pelvic or para-aortic lymph node dissection.

Pelvic exenteration
- Pelvic clearance, or more extensive surgery, may be performed for advanced cervical carcinoma, sometimes after treatment with chemoradiation.
- The hysterectomy specimen may be accompanied by adjacent or adherent organs, e.g. bladder, large bowel, and (in rare cases) pelvic sidewall and/or bone. Prior chemoradiation may obscure the primary tumour and also the extent of macroscopic tumour spread.
- Dissection of adherent or adjacent organs should be carried out in a way that does not compromise assessment of resection margins.

Preparation

Simple hysterectomy

- Orientate by identifying the posterior peritoneal reflection (which is lower), or by assessing the orientation of the adnexa, if these are attached (the ovaries are posterior to the fallopian tubes). The uterus should be opened (in the sagittal or coronal plane) to allow fixation. The method of opening will be determined by the presence of other pathological features, e.g. fibroids.
- For persistent cytological changes in cervical samples, or where there is suspicion of cervical pathology, consider amputating the cervix and handling this in similar way to a cone or loop biopsy.

Radical hysterectomy

- A photographic record of the specimen may be useful, and the resection margins may require painting with ink/dye before the specimen is opened.
- The uterus should be orientated as described above, and opened according to the method that optimises fixation and visualisation of the cervical tumour. Blocks must be taken to ensure that all of the core data items can be assessed.
- Consider trimming or removing the vaginal cuff to enable assessment of the cervical tumour. If this is done, epithelial strips from the resection margin of each vaginal cuff quadrant can be blocked separately for histological assessment of the whole circumferential vaginal resection margin.
- Examine the fornices and record the position and extent of any vaginal involvement.
- If there is only a short length of vaginal cuff attached to the specimen, the vaginal cuff (and resection margin) should be submitted in continuity with the cervix.
- Consider amputating the cervix before opening the uterus, depending on tumour size. Large, bulky tumours may not be amenable to sampling in this way.
- Lymph nodes are usually sent in separate pots, labelled according to their site of origin.

Pelvic exenteration

- A photographic record of the specimen may be useful. Consider painting resection margins with different colours of ink/dye and inflating the urinary bladder with formalin prior to specimen opening.
- Open adherent or adjacent organs to allow fixation without compromising resection margins.
- Hemisect the entire specimen in the sagittal plane through the uterus and neoplasm.[222] This allows detailed evaluation of the relationship of the tumour to adjacent anatomical structures and facilitates block selection.
- Lymph nodes are usually sent in separate pots, labelled according to the site of origin. Process nodes that are recovered from the mesocolon/mesorectum and parametria separately.

Details to document

Simple hysterectomy

- Measure the uterus in three dimensions (fundus to distal end of cervix, cornu to cornu, and anteroposterior).
- Record the dimensions of the adnexa.
- Record and measure any macroscopic cervical lesions,[11] including surface irregularities, biopsy or conisation sites, and masses.
- Include the distance to the nearest resection margin of any mass or lesion.

Radical hysterectomy

- Record and measure the specimen components, their gross appearances, and any macroscopic lesions.[23]
- Measure the length of the parametria (measurement of their width is of limited value, as this varies according to the elasticity of the tissue and the size of the uterus).
- Measure the thickness of the paracervical tissue and length of the vaginal cuff.
- Measure the cervical tumour in three dimensions if possible. In most studies, two-dimensional measurements of tumour size are provided for tumour staging and prognosis,[25,224] but a few studies have shown that measurements of tumour volume offer a more reliable prediction of prognosis than measurements in only one or two dimensions.[25,224]
- Record the position and the number of quadrants involved in the cervix. The risk of lymph node involvement increases progressively with involvement of one or more cervical quadrants by the tumour (from 2% if one quadrant is involved to 13% if three or four quadrants are involved).[225] Recording the position of the tumour within the cervix also enables audit of, and correlation with, radiological findings. Ensure that the distance to the closest resection margins is also measured.
- Record the dimensions of any visible site from which loop or cone biopsies have previously been taken.
- Note macroscopic tumour involvement of the parametrial and paracervical tissues. This may influence the method of dissection and block taking. It may be preferable to sample the tumour in continuity with the involved parametrial or paracervical tissues, rather than removing these to begin with. However, either method is acceptable.
- Document the presence of lymph nodes in the parametria.
- Note extension of the tumour into the uterine corpus (although this does not alter the stage of the cervical carcinoma).
- Sample the uterine corpus and adnexa according to standard protocols where these are macroscopically normal. Additional blocks may be required if there is evidence of involvement by tumour.
- Record the number of lymph nodes retrieved from each separate site and note macroscopic involvement and dimensions of involved nodes.

Pelvic exenteration

- Record and measure the specimen's components, their gross appearances, and any macroscopic lesions,[23] capturing relevant information on the relationship of the tumour to the bowel (usually the rectum) and urinary bladder.
- Describe the presence, and the extent of involvement, of any tumour in the vaginal fornices, parametria, urinary bladder, and rectum.
- Measure the distance from the tumour to the resection margins.
- Record the number and site of lymph nodes recovered from the specimen, including those submitted in separate containers. Note macroscopic involvement and dimensions of involved nodes.

Blocks

- Where hysterectomy has been undertaken following a recent abnormal cytological report, process the whole of the cervical transformation zone. This usually involves taking the bulk of the cervix in sagittal and parasagittal sections. Record the anatomical origin of each of the blocks.
- Where tumours are small, or where no macroscopic tumour has been identified, block the whole cervix, using the cone/loop biopsy technique.

- For macroscopic tumours, take blocks to demonstrate the maximum depth of invasion and the relationship to the surgical resection margins, notably the vaginal, anterior cervix/bladder reflection, posterior cervix/rectovaginal septum, and parametrial/paracervical margins.
- For large, bulky tumours block at least one section per centimetre, capturing the greatest tumour dimension and including the full thickness of the cervical wall, so that it is possible to identify the deepest point of invasion.
- Block the interface between the tumour and the adjacent cervix to demonstrate any CIN or CGIN from which the carcinoma may have arisen.[226]
- Take full-thickness blocks from the lower uterine segment, immediately proximal and adjacent to the tumour, to identify upward extension.
- Consider taking blocks of the vaginal resection margin, in continuity with the tumour, where the vaginal cuff is short (see above). Take separate blocks of the trimmed circumferential vaginal resection margin in cassettes designated according to their origin (i.e. label these to indicate the anatomical quadrant from which the blocks originated).
- Block the parametria and paracervical tissues in their entirety, recording laterality. Consider inking to define the true surgical margins and the apex of the parametria.[4]
- To assess infiltration of the rectum and bladder, sample the rectum and bladder perpendicular to the mucosa directly overlying the cervical tumour. Also, sample the closest circumferential resection margins.
- Consider using oversized tissue blocks when examining cervical tumours in exenteration specimens, in order to retain anatomical relationships and assess resection margins. Process additional standard-sized blocks of tumour to allow immunohistochemistry or other special stains to be undertaken if necessary.
- Block out the whole of each lymph node from each separate anatomical location, unless the node is grossly involved by tumour. Only one block is necessary from any grossly involved node. Process nodes smaller than 5 mm either bisected or whole. Large lymph nodes may require sectioning and processing in more than one block.
- *It is particularly important to record the origin and designation of all tissue blocks in the macroscopic section of the histology report, to allow internal or external review if necessary. Any reviewer will need to know the origin, resection margins, and laterality of each block in order to provide an accurate, informed opinion.*

Processing/staining

- Use standard H&E.
- Cut a single full-face section from each block.[219]
- Cut further levels as required.
- Consider histochemistry and immunohistochemistry to subtype tumours.

APPENDIX 6: INFORMATION ABOUT CANCER REGISTRIES

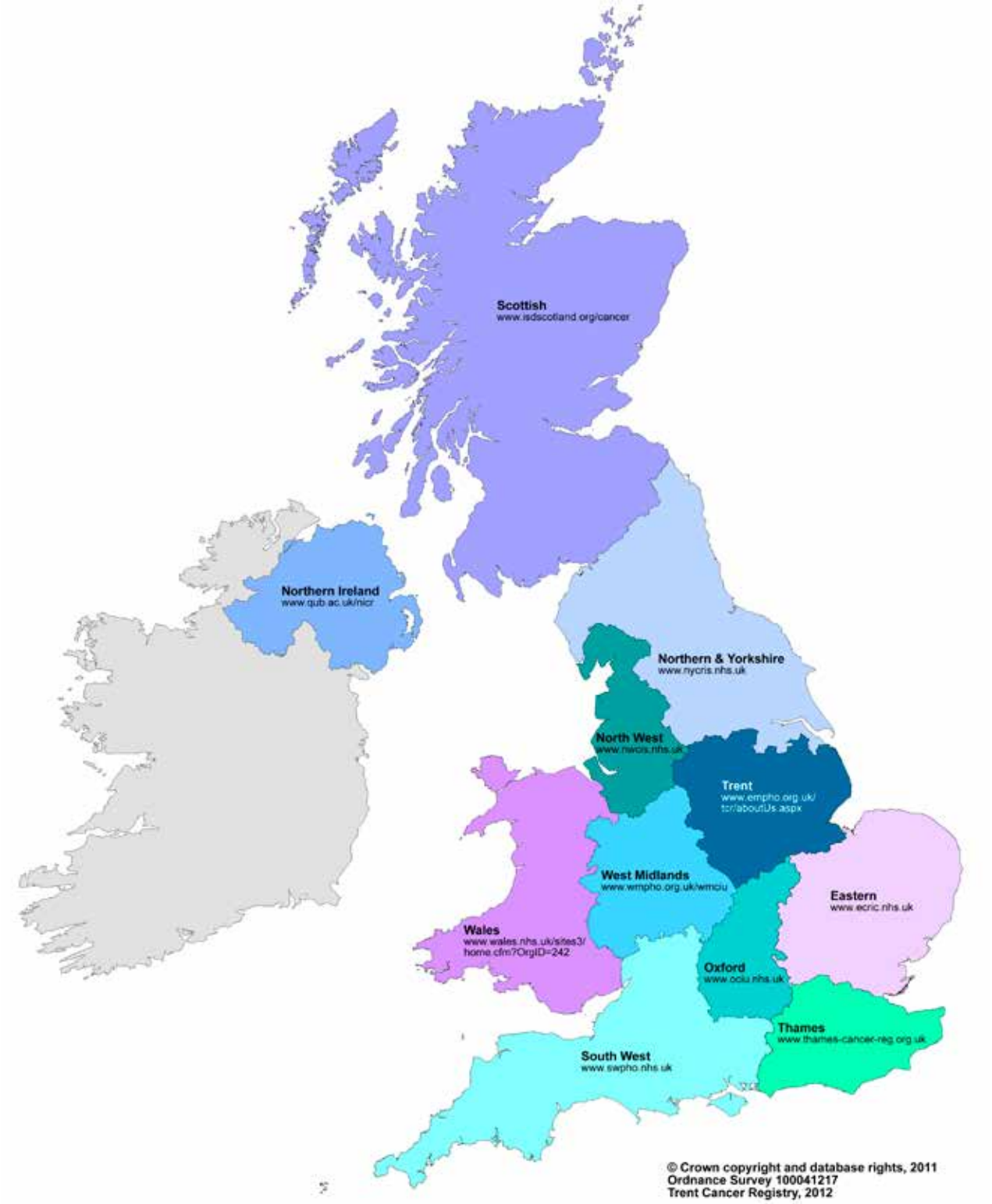

Note: This information is correct at the time of going to press but may be subject to change once the organisational design of Public Health England has been agreed. Source: Based on ONS Super Output Area and Ordnance Survey BoundaryLine products.

English regional registries

Eastern Cancer Registration & Information Centre (ECRIC)
Unit C, Magog Court
Shelford Bottom
Hinton Way
Cambridge CB22 3AD

Tel: 01223 213499
Website: www.ecric.nhs.uk

Director: Dr Jem Rashbass

South West Public Health Observatory (SWPHO)
Grosvenor House
149 Whiteladies Road
Clifton
Bristol BS8 2RA

Tel: 0117 970 6474
Website: www.swpho.nhs.uk

Director: Dr Julia Verne

North West Cancer Intelligence Service (NWCIS)
The Christie NHS Foundation Trust
The Palatine Centre
63–65 Palatine Road
Withington
Manchester M20 3LJ

Tel: 0161 446 8080
Website: www.nwcis.nhs.uk

General Manager: Mr Stephen Raynor

Thames Cancer Registry

1st Floor
Capital House
42 Weston Street
London SE1 3QD

Tel: 020 7378 7688
Website: www.thames-cancer-reg.org.uk

Director: Dr Elizabeth Davies

Northern & Yorkshire Cancer Registry & Information Service (NYCRIS)
Level 6, Bexley Wing (Institute of Oncology)
St James's University Hospital
Beckett Street
Leeds LS9 7TF

Tel: 0113 206 8830
Website: www.nycris.nhs.uk

Joint Directors: Professor John Wilkinson and Professor Brian Ferguson

Trent Cancer Registry

5 Old Fulwood Road
Sheffield S10 3TG

Tel: 0114 226 3560
Website: www.empho.org.uk/tcr/aboutUs.aspx

Director: Mr David Meechan

Oxford Cancer Intelligence Unit (OCIU)

4150 Chancellor Court
Oxford Business Park South
Oxford OX4 2GX

Tel: 01865 334770
Website: www.ociu.nhs.uk

Director: Dr Monica Roche

West Midlands Cancer Intelligence Unit (WMCIU)
Public Health Building
The University of Birmingham
Edgbaston
Birmingham B15 2TT

Tel: 0121 414 7711
Website: www.wmpho.org.uk/wmciu

Director: Dr Gill Lawrence

Scotland, Wales, and Northern Ireland

Scottish Cancer Registry
Information Services Division of NHS National Services Scotland (ISD Scotland)
Area 155, Gyle Square
1 South Gyle Crescent
Edinburgh EH12 9EB

Tel: 0131 275 6092
Website: www.isdscotland.org/cancer

Director: Dr David Brewster

Welsh Cancer Intelligence & Surveillance Unit
Public Health Wales NHS Trust
13th Floor, Brunel House
2 Fitzalan Road
Cardiff CF24 0HA

Tel: 02920 373500
Website: www.wales.nhs.uk/sites3/home.cfm?OrgID=242

Director: Vacant
General Manager: Shelagh Reynolds

Northern Ireland Cancer Registry
Centre for Public Health
Queen's University Belfast
Mulhouse Building
Grosvenor Road
Belfast BT12 6BJ

Tel: 028 9063 2573
Website: www.qub.ac.uk/nicr

Director: Dr Anna Gavin

National Registry of Childhood Tumours

National Registry of Childhood Tumours
Childhood Cancer Research Group
Richards Building
University of Oxford
Old Road Campus
Headington
Oxford OX3 7LG

Tel: 01865 617800
Website: www.ccrg.ox.ac.uk/index.htm

Registry Director: Dr Charles Stiller

Sources of cancer registration data

The Cervical Screening and Cancer e-Atlas is a freely available, web-based resource presenting information on screening coverage, timeliness, and results, as well as cancer incidence, mortality, and survival: www.empho.org.uk/tcr/cervicalEatlas.aspx

The Cancer e-Atlas presents national data on incidence, mortality, and survival for the main types of cancers: www.ncin.org.uk/cancer_information_tools/eatlas.aspx

The UK Cancer Information Service (UKCIS) is a web-based reporting tool, running across N3 (the NHS national network), providing registered users with access to cancer information for their area. Registration requests to access the UKCIS should be submitted to the appropriate regional cancer registry: www.ncin.org.uk/cancer_information_tools/ukcis.aspx

Regional cancer registry websites present local cancer registration information (see pages 94 and 95).

National Cancer Intelligence Network (NCIN) reports and publications are available at: www.ncin.org.uk/publications/default.aspx

Cancer Statistics: registrations series MB1 allows access to national and regional information about cancer incidence, including statistical tables with the numbers and rates of newly diagnosed cases of cancer by site and sex: www.ons.gov.uk/ons/publications/all-releases.html?definition=tcm%3A77-27454

Cancer Survival Trends contains information on 21 common cancers in England, including the latest 1- and 5-year, age-standardised, crude and relative survival rates: www.ons.gov.uk/ons/publications/all-releases.html?definition=tcm%3A77-21521

The Cancer*Mondial* website is provided by the International Agency for Research on Cancer (IARC) and gives access to various databases containing information on the occurrence of cancer worldwide: www-dep.iarc.fr

REFERENCES

1. Anderson MC, Brown L, Buckley CH, et al. Current views on cervical intraepithelial neoplasia. *Journal of Clinical Pathology*, 1991, 44: 969–978.
2. Heatley MK. How should we grade CIN? *Histopathology*, 2002, 40: 377–390.
3. McCluggage WG, Bharucha H, Caughley LM, et al. Interobserver variation in the reporting of cervical colposcopic biopsy specimens: comparison of grading systems. *Journal of Clinical Pathology,* 1996, 49: 833–835.
4. Robboy SJ, Mutter GL, Prat J, et al (eds). *Robboy's Pathology of the Female Reproductive Tract*. London, Churchill Livingstone, 2009.
5. Jenkins D, Tay SK, McCance DJ, et al. A histological and immunocytochemical study of cervical intraepithelial neoplasia (CIN) with associated HPV 6 and HPV 16 infections. *Journal of Clinical Pathology*, 1986, 39: 1177–1180.
6. Van Leeuwen AM, Pieters WJ, Hollema H, et al. Atypical mitotic figures and the mitotic index in cervical intraepithelial neoplasia. *Virchows Archiv,* 1995, 427: 139–144.
7. Smail S, Fiander A. Grading cervical intraepithelial neoplasia. *Histopathology,* 2002, 40: 385–390.
8. Wilson GE. The classification of cervical intraepithelial neoplasia. *Histopathology,* 2002, 40: 380–385.
9. Al-Nafussi A, Hughes DE. Histological features of CIN3 and their value in predicting invasive microinvasive squamous carcinoma. *Journal of Clinical Pathology*, 1994, 47: 799–804.
10. Heatley MK, Bury JP. The correlation between the grade of dyskaryosis on cervical smear, grade of cervical intraepithelial neoplasia (CIN) on punch biopsy and the final histological diagnosis on cone biopsies of the cervix. *Cytopathology,* 1998, 9: 93–99.
11. Brown LR, Andrew A, and Hirschowitz L, et al. *Tissue Pathways for Gynaecological Pathology.* London, Royal College of Pathologists, 2008. Available at: www.rcpath.org/NR/rdonlyres/BBA1A2E8–1174–4BEA-BCEF-39E5FBEA41CC/0/g073_tpgynae_jul08.pdf. Accessed 5 March 2012.
12. Heatley MK. How many histological levels should be examined from tissue blocks originating in cone biopsy and large loop excision of the transformation zone specimens of cervix? *Journal of Clinical Pathology*, 2001, 54: 650–651.
13. Malpica A, Deavers M, and Euscher E. *Biopsy Interpretation of the Uterine Cervix and Corpus*. Philadelphia, Lippincott Williams & Wilkins, 2010.
14. Roteli-Martins CM, Alves VA, Santos RT, et al. Value of morphological criteria in diagnosing cervical HPV lesions confirmed by in situ hybridization and hybrid capture assay. *Pathology – Research and Practice,* 2001, 197: 677–682.
15. McCluggage WG. Immunohistochemistry as a diagnostic aid in cervical pathology. *Pathology,* 2007, 39: 97–111.
16. Mittal K. Utility of proliferation-associated marker MIB-1 in evaluating lesions of the uterine cervix. *Advances in Anatomic Pathology*, 1999, 6: 177–185.
17. Mittal K. Utility of MIB-1 in evaluating cauterized cervical cone biopsy margins. *International Journal of Gynecological Pathology*, 1999, 18: 211–214.
18. Sanati S, Huettner P, Ylagan LR. Role of ProExC: a novel immunoperoxidase marker in the evaluation of dysplastic squamous and glandular lesions in cervical specimens. *International Journal of Gynecological Pathology,* 2010, 29: 79–87.
19. *Colposcopy and Programme Management: Guidelines for the NHS Cervical Screening Programme* (NHSCSP Publication No 20). Sheffield, NHS Cancer Screening Programmes, 2010. Available at: www.cancerscreening.nhs.uk/cervical/publications/nhscsp20.pdf. Accessed 5 March 2012.
20. Flannelly G, Bolger B, Fawzi H, et al. Follow up after LLETZ: could schedules be modified according to risk of recurrence? *BJOG*, 2001, 108: 1025–1030.
21. Shepherd JH. Staging announcement. FIGO staging of gynecologic cancers; cervical and vulva. *International Journal of Gynecological Cancer,* 1995, 5: 319. Erratum in: *International Journal of Gynecological Cancer,* 1995, 5: 465.
22. Girardi F, Burghardt E, Pickel H. Small FIGO stage IB cervical cancer. *Gynecologic Oncology,* 1994, 55: 427–432.
23. Hirschowitz L, Ganesan R, Singh N, et al. *Dataset for Histopathological Reporting of Cervical Neoplasia* (3rd edition). London, Royal College of Pathologists, 2011. Available at: www.rcpath.org/index.asp?PageID=1152. Accessed 5 March 2012.
24. Raspagliesi F, Ditto A, Quattrone P, et al. Prognostic factors in microinvasive cervical squamous cell cancer: long-term results. *International Journal of Gynecological Cancer,* 2005, 15: 88–93.
25. Burghardt E, Baltzer J, Tulusan AH, et al. Results of surgical treatment of 1028 cervical cancers studied with volumetry. *Cancer,* 1992, 70: 648–655.

26. Burghardt E, Holzer E. Diagnosis and treatment of microinvasive carcinoma of the cervix uteri. *Obstetrics and Gynecology,* 1977, 49: 641–653.
27. Trattner M, Graf A H, Lax S, et al. Prognostic factors in surgically treated stage Ib–IIb cervical carcinomas with special emphasis on the importance of tumour volume. *Gynecologic Oncology,* 2001, 82: 11–16.
28. Kurman R J, Ellenson LH, Ronnett BM, eds. *Blaustein's Pathology of the Female Genital Tract*, 6th edition. New York, Springer, 2011.
29. Sedlis A, Sall S, Tsukada Y, et al. Microinvasive carcinoma of the uterine cervix: a clinical–pathologic study. *American Journal of Obstetrics and Gynecology,* 1979, 133: 64–74.
30. Reich O, Pickel H, Tamussino K, et al. Microinvasive carcinoma of the cervix: site of first focus of invasion. *Obstetrics and Gynecology,* 2001, 97: 890–892.
31. Reich O, Pickel H. Multifocal stromal invasion in microinvasive squamous cell carcinoma of the cervix: how to measure and stage these lesions. *International Journal of Gynecological Pathology,* 2002, 21: 416–417.
32. Winter R. Conservative surgery for microinvasive carcinoma of the cervix. *Journal of Obstetrics and Gynecology Research,* 1998, 24: 433–436.
33. Gadduci A, Sartori E, Maggino T, et al.The clinical outcome of patients with stage Ia1 and Ia2 squamous cell carcinoma of the uterine cervix: a Cooperation Task Force (CTF) study. *European Journal of Gynaecological Oncology,* 2003, 24: 433–436.
34. Tavassoli FA, Devilee P, eds. *World Health Organization Classification of Tumours: Pathology and Genetics: Tumours of the Breast and Female Genital Organs*. Lyon, IARC Press, 2003.
35. Stock RJ, Zaino R, Bundy BN, et al. Evaluation and comparison of histopathologic grading systems of epithelial carcinoma of the uterine cervix: Gynecologic Oncology Group studies. *International Journal of Gynecological Pathology,* 1994, 13: 99–108.
36. Kristensen GB, Abeler VM, Risberg B, et al. Tumour size, depth of invasion, and grading of the invasive tumour front are the main prognostic factors in early squamous cell cervical carcinoma. *Gynecologic Oncology,* 1999, 74: 245–251.
37. Singh N, Arif S. Histopathologic parameters of prognosis in cervical cancer – a review. *International Journal of Gynecological Cancer,* 2004, 14: 741–750.
38. Pecorelli S. Revised FIGO staging for carcinoma of the vulva, cervix, and endometrium. *International Journal of Gynecology and Obstetrics,* 2009, 105: 103–104.
39. McCluggage WG, Hirschowitz L, Ganesan R, et al. Which staging system to use for gynaecological cancers: a survey with recommendations for practice in the UK. *Journal of Clinical Pathology,* 2010, 63: 768–770.
40. Tseng CJ, Pao CC, Tseng LH, et al. Lymphoepithelioma-like carcinoma of the uterine cervix: association with Epstein–Barr virus and human papillomavirus. *Cancer*,1997, 80: 91–97.
41. Kurman R J, Toki T, Schiffman MH. Basaloid and warty carcinomas of the vulva. Distinctive types of squamous cell carcinoma frequently associated with human papillomaviruses. *American Journal of Surgical Pathology,* 1993, 17: 133–145.
42. Martorell MA, Julian JM, Calabuig C, et al. Lymphoepithelioma-like carcinoma of the uterine cervix. *Archives of Pathology and Laboratory Medicine,* 2002, 126: 1501–1505.
43. Noel J, Lespagnard L, Fayt I, et al. Evidence of human papilloma virus infection but lack of Epstein–Barr virus in lymphoepithelioma-like carcinoma of uterine cervix: report of two cases and review of the literature. *Human Pathology,* 2001, 32: 135–138.
44. Skinner NE, Horowitz RI, and Majmudar B. Lymphoepithelioma-like carcinoma of the uterine cervix. *Southern Medical Journal,* 2000, 93: 1024–1027.
45. Koenig C, Turnicky RP, Kankam CF, et al. Papillary squamotransitional cell carcinoma of the cervix: a report of 32 cases. *American Journal of Surgical Pathology,* 1997, 21: 915–921.
46. Lininger RA, Wistuba I, Gazdar A, et al. Human papillomavirus type 16 is detected in transitional cell carcinomas and squamotransitional cell carcinomas of the cervix and endometrium. *Cancer,* 1998, 83: 521–527.
47. Harnden P, Kennedy W, Andrew AC, et al. Immunophenotype of transitional metaplasia of the uterine cervix. *International Journal of Gynecological Pathology,* 1999, 18: 125–129.
48. Weir MM, Bell DA, and Young RH. Transitional cell metaplasia of the uterine cervix and vagina: an underrecognized lesion that may be confused with high-grade dysplasia. A report of 59 cases. *American Journal of Surgical Pathology,* 1997, 21: 510–517.
49. Jovanovic AS, McLachlin CM, Shen L, et al. Postmenopausal squamous atypia: a spectrum including "pseudo-koilocytosis". *Modern Pathology,* 1995, 8: 408–412.
50. Pinto AP, Schlecht NF, Woo TY, et al. Biomarker (ProEx C, p16(INK4A), and MiB-1) distinction of high-grade squamous intraepithelial lesion from its mimics. *Modern Pathology,* 2008, 21: 1067–1074.

51. Egan AJ , Russell P. Transitional (urothelial) cell metaplasia of the uterine cervix: morphological assessment of 31 cases. *International Journal of Gynecological Pathology,* 1997, 16: 89–98.
52. El-Bahrawy M. Expression of p16 in post-radiotherapy cervical biopsies. *Histopathology,* 2011, 58: 1174–1176.
53. Sasieni P, Adams J. Changing rates of adenocarcinoma and adenosquamous carcinoma of the cervix in England. *Lancet,* 2001, 357: 1490–1493.
54. Houghton O, Jamison J, Wilson R, et al. p16 immunoreactivity in unusual types of cervical adenocarcinoma does not reflect human papillomavirus infection. *Histopathology,* 2010, 57: 342–350.
55. Young RH, Clement PB. Pseudoneoplastic glandular lesions of the uterine cervix. *Seminars in Diagnostic Pathology,* 1991, 8: 234–249.
56. McCluggage WG. Endocervical glandular lesions: controversial aspects and ancillary techniques. *Journal of Clinical Pathology,* 2003, 56: 164–173.
57. Al-Fehmi R, Qureshi F, Lawrence WG, et al. Apoptosis, proliferation, and expression of p53 and bcl-2 in endocervical glandular intraepithelial lesions and invasive endocervical adenocarcinoma. *International Journal of Gynecological Pathology,* 2004, 23: 1–6.
58. Cameron RI, Maxwell P, Jenkins D, et al. Immunohistochemical staining with MIB1, bcl2 and p16 assists in the distinction of cervical glandular intraepithelial neoplasia from tubo-endometrial metaplasia, endometriosis and microglandular hyperplasia. *Histopathology*, 2002, 41: 313–321.
59. Ostör AG, Duncan A, Quinn M, et al. Adenocarcinoma in situ of the uterine cervix: an experience with 100 cases. *Gynecologic Oncology,* 2000, 79: 207–210.
60. McCluggage WG, Shah R, Connolly LE, et al. Intestinal-type cervical adenocarcinoma *in situ* and adenocarcinoma exhibit a partial immunophenotype with consistent expression of CDX2. *International Journal of Gynecological Pathology*, 2008, 27: 92–100.
61. Schlesinger C, Silverberg SG. Endocervical adenocarcinoma in situ of tubal type and its relation to atypical tubal metaplasia. *International Journal of Gynecological Pathology*, 1999, 73: 305–311.
62. Park JJ, Sun D, Quade BJ, et al. Stratified mucin producing intraepithelial lesions of the cervix: adenosquamous or columnar cell neoplasia? *Americal Journal of Surgical Pathology,* 2000, 24: 1414–1419.
63. Ostör AG. Early invasive adenocarcinoma of the uterine cervix. *International Journal of Gynecological Pathology,* 2000, 19: 29–38.
64. Rollason TP, Cullimore J, Bradgate MG. A suggested columnar cell morphological equivalent of squamous carcinoma in situ with early stromal invasion. *International Journal of Gynecological Pathology,* 1989, 8: 230–236.
65. Wheeler D T, Kurman R J. The relationship of glands to thick-wall blood vessels as a marker of invasion in endocervical adenocarcinoma. *International Journal of Gynecological Pathology*, 2005, 24: 125–130.
66. Yahata T, Nishino K, Kashima K, et al. Conservative treatment of stage 1A1 adenocarcinoma of the uterine cervix with a long-term follow-up. *International Journal of Gynecological Cancer,* 2010, 20: 1063–1066.
67. Ceballos KM, Shaw D, Daya D. Microinvasive cervical adenocarcinoma (FIGO stage 1A tumours): results of surgical staging and outcome analysis. *Americal Journal of Surgical Pathology,* 2006, 30: 370–374.
68. Tambouret R, Bell D A, Young R H. Microcystic endocervical adenocarcinomas: a report of eight cases. *Americal Journal of Surgical Pathology,* 2000, 24: 369–374.
69. Mansor S, McCluggage WG. Cervical adenocarcinoma resembling breast lobular carcinoma: a hitherto undescribed variant of primary cervical adenocarcinoma. *International Journal of Gynecological Pathology,* 2010, 29: 594–599.
70. Dabbs DJ, Geisinger KR, Norris HT. Intermediate filaments in endometrial and endocervical carcinomas. The diagnostic utility of vimentin patterns. *Americal Journal of Surgical Pathology,* 1986, 10: 568–576.
71. Kong CS, Beck AH, Longacre TA. A panel of 3 markers including p16, ProExC, or HPV ISH is optimal for distinguishing between primary endometrial and endocervical adenocarcinomas. *Americal Journal of Surgical Pathology,* 2010, 34: 915–926.
72. Castrillon DH, Lee KR, Nucci MR. Distinction between endometrial and endocervical adenocarcinoma: an immunohistochemical study. *International Journal of Gynecological Pathology,* 2002, 21: 4–10.
73. McCluggage WG, Sumathi VP, McBride HA, et al. A panel of immunohistochemical stains, including carcinoembryonic antigen, vimentin, and estrogen receptor, aids the distinction between primary endometrial and endocervical adenocarcinomas. *International Journal of Gynecological Pathology,* 2002, 21: 11–15.
74. Suarez-Penaranda JM, Abdulkader I, Baron-Duarte FJ, et al. Signet-ring cell carcinoma presenting in the uterine cervix: report of a primary and 2 metastatic cases. *International Journal of Gynecological Pathology,* 2007, 26: 254–258.
75. McKenna M, McCluggage WG. Signet-ring cells of stromal derivation in the uterine cervix secondary to cauterisation: report of a previously undescribed phenomenon. *Journal of Clinical Pathology,* 2008, 61: 648–651.

76. Young RH, Clement PB. Endocervical adenocarcinoma and its variants: their morphology and differential diagnosis. *Histopathology,* 2002, 41: 185–207.
77. Hart WR. Symposium part II: special types of adenocarcinoma of the uterine cervix. *International Journal of Gynecological Pathology,* 2002, 21: 327–346.
78. Mikami Y, Kiyokawa T, Hata S, et al. Gastrointestinal immunophenotype in adenocarcinomas of the uterine cervix and related glandular lesions: a possible link between lobular endocervical glandular hyperplasia/pyloric gland metaplasia and 'adenoma malignum'. *Modern Pathology,* 2004, 17: 962–972.
79. Jones MW, Silverberg SG, Kurman RJ. Well-differentiated villoglandular adenocarcinoma of the uterine cervix: a clinicopathological study of 24 cases. *International Journal of Gynecological Pathology,* 1993, 12: 1–7.
80. Heatley MK. Villoglandular adenocarcinoma of the uterine cervix – a systematic review of the literature. *Histopathology,* 2007, 51: 268–269.
81. Fadare O, Zheng W. Well-differentiated papillary villoglandular adenocarcinoma of the uterine cervix with a focal high-grade component: is there a need for reassessment? *Virchows Archiv*, 2005, 447: 883–837.
82. Kojima A, Mikami Y, Sudo T, et al. Gastric morphology and immunophenotype predict poor outcome in mucinous adenocarcinoma of the uterine cervix. *American Journal of Surgical Pathology,* 2007, 31: 664–672.
83. Kusanagi Y, Kogima A, Mikami Y, et al. Absence of high-risk human papillomavirus (HPV) detection in endocervical adenocarcinoma with gastric morphology and phenotype. *American Journal of Pathology,* 2010, 177: 2169–2175.
84. McCluggage WG, Harley I, Houghton JP, et al. Composite cervical adenocarcinoma composed of adenoma malignum and gastric type adenocarcinoma (dedifferentiated adenoma malignum) in patient with Peutz–Jeghers syndrome. *Journal of Clinical Pathology,* 2010, 63: 935–941.
85. Hirschowitz L, Sen C, Murdoch J. Primary endometrioid adenocarcinoma of the cervix with widespread squamous metaplasia – a potential diagnostic pitfall. *Diagnostic Pathology,* 2007, 2: 40.
86. Hanselaar A, van Loosbroek M, Schuurbiers O, et al. Clear cell adenocarcinoma of the vagina and cervix. An update of the central Netherlands registry showing twin age incidence peaks. *Cancer,* 1997, 79: 2229–2236.
87. Matias-Guiu X, Lerma E, Prat J. Clear cell tumours of the female genital tract. *Seminars in Diagnostic Pathology,* 1997, 14: 233–239.
88. Zhou C, Gilks CB, Hayes M, et al. Papillary serous carcinoma of the uterine cervix: a clinicopathologic study of 17 cases. *American Journal of Surgical Pathology,* 1998, 22: 113–120.
89. Nofech-Mozes S, Rasty G, Ismiil N, et al. Immunohistochemical characterization of endocervical papillary serous carcinoma. *International Journal of Gynecological Cancer,* 2006, 16(Suppl 1): 286–92.
90. Clement PB, Young RH, Keh P, et al. Malignant mesonephric neoplasms of the uterine cervix. A report of eight cases, including four with a malignant spindle cell component. *American Journal of Surgical Pathology,* 1995, 19: 1158–1171.
91. McCluggage WG, Oliva E, Herrington CS, et al. CD10 and calretinin staining of endocervical glandular lesions, endocervical stroma and endometrioid adenocarcinomas of the uterine corpus: CD10 positivity is characteristic of, but not specific for, mesonephric lesions and is not specific for endometrial stroma. *Histopathology,* 2003, 43: 144–150.
92. Silver SA, Devouassoux-Shisheboran M, Mezzetti TP, et al. Mesonephric adenocarcinomas of the uterine cervix: a study of 11 cases with immunohistochemical findings. *American Journal of Surgical Pathology,* 2001, 25: 379–387.
93. Oliva E, Clement PB, Young RH. Tubal and tubo-endometrioid metaplasia of the uterine cervix. Unemphasized features that may cause problems in differential diagnosis: a report of 25 cases. *American Journal of Clinical Pathology,* 1995, 103: 618–623.
94. Ismail SM. Cone biopsy causes cervical endometriosis and tubo-endometrioid metaplasia. *Histopathology*, 1991, 18: 107–114.
95. Al-Nafussi AI, Rahilly M. The prevalence of tubo-endometrial metaplasia and adenomatoid proliferation. *Histopathology,* 1993, 22: 177–179.
96. McCluggage WG, Maxwell P, McBride HA, et al. Monoclonal antibodies Ki-67 and MIB1 in the distinction of tuboendometrial metaplasia from endocervical adenocarcinoma and adenocarcinoma *in situ* in formalin-fixed material. *International Journal of Clinical Pathology,* 1995, 14: 209–216.
97. McCluggage G, McBride H, Maxwell P, et al. Immunohistochemical detection of p53 and bcl-2 proteins in neoplastic and non-neoplastic endocervical glandular lesions. *International Journal of Gynecological Pathology,* 1997, 16: 22–27.
98. Marques T, Andrade LA, Vassallo J. Endocervical tubal metaplasia and adenocarcinoma *in situ*: role of immunohistochemistry for carcinoembryonic antigen and vimentin in differential diagnosis. *Histopathology*, 1996, 28: 549–550.

99. Baker PM, Clement PB, Bell DA, et al Superficial endometriosis of the uterine cervix: a report of 20 cases of a process that may be confused with endocervical glandular dysplasia or adenocarcinoma in situ. *International Journal of Gynecological Pathology,* 1999, 18: 198–205.
100. Greeley C, Schroeder S, Silverberg SG. Microglandular hyperplasia of the cervix: a true "pill" lesion? *International Journal of Gynecological Pathology,* 1995, 14: 50–54.
101. Young RH, Scully RE. Atypical forms of microglandular hyperplasia of the cervix simulating carcinoma. A report of five cases and review of the literature. *American Journal of Surgical Pathology,* 1989, 13: 50–56.
102. Jacques SM, Qureshi F, Lawrence WD. Surface epithelial changes in endometrial adenocarcinoma: diagnostic pitfalls in curettage specimens. *International Journal of Gynecological Pathology,* 1995, 14: 191–197.
103. Jones MA, Young RH. Atypical oxyphilic metaplasia of the endocervical epithelium: a report of six cases. *International Journal of Gynecological Pathology,* 1997, 16: 99–102.
104. Seidman JD, Tavassoli FA. Mesonephric hyperplasia of the uterine cervix: a clinicopathologic study of 51 cases. *International Journal of Gynecological Pathology,* 1995, 14: 293–299.
105. Nucci MR, Young RH. Arias–Stella reaction of the endocervix: a report of 18 cases with emphasis on its varied histology and differential diagnosis. *American Journal of Surgical Pathology,* 2004, 28: 608–612.
106. Jones MA, Young RH. Endocervical type A (noncystic) tunnel clusters with cytologic atypia. A report of 14 cases. *American Journal of Surgical Pathology,* 1996, 20: 1312–1318.
107. Nucci MR, Ferry JA, Young RH. Ectopic prostatic tissue in the uterine cervix: a report of four cases and review of ectopic prostatic tissue. *American Journal of Surgical Pathology,* 2000, 24: 1224–1230.
108. McCluggage WG, Ganesan R, Hirschowitz L, et al. Ectopic prostatic tissue in the uterine cervix and vagina: report of a series with a detailed immunohistochemical analysis. *American Journal of Surgical Pathology,* 2006, 30: 209–215.
109. Nucci MR, Clement PB, Young RH. Lobular endocervical glandular hyperplasia, not otherwise specified: a clinicopathologic analysis of thirteen cases of a distinctive pseudoneoplastic lesion and comparison with fourteen cases of adenoma malignum. *American Journal of Surgical Pathology,* 1999, 23: 886–891.
110. Jones MA, Young RH, Scully RE. Diffuse laminar endocervical glandular hyperplasia. A benign lesion often confused with adenoma malignum (minimal deviation adenocarcinoma). *American Journal of Surgical Pathology,* 1991, 15: 1123–1129.
111. Clement PB, Young RH. Florid cystic endosalpingiosis with tumour-like manifestations: a report of four cases including the first reported cases of transmural endosalpingiosis of the uterus. *American Journal of Surgical Pathology,* 1999, 23: 166–175.
112. Young RH, Clement PB. Endocervicosis involving the uterine cervix: a report of four cases of a benign process that may be confused with deeply invasive endocervical adenocarcinoma. *International Journal of Gynecological Pathology,* 2000, 19: 322–328.
113. Gilks CB, Young RH, Clement PB, et al. Adenomyomas of the uterine cervix of endocervical type: a report of ten cases of a benign cervical tumour that may be confused with adenoma malignum. *Modern Pathology,* 1996. 9: 220–224. Erratum in: *Modern Pathology,* 1996, 9: 803.
114. Daya D, Young RH. Florid deep glands of the uterine cervix. Another mimic of adenoma malignum. *American Journal of Clinical Pathology,* 1995, 103: 614–617.
115. Clement PB, Young RH. Deep Nabothian cysts of the uterine cervix. A possible source of confusion with minimal-deviation adenocarcinoma (adenoma malignum). *International Journal of Gynecological Pathology,* 1989, 8: 340–348.
116. McGalie CE, McBride HA, McCluggage WG. Cytomegalovirus infection of the cervix: morphological observations in five cases of a possibly under-recognised condition. *Journal of Clinical Pathology,* 2004, 57: 691–694.
117. Scott M, Lyness RW, McCluggage WG. Atypical reactive proliferation of endocervix: a common lesion associated with endometrial carcinoma and likely related to prior endometrial sampling. *Modern Pathology,* 2006, 19: 470–474.
118. Gilks CB, Young RH, Gersell DJ, et al. Large cell neuroendocrine carcinoma of the uterine cervix: a clinicopathologic study of 12 cases. *American Journal of Surgical Pathology,* 1997, 21: 905–914.
119. Albores-Saavedra J, Martinez-Benitez B, Luevano E. Small cell carcinomas and large cell neuroendocrine carcinomas of the endometrium and cervix: polypoid tumours and those arising in polyps may have a favourable prognosis. *International Journal of Gynecological Pathology,* 2008, 27: 333–339.
120. Sato Y, Shimamoto T, Amada S, et al. Large cell neuroendocrine carcinoma of the uterine cervix: a clinicopathological study of six cases. *International Journal of Gynecological Pathology,* 2003, 22: 226–230.
121. Conner MG, Richter H, Moran CA, et al. Small cell carcinoma of the cervix: a clinicopathologic and immunohistochemical study of 23 cases. *Annals of Diagnostic Pathology,* 2002, 6: 345–348.

122. Grayson W, Rhemtula HA, Taylor LF, et al. Detection of human papillomavirus in large cell neuroendocrine carcinoma of the uterine cervix: a study of 12 cases. *Journal of Clinical Pathology,* 2002, 55: 108–114.
123. Ishida GM, Kato N, Hayasaka T, et al. Small cell neuroendocrine carcinomas of the uterine cervix: a histological, immunohistochemical and molecular genetic study. *International Journal of Gynecological Pathology,* 2004, 23: 366–372.
124. Stoler MH, Mills SE, Gersell DJ, et al. Small-cell neuroendocrine carcinoma of the cervix. A human papillomavirus type 18-associated cancer. *American Journal of Surgical Pathology,* 1991, 15: 28–32.
125. Travis WD, Linnoila RI, Tsokos MG, et al. Neuroendocrine tumours of the lung with proposed criteria for large-cell neuroendocrine carcinoma. An ultrastructural, immunohistochemical and flow cytometric study of 35 cases. *American Journal of Surgical Pathology,* 1991, 15: 529–553.
126. McCluggage WG, Kennedy K, Busam KJ. An immunohistochemical study of cervical neuroendocrine carcinomas: Neoplasms that are commonly TTF1 positive and which may express CK20 and P63. *American Journal of Surgical Pathology,* 2010, 34: 525–532.
127. Wang TY, Chen BF, Yang YC, et al. Histologic and immunophenotypic classification of cervical carcinomas by expression of the p53 homologue p63: a study of 250 cases. *Human Pathology,* 2001, 32: 479–486.
128. Farley JH, Hickey KW, Carlson JW, et al. Adenosquamous histology predicts a poor outcome for patients with advanced-stage, but not early-stage, cervical carcinoma. *Cancer,* 2003, 97: 2196–2202.
129. Samlal RA, Ten Kate FJ, Hart AA, et al. Do mucin-secreting squamous cell carcinomas of the uterine cervix metastasize more frequently to pelvic lymph nodes? A case–control study. *International Journal of Gynecologic Pathology,* 1988, 17: 201–204.
130. Littman P, Clement PB, Henriksen B, et al. Glassy cell carcinoma of the cervix. *Cancer,* 1976, 37: 2238–2346.
131. Kato N, Katayama Y, Kaimori M, et al. Glassy cell carcinoma of the uterine cervix: histochemical, immunohistochemical, and molecular genetic observations. *International Journal of Gynecologic Pathology,* 2002, 21: 134–140.
132. Ferry JA, Scully RE. "Adenoid cystic" carcinoma and adenoid basal carcinoma of the uterine cervix. A study of 28 cases. *American Journal of Surgical Pathology,* 1988, 12: 134–144.
133. Grayson W, Taylor LF, Cooper K. Adenoid cystic and adenoid basal carcinoma of the uterine cervix: comparative morphologic, mucin, and immunohistochemical profile of two rare neoplasms of putative 'reserve cell' origin. *American Journal of Surgical Pathology,* 1999, 23(4): 448–458.
134. Albores-Saavedra J, Manivel C, Mora A, et al. The solid variant of adenoid cystic carcinoma of the cervix. *International Journal of Gynecologic Pathology,* 1992, 11: 2–10.
135. Brainard JA, Hart WR. Adenoid basal epitheliomas of the uterine cervix: a reevaluation of distinctive cervical basaloid lesions currently classified as adenoid basal carcinoma and adenoid basal hyperplasia. *American Journal of Surgical Pathology,* 1998, 22: 965–975.
136. Parwani AV, Smith Sehdev AE, Kurman RJ, et al. Cervical adenoid basal tumors comprised of adenoid basal epithelioma associated with various types of invasive carcinoma: clinicopathologic features, human papillomavirus DNA detection, and P16 expression. *Human Pathology,* 2005, 36: 82–90.
137. Clement PB, Zubovits JT, Young RH, et al. Malignant mullerian mixed tumours of the uterine cervix: a report of nine cases of a neoplasm with morphology often different from its counterpart in the corpus. *International Journal of Gynecological Pathology,* 1998, 17: 211–222.
138. McCluggage WG. Mullerian adenosarcoma of the female genital tract. *Advances in Anatomic Pathology,* 2010, 17: 122–129.
139. Nielsen GP, Oliva E, Young RH, et al. Alveolar soft-part sarcoma of the female genital tract. *International Journal of Gynecological Pathology,* 1995, 24: 131–135.
140. Rabban JT, Zaloudek CJ, Shekitka KM, et al. Inflammatory myofibroblastic tumour of the uterus: a clinicopathologic study of 6 cases emphasizing distinction from aggressive mesenchymal tumours. *American Journal of Surgical Pathology,* 2005, 29: 1348–55.
141. Kabbani W, Deavers MT, Malpica A, et al. Uterine tumour resembling ovarian sex-cord tumour: report of a case mimicking cervical adenocarcinoma. *International Journal of Gynecological Pathology,* 2003, 22: 297–302.
142. Daya D, Scully RE. Sarcoma botryoides of the uterine cervix in young women: a clinicopathological analysis of 13 cases. *Gynecologic Oncology,* 1998, 29: 290–304.
143. Laskin WB, Fetsch JF, Tavassoli FA. Superficial cervicovaginal myofibroblastoma: fourteen cases of a distinctive mesenchymal tumour arising from the specialized subepithelial stroma of the lower female genital tract. *Human Pathology,* 2001, 32: 715–725.
144. Ganesan R, McCluggage WG, Hirschowitz L, et al. Superficial myofibroblastoma of the lower female genital tract: report of a series including tumours with a vulval location. *Histopathology,* 2005, 46: 137–143.

145. Ferry JA, Young RH. Malignant lymphoma of the genitourinary tract. *Current Diagnostic Pathology,* 1997, 4: 145–169.
146. Kosari F, Daneshbod Y, Parwaresch R, et al. Lymphomas of the female genital tract. A study of 186 cases and review of the literature. *American Journal of Surgical Pathology,* 2005, 29: 1512–1520.
147. Geyer JT, Ferry JA, Harris NL, et al. Florid reactive lymphoid hyperplasia of the lower female genital tract (lymphoma-like lesion): a benign condition that frequently harbors clonal immunoglobulin heavy chain gene rearrangements. *American Journal of Surgical Pathology,* 2010, 34: 161–168.
148. Patel DS, Bhagavan BS. Blue nevus of the uterine cervix. *Human Pathology,* 1985, 16: 79–86.
149. Chan KC, Butz WR, Hapke MR. Primary malignant melanoma of the uterine cervix: case report with world literature review. *International Journal of Gynecological Pathology,* 1999, 18: 265–273.
150. McCluggage WG, Hurrell DP, Kennedy K. Metastatic carcinomas in the cervix mimicking primary cervical adenocarcinoma and adenocarcinoma in situ: report of a series of cases. *American Journal of Surgical Pathology,* 2010, 34: 735–741.
151. *HPV Triage and Test of Cure: Implementation Guidance* (NHSCSP Good Practice Guide No 3). Sheffield, NHS Cancer Screening Programmes, 2011.
152. Stoler MH, Vichnin MD, Ferenczy A, et al. FUTURE I, II and III Investigators. The accuracy of colposcopic biopsy: analyses from the placebo arm of the Gardasil clinical trials. *International Journal of Cancer,* 2011, 128: 1354–1362.
153. Ostör AG. Natural history of cervical intraepithelial neoplasia: a critical review. *International Journal of Gynecological Pathology,* 1993, 12: 186–192.
154. Martin-Hirsch PP, Paraskevaidis E, Bryant A, et al. Surgery for cervical intraepithelial neoplasia. *Cochrane Database of Systematic Reviews,* 2010, 6: CD001421.
155. Abu-Rustum NR, Sonoda Y, Black D, et al. Fertility-sparing radical abdominal trachelectomy for cervical carcinoma: technique and review of the literature. *Gynecological Oncology,* 2006, 103: 807–813.
156. Reid WA, Al-Nafussi AI, Rebello G, et al. Effect of using templates on the information included in histopathology reports on specimens of uterine cervix taken by loop excision of the transformation zone. *Journal of Clinical Pathology,* 1999, 52: 825–828.
157. Soutter WP, Sasieni P, Panoskaltsis T. Long-term risk of invasive cervical cancer after treatment of squamous cervical intraepithelial neoplasia. *International Journal of Cancer,* 2006, 118: 2048–2055.
158. Flannelly G, Bolger B, Fawzi H, et al. Follow up after LLETZ: could schedules be modified according to risk of recurrence? *BJOG*, 2001, 108: 1025–1030.
159. Palmer JE, Wales K, Ellis K, et al. The multidisciplinary colposcopy meeting: recommendations for future service provision and an analysis of clinical decision making. *BJOG*, 2010, 117: 1060–1066.
160. Moss EL, Pearmain P, Askew S, et al. Implementing the national invasive cervical cancer audit: a local perspective. *BJOG*, 2010, 117: 1411–1416.
161. Arbyn M, Sasieni P, Meijer CJM, et al. Clinical applications of HPV testing: a summary of meta-analyses. *Vaccine*, 2006, 24(Suppl 3): 78–89.
162. Cuzick J, Arbyn M, Sankaranarayanan R, et al. Overview of human papillomavirus-based and other novel options for cervical cancer screening in developed and developing countries. *Vaccine*, 2008, 26(Suppl): 29–41.
163. Kelly RS, Patnick J, Kitchener HC, et al. NHSCSP HPV Special Interest Group. HPV testing as a triage for borderline or mild dyskaryosis on cervical cytology: results from the Sentinel Sites study. *British Journal of Cancer,* 2011, 105 983–988.
164. Legood R, Gray A, Wolstenholme J, et al. Lifetime effects, costs, and cost effectiveness of testing for human papillomavirus to manage low-grade cytological abnormalities: results of the NHS pilot studies. *BMJ,* 2006, 332(7533): 79–85.
165. Moss S, Gray A, Legood R, et al. Effect of testing for human papillomavirus as a triage during screening for cervical cancer: observational before and after study. *BMJ,* 2006, 332(7533): 83–85.
166. *Evaluation of Sentinel Sites for HPV Triage and Test and Cure.* Sheffield, NHS Cancer Screening Programmes, 2011. Available at: www.cancerscreening.nhs.uk/cervical/sentinelfinalreport.pdf. Accessed 5 March 2012.
167. *Improving Outcomes: A Strategy for Cancer*. London, Department of Health, 2011.
168. Kitchener HC, Walker PG, Nelson L et al. HPV testing as an adjunct to cytology in the follow up of women treated for cervical intraepithelial neoplasia. *BJOG,* 2008, 115: 1001–1007.
169. Smith JHF. The future of cervical screening in the UK. *Diagnostic Histopathology,* 2009, 15: 330–334.
170. *Recommended Code of Practice for Laboratories Participating in the UK Cervical Screening Programmes.* London, British Society for Clinical Cytology, 2010. Available at: www.clinicalcytology.co.uk/resources/cop/BSCC_COP_2010.pdf. Accessed 5 March 2012.

171. *Achievable standards, Benchmarks for reporting and Criteria for evaluating cervical cytopathology* (NHSCSP Publication No 1). Second edition. Sheffield, NHS Cancer Screening Programmes, 2000. Available at: www.cancerscreening.nhs.uk/cervical/publications/cc-02.html. Accessed 5 March 2012.
172. *Quality Assurance Guidelines for the Cervical Screening Programme* (NHSCSP Publication No 3). Sheffield, NHS Cancer Screening Programmes, 1996. Available at: www.cancerscreening.nhs.uk/cervical/publications/qa-02.html. Accessed 5 March 2012.
173. *Key Performance Indicators in Pathology: Recommendations from The Royal College of Pathologists.* London, Royal College of Pathologists, May 2011. Available at: www.rcpath.org/NR/rdonlyres/A9568A98–80B8–4A28-B06E-AB9A8D769953/0/key_performance_indicators_in_pathology_3_2.pdf. Accessed 5 March 2012.
174. *Audit of Invasive Cervical Cancers* (NHSCSP Publication No 28). Sheffield, NHS Cancer Screening Programmes, 2006. Available at: www.cancerscreening.nhs.uk/cervical/publications/nhscsp28.html. Accessed 5 March 2012.
175. O'Sullivan JP, A'Hern RP, Chapman PA et al*.* A case–control study of true positive versus false negative cervical smears in women with cervical intraepithelial neoplasia (CIN) III. *Cytopathology*, 1998, 9: 155–161.
176. O'Sullivan JP, Ismail SM, Barnes WS, et al*.* Inter- and intra-observer variation in the reporting of cervical smears: specialist cytopathologists versus histopathologists. *Cytopathology*, 1996, 7: 78–89.
177. Mitchell H, Medley G. Differences between Papanicolaou smears with correct and incorrect diagnoses. *Cytopathology*, 1995, 6: 368–375.
178. McCord ML, Stovall TG, Summitt RL Jr, et al*.* Discrepancy of cervical cytology and colposcopic biopsy: is cervical conization necessary? *Obstetrics and Gynaecology*, 1991, 77: 715–719.
179. Waddell CA. Glandular abnormalities: dilemmas in cytological prediction and clinical management. *Cytopathology*, 1997, 8: 27–30.
180. Valente PT, Schantz HD, Schultz M. Cytologic atypia associated with microglandular hyperplasia. *Diagnostic Cytopathology,* 1994, 10: 326–331.
181. Lee KR, Manna EA, St John T. Atypical endocervical glandular cells: accuracy of cytologic diagnosis. *Diagnostic Cytopathology,* 1995, 13: 202–208.
182. Palmer JE, Ellis K, Dudding N, et al. The multidisciplinary colposcopy meeting: recommendations for future service provision and an analysis of clinical decision making. *BJOG*, 2010, 117: 1060–1066.
183. *Manual for Cancer Services*. London, Department of Health, 2004.
184. *Expert Advisory Group on Cancer. A Policy Framework for Commissioning Cancer Services: A Report to the Chief Medical Officers of England and Wales* (The Calman–Hine Report). London, Department of Health, 1995.
185. Ruhstaller T, Roe H, Thurlimann B, et al*.* The multidisciplinary meeting: an indispensable aid to communication between different specialities. *European Journal of Cancer,* 2006, 42: 2459–2462.
186. *Guidance on Commissioning Cancer Services: Improving Outcomes in Gynaecological Cancers – The Manual*. London, Department of Health, 1999.
187. *Cancer Statistics Registrations: Registrations of Cancer Diagnosed in 2008, England.* Edition MB1 39. London, Office for National Statistics, 2010. Available at: www.ons.gov.uk/ons/rel/vsob1/cancer-statistics-registrations--england--series-mb1-/no--39--2008/index.html. Accessed 5 March 2012.
188. International Agency for Research on Cancer (IARC), World Health Organization, www.iarc.fr. Accessed 7 March 2011.
189. Union for International Cancer Control (UICC), www.uicc.org. Accessed 7 March 2011.
190. International Association of Cancer Registries (IACR), www.iacr.com.fr. Accessed 7 March 2011.
191. Gillis CR. *Review of Cancer Registration in England.* London, Kings Fund, 2000.
192. *Core Contract for Purchasing Cancer Registration*, EL(96)7. London, NHS Executive, 1996.
193. United Kingdom Association of Cancer Registries (UKACR), www.ukacr.org. Accessed 23 February 2011.
194. *Healthy Lives, Healthy People: Our Strategy for Public Health in England.* White Paper. London, Department of Health, 2010.
195. *Healthy Lives, Healthy People: Update and Way Forward.* HM Government policy statement. London, Department of Health, 2011.
196. *Transforming Public Health Bulletin* (Public Health Bulletin Issue 1). London, Department of Health, 2011. Available at: www.dh.gov.uk/en/Publicationsandstatistics/Bulletins/PublicHealthbulletin/index.htm. Accessed 20 July 2011.
197. *Cancer Registration Principles and Methods*. IARC Scientific Publication No. 95. Lyon, IARC, 1991.
198. European Network of Cancer Registries (ENCR), www.encr.com.fr. Accessed 7 March 2011.
199. Radiotherapy Dataset (RTDS), www.canceruk.net/rtservices/rtds/. Accessed 8 March 2011.
200. National Cancer Dataset. NHS Information Centre, www.ic.nhs.uk/services/datasets/dataset-list/cancer. Accessed 21 February 2011.

201. *The Standard NHS Contracts for Acute Hospital, Mental Health, Community and Ambulance Services and Supporting Guidance*. London, Department of Health, 2010.
202. National Cancer Data Repository, www.ncin.org.uk/collecting_and_using_data/national_cancer_data_repository/default.aspx. Accessed 18 March 2011.
203. HM Government. The National Health Service Act 2006, Chapter 41, Part 13, Section 251, Control of Patient Information.
204. HM Government. Health and Social Care Act 2001, Chapter 15, Part 5, Section 60, Control of Patient Information..
205. HM Government. Statutory Instrument 2002, No. 1438. The Health Service (Control of Patient Information) Regulations 2002.
206. National Information Governance Board for Health and Social Care (NIGB); Ethics and Confidentiality Committee (ECC), www.nigb.nhs.uk/ecc. Accessed 8 March 2011.
207. HM Government. Data Protection Act 1998, Chapter 29.
208. NHS Cervical Screening Programme – quality assurance, www.cancerscreening.nhs.uk/cervical/quality-assurance.html. Accessed 3 March 2011.
209. NHS Information Centre. National Clinical Audi Support Programme (NCASP) – Cancer, www.ic.nhs.uk/services/national-clinical-audit-support-programme-ncasp/cancer. Accessed 28 February 2011.
210. *The Cancer Reform Strategy*. Policy Document. London, Department of Health, 2007.
211. National Cancer Intelligence Network (NCIN), www.ncin.org.uk. Accessed 28 February 2011.
212. National Cancer Intelligence Network (NCIN) – site-specific work on gynaecological cancers, www.ncin.org.uk/cancer_type_and_topic_specific_work/cancer_type_specific_work/gynae.aspx. Accessed 1 March 2011.
213. *Delivering the Cancer Reform Strategy*. Report by the Comptroller and Auditor General, HC 568 Session 2010–2011. London, National Audit Office, 2010.
214. *The Operating Framework for the NHS in England 2011/12.* London, Department of Health, 2010.
215. *Delivering the Cancer Reform Strategy.* 24th Report. London: HM Government Public Accounts Committee, March 2011.
216. Heatley MK. A comparison of three methods of orienting cervical punch biopsies. *Journal of Clinical Pathology,* 1999, 52: 149–150.
217. Byrom J, Douce G, Jones PW et al. Should punch biopsies be used when high-grade disease is suspected at initial colposcopic assessment? *International Journal of Gynecological Cancer*, 2006, 16: 253–256.
218. Montz FJHC, Thompson LD. Large-loop excision of the transformation zone: effect on the pathological interpretation of resection margins. *Obstetrics and Gynecology,* 1993, 81: 976–982.
219. *Histopathology Reporting in Cervical Screening* (NHSCSP Publication No 10). Sheffield, NHS Cancer Screening Programmes, 1999.
220. Scurry JPK, Wells M. Gross examination of uterine specimens (ACP Broadsheet No 138). *Journal of Clinical Pathology,* 1995, 48: 323–324.
221. Heatley MK. Distribution of cervical intraepithelial neoplasia: are hysterectomy specimens sampled appropriately? *Journal of Clinical Pathology,* 1995, 48: 323–324
222. Kalof AN, Danmanesh F, Longacre TA et al. *Cancer Protocols and Checklists: Uterine Cervix*. Northfield, IL, College of American Pathologists, 2011.
223. *Histopathology of the Uterine Cervix – Digital Atlas*. WHO IARC Screening Group, 2011. Available at: http://screening.iarc.fr/atlashisto.php?lang=1. Accessed 5 March 2012.
224. Pickel H, Haas J, Lahousen M. Prognostic factors in cervical cancer. *European Journal of Obstetrics and Gynecology and Reproductive Biology,* 1997, 71: 209–213
225. Maiman MA, Fruchter RG, DiMaio TM et al. Superficially invasive squamous cell carcinoma of the cervix. *Obstetrics and Gynecology,* 1988, 72: 399–403.
226. Scurry J, Patel K, Wells MG. Gross examination of uterine specimens, ACP Broadsheet No 138. *Journal of Clinical Pathology,* 1993, 46: 388–393.

NHS Cancer Screening Programmes
Fulwood House
Old Fulwood Road
Sheffield
S10 3TH

September 2012