Educational case

Deciduosis

History

- 29 year old
- 36 weeks pregnant
- Lumpy areas noted on examination of cervix - ? cancer

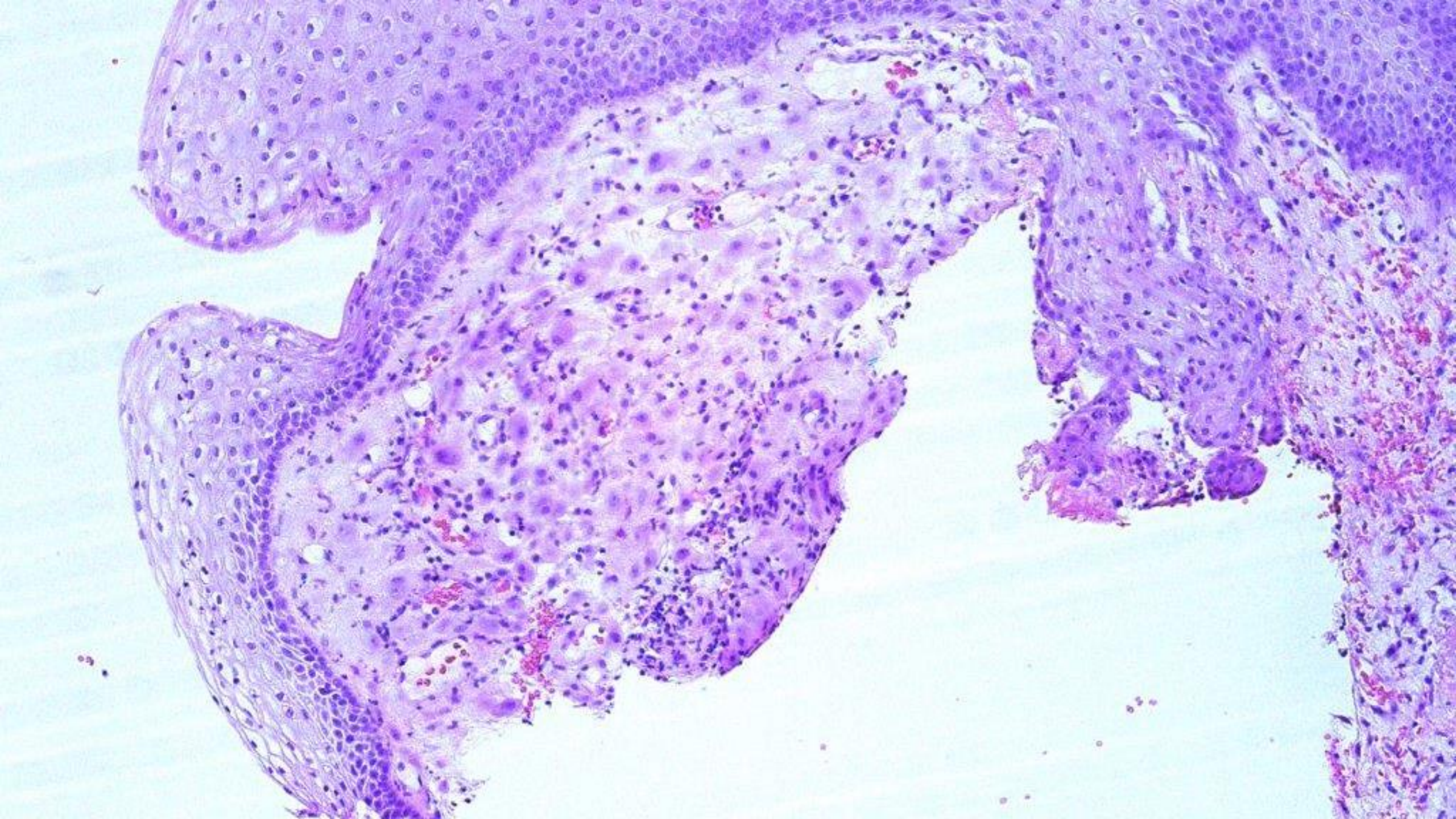



Description

- Sub-surface area of cells with generous eosinophilic cytoplasm
- Many cells have indistinct cell boundaries
- Moderate nuclear variation, but no mitotic activity or abnormal chromatin
- No stromal reaction or necrosis
- Normal squamous and glandular epithelium adjacent to area

Differential diagnosis

- Invasive squamous cell carcinoma – not favoured as
  - Dissociated cells
  - No atypia
  - No mitotic activity
  - No CIN3
- Deciduosis – favoured diagnosis
  - Description in keeping with this diagnosis
  - History consistent with appearance