Educational case

CIN3 involving gland clefts

Or

Invasive carcinoma with a CIN3-like pattern

History

- 27 year old woman
- Borderline smear and was HR HPV positive in 2018.
- In October 2019 presented with irregular bleeding, no biopsies.
- In 2020 presented with a ‘severe smear’
- Colposcopic opinion CIN2/3.
- LLETZ biopsy done and measured 20 x 15 x 10mm.
- Sampled in 4 slices amounting to 5mm thickness per slice (thicker than the recommended 2-3mm per slice)

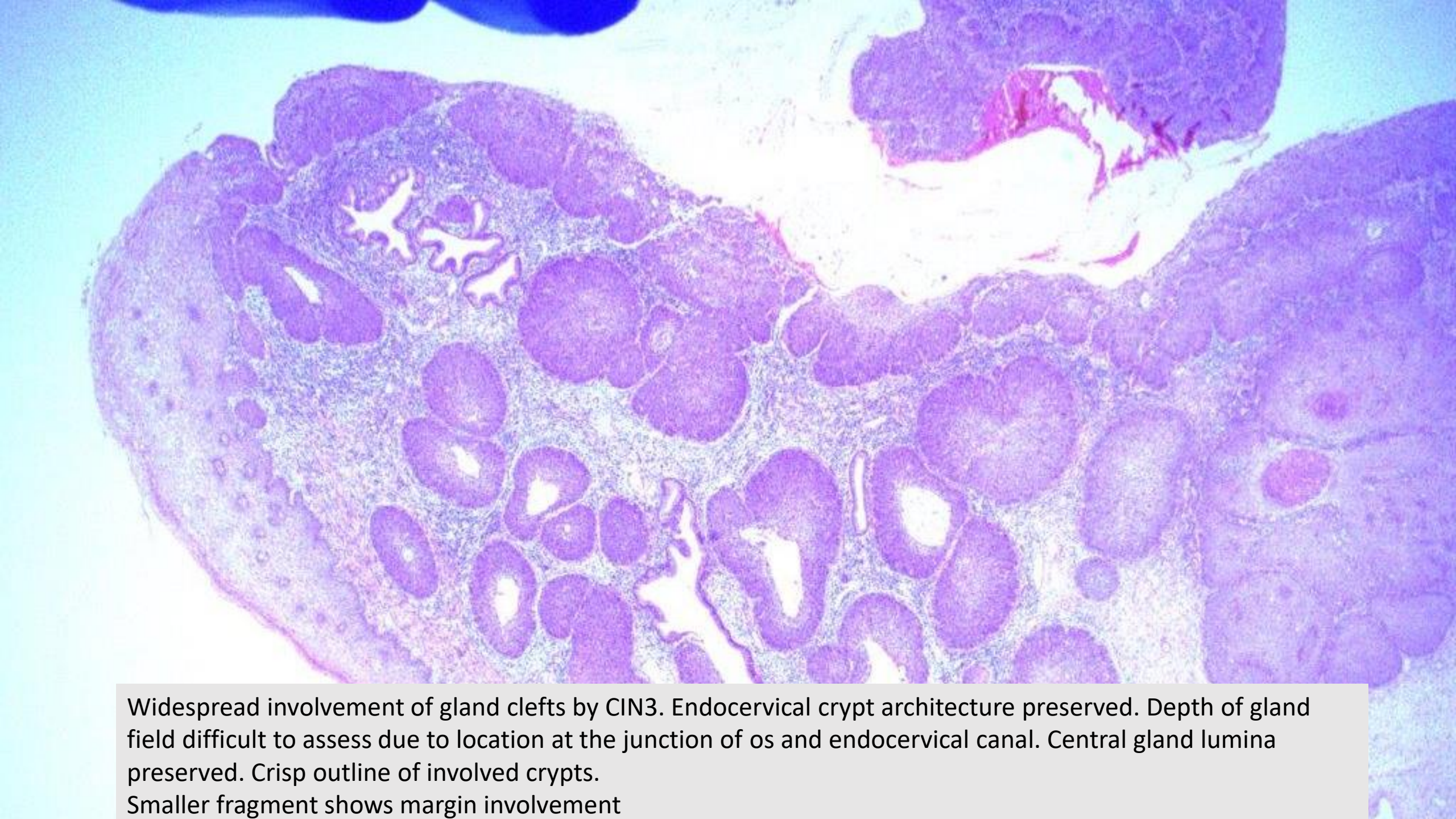

Widespread involvement of gland clefts by CIN3. Endocervical crypt architecture preserved. Depth of gland field difficult to assess due to location at the junction of os and endocervical canal. Central gland lumina preserved. Crisp outline of involved crypts.
Smaller fragment shows margin involvement

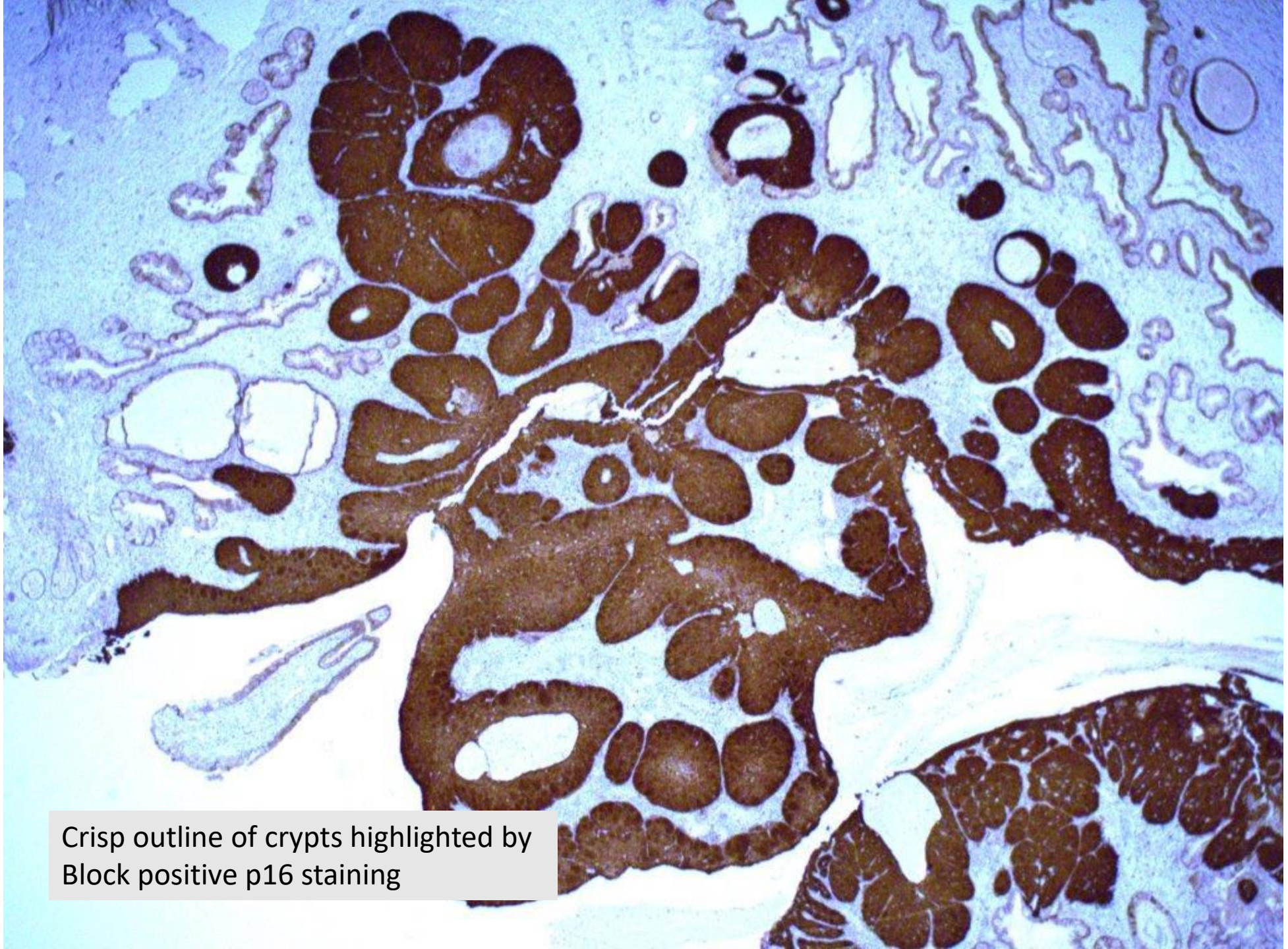

Crisp outline of crypts highlighted by Block positive p16 staining

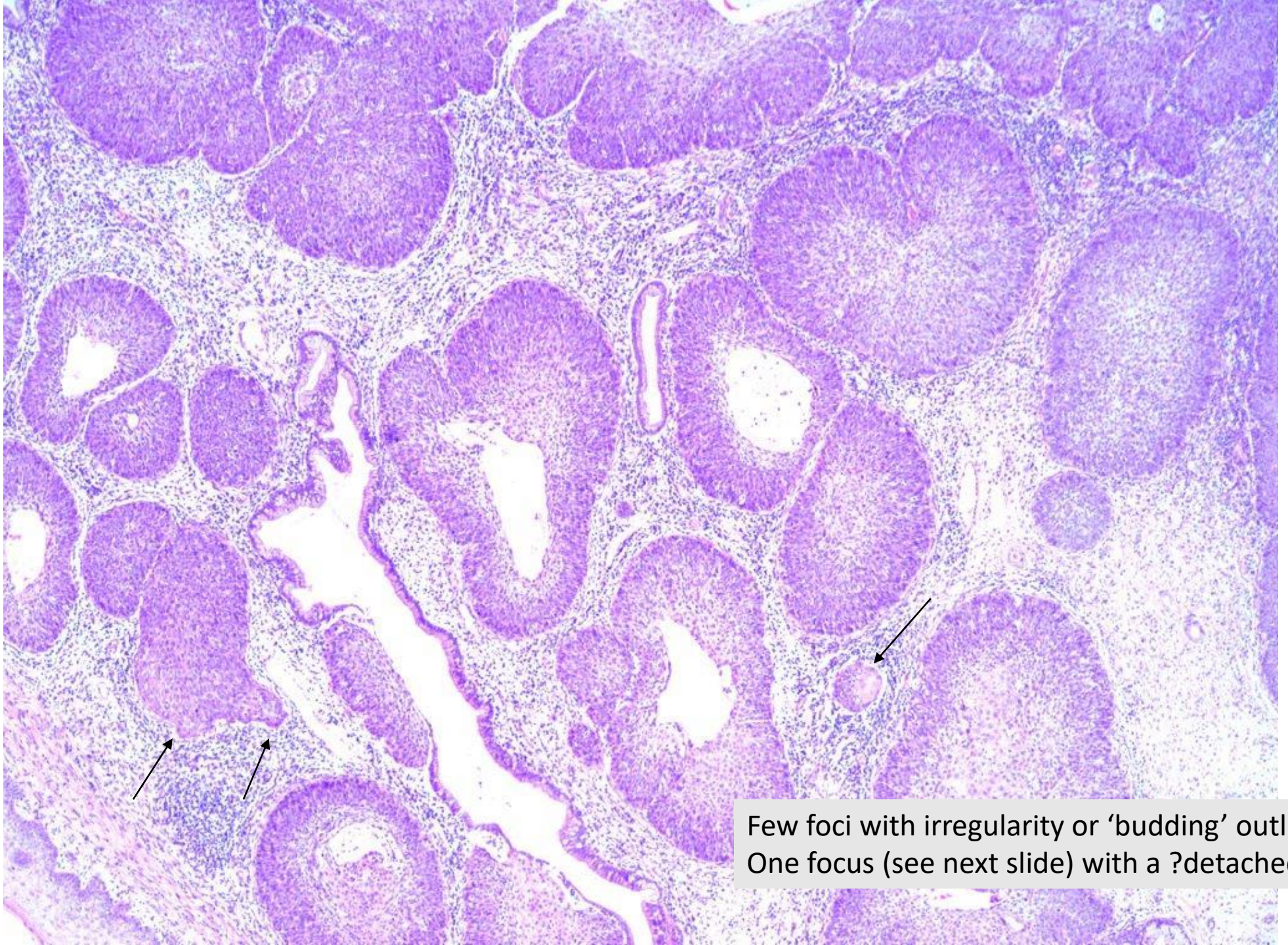

Few foci with irregularity or ‘budding’ outlines
One focus (see next slide) with a ?detached bud

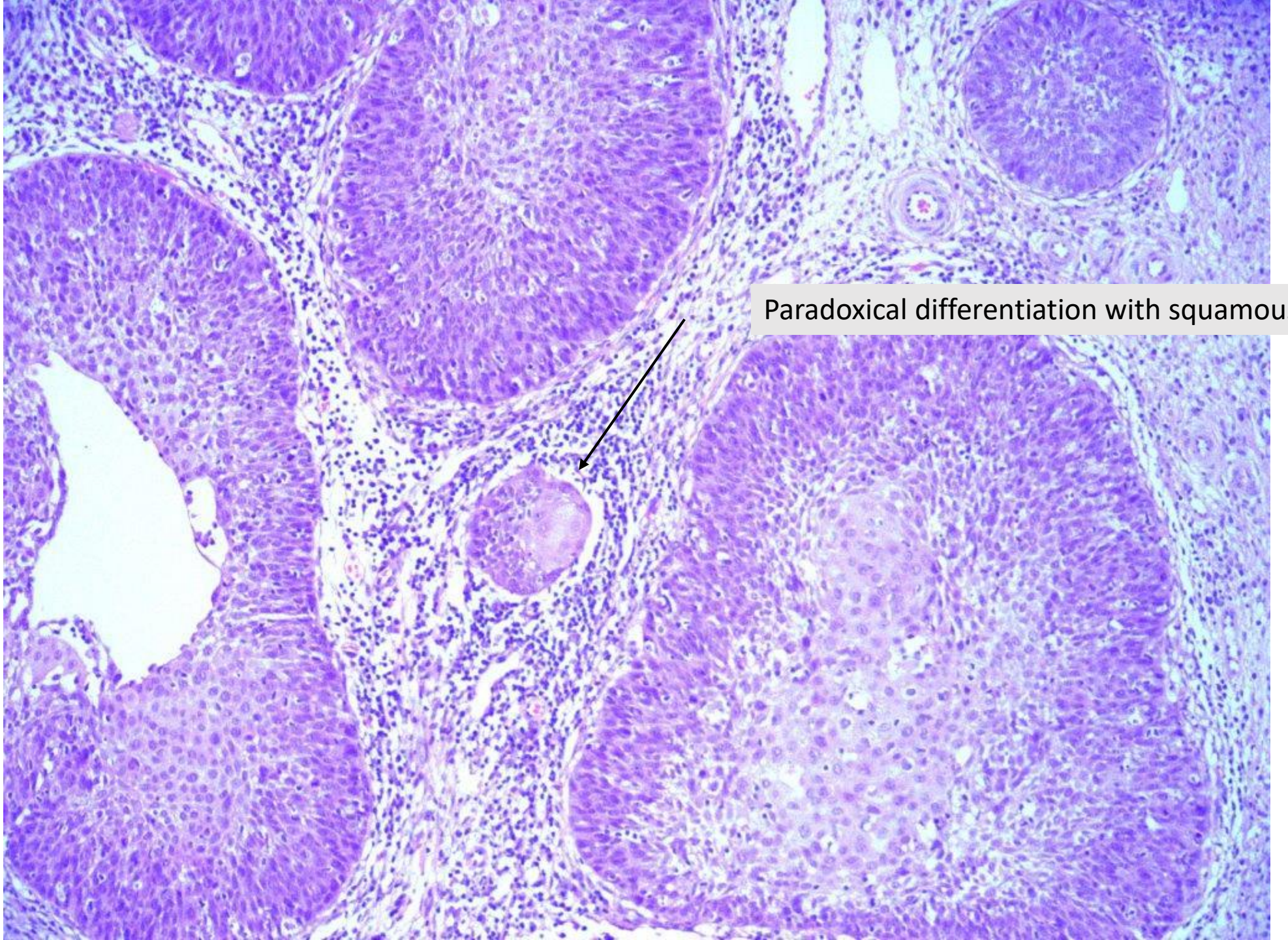
Paradoxical differentiation with squamous whorl

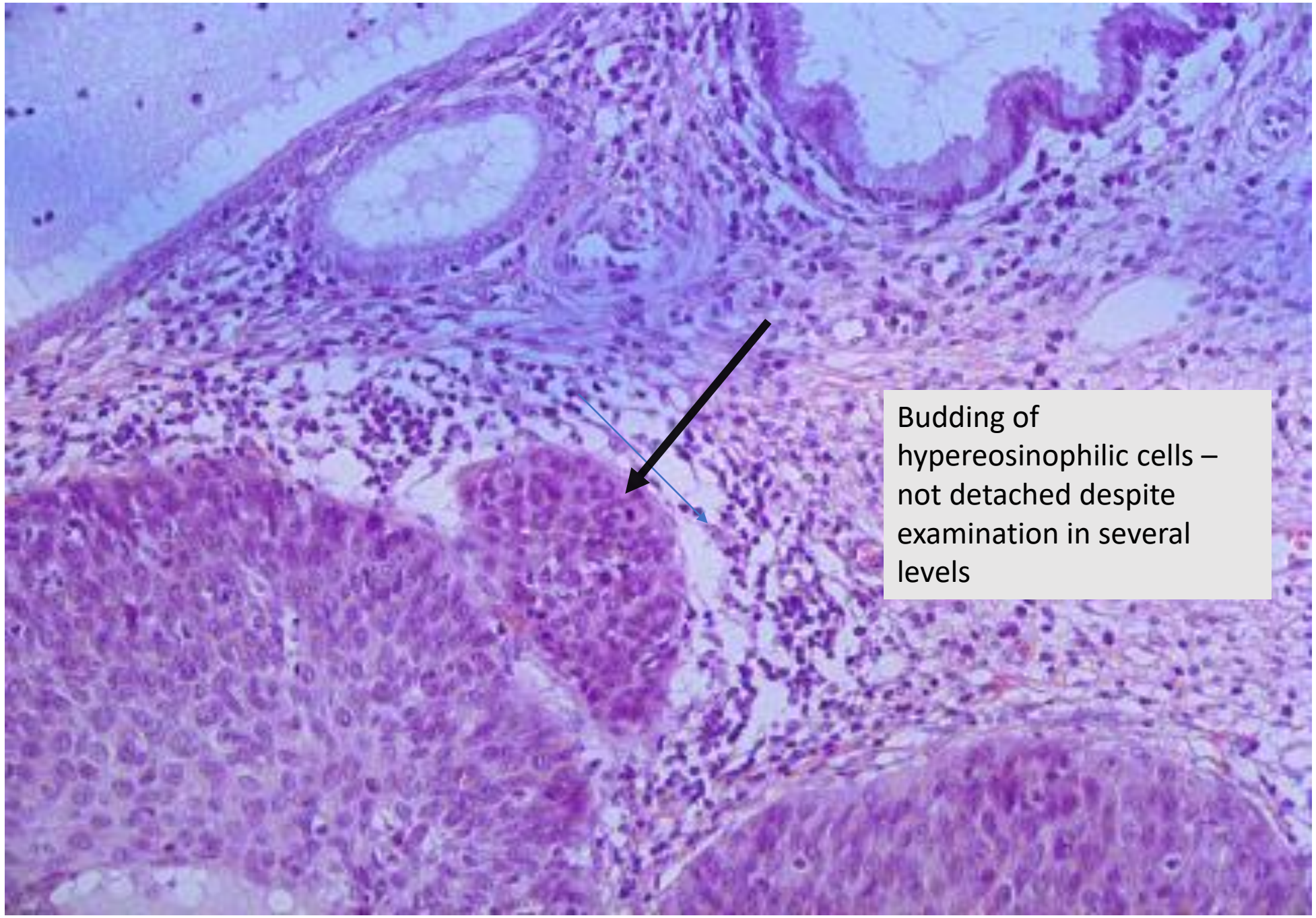
Budding of hypereosinophilic cells – not detached despite examination in several levels

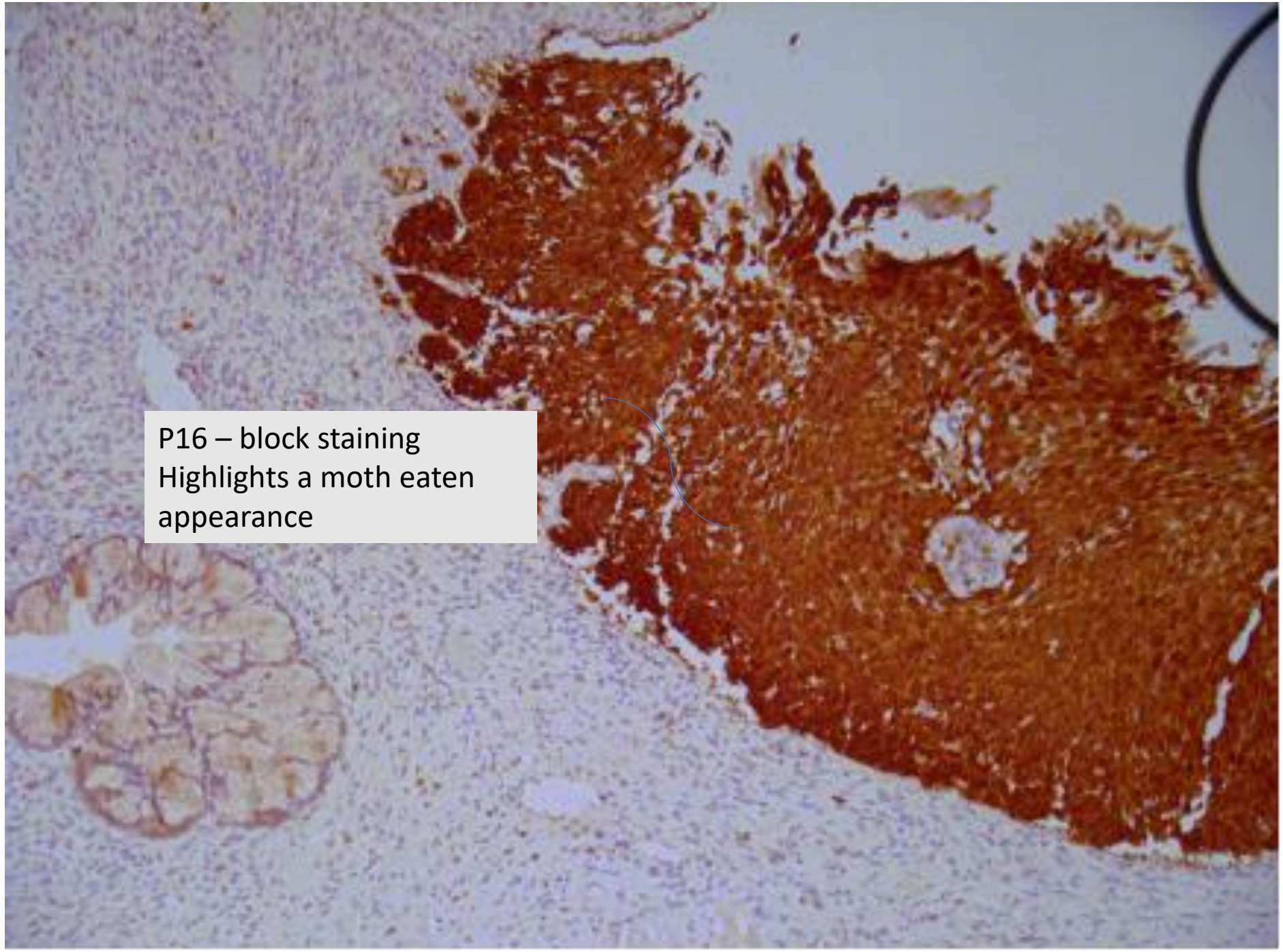
P16 – block staining
Highlights a moth eaten
appearance

Differential diagnosis

- Invasive carcinoma with CIN3-like pattern – not favoured as
  - Crypt architecture preserved
  - Involved crypts confined to the superficial part of the cervix
- CIN3 involving crypts with foci of intraepithelial differentiation – not favoured as
  - Difficult to assess small rounded groups of cells that are seen in relation to the base of the surface and glandular epithelium. Some of these groups are surrounded by inflamed stroma and a basal peripheral palisade is not clearly seen. However, there are no detached single cells or angulate buds that are typically seen with invasion.

In summary.....

- The features in this LLETZ specimen are difficult to evaluate. There is extensive gland cleft involvement and cross-cutting making assessment difficult. It is best that this case is discussed at colposcopy/oncology MDT and consideration is given to a repeat loop/LLETZ examination. If the second specimen shows no evidence of definite invasive disease, the present specimen is best regarded as having a stage IA1 squamous cell carcinoma of the cervix (single focus, less than 1mm in depth from adjacent basement membrane - slide 6) and followed-up appropriately.