Educational case

CGIN

Or

Invasive carcinoma

History

- 39-year-old woman with a history of severe ‘smear’
- Colp appearance high grade
- Partly disrupted LLETZ specimen measuring 18 x 15 x 8mm from this
- Completely sampled in parallel slices

The lobular configuration in this focus is lost and replaced by a complex proliferation of glands which have a back-to-back configuration.

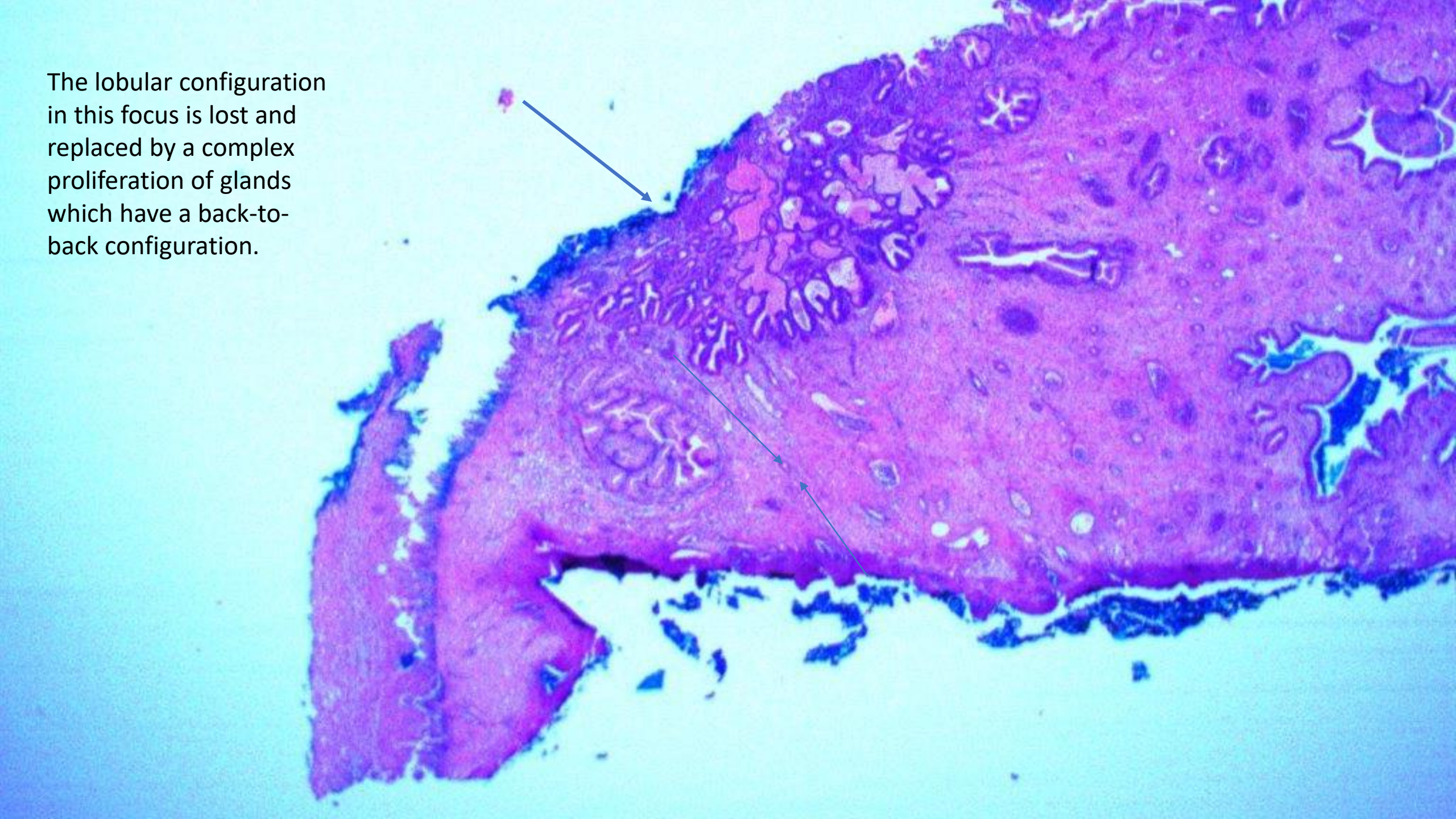

There is no evidence of destructive stromal invasion
or lymphovascular invasion.

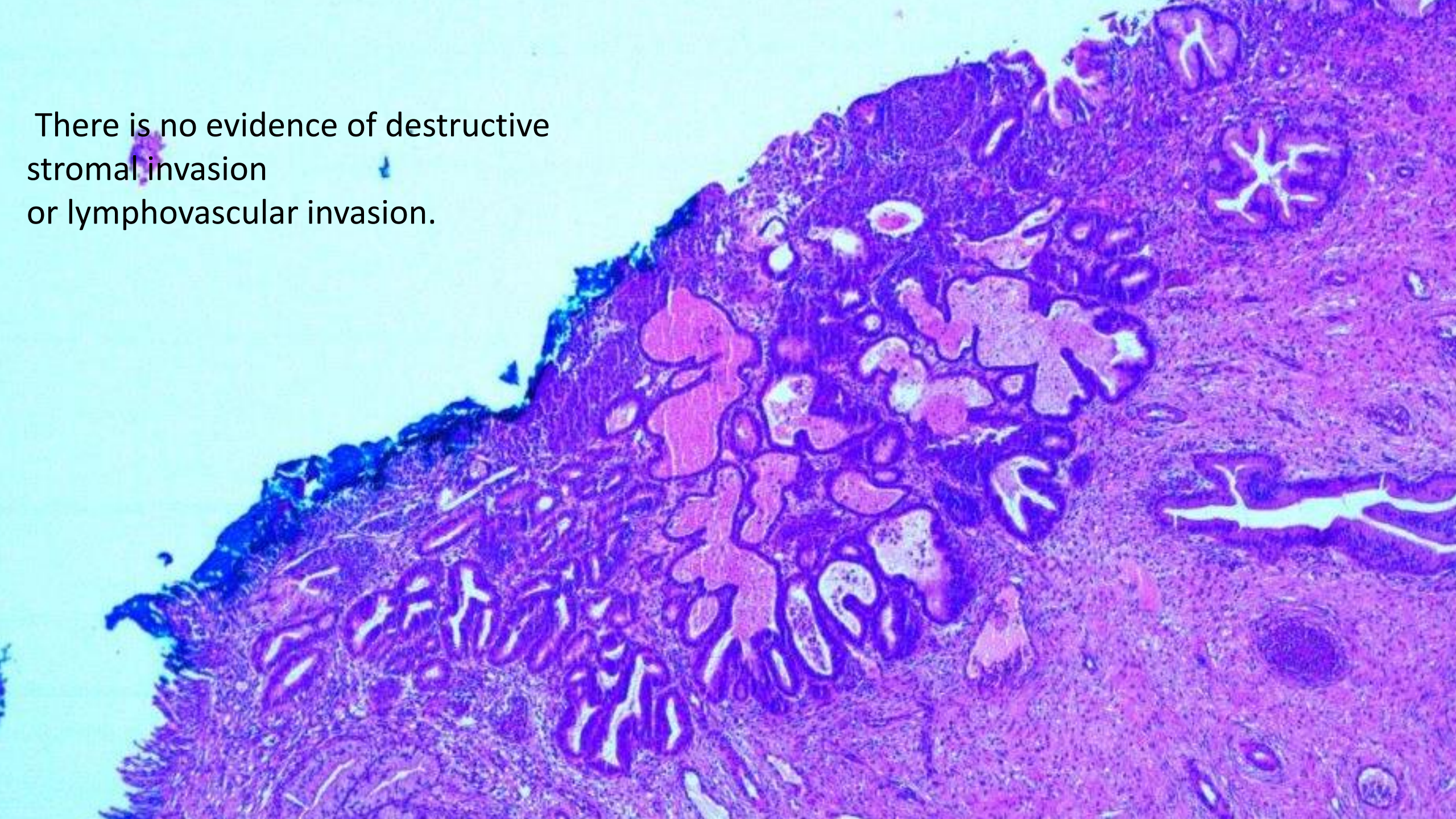

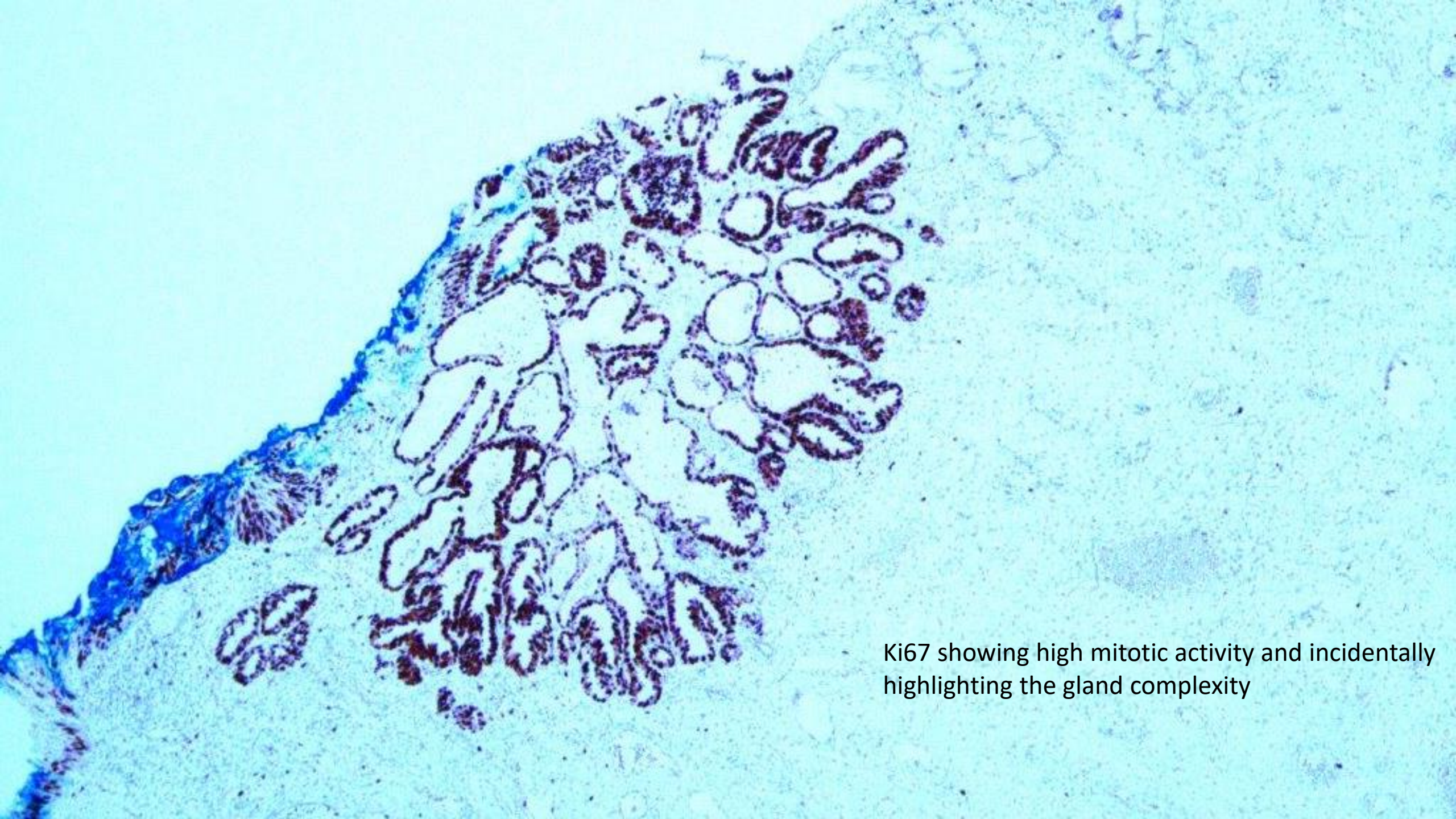

Ki67 showing high mitotic activity and incidentally highlighting the gland complexity

Differential diagnosis

- CGIN – not favoured as
  - Crypt architecture lost
  - Closely packed glands of varying shapes and sizes
  - Several dilated crypts – some containing acute inflammatory cells
- Invasive adenocarcinoma – Silva Pattern A
  - Degree of gland crowding and loss of architecture
  - Complex growth pattern
  - No destructive invasion
  - No lymphovascular invasion
  - Depth of invasion of these lesions is difficult to measure and therefore the thickness of invasion is taken and in this instance is 1.5mm.

Silva classification – Pattern-based classification of HPV-associated endocervical adenocarcinoma

- Pattern A – non destructive invasion
  - · Well-demarcated glands with rounded contours
  - · No lymphovascular invasion
  - · Complex intraglandular growth acceptable (i.e. cribriform growth, papillae)
  - · Lack of solid growth (i.e. architecturally well to moderately differentiated)

  Clinical correlate – low risk of nodal spread and can be treated conservatively

  Ref:

  Park KJ, Roma AA. Pattern based classification of endocervical adenocarcinoma: a review. Pathology. 2018 Feb;50(2):134-140

Silva pattern based classification of HPV associated endocervical adenocarcinoma

Pattern	Risk stratification system
Pattern A	• **Well-demarcated glands with rounded contours, frequently forming groups**
	• **No destructive stromal invasion**
	• **No single cells or cell detachment**
	• **No lymphovascular invasion**
	• **Complex intraglandular growth acceptable, i.e., cribriform, papillae**
	• **Lack of solid growth, i.e., architecture well-moderately differentiated**
	• **Depth of the tumour or relationship to large cervical vessels not relevant**
Pattern B	• **Localised (limited, early) destructive stromal invasion arising from pattern A glands (well-demarcated glands)**
	• **Individual or small groups of tumour cells, separated from the rounded gland, often in a focally desmoplastic or inflamed stroma**
	• **Foci may be single, multiple, or linear at base of tumour**
	• **Lymphovascular invasion +/−**
	• **Lack of solid growth, i.e., architecturally well-moderately differentiated**
Pattern C	• **Diffuse destructive stromal invasion, characterised by: diffusely infiltrative glands, with associated extensive desmoplastic response; glands often angulated or with a canalicular pattern, with interspersed open glands**
	• **Confluent growth filling a 4× field (5 mm): glands, papillae (stroma only within papillae), or mucin lakes**
	• **Solid, poorly differentiated component (architecturally high grade); nuclear grade is disregarded**
	• **Lymphovascular invasion +/−**

Park KJ, Roma AA. Pattern based classification of endocervical adenocarcinoma: a review. Pathology. 2018 Feb;50(2):134-140