Educational Case

CIN 1

Cervical biopsy worked case

- Age 24
- First cervical sample
- HPV positive, LG dyskaryosis on cytology
- Referred to colposcopy
- Colposcopy opinion – SCJ seen, ?HG CIN
- Biopsy taken

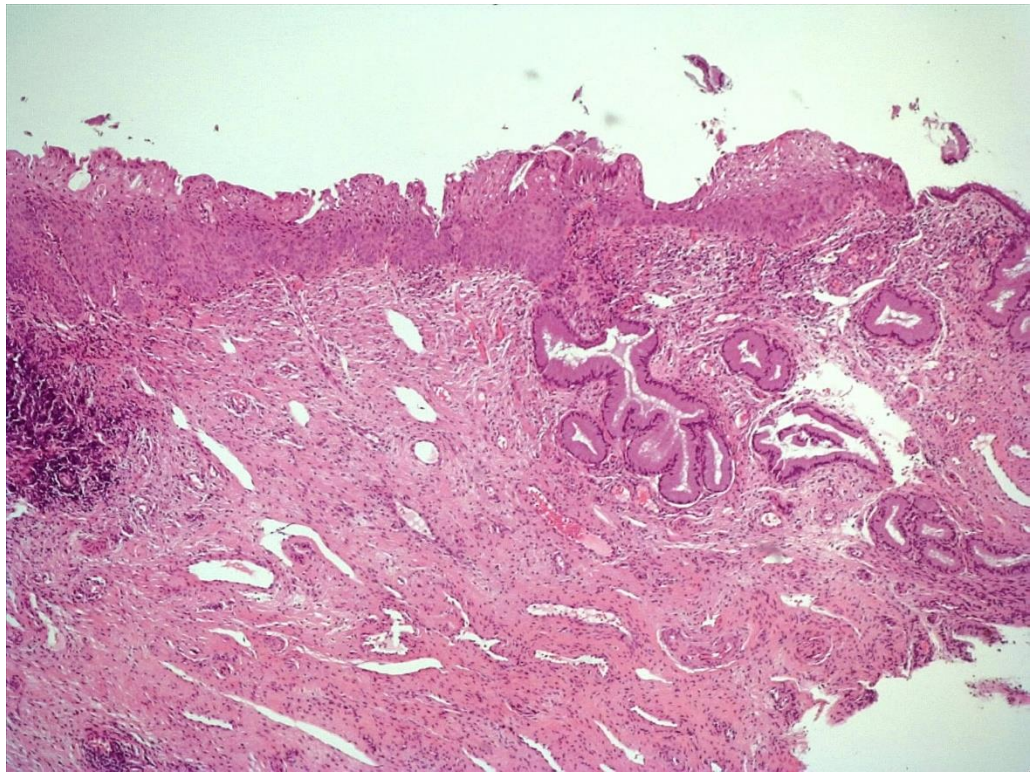

H+E, x 5

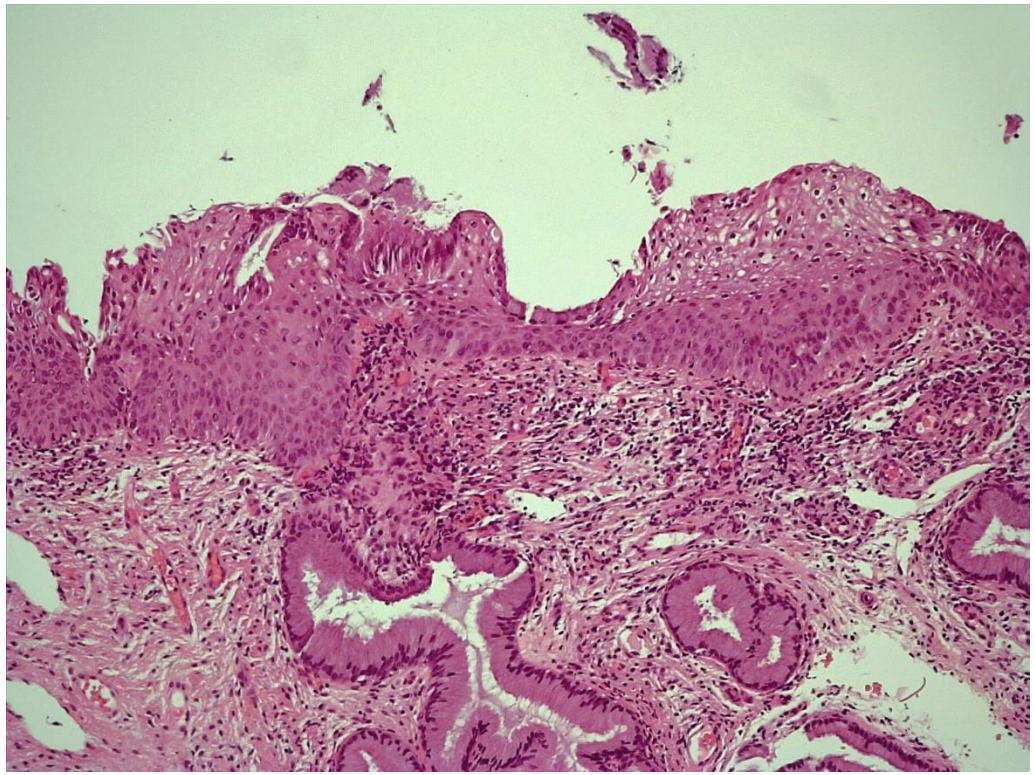

H+E, x 10

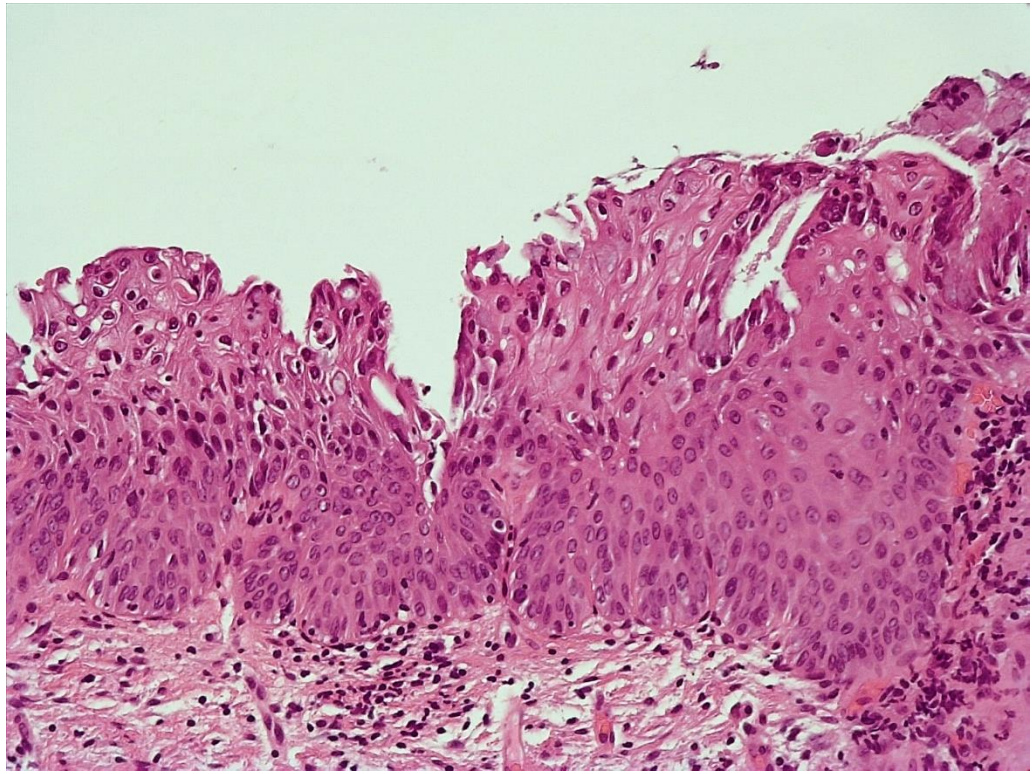

H+E, x 20

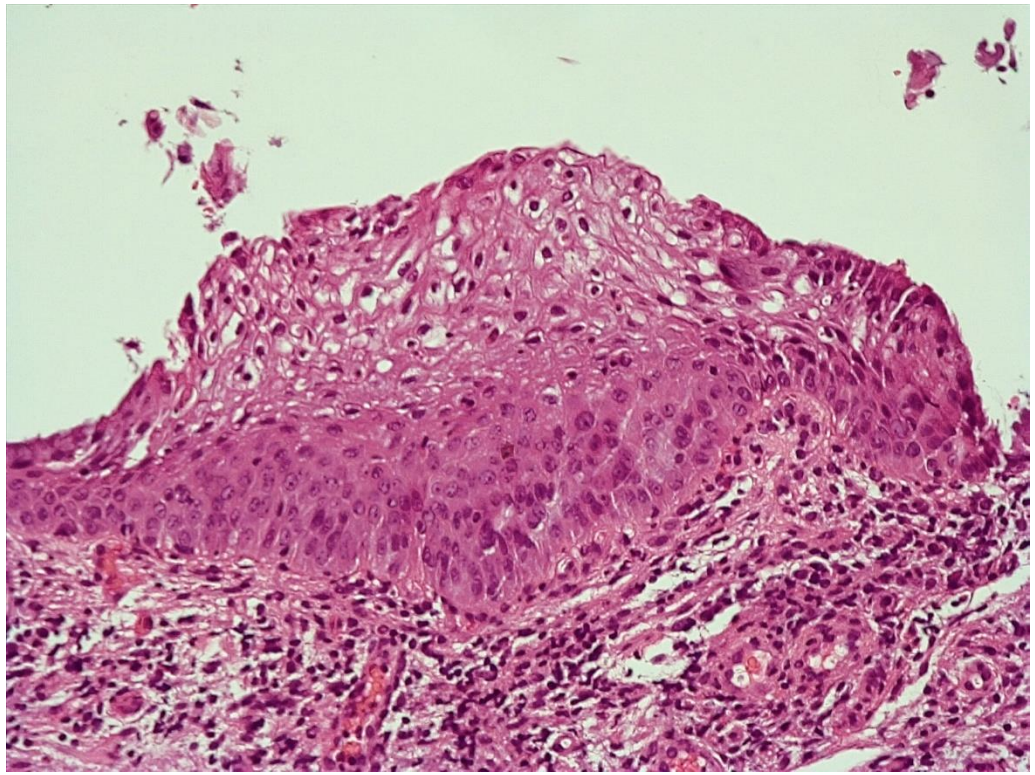

H+E, x 20

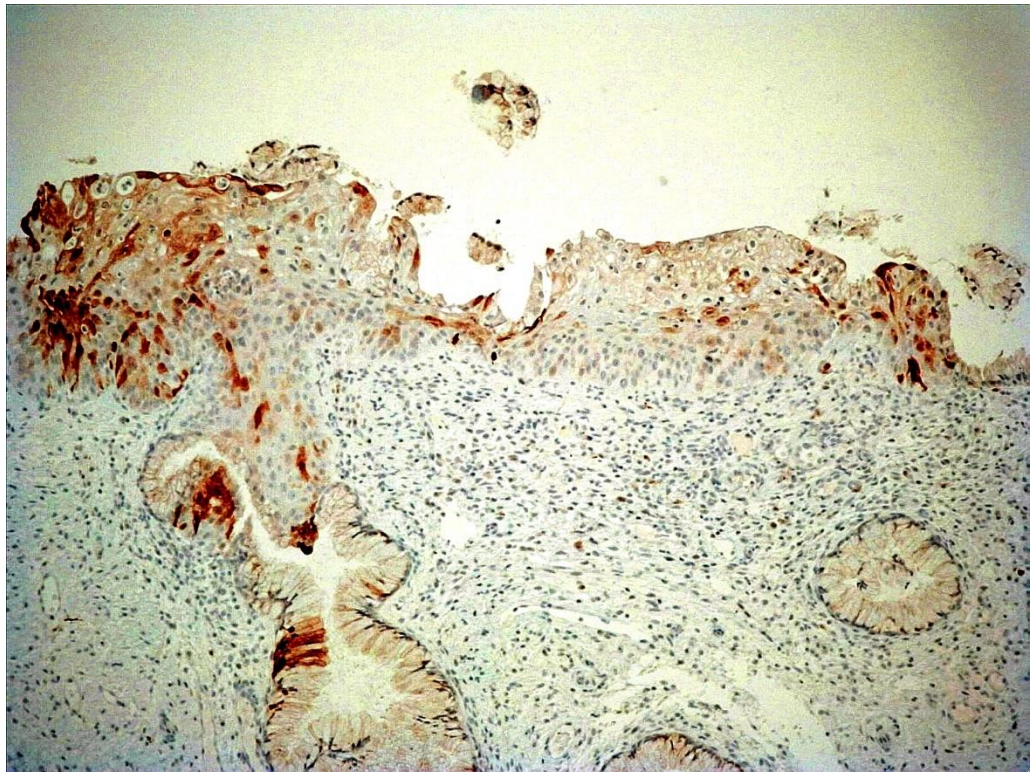

P16 stain, x 10

Case discussion

- Biopsy contains TZ and SCJ
- Focal koilocytes and basal changes in immature metaplastic squamous epithelium ?CIN1 ?CIN2
- P16 stain shows normal type staining with no evidence of any block positivity
- Overall interpreted as CIN1 with viral change
- No HG CIN identified on this biopsy
- No glandular dyskaryosis identified
- No invasive disease present