Cervical Glandular Neoplasia – diagnosis, detecting invasion and distinguishing benign mimics

Illustrations

Lead Author: Raji Ganesan

r.ganesan@nhs.net

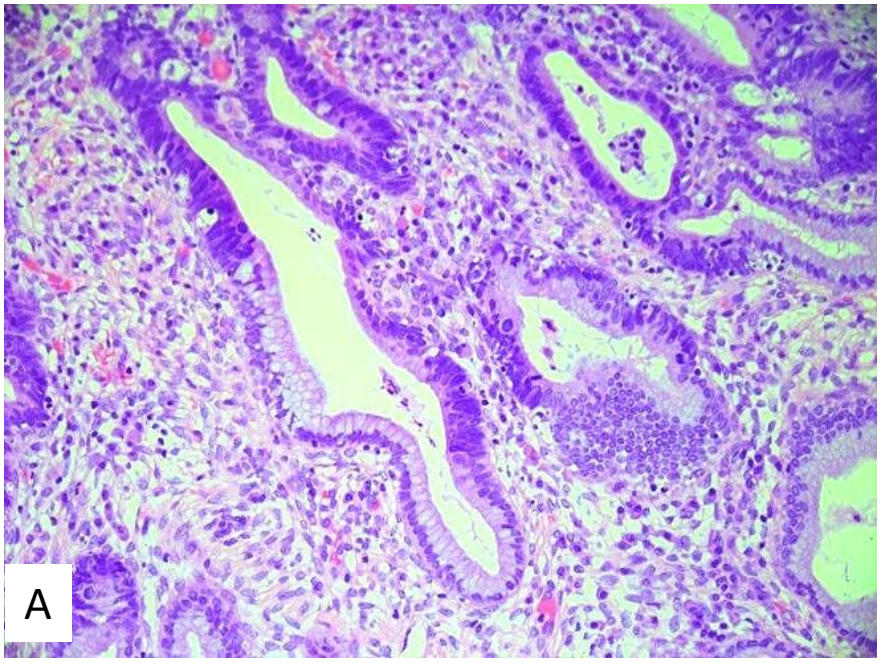

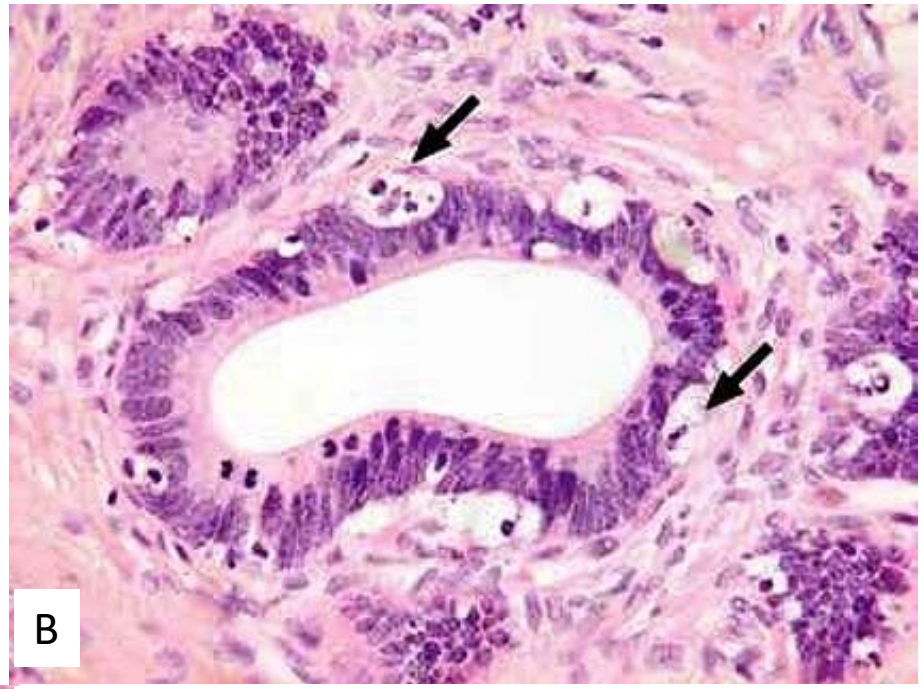

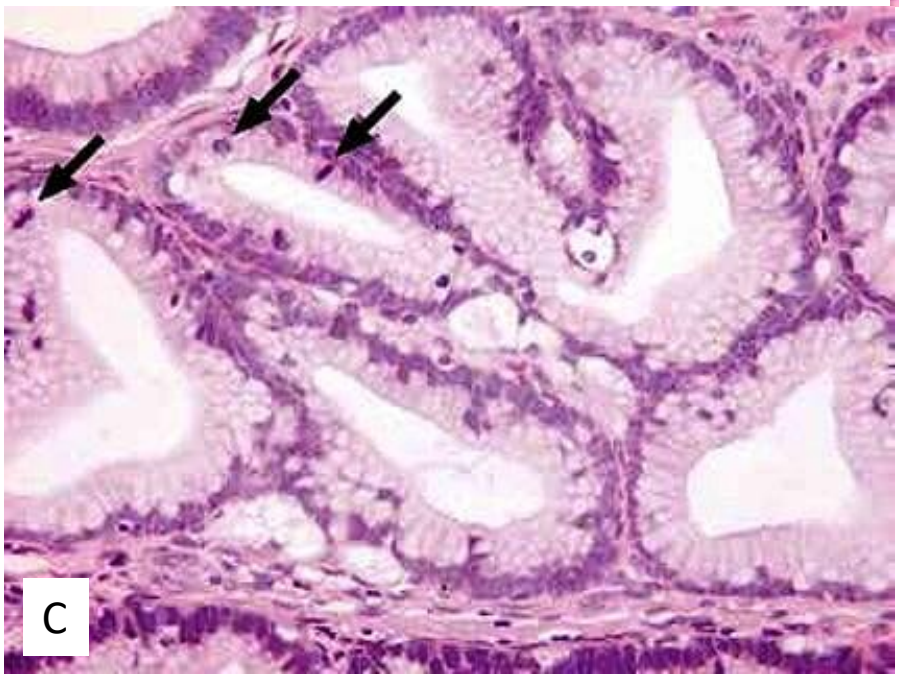

A. Low power view showing hyperchromasia of the glands with CGIN. The hyperchromatic and stratified nuclei show an abrupt junction with normal nuclei.

B. Basal apoptotic bodies.

C. Supranuclear mitoses.

D. CGIN with goblet cells

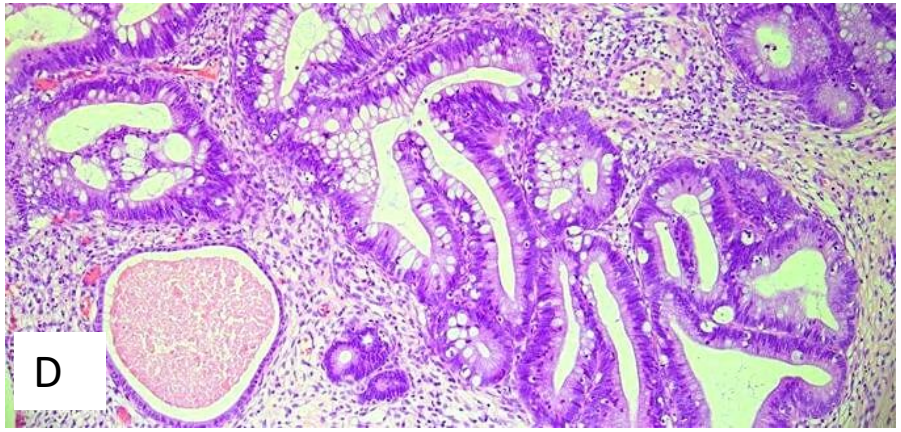

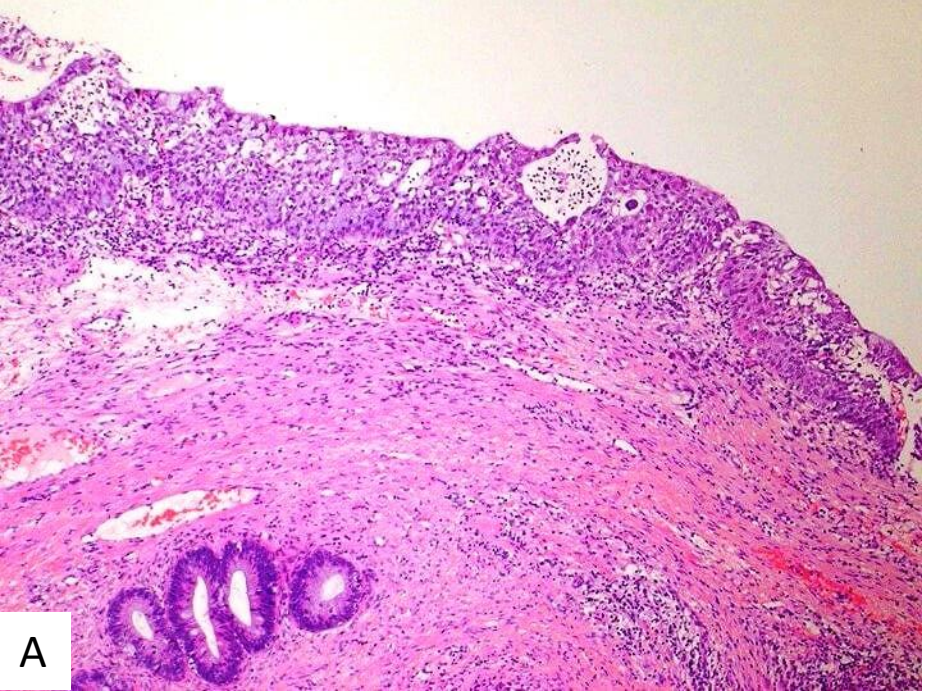

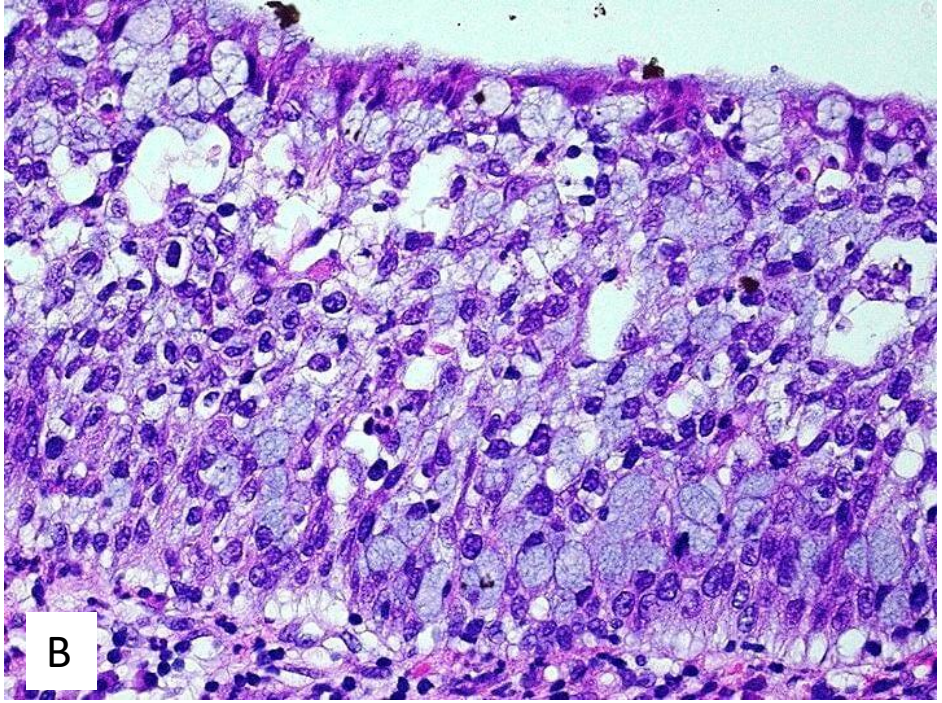

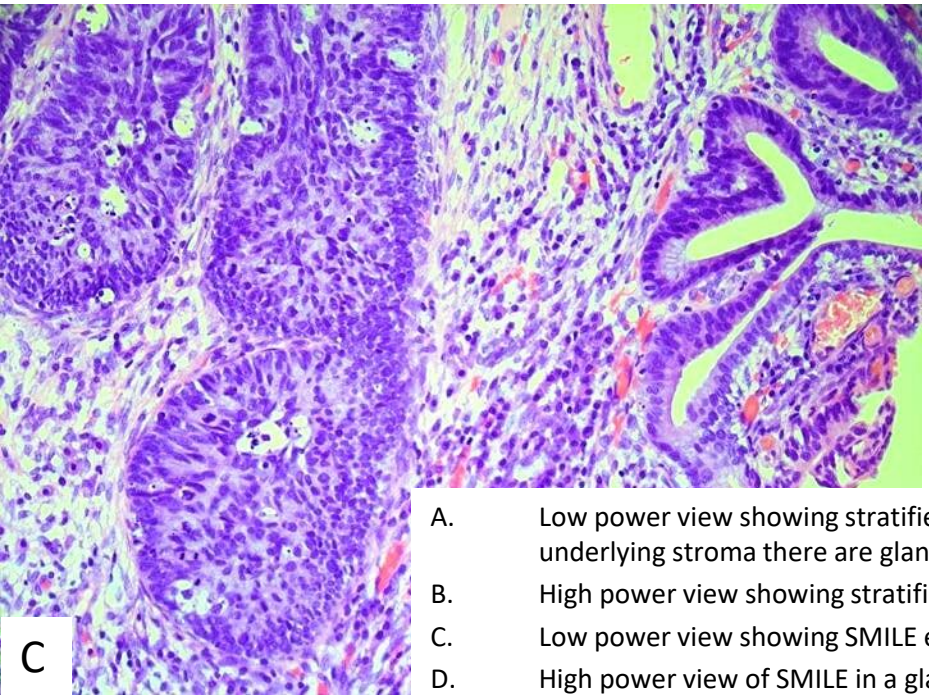

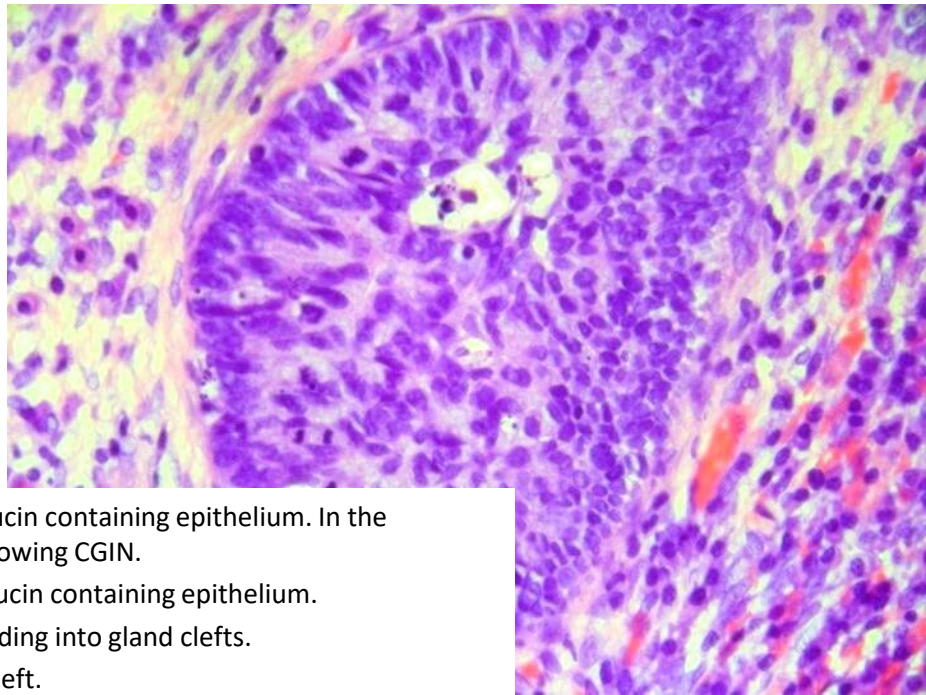

A. Low power view showing stratified mucin containing epithelium. In the underlying stroma there are glands showing CGIN.

B. High power view showing stratified mucin containing epithelium.

C. Low power view showing SMILE extending into gland clefts.

D. High power view of SMILE in a gland cleft.

Tuboendometrioid or tubal metaplasia

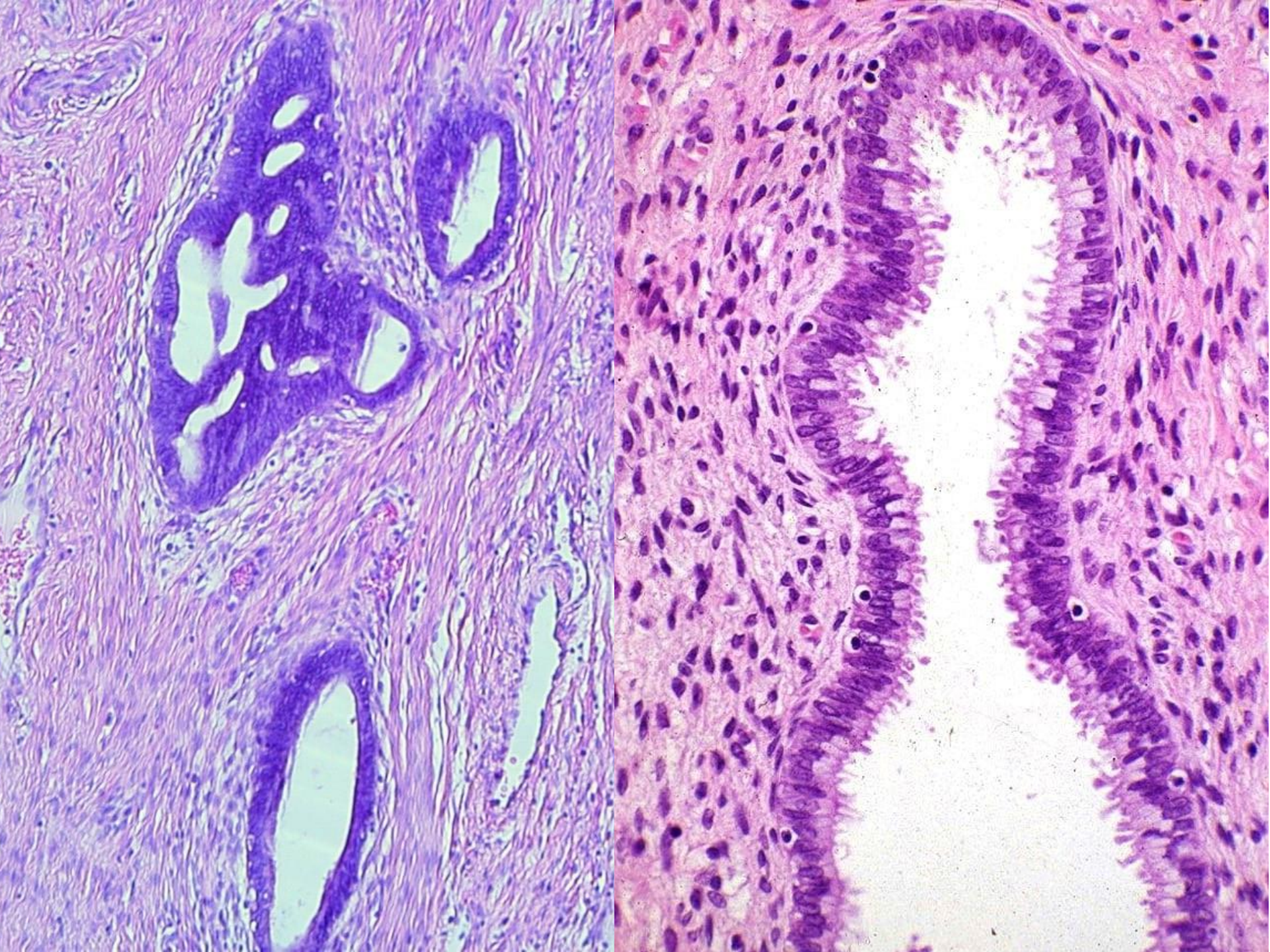

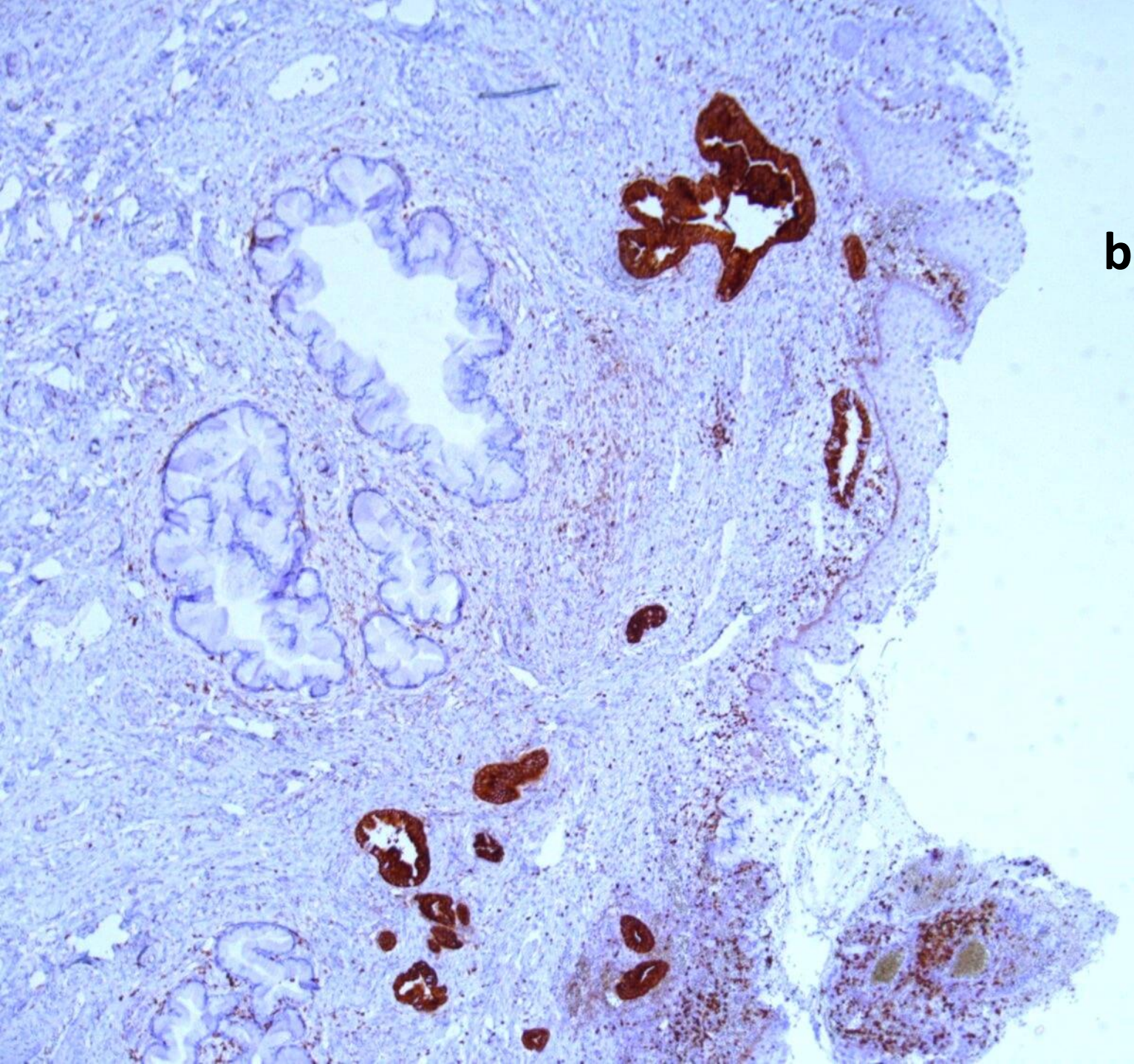
bcl2

Cervical endometriosis

The glands are lined by columnar epithelium and may be mitotically active.

Surrounding endometrial type stroma (may also be mitotically active) is seen.

Stroma often haemorrhagic.

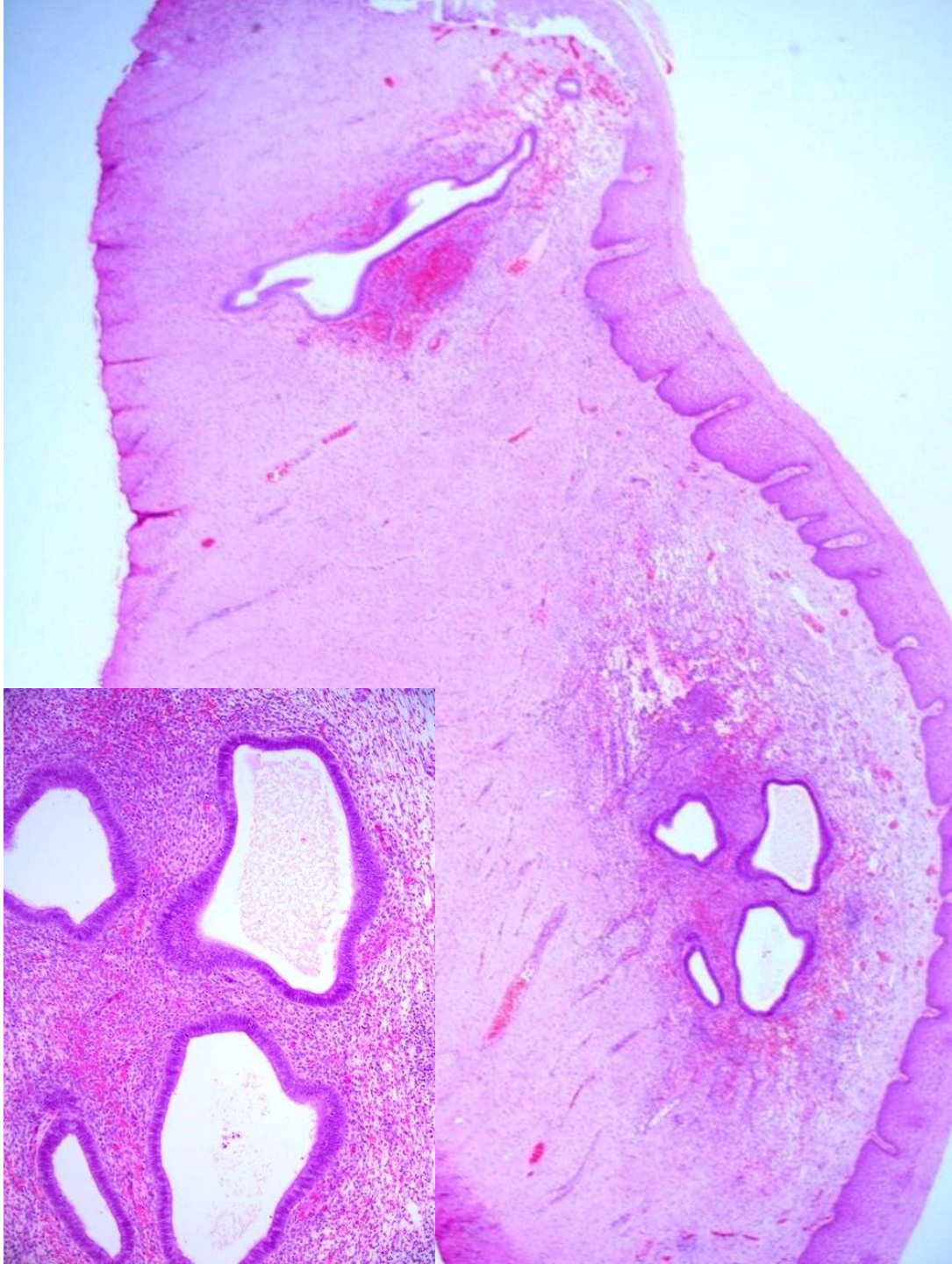

Mimics of SMILE

- Immature squamous metaplasia
  - mucin is usually confined largely to the surface layer while in SMILE it is present throughout the full epithelial thickness.
  - The nuclei are more atypical and hyperchromatic in SMILE than in immature squamous metaplasia.
  - SMILE is block positive for p16

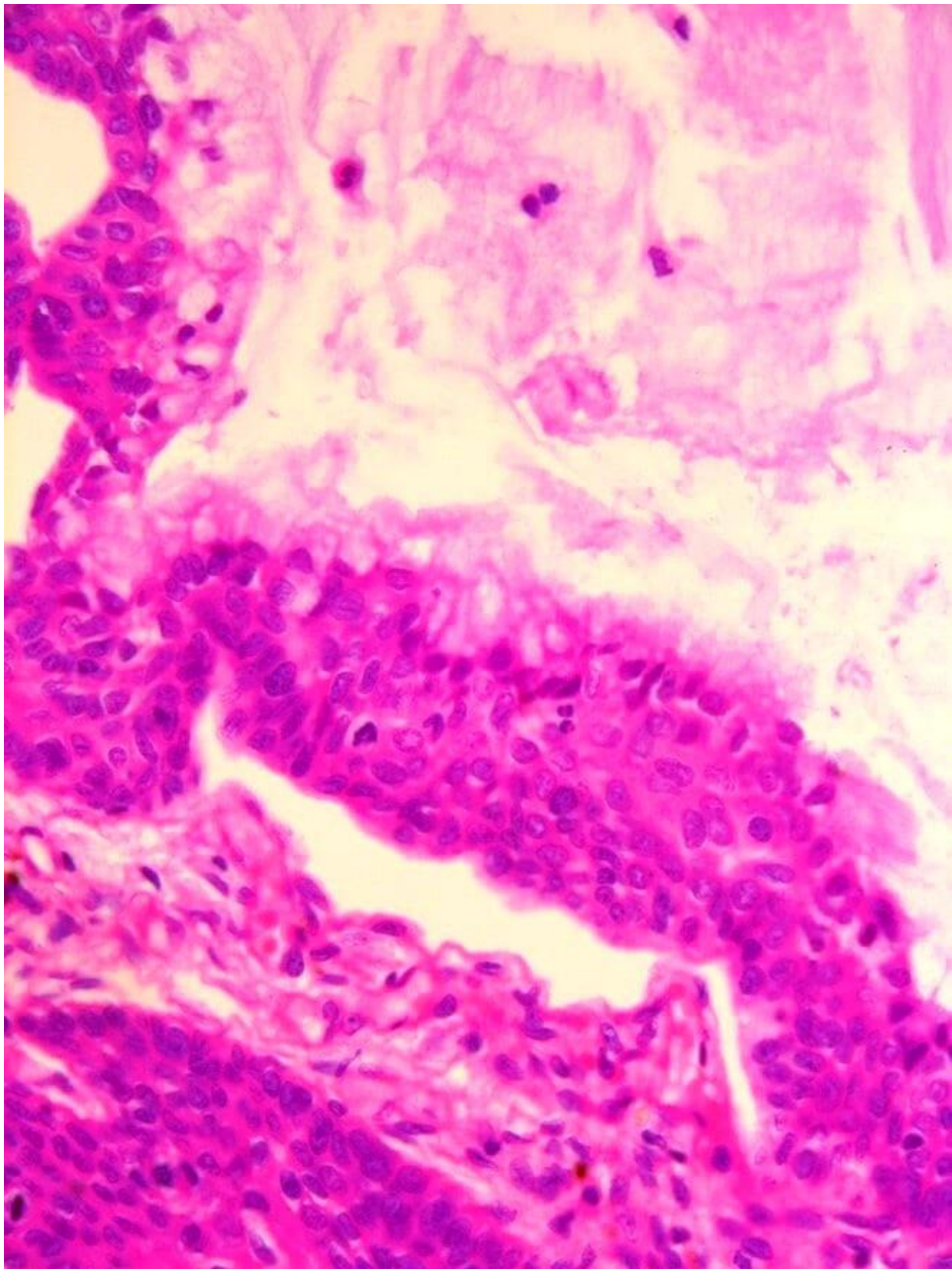

Features of invasion

- Paradoxical differentiation i.e. apparently squamous appearing buds or nests arising from CGIN
- Loss of normal gland lobularity
- Back to back arrangement of glands without intervening stroma
- Solid areas
- Intravascular tumour
- Glands around thick walled blood vessels in deep stroma or around nerves

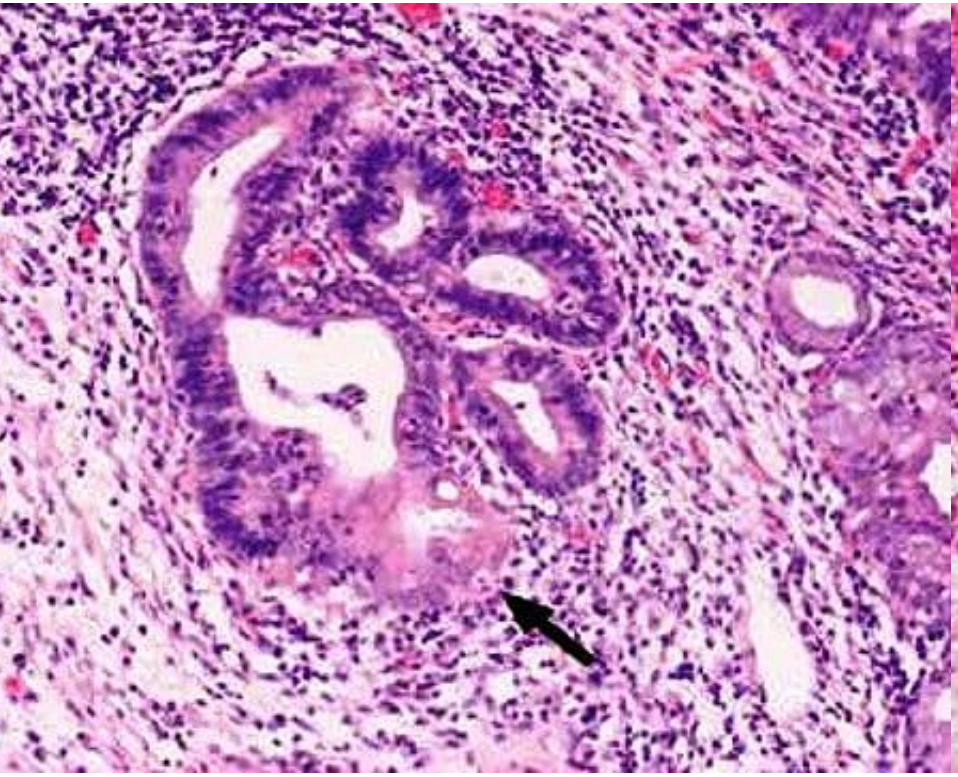

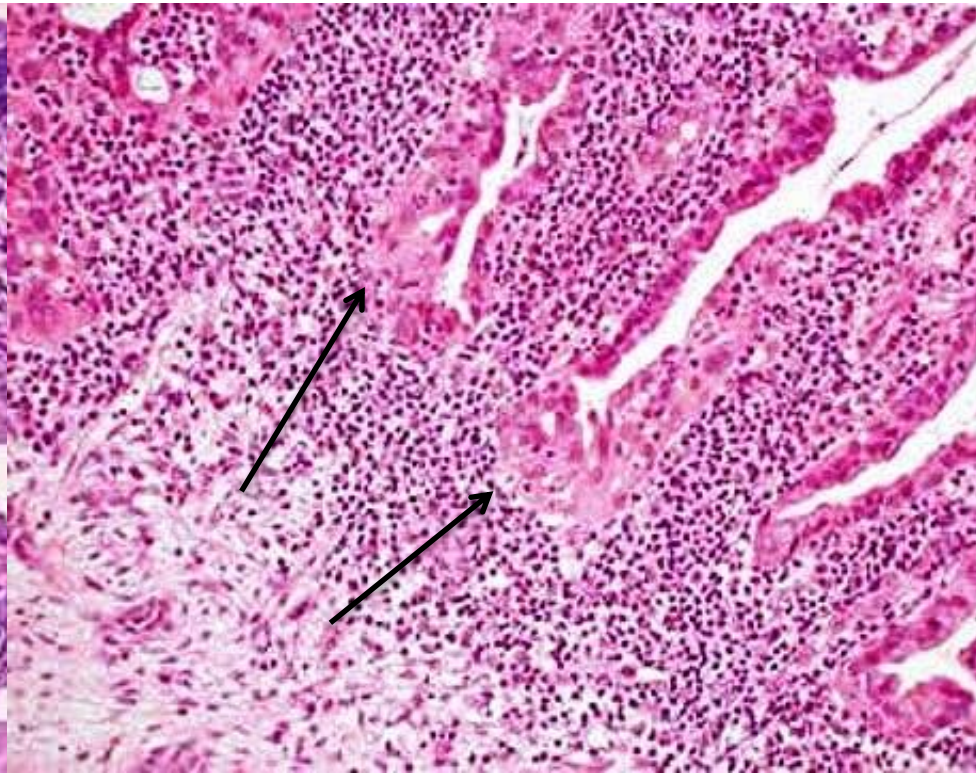

Paradoxical differentiation - the presence of small buds, glands or solid nests of cells with abundant eosinophilic cytoplasm (squamoid appearance) that arise from glands involved by CGIN



Glandular architectural complexity - which is beyond that compatible with the normal endocervical glandular field often best appreciated on low power.

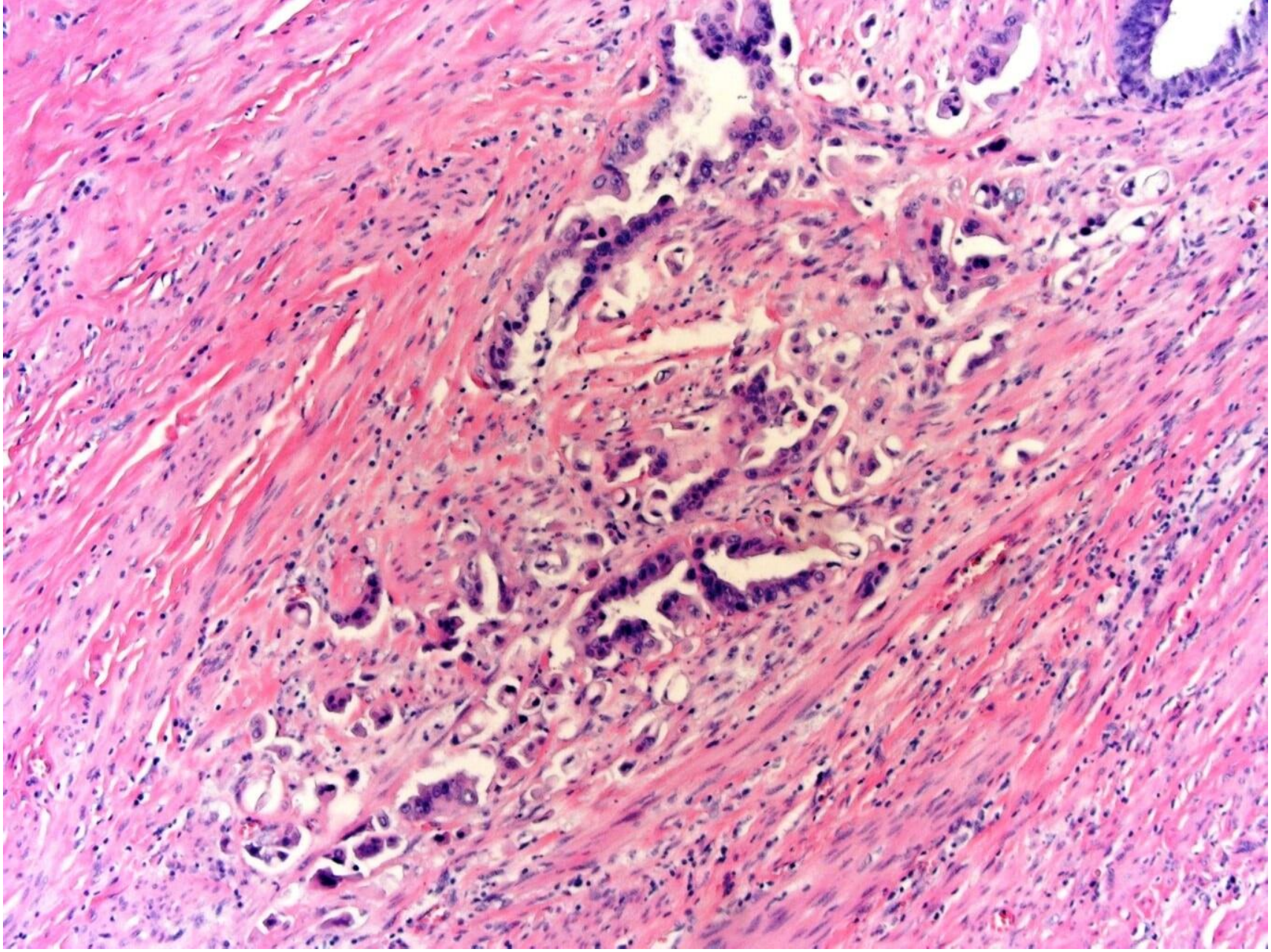

Obvious infiltrative growth pattern – with irregular glands and partial gland profiles infiltrating the stroma with an associated desmoplastic reaction.

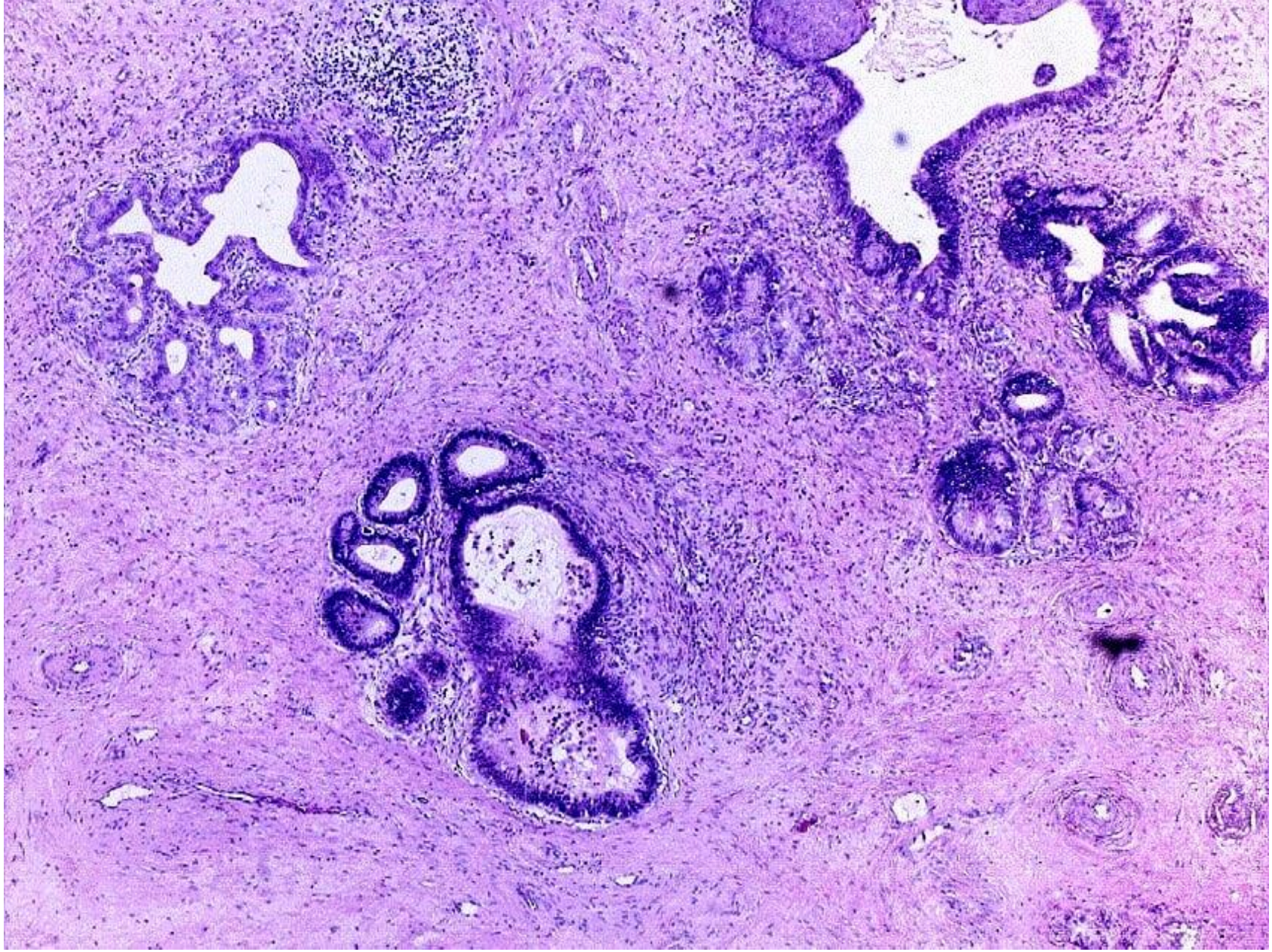

Obvious infiltrative growth pattern – irregular glands infiltrating the stroma with an associated desmoplastic, inflammatory reaction.

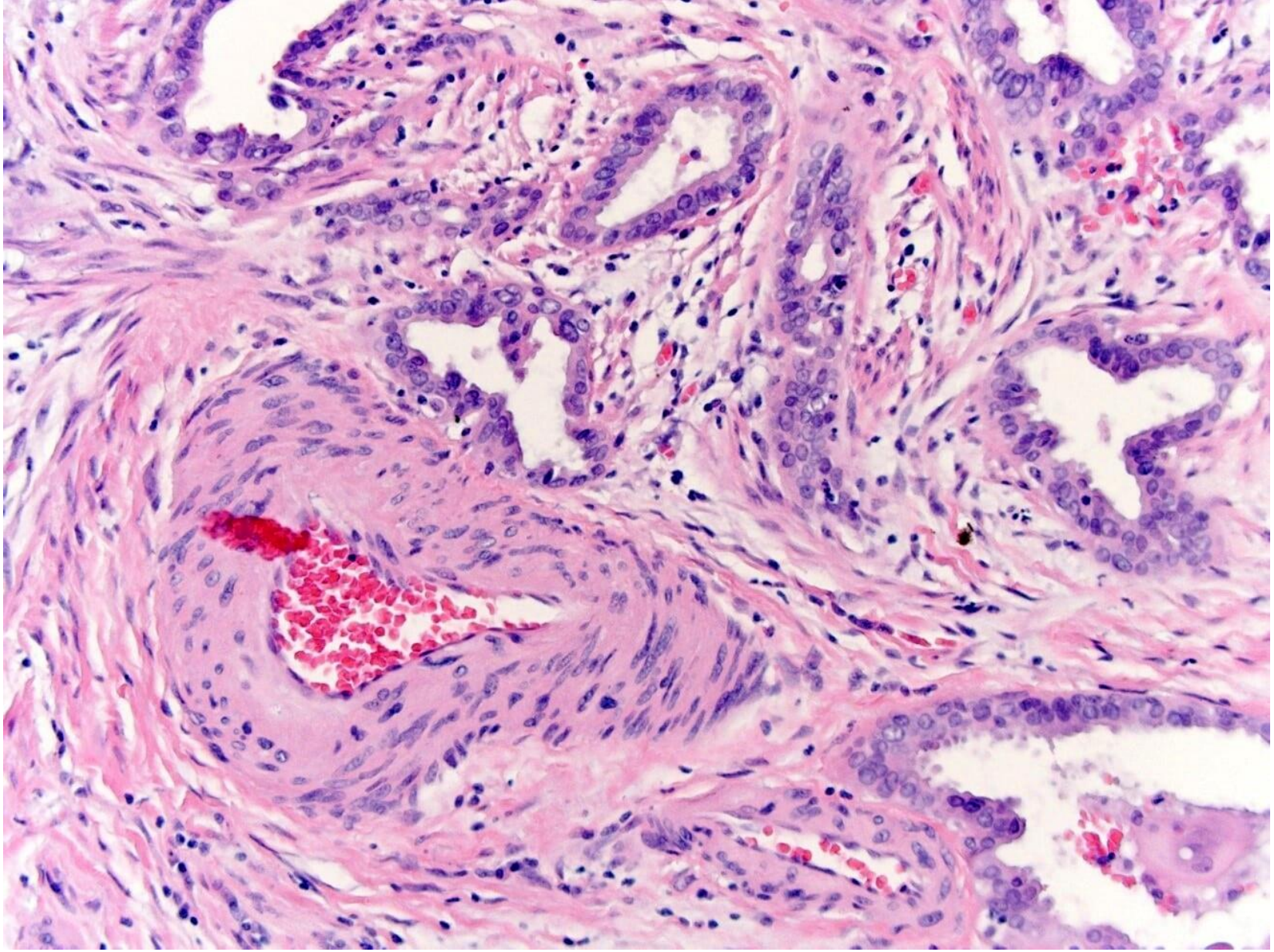

Abnormal glands abutting on or surrounding thick-walled blood vessels

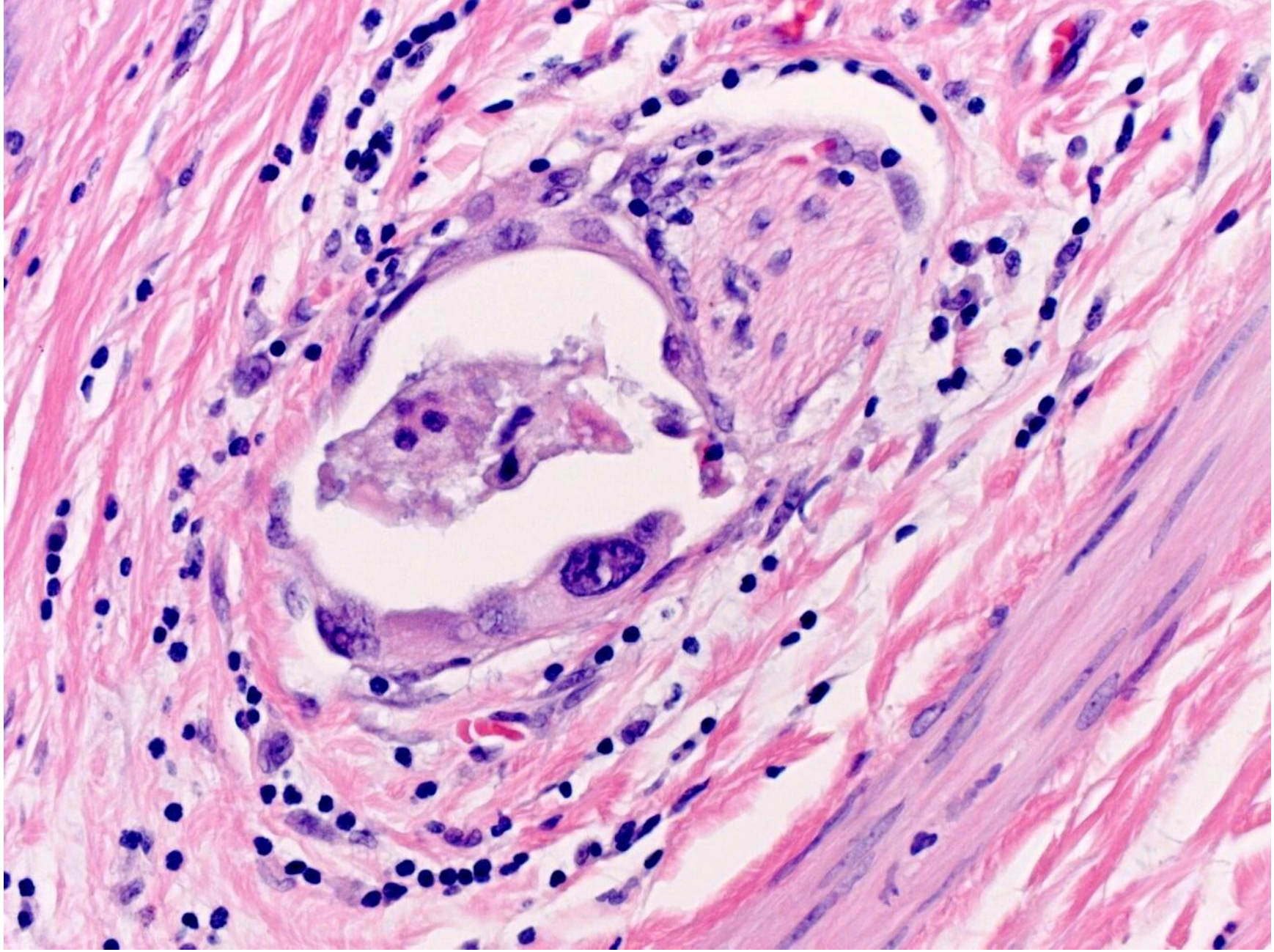

Perineural invasion

Feature supporting benignity

Preservation of lobular architecture

A. Mesonephric hyperplasia

B. Tunnel clusters

