Cervical Squamous Neoplasia - Diagnosis, detecting invasion and distinguishing benign mimics

Lead Author : Prof Raji Ganesan

January 2024

Session Description
Learning Objectives

- By the end of this session you should know:

— Criteria for recognition of Squamous Cervical intra-epithelial neoplasia (CIN)

— How to use and interpret P16 in the diagnosis of CIN

— How to distinguish CIN from benign mimics

— Features of invasive squamous carcinoma of the cervix

- Before commencing this session you should ideally have read:

— NHSCSP Publication Cervical Screening programme: histopathology reporting handbook

— Darragh TM, Colgan TJ, Thomas Cox J, et al. The Lower AnogenitalSquamous Terminology Standardization project for HPV-associated lesions: background and consensus recommendations from the College of American Pathologists and the American Society for Colposcopy and Cervical Pathology. Int J Gynecol Pathol 2013; 32(1): 76-115

— Interpretation of p16 Immunohistochemistry In Lower AnogenitalTract Neoplasia, BAGP

— RCPath Standards and datasets for reporting cancers : Dataset for histological reporting of cervical neoplasia, GO71.

— Have a basic knowledge of cervical intraepithelial neoplasia

CIN – cervical intraepithelial neoplasia

CIN is graded in the UK into three -CIN1, CIN2 and CIN3. In most parts of the world, the classification is two-tier into LSIL (low grade squamous intra-epithelial lesion) and HSIL (high grade squamous intra-epithelial lesion). CIN 1 matches to LSIL and CIN2 and 3 match to HSIL. CIN 1 maybe referred to as Low Grade (LG) CIN whereas CIN 2 and CIN 3 are as High Grade (HG) CIN. Grading of CIN is done on basis of the degree of involvement of the squamous epithelium involved. Differentiating “pure” viral change/ HPV related changes from CIN 1 is inherently subjective and therefore may be problematic.

In practical terms:
CIN1 involves the lower third of the thickness of the squamous epithelium involved. CIN2 involves the lower 2/3rds of the thickness of the squamous epithelium involved.
CIN3 involves over 2/3rds of the thickness of the squamous epithelium involved.

CIN1 is characterized by the lower third of the epithelium showing proliferation of basal/parabasal-like cells that may show mitotic activity. Usually atypical mitoses are not seen. N:C ratio is raised and the nuclei show mild pleomorphism. The cells in the upper two thirds retain features of maturation/differentiation.

Benign mimics of CIN1/ LGCIN:
Reactive or inflammatory features may mimic CIN1 and this overdiagnosis is a known problem in this context, with as many as 50% of biopsies diagnosed as CIN1 being classified as benign/reactive on expert review. p16 immunohistochemistry has no utility at this diagnostic interface, because many CIN1 are negative. However, HPV RNA in situ hybridization may demonstrate the presence of low-risk HPV.

Atrophic squamous epithelium, immature metaplastic squamous epithelium and congenital transformation zone also are likely differentials. These are morphological differentials and there is no role of IHC.

CIN 2 and CIN 3

CIN2 shows nuclear hyperchromasia, coarse chromatin, irregular membranes, increased N:C ratio, and mitotic activity in the lower two thirds of the epithelium, but with accumulation of cytoplasm in the uppermost cell layers. CIN 3 shows atypia and mitotic activity into the upper thirds of the epithelium. Distinguishing between CIN 2 and CIN 3 can be challenging as can distinguishing between CIN1 and CIN2. The former is clinically irrelevant because both are followed by as high grade CIN.

In differentiating CIN 1 from CIN 2 extension of basal/parabasal morphology and mitotic activity beyond the lower epithelial third favours CIN2. It is helpful to use p16 immunohistochemistry in morphologically ambiguous cases when CIN2 is suspected, especially in young women (aged < 30 years). Absence of block-type p16 staining favours CIN1.

CIN involving thin, attenuated or atrophic squamous epithelium can be problematic
due to the difficulty in distinguishing immature metaplastic or atrophic squamous epithelium from one with CIN. Thin, attenuated or partly denuded squamous epithelium can also be difficult to grade given that these may only be 3-5 cells thick.

Use and Interpretation of P16 to aid with diagnosis of CIN
It is known that most, if not all, carcinomas of the cervix are HPV driven
p16 is used as a surrogate marker for HPV infection
In problematic cases of HG CIN the use of P16 immunohistochemistry can aid with interpretation
The use and interpretation of P16 should follow LAST and BAGP guidance.

Invasive squamous carcinoma of the cervix (SCC)

Almost all SCCs of the cervix are HPV associated carcinomas and arise from CIN3 on the surface and that involving gland crypts. Unlike the rounded outline of CIN3 involving gland crypts, cells of SCC are seen as infiltrating, angulated, irregularly sized and shaped nests, anastomosing cords, and solid sheets separated by an intervening desmoplastic or inflammatory stroma. In its earliest form stromal invasion is associated with irregular ragged epithelial nests, increased epithelial cell eosinophilia (paradoxical maturation), stromal loosening, or desmoplasia.

Normal cervical squamous epithelium

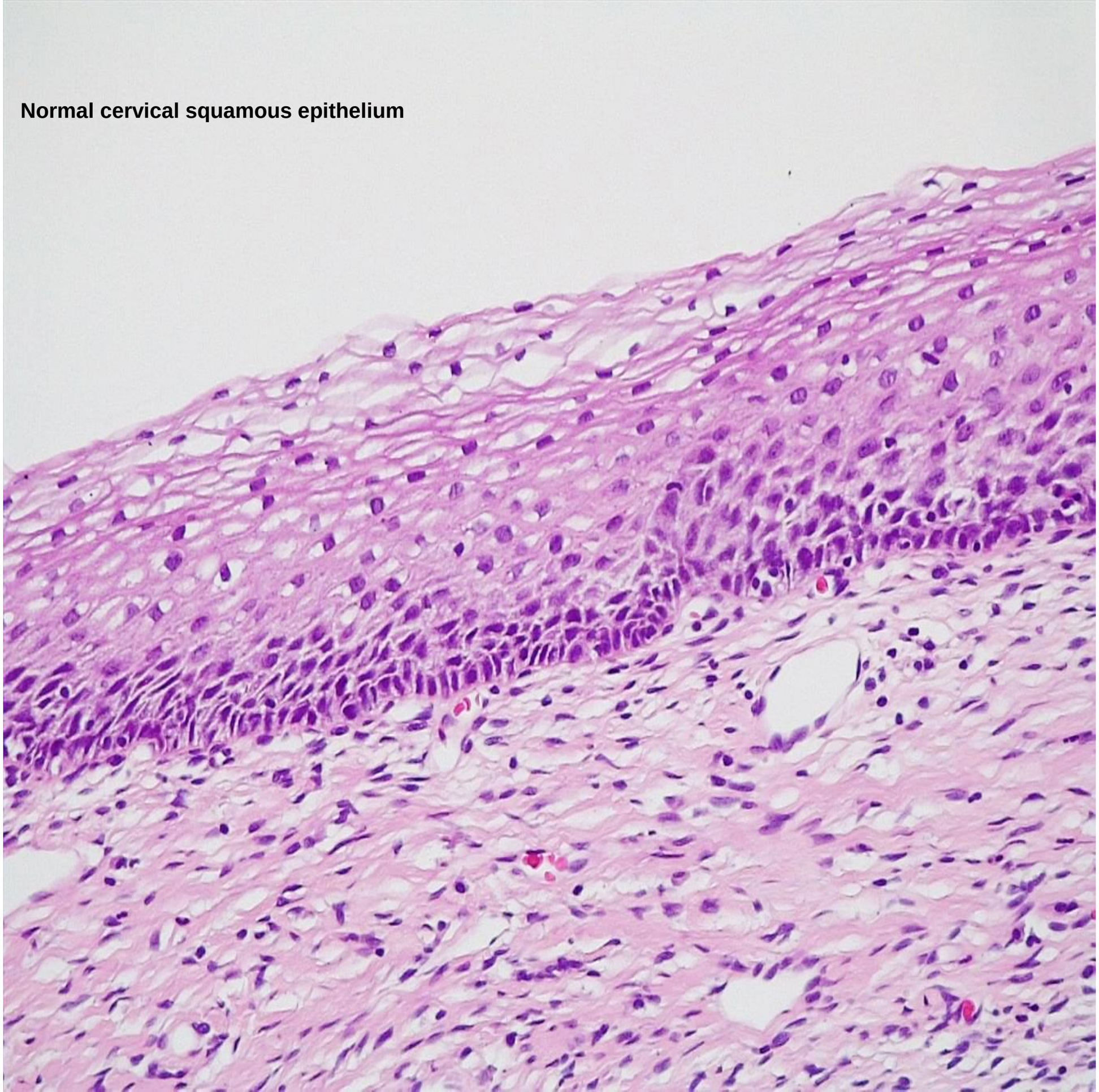

Normal cervical mucinous and ciliated epithelium

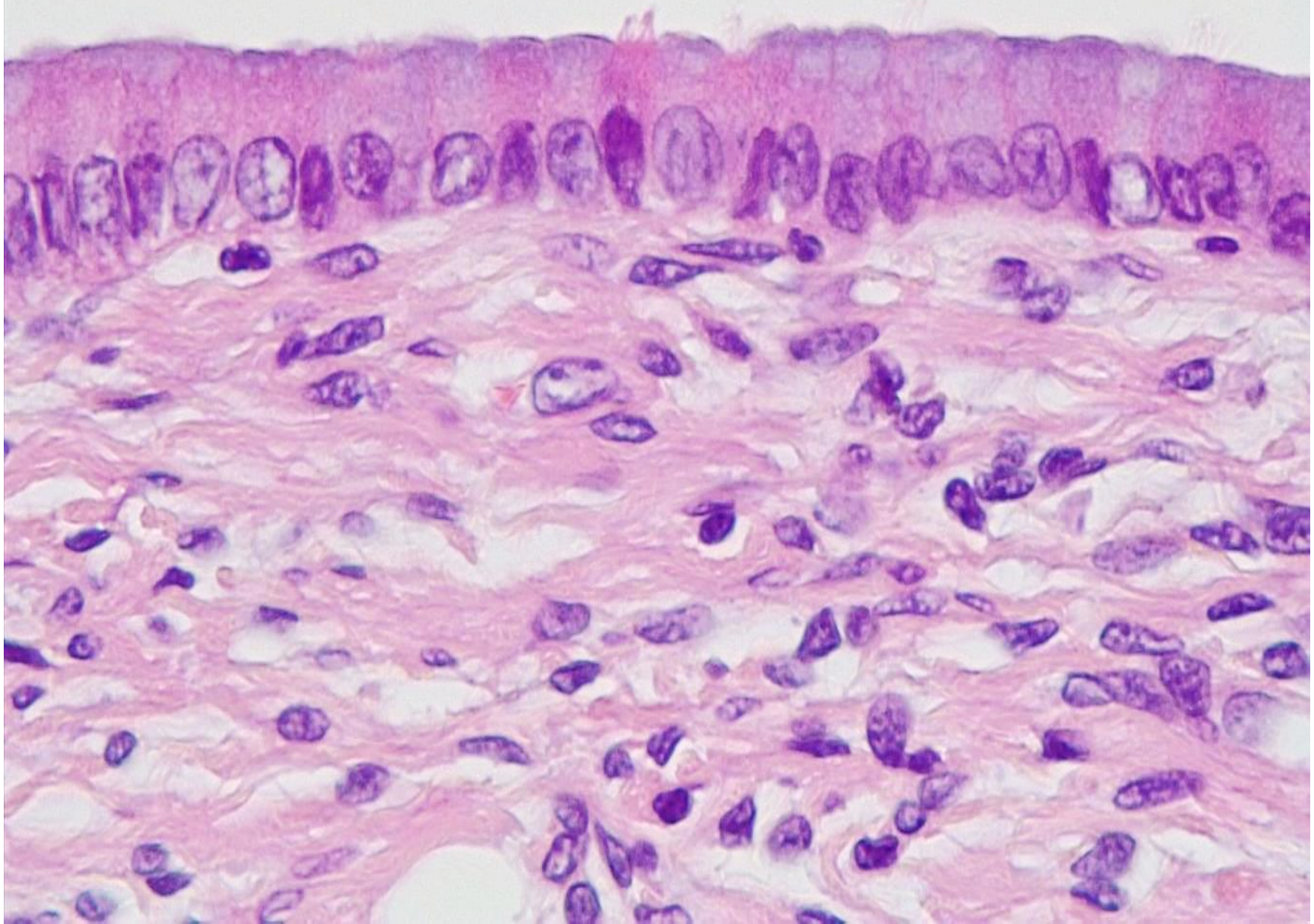

Immature squamous metaplasia

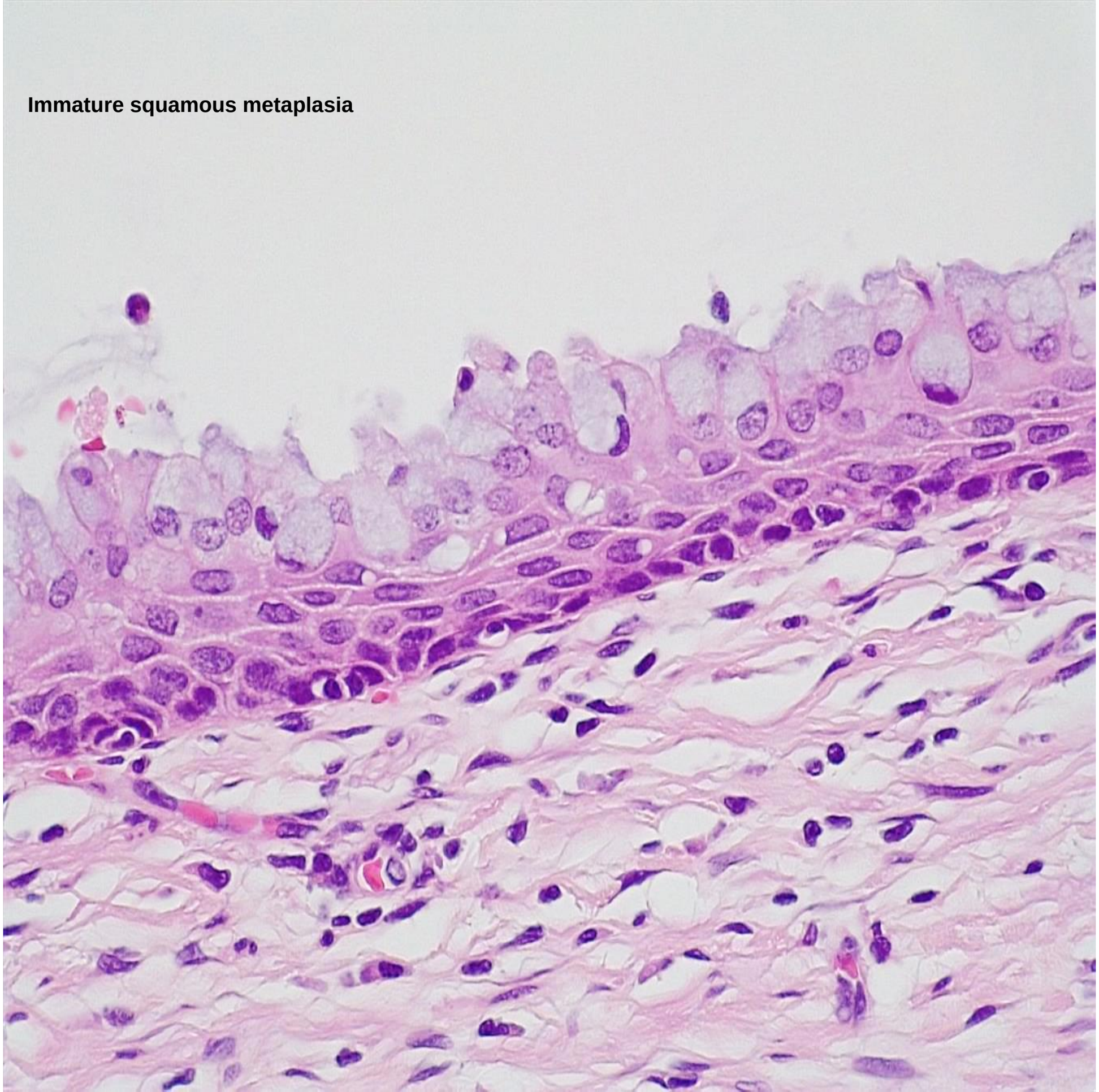

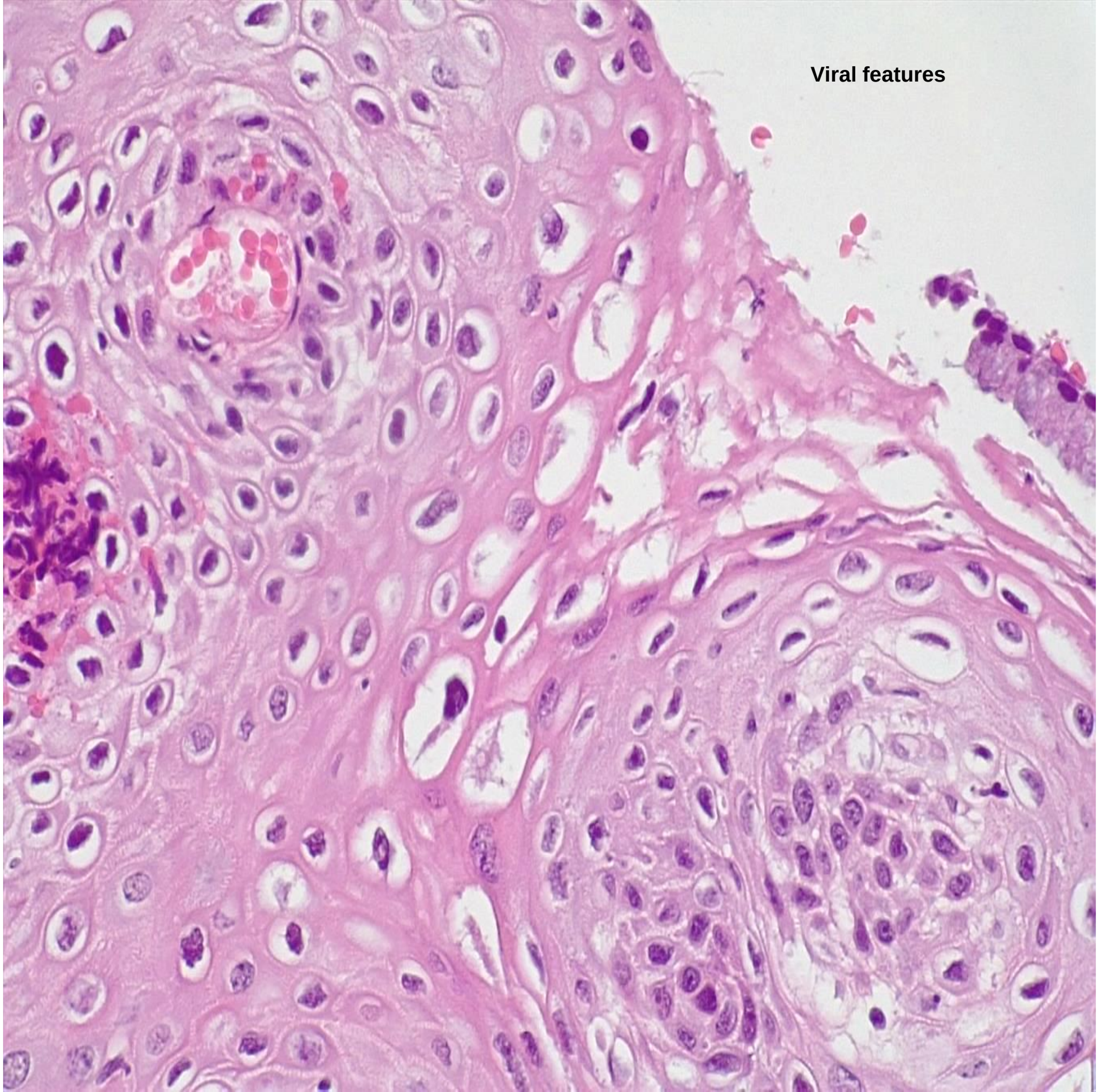
Viral features

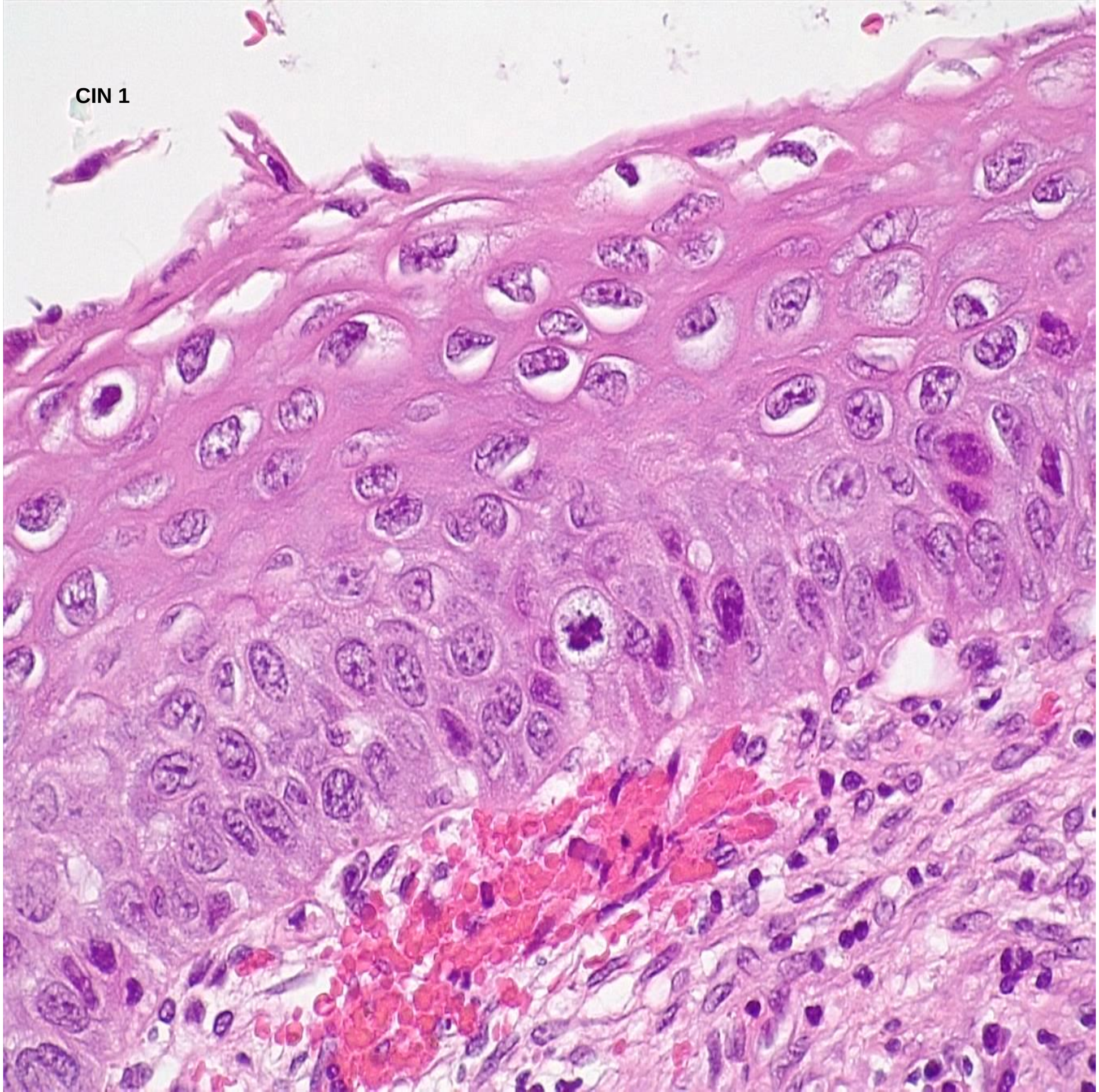
CIN 1

CIN 3

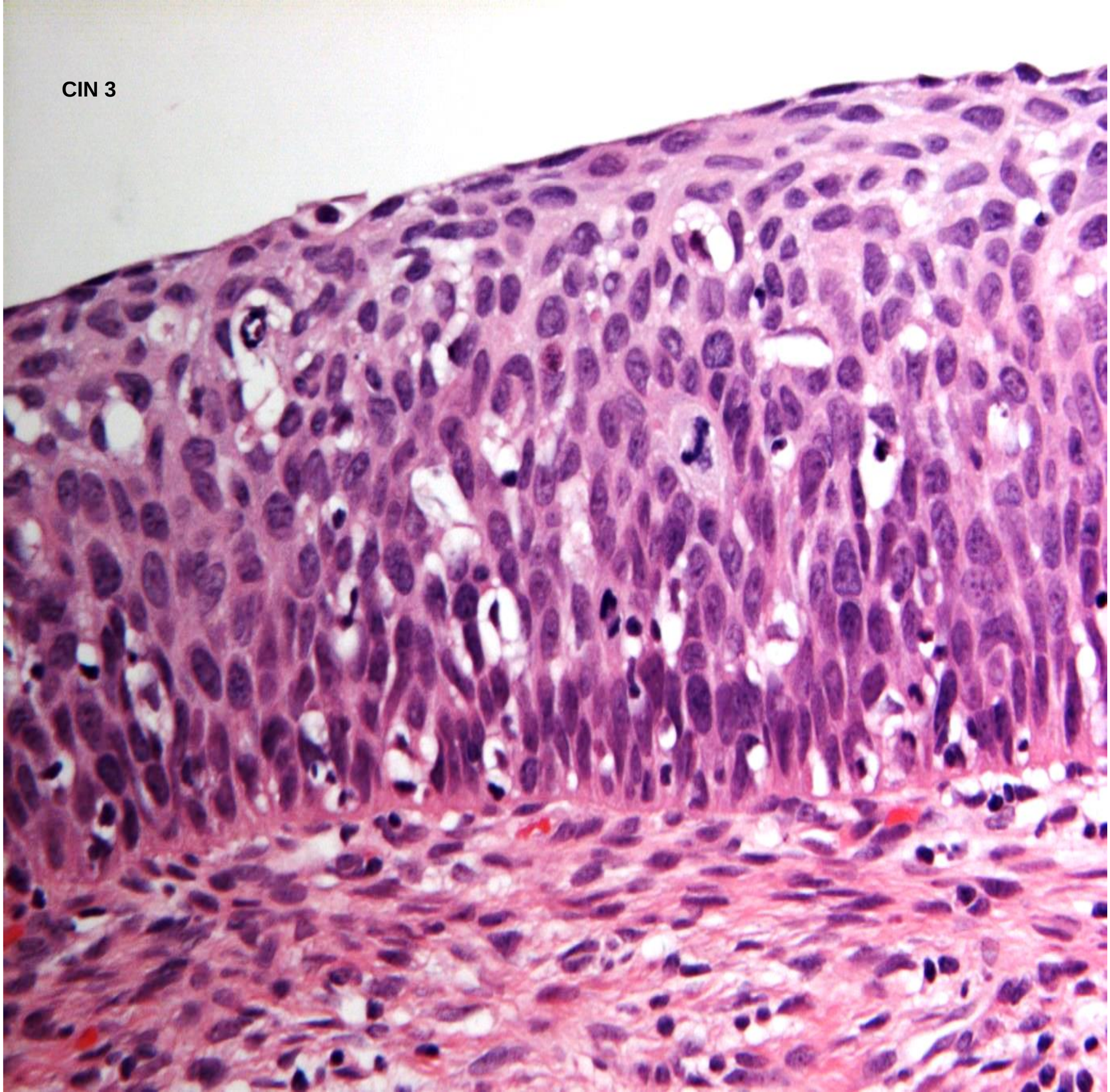

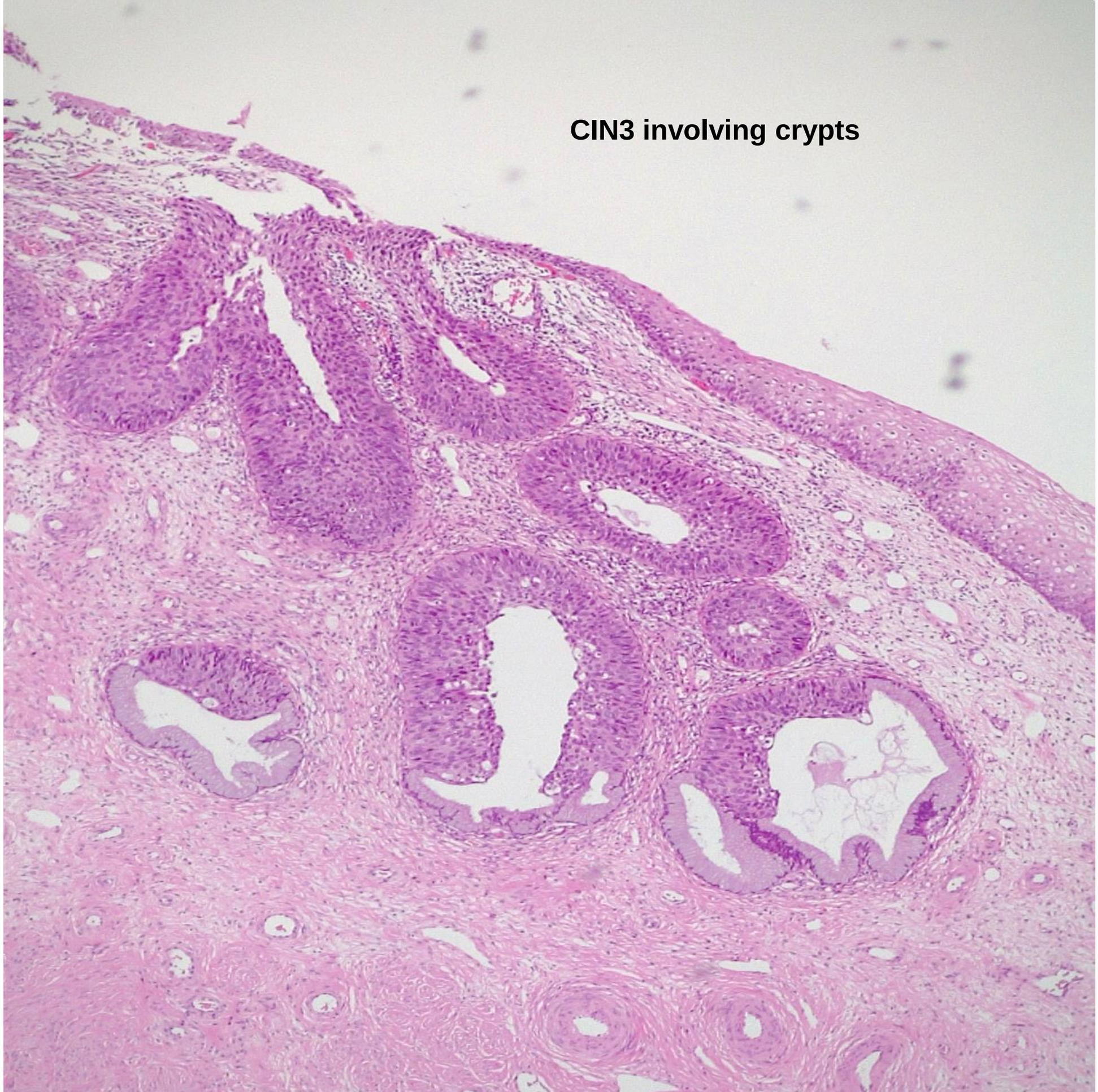
CIN3 involving crypts

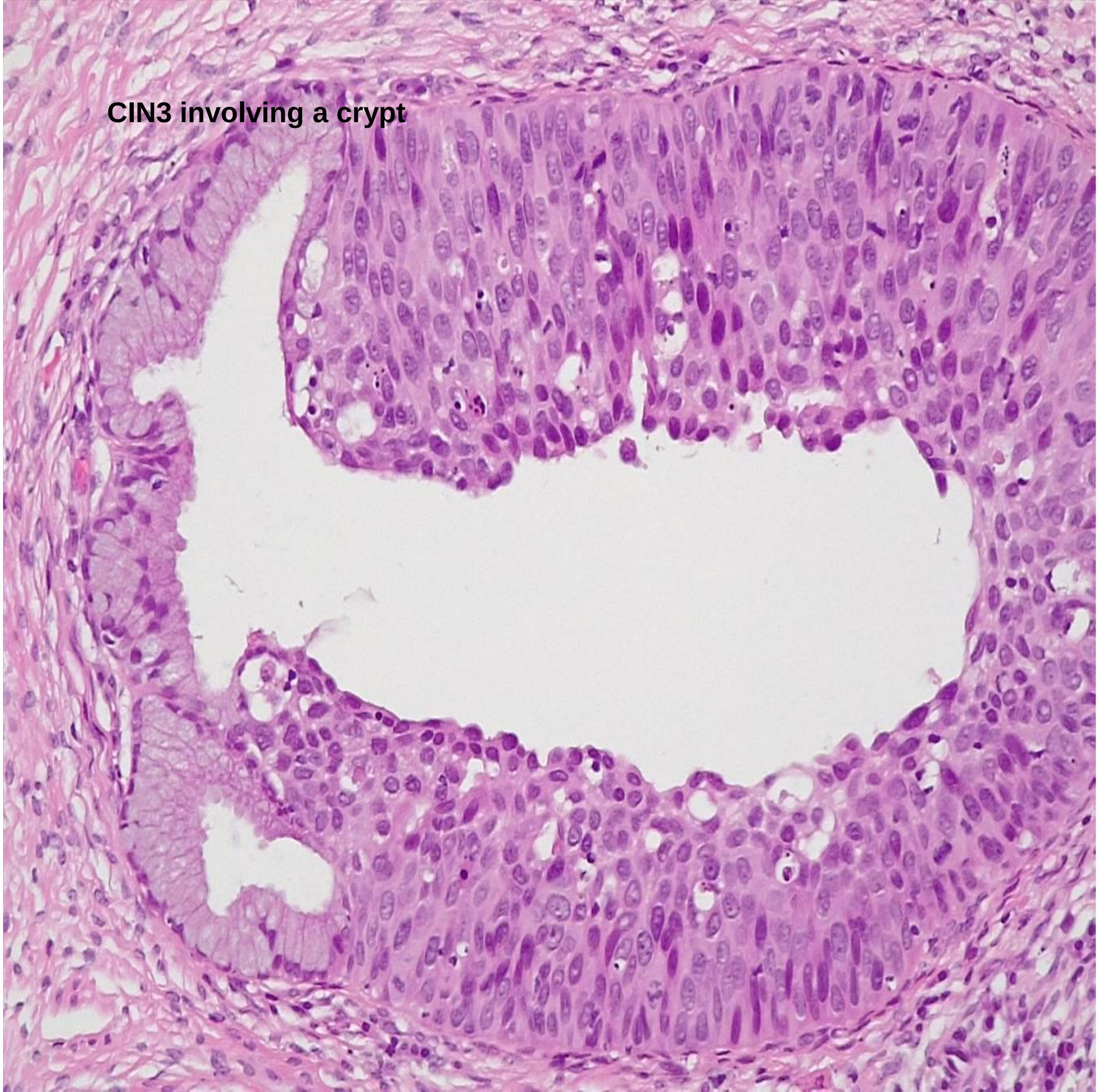
CIN3 involving a crypt

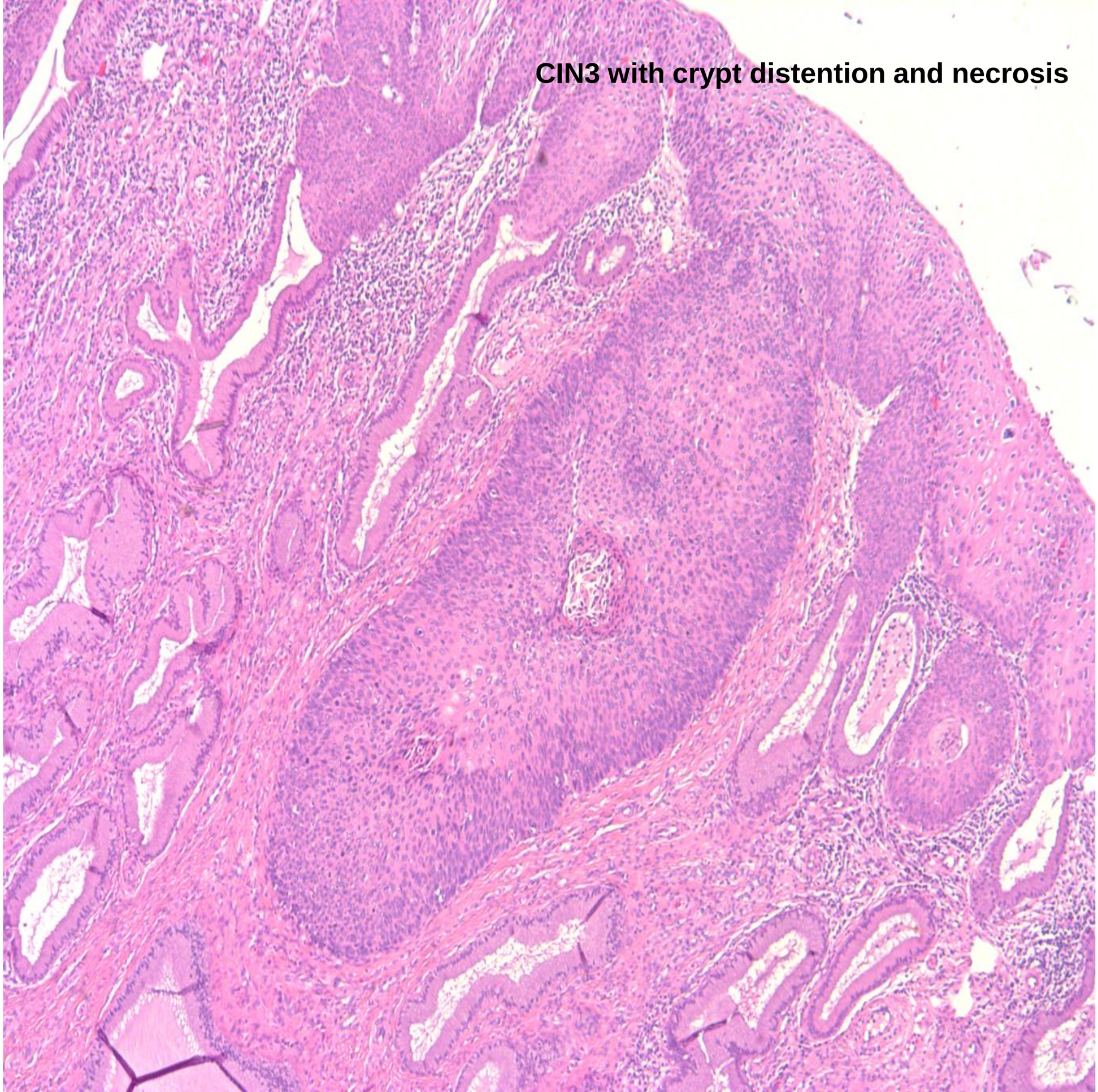
CIN3 with crypt distention and necrosis

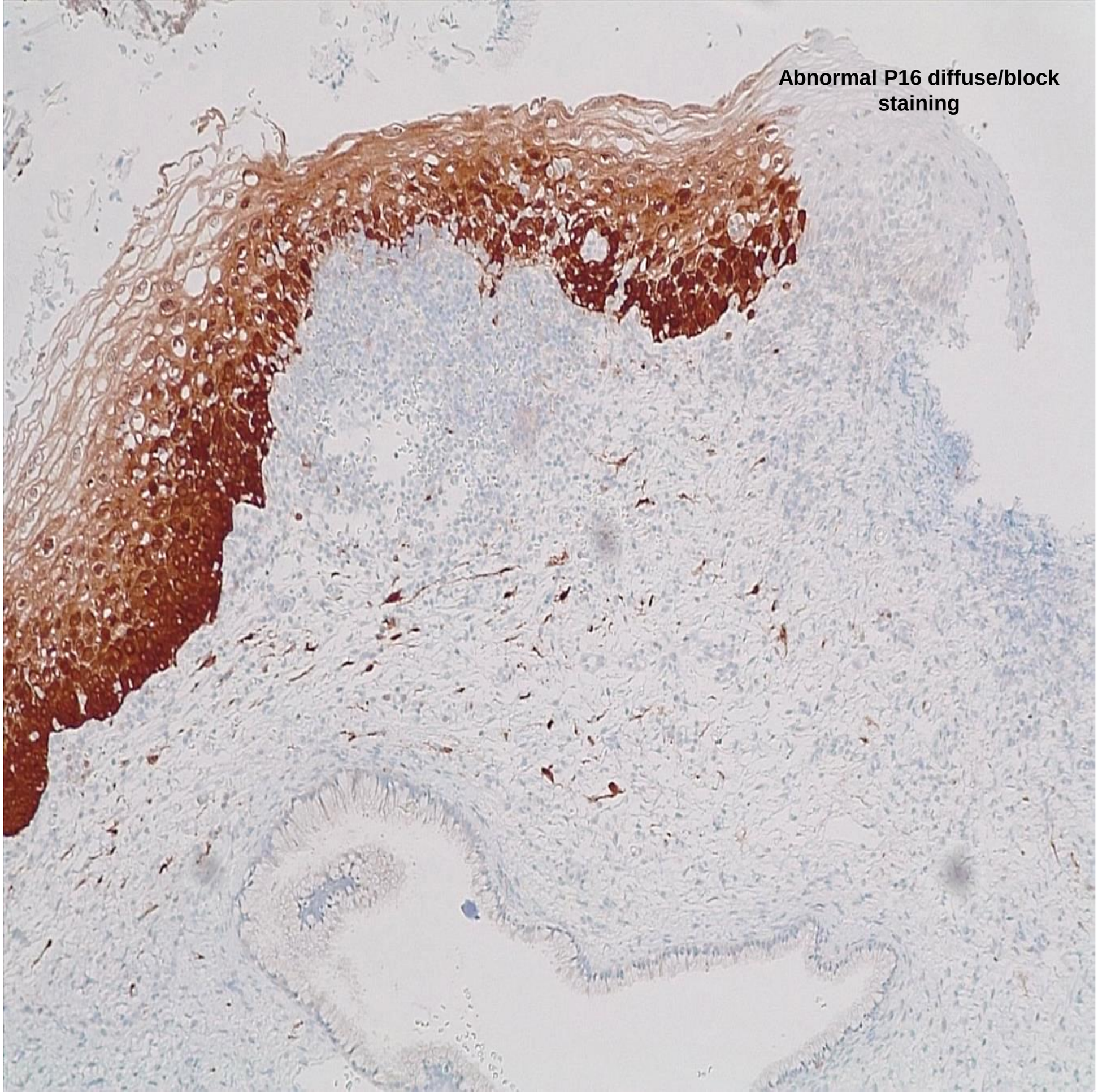
Abnormal P16 diffuse/block staining

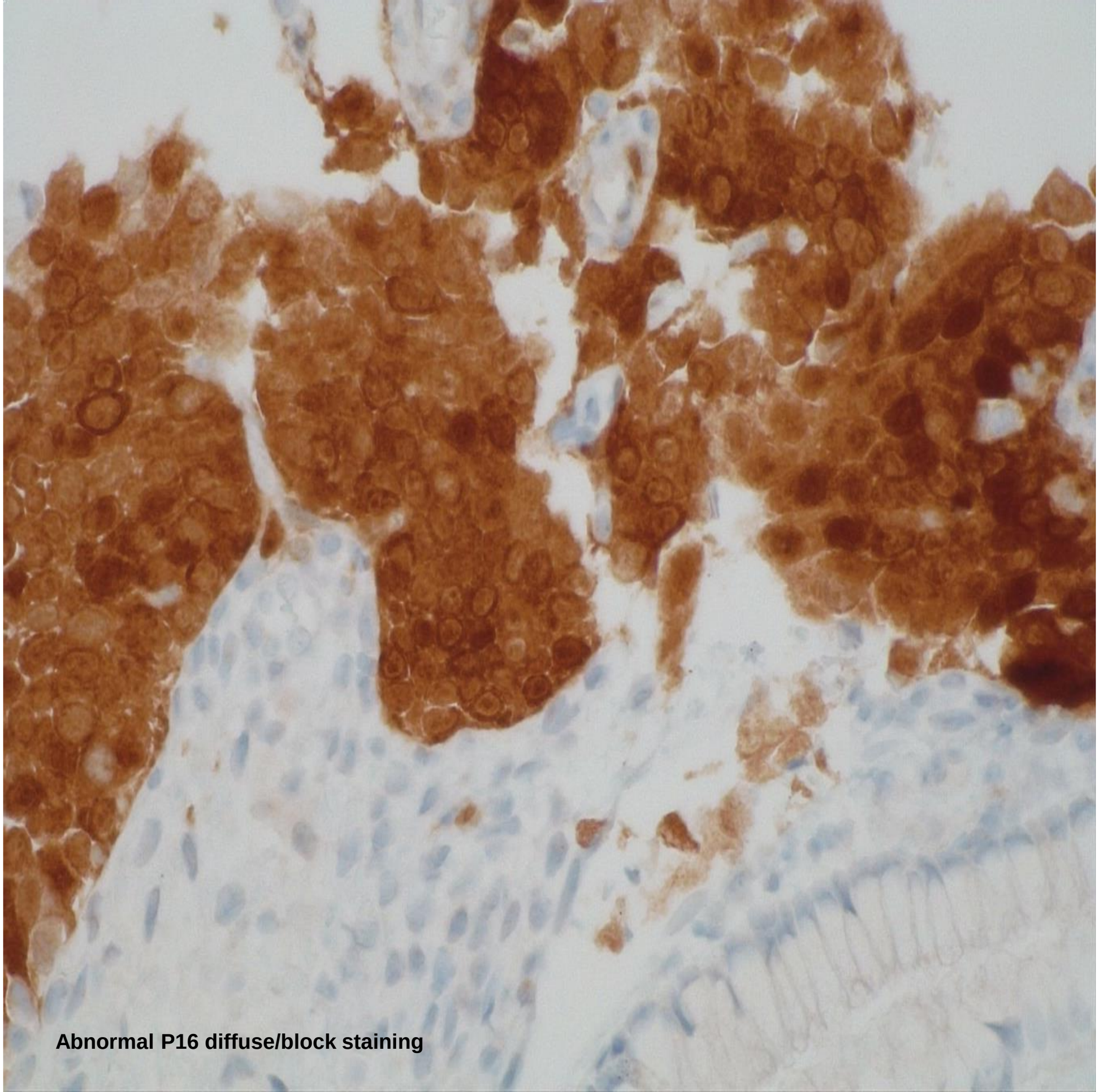

Abnormal P16 diffuse/block staining