The British Association of
Gynaecological Pathologists

17th Annual Meeting

- Challenges in Endometrial Biopsy Pathology Interpretation: Epithelial Entities.
- Joe Rabban MD MPH
- Pathology Department, University of California San Francisco, USA
- June 10, 2021

The British Association of Gynaecological Pathologists

Speaker disclosures

I have the following to disclose:

My spouse receives salary and stock options from Merck & Co.

I am not discussing any commercial products



International Journal of Gynecological Pathology
38:S1–S2, Lippincott Williams & Wilkins, Baltimore
Copyright © 2018 International Society of Gynecological Pathologists. Published by Wolters Kluwer Health, Inc.
on behalf of the International Society of Gynecological Pathologists.
OPEN

Editorial

The International Society of Gynecological Pathologists (ISGyP) Endometrial Carcinoma Project

W. Glenn McCluggage, F.R.C.Path., Anais Malpica, M.D., Xavier Matias-Guiu, M.D., Esther Oliva, M.D., and Vinita Parkash, M.D.

- **9 papers published January 2019 in Int. J. Gynecol. Pathol.**
- **All are OpenAccess at** https://journals.lww.com/intjgynpathology/toc/2019/01001
- **Consensus recommendations and guidelines for:**

Gross specimen processing and sampling
Diagnosis / tumor typing / differential diagnosis
Grading and staging
Lynch syndrome screening
Genomic classification
Clinical prognostic models

Challenges in Endometrial Biopsy Interpretation

Epithelial Entities

1. **Glandular proliferations:**

    - **Hyperplasia: is it atypical or not ?**
    - **Atypical hyperplasia versus grade 1 endometrioid carcinoma ?**

2. **Low grade endometrioid carcinoma:**

    - **Benign mimics**
    - **Variants that may mimic high grade cancers**

Two-Prong Approach to Endometrial Epithelial Abnormalities in Biopsies

1. **What is the dominant morphologic pattern ?**

2. **What are the major clinically relevant groups of diagnostic possibilities?**

Two-Prong Approach to Endometrial Epithelial Abnormalities in Biopsies

1. Morphologic Patterns

- Glandular
- Papillary
- Mucin-rich
- Clear cell-rich
- Squamous
- Solid
- Biphasic / spindled
- Necrotic

Two-Prong Approach to Endometrial Epithelial Abnormalities in Biopsies

2. Clinically relevant groups of diagnostic possibilities

- **Benign**
- **“Benign” but associated with neoplasia** *(clinical action advised)*
- **Precursor lesion**
- **Low risk cancer**
- **High risk cancer**
- **Secondary cancer**

Two-Prong Approach to Endometrial Epithelial Abnormalities in Biopsies

Targeted Differential Diagnosis

	Glandular	Papillary	Mucin-rich	Clear cells	Squamous	"Biphasic"	Solid
Benign	Disordered proliferative pattern	Surface papillary syncytial metaplasia	Microglandular endocervical hyperplasia	Arias stella reaction		Polyp	
Precursor	Atypical hyperplasia	Papillary proliferation of endometrium			Morular metaplasia		
Low risk cancer	Endometrioid carcinoma	Papillary variant endometrioid carcinoma	Mucin-rich endometrioid carcinoma	Endometrioid carcinoma with secretory change	Endometrioid carcinoma with squamous differentiation	CHEC APA Progestin treated cancer	Grade 2 endometrioid carcinoma
High risk cancer	Pseudoglandular serous carcinoma	Serous carcinoma Clear cell carcinoma		Clear cell carcinoma		Carcinosarcoma Dedifferentiated carcinoma	Undifferentiated carcinoma Serous carcinoma
Secondary cancer	Endocervical carcinoma Colon cancer	Endocervical carcinoma	Endocervical carcinoma Colon cancer		Cervical squamous cell carcinoma		

Outline of Talk

Challenges in Endometrial Biopsies

- Glandular
- Papillary
- Mucin-rich
- Squamous
- Clear cell-rich
- Solid
- Biphasic / spindled
- Necrotic

Practical Approaches to Common Problems

Glandular Pattern Pathology

- Benign

Disordered proliferative pattern
Hyperplasia without atypia
Polyp with gland crowding

- Low risk cancer / precursor

Atypical hyperplasia / EIN
Grade 1 endometrioid carcinoma
Progestin-treated residual endometrioid carcinoma

- High risk cancer

Serous carcinoma (pseudo-glandular pattern variant)
Mesonephric-like carcinoma

- Secondary cancer

Endocervical adenocarcinoma
Colorectal adenocarcinoma

Glandular Pattern Pathology

- Benign

  Disordered proliferative pattern

  Hyperplasia without atypia

  Polyp with gland crowding

- Low risk cancer / precursor

  Atypical hyperplasia / EIN

  Grade 1 endometrioid carcinoma

  Progestin-treated residual endometrioid carcinoma

- High risk cancer

  Serous carcinoma (pseudo-glandular pattern variant)

  Mesonephric-like carcinoma

- Secondary cancer

  Endocervical adenocarcinoma

  Colorectal adenocarcinoma

Endometrial Hyperplasia without Atypia

Definition (5th W.H.O):

- **Increased endometrial gland-to-stroma ratio**
- **Tubular, branching, and/or cystically dilated glands**
- **Uniform nuclear appearance across entire sample**
  no focal areas of nuclear atypia
- **No clinical need to distinguish simple verus complex**

Endometrial Hyperplasia

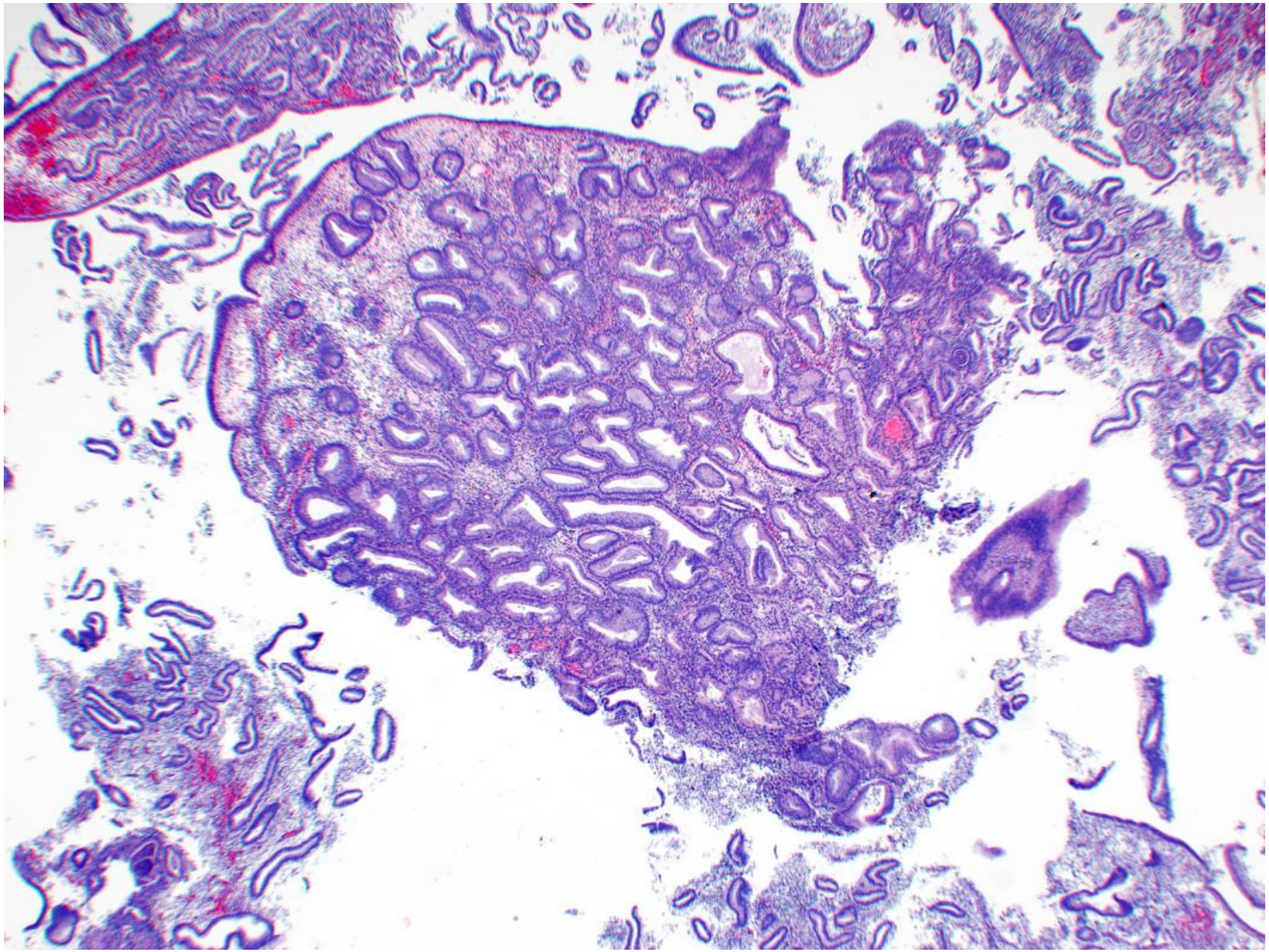

Endometrial Hyperplasia

Without Atypia

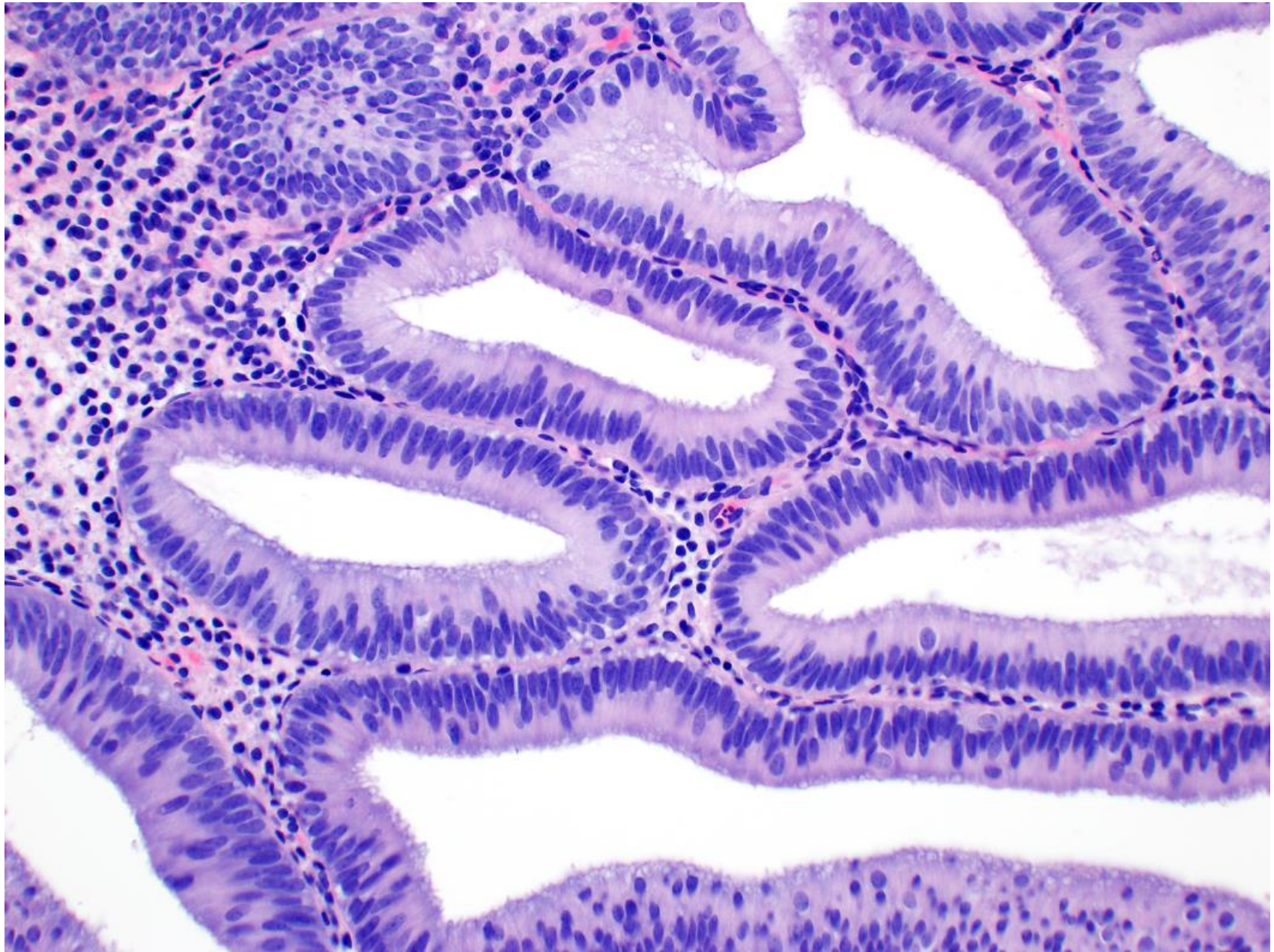

Endometrial Hyperplasia without Atypia

Definition (5th W.H.O):

- **Increased endometrial gland-to-stroma ratio** →

Practical Challenges

<u>No objective definitions for:</u>

- **"Increased" gland/stroma ratio**
- **Minimum size requirement**

Practical Approach (subjective)

- **Set normal proliferative pattern endometrium as the <u>reference</u> for normal gland/stroma ratio**

  up to ~50% glands / ~50% stroma

- **Minimum size remains subjective**

“Gland-o-gram”

Visual reference for gland / stroma ratio

~33%



~50%



~75%



~90%



Endometrial Hyperplasia without Atypia

Spectrum of crowding and size of focus

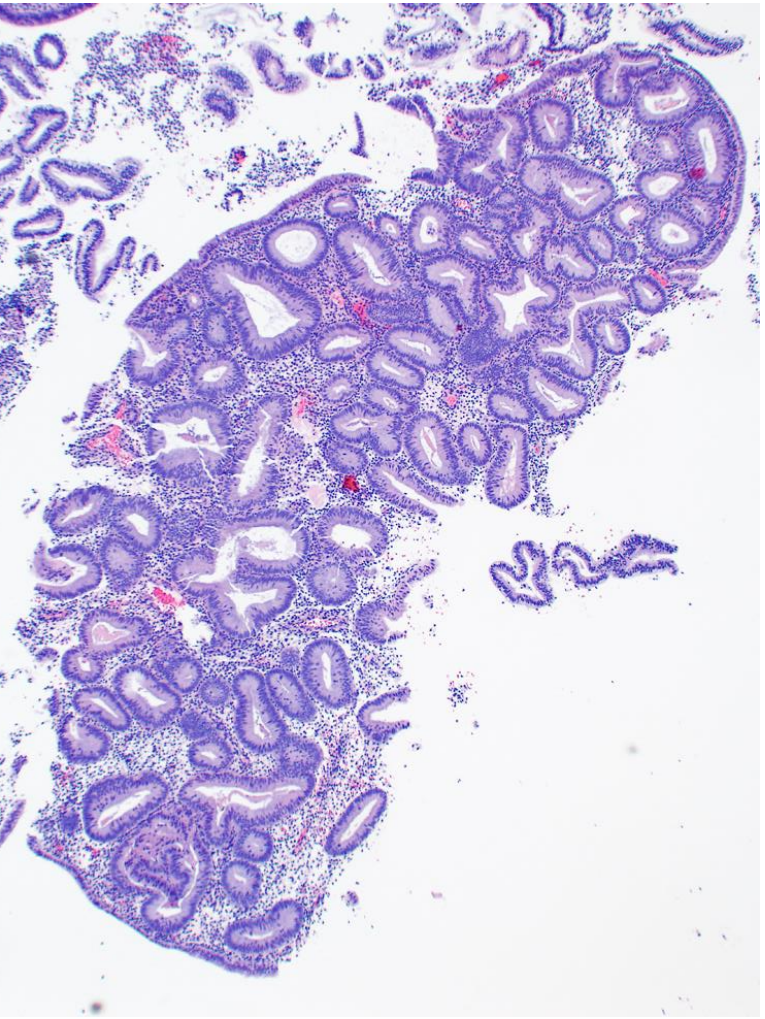

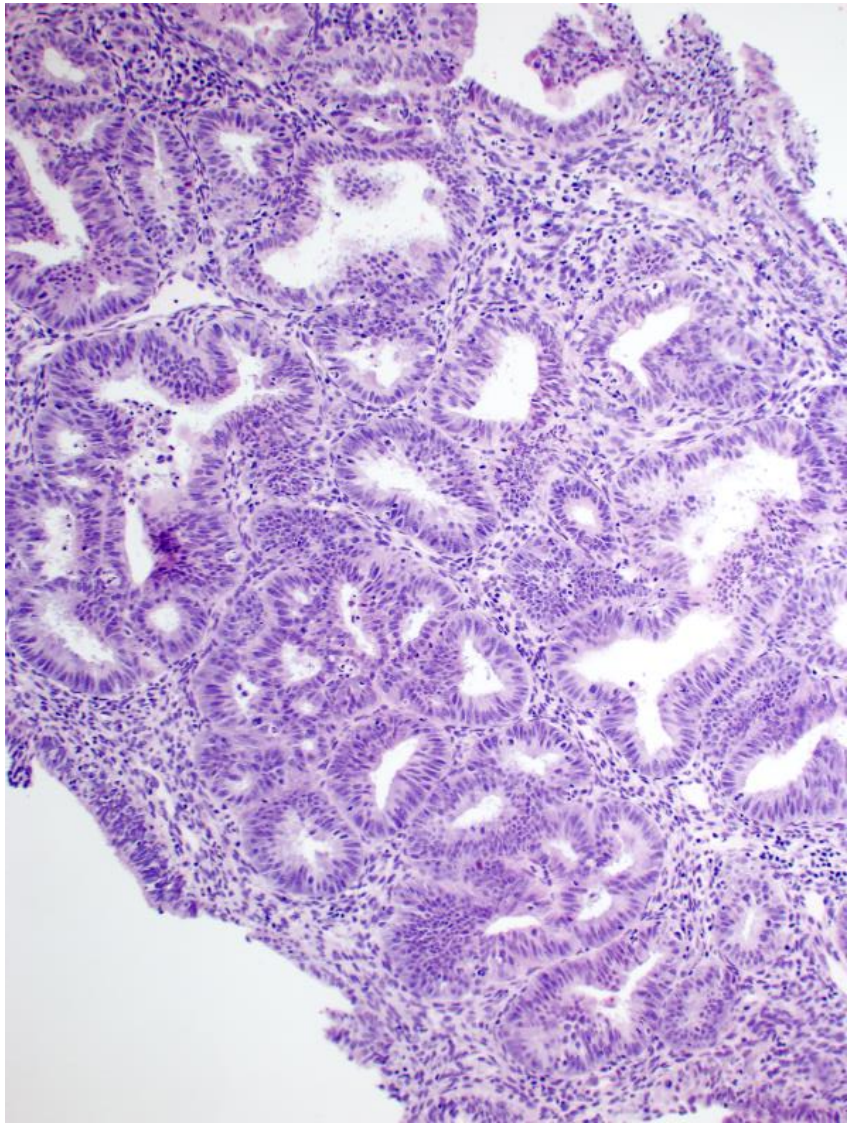

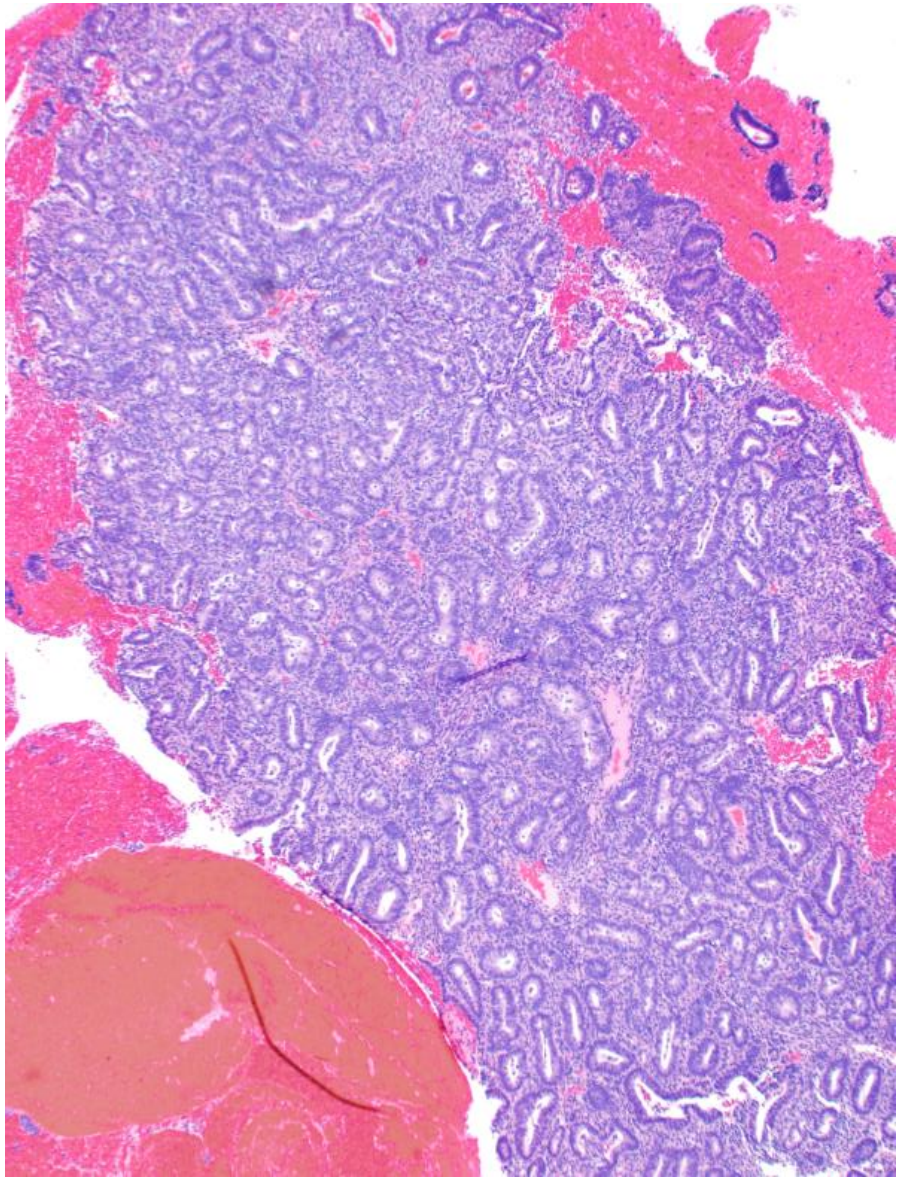

? Endometrial Hyperplasia ?

? Crowded enough ?

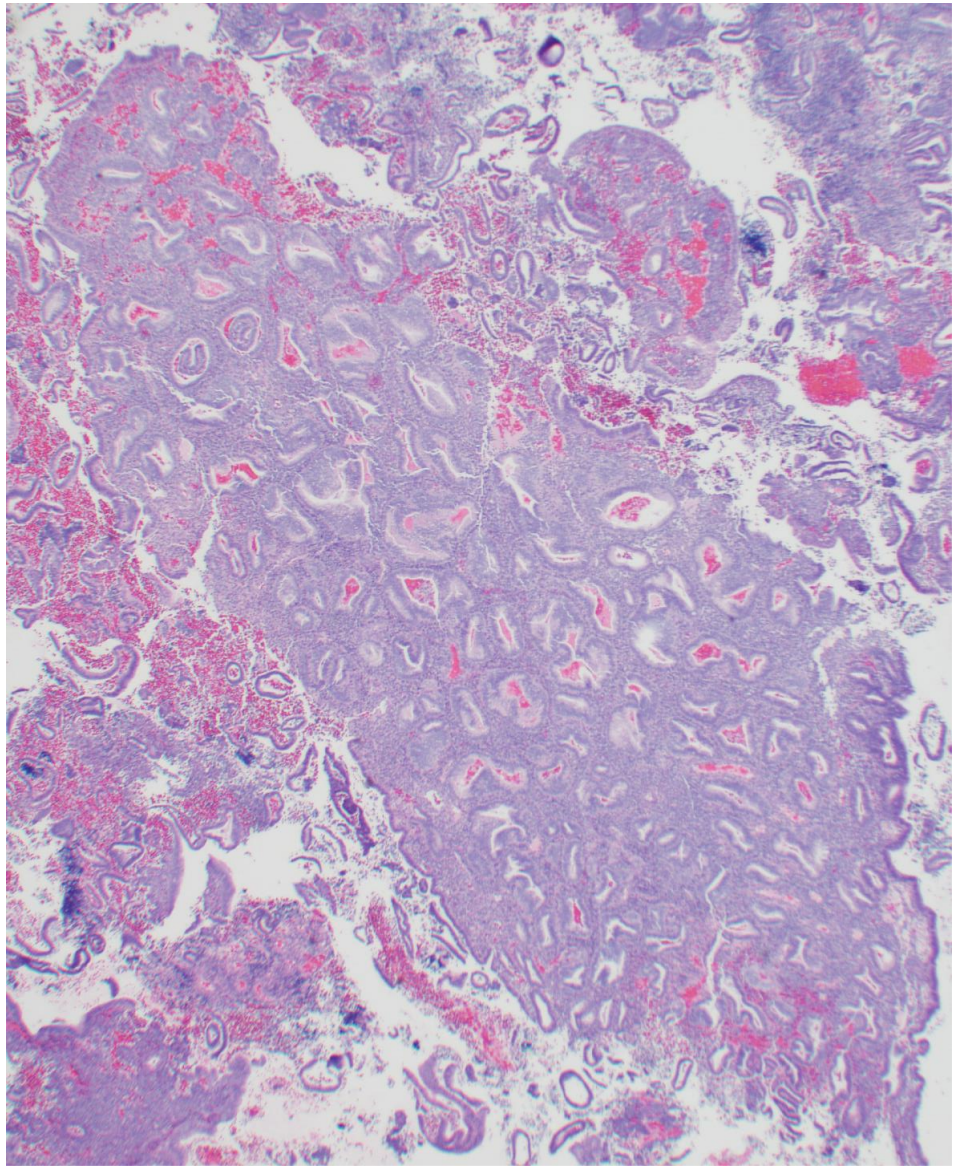

? Large enough focus ?

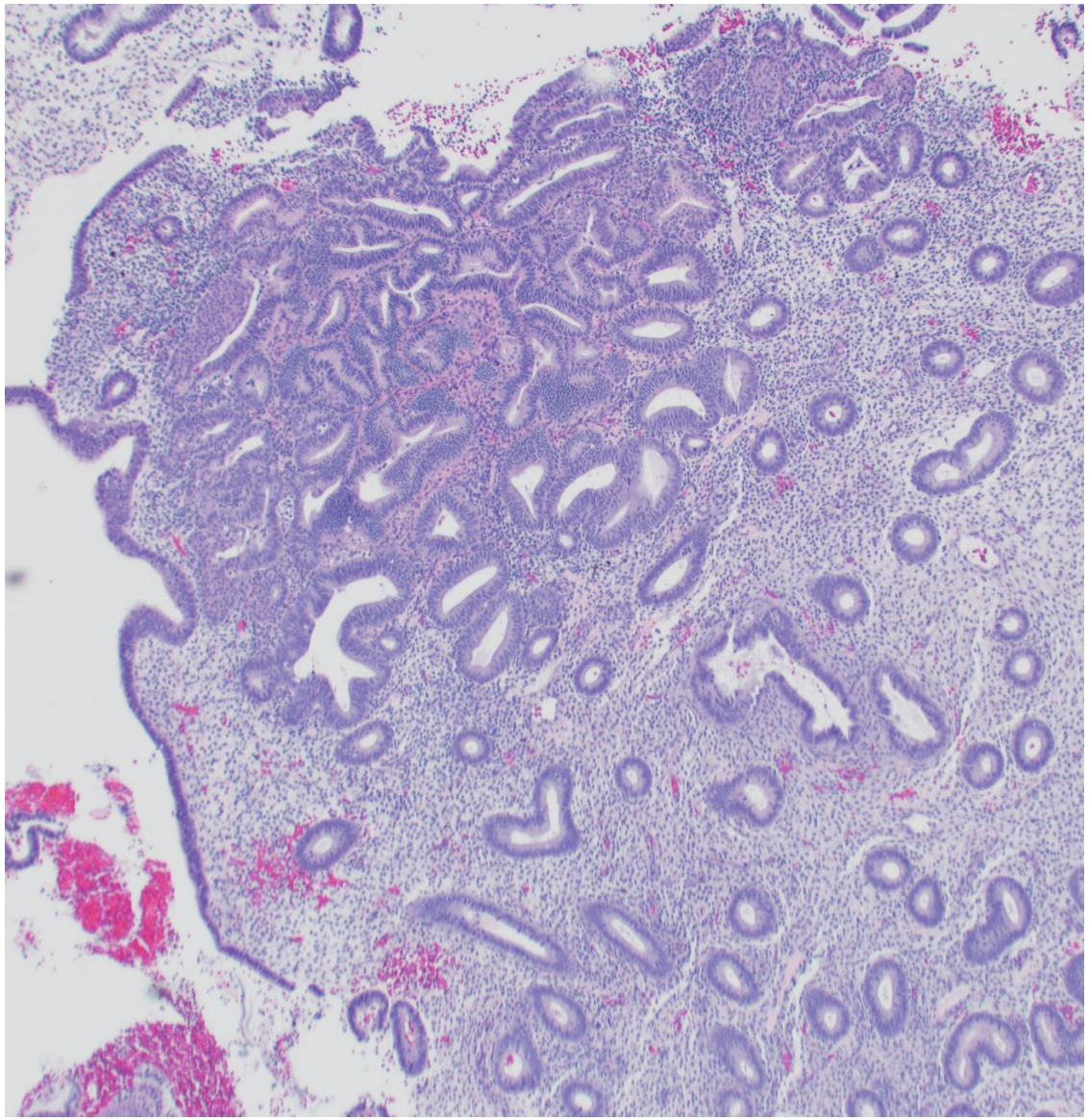

Endometrial Hyperplasia without Atypia

Definition (5th W.H.O):

- Increased endometrial gland-to-stroma ratio
- **Tubular, branching, and/or cystically dilated glands** → **Overlap with "disordered proliferative pattern"**

Practical Challenges

Disordered Proliferative Pattern Endometrium

Not Hyperplasia

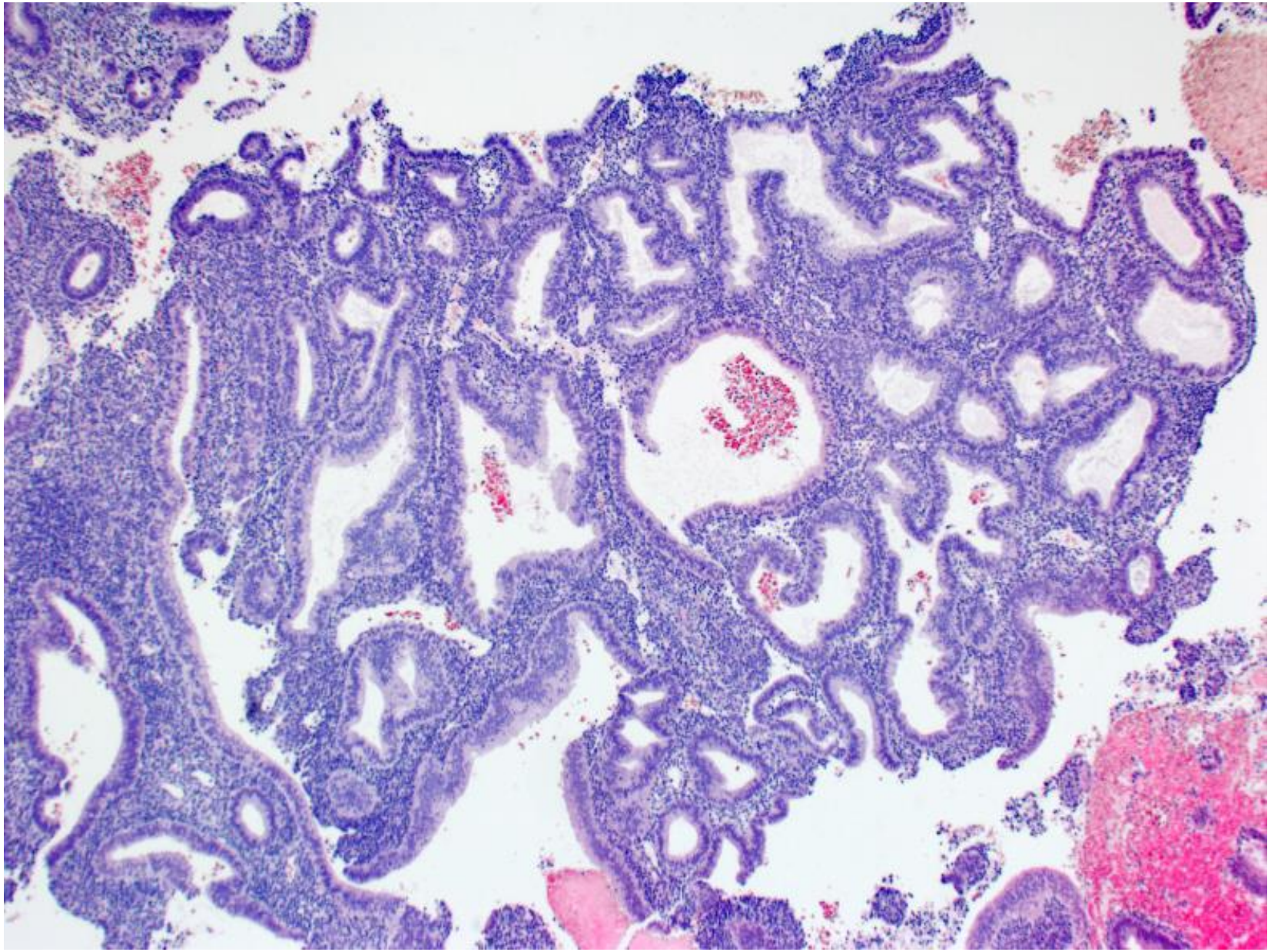

Endometrial Hyperplasia without Atypia

Definition (5th W.H.O):

- Increased endometrial gland-to-stroma ratio
- Tubular, branching, and/or cystically dilated glands
- **Uniform nuclear appearance across entire sample**
  no focal areas of nuclear atypia

Practical Challenges

Metaplasias may mimic atypia

- Tubal (ciliated)
- Hobnail
- Eosinophilic
- Syncytial

Tissue Artifacts that Mimic Hyperplasia



Telescope artifact

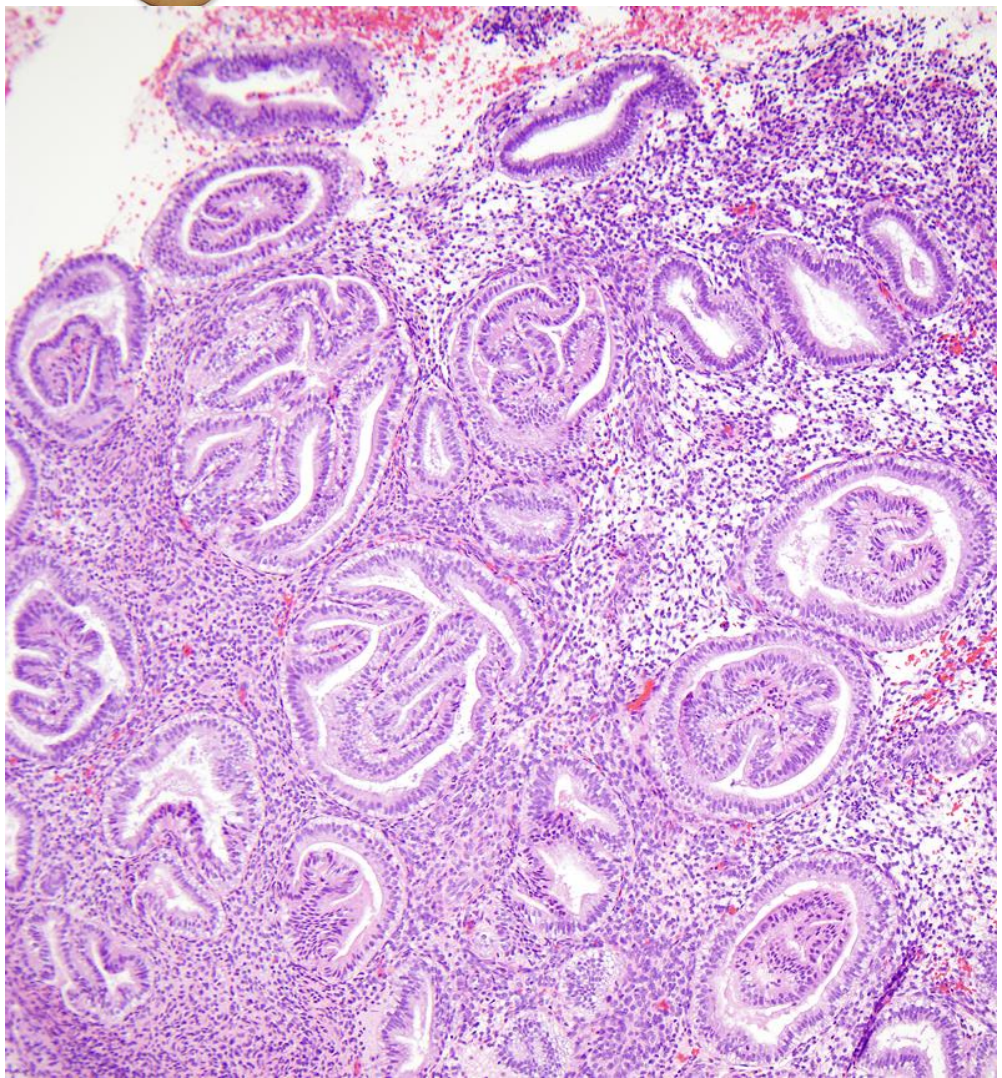

Glands stripped away from stroma

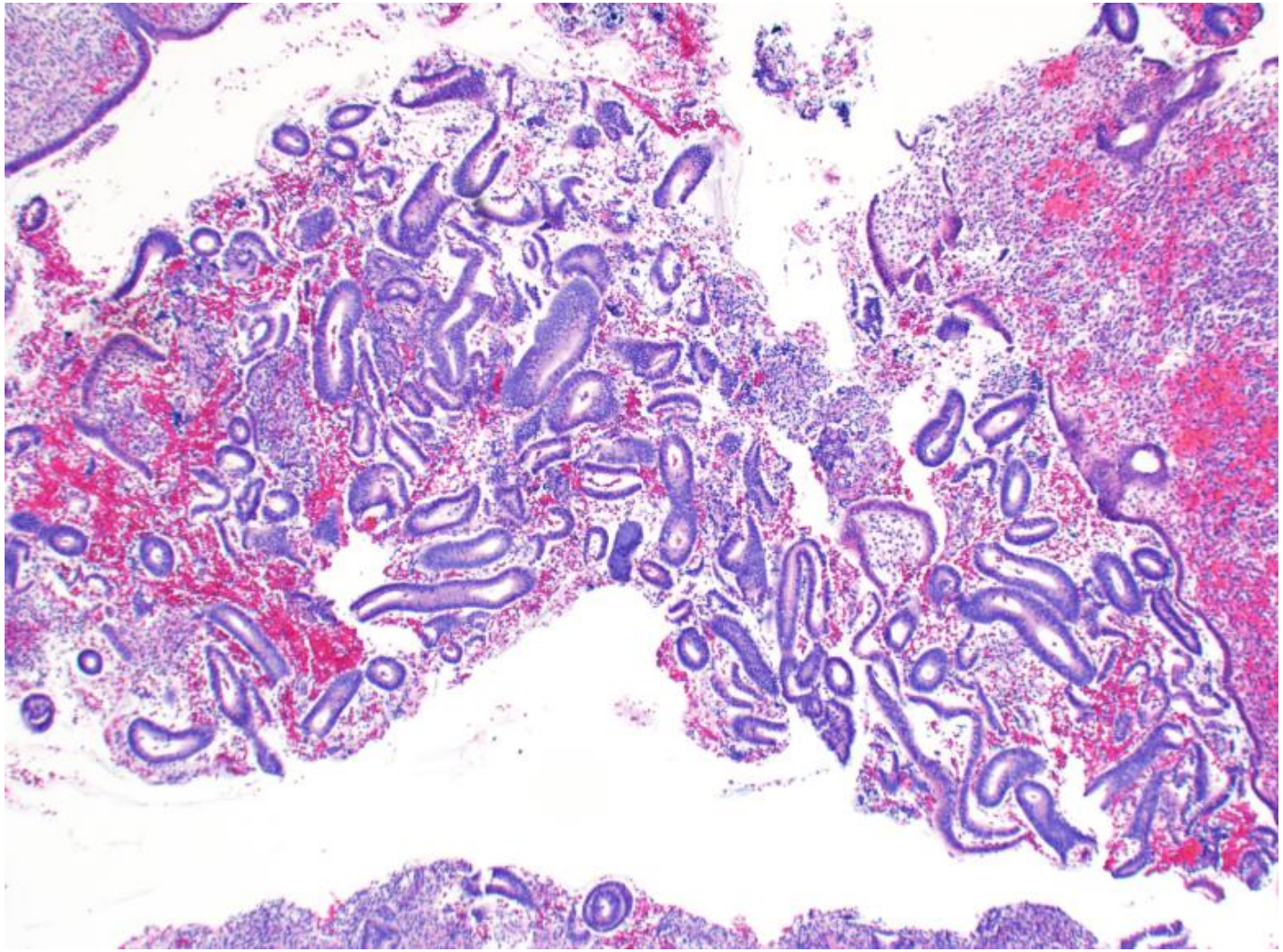

Hormonal Changes that Mimic Hyperplasia

Endometrial Breakdown

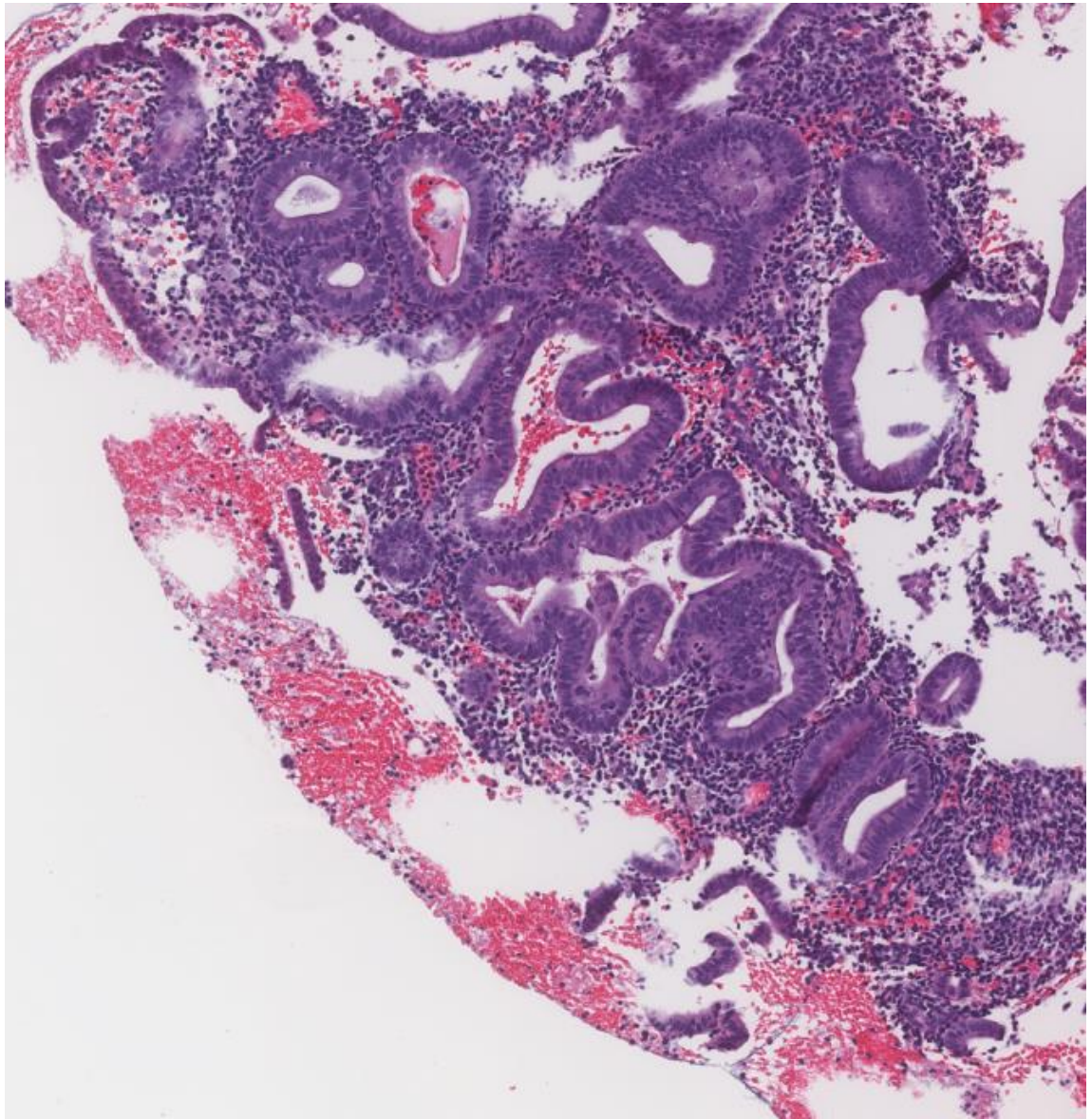

Gestational endometrium

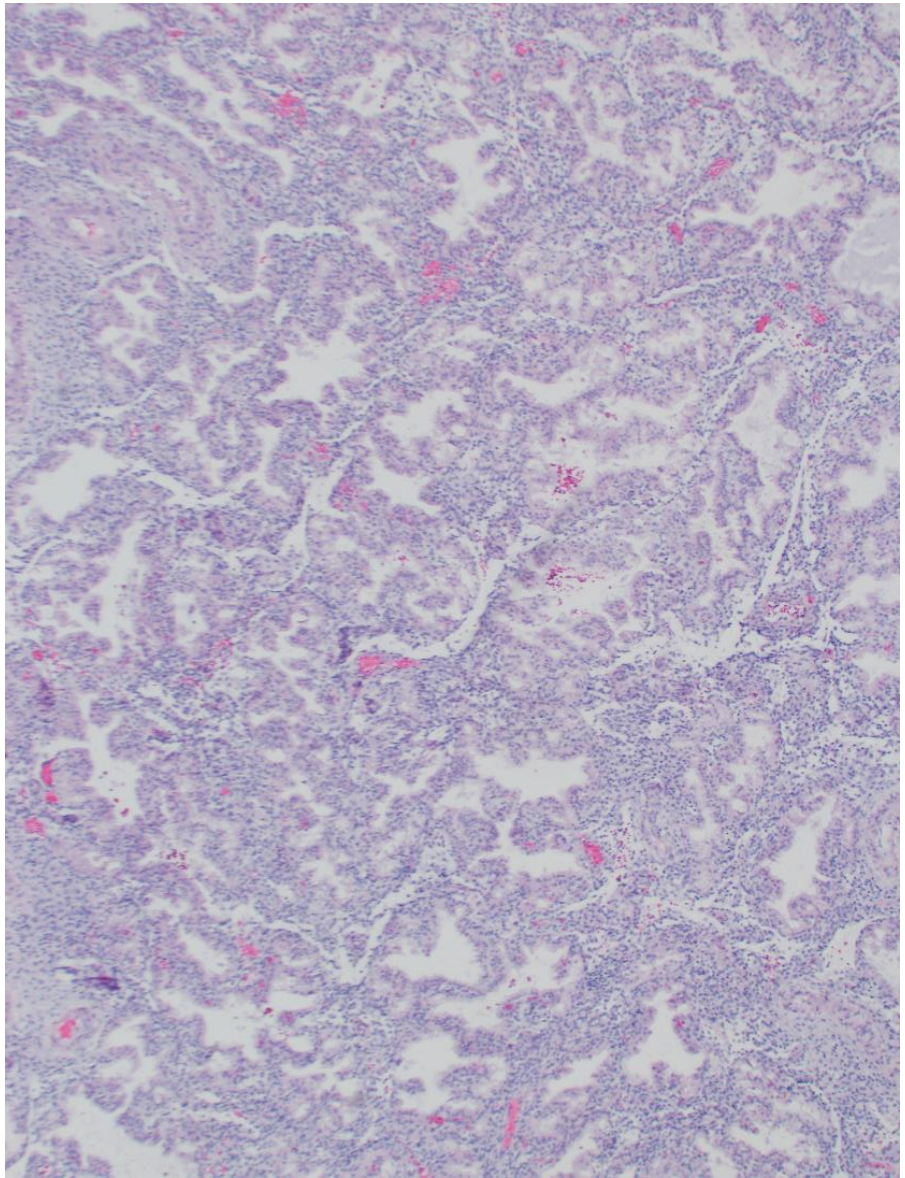

Glandular Pattern Pathology

- Benign



Disordered proliferative pattern

Polyp with gland crowding

Hyperplasia without atypia

- Low risk cancer / precursor

Atypical hyperplasia

Grade 1 endometrioid carcinoma

Progestin-treated residual endometrioid carcinoma

- High risk cancer

Serous carcinoma (pseudo-glandular pattern variant)

- Secondary cancer

Endocervical adenocarcinoma

Colorectal adenocarcinoma

Gland Crowding in Endometrial Polyp

A Continuous Spectrum

- **Normal range of crowded glands**
- **Hyperplasia without atypia**
- **Hyperplasia with atypia**
- **Endometrioid adenocarcinoma, grade 1**



- *Criteria are subjective*
- *Observer differences may occur*

Gland Crowding in Endometrial Polyp

Likely within Upper Limit of Normal

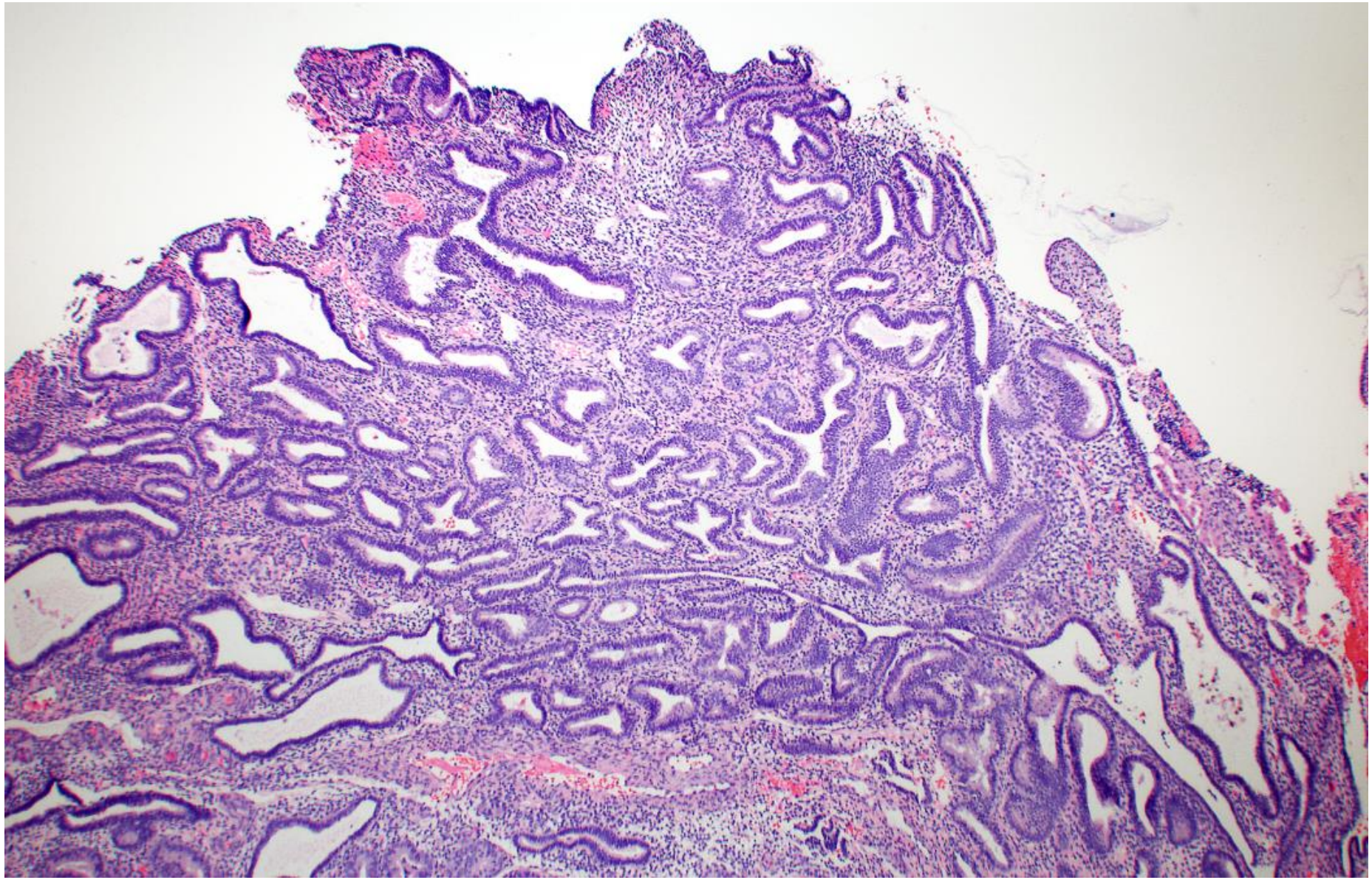

Gland Crowding in Endometrial Polyp

Hyperplasia

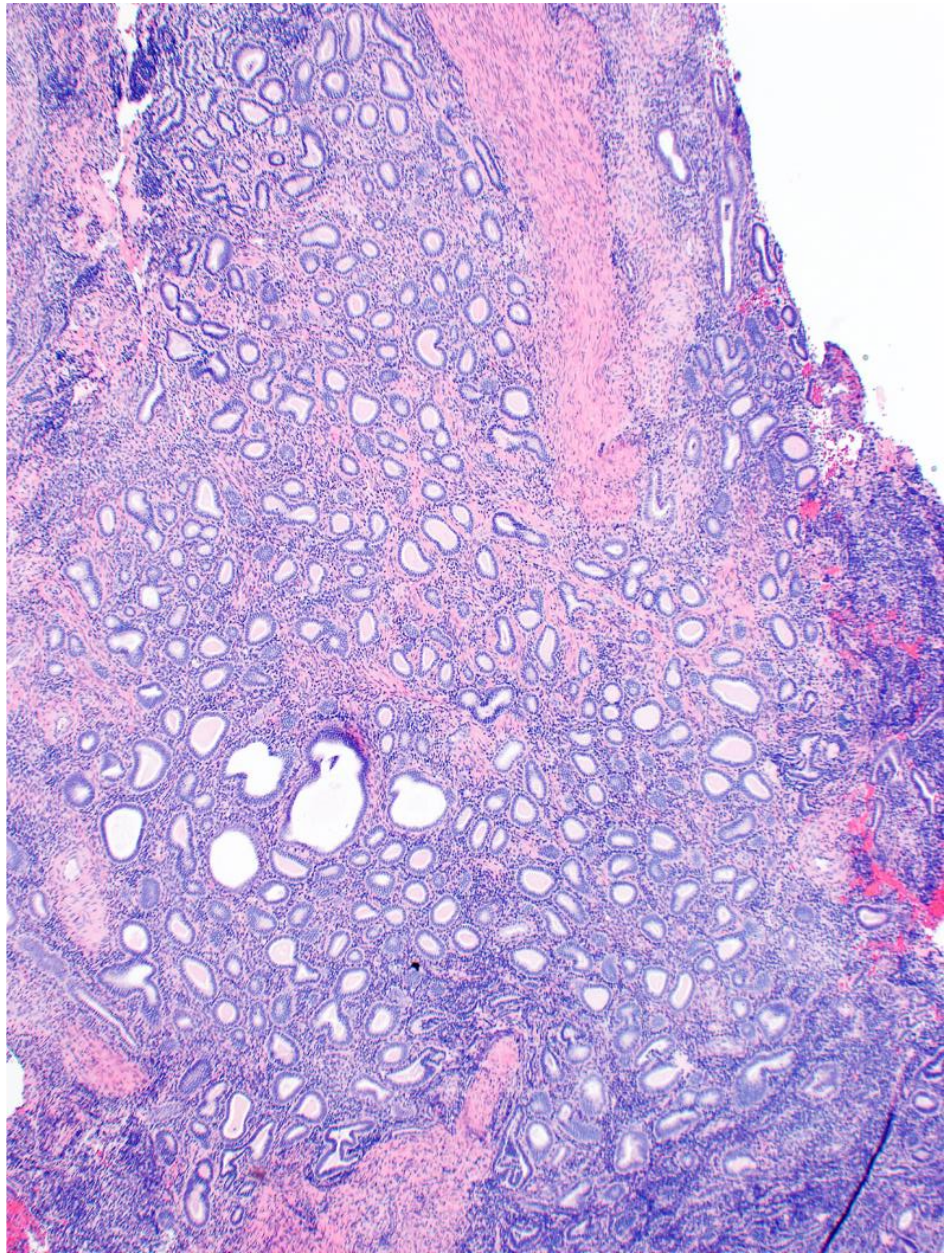

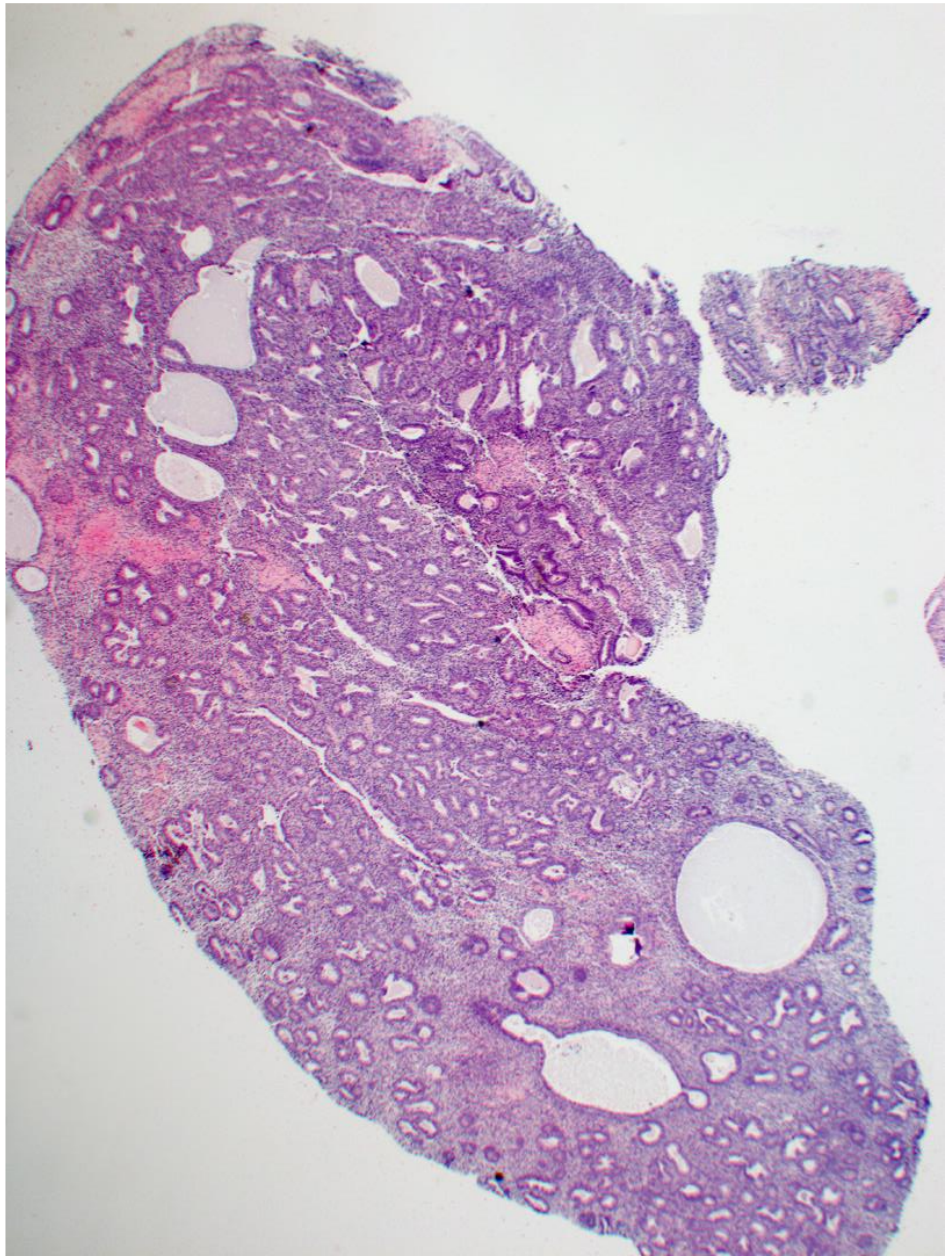

Glandular Pattern Pathology

- Benign
  - Disordered proliferative pattern
  - Hyperplasia without atypia
  - Polyp with gland crowding
- Low risk cancer / precursor
  - **Atypical hyperplasia / EIN**
  - Grade 1 endometrioid carcinoma
  - Progestin-treated residual endometrioid carcinoma
- High risk cancer
  - Serous carcinoma (pseudo-glandular pattern variant)
  - Mesonephric-like carcinoma
- Secondary cancer
  - Endocervical adenocarcinoma
  - Colorectal adenocarcinoma

Atypical Endometrial Hyperplasia

Definition (5th W.H.O):

- **Increased endometrial gland-to-stroma ratio**
- **Altered cytologic appearance**
  (compared to background)

- **Findings are <u>distinct</u> from background glands**
- **Pure metaplasia must be excluded**
- **No clinical need to distinguish simple versus complex**

Clinical Significance of W.H.O. Atypical Hyperplasia

Hyperplasia	Risk for progression to cancer	Management
with atypia	**23% to 52%**	**Hysterectomy** (some indications for hormonal therapy)
without atypia	**2%**	**Symptomatic**

Caveats:

- **Reproducibility is a well-known problem**
  (even amongst specialist pathologists)
- **Over-diagnosis and under-diagnosis may occur**

Kurman et al. Cancer. 1985; 56:403-12.
Horn et al. Int J Gyn Cancer 2004
ACOG Committee Opinion 631; May 2015

Atypical Endometrial Hyperplasia

Definition (5th W.H.O):

- **Increased endometrial gland-to-stroma ratio** →

Practical Challenges

No objective definitions for:

- **“Increased” gland/stroma ratio**
- **Minimum size requirement**

Atypical Endometrial Hyperplasia

Definition (5th W.H.O):

- Increased endometrial gland-to-stroma ratio
- **Altered cytologic appearance**
  (compared to background)

Practical Challenges

No objective definition of "altered"

4th W.H.O. criteria:
(not mentioned in 5th W.H.O.)

- **Round nuclei**
- **Nucleoli**
- **Nuclear pleomorphism**
- **Nuclear enlargement**

- **Vesicular chromatin** (other experts)

Atypical Endometrial Hyperplasia

Definition (5th W.H.O):

- **Increased endometrial gland-to-stroma ratio**
- **Altered cytologic appearance**
  (compared to background)
- **Findings are <u>distinct</u> from background glands**

Practical Challenges

- **Difficult to appreciate in small or fragmented samples**

Atypical Endometrial Hyperplasia

Definition (5th W.H.O):

- **Increased endometrial gland-to-stroma ratio**
- **Altered cytologic appearance**
  (compared to background)
- **Findings are distinct from background glands**
- **Pure metaplasia must be excluded**

Practical Challenges

- **Metaplasia may mimic atypia**
- **Metaplasia and atypia may co-exist**

Endometrial Hyperplasia

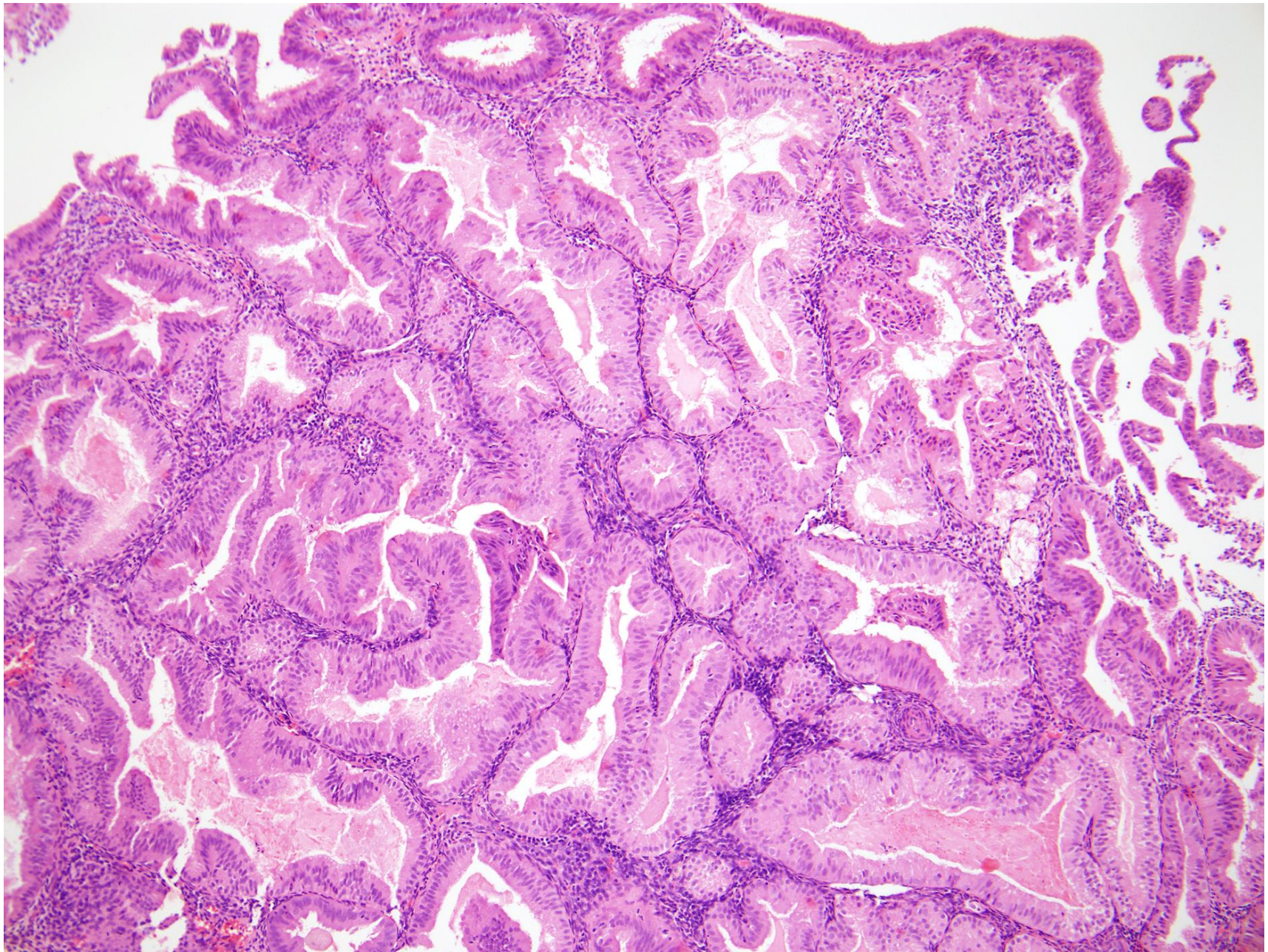

Endometrial Hyperplasia with Atypia

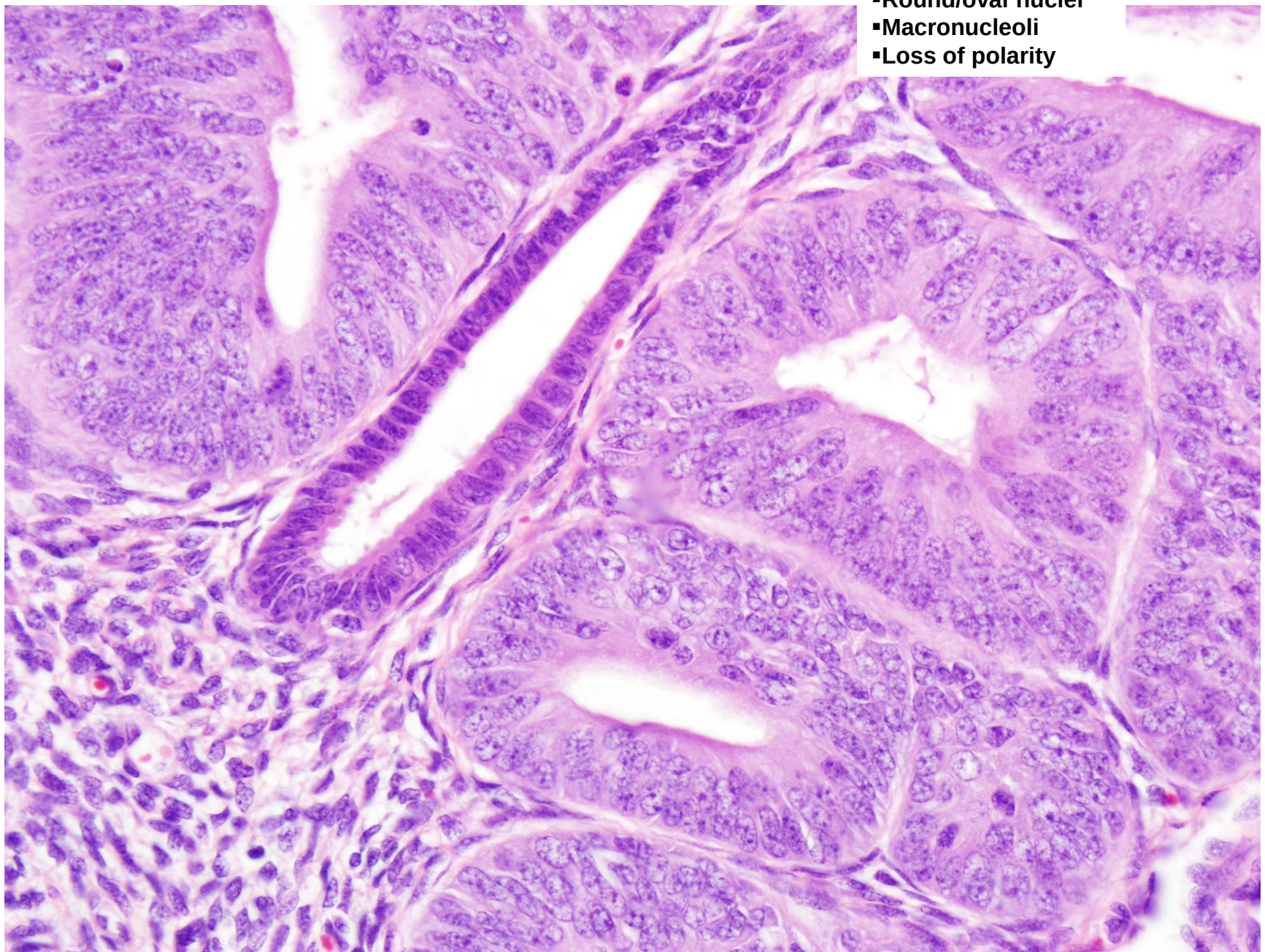

- Round/oval nuclei
- Macronucleoli
- Loss of polarity

Endometrial Hyperplasia with Atypia

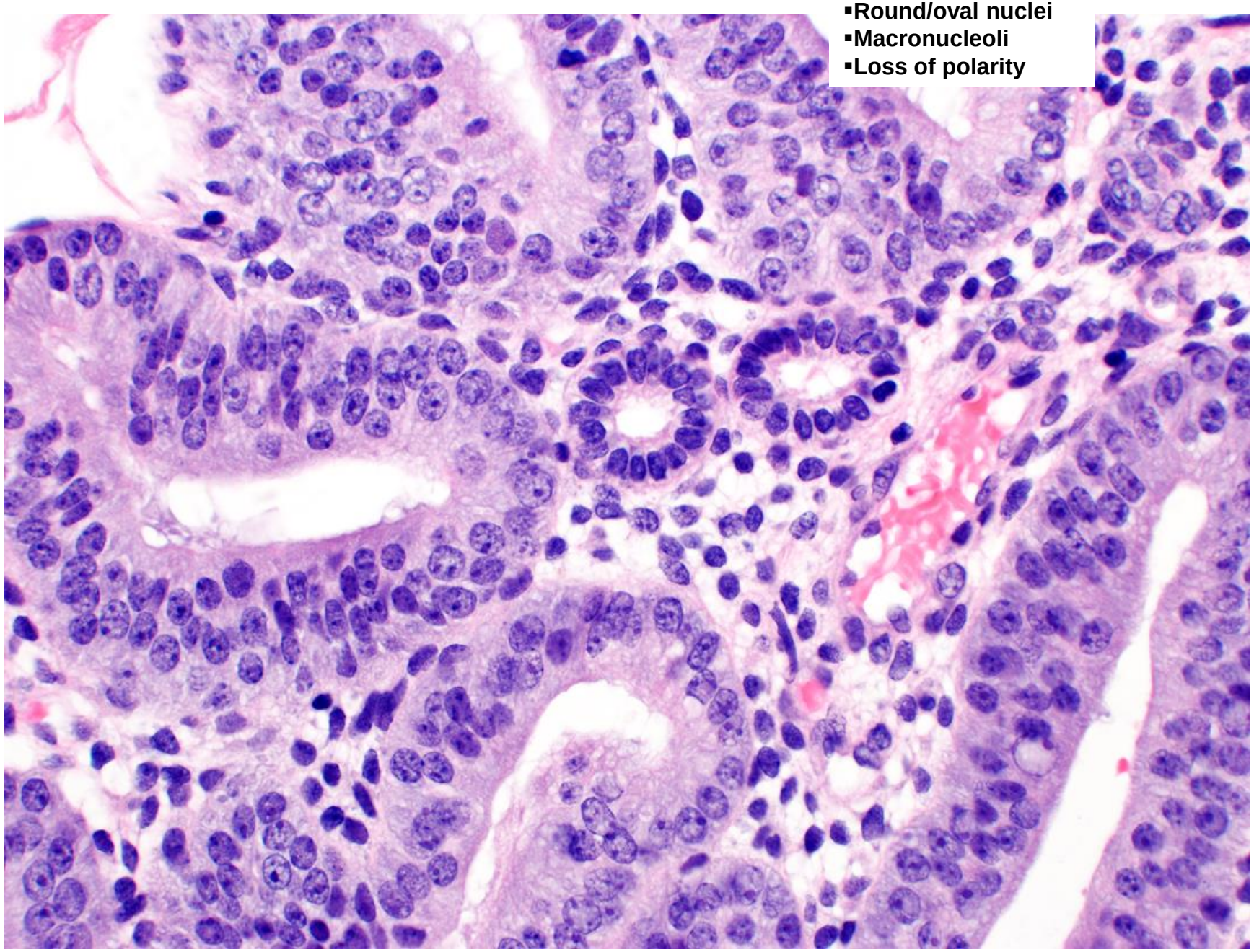

Endometrial Hyperplasia with Atypia

- Round/oval nuclei
- Loss of polarity
- Vesicular chromatin

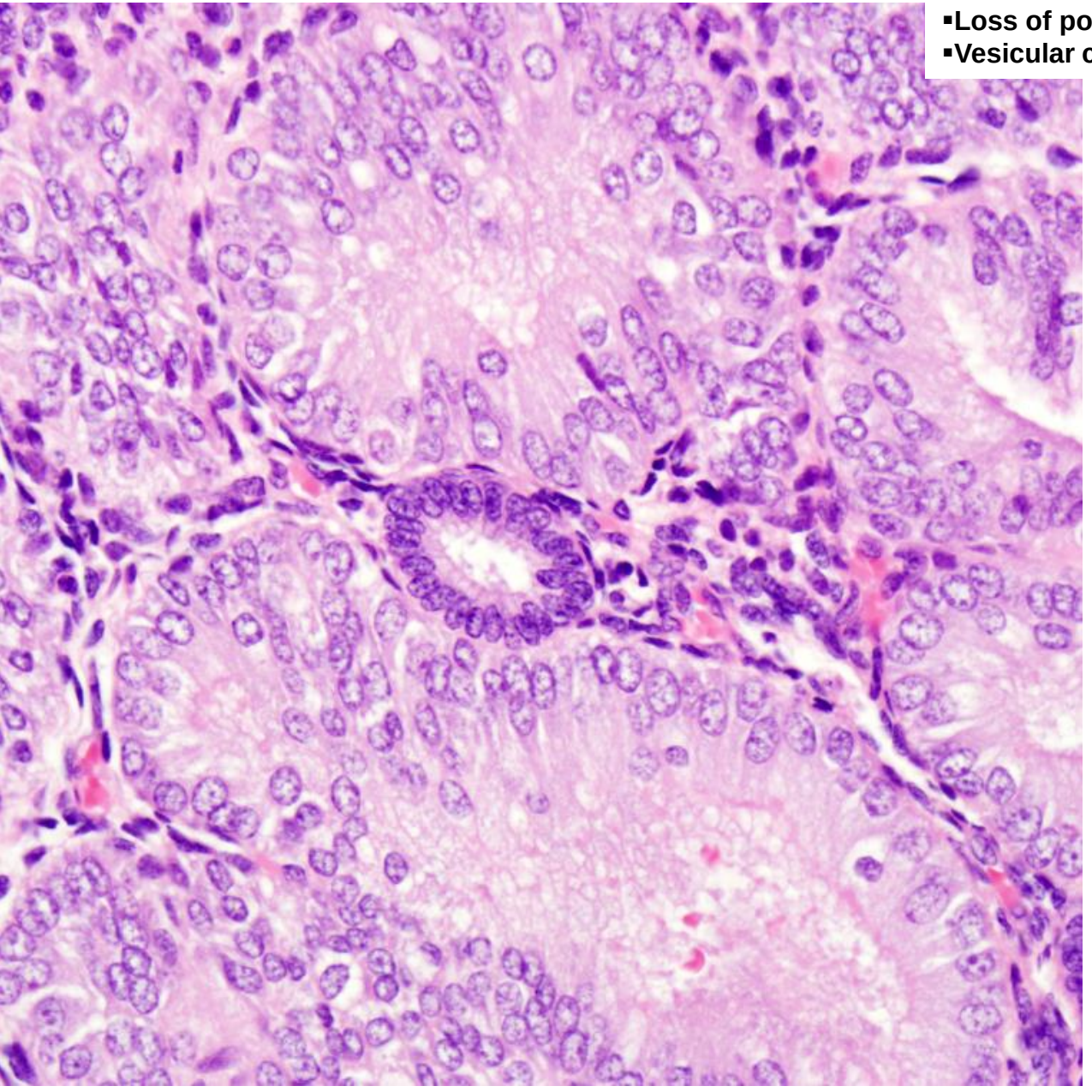

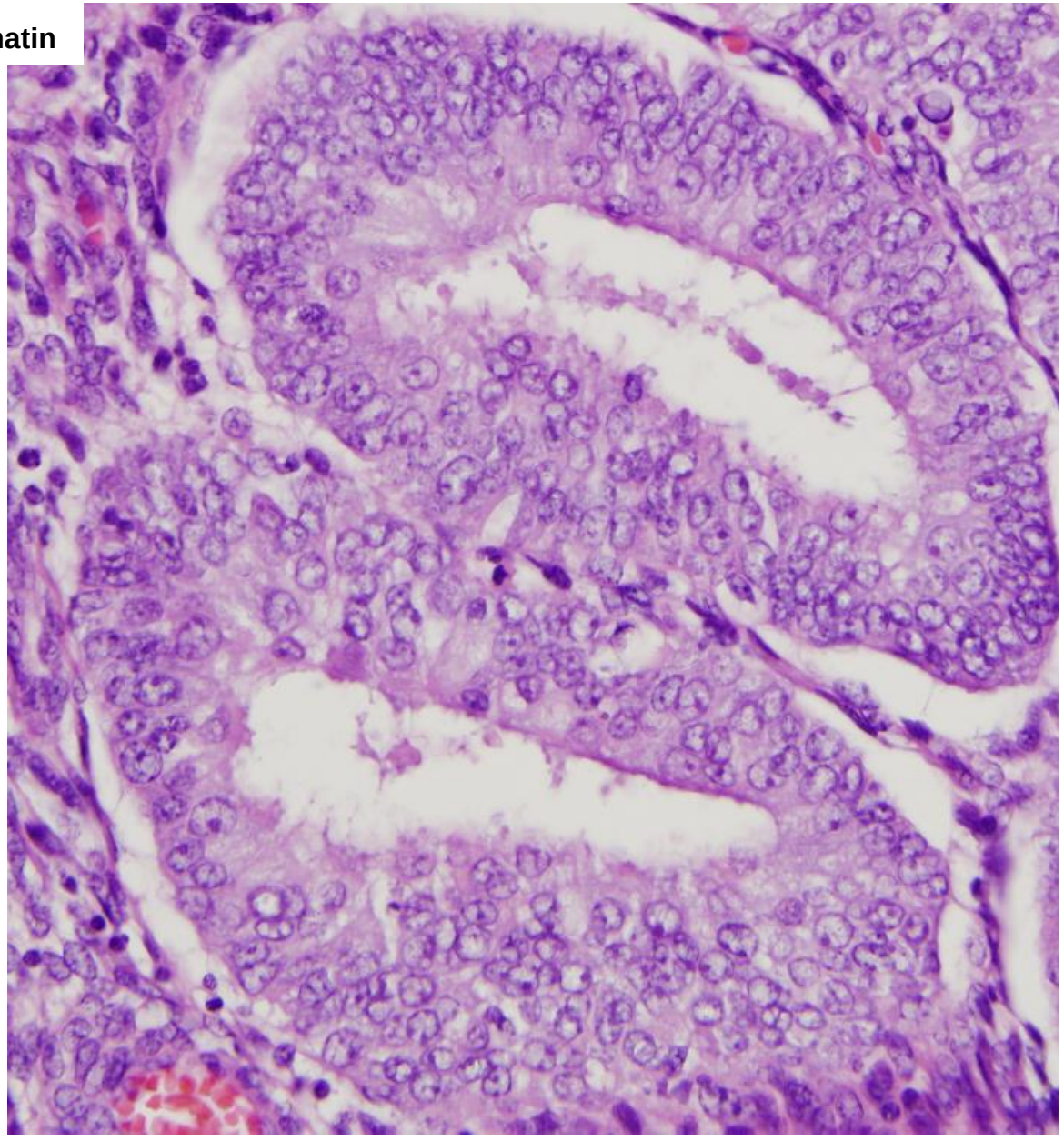

Endometrioid Intraepithelial Neoplasia (EIN)

Criteria:

1. **Area of glands is more than area of stroma**
2. **Crowded glands must be > 1 mm** **(~ half field @ 10x obj.)**
3. **Cytology must look different from adjacent normal glands**

Baak et al. Cancer 2005; 103: 2304-2312

- ***Glands > Stroma***
- ***Lesion > 1mm***

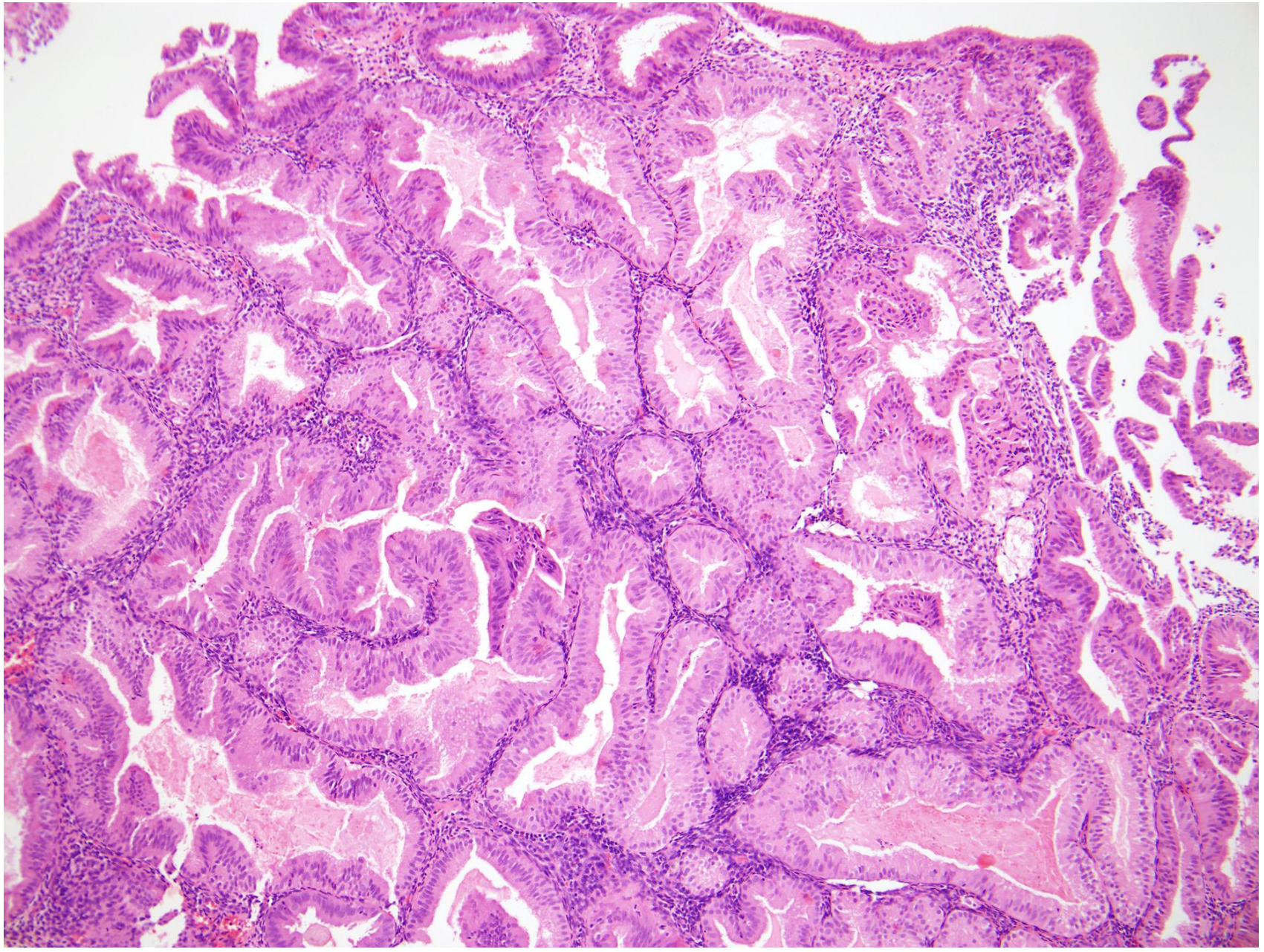

- ***Glands > Stroma***
- ***Lesion > 1mm***
- ***Cytology is different than background***

EIN

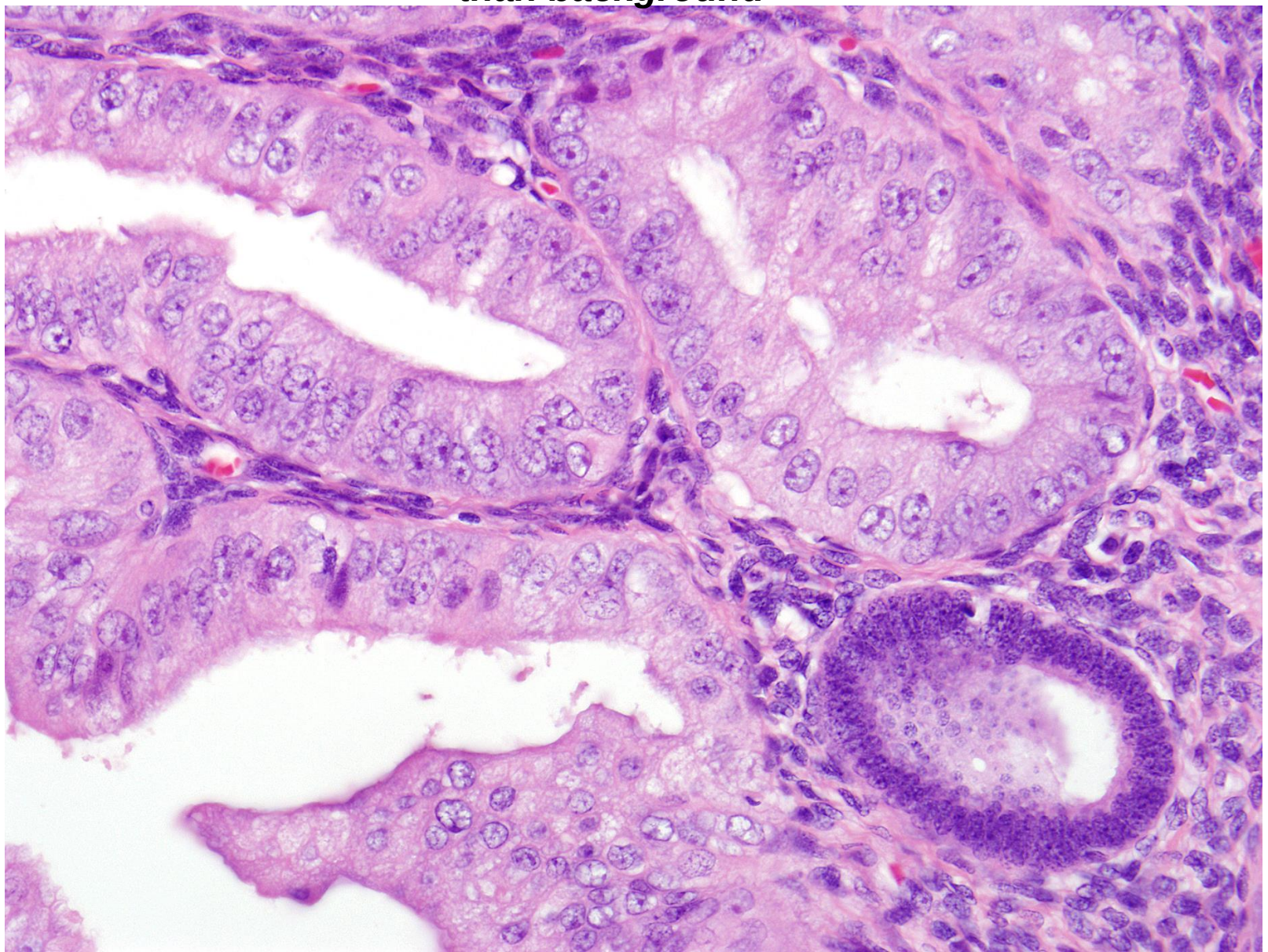

Clinical Significance of EIN

EIN	Risk for progression to cancer
Present	19% to 32%
Absent	0% to <0.6%

Hecht et al. Mod Pathol 2005
Baak et al. Cancer 2005

WHO Hyperplasia	Risk for progression to cancer
with atypia	23% to 52%
without atypia	2%

Kurman et al. Cancer 1985
Horn et al. Int J Gyn Cancer 2004

Practical Note: **Reproducibility is <u>same</u> for both systems**

Ordi 2013 Histopathology
Usubutun. 2012 Mod Pathol
Kane. 2012 IJGP

Which System Should Be Used: WHO or EIN

Professional Organization Consensus Statement	Recommendation
British Association of Gynecological Pathologists **RCPath Tissue Pathways** www.rcpath.org 2015	**WHO** (no mention of EIN)
National Comprehensive Cancer Network Guidelines Uterine Neoplasms Version 2.2018 — May 25, 2018	**Precursor lesions are not addressed.**
International Society of Gynecological Pathologists Endometrial Cancer Reporting Recommendations Rabban et al. Int J Gyn Pathol. 2019; 38: S25-S39	**WHO and EIN are equivalent.** Either are OK to use.
College of American Pathologists Cancer Checklist Protocol for Endometrial Cancer Version: Endometrium 4.0.0.0, June 2017	**WHO** (avoid EIN)
American College of Obstetricians & Gynecologists* SGO Committee Recommendation Ob Gyn. 2015; 125: 1272-1278	**EIN** (avoid WHO)

* no pathologists on the consensus panel

Practical strategy:

Any change to your current practice should only be considered with direct engagement of your clinicians.

Ciliated / Tubal Metaplasia of Endometrium

A Mimic of Atypical Hyperplasia

- **Resembles fallopian tube epithelium**
- **May colonize surface endometrium and/or deeper glands**
- **Often accompanied by other metaplasias** (eosinophilic, squamous)
- **Often associated with stromal breakdown**

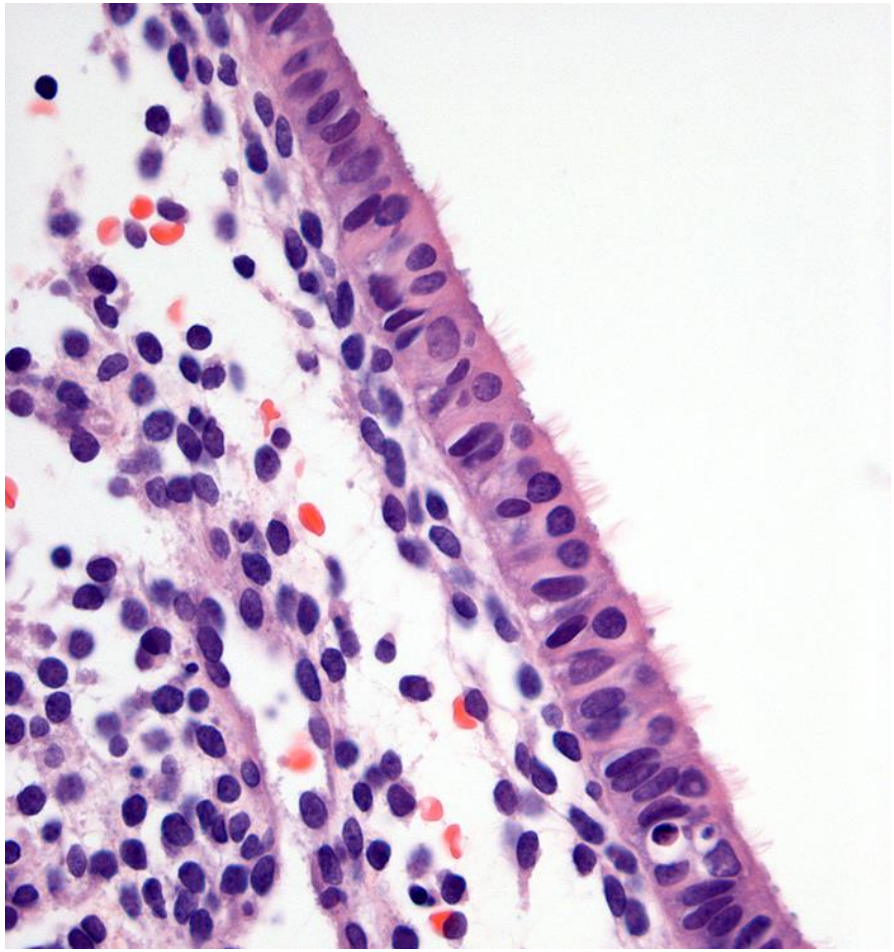

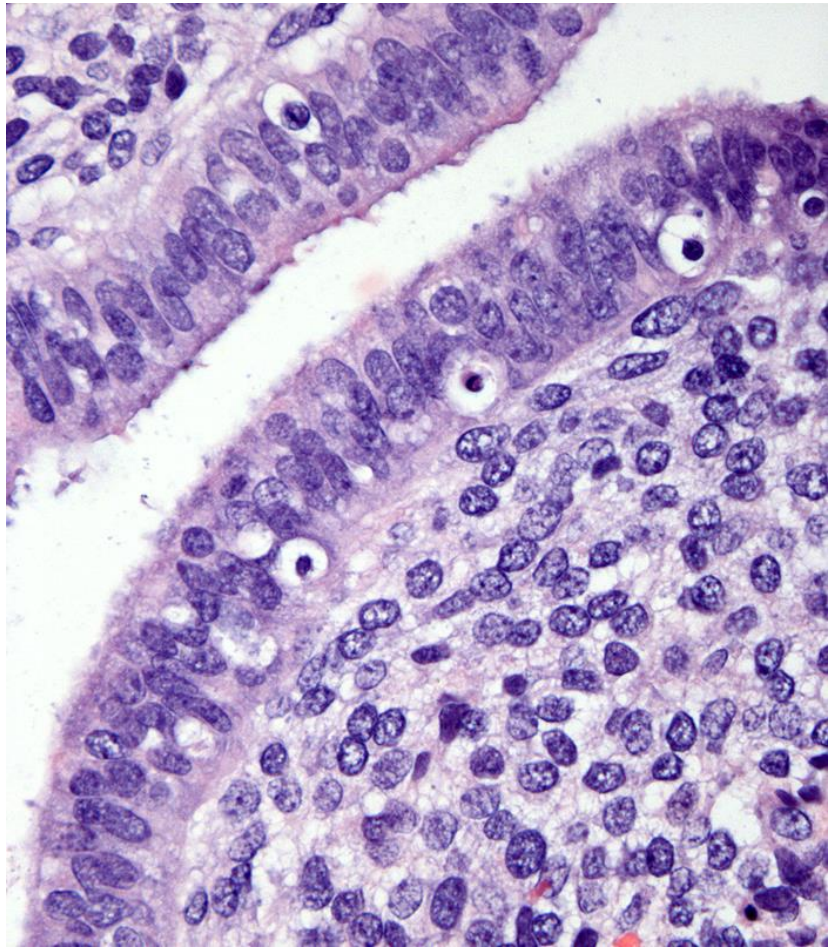

Ciliated / Tubal Metaplasia of Endometrium

A Mimic of Atypical Hyperplasia

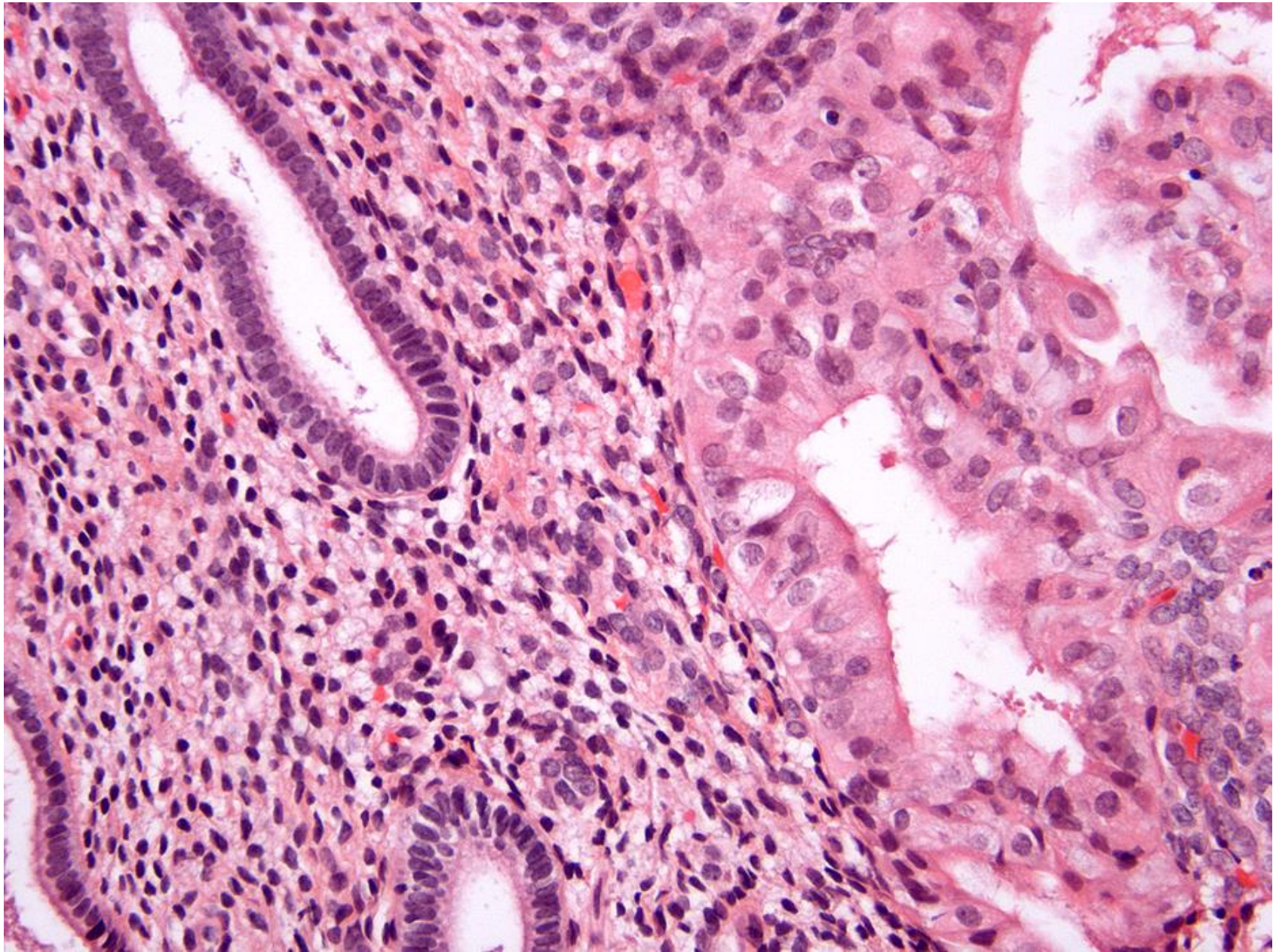

Ciliated / Tubal Metaplasia of Endometrium

A Mimic of Atypical Hyperplasia

Practical strategies:

- **Apply a high threshold for atypical hyperplasia if metaplasia is present.**
- **Look for nuclear atypia in non-metaplastic crowded glands**
- **Obtain input from colleagues for consensus**

Glandular Pattern Pathology

- Benign
  - Disordered proliferative pattern
  - Hyperplasia without atypia
  - Polyp with gland crowding
- Low risk cancer / precursor
  - Atypical hyperplasia / EIN
  - **Grade 1 endometrioid carcinoma**
  - Progestin-treated residual endometrioid carcinoma
- High risk cancer
  - Serous carcinoma (pseudo-glandular pattern variant)
  - Mesonephric-like carcinoma
- Secondary cancer
  - Endocervical adenocarcinoma
  - Colorectal adenocarcinoma

Grade 1 Endometrioid Carcinoma

Distinction from Atypical Hyperplasia

Definition (5th W.H.O):

1. **Endometrial glandular proliferation with loss of intervening <u>endometrial</u> stroma**

Classical Patterns
▪ **Confluent glands**
▪ **Cribriform pattern**
▪ **Maze / labyrinth-like pattern**
▪ **Complex papillary / villoglandular pattern**

Grade 1 Endometrioid Carcinoma

Confluent glandular growth

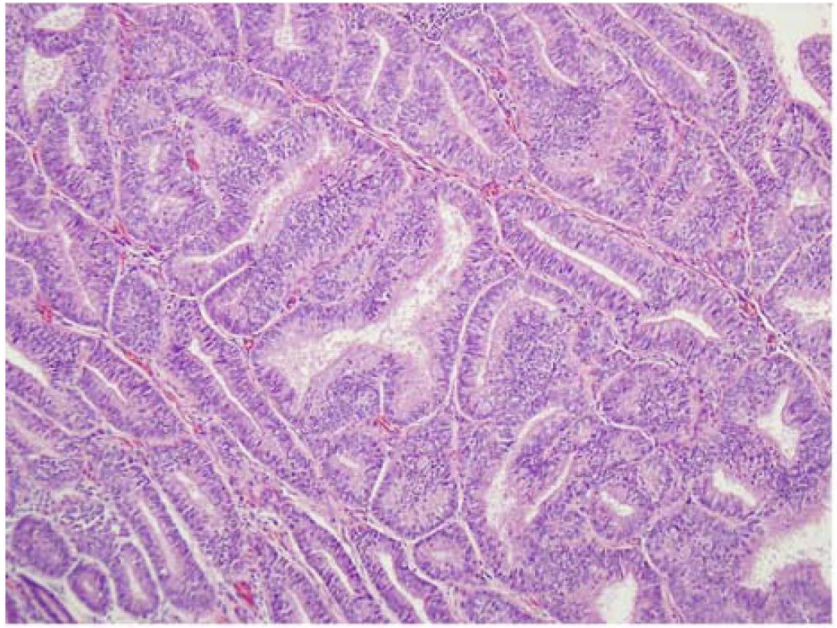

Cribriform growth

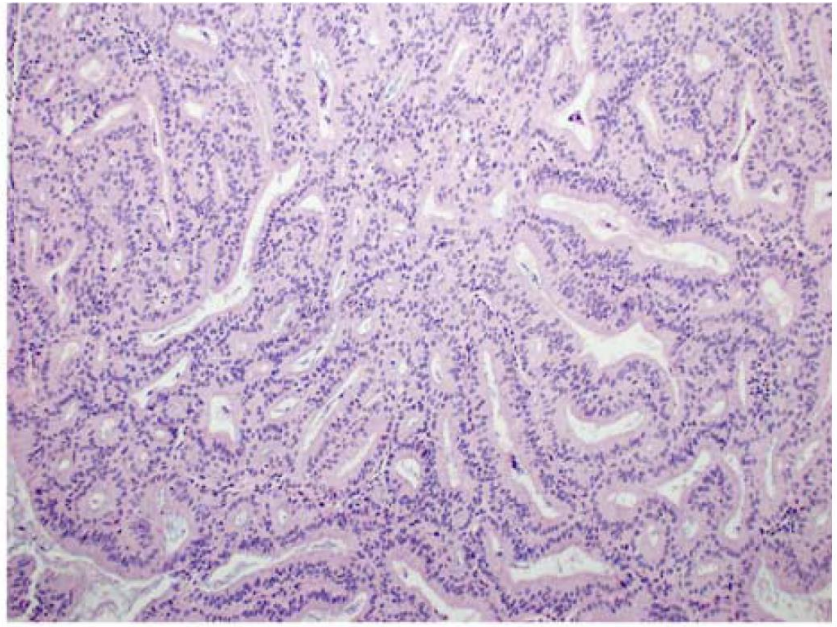

Complex papillary growth

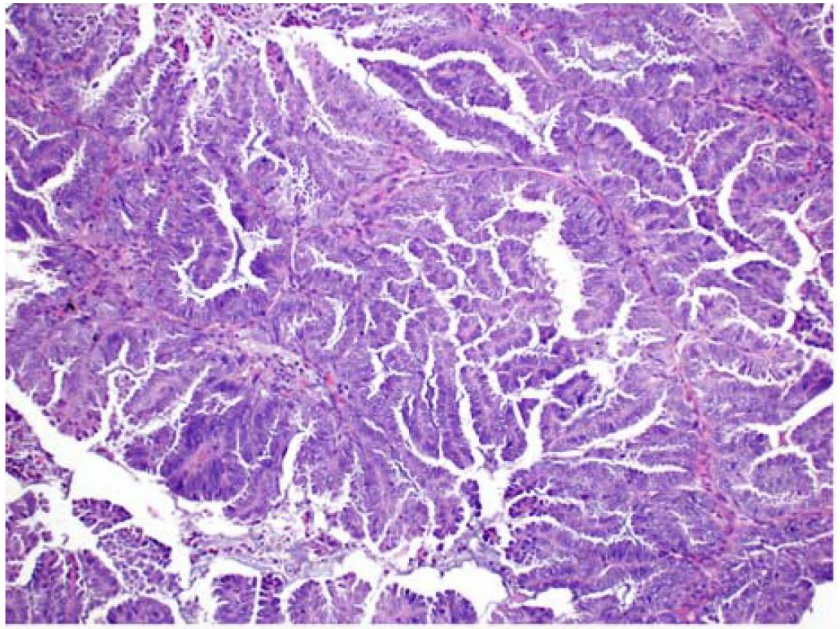

Labyrinth-like growth

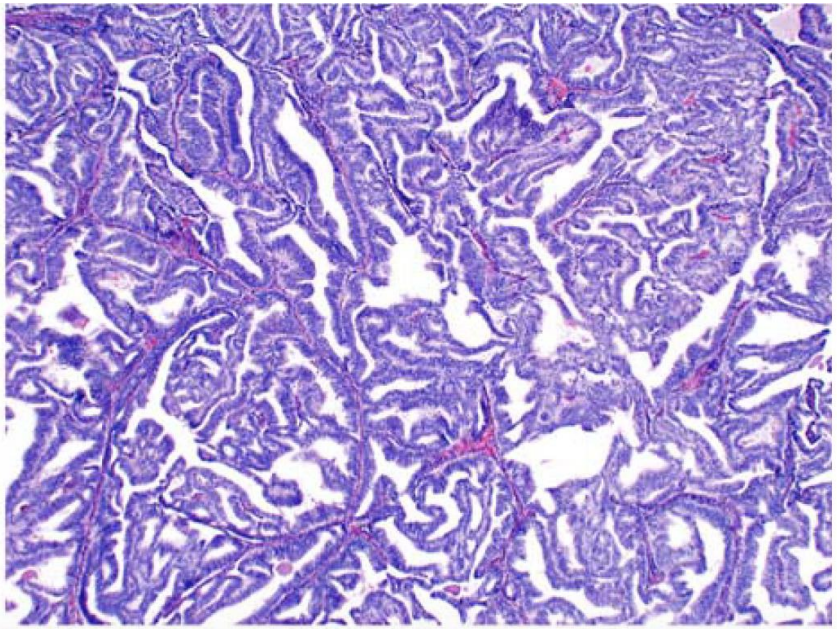

Grade 1 Endometrioid Carcinoma

Distinction from Atypical Hyperplasia

Definition (5th W.H.O):

1. **Endometrial glandular proliferation with loss of intervening <u>endometrial</u> stroma**

<u>Caveat:</u> other types of cells may be present between cancer glands

Endothelial cells
Fibroblasts
Inflammatory cells
Histiocytes

<u>Practical point</u>: "back-to-back" or "fused" glands is NOT required to classify as cancer

<u>Potential pitfall:</u> under-diagnosis of such cases as atypical hyperplasia

Presence of intervening true endometrial stroma excludes cancer

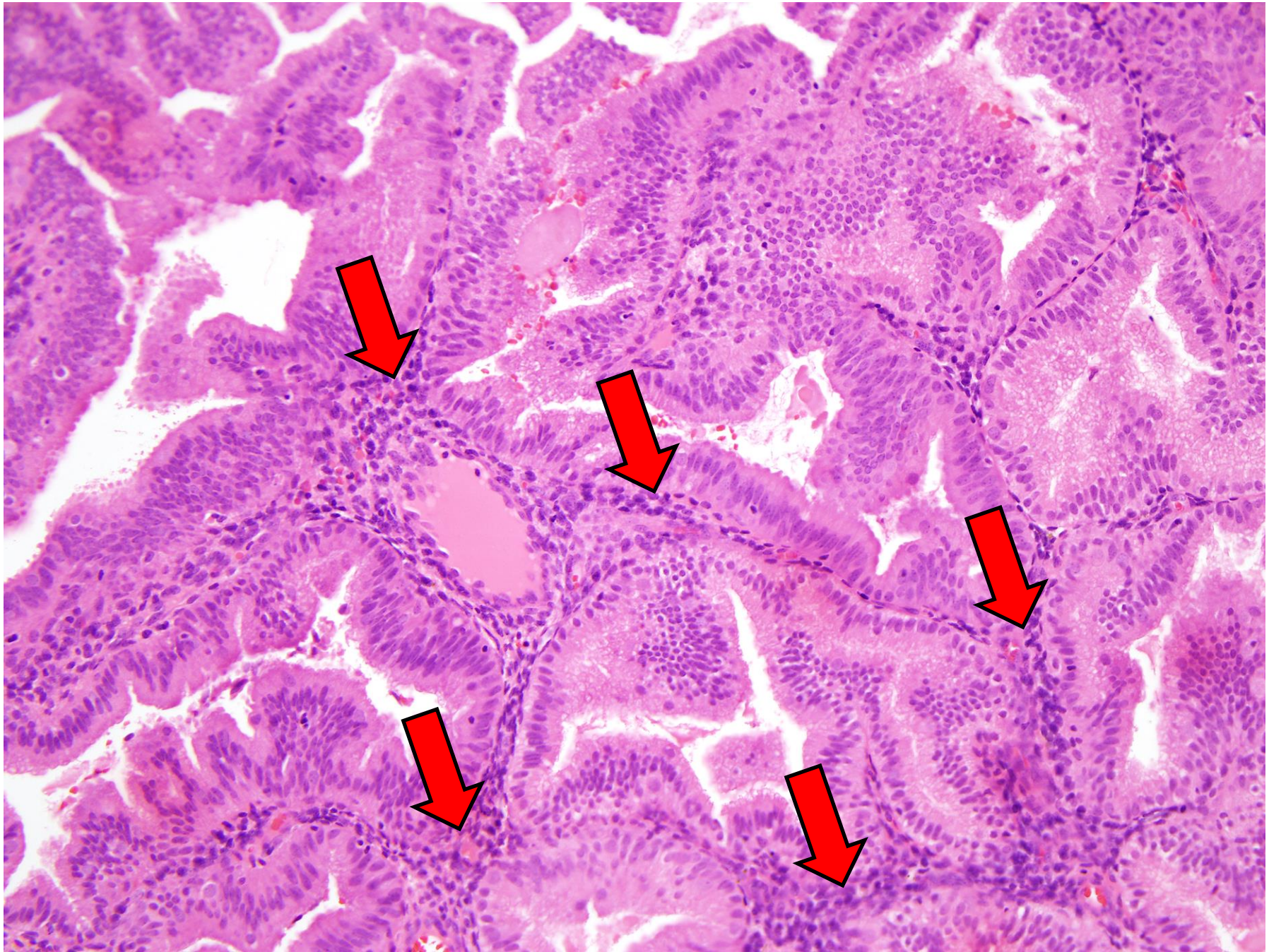

Definition of Loss of “True” Endometrial Stroma

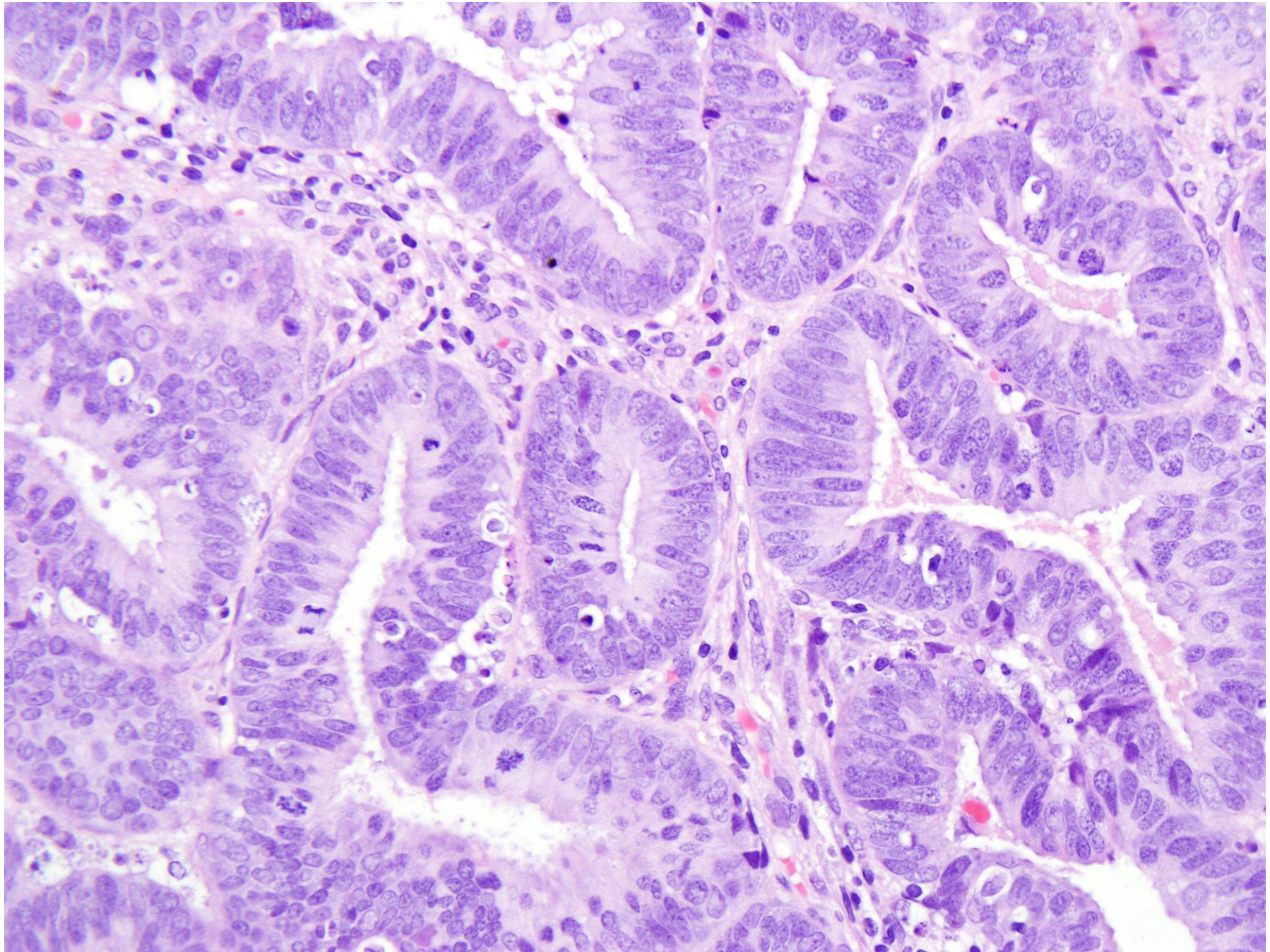

Cells Present:
Endothelial cells
Fibroblasts
Inflammatory cells
Histiocytes

Grade 1 Endometrioid Carcinoma

Distinction from Atypical Hyperplasia

Definition (5th W.H.O):

1. **Endometrial glandular proliferation with loss of intervening <u>endometrial</u> stroma**

Practical Challenge:

- **No objective definition of the minimum size/amount needed to qualify as cancer**

Remains a subjective matter, prone to observer disagreement

However, the concern is likely clinically relevant (based on one study): PMID: 22498938

Biopsy containing atypical hyperplasia	Cancer in hysterectomy
Without concern for cancer	**40%**
With foci concerning for cancer	**69%**

P<0.0001

Enough to call cancer ?

How to classify and report ?

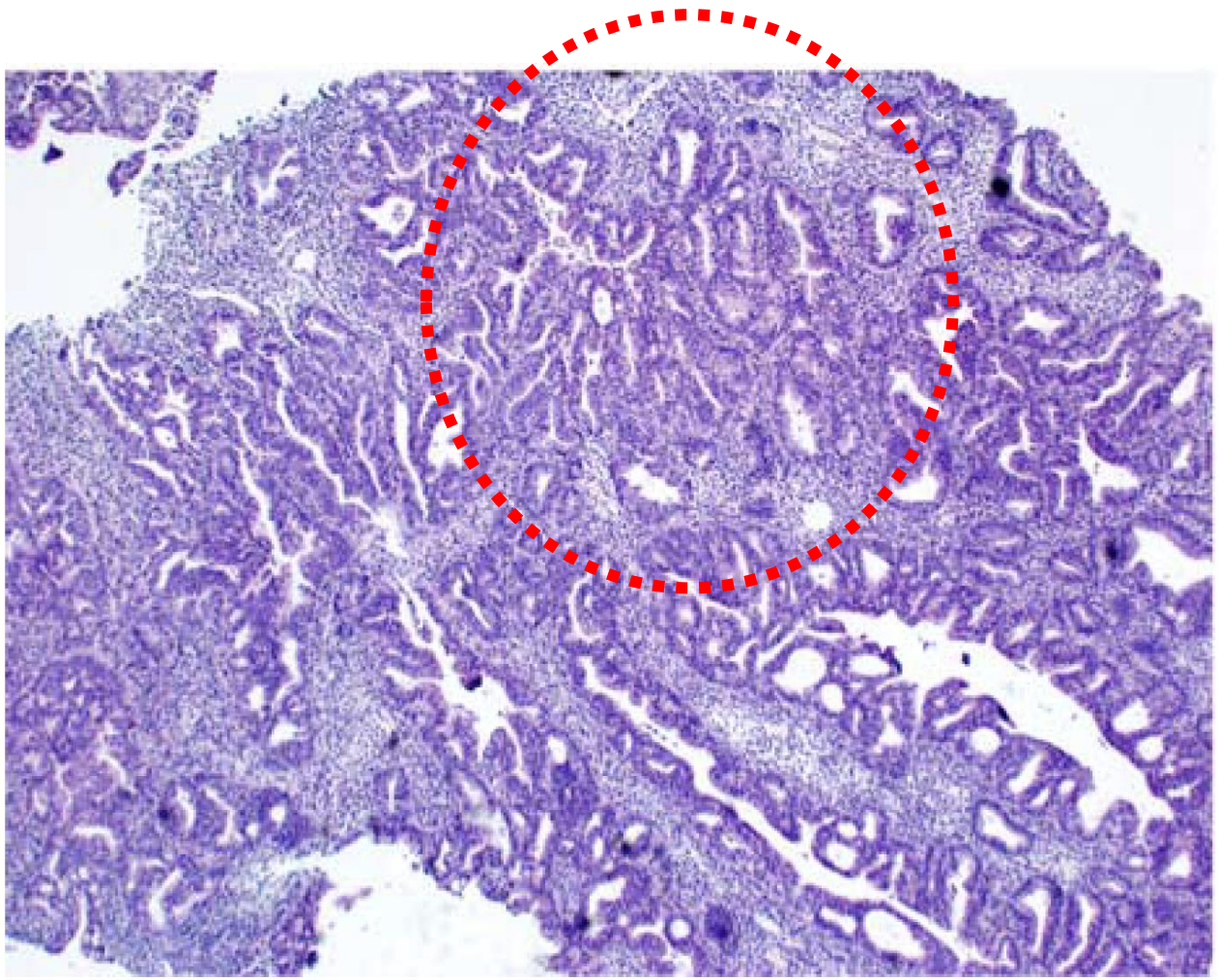

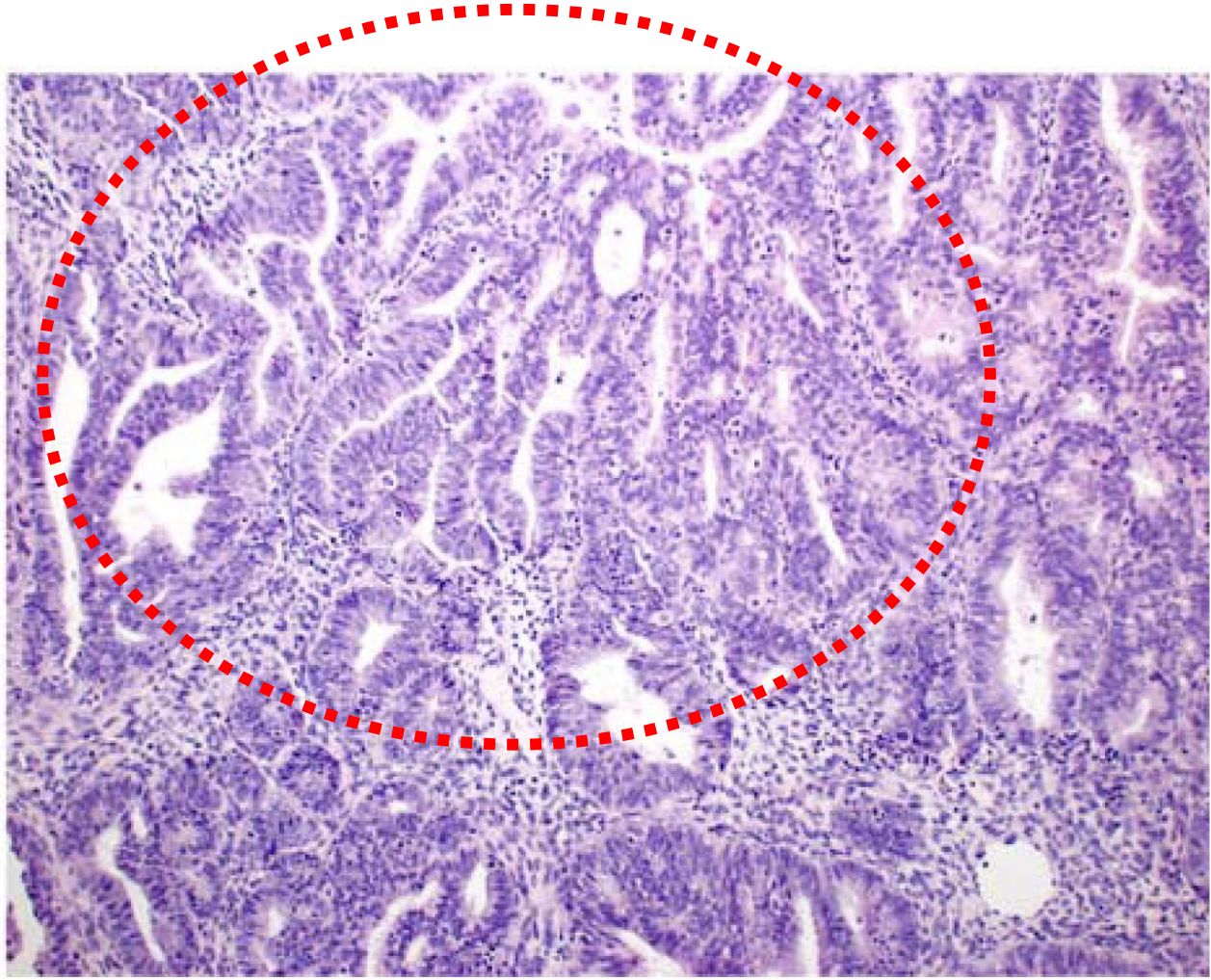

Rabban et al. Int J Gyn Pathol. 2019; 38: S25-S39

Grade 1 Endometrioid Carcinoma

Distinction from Atypical Hyperplasia

ISGyP Recommendation

PMID: 30550482

Document if atypical hyperplasia contains foci that raise concern but ultimately fail to meet criteria for cancer

Example diagnoses:

- Atypical hyperplasia, bordering on endometrioid cancer, grade 1
- Atypical hyperplasia, suspicious for endometrioid cancer, grade 1
- Atypical hyperplasia, cannot rule out endometrioid cancer, grade 1

Extensively fragmented specimen suspicious for cancer

How to report ?

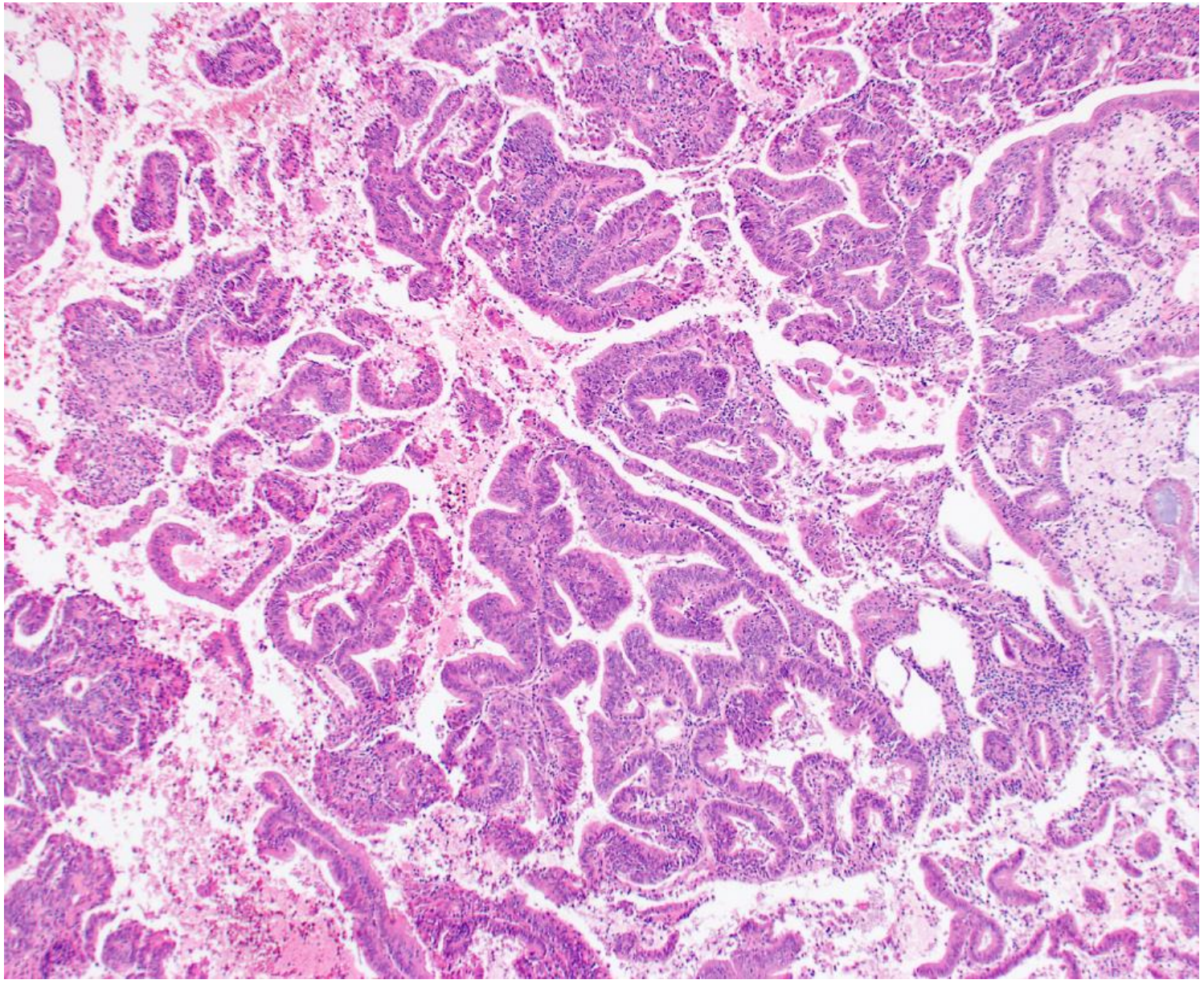

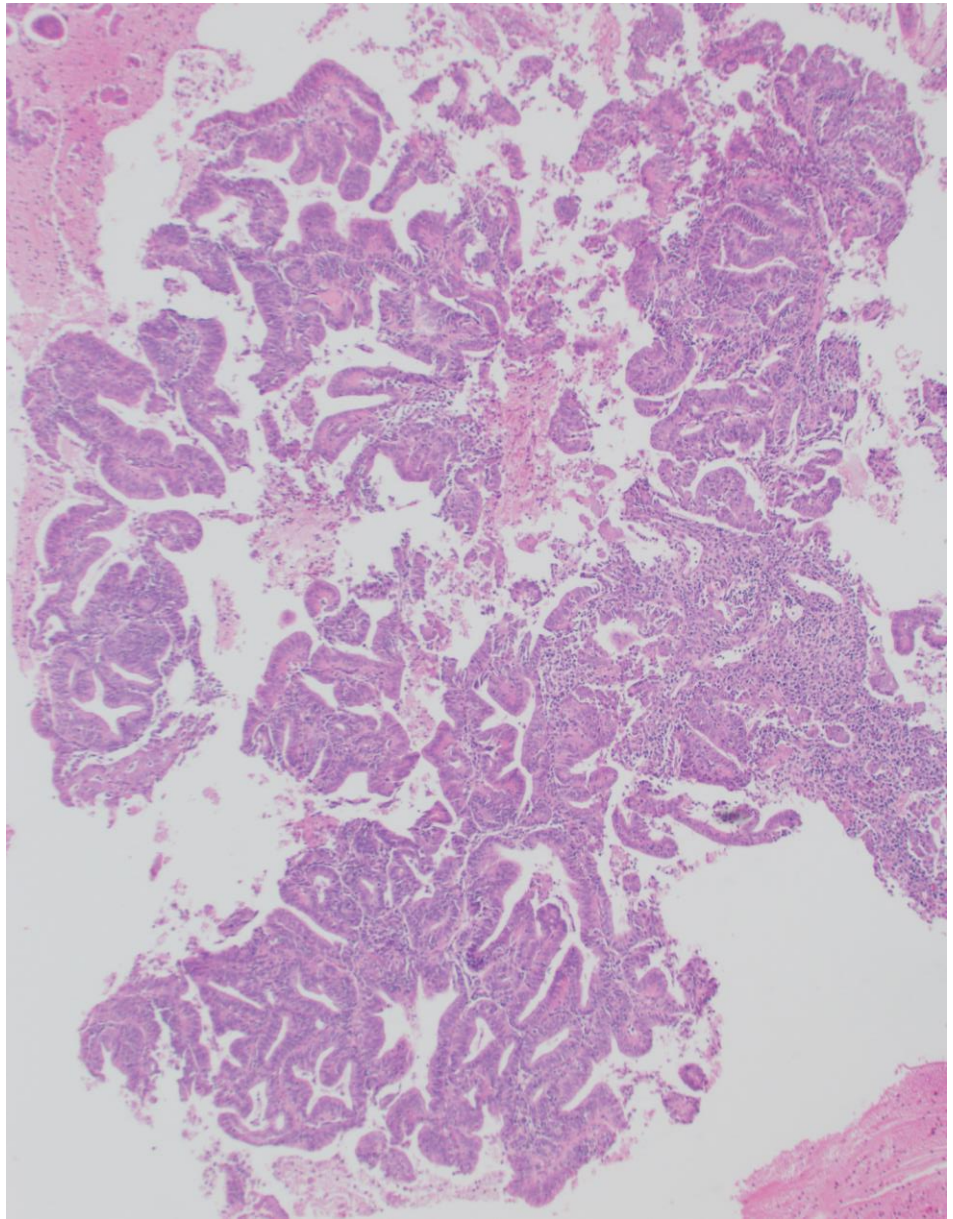

Extensively fragmented specimen suspicious for cancer

My personal approach:

Abnormal endometrioid glandular proliferation, cannot exclude carcinoma.

Comment:

- *Not simply just atypical hyperplasia*
- *Too fragmented to be definitive*
- *Highly concerning for carcinoma*
- *Consider re-sampling*

Grade 1 Endometrioid Carcinoma

Distinction from Atypical Hyperplasia

Definition (5th W.H.O):

1. Endometrial glandular proliferation with loss of intervening endometrial stroma

2. **Endometrial glandular proliferation with stromal desmoplasia**

- **Highly uncommon for endometrial biopsy to sample myoinvasive cancer**
- **Challenging differential diagnoses in a biopsy:**

Altered stroma without cancer
Hyperplasia involving a degenerating polyp
Atypical polypoid adenomyoma
Residual progestin-treated atypical hyperplasia

Glandular Pattern Pathology

- Benign
  - Disordered proliferative pattern
  - Hyperplasia without atypia
  - Polyp with gland crowding
- Low risk cancer / precursor
  - Atypical hyperplasia / EIN
  - Grade 1 endometrioid carcinoma
  - **Progestin-treated residual endometrioid carcinoma**
- High risk cancer
  - Serous carcinoma (pseudo-glandular pattern variant)
  - Mesonephric-like carcinoma
- Secondary cancer
  - Endocervical adenocarcinoma
  - Colorectal adenocarcinoma

Fertility-sparing Management of Endometrioid Carcinoma

Strategy:	▪ **Delay hysterectomy until after fertility plan completed** ▪ **Attempt high dose progestin therapy** (oral and/or IUD)
Eligibility:	▪ **Atypical hyperplasia** ▪ **Grade 1 endometrioid carcinoma**
Treatment Goal:	**Complete glandular atrophy by 6 months** **(NCCN guidelines)**

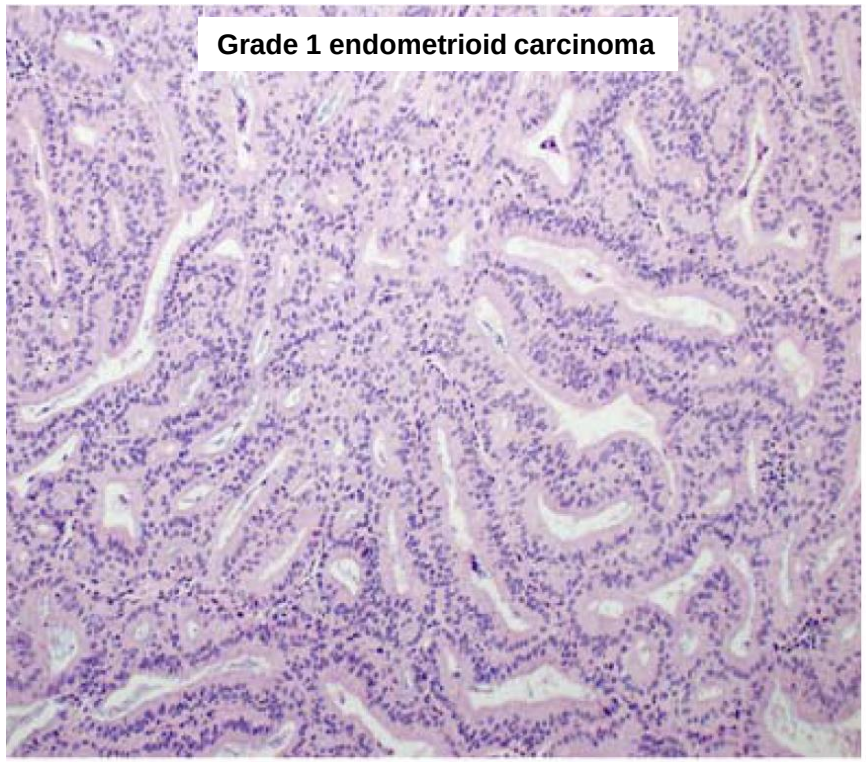

Progestin

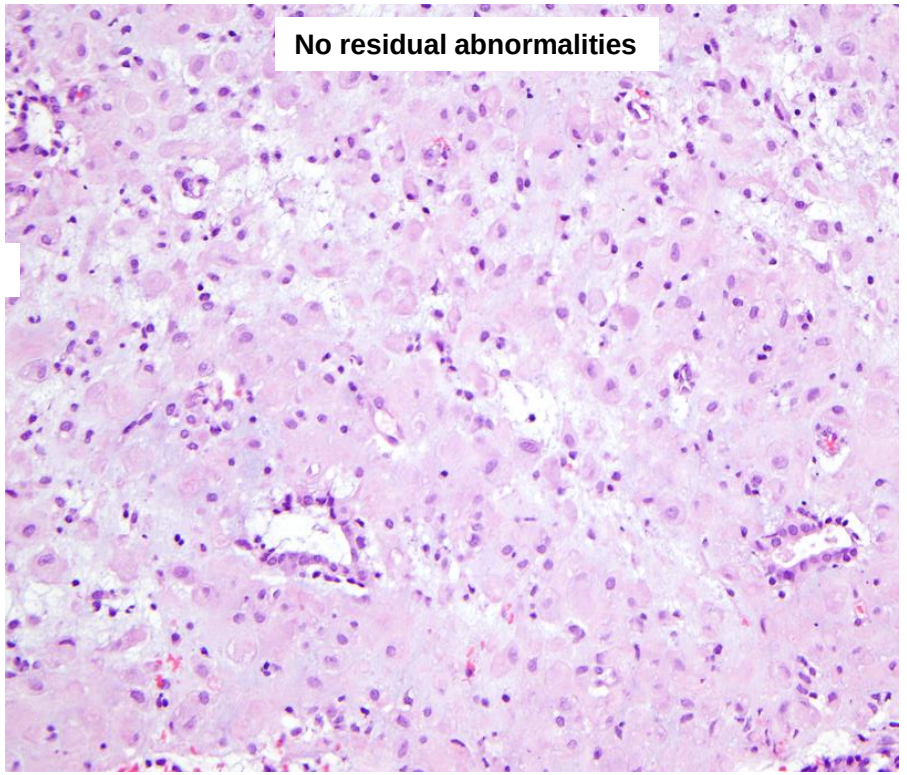

NCCN Guidelines for Uterine Neoplasms v1. 2021 www.nccn.org

Fertility-sparing Management of Endometrioid Carcinoma

Dependent on Interim Surveillance Biopsies

Interim Status of Endometrium	Clinical Plan Based on Biopsy Report
Complete resolution	▪ **Ready to attempt pregnancy** ▪ **Hysterectomy after delivery**
Partial resolution	▪ **Continue progestin therapy** ▪ **Continue surveillance biopsies**
Incomplete resolution at ~6 months	**Consider immediate hysterectomy**
Progression to worse disease	**Consider immediate hysterectomy**

Key components:

1.) Findings in current surveillance biopsy

2.) Trend over time in the findings (compared to prior surveillance biopsy)

Fertility-sparing Management of Endometrioid Carcinoma

Dependent on Interim Surveillance Biopsies

Practical Challenges:

What criteria to use in evaluating surveillance biopsies ?

What terminology to use in reporting surveillance biopsies ?

An evolving area; many unanswered issues

Prior surveillance biopsies may not be available for comparison

International Journal of Gynecological Pathology
00:1–9, Lippincott Williams & Wilkins, Baltimore
Copyright © 2021 by the International Society of Gynecological Pathologists

Original Article

Survey on Reporting of Endometrial Biopsies From Women on Progestogen Therapy for Endometrial Atypical Hyperplasia/Endometrioid Carcinoma

Raji Ganesan, F.R.C.Path., C. Blake Gilks, M.D., Robert A. Soslow, M.D., and W. Glenn McCluggage, F.R.C.Path.

PMID: 33935157

The British Association of Gynaecological Pathologists

International Society of Gynecological Pathologists
Established in 1976

Progestin-treated residual endometrioid abnormalities

Criteria for residual disease

- **<u>Usual criteria</u> for cancer / atypical hyperplasia are too strict in this setting.**
  Progestin may down-grade appearance of residual disease

- **<u>Special criteria</u> for this setting:**
  Any 1 criteria predicts failure of progestin treatment if present at ~7-9 months.

Any 1 = residual disease

Architectural atypia, even if normal cytology
Papillary branching
Crowded glands
Cribriform glands

Cytologic atypia, even if normal architecture
Nucleoli
Coarse chromatin

Wheeler et al. PMID: 17592264
Validated independently by PMID: 23010707

Progestin-treated residual endometrioid abnormalities

Cribriform glands

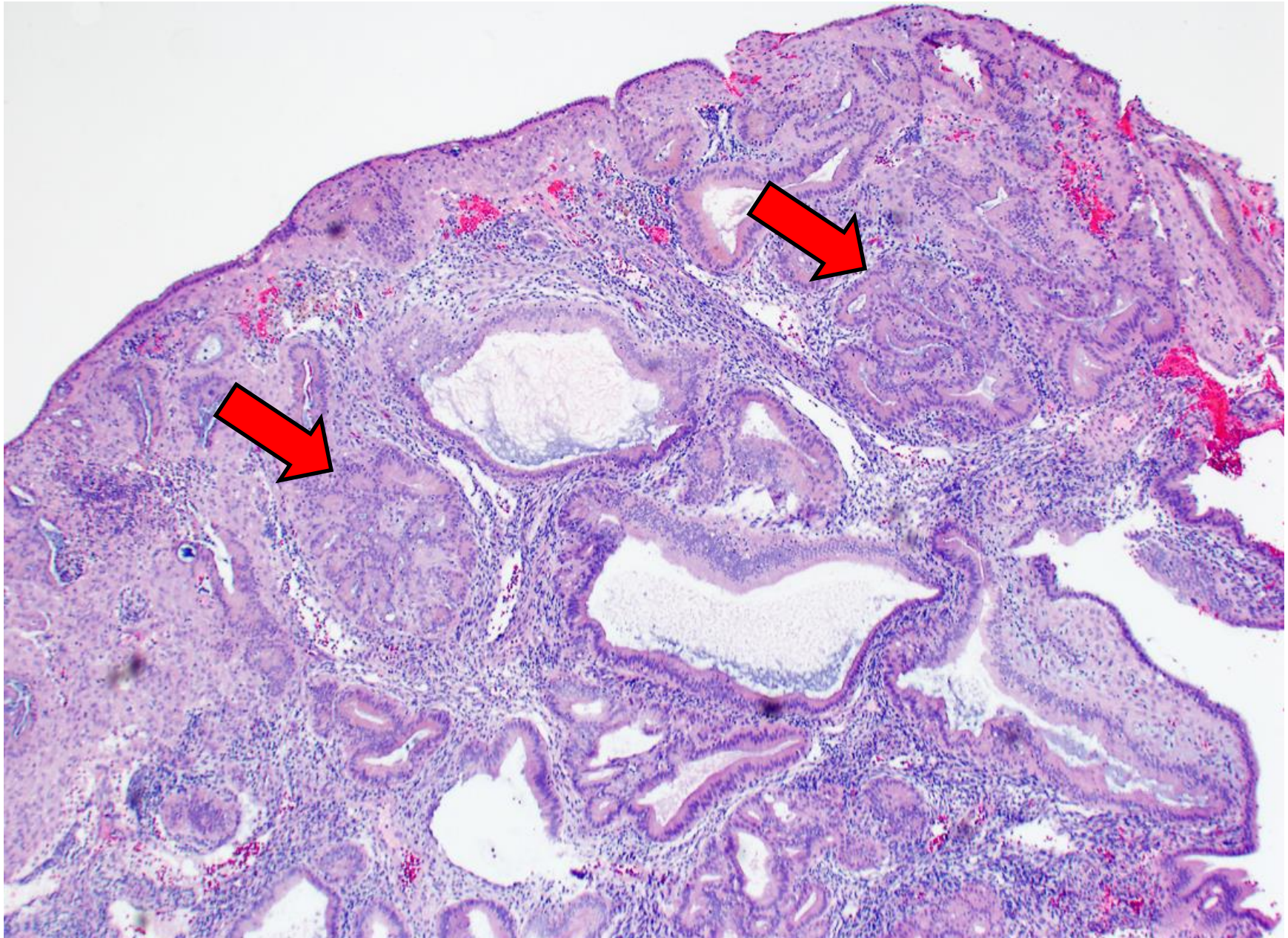

Progestin-treated residual endometrioid abnormalities

Crowded glands

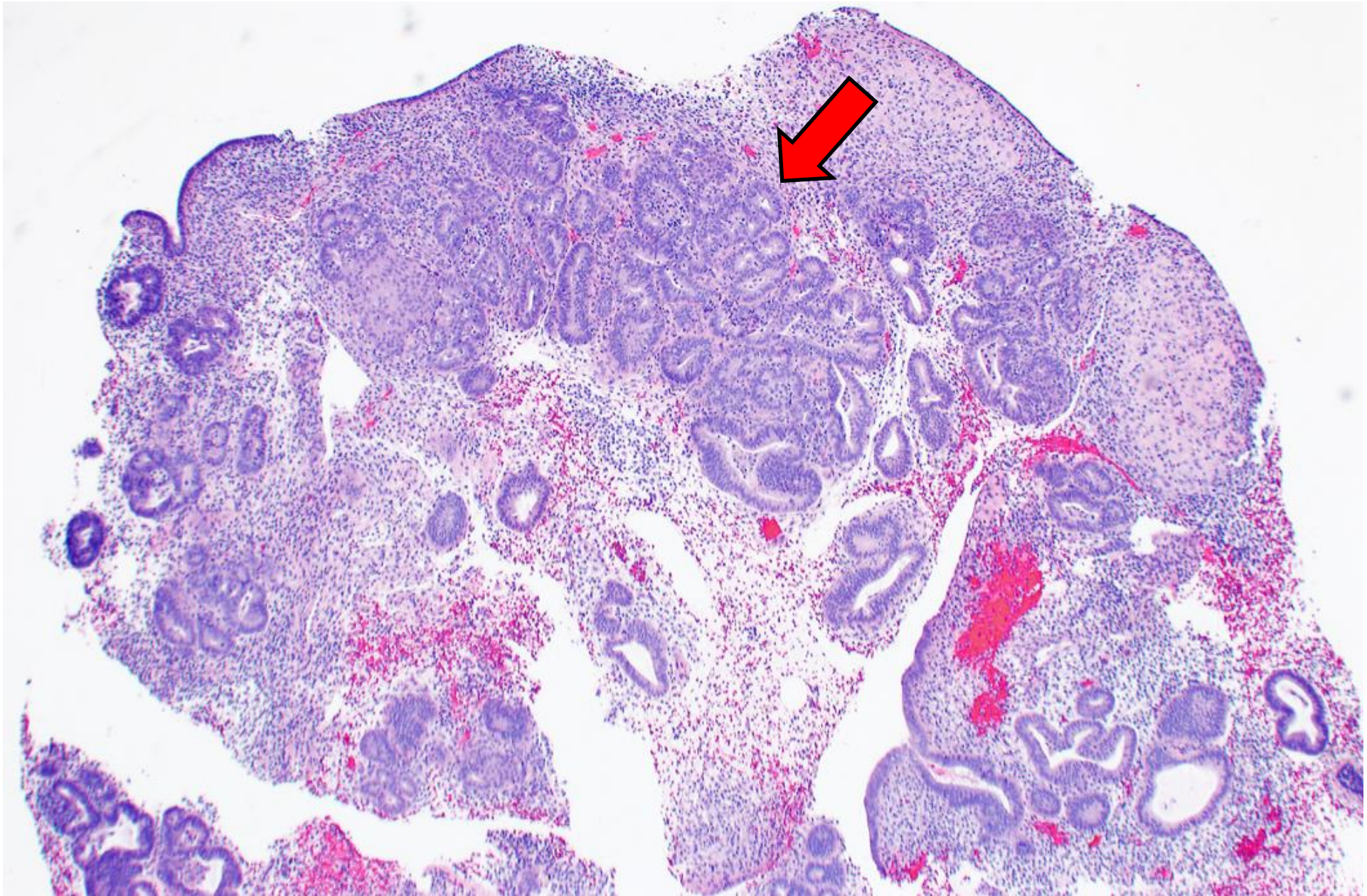

Progestin-treated residual endometrioid abnormalities

Crowded, branching glands

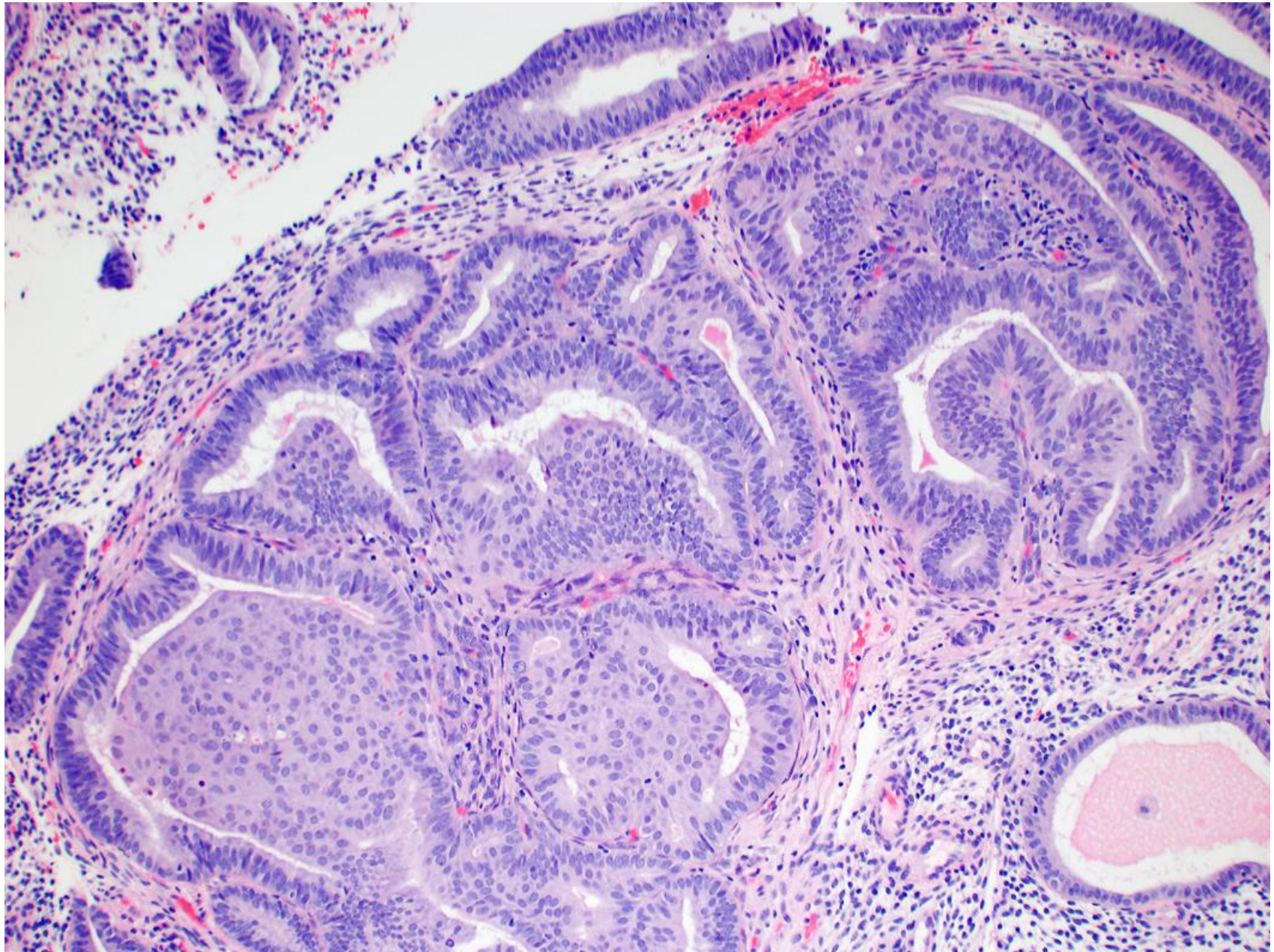

Progestin-treated residual endometrioid abnormalities

With atypia

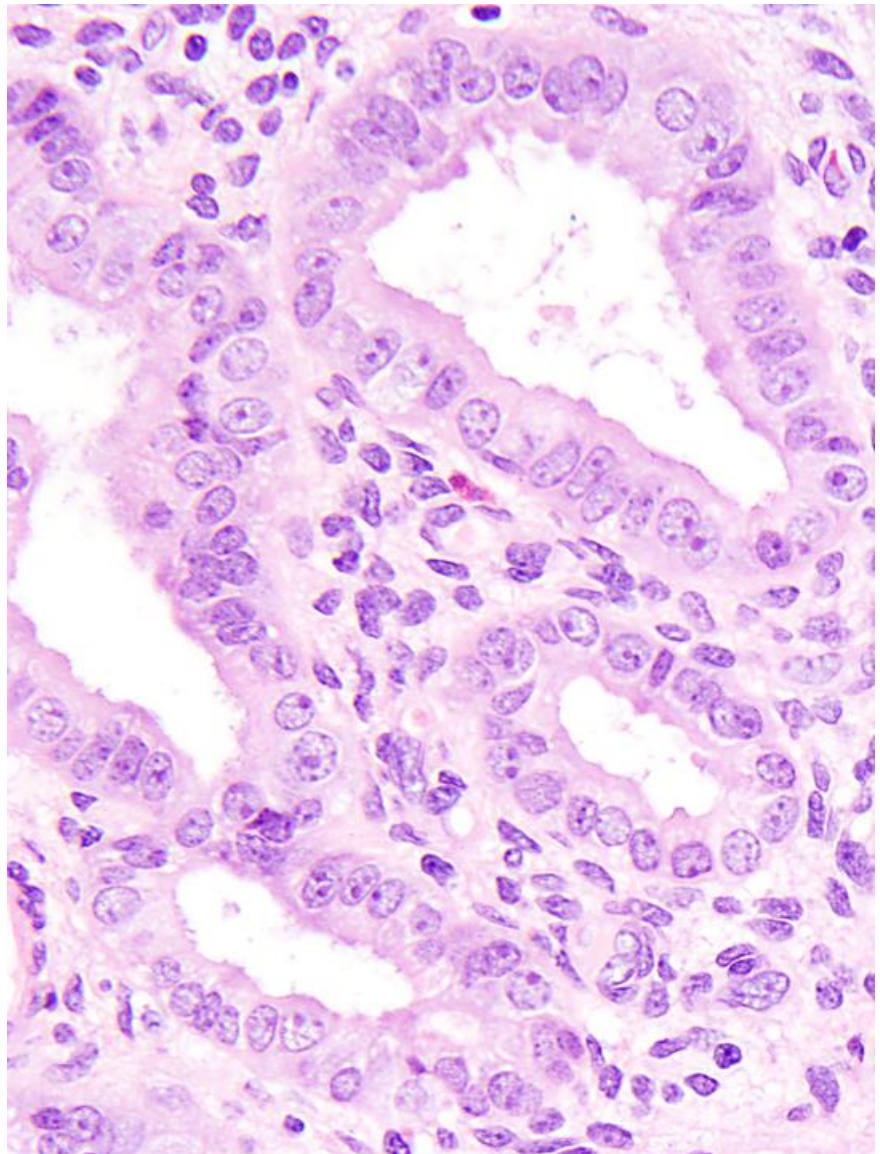

Without atypia

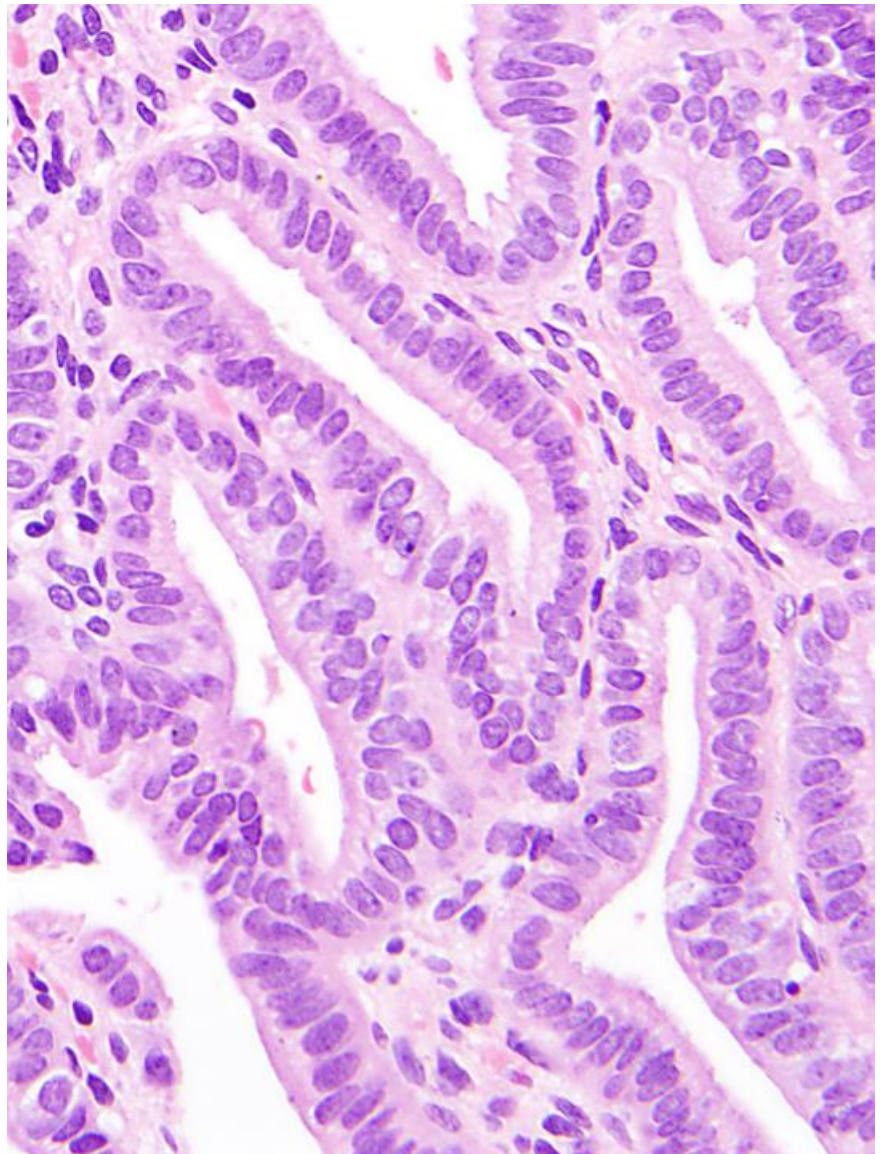

Progestin-treated residual endometrioid abnormalities

Branching glands



Irregular crowded glands

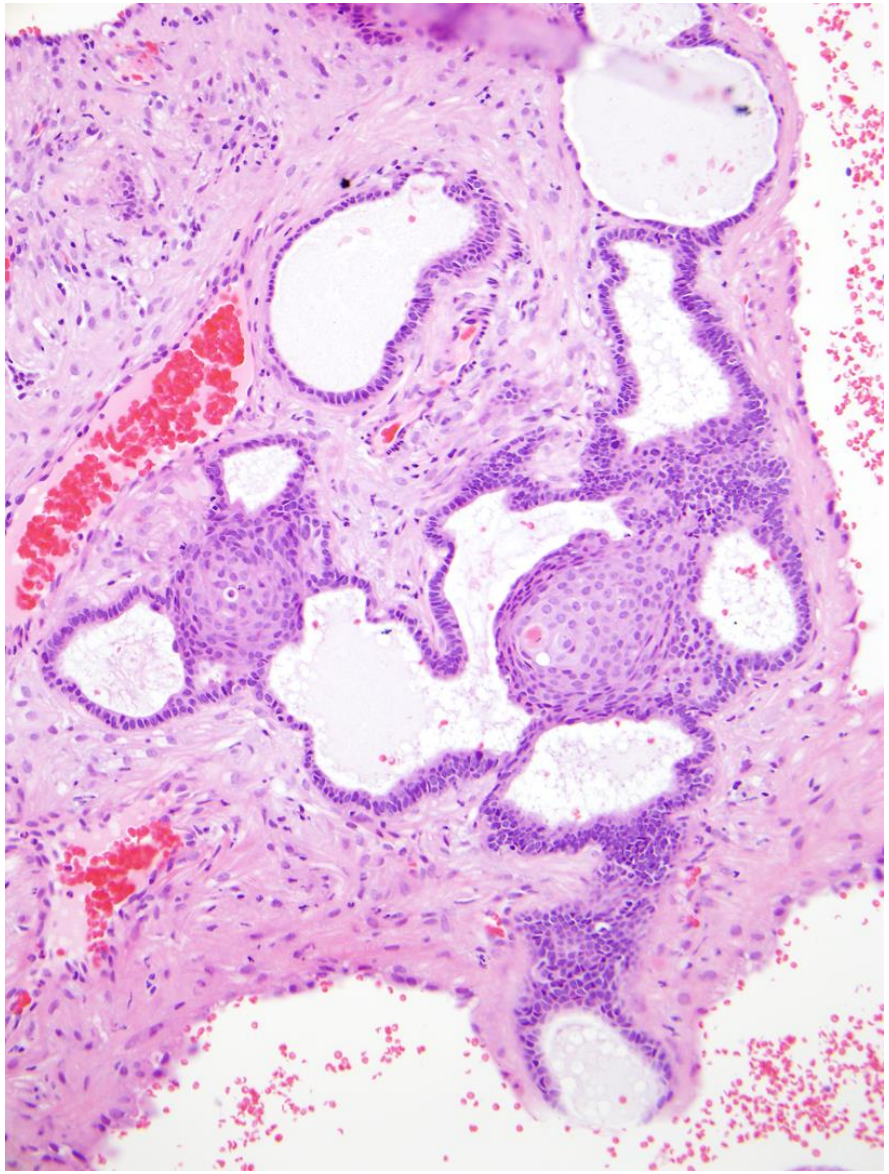

Progestin-treated residual endometrioid abnormalities

Practical approach to reporting surveillance biopsies

- **Criteria: use** *Wheeler et al* PMID: 17592264
- **Document "trend over time" by comparing to prior biopsies**
- **Terminology is less important than documenting:**

    a. **presence/absence of abnormalities**
    b. **trend over time in biopsies**

Progestin-treated residual endometrioid abnormalities

Practical approach to reporting surveillance biopsies

Final Diagnosis *Example*:

Residual glandular abnormalities with progestin-treatment effects.

Comment:

- *Not a complete response to progestin.*
- *No classic features of carcinoma or atypical hyperplasia*
- *Abnormal gland crowding and branching indicates incomplete regression.*
- *Amount and extent of abnormality is less than in the most recent surveillance biopsy.*

Cite Wheeler et al PMID: 17592264

Glandular Pattern Pathology

- Benign
  - **Disordered proliferative pattern**
  - **Hyperplasia without atypia**
  - **Polyp with gland crowding**
- Low risk cancer / precursor
  - **Atypical hyperplasia / EIN**
  - **Grade 1 endometrioid carcinoma**
  - **Progestin-treated residual endometrioid carcinoma**
- High risk cancer
  - **Serous carcinoma** (pseudo-glandular pattern variant)
  - **Mesonephric-like carcinoma**
- Secondary cancer
  - **Endocervical adenocarcinoma**
  - **Colorectal adenocarcinoma**

Pseudo-glandular Serous Carcinoma

Definition: **a morphologic variant of serous carcinoma with simple gland-like growth mimicking grade 1 endometrioid carcinoma or atypical hyperplasia**

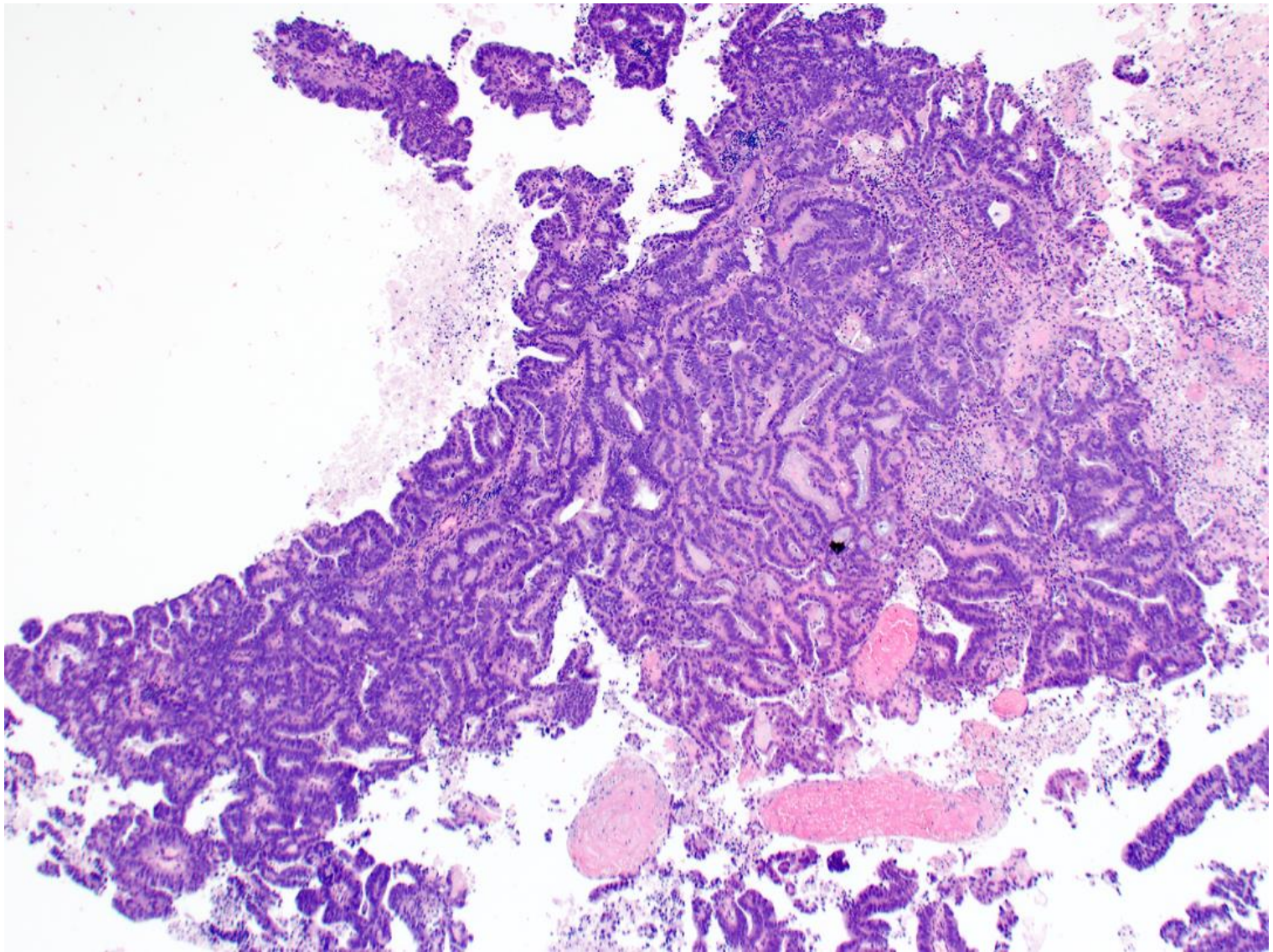

Pseudo-glandular Serous Carcinoma

Mimics atypical hyperplasia

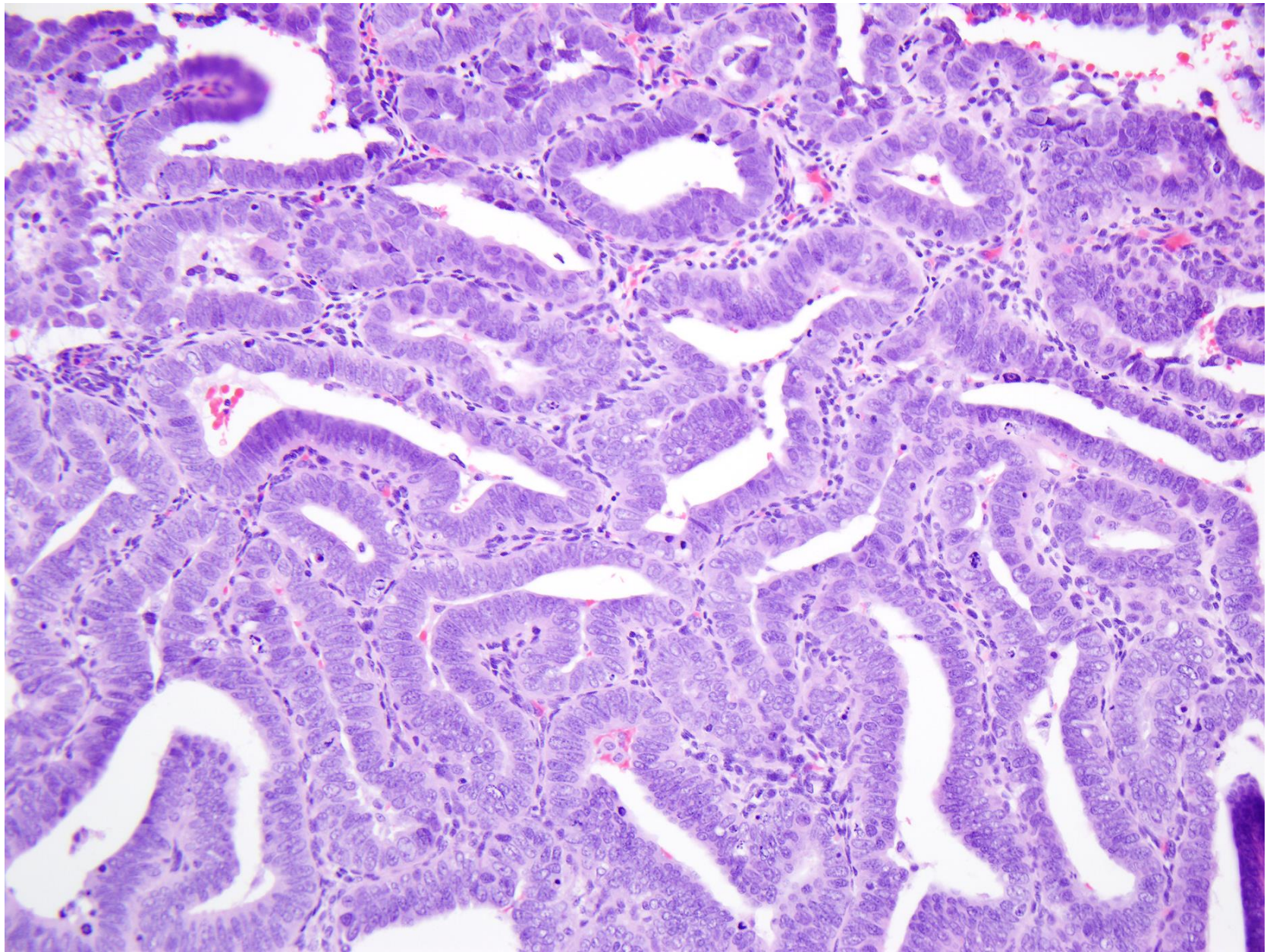

Pseudo-glandular Serous Carcinoma

Mimics grade 1 endometrioid carcinoma

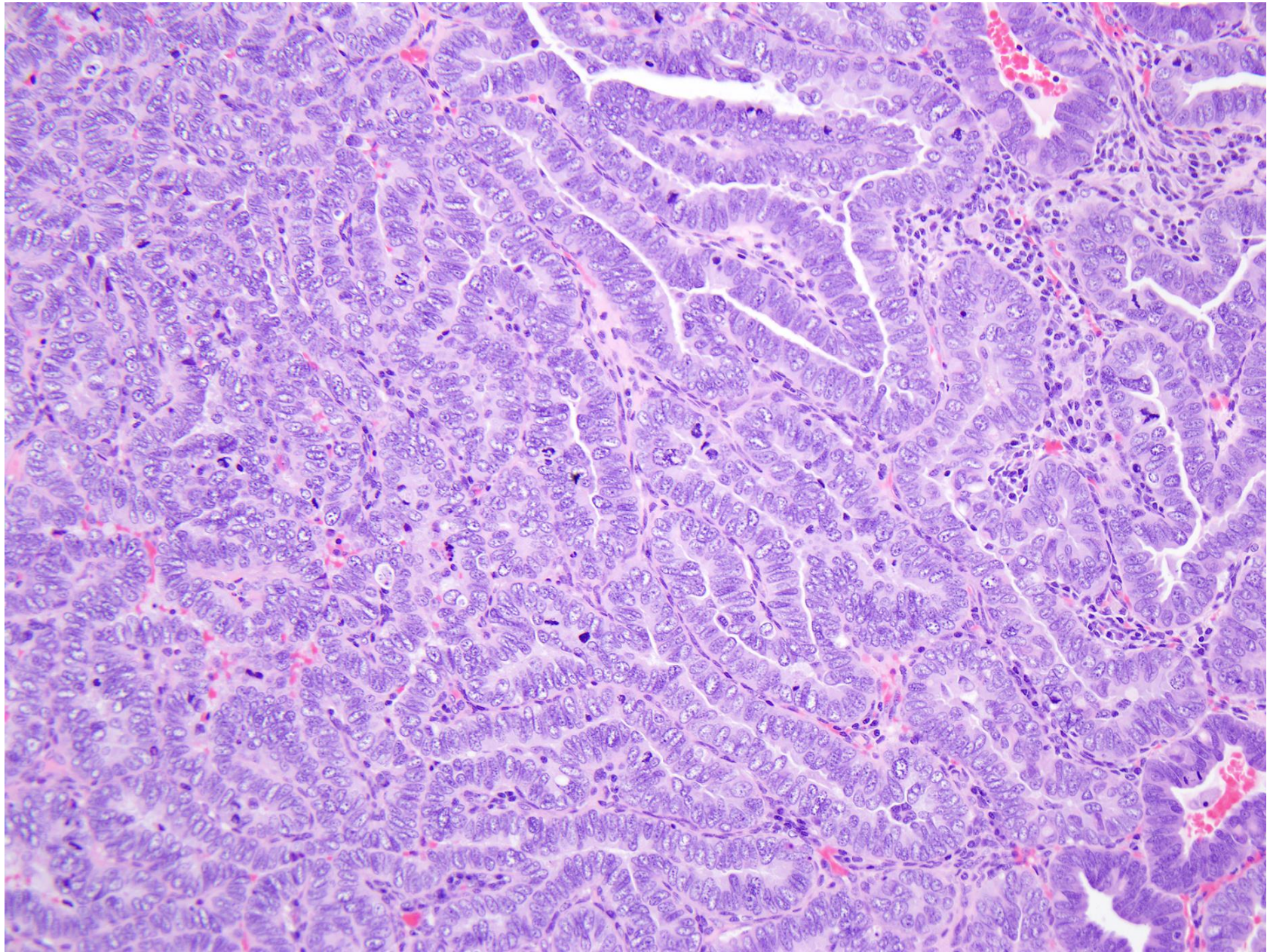

Pseudo-glandular Serous Carcinoma

Mimics atypical hyperplasia in a polyp

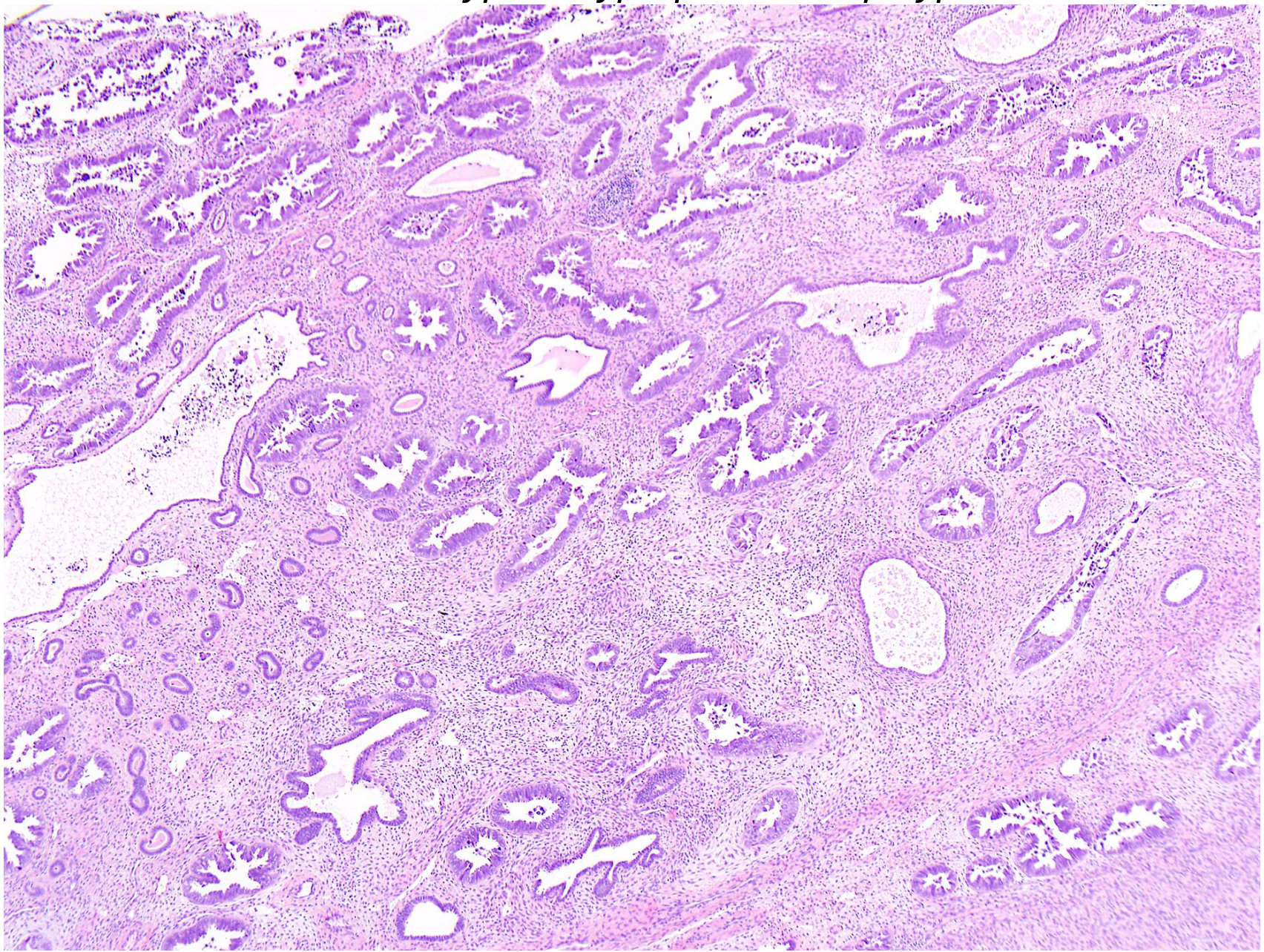

Pseudo-glandular Serous Carcinoma

Mimics grade 1 endometrioid cancer in a polyp

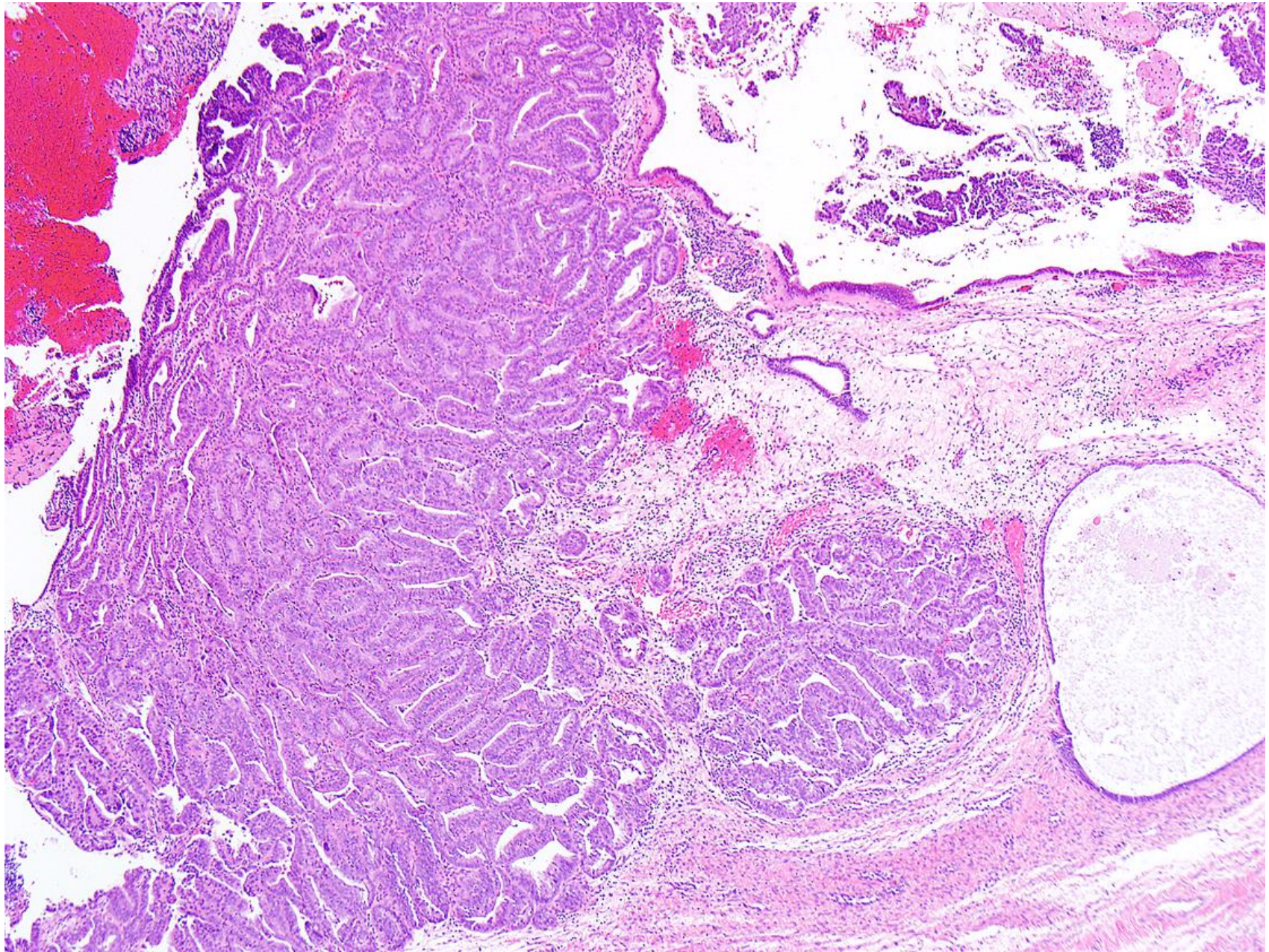

Distinguishing Endometrioid versus Serous Carcinoma

Concordance of Architecture and Nuclear Grade

	Grade 1 Endometrioid Carcinoma	Pseudo-glandular Serous Carcinoma
Architectural grade	**Low**	**Low**
Nuclear grade	**Low**	**High**

Concordant **Discordant**

<u>High nuclear grade:</u>

- **High N/C ratio**
- **Pleomorphic**
- **Hyperchromatic**
- **Macronucleoli**
- **Brisk, atypical mitoses**

Pseudo-glandular Serous Carcinoma

Discordant architecture versus nuclear grade

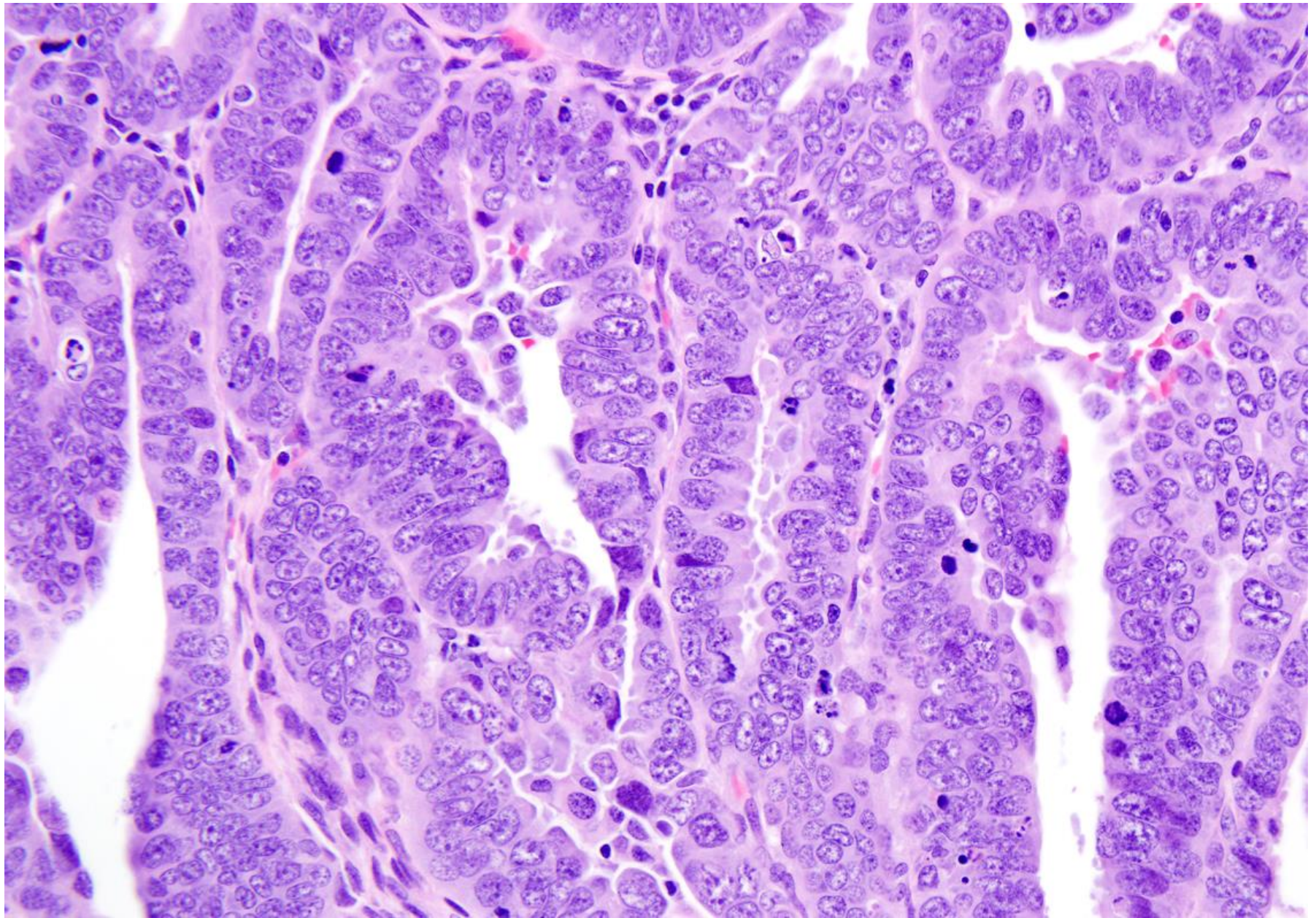

Pseudo-glandular Serous Carcinoma

Brisk mitoses

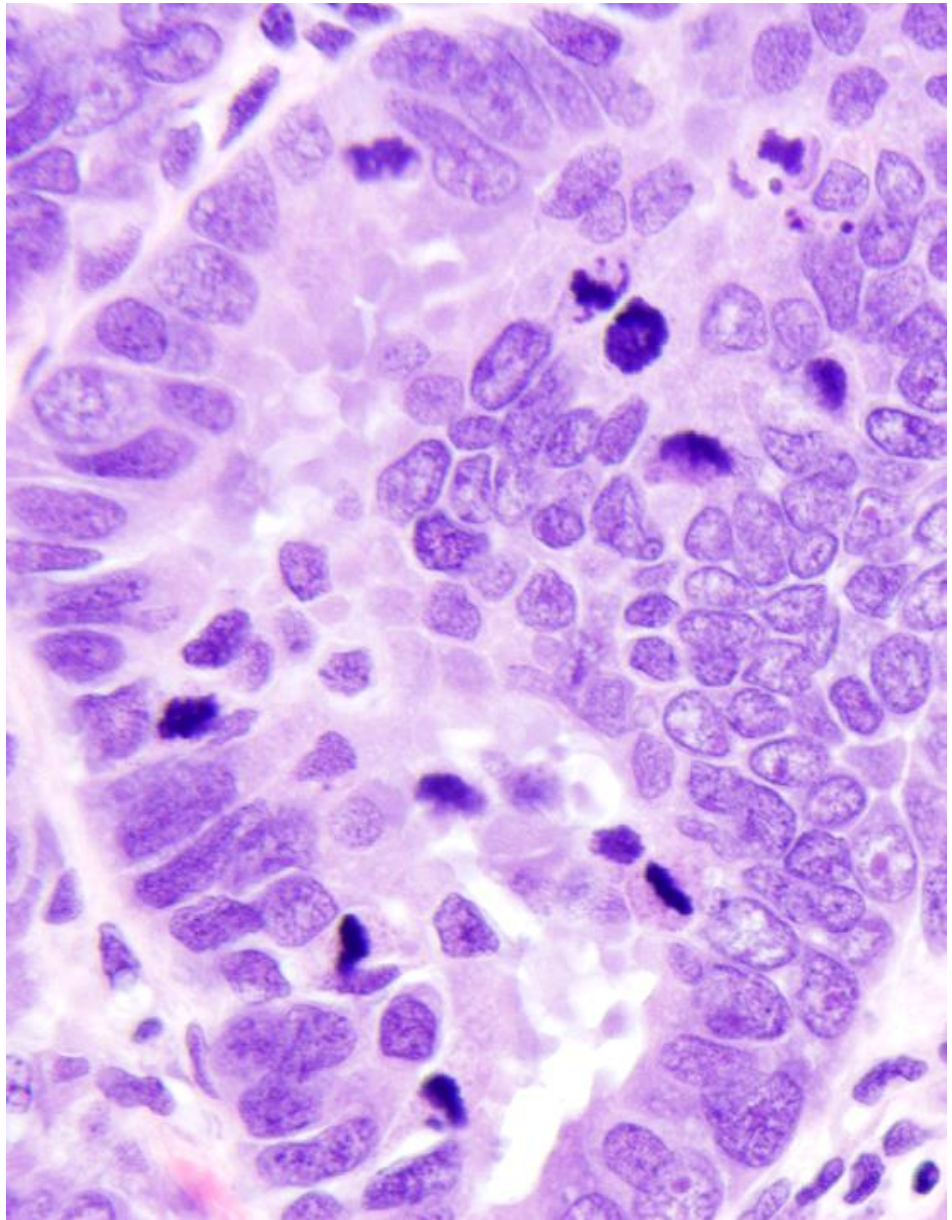

Atypical mitoses, macronucleoli

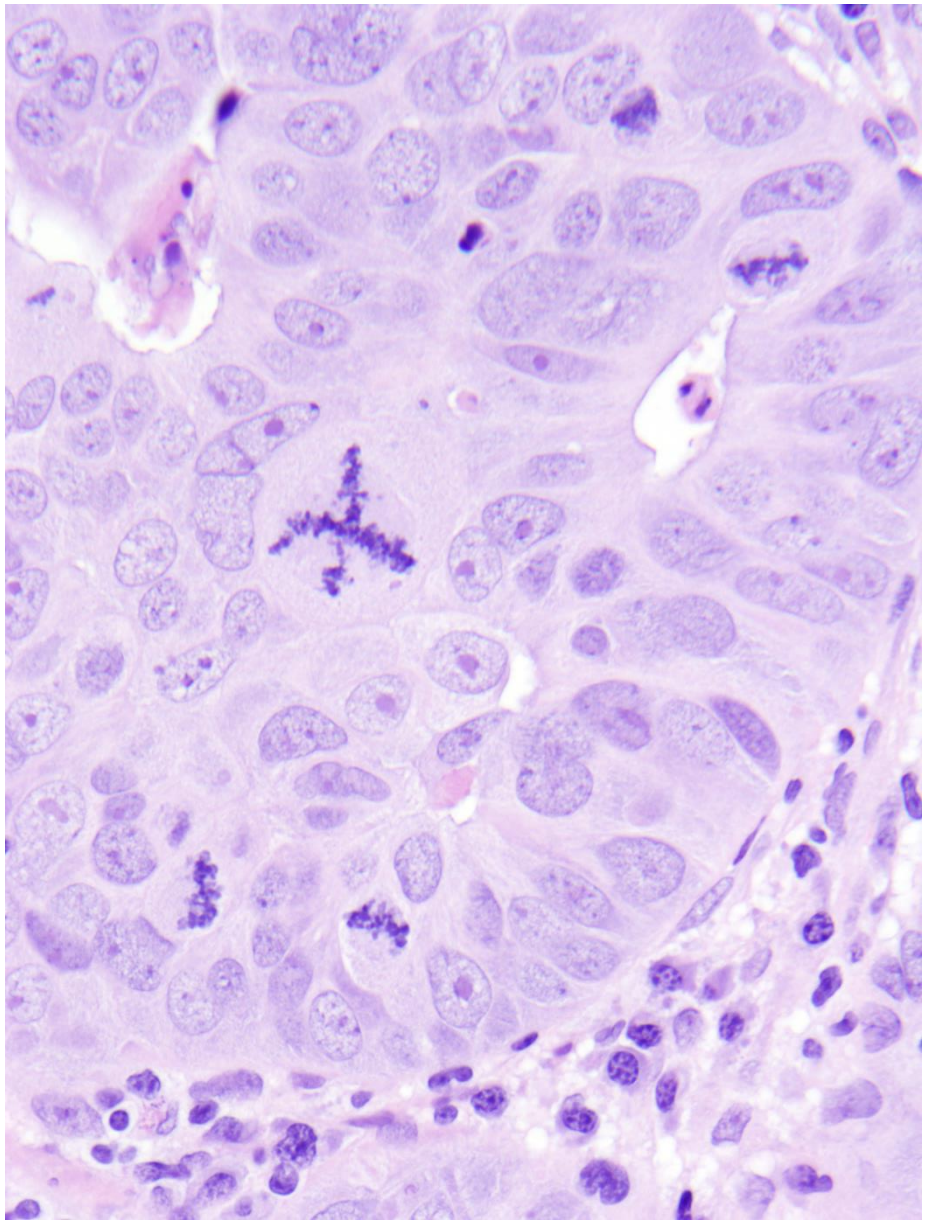

Pseudo-glandular Serous Carcinoma

Large purple smudged nuclei

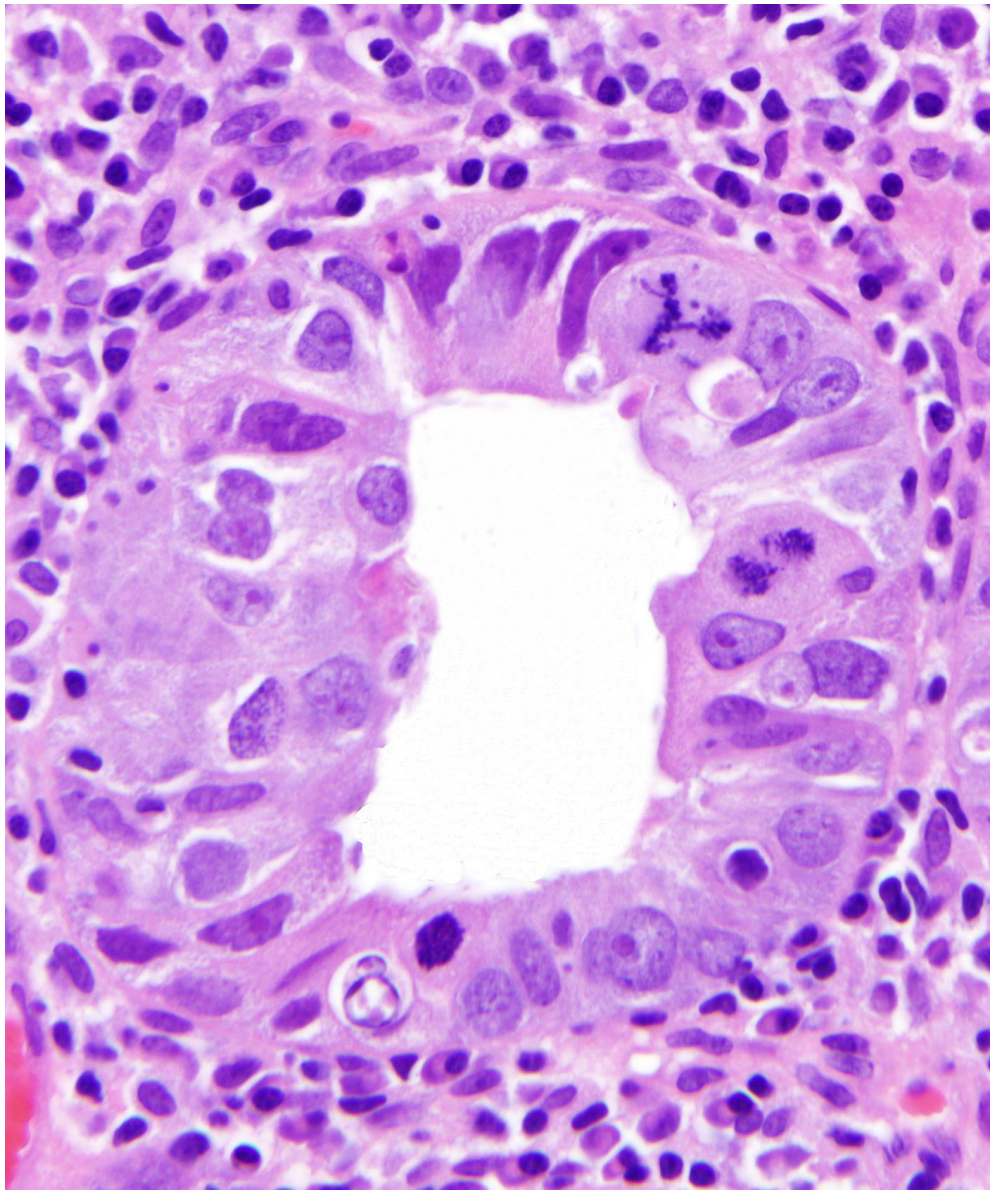

Severe atypia, high N/C ratio

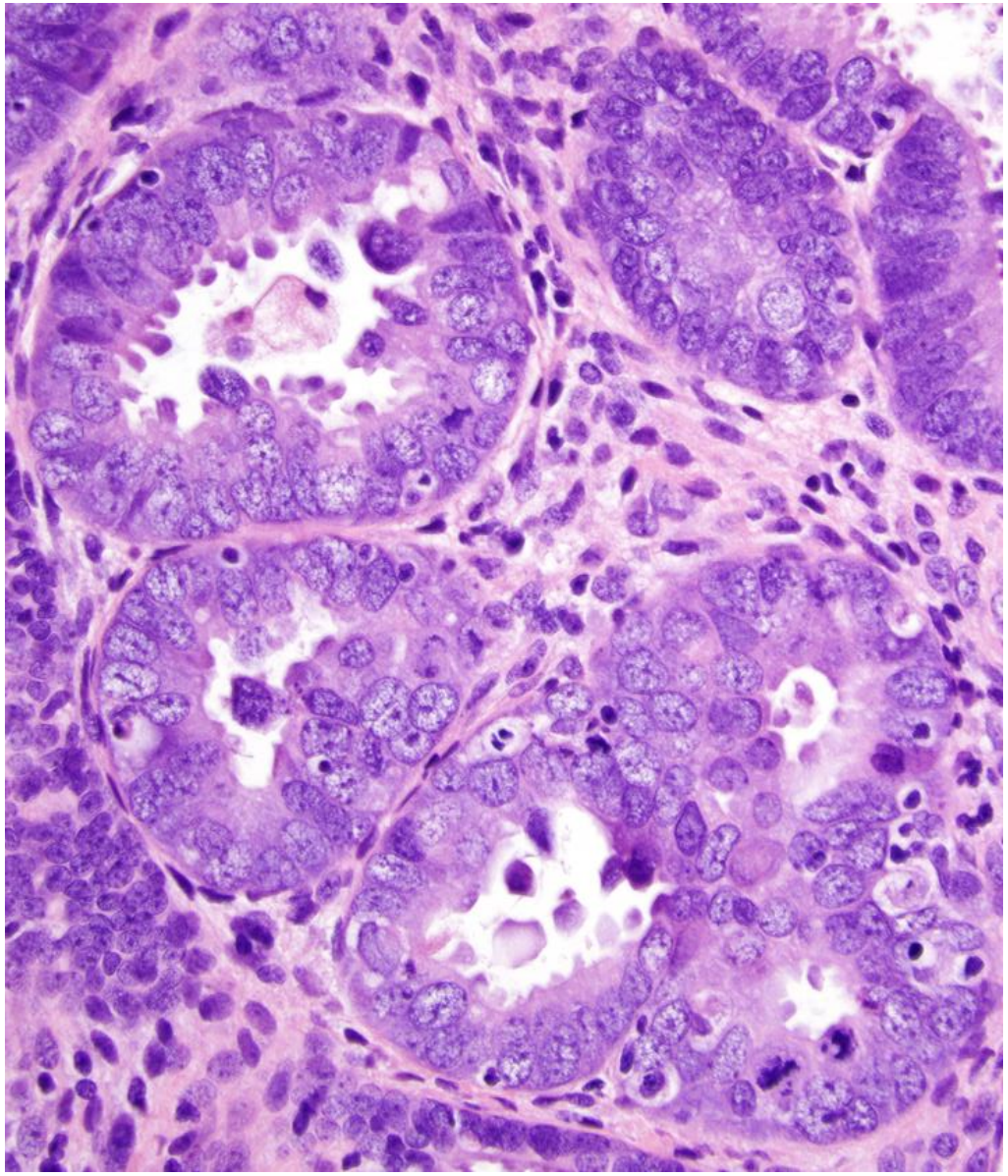

Distinguishing Endometrioid versus Serous Carcinoma

Practical Issue:

In a biopsy, is it acceptable to use H&E alone to diagnosis pseudo-glandular serous carcinoma ?

My personal view:

Typically not because: 1.) morphology / sampling may not always be classic
2.) clinical management implications are significant.

Confirmation by immunohistochemistry is advisable.

Distinguishing Endometrioid versus Serous Carcinoma

ISGyP Recommended Immunostains

- *A panel of stains is advised*
- *Integrate results with morphology*
- *Exceptions to expected results do occur*

	Endometrioid Carcinoma	Serous Carcinoma
First choice panel		
p53	Wild type	Aberrant
p16	Negative	Positive
Estrogen receptor	Often positive	Often negative
May use instead of ER		
PTEN	Often lost	Usually intact
Add if results of initial stains are problematic		
MMR proteins	Often lost	Usually intact
ARID1A	Often lost	Usually intact

p53 stain critical components:

- **Titration to aberrant/wild type controls**
- **Awareness of 3 patterns of aberrancy**
- **Clear reporting terminology**

Kobel 2019 PMID: 29517499

Murali et al. Int. J. Gyn. Pathol. 2019; 38: S40-S63

p53 Immunostain Interpretation in Endometrial Cancer

Variable nuclear staining

Wild type result

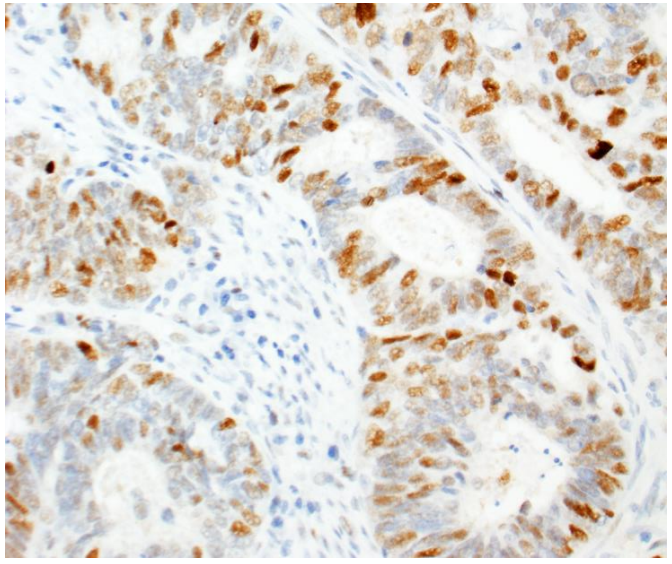

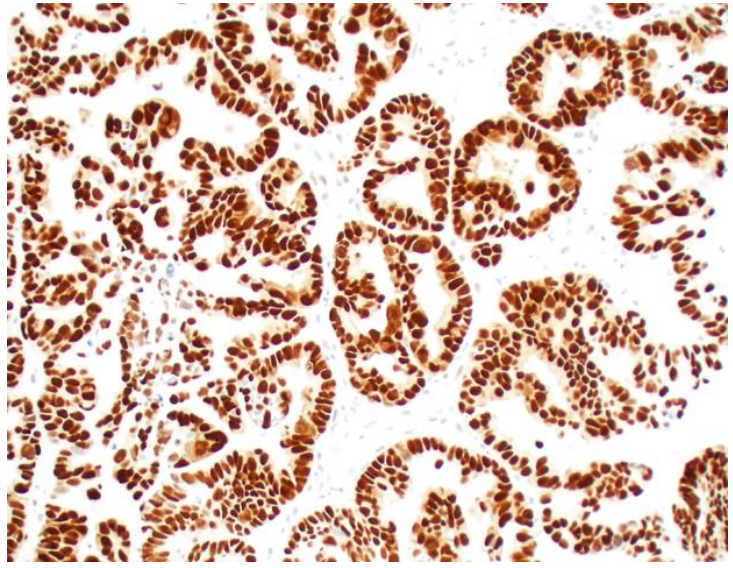

Overexpression pattern

Aberrant result

Null pattern

Aberrant result

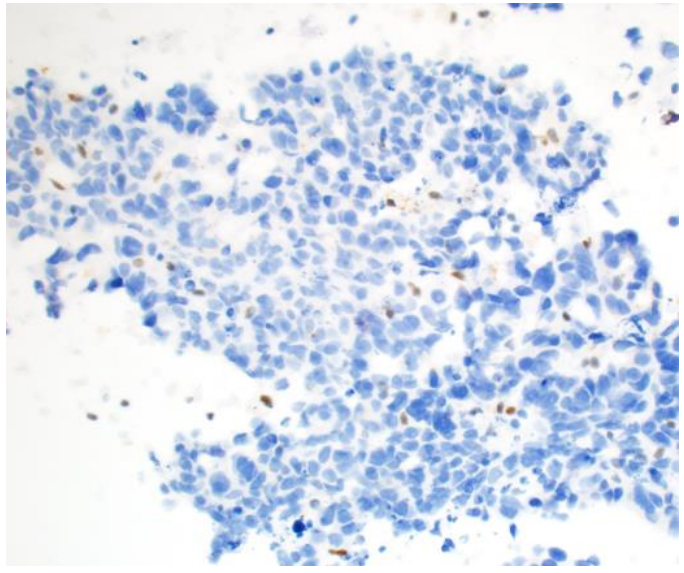

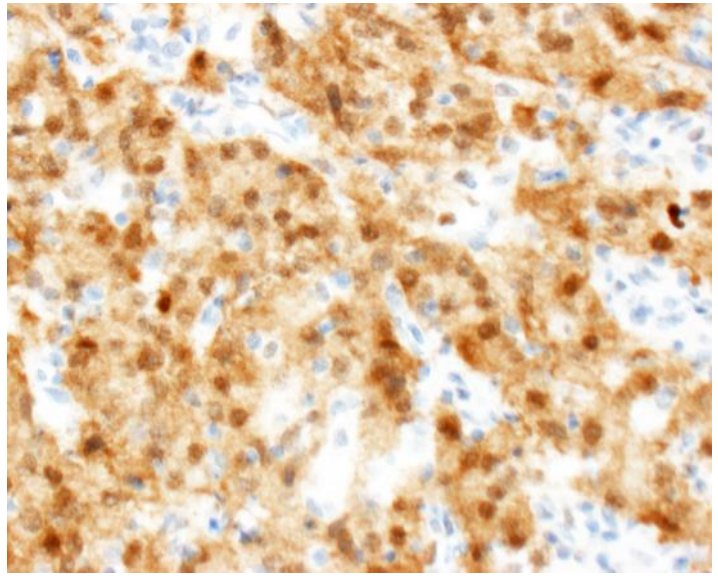

Cytoplasmic pattern

Aberrant result

Extensive Necrosis + “Low Grade” Glandular Pattern Cancer

- *Unlikely to be grade 1 endometrioid carcinoma*
- *Rule out serous carcinoma, carcinosarcoma, dedifferentiated carcinoma, myoinvasive carcinoma*

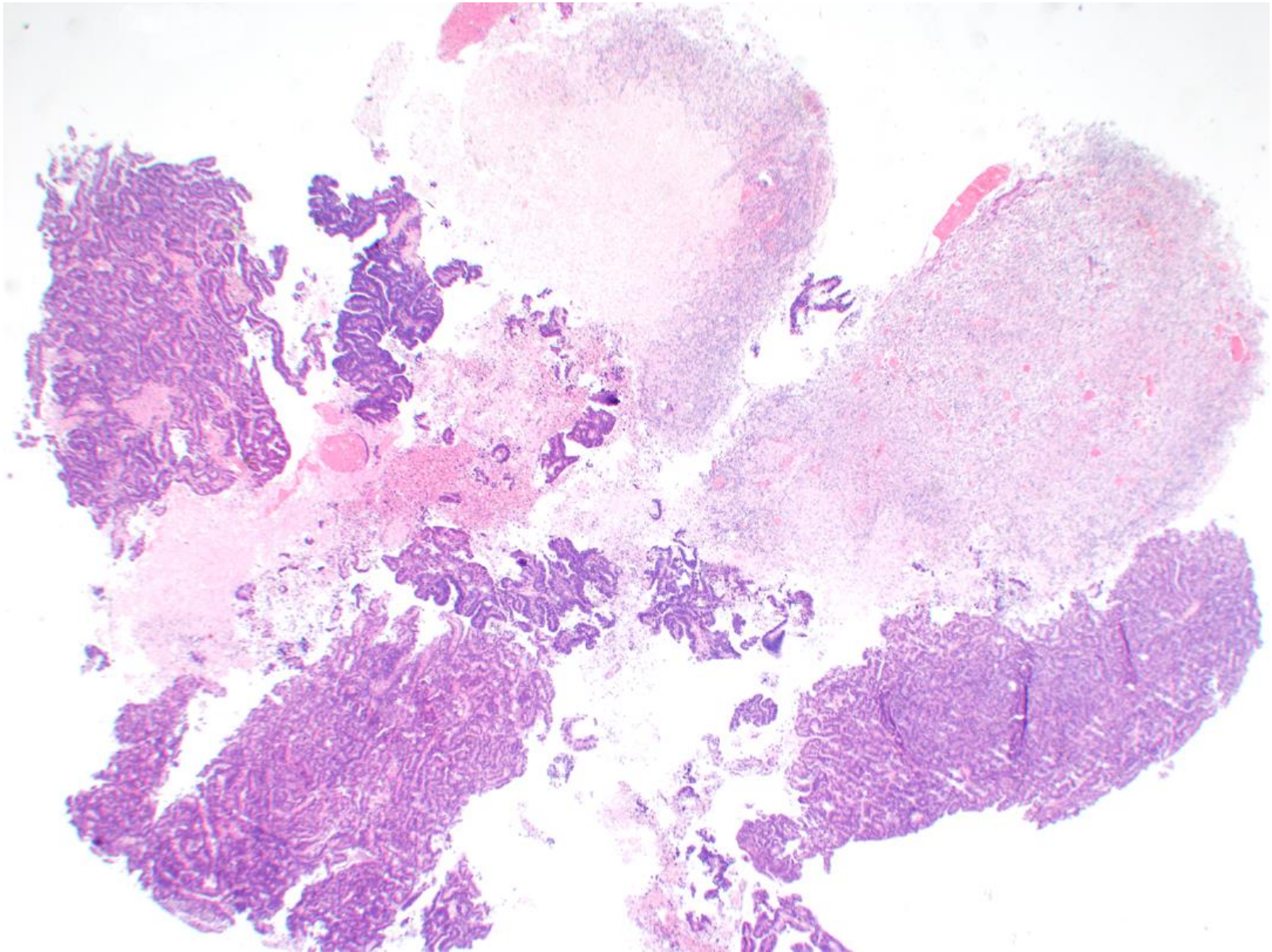

Primary Endocervical Adenocarcinoma

Secondary Involvement of Endometrial Biopsy

- Apical mitotic figures
- Basal apoptotic bodies
- Mucin
- hrHPV ISH+, p16 positive (for HPV-associated types)

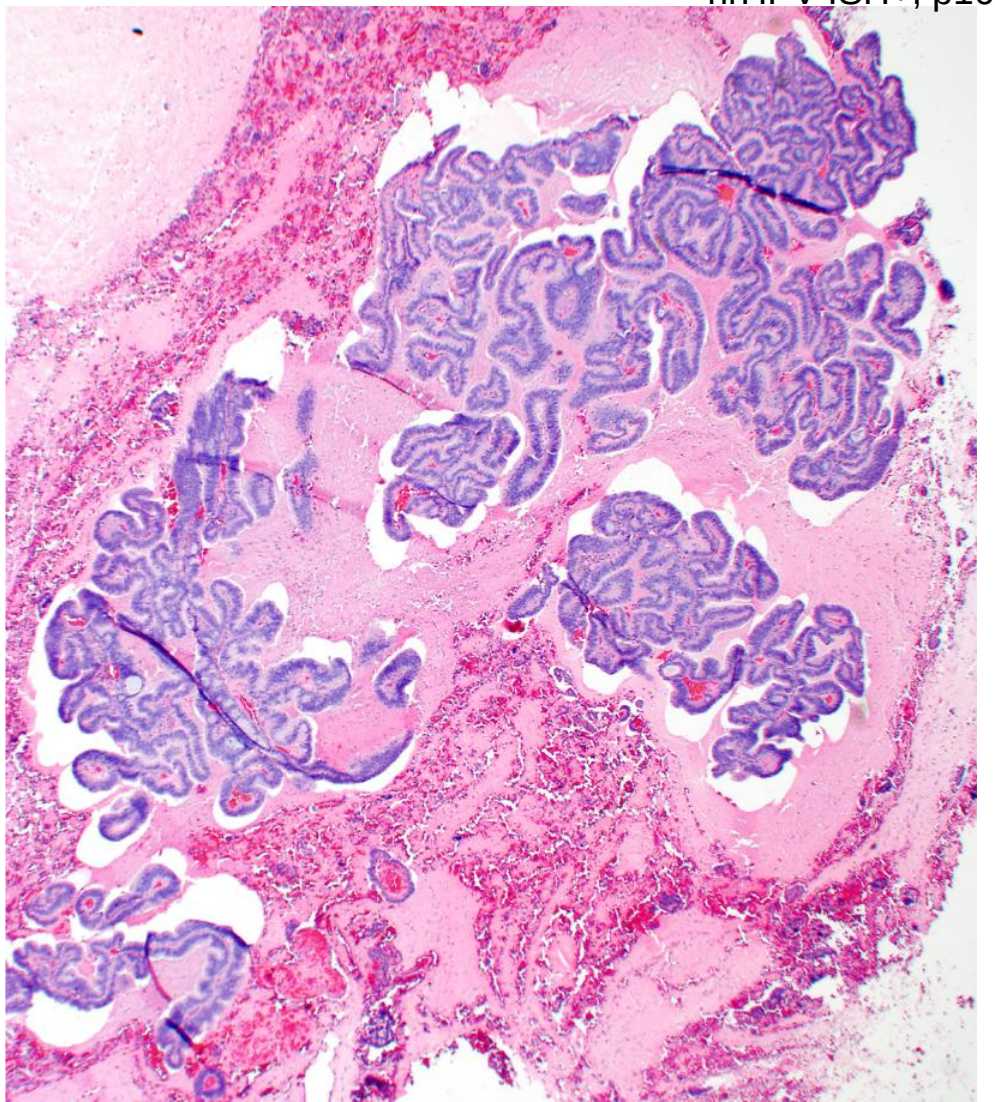

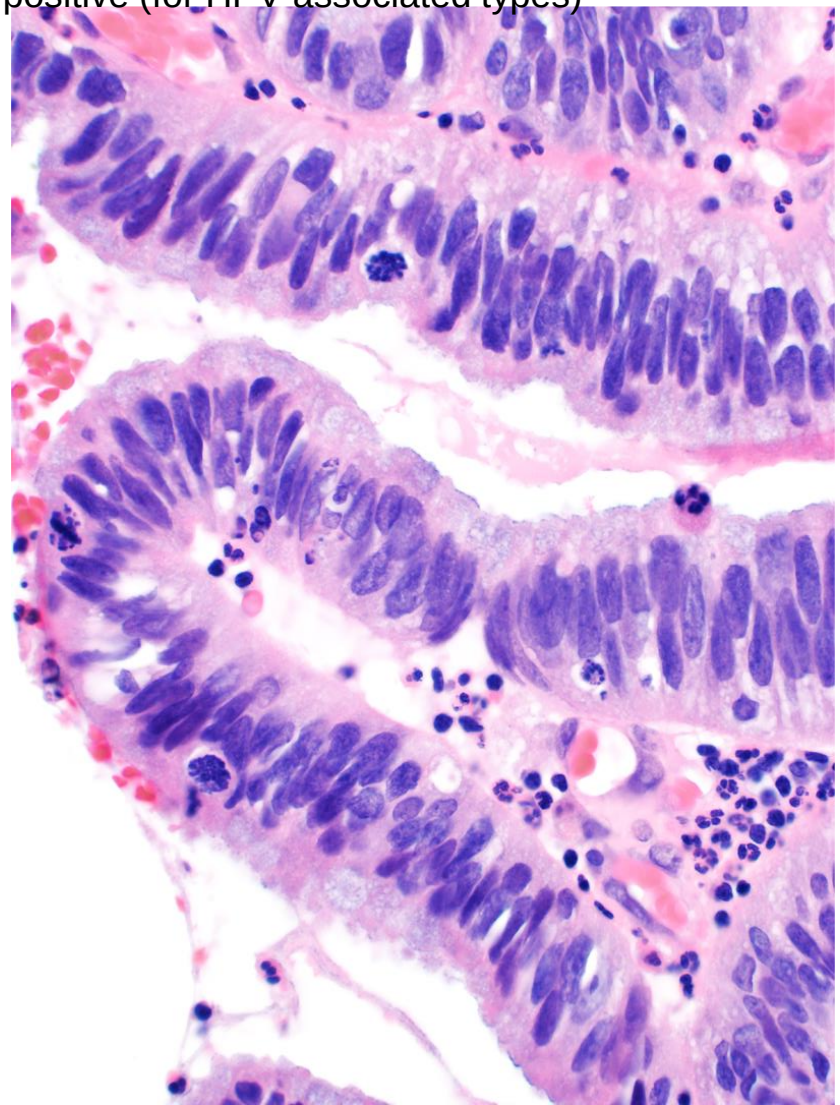

Patterns of Endometrial Epithelial Abnormalities

- Glandular
- **Papillary**

Papillary Pattern Pathology

- Benign
  - **Surface papillary syncytial change**
- Benign but associated with neoplasia *(clinical action advised)*
  - **Papillary proliferation of endometrium**
- Low risk cancer
  - **Papillary variants of low grade endometrioid carcinoma**
  - **Progestin-treated residual endometrioid carcinoma**
- High risk cancer
  - **Serous carcinoma** (classic papillary morphology)
  - **Clear cell carcinoma**
- Secondary cancer
  - **Endocervical adenocarcinoma, villoglandular type**
  - **Pelvic serous tumor**

Distinguishing Endometrioid versus Serous Carcinoma

Concordance of Architecture and Nuclear Grade

	Papillary Variants of Endometrioid Carcinoma	Papillary Pattern Serous Carcinoma
Architectural grade	**Low**	**Low**
Nuclear grade	**Low**	**High**

Concordant **Discordant**

High nuclear grade:

- High N/C ratio
- Pleomorphic
- Hyperchromatic
- Macronucleoli
- Brisk, atypical mitoses

Endometrial Serous Carcinoma

Papillary pattern

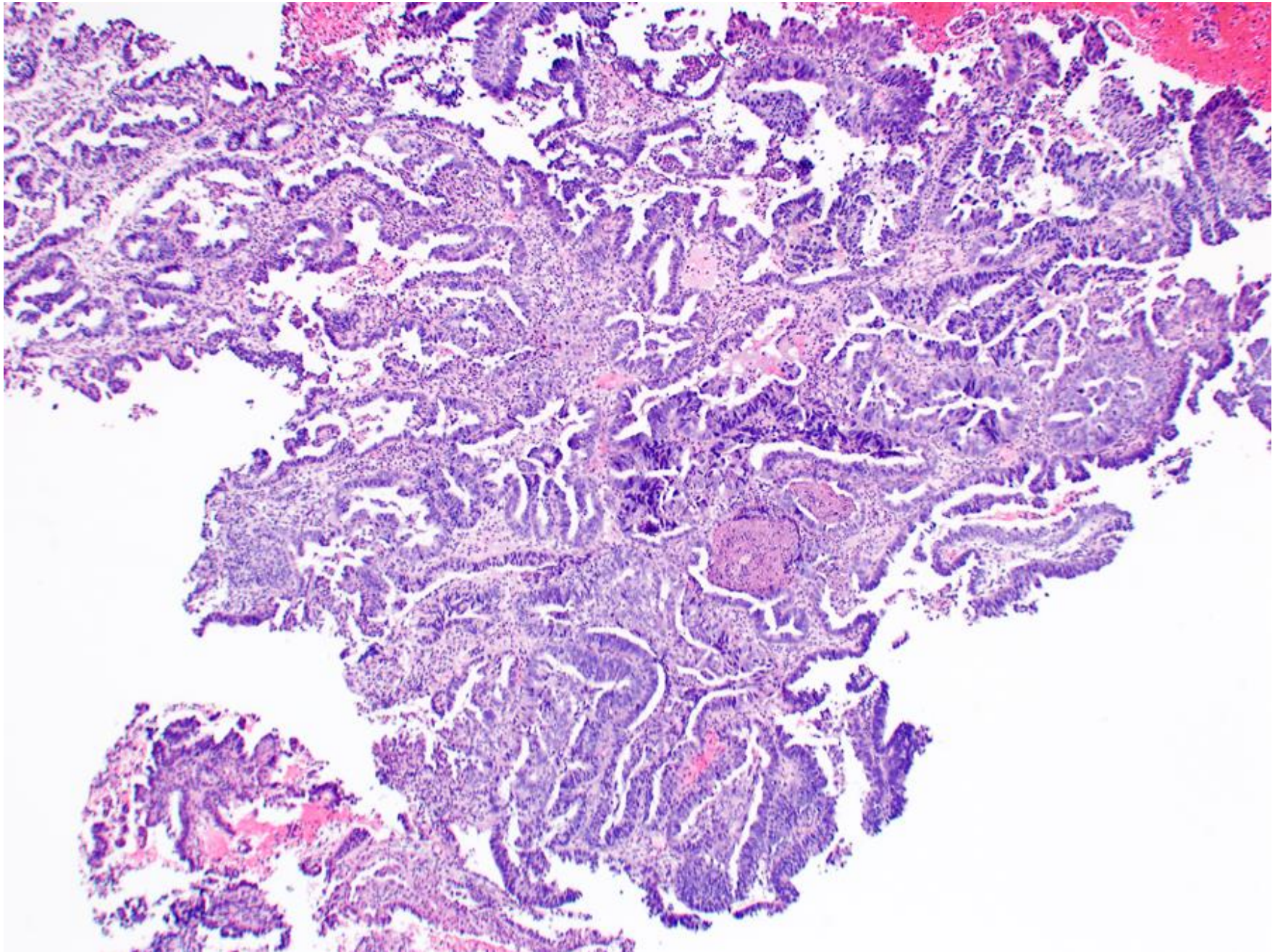

Endometrial Serous Carcinoma

Papillary pattern

Pleomorphic nuclei

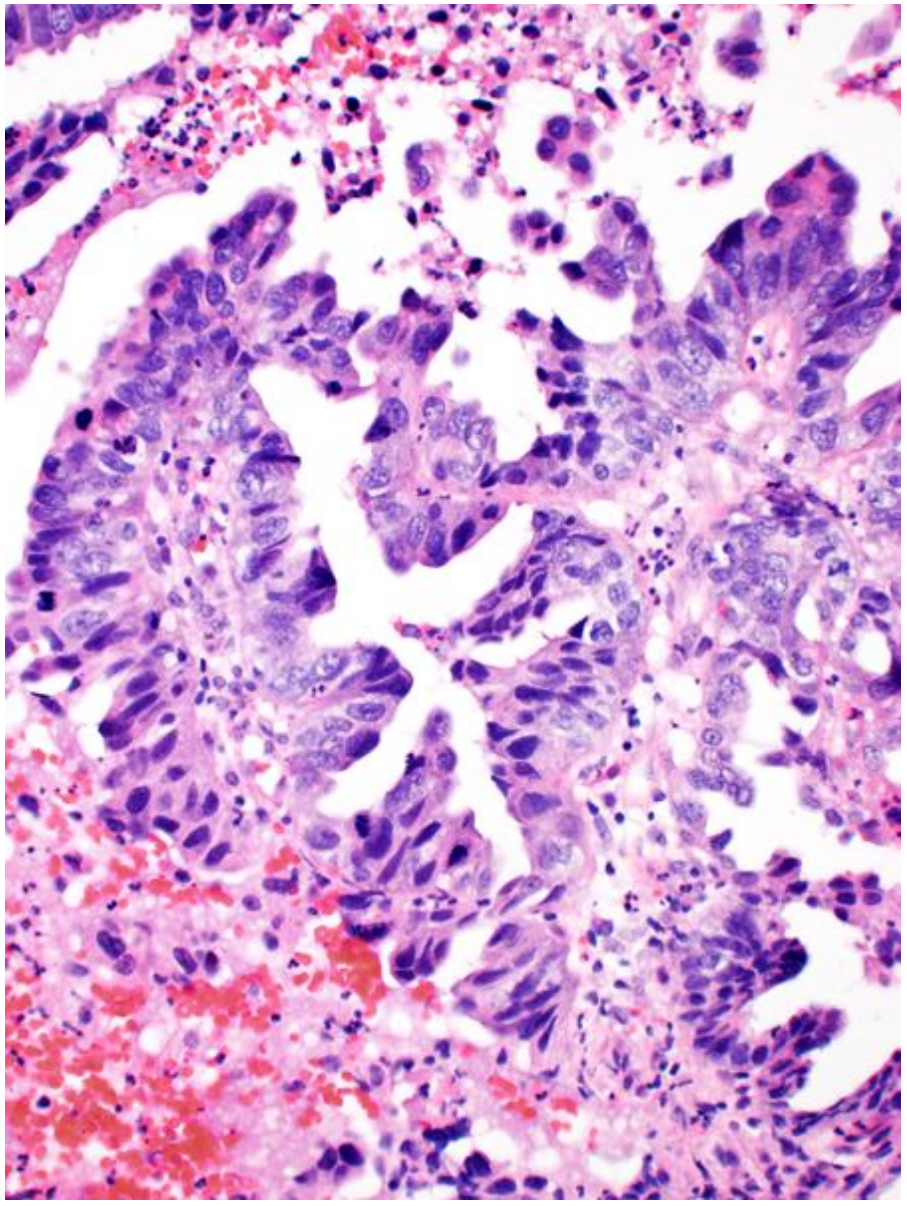

Atypical Mitoses

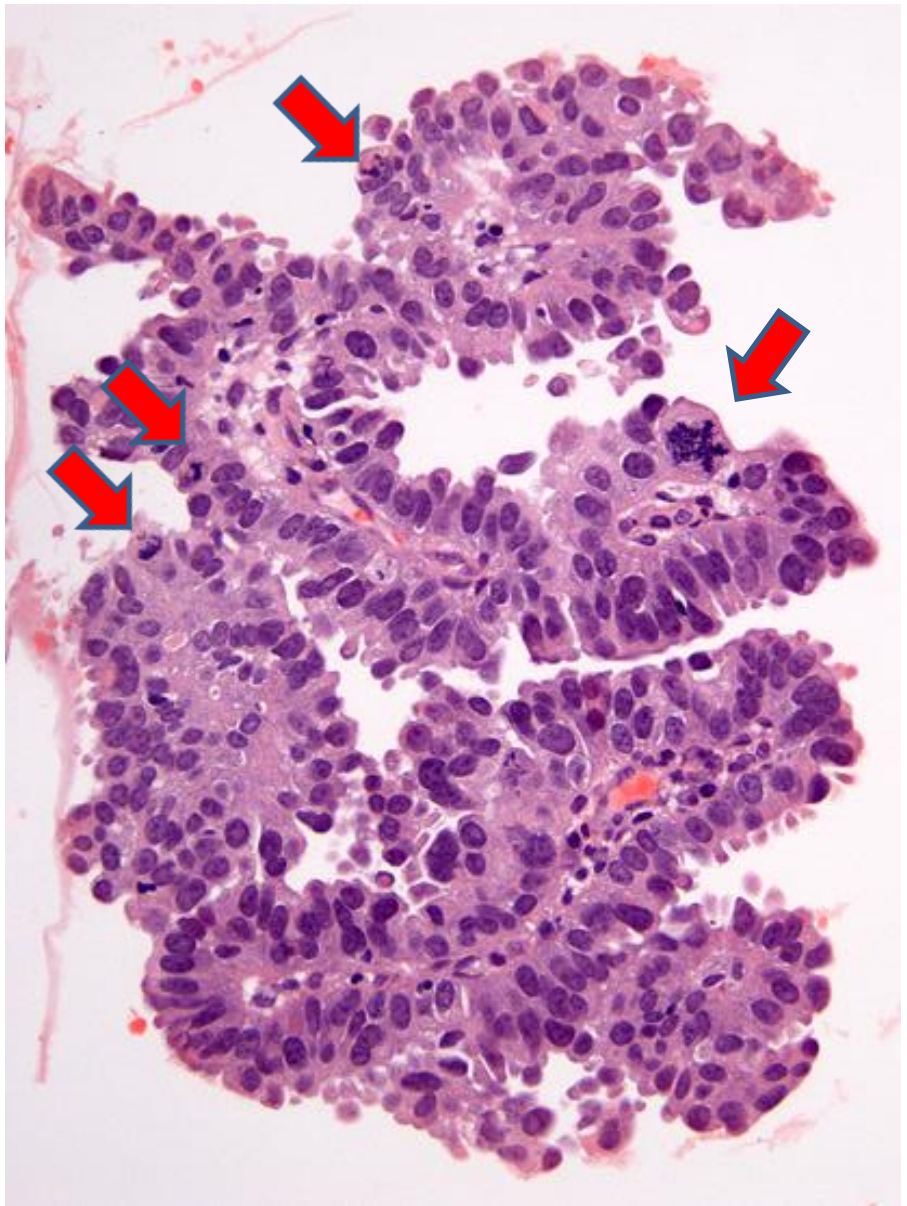

Papillary Variants of Low Grade Endometrioid Carcinoma

May mimic papillary pattern serous carcinoma

- **Villoglandular endometrioid carcinoma**
- **Endometrioid carcinoma with small non-villous papillae**
- **Endometrioid carcinoma with artifactual bud-like sloughing**

Villoglandular endometrioid adenocarcinoma

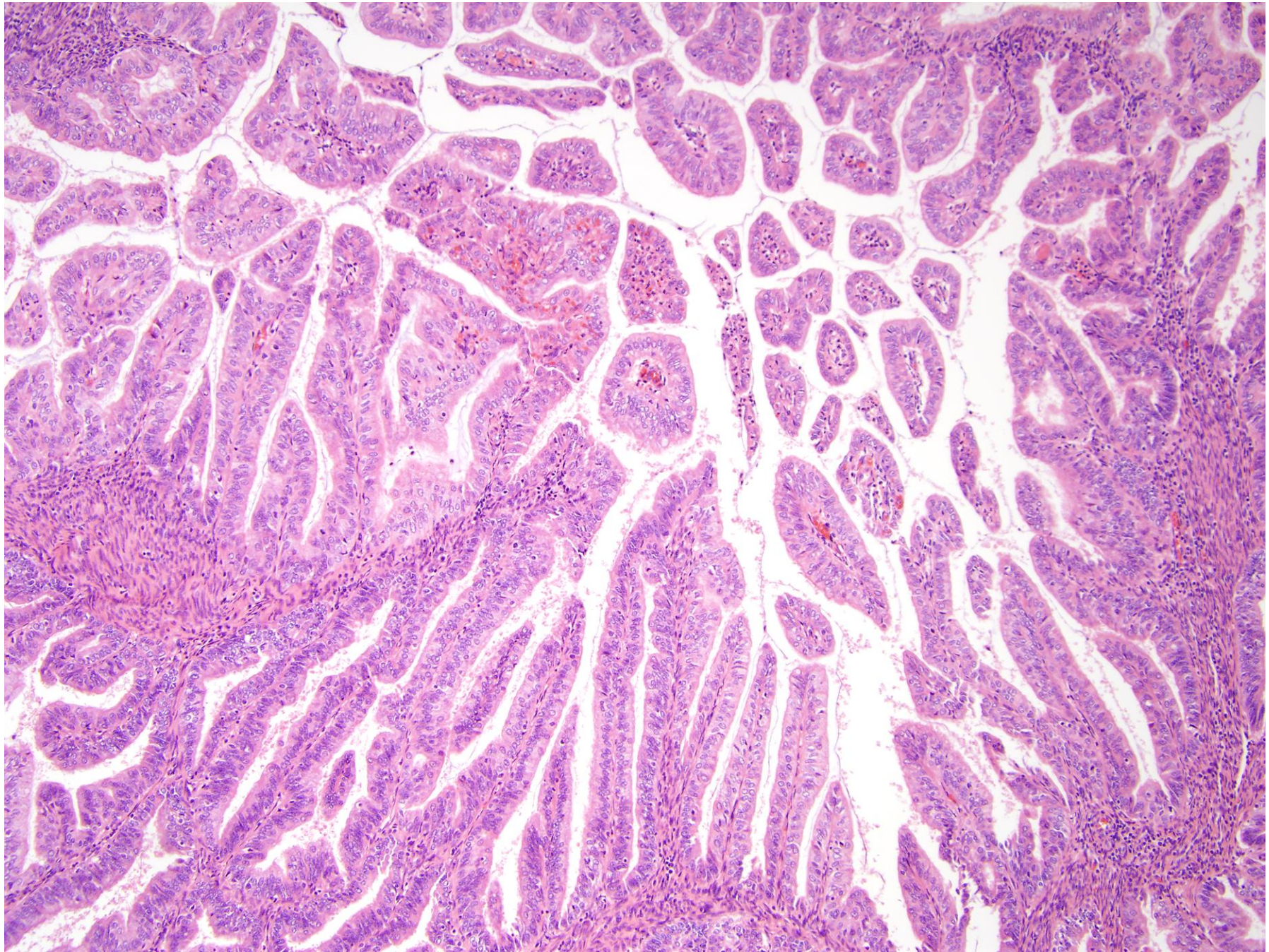

Villoglandular endometrioid adenocarcinoma

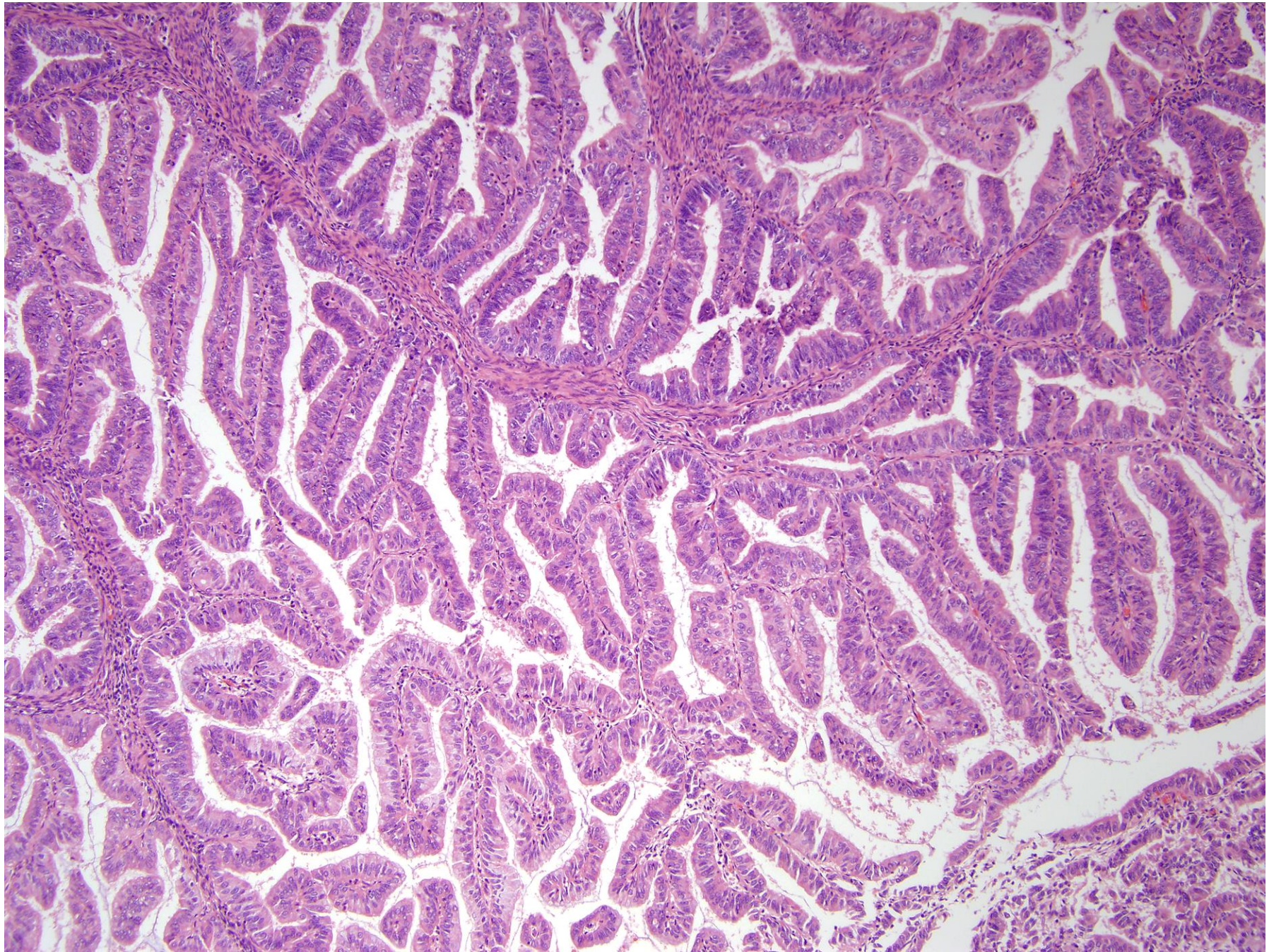

Villoglandular endometrioid adenocarcinoma

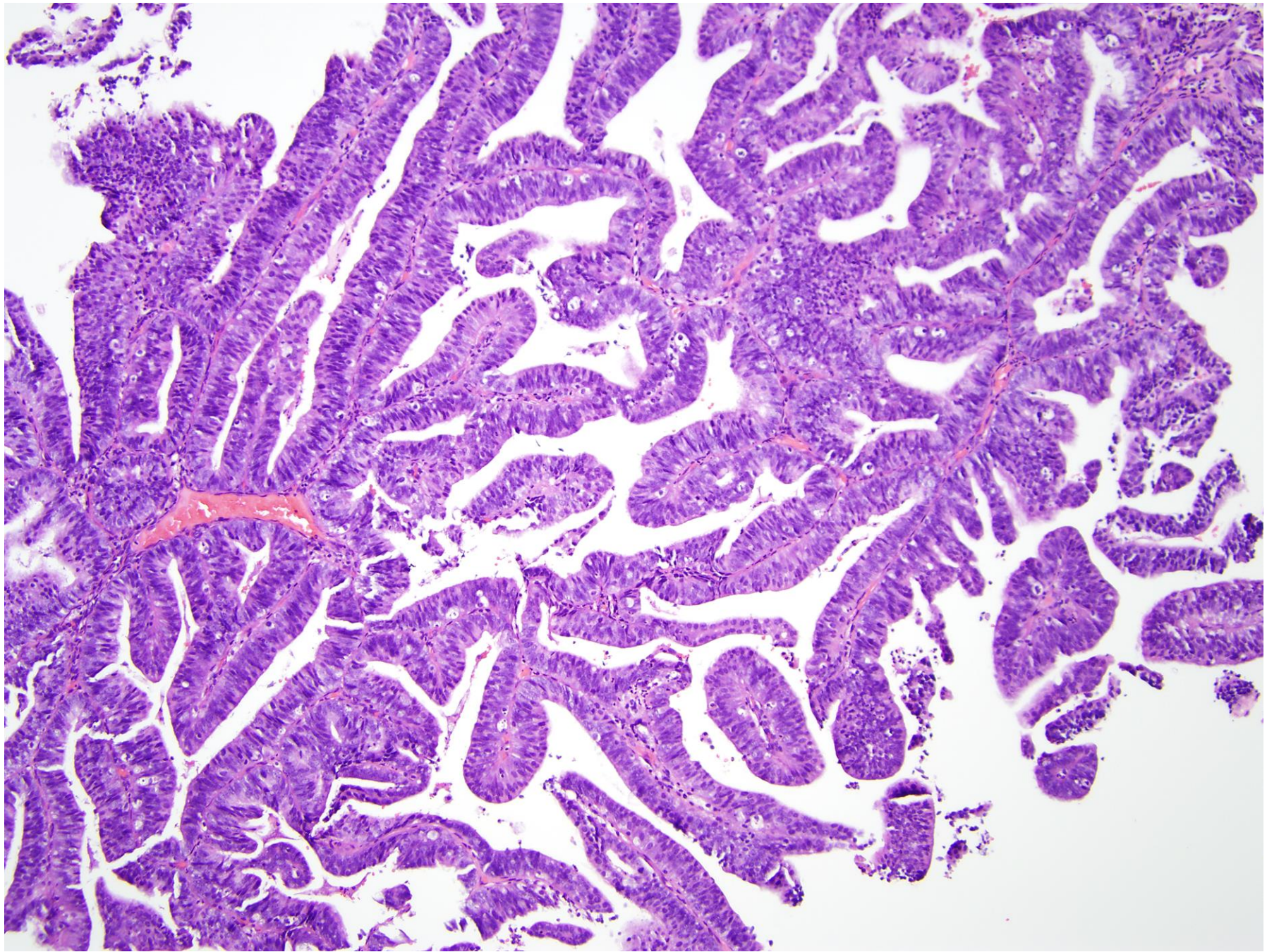

Villoglandular endometrioid adenocarcinoma

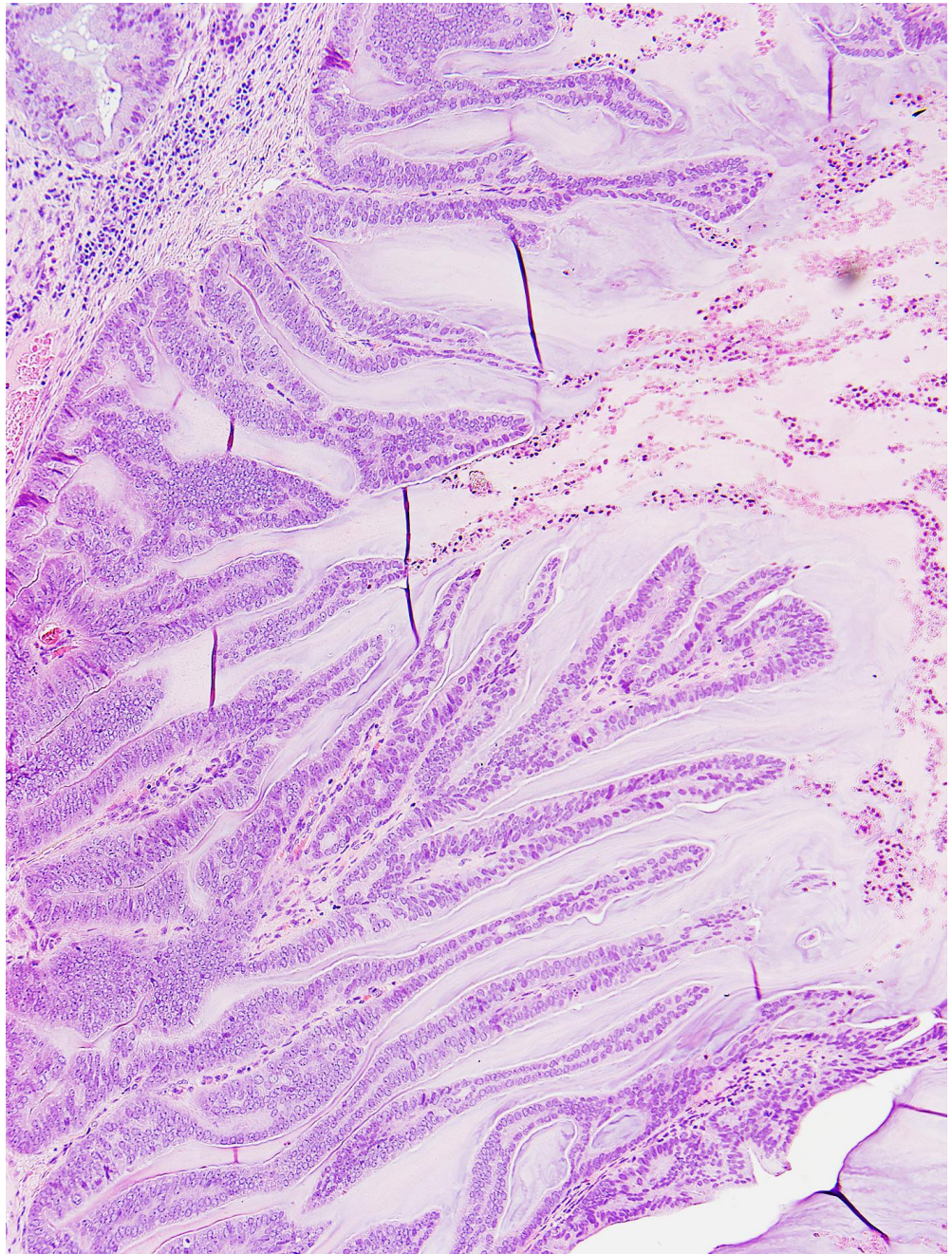

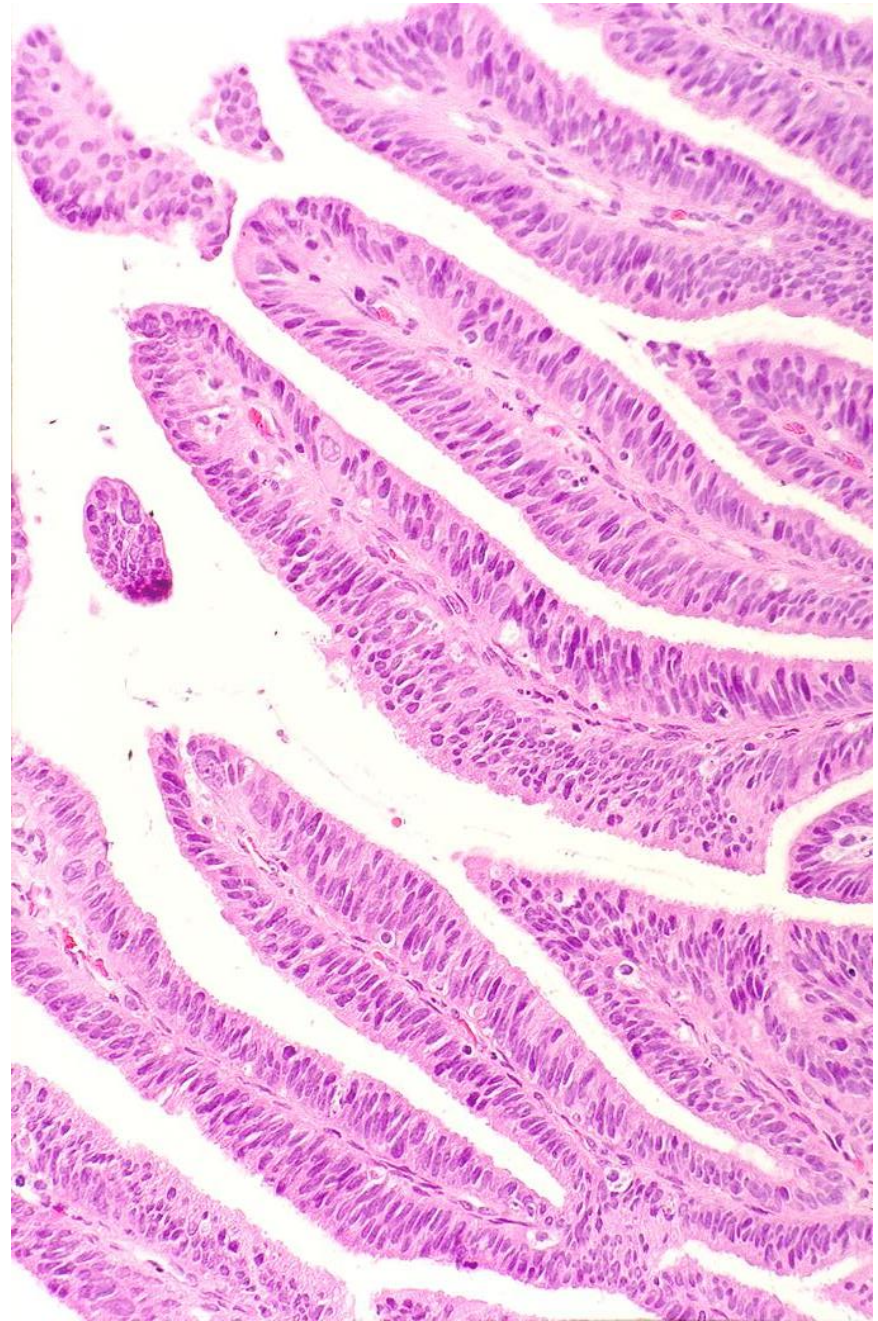

Villoglandular endometrioid adenocarcinoma

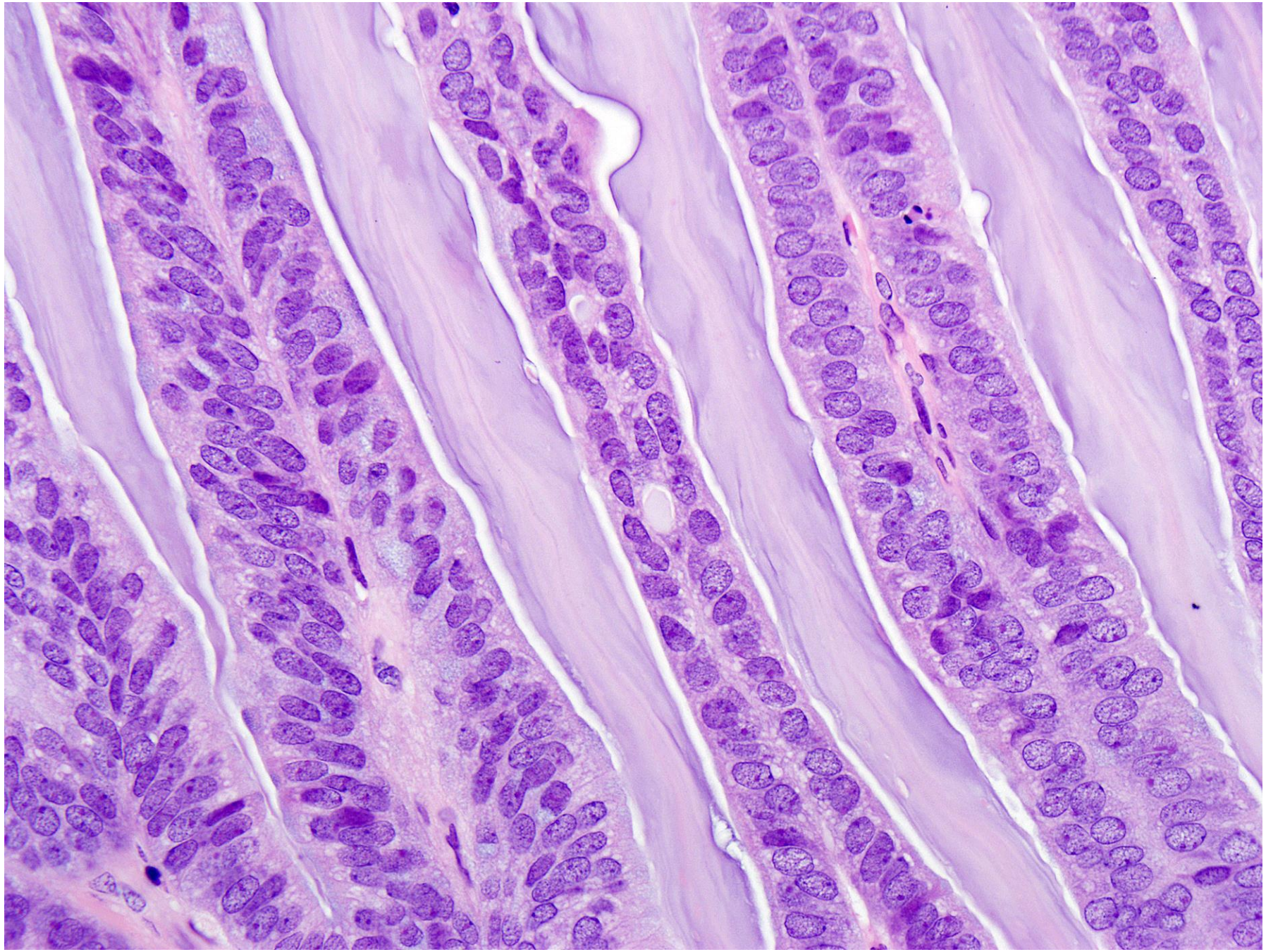

Endometrioid adenocarcinoma with small non-villous papillae

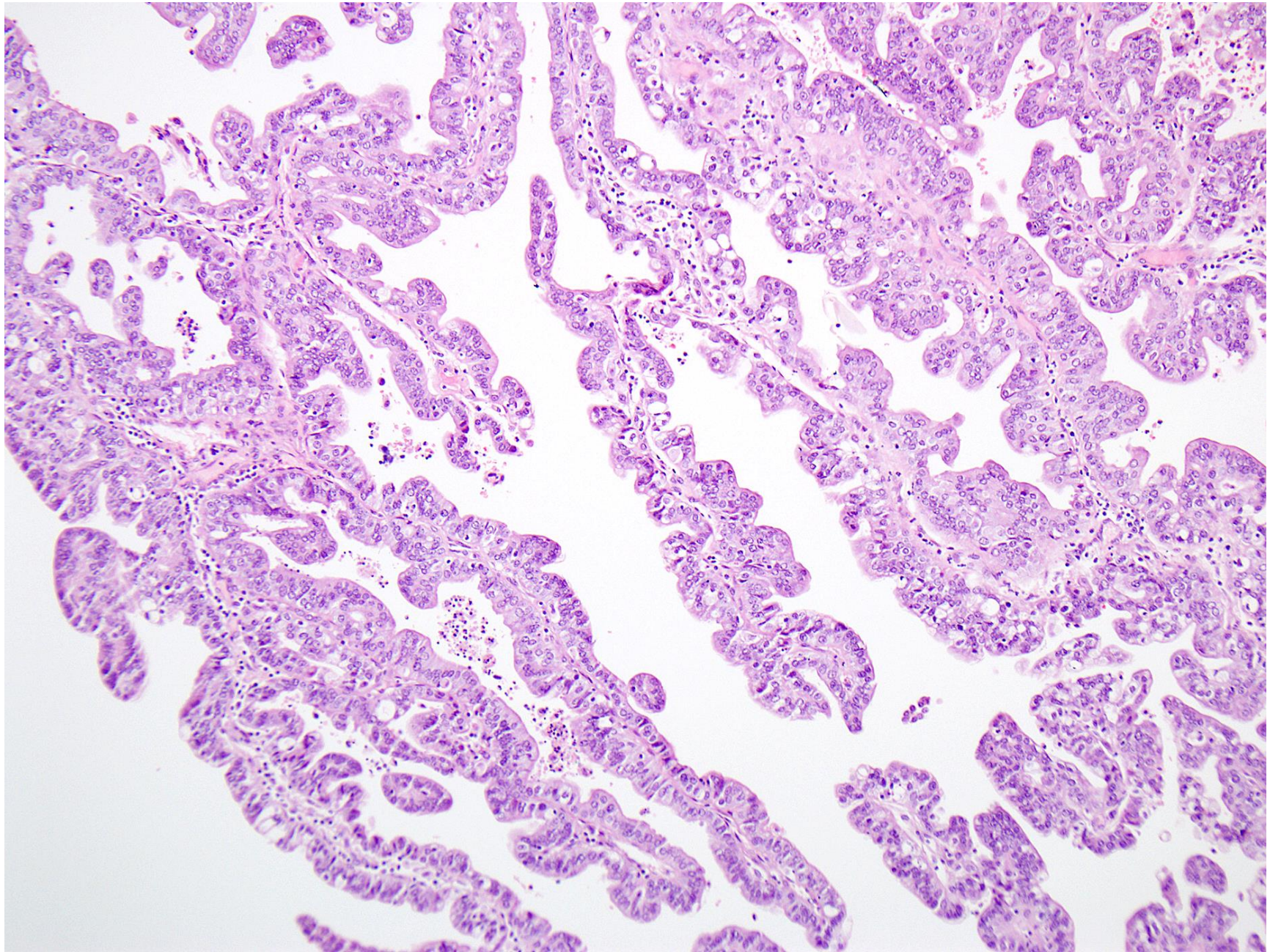

Endometrioid adenocarcinoma with small non-villous papillae

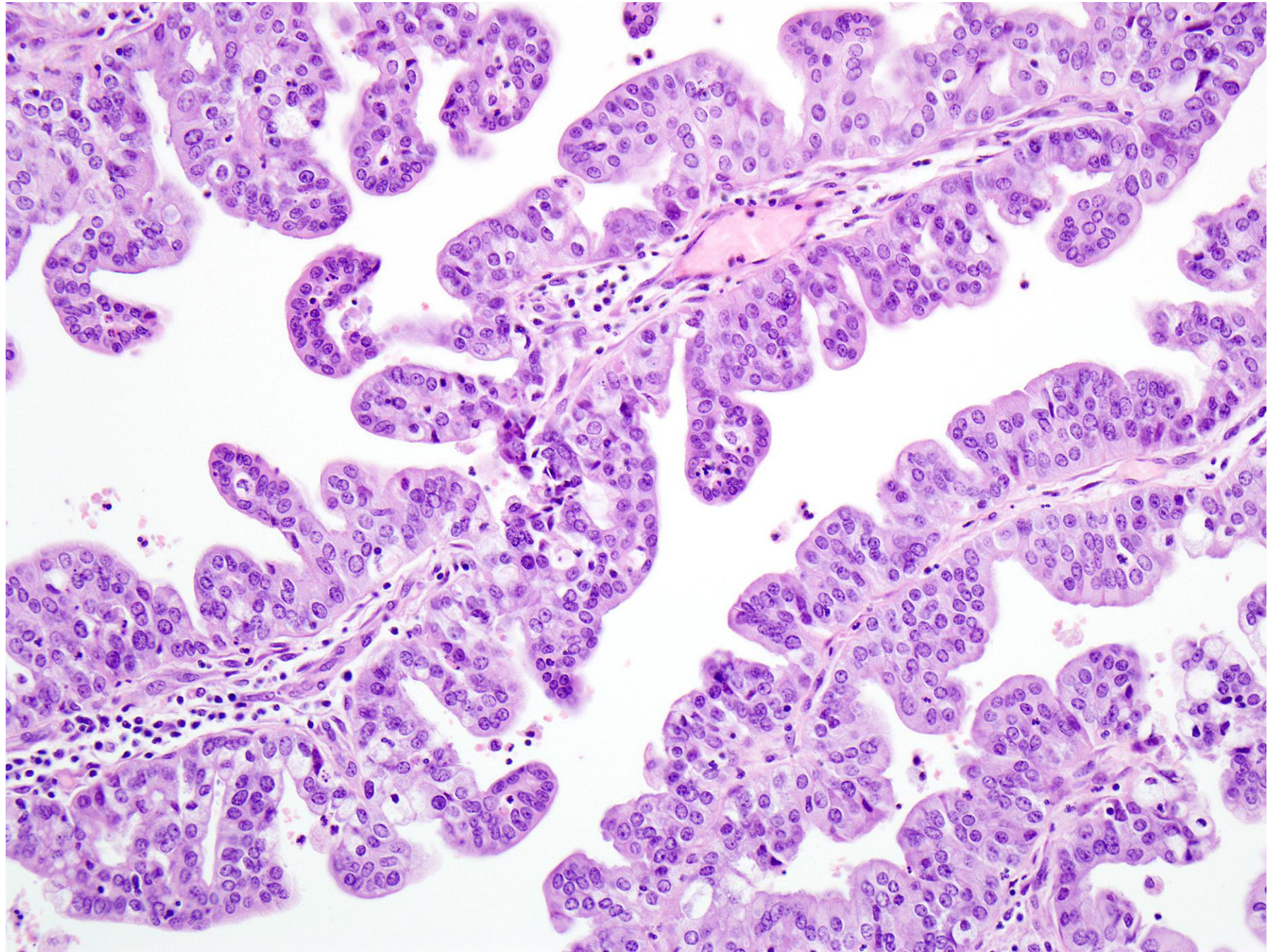

Endometrioid adenocarcinoma with small non-villous papillae

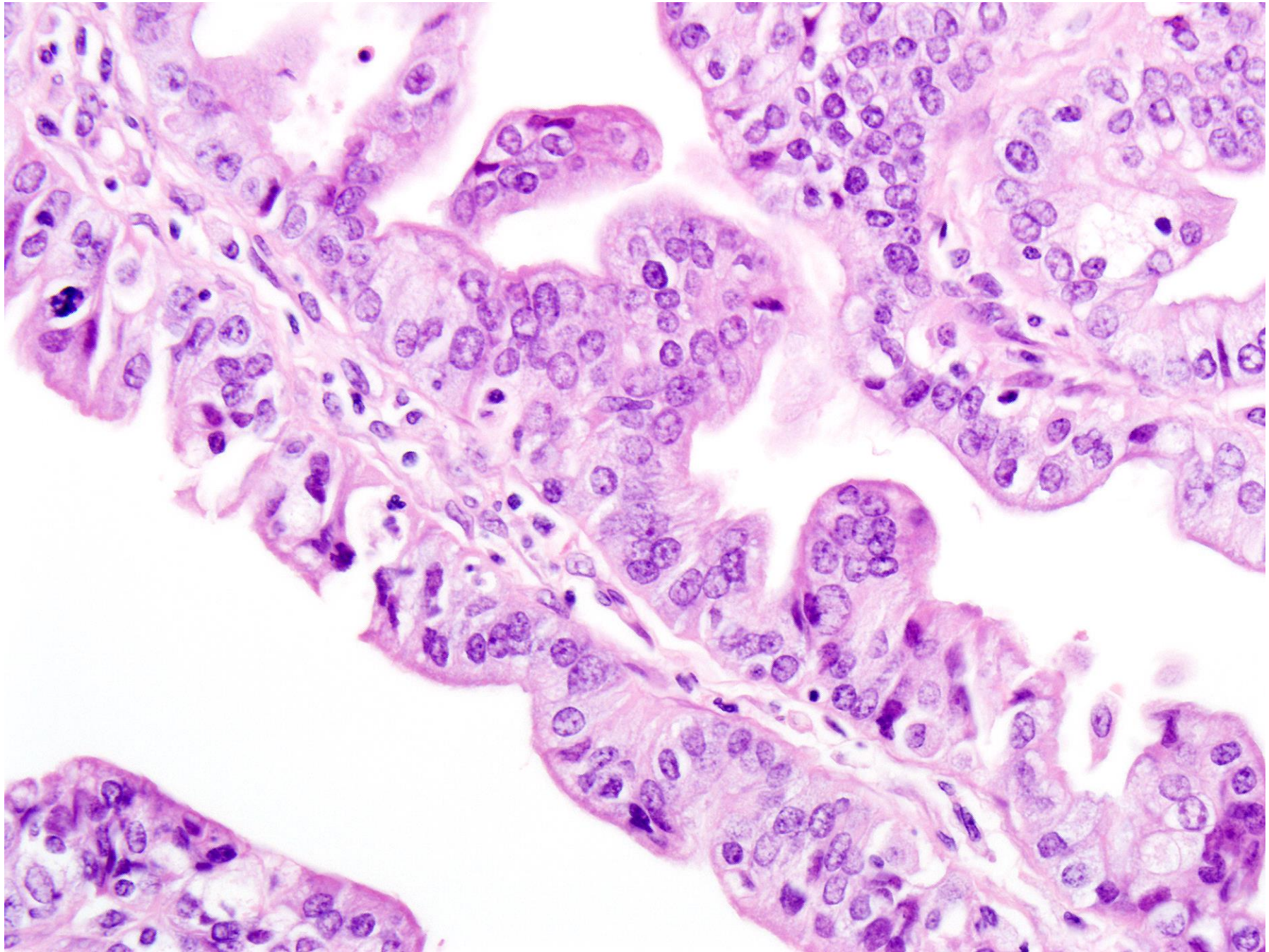

Endometrioid adenocarcinoma with sloughing artifact

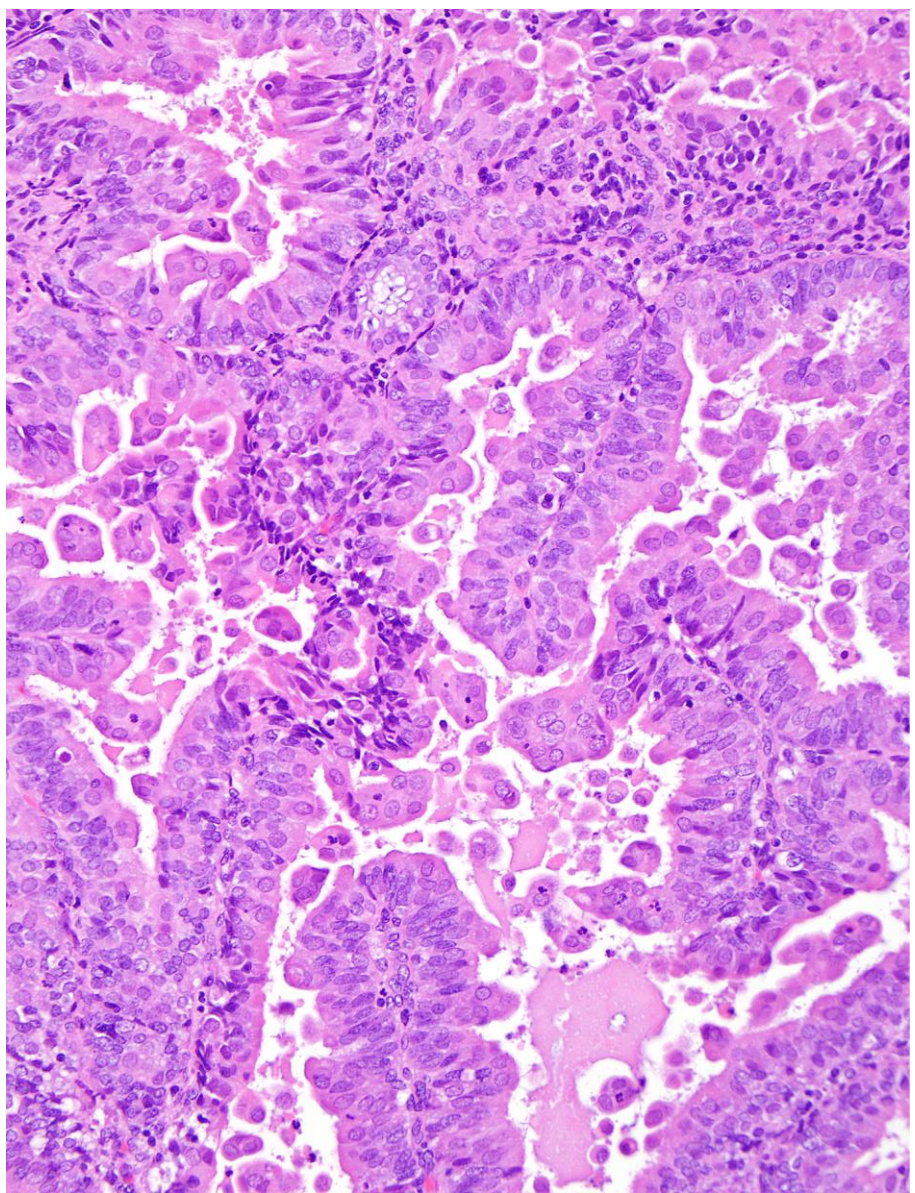

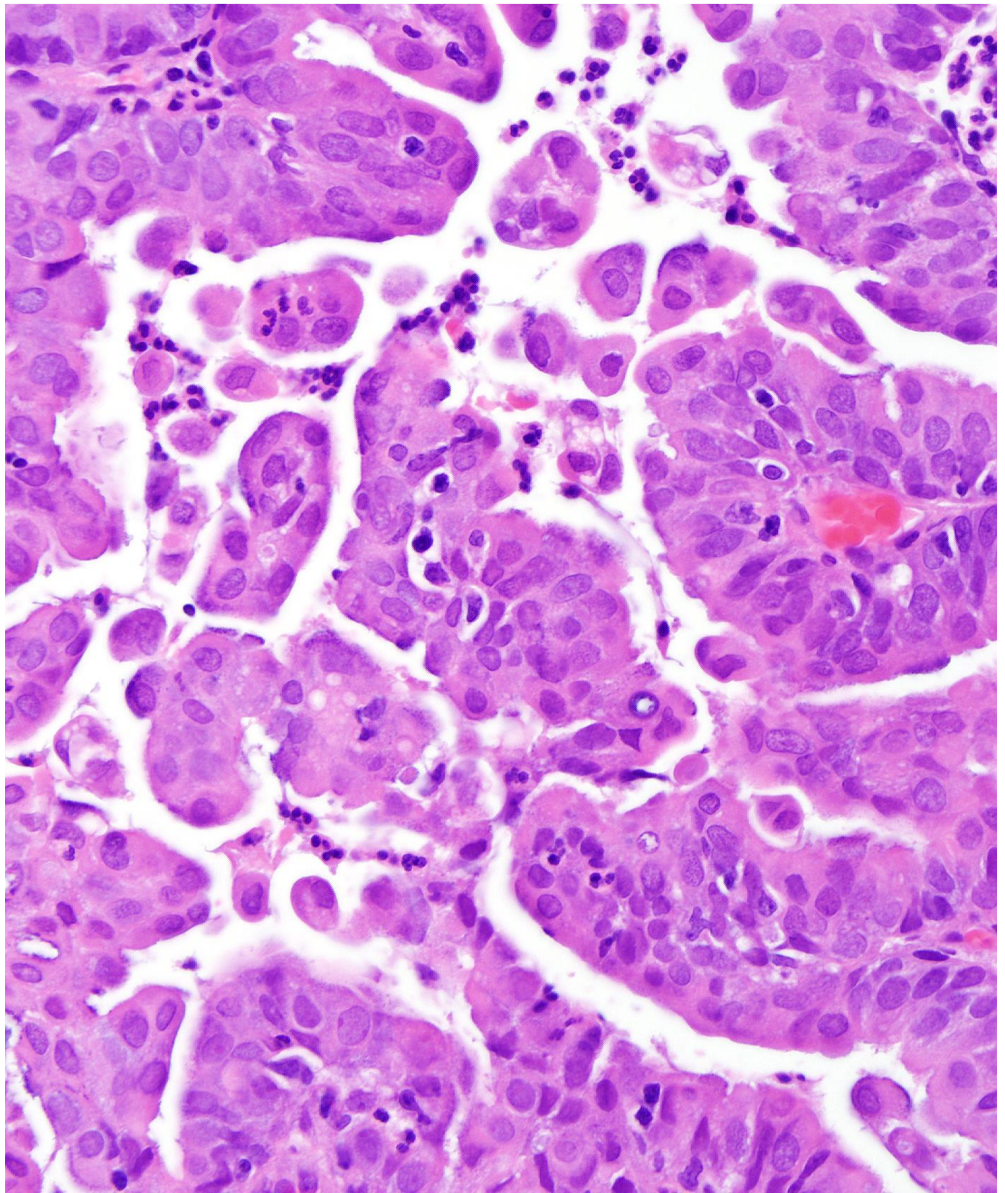

Papillary Pattern Pathology

- Benign
  - **Surface papillary syncytial change**
- Benign but associated with neoplasia *(clinical action advised)*
  - **Papillary proliferation of endometrium**
- Low risk cancer
  - **Papillary variants of low grade endometrioid carcinoma**
  - **Progestin-treated residual endometrioid carcinoma**
- High risk cancer
  - **Serous carcinoma** (classic papillary morphology)
  - **Clear cell carcinoma**
- Secondary cancer
  - **Endocervical adenocarcinoma, villoglandular type**
  - **Pelvic serous tumor**

Surface papillary syncytial change

Definition

- **Benign degenerative / reactive change**
- **Associated with stromal breakdown**
- **Often accompanied by ciliated metaplasia**

Morphology

Architecture
Loss of columnar shaped endometrial epithelium
Syncytial formation, stratification
Tufting, bud-like micropapillary branching, hobnail growth
Overlying condensed stromal aggregates

Cytology
Abundant eosinophilic cytoplasm (low N/C ratio)
Bland nuclei
No mitoses

Surface papillary syncytial change

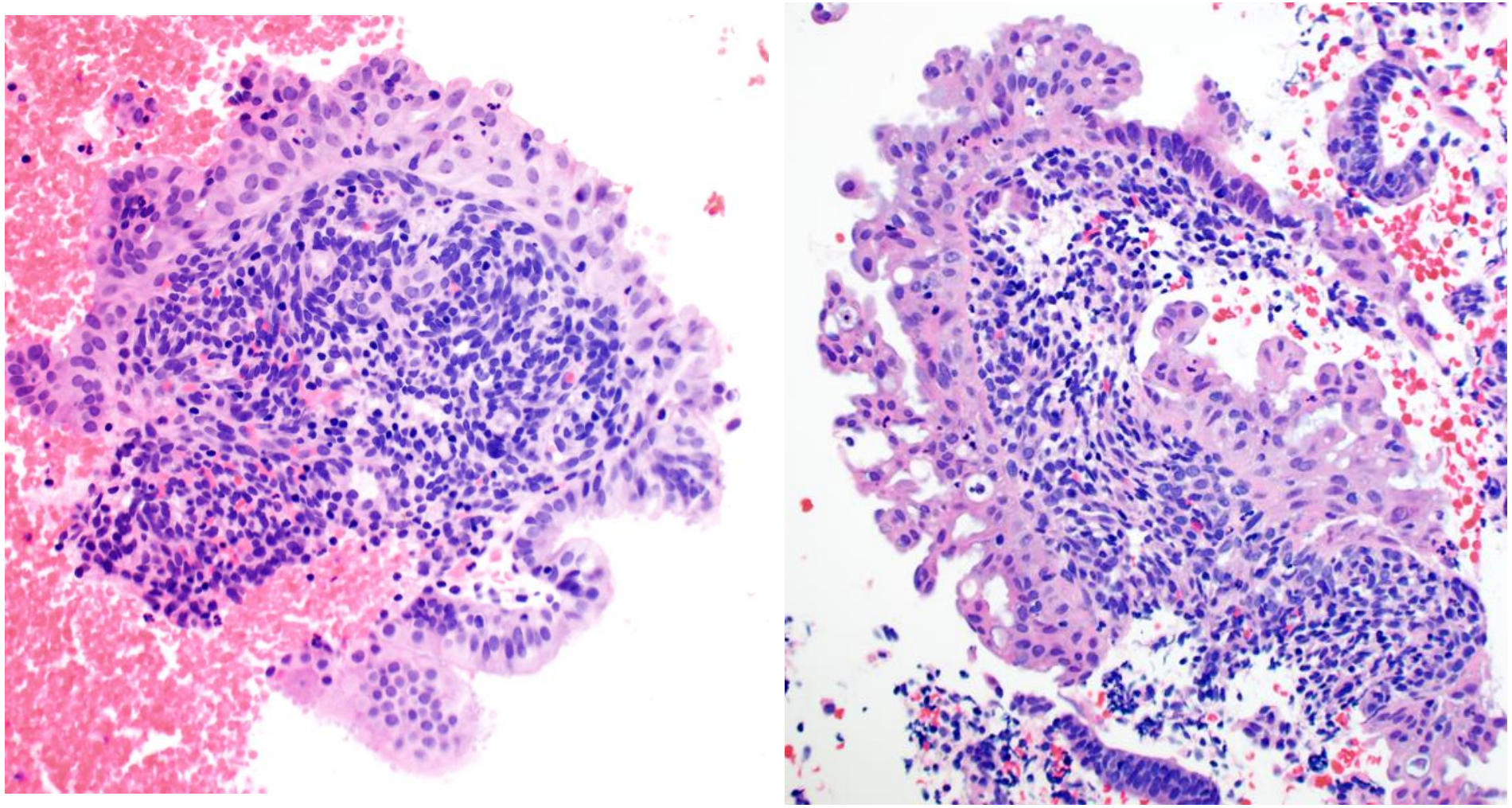

Surface papillary syncytial change

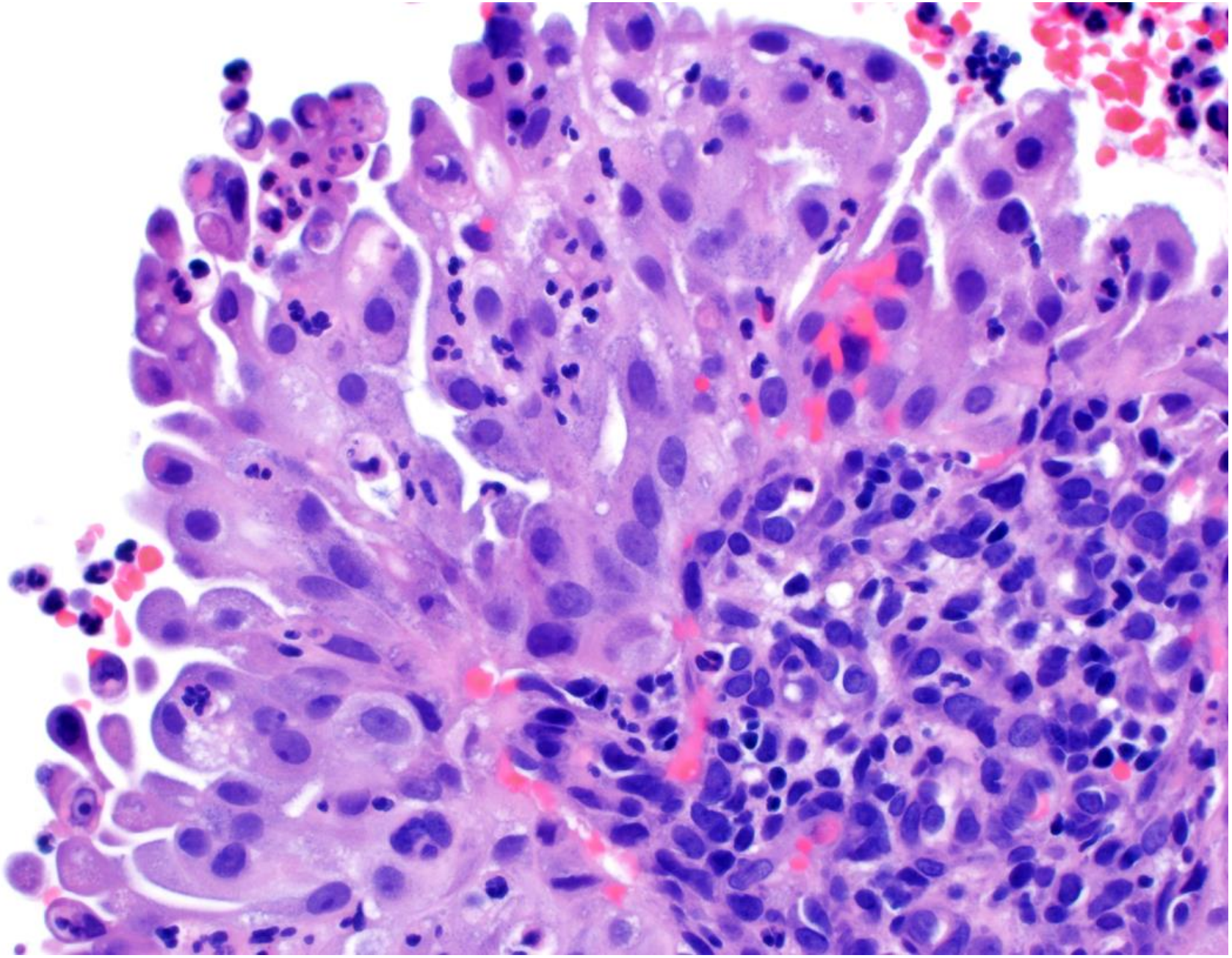

Surface papillary syncytial change

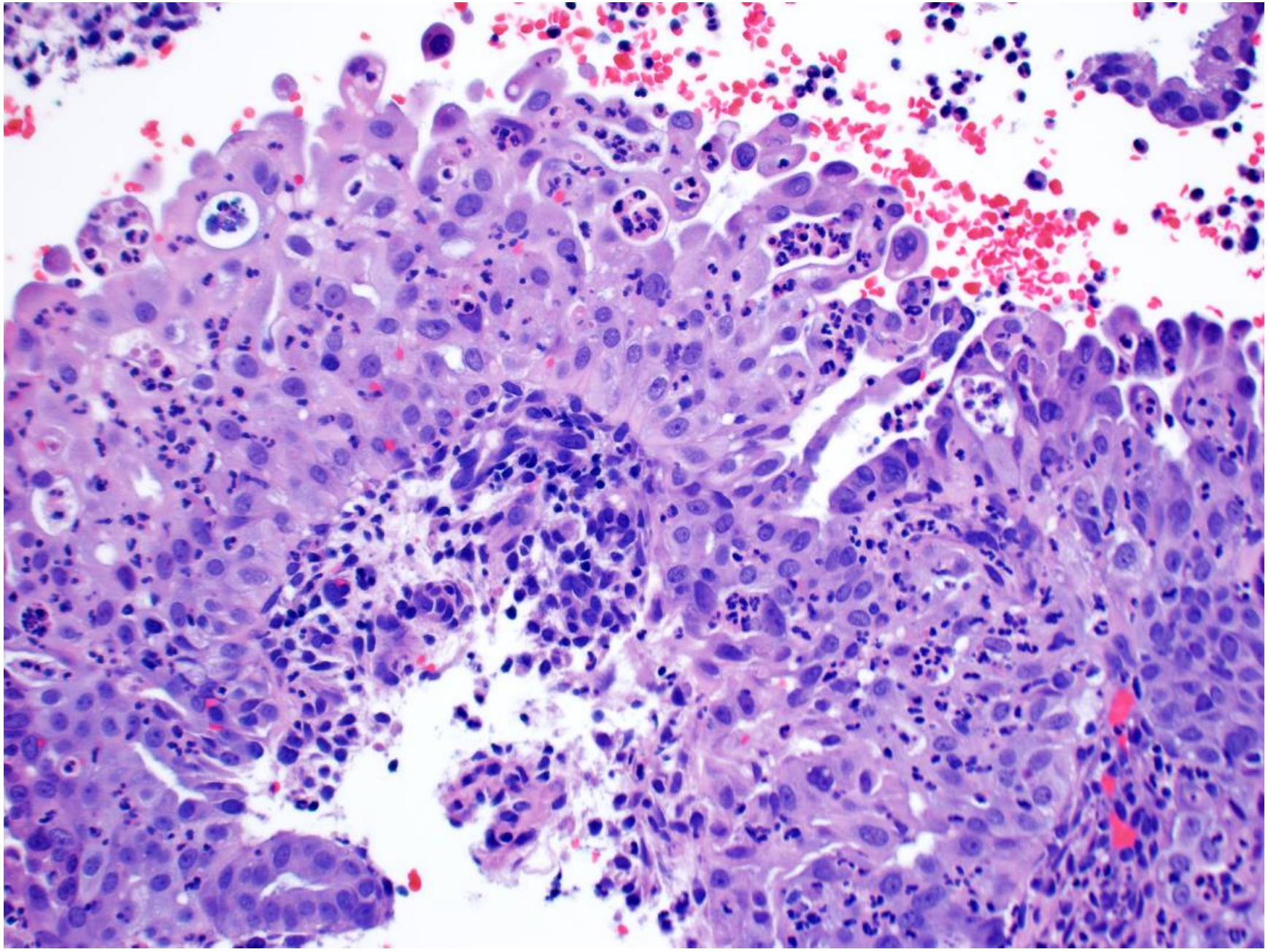

Surface papillary syncytial change

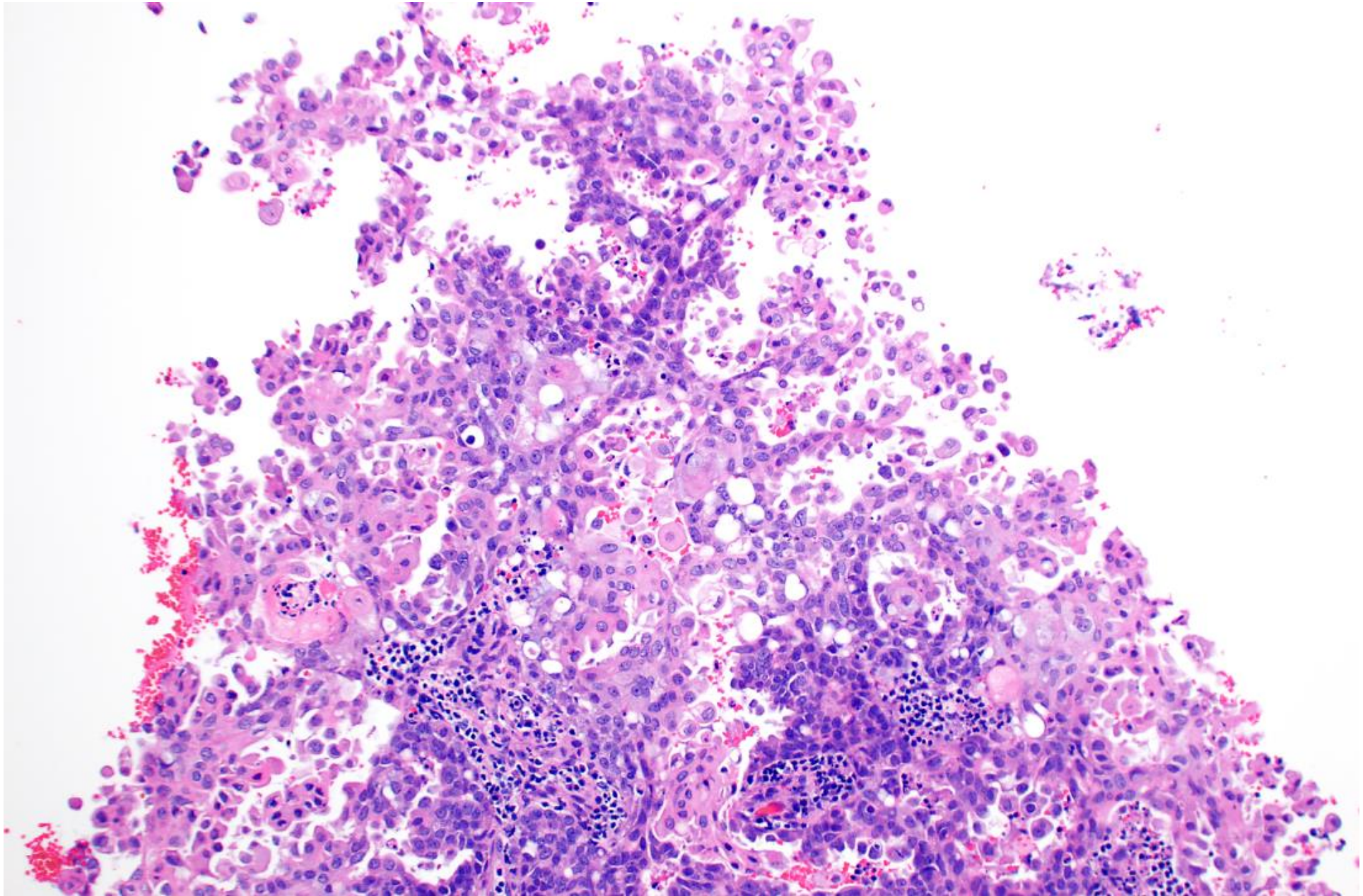

Papillary Pattern Pathology

- Benign
  - **Surface papillary syncytial change**
- Benign but associated with neoplasia *(clinical action advised)*
  - **Papillary proliferation of endometrium**
- Low risk cancer
  - **Papillary variants of low grade endometrioid carcinoma**
  - **Progestin-treated residual endometrioid carcinoma**
- High risk cancer
  - **Serous carcinoma** (classic papillary morphology)
  - **“Minimal” serous carcinoma**
- Secondary cancer
  - **Endocervical adenocarcinoma, villoglandular type**
  - **Pelvic serous tumor**

Minimal Forms of Endometrial Serous Carcinoma

Definition

- **Not a diagnostic category or specific tumor “type”**
- **A descriptive term for small volume tumor (< 1cm)**
- **<u>Same clinical significance/management</u> as typical serous carcinoma**

~50% chance of extra-uterine disease even if uterine involvement is confined to microscopic foci in a polyp

Presentation

- **Predilection for elderly women**
- **Often involves atrophic endometrium or endometrial polyp**

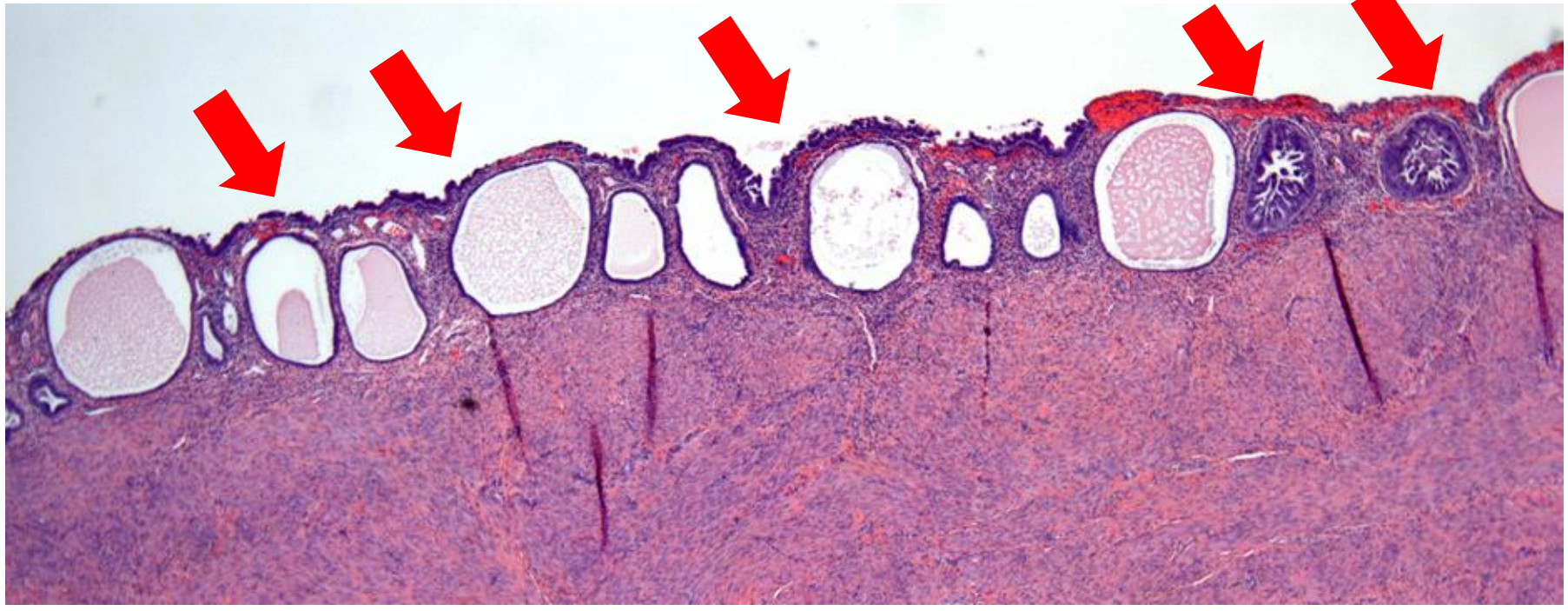

Minimal Forms of Endometrial Serous Carcinoma

Diagnostic criteria:

- **Cytologic features are sufficient.** No architectural alteration required
- **High N/C ratio**
- **Severe nuclear pleomorphism**
- **Brisk, atypical mitoses**
- **Aberrant p53, p16** (same as for typical serous carcinoma)

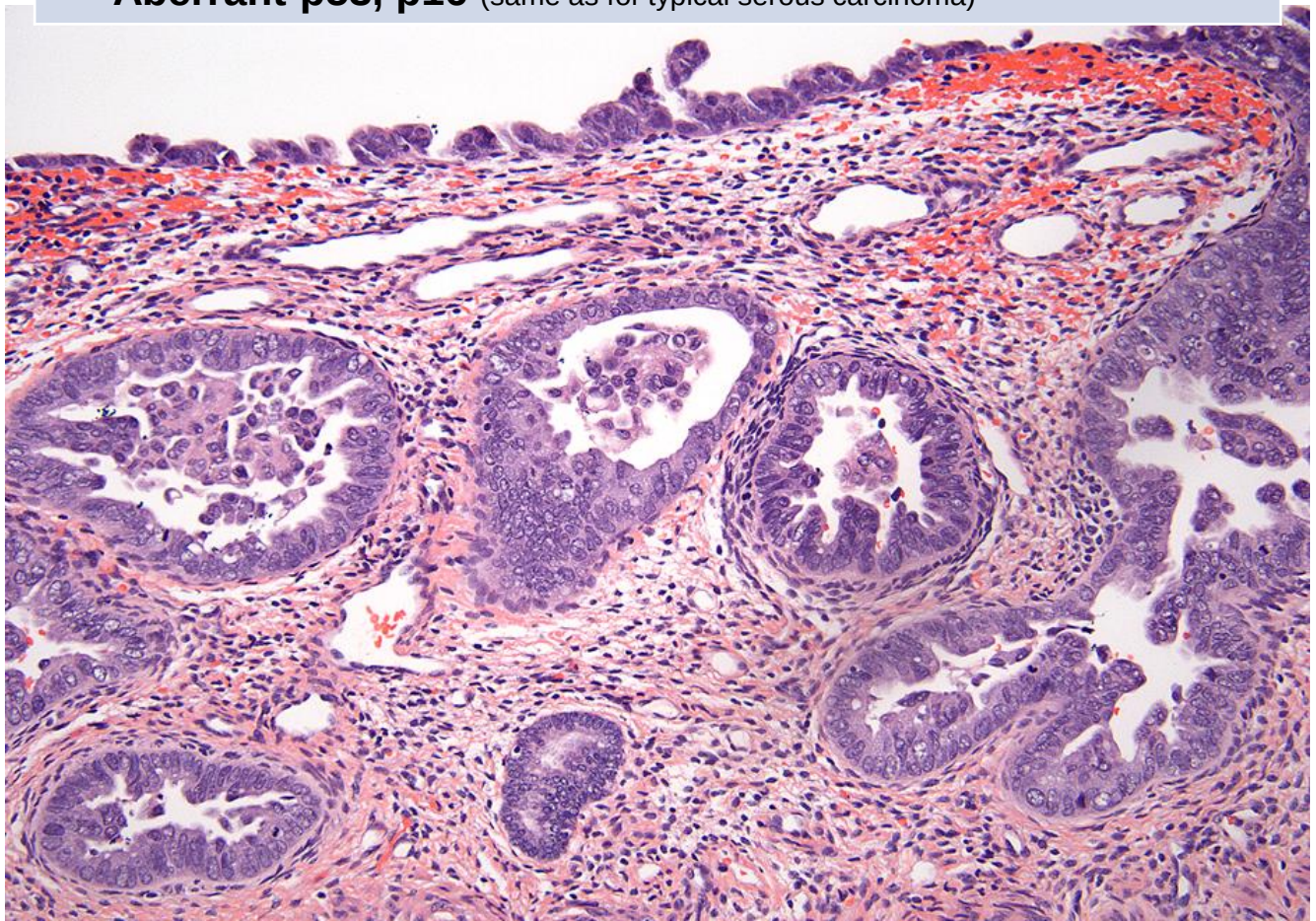

Minimal Forms of Endometrial Serous Carcinoma

Diagnostic Problem in Biopsy:

Only scant detached strips and clusters

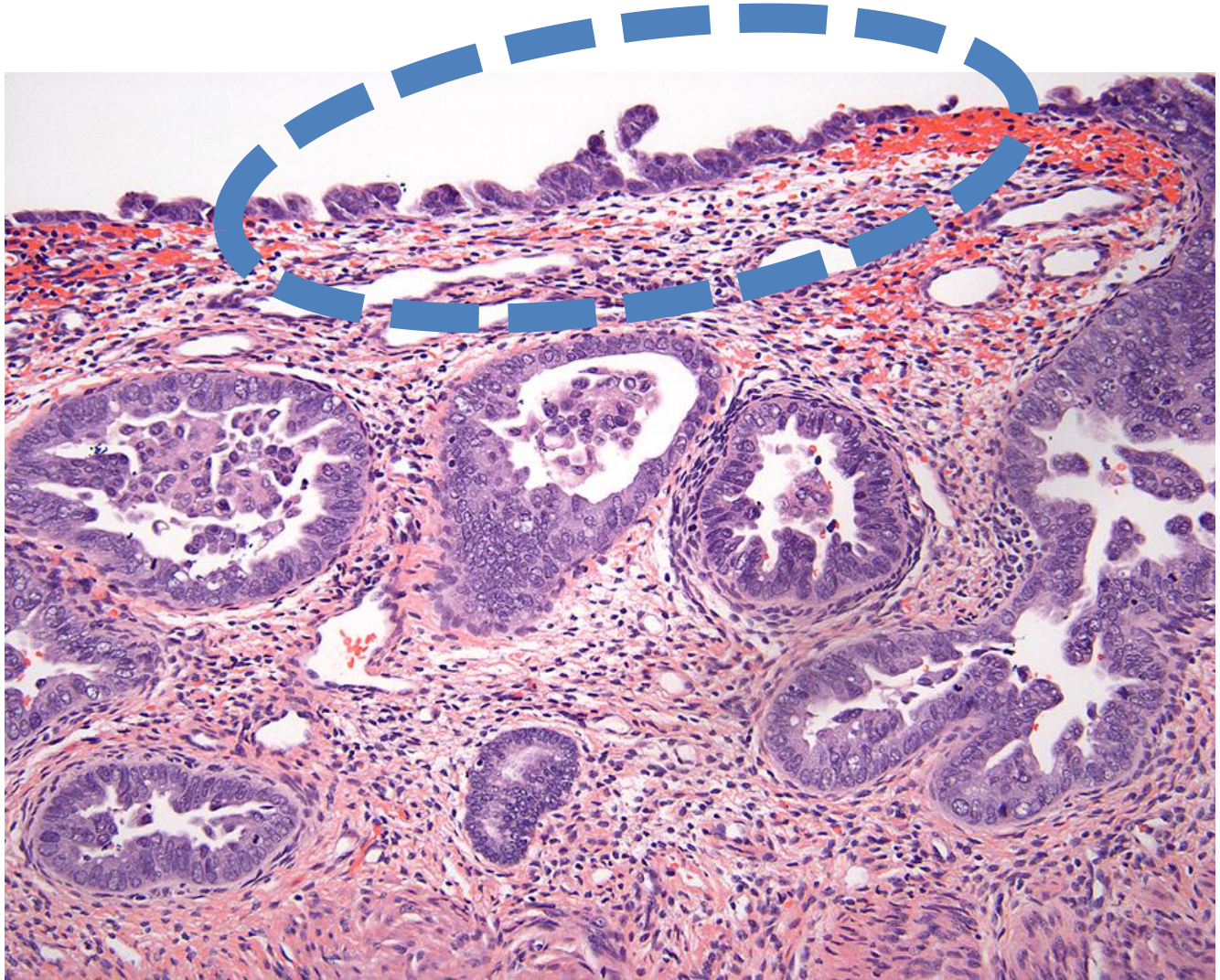

Minimal Forms of Endometrial Serous Carcinoma

Scant tumor in benign atrophic endometrium

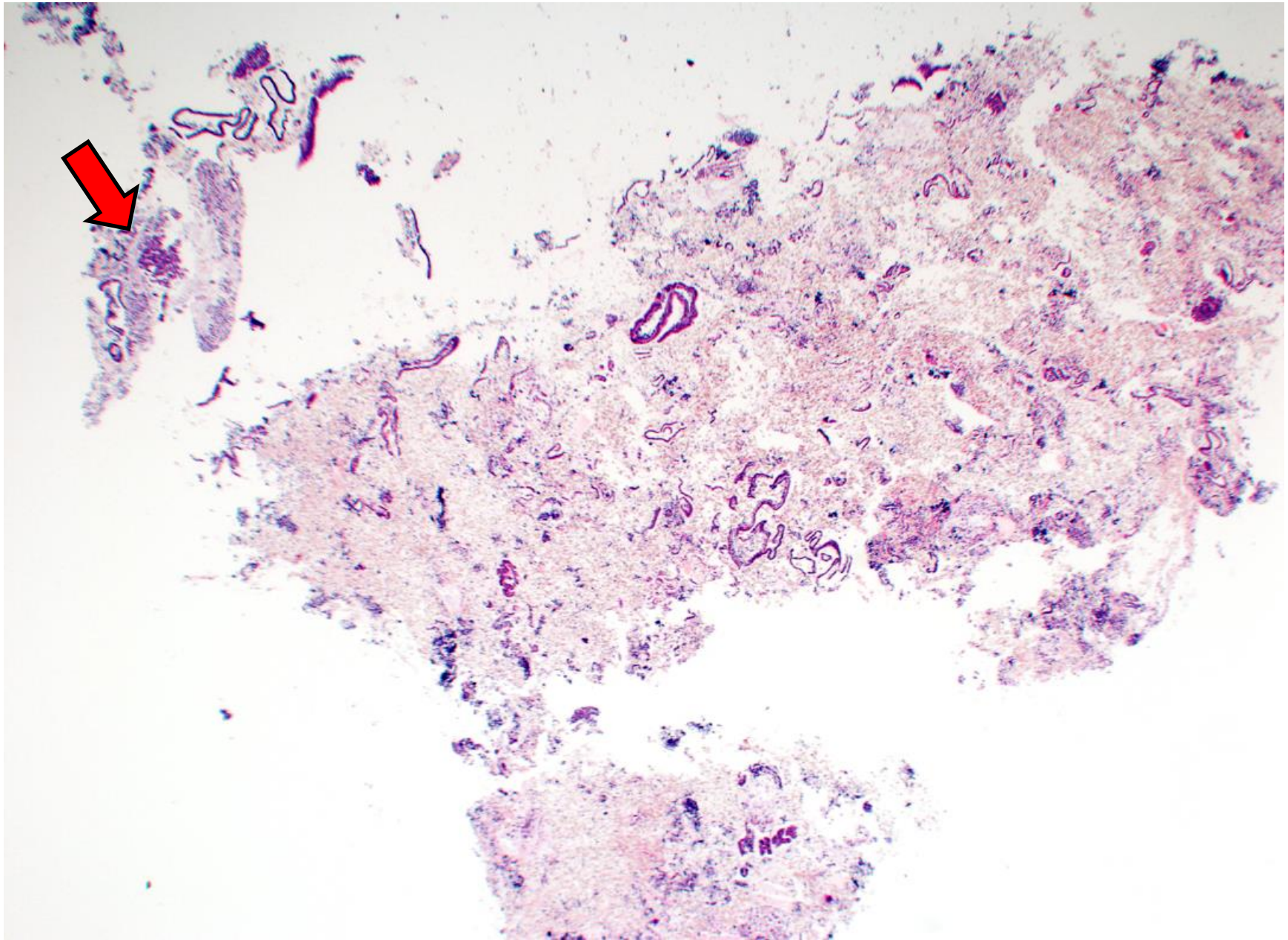

Minimal Forms of Endometrial Serous Carcinoma

Scant tumor in benign atrophic endometrium

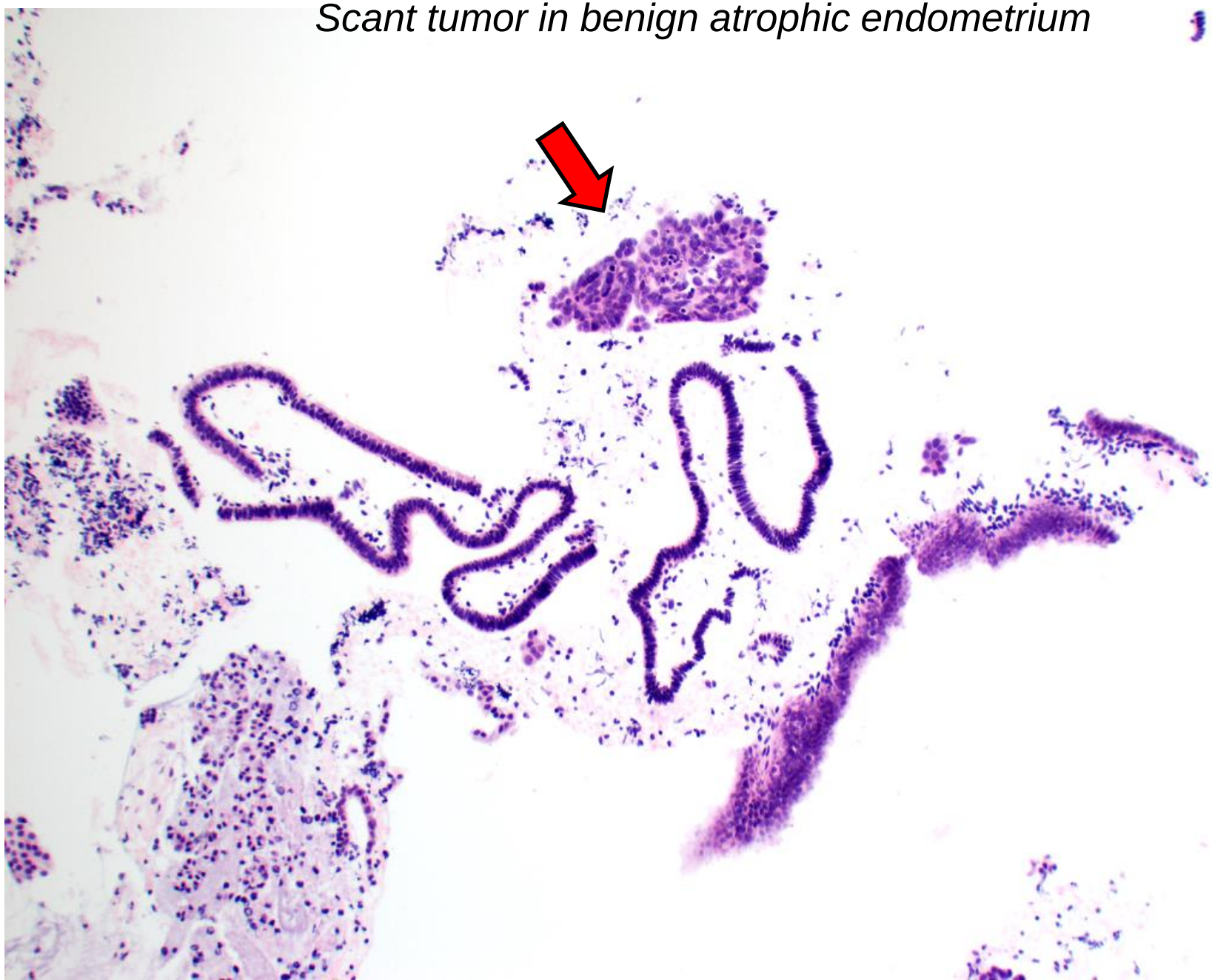

Minimal Forms of Endometrial Serous Carcinoma

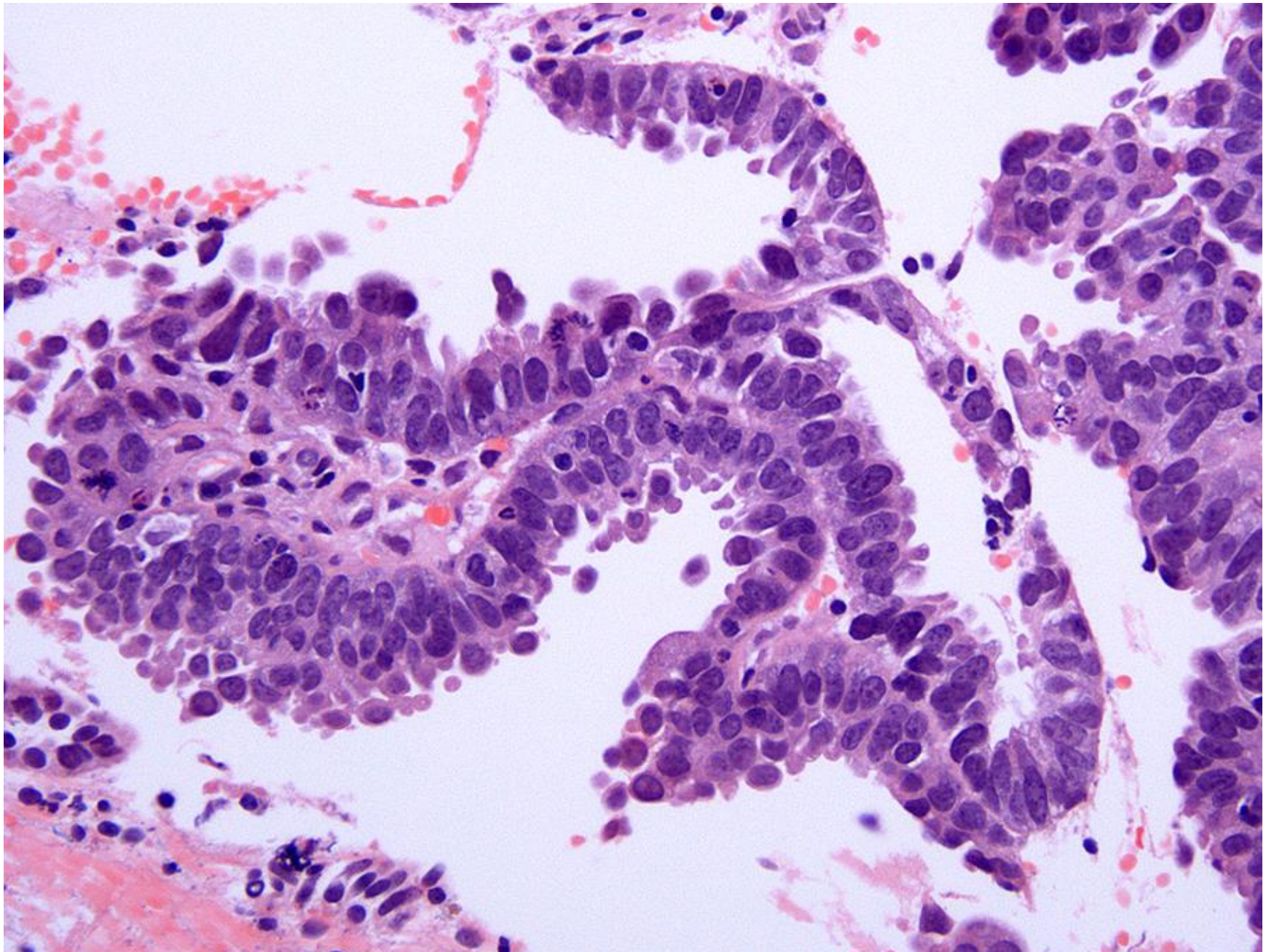

Minimal Forms of Endometrial Serous Carcinoma

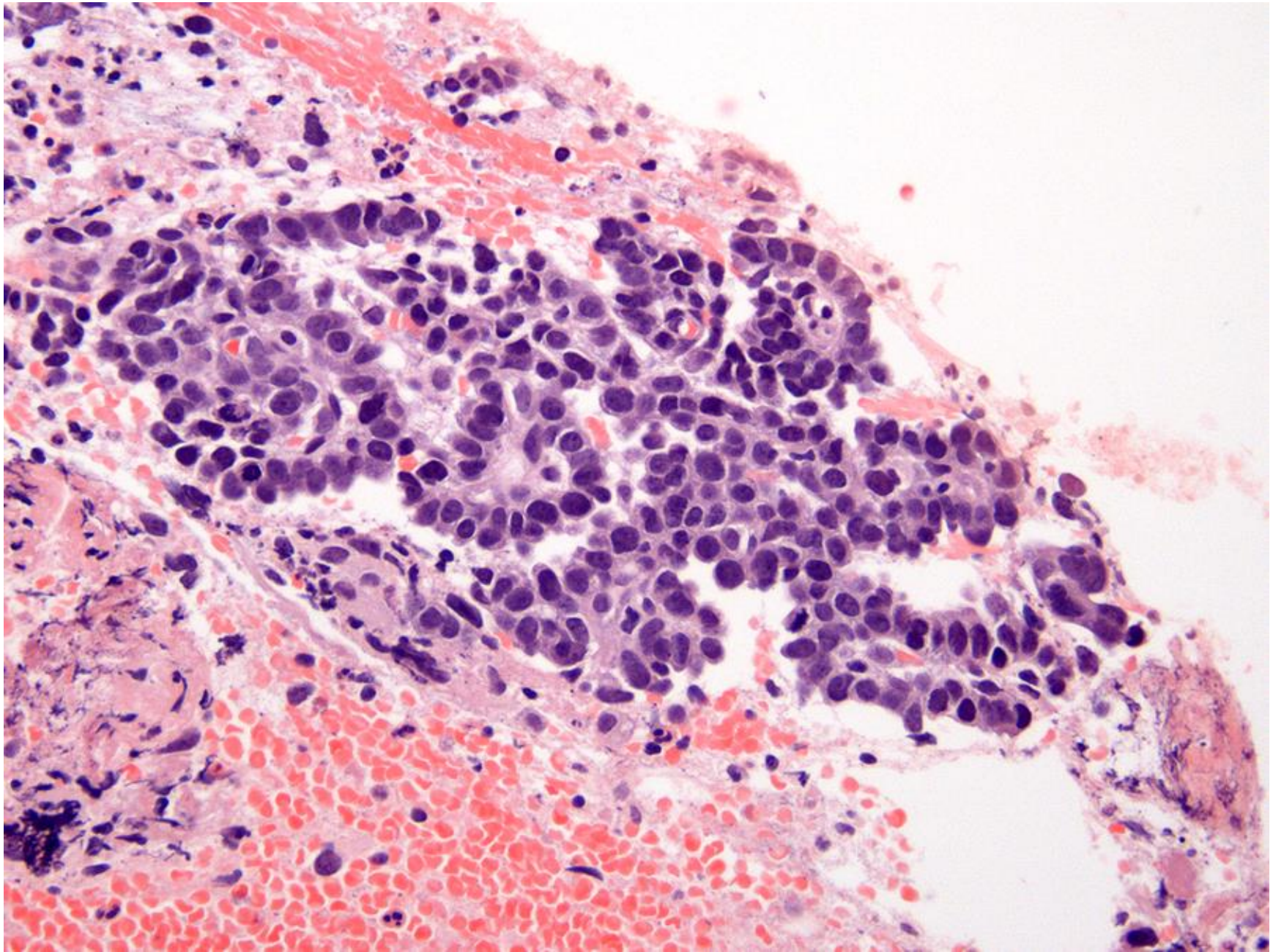

Minimal Forms of Endometrial Serous Carcinoma

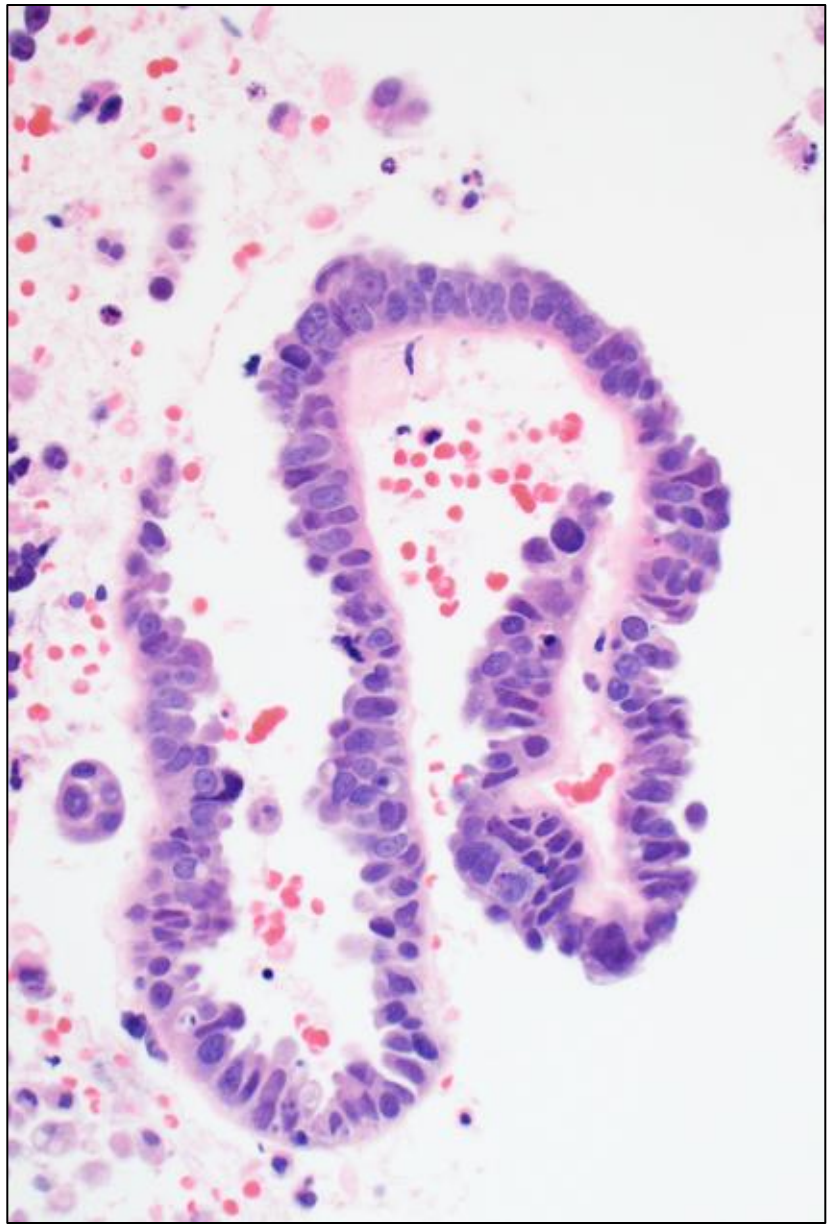

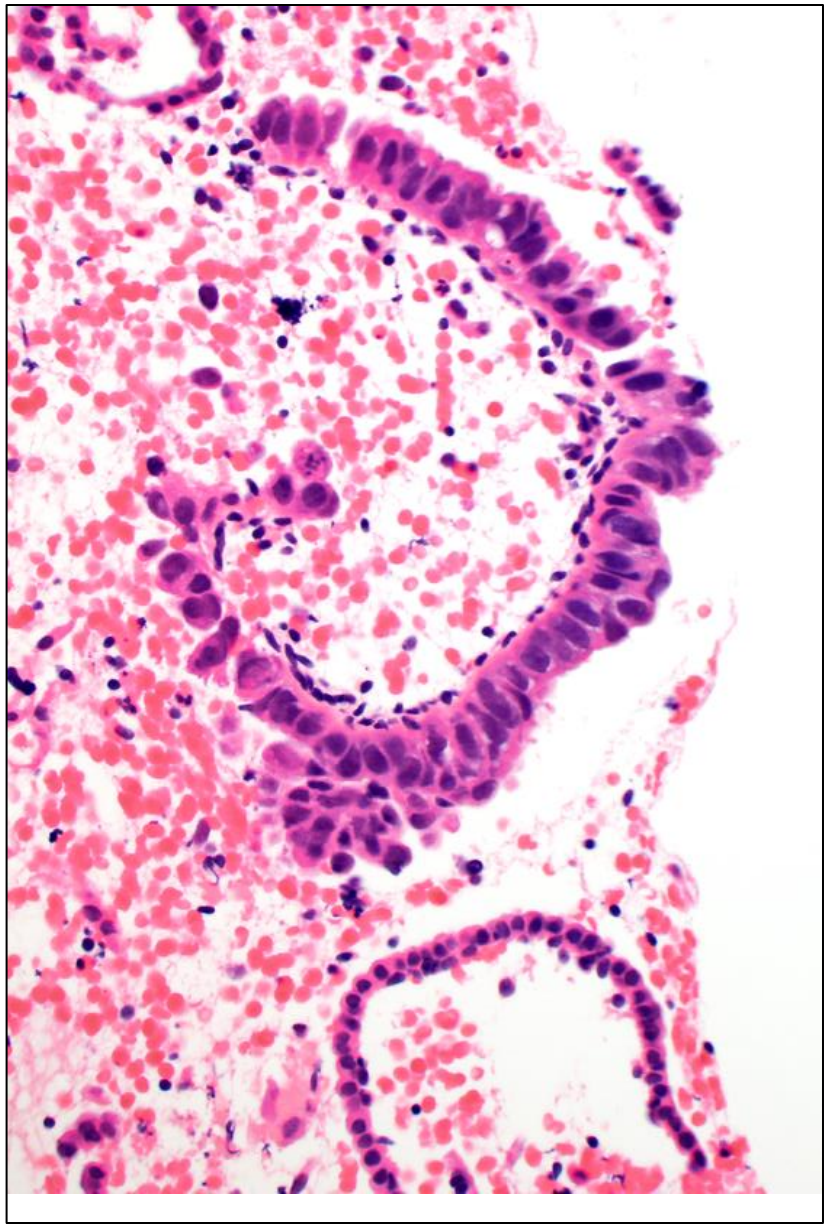

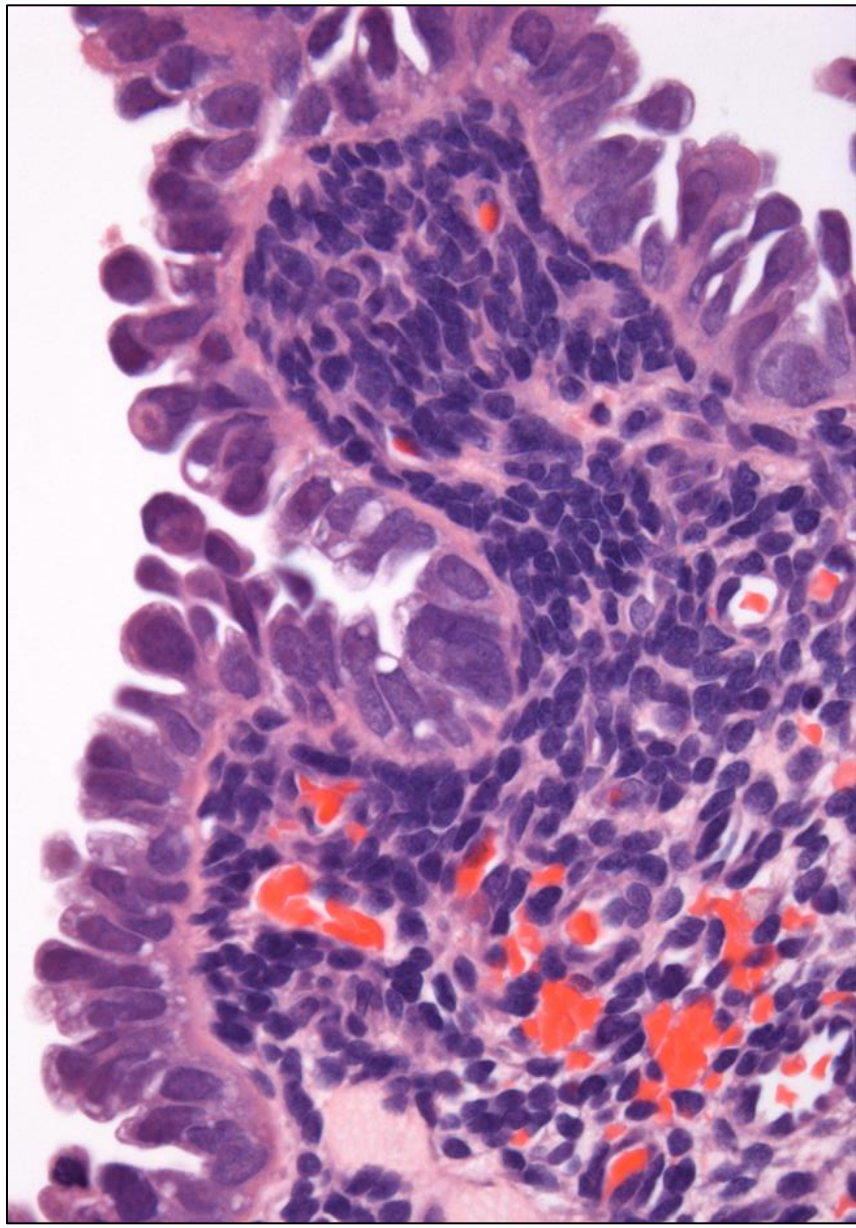

Minimal Forms of Endometrial Serous Carcinoma

Practical strategies for atrophic biopsies:

- **Presume serous carcinoma is present until proven otherwise by careful examination**
- **Consider a low threshold for working up atypia with p53/p16**
- **Report terminology:**

Minimal Forms of Endometrial Serous Carcinoma

Practical strategies for atrophic biopsies:

- **Presume serous carcinoma is present until proven otherwise by careful examination**
- **Consider a low threshold for working up atypia with p53/p16**
- **Report terminology:**

If criteria are fully met, report as "Serous carcinoma"

My personal view: avoid term "serous intraepithelial carcinoma"

If criteria are not full met, report with descriptive diagnosis and advise further work up

Papillary Pattern Pathology

- Benign
  - Surface papillary syncytial change
- Benign but associated with neoplasia *(clinical action advised)*
  - **Papillary proliferation of endometrium**
- Low risk cancer
  - Papillary variants of low grade endometrioid carcinoma
  - Progestin-treated residual endometrioid carcinoma
- High risk cancer
  - **Serous carcinoma** (classic papillary morphology)
  - Clear cell carcinoma
- Secondary cancer
  - Endocervical adenocarcinoma, villoglandular type
  - Pelvic serous tumor

Papillary Proliferation of Endometrium

Definition

- Benign papillary alteration
- Mostly in polyps

Morphology

Architecture
Simple or complex papillary branching

Cytology
Bland nuclei
No abnormal mitotic activity
Mucinous and/or eosinophilic metaplasia

Clinical Significance

Risk of concurrent / subsequent atypical hyperplasia or grade 1 endometrioid carcinoma
Risk: ~12% if focal ~80% if diffuse
Recommend further clinical evaluation to rule out cancer

Ip. Am J Surg Pathol. 2013; 37: 167
Lehman. Am J Surg Pathol. 2001; 25: 1347

Papillary Proliferation of Endometrium

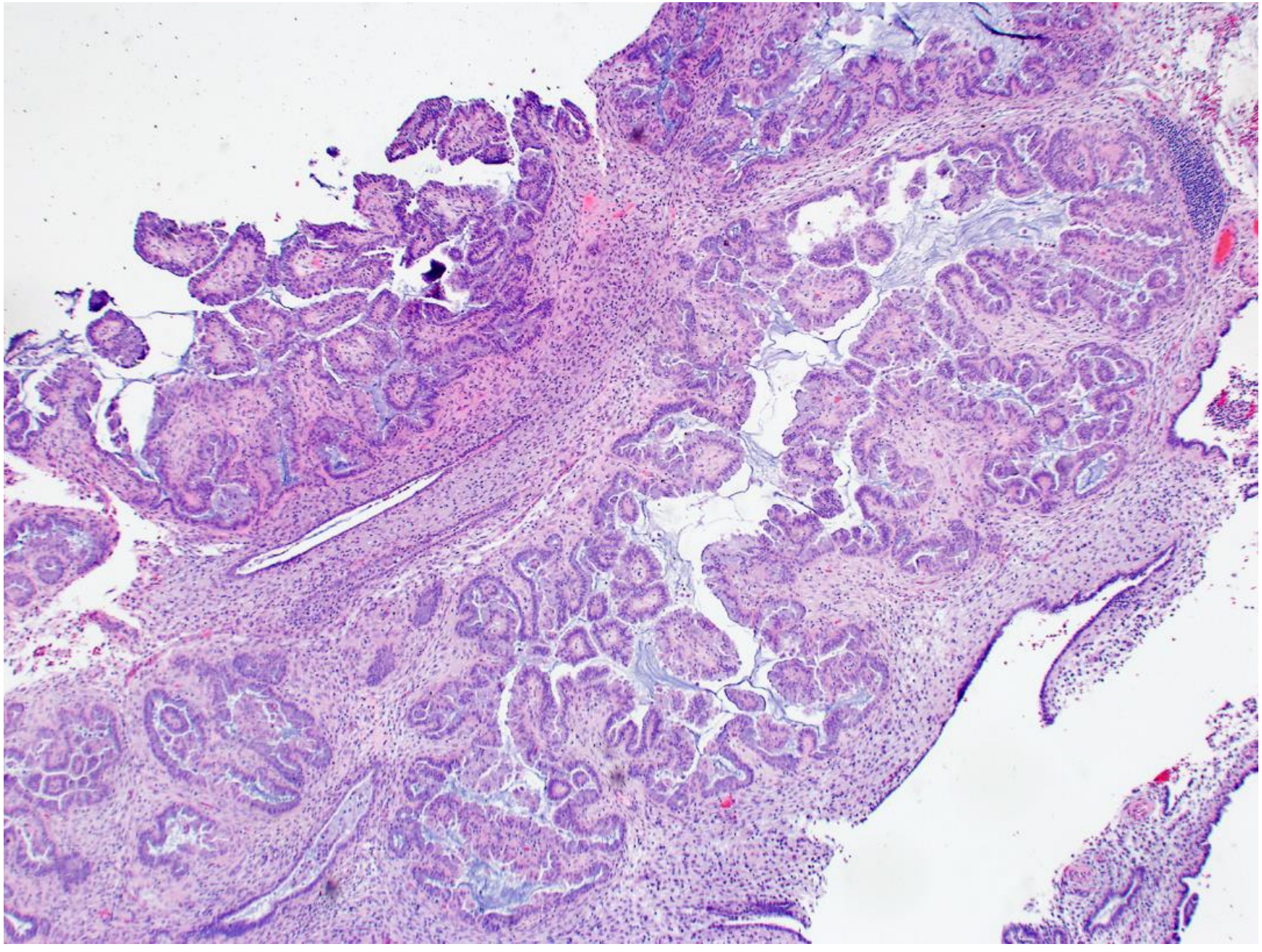

Papillary Proliferation of Endometrium

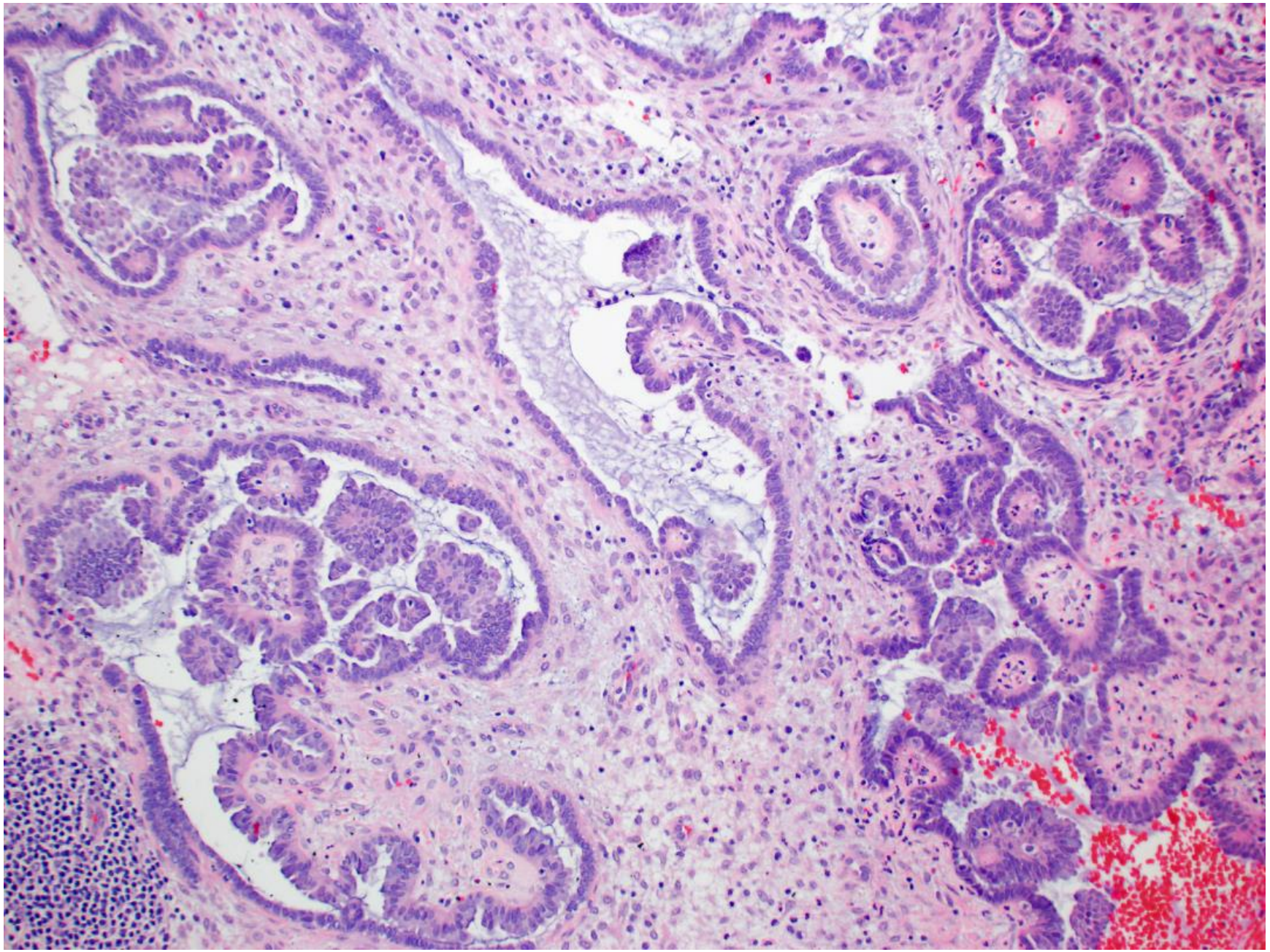

Papillary Proliferation of Endometrium

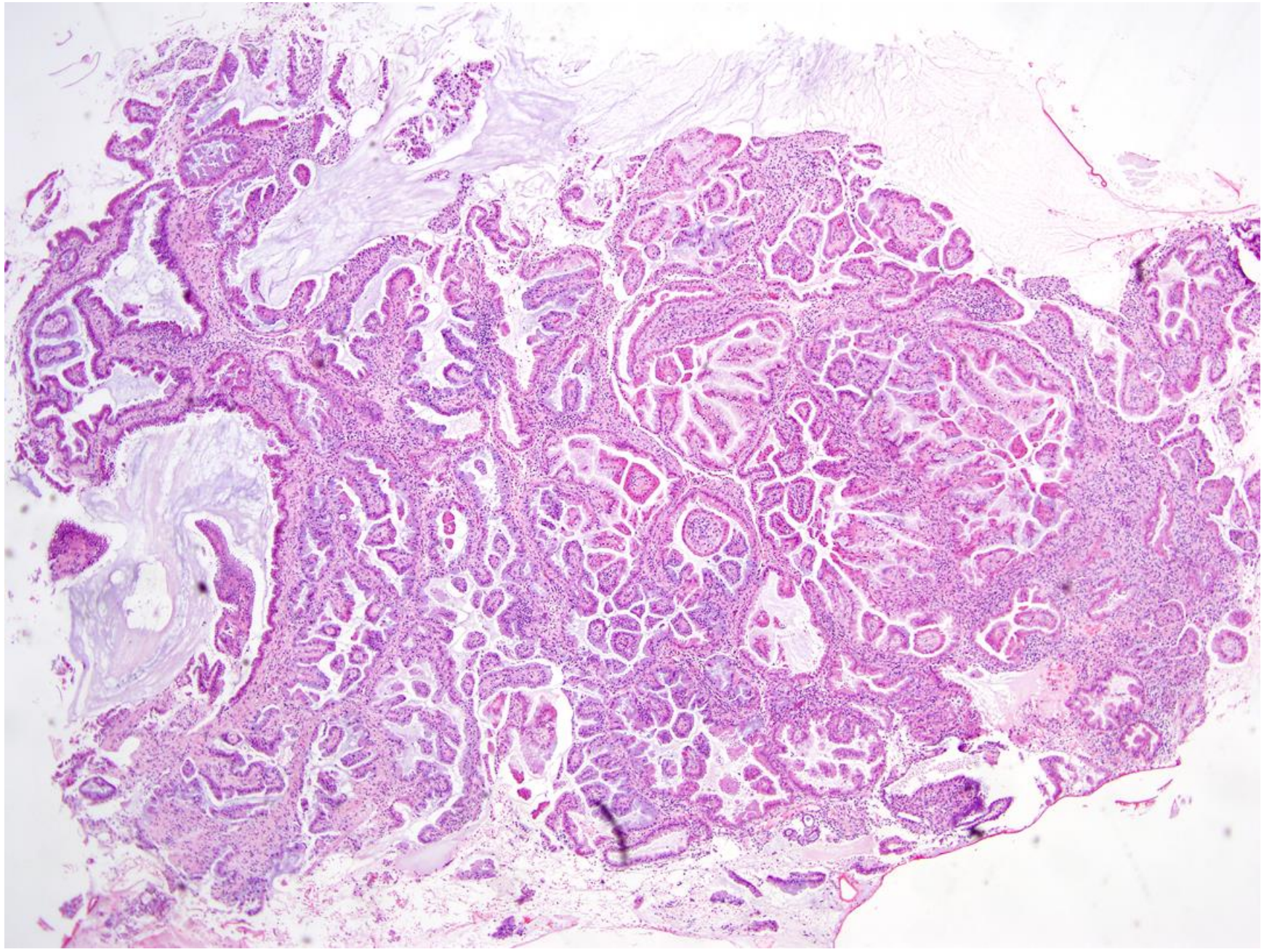

Papillary Proliferation of Endometrium

Mucinous Metaplasia

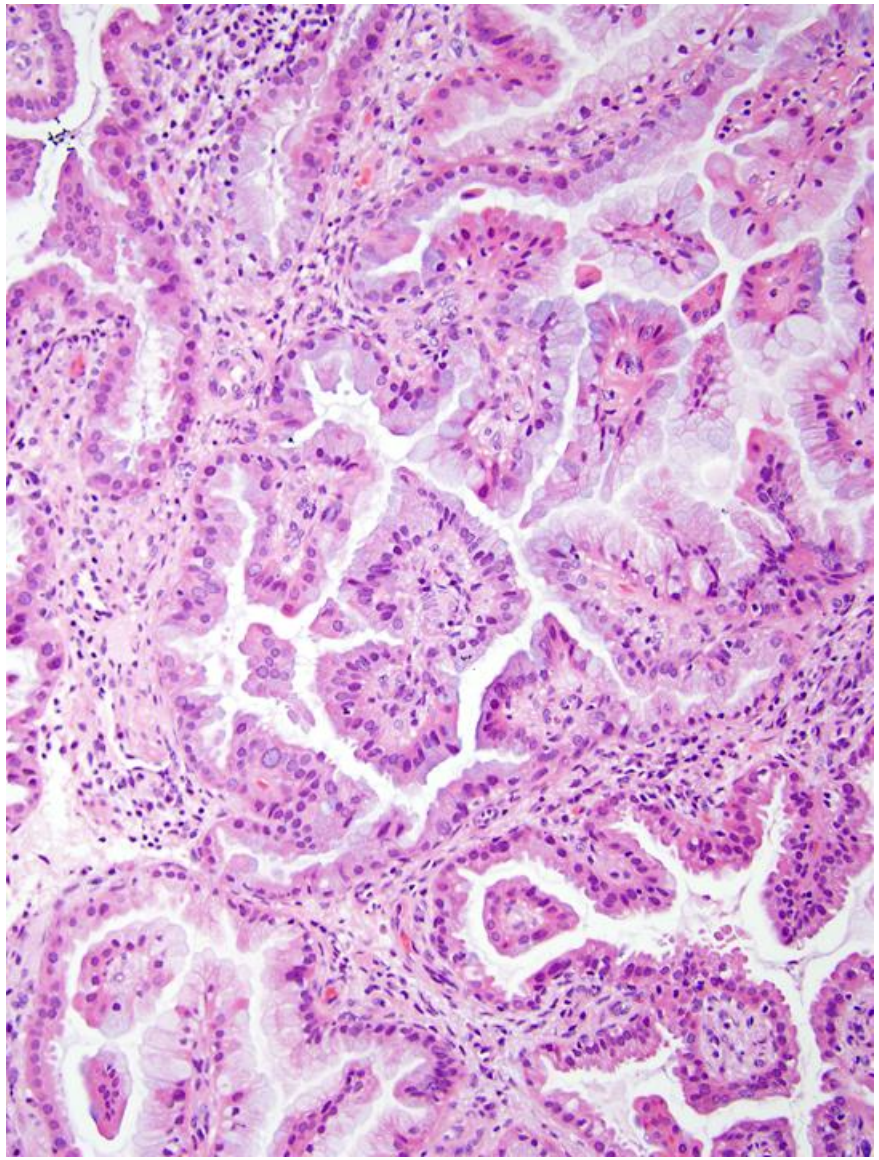

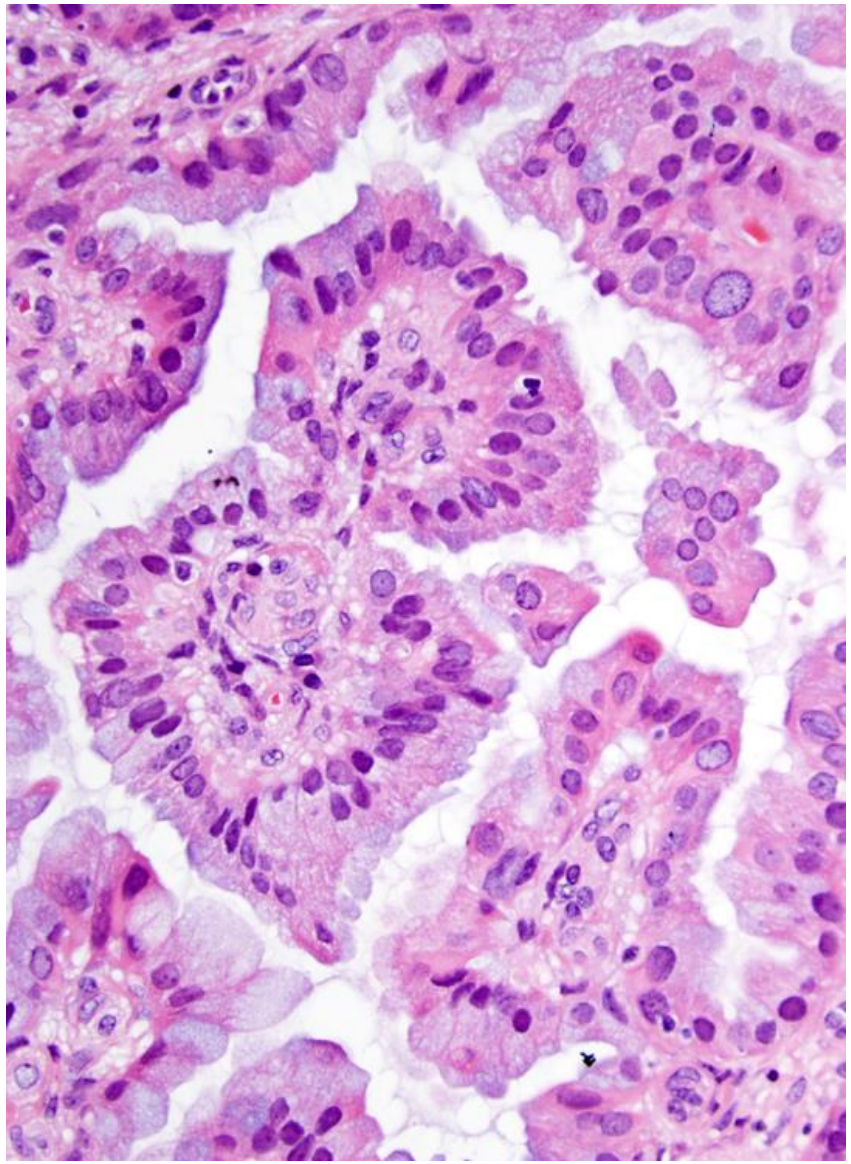

Papillary Proliferation of Endometrium

Mucinous Metaplasia
No atypia or abnormal mitoses

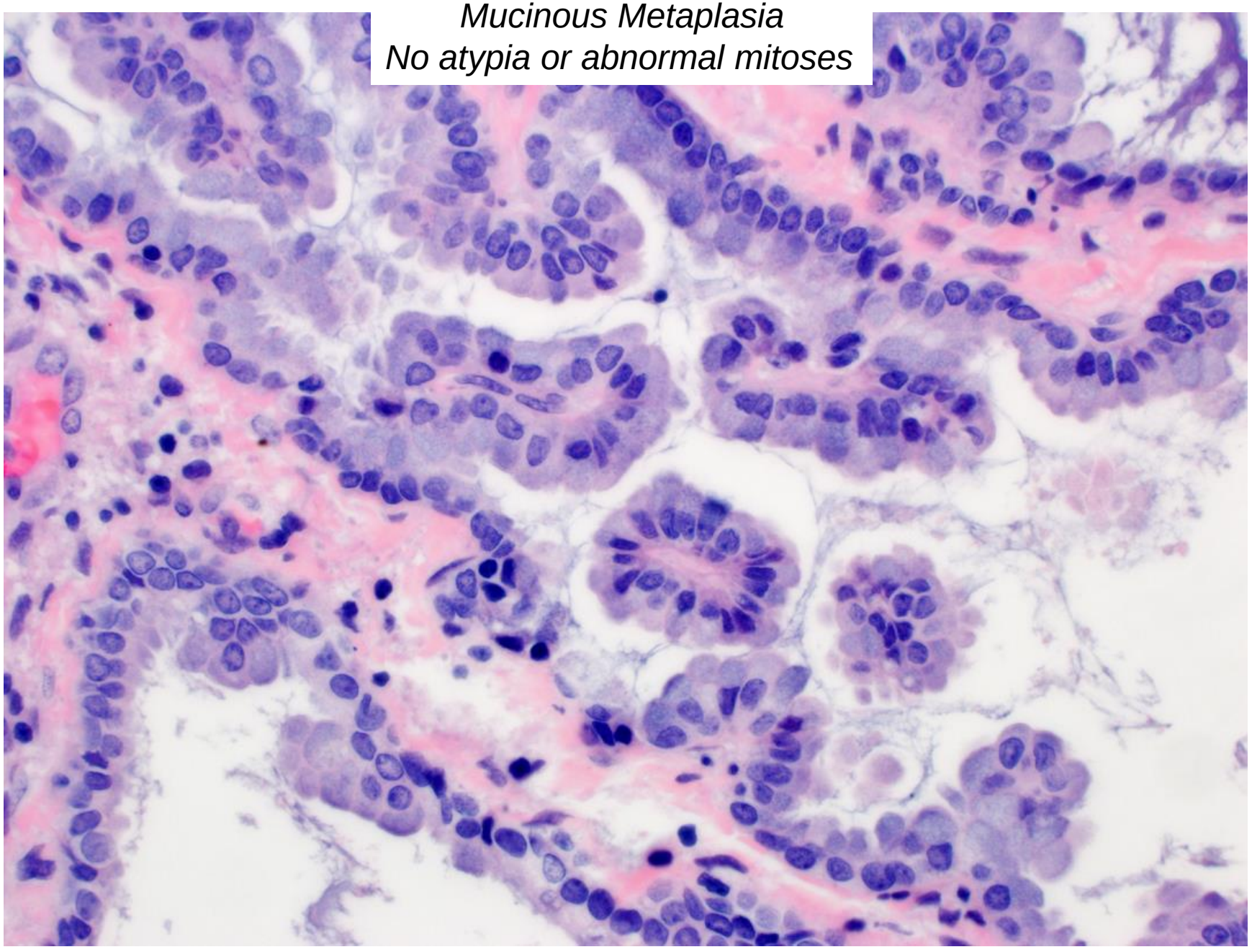

Papillary Proliferation of Endometrium

Eosinophilic Metaplasia

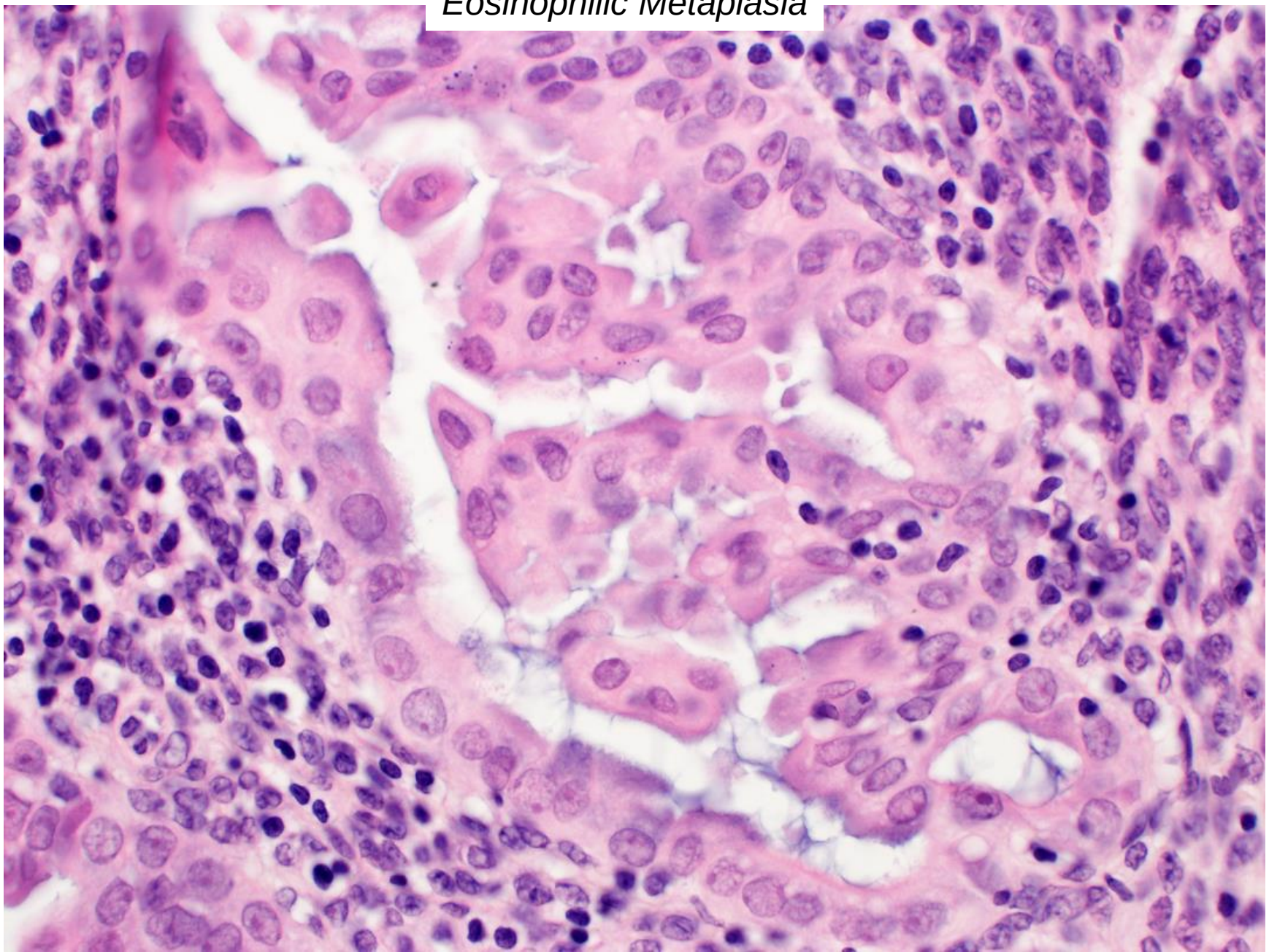

Papillary Proliferation of Endometrium

Practical Strategy: Specimen Management and Reporting

In a biopsy/polypectomy

- **Confirm entire sample / polyp has been submitted**
  (to exclude atypical hyperplasia/cancer)
- **Document risk for concurrent/subsequent disease**
  (cite references)
- **Recommend clinical evaluation to exclude any residual polyp, nodules, mass**

In a hysterectomy

- **Consider examining entire endometrium and polyps**
  (to exclude atypical hyperplasia/cancer)

Ip. Am J Surg Pathol. 2013; 37: 167
Lehman. Am J Surg Pathol. 2001; 25: 1347

Patterns of Endometrial Epithelial Abnormalities

- Glandular
- Papillary
- **Mucin-rich**

Mucinous Pattern Pathology

- Benign
  - **Contamination by endocervical microglandular hyperplasia**
  - **Mucinous metaplasia**
- Low risk cancer
  - **Endometrioid carcinoma with mucinous features**
- High risk cancer
  - **Endometrial gastric (gastro-intestinal) type adenocarcinoma**
- Secondary cancer
  - **Endocervical adenocarcinoma**
  - **Colorectal adenocarcinoma**

Endocervical microglandular hyperplasia (MGH)

Definition

- **Benign alteration in endocervix / endocervical polyps**
- **Often in premenopausal women with progestin exposure**
- ***Rare in post-menopausal* women**

- **May be present as a contaminant in endometrial biopsy**

Criteria

Crowded / cribriform endocervical glands
Admixed squamous metaplasia / reserve cell hyperplasia
Intra-luminal mucin and neutrophils
Vacuoles / micro-cystic spaces

Diagnostic problem:

➡ *Resembles MGH-like endometrial cancer in older women*
Caution advised before diagnosing "MGH" in older women

Endocervical Microglandular Hyperplasia (MGH)

Contaminant in endometrial sampling

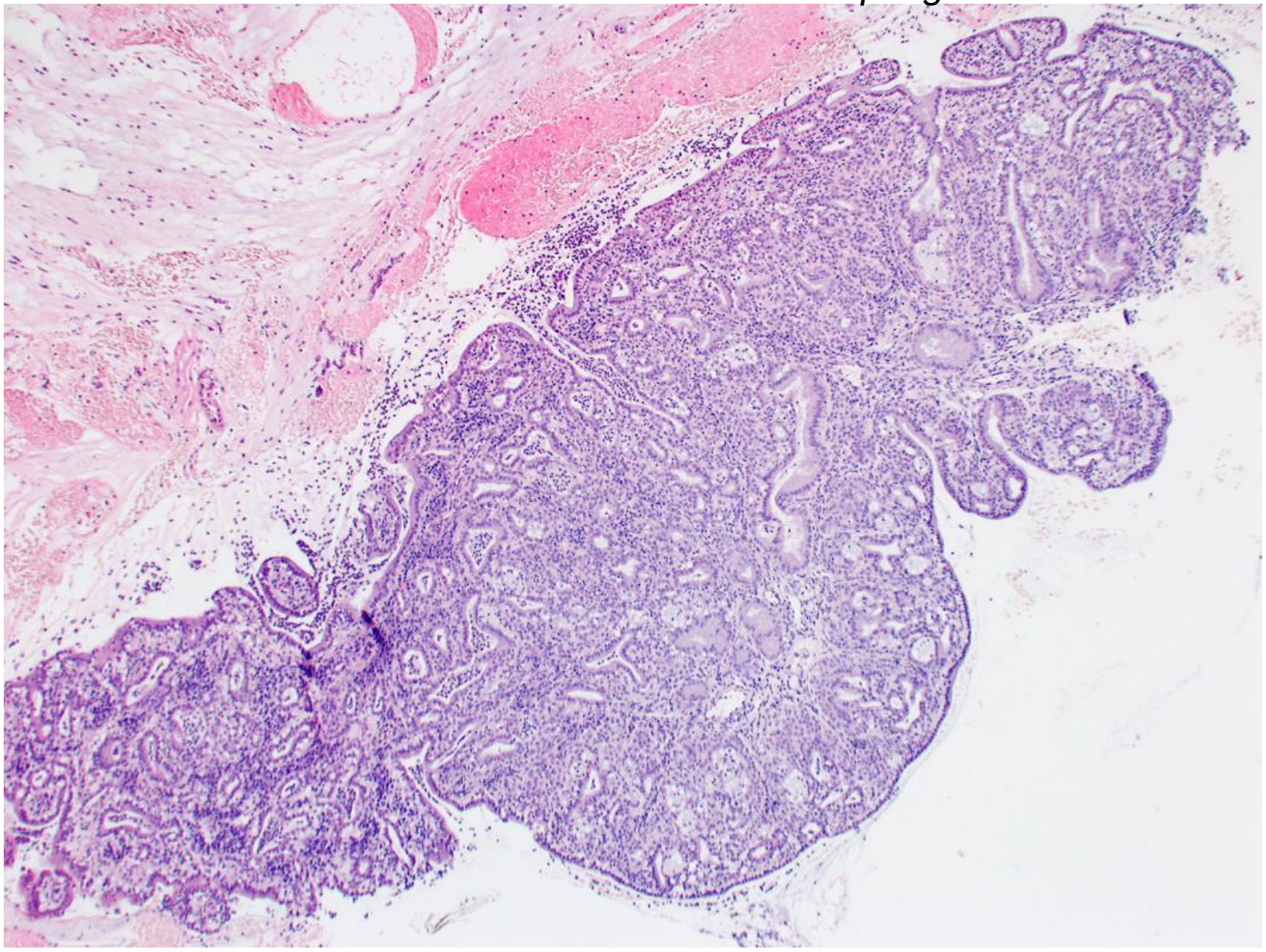

Endocervical Microglandular Hyperplasia (MGH)

Squamous metaplasia

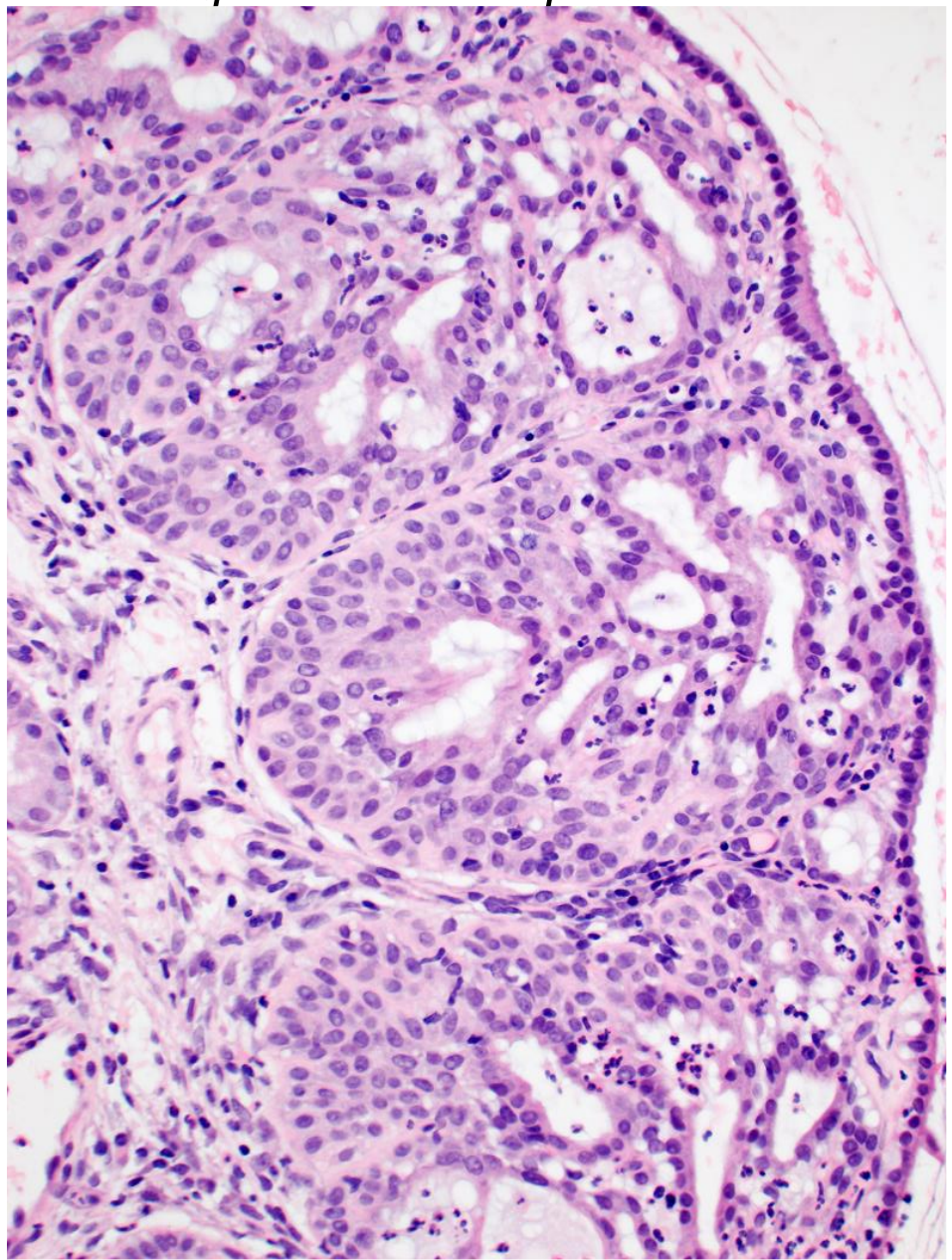

Vacuoles, microcysts

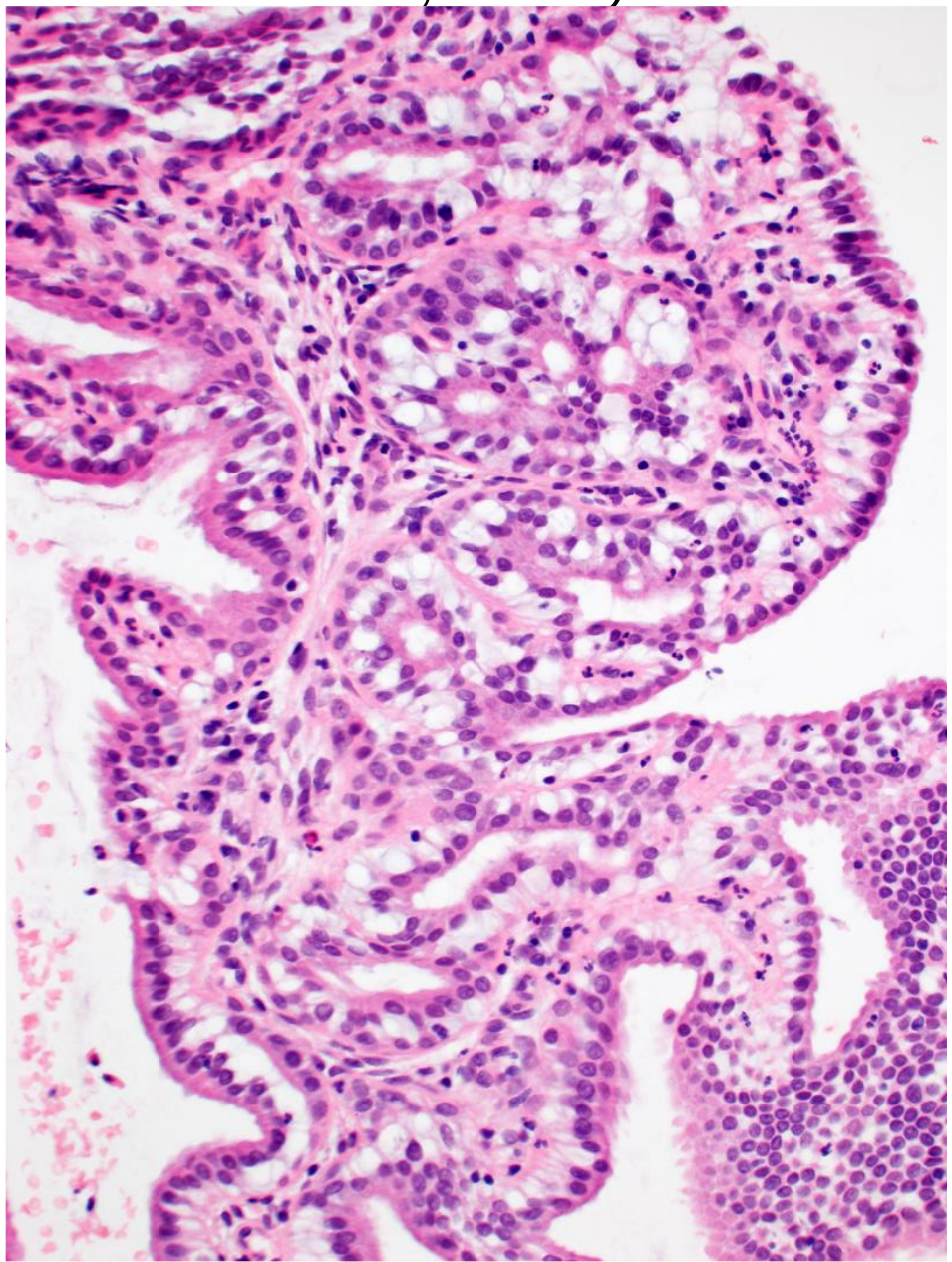

MGH-Like Lesion in Post-menopausal Biopsy

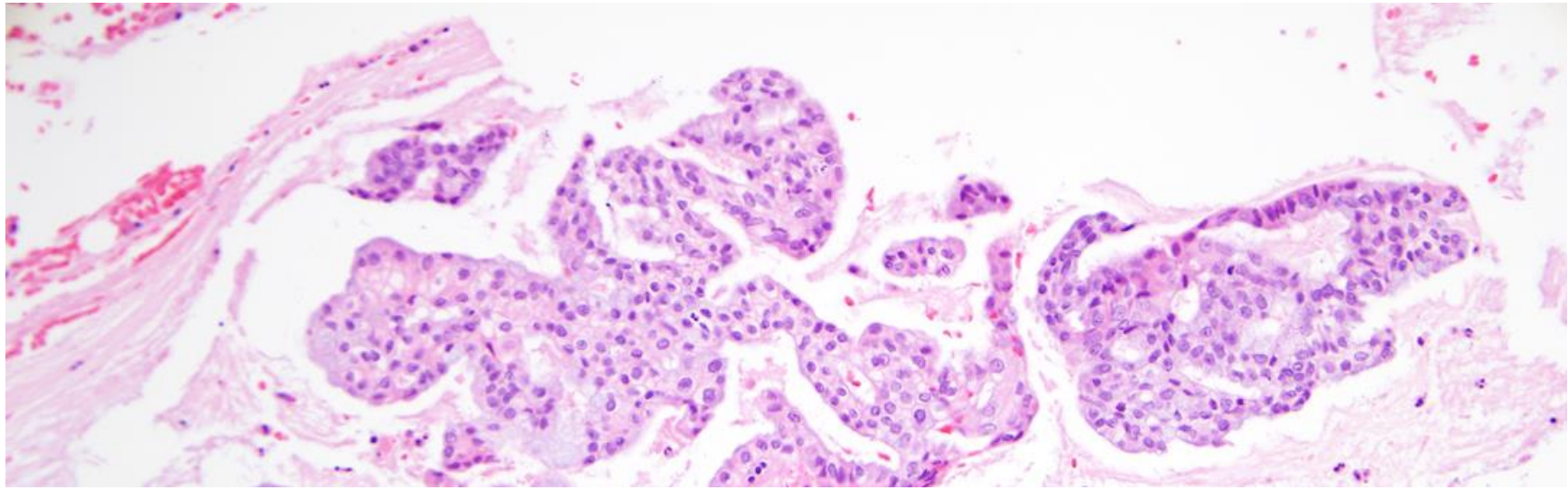

Endometrioid Carcinoma with MGH-like Features

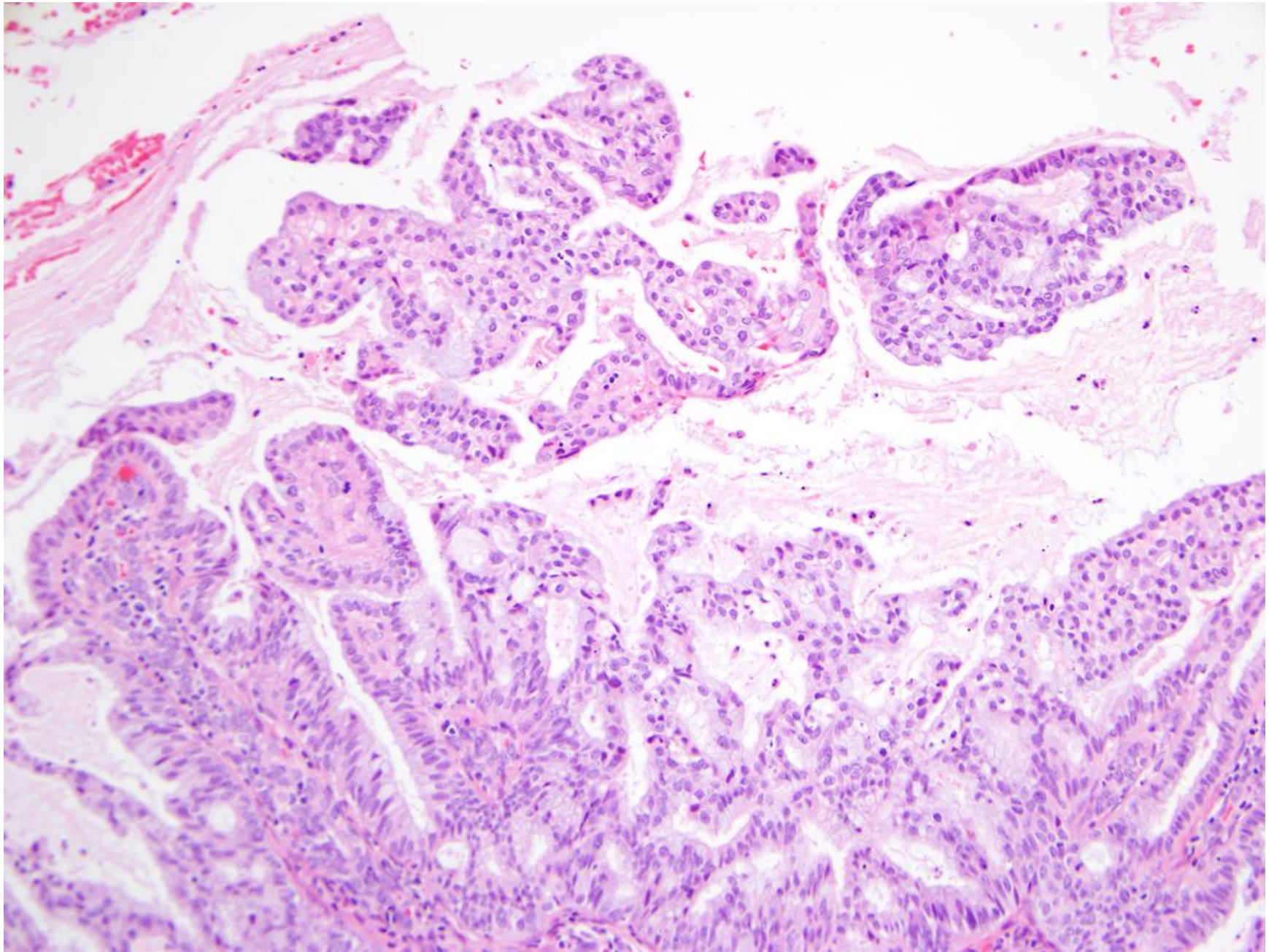

Endometrioid Carcinoma with MGH-like Features

Presentation

- Post-menopausal age
- Not linked to exogenous hormone use

Morphology

- Endometrioid carcinoma +/- mucinous features
- Grade 1, Stage 1A

- MGH-like changes at tumor surface / periphery

Zaloudek et al. Int J Gyn Pathol 1997; 16: 52
Young et al. Am J Surg Pathol 1992;16: 1092

Endometrioid Carcinoma with MGH-like Features

Biopsy fragments mimic endocervical MGH

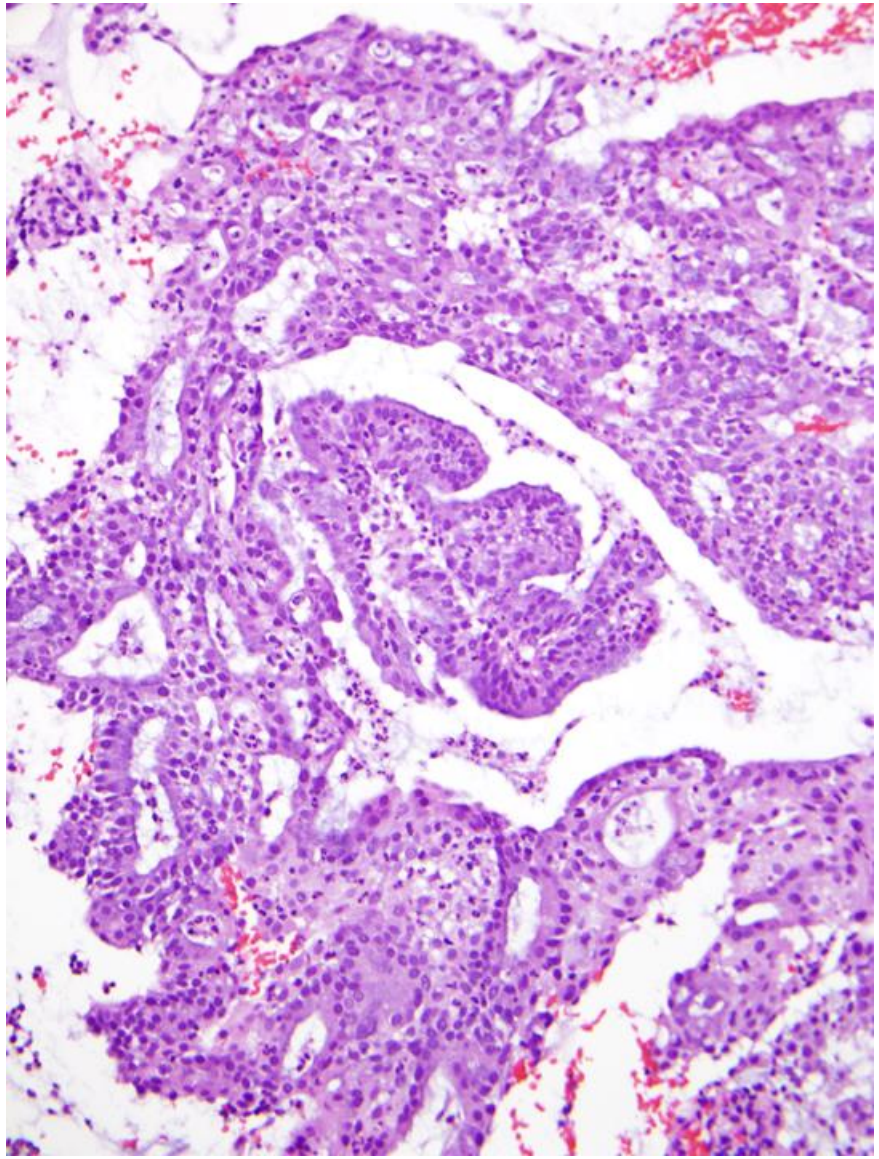

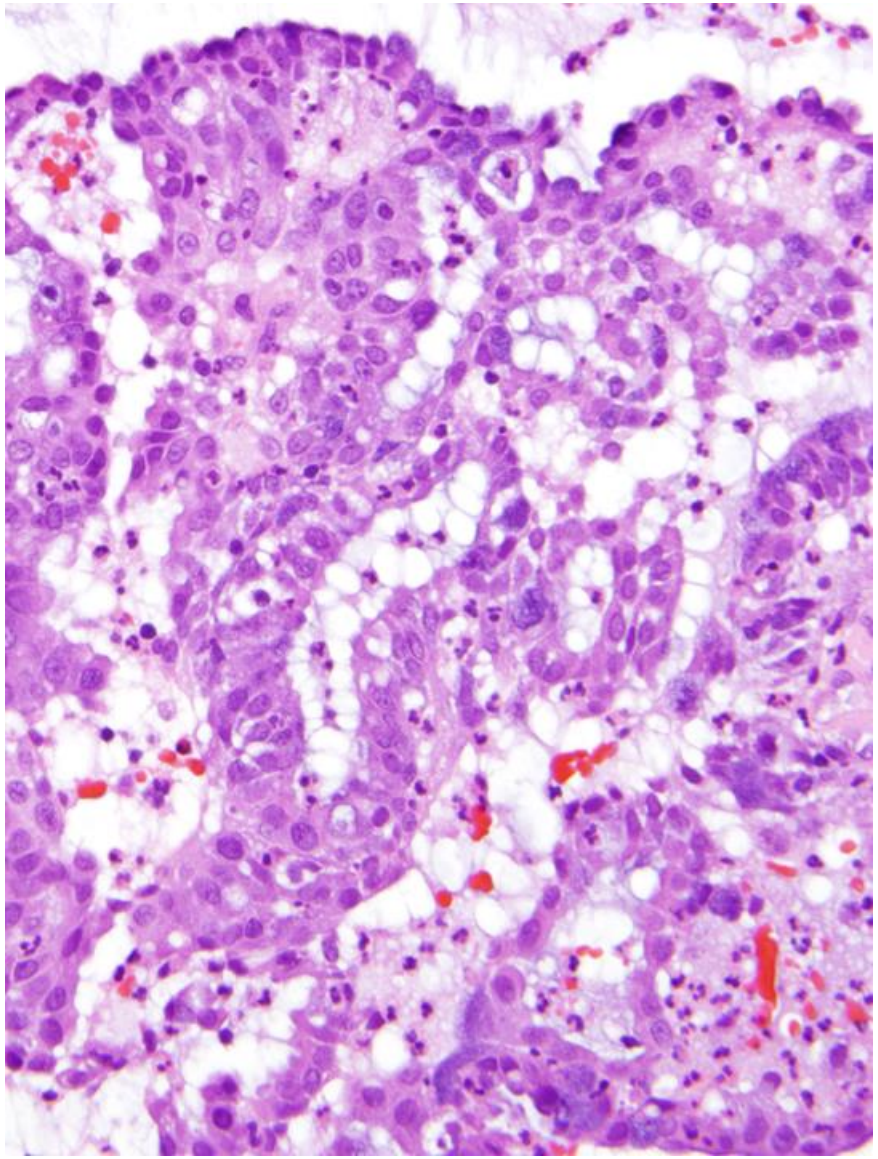

Complex Mucinous Glandular Proliferation

Does not meet criteria for cancer or atypical hyperplasia

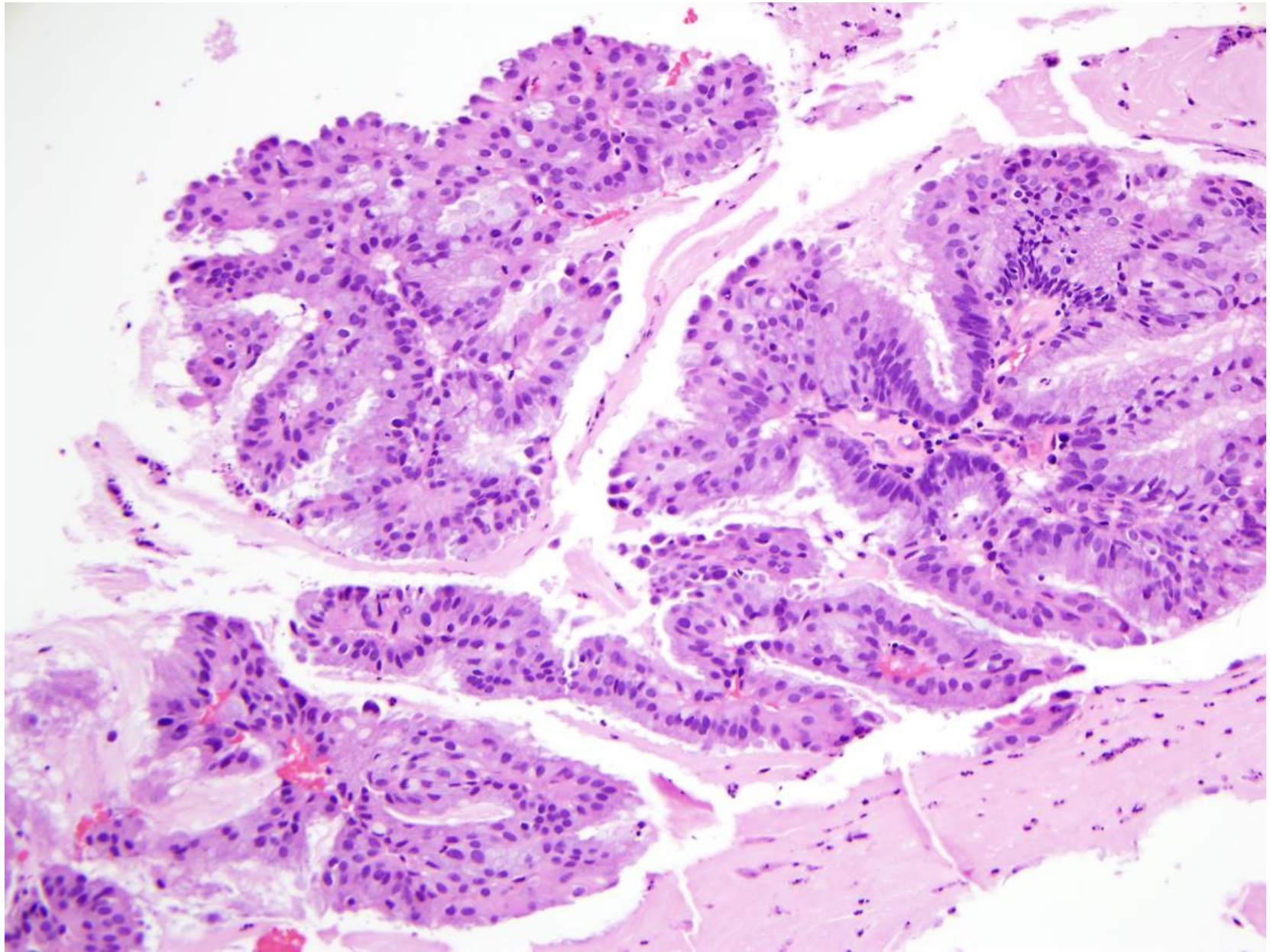

Complex Mucinous Glandular Proliferation

Does not meet criteria for cancer or atypical hyperplasia

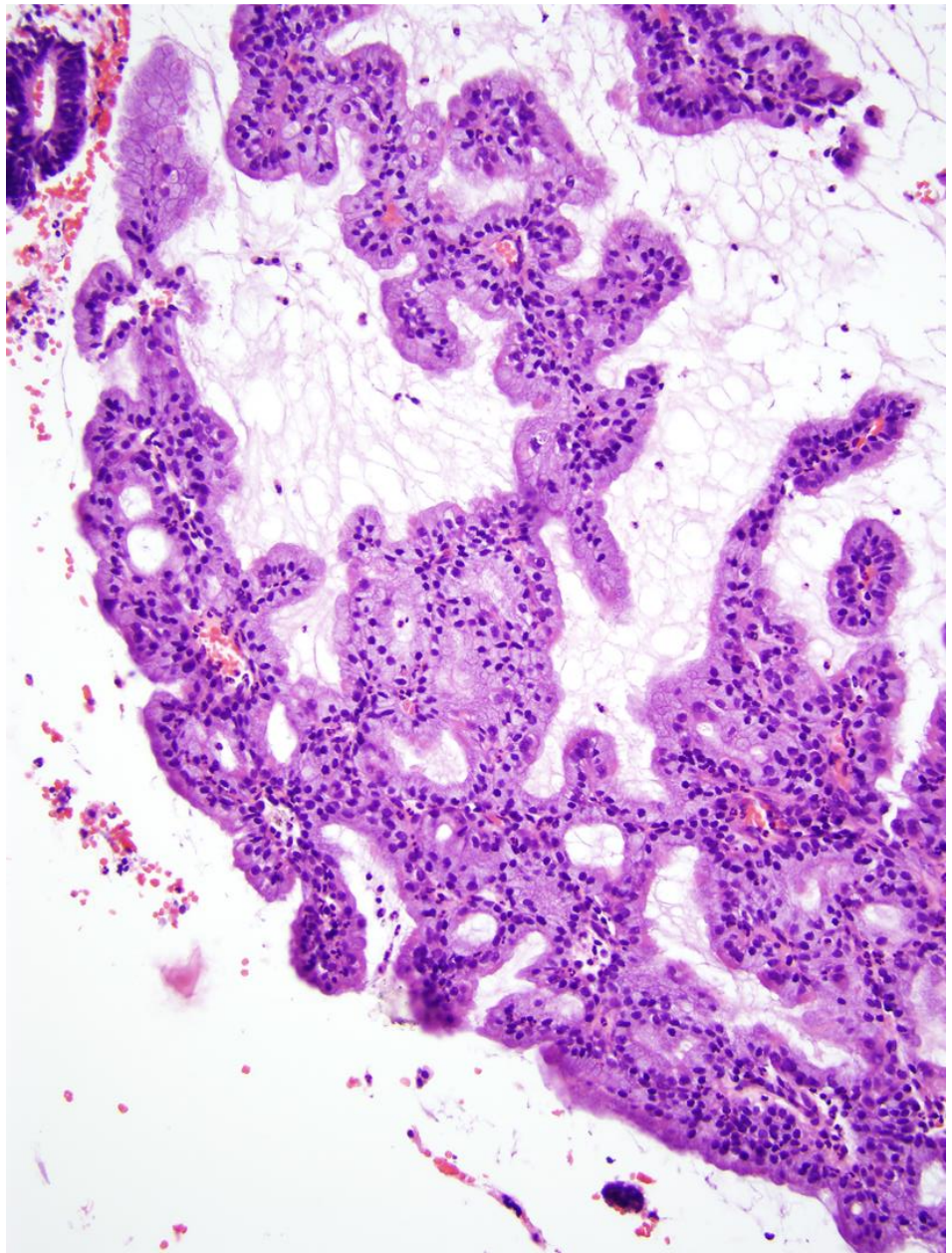



Complex Mucinous Glandular Proliferation

Caution advised, particularly in post-menopausal women

- **Practical strategy for reporting:**

  Diagnosis: “complex mucinous glandular proliferation”.

  Comment: cannot exclude un-sampled carcinoma, further work up advised.

Vang. Int J Surg Pathol 2003;11:261-70
Nucci. Mod Pathol. 1999;12:1137-42.

Patterns of Endometrial Epithelial Abnormalities

- Glandular
- Papillary
- Mucin-rich
- **Squamous**

Squamous Pattern Pathology

- Benign but associated with neoplasia (*clinical action advised)*

Morular metaplasia

- Low risk cancer / precursor

Atypical polypoid adenomyoma

Endometrioid carcinoma with squamous differentiation

- Secondary cancer

Cervical HSIL / squamous cell carcinoma

- Diagnostic mimics

Trophoblastic tumor / placental site nodule

Epithelioid smooth muscle tumor / PEComa

Granulomatous endometritis

Morular Metaplasia

"Morus" plant family
Mullberry



Image from www. plantogram.com

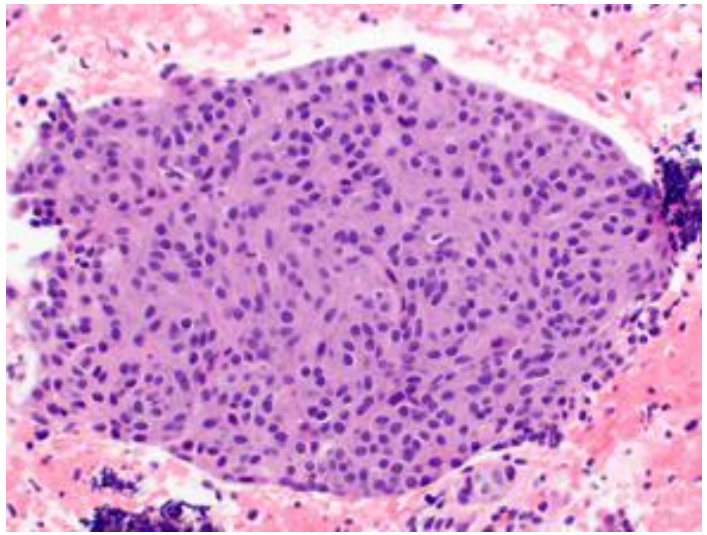

Morular Metaplasia

Definition

Solid nests of bland immature epithelium

- **Usually embedded within endometrial glands**
- **Occasionally free-floating**

Clinical relevance

- **Rarely found in normal endometrium**
- **Strongly associated with concurrent or subsequent disease, even if isolated morules:**

endometrial hyperplasia
endometrioid carcinoma
atypical polypoid adenomyoma

Lin 2009 PMID: 19180120
McCluggage 2019 PMID: 30085940

Morular Metaplasia within Hyperplasia

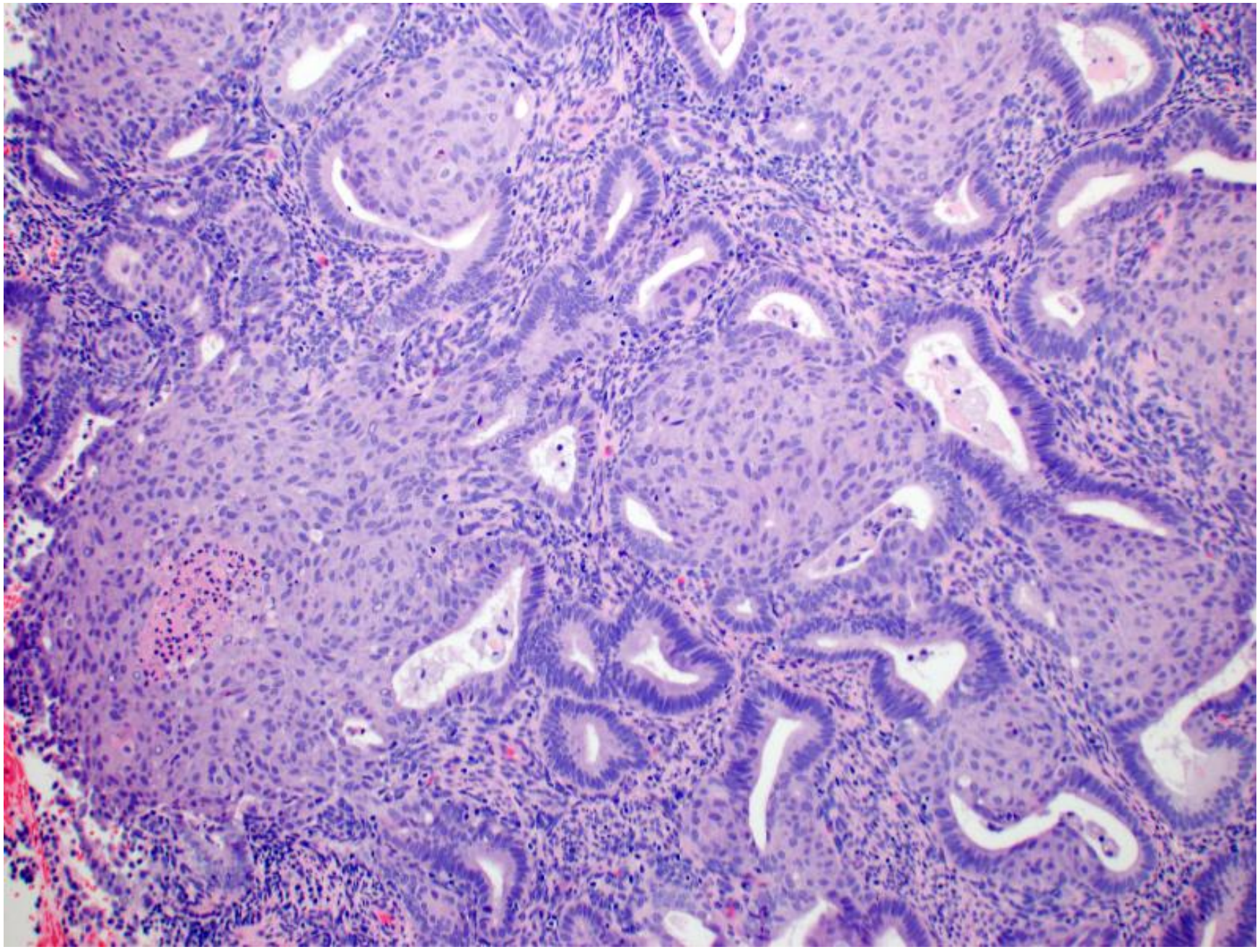

Free-floating Morules

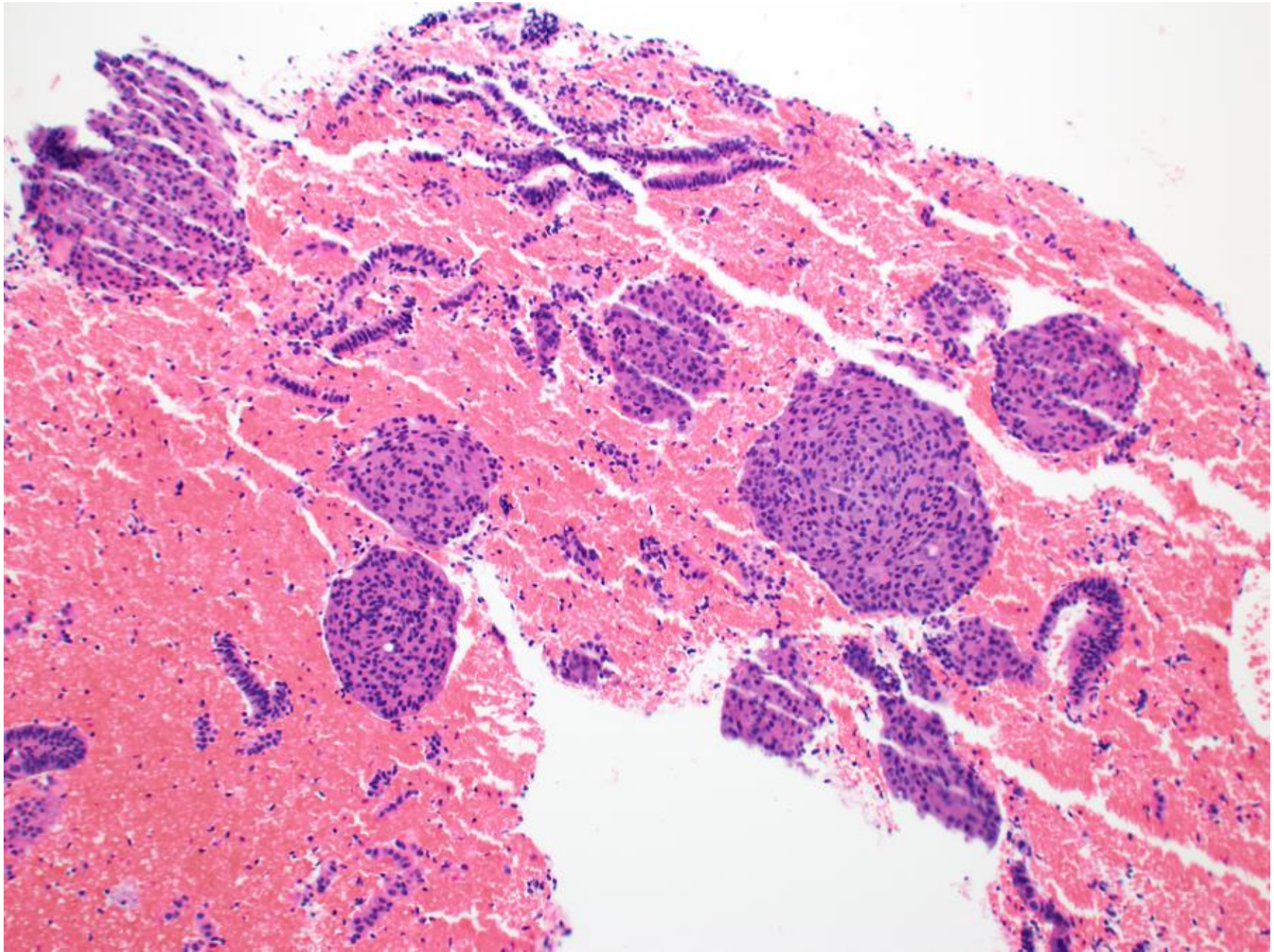

Free-floating Morules

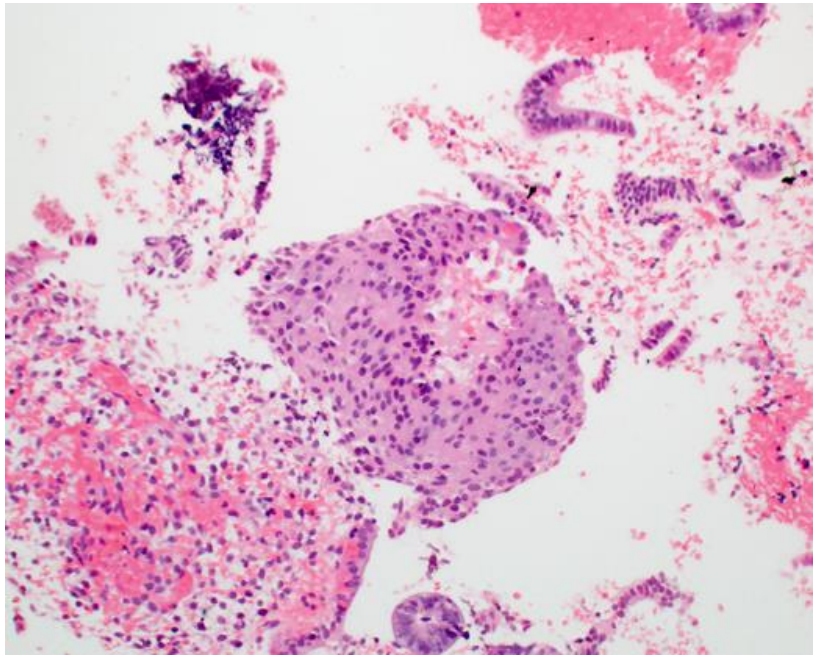

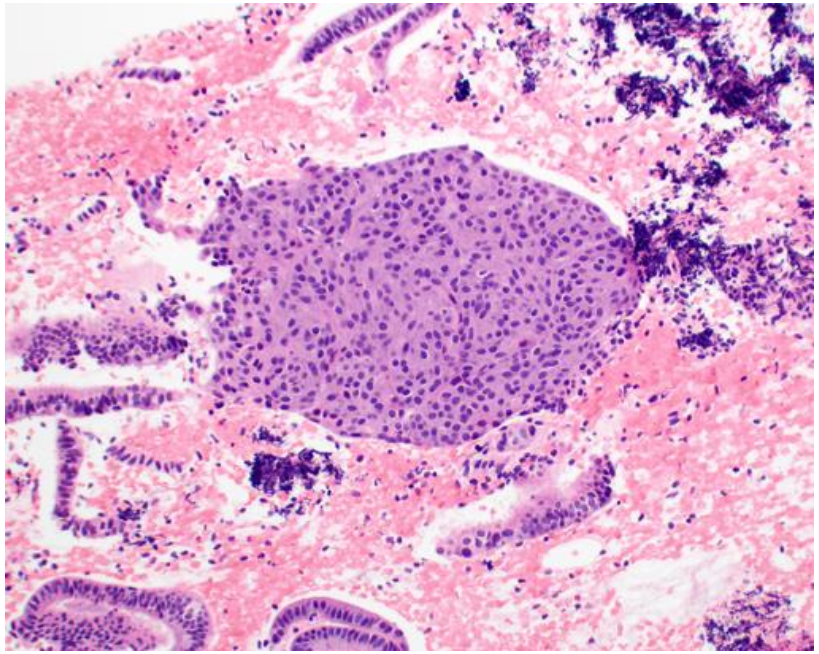

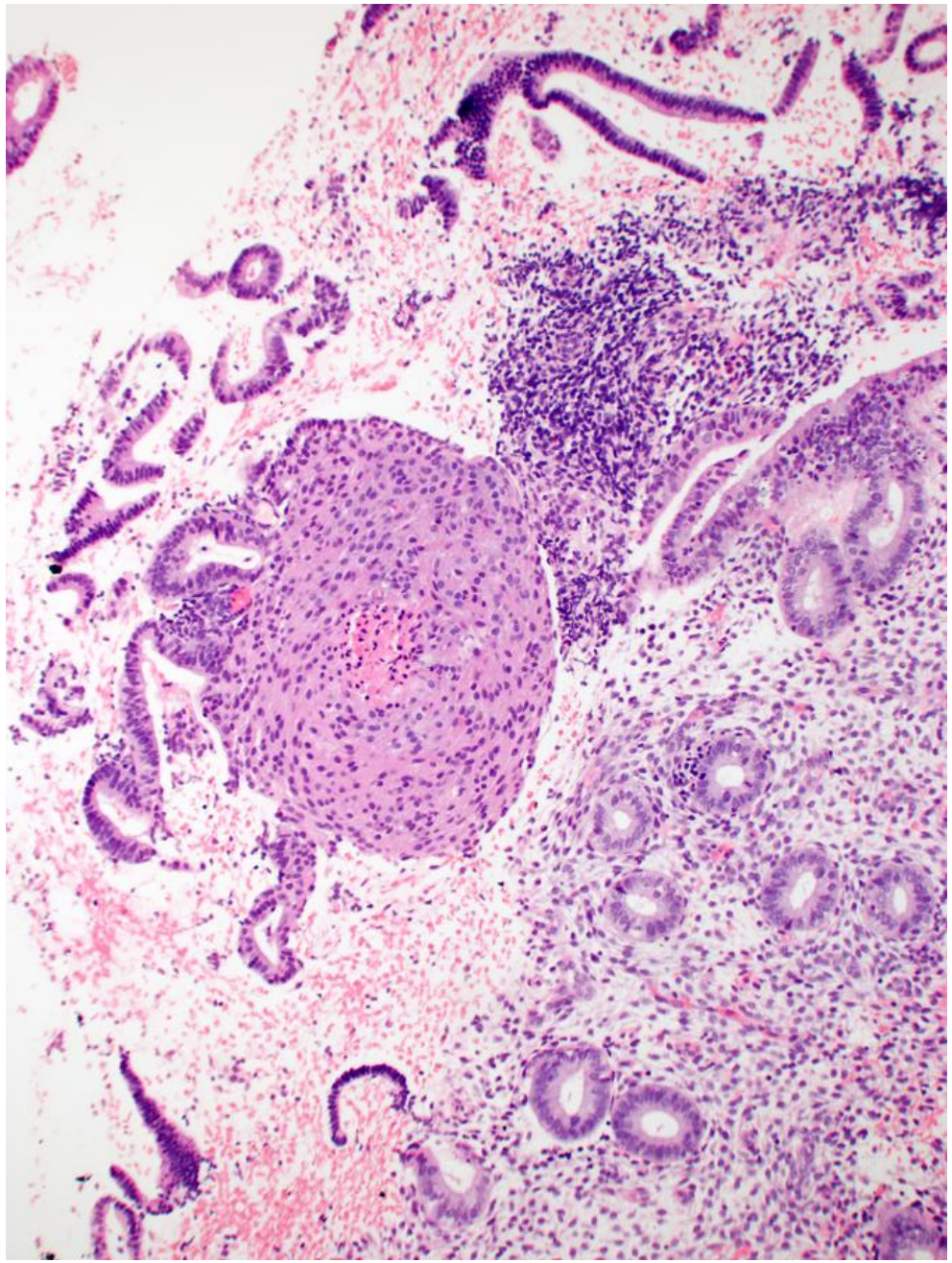

Free-floating Morules

Even in the absence of endometrial hyperplasia, these merit reporting

<u>Report Comment:</u>

- **Small risk of concurrent or subsequent precursor/cancer**
- **Clinical correlation for un-sampled lesion**
- **Long term follow up**

- **Cite:**
  - Lin 2009 PMID: 19180120
  - McCluggage 2019 PMID: 30085940

Squamous Pattern Pathology

- Benign but associated with neoplasia (*clinical action advised)*

  Morular metaplasia

- Low risk cancer / precursor

  Atypical polypoid adenomyoma

  Endometrioid carcinoma with squamous differentiation

- Secondary cancer

  

  Cervical HSIL / squamous cell carcinoma

- Diagnostic mimics

  Trophoblastic tumor / placental site nodule

  Epithelioid smooth muscle tumor / PEComa

  Granulomatous endometritis

Cervical HSIL / Squamous Cell Carcinoma in Endometrial Biopsy

Etiology:

- **Contamination by cervical tumor**
- **Direct extension of cervical tumor**

Pitfalls:

- **Morules**
- **Endometrioid carcinoma with massive squamous differentiation**
- **Primary endometrial squamous cell carcinoma** *(exceedingly rare)*

Cervical HSIL colonizing endometrial surface

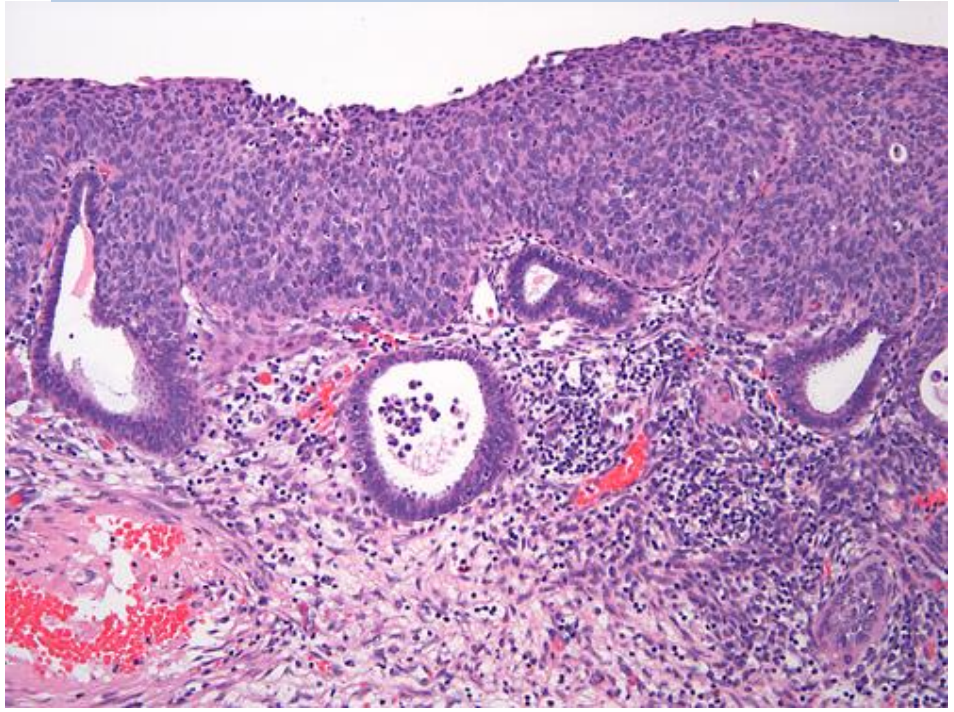

Cervical squamous cell carcinoma invading myometrium

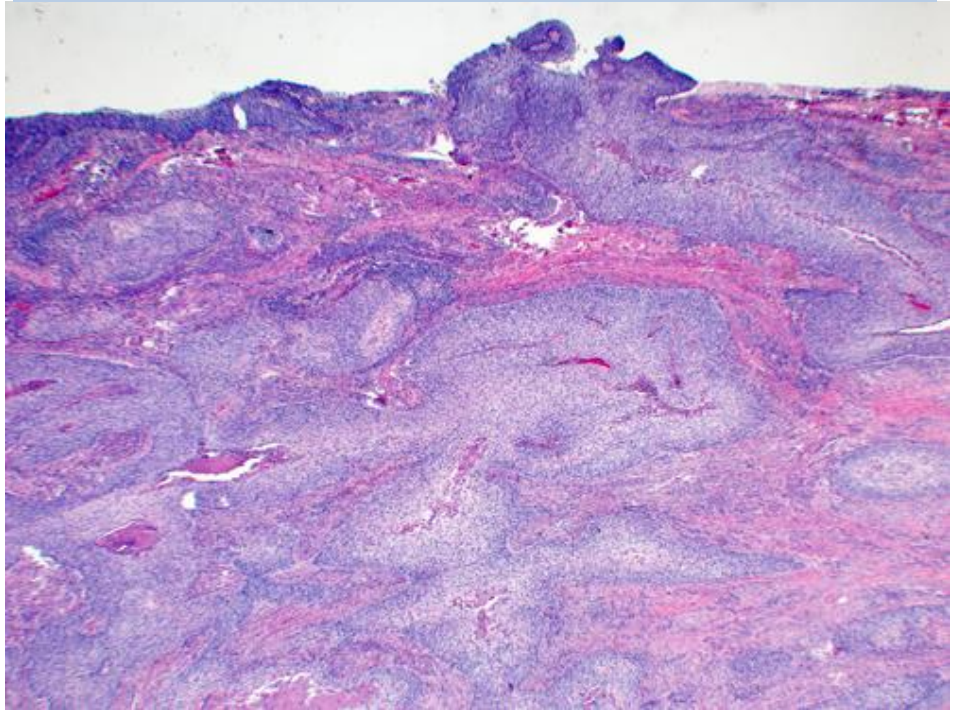

Contamination of Endometrial Biopsy by Cervical HSIL

Mimic Morules

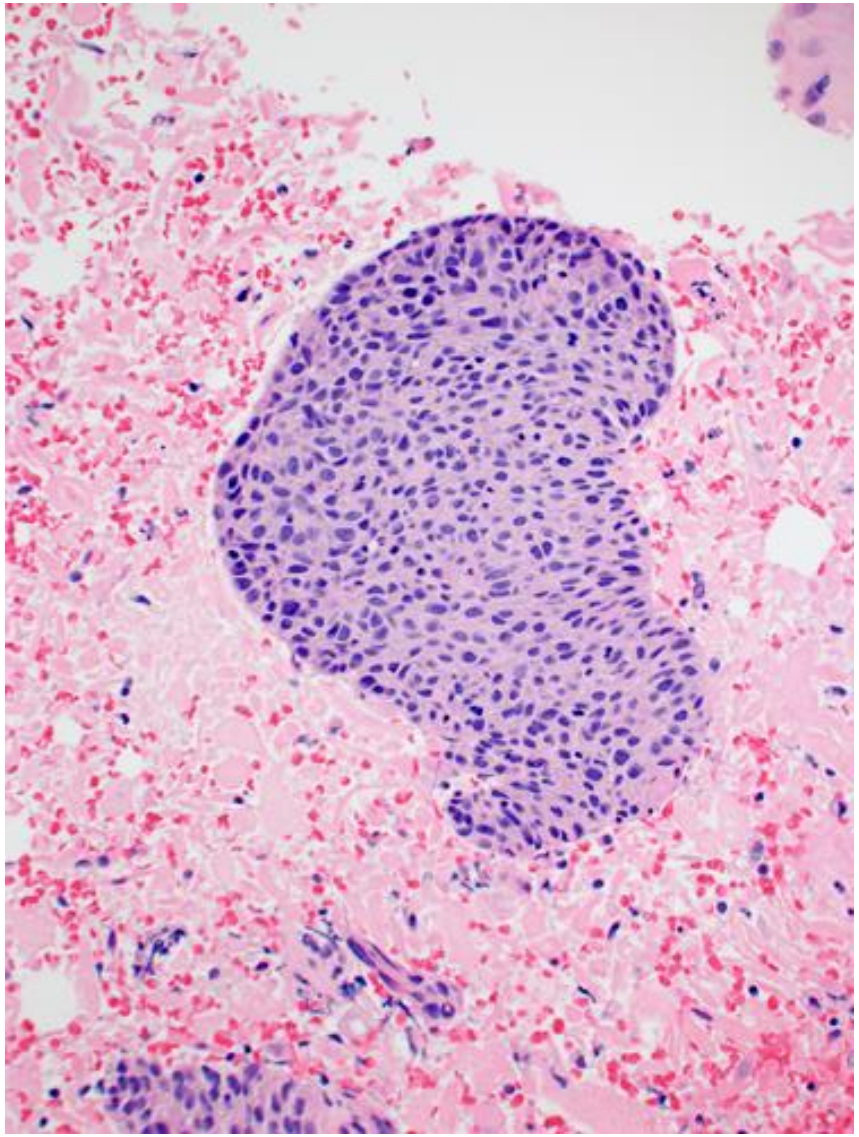

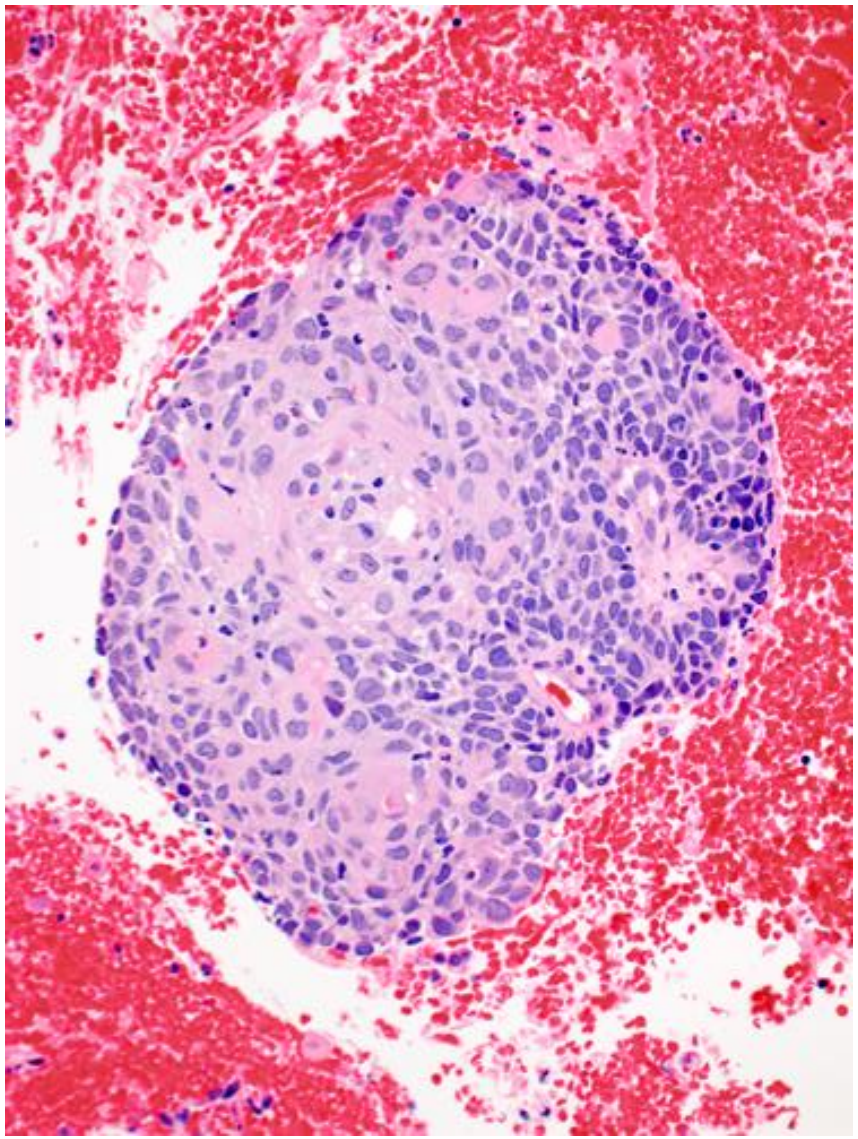

Endometrioid carcinoma with massive squamous differentiation

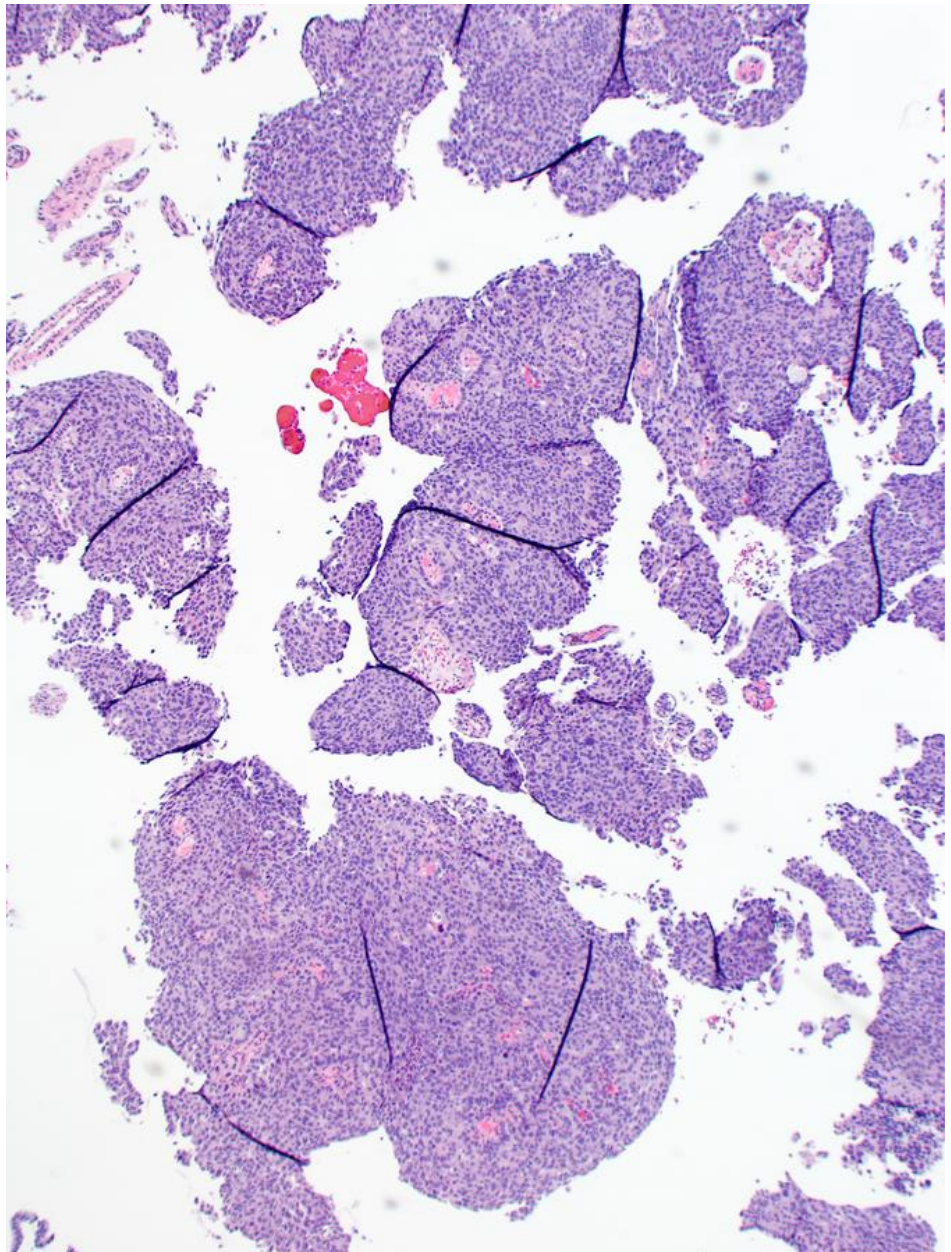

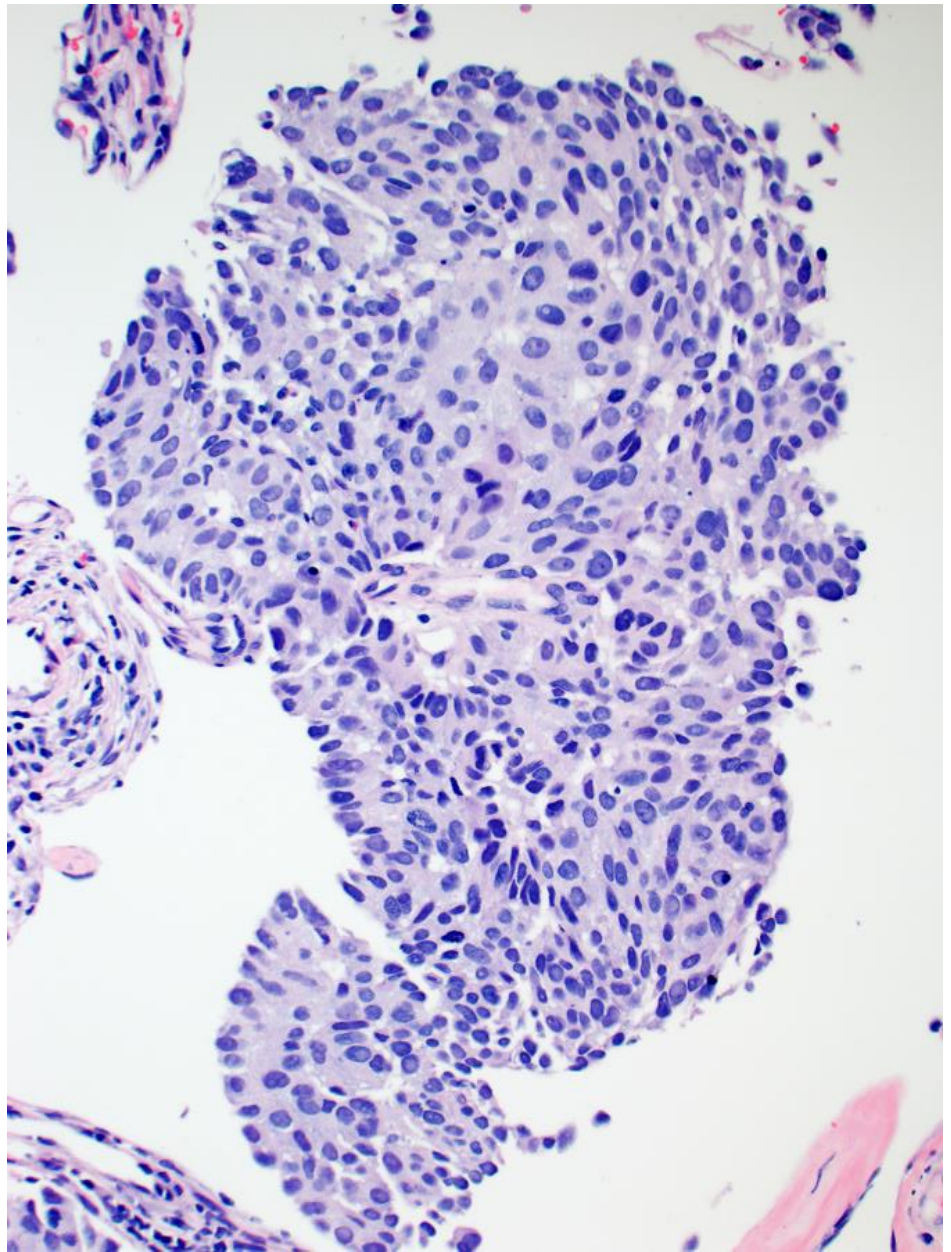

Contamination of Endometrial Biopsy by Cervical HSIL

p16



high risk HPV ISH

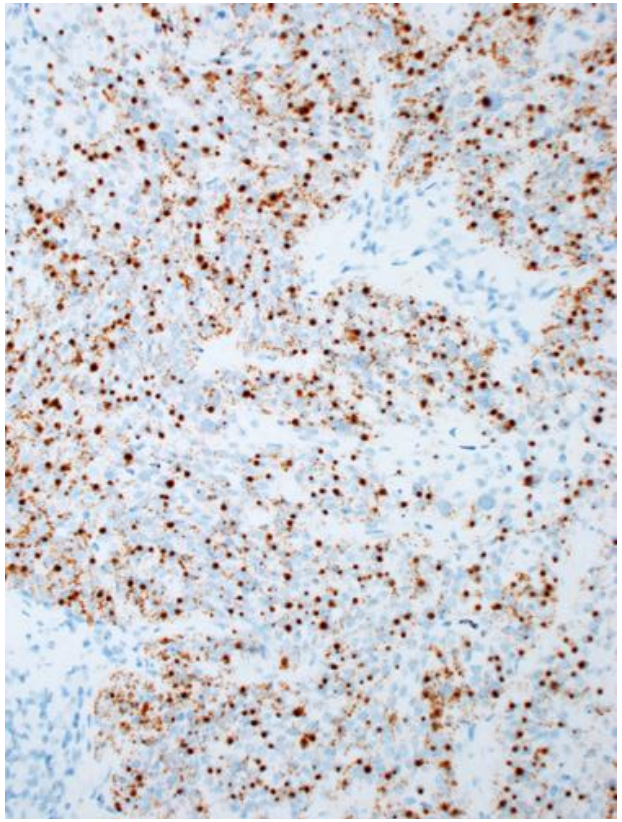

Challenges in Endometrial Biopsies

Epithelial Entities

1. **Glandular proliferations:**
   - **Hyperplasia: is it atypical or not ?**
   - **Atypical hyperplasia versus grade 1 endometrioid carcinoma ?**

2. **Low grade endometrioid ca**
   - **Benign mimics**
   - **Variants that m** **rs**

