Deceptively Bland Mimics of Uterine Leiomyoma

Joseph Rabban MD MPH
Professor
Director of Gynecologic Pathology
UCSF Pathology Department

Joseph.Rabban@ucsf.edu

UCSF
University of California
San Francisco



Uterine Mesenchymal Tumors

- **Vast majority are leiomyomas**

Variants
Conventional
Cellular
Degenerating
Mitotically active
Myxoid
Epithelioid
Intravenous
Fumarate hydratase deficient morphology

- **Uterine sarcomas are rare**

Rare
Leiomyosarcoma
Endometrial stromal sarcoma
Adenosarcoma

Very Rare
Perivascular epithelioid cell tumor
Inflammatory myofibroblastic tumor
Uterine tumor resembling ovarian sex cord tumor

Very Rare
Undifferentiated uterine sarcoma
Rhabdomyosarcoma
NTRK fusion sarcoma
KAT6A/B::KANSL1 fusion sarcoma

Uterine Mesenchymal Tumors

- **Vast majority are leiomyomas**



Potential <u>diagnostic pitfalls</u> due to morphologic <u>mimicry</u>

- **Uterine sarcomas are rare**

Uterine Smooth Muscle Tumor

Practical diagnostic steps

Step 1. **Confirm smooth muscle differentiation**

exclude deceptive malignant potential mimics

Step 2. **Classify the degree of malignant potential**

leiomyoma / STUMP / leiomyosarcoma

Step 3. **Screen for hereditary risk**

fumarate hydratase-deficient morphology (HLRCC syndrome)

Uterine Leiomyoma

Clinically relevant "low grade" deceptive mimics

Leiomyoma Morphology	Mimics with Malignant Potential
Spindle cell / cellular	Low grade endometrial stromal sarcoma
	KAT6A/B::KANSL1 fusion tumor
	NTRK fusion tumor
	Inflammatory myofibroblastic tumor
Myxoid / inflammatory	Inflammatory myofibroblastic tumor
Epithelioid	Perivascular epithelioid cell tumor





Uterine Smooth Muscle Tumors

Practical Issues with Immunohistochemistry

- **Sensitivity of myoid markers is highly variable**

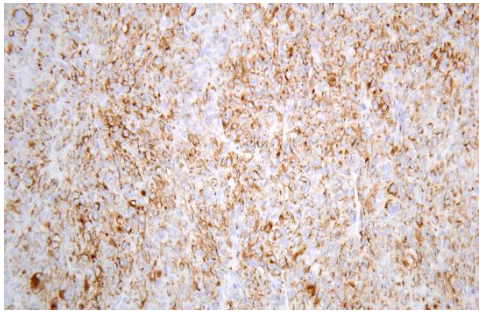

Smooth muscle actin
Smooth muscle myosin
Desmin
Caldesmon

Some cases may mark with only 1 of 4 markers

- *Evaluate all 4 markers before excluding myoid differentiation*

Uterine Smooth Muscle Tumors

Practical Issues with Immunohistochemistry

- Sensitivity of myoid markers is highly variable
- **CD10 can be patchy** (not pathognomonic for endometrial stromal differentiation)

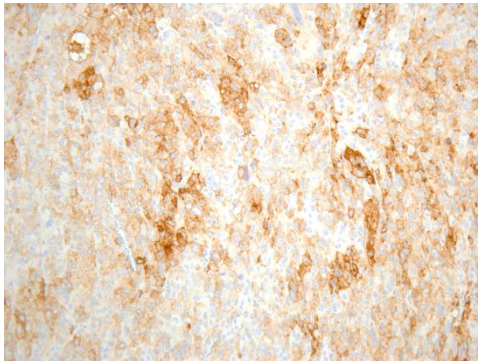

Uterine Smooth Muscle Tumors

Practical Issues with Immunohistochemistry

- **Sensitivity of myoid markers is highly variable**
- **CD10 can be patchy** (not pathognomonic for endometrial stromal differentiation)
- **Keratin can be positive** (especially in epithelioid variants)

Use EMA instead of keratin to exclude carcinoma

Low Grade Endometrial Stromal Tumors

Practical Issues with Immunohistochemistry

- **CD10 is usually uniformly strong**

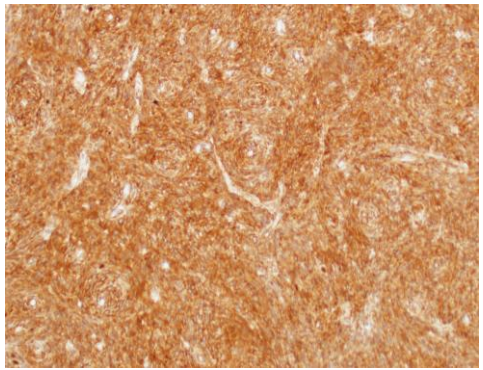

- **Myoid markers often negative but can be patchy positive**

Particularly if prominent smooth muscle differentiation is present

Uterine Mesenchymal Tumors

Practical Issues with Immunohistochemistry

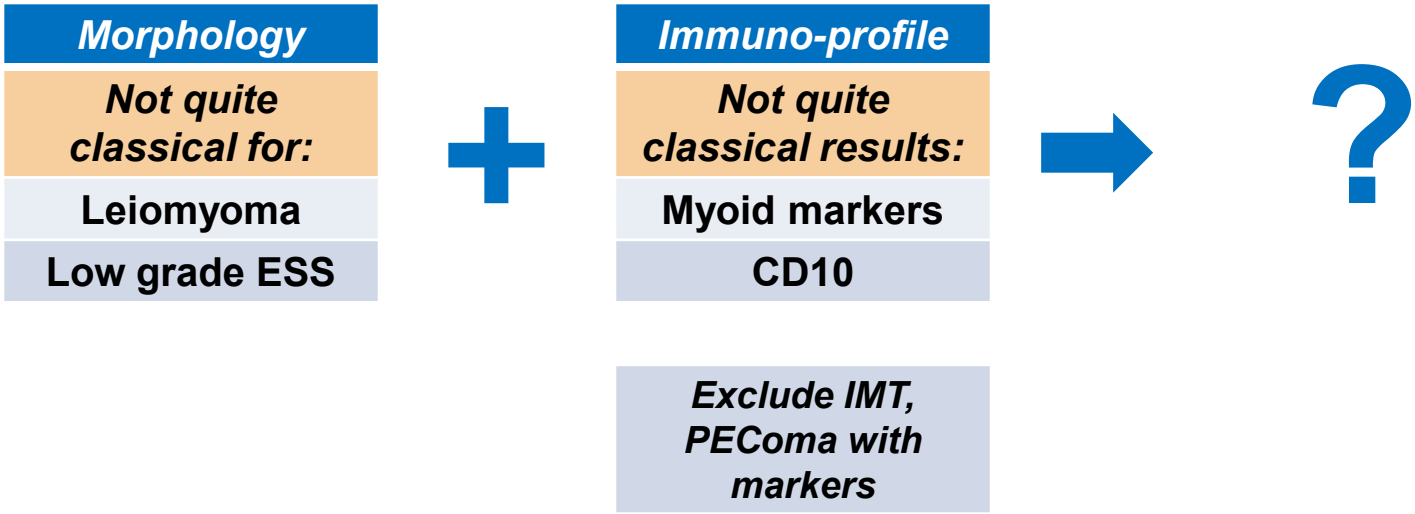

Uterine Mesenchymal Tumors

Practical Issues with Immunohistochemistry

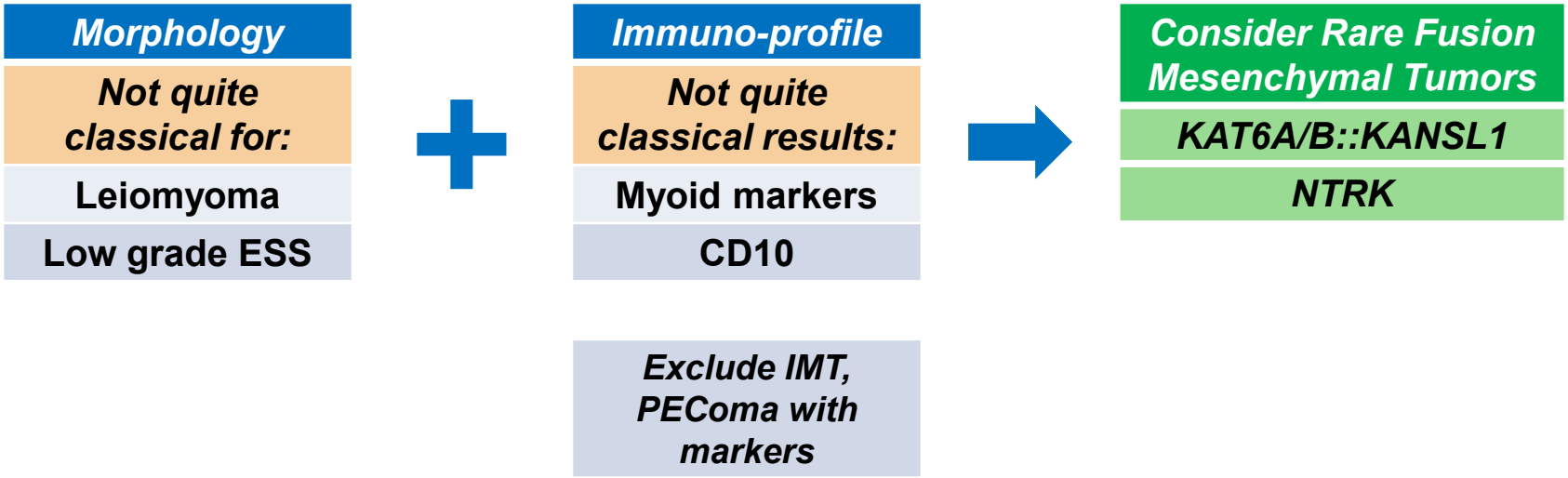

Uterine Leiomyoma

Clinically relevant "low grade" deceptive mimics

Leiomyoma Morphology	Mimics with Malignant Potential
	Low grade endometrial stromal sarcoma
Spindle cell	***KAT6A/B::KANSL1* fusion tumor**





KAT6A/B::KANSL1 Uterine Mesenchymal Tumor

New Entity

Definition:

- **Uterine mesenchymal tumor with *KAT6A/B::KANSL1* fusion**
  overlapping myoid / endometrial stromal morphology
- **Rare: <3 dozen cases reported**
  first series in 2022 PMID: 35575789
- **All adult ages** (median age 50)
- **Most confined to uterus, rare advanced stage cases**

Clinical relevance:

- **28% recur, 11% die of tumor**

- **Potential under-diagnosis as leiomyoma or LG-ESS**

PMID: 39392508, 35575789, 37307879, 25621995, 33876771, 31027501, 15313893

KAT6A/B::KANSL1 Uterine Mesenchymal Tumor

Macrosopic features:

- **2 to >20 cm** (median ~ 8 cm)
- **Well circumscribed**

Microscopic features:

- **Spindled / oval monomorphic cells in solid pattern** →
- **Thin-walled arteriolar network**
- **Low mitotic rate** (median <3/10 hpf)
- **Rare LVSI**
- **Rare "infiltrating" borders**

Variable patterns
▪ Necrosis
▪ Myxoid change
▪ Sex cord-like
▪ Hyaline collagen deposits

PMID: 39392508, 35575789, 37307879, 25621995, 33876771, 31027501, 15313893

KAT6A/B::KANSL1 Uterine Mesenchymal Tumor

Deceptive well-circumscribed growth



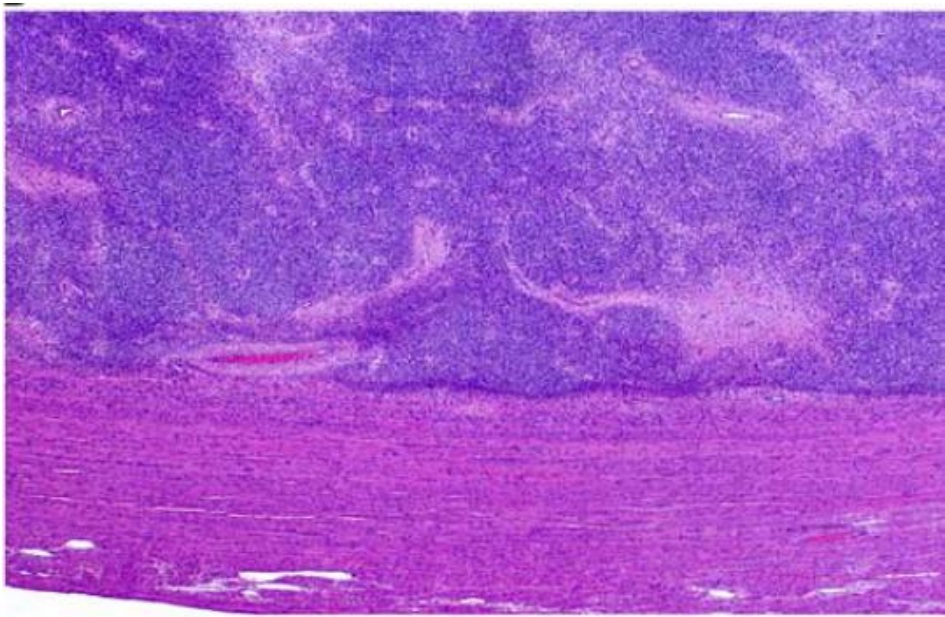

Figures from PMID: 35575789

KAT6A/B::KANSL1 Uterine Mesenchymal Tumor

Rare infiltrative growth

Myoinvasion

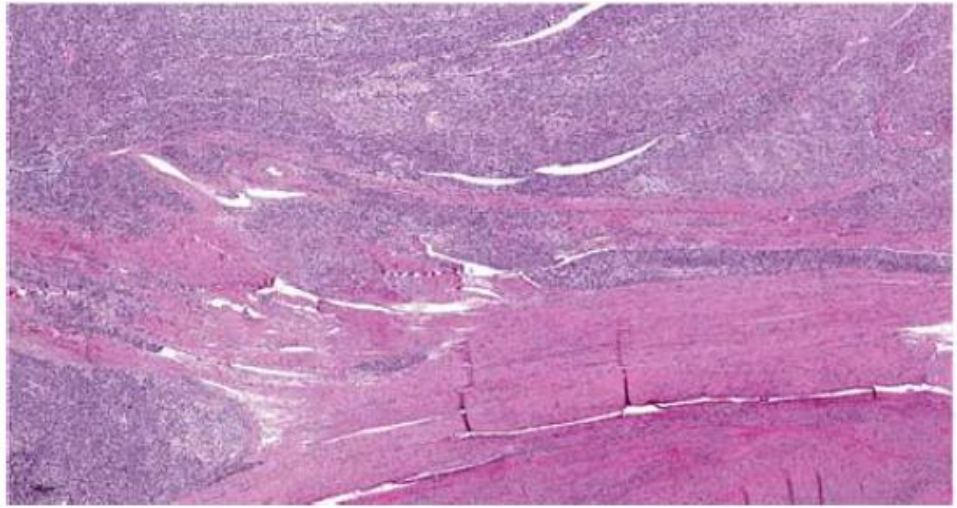

Lymphovascular invasion

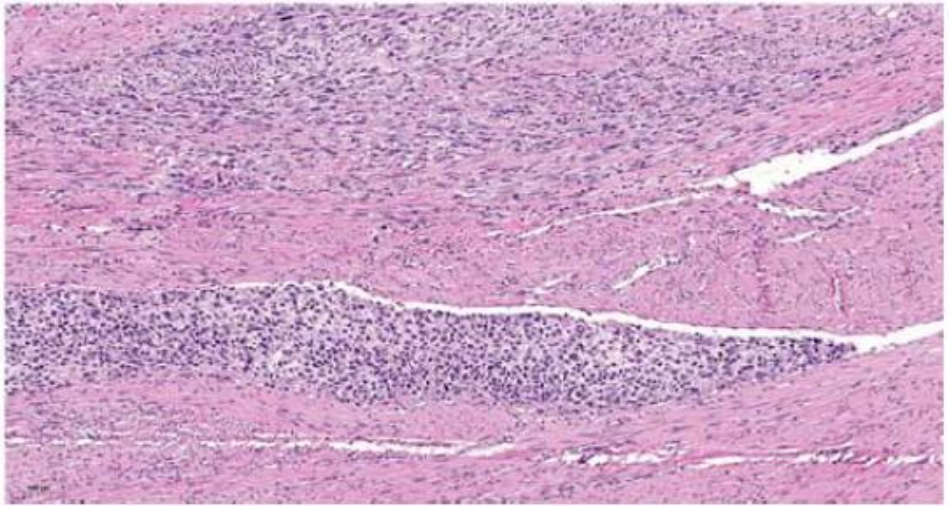

Figures from PMID: 35575789

KAT6A/B::KANSL1 Uterine Mesenchymal Tumor

Mimics low grade endometrial stromal differentiation

Thin-walled arteriolar network

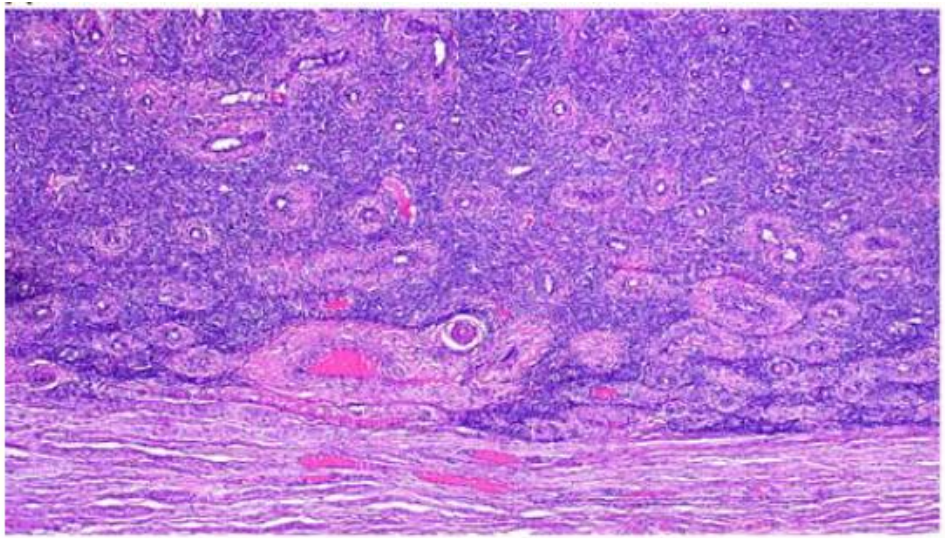

Monotonous oval / spindled cells

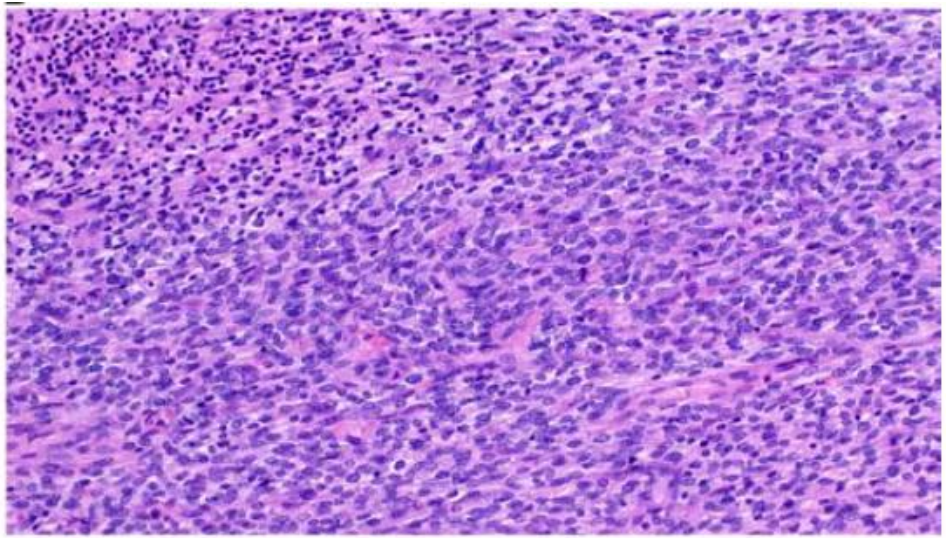

Figures from PMID: 35575789

KAT6A/B::KANSL1 Uterine Mesenchymal Tumor

Mimics leiomyoma differentiation

Fascicular spindle cell growth

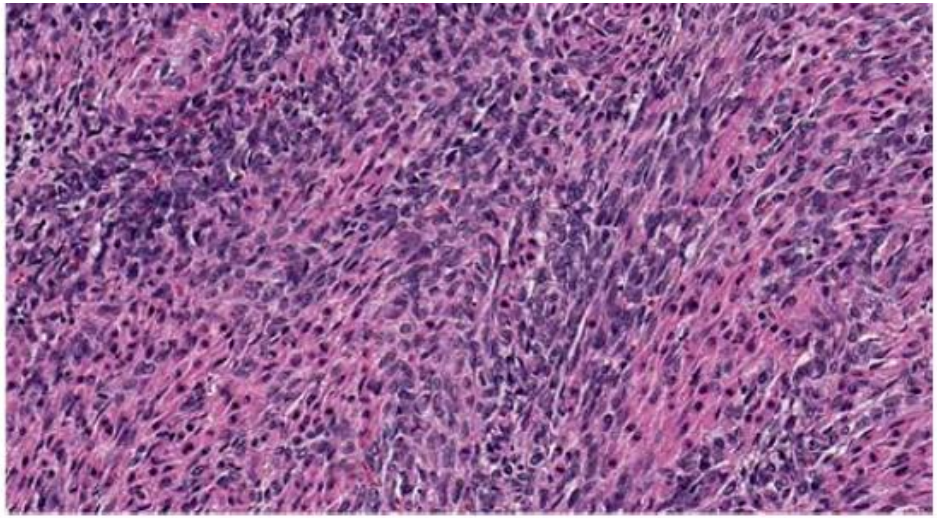

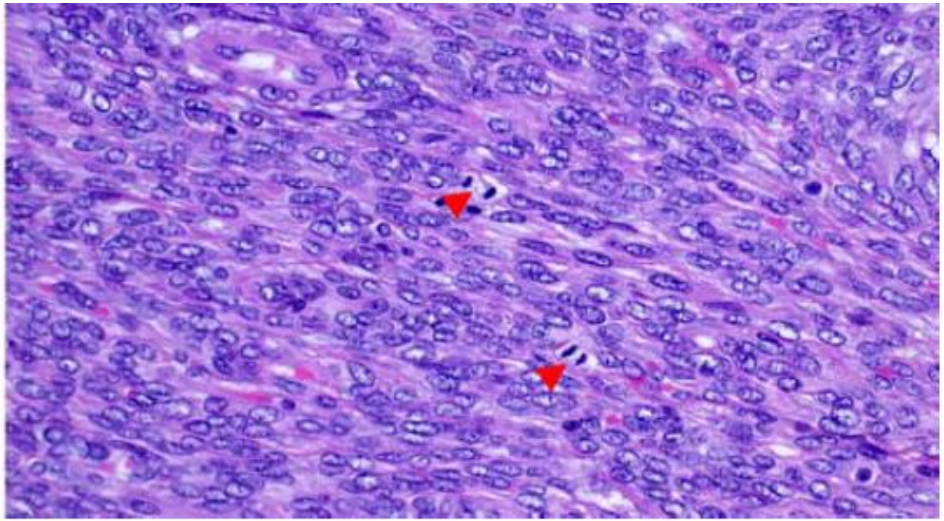

Figures from PMID: 35575789

KAT6A/B::KANSL1 Uterine Mesenchymal Tumor

Myxoid features

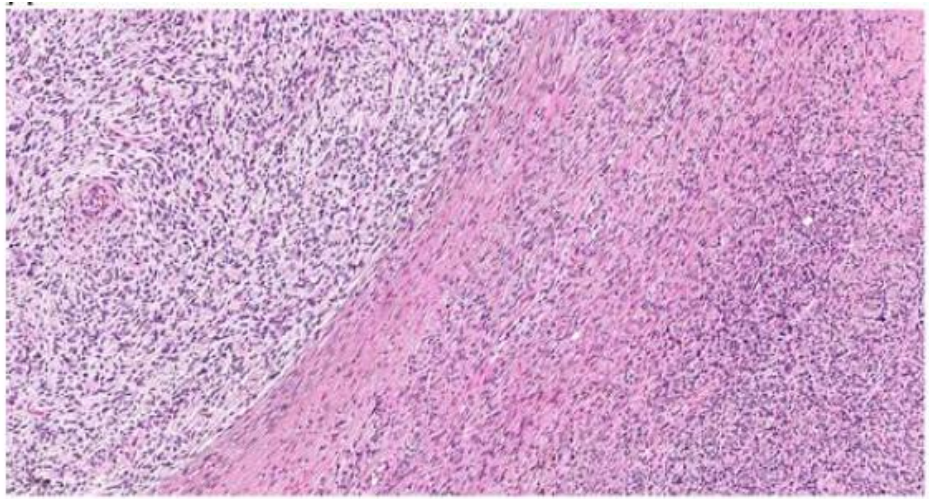

Plump cells

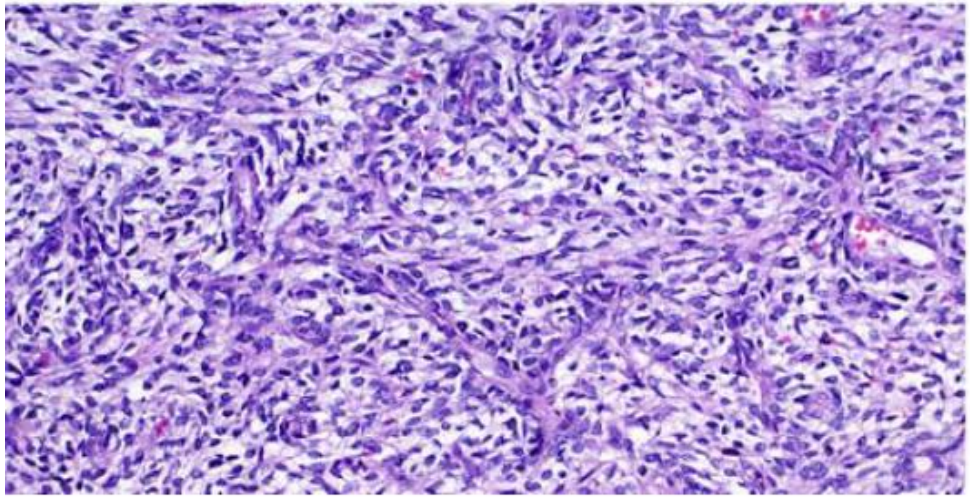

Figures from PMID: 35575789

KAT6A/B::KANSL1 Uterine Mesenchymal Tumor

Immunohistochemistry

Variable staining	Positive
▪ CD10	▪ Estrogen receptor
▪ Smooth muscle stains	▪ Progesterone receptor
▪ Keratin	

Molecular diagnosis

Tumor sequencing (NGS panel or RNA fusion panel)

Present	▪ ***KAT6A::KANSL1*** **or** ▪ ***KAT6B::KANSL1***
Absent	▪ **LG-ESS fusions** ▪ **Leiomyoma mutations** (MED12, FH)

KAT6

Function

- Histone acetylation
- Epigenetic control of gene transcription

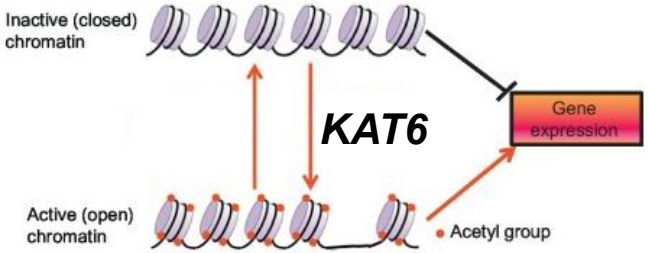

Tumor classification

- DNA methylation signature suggests *KAT6A/B::KANSL1* uterine tumor is unique

- Cell origin / tumor “type” yet to be defined

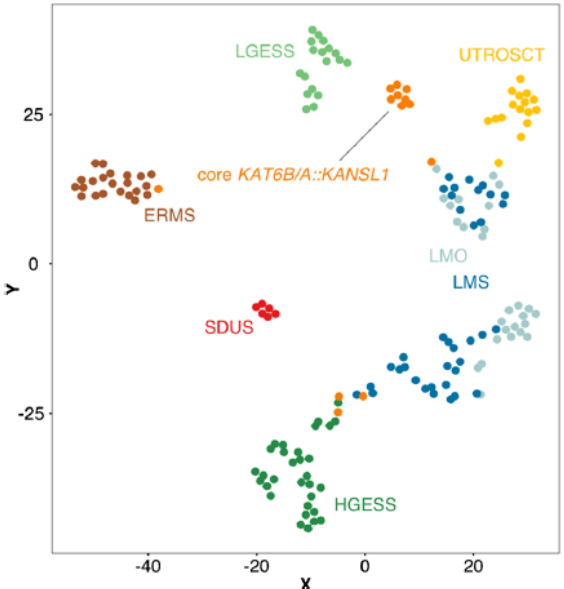

PMID: 39392508

KAT6A/B::KANSL1 Uterine Mesenchymal Tumor

Behavior

- **~85% present as Stage I**
- **28% recur, 11% die of tumor,** as early as within 1 year
- **Too early to identify prognostic variables**

Management

- **Not enough known**
- ***KAT6* inhibitors in early clinical trials for breast cancer** PMID: 38824244

PMID: 39392508

Uterine Leiomyoma

Clinically relevant "low grade" deceptive mimics

Leiomyoma Morphology	Mimics with Malignant Potential
	Low grade endometrial stromal sarcoma
	KAT6A/B::KANSL1 fusion tumor
Spindle cell	***NTRK* fusion tumor**





NTRK Fusion Uterine Tumor

New Entity

Definition:

- **Fibrosarcoma-like tumor with *NTRK* fusion**
- **Young women** (age 20's to 40's)
- **Cervical polypoid mass**
- **2 cm to 16 cm**
- **Stage I**

Clinical relevance:

- **Small risk for recurrence, metastasis, death**
- **Responsive to targeted therapy** (Trk inhibitors)

Chiang. Am. J. Surg. Pathol. 2018; 42:791–798
Croce. Mod. Pathol. 2019 32; 7:1008-1022
Rabban. Histopathol. 2020; 77; 100-111
Hodgson .Int J Gynecol Pathol. 2020 Feb Epub ahead of print

NTRK Fusion Uterine Tumor

Morphology:

- Haphazard fascicles
- Spindle cells with mild to moderate atypia
- Variable mitotic rate / necrosis
- Infiltrative borders

Doesn't fit into classic category
+/- leiomyoma
+/- adenosarcoma
+/- fibrosarcoma

Immunophenotype:

- Negative for myoid markers
- Negative for endometrial stromal markers
- Positive S100, CD34

Unusual profile

Chiang. Am. J. Surg. Pathol. 2018; 42:791–798
Croce. Mod. Pathol. 2019 32; 7:1008-1022
Rabban. Histopathol. 2020; 77; 100-111
Hodgson .Int J Gynecol Pathol. 2020 Feb Epub ahead of print

NTRK Fusion Uterine Tumor

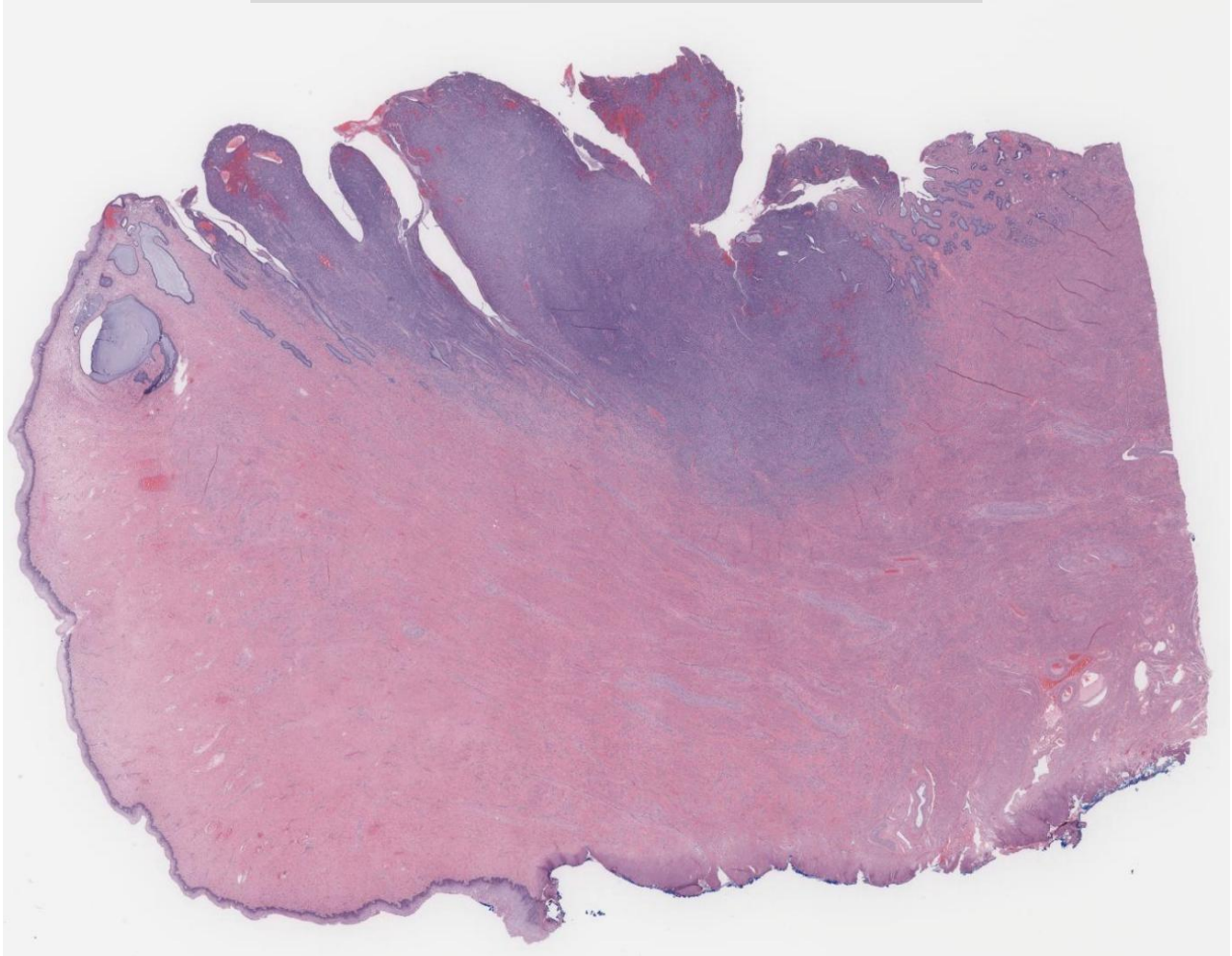

NTRK Fusion Uterine Tumor

Slightly haphazard fascicles

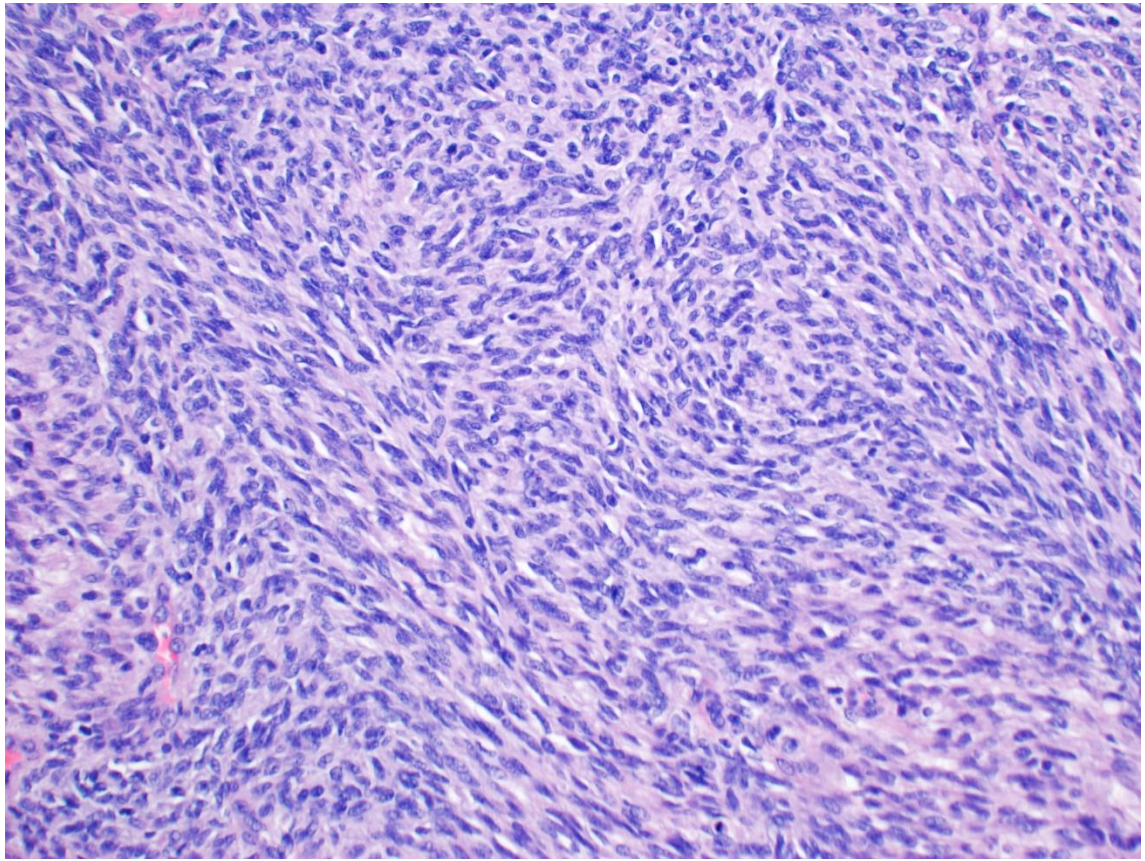

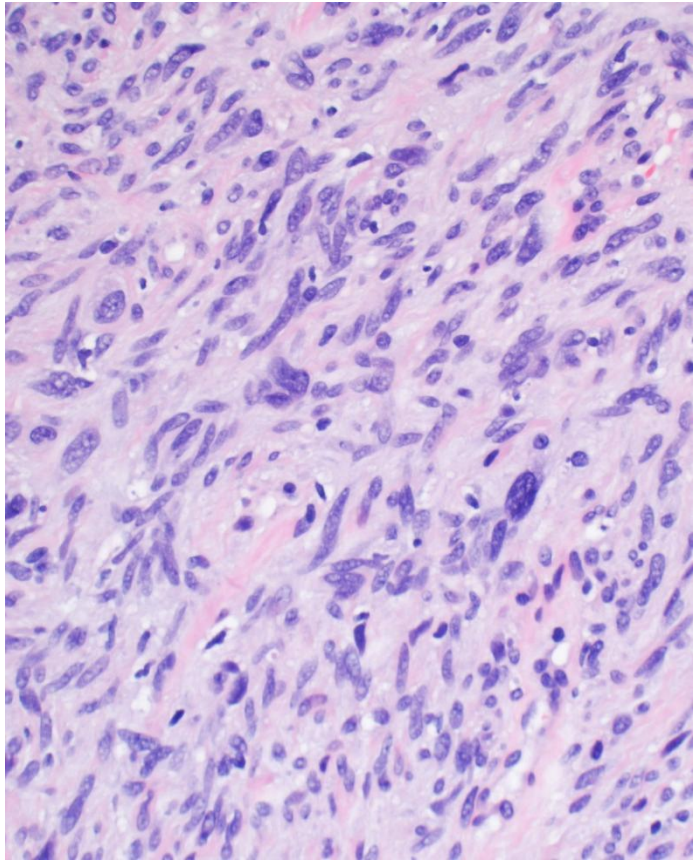

NTRK Fusion Uterine Tumor

Entrapped endocervical glands mimics adenosarcoma



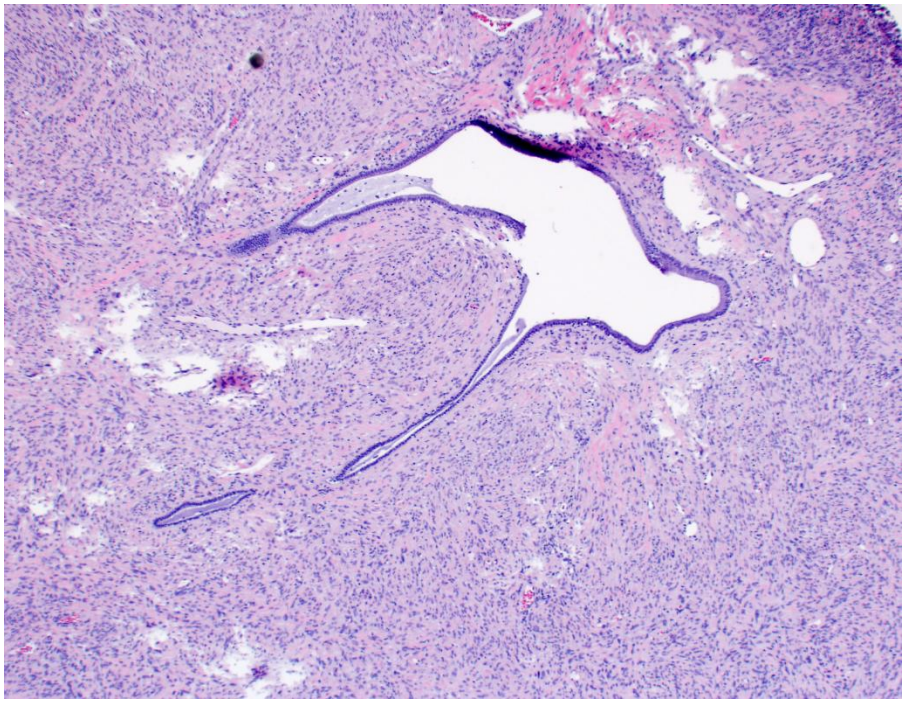

NTRK Fusion Uterine Tumor

Infiltrative borders

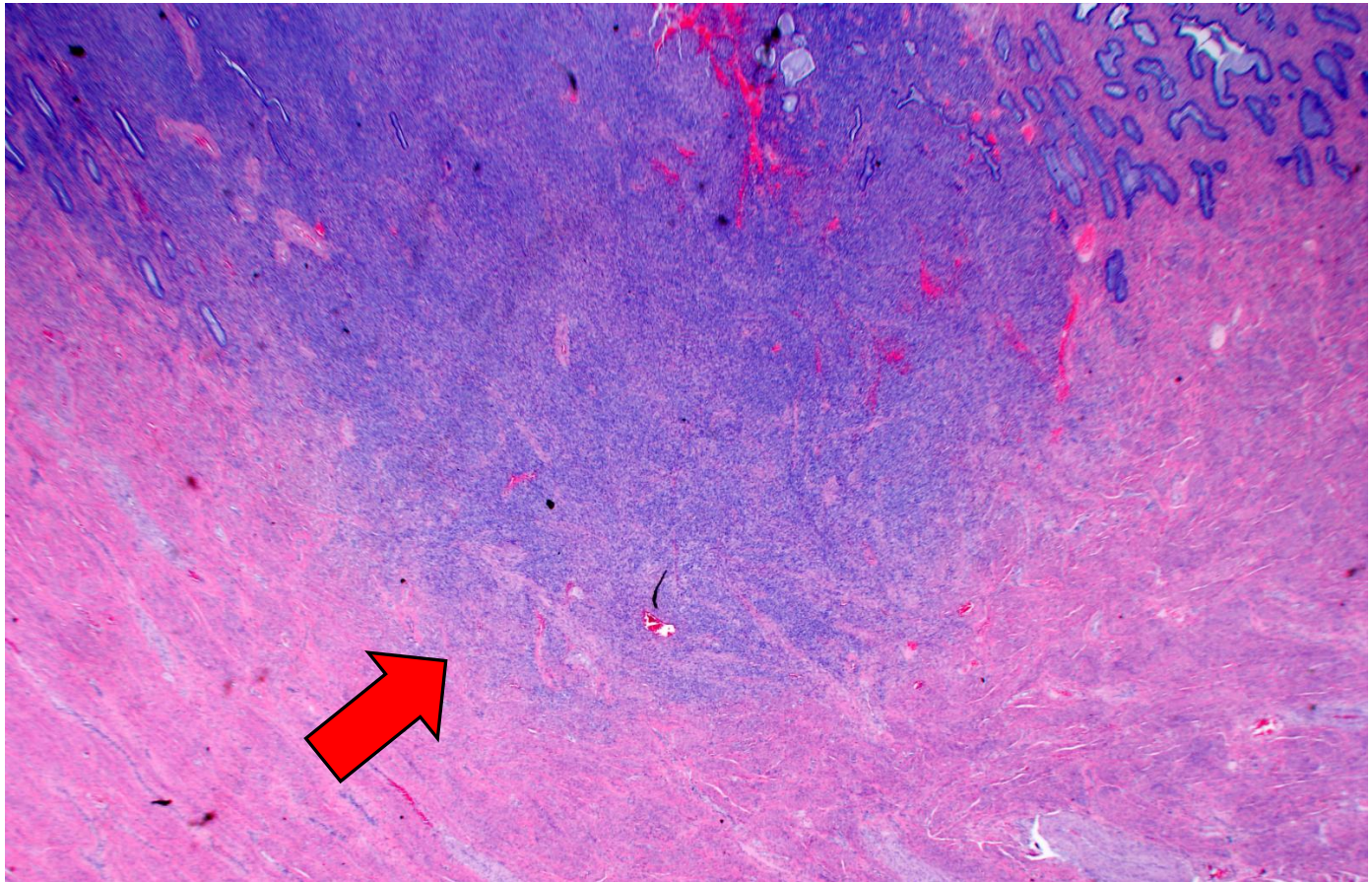

NTRK Fusion Uterine Tumor

IHC	
Smooth muscle	Negative
CD10	Negative
ER, PR	Negative
CD34	Positive
S100	Positive
SOX10	Negative
H3K27me3	Negative

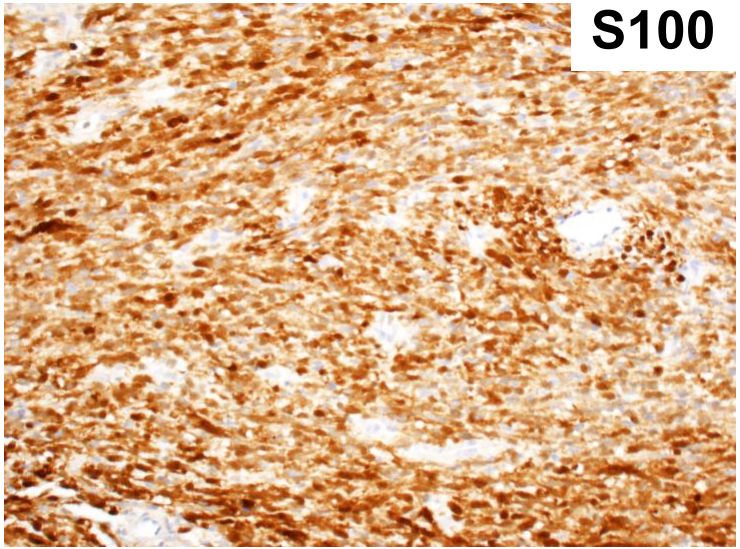

NTRK Fusion Uterine Tumor

pan-TRK IHC

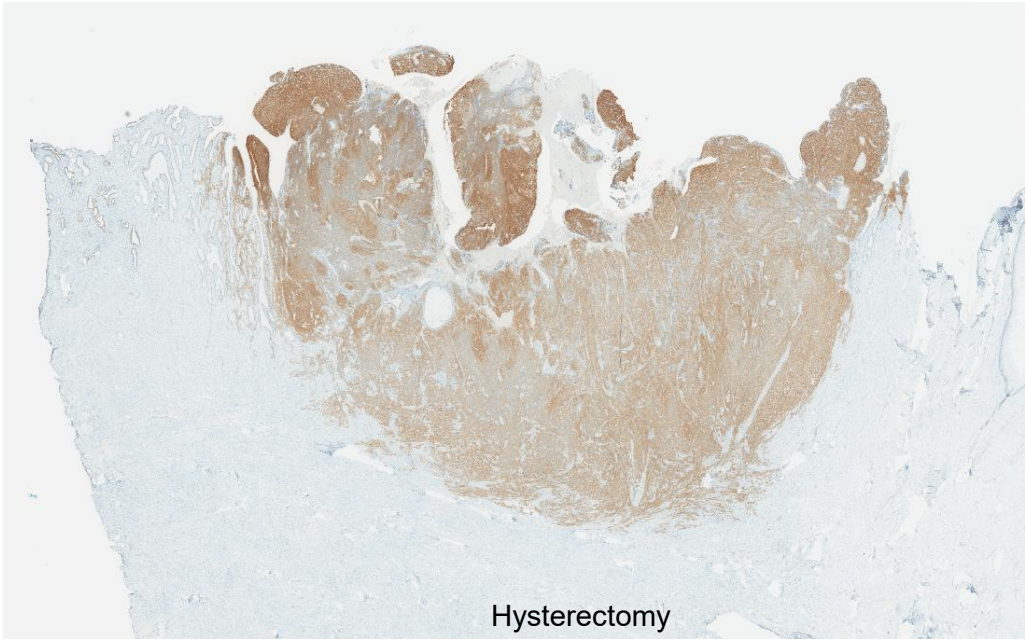

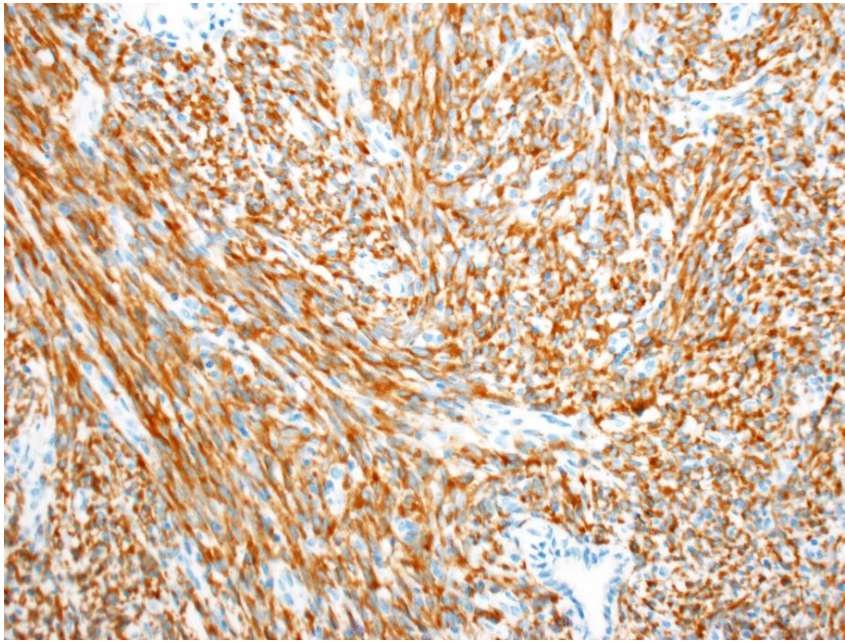

Clinical relevance of recognizing *NTRK* fusion uterine tumor

1. Metastatic / recurrent potential in a subset

-not enough cases to identify prognostic variables

	Stage I	Metastasis / Local recurrence	Death
Chiang et al. AJSP 2018	4/4	1/4	1/4
Croce et al. Mod Pathol 2019	5/7	2/6	0
Rabban et al. Histopath. 2020	3/3	1/3	0
Michael et al. AJSP 2019	1/1	0	0

Clinical relevance of recognizing *NTRK* fusion uterine tumor

1. Metastatic / recurrent potential in a subset

-not enough cases to identify prognostic variables

	Stage I	Metastasis / Local recurrence	Death
Chiang et al. AJSP 2018	4/4	1/4	1/4
Croce et al. Mod Pathol 2019	5/7	2/6	0
Rabban et al. Histopath. 2020	3/3	1/3	0
Michael et al. AJSP 2019	1/1	0	0

2. **TRK inhibitor therapy approved by FDA for *NTRK* fusion positive tumors**
   - **Larotrectinib**
   - **Entrectinib**

Drilon et al. NEJM 2018
Doebele et al. Lanc Oncol 2020

Triggers to Work-up *NTRK* fusion uterine tumor

- **Morphology suggestive of, but not classic for:**

Leiomyoma
Adenosarcoma
“fibrosarcoma”

- **Unusual immunophenotype for smooth muscle / endometrial stromal tumor:**

Negative smooth muscle markers
Negative CD10
Negative ER, PR

Uterine Leiomyoma

Clinically relevant "low grade" deceptive mimics

Leiomyoma Morphology	Mimics with Malignant Potential
	Low grade endometrial stromal sarcoma
	KAT6A/B::KANSL1 fusion tumor
Spindle cell	*NTRK* fusion tumor
	→ **Inflammatory myofibroblastic tumor**
Myxoid	→ **Inflammatory myofibroblastic tumor**





Uterine Inflammatory Myofibroblastic Tumor (IMT)

Definition:

- ***ALK or ROS1* fusion mesenchymal tumor with variable myxoid and inflammatory features**
- **All ages affected**
- **May present as a polyp, mass or advanced stage tumor**

Clinical significance

- **~10% have malignant potential**
- **Targeted therapy is available**

Rabban et al, AJSP 2005; 29: 1348-1355
Parra-Herran et al, AJSP 2015;39:157–168
Haimes et al, AJSP 2017;41:773–780
Bennett et al, Mod Pathol 2017 30, 1489–1503
Devereaux et al. AJSP 2019;43:64–74

Uterine IMT

Pitfalls that Mimic Leiomyoma

- **Macroscopic appearance may be well circumscribed**
- **Tumor cells may mimic leiomyoma with degenerative myxoid–like features**
- **Myxoid / inflammatory features may be focal / limited**
- **Myoid markers are positive**

- *IMT may also mimic myxoid variants of leiomyosarcoma, LG-ESS*

Uterine IMT

May be gelatinous / myxoid

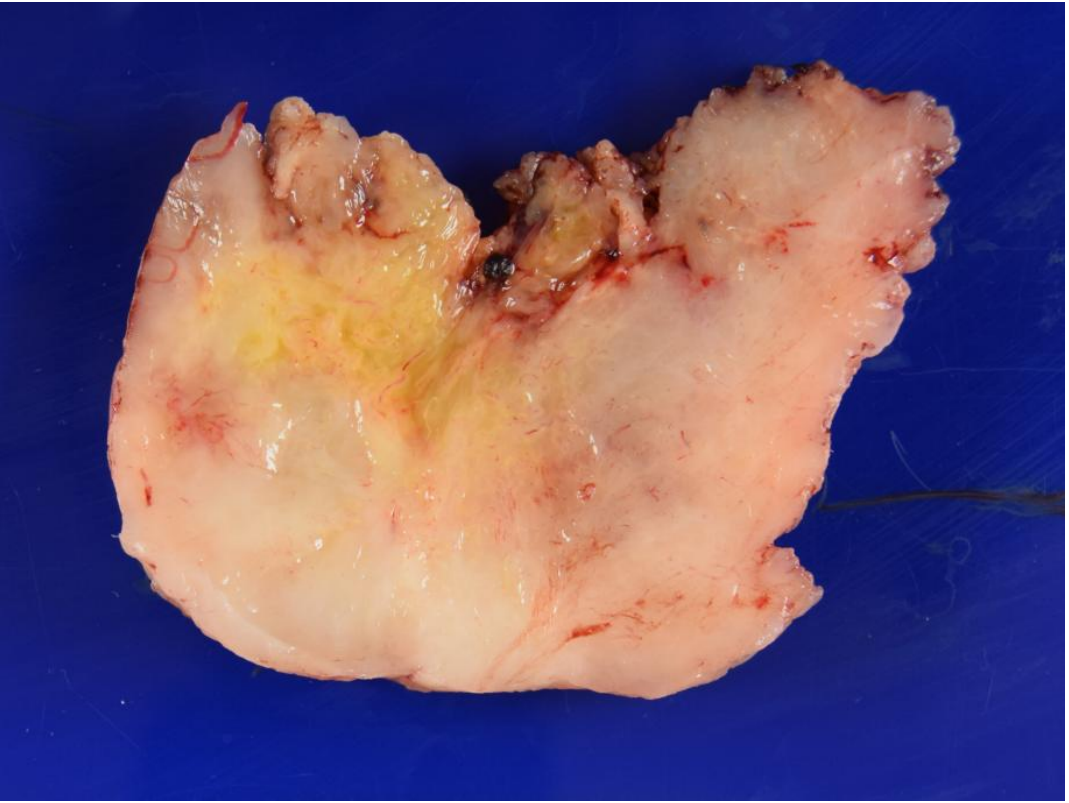

May resemble leiomyoma

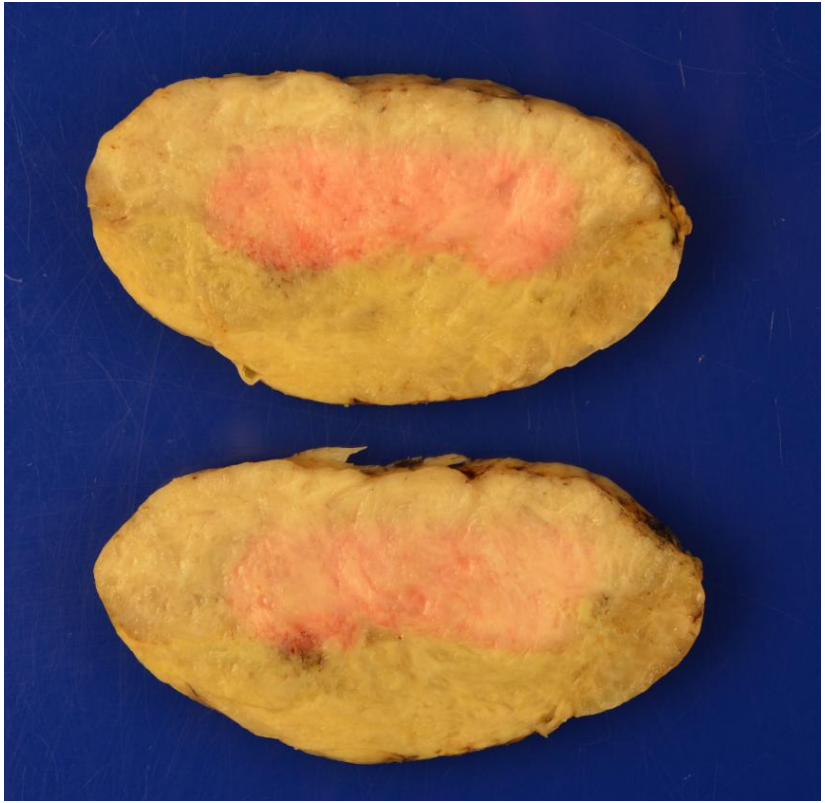

Uterine IMT

2 Main Architectural Patterns

- Both present in almost all cases
- Relative amount of each varies

Hypocellular myxoid pattern

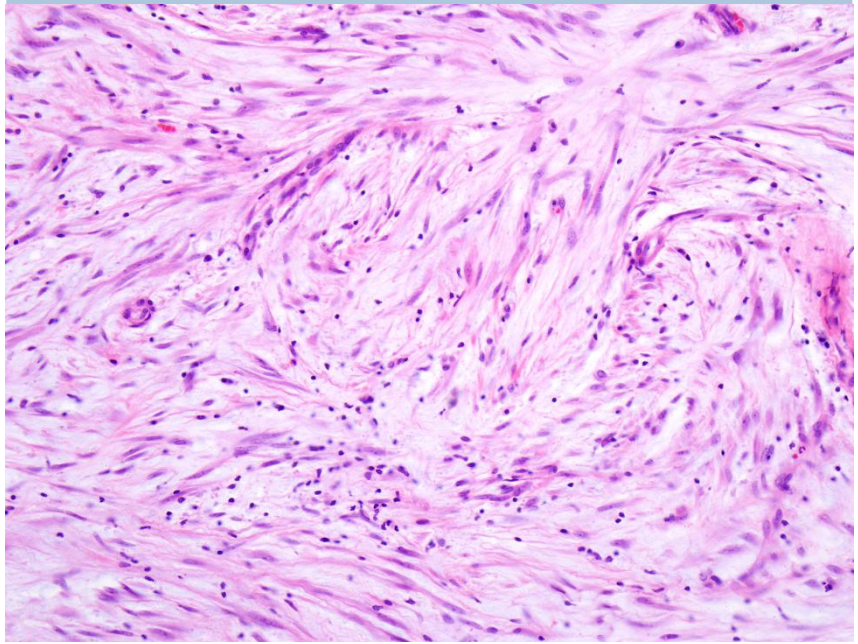

Compact fascicular pattern

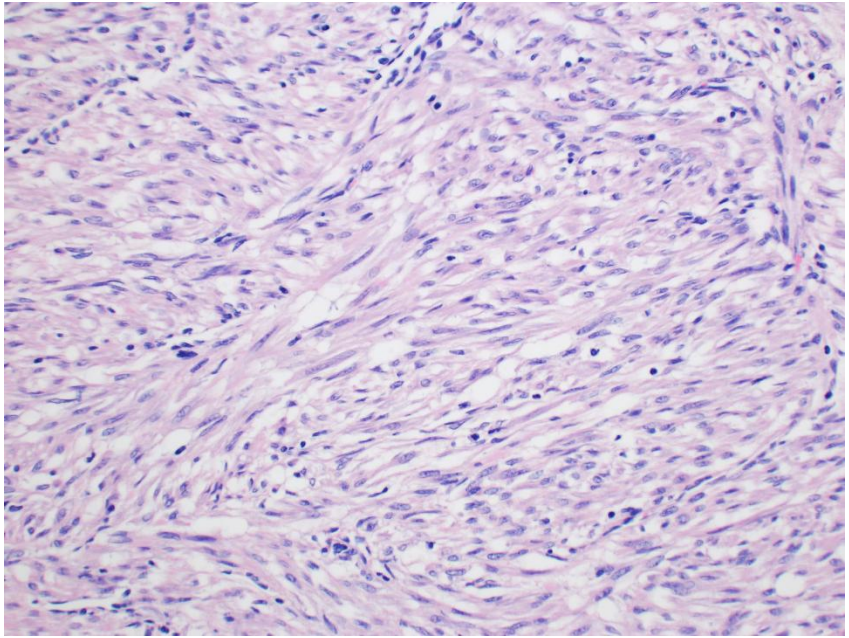

Uterine IMT: Hypocellular Patterns

Nodular fasciitis-like

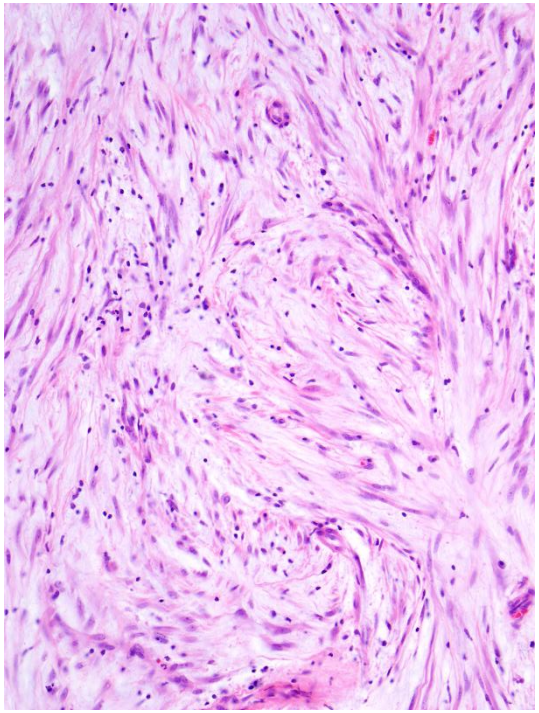

Myxoid pools

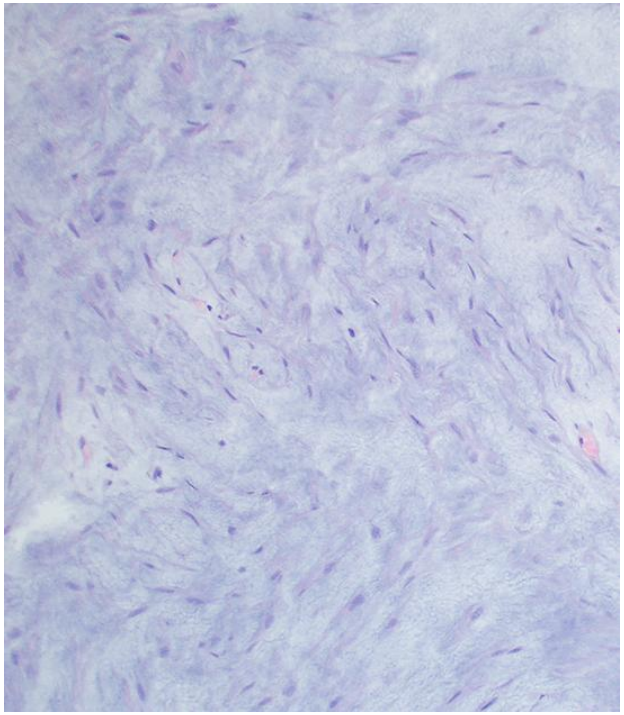

Pseudocysts

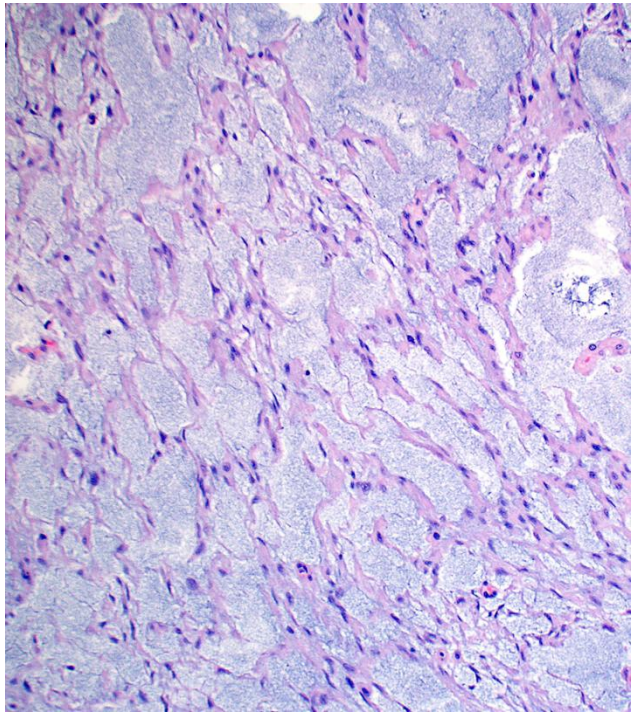

Myxoid Leiomyoma: Very Rare Diagnosis of Exclusion

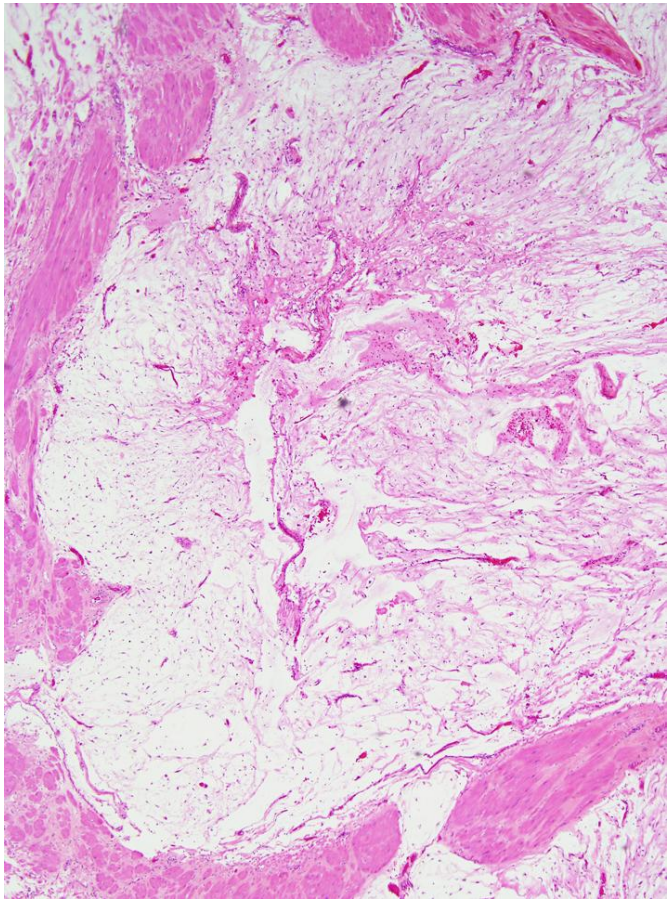

Exclude Mimics First

- IMT
- Myxoid LG-ESS
- Leiomyosarcoma

Uterine IMT: Fascicular Patterns

May mimic leiomyoma

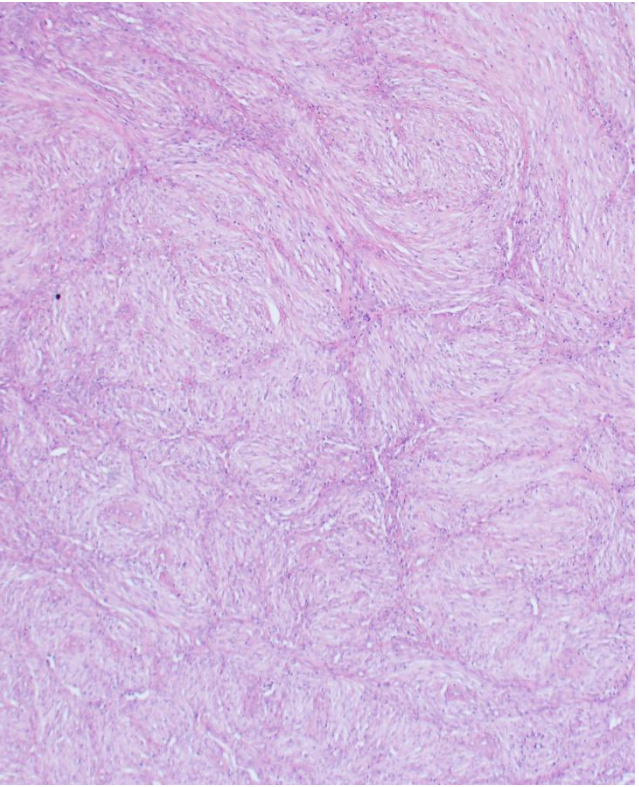

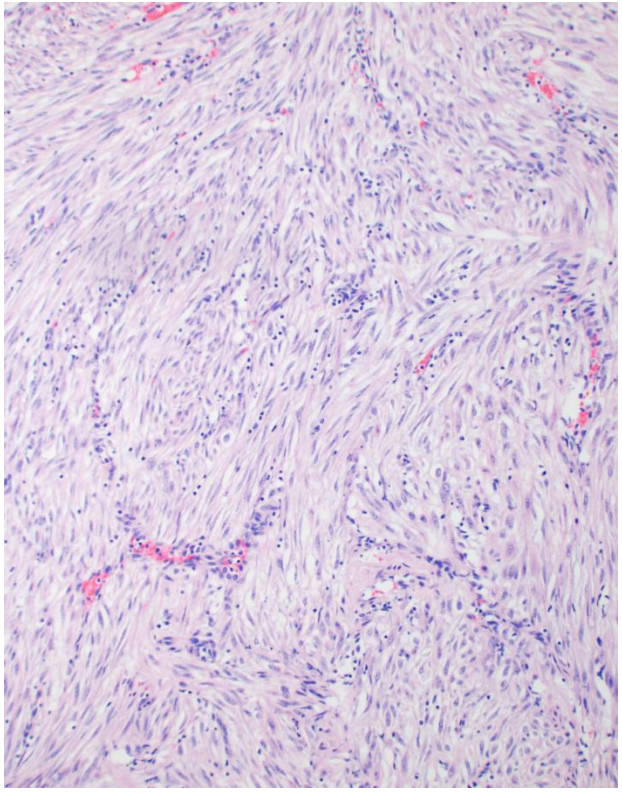

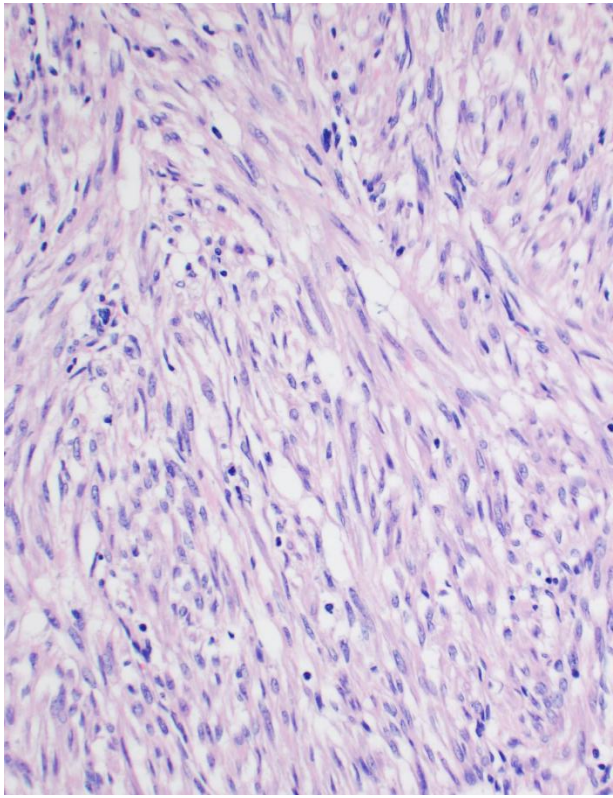

Uterine IMT

Bland spindled cells

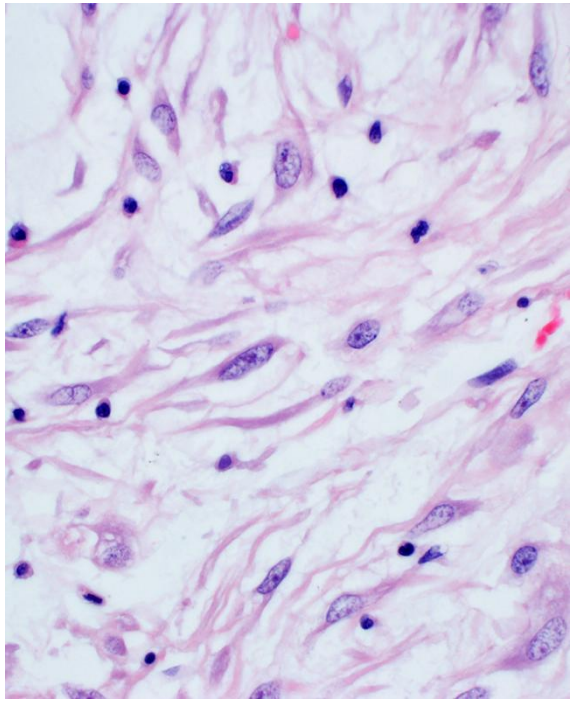

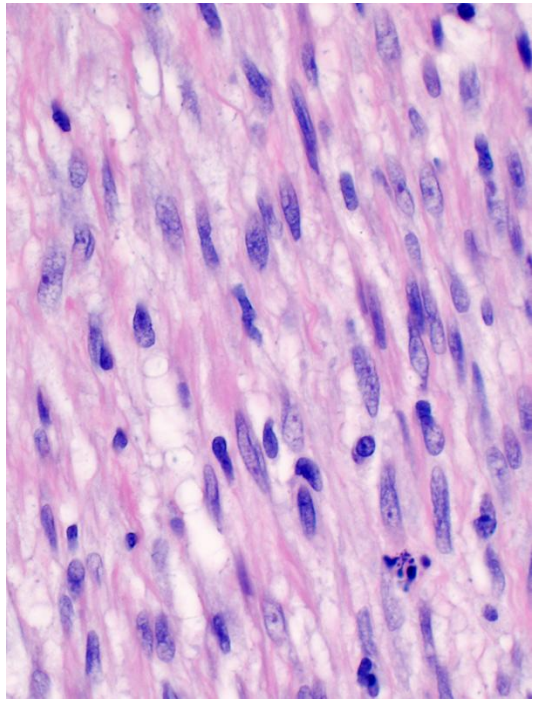

Rarely, epithelioid cells

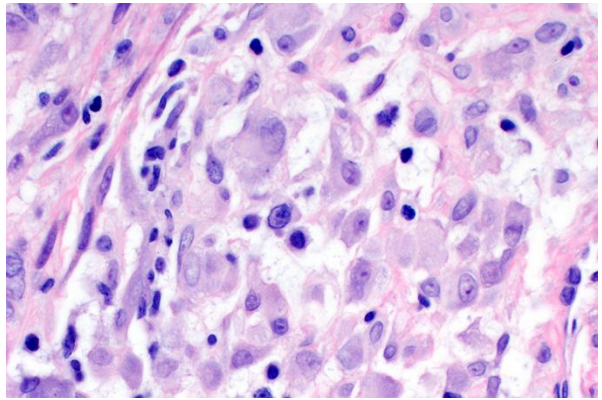

Rarely, nuclear atypia

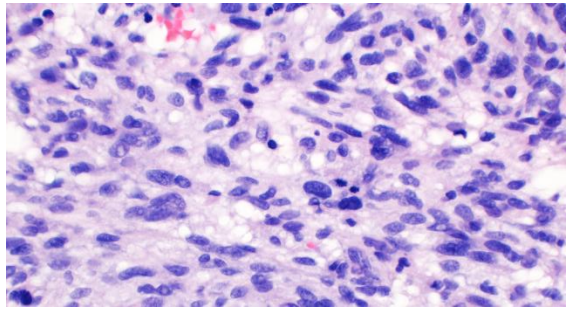

Uterine IMT: Inflammatory Infiltrate

Amount may be variable

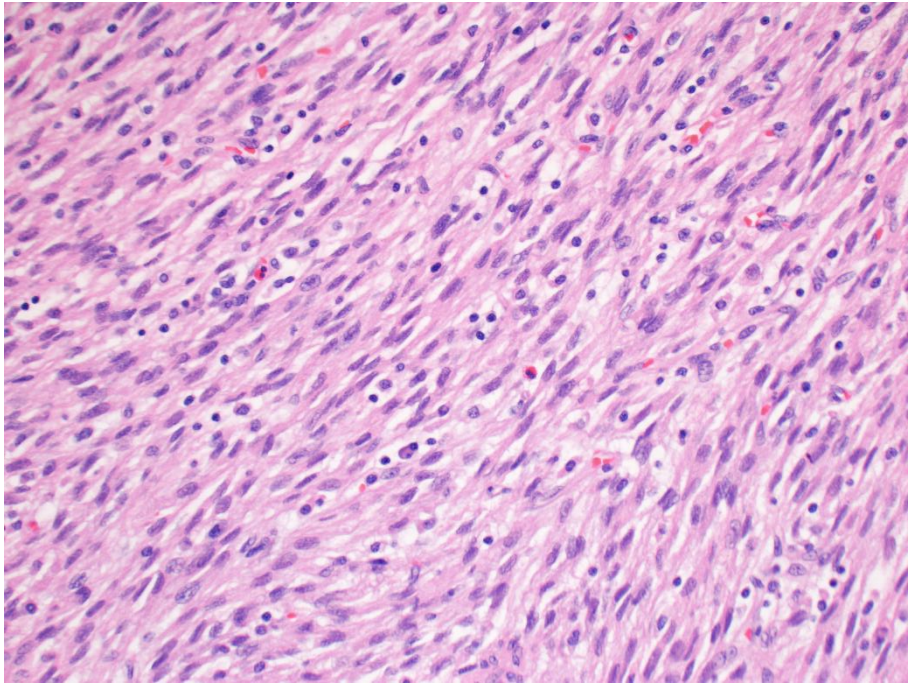

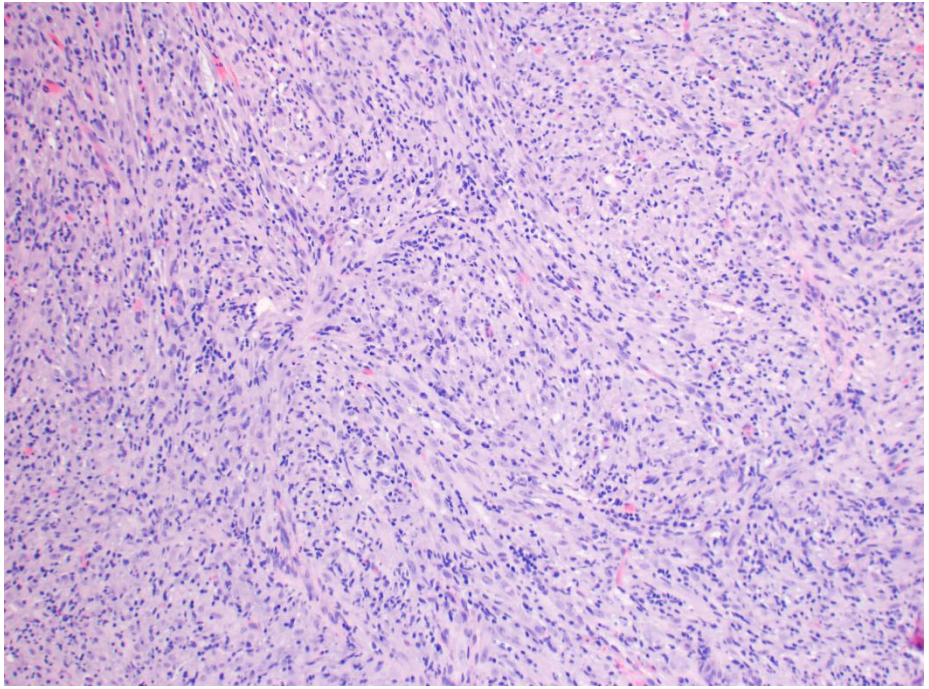

Uterine IMT: Immunohistochemistry

Myoid	▪ Variable actin, desmin, caldesmon
CD10	▪ Variable positive
ER	▪ Positive

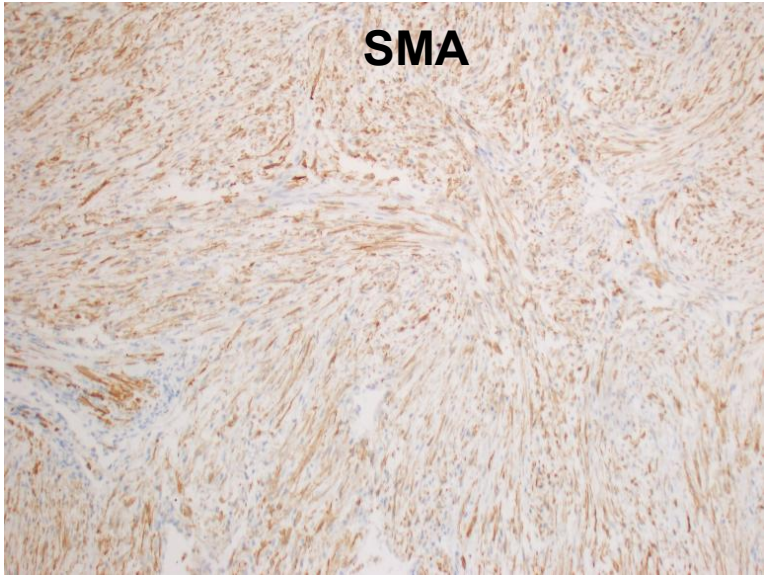

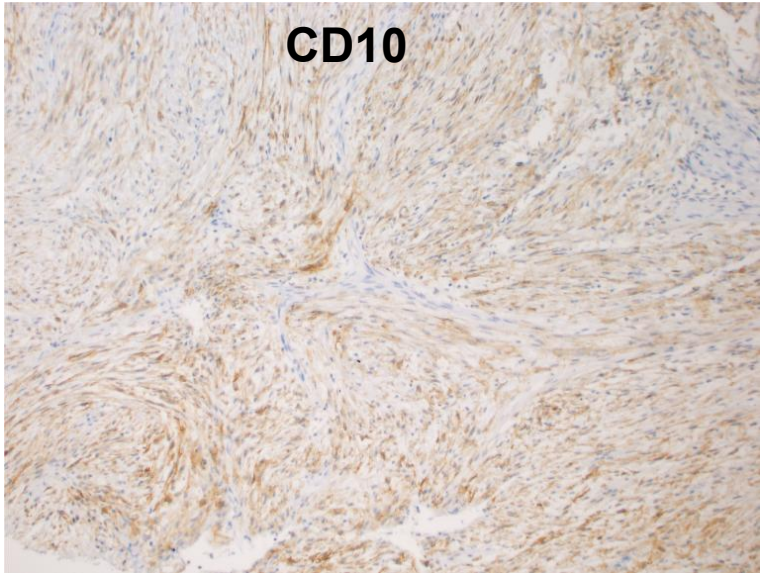

Uterine IMT: ALK Receptor Tyrosine Kinase Fusion Driven Tumor

Tests to detect *ALK* fusion:

- **FISH** break apart probe
- **RNA sequencing** for fusion
- **Immunostaining** to detect fusion protein: sensitivity & specificity is very high

	ALK Staining Pattern
Distribution	Mostly: **Diffuse**
Intensity	Mostly: **Strong**
	Fascicular pattern areas may show lesser staining than myxoid areas
Pattern	Mostly: **Granular cytoplasmic**
	+/- para-nuclear accentuation

Rabban et al, AJSP 2005; 29: 1348-1355
Mohammad et al, AJSP 2018; 42:1353-1359
Parra-Herran et al. Am. J. Surg. Pathol. 2016; 40: 285-301

Uterine IMT: ALK Immunostain

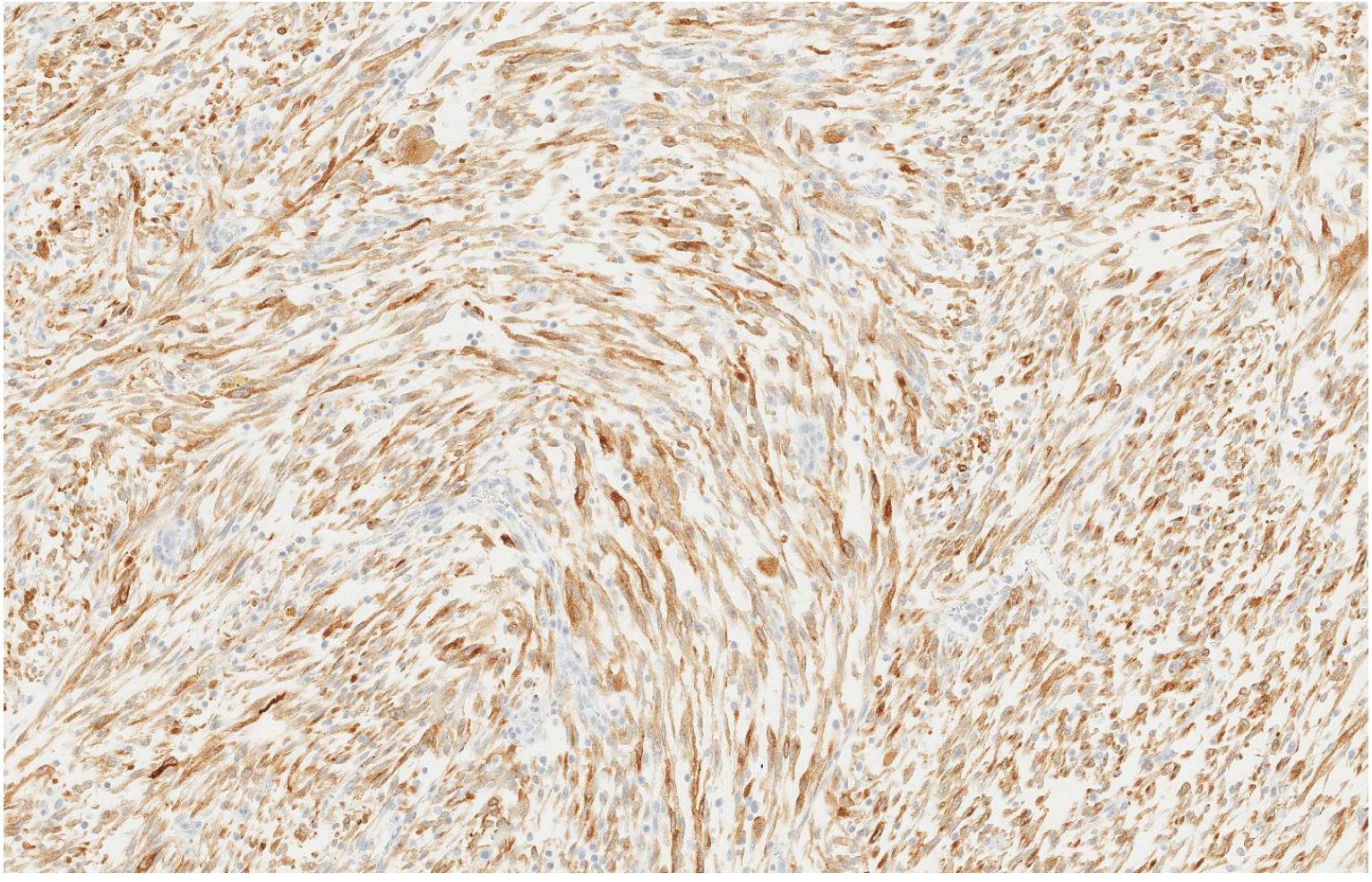

Uterine IMT: *Evolving Understanding of Pathogenesis*

- **Nearly all involve *ALK***
- **Emerging rare cases involve *ROS1***
    - **If ALK IHC is negative, but morphology is highly suspicious, consider *ROS1* IHC or molecular test**

ROS1 rearranged uterine IMT

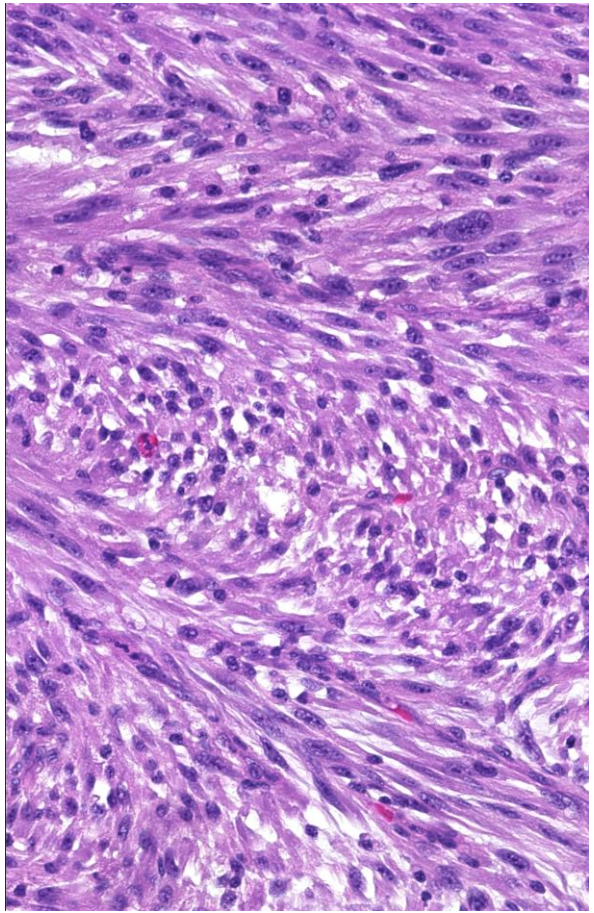

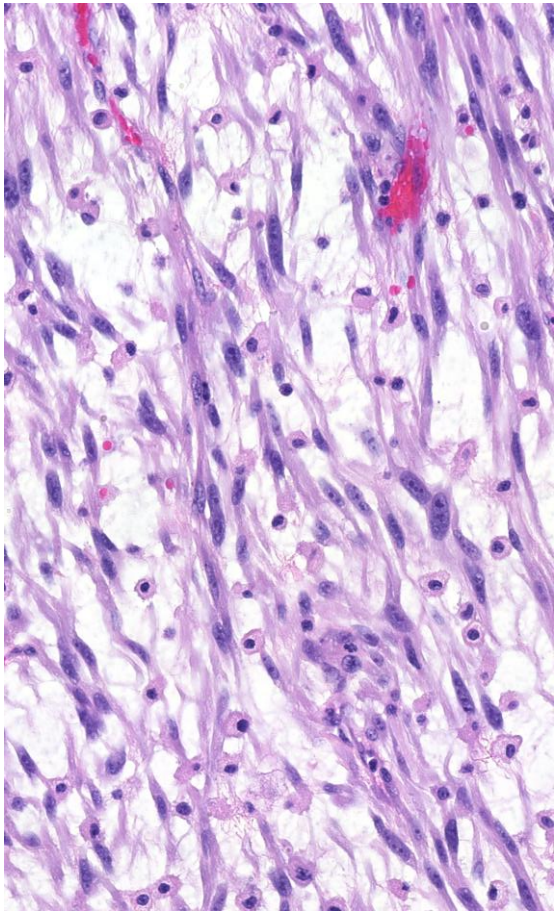

ROS1 IHC

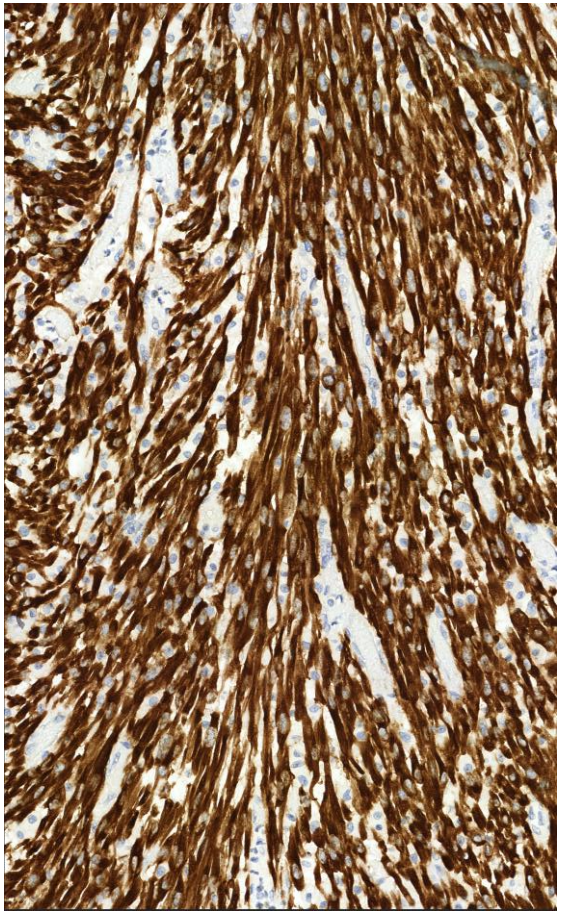

Images courtesy of Dr. Anjelica Hodgson

Uterine IMT: Prognosis

- **~10% are aggressive** (> stage I; recurrence; death)
- **Prognostic risk factors**:

Older Literature
Tumor size > 8 cm
Infiltrative border
Myxoid versus fascicular pattern
Tumor necrosis
Mitotic index
LVSI

New Risk Score System

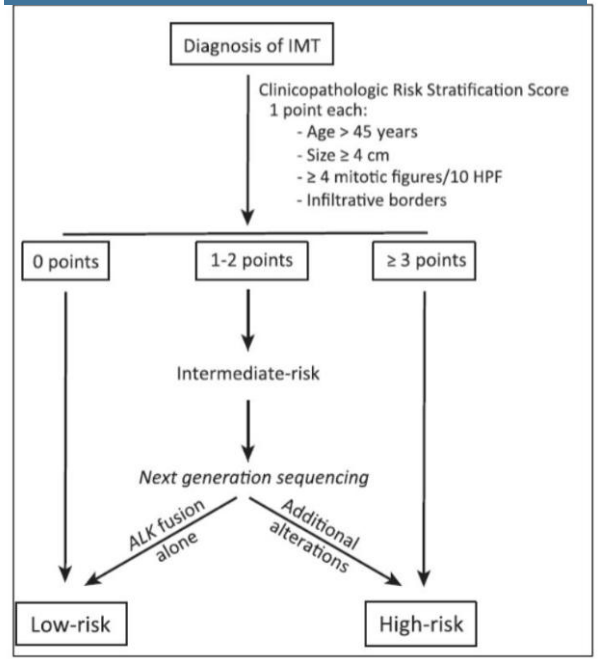

PMID: 36344483

- ***ALK* inhibitor therapy available**

Many Uterine IMT are Under-Diagnosed

Retrospective review using ALK staining of:	Under-diagnosed IMT
Leiomyoma	Up to 0.3%
Myxoid leiomyosarcoma	Up to 13%
STUMP	Up to 9 %

- IMTs at time of Cesarean section / peri-partum mimic leiomyoma

Haimes et al. Am. J. Surg. Pathol. 2017; 41: 773-780
Pickett et al. Am. J. Surg. Pathol. 2017; 41: 1433-1442
Parra-Herran et al. Am. J. Surg. Pathol. 2015; 39: 157-168
Parra-Herran et al. Am. J. Surg. Pathol. 2016; 40: 285-301
Devereaux et al. Am. J. Surg. Pathol. 2019; 43: 64-74
Subbiah et al. J. Hem. Oncol. 2015; 8: 66
Ptakova et al. Virch. Archiv. 2018; 473: 588-590

Triggers to Order ALK IHC to Exclude Uterine IMT

My personal approach is any 1 feature is enough

Clinical setting	▪ **Peri-partum "fibroid"**
	▪ **Extra-uterine "fibroid"**
	▪ **Recurrent "STUMP"**
Macroscopic findings	▪ **Gelatinous texture**
Microscopic findings	▪ **Any myxoid features**
	▪ **Any inflammatory features**
Preliminary impression	▪ **Myxoid leiomyoma**
	▪ **Myxoid leiomyosarcoma**
	▪ **Myxoid endometrial stromal sarcoma**
	▪ **STUMP** (even if not myxoid or inflammatory cells)

Uterine Leiomyoma

Clinically relevant "low grade" deceptive mimics

Leiomyoma Morphology	Mimics with Malignant Potential
	Low grade endometrial stromal sarcoma
Spindle cell	*KAT6A/B::KANSL1* fusion tumor *NTRK* fusion tumor Inflammatory myofibroblastic tumor
Myxoid	Inflammatory myofibroblastic tumor
Epithelioid	**Perivascular epithelioid cell tumor**





Epithelioid Leiomyoma

- **Rare**
- **Benign**

- **Incidental microscopic variant:**

  Plexiform tumorlet

- **Diagnostic relevance:**

  May mimic PEComa
  similar morphology and smooth muscle IHC positive

Epithelioid Leiomyoma

Eosinophilic cytoplasm

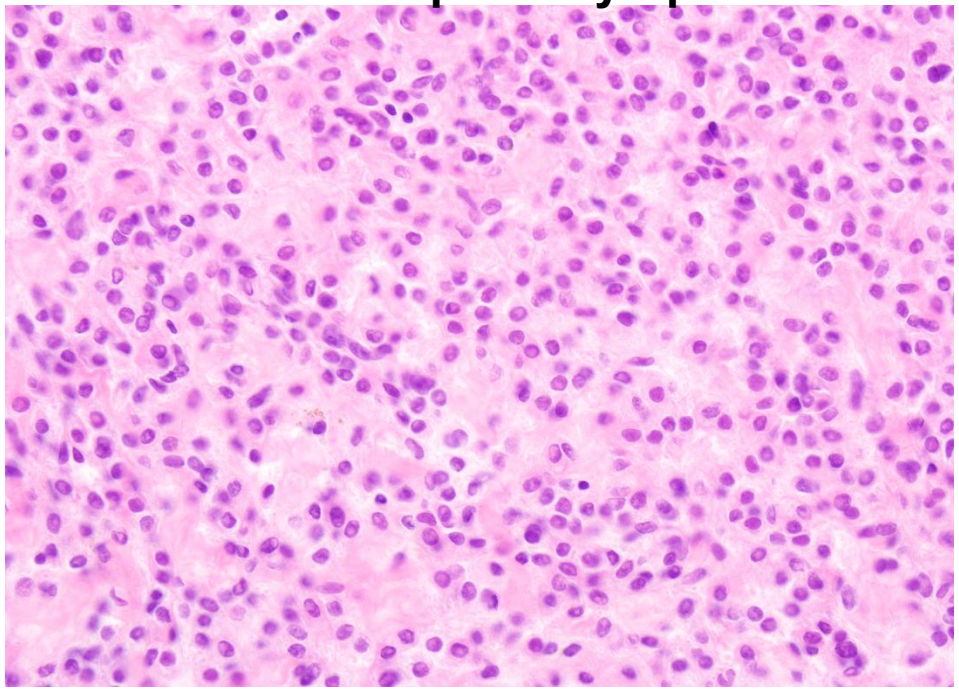

Clear cytoplasm

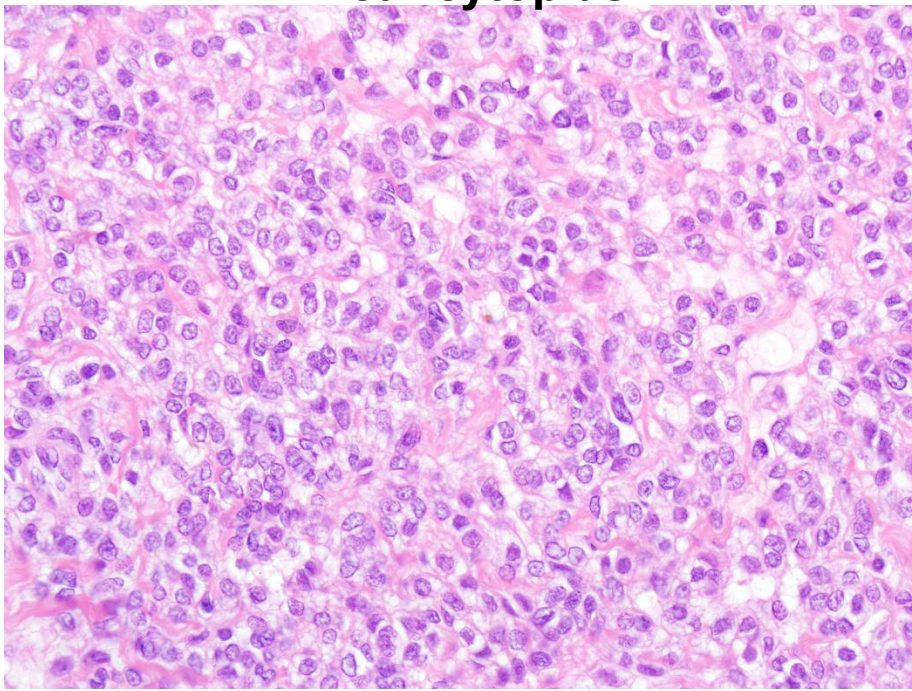

Epithelioid Leiomyoma

Plexiform Tumorlet

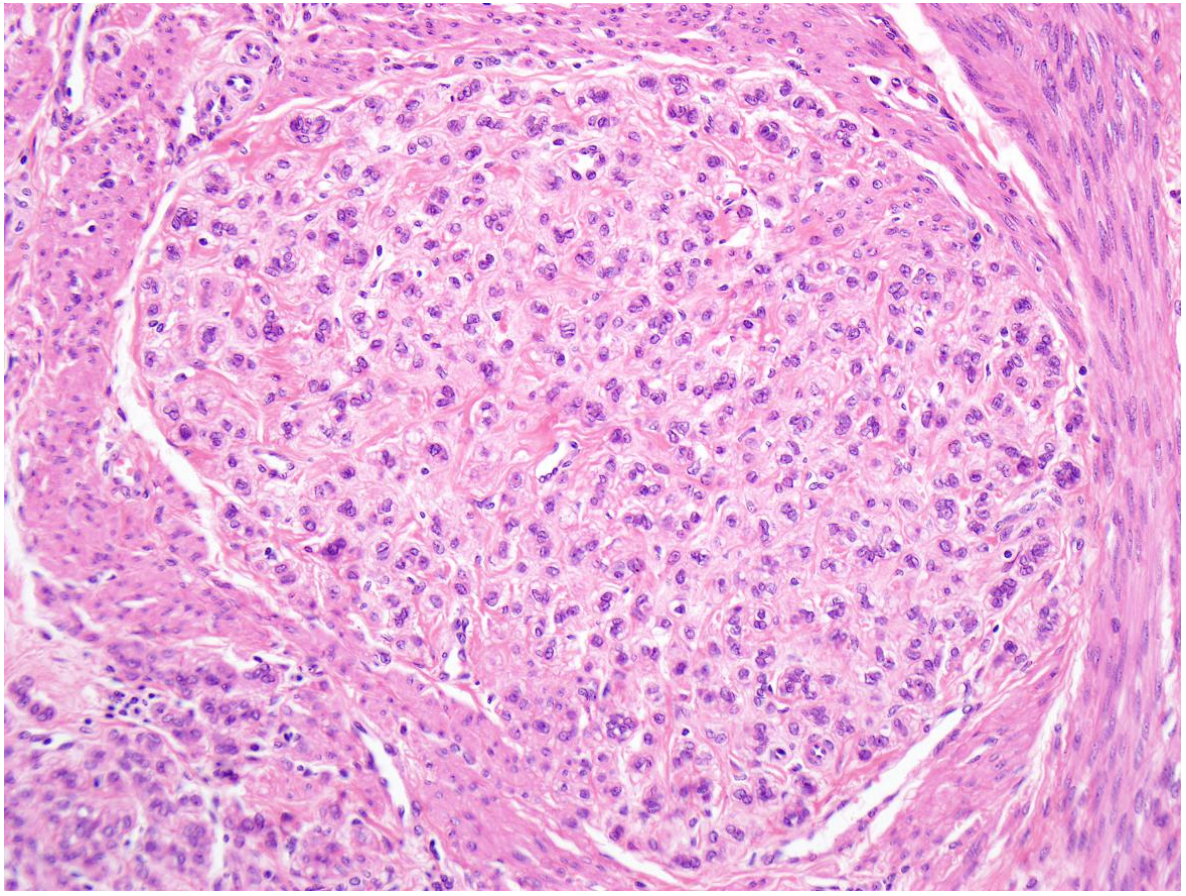

Epithelioid Leiomyoma

A diagnosis of exclusion:

Spectrum of Morphology (bland to malignant)	**PEComa**
Malignant Morphology	**Endometrial stromal tumor**
	Carcinoma: Endometrioid / clear cell carcinoma
	Squamous cell carcinoma (cervix)
	Trophoblastic tumor
	Melanoma

PEComa: Perivascular Epithelioid Cell Tumor

Clinical reasons to distinguish from epithelioid smooth muscle tumors

Prognostic risk	▪ **~30% recur; ~20% fatal**
Tumor syndrome risk	▪ **Other tumors of PEComa family (pLAM)**
	▪ **~10 % tuberous sclerosis complex**
Targeted therapy	▪ **Advanced stage / metastatic disease** mTOR inhibitor if *TSC* mutation is present

PEComa: Perivascular Epithelioid Cell Tumor

- **Rare mesenchymal tumor of uncertain cell origin**
  - -retroperitoneum, soft tissue, uterus, skin, bowel, bladder
- **Dual melanocytic and myoid immunophenotype**
- **Molecular classification**
  - **About half have *TSC1 or TSC2* mutation**
  - **Less than half have a translocation** (*TFE3, RAD51*, others)
  - **Minority are unknown alteration**

Uterine PEComa: Morphology

- Size range <1 cm to ~20 cm
- 2 morphologic patterns:

Epithelioid Pattern	
Architecture	Sheets, nests, “alveolar”
Cell shape	Epithelioid
Cytoplasm	Clear, granular eosinophilic

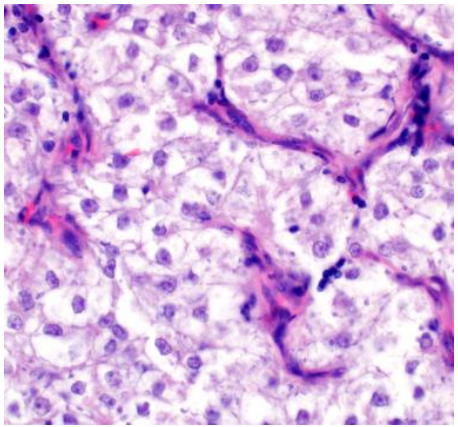

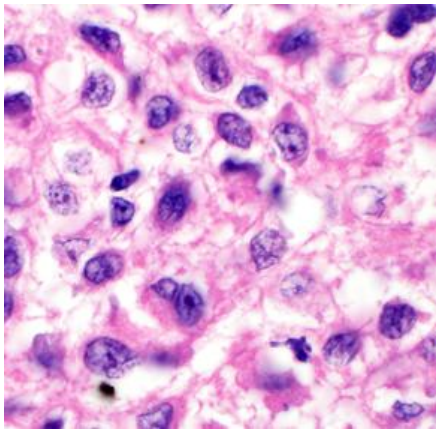

Spindle Cell Pattern	
Architecture	Fascicles, sheets
Cell shape	Spindled
Cytoplasm	Granular, eosinophilic, clear

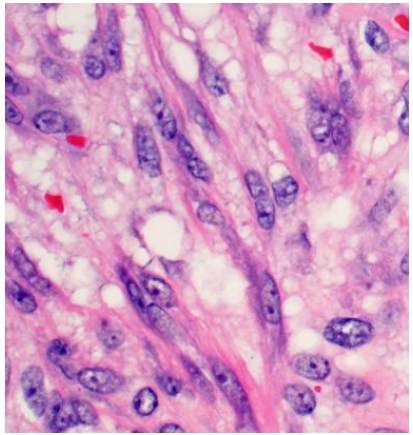

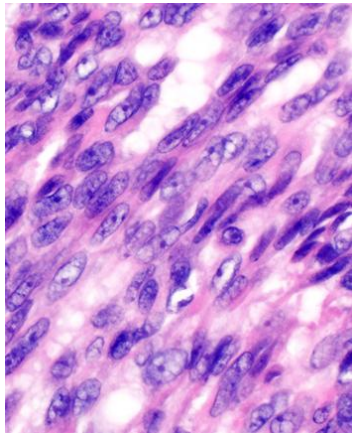

Uterine PEComa

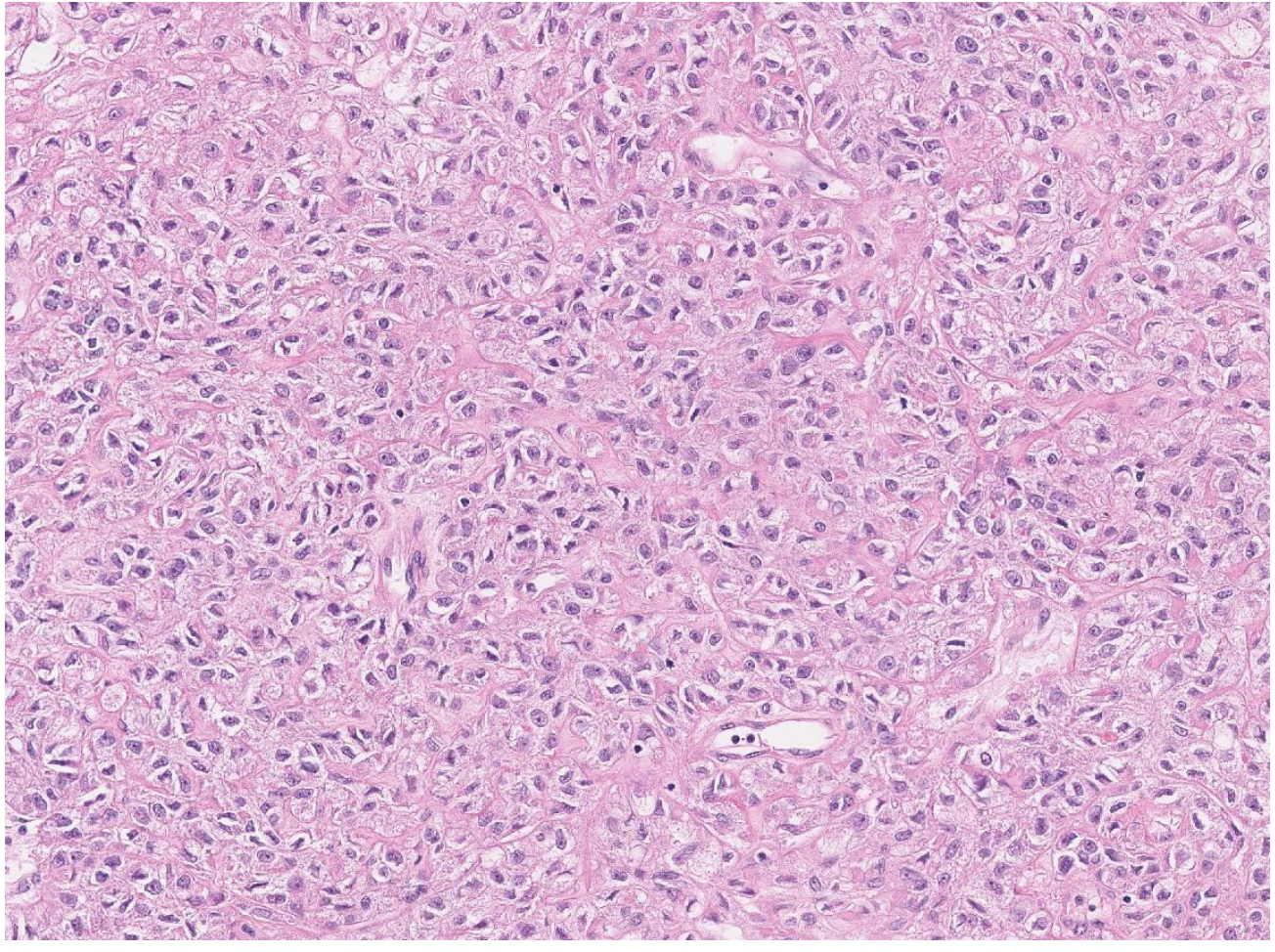

Uterine PEComa

Clear, foamy cytoplasm

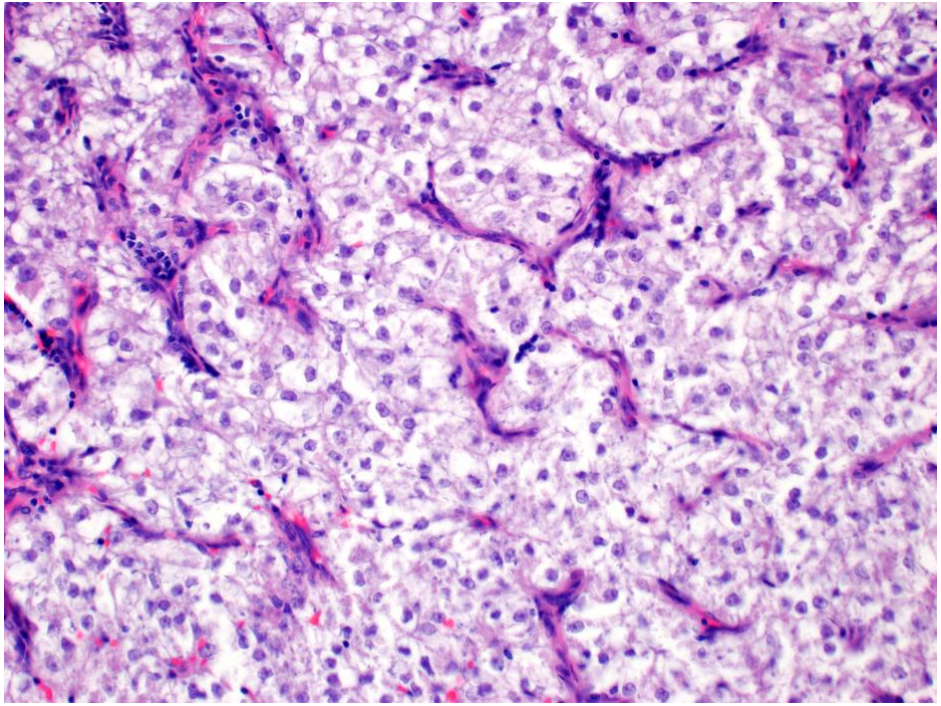

Granular cytoplasm

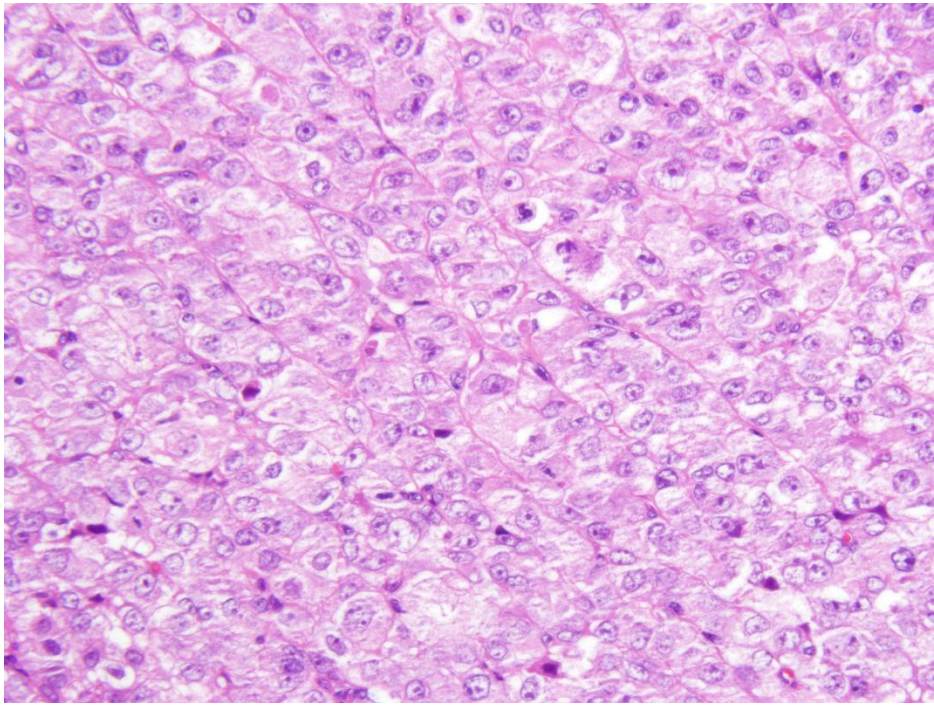

Uterine PEComa

Epithelioid / rhabdoid cells

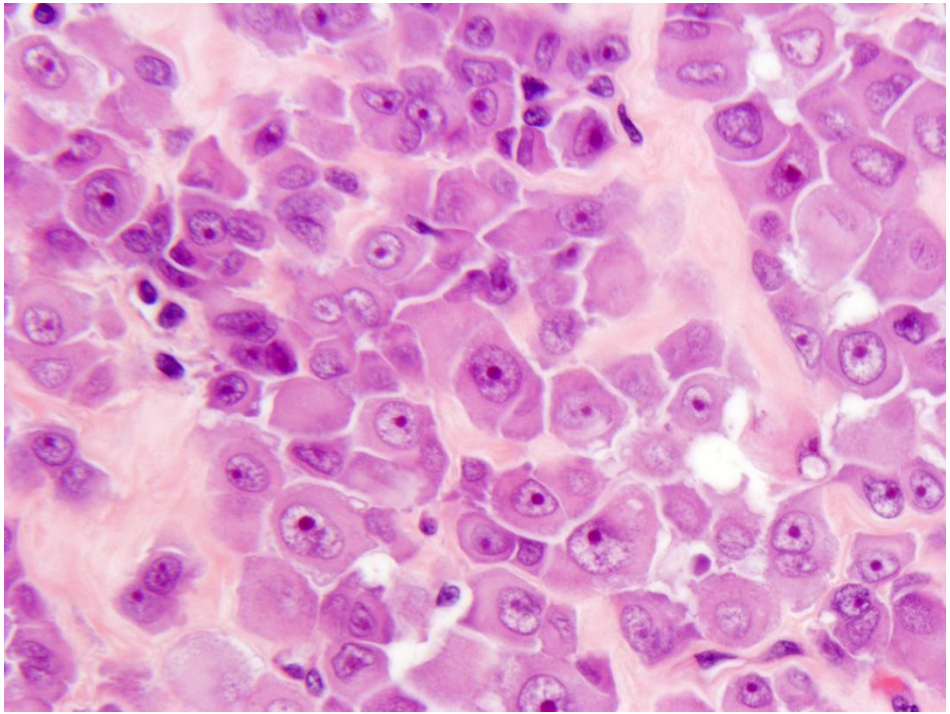

Spindled cells

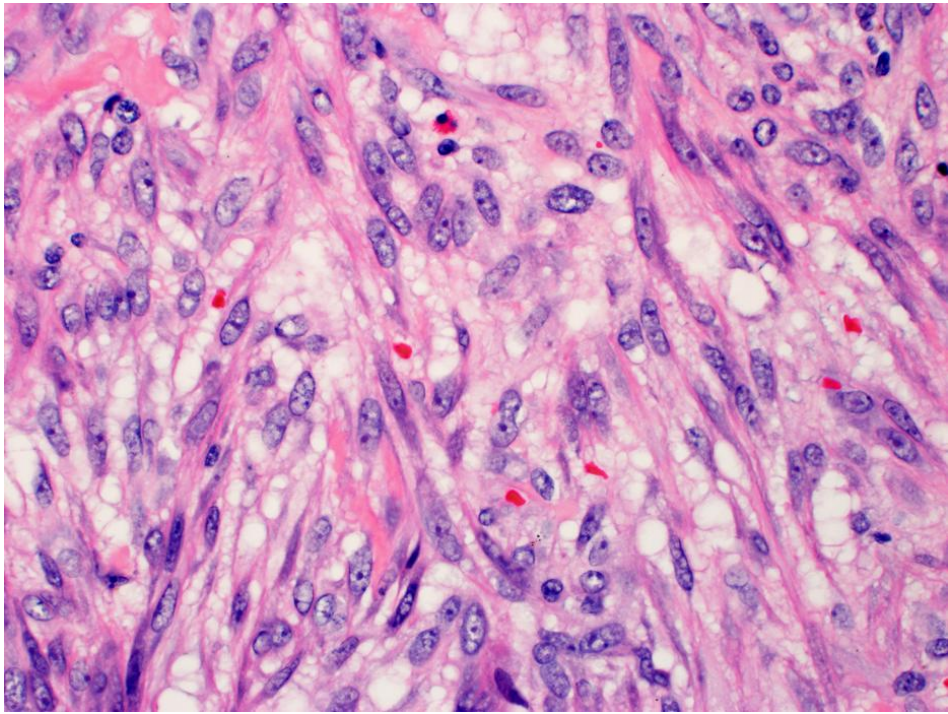

Uterine PEComa

Hyaline stroma / “sclerosis”

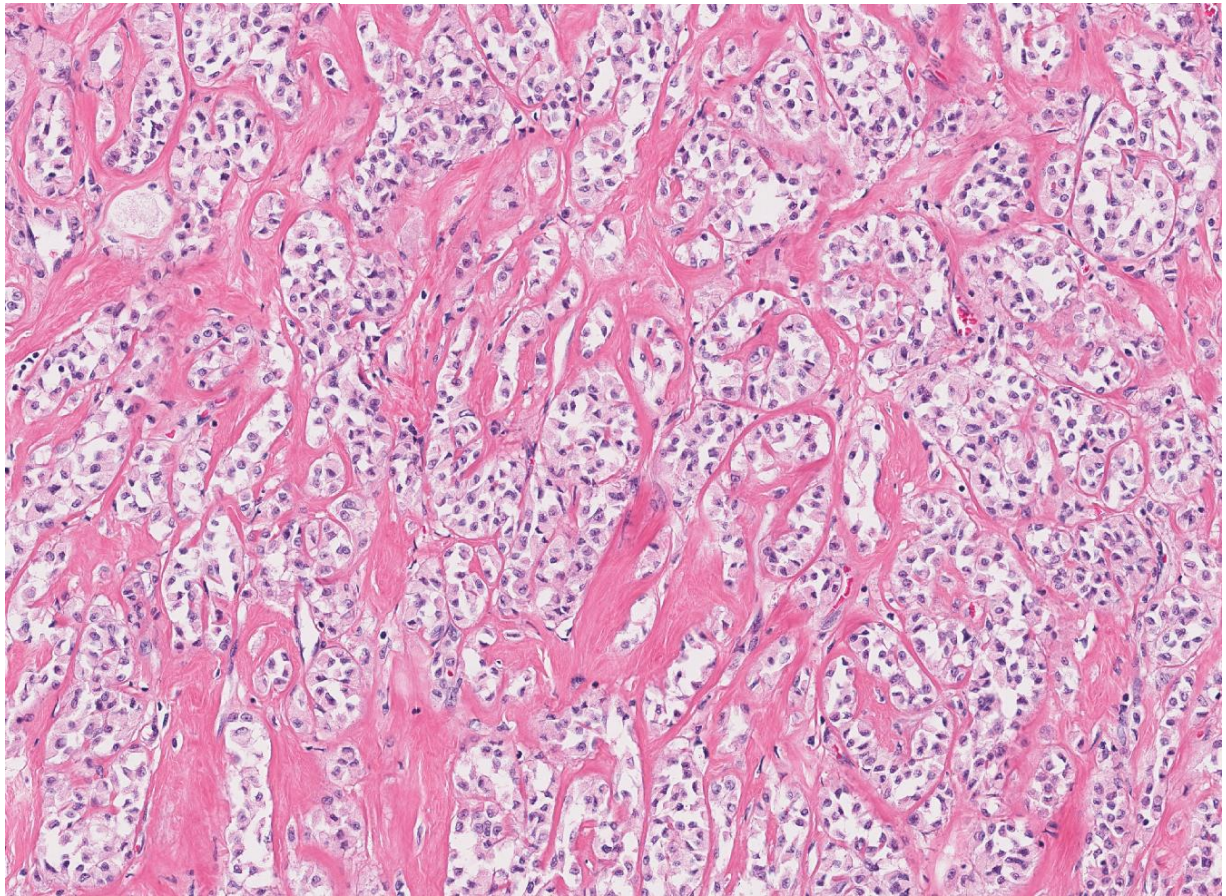

Uterine PEComa

Dual Immunophenotype

Myoid Markers
Smooth muscle actin
Desmin
Caldesmon

+

Melanocytic Markers*
Cathepsin K
HMB34
Melan A
MiTF

***advise requiring at least 2 positive**

**individual markers not specific for PEComa*

Uterine PEComa

HMB45 often patchy, weak

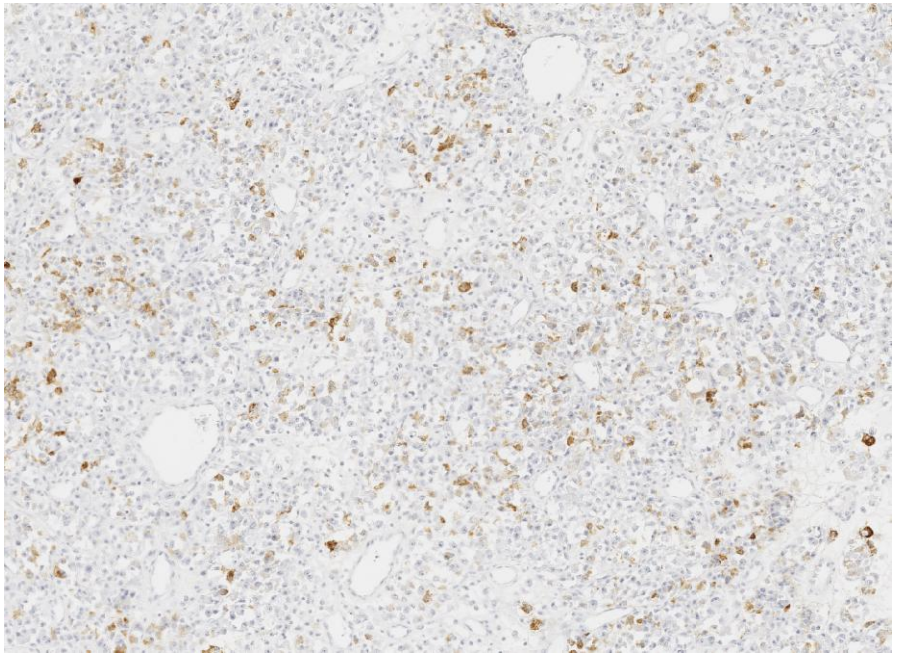

Cathepsin K

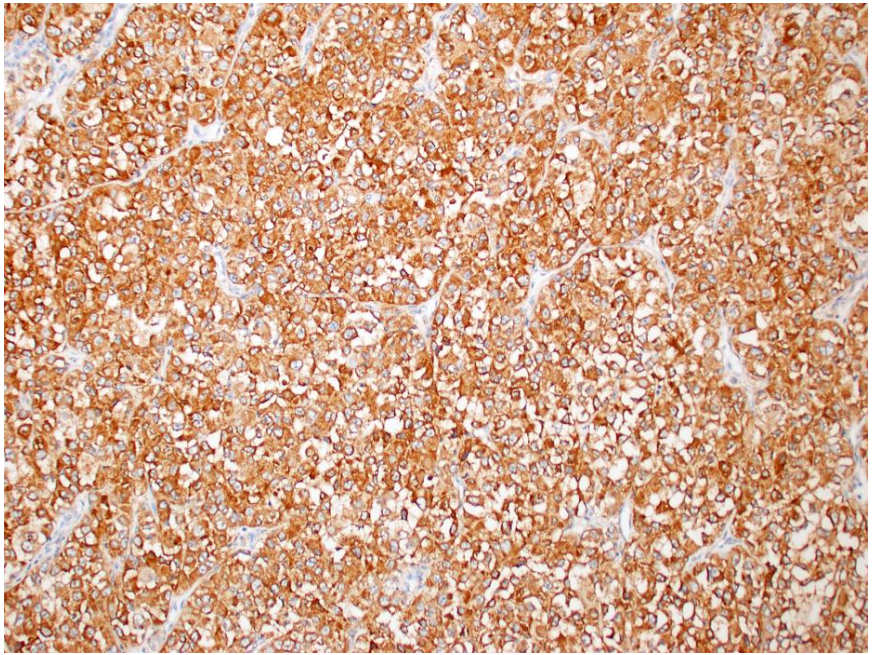

Uterine PEComa

Melan A

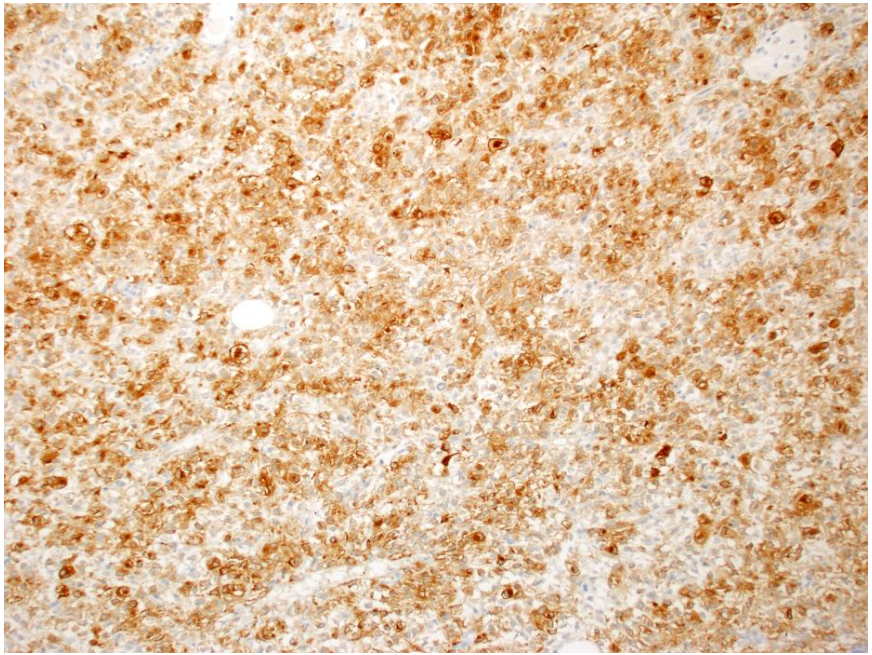

MiTF

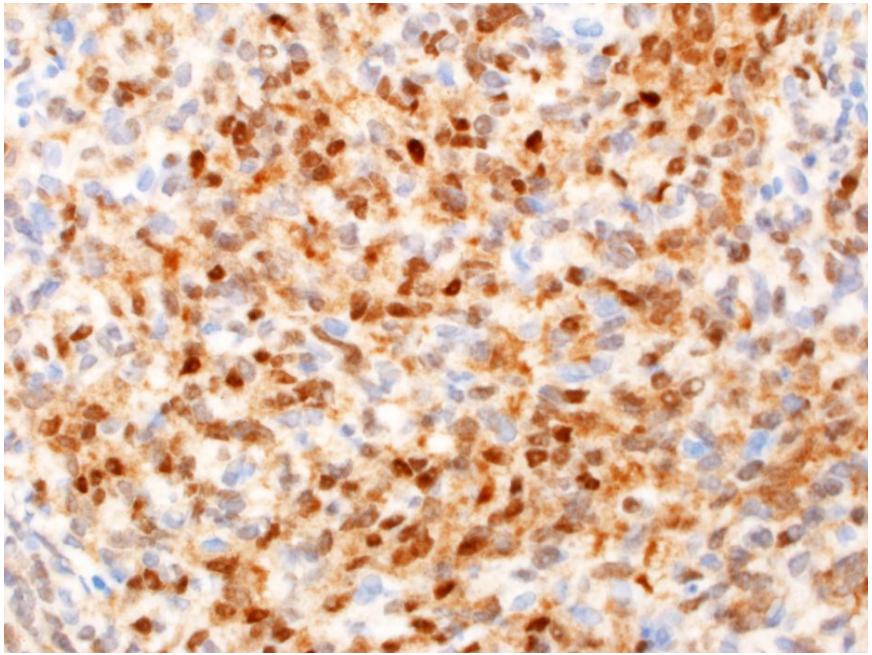

Uterine PEComa: Prognostic Criteria

Limited Data

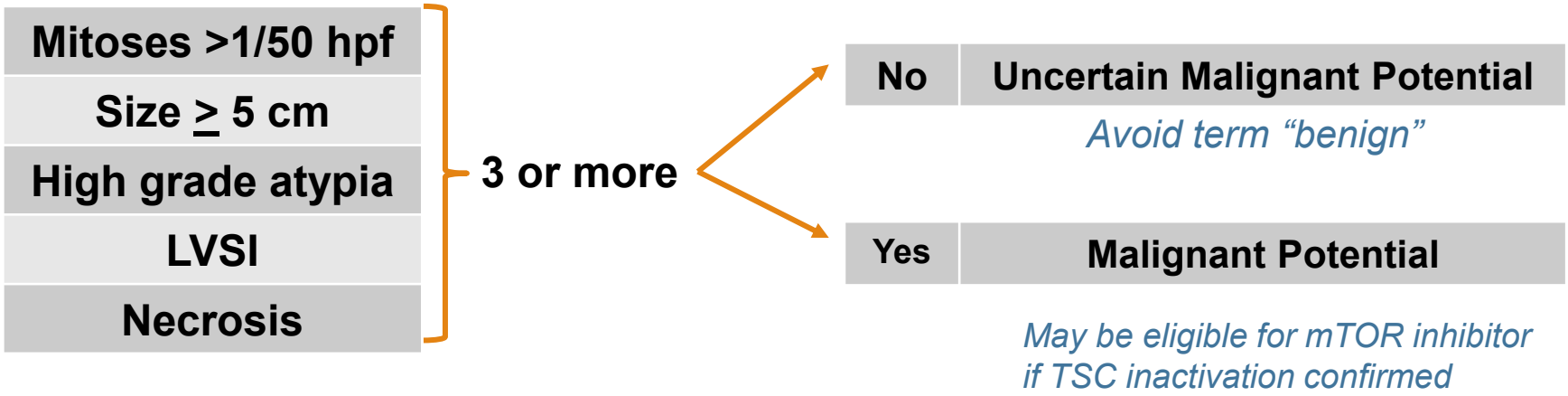

Regardless of malignant potential,
clinical evaluation for tuberous sclerosis complex is advised

Bennett, Am J Surg Pathol 2018;42:1370–1383

Gynecologic Lymphangioleiomyomatosis (LAM)

Myometrial LAM

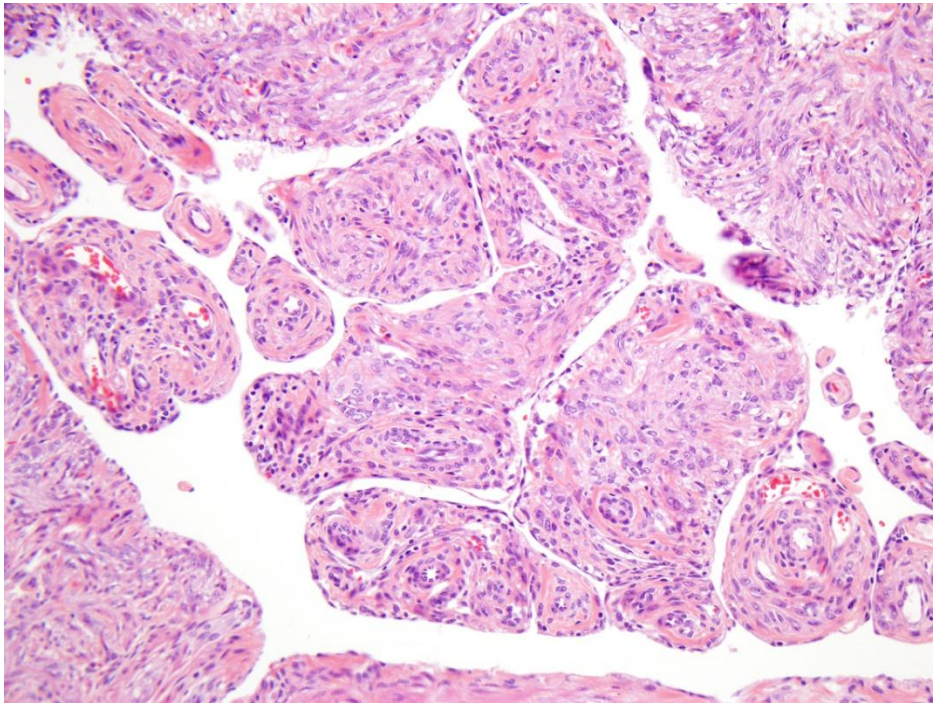

Pelvic lymph node LAM

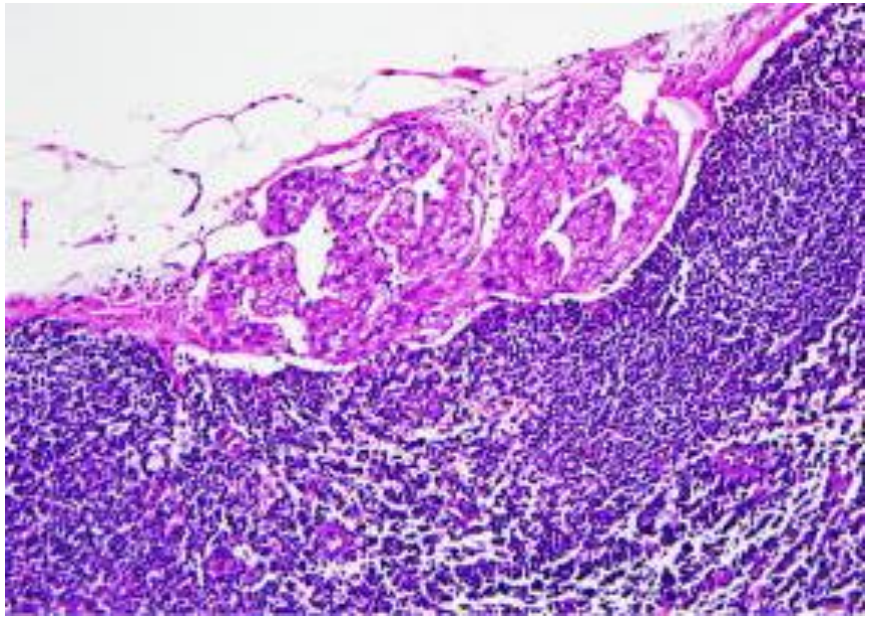

Rabban. Am J Surg Pathol 2015;39:1015–1025
Schoolmeester. Am J Surg Pathol. 2015; 39:1404–1410

Uterine Leiomyoma

Clinically relevant “low grade” deceptive mimics

Leiomyoma Morphology	Mimics with Malignant Potential
Spindle cell	*KAT6A/B::KANSL1* fusion tumor *NTRK* fusion tumor Inflammatory myofibroblastic tumor
Myxoid	Inflammatory myofibroblastic tumor
Epithelioid	Perivascular epithelioid cell tumor





