The British Association of Gynaecological Pathologists

bsccp The British Society for Colposcopy and Cervical Pathology

Cervical Histopathology Course – BAGP/ BSCCP



Deirdre Lyons
MB MRCOG MSc Digital Healthcare
Lead Clinician for Colposcopy and CSPL Imperial College healthcare NHS Trust
London SQAS Professional Clinical Advisor
President BSCCP

The British Association of Gynaecological Pathologists

bsccp The British Society for Colposcopy and Cervical Pathology

Basic Cervical Histopathology Course

- Colposcopy for Colposcopists and Pathologists
- Deirdre Lyons
- BSCCP
- 26/02/2025

The British Association of Gynaecological Pathologists

bsccp The British Society for Colposcopy and Cervical Pathology

Speaker disclosures

Choose one

- ❑ I have the following to disclose

- ❑ Invited speaker by Procare
- ❑ Invited speaker by MSD

Colposcopy for Colposcopists and Cervical Pathologists

- Colposcopy – Greek - literally means inspection of the vagina. However, it is also commonly associated with the inspection of the cervix.

- First introduced early in the last century (1925) by Hinselman and includes visualisation of the lower genital tract before and after applying an acetic acid solution under magnification with an appropriate light source.

- Widespread adoption of this technique is mainly attributed to its advantages which include low cost, safety, short duration, ease and ability to combine diagnosis and treatment in one visit.

Colposcopy for Colposcopists and Cervical Pathologists

- Colposcopy is a tool for triaging screen positive women regardless of method used for cervical cancer screening

- A number of KPI's in WHO toolkit –
- '' The applicability and use of colposcopy for multiple purposes e.g. as triage to determine if precancerous lesion treatment is required, as further evaluation for large lesions or suspected cancer, and/or biopsy guidance, etc.''

Dorji, N. et al. Evaluation of the diagnostic performance of colposcopy in the diagnosis of histologic cervical intraepithelial neoplasia 2+ (CIN2+). *BMC Cancer (2022) 22:930.* https://doi.org/10.1186/s12885-022-10030-7

Improving data for decision-making: a toolkit for cervical cancer prevention and control programmes. © World Health Organization 2018. ISBN 978-92-4-151425-5

Hans Hinselmann : the inventor of the colposcope



- 1884-1959

Son of a brewer
PhD- malignant pigmented tumors of the vulva

1921 Prof University of Bonn
1925 General Hospital Altona, Hamburg
Wrote seminal paper on Colposcopy

1930-46 Frauenklinik Altona in Hamburg

Active supporter National Socialism
Experiments at Auschwitz
Prison 1946-49 for forced sterilisations

1956 Member German Society O&G

tiert nach Lexer)). Dazu kommt noch, daß die meist vorhandenen Hautabschürfungen in der Verletzungsgegend, die eine Infektion allenfalls begünstigen, inzwischen zur Abheilung gebracht werden können. Deshalb erscheint das Abwarten in vielen Fällen doch vorteilhafter zu sein, als die sofortige Operation, insbesondere auch deshalb, weil es außer einem geringgradigen Zeitverlust keinerlei Nachteile bringt.

Interessante Beobachtungen aus dem Gebiet der Sehnenregeneration bzw. über das Verhalten von operierten Sehnen wären den pathologischen Anatomen sicher möglich. Da aber die alten Sehnenverletzungen kaum im Zusammenhang mit der Todesursache stehen, entgehen sie meist der Aufmerksamkeit des Sezierenden, obwohl für Chirurgen und Orthopäden gerade solche Befunde auch sehr wissenswert wären. Vielleicht ist es gerade jetzt auf Grund der vielen Muskel- und Sehnenverletzungen des Krieges möglich, hier neue Beobachtungen zu machen.

Verwendete Literatur.

Albrecht: Arch. f. Orthopäd. und Unfallchirurgie 23. Bd., H. 13. 1924. — Bier: D.m.W. 1917 18. — Braus: Anatomie des Menschen, I. Bd., 1922. — Handb. d. prakt. Chir. VI. Bd., 1923. — Maydl: D. Zschr. f. Chir. 1888. — Lexer: Allgem. Chirurgie 1922. — Küttner: D.m.W. 1922. — Saar: Die Sportverletzungen. —, Salomon: Arch. f. Chir. 1921. — Schwarz: D. Zschr. f. Chir. Bd. 173. — Wehner: D. Zschr. f. Chir. Bd. 177.

Aus der Frauenklinik der Universität Bonn.
(Direktor: Geh.-Rat von Franqué.)

Verbesserung der Inspektionsmöglichkeiten von Vulva, Vagina und Portio.

Von Prof. Dr. Hans Hinselmann, Oberarzt der Klinik *).

Ausgehend von den Bedürfnissen der Frühdiagnose und der Aetiologie des Portiokarzinoms war ich bestrebt, die Besichtigung der Portio zu verbessern. Von vorhandenen Mitteln bot sich mir zunächst die von Eickensche Stirn-

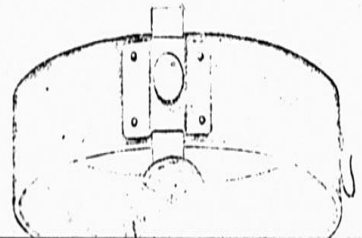

Zu diesem Zweck habe ich die Leitzsche binokulare Präparierlupe mit einer Beleuchtung versehen lassen. Auf diese Weise kann man bei großem Objektabstand und intensiver Beleuchtung Scheide und Portio ableuchten und Vergrößerungen von 3,5 an erreichen. Je nach Länge der Scheide und Zugänglichkeit der Portio kann man sie in situ mit Vergrößerungen bis 10,5 bis 30 beobachten. Mit dieser Einrichtung habe ich seit Monaten in zunehmendem Maße gerne gearbeitet. Sie gestattet uns, alle Erkrankungen der Vulva, des Vestibulums, der Scheide und der Portio in einer Weise zu studieren, wie es bisher nicht möglich war.

Die Optik habe ich auf einem Stativ anbringen lassen, das Bewegungen in allen Richtungen gestattet und zu feinster Einstellung eine Mikrometerschraube trägt.

Man untersucht im allgemeinen ohne Zedernöl, vereinzelt empfiehlt sich außerdem die Aufhellung mit Zedernöl.

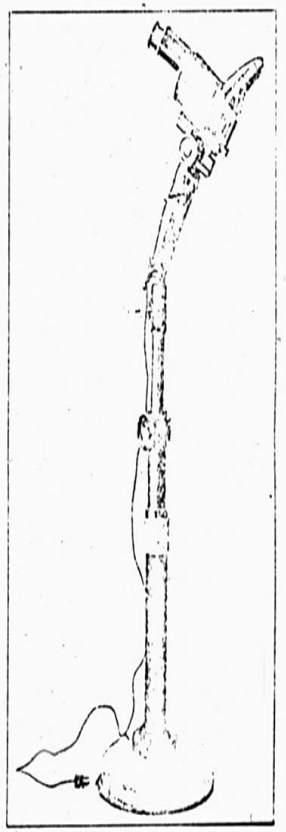

Fig. 2. Kolposkop.

Die Leistungsfähigkeit dieser Methode besteht darin, daß sie uns Veränderungen aller Bestandteile der Haut, der Epidermis, des Bindegewebes und der Gefäße erkennen läßt, die

Hans Hinselmann

Key figure in medical history,

Deserves credit for
the untold number of lives
he has saved

But complicit in the
unbearable suffering inflicted on
Jewish women in Auschwitz's
Block 10

Thus deserves a qualified entry
in the history books

The British Association of Gynaecological Pathologists

bsccp The British Society for Colposcopy and Cervical Pathology

Colposcopy

Colposcopy- a procedure to take a closer look at a cervix and vagina using a special instrument called colposcope. This is used to check for pre-cancerous cells or abnormal areas. The instrument can magnify the area between 10 and 40 times and takes photographs of the cervix

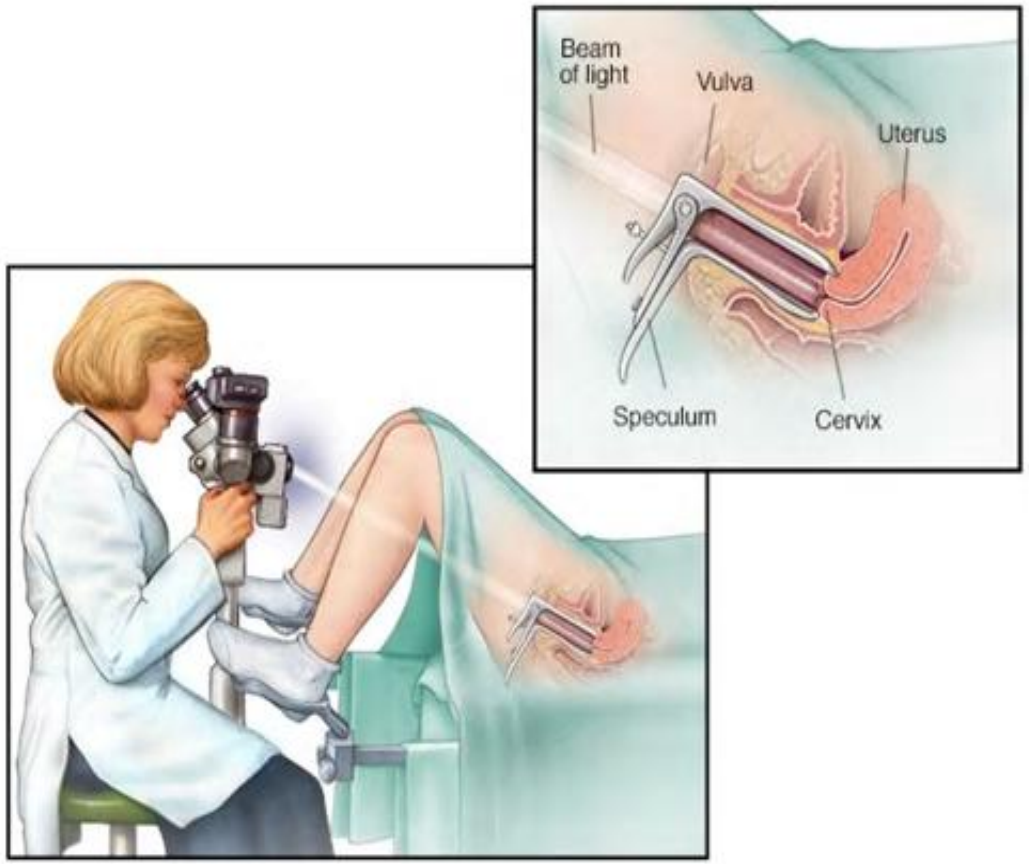

The British Association of Gynaecological Pathologists

bsccp The British Society for Colposcopy and Cervical Pathology

Colposcopy for Colposcopists and Cervical Pathologists



251,251 referrals to colposcopy in 2023-24

(All ages, all referral reasons)

An increase of 1.8% from the previous year, when 246,762 were referred.

The British Association of Gynaecological Pathologists

bsccp The British Society for Colposcopy and Cervical Pathology

Colposcopy for Colposcopists and Cervical Pathologists

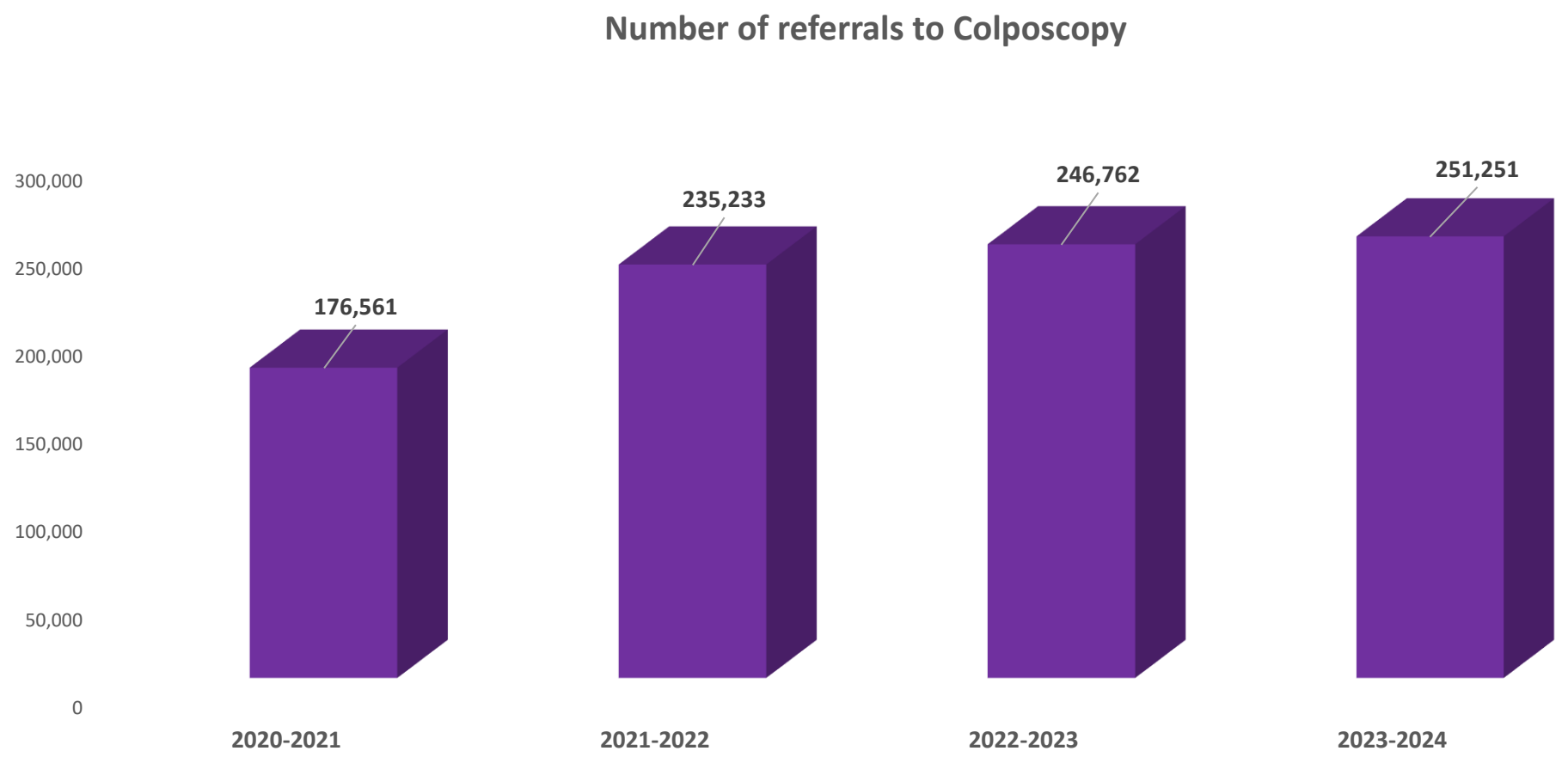

The British Association of Gynaecological Pathologists

bsccp The British Society for Colposcopy and Cervical Pathology

Colposcopy for Colposcopists and Cervical Pathologists

Table 20: NHS Cervical Screening Programme: Individuals referred to colposcopy: referral indication of first offered appointment, by NHS region[1], all ages

England, 2023-24

numbers/*percentages*

		NHS region[1]						
Referral indication (screening result, clinical, or other)	England	North East and Yorkshire	North West	Midlands	East of England	London	South East	South West
Total number of referrals	**251,251**	**38,138**	**33,658**	**39,380**	**26,002**	**54,358**	**27,940**	**31,775**
Screening sample - Total[2]	*63.3*	*55.8*	*50.7*	*59.2*	*55.9*	*70.7*	*82.7*	*67.5*
Inadequate[3]	*0.7*	*1.1*	*0.9*	*0.4*	*0.8*	*0.8*	*0.2*	*0.9*
Borderline changes	*18.7*	*18.0*	*13.8*	*23.0*	*16.4*	*17.1*	*23.9*	*19.5*
Low-grade dyskaryosis	*32.9*	*25.8*	*26.9*	*25.9*	*26.6*	*43.1*	*43.8*	*34.8*
High-grade dyskaryosis (moderate)	*6.5*	*7.3*	*4.4*	*5.1*	*5.9*	*6.2*	*10.0*	*7.6*
High-grade dyskaryosis (severe)	*3.9*	*2.8*	*4.3*	*4.3*	*5.5*	*3.1*	*4.2*	*4.1*
High-grade dyskaryosis /?invasive carcinoma	*0.2*	*0.2*	*0.1*	*0.2*	*0.1*	*0.1*	*0.3*	*0.2*
?Glandular neoplasia (endocervical)	*0.3*	*0.5*	*0.3*	*0.3*	*0.4*	*0.3*	*0.3*	*0.3*
Clinical indication - urgent	*6.5*	*7.7*	*6.6*	*7.6*	*4.4*	*6.3*	*2.5*	*9.3*
Clinical indication - non urgent	*12.5*	*11.6*	*16.4*	*7.7*	*9.8*	*18.8*	*6.4*	*12.6*
Other[4]	*17.6*	*24.9*	*26.3*	*25.5*	*30.0*	*4.3*	*8.4*	*10.6*

https://view.officeapps.live.com/op/view.aspx.files.digital.nhs.uk.cervical-screening-programme-eng-2023-24

The British Association of Gynaecological Pathologists

bsccp The British Society for Colposcopy and Cervical Pathology

Colposcopy for Colposcopists and Cervical Pathologists

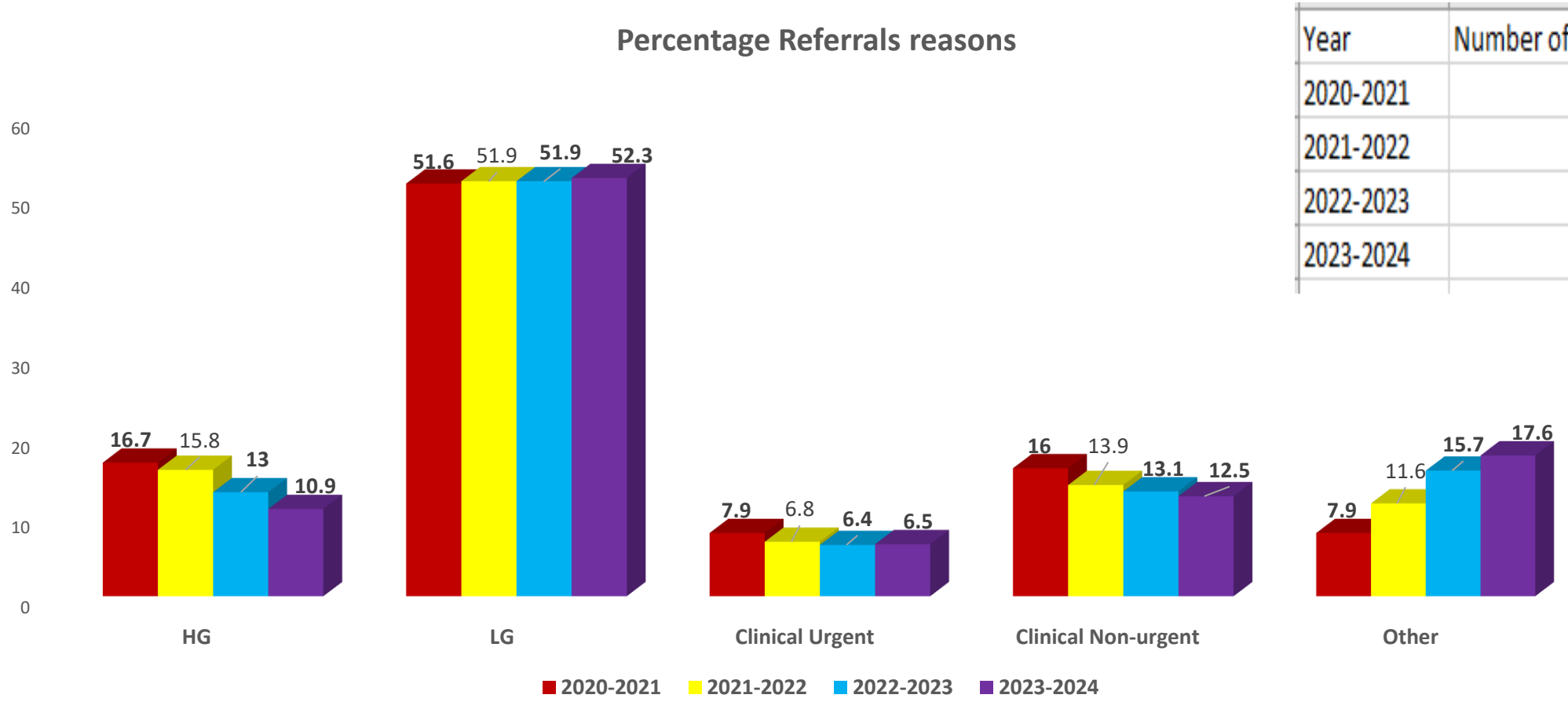

Year	Number of referrals
2020-2021	176,561
2021-2022	235,233
2022-2023	246,762
2023-2024	251,251

The British Association of Gynaecological Pathologists

bsccp | The British Society for Colposcopy and Cervical Pathology

Colposcopy for Colposcopists and Cervical Pathologists

Individuals referred after non-negative[2] sample (i.e. category 1/8/3 result) — numbers/*percentages*

NHS region[1]	Total	Total with known result	Cervical cancer	CIN3 & adenocarcinoma in situ	CIN2	CIN1	HPV only	No CIN/ No HPV	Non-cervical cancer	Seen in colposcopy result n/k	Inadequate biopsy	Colposcopy NAD
Numbers												
England	**132,391**	**126,565**	**99**	**3,704**	**8,367**	**29,541**	**17,440**	**8,006**	**3**	**1,183**	**1,256**	**56,966**
North East and Yorkshire	17,513	17,033	12	373	1,032	3,704	1,556	1,470	-	-	164	8,722
North West	14,118	13,525	9	305	804	2,237	1,674	334	-	593	148	7,421
Midlands	20,002	18,030	19	846	1,201	2,966	2,214	1,171	-	389	179	9,045
East of England	11,630	11,307	15	426	662	1,685	1,042	529	-	39	39	6,870
London	35,723	33,971	26	745	2,433	9,425	6,064	2,003	2	137	298	12,838
South East	26,199	25,499	11	631	1,503	7,170	3,473	2,014	1	15	356	10,325
South West	7,206	7,200	7	378	732	2,354	1,417	485	-	10	72	1,745
Percentage of cases with known result												
England		***100.0***	***0.1***	***2.9***	***6.6***	***23.3***	***13.8***	***6.3***	***0.0***	***0.9***	***1.0***	***45.0***
North East and Yorkshire		*100.0*	*0.1*	*2.2*	*6.1*	*21.7*	*9.1*	*8.6*	-	-	*1.0*	*51.2*
North West		*100.0*	*0.1*	*2.3*	*5.9*	*16.5*	*12.4*	*2.5*	-	*4.4*	*1.1*	*54.9*
Midlands		*100.0*	*0.1*	*4.7*	*6.7*	*16.5*	*12.3*	*6.5*	-	*2.2*	*1.0*	*50.2*
East of England		*100.0*	*0.1*	*3.8*	*5.9*	*14.9*	*9.2*	*4.7*	-	*0.3*	*0.3*	*60.8*
London		*100.0*	*0.1*	*2.2*	*7.2*	*27.7*	*17.9*	*5.9*	*0.0*	*0.4*	*0.9*	*37.8*
South East		*100.0*	*0.0*	*2.5*	*5.9*	*28.1*	*13.6*	*7.9*	*0.0*	*0.1*	*1.4*	*40.5*
South West		*100.0*	*0.1*	*5.3*	*10.2*	*32.7*	*19.7*	*6.7*	-	*0.1*	*1.0*	*24.2*

What we want you to know…



Defining the abnormality – recap the TZ

AWE & $I_{2\ Neg}$

Vascular patterns

IFCPC terminology and Swedescore

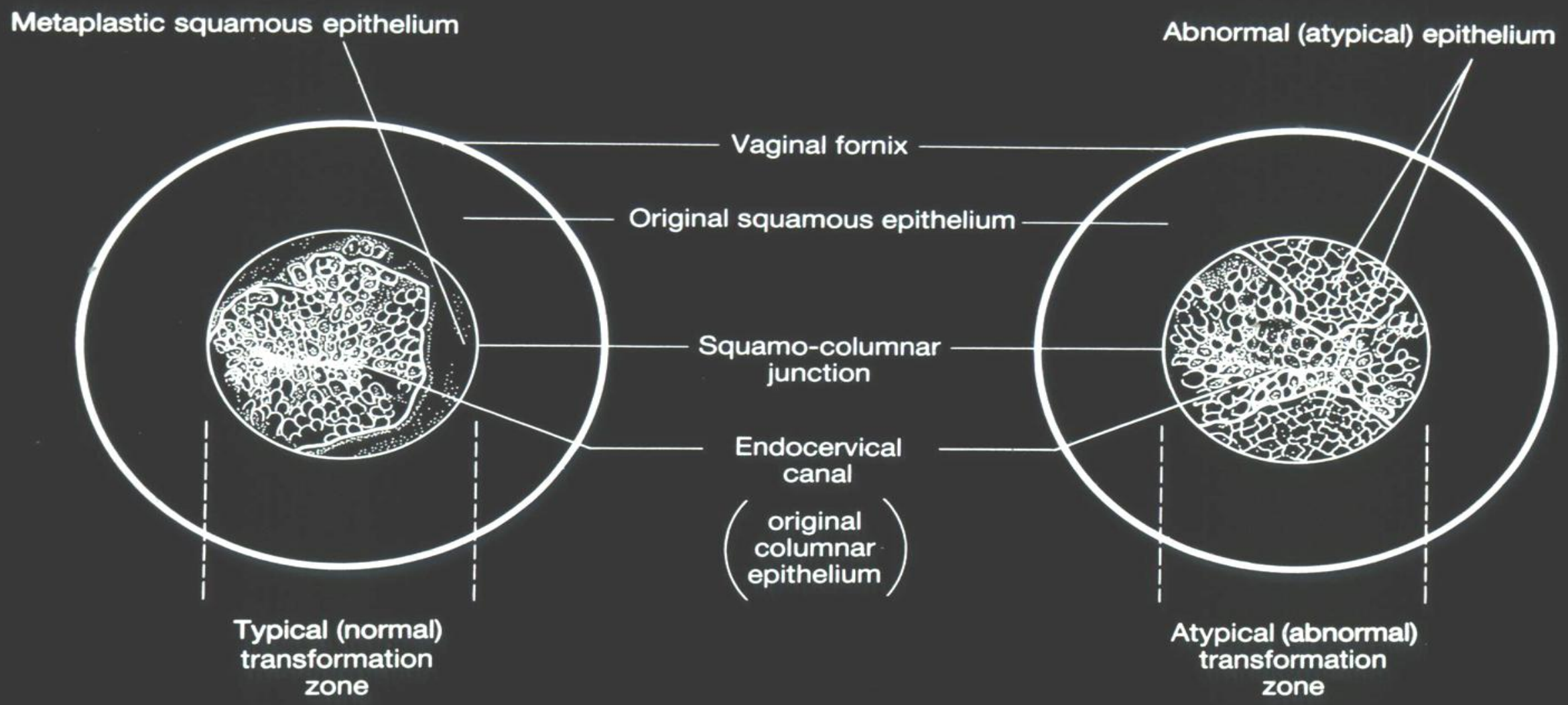
Metaplastic squamous epithelium
Abnormal (atypical) epithelium
Vaginal fornix
Original squamous epithelium
Squamo-columnar junction
Endocervical canal
(original columnar epithelium)
Typical (normal) transformation zone
Atypical (abnormal) transformation zone

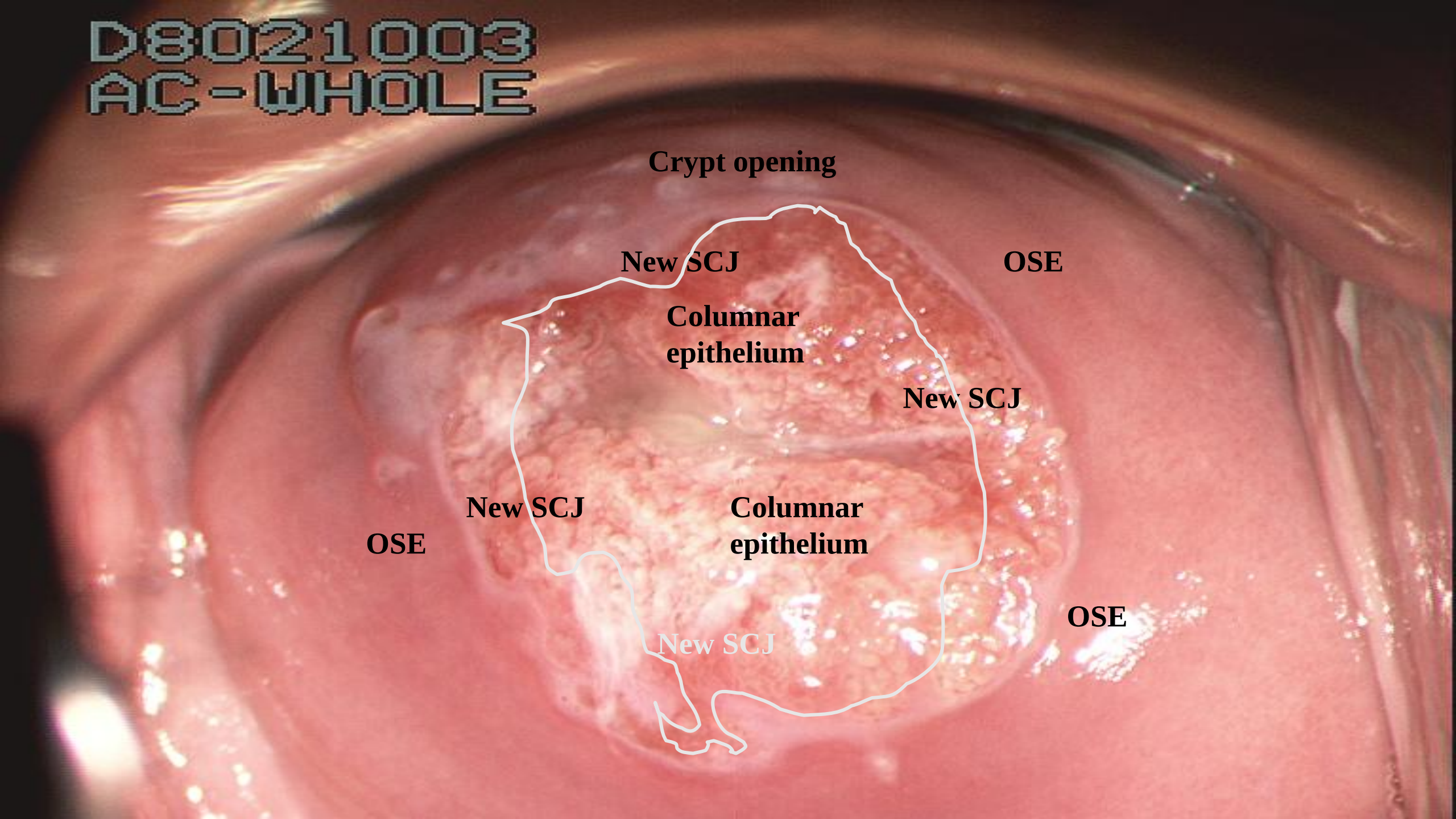
D8021003
AC-WHOLE
Crypt opening
New SCJ
OSE
Columnar epithelium
New SCJ
New SCJ
Columnar epithelium
OSE
OSE
New SCJ

Colposcopy for Colposcopists and Cervical Pathologists

ACETO-WHITE EPITHELIUM

3-5% Acetic acid for 1 minute

Reflection of increased nuclear density: protein reaction

- Immature metaplasia
- CIN
- HPV



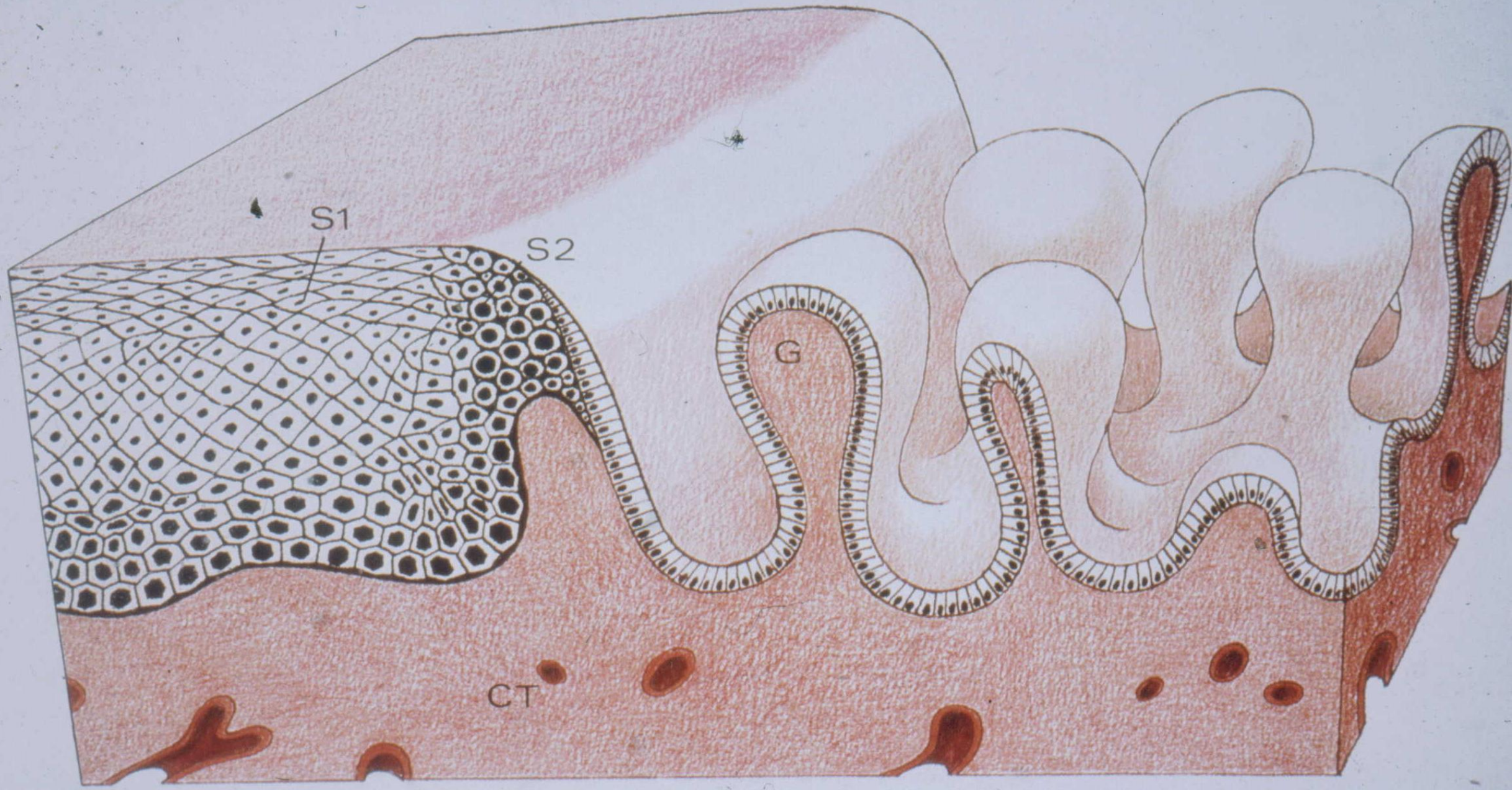

Cartier 1977

Colposcopy for Colposcopists and Cervical Pathologists

IODINE NEGATIVE EPITHELIUM

Lugol's iodine: Sol^{n} of $KI+I_2$ in water

Areas of increased nuclear density:
glycogen reaction

Immature metaplasia
CIN
HPV
Atrophia

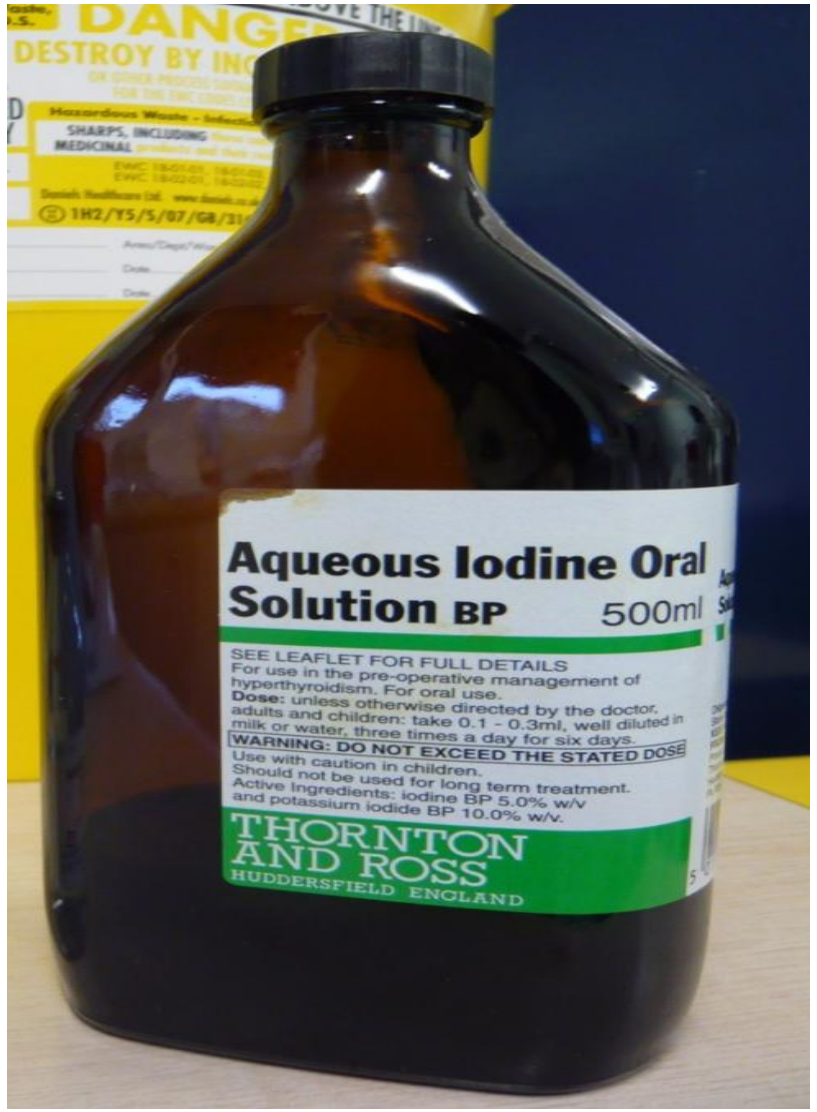

Colposcopy for Colposcopists and Cervical Pathologists

NORMAL COLPOSCOPY

- Normal saline (green filter)
- Acetic Acid (3% or 5%)
- Lugol's Iodine

Colposcopy for Colposcopists and Cervical Pathologists

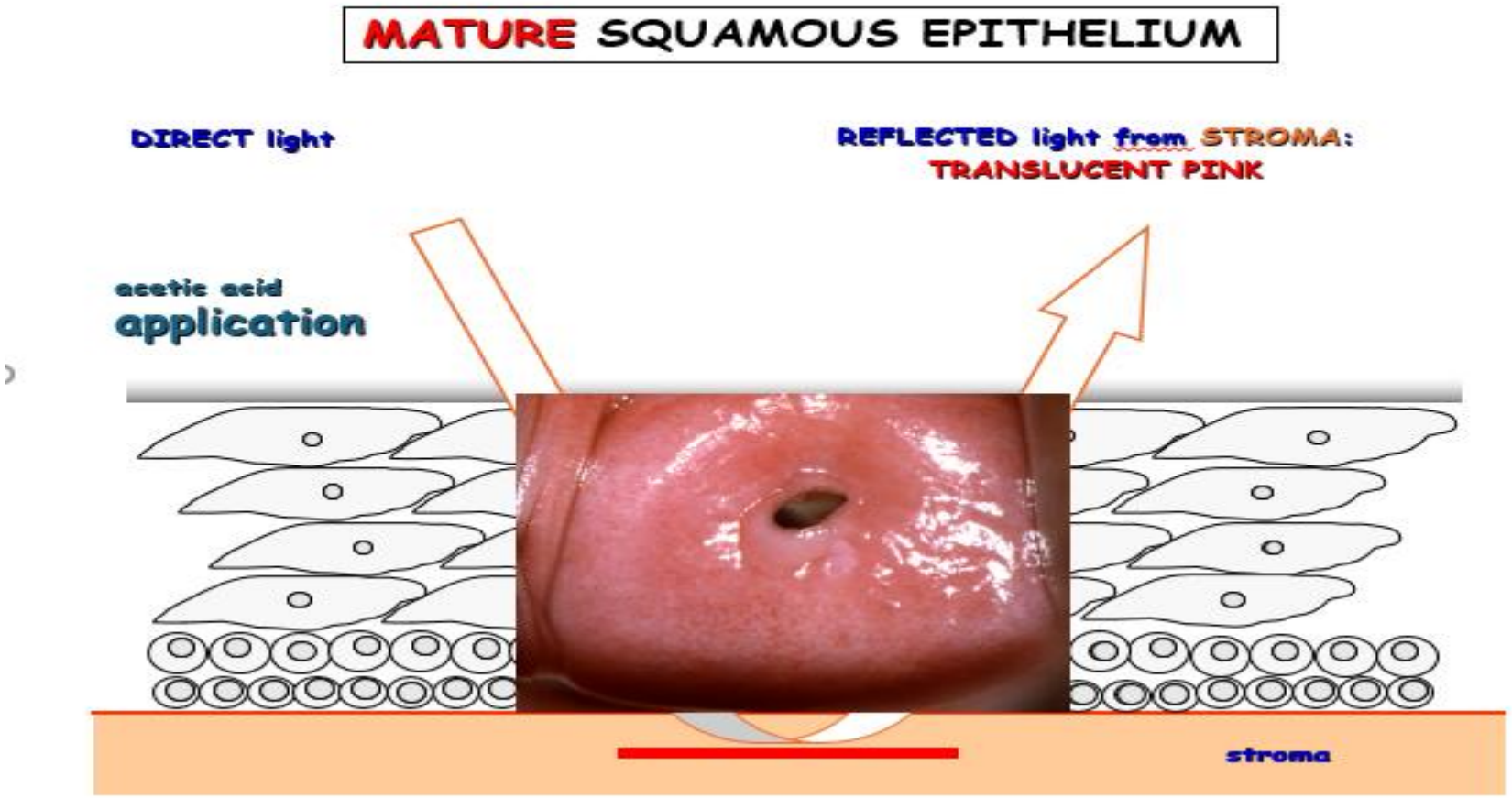

Colposcopy for Colposcopists and Cervical Pathologists

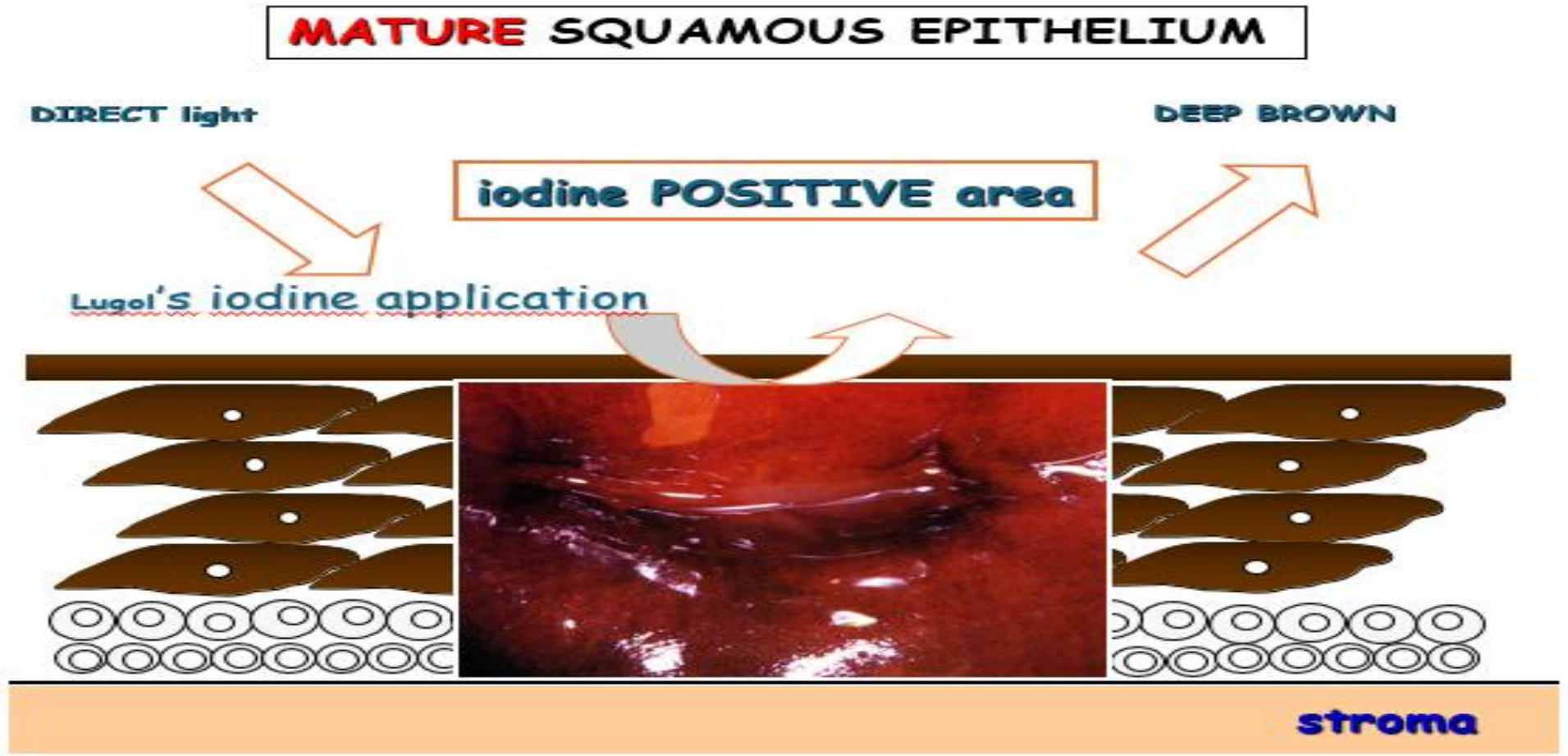

Colposcopy for Colposcopists and Cervical Pathologists



Colposcopy for Colposcopists and Cervical Pathologists

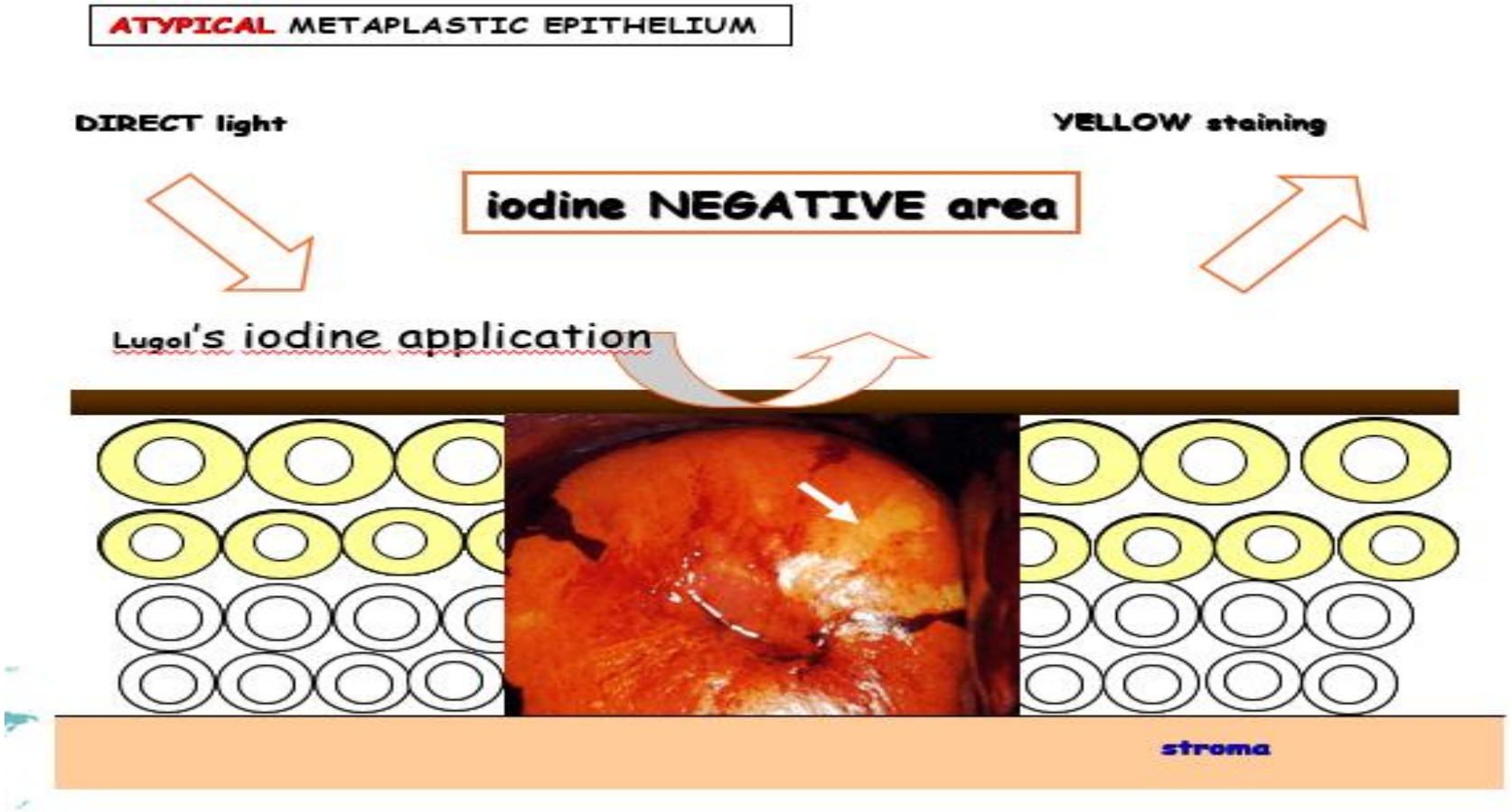

The British Association of Gynaecological Pathologists

bsccp | The British Society for Colposcopy and Cervical Pathology

Concept of Gland/Crypt openings & Last Gland

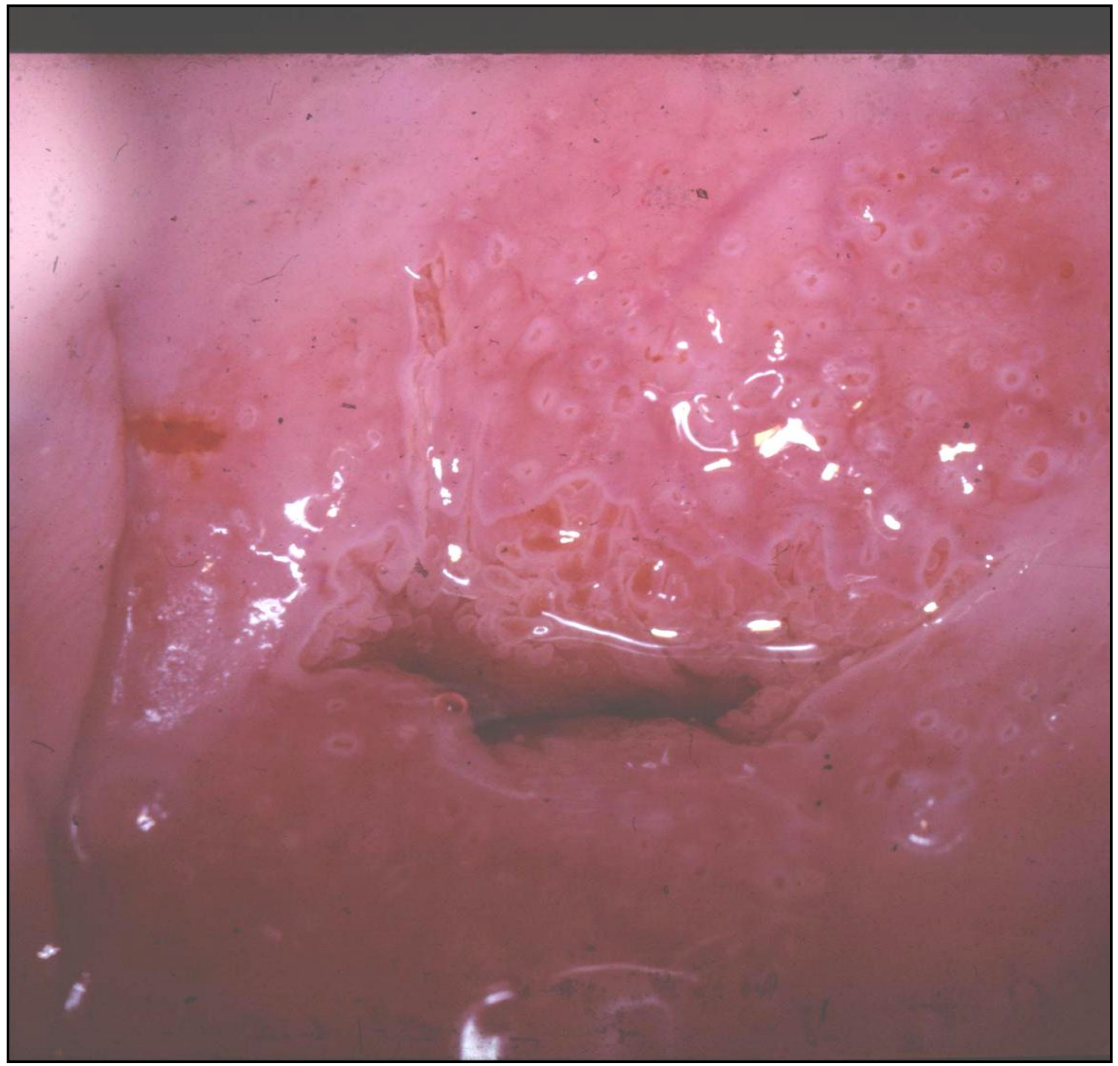

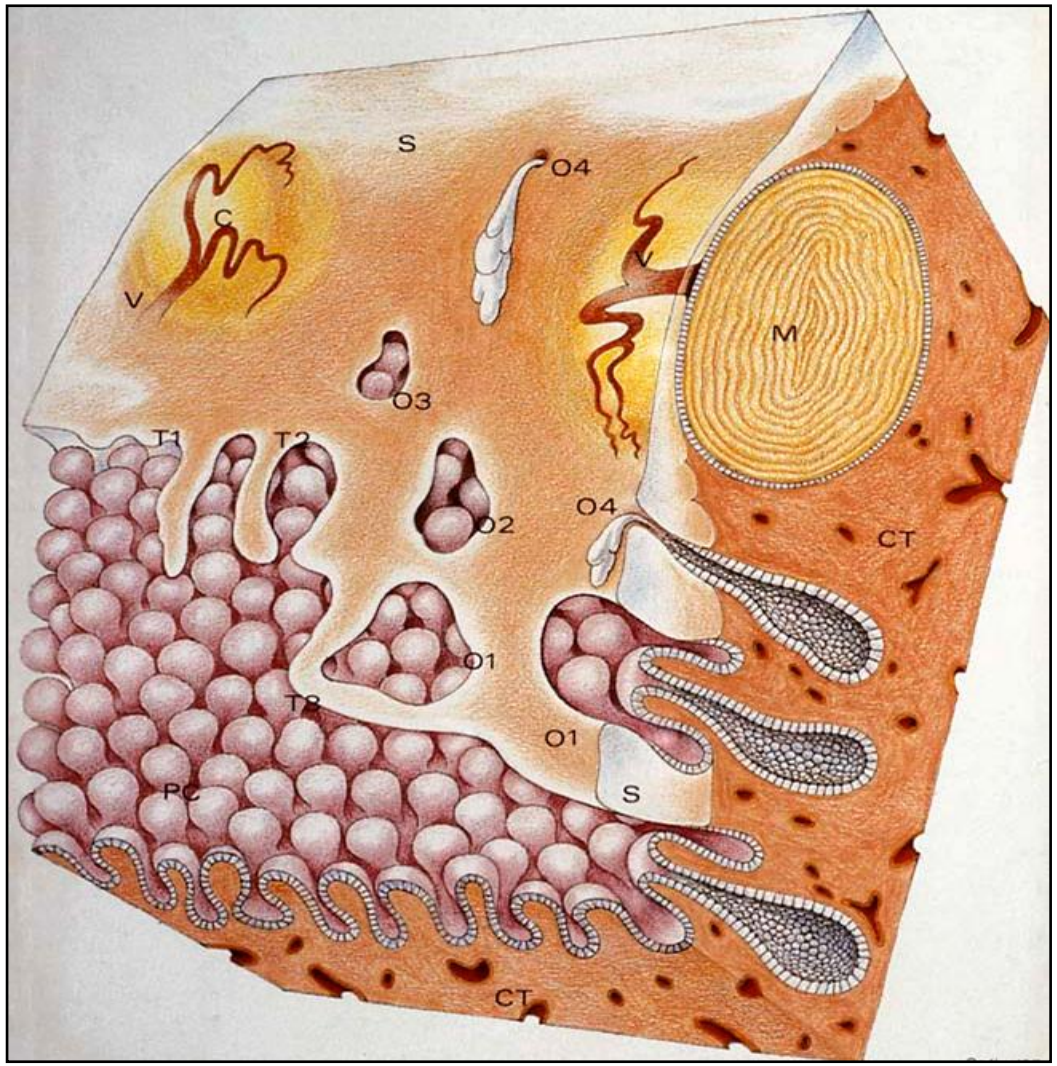

The British Association of Gynaecological Pathologists

bsccp The British Society for Colposcopy and Cervical Pathology

Colposcopy for Colposcopists and Cervical Pathologists

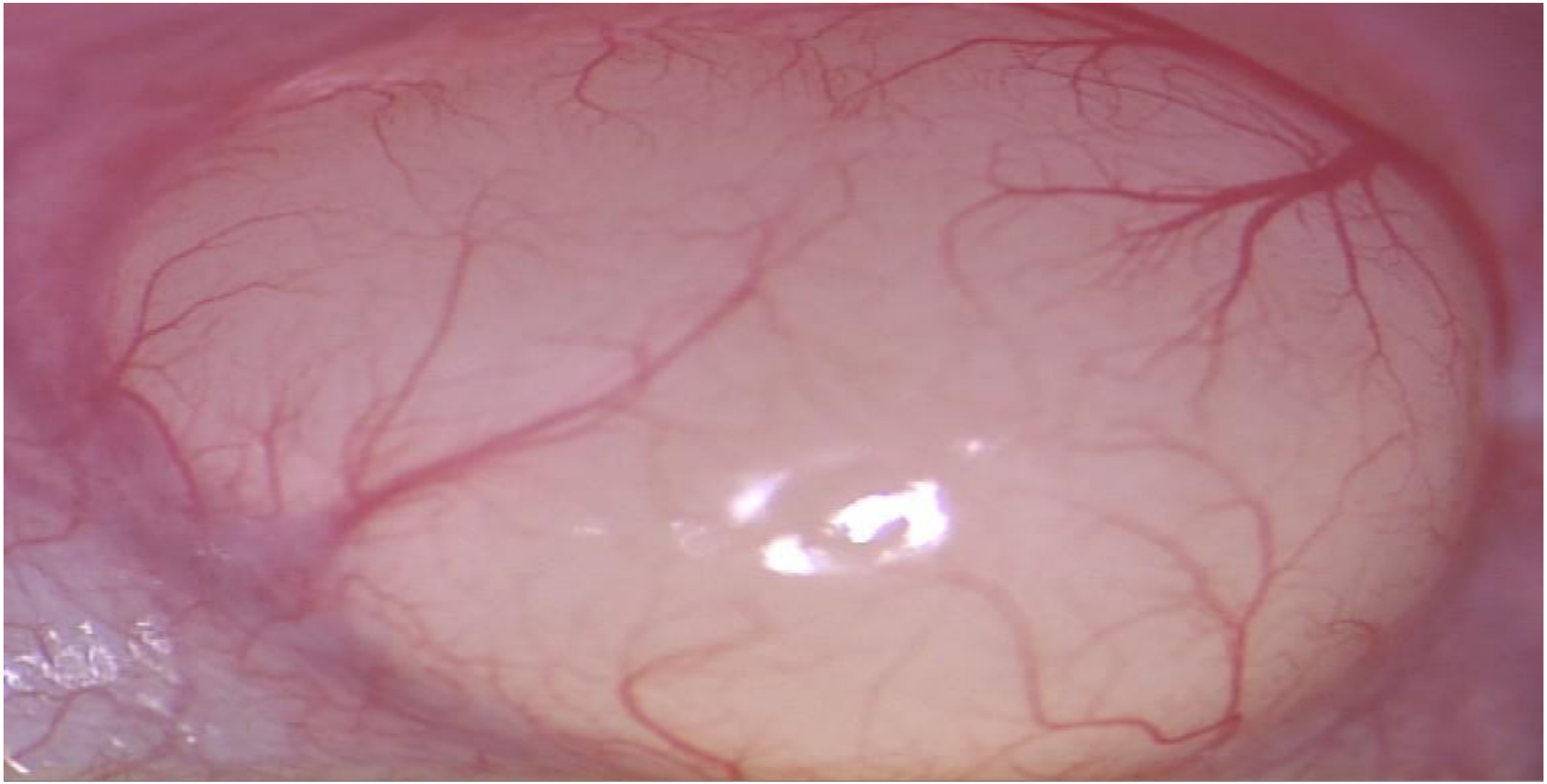

Structured approach to description

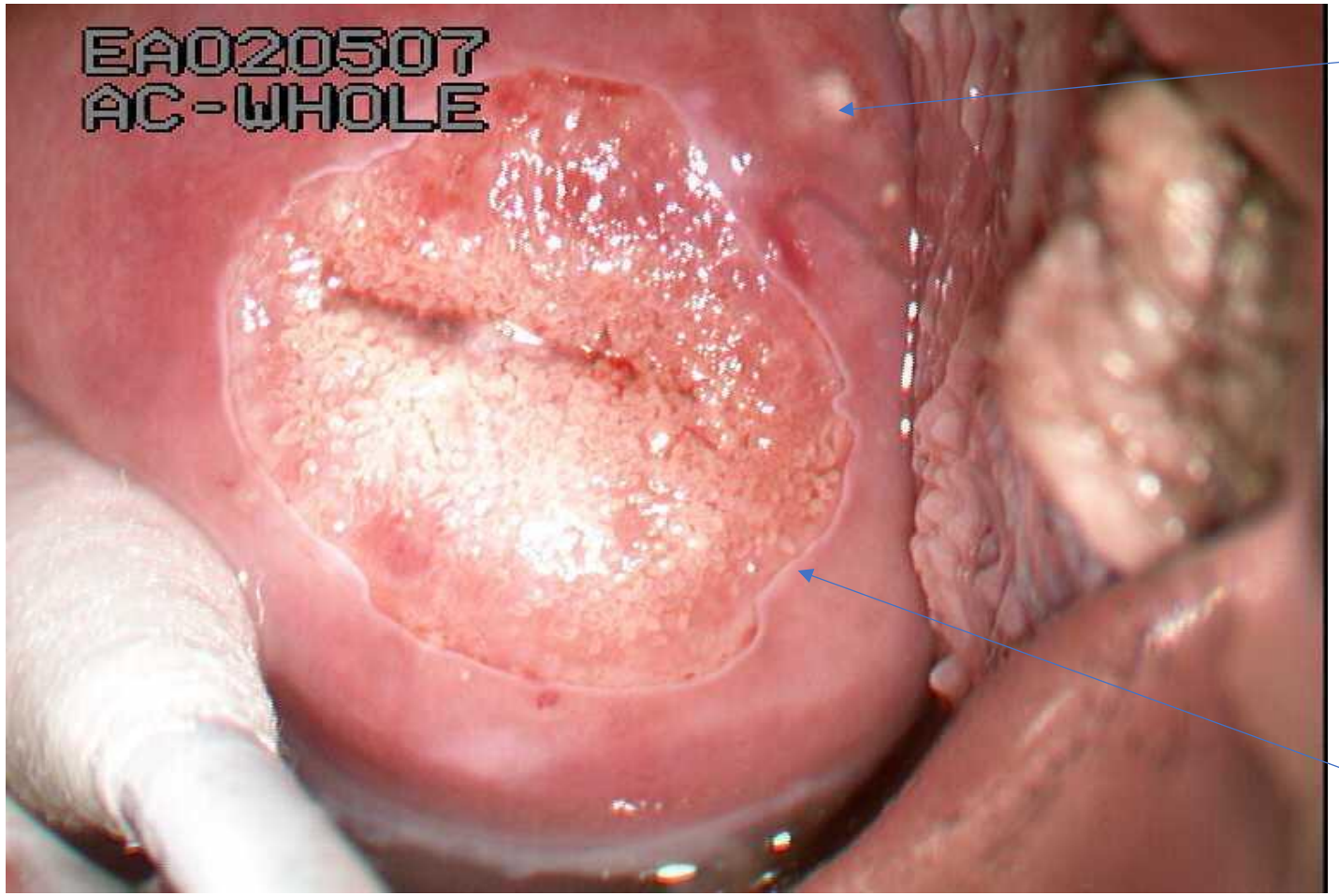

Last gland original SCJ

Adequate

Type 1 TZ

Normal

New SCJ

The British Association of Gynaecological Pathologists

bsccp The British Society for Colposcopy and Cervical Pathology

Colposcopy for Colposcopists and Cervical Pathologists

DOCUMENTATION

Squamo Columnar Junction
Site and Size of Lesion
Biopsy Site

Feature suggesting severity
- Abnormal vessels
- Degree of acetowhite
- Mosaicsm
- Punctation
- Surface contour



WWW.IFCPC.ORG

Bornstein et al Am J Obstet Gynecol Vol 120 No 1 July 2012

The British Association of Gynaecological Pathologists

bsccp | The British Society for Colposcopy and Cervical Pathology

Colposcopy for Colposcopists and Cervical Pathologists

2011 IFCPC colposcopic terminology of the cervix				
Basic definitions		SCJ visualization: complete/partial/none Adequate/inadequate for the reason … (i.e. : cervix obscured by inflammation, bleeding, scar)		
Normal colposcopic findings		Original squamous epithelium , Columnar epithelium including ectopy , Transformation zone types 1,2,3		Deciduosis in pregnancy , Atrophic epithelium , Nabothian cyst , Gland (crypt) openings
Abnormal colposcopic findings	**General principles**	Inside or outside the T -zone . Number of cervical quadrants the l esion covers . Size of the lesion in percentage of cervix . Lugol's staining (Schiller's test) : stained/non -stained		
	Grade 1 (Minor)	Fine aceto -white epithelium		Fine mosaic , Fine punctation
	Grade 2 (Major)	Dense aceto -white epithelium . Coarse mosaic . Coarse punctuation . Leukoplakia	Sharp border . Exophytic lesion . Inner border sign . Ridge sign	Rapid appearanc e of acetowhitening . Cuffed gland (crypt) openings
Suspicious for invasion		Atypical vessels, fragile vessels, Irregular surface Necrosis . Ulceration (necrotic), tumor/gross neoplasm		
Miscellaneous findings		Erosion (traumatic) Inflammation	Endometriosis , Condyloma . Polyp (Ectocervical/ endocervical)	Stenosis . Congenital anomaly . Post treatment consequence

The British Association of Gynaecological Pathologists

bsccp The British Society for Colposcopy and Cervical Pathology

Colposcopy for Colposcopists and Cervical Pathologists

Transformation Zone Classification



Type 1

- **Completely ectocervical**
- **Fully visible**
- **small or large**

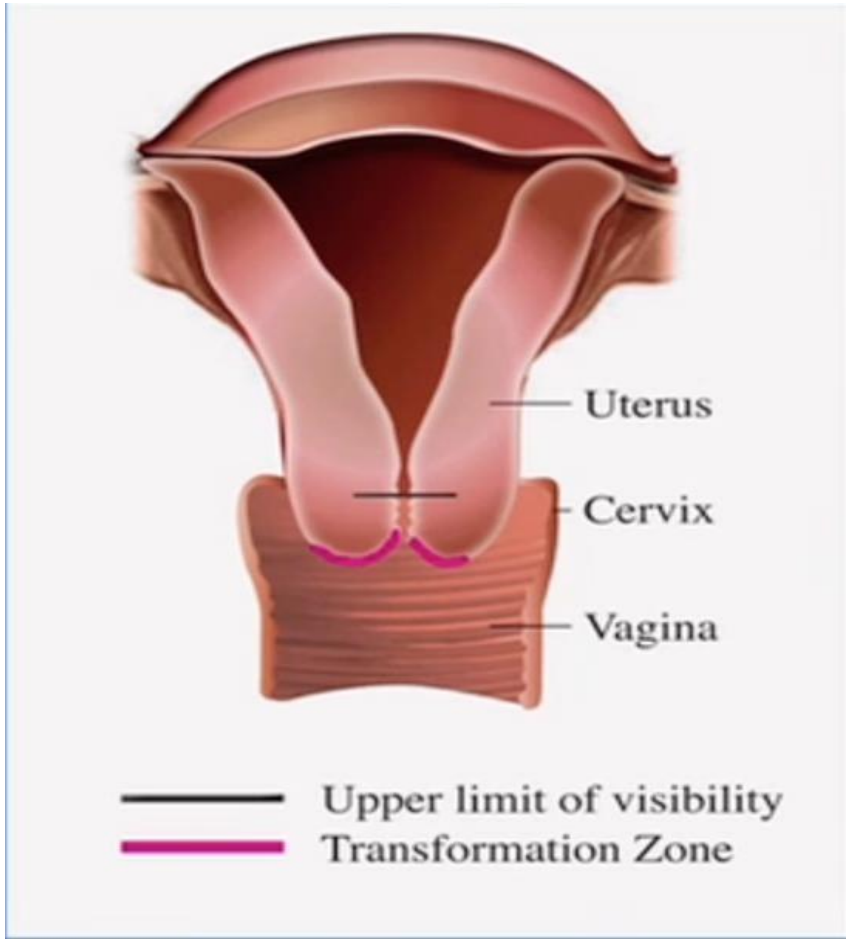

Colposcopy for Colposcopists and Cervical Pathologists

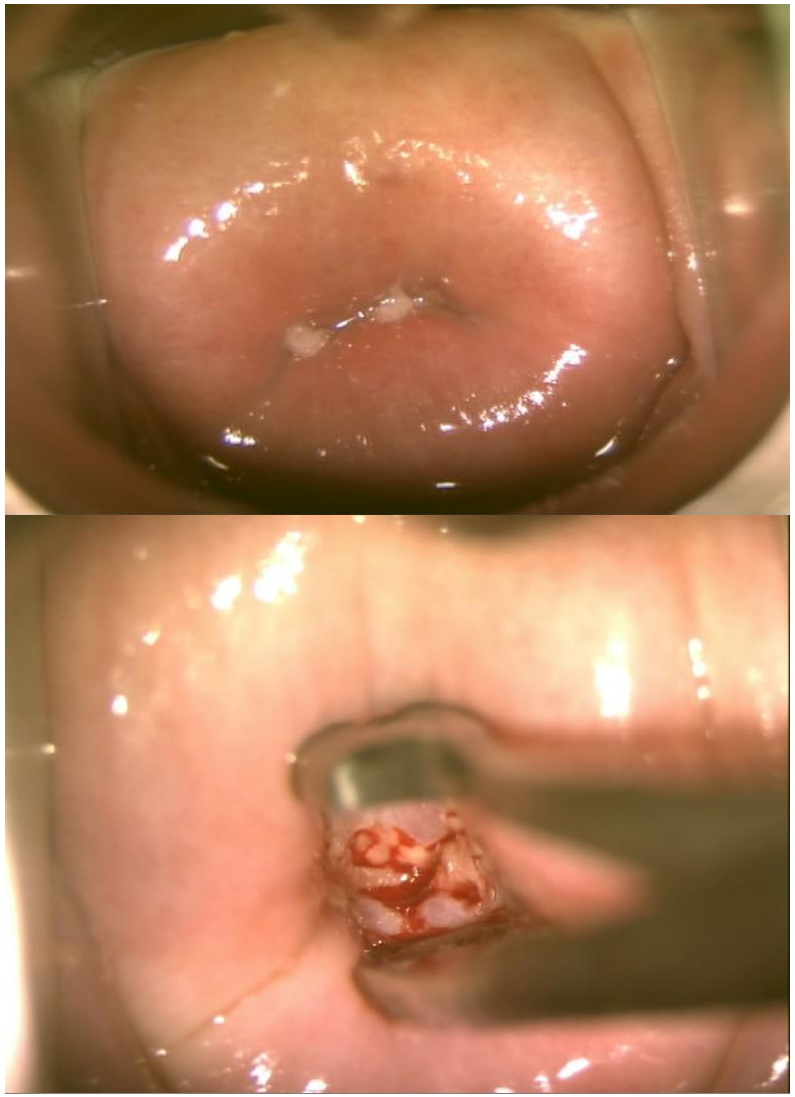

Type 2

- Has endocervical component
- Fully visible
- May have ectocervical component which may be small or large
- May need assistance to view

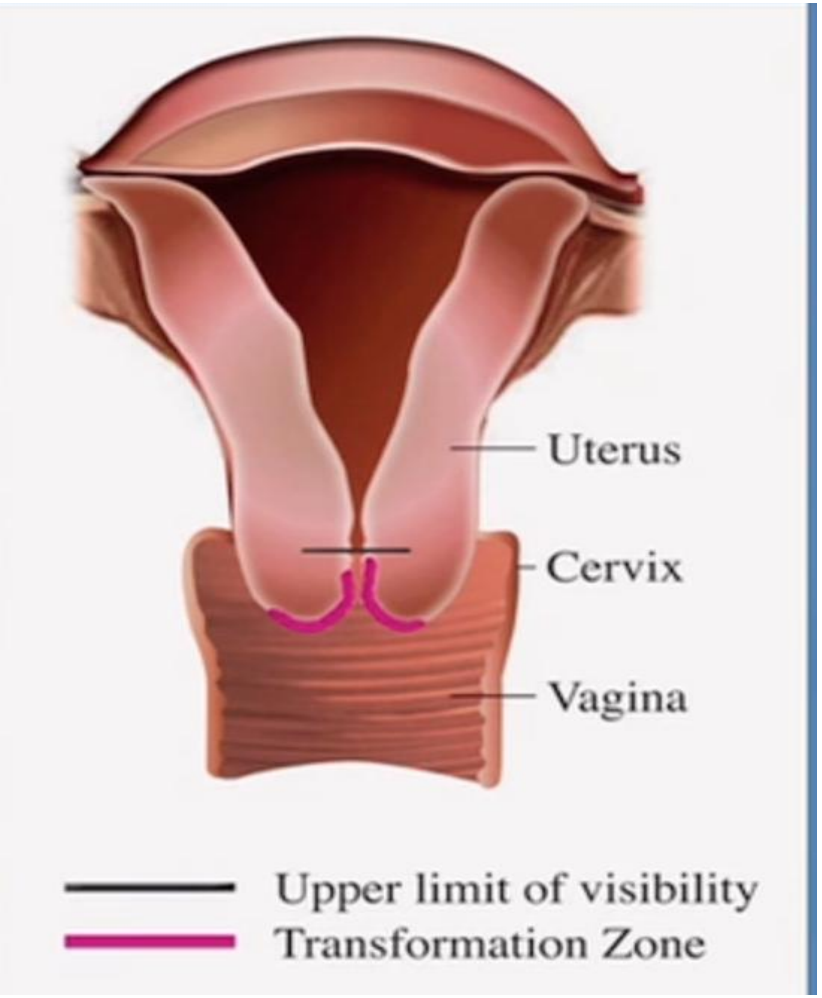

Colposcopy for Colposcopists and Cervical Pathologists



Type 3

- Has endocervical component
- Is not fully visible
- May have ectocervical component which may be small or large

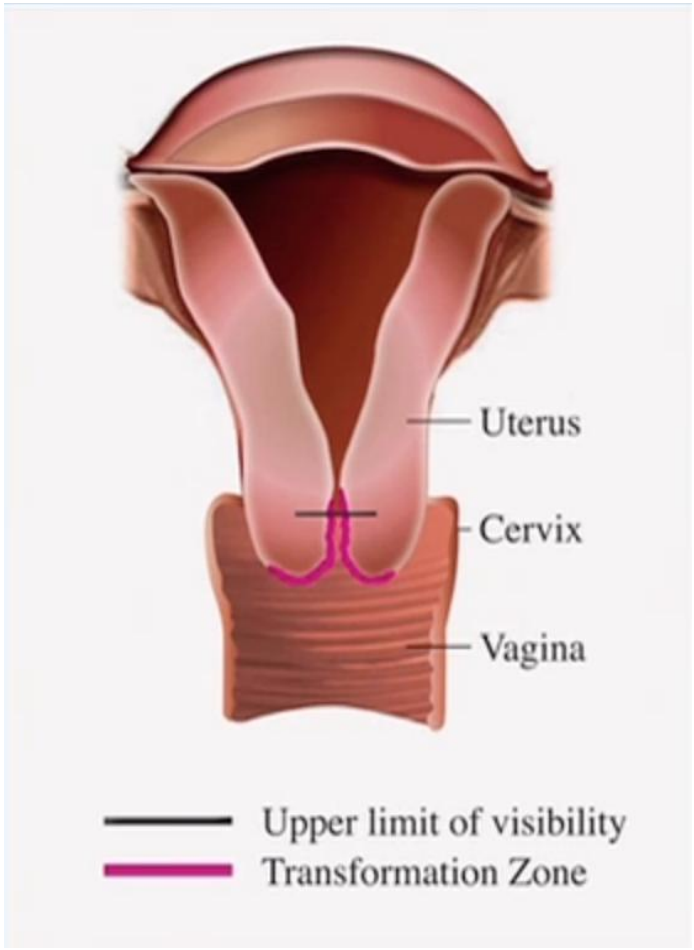

Colposcopy for Colposcopists and Cervical Pathologists

Challenges

Identifying the SCJ

–Kogan's Forceps

–Desjardin's forceps

–Cotton buds

–Oestrogen preparation

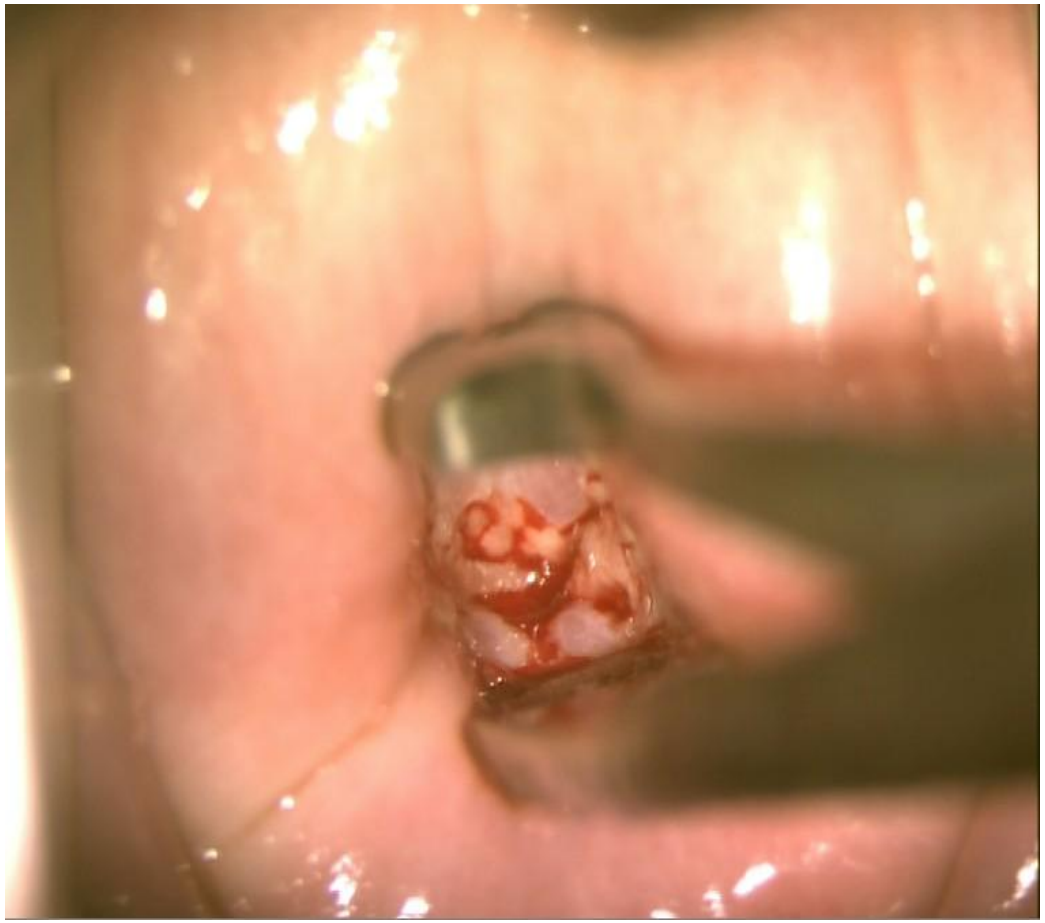

The British Association of Gynaecological Pathologists

bsccp The British Society for Colposcopy and Cervical Pathology

Colposcopy for Colposcopists and Cervical Pathologists

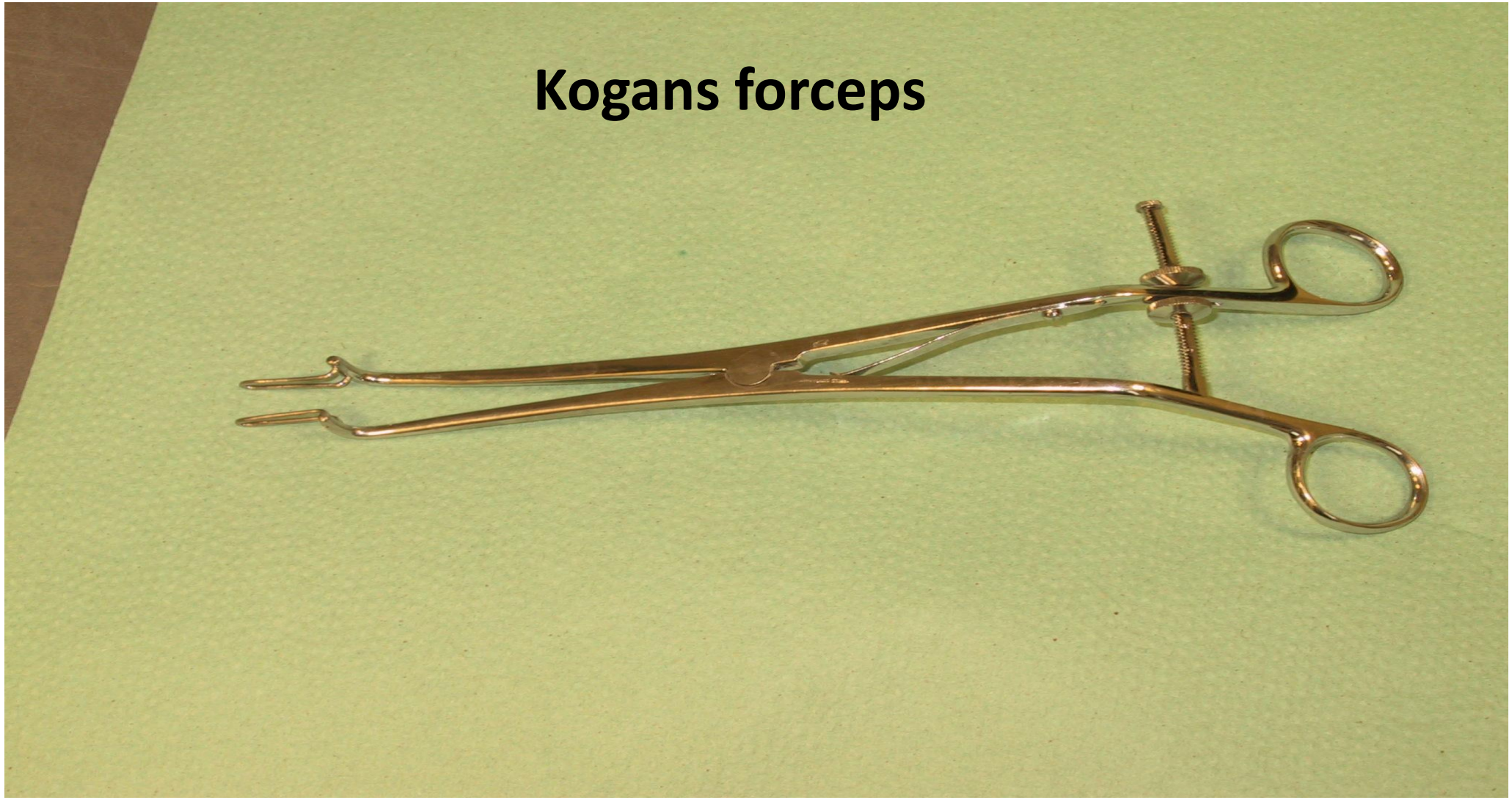

The British Association of Gynaecological Pathologists

bsccp The British Society for Colposcopy and Cervical Pathology

Colposcopy for Colposcopists and Cervical Pathologists

Ensuring an adequate view – Retraction of Vaginal Walls

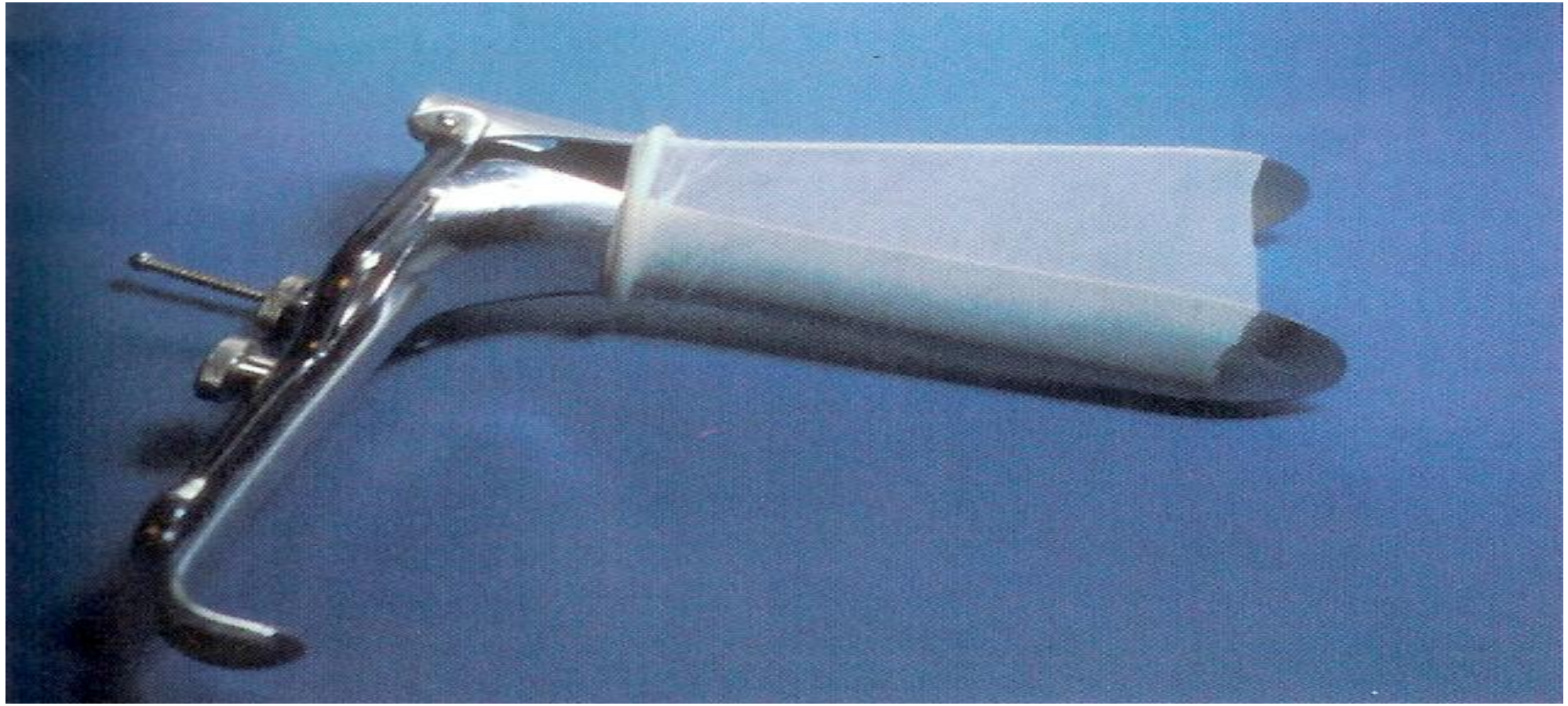

The British Association of Gynaecological Pathologists

bsccp | The British Society for Colposcopy and Cervical Pathology

Colposcopy for Colposcopists and Cervical Pathologists

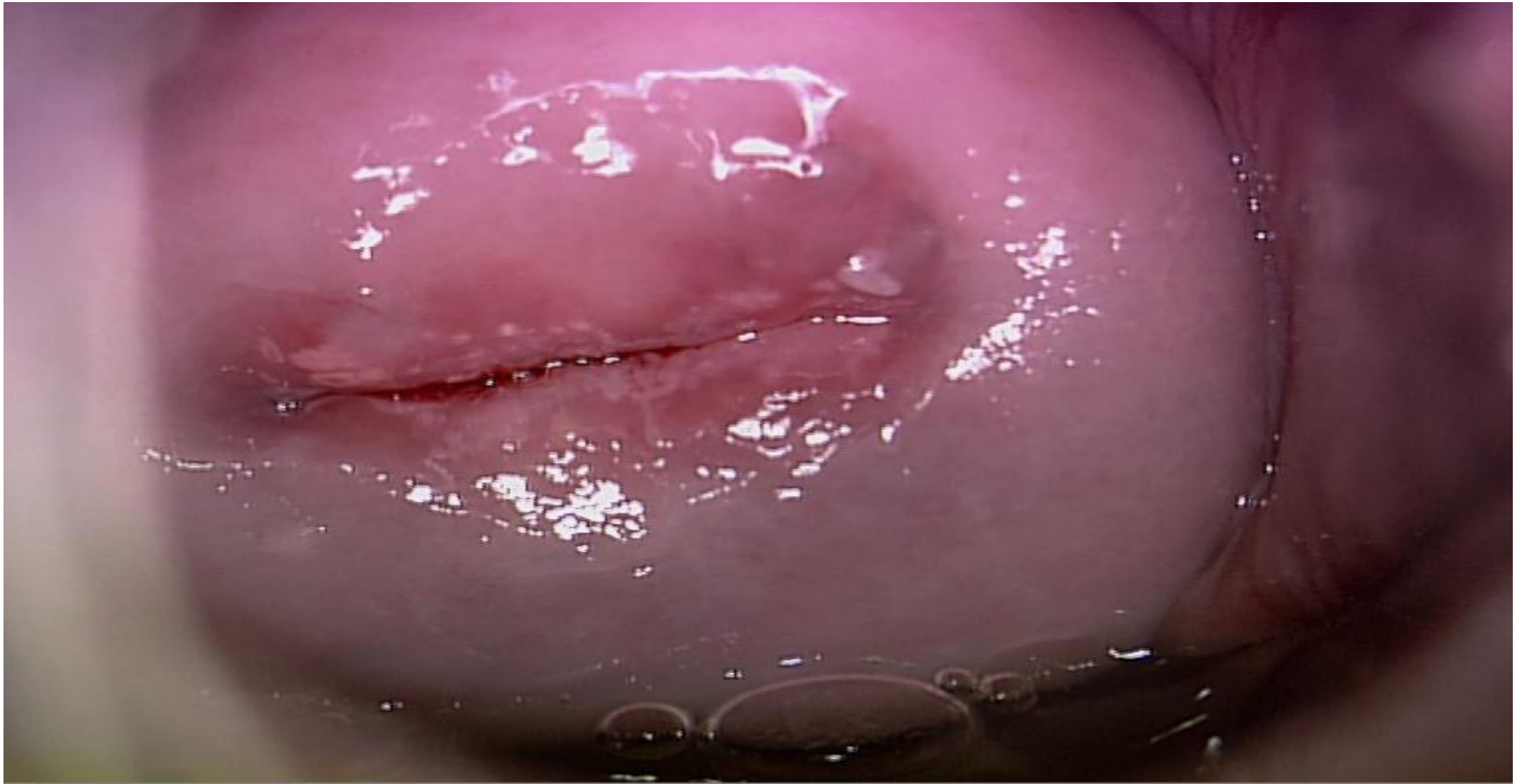

The British Association of Gynaecological Pathologists

bsccp The British Society for Colposcopy and Cervical Pathology

Colposcopy for Colposcopists and Cervical Pathologists

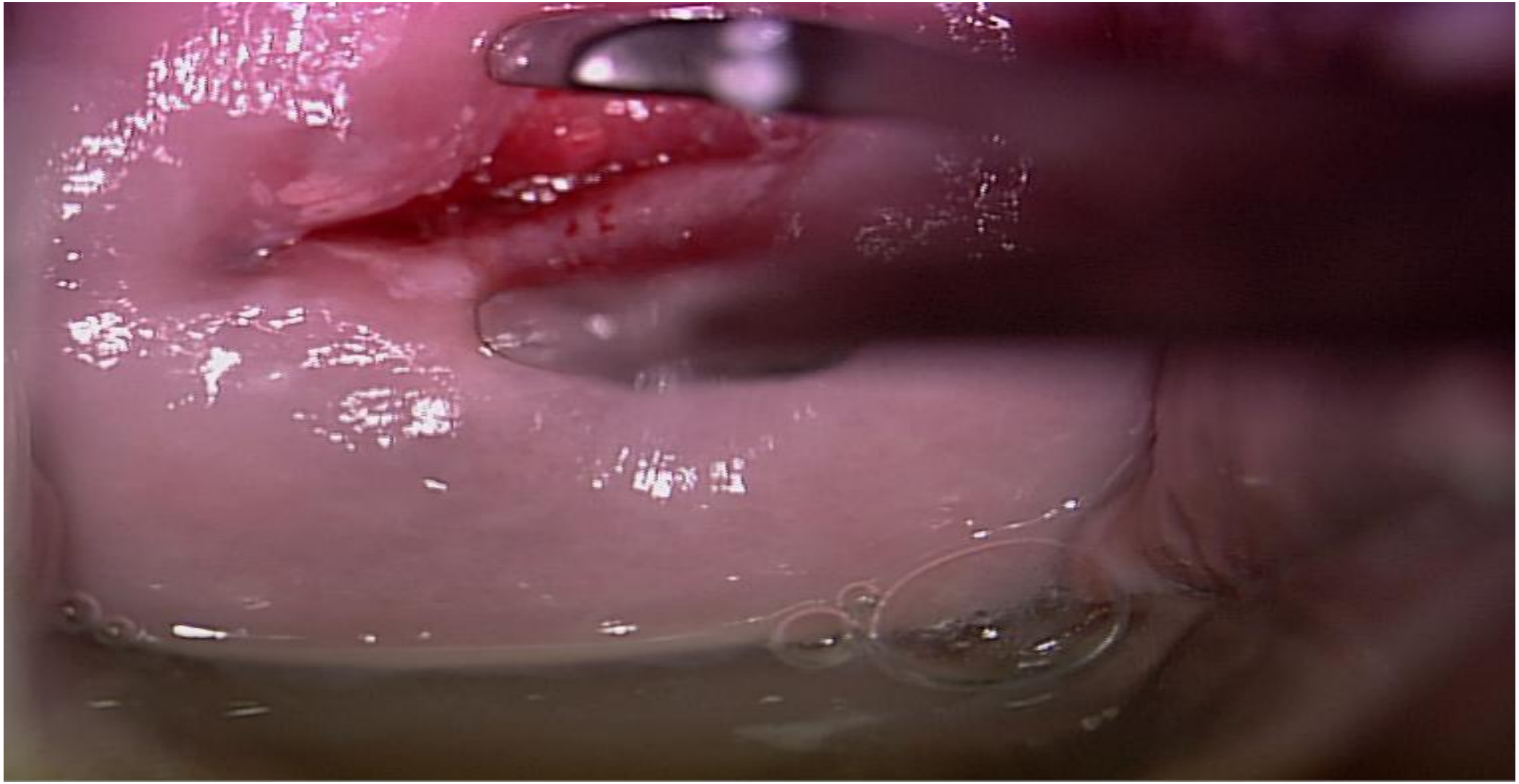

The British Association of Gynaecological Pathologists

bsccp | The British Society for Colposcopy and Cervical Pathology

Colposcopy for Colposcopists and Cervical Pathologists

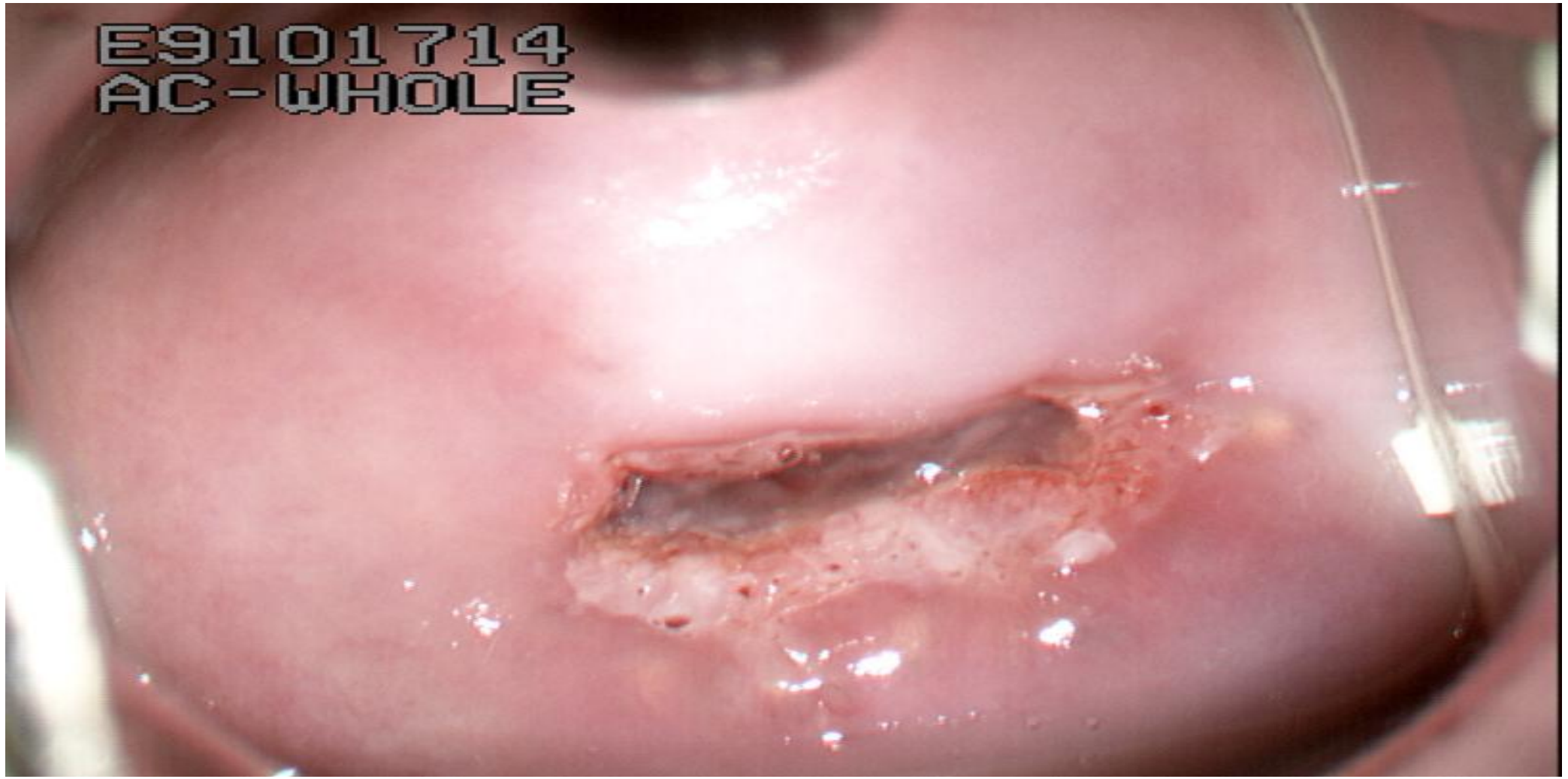

The British Association of Gynaecological Pathologists

bsccp The British Society for Colposcopy and Cervical Pathology

Colposcopy for Colposcopists and Cervical Pathologists

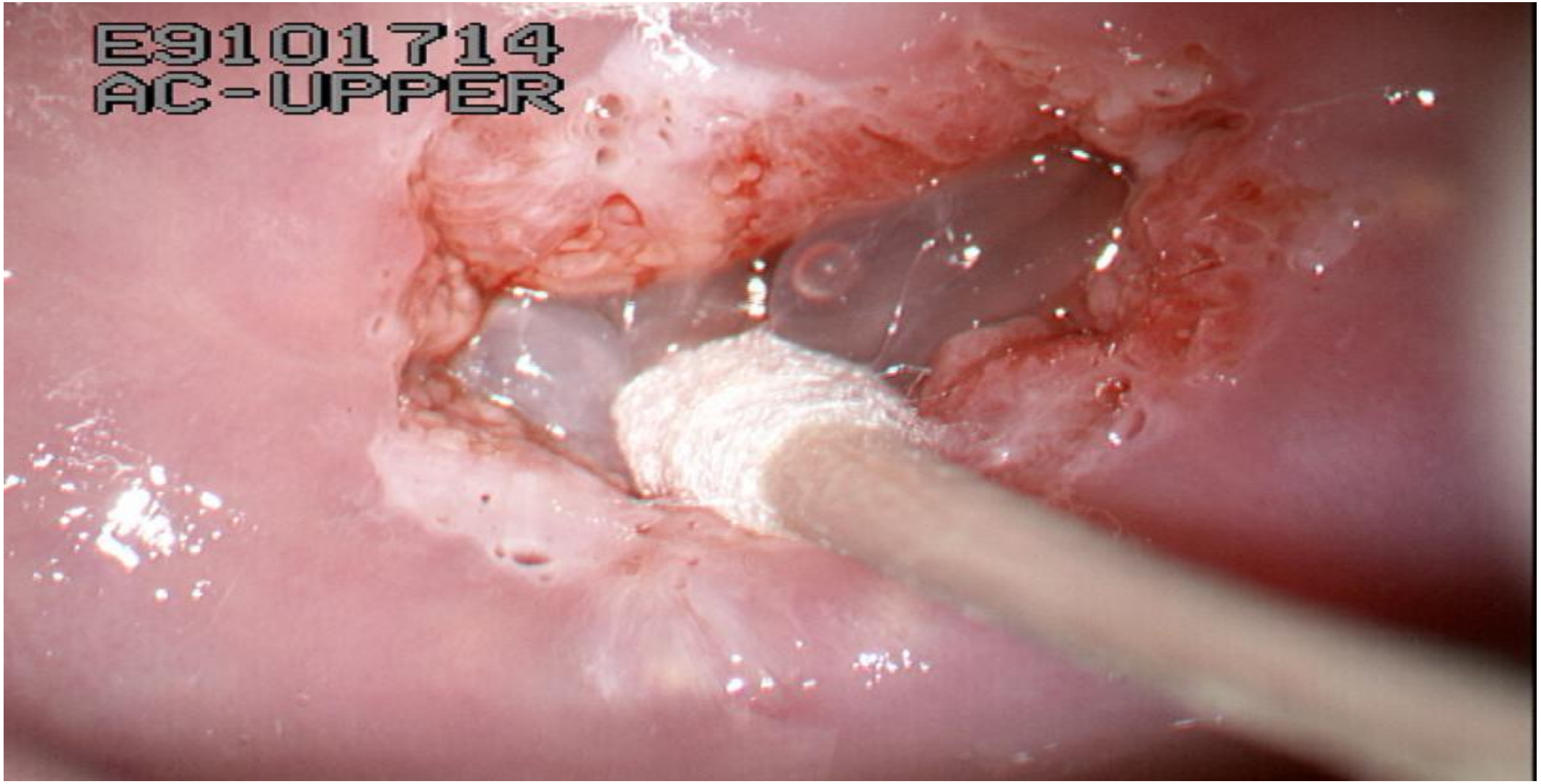

The British Association of Gynaecological Pathologists

bsccp The British Society for Colposcopy and Cervical Pathology

Colposcopy for Colposcopists and Cervical Pathologists



Positive predictors of High-Grade disease:

Atypical vessels- 62.5%

Coarse punctation 53.8%

Coarse Mosaicism

Colposcopy for Colposcopists and Cervical Pathologists

Outside the TZ…



The British Association of Gynaecological Pathologists

bsccp The British Society for Colposcopy and Cervical Pathology

Colposcopy for Colposcopists and Cervical Pathologists

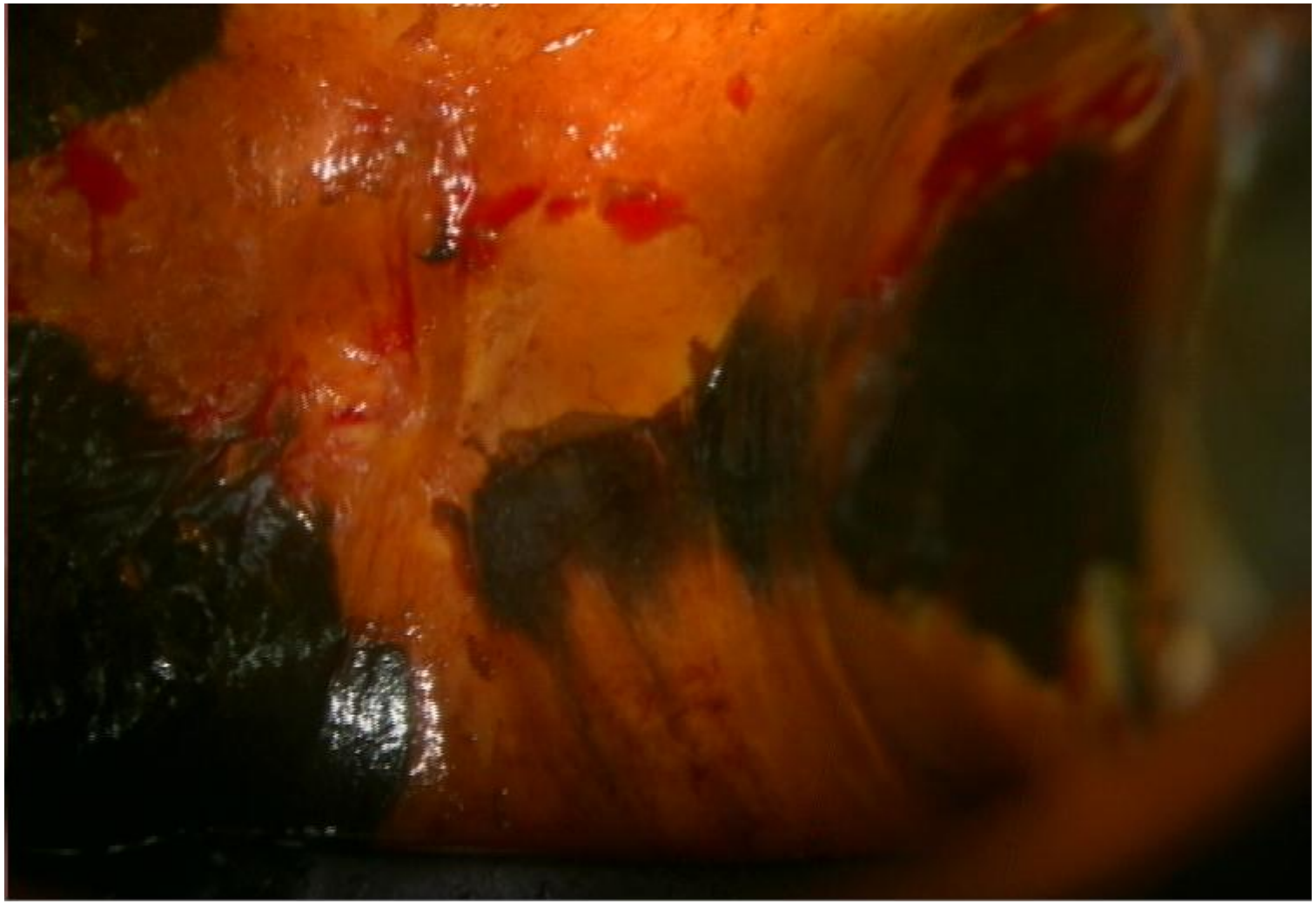

Colposcopy for Colposcopists and Cervical Pathologists

Size of cervical lesions

Kierkegaard 1995: lesion size has independent predictive value

Ferris 2005: Size of cervical lesions correlates directly with the severity of disease.

Hopman et al. 1995 reported an inter-observer agreement rate of 68% when evaluating colposcopic photographs for lesion size.

Hammes 2007: Lesions >50% of cervix had higher probability for high-grade lesion / carcinoma (OR, 3.45).

The British Association of Gynaecological Pathologists

bsccp | The British Society for Colposcopy and Cervical Pathology

Colposcopy for Colposcopists and Cervical Pathologists



The British Association of Gynaecological Pathologists

bsccp | The British Society for Colposcopy and Cervical Pathology

Colposcopy for Colposcopists and Cervical Pathologists

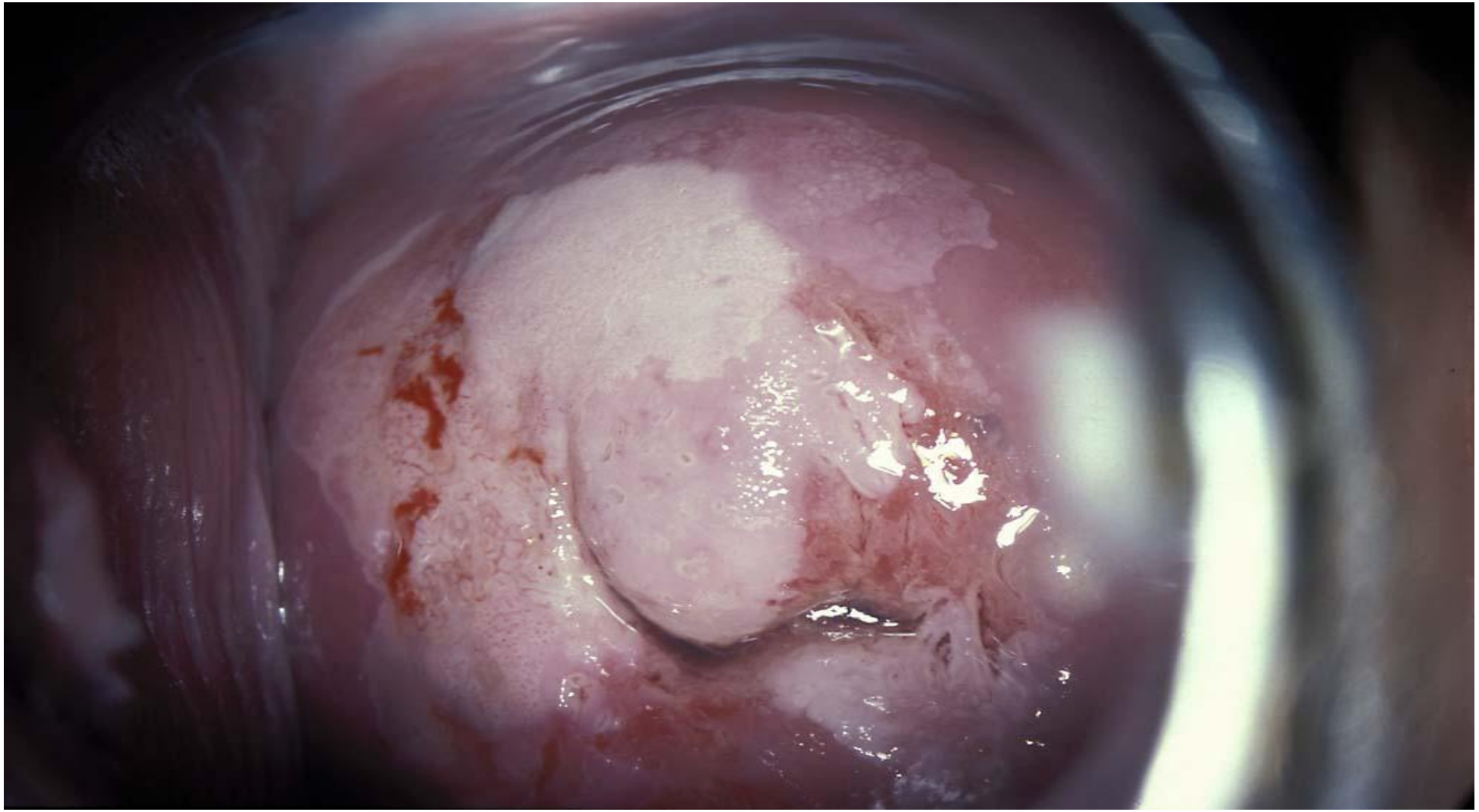

Colposcopy for Colposcopists and Cervical Pathologists

Abnormal vascular pattern

Punctation

Mosaic

Abnormal Vessels

- Loops
- Corkscrews
- "Pollarded vessels"



Colposcopy for Colposcopists and Cervical Pathologists

- Green filter and saline - high power magnification
- Can identify subtle vessel changes

- Afferent and efferent capillaries within the villi of columnar epithelium become compressed during the normal metaplastic process and are not incorporated within the newly formed squamous epithelium.

- Form a fine network below the basement membrane

The British Association of Gynaecological Pathologists

bsccp The British Society for Colposcopy and Cervical Pathology

Colposcopy for Colposcopists and Cervical Pathologists





Colposcopy for Colposcopists and Cervical Pathologists

- When CIN develops as a result of HPV infection and atypical metaplasia, the afferent and efferent capillary system may be trapped (incorporated) into the diseased dysplastic epithelium through several elongated stromal papillae
- Thin layer of epithelium may remain on top of these vessels
- Forms the basis of the punctate and mosaic blood vessel patterns

- Terminating vessels in the stromal papillae underlying the thin epithelium may appear as black points in a stippling pattern in an **end-on view** under the colposcope, making what are called punctate areas - **Punctation**

Colposcopy for Colposcopists and Cervical Pathologists

- Interconnecting blood vessels in the stromal papillae, running parallel to the surface, may be observed colposcopically as cobbled areas similar to a mosaic pattern – **Mosaicism**
- Epithelium appears as individual blocks: small or large, round or polygonal, and regular or irregular.
- Fine mosaic and punctation - fine-calibre blood vessels that appear in close proximity to one another
- Coarse mosaic and punctuation - vessels of larger calibre and with larger intercapillary distances

The British Association of Gynaecological Pathologists

bsccp The British Society for Colposcopy and Cervical Pathology

Colposcopy for Colposcopists and Cervical Pathologists



The British Association of Gynaecological Pathologists

bsccp The British Society for Colposcopy and Cervical Pathology

Colposcopy for Colposcopists and Cervical Pathologists

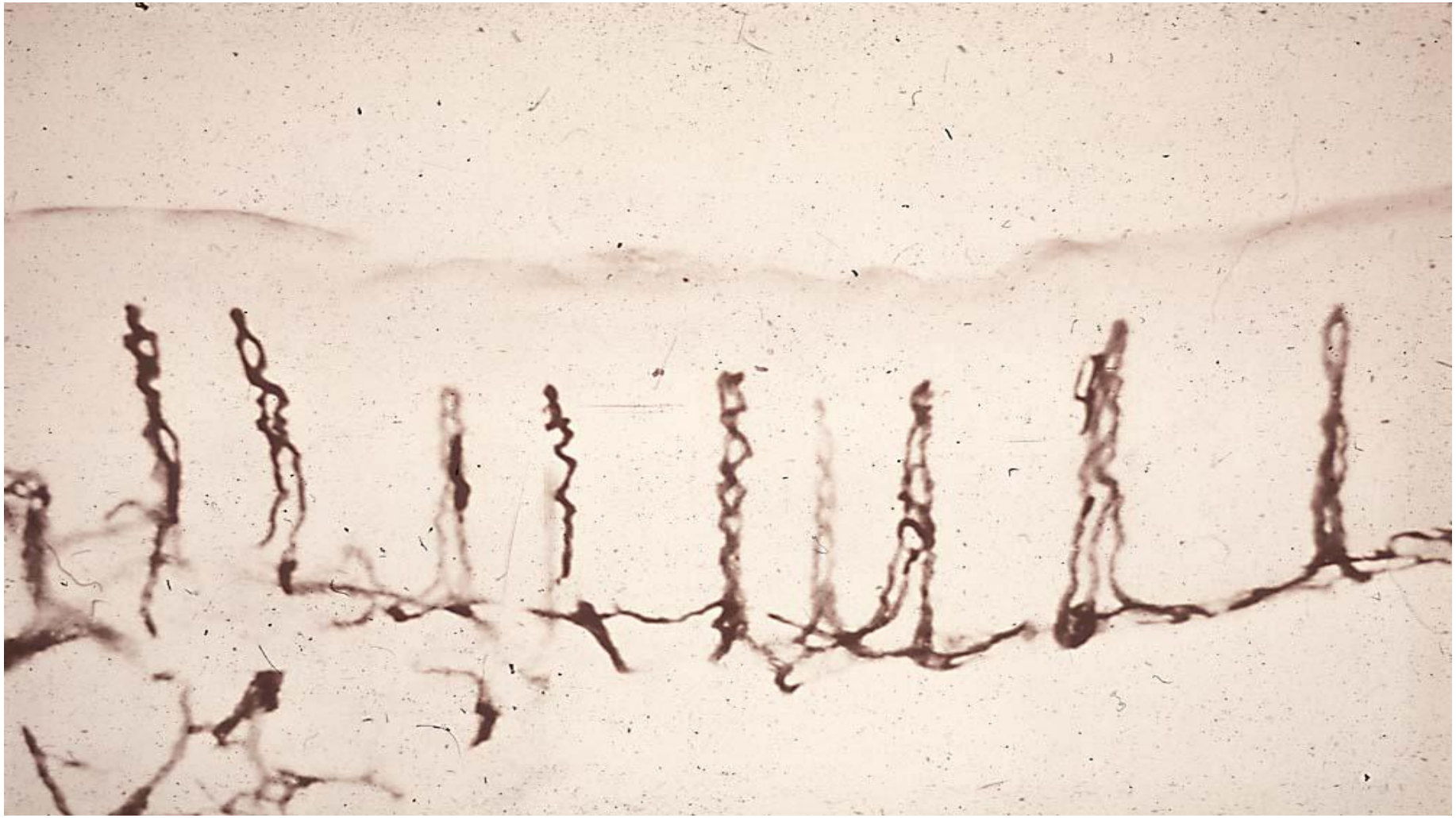

The British Association of Gynaecological Pathologists

bsccp | The British Society for Colposcopy and Cervical Pathology

Colposcopy for Colposcopists and Cervical Pathologists

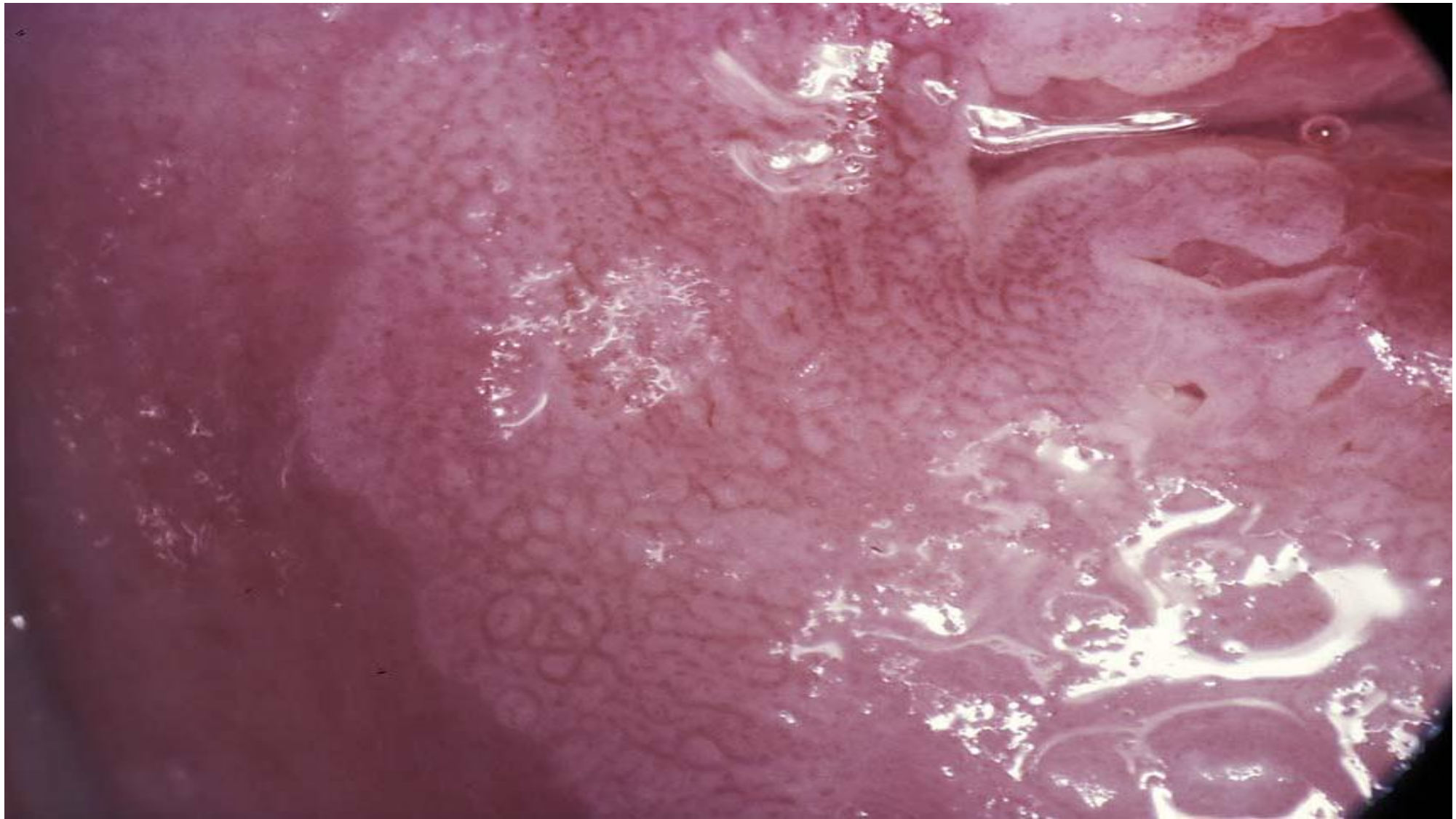

The British Association of Gynaecological Pathologists

bsccp | The British Society for Colposcopy and Cervical Pathology

Colposcopy for Colposcopists and Cervical Pathologists



Colposcopy for Colposcopists and Cervical Pathologists

Atypical vessels

A focal abnormal colposcopic pattern in which the blood vessel pattern appears not as punctation or mosaic or as the finely branching capillaries of a normal epithelium, but rather as irregular vessels with an abrupt and interrupted course appearing as commas, corkscrew capillaries, or spaghetti-like forms

Colposcopy for Colposcopists and Cervical Pathologists

- **Normal blood vessels** of the cervix have the branching pattern of a tree, with a central stem from which smaller branches spread out. As the branches divide, they become thinner
- **Atypical vessels** suddenly appear and disappear, have truncated branches (a "pollarded tree") or no branches, and have uneven calibres





The British Association of Gynaecological Pathologists

bsccp | The British Society for Colposcopy and Cervical Pathology

Colposcopy for Colposcopists and Cervical Pathologists



The British Association of Gynaecological Pathologists

bsccp | The British Society for Colposcopy and Cervical Pathology

Colposcopy for Colposcopists and Cervical Pathologists

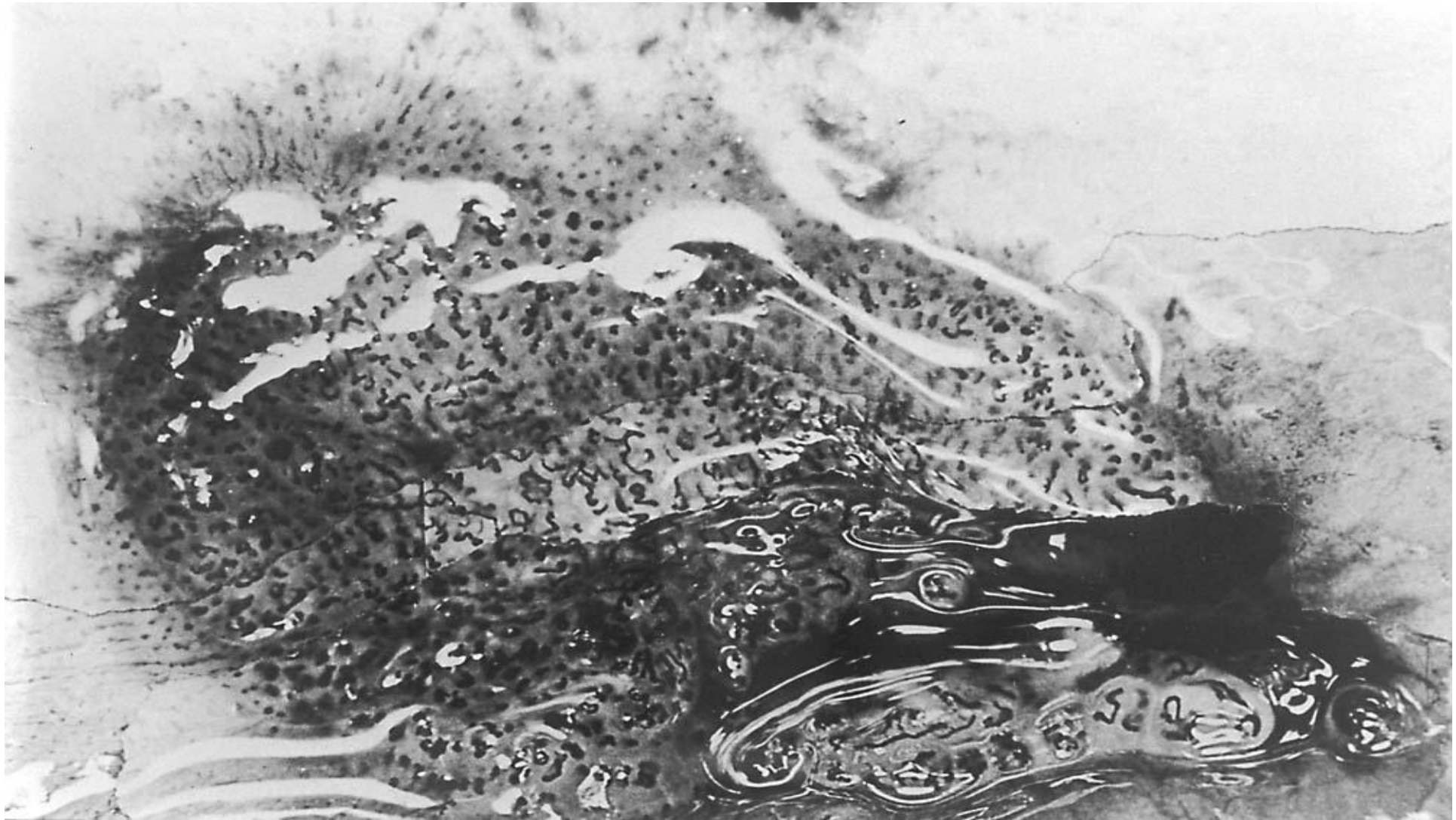

The British Association of Gynaecological Pathologists

bsccp The British Society for Colposcopy and Cervical Pathology

Colposcopy for Colposcopists and Cervical Pathologists



The British Association of Gynaecological Pathologists

bsccp The British Society for Colposcopy and Cervical Pathology

Colposcopy for Colposcopists and Cervical Pathologists

Taking a biopsy





The British Association of Gynaecological Pathologists

bsccp | The British Society for Colposcopy and Cervical Pathology

Colposcopy for Colposcopists and Cervical Pathologists

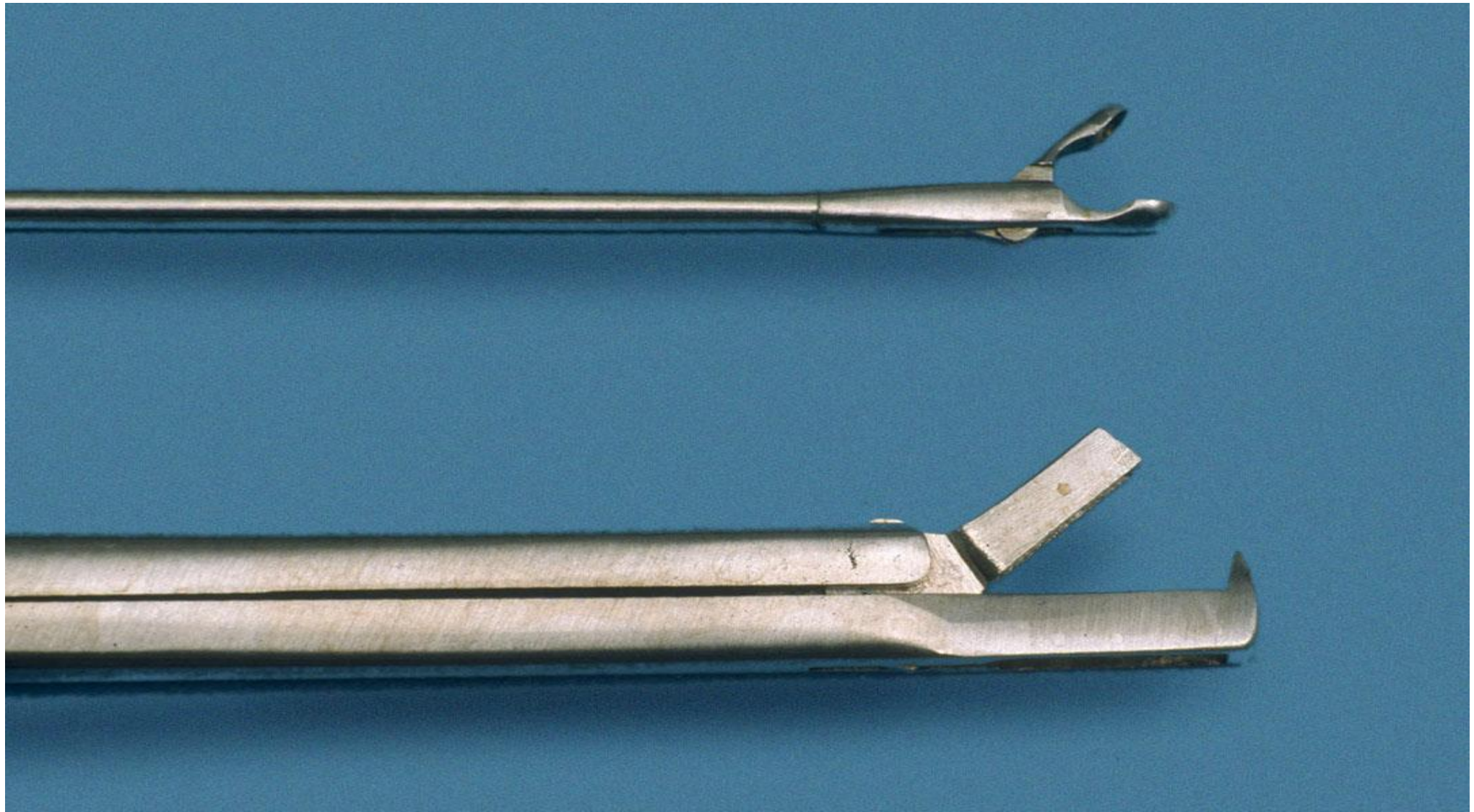

The British Association of Gynaecological Pathologists

bsccp | The British Society for Colposcopy and Cervical Pathology

Colposcopy for Colposcopists and Cervical Pathologists

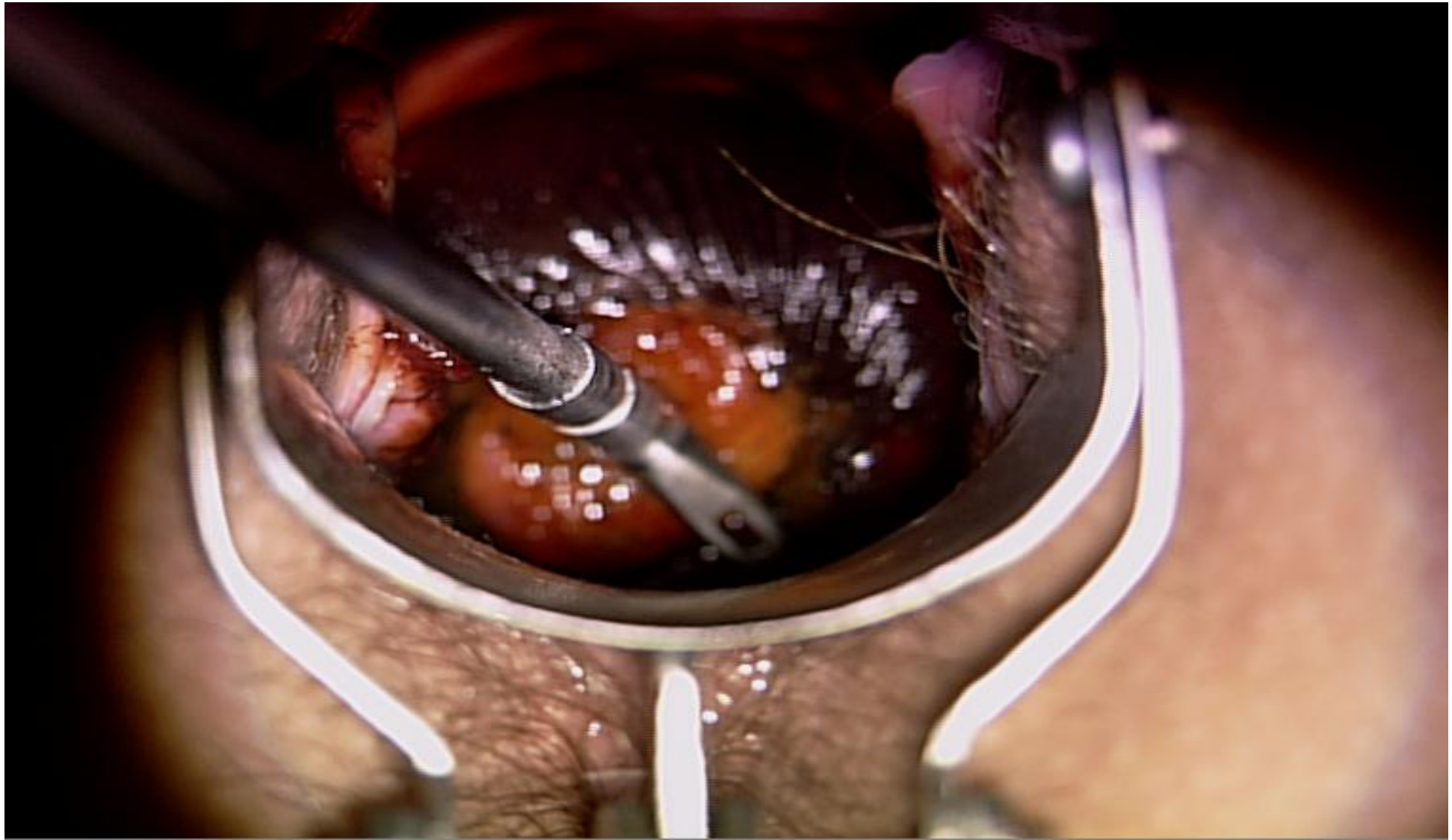

The British Association of Gynaecological Pathologists

bsccp | The British Society for Colposcopy and Cervical Pathology

Colposcopy for Colposcopists and Cervical Pathologists

Haemostasis





The British Association of Gynaecological Pathologists

bsccp The British Society for Colposcopy and Cervical Pathology

Colposcopy for Colposcopists and Cervical Pathologists



The British Association of Gynaecological Pathologists

bsccp The British Society for Colposcopy and Cervical Pathology

Colposcopy for Colposcopists and Cervical Pathologists

Standardising Colposcopy: The Swedescore

	0	1	2	Score
Aceto uptake	0 or transparent	Shady, milk	Distinct, stearin	
Margins and surface	0 el diffuse	Sharp but irregular, jagged, "geographical". Satellites	Sharp and even, difference in surface level incl. "cuffing"	
Vessels	Fine, regular	Absent	Coarse or atypical vessels	
Lesion size	<5 mm	5-15 mm or 2 quadrants	> 15 mm or 3-4 quadrants or endocervically undefined	
Iodine staining	Brown	Faintly or patchy yellow	Distinct yellow	
			Total score	

Final score	Colposcopic prediction of probable histology
0–4:	Normal/CIN1
5–6:	CIN2/CIN3
7–10:	CIN3/suspected cancer

https://screening.iarc.fr/atlascolpodetailswede

Colposcopy for Colposcopists and Cervical Pathologists

Colposcopic features suggestive of *low grade* disease (minor change)

- A smooth surface with an irregular outer border.
- Slight acetowhite change, slow to appear and fast to disappear.
- Mild, often speckled iodine positivity
- Fine punctation and fine regular mosaic

Colposcopy for Colposcopists and Cervical Pathologists

Colposcopic features suggestive of *high grade* disease (major change)

- A generally smooth surface with an sharp outer border.
- Dense acetowhite change, that appears early and is slow to resolve; it may appear oyster white.
- Iodine negativity, a yellow appearance in a previously densely white epithelium.
- Coarse punctation and wide irregular mosaics of differing size.
- Dense acetowhite change within columnar epithelium may indicate glandular disease.

The British Association of Gynaecological Pathologists

bsccp The British Society for Colposcopy and Cervical Pathology

Colposcopy for Colposcopists and Cervical Pathologists

Glandular abnormality

The British Association of Gynaecological Pathologists

bsccp The British Society for Colposcopy and Cervical Pathology

Colposcopy for Colposcopists and Cervical Pathologists

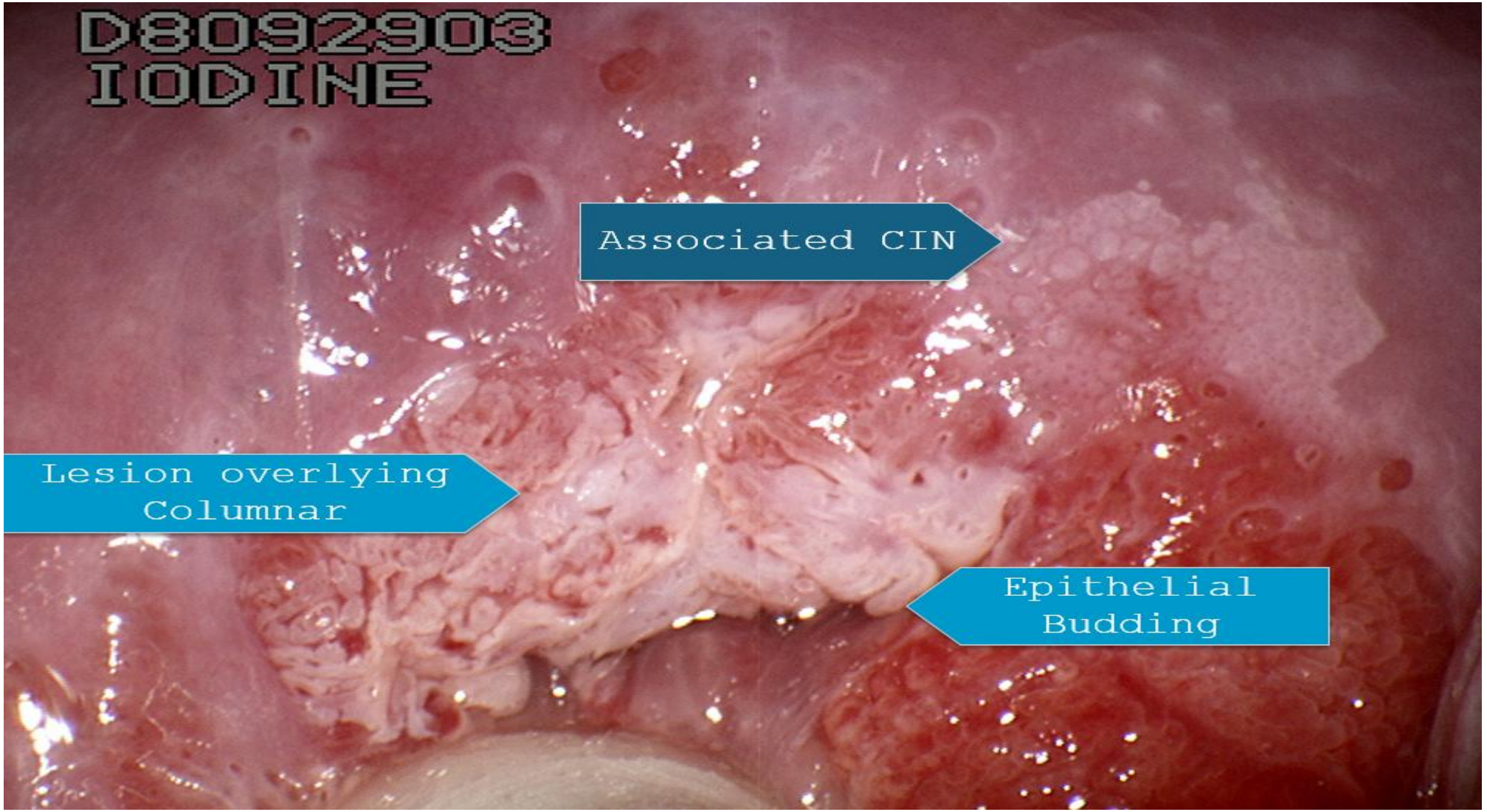

The British Association of Gynaecological Pathologists

bsccp The British Society for Colposcopy and Cervical Pathology

Colposcopy for Colposcopists and Cervical Pathologists

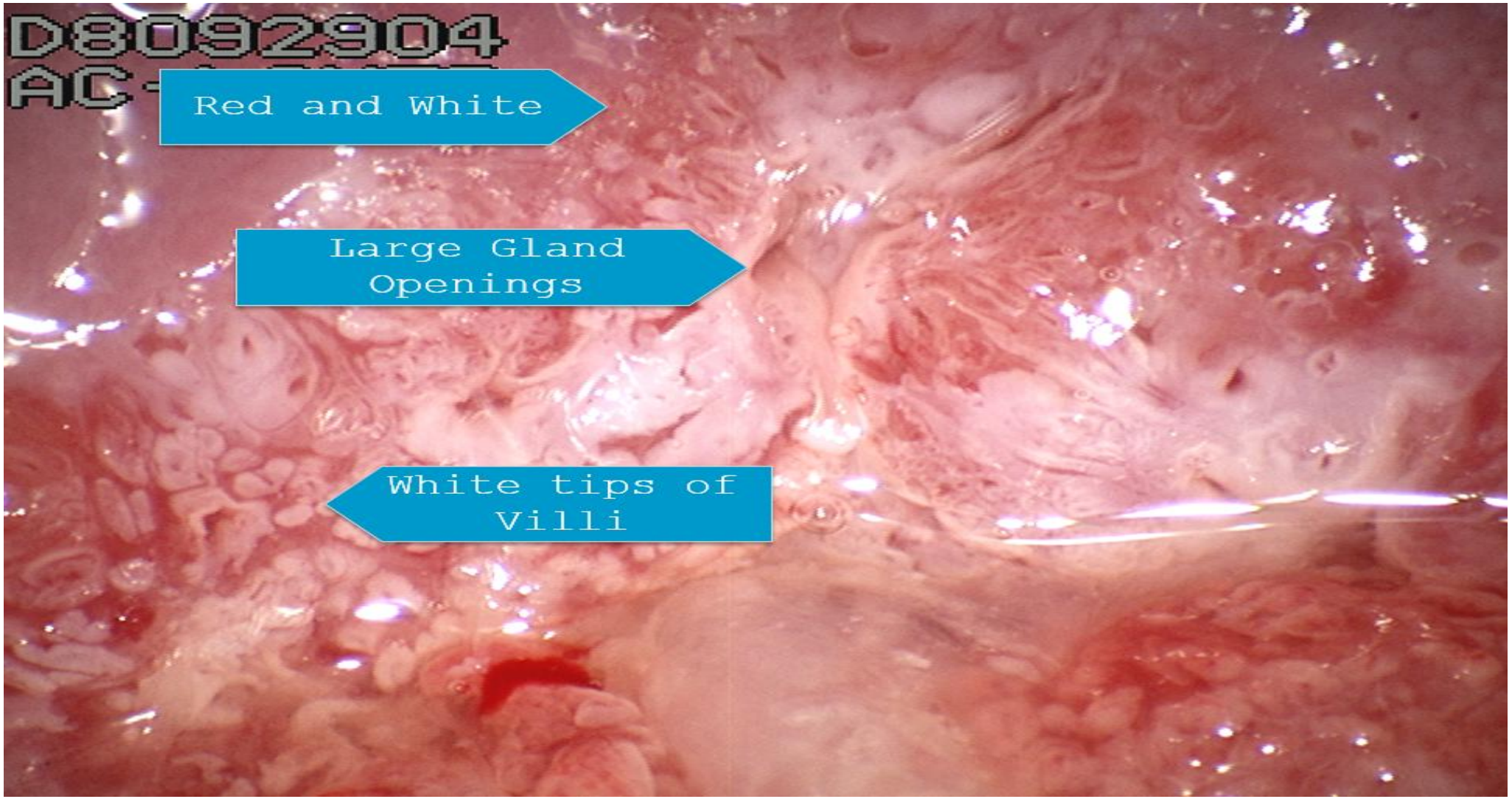

The British Association of Gynaecological Pathologists

bsccp | The British Society for Colposcopy and Cervical Pathology

Colposcopy for Colposcopists and Cervical Pathologists

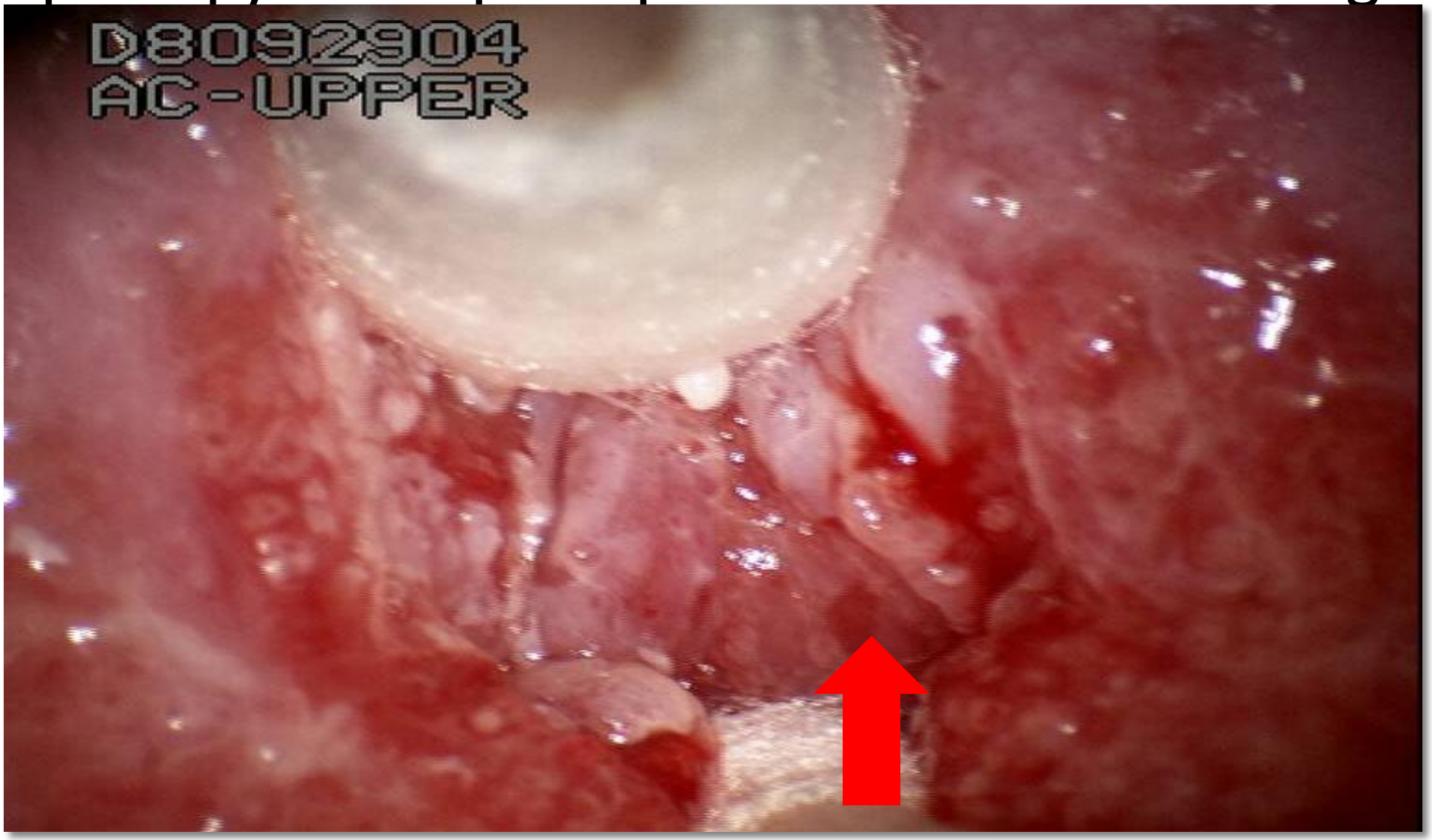

The British Association of Gynaecological Pathologists

bsccp The British Society for Colposcopy and Cervical Pathology

Colposcopy for Colposcopists and Cervical Pathologists

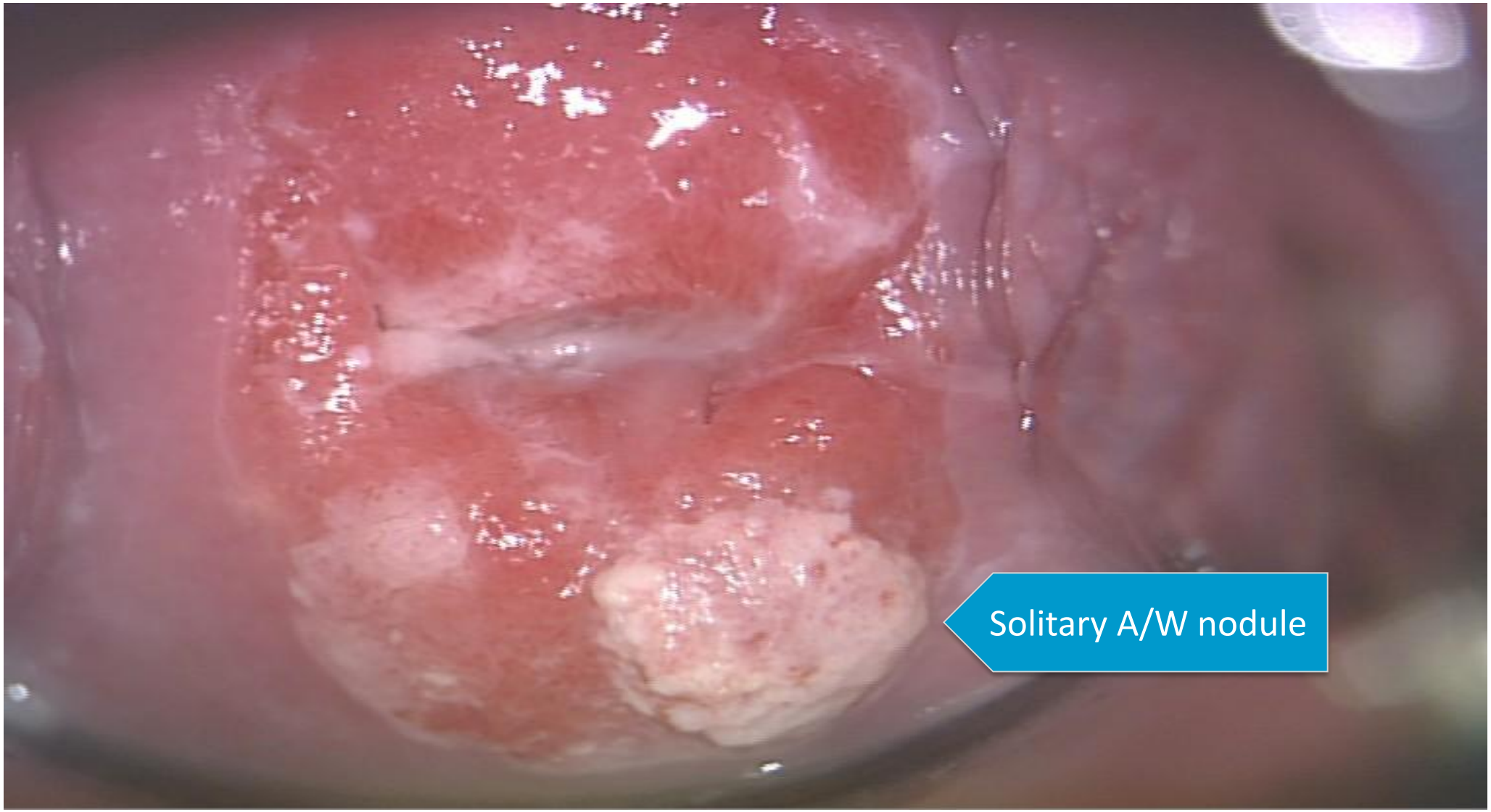

The British Association of Gynaecological Pathologists

bsccp The British Society for Colposcopy and Cervical Pathology

Colposcopy for Colposcopists and Cervical Pathologists

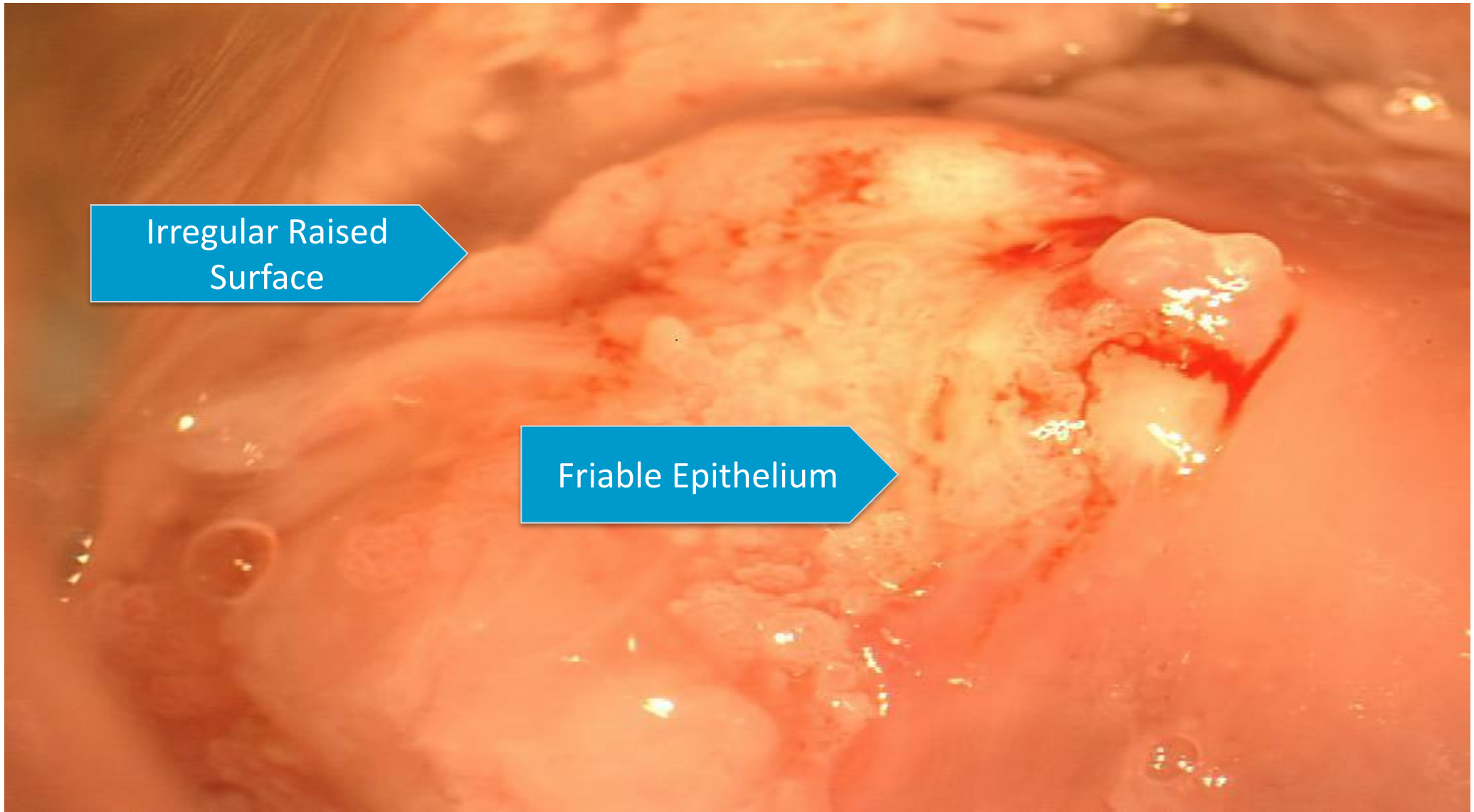

Colposcopy for Colposcopists and Cervical Pathologists

Colposcopic features suggestive of ***invasive cancer***

A. Irregular surface. Erosion or Ulceration

B. Dense Acetowhite Change.

C. Wide Irregular Punctation and Mosaic.

D. Abnormal Vessels.

The British Association of Gynaecological Pathologists

bsccp | The British Society for Colposcopy and Cervical Pathology

Colposcopy for Colposcopists and Cervical Pathologists



The British Association of Gynaecological Pathologists

bsccp The British Society for Colposcopy and Cervical Pathology

Colposcopy for Colposcopists and Cervical Pathologists

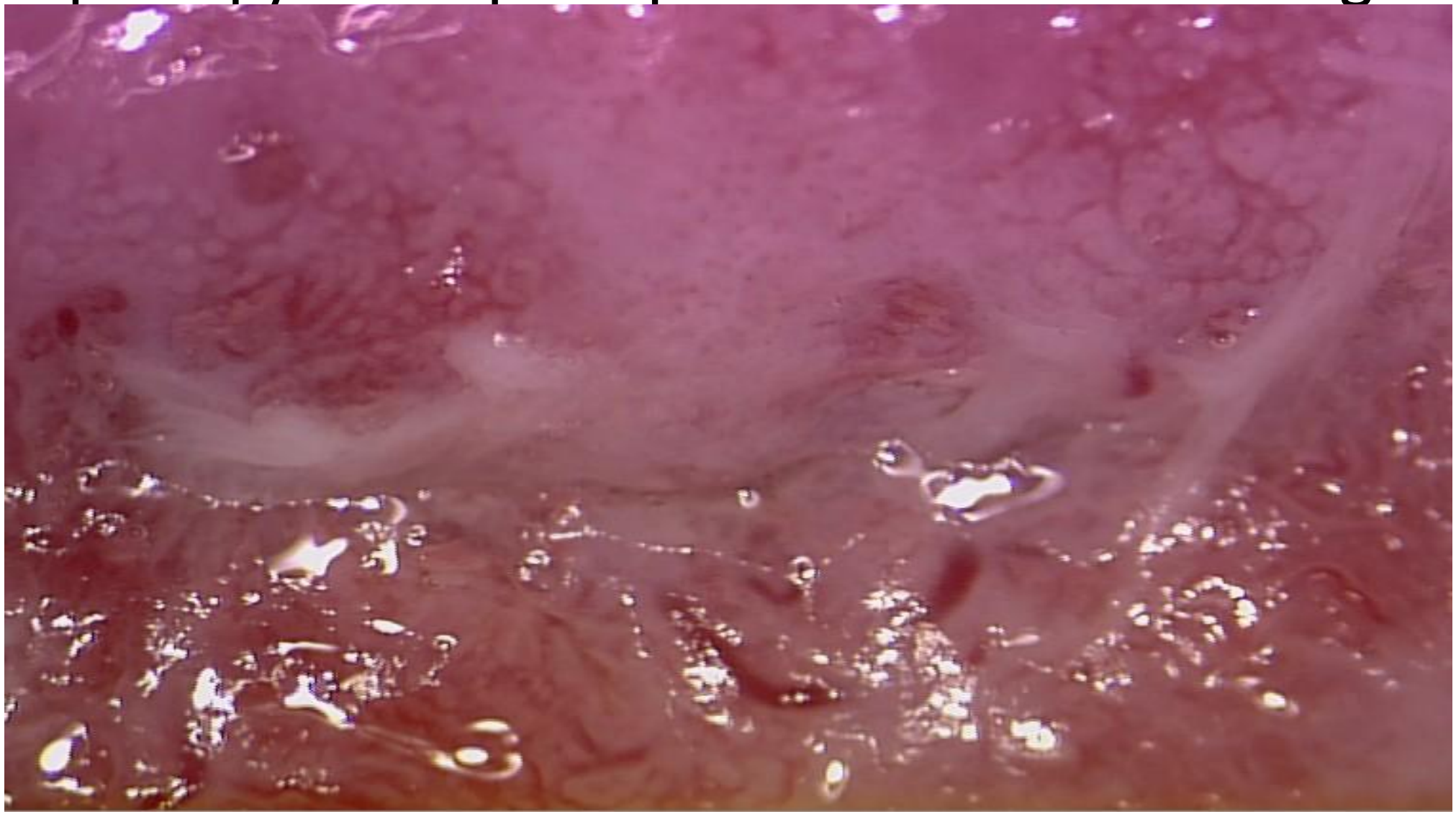

The British Association of Gynaecological Pathologists

bsccp The British Society for Colposcopy and Cervical Pathology

Colposcopy for Colposcopists and Cervical Pathologists



The British Association of Gynaecological Pathologists

bsccp | The British Society for Colposcopy and Cervical Pathology

Colposcopy for Colposcopists and Cervical Pathologists

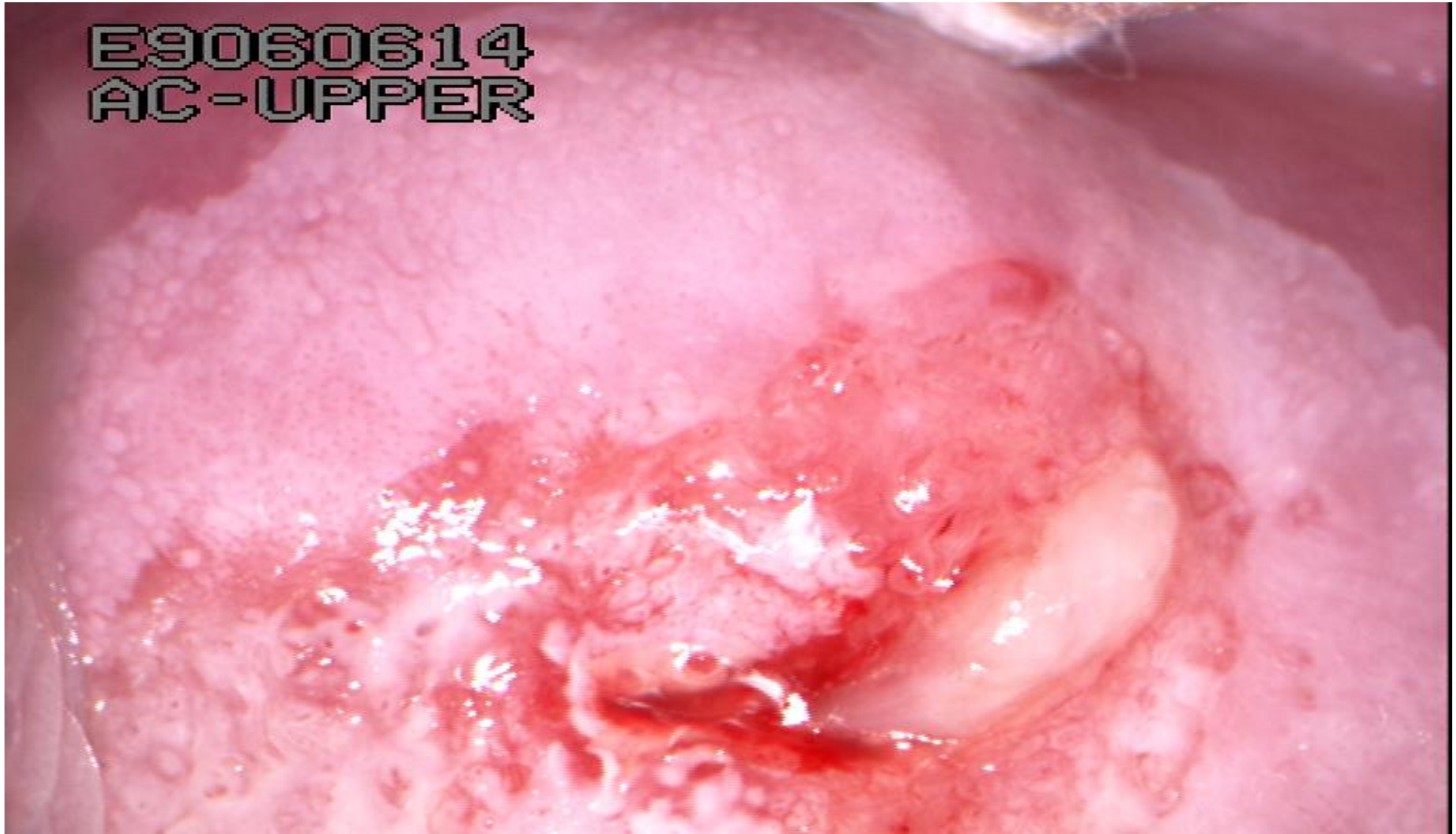

The British Association of Gynaecological Pathologists

bsccp The British Society for Colposcopy and Cervical Pathology

Colposcopy for Colposcopists and Cervical Pathologists

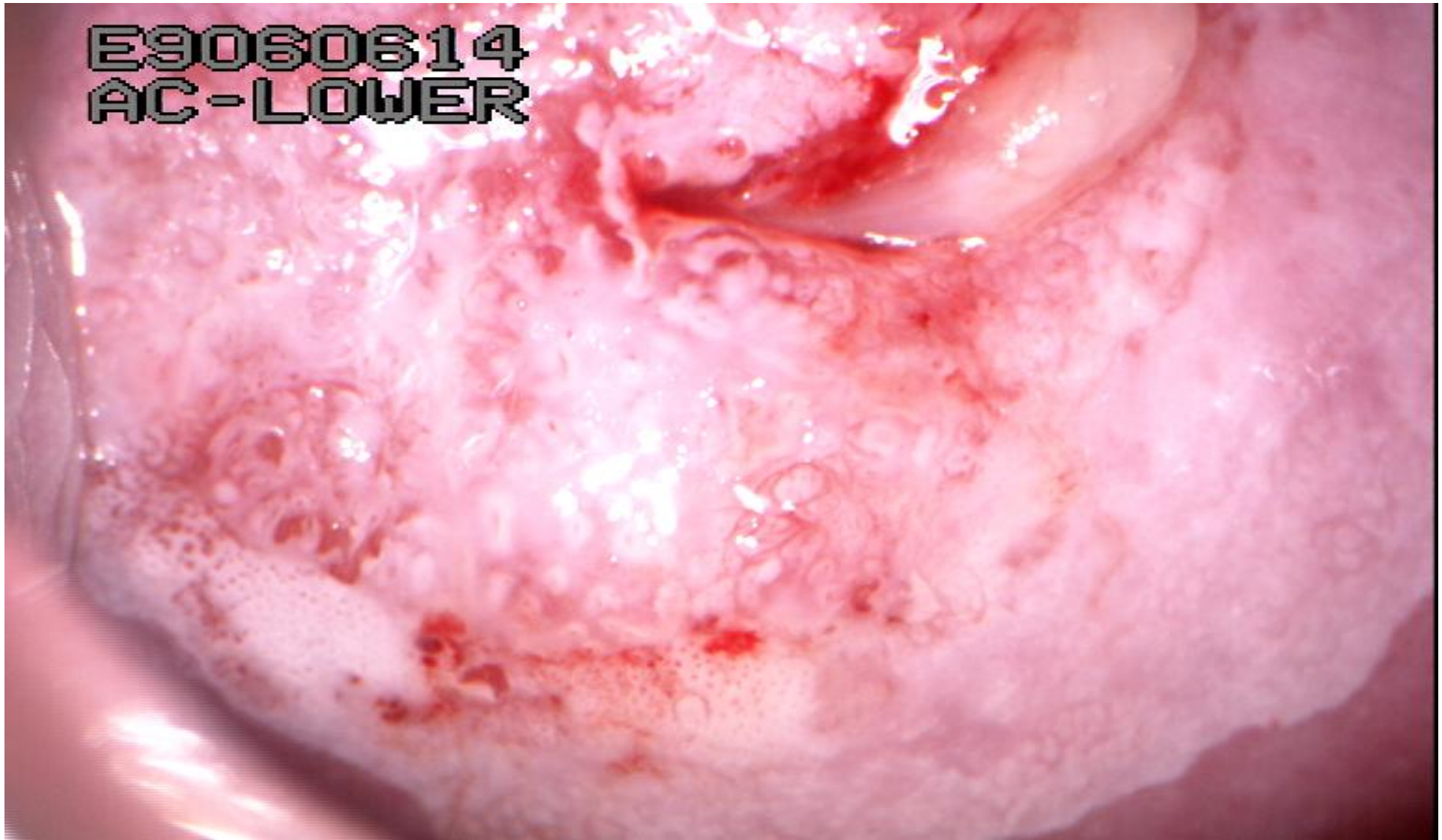

The British Association of Gynaecological Pathologists

bsccp The British Society for Colposcopy and Cervical Pathology

Colposcopy for Colposcopists and Cervical Pathologists

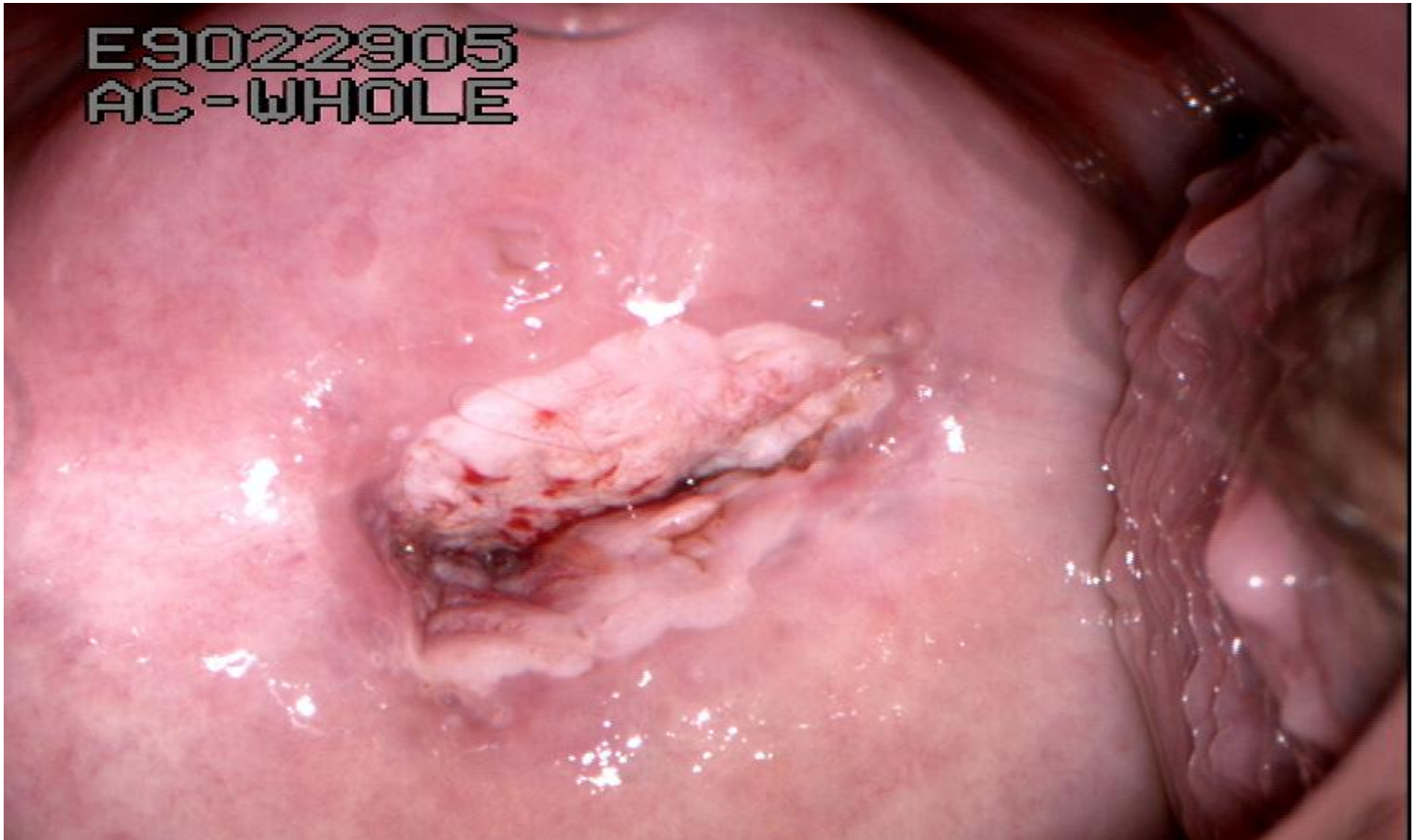

The British Association of Gynaecological Pathologists

bsccp The British Society for Colposcopy and Cervical Pathology

Colposcopy for Colposcopists and Cervical Pathologists



The British Association of Gynaecological Pathologists

bsccp | The British Society for Colposcopy and Cervical Pathology

Colposcopy for Colposcopists and Cervical Pathologists

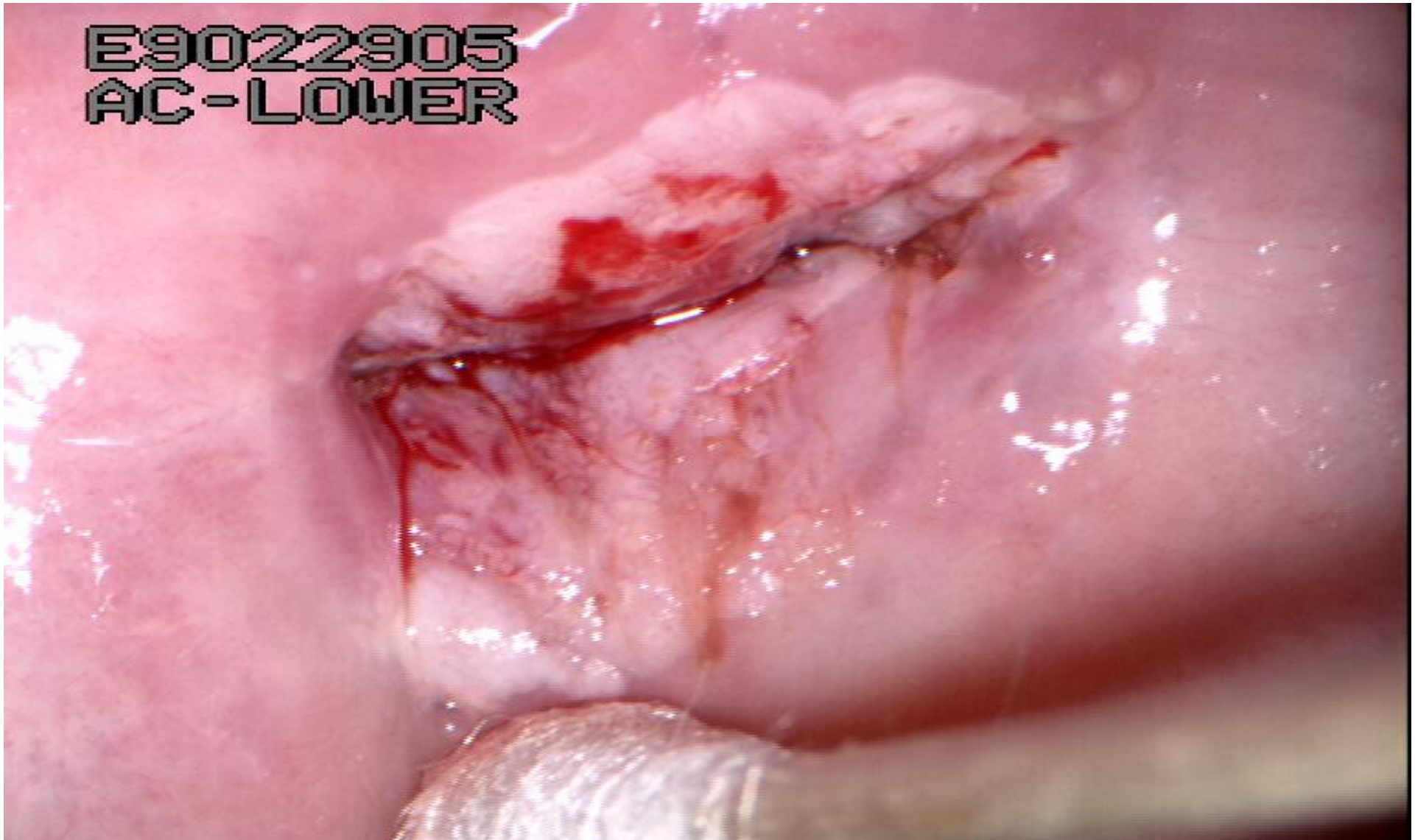

The British Association of Gynaecological Pathologists

bsccp | The British Society for Colposcopy and Cervical Pathology

Colposcopy for Colposcopists and Cervical Pathologists

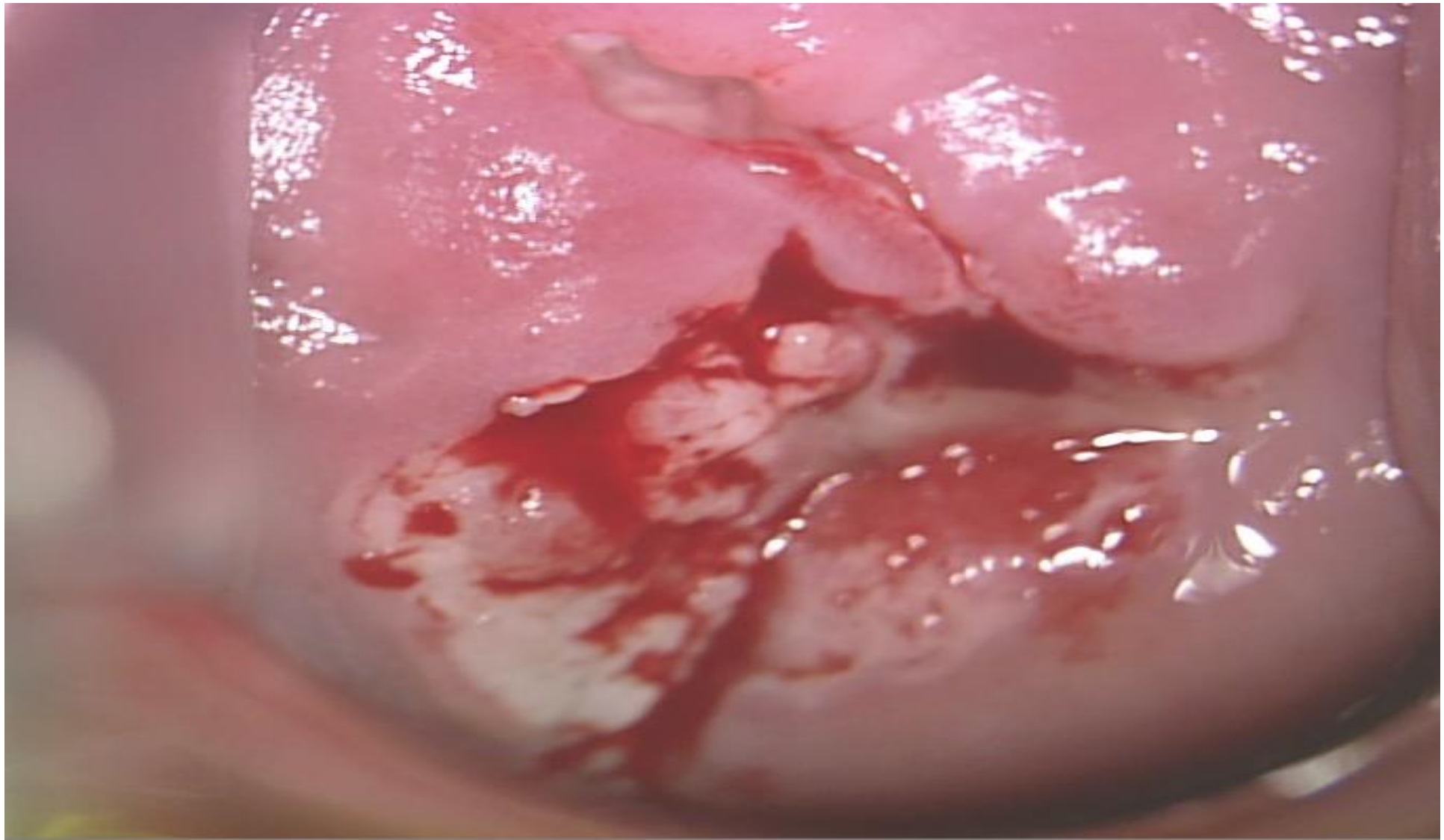

The British Association of Gynaecological Pathologists

bsccp The British Society for Colposcopy and Cervical Pathology

Colposcopy for Colposcopists and Cervical Pathologists

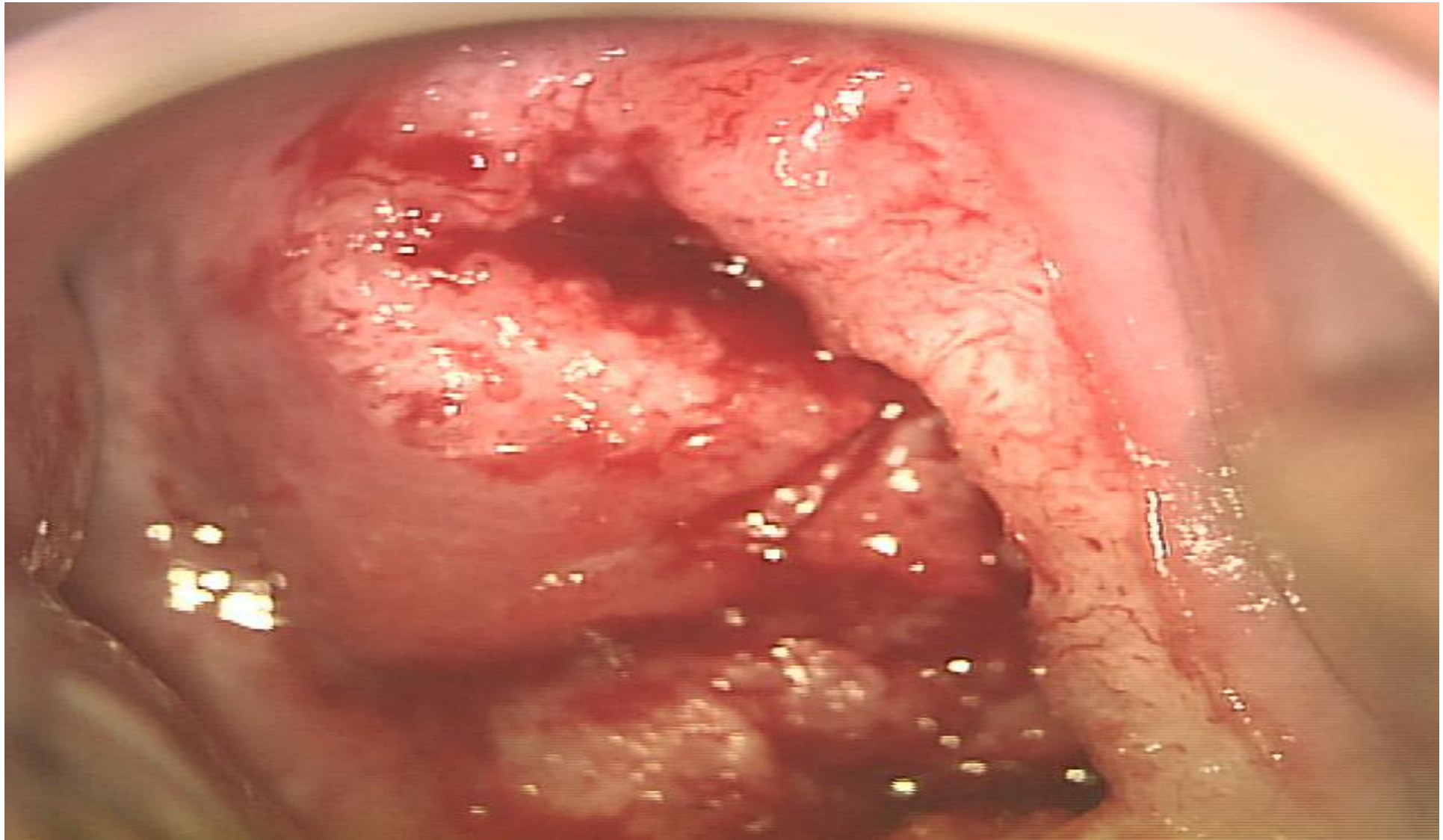

Colposcopy for Colposcopists and Cervical Pathologists

Aims of treatment

Prevent invasive cancer of the cervix

Prevent persistence of CIN

Minimum of harm to woman



Colposcopy for Colposcopists and Cervical Pathologists

Ideal treatment

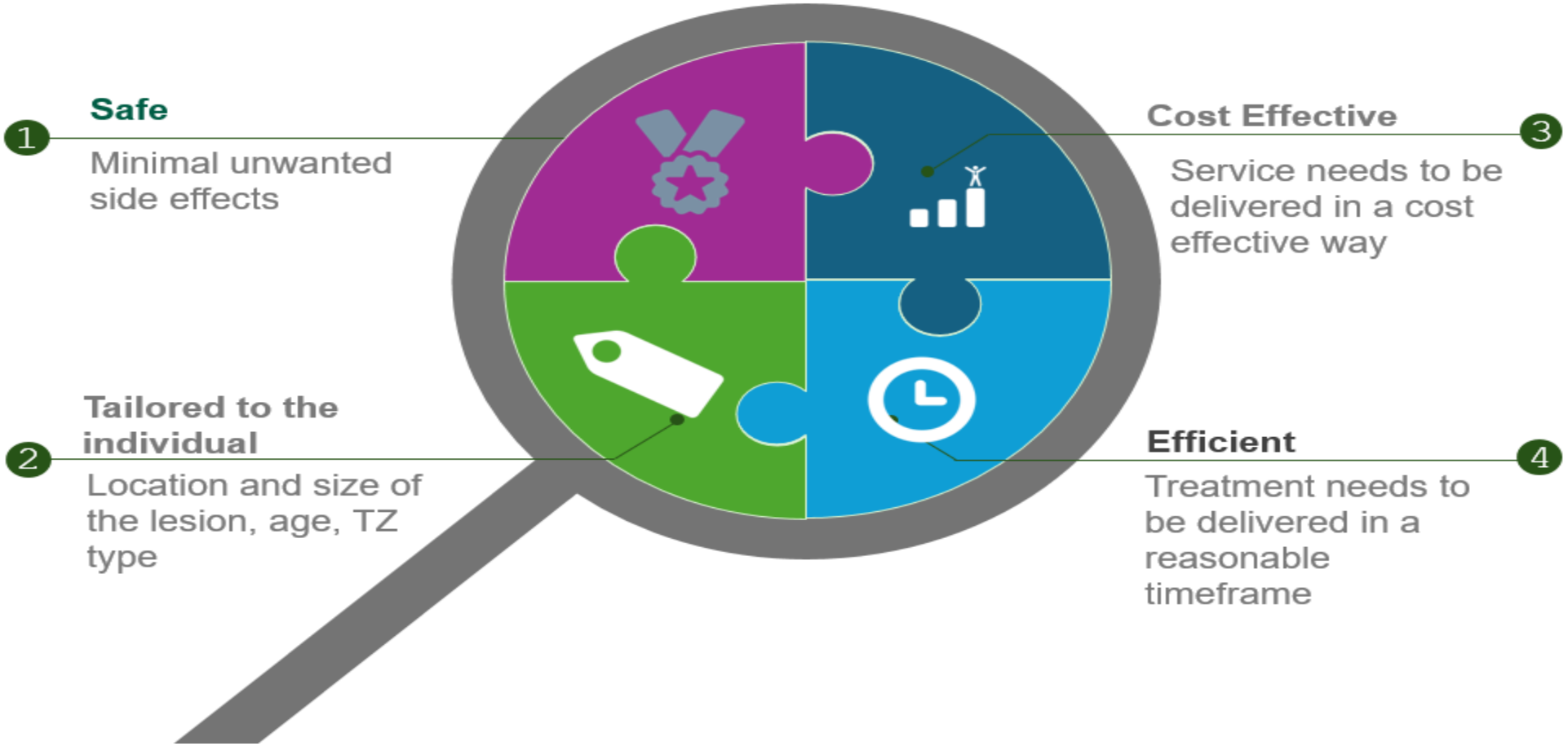

Colposcopy for Colposcopists and Cervical Pathologists

Methods for treating CIN

Ablative	Excisional
Electrocautery	**LLETZ**
Cold/thermal Coagulation	Cold Knife excision
(*Electrocoagulation Diathermy*)	Laser /NETZ /SWETZ excision
Cryotherapy (LG only)	Hysterectomy
Laser Vaporization	

Colposcopy for Colposcopists and Cervical Pathologists

Treatment principles

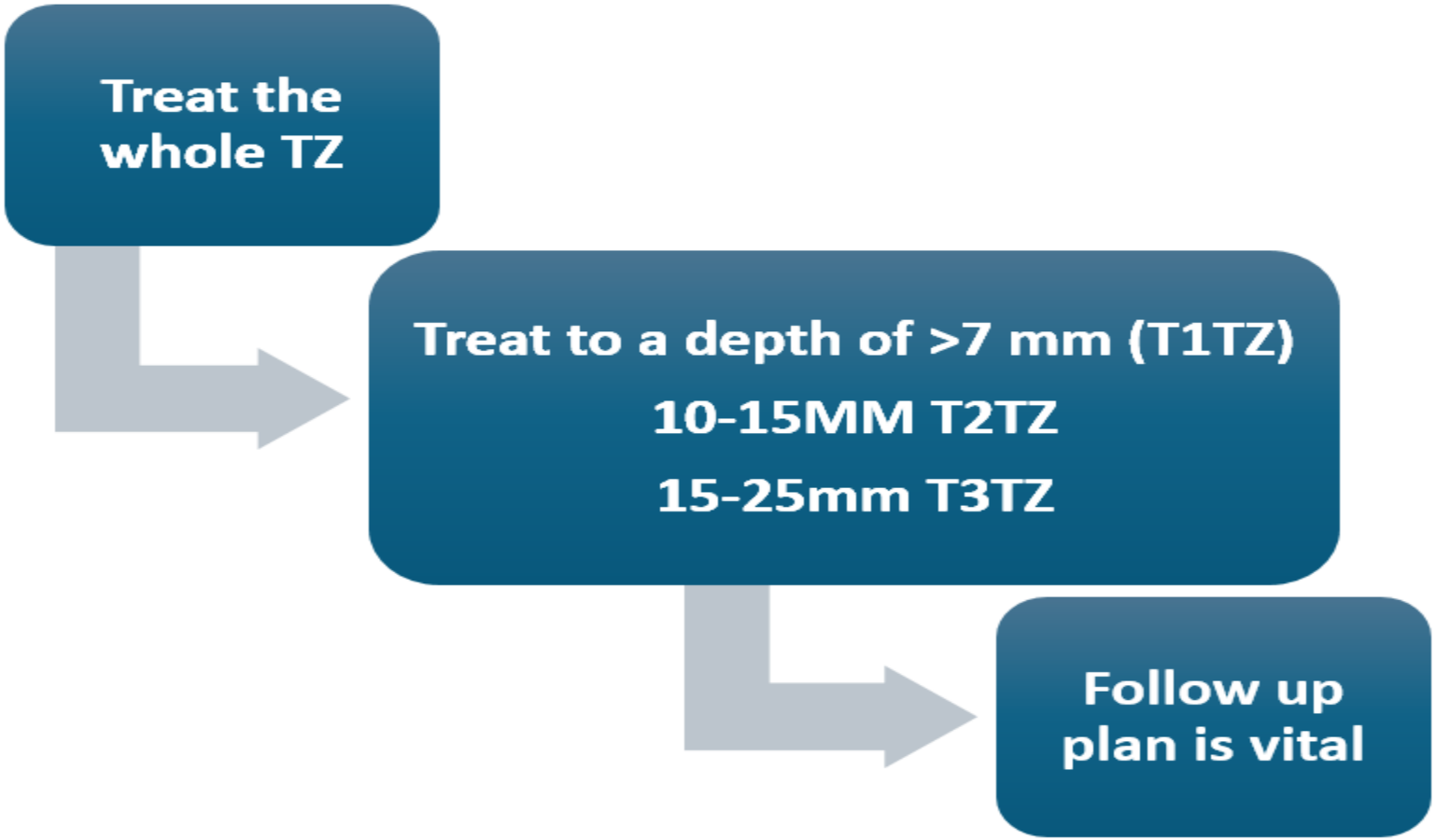

The British Association of Gynaecological Pathologists

bsccp The British Society for Colposcopy and Cervical Pathology

Colposcopy for Colposcopists and Cervical Pathologists

Summary

- Understanding the TZ is fundamental to colposcopy
- Treating the whole TZ is fundamental to successful management of CIN
- Colposcopy is one part of the assessment for pre-malignancy and early malignancy.
- One can have the wrong colposcopy impression, but with a proper knowledge of the algorithms, still manage the patient correctly

The British Association of Gynaecological Pathologists

bsccp The British Society for Colposcopy and Cervical Pathology

Colposcopy for Colposcopists and Cervical Pathologists

Thank you for your attention