The British Association of Gynaecological Pathologists

**Lecturer – Prof W Glenn McCluggage**



I am a consultant Histopathologist in Belfast Health and Social Care Trust, Belfast and an Honorary Professor in Gynaecological Pathology of Queen's University of Belfast. I have published over 670 papers in peer reviewed journals, including original publications and many invited editorials and reviews. I am on the Editorial Board of several major pathology journals (Modern Pathology, Human Pathology, Advances in Anatomic Pathology, International Journal of Gynecological Pathology, Virchows Archives) and associate editor of Histopathology. I am past President of International Society of Gynecological Pathologists and was previously secretary of this society. Previously I was President of the British Association of Gynaecological Pathologists. I have an extremely busy referral practice and receive numerous consultation cases from all over the world. I have been invited to lecture at numerous national and international meetings. I have authored or coauthored the various Royal College of Pathologists datasets in United Kingdom on reporting of gynaecological malignancies and have chaired the ICCR (International Collaboration on Cancer Reporting) panels developing international guidelines for reporting endometrial, ovarian, cervical, vulval and vaginal carcinomas. I am also the ICCR series champion for gynaecological neoplasms. I have been part of the last four World Health Organization (WHO) groups formulating the classification of Tumours of the Female Genital Tract and am one of the editors on the upcoming 2025/2026 WHO Classification.

The British Association of Gynaecological Pathologists

# Everyday Dilemmas in Gynaecological Pathology

- CHALLENGES IN REPORTING ENDOMETRIOSIS ASSOCIATED OVARIAN NEOPLASMS
- W GLENN MCCLUGGAGE
- 7/3/2025

The British Association of Gynaecological Pathologists

# Speaker disclosures

I have undertaken some paid work for GSK

# OUTLINE OF TALK

- Brief background about neoplastic transformation in endometriosis
- What are the endometriosis-associated neoplasms?
- Some problematic cases

# STROMAL ENDOMETRIOSIS

- To diagnose endometriosis usually need endometrioid-type glands and stroma; can diagnose with endometrioid-type glands and pigment laden macrophages
- Can make diagnose with endometrioid-type stroma only (stromal endometriosis)
- Stromal endometriosis- often “missed” by pathologists
- Stromal endometriosis not rare
- PMID: 19155237: 274 cases of peritoneal biopsies with diagnosis of endometriosis; stromal endometriosis in 45%; usually associated with typical endometriosis but in 6.6% of cases occurred alone

# STROMAL ENDOMETRIOSIS PERITONEUM

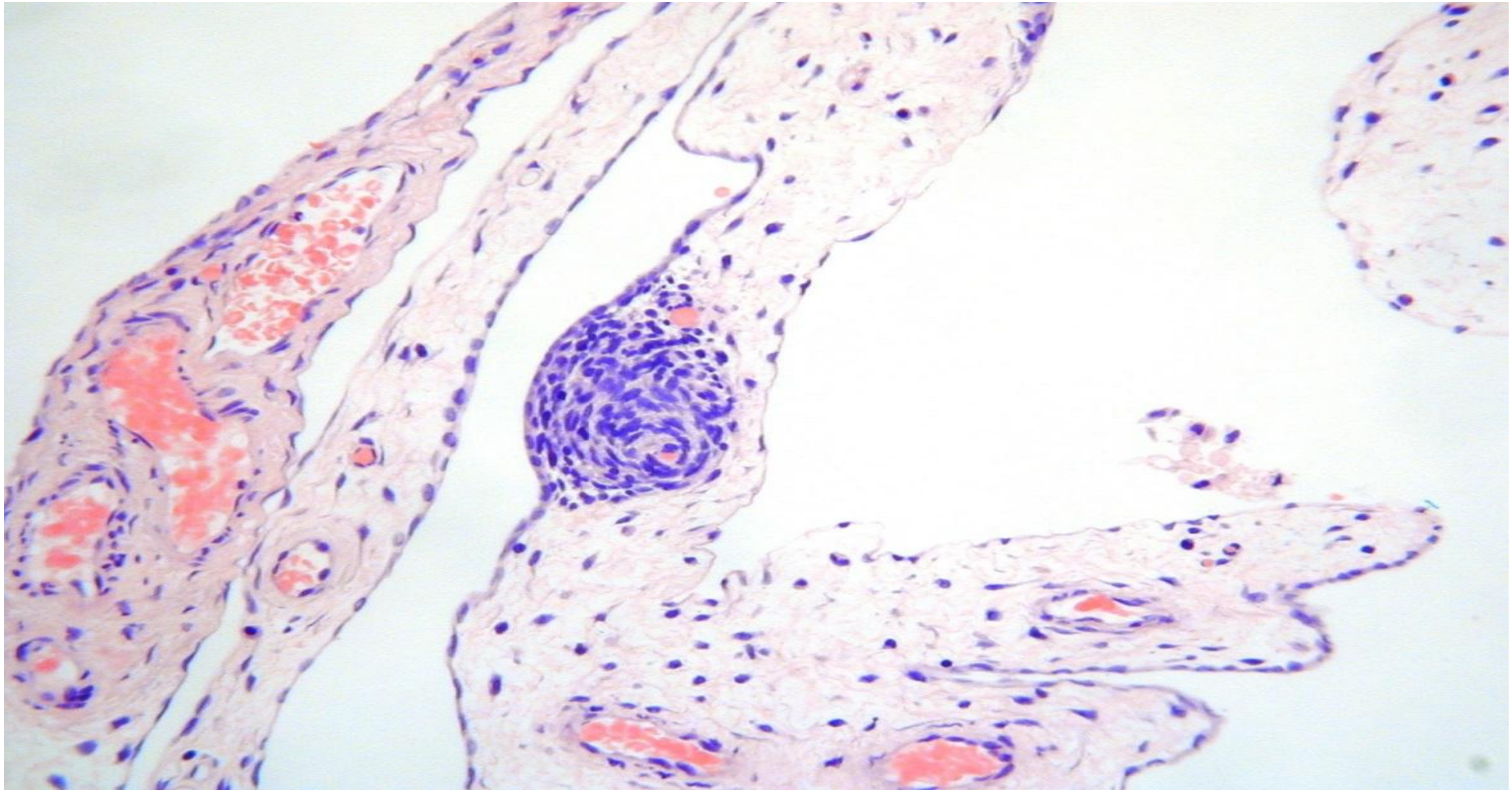

# STROMAL ENDOMETRIOSIS OVARY

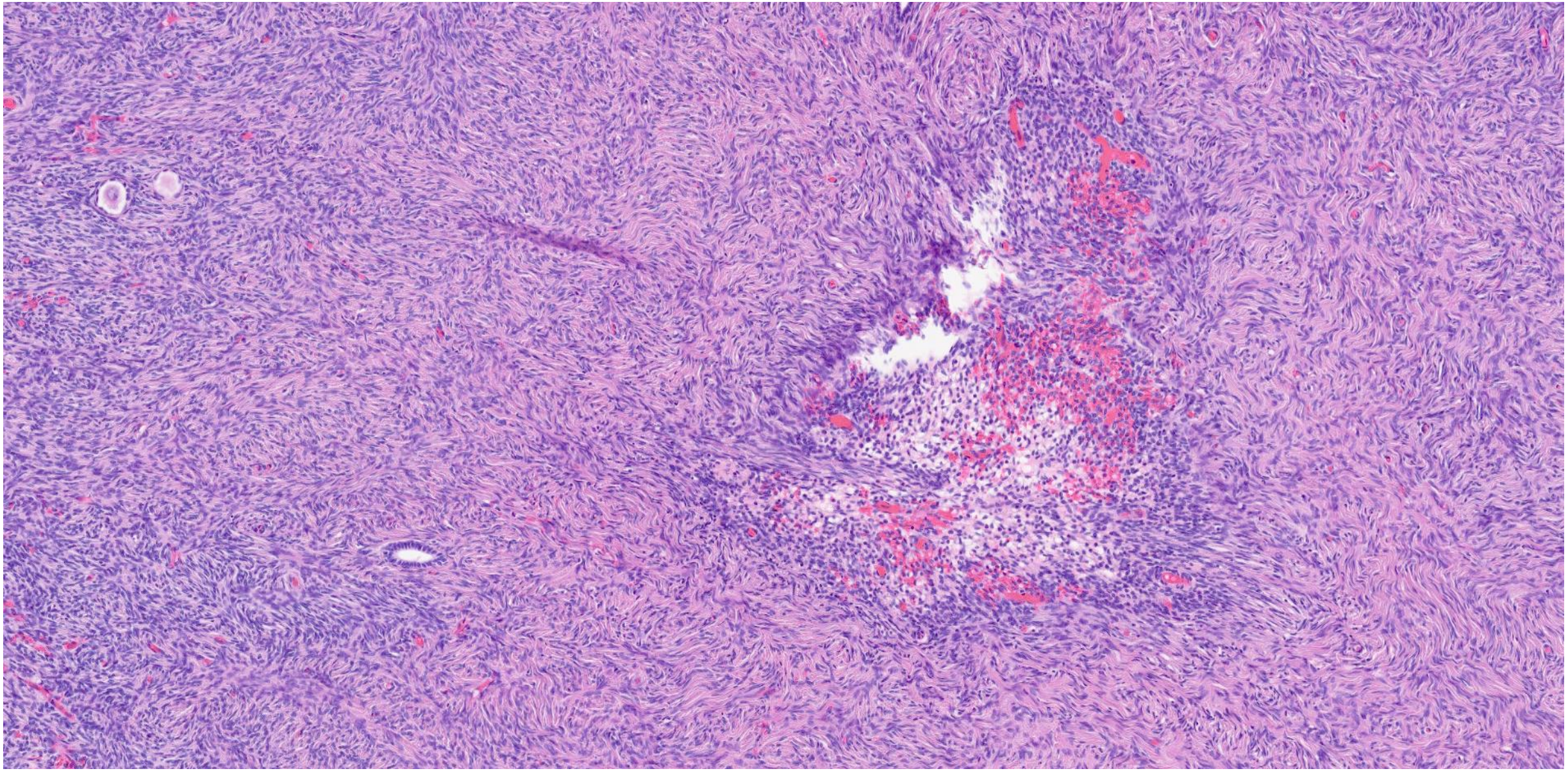

# RISK OF MALIGNANT TRANSFORMATION IN ENDOMETRIOSIS

- Endometriosis estimated to affect 10-15% of women in reproductive years
- Malignant transformation of endometriosis first reported by Sampson in 1925
- Low, but definite, propensity to undergo malignant transformation (estimated to be about 1% of cases of ovarian endometriosis)
- Patients with endometriosis estimated to have a 2- 3 fold increased risk of developing ovarian carcinoma compared to general population
- Malignant transformation most commonly occurs in ovarian endometriosis but can involve endometriosis at any site

# ENDOMETRIOSIS-ASSOCIATED NEOPLASMS (EANs)

- Most common in ovary but occasionally at extraovarian sites
- Most common are **endometrioid** and **clear cell** neoplasms (usually malignant but occasionally benign or borderline)
- **Seromucinous** neoplasms
- **Mesonephric-like** neoplasms
- Rarely LGESS, adenosarcomas, carcinosarcomas (with endometrioid or clear cell epithelial component)
- When other tumours (such as LGSC/ HGSC/ mucinous carcinoma) occur in association with endometriosis- usually regarded as coincidental

# HISTOPATHOLOGY 2020;76;76-92

Histopathology

*Histopathology* 2020, **76**, 76–92. DOI: 10.1111/his.13970

REVIEW

## Endometriosis-related pathology: a discussion of selected uncommon benign, premalignant and malignant lesions

W Glenn McCluggage

*Department of Pathology, Belfast Health and Social Care Trust, Belfast, UK*

McCluggage W G
(2020) *Histopathology* **76**, 76–92. https://doi.org/10.1111/his.13970

# PMID 36759286

REVIEW

## The diverse morphology and immunophenotype of ovarian endometrioid carcinomas

KAREN L. TALIA[1], W. GLENN MCCLUGGAGE[2]

*[1]Royal Children's Hospital, Royal Women's Hospital and Australian Centre for the Prevention of Cervical Cancer, Melbourne, Vic, Australia; [2]Department of Pathology, Belfast Health and Social Care Trust, Belfast, Northern Ireland, United Kingdom*

# REFERRAL PRACTICE- OVARIAN CARCINOMAS

- Many cases which result in referrals are endometrioid and mucinous neoplasms (more referrals compared to their relative frequency)
- Mucinous- primary or secondary; borderline or expansile invasion
- Endometrioid- multiple differentials

# UNUSUAL MORPHOLOGICAL VARIANTS OF ENDOMETRIOID CARCINOMA

- Not types or subtypes but morphological variants: most (not all) mentioned in text in WHO 2020
- Endometrioid carcinomas resembling serous borderline tumour
- “Metaplastic” changes (clear cell change, oncocytic/ oxyphilic/ eosinophilic change, squamous/ morular metaplasia)
- Endometrioid carcinoma with sex cord-like formations (Sertoliform-like)
- Endometrioid carcinoma with spindle cell differentiation/ corded and hyalinised endometrioid carcinoma (CHEC)
- Pilomatrix carcinoma-like endometrioid carcinoma
- Some of these “variants” more prevalent in ovary and some more prevalent in endometrium

# ENDOMETRIOID CARCINOMA WITH CLEAR CELL CHANGE

- Just like in endometrium, this is a difficult area
- Clear cell change may involve squamous or glandular elements
- Secretory variant of endometrioid carcinoma (subnuclear and/ or supranuclear vacuolation)
- May result in misdiagnosis as clear cell carcinoma or component of clear cell carcinoma
- Clear cells areas in endometrioid carcinomas are often positive with HNF1 beta (very non-specific marker which is positive in many carcinomas) and rarely may be Napsin A positive

# SECRETORY ENDOMETRIOID CARCINOMA

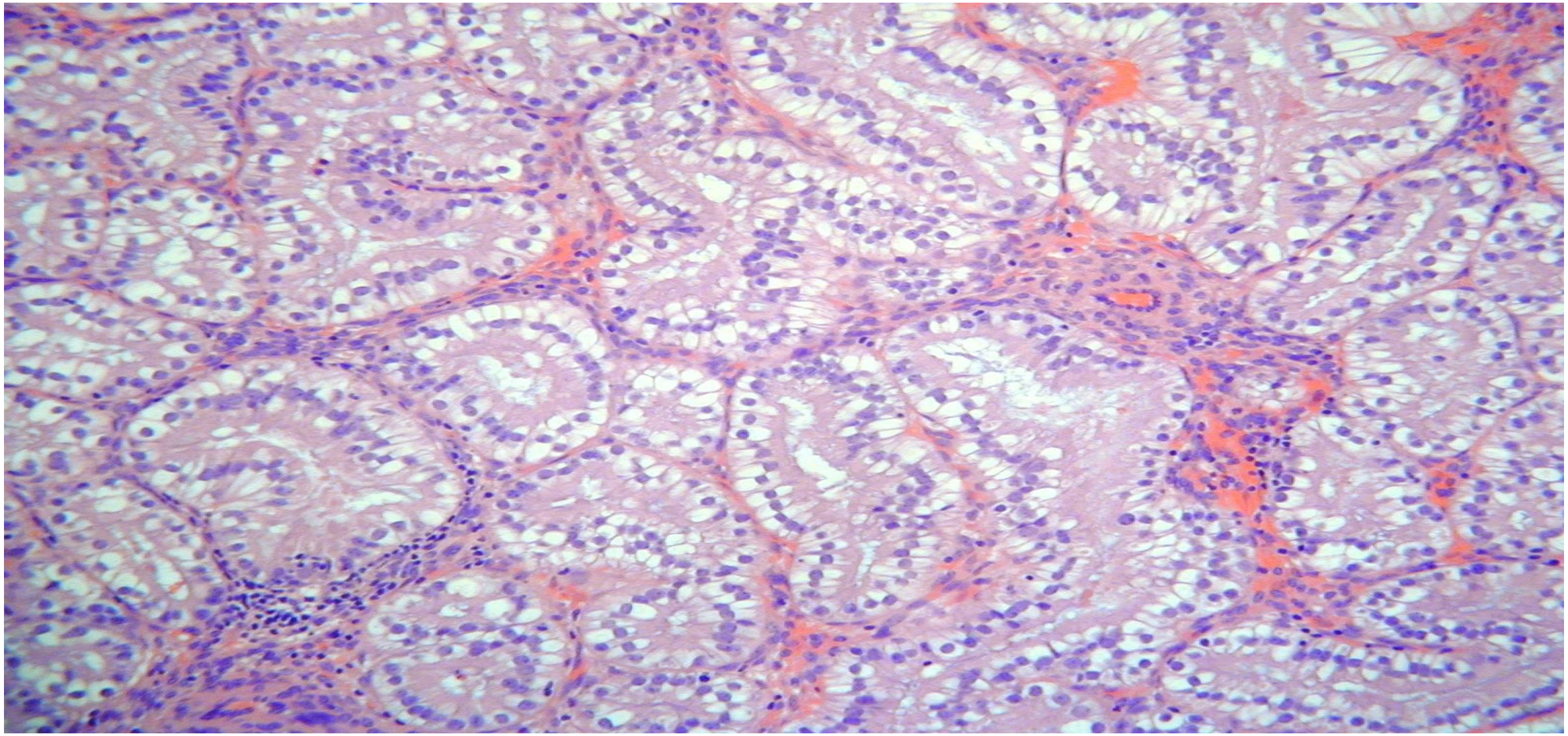

# CLEAR CELL CHANGE IN SQUAMOUS ELEMENTS IN ENDOMETRIOID CARCINOMA

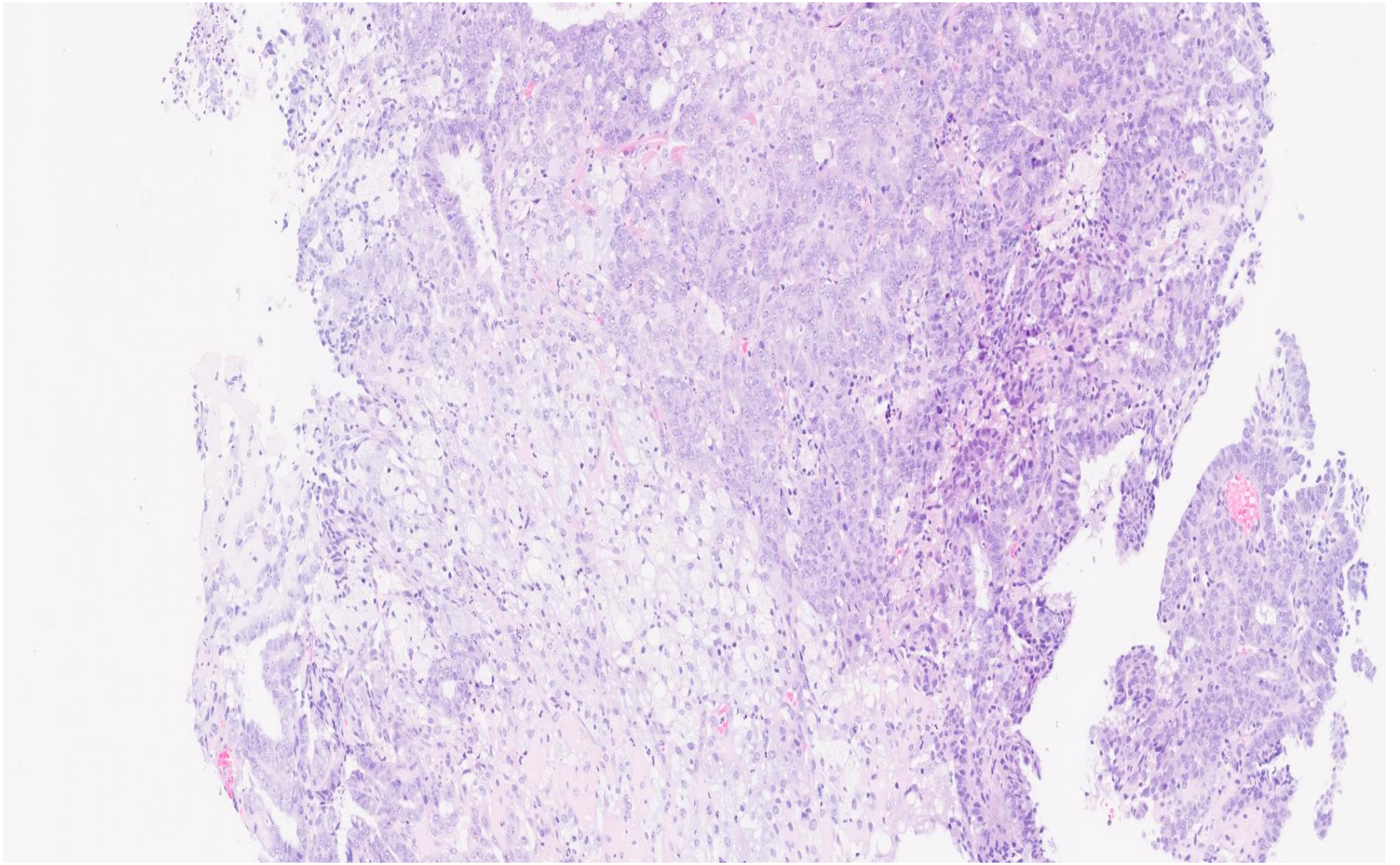

# ENDOMETRIOID CARCINOMA WITH CLEAR CELL CHANGE

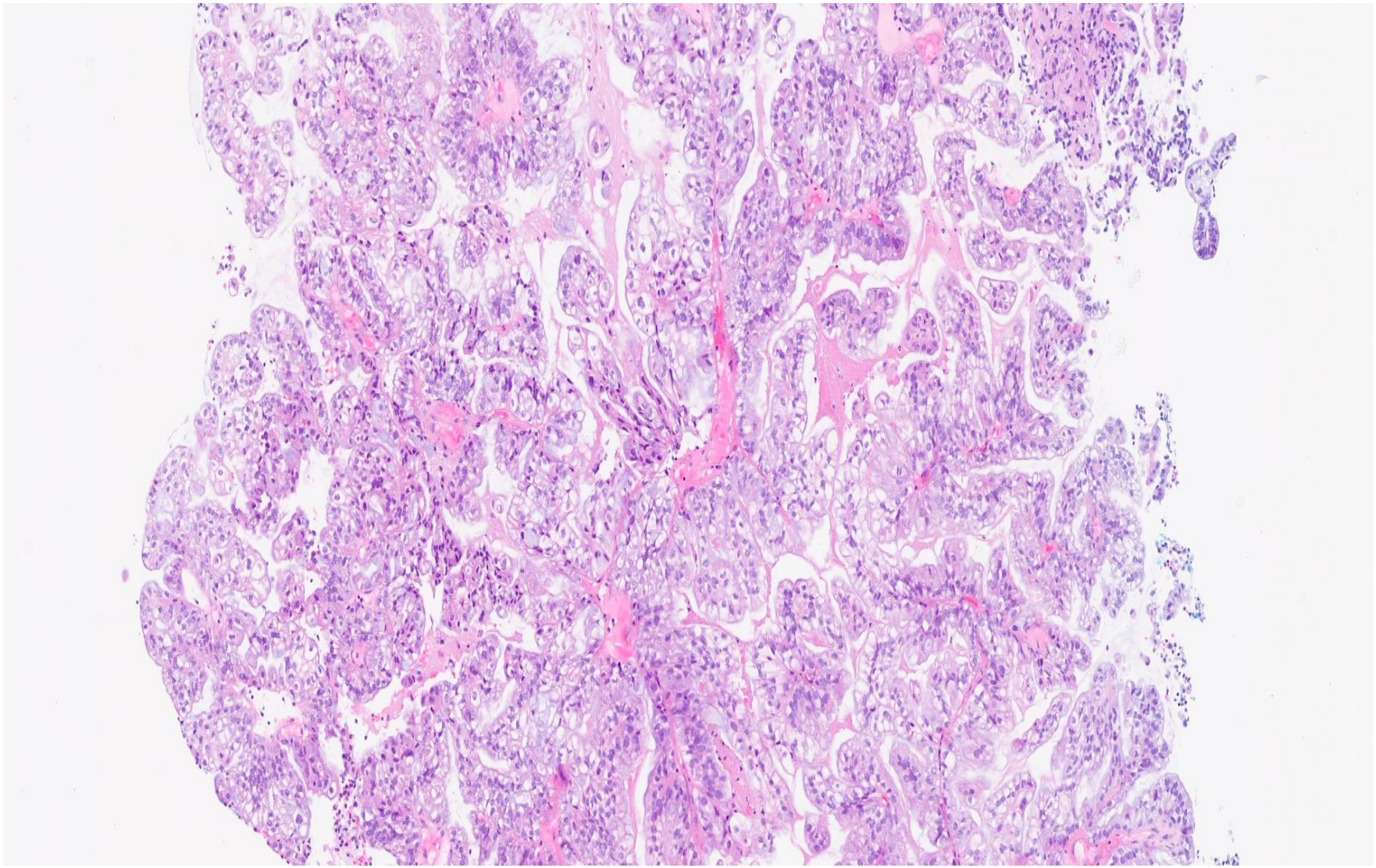

# ENDOMETRIOID CARCINOMA WITH CLEAR CELLS

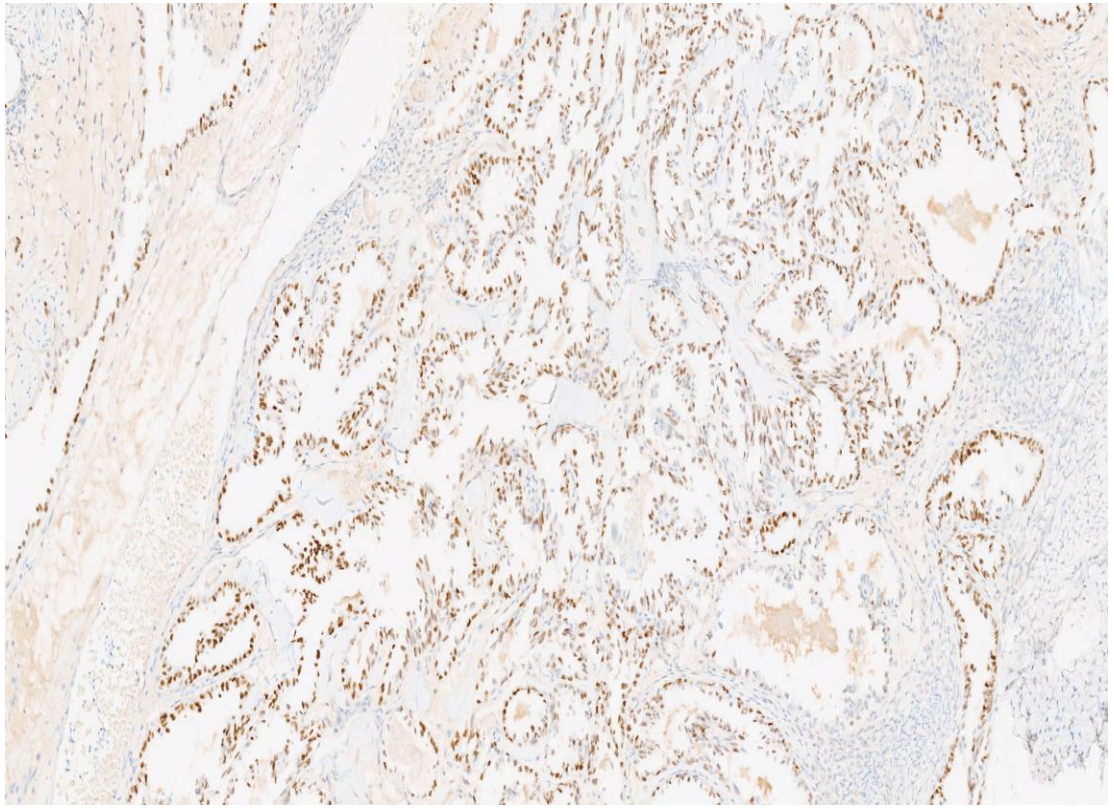

**ER**

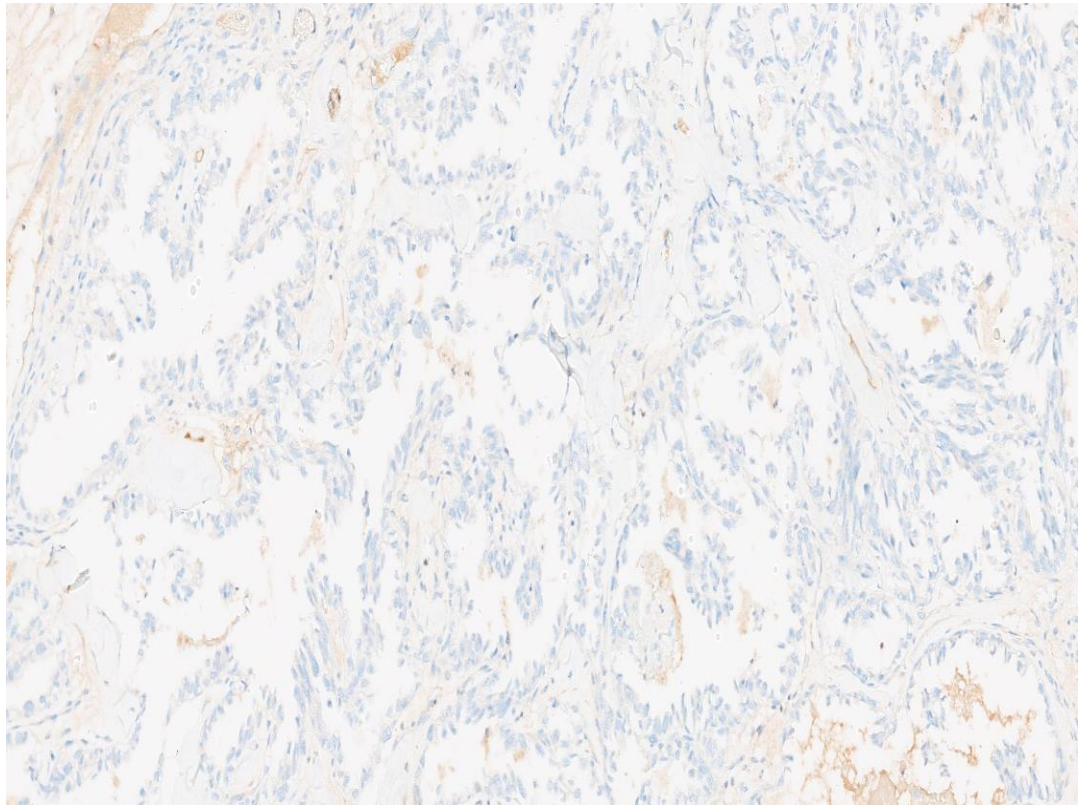

**Napsin A**

# ENDOMETRIOID CARCINOMA WITH CLEAR CELLS

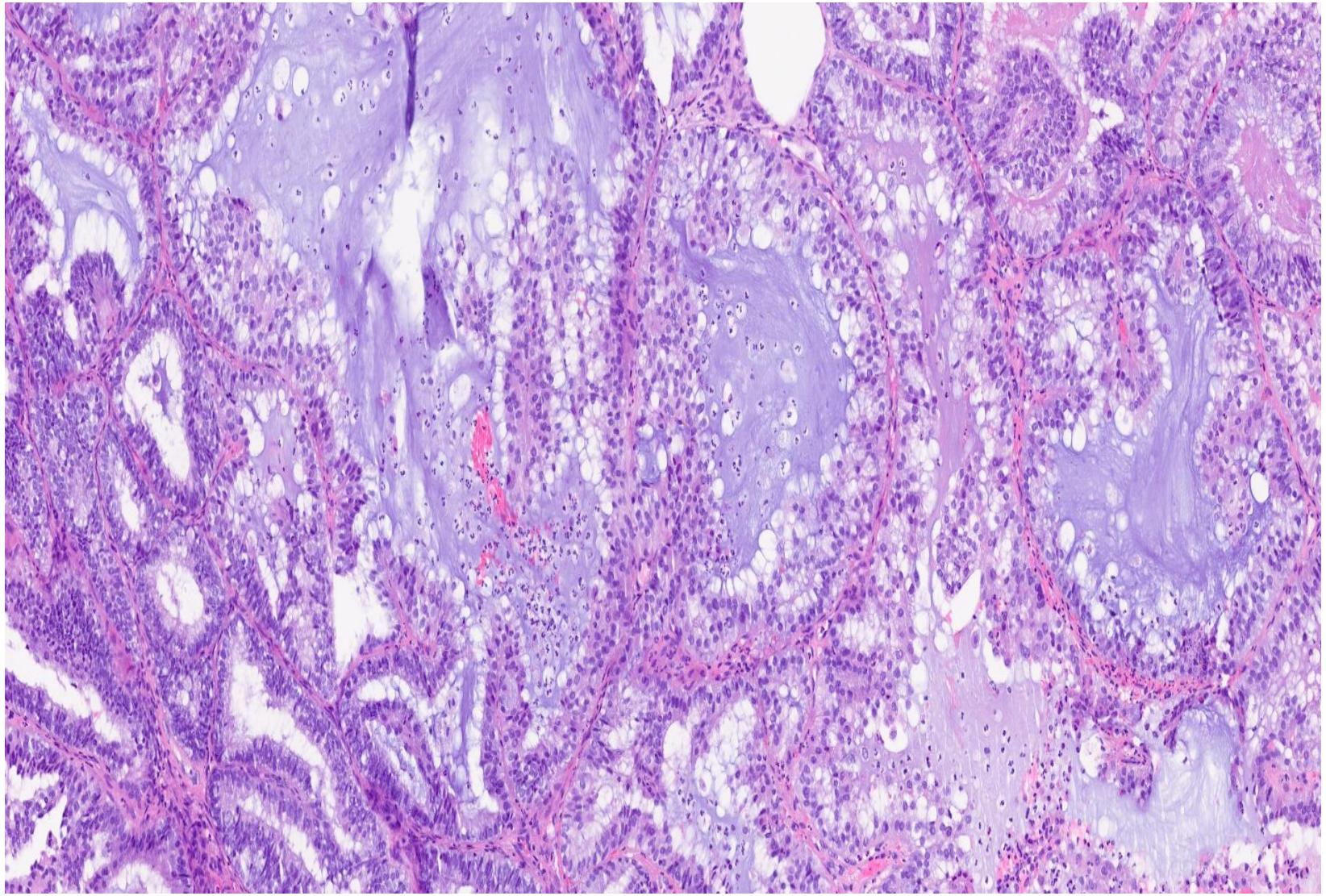

# ENDOMETRIOID CARCINOMA WITH CLEAR CELLS

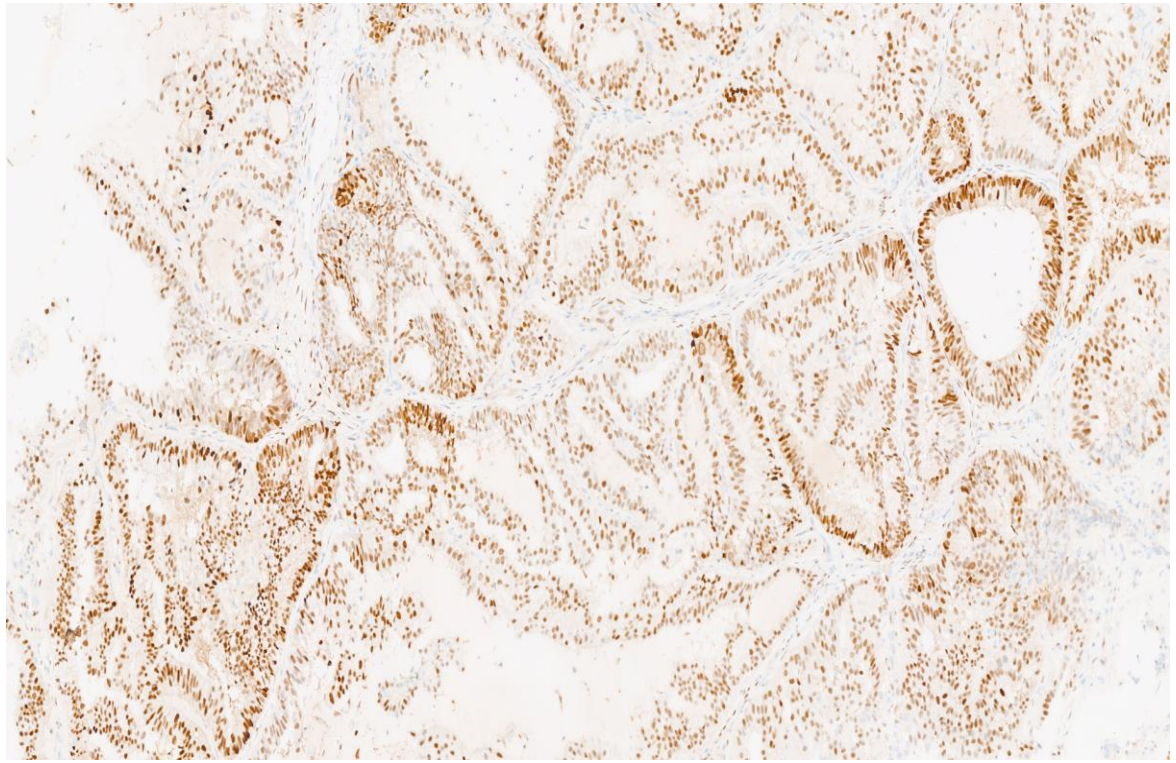

**ER**

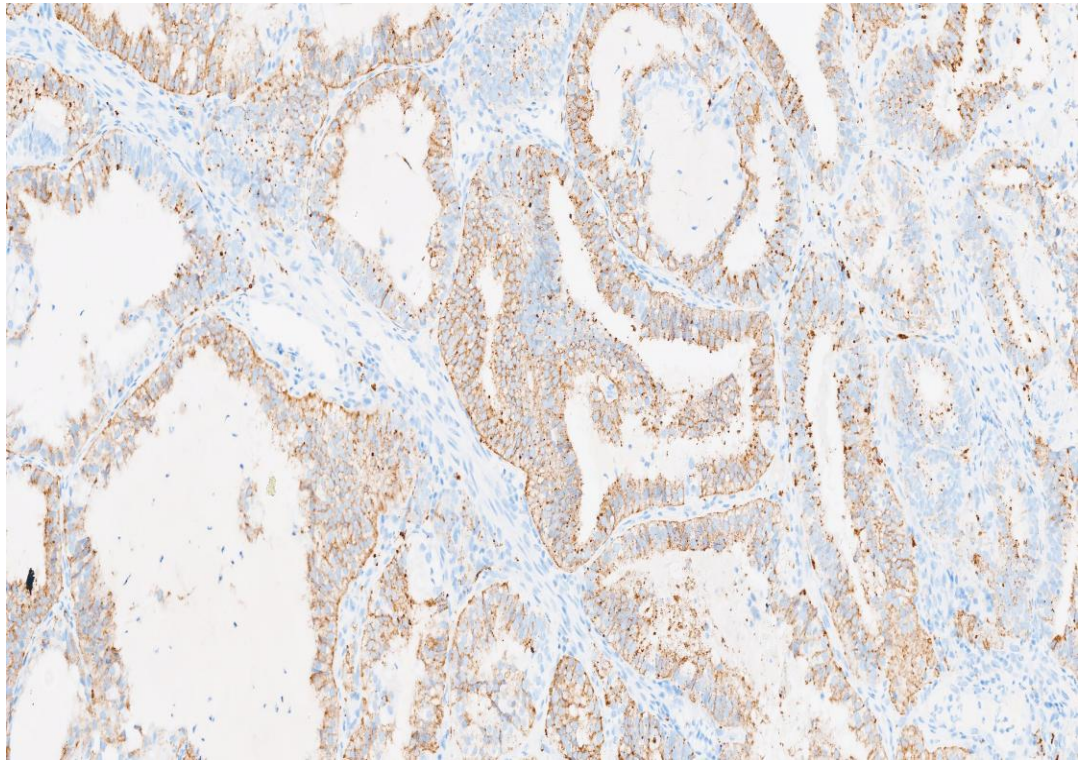

**Napsin A**

# MIXED ENDOMETRIOID AND CLEAR CELL CARCINOMA

- Most common mixed carcinoma in ovary but tendency to overdiagnose
- Association with endometriosis
- Have high threshold before making diagnosis; more likely to be endometrioid carcinoma with cytoplasmic clearing
- Need to see two different morphologies and immunophenotypes
- Mixed ovarian carcinomas are rare (<1%); historically was 10-12%

# ENDOMETRIOID CARCINOMA WITH SEX CORD-LIKE FORMATIONS

- Well-known and long emphasised problem in literature but still results in problems
- Mimicry of AGCT, Sertoli or Sertoli Leydig cell tumour
- Referred to as endometrioid carcinoma with sex cord-like elements or Sertoliform variant of endometrioid carcinoma
- Look for areas of typical endometrioid carcinoma and confirmatory endometrioid features (endometriosis, squamous elements)

# ENDOMETRIOID CARCINOMA WITH SEX CORD-LIKE FORMATIONS

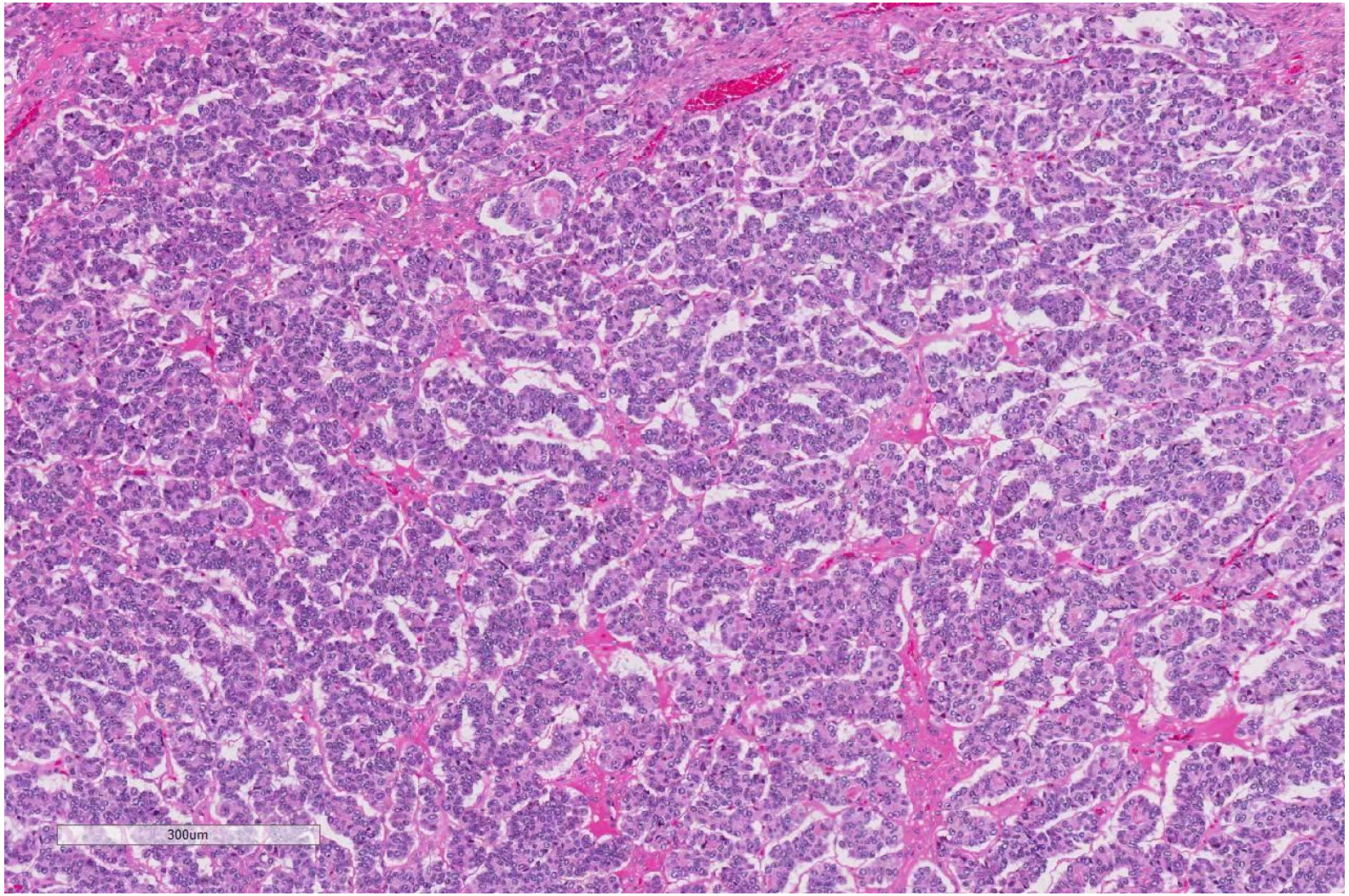

# ENDOMETRIOID CARCINOMA WITH SEX CORD-LIKE FORMATIONS

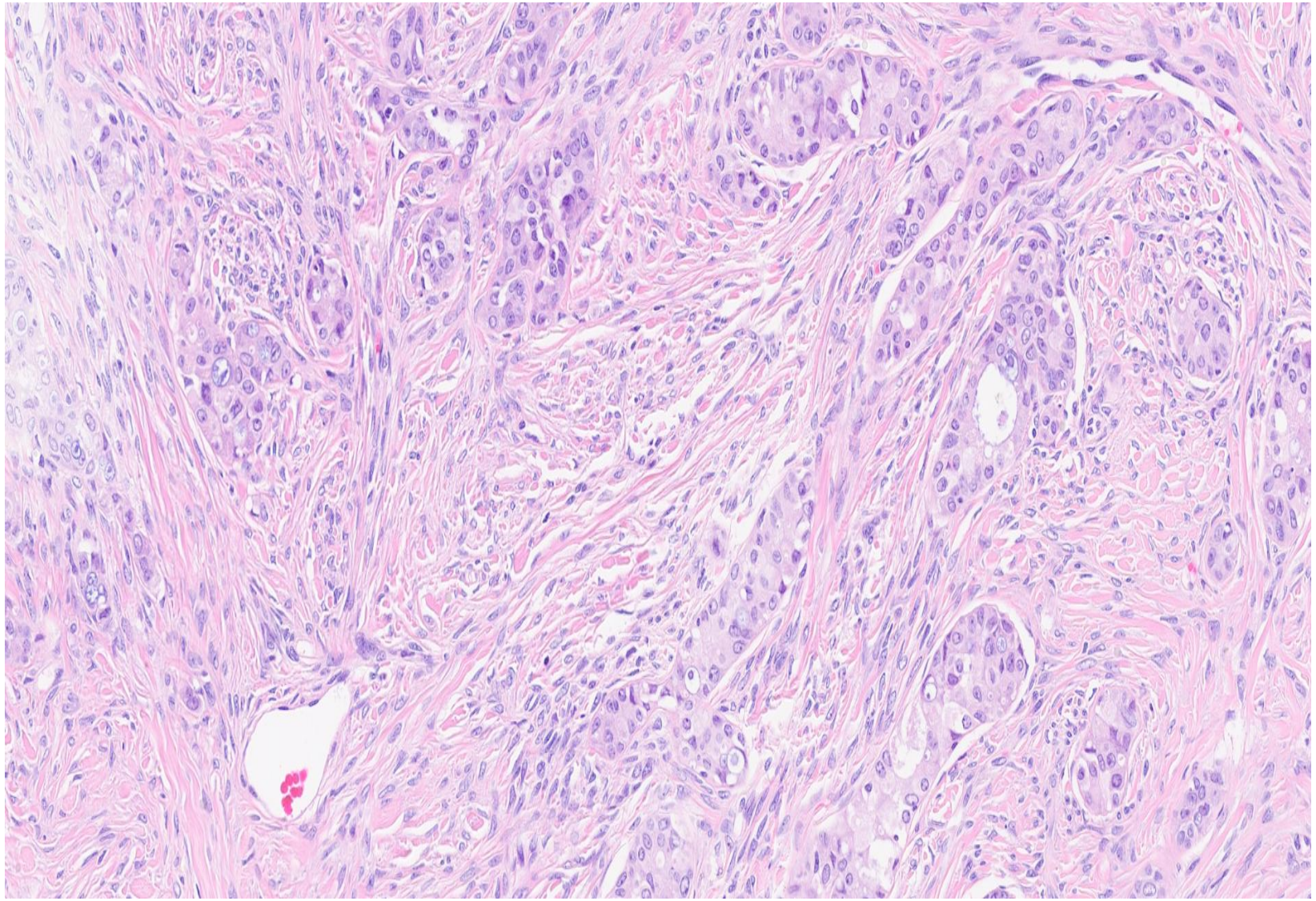

# USEFUL PANEL

- Endometrioid carcinoma- EMA, CK7, PAX8, BerEP4
- Sex cord-stromal tumour- inhibin, calretinin, SF1
- Broad spectrum cytokeratins of no value

# ENDOMETRIOID CARCINOMA WITH SEX CORD-LIKE FORMATIONS- EMA

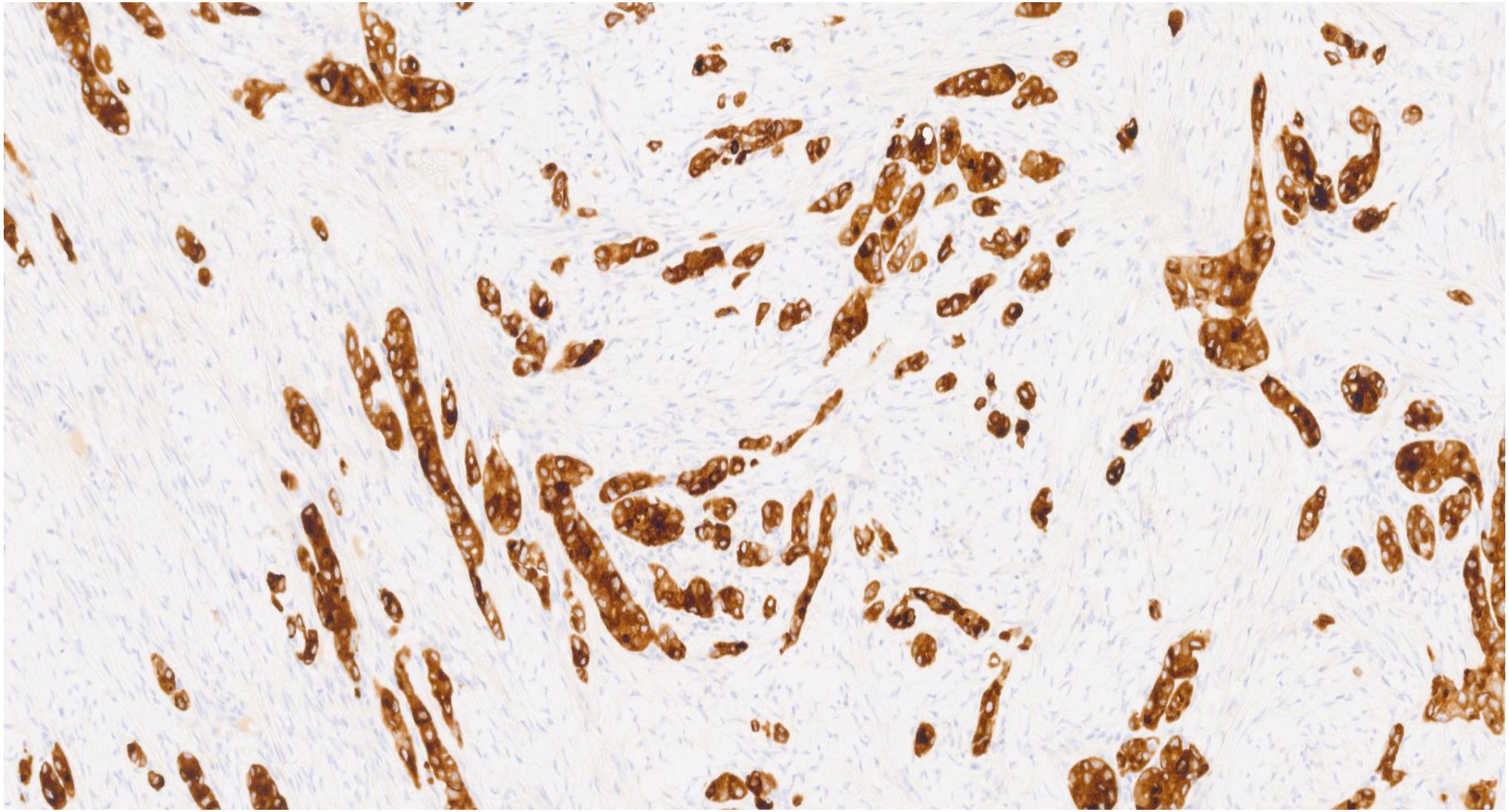

# INHIBIN IS RARELY POSITIVE IN ADENOCARCINOMAS

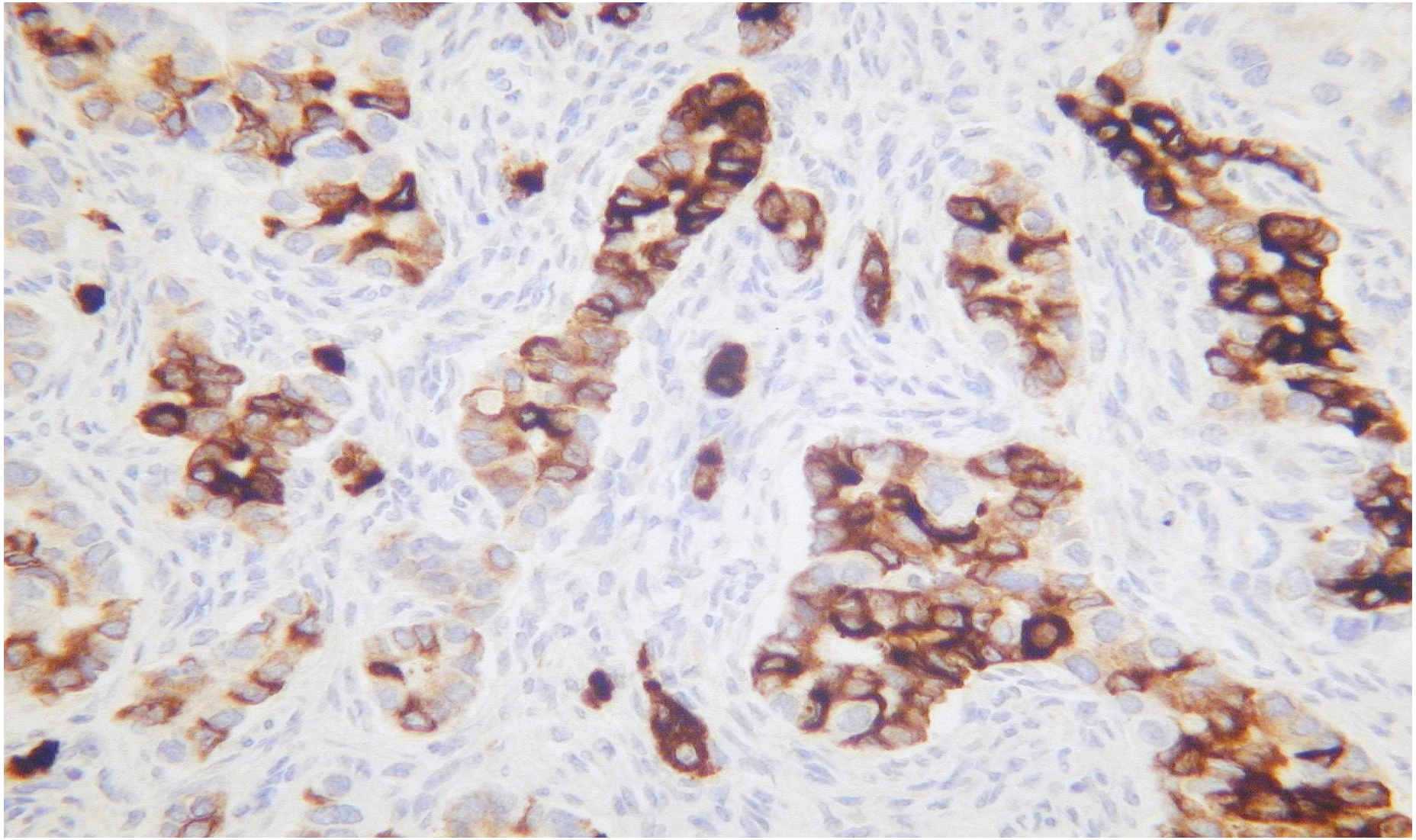

# TYPICAL IMMUNOPHENOTYPE OF OVARIAN ENDOMETRIOID CARCINOMA

- Typically diffusely positive with ER, PR, CK7, PAX8, CA125
- Vimentin may be positive or negative- literature varies widely (3-84%)
- Typically negative with WT1, CK20, CEA, CDX2, SATB2, Napsin A
- Typically p16 focally positive
- p53 usually wild-type but occasionally mutation-type (usually in grade 3 as a progression event)
- BUT EXCEPTIONS

# PROPENSITY FOR OVARIAN ENDOMETRIOID CARCINOMA TO EXHIBIT ABERRANT IMMUNOPHENOTYPE

- Propensity for unusual/ aberrant immunophenotype (as well as morphology)
- Immunohistochemistry often performed, especially with unusual morphology
- May be negative with CK7, CA125, PAX8, ER, PR individually or in combination
- May be positive with CK20, CDX2, SATB2, TTF1, WT1 individually or in combination
- May be positive with neuroendocrine markers
- Don’t need diagnostic immunohistochemistry in classic cases of ovarian endometrioid carcinoma; I do ER, MMR and p53 for molecular classification and Lynch syndrome triage

# PROPENSITY FOR OVARIAN ENDOMETRIOID CARCINOMA TO EXHIBIT ABERRANT IMMUNOPHENOTYPE

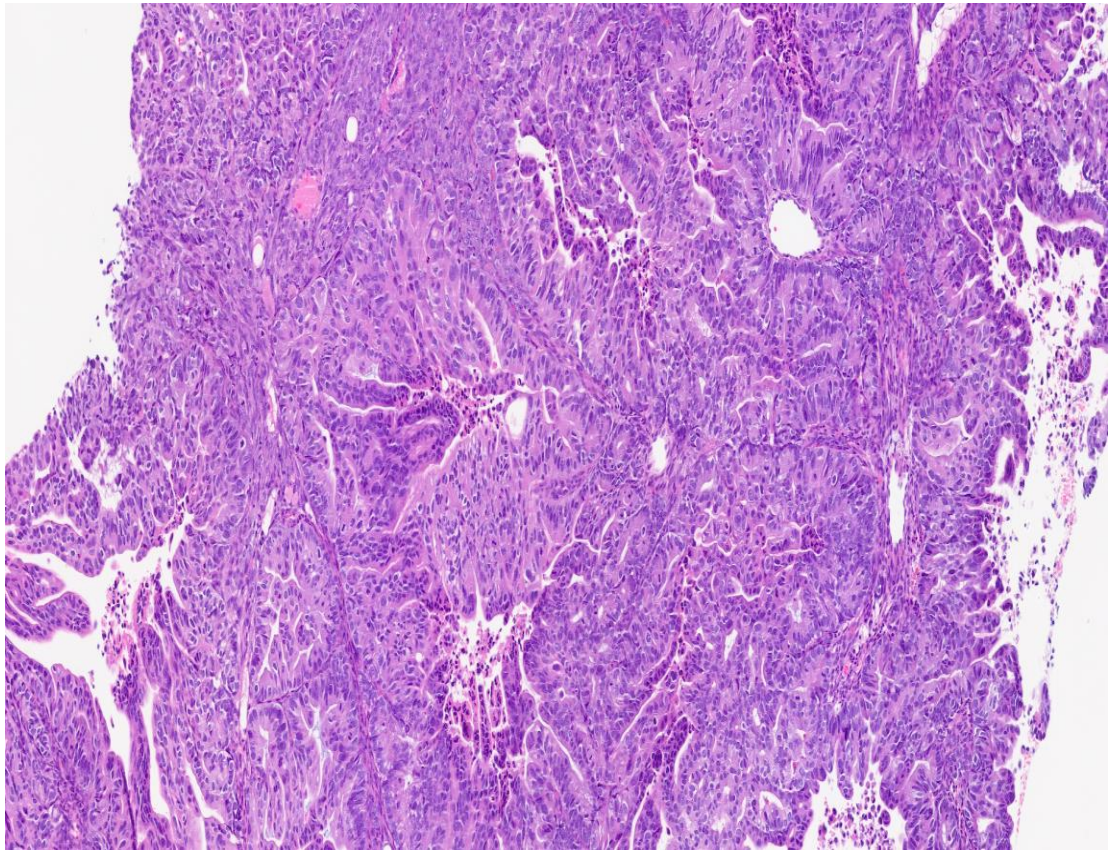

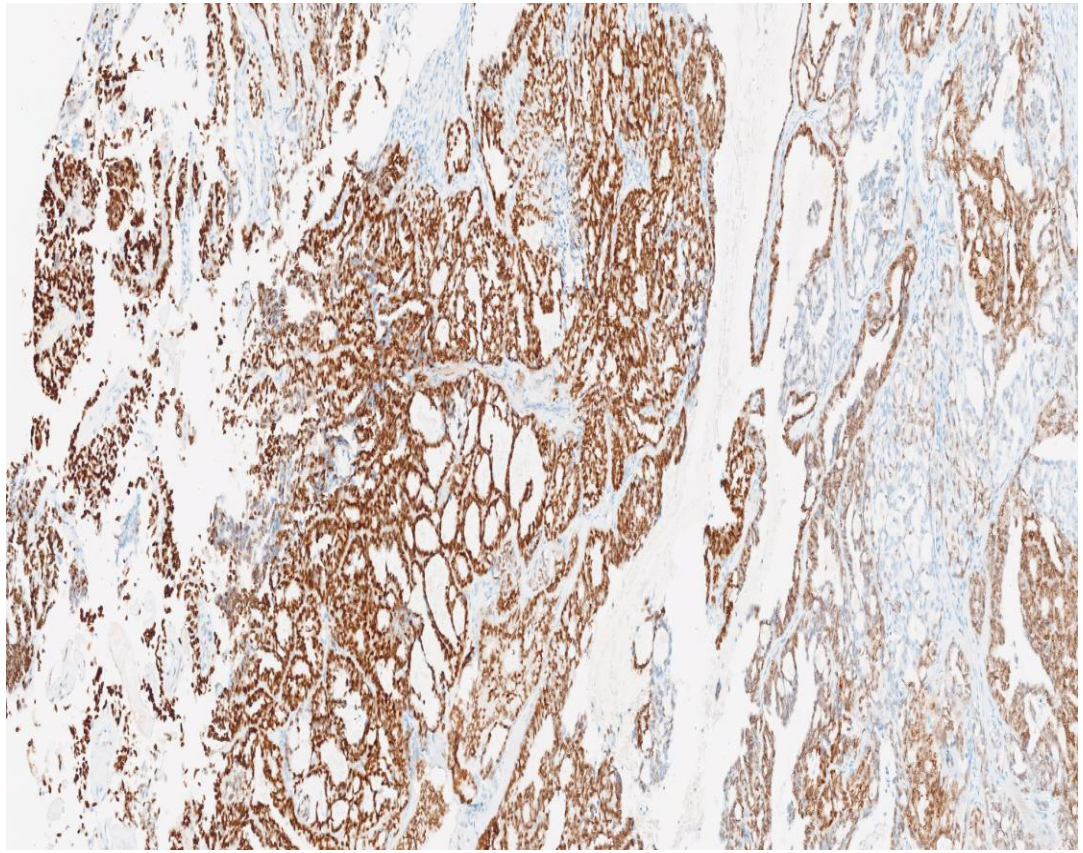

**PAX8**

# PROPENSITY FOR OVARIAN ENDOMETRIOID CARCINOMA TO EXHIBIT ABERRANT IMMUNOPHENOTYPE

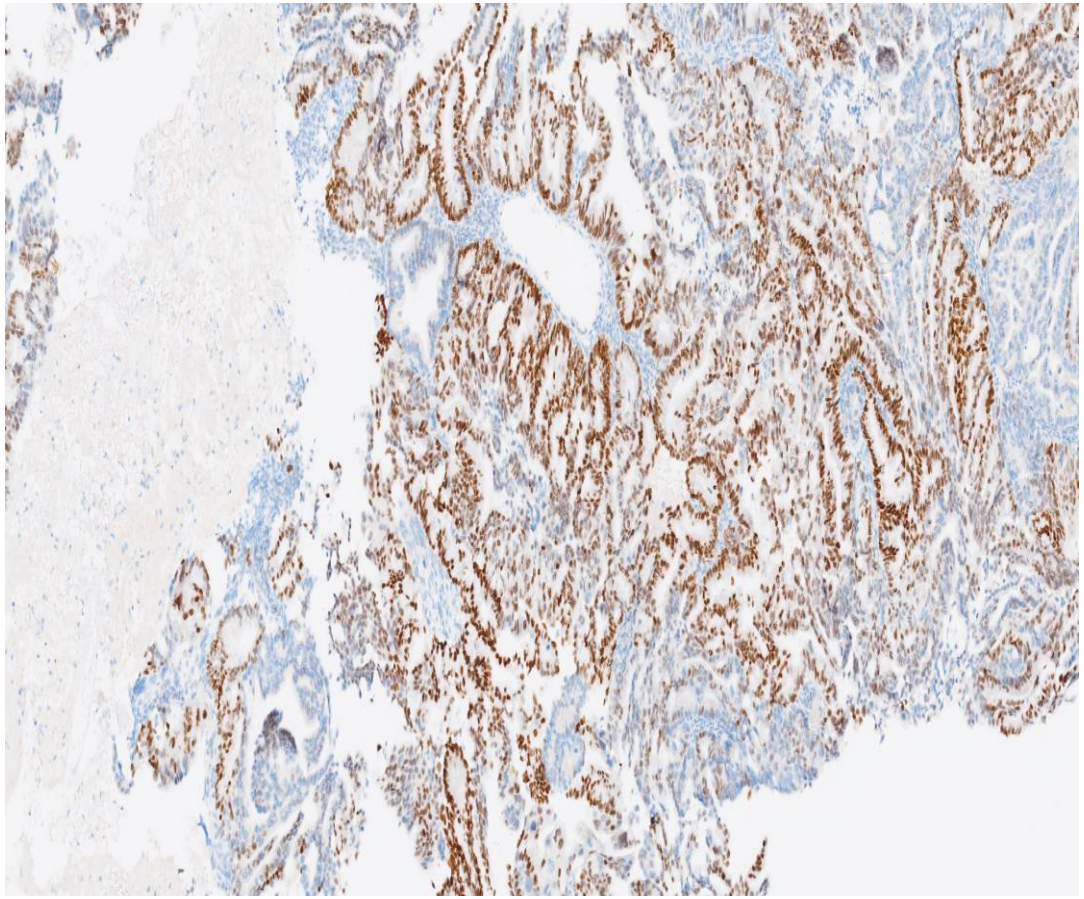

**CDX2**

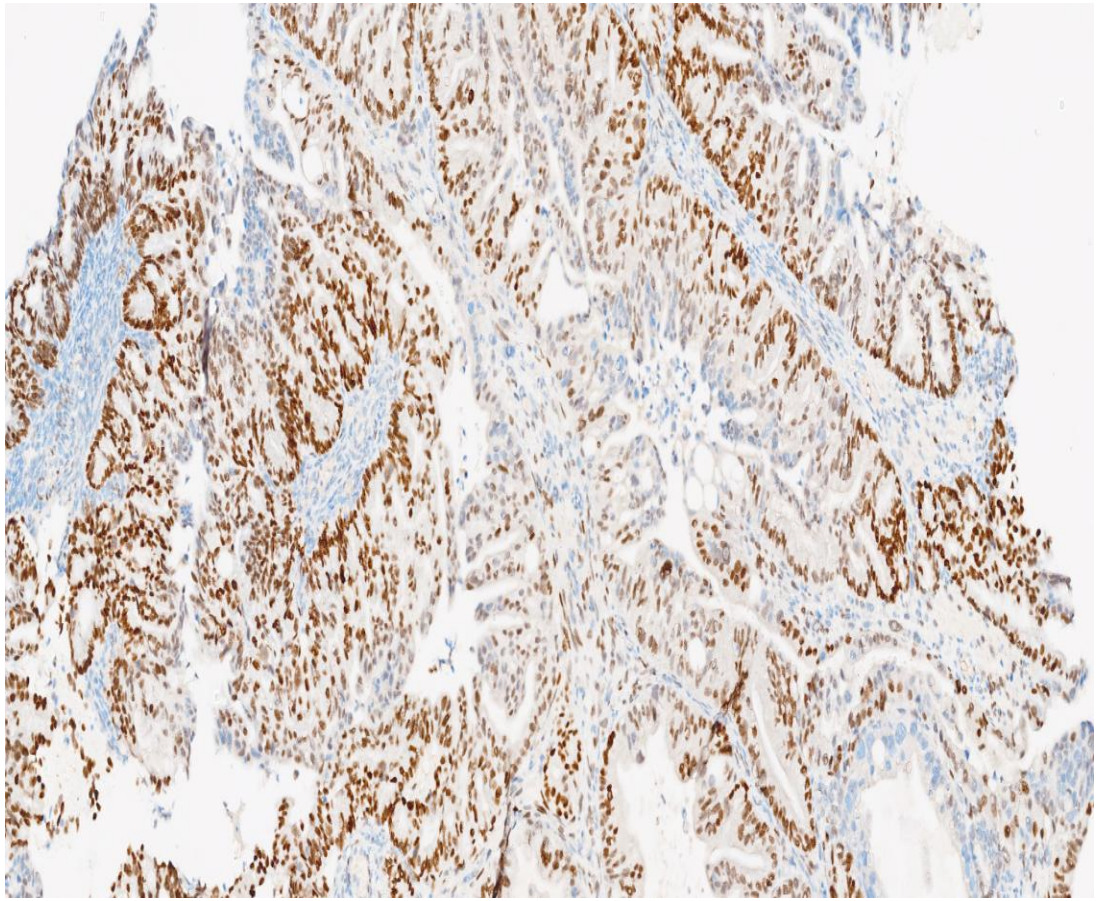

**SATB2**

# ENDOMETRIOID CARCINOMA- ABERRANT NEUROENDOCRINE MARKER EXPRESSION

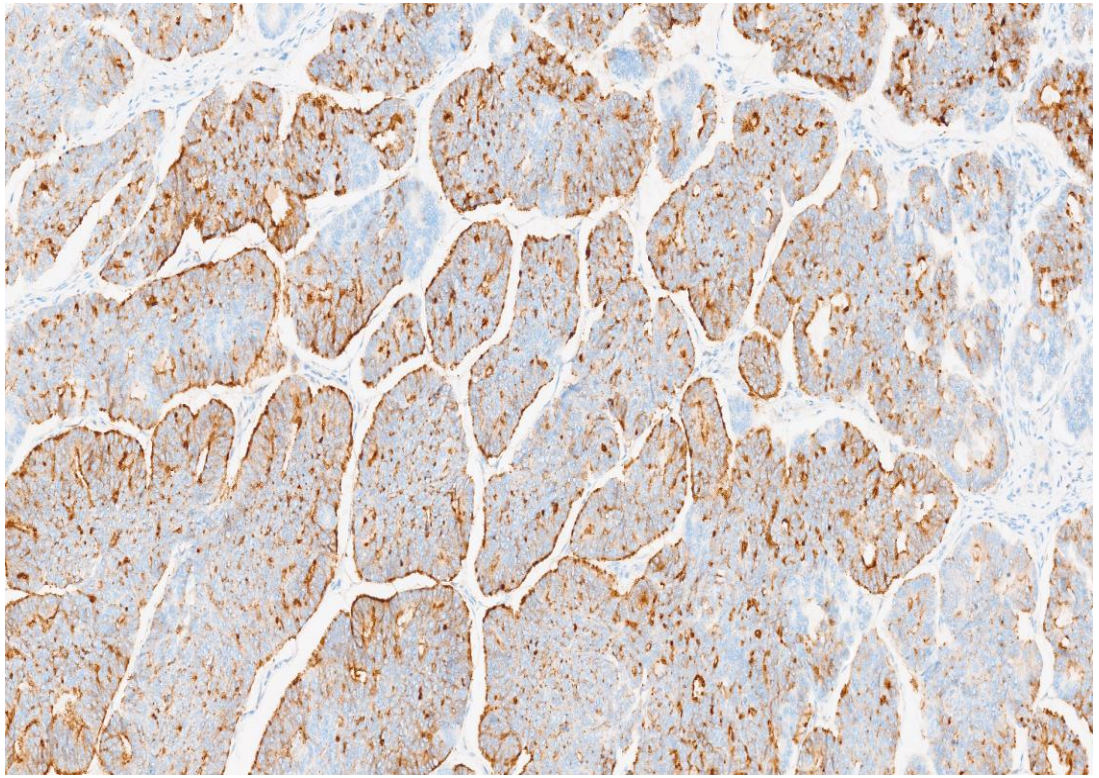

**chromogranin**

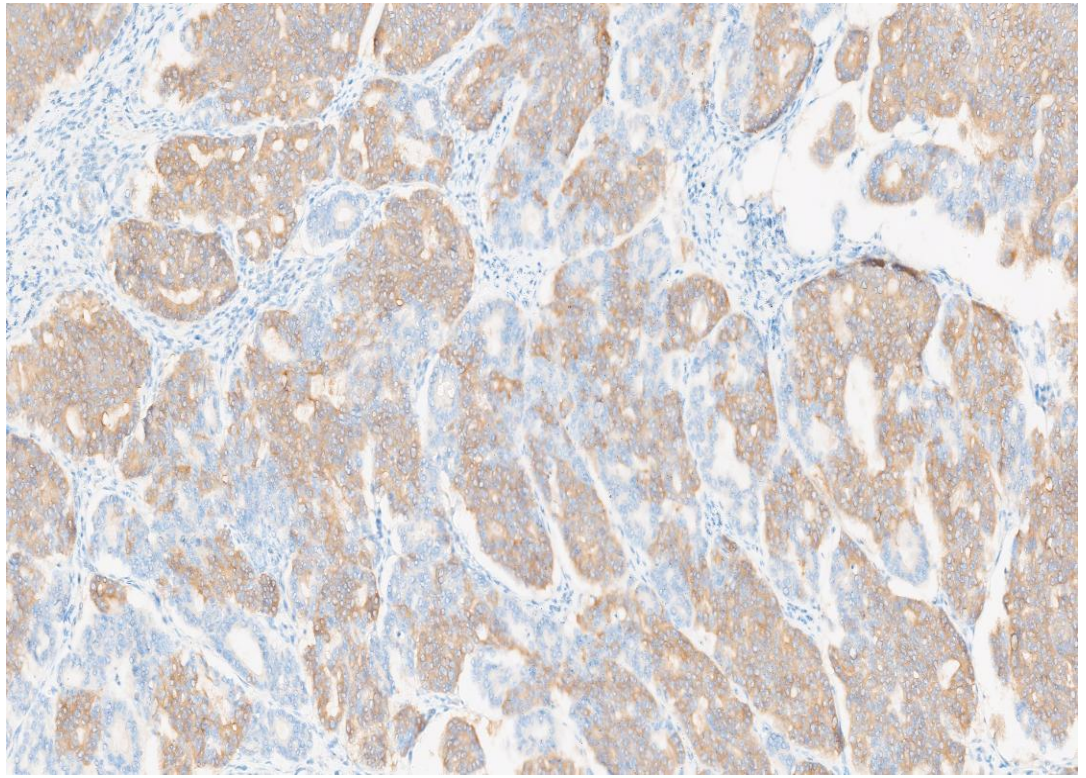

**synaptophysin**

# MMR IMMUNOHISTOCHEMISTRY IN OVARIAN ENDOMETRIOID AND CLEAR CELL CARCINOMAS

- International Collaboration on Cancer Reporting (ICCR) discusses but does not recommend as core item; probably should do and recommend in next update
- I do MMR immunohistochemistry on all ovarian endometrioid and clear cell carcinomas
- MMRd occurs in 10-12% of ovarian endometrioid carcinomas (mostly MLH1/ PMS2 loss secondary to MLH1 promotor methylation); about 4% associated with Lynch syndrome
- MMRd more uncommon in ovarian clear cell carcinomas (4-6%)
- No pathognomonic clinicopathological features to identify MMRd endometrioid and clear cell carcinomas

# TCGA ENDOMETRIAL CARCINOMA APPLIED TO OVARIAN ENDOMETRIOID CARCINOMA- PMID 32737030

- 511 cases of ovarian endometrioid carcinoma
- 3.5% *POLE*; 13.7% MMR deficient; 9.6% *TP53* abnormal; 73.2% NSMP
- Median overall survival: not reached for *POLE*; 12.3 years in MMR deficient; 4.7 years in *TP53* abnormal; 18.1 years in NSMP
- Molecular classification provides prognostic information in ovarian endometrioid carcinomas and may influence management strategies

# ESGO-ESMO-ESP CONSENSUS RECOMMENDATIONS: PMID 38307807 (2024)

ESMO GOOD SCIENCE BETTER MEDICINE BEST PRACTICE

ANNALS OF ONCOLOGY driving innovation in oncology

SPECIAL ARTICLE

## ESGO–ESMO–ESP consensus conference recommendations on ovarian cancer: pathology and molecular biology and early, advanced and recurrent disease☆

J. A. Ledermann[1*†], X. Matias-Guiu[2,3,4*†], F. Amant[5,6], N. Concin[7,8], B. Davidson[9,10], C. Fotopoulou[11], A. González-Martin[12], C. Gourley[13], A. Leary[14], D. Lorusso[15,16], S. Banerjee[17], L. Chiva[18], D. Cibula[19], N. Colombo[20,21], S. Croce[22], A. G. Eriksson[10,23], C. Falandry[24,25], D. Fischerova[19], P. Harter[8,26], F. Joly[27], C. Lazaro[28], C. Lok[6], S. Mahner[26,29], F. Marmé[26,30,31], C. Marth[7], W. G. McCluggage[32], I. A. McNeish[11], P. Morice[33], S. Nicum[1], A. Oaknin[34], J. A. Pérez-Fidalgo[35], S. Pignata[36], P. T. Ramirez[37], I. Ray-Coquard[38], I. Romero[39], G. Scambia[15,16], J. Sehouli[40,41], R. Shapira-Frommer[42], S. Sundar[43,44], D. S. P. Tan[45,46,47,48], C. Taskiran[49], W. J. van Driel[6], I. Vergote[5], F. Planchamp[50], C. Sessa[51] & A. Fagotti[15,16*]

# WHAT IS THE ROLE OF MOLECULAR CLASSIFICATION IN OVARIAN ENDOMETRIOID AND CLEAR CELL CARCINOMAS?

**Recommendation 4.1:** A TCGA-based molecular classification as used for endometrial carcinomas can be considered to stratify ovarian EC [IV, B].

Consensus: 95% (38) yes, 5% (2) no, 0% (0) abstain (40 voters)

**Recommendation 4.2:** Molecular markers are not recommended for prognostication in ovarian CCC [IV, D].

Consensus: 90.2% (37) yes, 0% (0) no, 9.8% (4) abstain (41 voters)

**Recommendation 4.3:** DNA MMR IHC and/or MSI testing is recommended in ovarian EC and CCC [II, A].

Consensus: 100% (40) yes, 0% (0) no, 0% (0) abstain (40 voters)

# CASE 1

- Referral case
- F 50
- Ovarian mass: stage IA

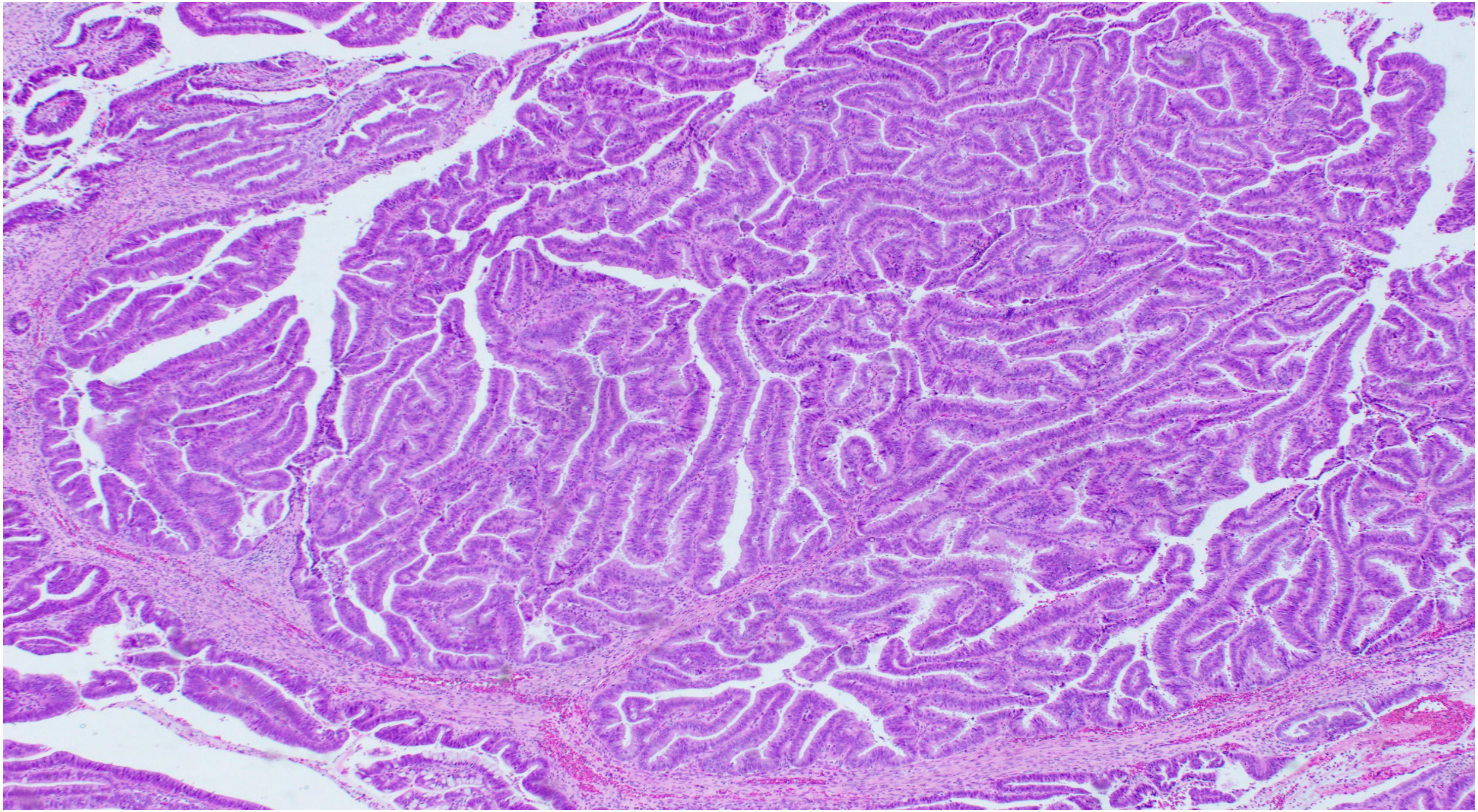

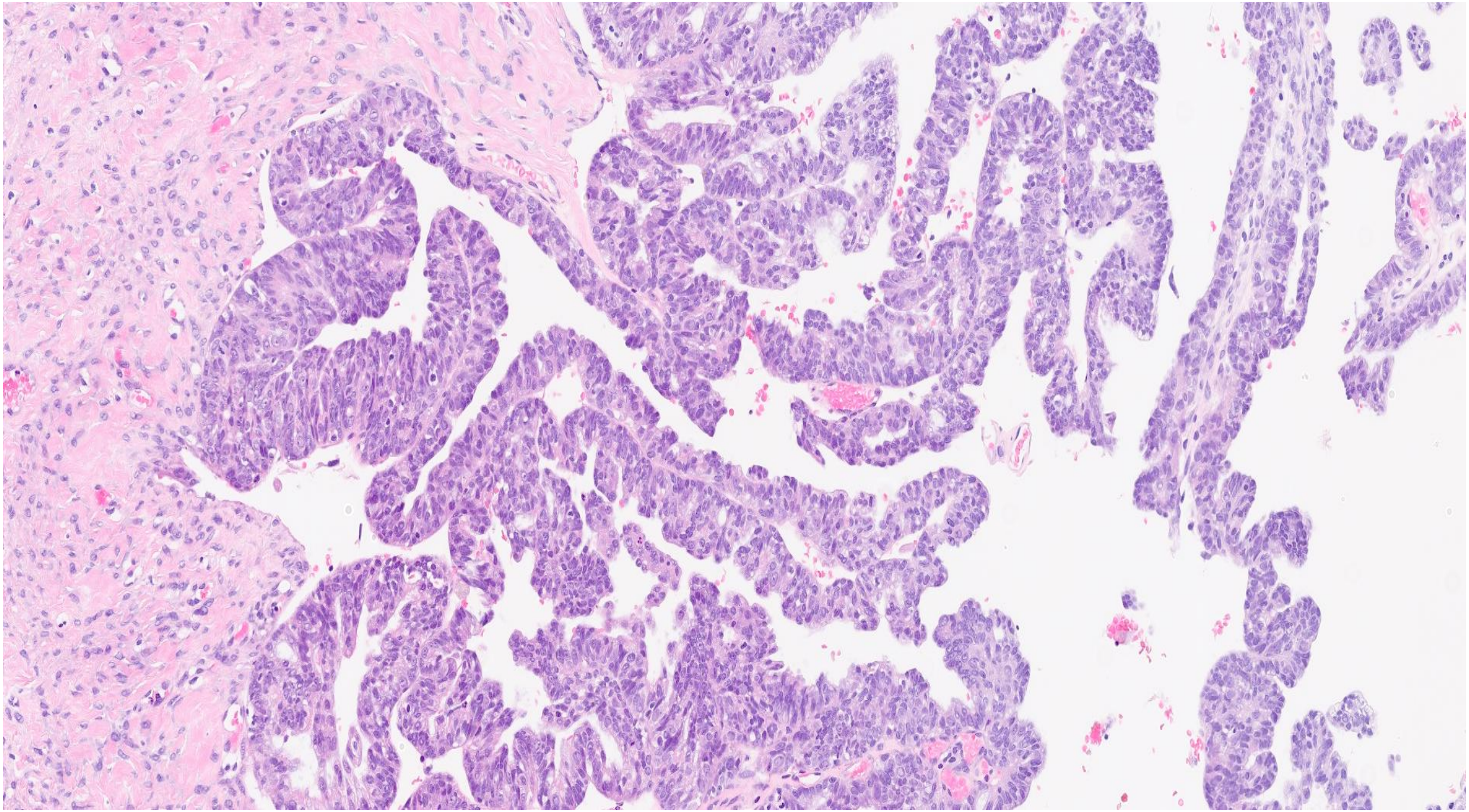

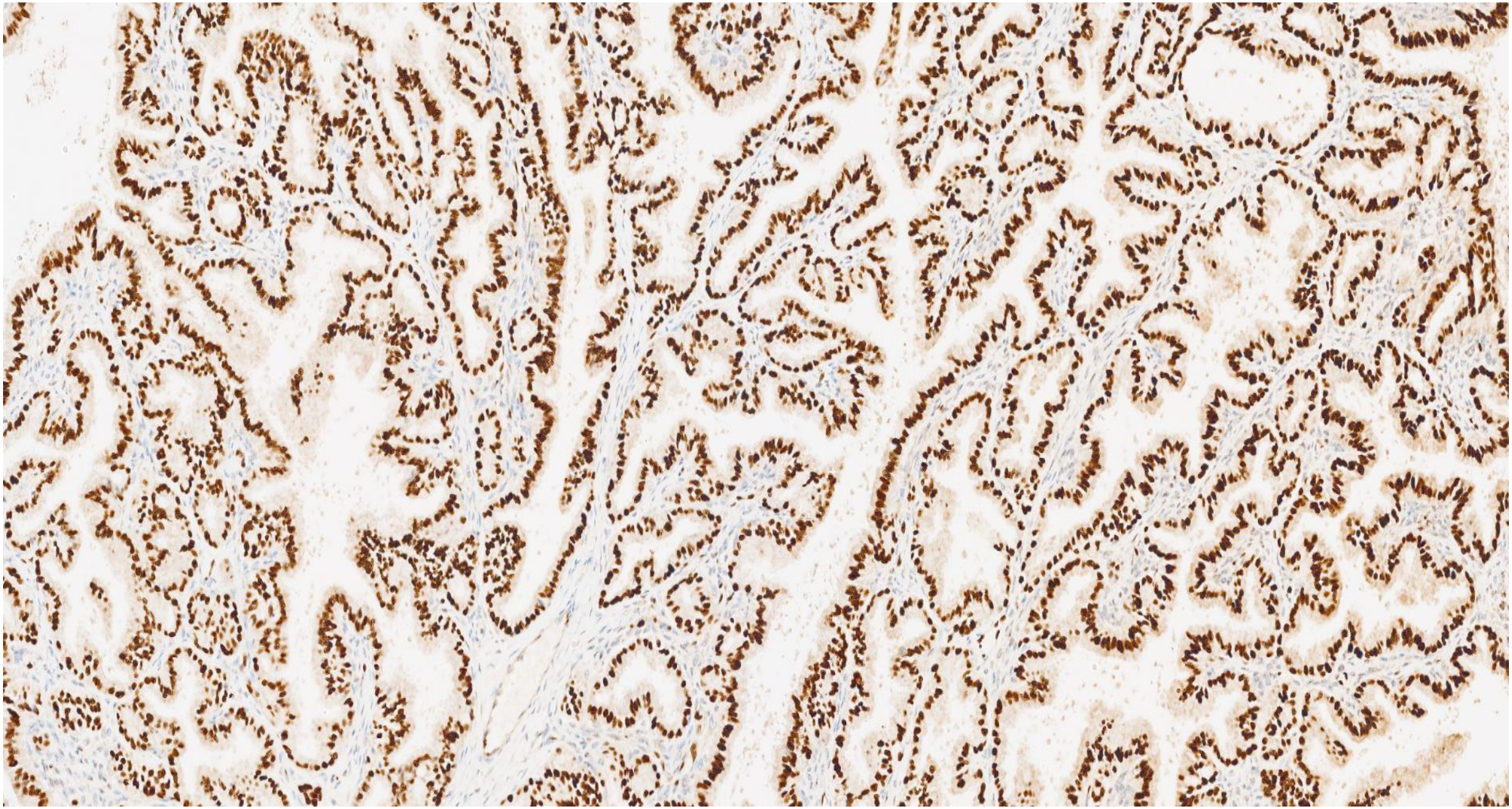

WT1

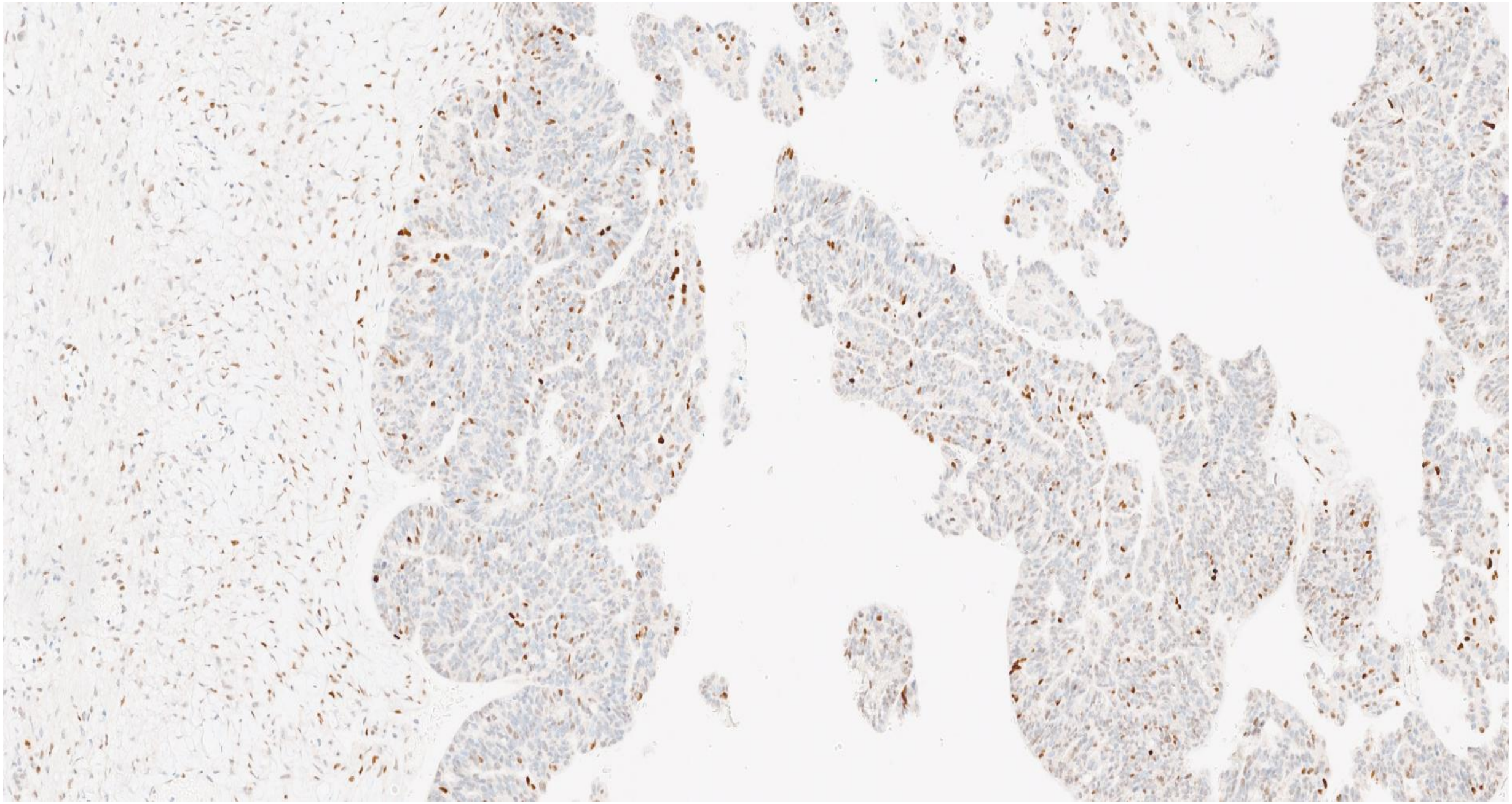

p53

# OTHER IMMUNOHISTOCHEMISTRY

- PAX8 diffusely positive
- ER diffusely positive
- p16 focal
- Napsin A negative

# REFERRAL DIAGNOSIS

- Serous carcinoma
- ? LGSC, ? HGSC

# PMID 33782345

*International Journal of Gynecological Pathology*
**00**:1–12, Lippincott Williams & Wilkins, Baltimore
Copyright © 2021 by the International Society of Gynecological Pathologists

Original Article

## WT1 Positive Ovarian Endometrioid Tumors: Observations From Consult Cases and Strategies for Distinguishing From Serous Neoplasms

Simon Rajendran, F.R.C.Path. and W. Glenn McCluggage, F.R.C.Path.

# PMID 33782345

- 23 ovarian endometrioid neoplasms, mainly received in consultation which were WT1 positive
- Some were typical endometrioid carcinomas and problems arose due to aberrant WT1 staining
- Sometimes associated endometriosis or squamous elements
- Most thought to be LGSC or HGSC or serous carcinoma which was difficult to classify
- Stressed that diagnosis of HGSC unlikely in presence of two grossly and histologically normal fallopian tubes
- Stressed that diagnostic immunohistochemistry not needed in prototypical ovarian endometrioid carcinomas
- With typical ovarian endometrioid carcinoma, I just do ER, p53, MMR immunohistochemistry

# CASE 2

- Referral case
- F 37
- Unilateral 10 cm ovarian mass with intact capsule
- Hysterectomy, BSO and omentectomy; other organs, including contralateral ovary, normal

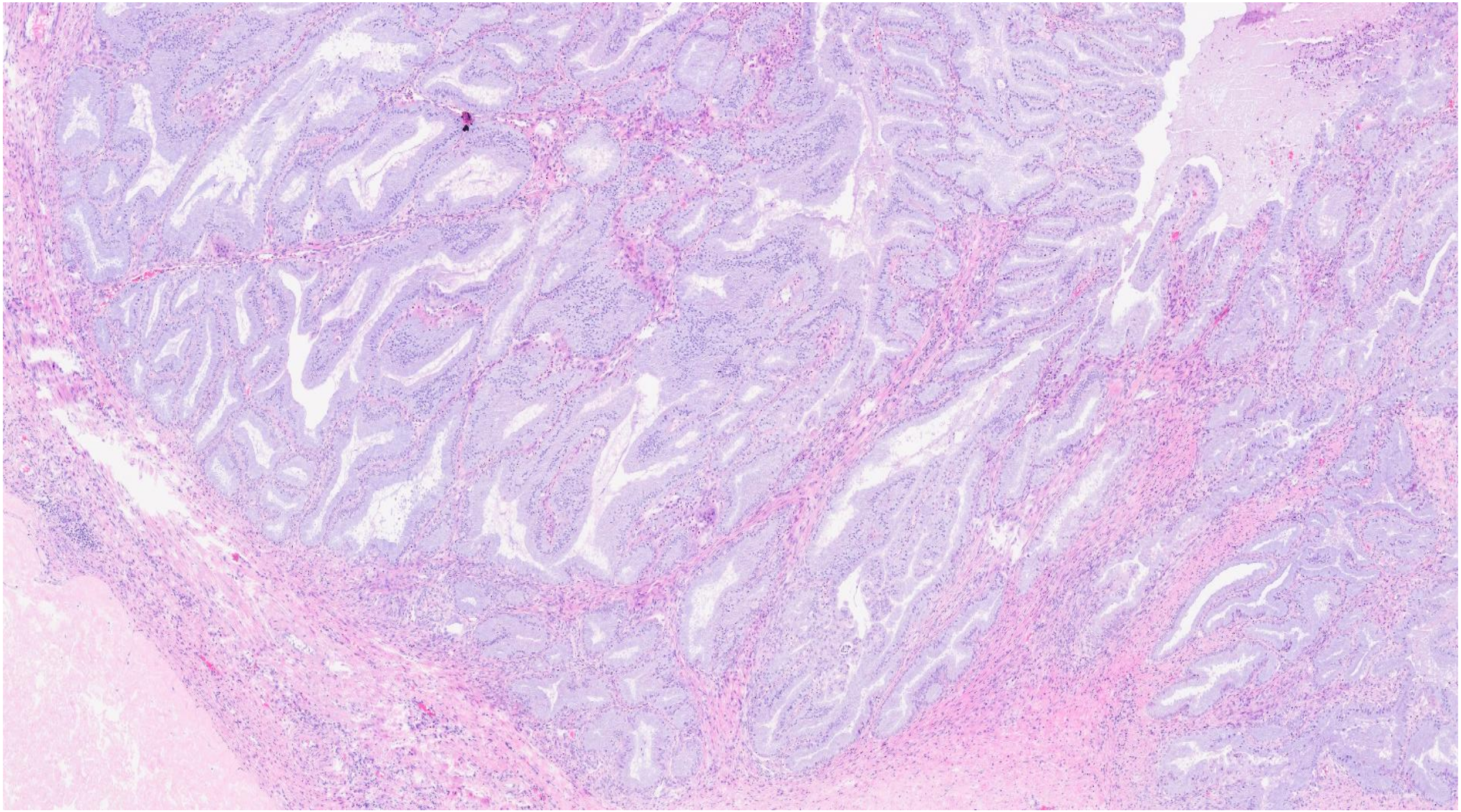

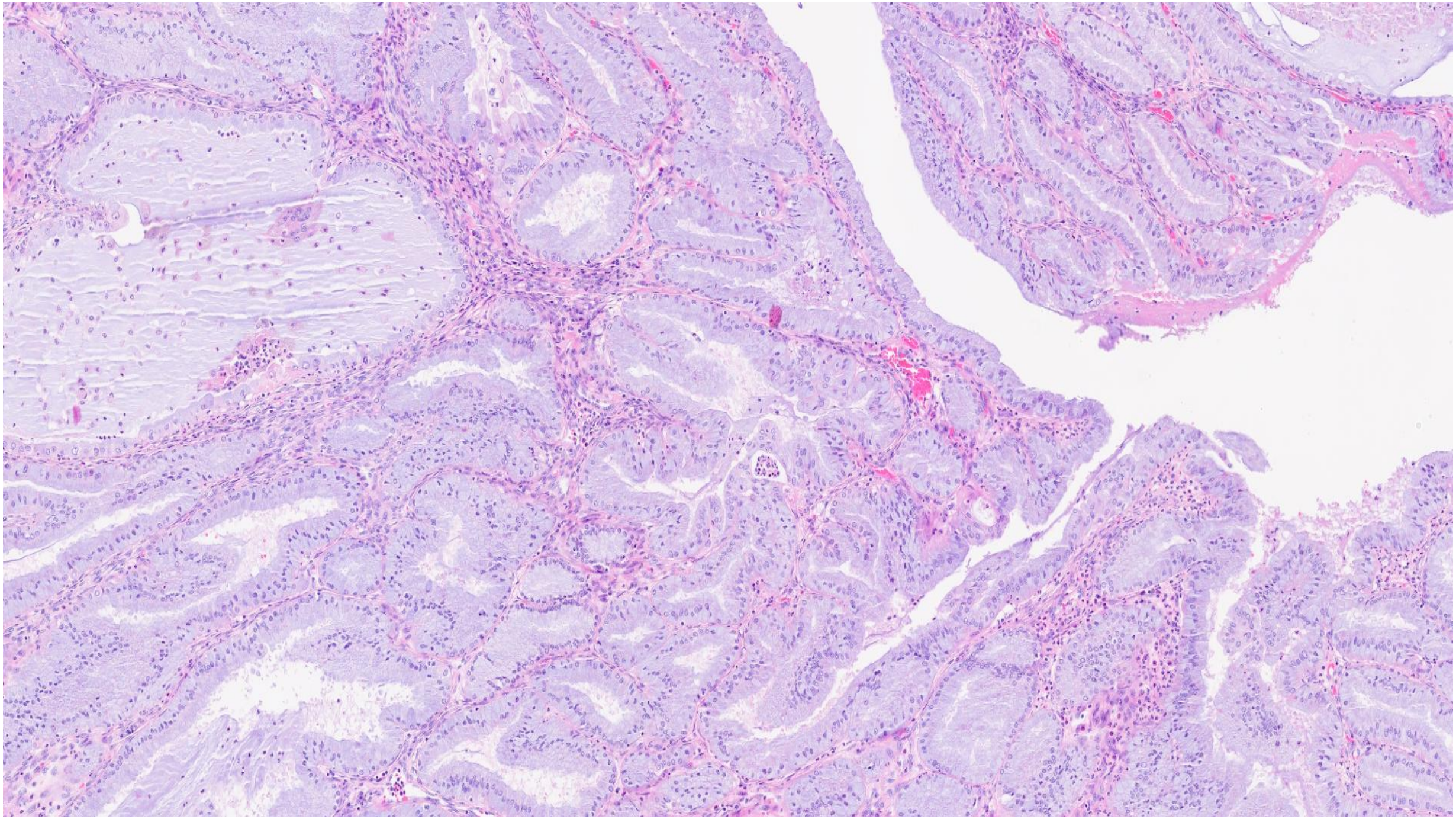

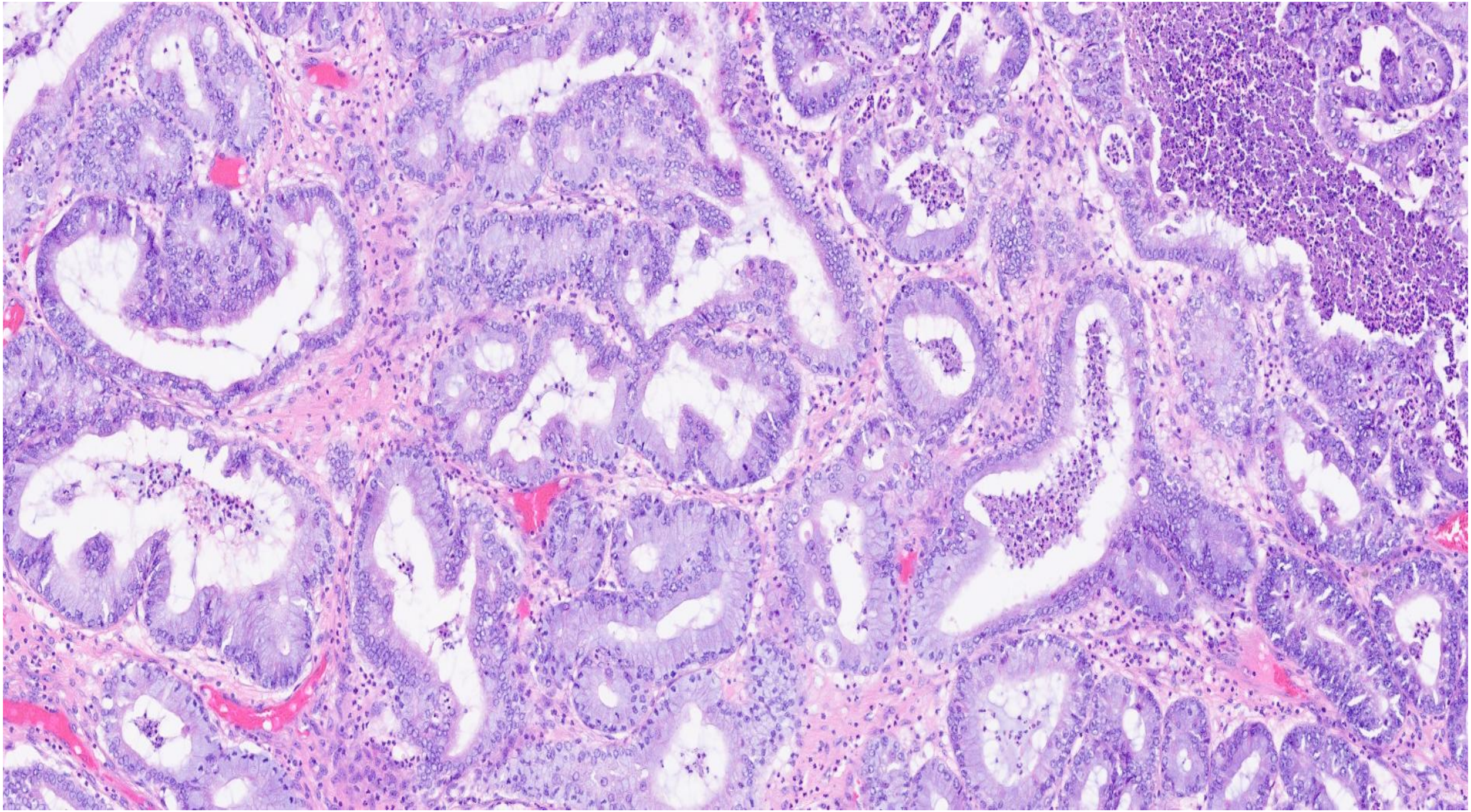

# REFERRAL DIAGNOSIS

- ? Mucinous borderline tumour
- ? Grade 1 mucinous adenocarcinoma with expansile invasion

# IMMUNOHISTOCHEMISTRY- ER

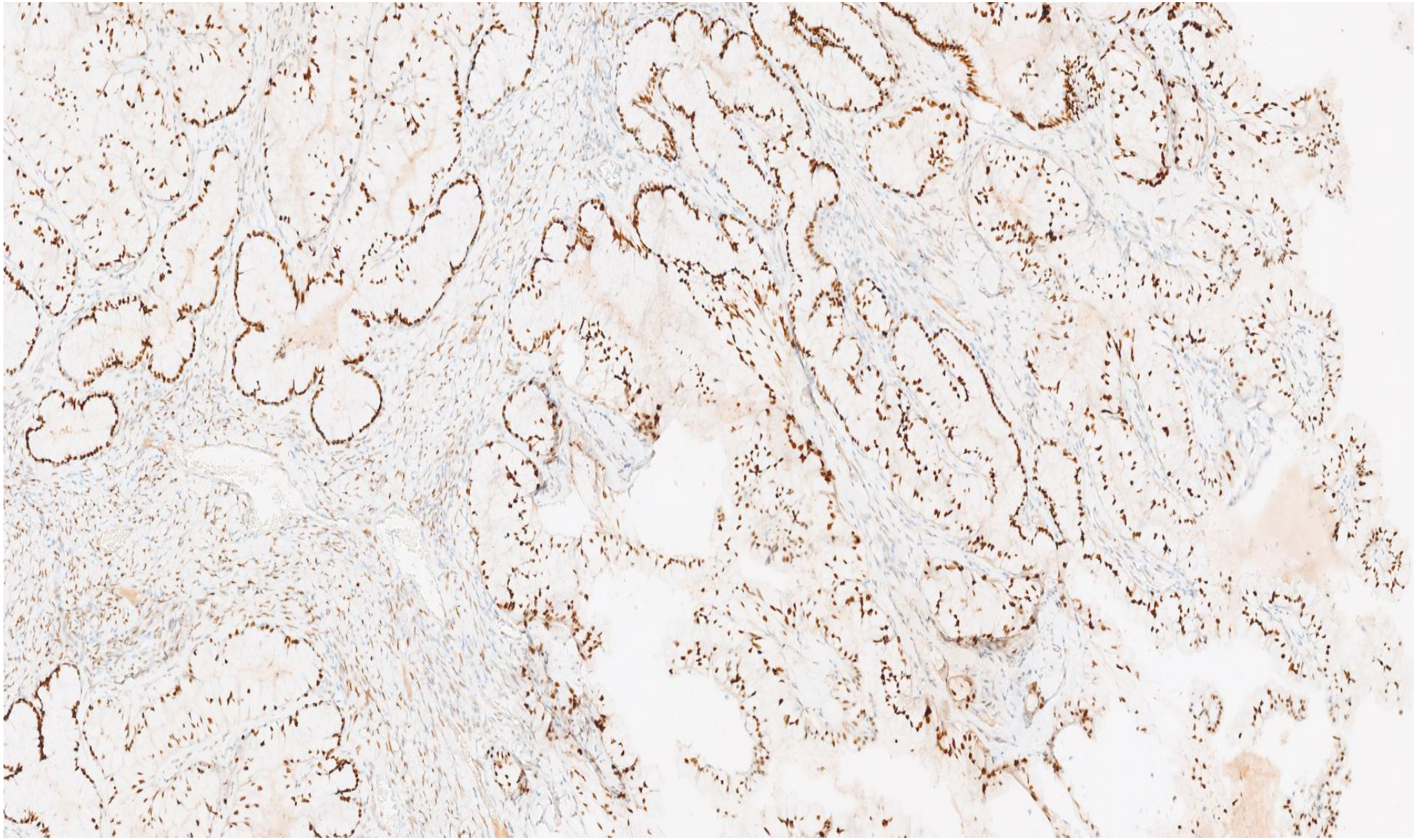

# IMMUNOHISTOCHEMISTRY- PAX8

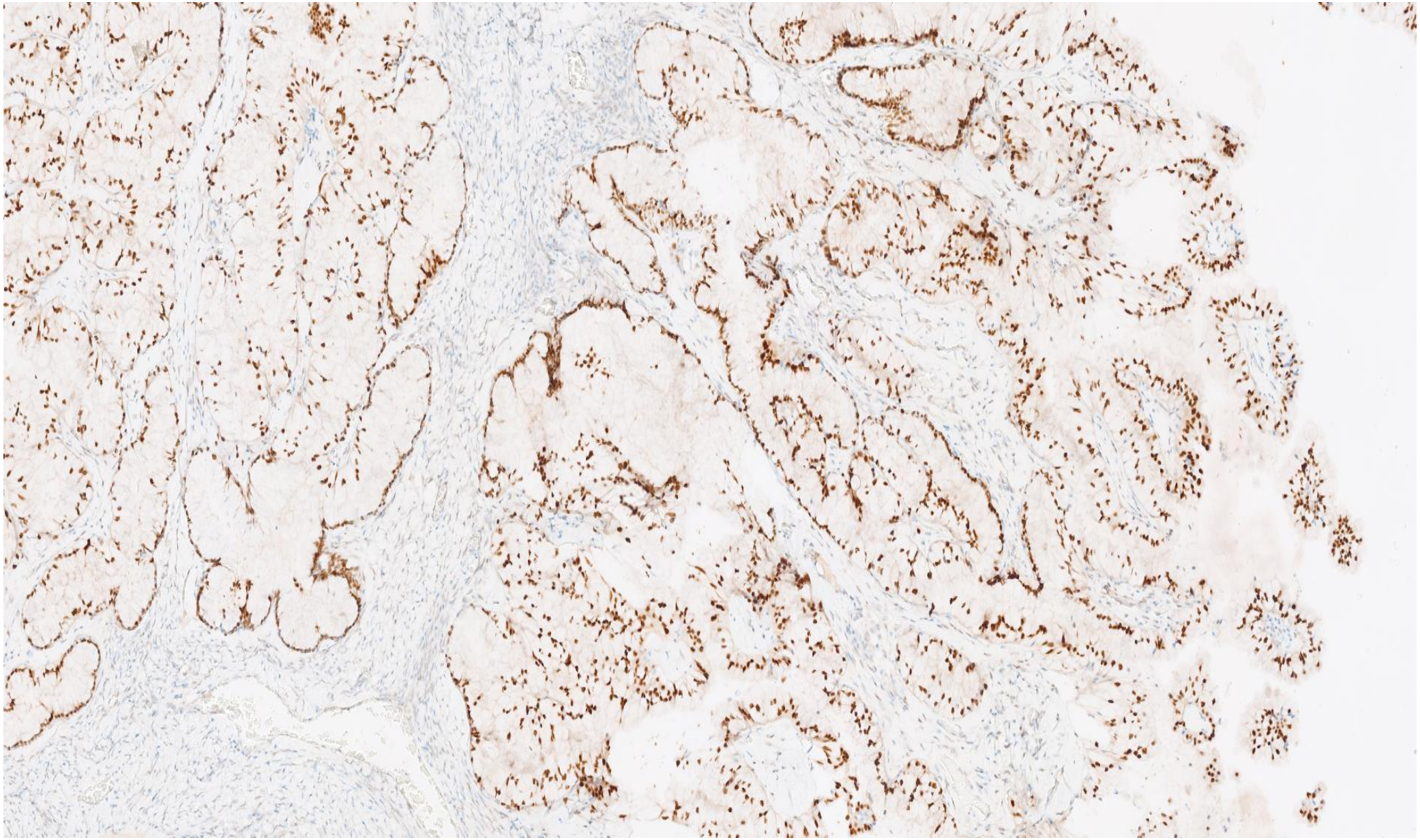

# IMMUNOHISTOCHEMISTRY- CA125

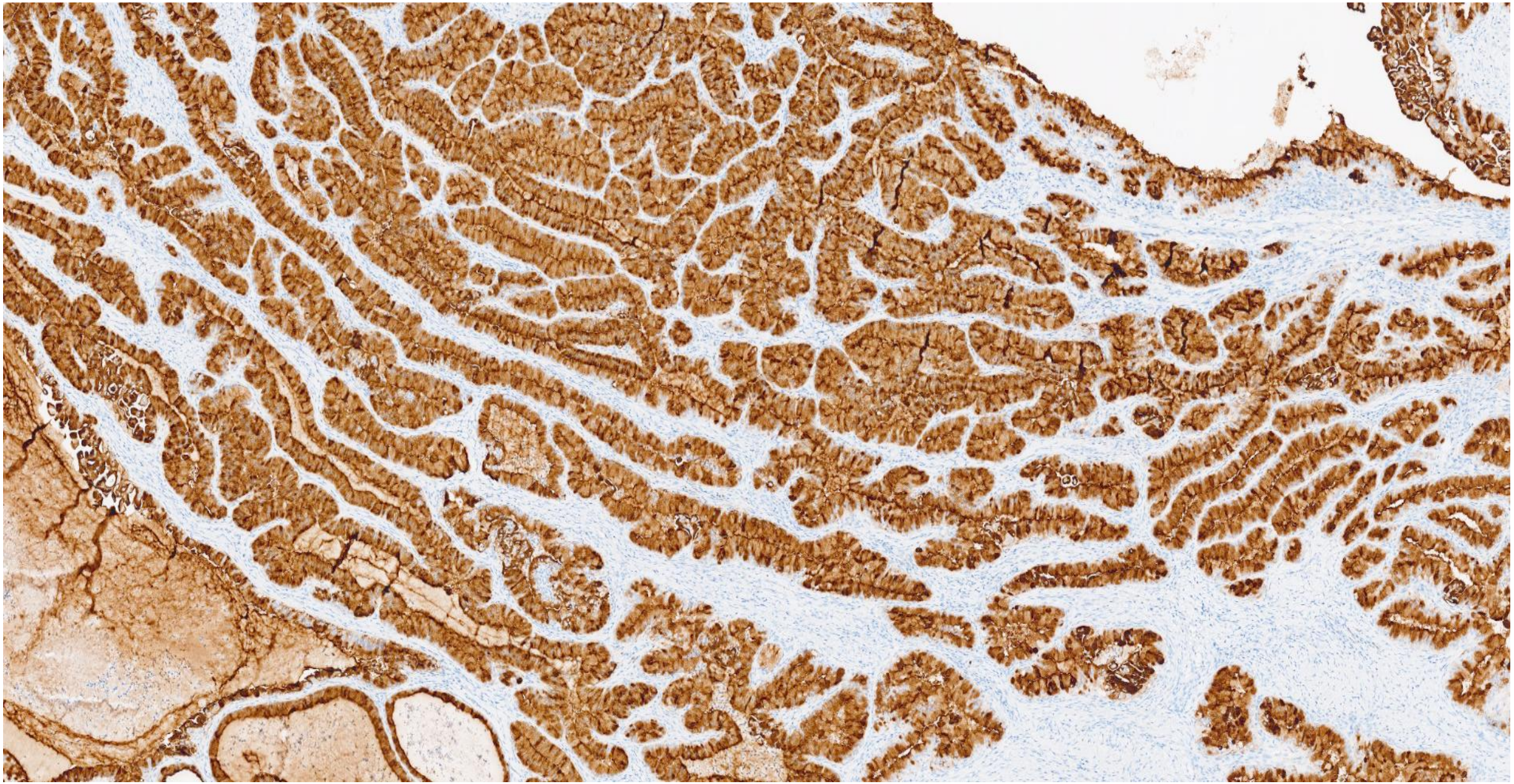

# IMMUNOHISTOCHEMISTRY

- Diffuse- ER, PR, CK7, PAX8, CA125
- Negative- CK20, CEA, CDX2, SATB2
- p53- wild-type
- MMR retained

# DIAGNOSIS

- Grade 1 endometrioid adenocarcinoma with predominantly mucinous differentiation

# ? WHY NOT PRIMARY OVARIAN MUCINOUS TUMOUR (BORDERLINE OR CARCINOMA)

- Architecture wrong for mucinous borderline tumour
- Primary ovarian mucinous borderline tumours and carcinomas are intestinal type tumours (don’t necessarily need goblet cells); these are almost invariably negative for ER, PR, CA125 and PAX8 is usually negative or focal and weak

# PMID 30480647

*International Journal of Gynecological Pathology*
**38:**568–575, Lippincott Williams & Wilkins, Baltimore
Copyright © 2018 by the International Society of Gynecological Pathologists

Original Article

## Ovarian Endometrioid Carcinoma Misdiagnosed as Mucinous Carcinoma: An Underrecognized Problem

Randi Woodbeck, M.D., Linda E. Kelemen, M.Sc., Sc.D., and Martin Köbel, M.D.

# ENDOMETRIOID CARCINOMA WITH MUCINOUS DIFFERENTIATION

- WHO 2020- most mucinous carcinomas of endometrium considered variants of endometrioid carcinoma; also category of gastric/gastrointestinal/ intestinal-type mucinous carcinoma of endometrium
- Similar comments pertain in ovary
- Some ovarian endometrioid carcinomas are predominantly or even entirely mucinous and can be misdiagnosed as mucinous carcinoma- old category of Mullerian/ endococervical mucinous carcinoma
- Different architecture than ovarian mucinous carcinomas and may contain squamous elements or associated endometriosis
- These are usually ER, PR, PAX8, CA125 positive; true mucinous carcinomas are almost always negative with these markers (may be weak PAX8 positivity)

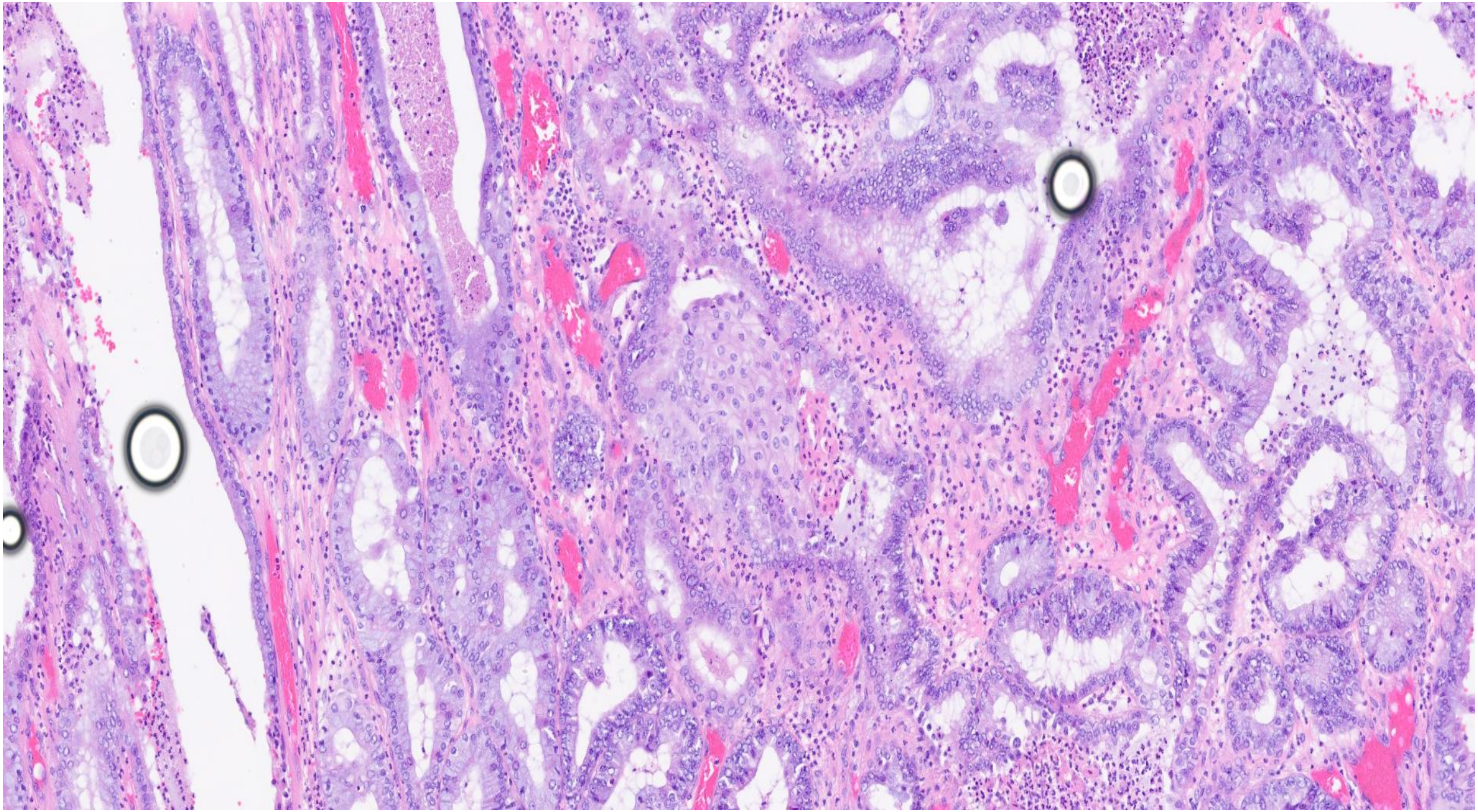

# CASE 3

- Referral case
- F 33
- Removal of ovarian mass
- Few months later, “recurred” in other ovary with extensive pelvic disease; resected and was same tumour
- Uniform morphology throughout whole tumour with no morphologically different elements
- No tumour in uterine corpus or cervix

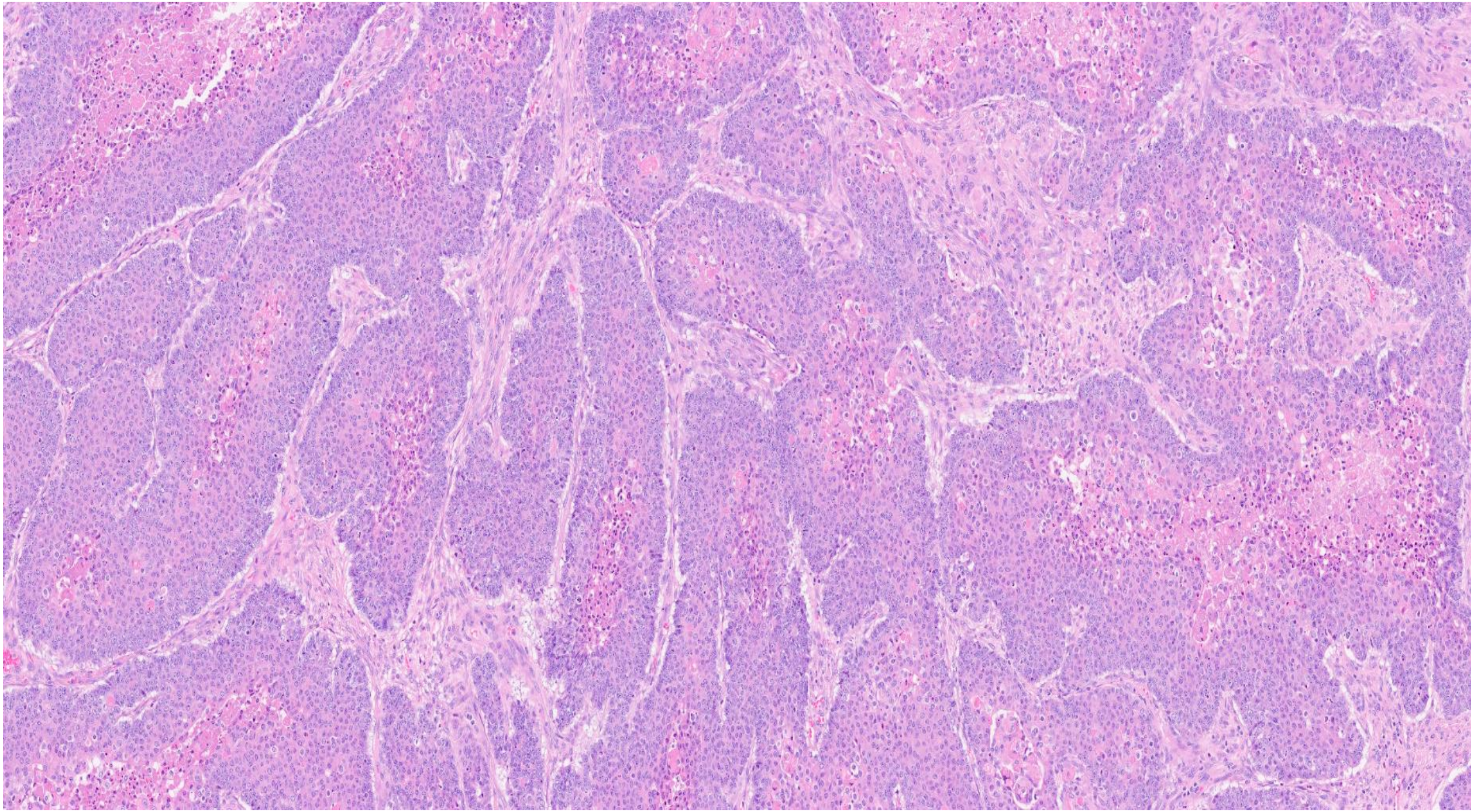

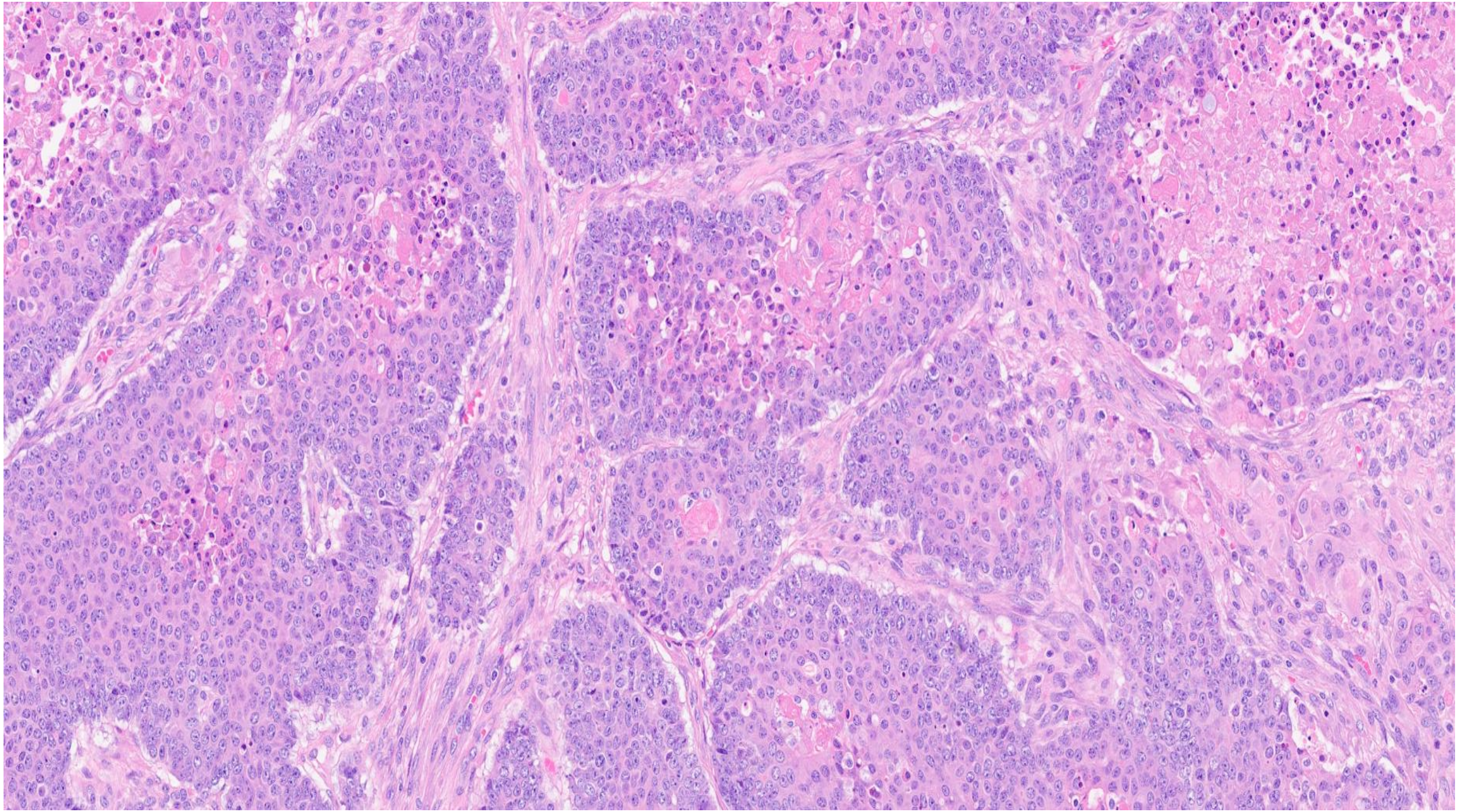

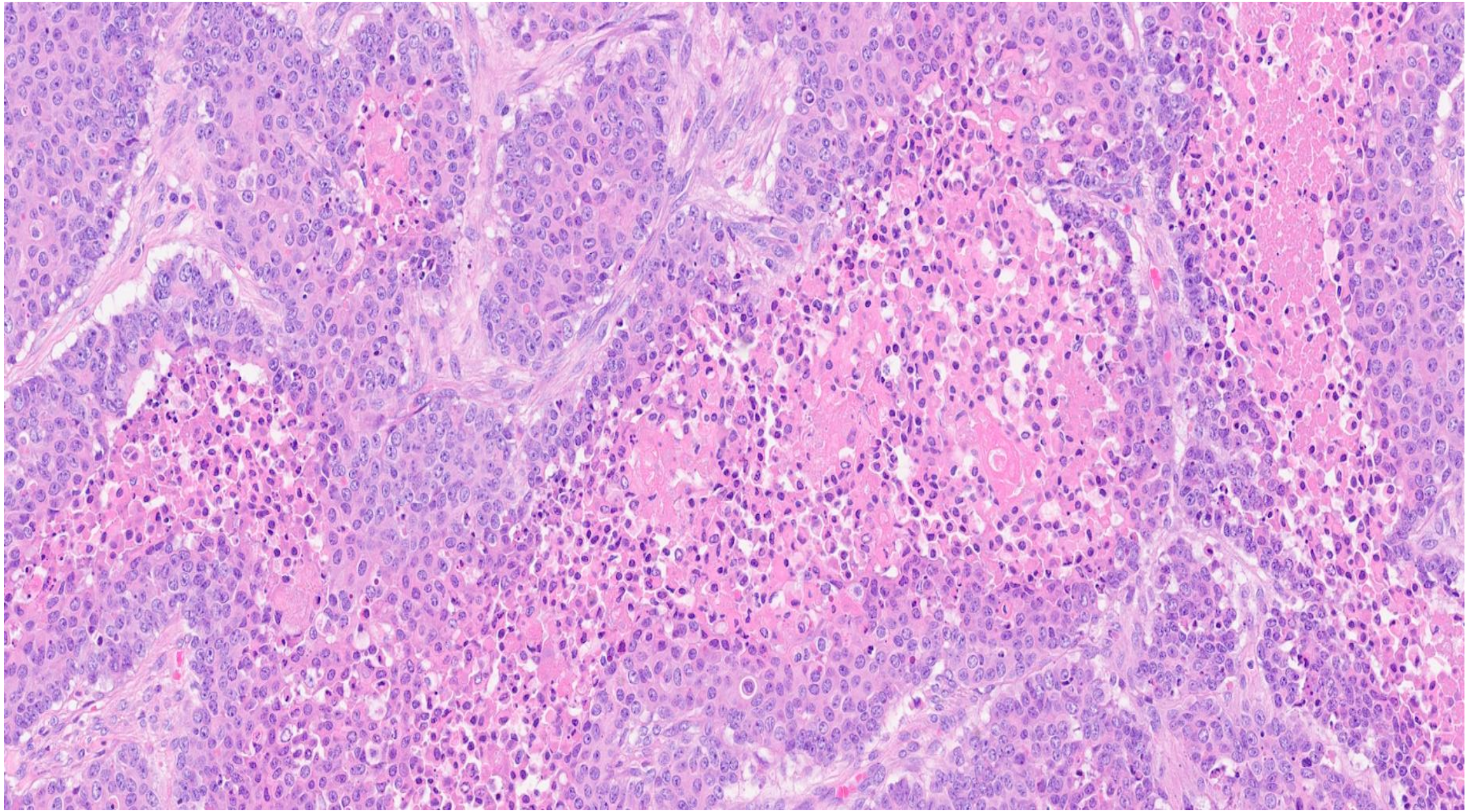

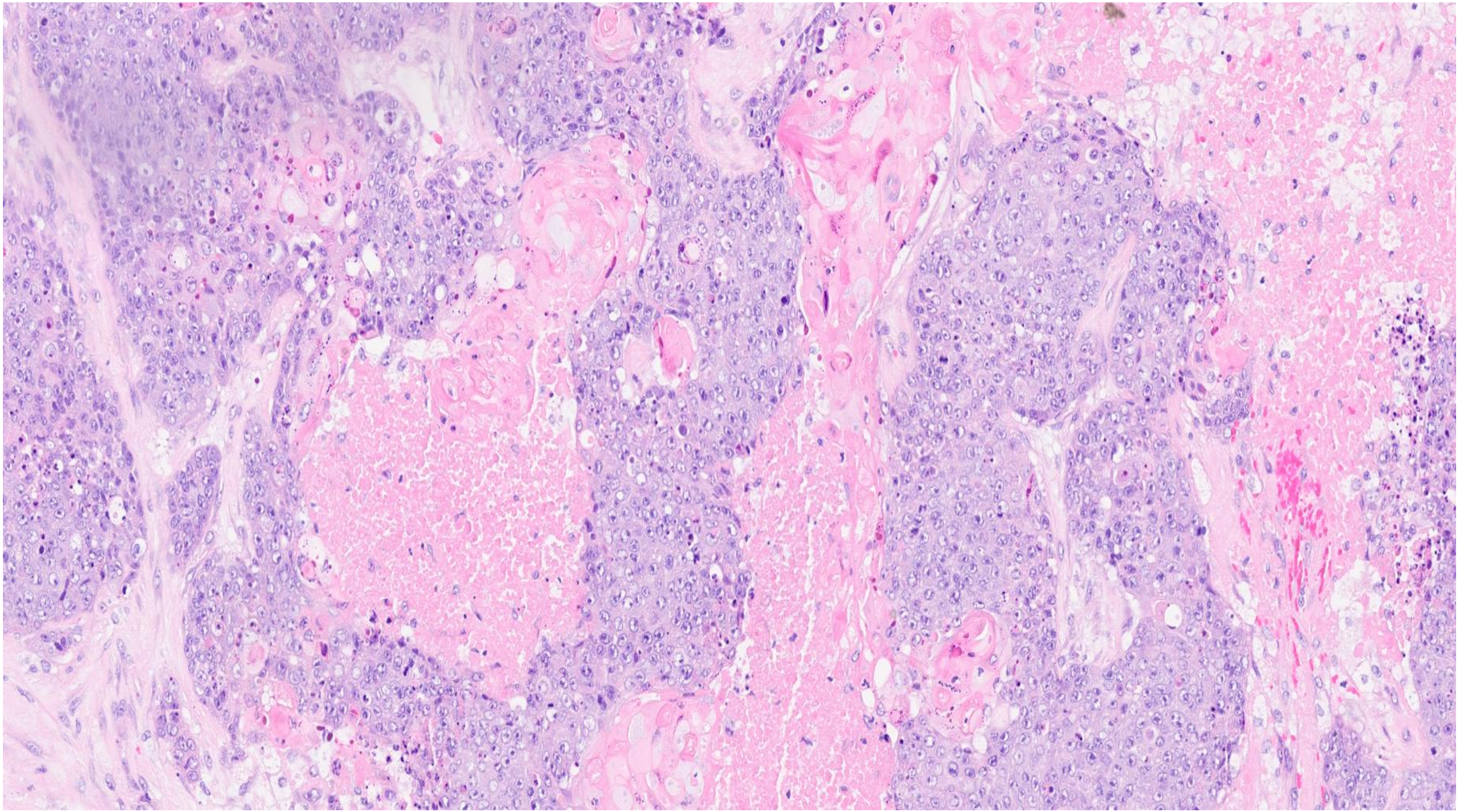

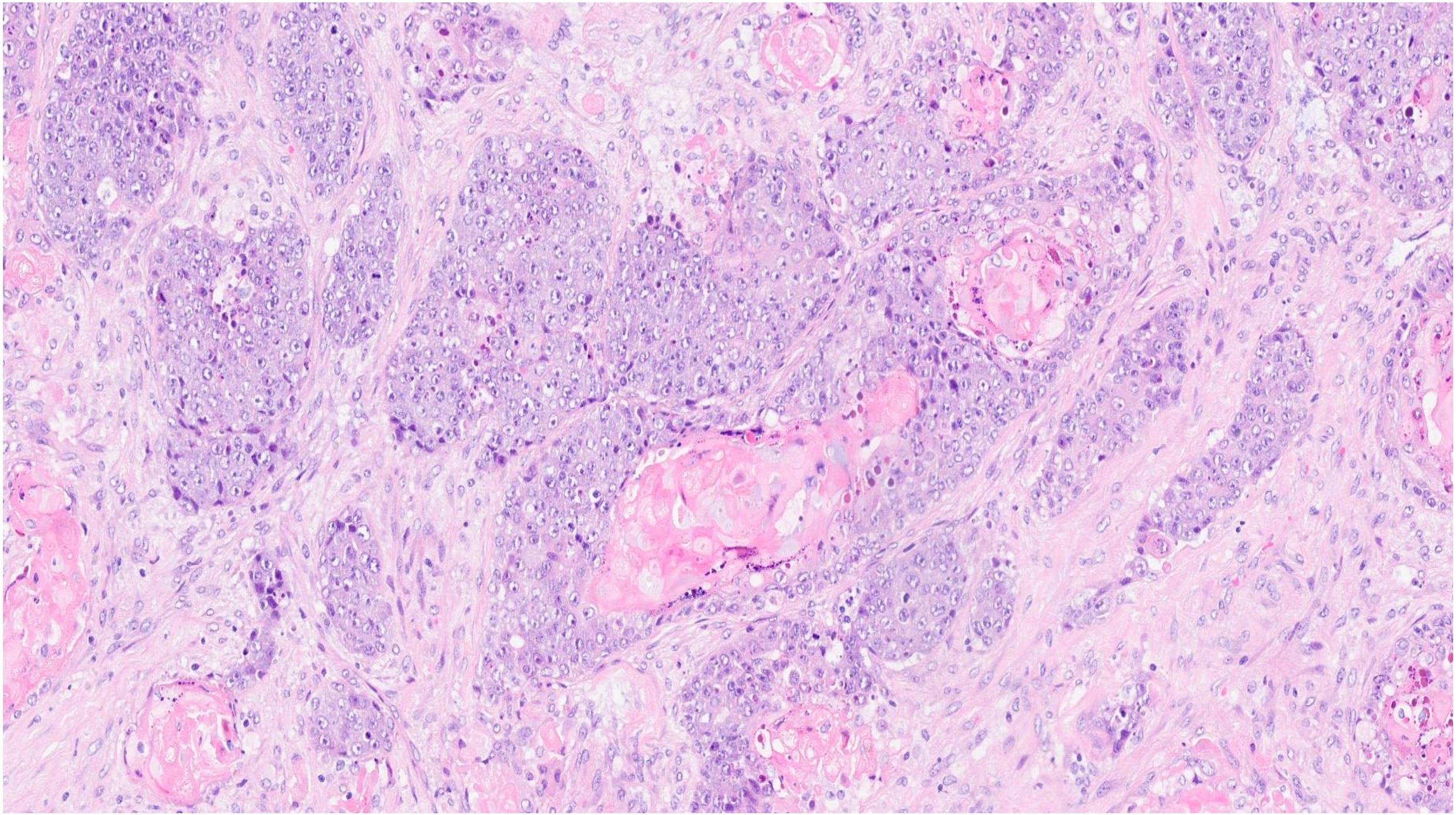

# ORIGINAL IMMUNOHISTOCHEMISTRY

- ER, PR, PAX8, WT1, CK20, GATA3 negative
- CK7, p63, CK5/6, CDX2, p16 focally positive
- p53 wild-type

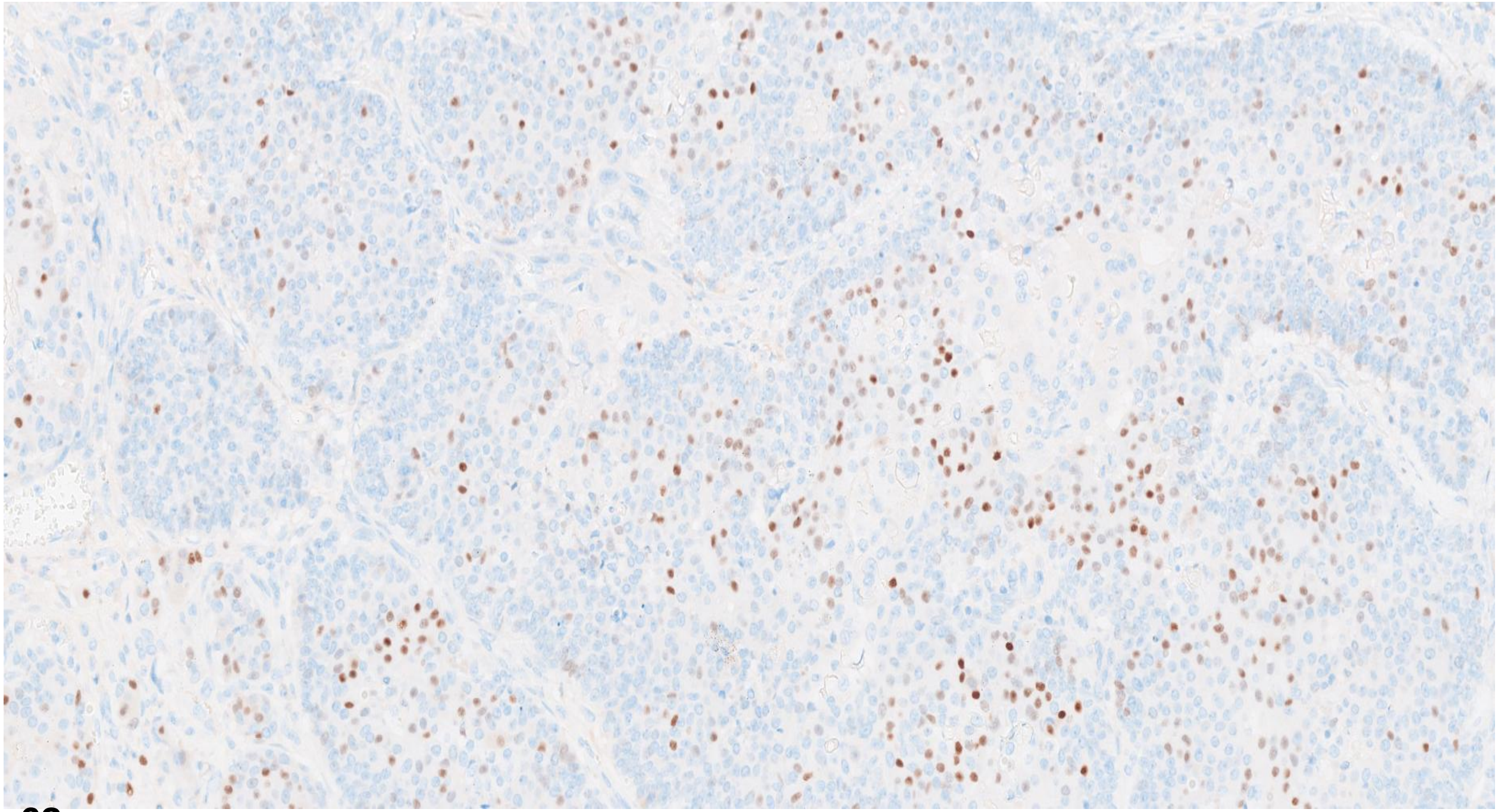
p63

# REFERRAL DIAGNOSIS

- squamous cell carcinoma; no teratomatous elements, no benign or borderline Brenner component, no endometriosis, no obvious endometrioid component

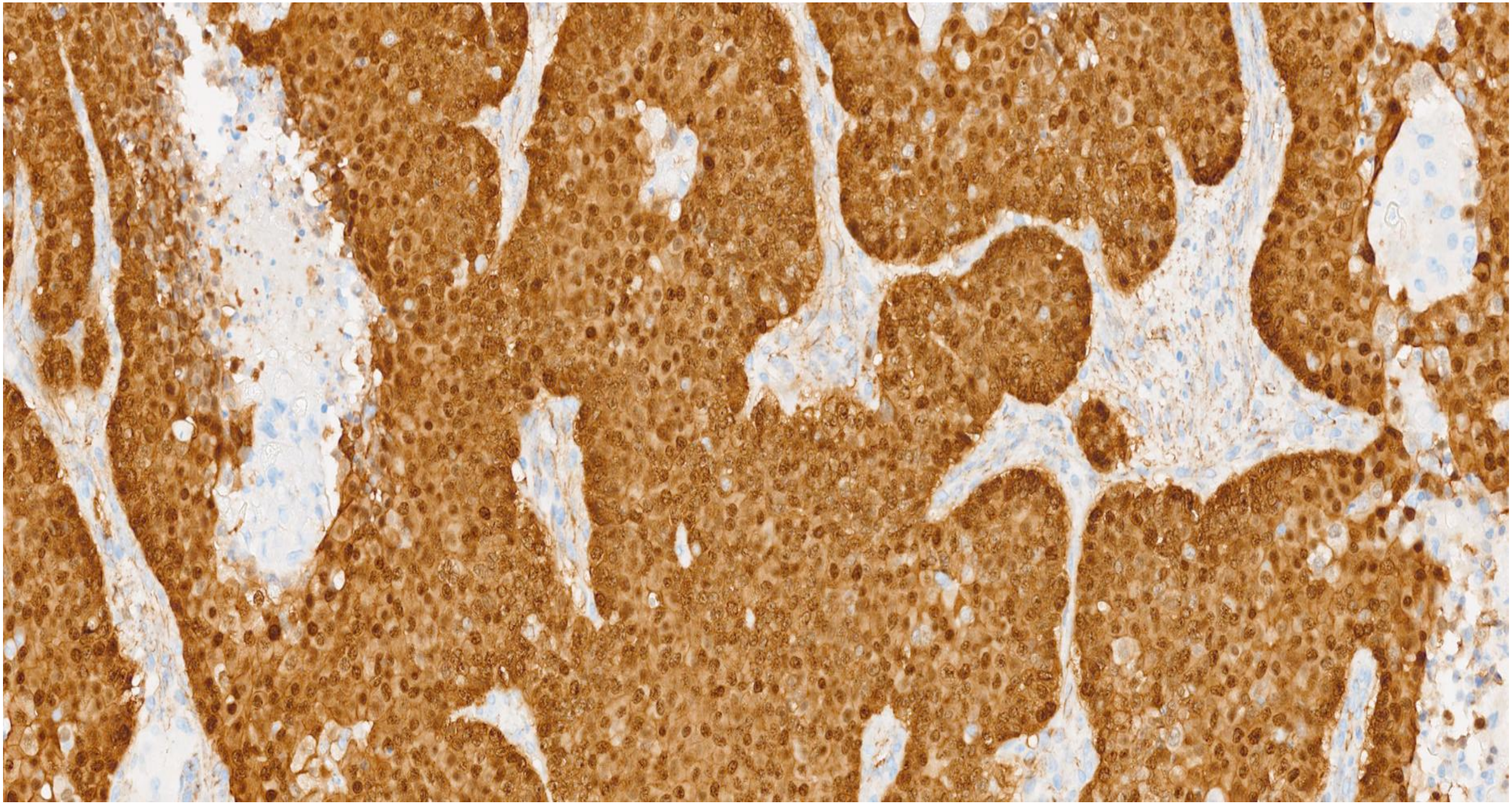

**Beta- catenin**

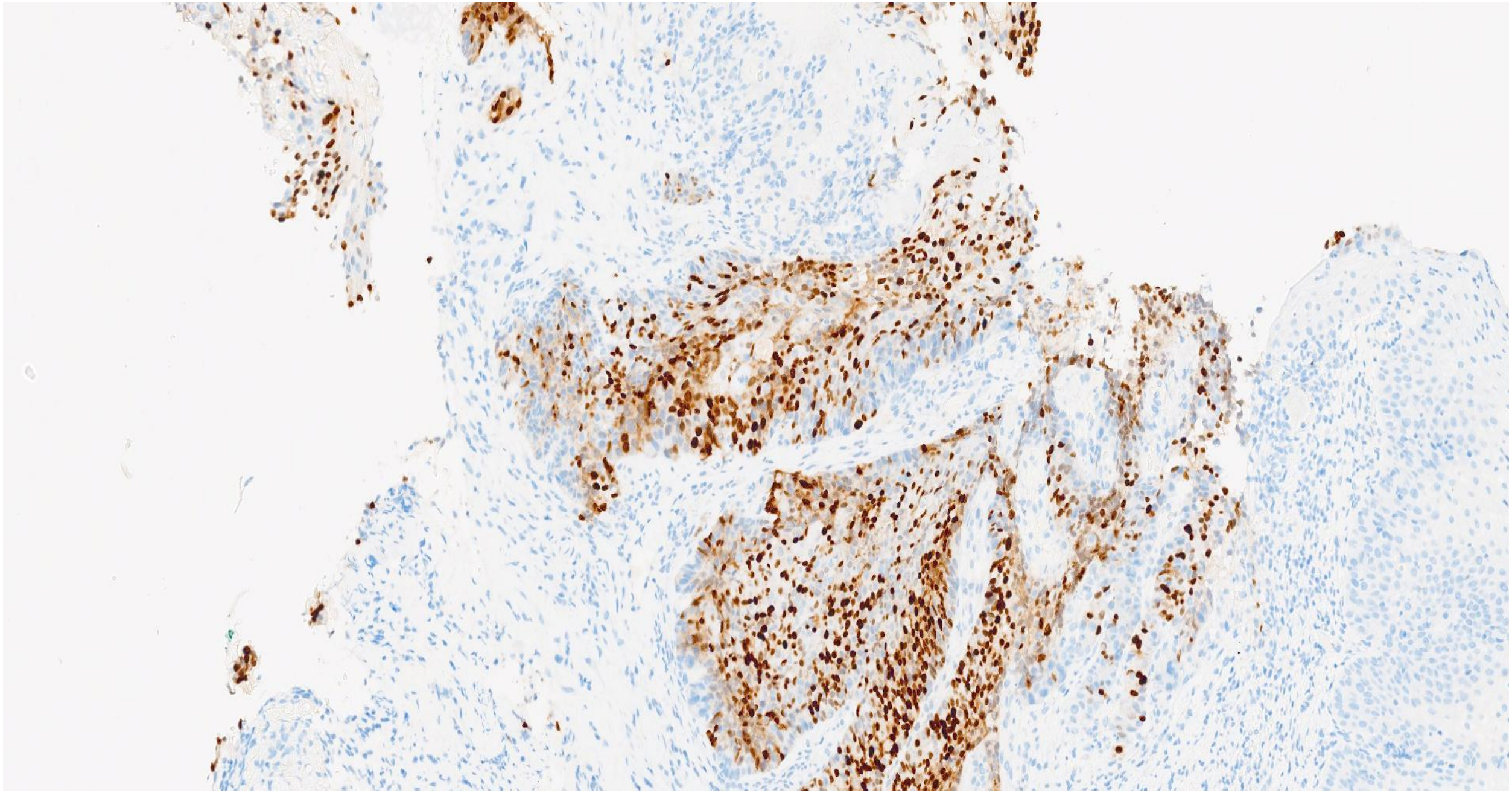

CDX2

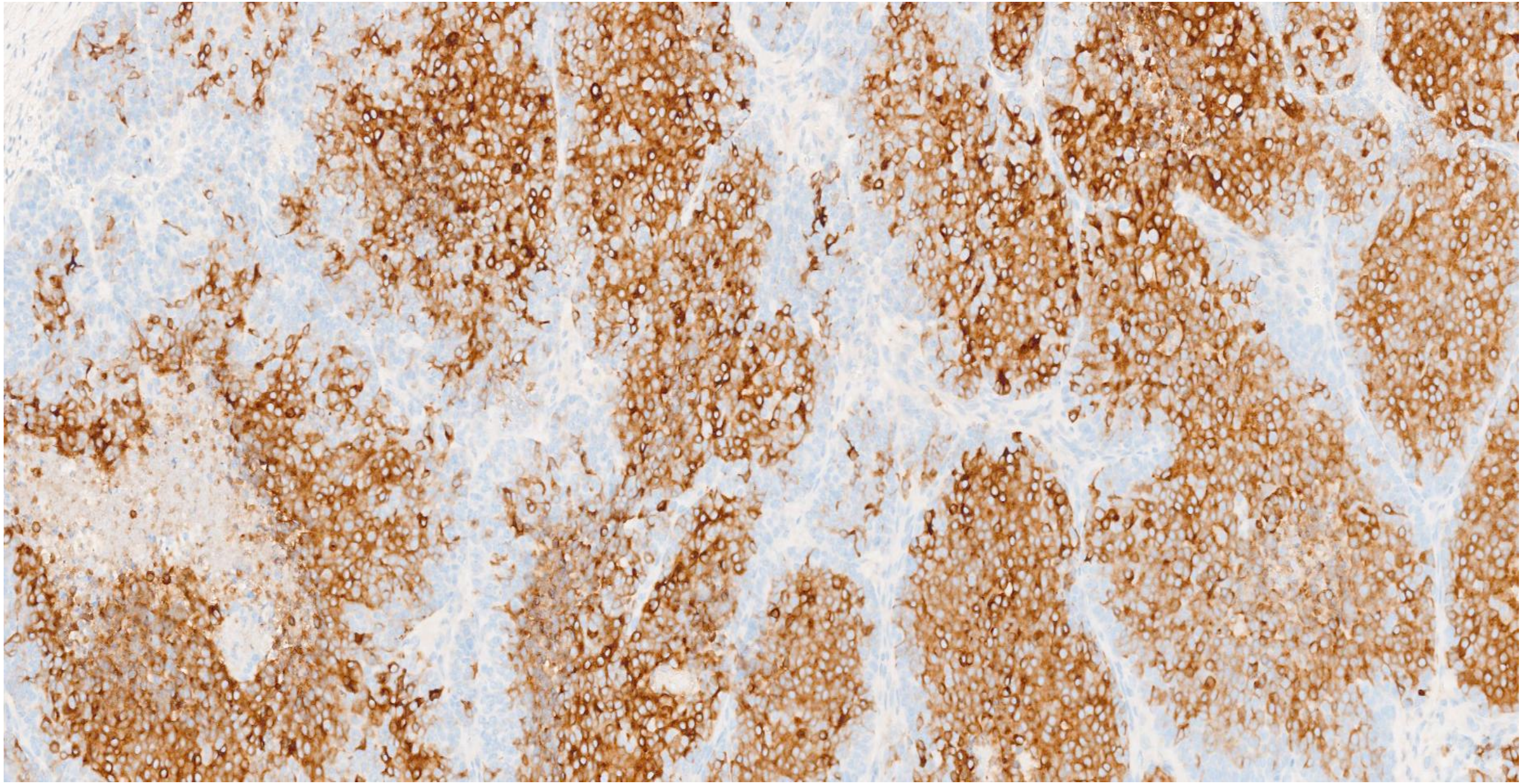

**synaptophysin**

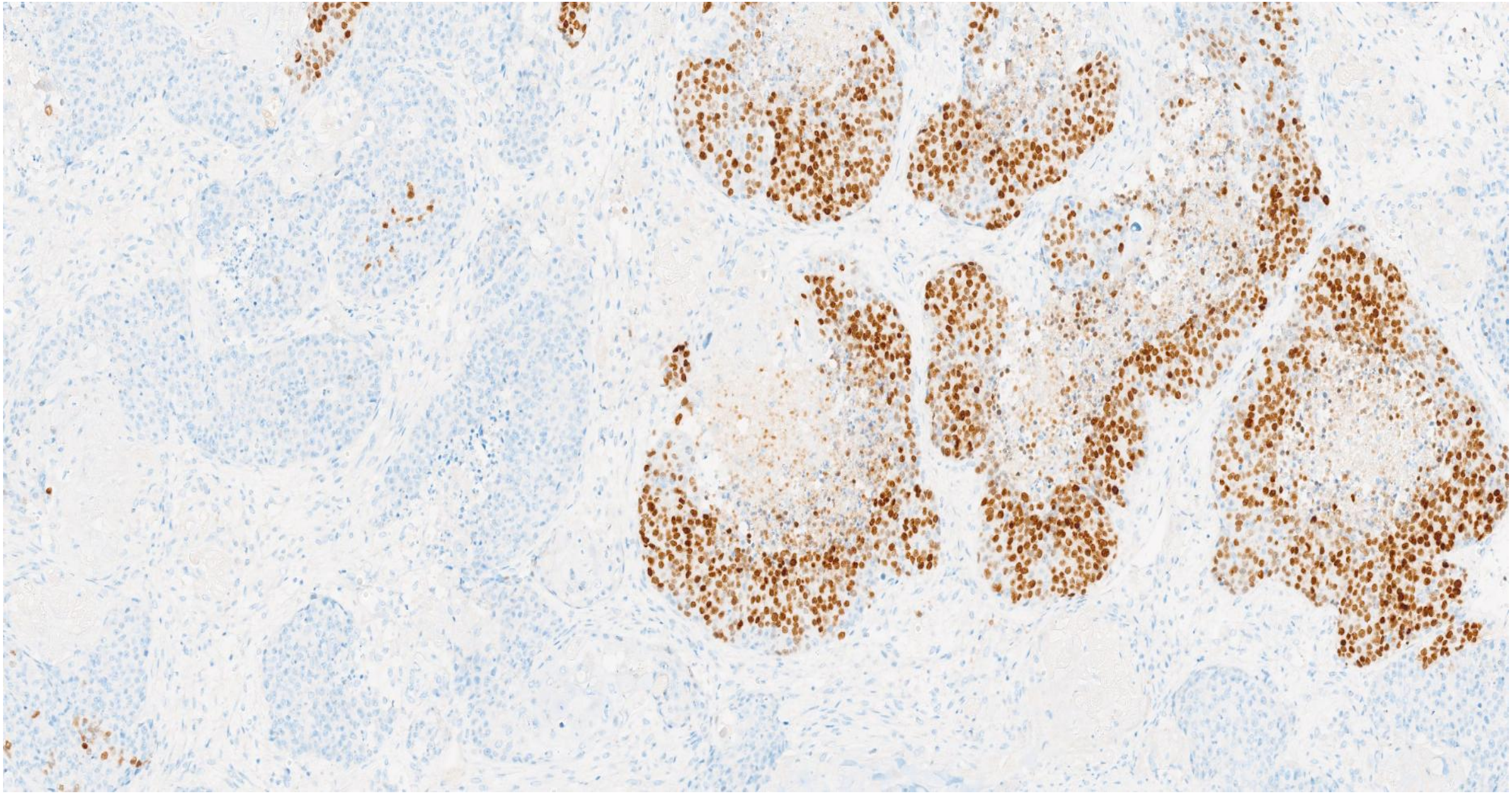

**TTF1**

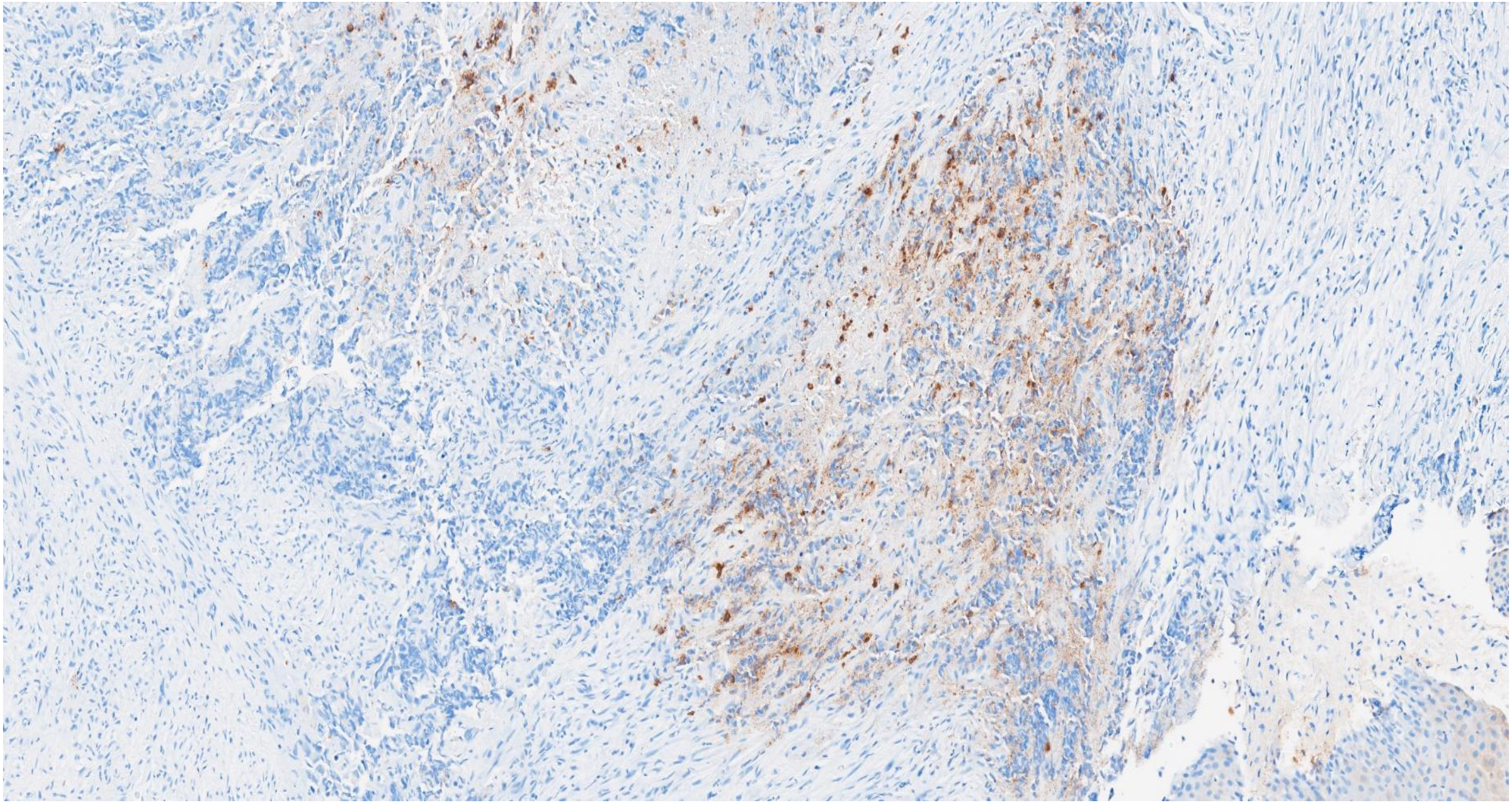

**chromogranin**

# PILOMATRIX CARCINOMA-LIKE ENDOMETRIOID CARCINOMA- PMID 33811207

*International Journal of Gynecological Pathology*
**00:**1–6, Lippincott Williams & Wilkins, Baltimore
Copyright © 2021 by the International Society of Gynecological Pathologists

Original Article

## FIGO Grade 3 Endometrioid Adenocarcinomas With Diffusely Aberrant β-Catenin Expression: An Aggressive Subset Resembling Cutaneous Pilomatrix Carcinomas

Paul Weisman, M.D., Kay J. Park, M.D., and Jin Xu, M.D.

# PILOMATRIX CARCINOMA-LIKE ENDOMETRIOID CARCINOMA: PMID 33811207

- Originally reported in uterus but also occur in ovary
- Strong morphological and immunohistochemical similarity to cutaneous pilomatrix carcinoma
- Solid basophilic cells with prominent necrosis and “shadow” cells
- Morphological variant of grade 3 endometrioid carcinoma
- Typically aberrant nuclear and cytoplasmic beta-catenin staining and often CDX2 positive
- Loss of ER, PR and PAX8
- Often neuroendocrine marker positivity (especially synaptophysin)
- Also sometimes (not always) focal conventional low-grade endometrioid component
- Aggressive behaviour and may present with metastatic disease with no conventional low-grade endometrioid component
- Some are MMR deficient; some are NSMP
- MAY BE MISDIAGNOSED AS UNDIFFERENTIATED CARCINOMA, NEUROENDOCRINE CARCINOMA, SQUAMOUS CELL CARCINOMA (these may all contain a component of low-grade endometrioid carcinoma)

# PMID 39475375

ORIGINAL ARTICLE

## High-grade Endometrial Carcinomas With Solid Basaloid Morphology and Geographic Necrosis Lacking Definitive Pilomatrix-like Features: Clinicopathologic Characteristics Including Aggressive Behavior and Novel Molecular Events

*David K. Carlson, MD,* Cheyenne Painter, MS,† Sarah E. Gradecki, MD,* Kari L. Ring, MD,‡ Eli S. Williams, PhD,* and Anne M. Mills, MD**

# PMID 39475375

- High-grade endometrioid carcinoma with solid-basaloid morphology and geographic necrosis (SB-GN)
- Overlap with pilomatrix carcinoma-like endometrioid carcinoma (but no shadow cells)
- Aggressive behaviour
- Sometimes MMR deficient; sometimes NSMP
- Some (not all) have nuclear CDX2, beta-catenin staining and *CTNNB1* mutations
- Other variants present: somatic Notch pathway (*NOTCH1/NOTCH2/NOTCH3*) variants

# ENDOMETRIOID CARCINOMA WITH MALIGNANT SQUAMOUS ELEMENTS

- Squamous differentiation common in endometrioid carcinoma and is usually morphologically bland (morular or typical)
- Rarely the squamous elements “overgrow” the endometrioid component and are overtly malignant
- Essentially this represents a squamous cell carcinoma arising out of an endometrioid carcinoma
- Terminology controversial but I recommend to call squamous cell carcinoma arising out of endometrioid carcinoma rather than endometrioid carcinoma with squamous differentiation or adenosquamous carcinoma
- These are clinically aggressive neoplasms
- With squamous cell carcinoma in ovary, sample well to identify teratomatous elements or more uncommonly endometrioid carcinoma (or endometriosis) or Brenner tumour

# SQUAMOUS CELL CARCINOMA ARISING IN ENDOMETRIOID CARCINOMA

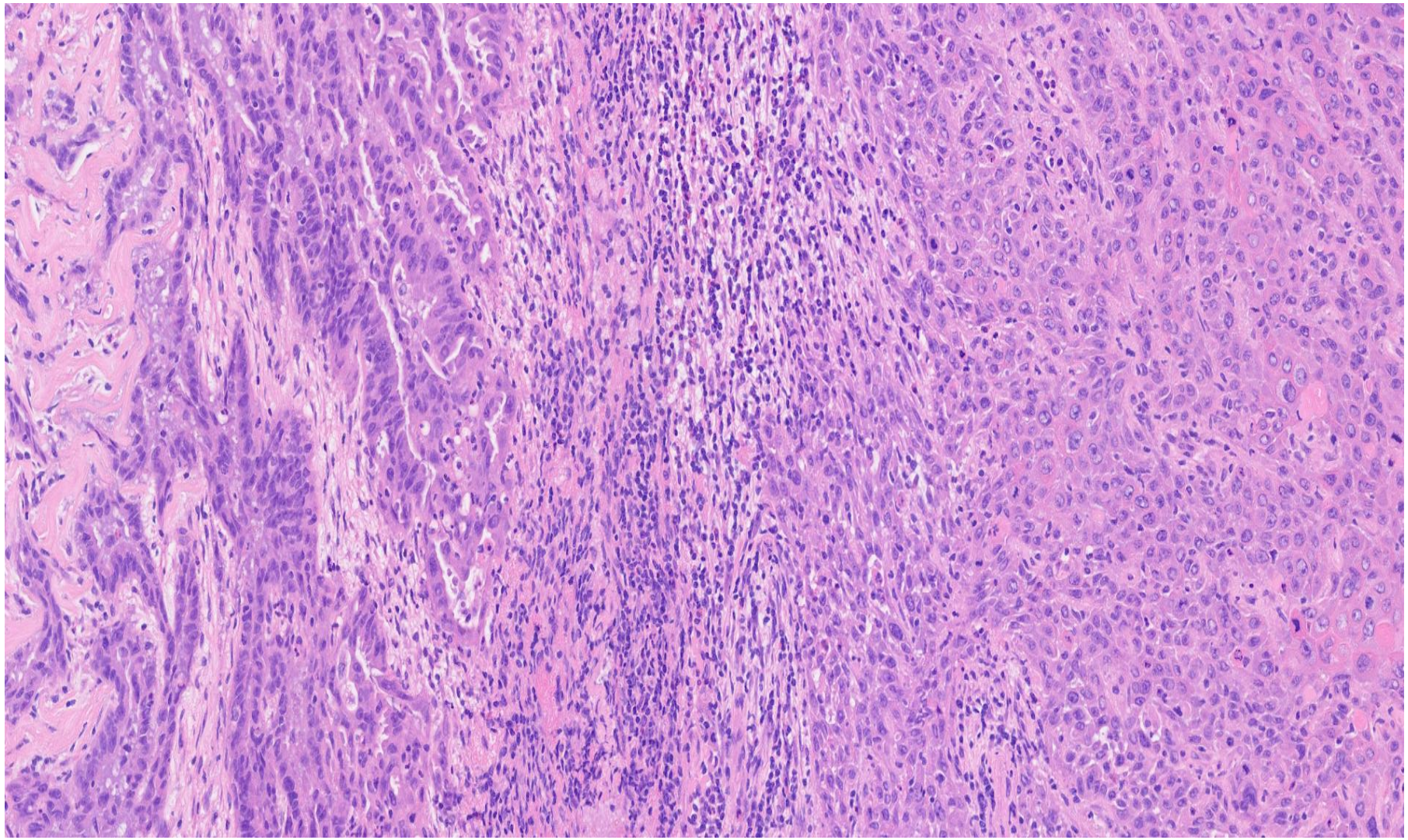

# CHARACTERISTIC IMMUNOPHENOTYPE OF OVARIAN CLEAR CELL CARCINOMA

- ER/ PR usually negative (but occasionally focally positive, especially ER)
- p53 usually wild-type but sometimes (uncommon) mutation-type
- p16 usually focal
- WT1 usually negative
- **Napsin A** usually positive but often focal and may be negative
- **AMACR/ rasemase** often positive but very non-specific marker
- **HNF1 beta** usually diffusely positive but very non-specific marker
- Uncommonly get loss of MMR protein expression

# CASE 4

- F 40
- Unilateral oophorectomy for endometriotic cyst

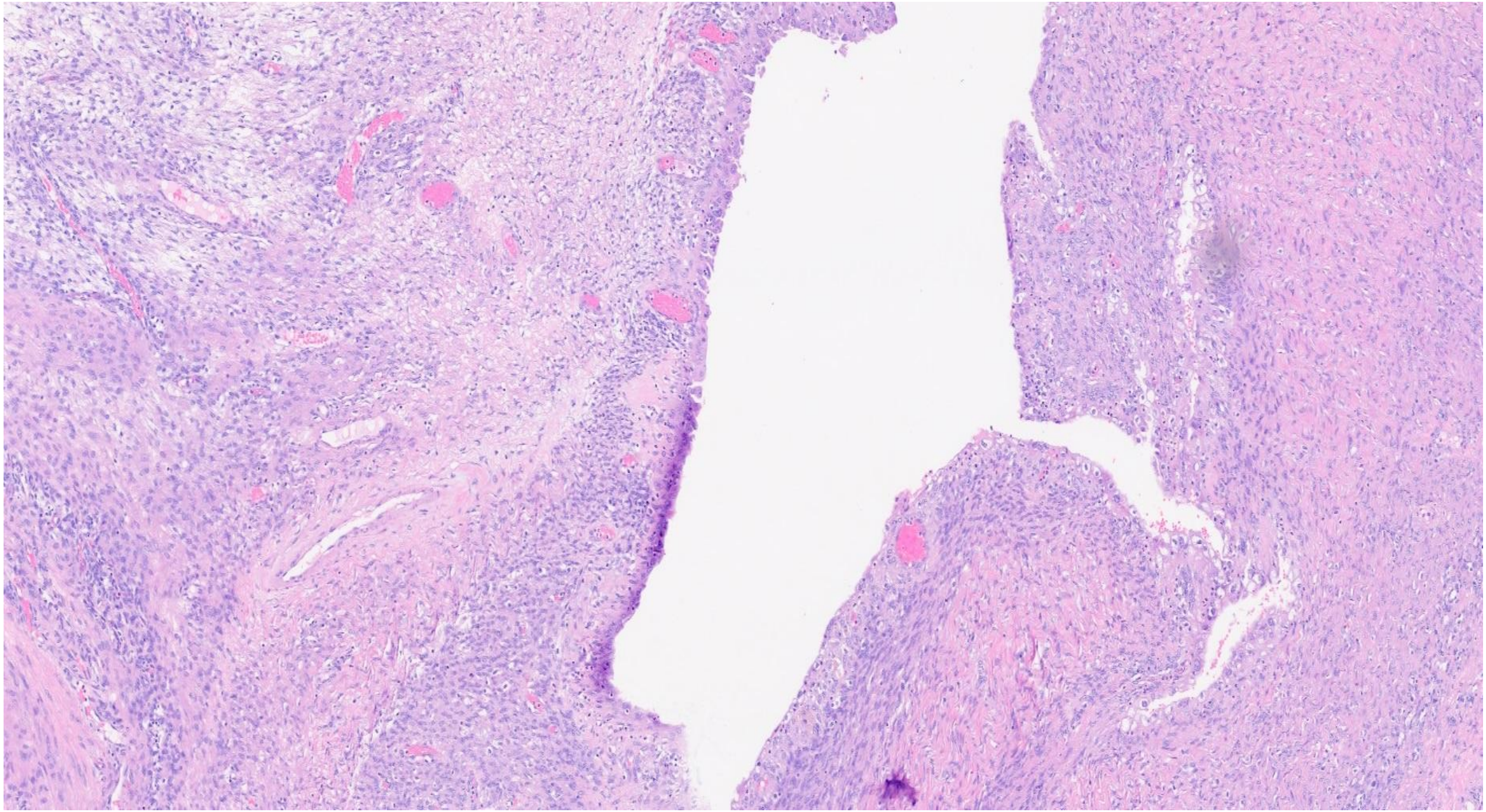

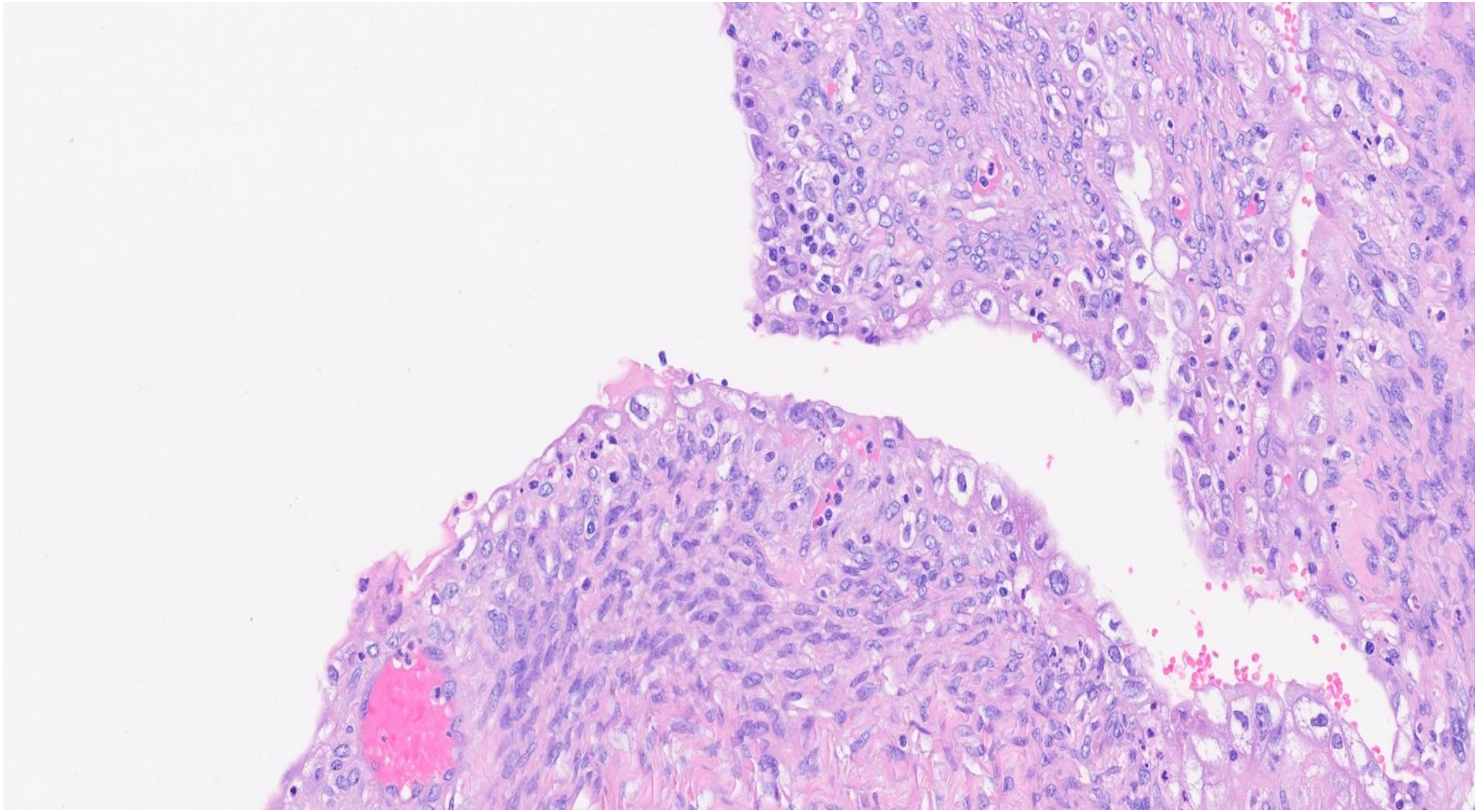

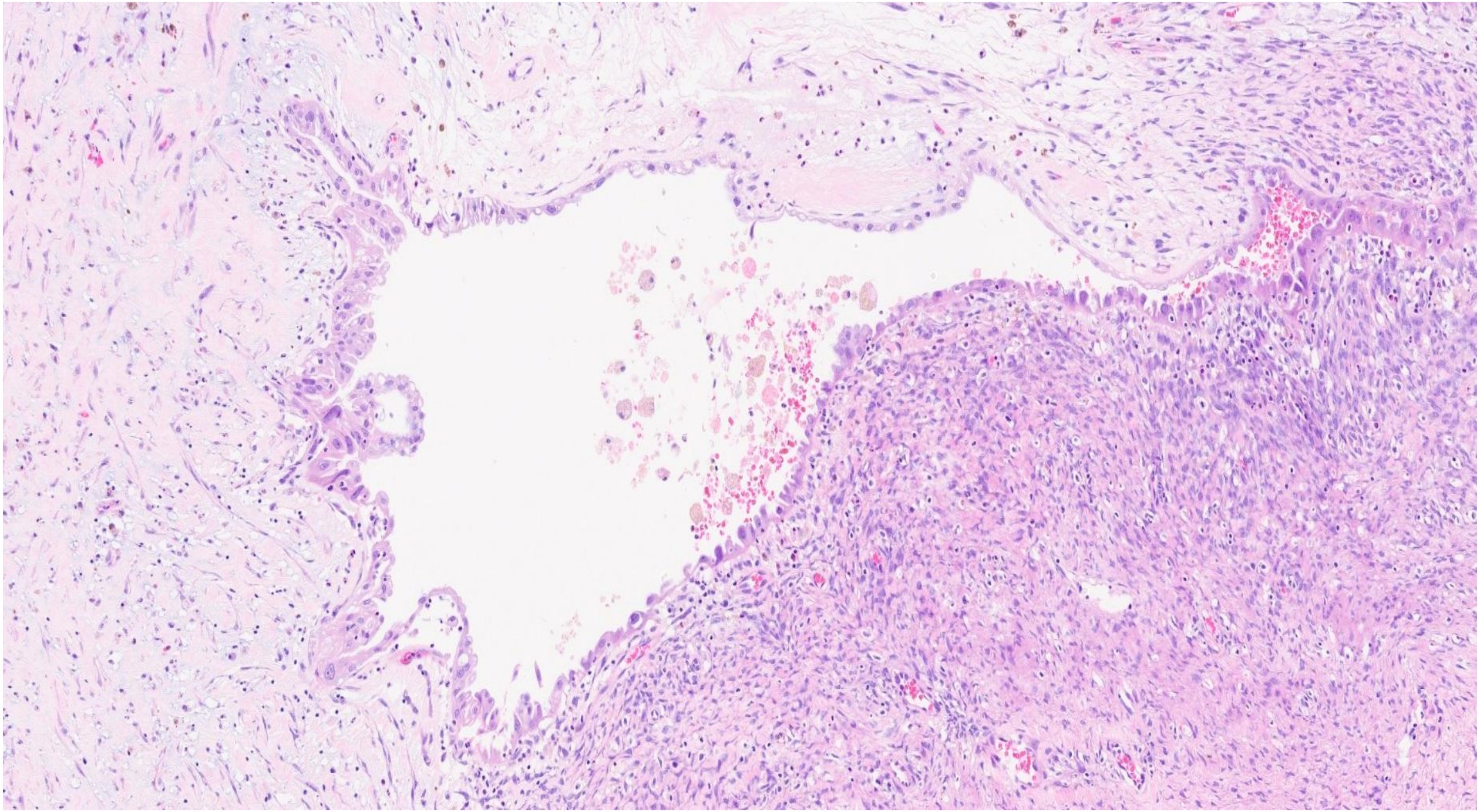

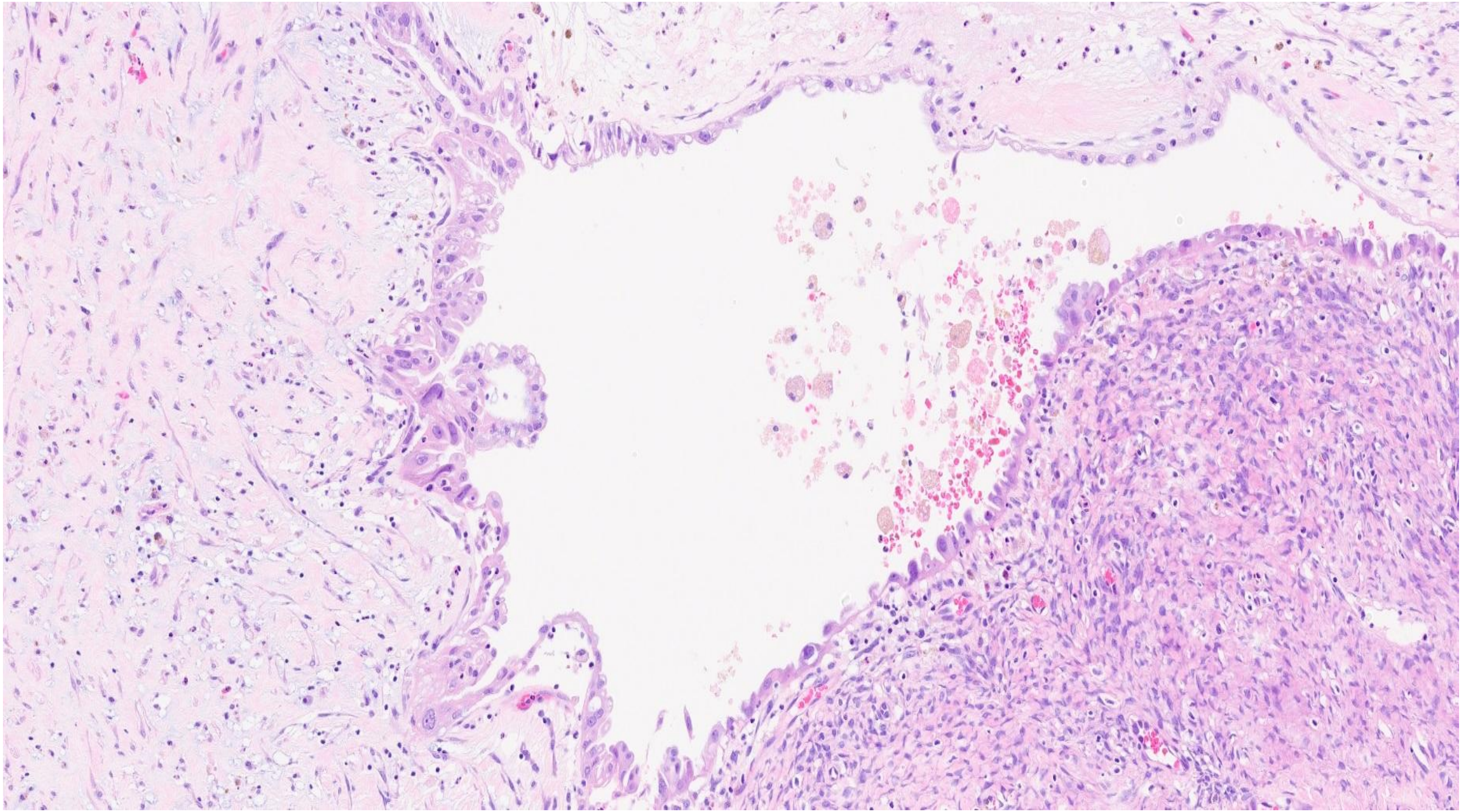

# IMMUNOHISTOCHEMISTRY

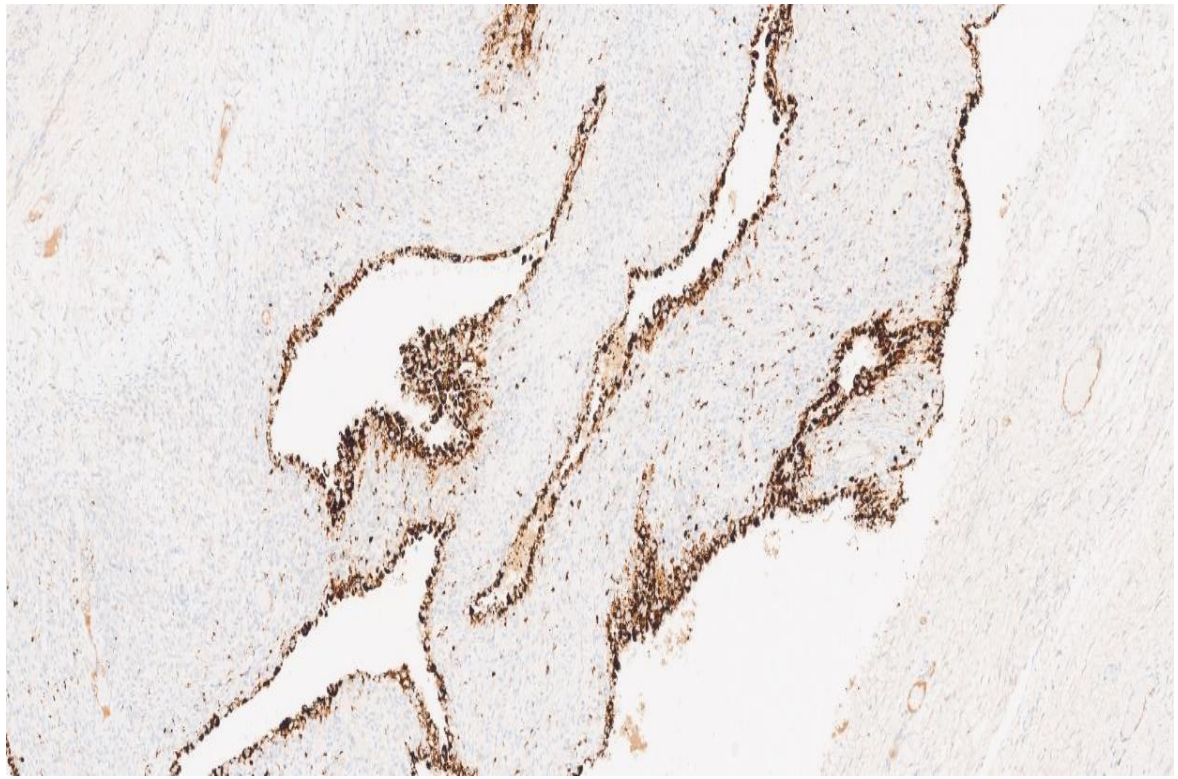

**Napsin A**

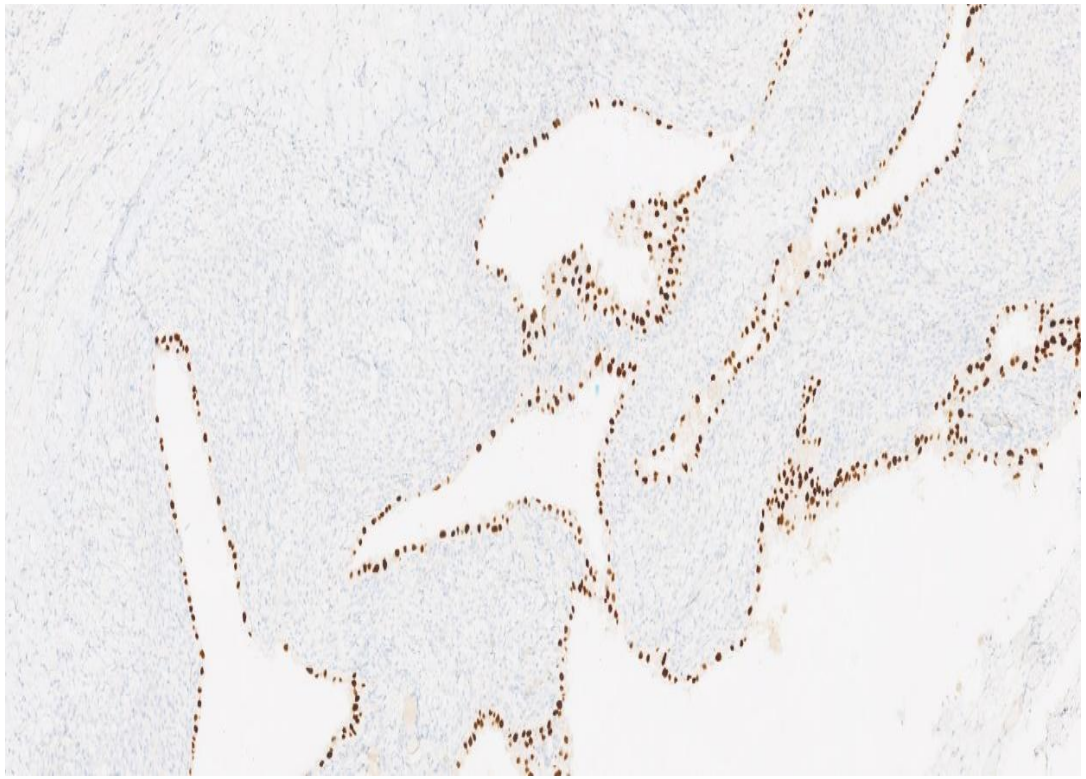

**HNF1 beta**

# IMMUNOHISTOCHEMISTRY

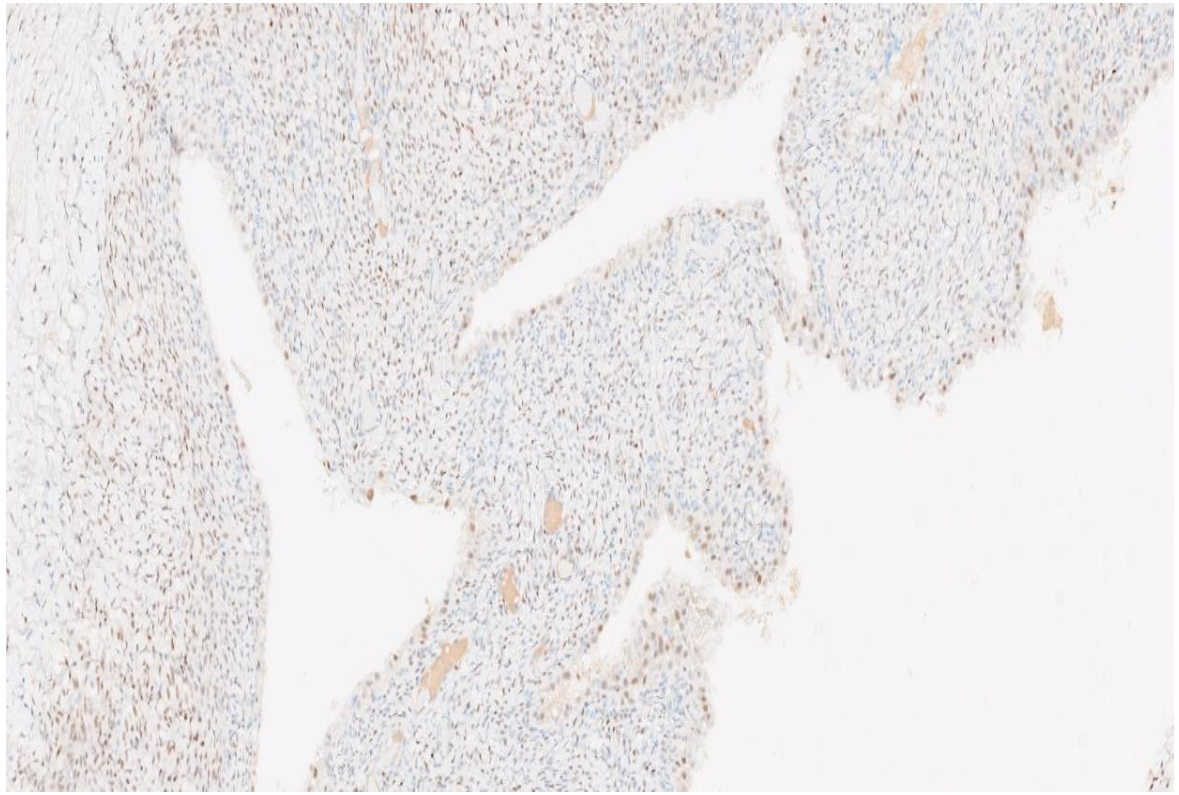

**ER**

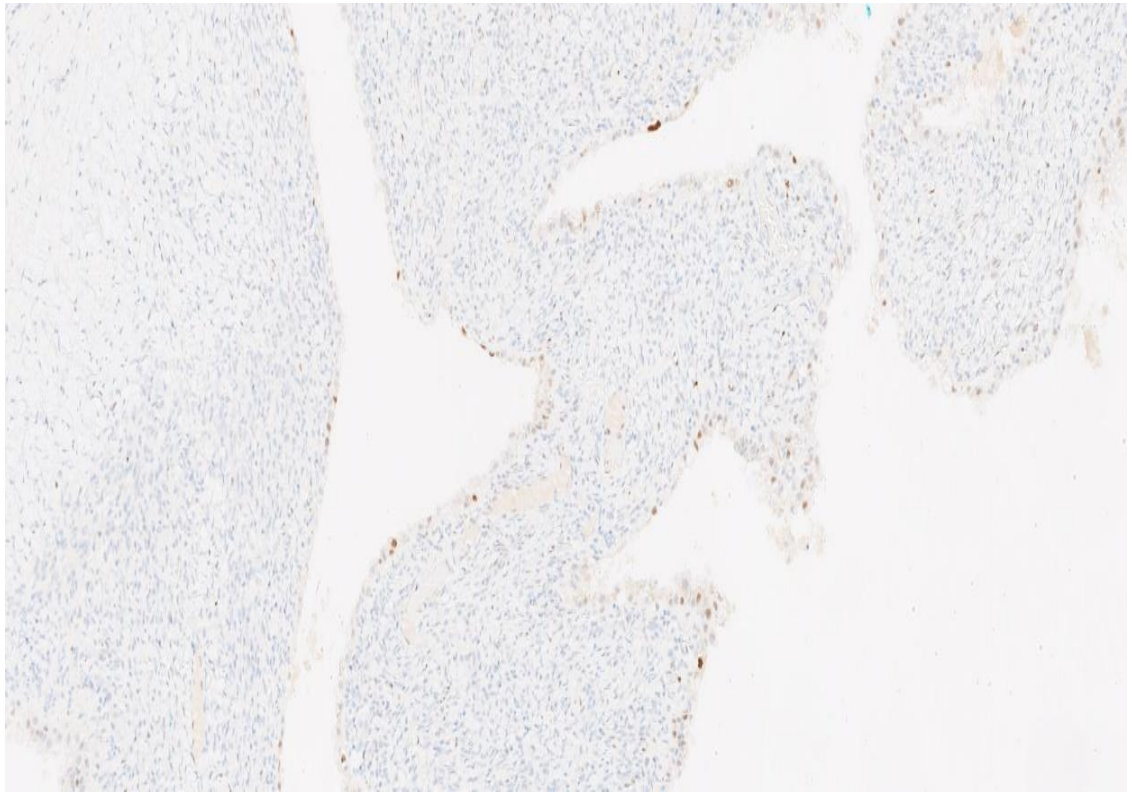

**p53**

# SUMMARY OF IMMUNOHISTOCHEMISTRY

- Napsin A, HNF1 beta, racemase diffusely positive
- PAX8 diffusely positive
- ER focal weak positivity
- WT1, PR negative
- MMR proteins retained
- p53 wild-type

# ? WHAT TO CALL

- ? Clear cell carcinoma
- ? Intracystic clear cell carcinoma
- ? Intraepithelial clear cell carcinoma
- ? Clear cell carcinoma in situ
- ? Clear cell borderline tumour
- ? Atypical endometriosis
- ? Endometriosis with description
- NEED SOME RECOMMENDATIONS

# PAPER UNDERGOING REVIEW

- Various procedures- hysterectomy, BSO; oophorectomy
- Areas of typical endometriosis merging with areas of clear cell proliferations **(need to see some stratification, not just flat monolayer) morphologically (hobnail cells, atypia, some mitoses, cytoplasmic clearing)** and immunophenotypically in keeping with clear cell carcinoma
- No “invasion” into surrounding stroma
- Uneventful short-term follow-up
- Molecular in some cases; one had a pathogenic *MSH6* variant

# PROPOSAL: PAPER UNDERGOING REVIEW

- Call these clear cell carcinoma in situ
- BUT need close liaison with clinician to ensure no adjuvant therapy or staging procedure
- Need conversation with clinician and patient to explain that this is not an invasive cancer
- Submit rest of ovarian tissue
- If cystectomy only, might consider oophorectomy

# OTHER POINTS

- ER not always totally negative; can be focally positive in “early” clear cell carcinomas
- Remember Napsin A can be positive in endometriotic cysts (including so-called atypical endometriosis)
- Remember HNF1 beta is a totally non-specific marker
- Can get molecular changes in endometriosis/ endometriotic cysts (including so-called atypical endometriosis)

# NAPSIN A IN ENDOMETRIOTIC CYST

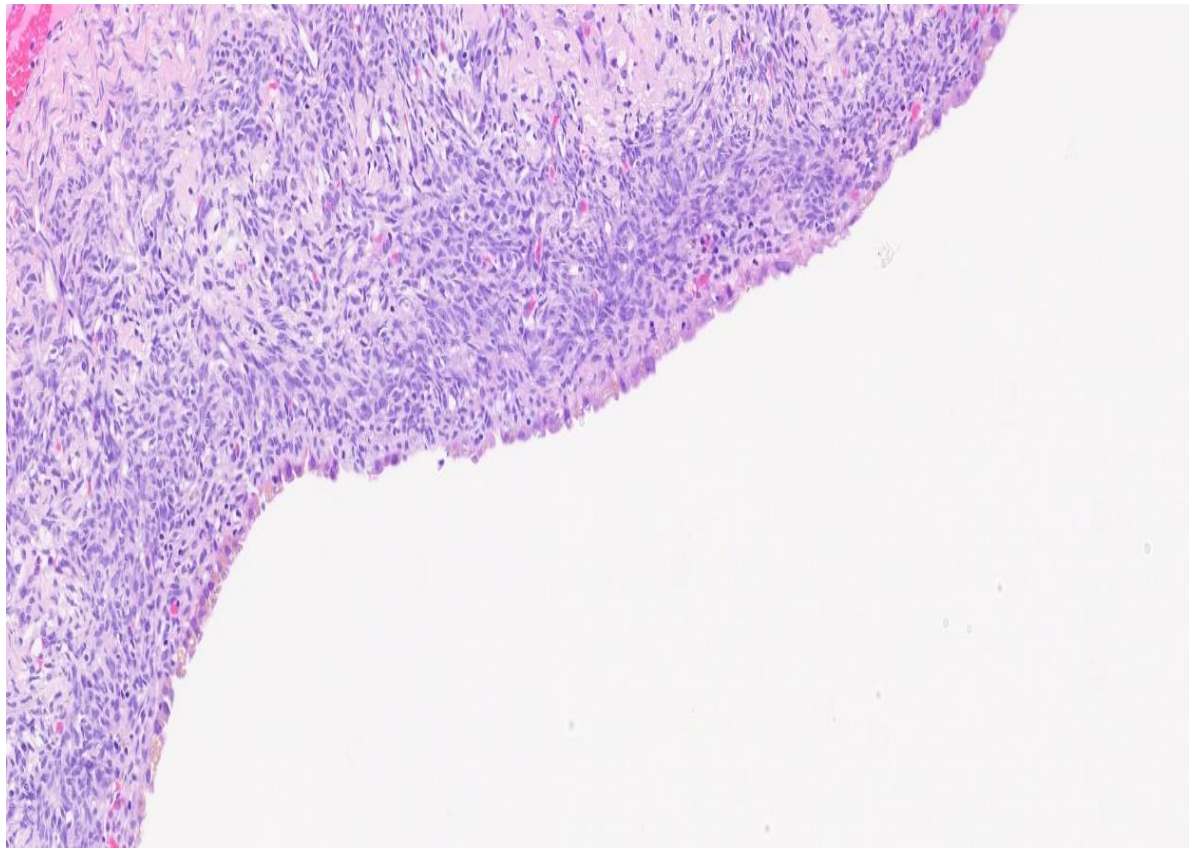

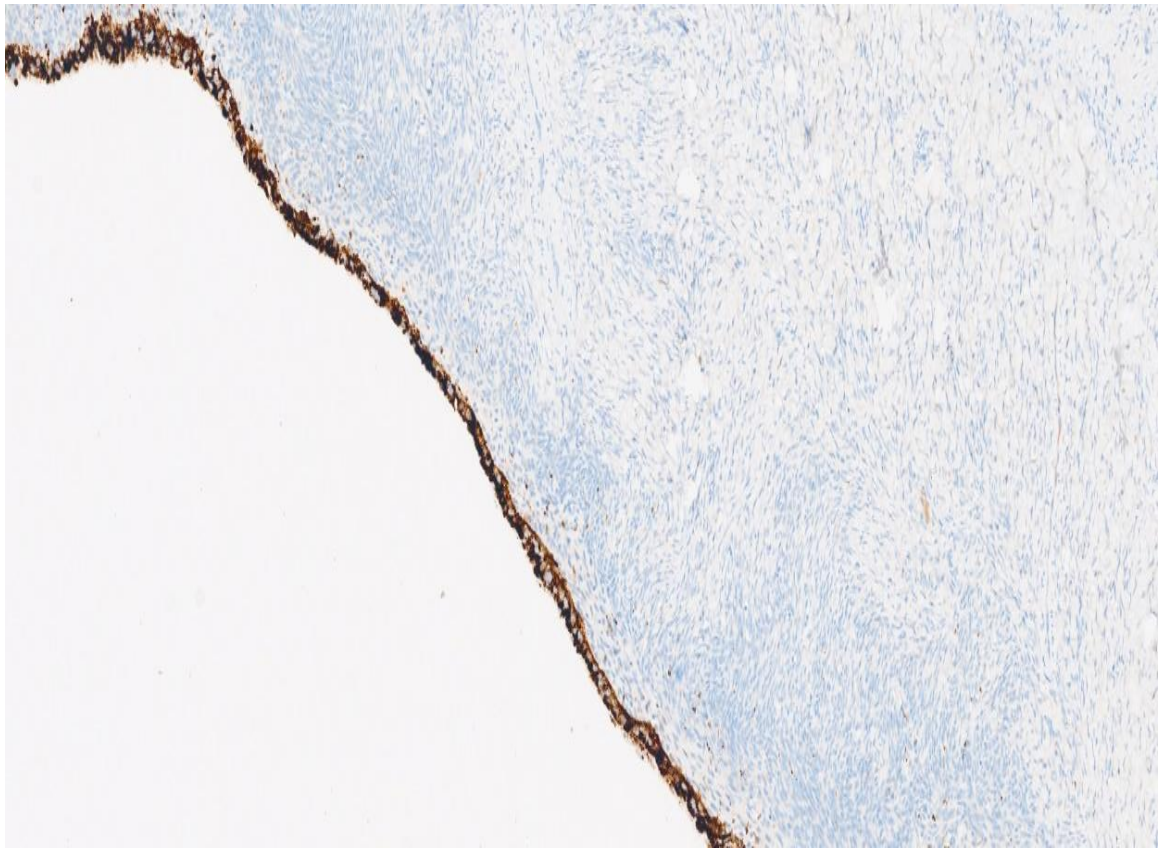

# NAPSIN A IN HOBNAIL EPITHELIUM ON SURFACE OF INFARCTED ENDOMETRIAL POLYP: PMID 38781161

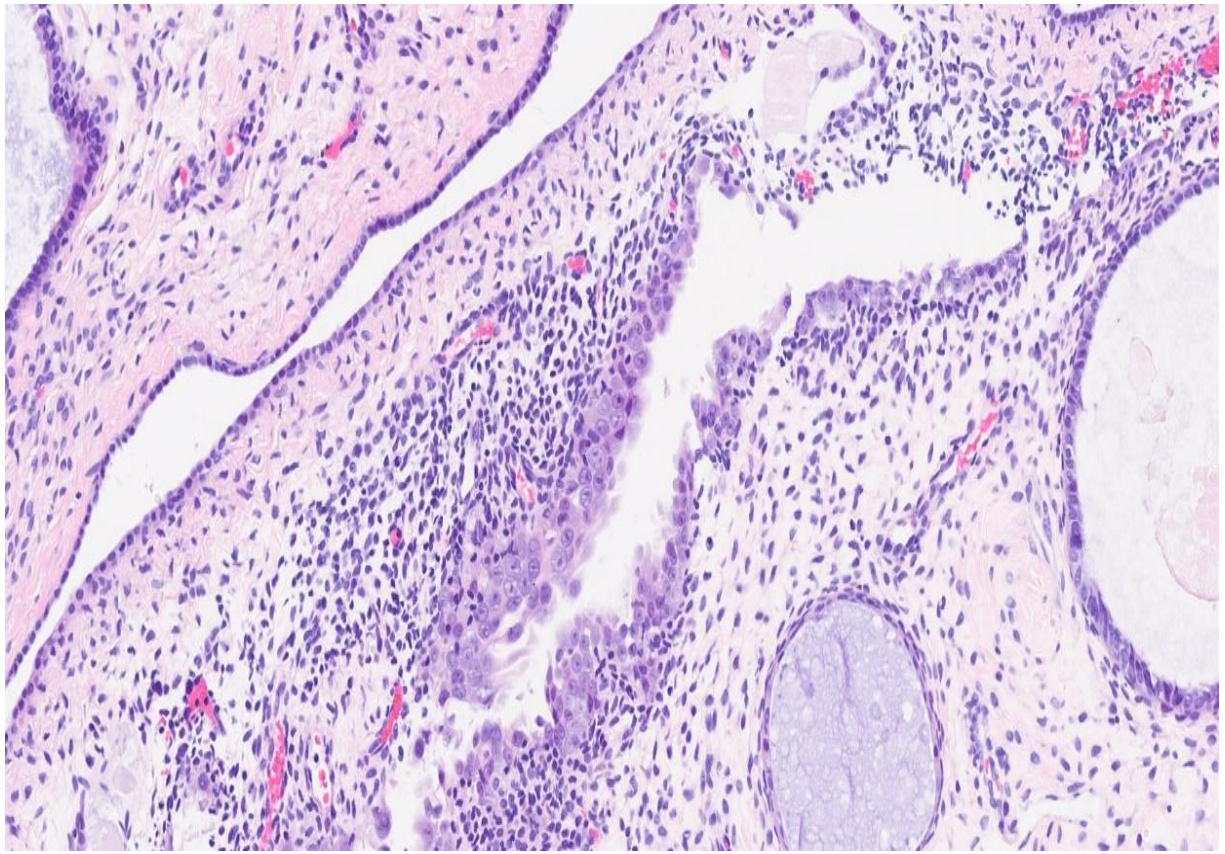

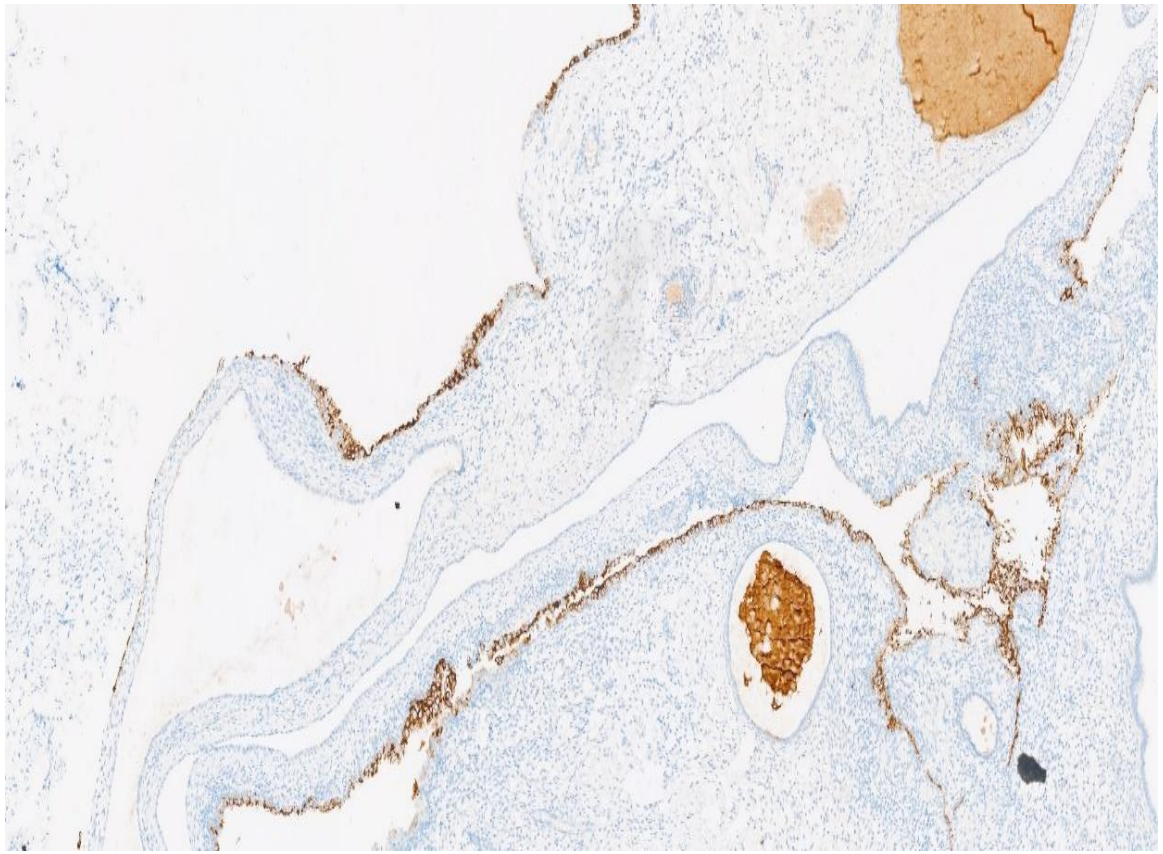

# HNF 1 BETA- NON-SPECIFIC MARKER

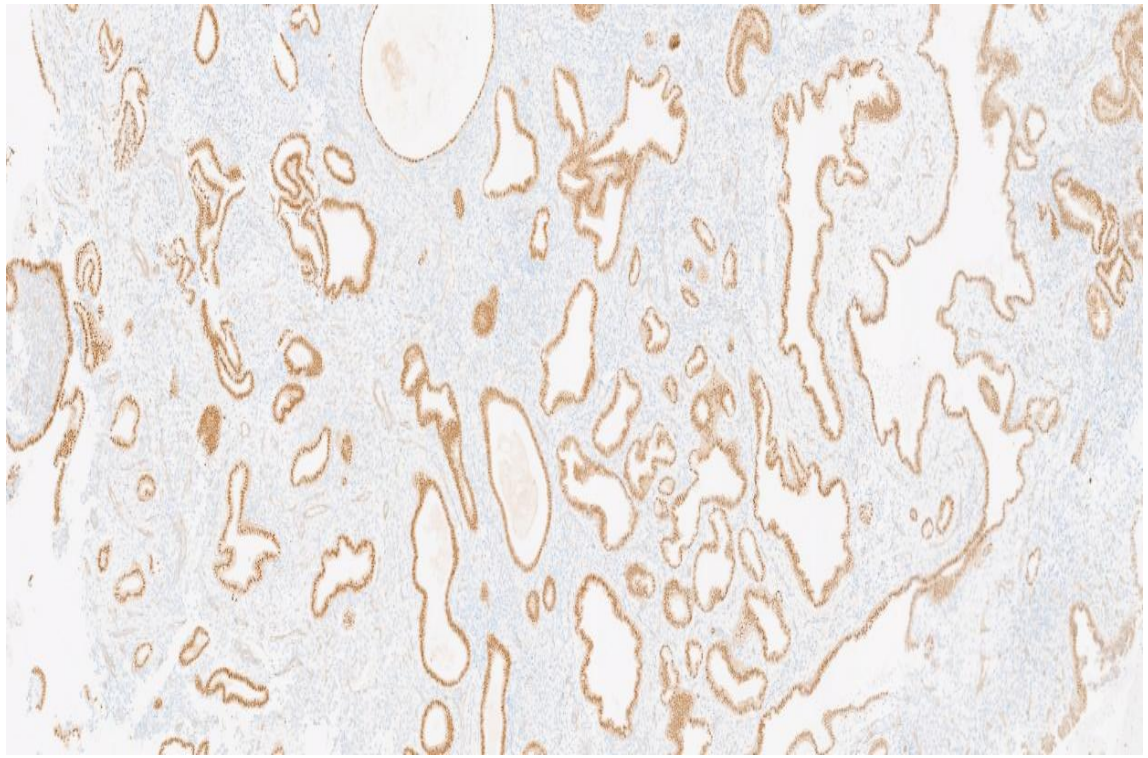

**Benign endometrial polyp**

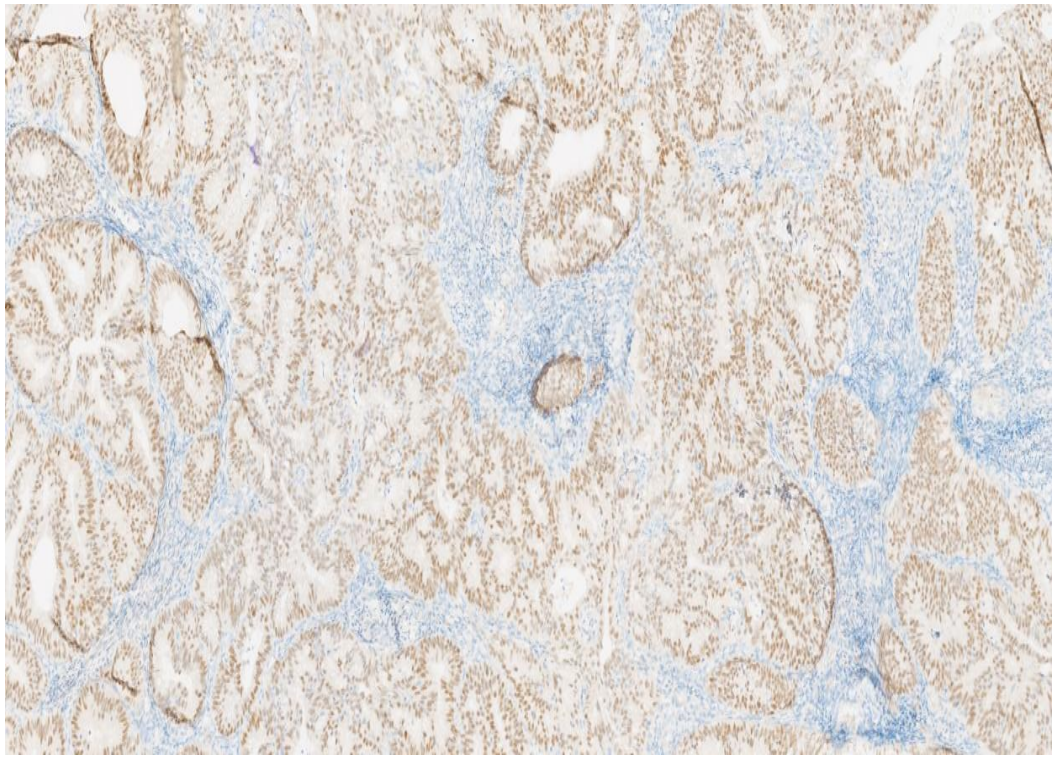

**Low-grade endometrioid carcinoma**

# SEROMUCINOUS BORDERLINE TUMOURS

- WHO 2020- “An architecturally complex papillary neoplasm composed of an admixture of Mullerian type epithelia, lacking confluent or destructive stromal invasion”
- May be bilateral
- Often associated with endometriosis; may arise in endometriotic cyst
- Typically smaller than mucinous borderline tumours with smooth external surface and internal papillary excrescences
- Typically oedematous stromal core containing polymorphs
- Admixture of “proliferating” cell types with stratification and tufting (serous/ ciliated, endometrioid, mucinous, squamous, clear cell, hobnail, “indifferent” eosinophilic)
- Uncommonly get areas of microinvasion and extraovarian implants
- Typically positive with Mullerian markers (CK7, CA125, PAX8, ER, PR) but typically WT1 negative
- Often *KRAS* and *ARID1A* mutations
- **CAN GET CARCINOMAS ARISING WITHIN; NOW CONSIDERED TO BE ENDOMETRIOID CARCINOMAS (CATEGORY OF SEROMUCINOUS CARCINOMA WAS REMOVED IN WHO 2020)**

# PMID 25723110. AJSP 2015; 39; 983-992-

ORIGINAL ARTICLE

## Ovarian Seromucinous Carcinoma

*Report of a Series of a Newly Categorized and Uncommon Neoplasm*

*Jennifer Taylor, MB and W. Glenn McCluggage, FRCPath*

# PMID 28125452 (AJSP 2017;41; 685-695)

ORIGINAL ARTICLE

## Morphologic Reproducibility, Genotyping, and Immunohistochemical Profiling Do Not Support a Category of Seromucinous Carcinoma of the Ovary

*Peter F. Rambau, MD,*† John B. McIntyre, PhD,‡ Jennifer Taylor, MD,§ Sandra Lee, MD,* Travis Ogilvie, MD,* Anna Sienko, MD,* Don Morris, MD,‡‖ Máire A. Duggan, MD,* W. Glenn McCluggage, MD,§ and Martin Köbel, MD**

# CASE 5

- F 30
- Removal of 6 cm unilateral ovarian mass

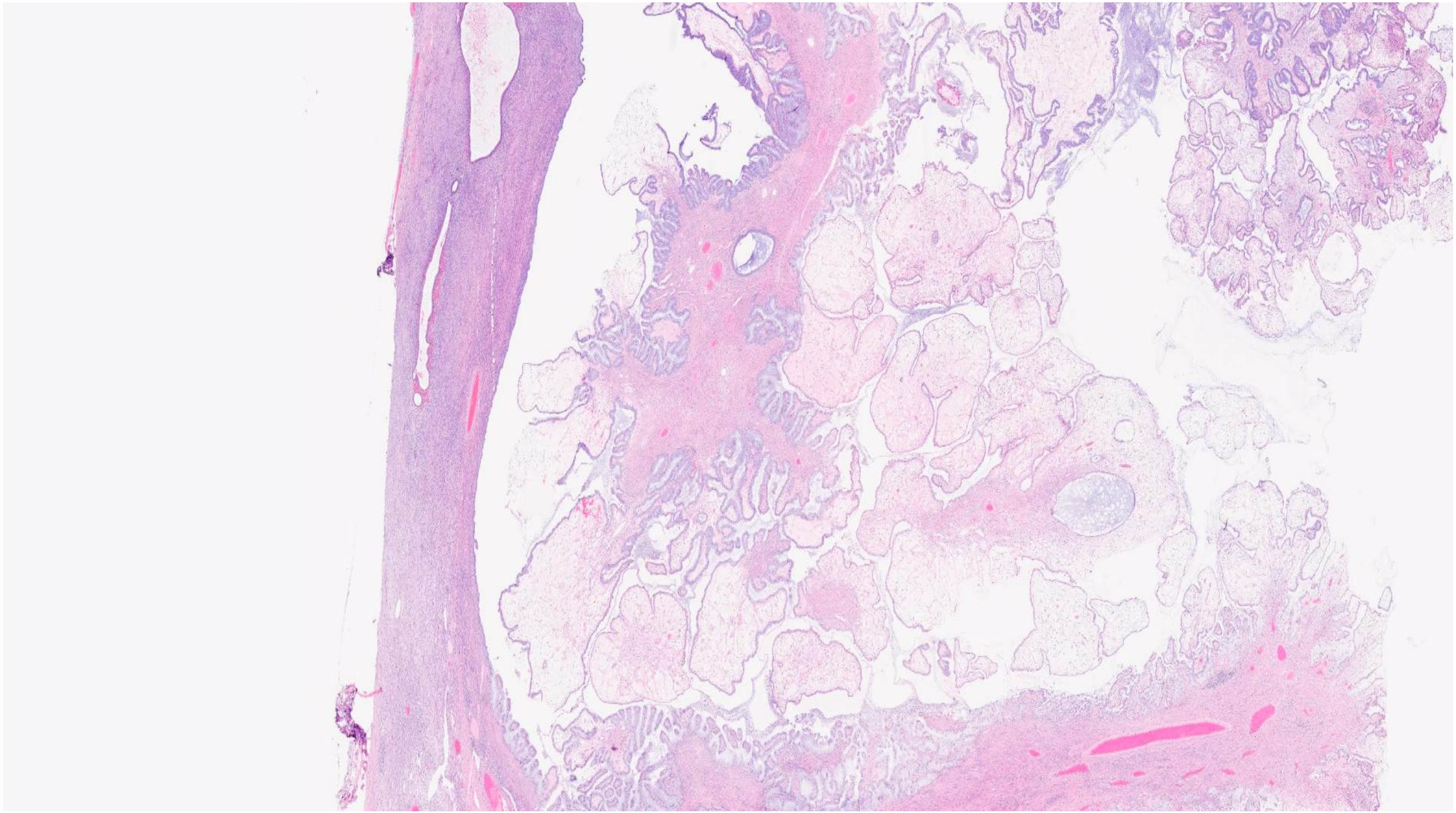

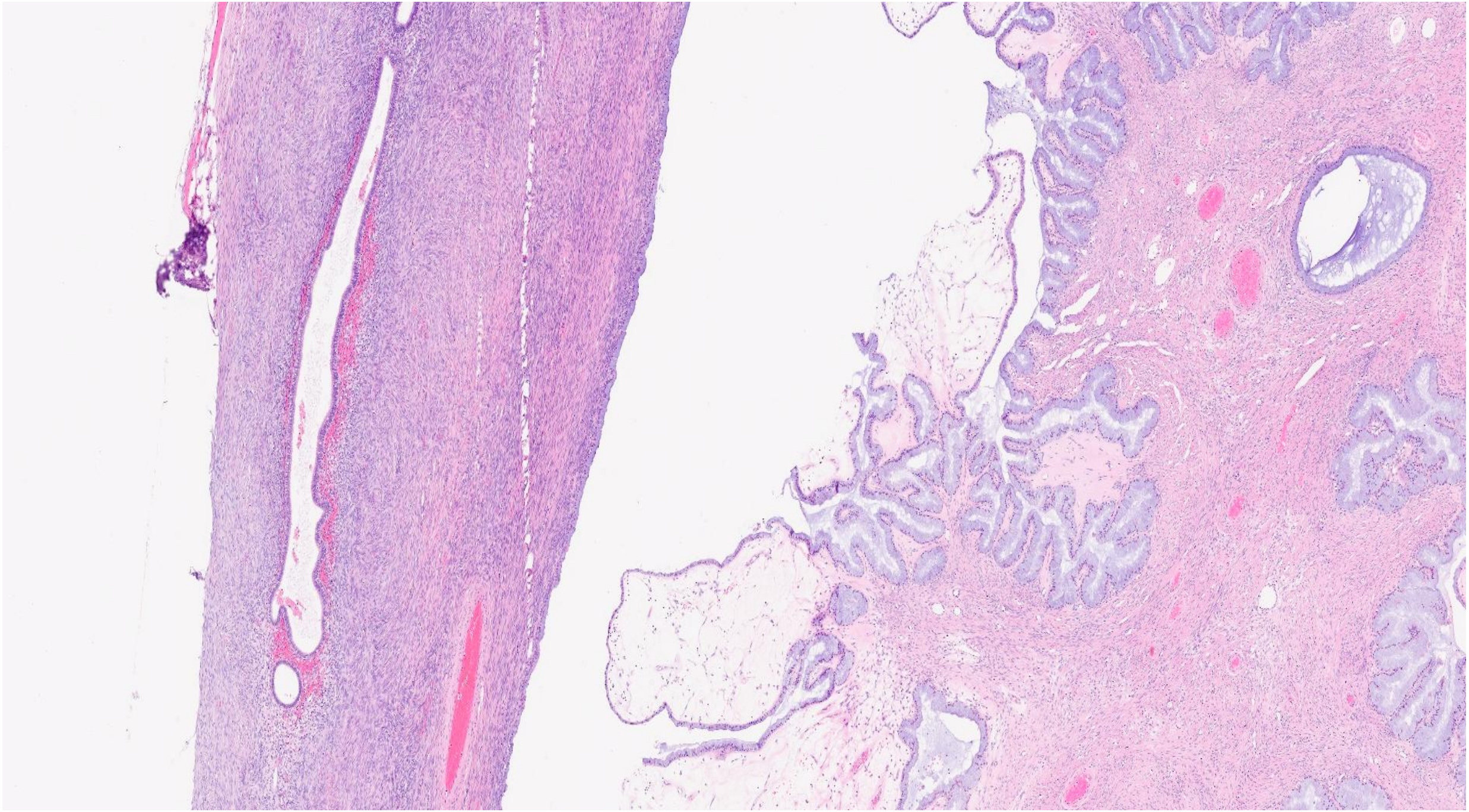

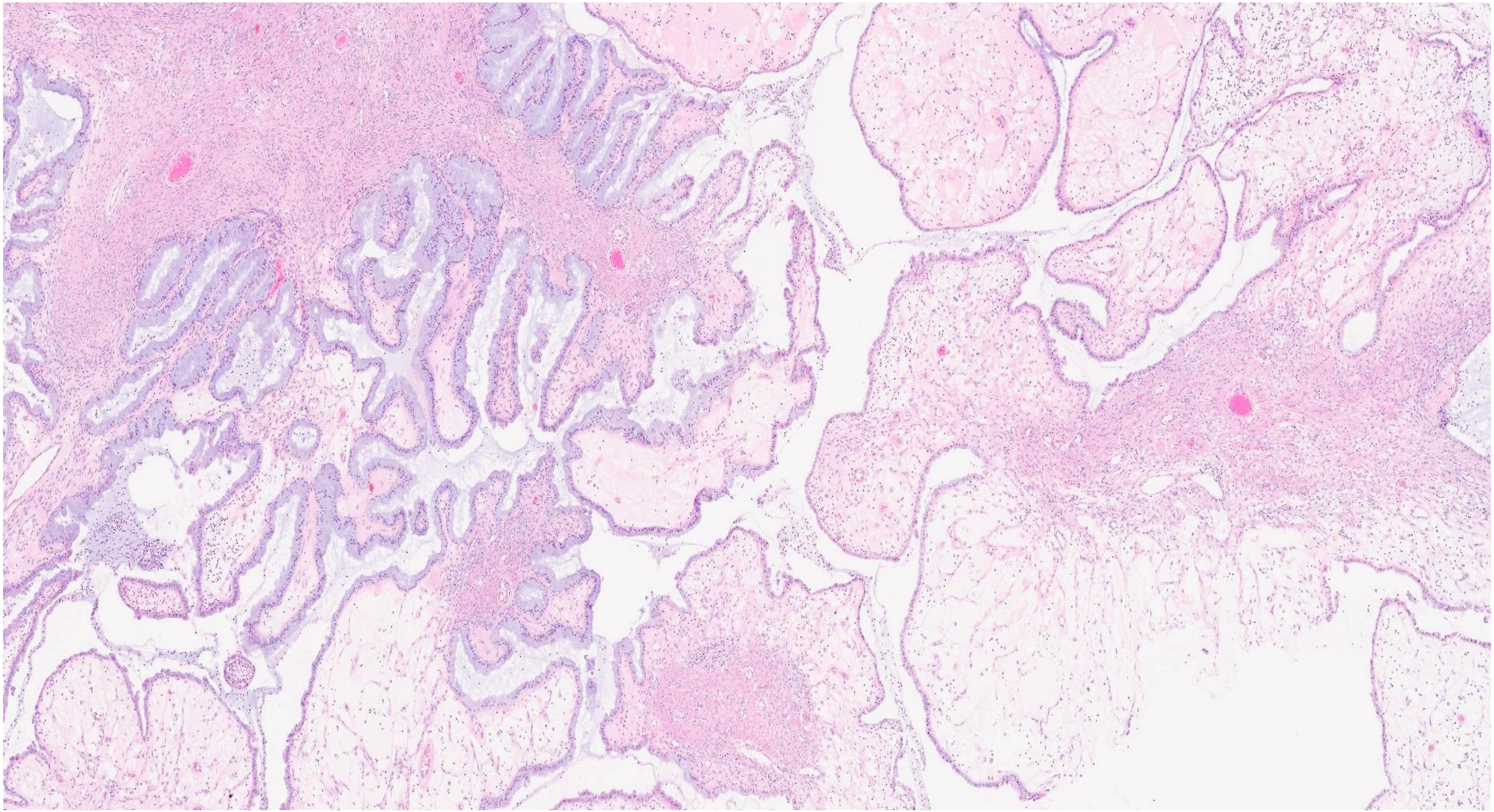

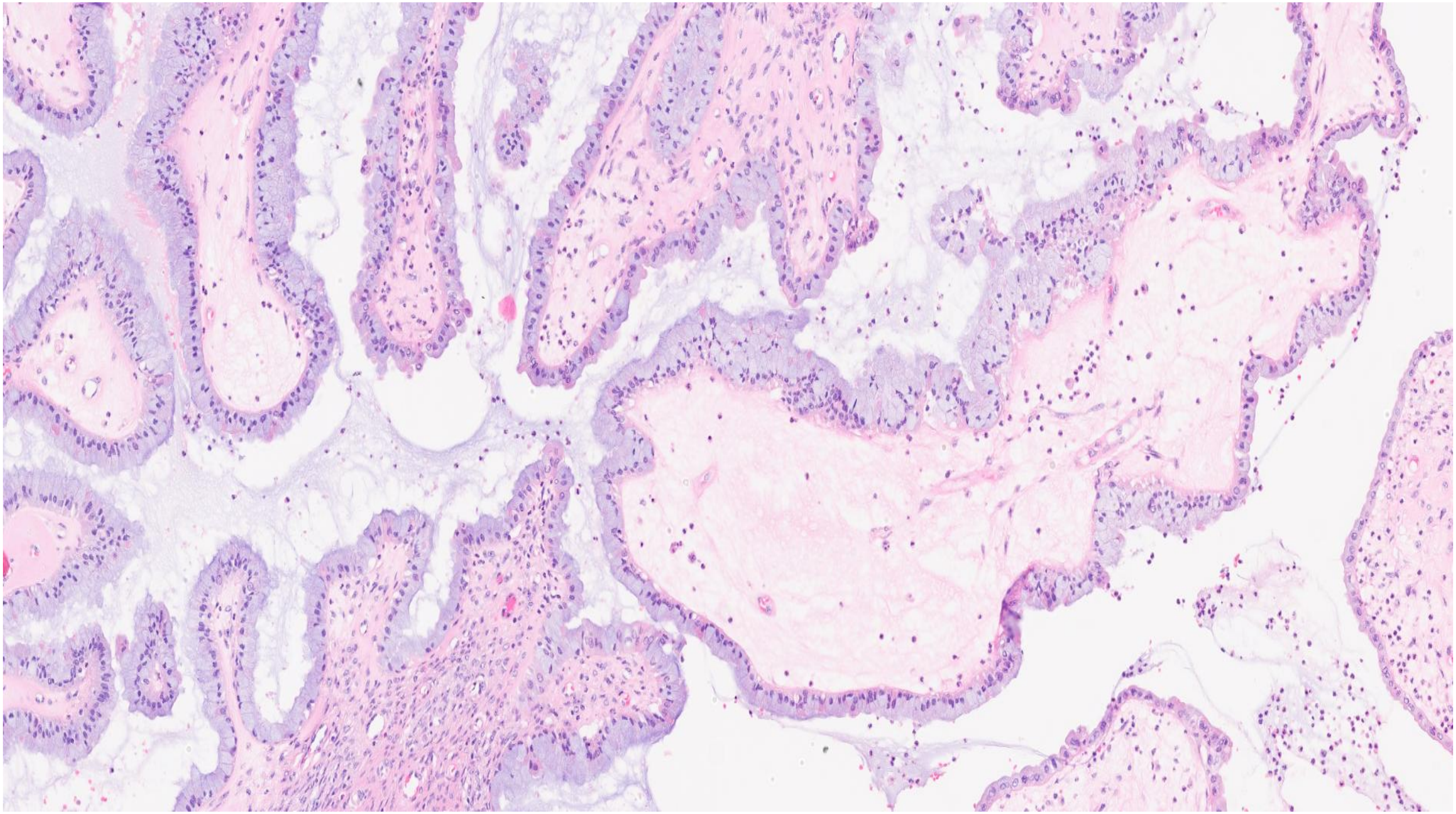

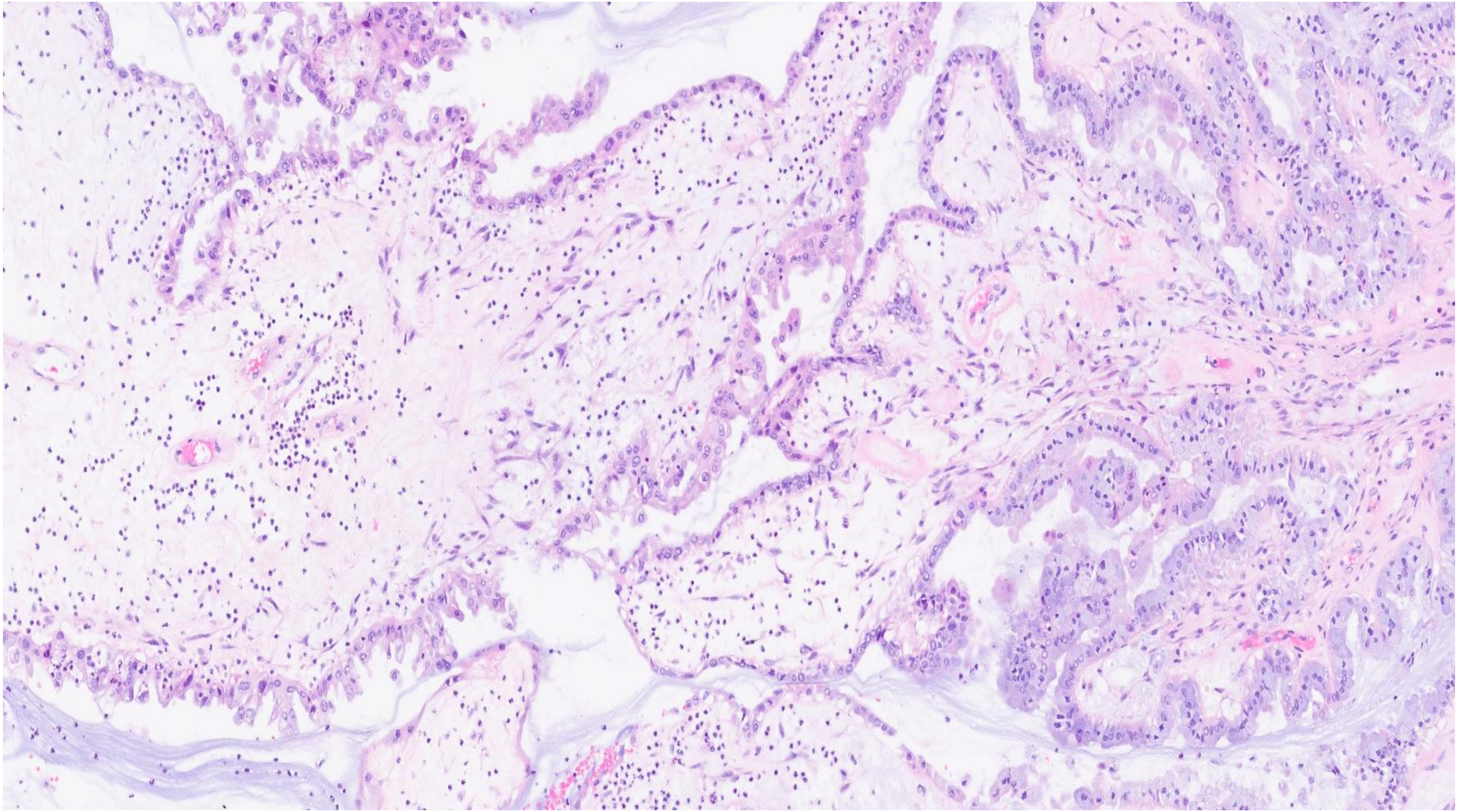

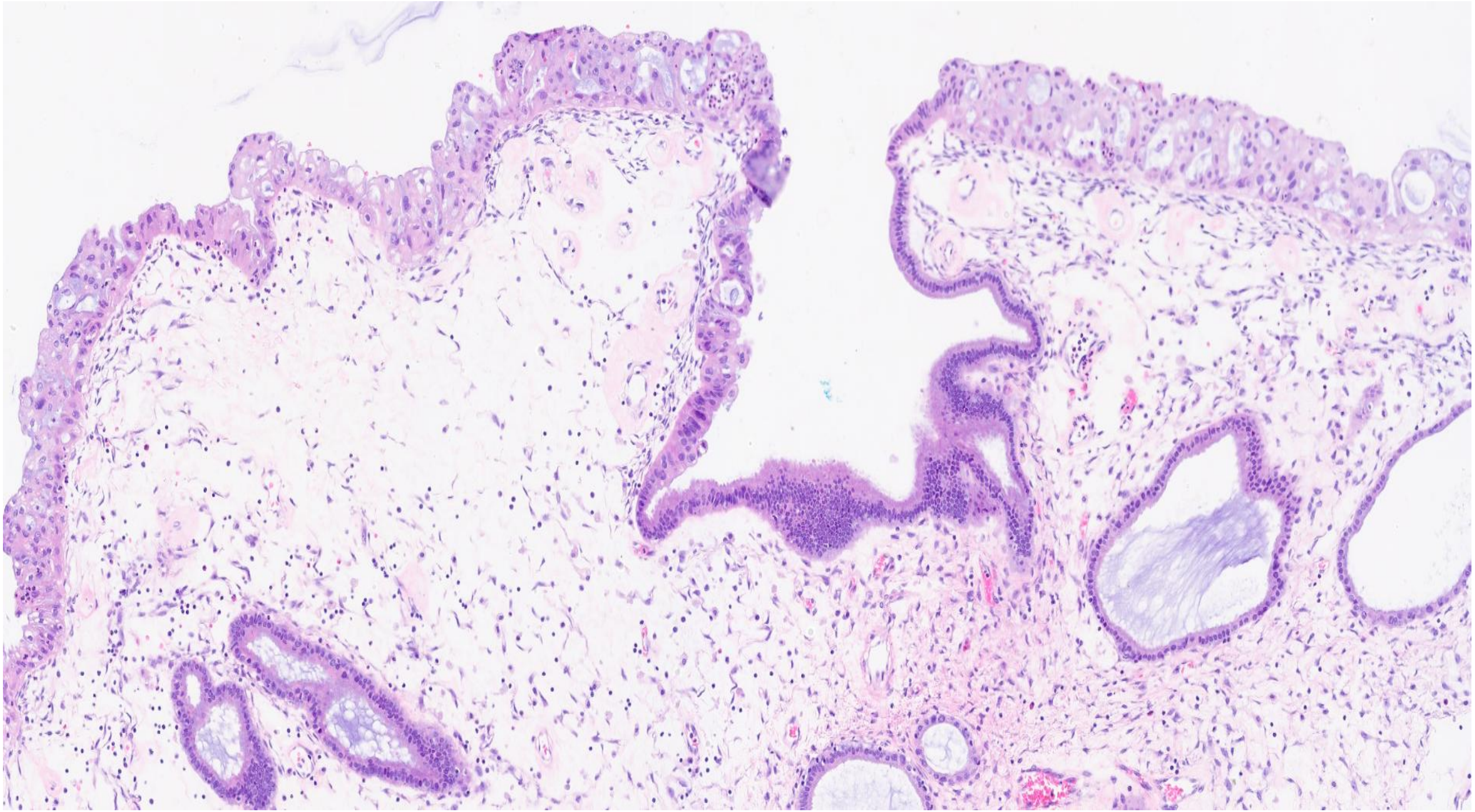

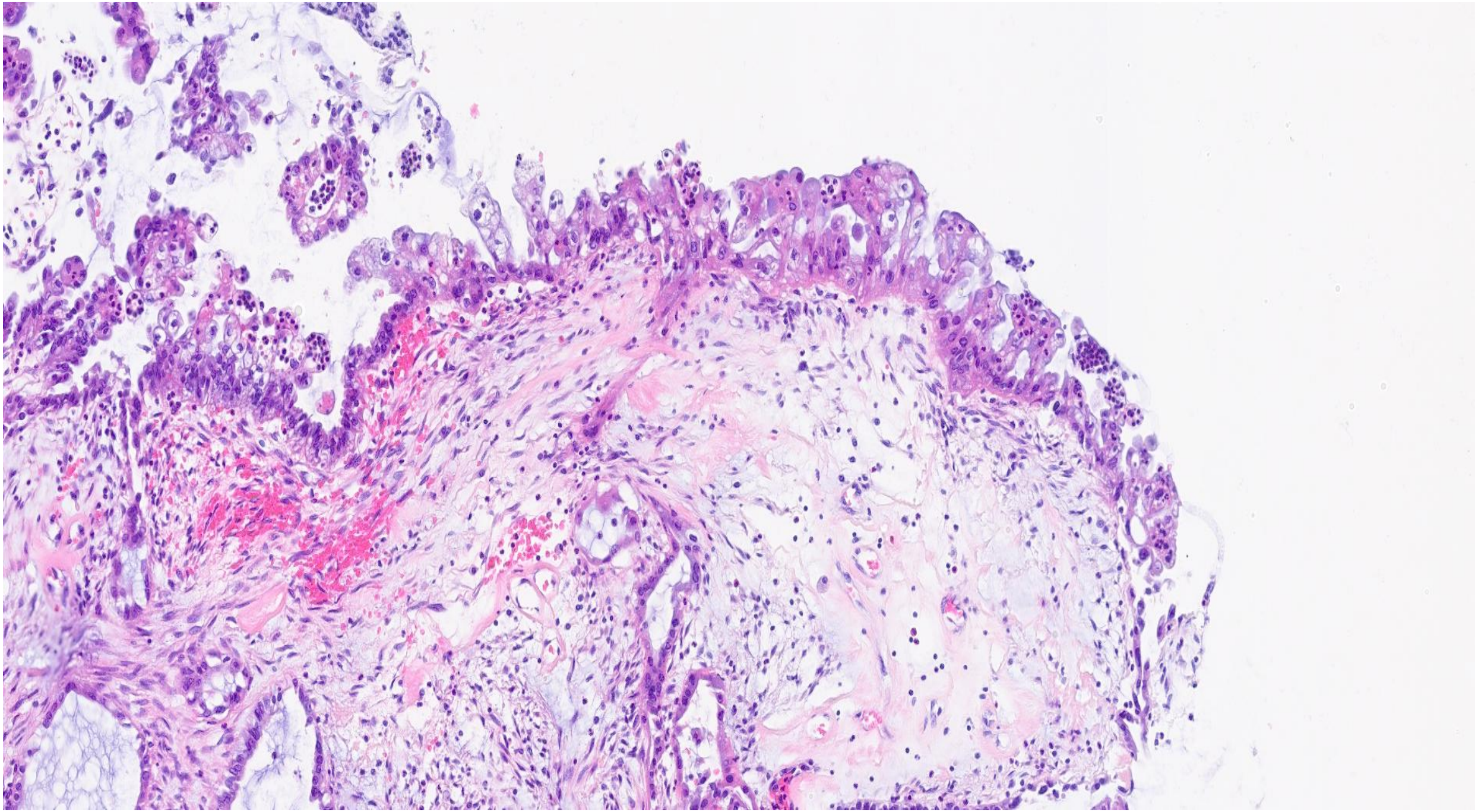

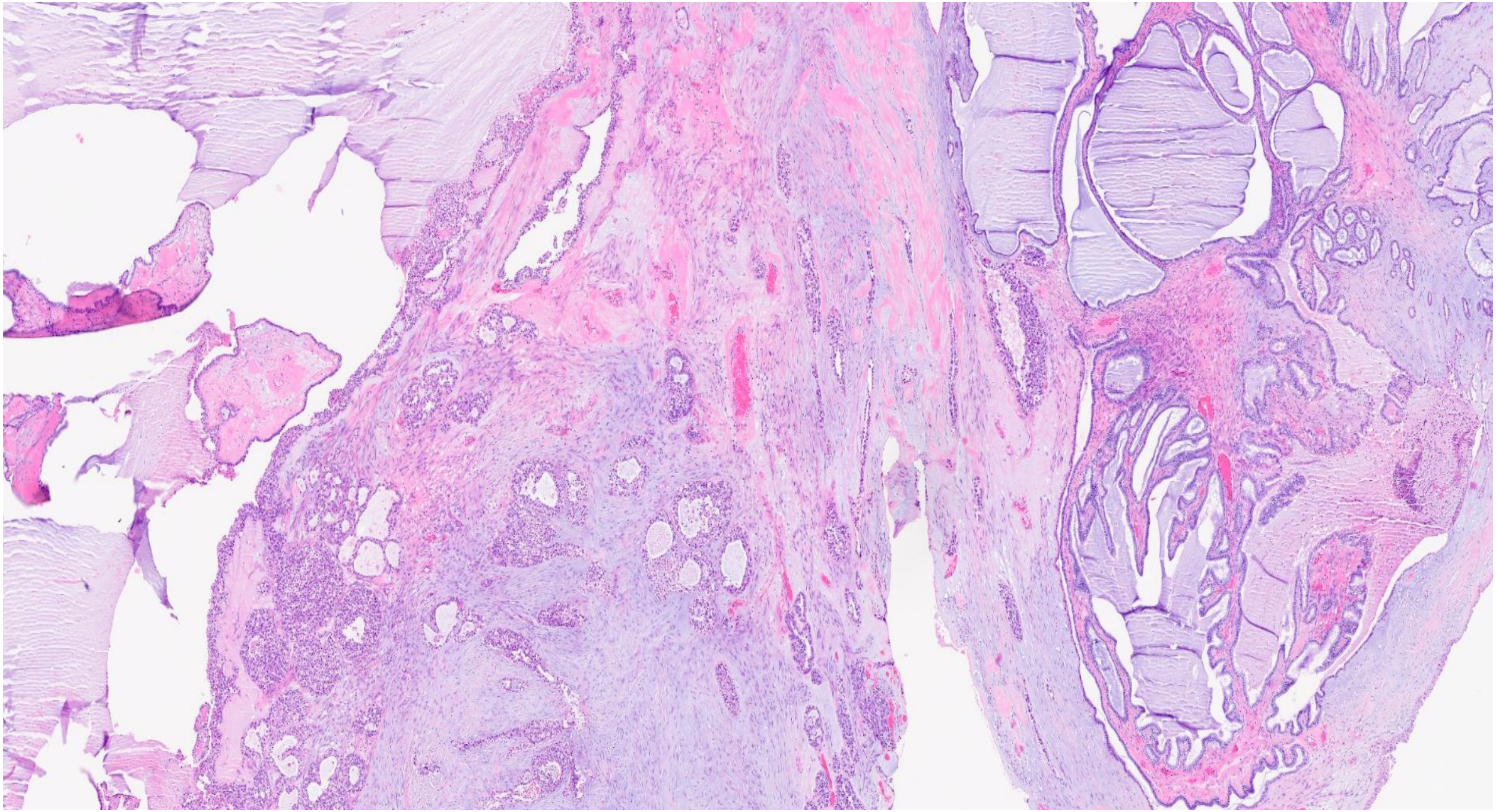

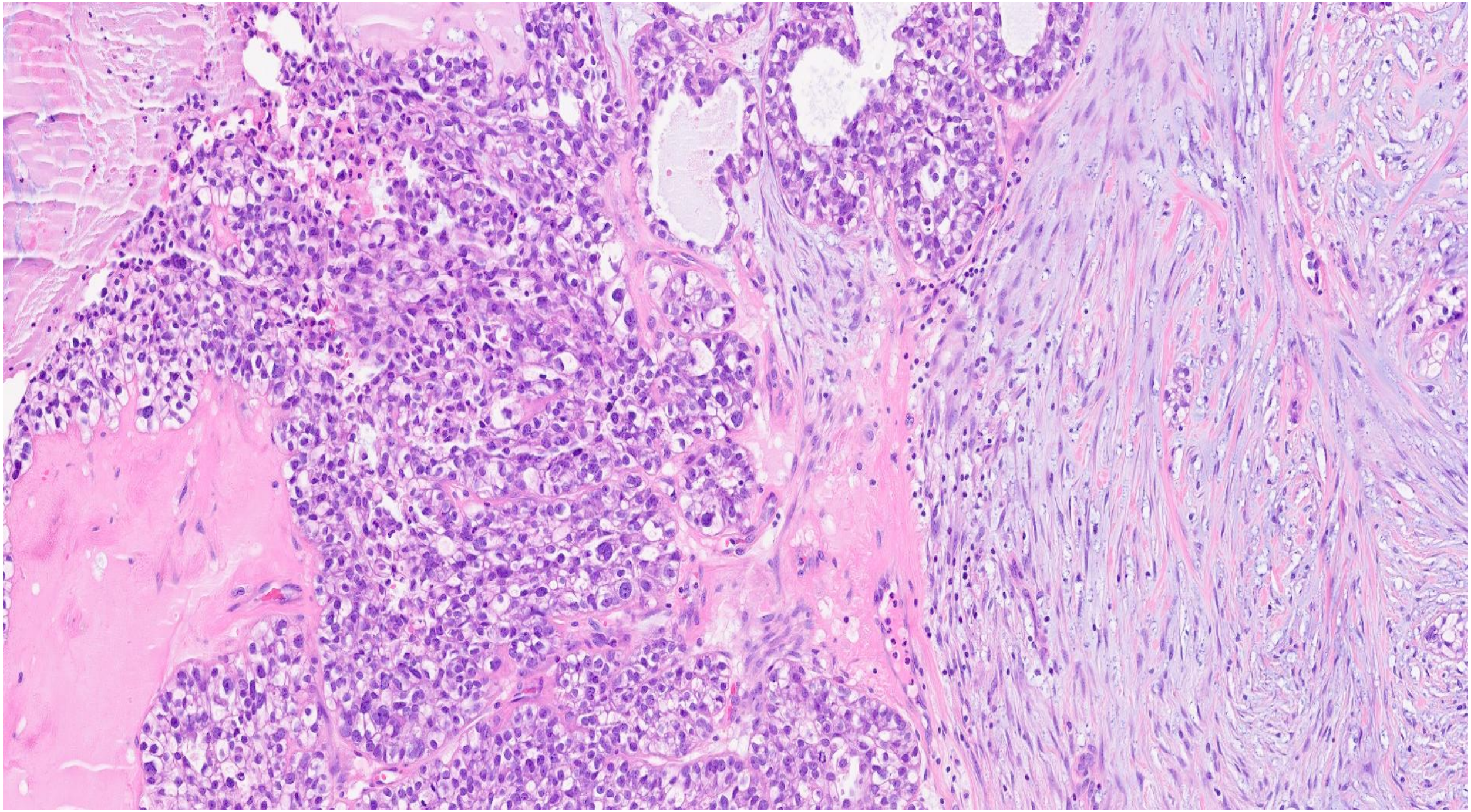

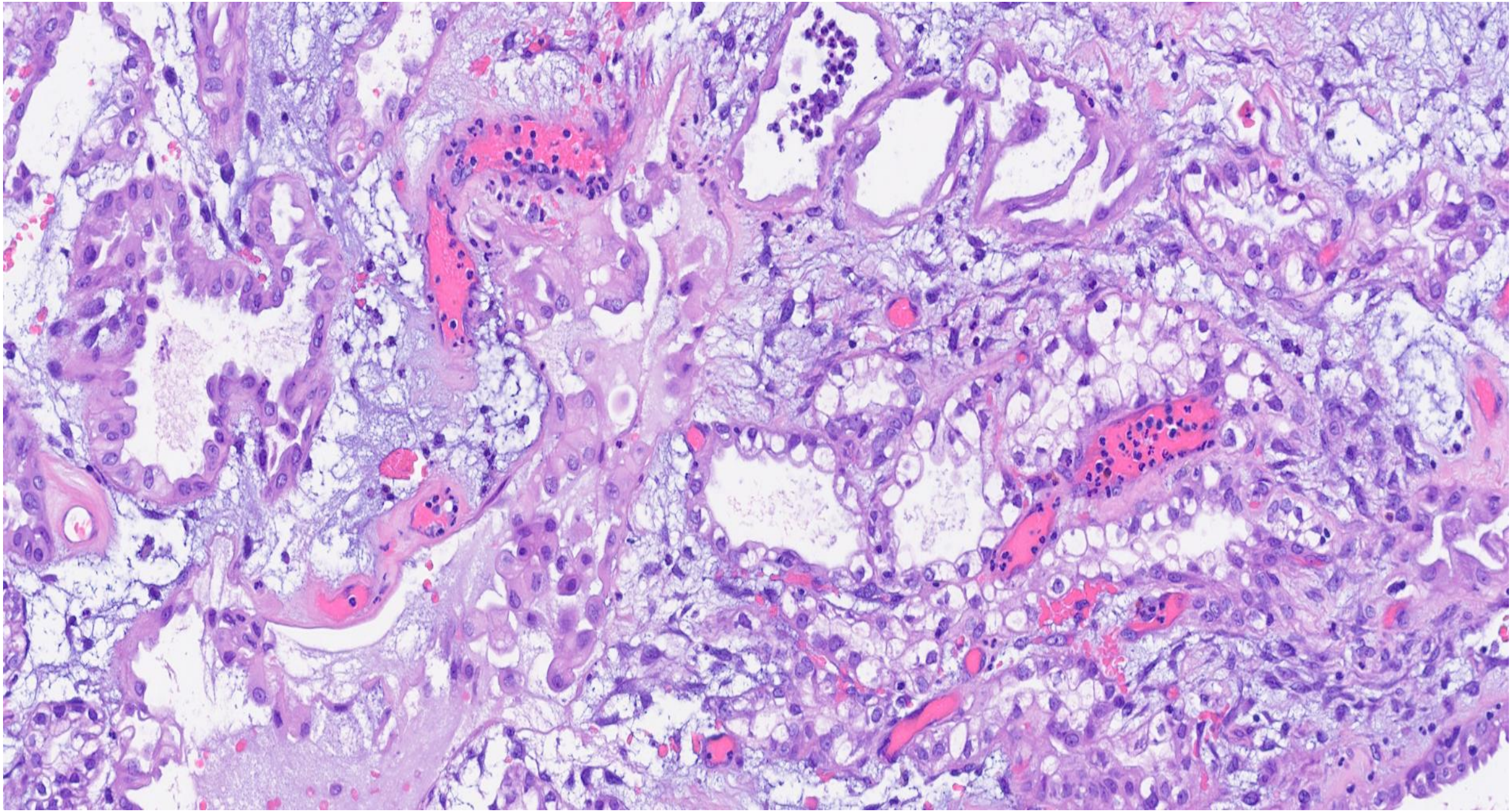

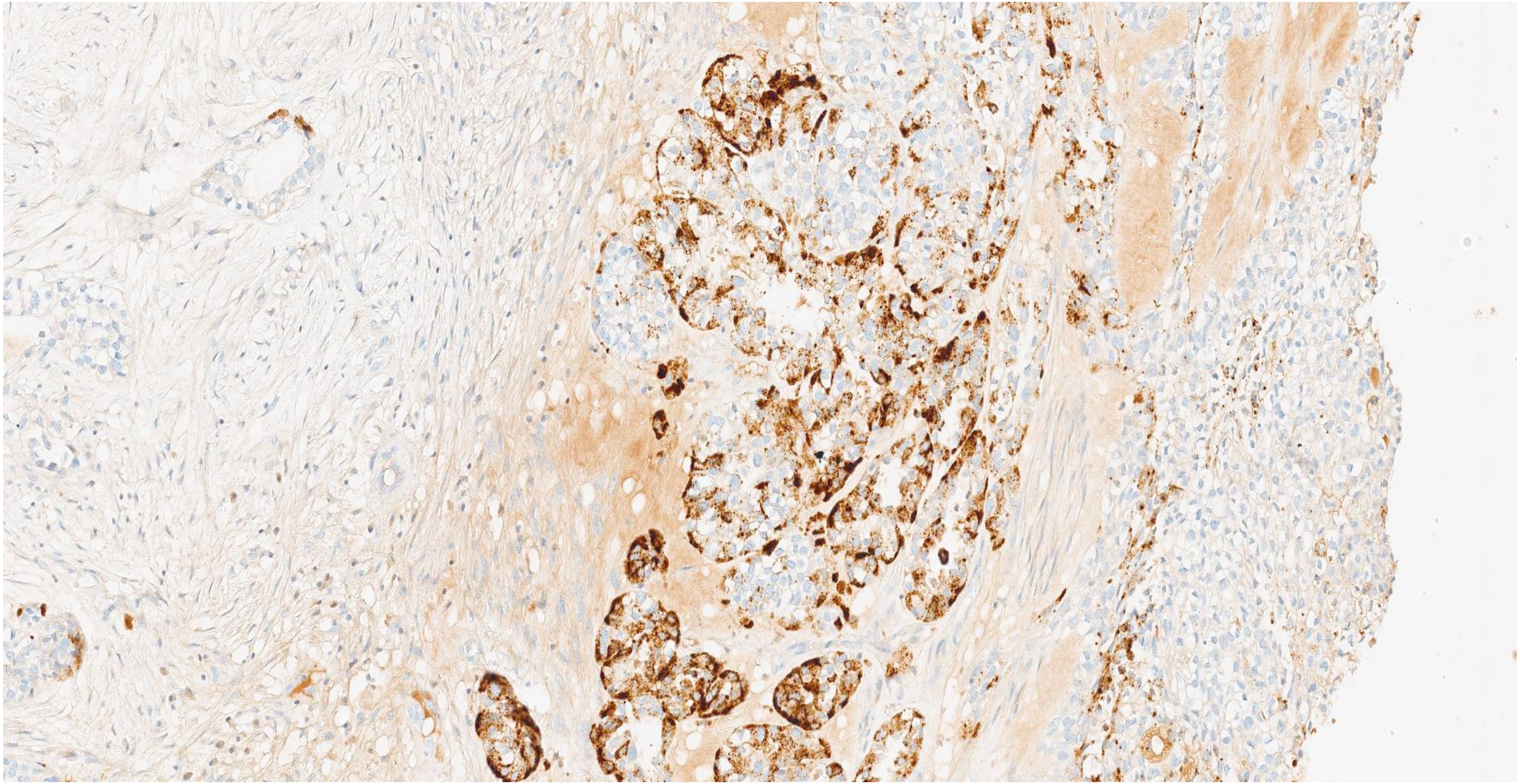

**NAPSIN A**

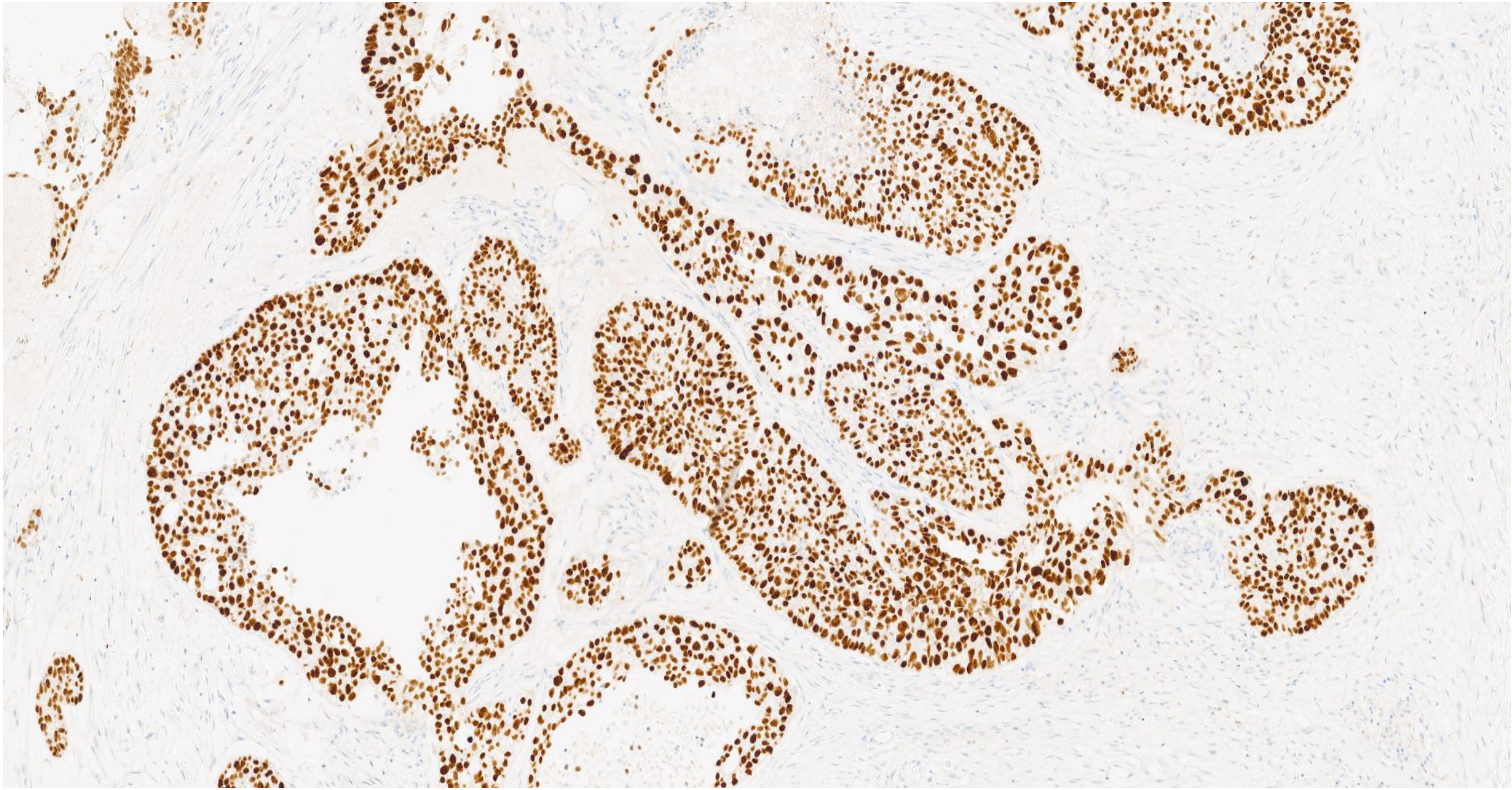

**HNF1 beta**

# IMMUNOHISTOCHEMISTRY

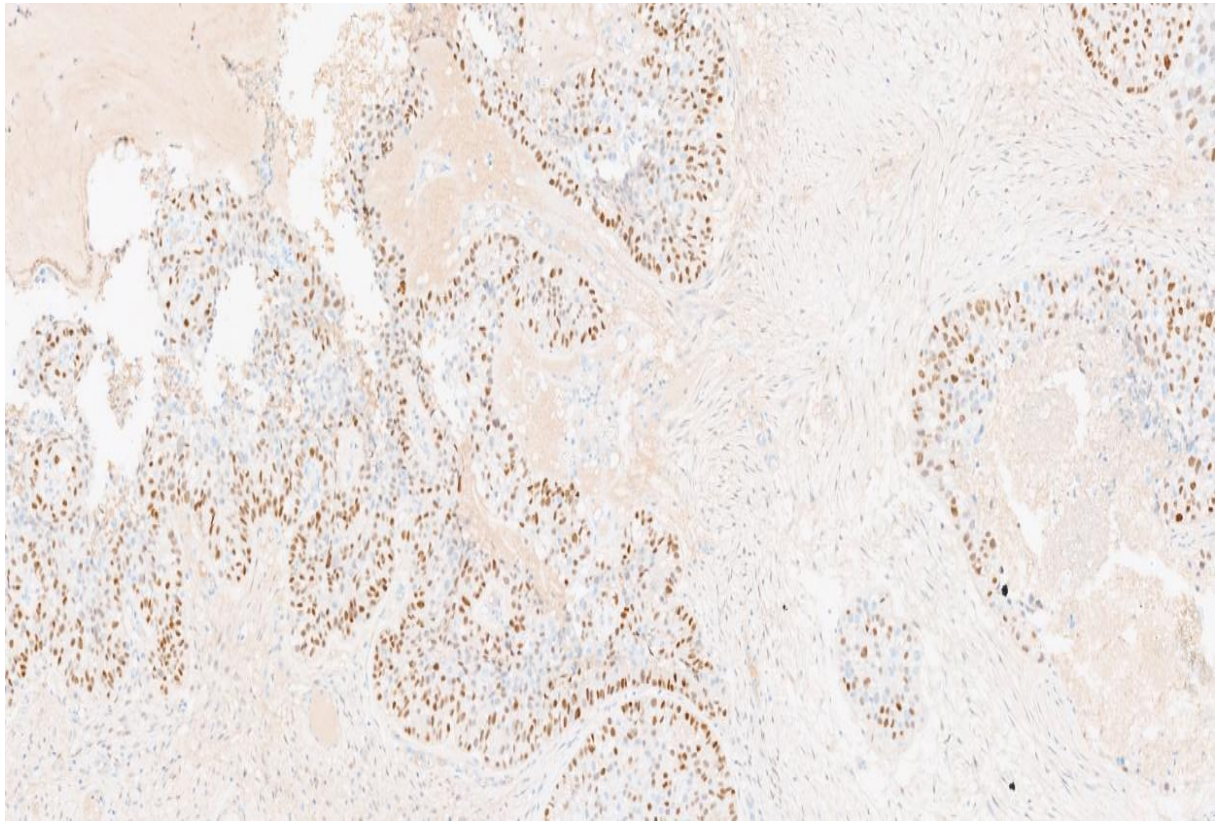

**ER**

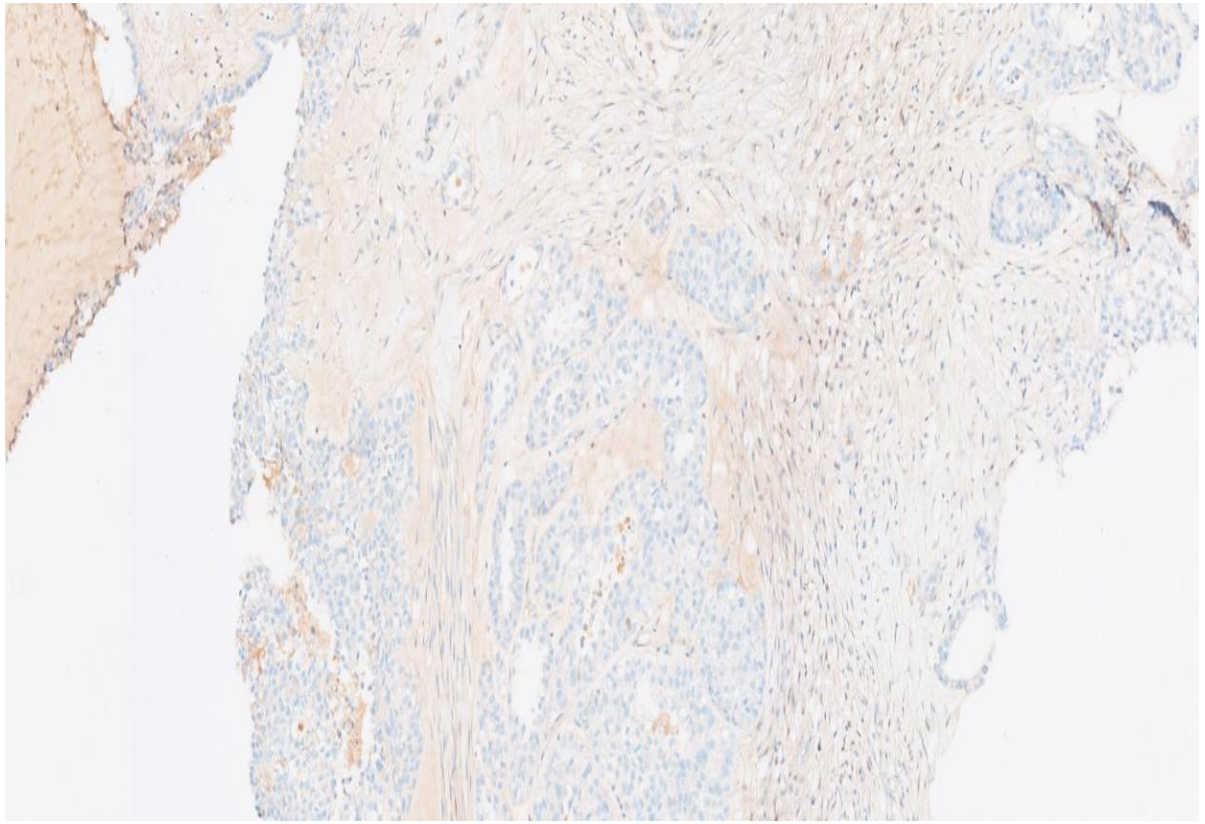

**PR**

# “TWIST IN TAIL”- PMID 33741765

*International Journal of Gynecological Pathology*
**41**:76–81, Lippincott Williams & Wilkins, Baltimore
Copyright © 2021 by the International Society of Gynecological Pathologists

Original Article

## Ovarian Clear Cell Tumors Associated With Seromucinous Borderline Tumor: A Case Series

Katherine M. Vroobel, F.R.C.Path. and W. Glenn McCluggage, F.R.C.Path.

# PMID 33741765

- clear cell tumours (borderline or clear cell carcinoma) arising in association with seromucinous borderline tumour (SMBT); often with associated endometriosis
- SMBT predominant component in all cases so need to sample well
- ? Clear cell neoplasm arises from clear cells which may be present in SMBT
- Clear cell neoplasm may merge with SMBT and have “subtle” tubulocystic features; may be difficult to diagnose and distinguish from clear cells in SMBT
- Clear cell neoplasms may be focally ER positive
- Have seen quite a few more cases since publication

# MESONEPHRIC-LIKE ADENOCARCINOMA: PMID 35384888 (2016)

Histopathology

*Histopathology* 2016, **68**, 1013–1020. DOI: 10.1111/his.12895

## Hormone receptor-negative, thyroid transcription factor 1-positive uterine and ovarian adenocarcinomas: report of a series of mesonephric-like adenocarcinomas

Marie McFarland, Charles M Quick[1] & W Glenn McCluggage

*Department of Pathology, Belfast Health and Social Care Trust, Belfast, UK, and* [1]*Department of Pathology, University of Arkansas for Medical Sciences, Little Rock, AR, USA*

Date of submission 25 July 2015
Accepted for publication 16 October 2015
Published online *Article Accepted* 20 October 2015

# HOW TO DIAGNOSE MLA?

- “New” entity so everyone wants to diagnose
- Always exceptions but in general should not diagnose if squamous elements present (unless mixed tumour)
- Should doubt diagnosis if MMR deficient/ MSI-H or p53 mutation-type staining/ *TP53* mutation
- Need to see a compatible morphology
- If characteristic MLA morphology is present, a front-line panel of TTF1, GATA3, ER, and PR should be done to help support the diagnosis
- TTF1 and/or GATA3 should be positive
- ER expression should be “limited” (most cases)
- Doubt diagnosis if PAX8 not diffuse and strong
- In non-classical cases, molecular testing (*KRAS/ NRAS*) and/ or specialist review may be valuable

# PAPILLARY THYROID CARCINOMA-LIKE NUCLEI

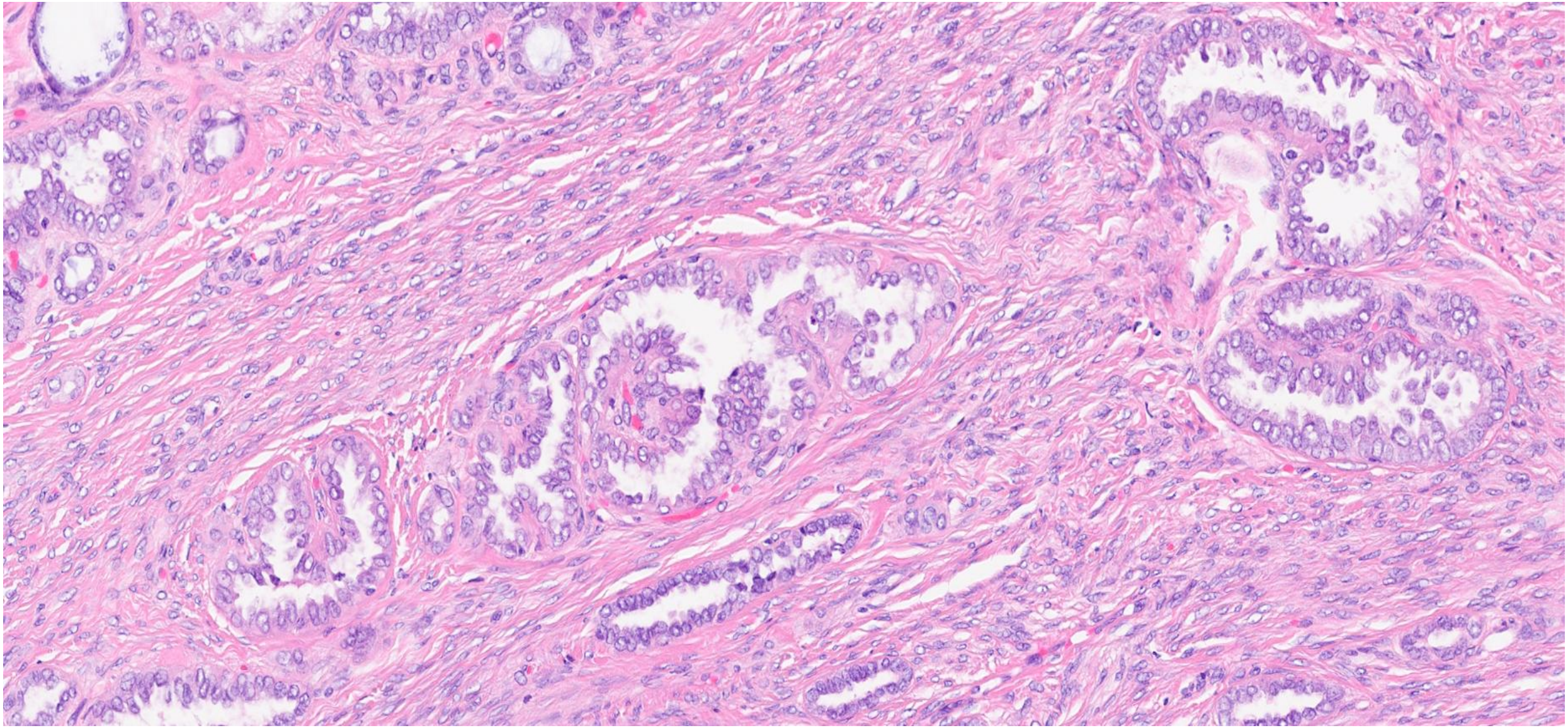

# IMMUNOHISTOCHEMISTRY MLA- CD10

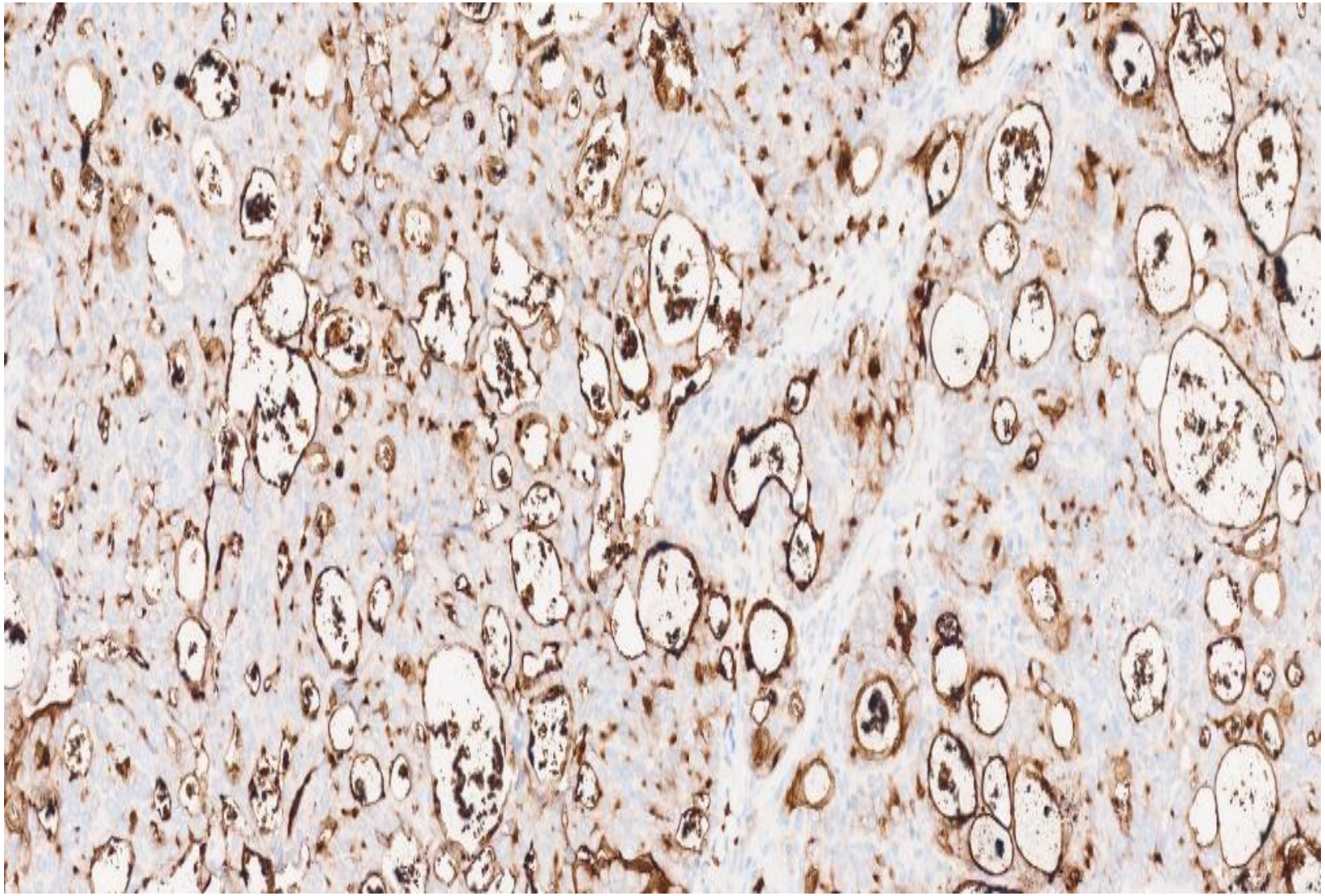

# IMMUNOHISTOCHEMISTRY MLA

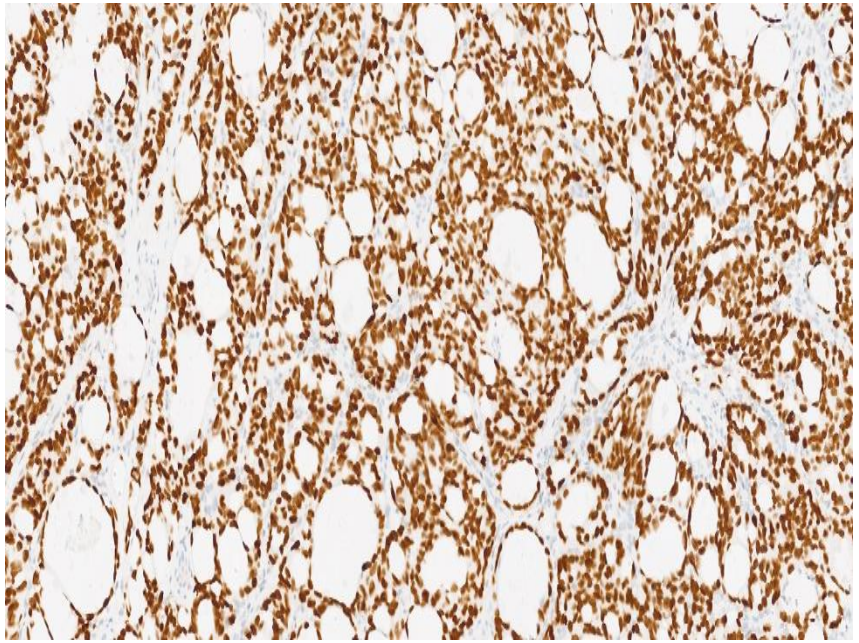

**TTF1**

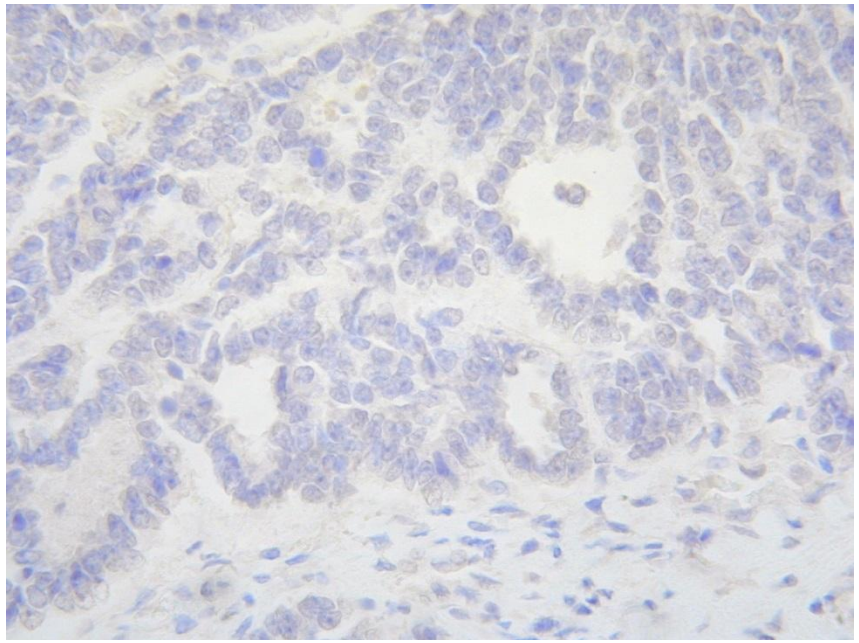

**ER**

# IMMUNOHISTOCHEMISTRY
# MLA- GATA3

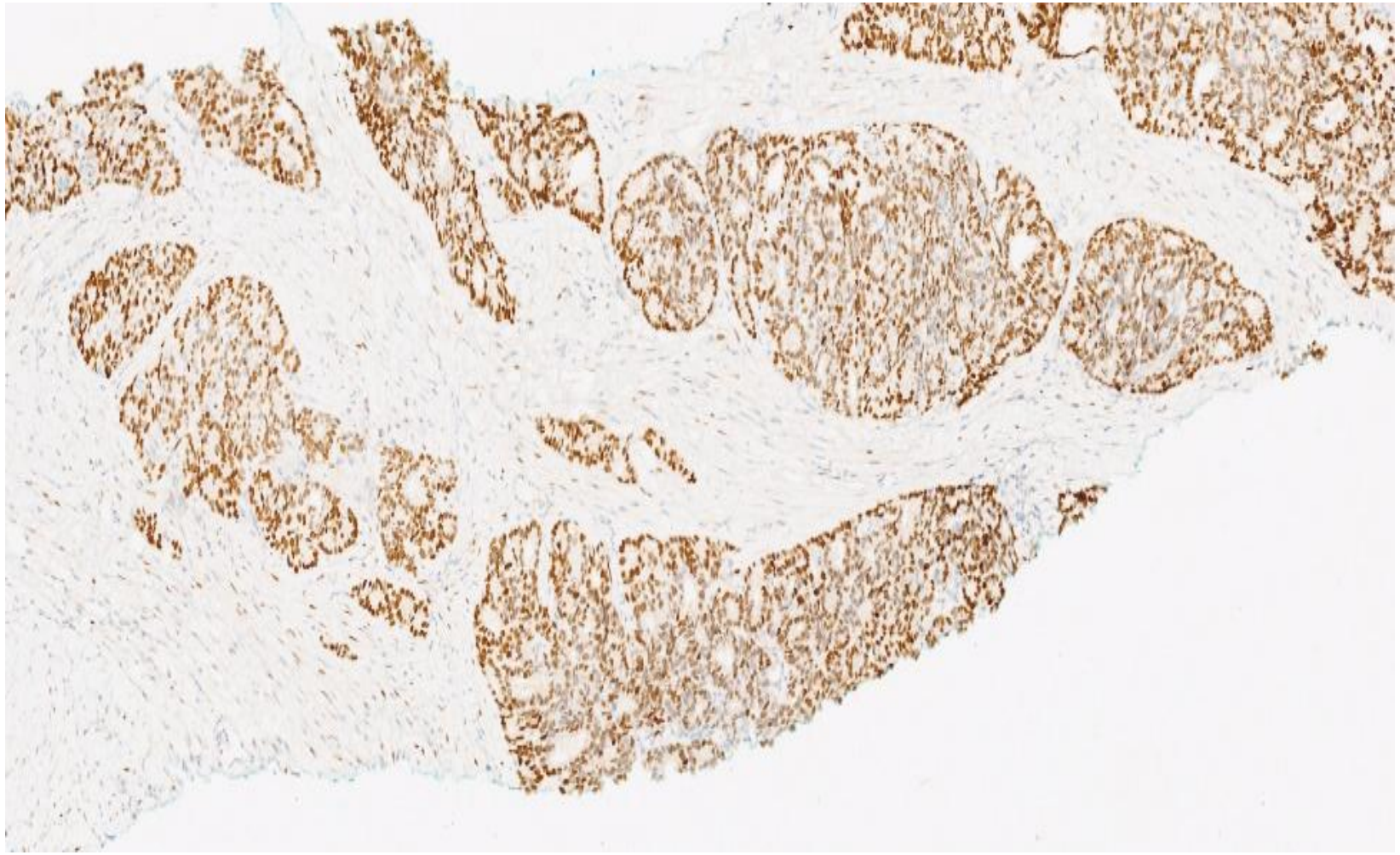

# COMMENTS REGARDING IMMUNOPHENOTYPE OF MLA

- Not all totally negative with ER/ PR; focal positivity allowable (difference from true mesonephric adenocarcinoma)
- More likely to be TTF1 positive than true mesonephric adenocarcinomas
- GATA3, TTF1, ER, PR is best combination to do
- CD10 less useful than GATA3 and TTF1
- Sometimes inverse relationship between GATA3 and TTF1 staining
- Beware non-specific thyroglobulin “positivity” of colloid-like material (along with TTF1 positivity may result in misdiagnosis of thyroid-type neoplasm)

# CASE 7

- F 45
- Prior hysterectomy and BSO for endometriosis
- Nodule on anterior abdominal wall

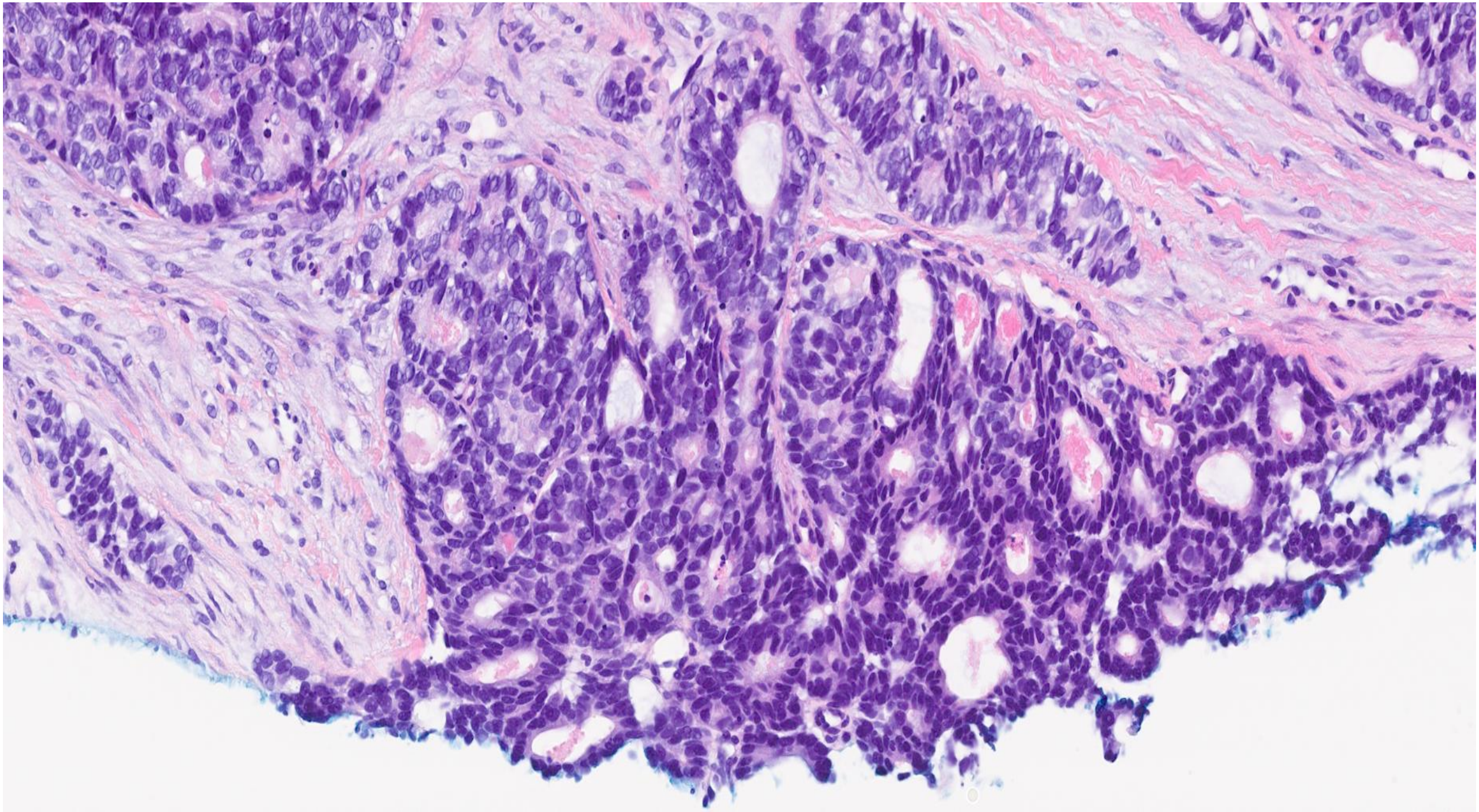

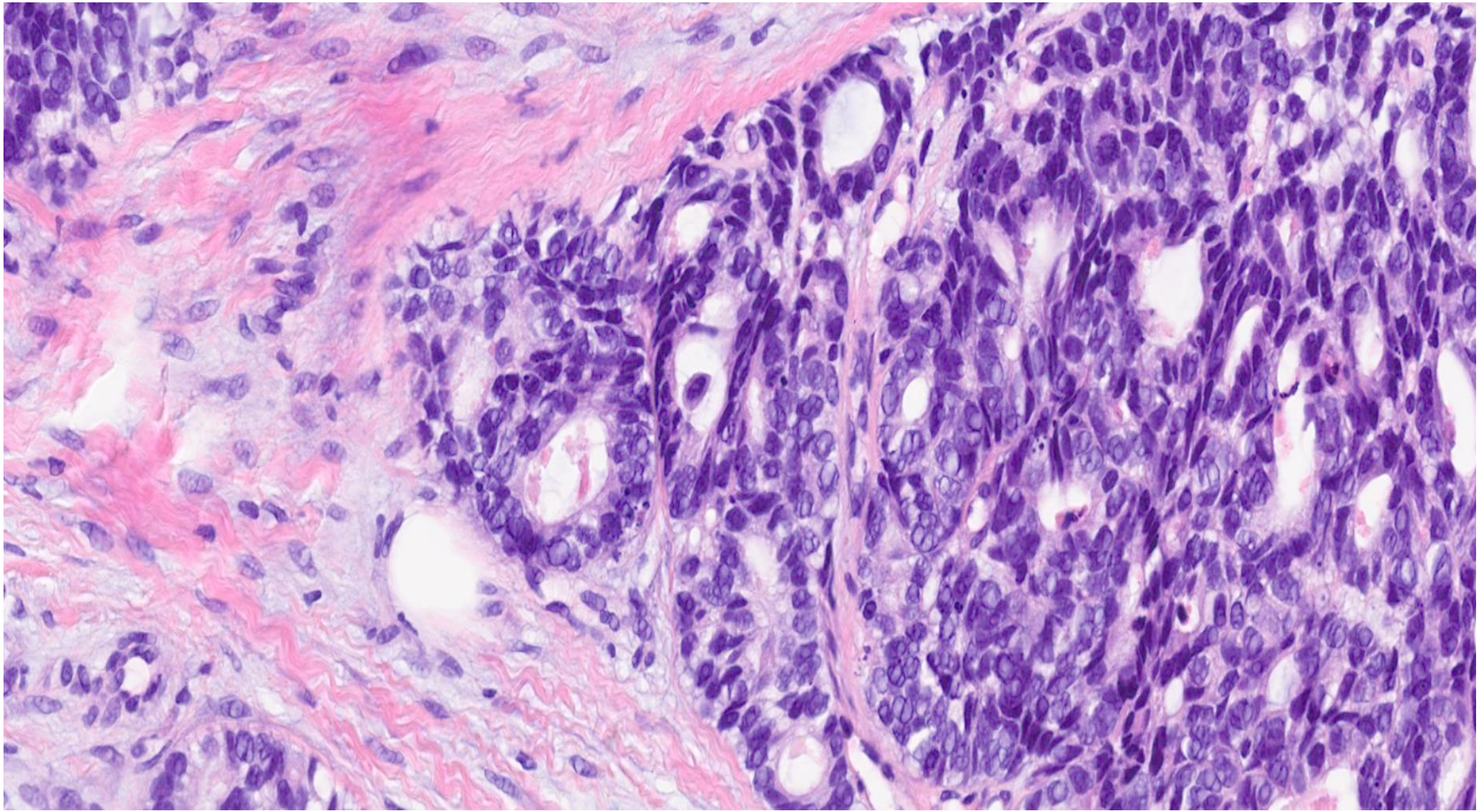

# TTF1

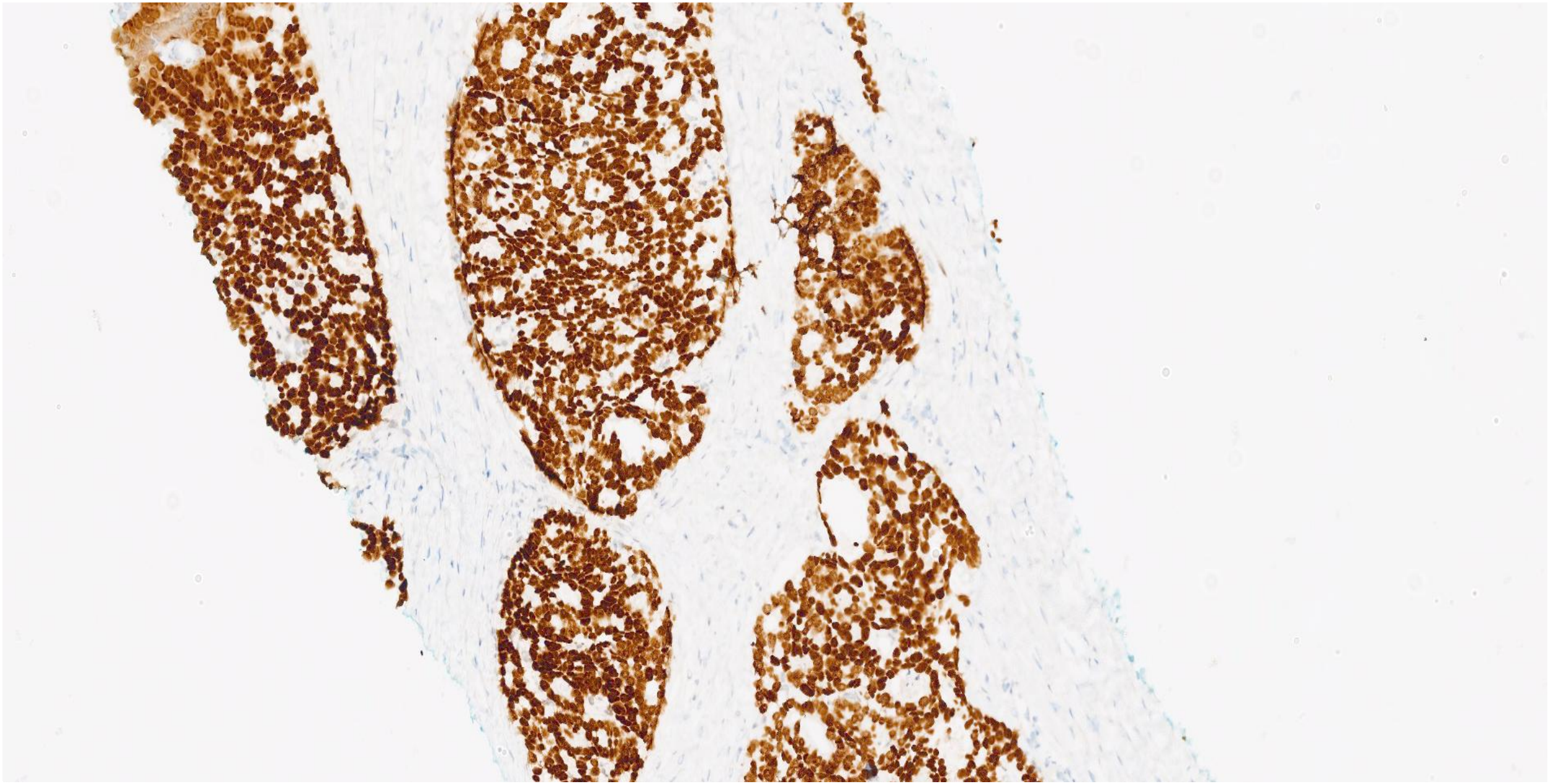

# GATA3

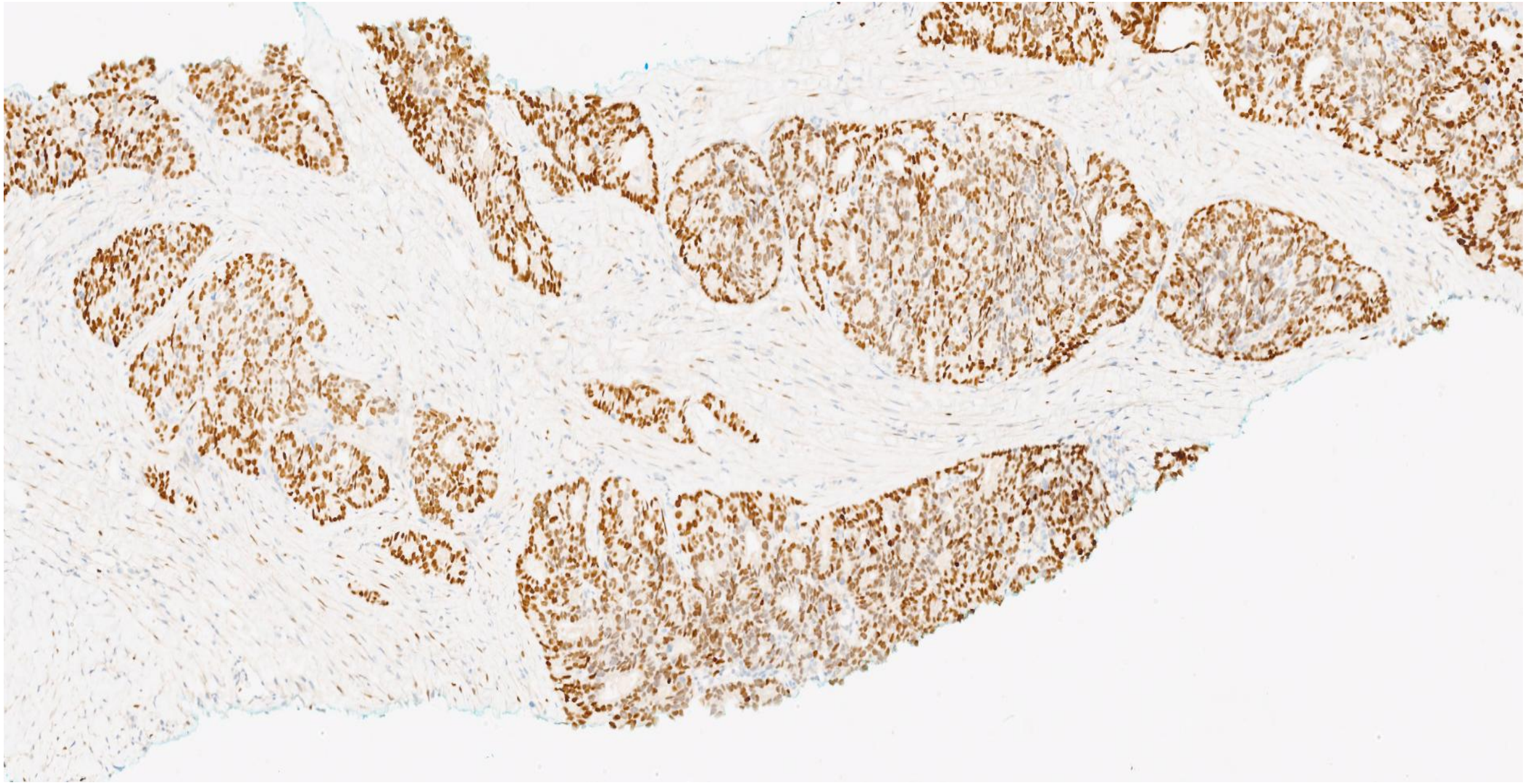

# CD10

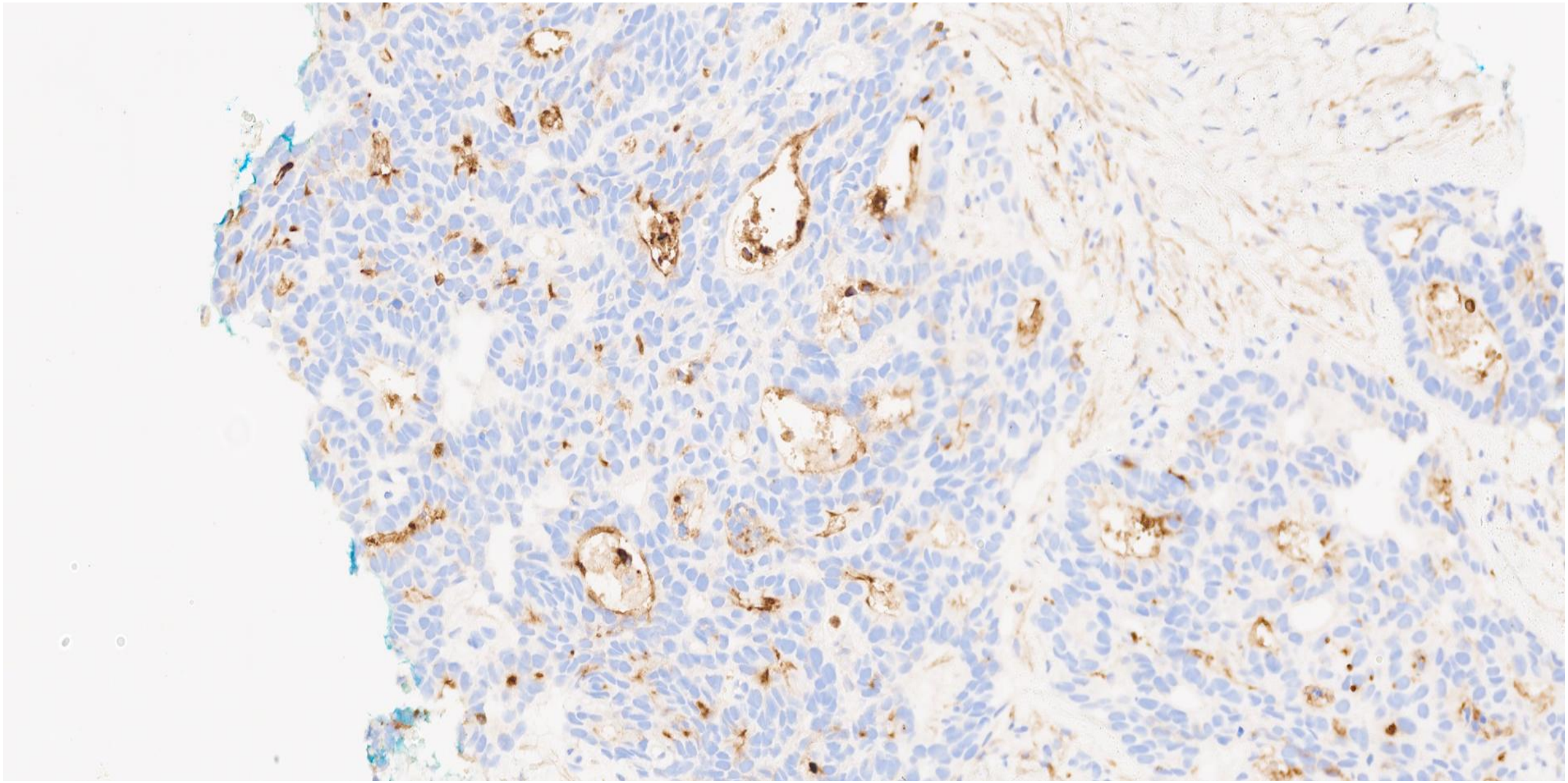

# ER

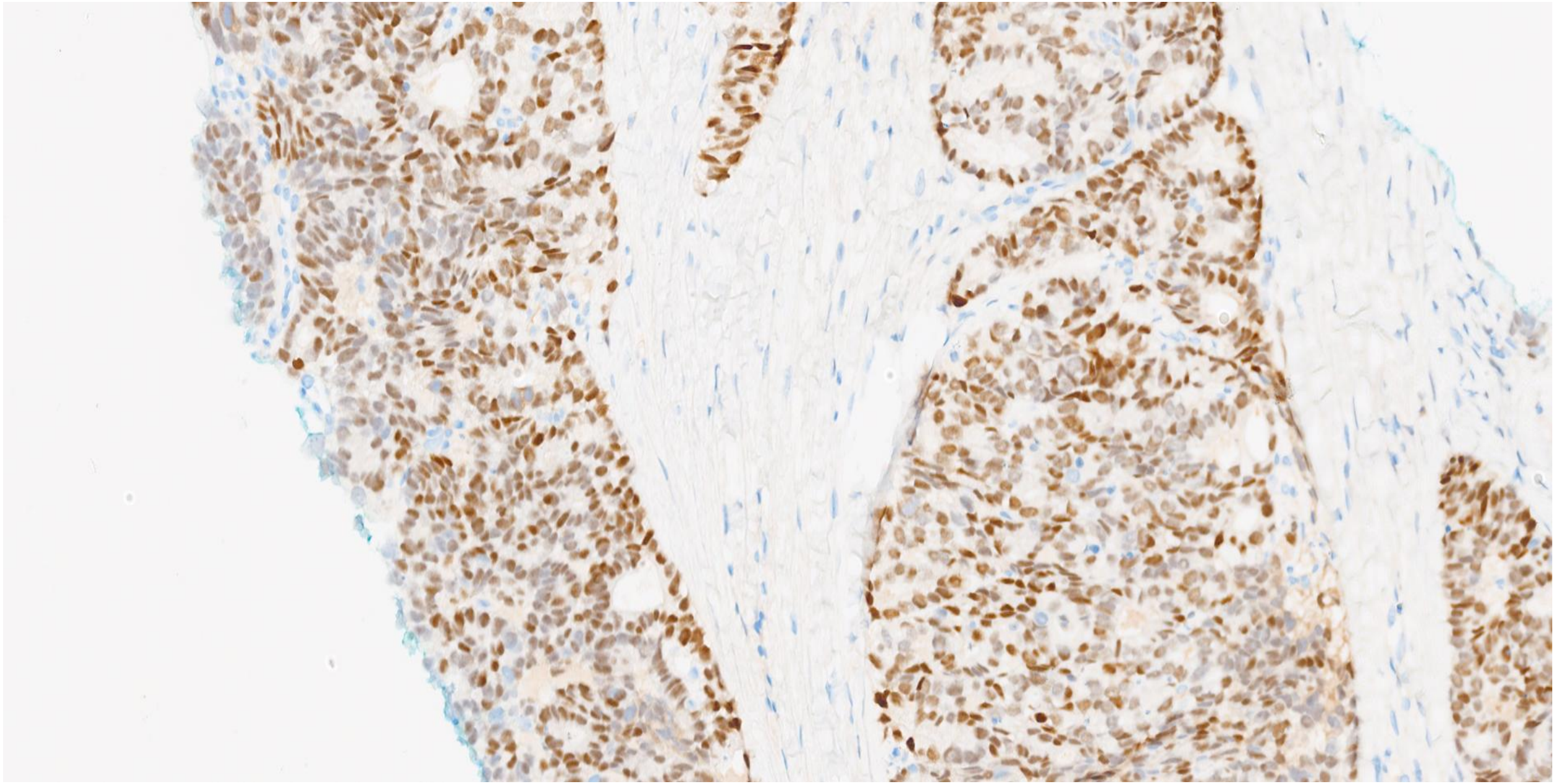

# FURTHER IMMUNOHISTOCHEMISTRY AND MOLECULAR

- MMR immunohistochemistry retained
- PAX8 diffuse
- p53 wild-type
- NGS- *KRAS* and *PIK3CA* mutations
- Diagnosis- MLA – probably arising in endometriosis

# RISK OF “OVERDIAGNOSIS” OF MLA

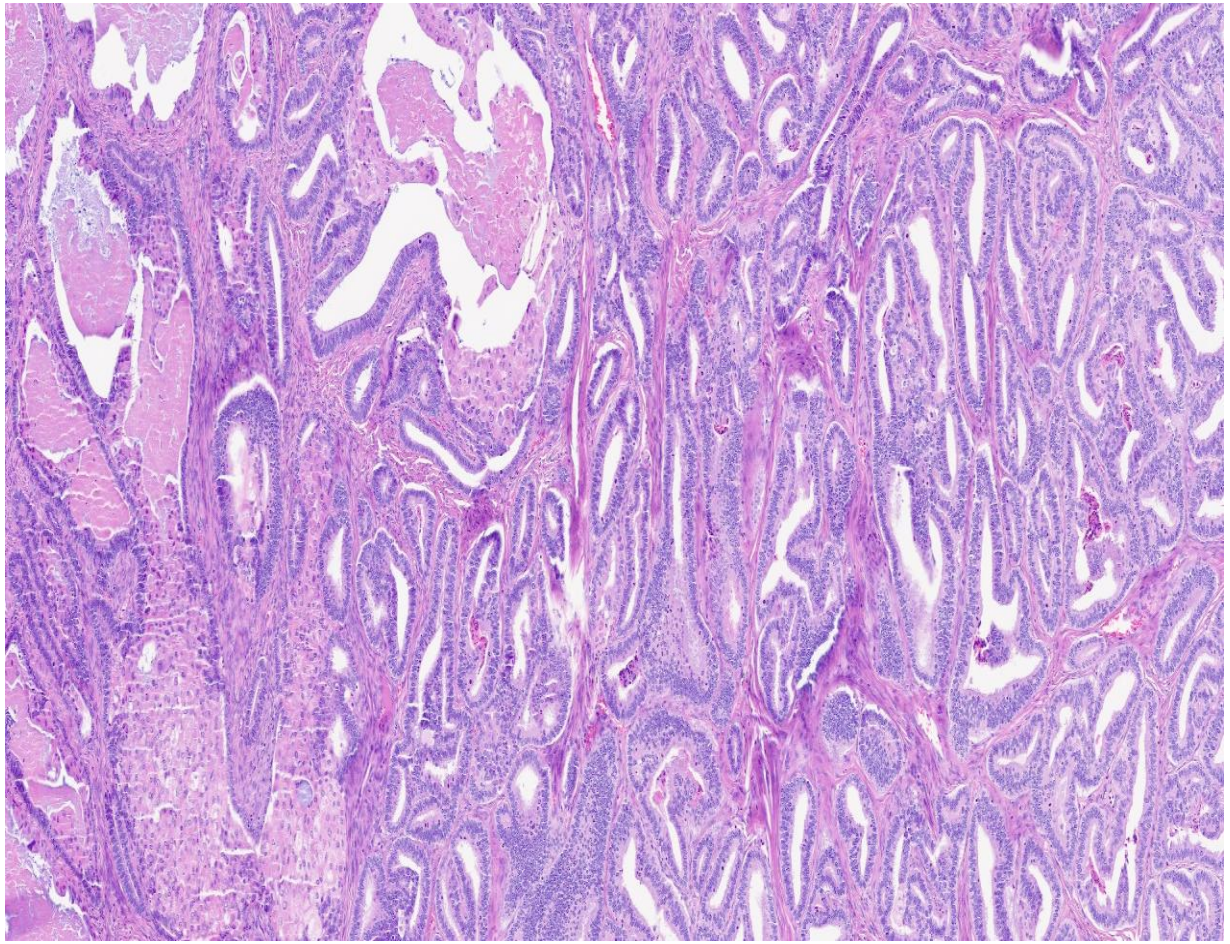

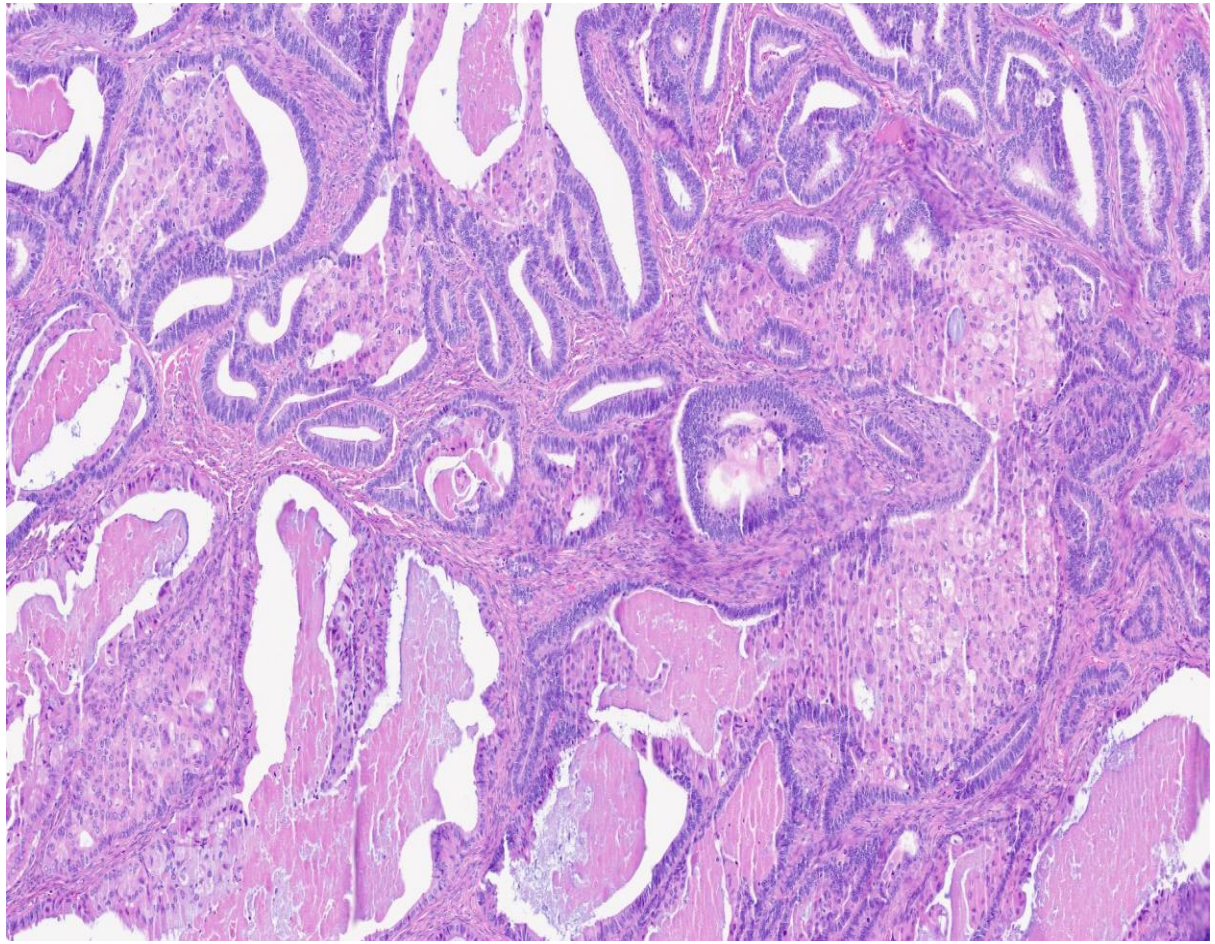

# RISK OF “OVERDIAGNOSIS” OF MLA

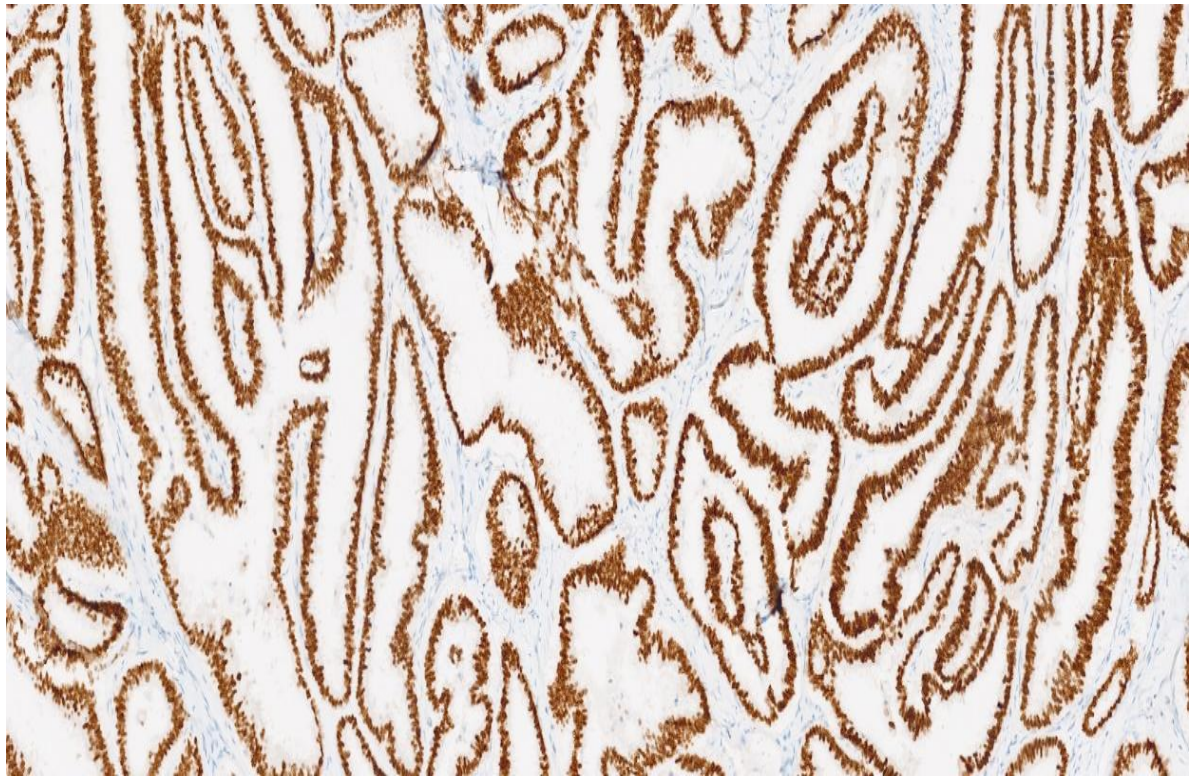

**TTF1**

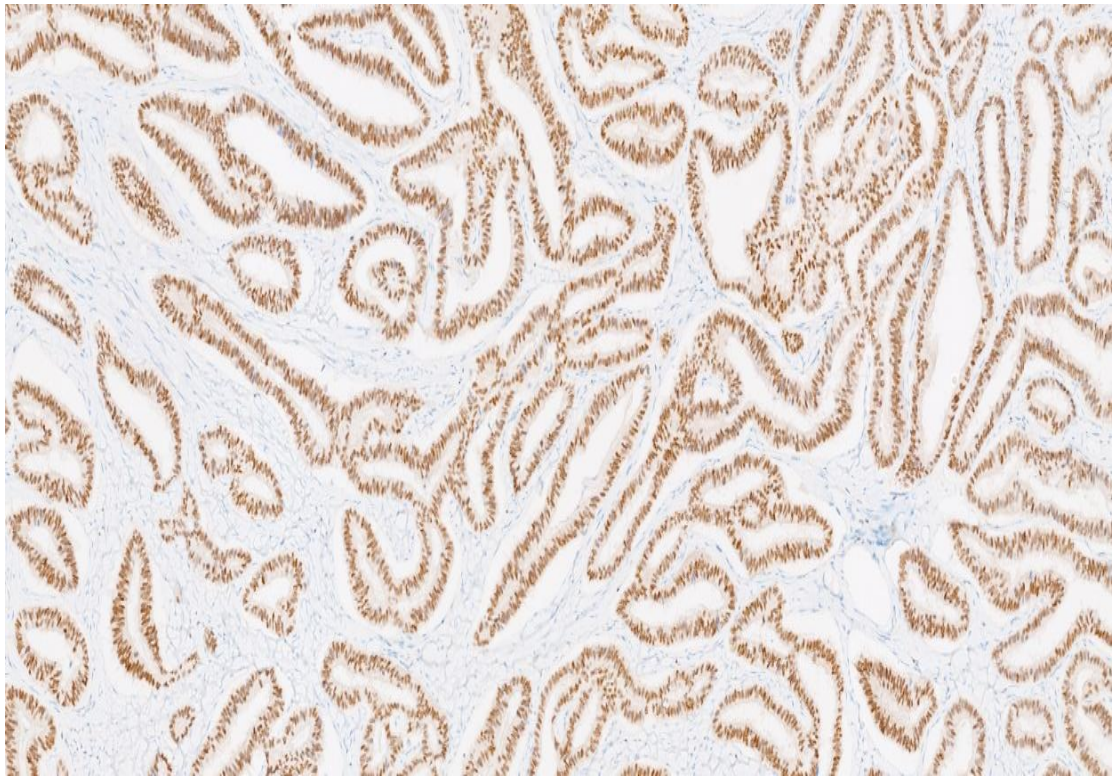

**GATA3**