CERVICAL EPITHELIAL LESIONS NOT TO BE MISSED

W Glenn McCluggage
Department of Pathology
Belfast Health and Social Care Trust
Belfast
United Kingdom

BENIGN CERVICAL EPITHELIAL LESIONS NOT TO BE OVERDIAGNOSED AS MALIGNANT

W Glenn McCluggage
Department of Pathology
Belfast Health and Social Care Trust
Belfast
United Kingdom

CASE 1

- F 40
- Presented with mucoid vaginal discharge; smear normal; bulky cervix
- Large polypoid lesion removed from cervix

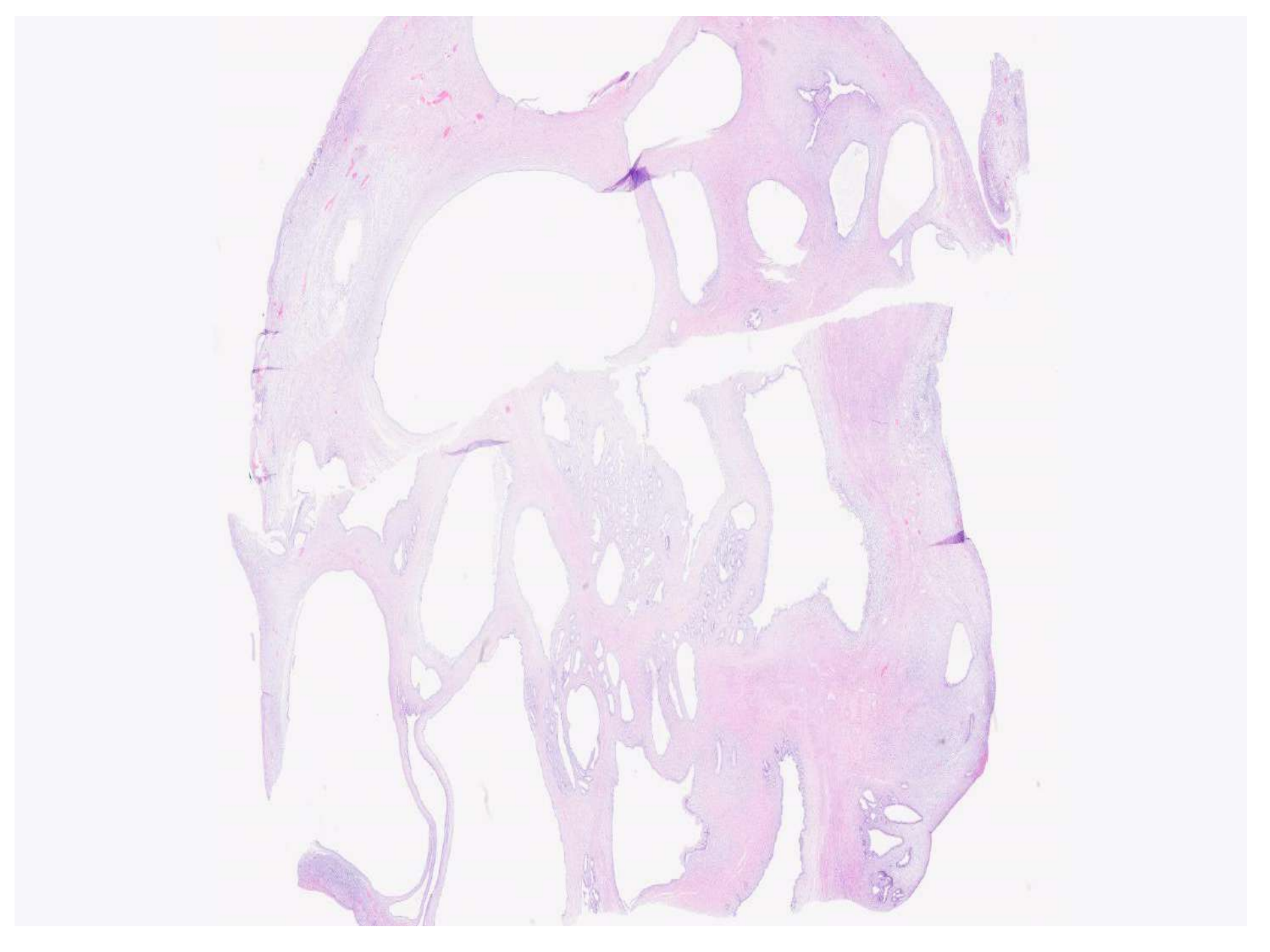

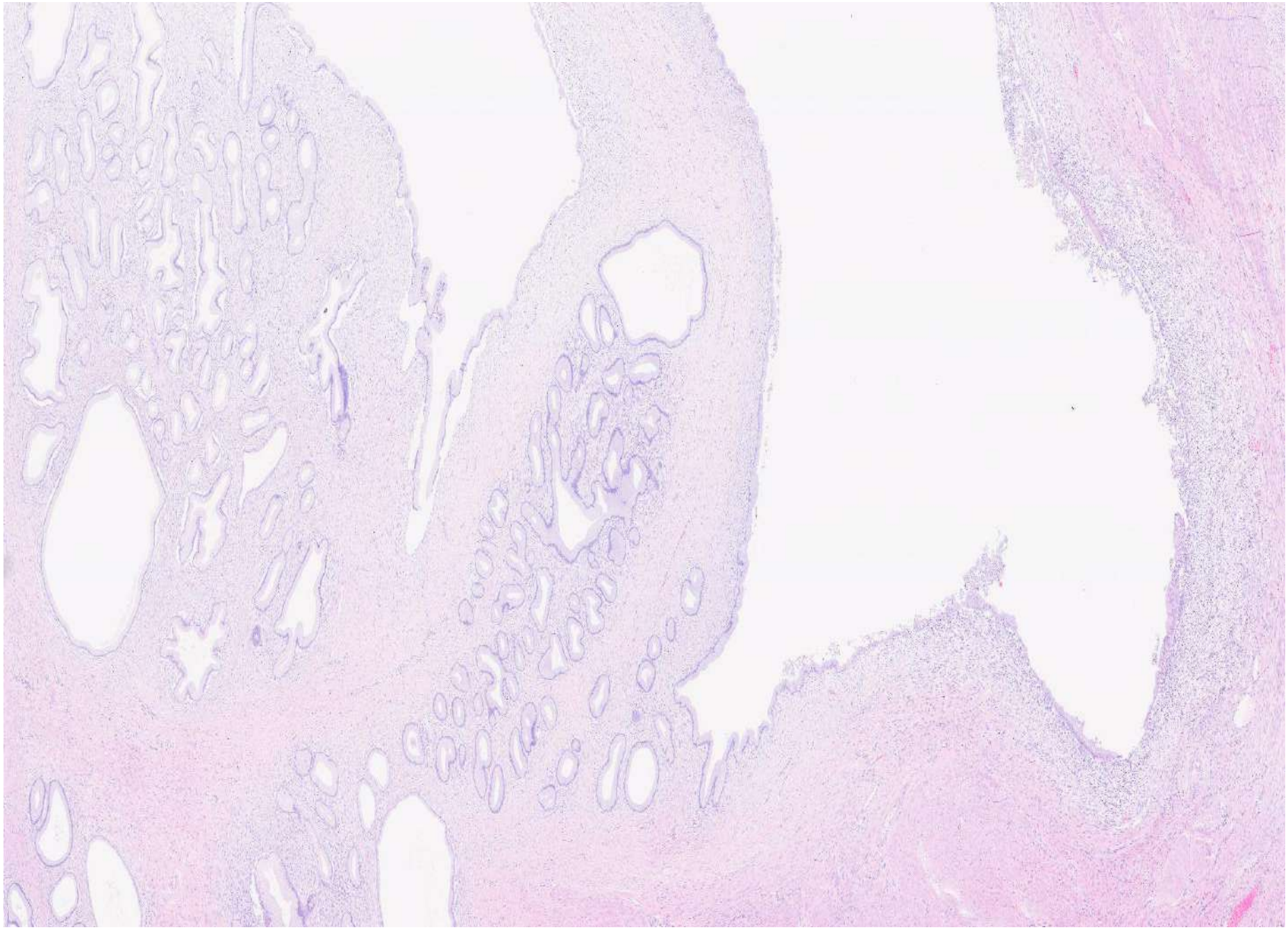

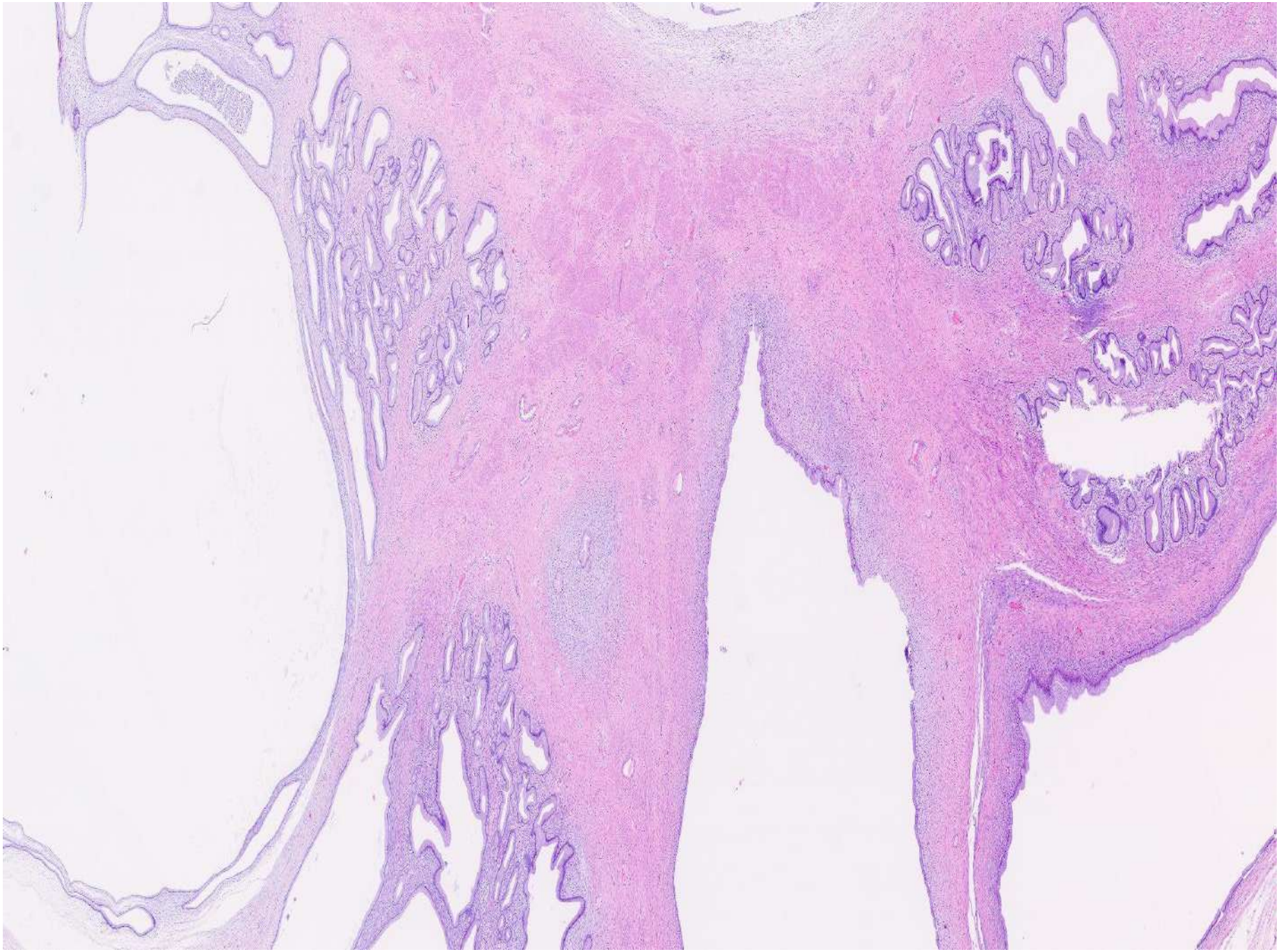

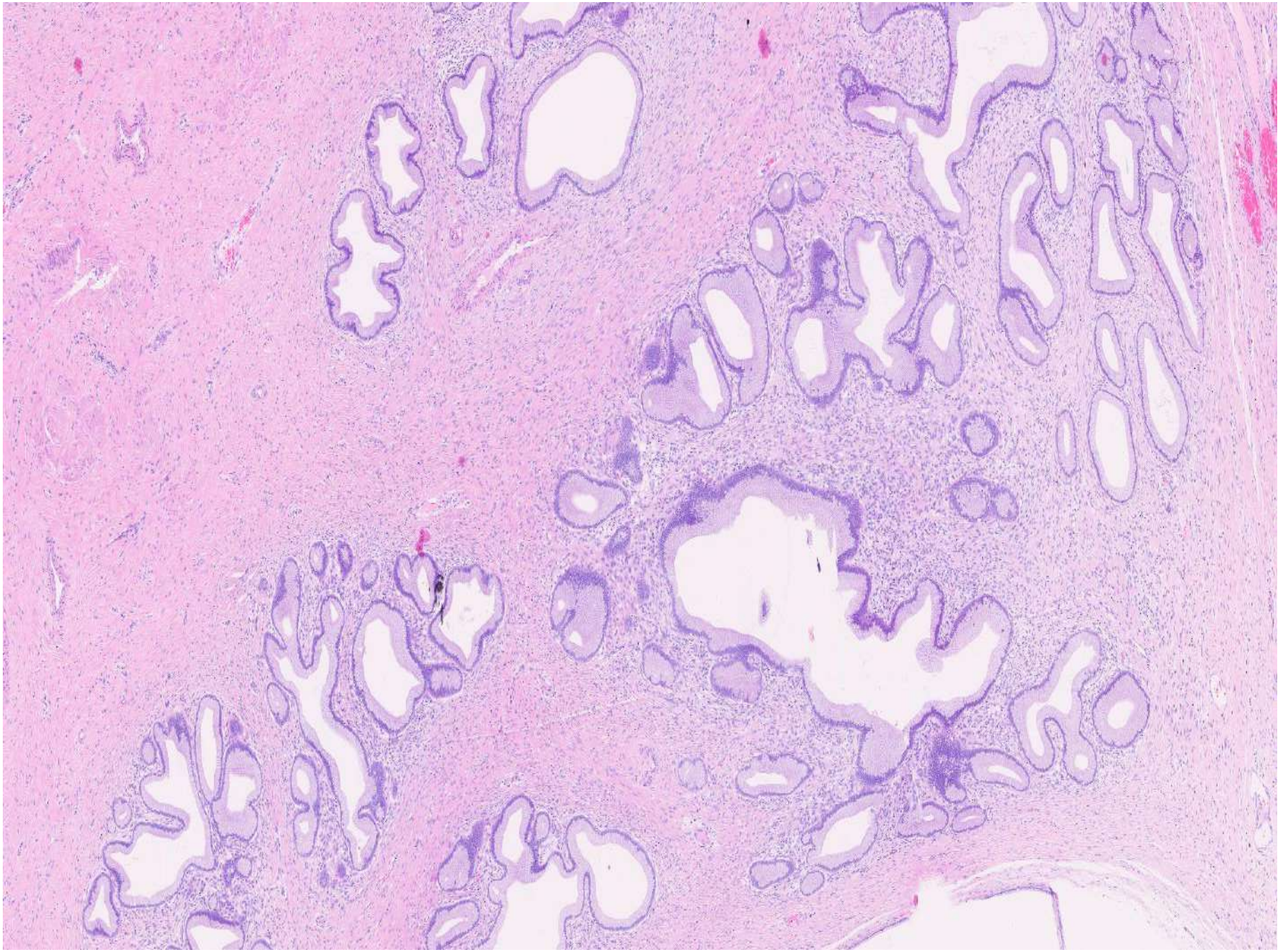

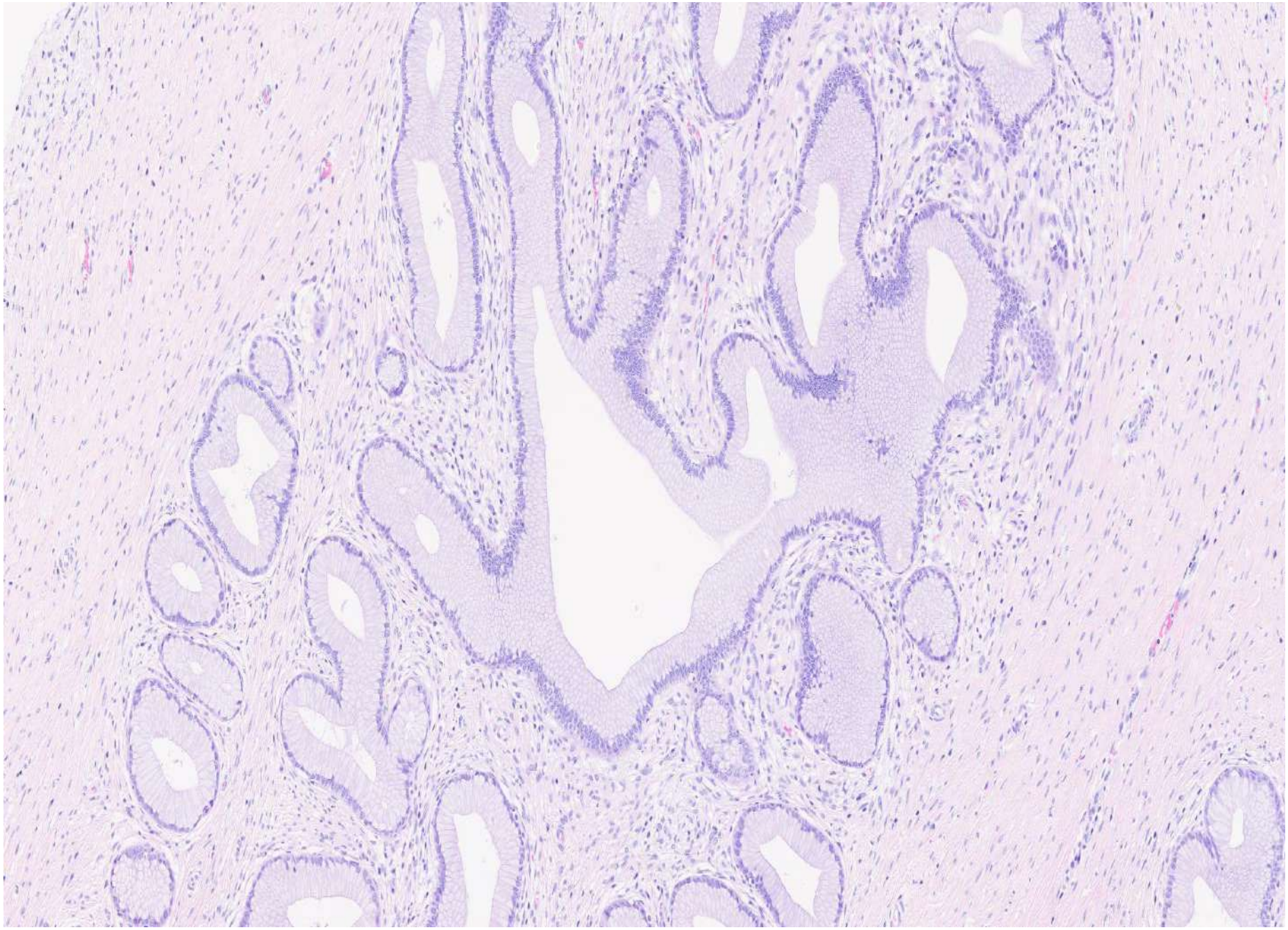

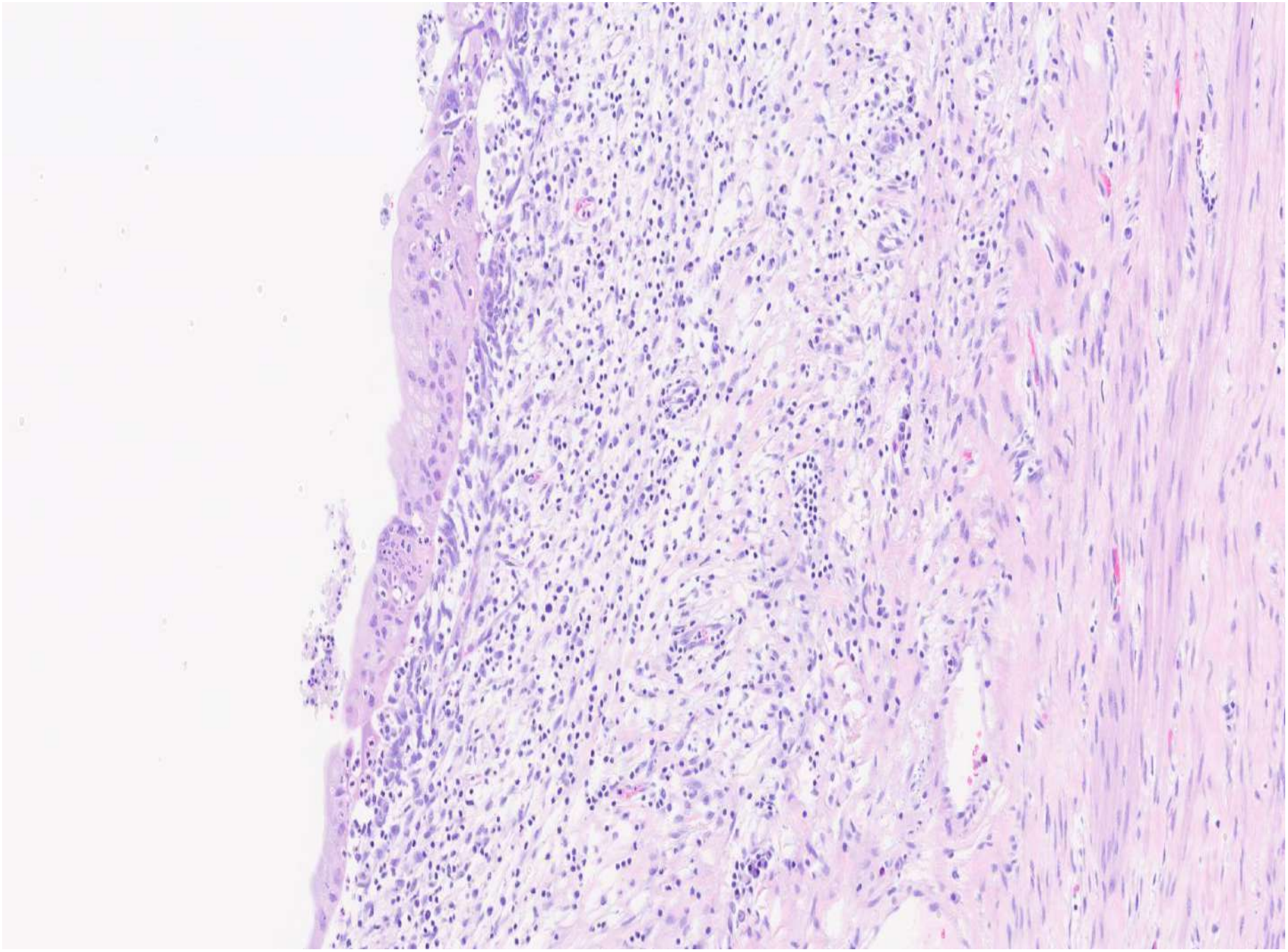

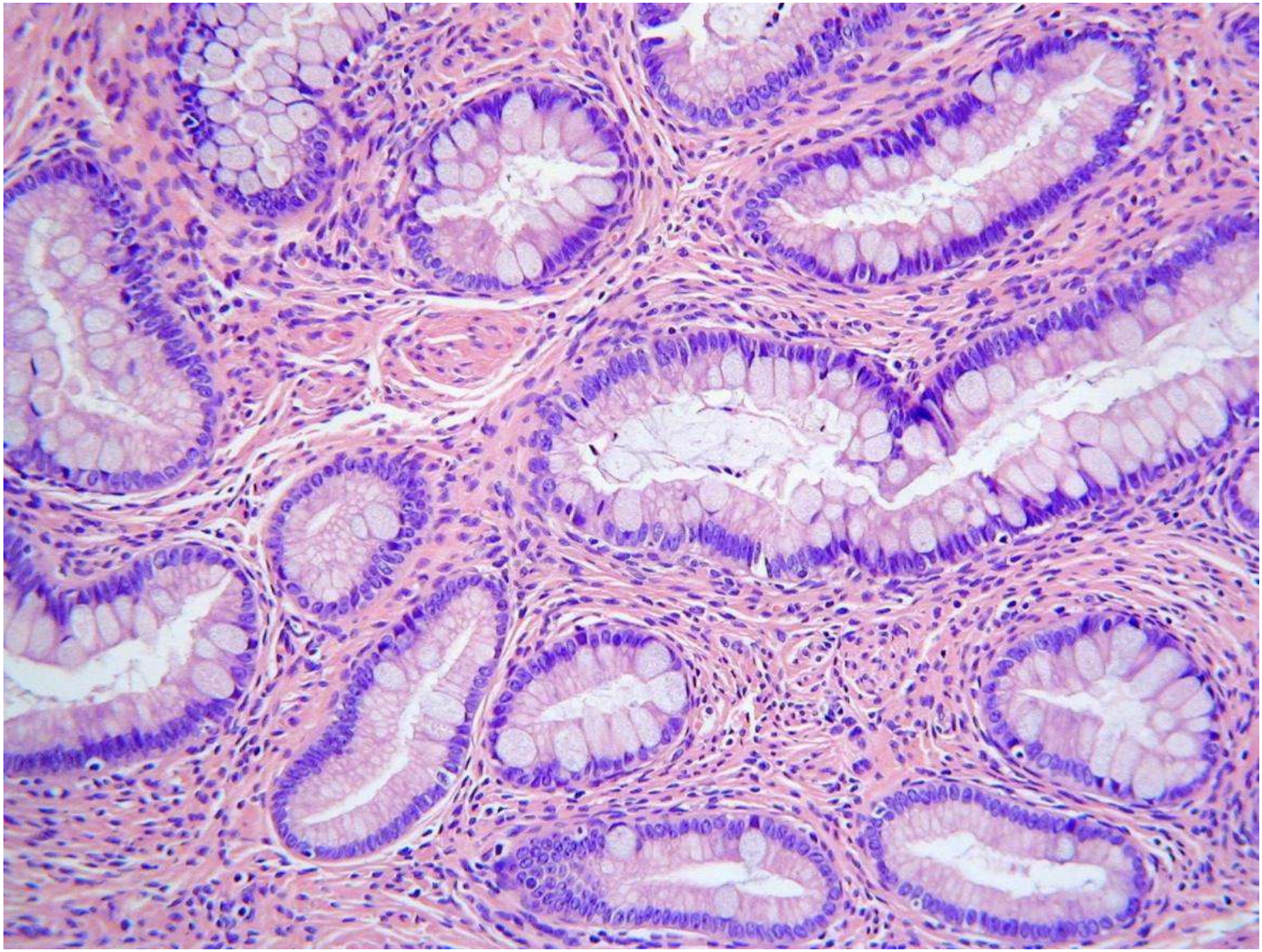

DIAGNOSIS: LOBULAR ENDOCERVICAL GLANDULAR HYPERPLASIA (LEGH)

- Uncommon lesion
- Benign cervical glandular lesion exhibiting gastric differentiation; also known as complex gastric (pyloric) metaplasia
- Sometimes associated with Peutz-Jeghers syndrome (worth mentioning on report)
- Sometimes associated with synchronous gastric type lesions elsewhere in female genital tract (worth mentioning on report)
- Often high in endocervical canal
- Positive with gastric markers but predominantly morphological diagnosis
- Usually lobular architecture (small glands surrounding dilated duct) but can be lost focally
- Often get goblet cells
- May extend quite deep into cervical wall
- MAY BE MISDIAGNOSED AS MORPHOLOGICALLY WELL-DIFFERENTIATED GASTRIC-TYPE ADENOCARCINOMA

LEGH- SUBTLE CYTOLOGIC DIFFERENCES FROM NORMAL ENDOCERVICAL GLANDS

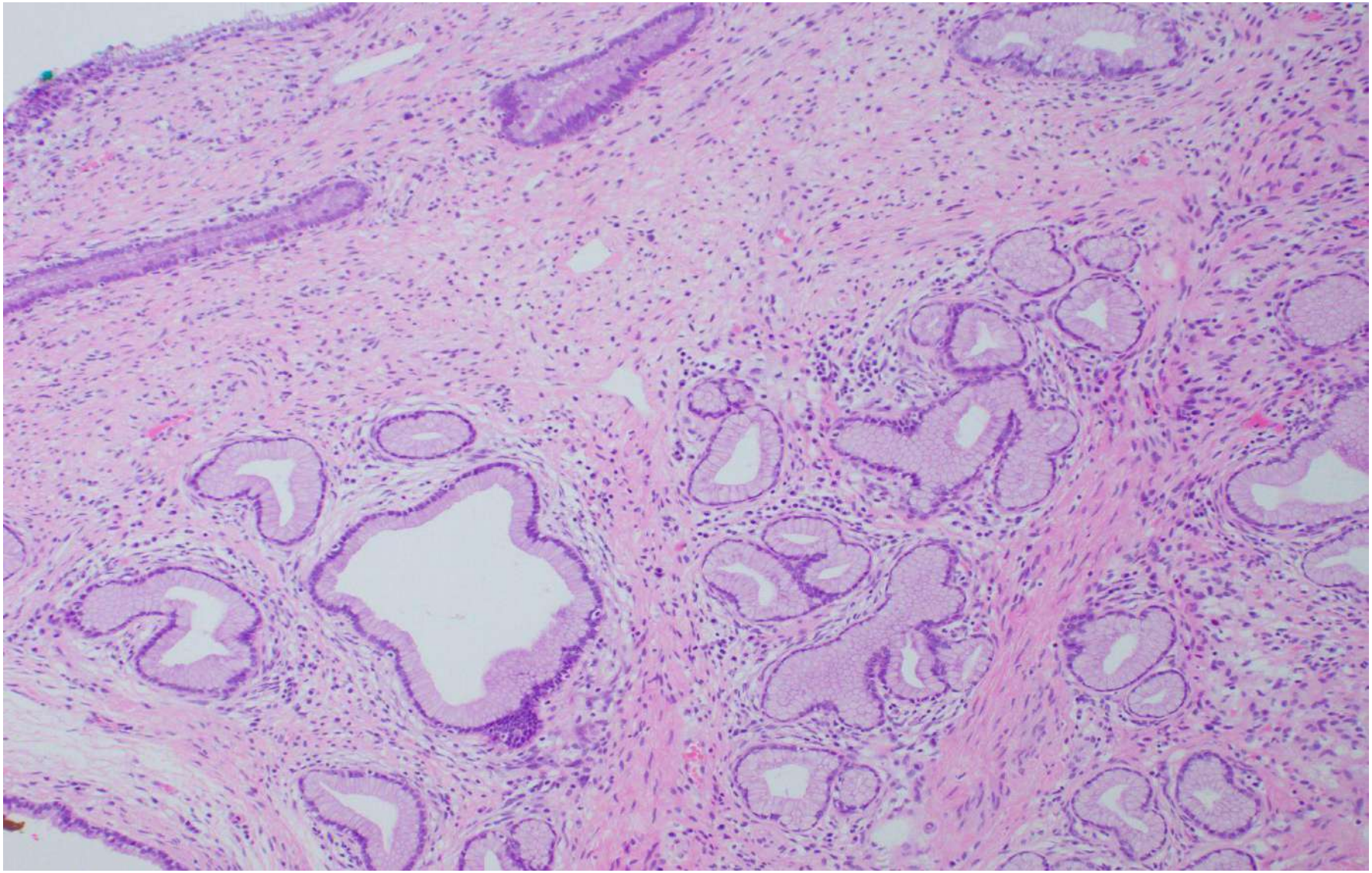

IMMUNOHISTOCHEMISTRY OF LEGH

- Predominantly a morphological diagnosis
- Most (not all) gastric lesions are negative with hormone receptors (useful in distinction of LEGH from other benign glandular lesions); ER may be weakly positive (especially in LEGH); PR typically negative
- Typically get significant number of neuroendocrine positive cells (occasionally can pick these up on morphology- “Paneth-like”)
- May be CDX2 positive

HORMONE RECEPTORS IN LEGH

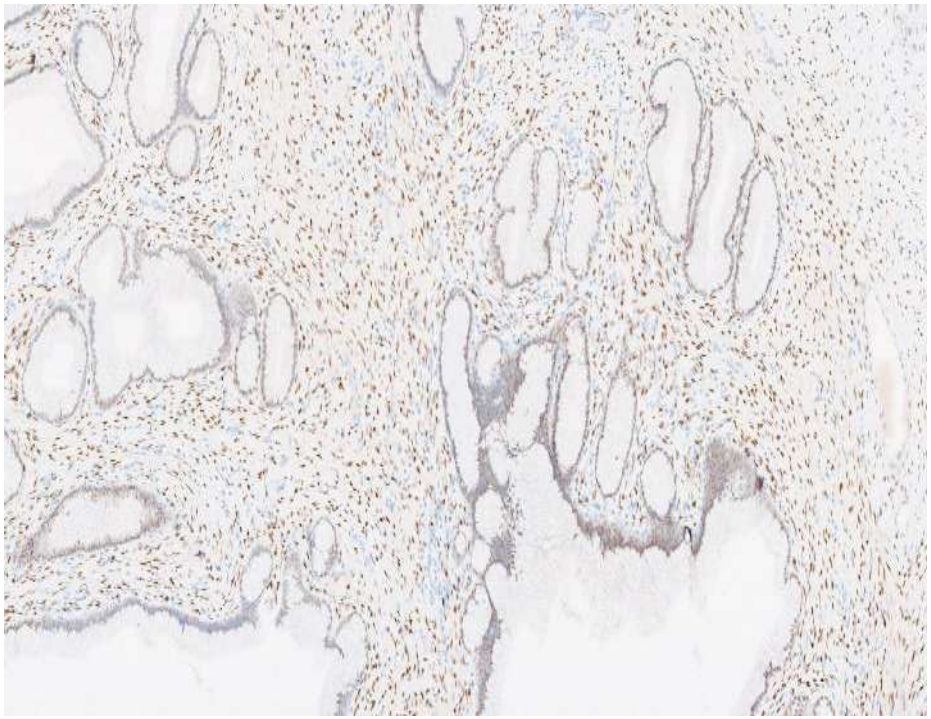

ER

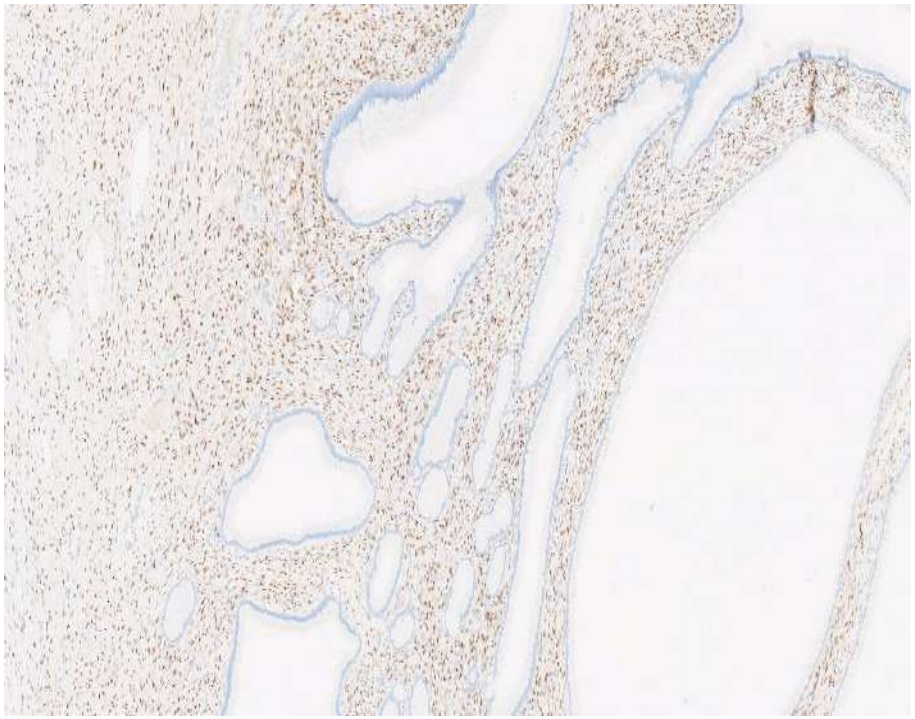

PR

NEUROENDOCRINE CELLS IN LEGH

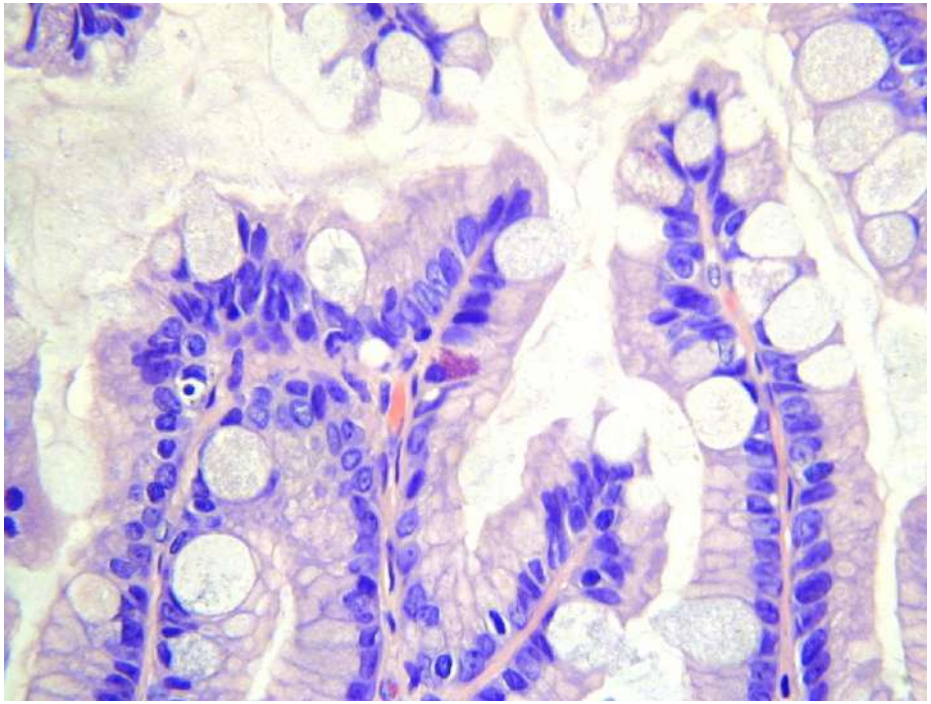

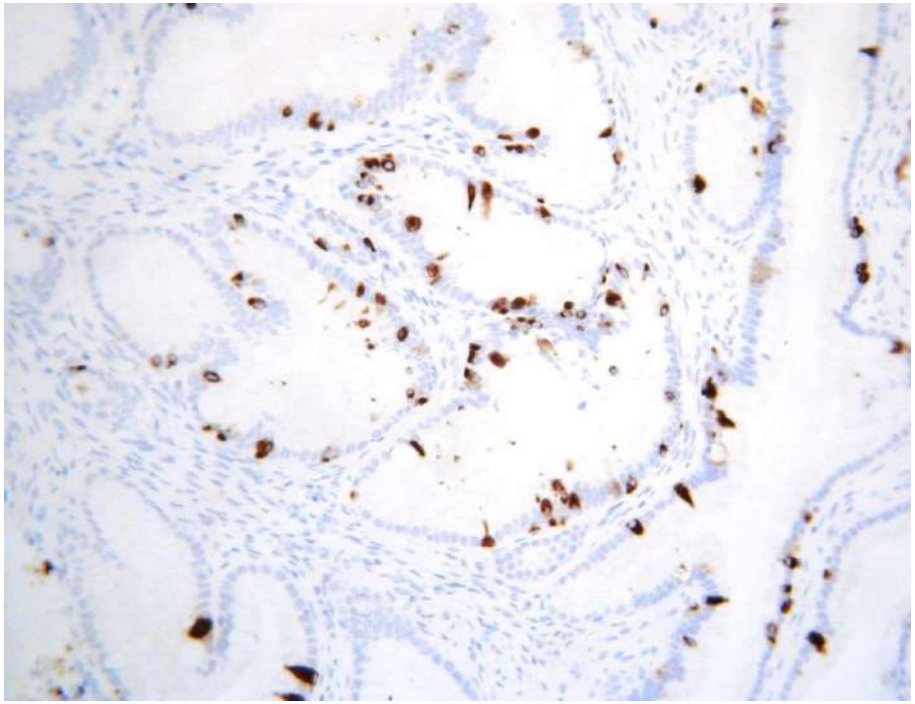

chromogranin

GASTRIC MARKERS IN CERVIX (AND ELSEWHERE IN FEMALE GENITAL TRACT)

- Two most commonly used are MUC6 and HIK1083
- HIK1083- not widely available
- HIK1083- less sensitive but much more specific
- MUC6- quite sensitive but sometimes only focally positive
- MUC6- very non-specific (normal endocervical and endometrial glands may be positive; HPV-associated adenocarcinomas may be positive; endometrial adenocarcinomas often positive; PMID 31021421)
- Other “gastric” markers (trefoil factor 2/ TFF2, CAIX, claudin 18); **claudin 18 is maybe becoming marker of choice, although many laboratories do not have (PMID 39652450)**
- Currently we don’t have a really good gastric marker in terms of specificity and sensitivity

MUC6 IN LEGH

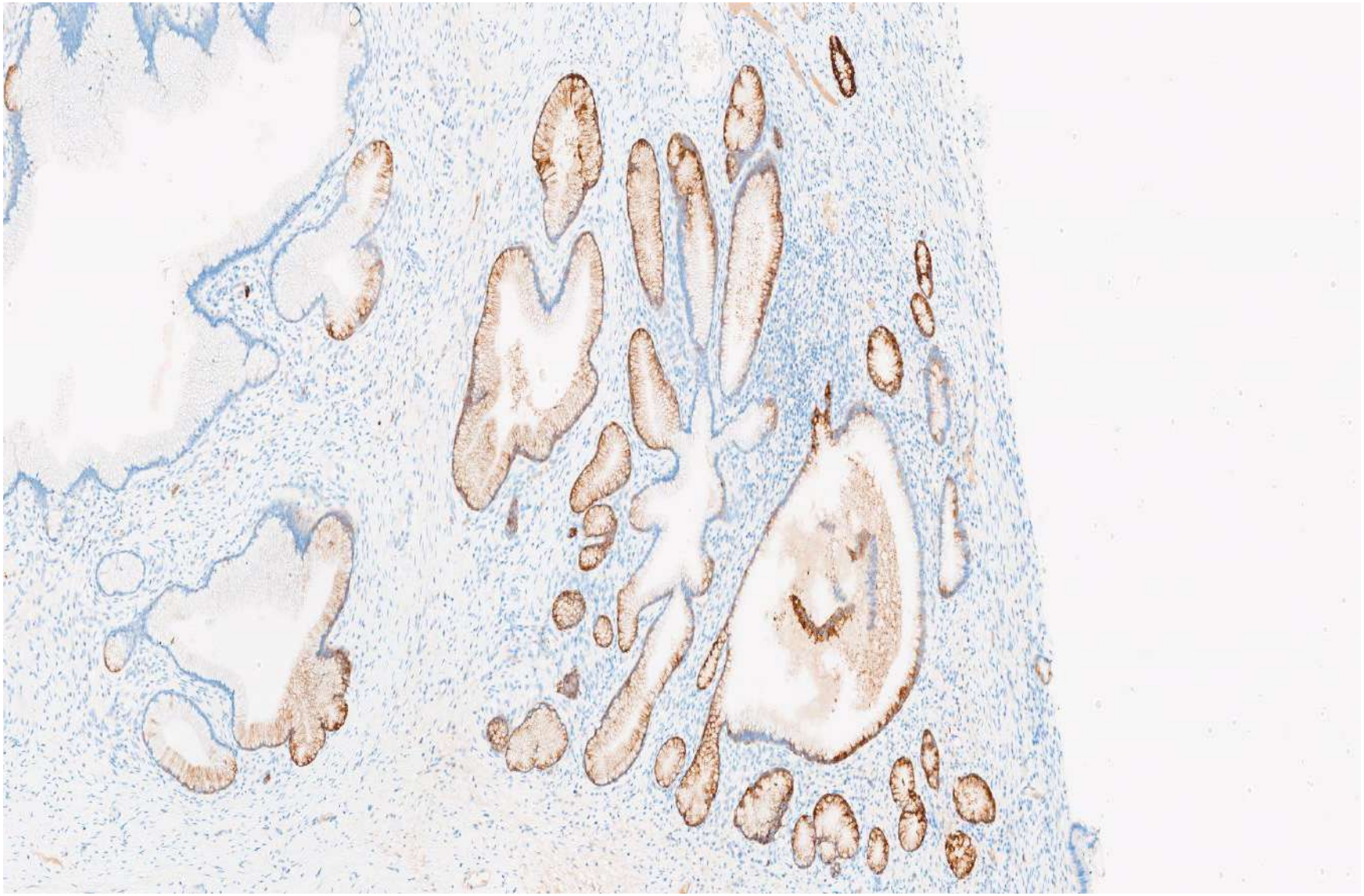

PMID 39652450

ORIGINAL ARTICLE

Claudin-18 and Mutation Surrogate Immunohistochemistry in Gastric-type Endocervical Lesions and their Differential Diagnoses

Lawrence Hsu Lin, MD, PhD,† Harsimar Kaur, MBBS,* David L. Kolin, MD, PhD,* Marisa R. Nucci, MD,* and Carlos Parra-Herran, MD**

PMID 29233547; 2018

Pathology (February 2018) 50(2), pp. 122–133

GYNAECOLOGICAL PATHOLOGY

The developing spectrum of gastric-type cervical glandular lesions

KAREN L. TALIA[1] AND W. GLENN MCCLUGGAGE[2]

[1]*Department of Pathology, Box Hill Hospital, Melbourne, Vic, Australia; and* [2]*Department of Pathology, Belfast Health and Social Care Trust, Belfast, Northern Ireland, United Kingdom*

GASTRIC TYPE CERVICAL LESIONS- Advances in Anatomic Pathology 2013;20;227-237

BENIGN

lobular endocervical glandular hyperplasia (complex pyloric/gastric metaplasia)

simple gastric/pyloric metaplasia

type A tunnel cluster

PREMALIGNANT

atypical lobular endocervical glandular hyperplasia

adenocarcinoma in situ (AIS) of gastric type

MALIGNANT

gastric-type adenocarcinoma (incorporating minimal deviation adenocarcinoma/ adenoma malignum)

SPECIFIC CONDITIONS

synchronous mucinous metaplasia and neoplasia of the female genital tract

Peutz-Jeghers syndrome

ATYPICAL LOBULAR ENDOCERVICAL GLANDULAR HYPERPLASIA (LEGH)

- very rare
- cytologic and/ or architectural abnormalities in LEGH
- atypical LEGH probably spectrum from mild reactive changes to precursor of gastric-type adenocarcinoma
- some (not all) gastric-type adenocarcinomas may arise from atypical LEGH
- regarded as type of gastric-type AIS
- MAY BE MISDIAGNOSED AS MORPHOLOGICALLY WELL-DIFFERENTIATED GASTRIC-TYPE ADENOCARCINOMA

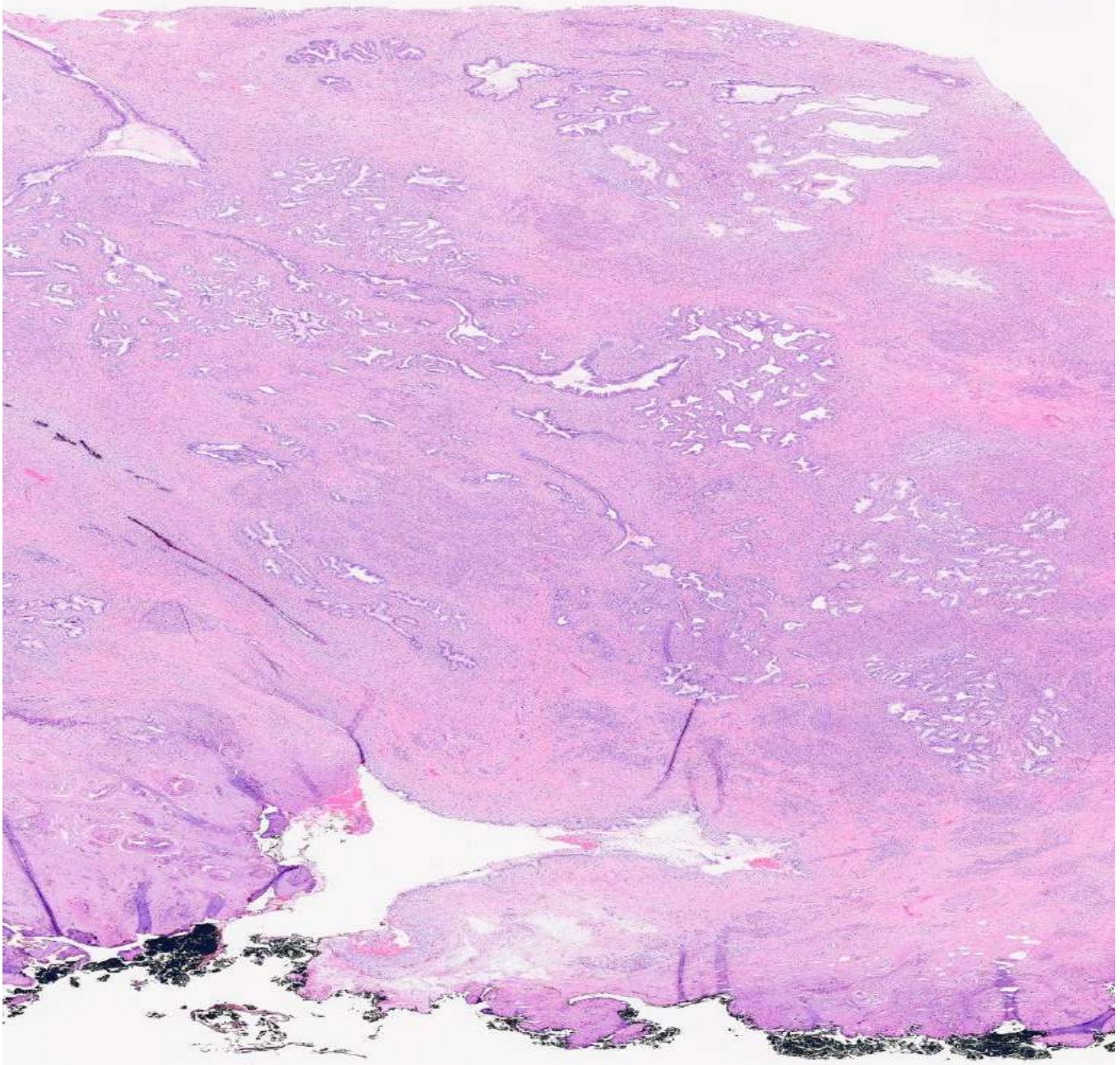

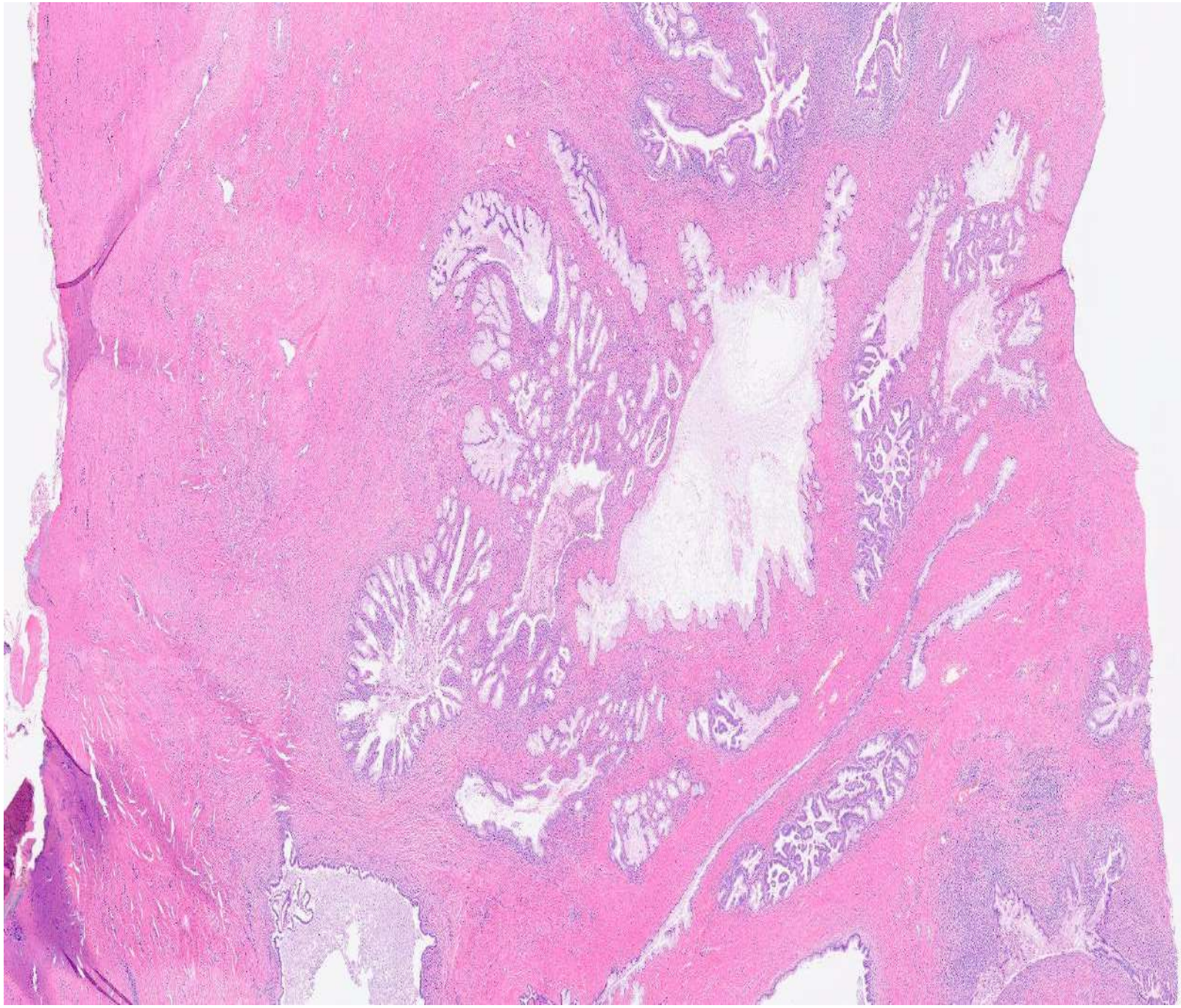

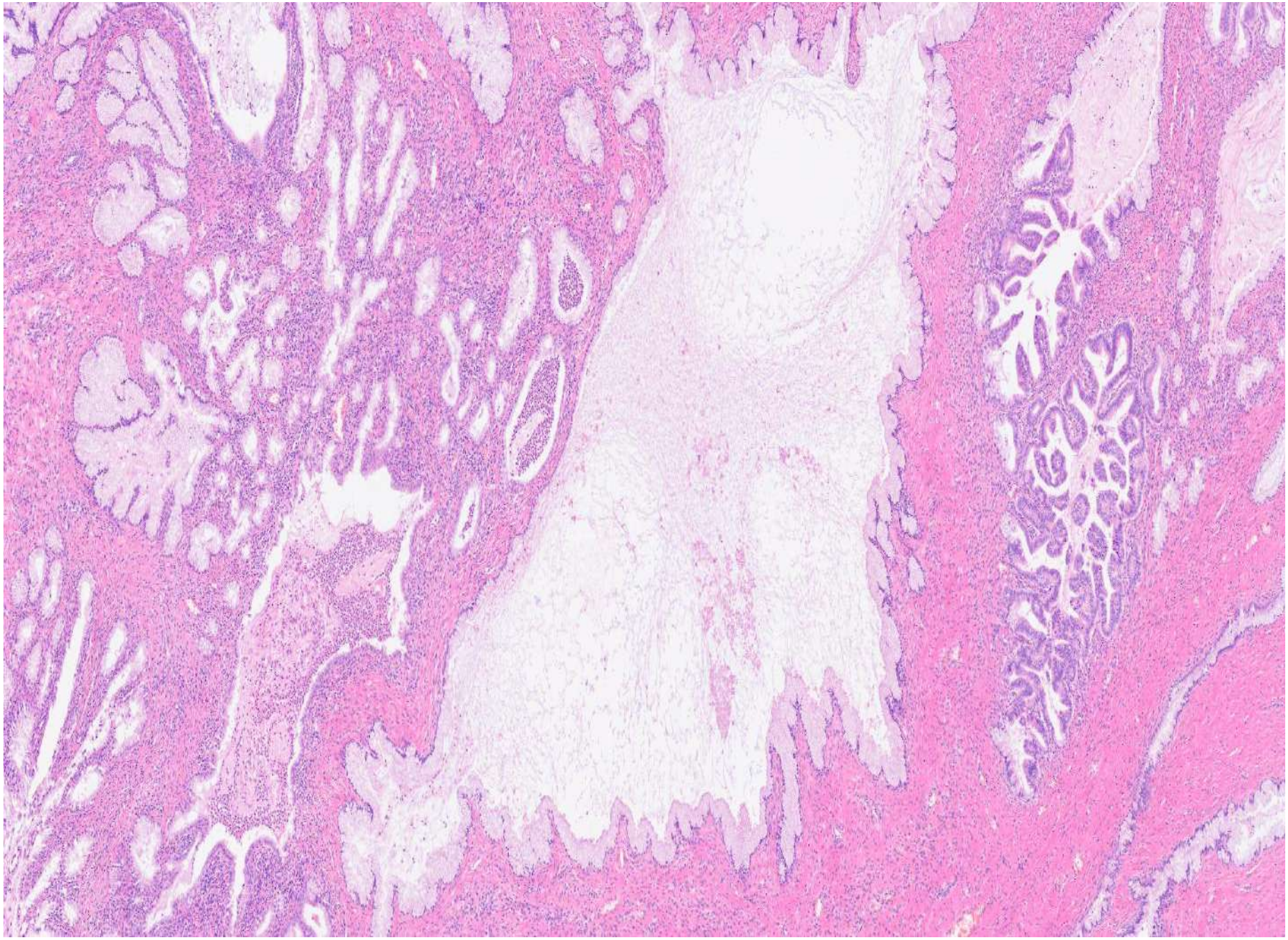

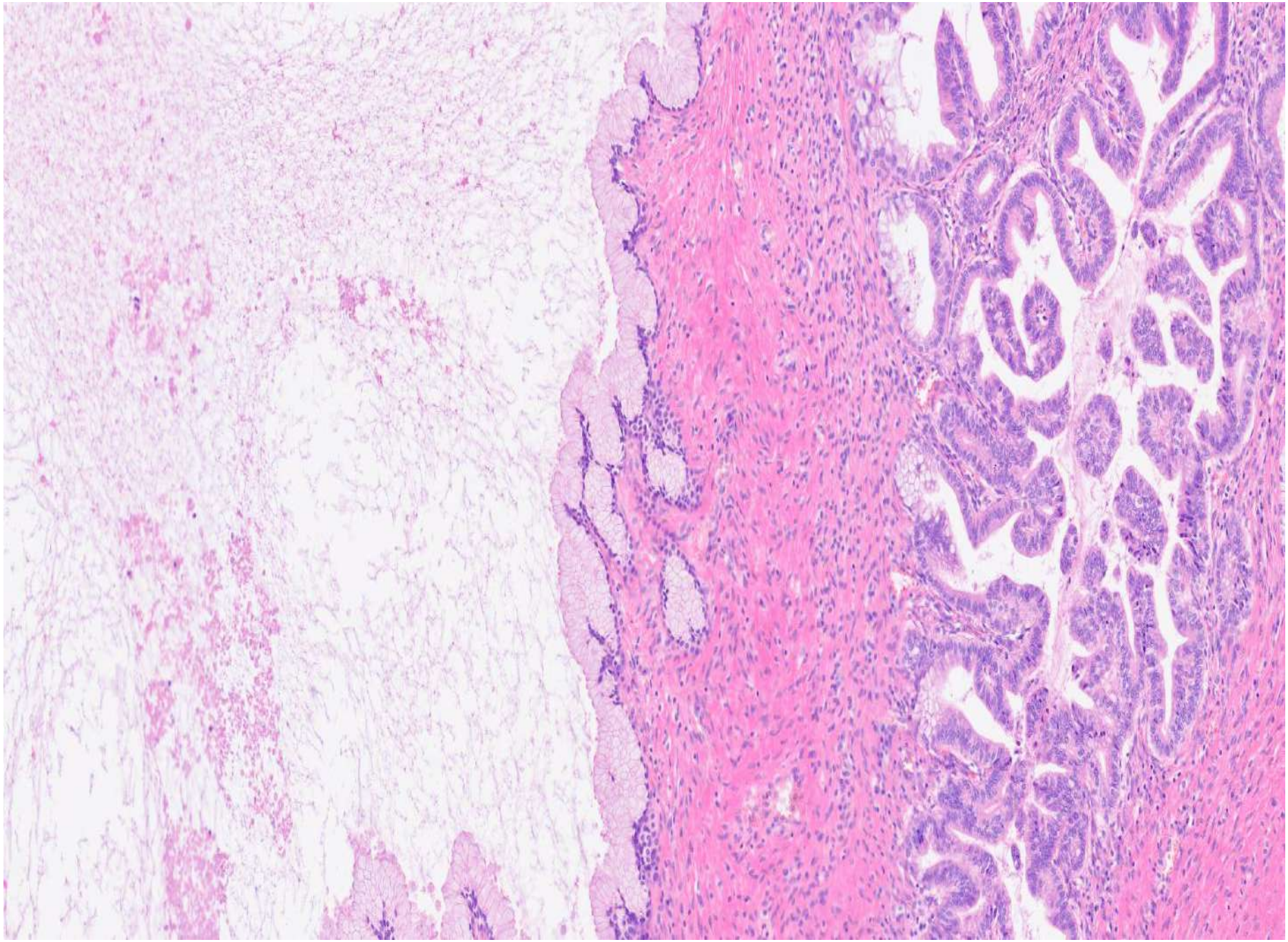

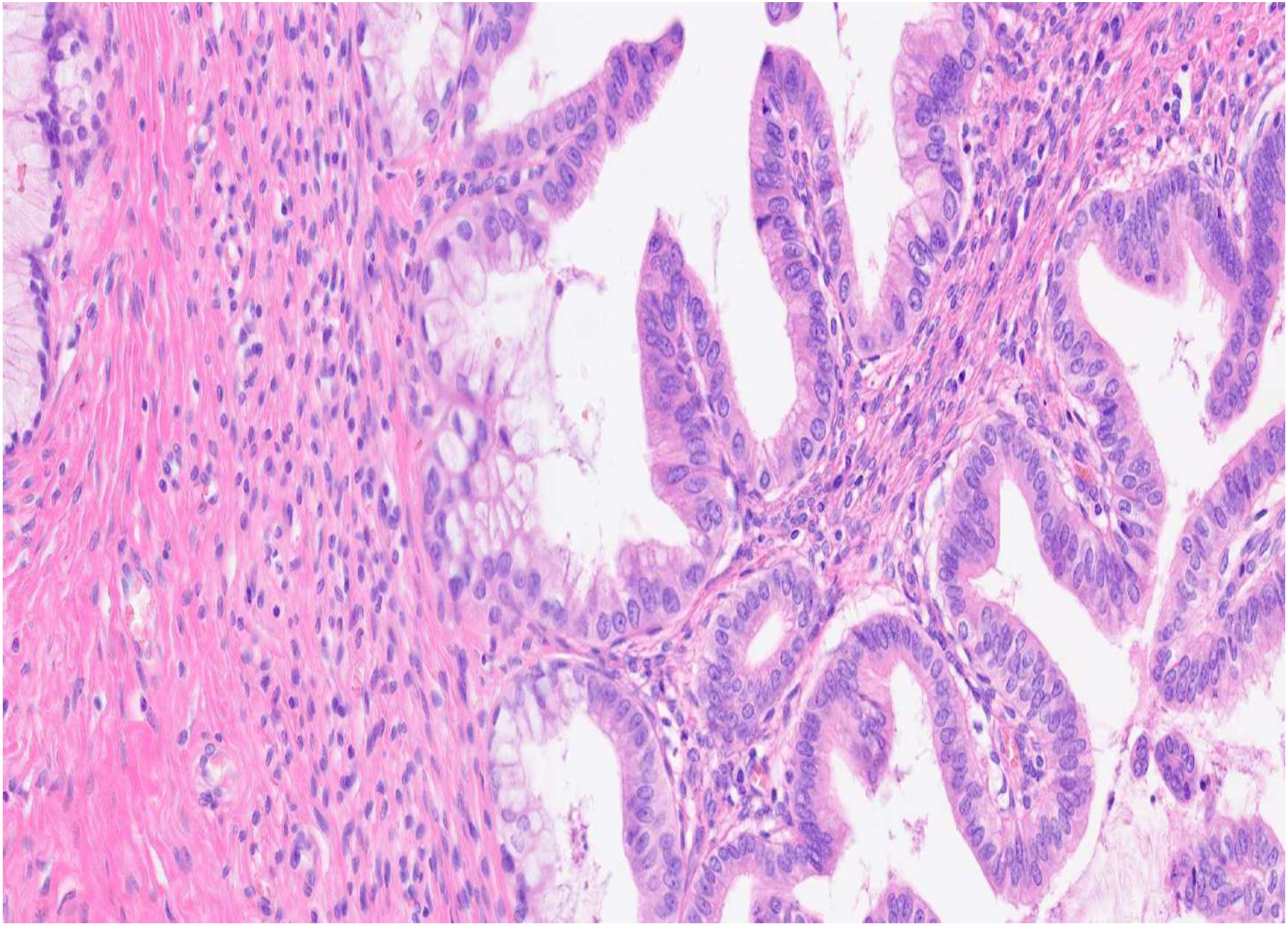

PMID 28394803

ORIGINAL ARTICLE

HPV-negative Gastric Type Adenocarcinoma In Situ of the Cervix

A Spectrum of Rare Lesions Exhibiting Gastric and Intestinal Differentiation

Karen L. Talia, FRCPA, Colin J.R. Stewart, FRCPA,† Brooke E. Howitt, MD,‡ Marisa R. Nucci, MD,‡ and W. Glenn McCluggage, FRCPath§*

AIS OF GASTRIC-TYPE

- HPV-independent AIS
- Usually at transformation zone but may extend to LUS
- May be purely gastric or mixed gastric and intestinal with goblet cells (more accurate terminology would be “gastrointestinal” type AIS)
- Generally low-grade nuclear atypia; subtle lesion
- Less frequent mitoses and apoptosis than in HPV associated AIS
- Probable precursor to gastric-type adenocarcinoma
- p16 negative or focal
- May be p53 mutated
- Hormone receptor negative
- May be positive with gastric markers
- May contain neuroendocrine positive cells

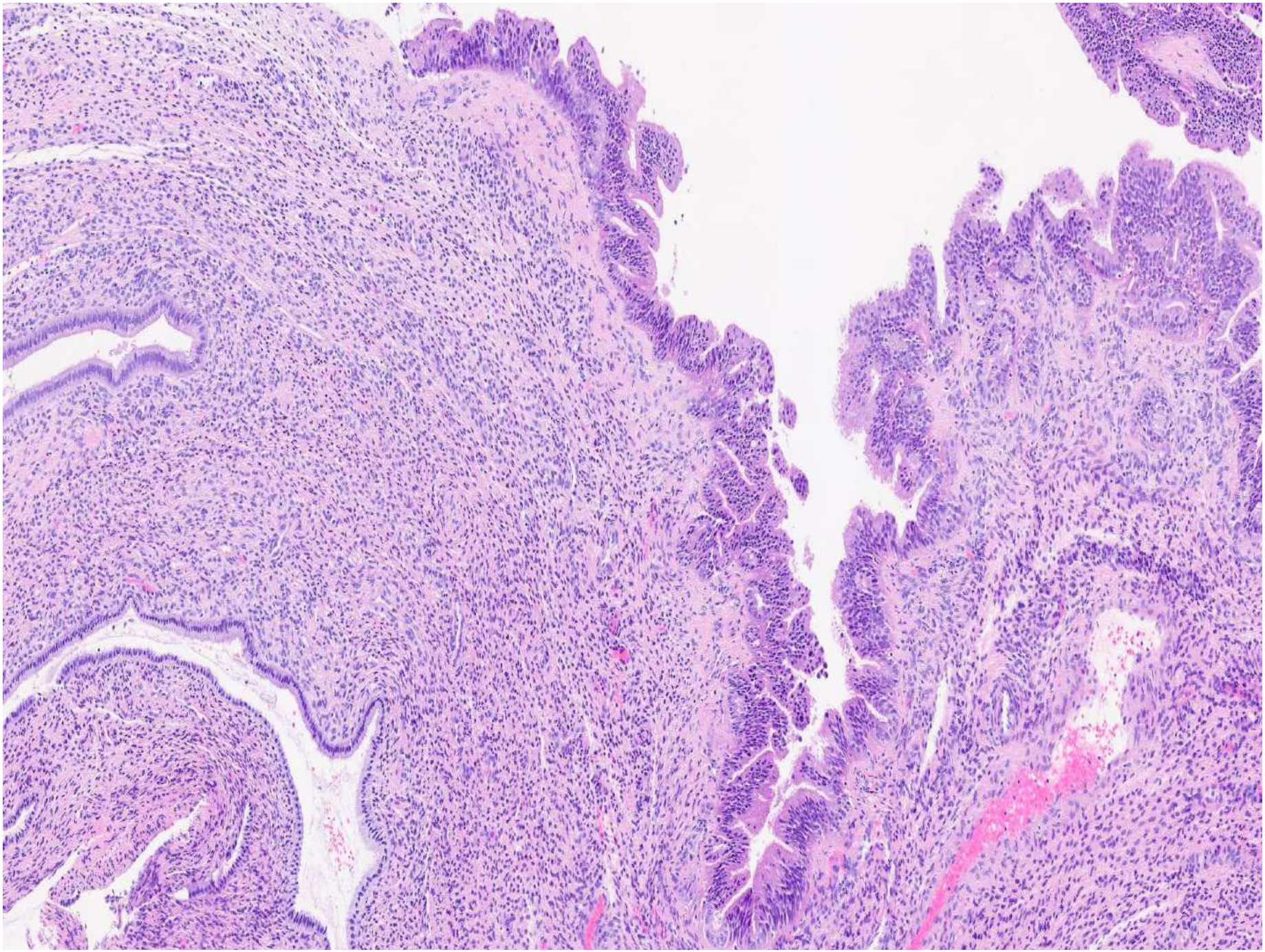

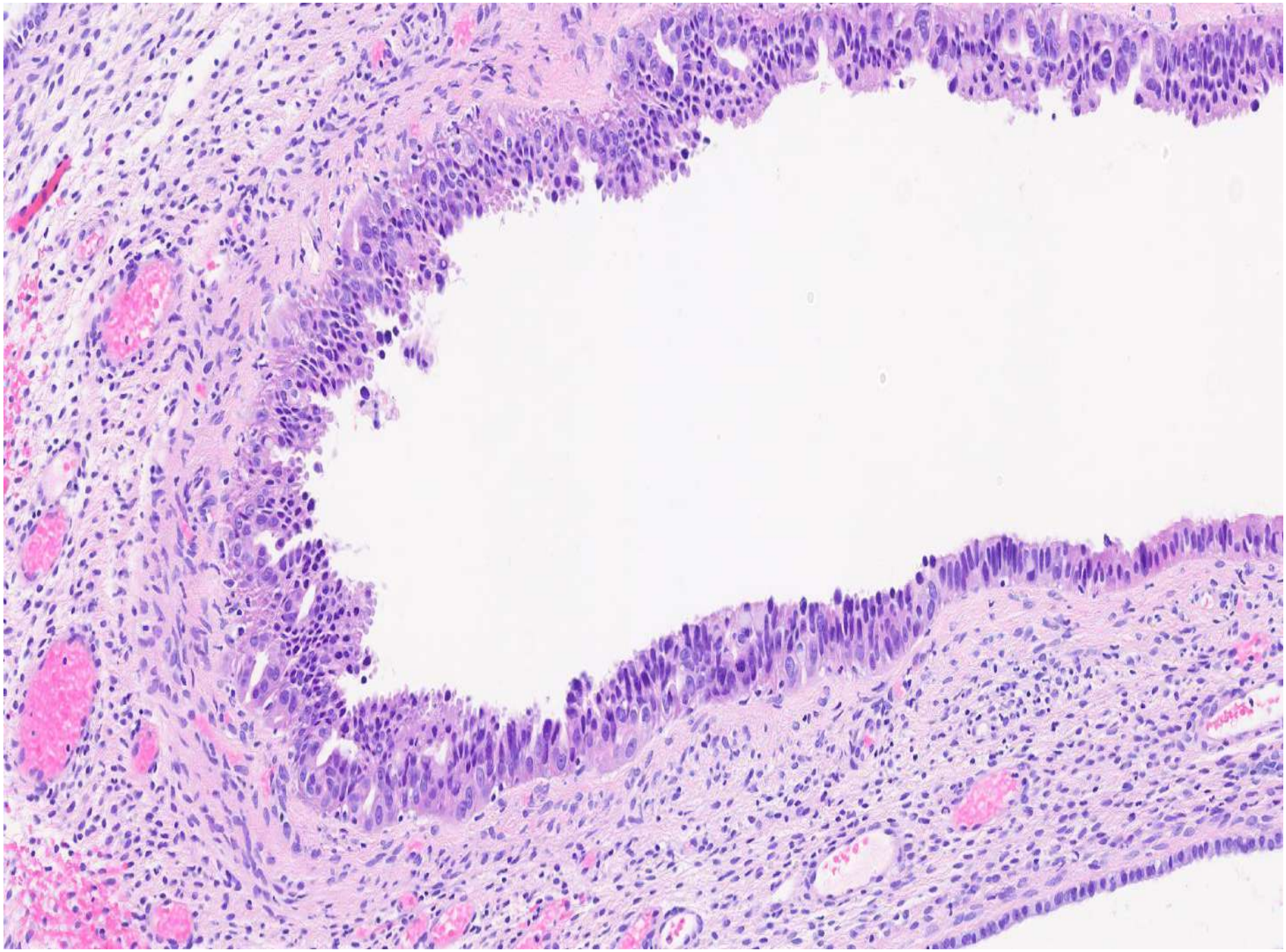

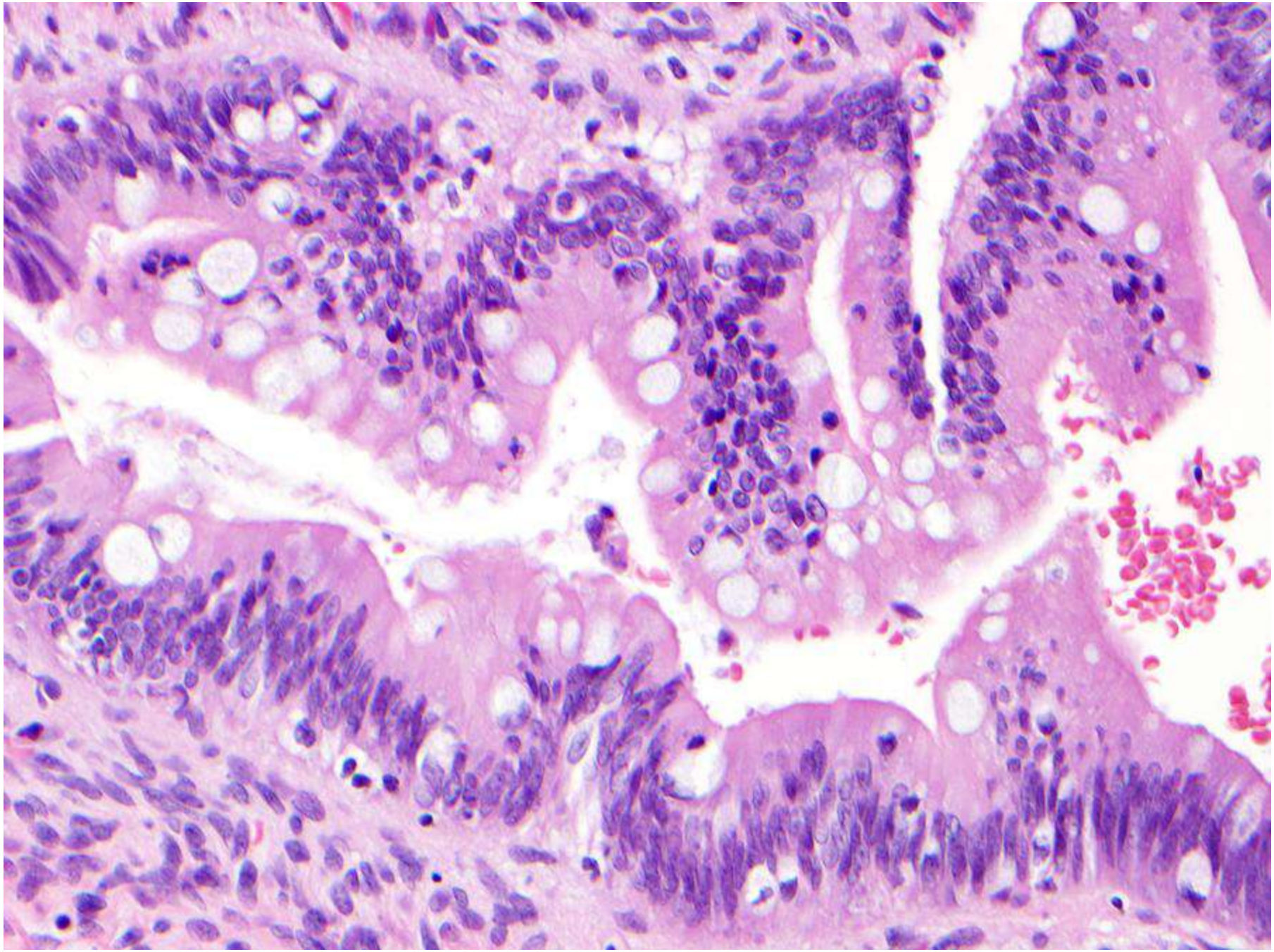

AIS OF GASTRIC TYPE

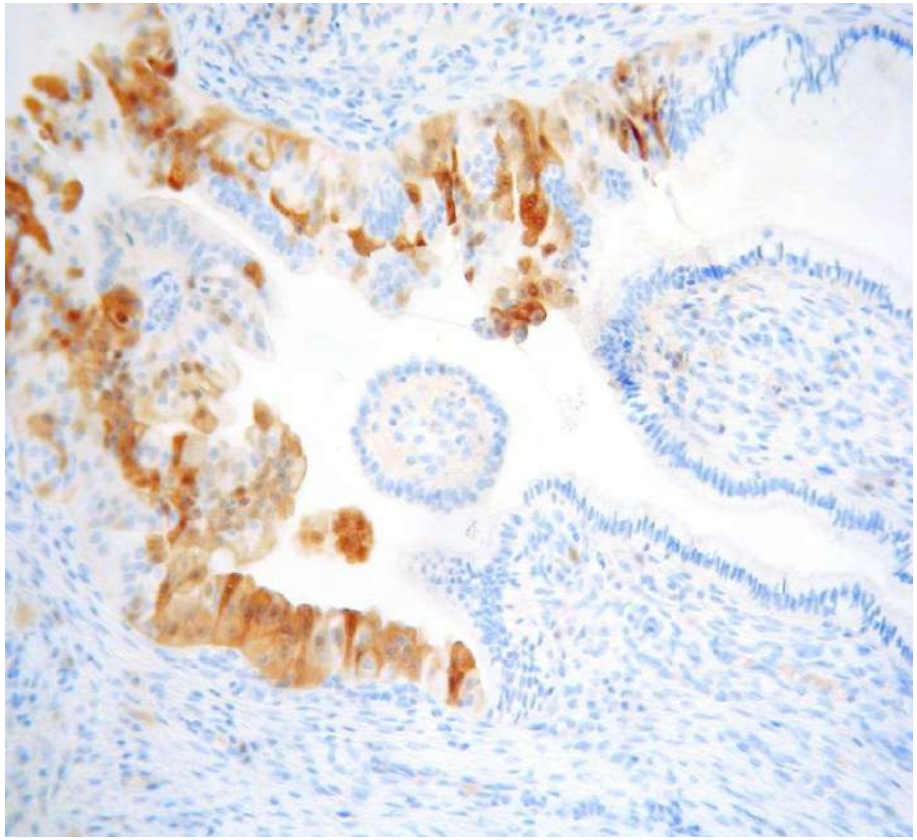

p16

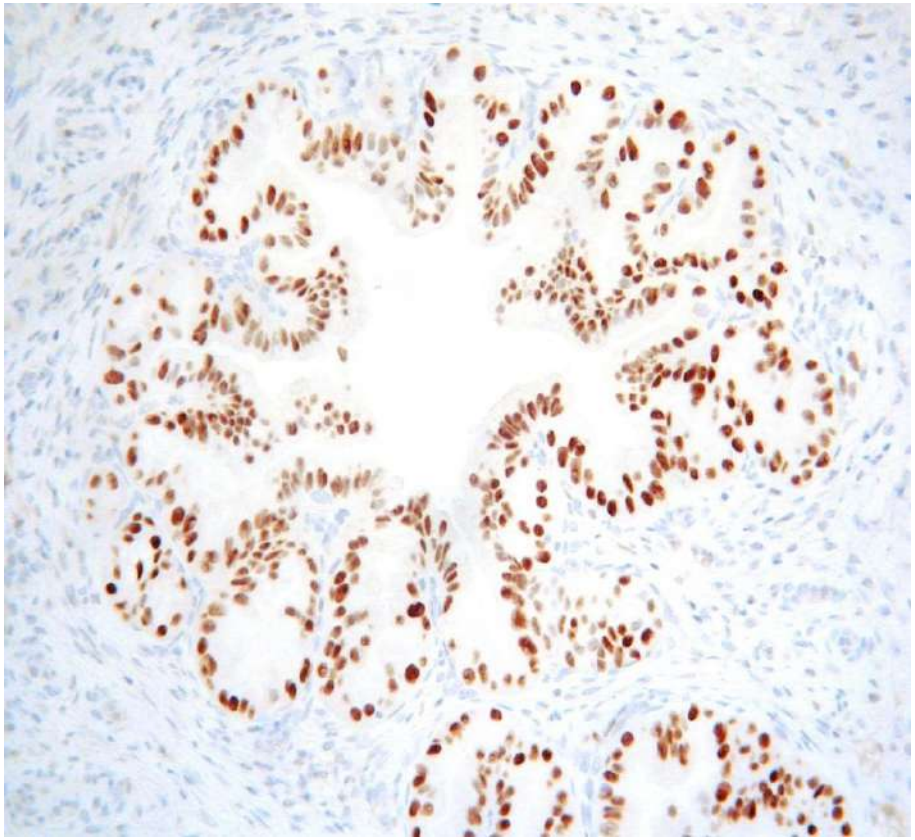

p53

AIS OF GASTRIC TYPE

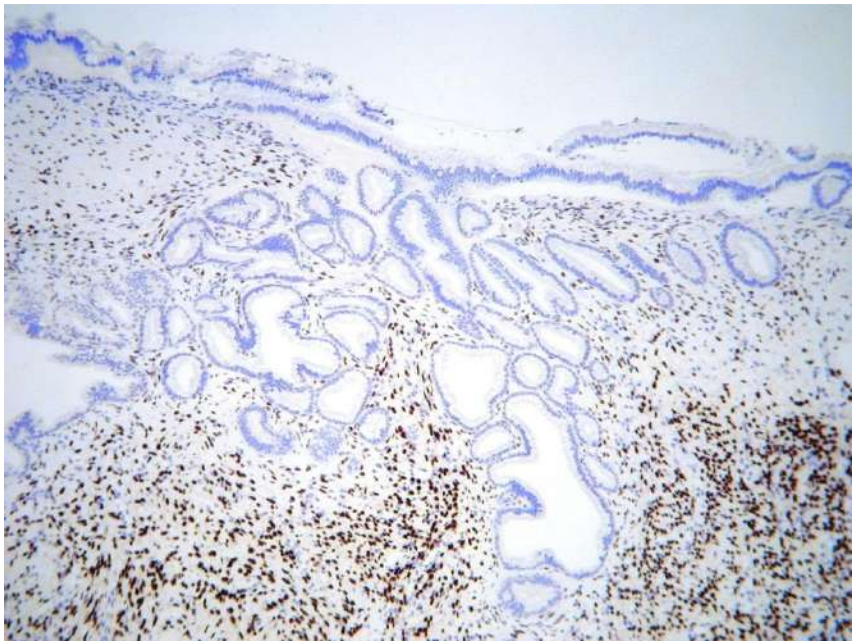

ER

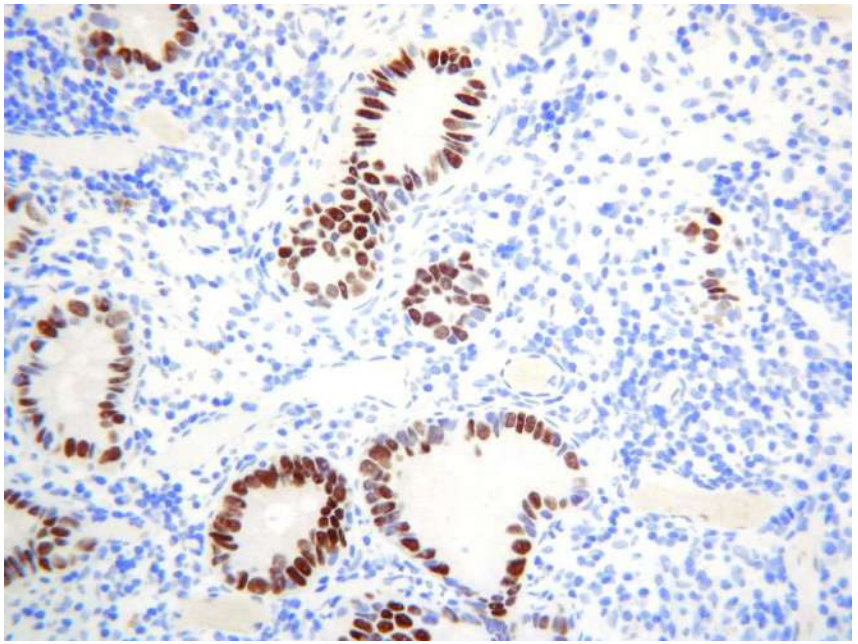

CDX2

INTESTINAL-TYPE AIS

- Do not use this terminology since goblet cells may be seen in HPV-associated and HPV-independent AIS
- Former- HPV-associated AIS with intestinal differentiation
- Latter- gastric-type AIS

DISTINCTION OF LEGH/ ATYPICAL LEGH FROM GASTRIC-TYPE ADENOCARCINOMA

- May be impossible on small biopsy
- LEGH typically has a lobular architecture, although can be lost focally
- Gastric-type adenocarcinoma often deep stromal involvement; LEGH usually confined to inner half of cervical stroma but can extend into outer half
- Gastric-type adenocarcinoma- usually areas of overt nuclear atypia
- Gastric-type adenocarcinoma- usually see areas of overt stromal response

MANAGEMENT OF LEGH/ ATYPICAL LEGH

- Need to take into account possible multifocal involvement of female genital tract
- Need to consider possibility of Peutz-Jeghers syndrome
- Ideally want to ensure total excision but may be very difficult since often high in endocervical canal
- Depends on fertility wishes
- Radiological examination

CASE 2

- F 35
- On progestogens
- Presented with postcoital bleeding
- Cervical friable mass seen and biopsied

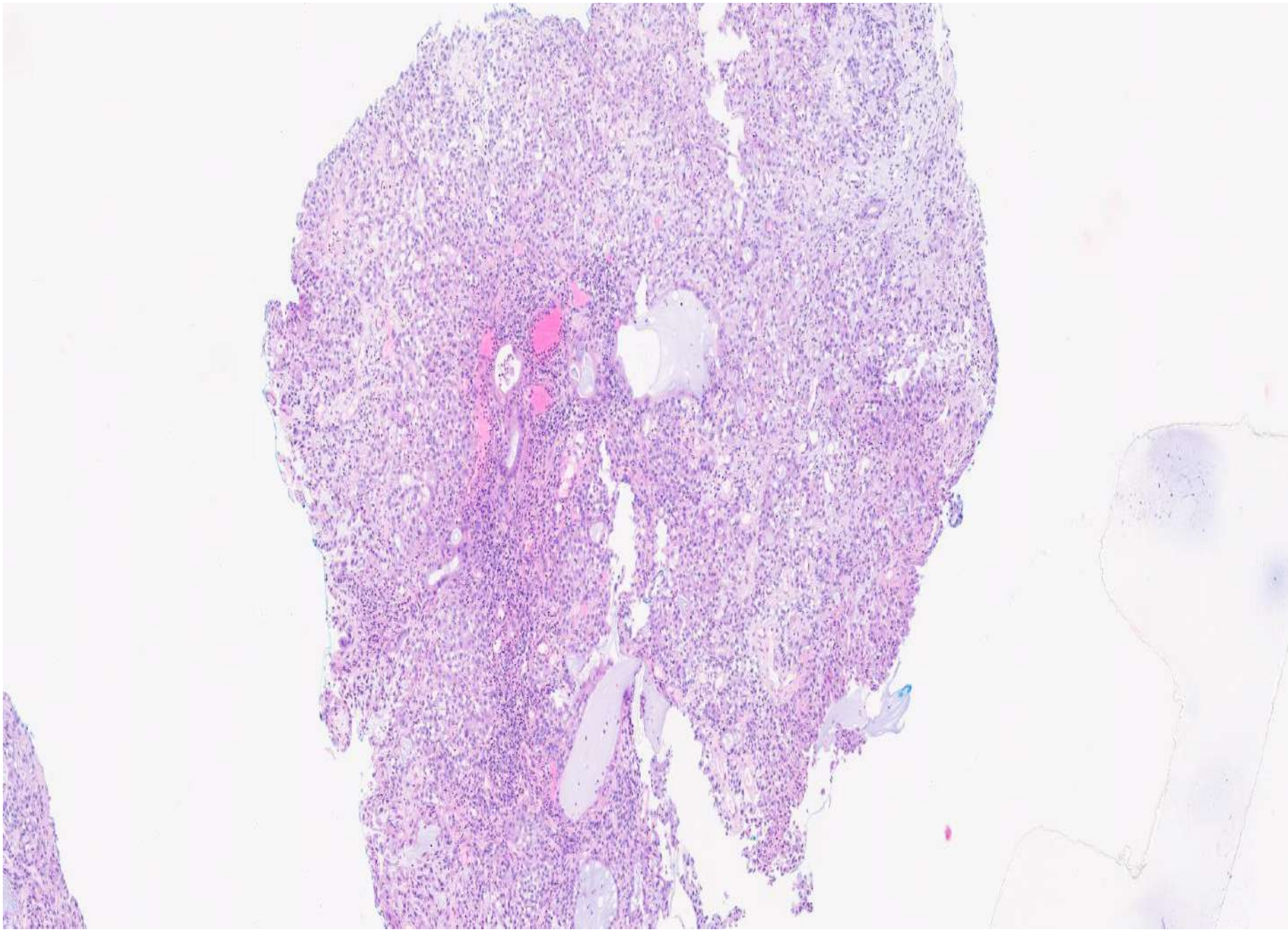

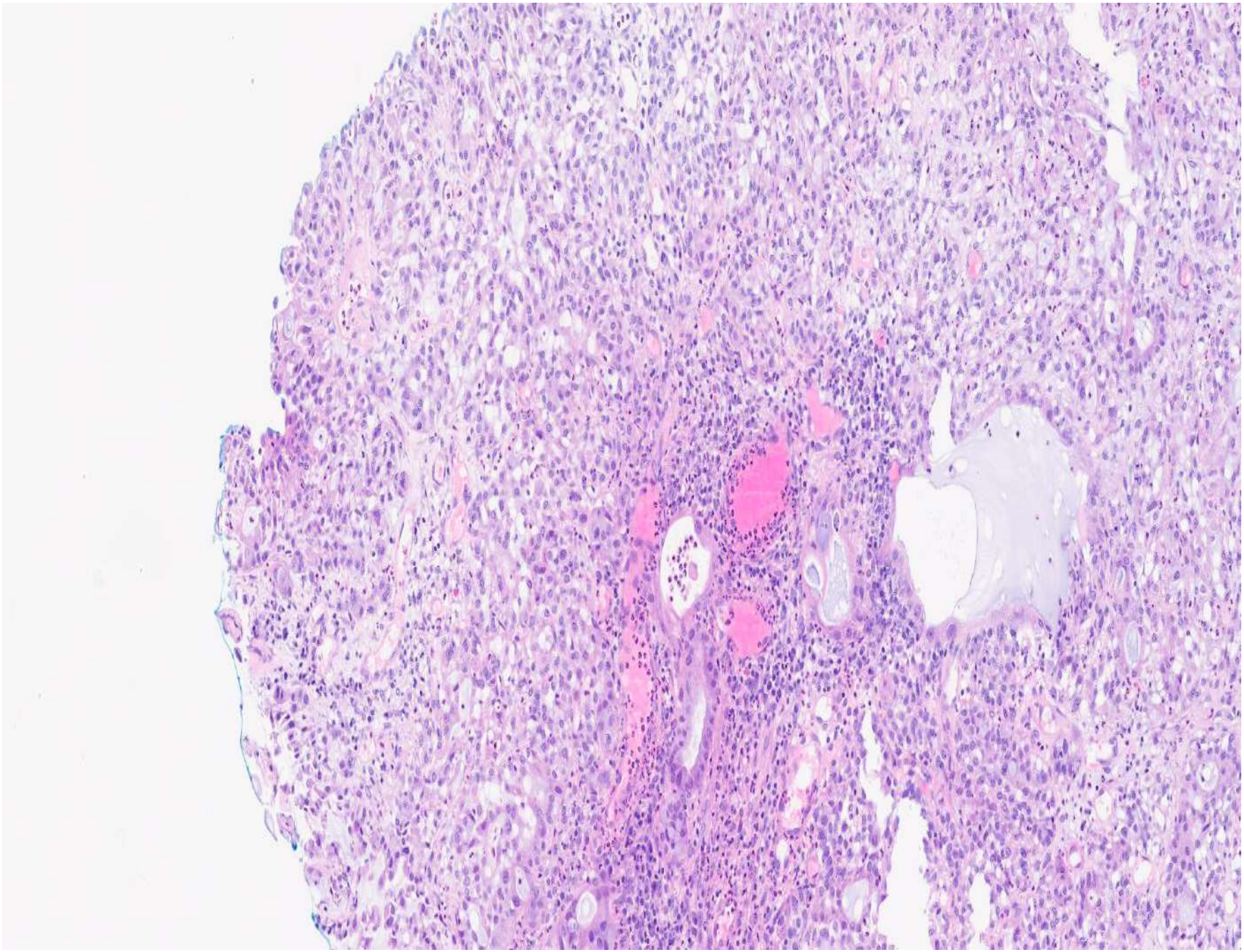

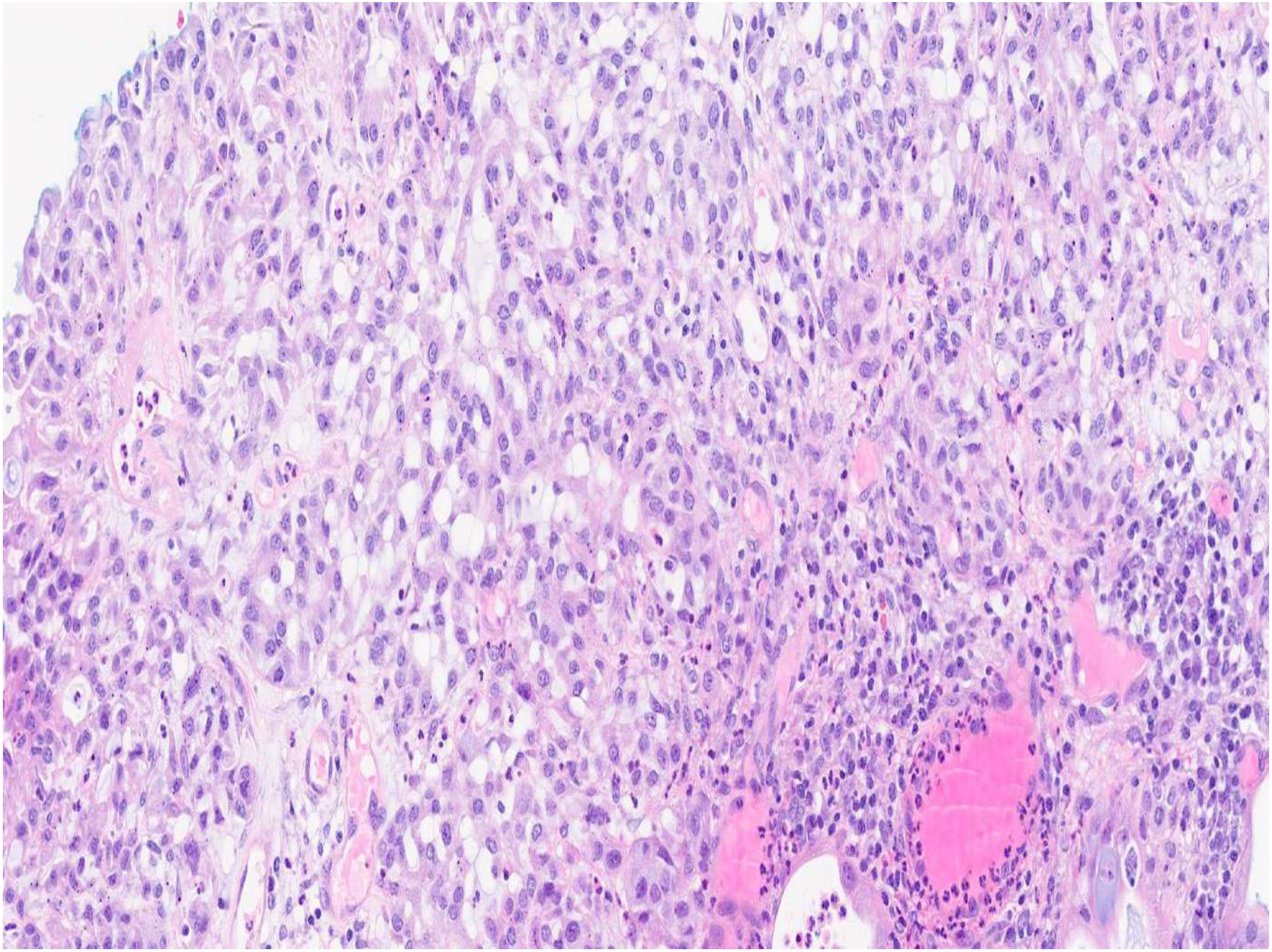

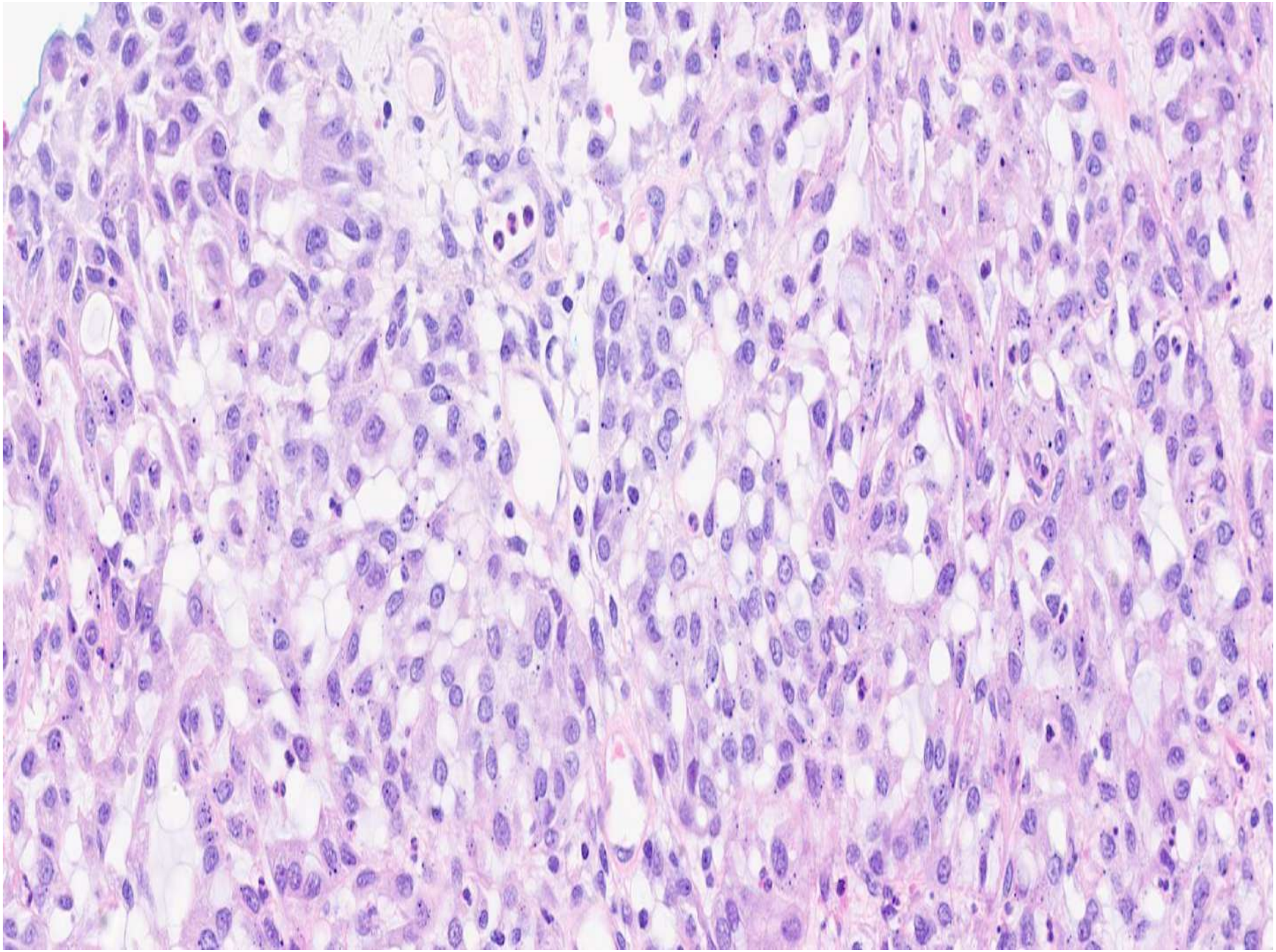

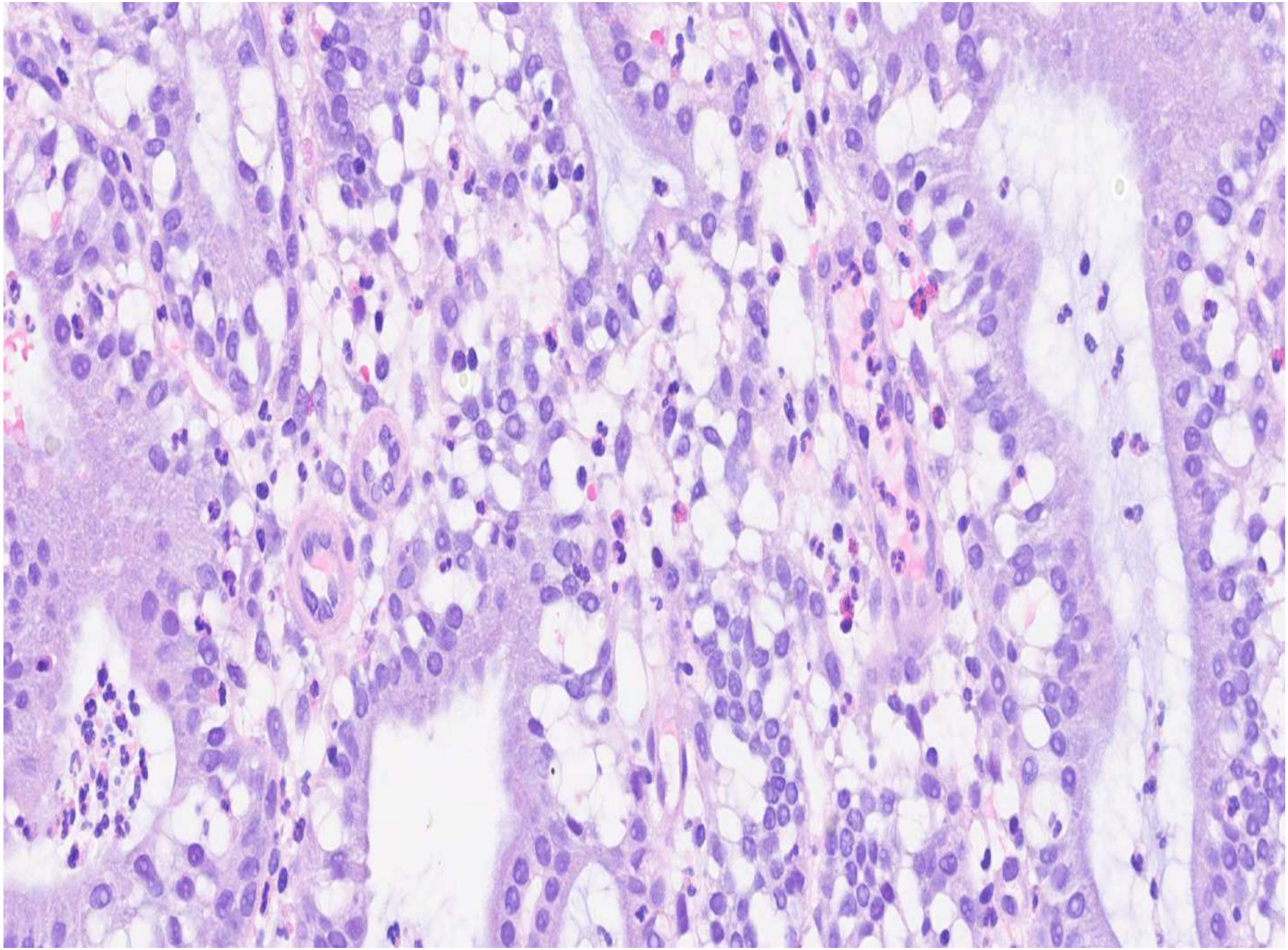

DIAGNOSIS- CERVICAL MICROGLANDULAR HYPERPLASIA

- common and typically easy to diagnose
- usually, but not invariably, young
- usually, but not always, associated with hormonal preparations
- unusual findings- SOLID, ONCOCYTIC, STROMAL HYALINISATION, SIGNET-RING CELLS- look for more typical areas as clue to diagnosis
- MAY BE MISDIAGNOSED AS CLEAR CELL CARCINOMA OR MICROGLANDULAR VARIANT OF ENDOMETRIOID CARCINOMA

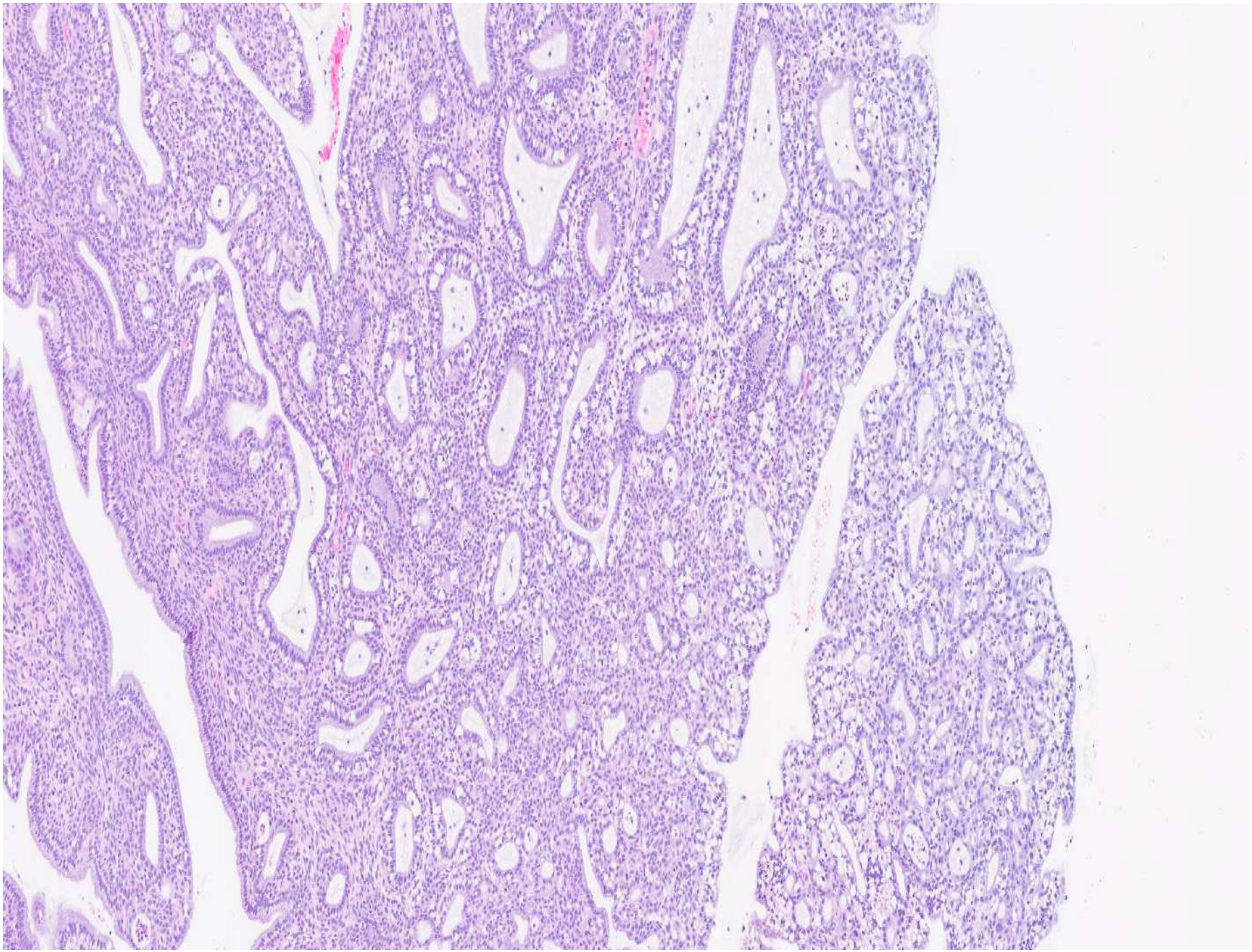

MICROGLANDULAR HYPERPLASIA

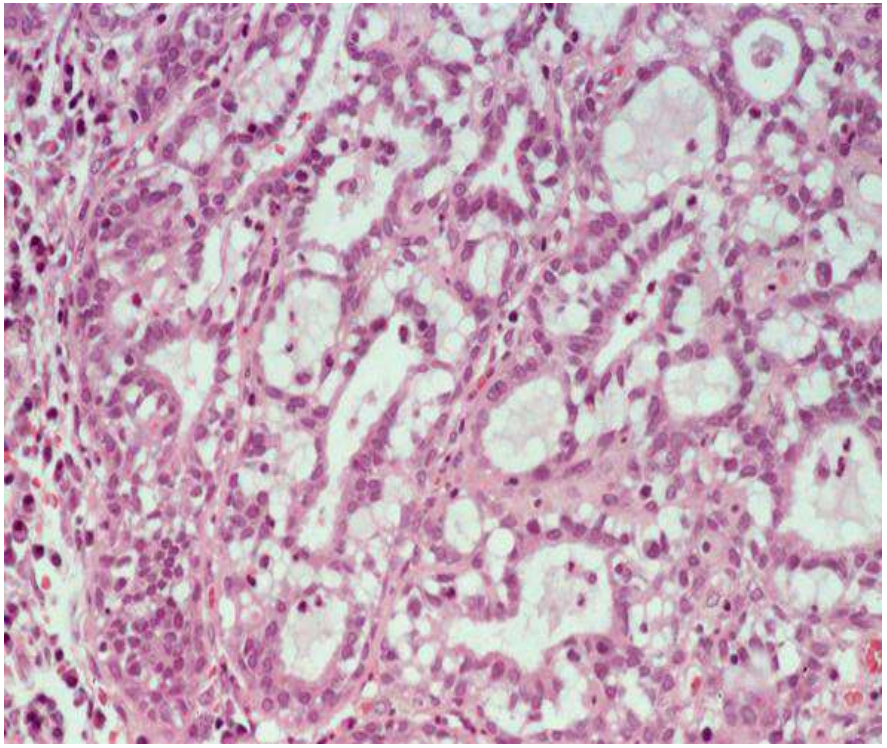

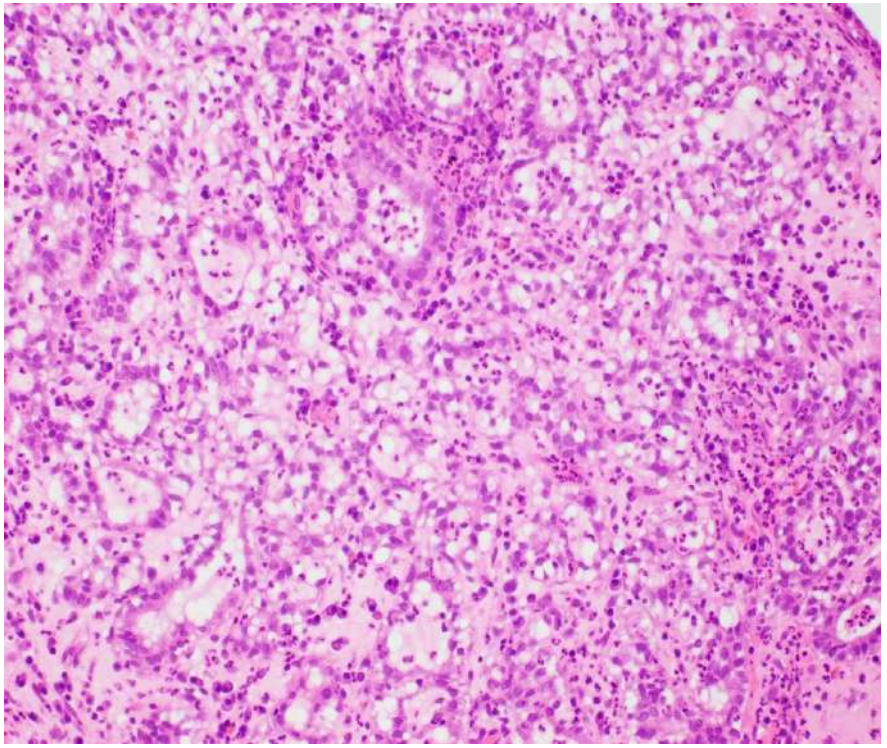

MGH CERVIX- SOLID

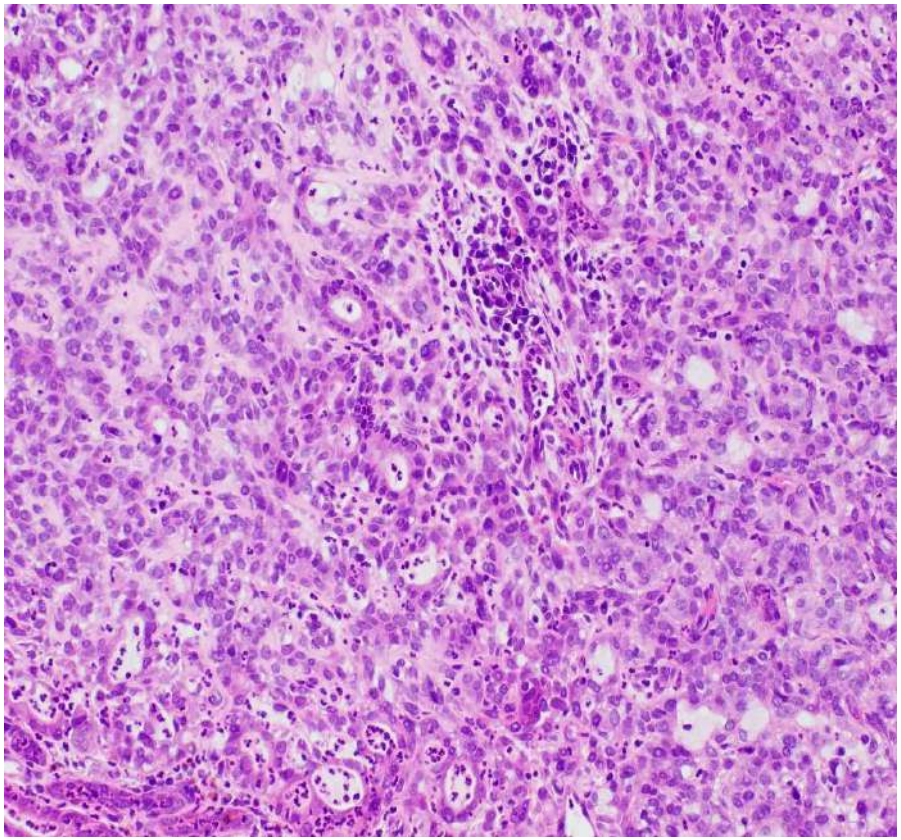

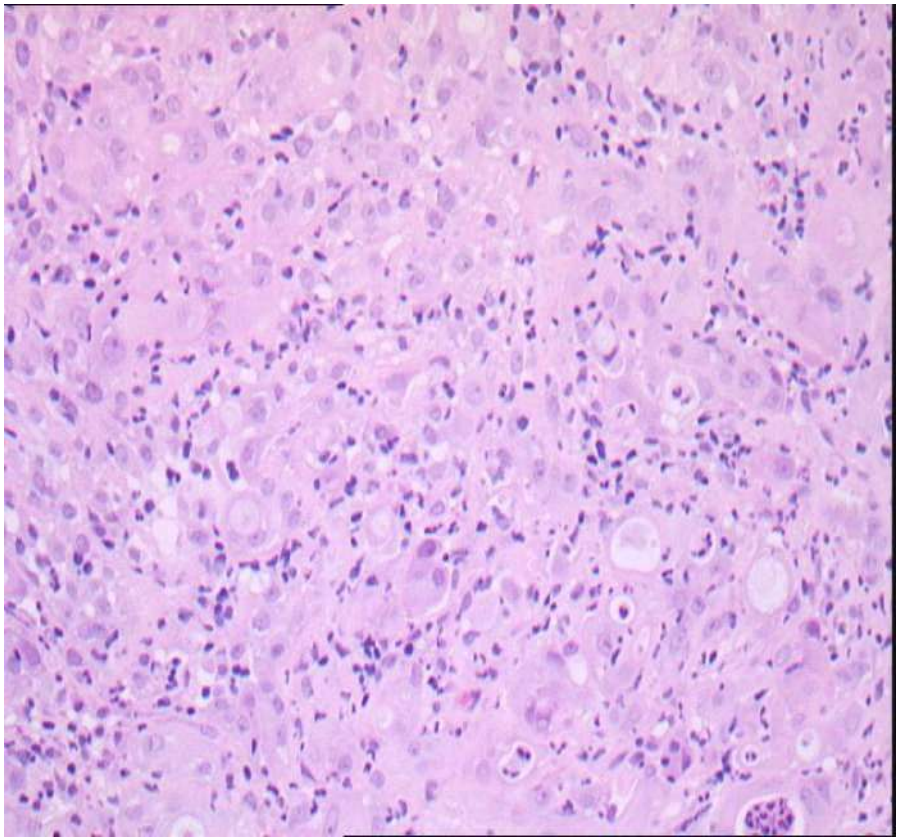

MGH CERVIX- STROMAL HYALINISATION MIMICKING CLEAR CELL CARCINOMA

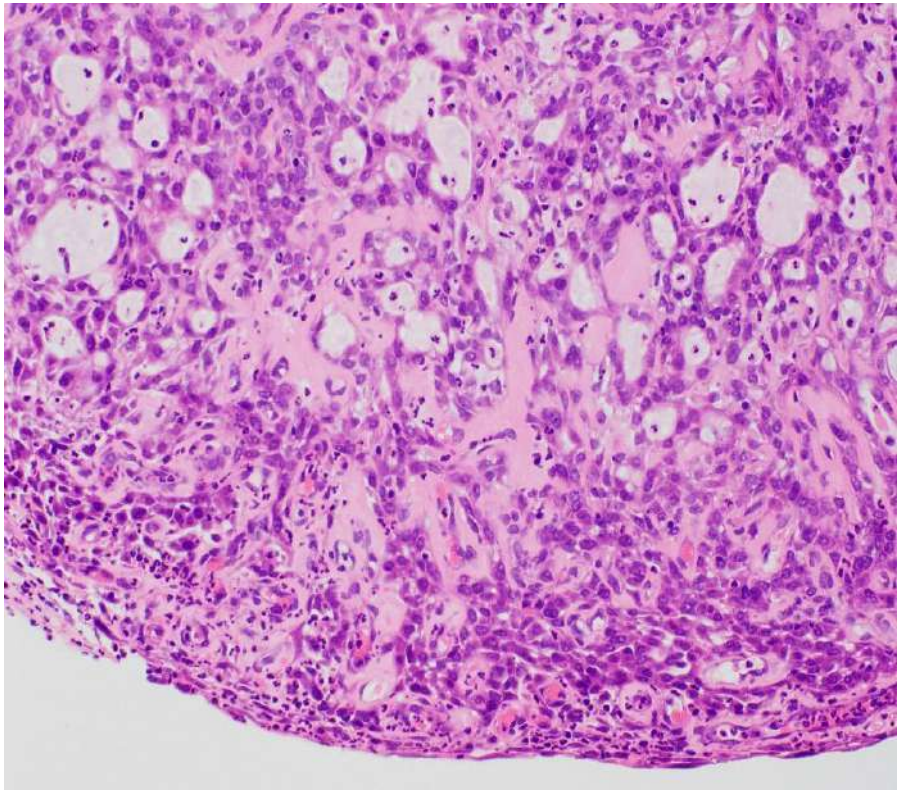

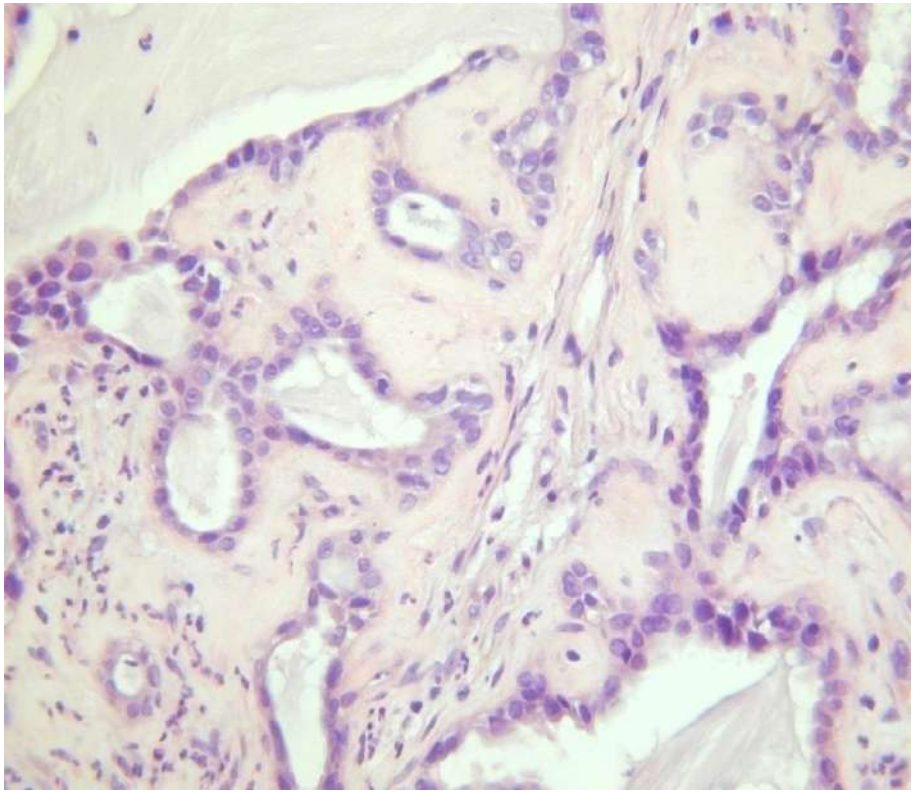

SIGNET RING CELLS

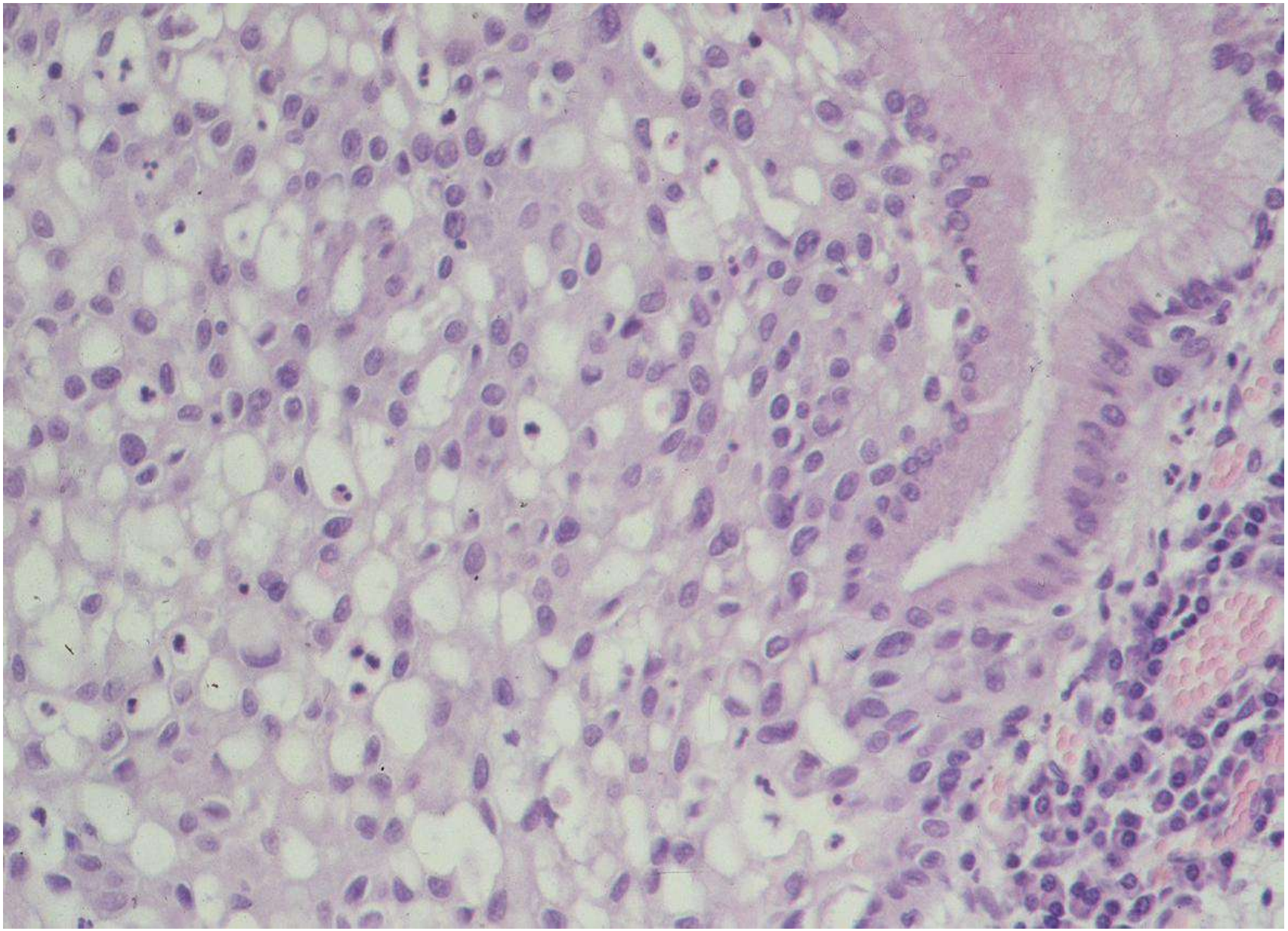

MICROGLANDULAR VARIANT OF ENDOMETRIOID CARCINOMA OF ENDOMETRIUM MIMICKING CERVICAL MGH

- usually on surface of endometrioid or mucinous adenocarcinoma but may be more widespread
- especially likely to be sampled on biopsy
- microglandular architecture
- may closely mimic cervical microglandular hyperplasia
- IMMUNOHISTOCHEMISTRY OF LIMITED VALUE- MANY STUDIES SHOW TOO MUCH OVERLAP (in my opinion, most useful marker is **p16**)
- PMID 35347751)- **p63** may also be of value (many more p63 positive cells in MGH, often with linear arrangement)

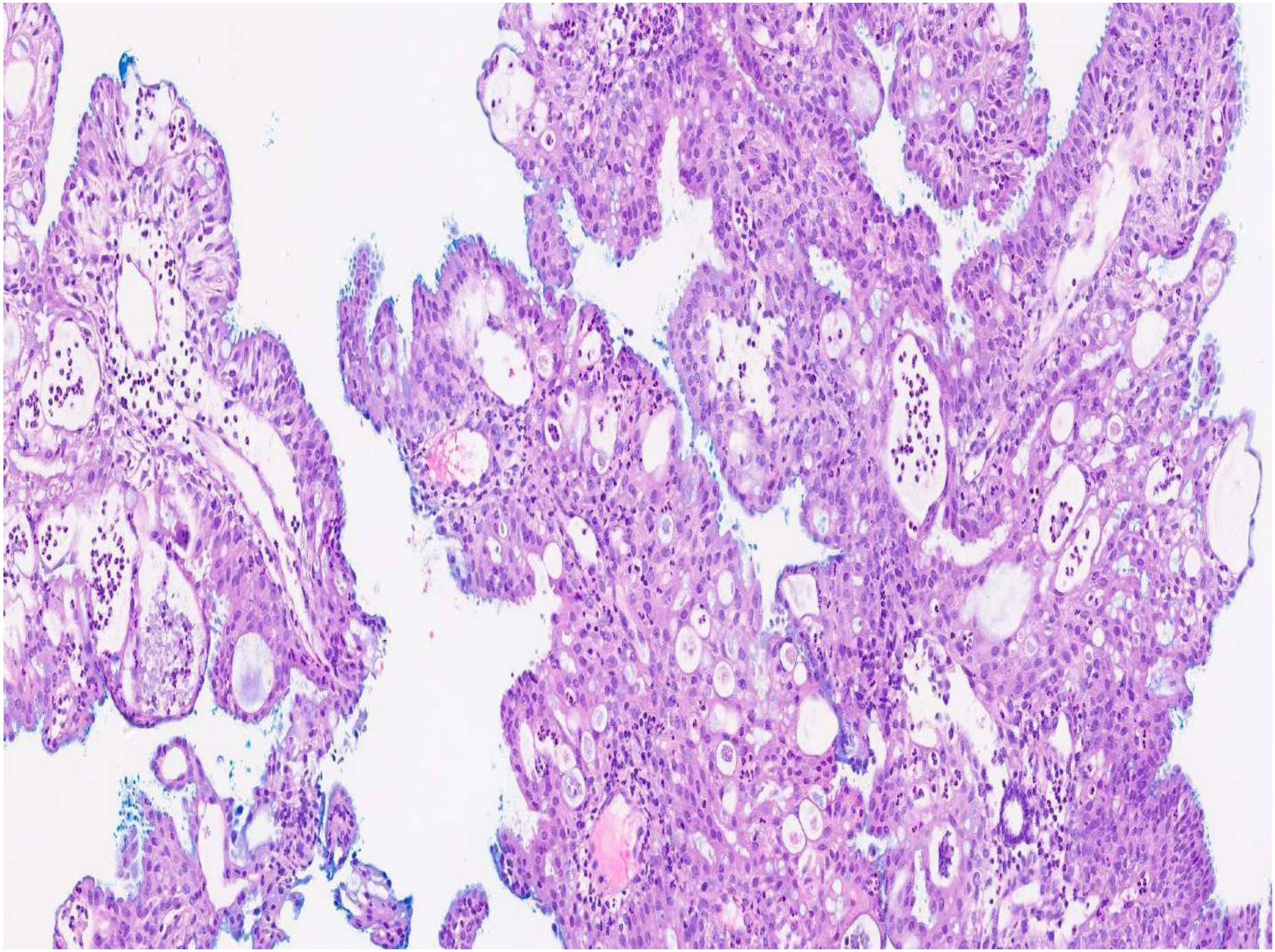

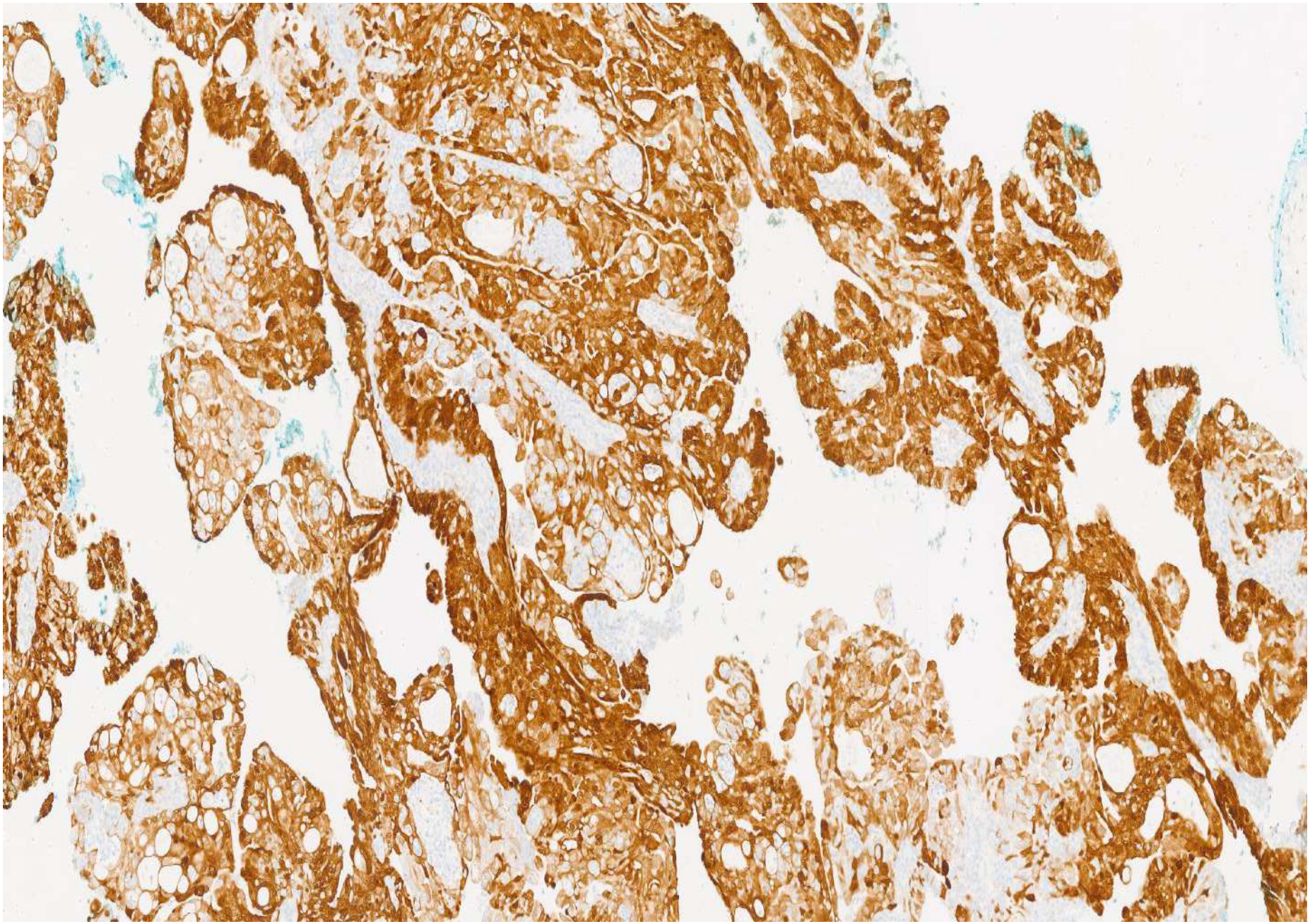

p16

PMID 35347751

Histopathology

Histopathology 2022, 80, 1102–1111. DOI: 10.1111/his.14655

Utility of p63 and PTEN staining in distinguishing cervical microglandular hyperplasia from endometrial endometrioid carcinoma with microglandular/mucinous features

Batoul A. Aoun[1] & Stephanie L. Skala[1,2]

[1]*Department of Pathology and* [2]*Rogel Cancer Center, University of Michigan, Ann Arbor, MI, USA*

Date of submission 1 February 2022
Accepted for publication 25 March 2022
Published online *Article Accepted* 28 March 2022

p63- MGH

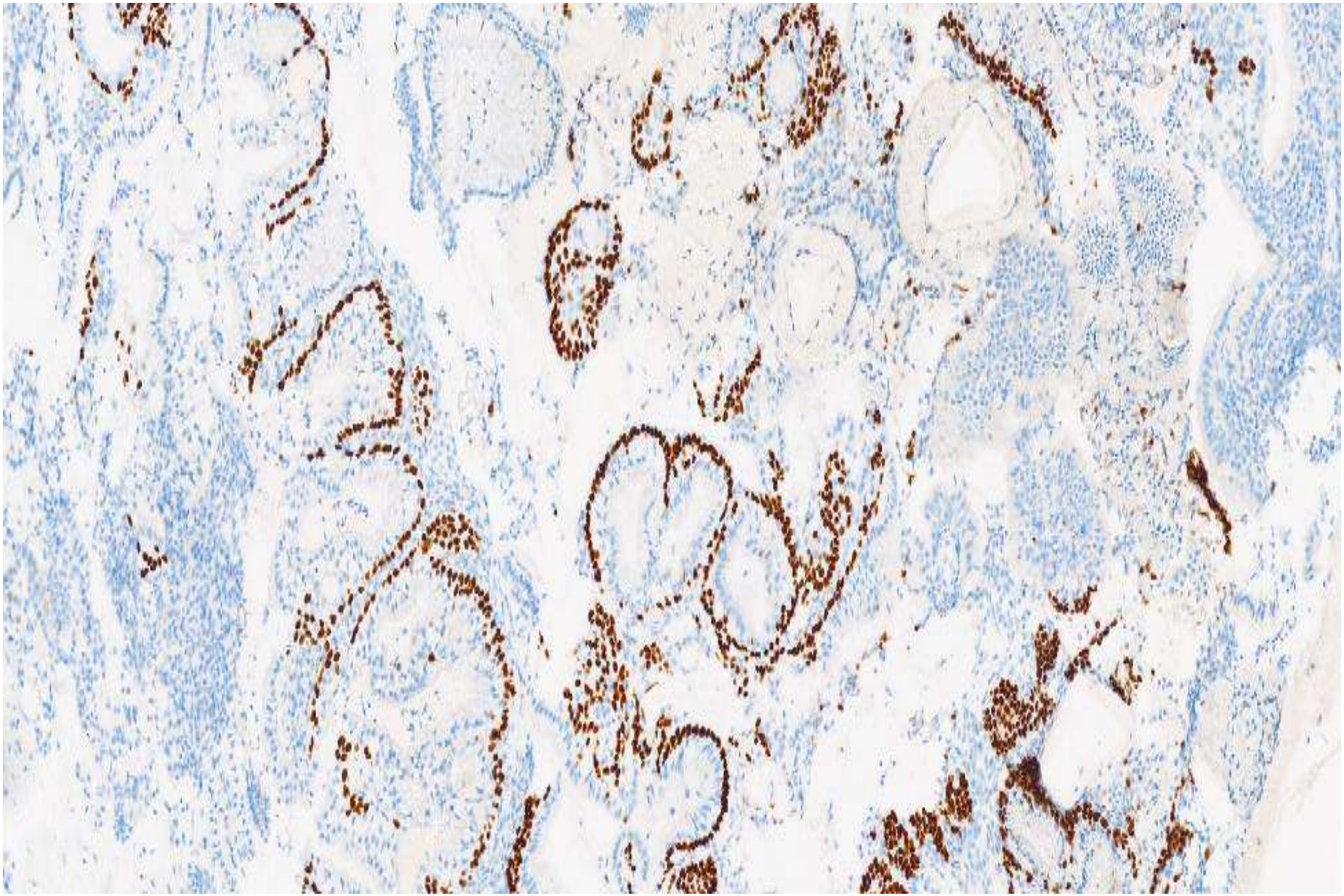

BUT DOESN'T ALWAYS WORK; p63 in ENDOMETRIOID CA WITH MICROGLANDULAR AREAS

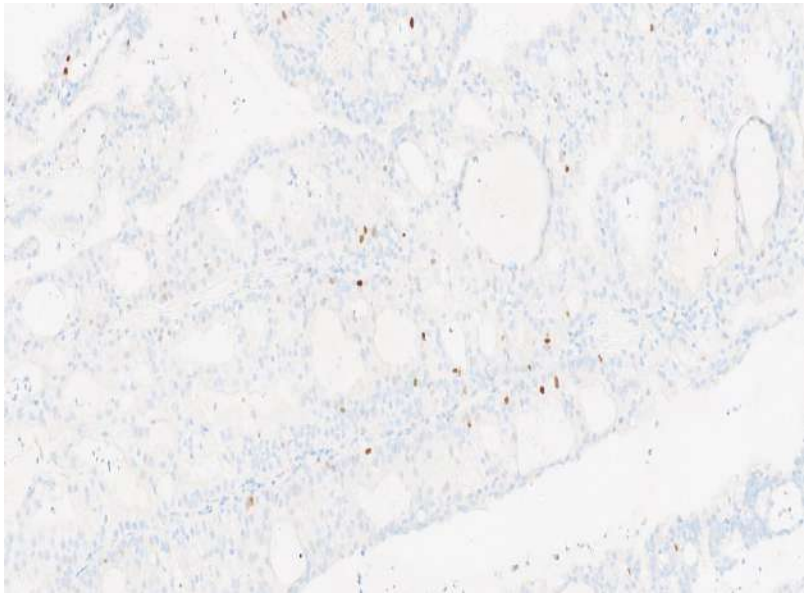

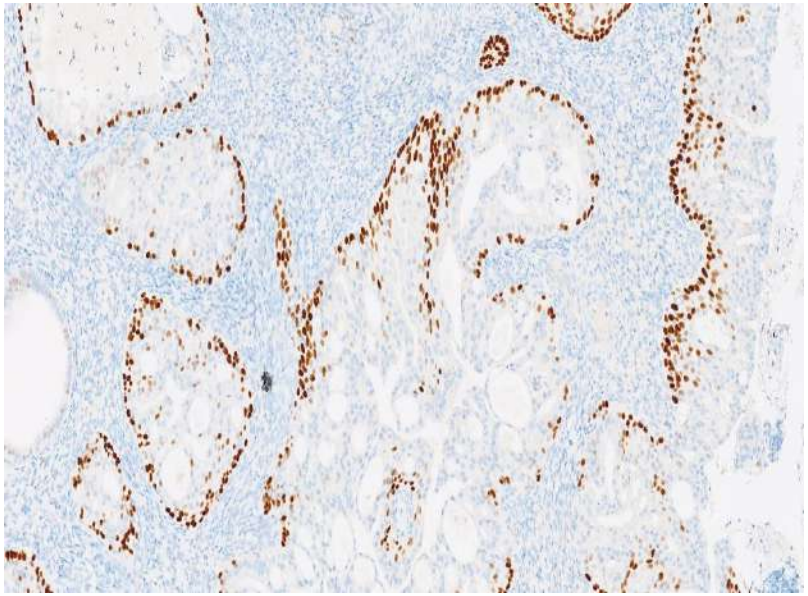

CASE 3 (A)

- F50
- LLETZ for CIN III

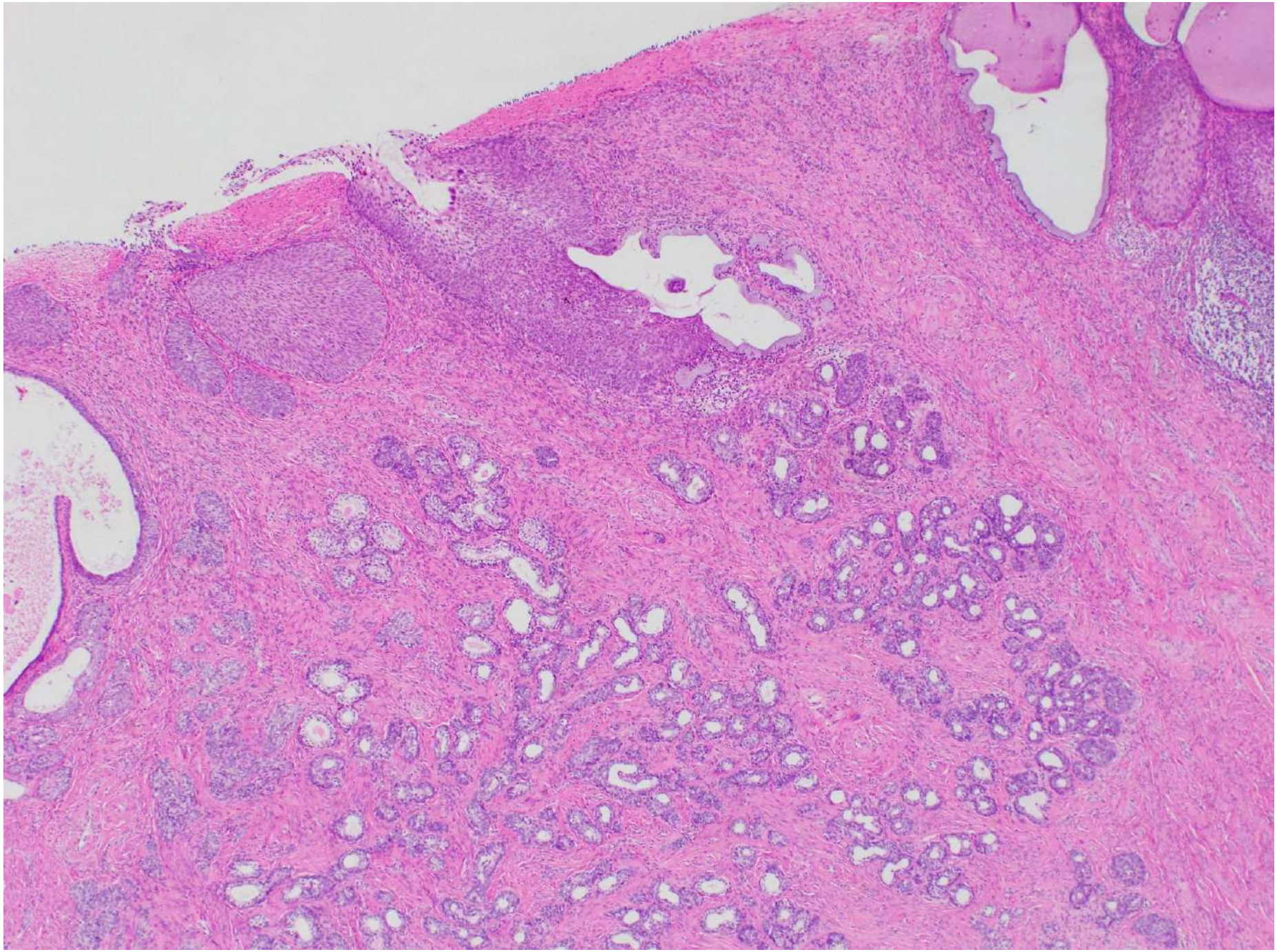

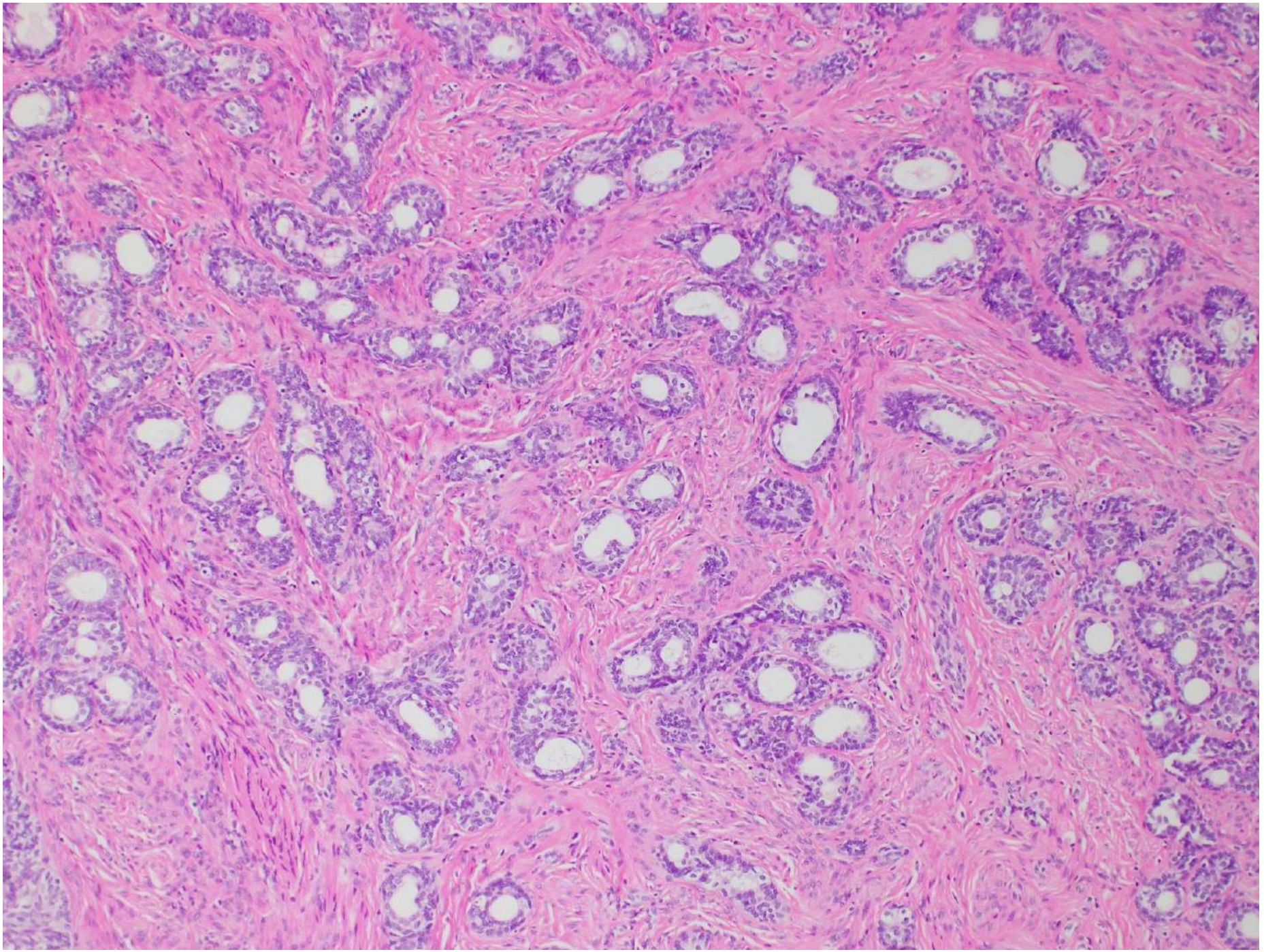

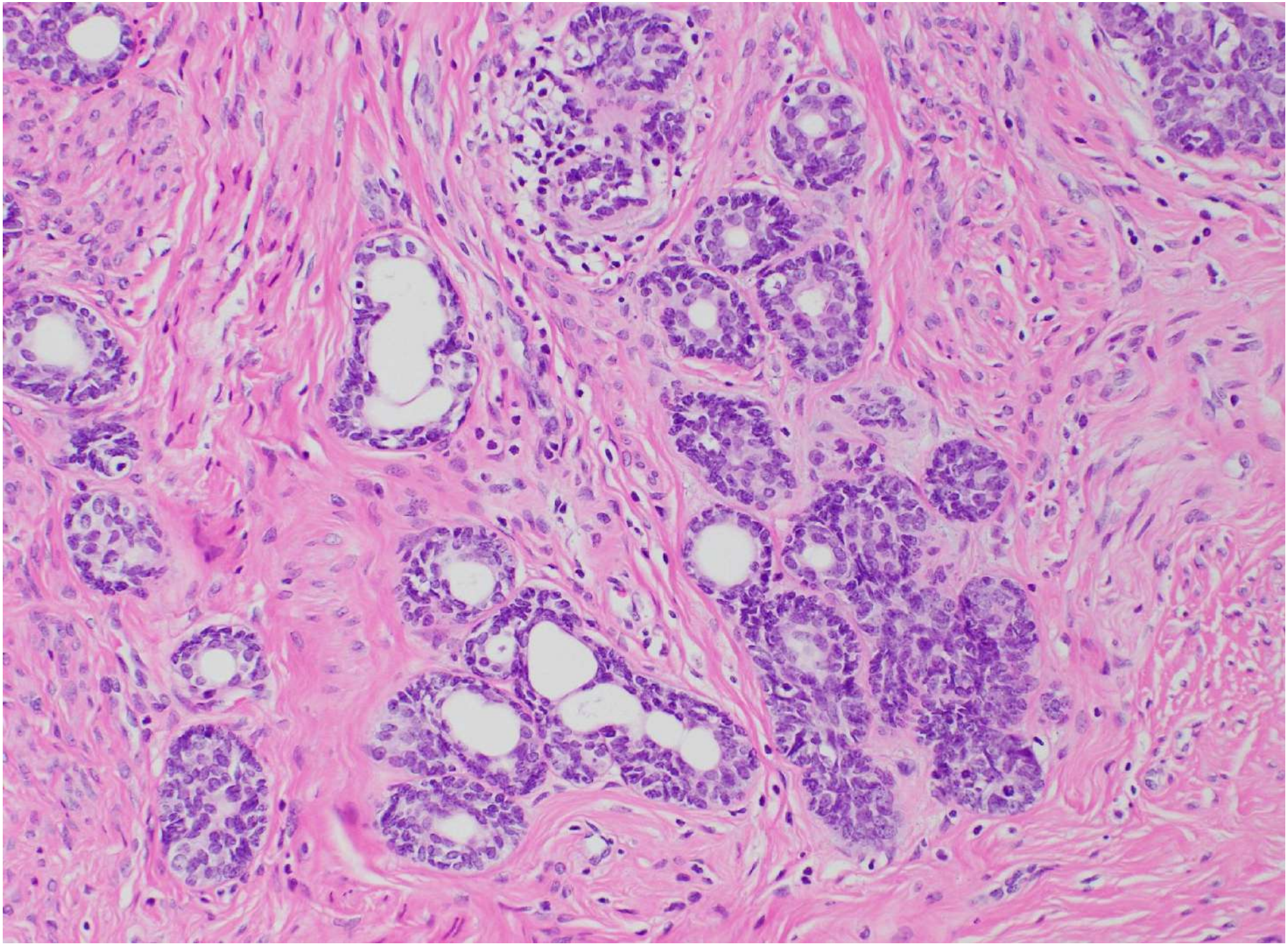

DIAGNOSIS: CERVIX ADENOID BASAL CARCINOMA

- Rare (< 1% of cervical malignancies)
- Associated with high-risk HPV (especially HPV 16)
- Often associated with HSIL or other carcinoma (especially squamous carcinoma); report as mixed carcinoma
- Usually an incidental finding in excision specimen for HSIL
- Indolent and has never been shown to metastasise in “pure” form; alternative names proposed “adenoid basal epithelioma” or “low-grade adenoid basal tumour”
- Term adenoid basal carcinoma retained in WHO 2020 and WHO 2025
- Management- in pure form does not require radical surgery or adjuvant treatment but make sure fully excised to exclude another component; need to make clinician aware of this

IMMUNOHISTOCHEMISTRY

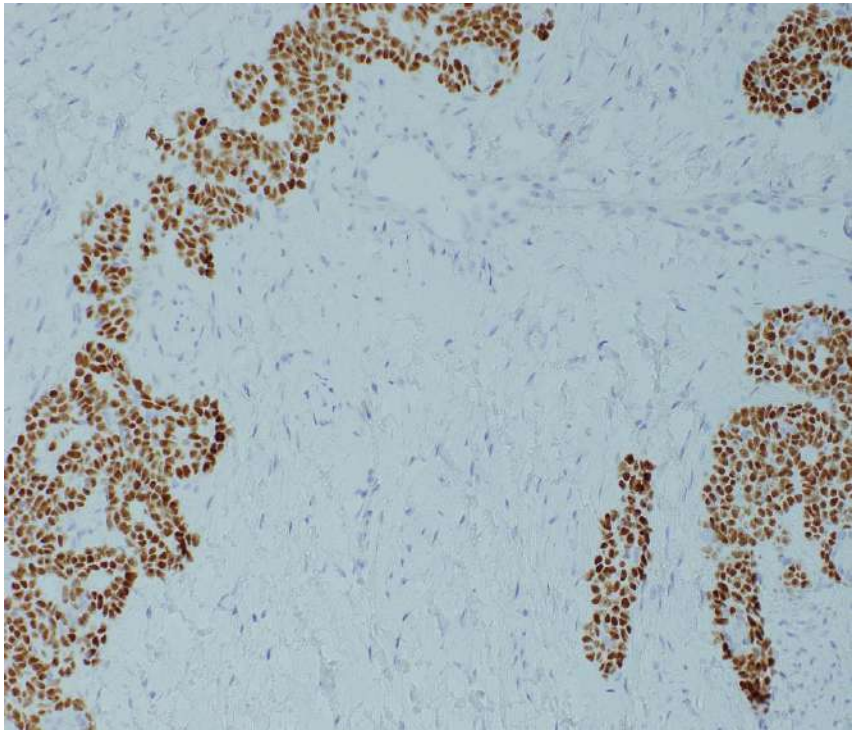

p63

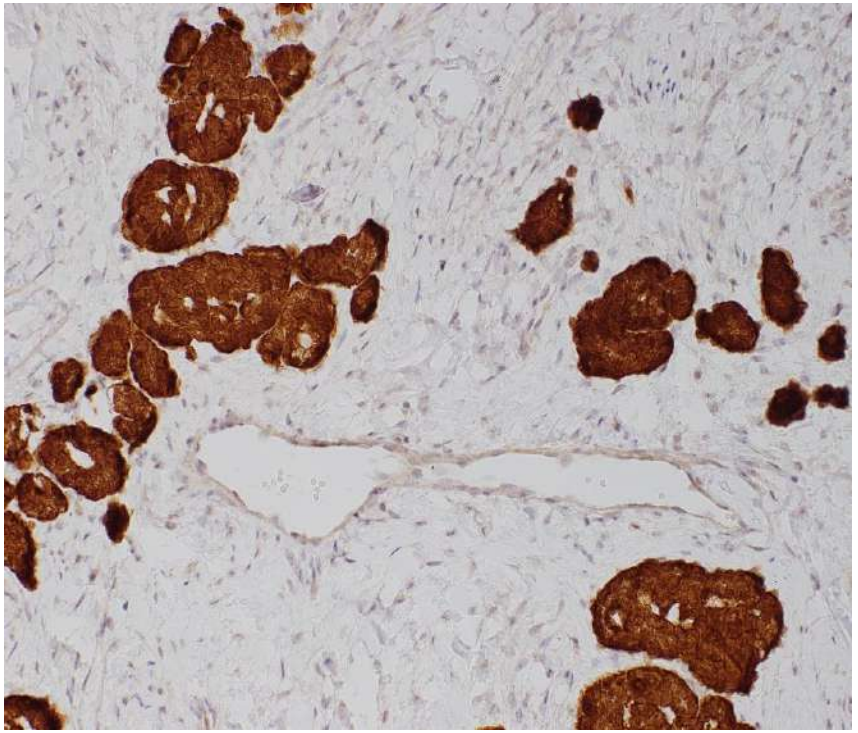

p16

PMID 33021555

International Journal of Gynecological Pathology
00:1–8, Lippincott Williams & Wilkins, Baltimore
Copyright © 2020 by the International Society of Gynecological Pathologists

Original Article

Skene's Gland Derivatives in the Female Genital Tract and Cervical Adenoid Basal Carcinoma are Consistently Positive With Prostatic Marker NKX3.1

Rand Hawari, F.R.C.Path., Larissa Fernandes, F.I.B.M.S., Kay J. Park, M.D., and W. Glenn McCluggage, F.R.C.Path.

PATHOLOGY : PMID 33032811

ANATOMICAL PATHOLOGY

NKX3.1 expression in cervical 'adenoid basal cell carcinoma': another gynaecological lesion with prostatic differentiation?

COLIN J. R. STEWART[1,2], JOANNE MOSES[3]

[1]Department of Pathology, King Edward Memorial Hospital, Perth, WA, Australia; [2]School of Women's and Infants' Health, University of Western Australia, WA, Australia; [3]LabPlus, Auckland City Hospital, Auckland, New Zealand

CERVIX ADENOID BASAL CARCINOMA-NKX3.1

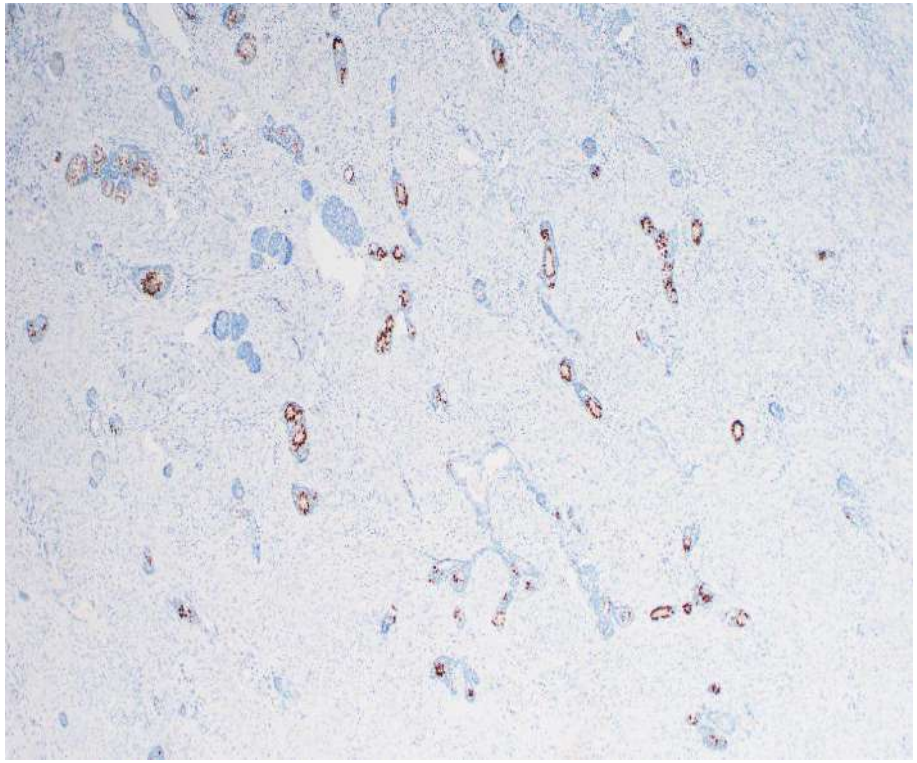

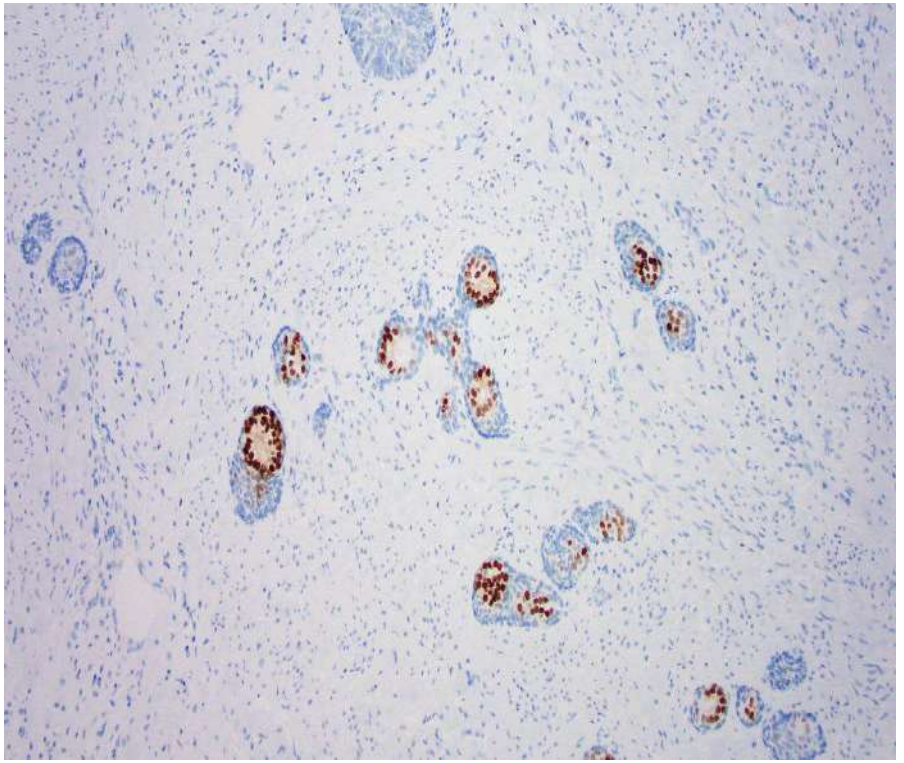

CERVIX ADENOID BASAL CARCINOMA

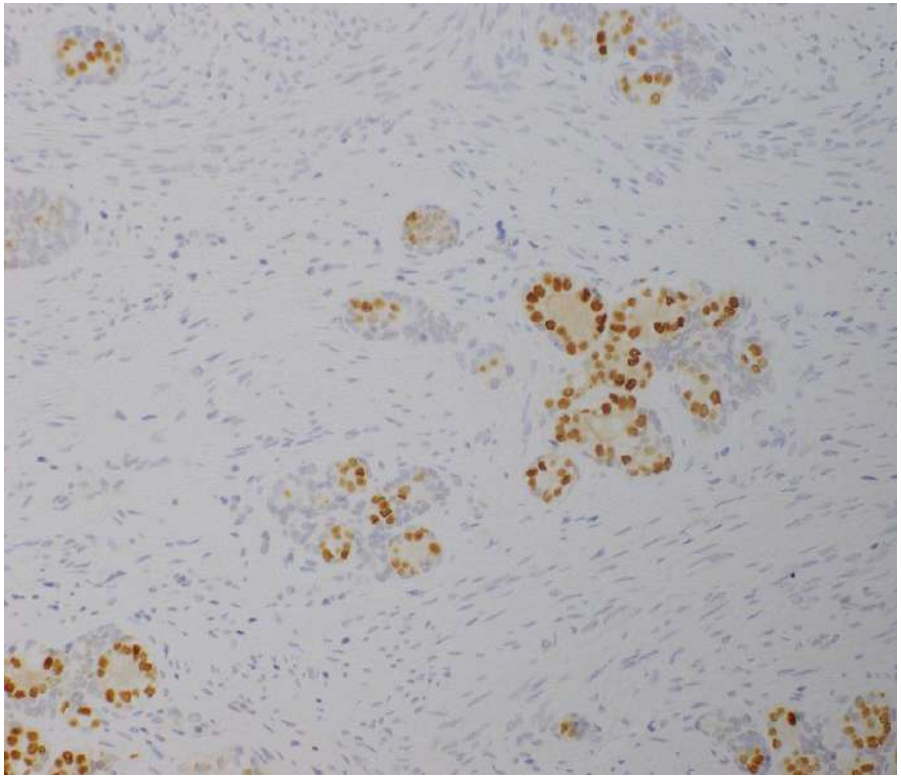

NKX3.1

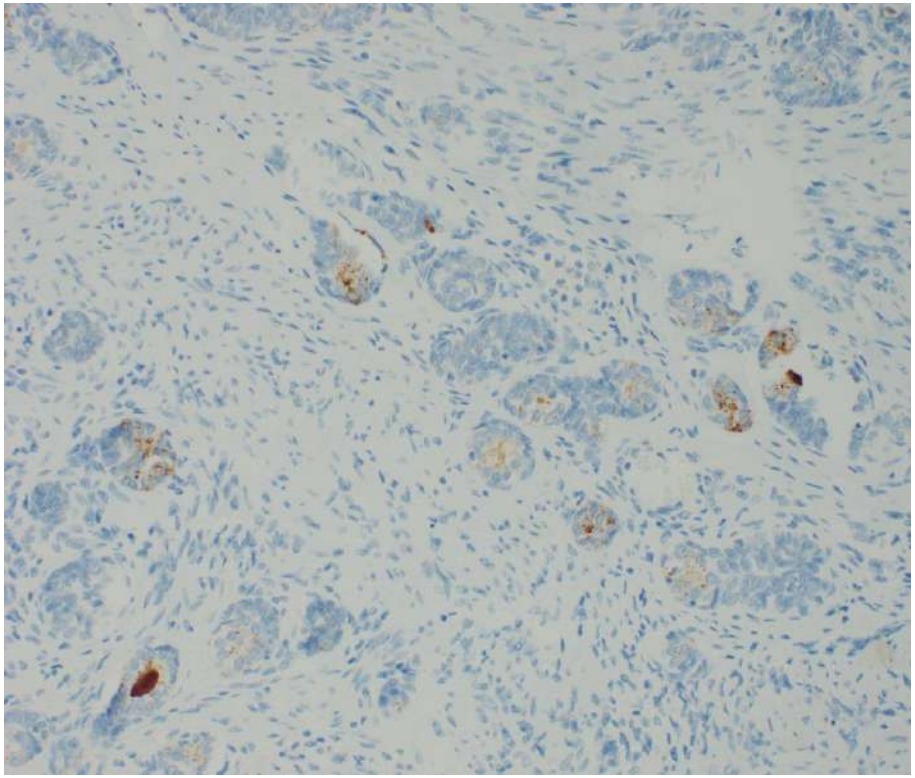

PSAP

PMID 33021555

- Cervical ectopic prostatic tissue (all 11 cases NKX3.1 positive)
- Vaginal tubulosquamous polyp (all 3 cases NKX3.1 positive)
- Cervical adenoid basal carcinoma (all 6 cases NKX3.1 positive); 3 of 5 cases positive (focal) with PSAP (all PSA negative)
- NKX3.1 is a better marker of ectopic prostatic tissue and tubulosquamous polyp than traditional prostatic markers which may be negative

? IS ADENOID BASAL CARCINOMA RELATED TO ECTOPIC PROSTATIC TISSUE- PROS

- “similar” morphology (bland morphology, no stromal response)
- NKX3.1 and PSAP often positive
- Coexistence in occasional cases (1 case in our study)
- Could adenoid basal carcinoma be secondary to persistent high-risk HPV infection of ectopic prostatic tissue- PMID 33021555

? IS ADENOID BASAL CARCINOMA RELATED TO ECTOPIC PROSTATIC TISSUE- CONS

- Some “differences” in morphology
- Ectopic prostatic tissue usually at ectocervix; adenoid basal carcinoma usually at transformation zone
- Adenoid basal carcinoma is high-risk HPV-associated lesion

CASE 3 (B)

- F50
- LLETZ for CIN III

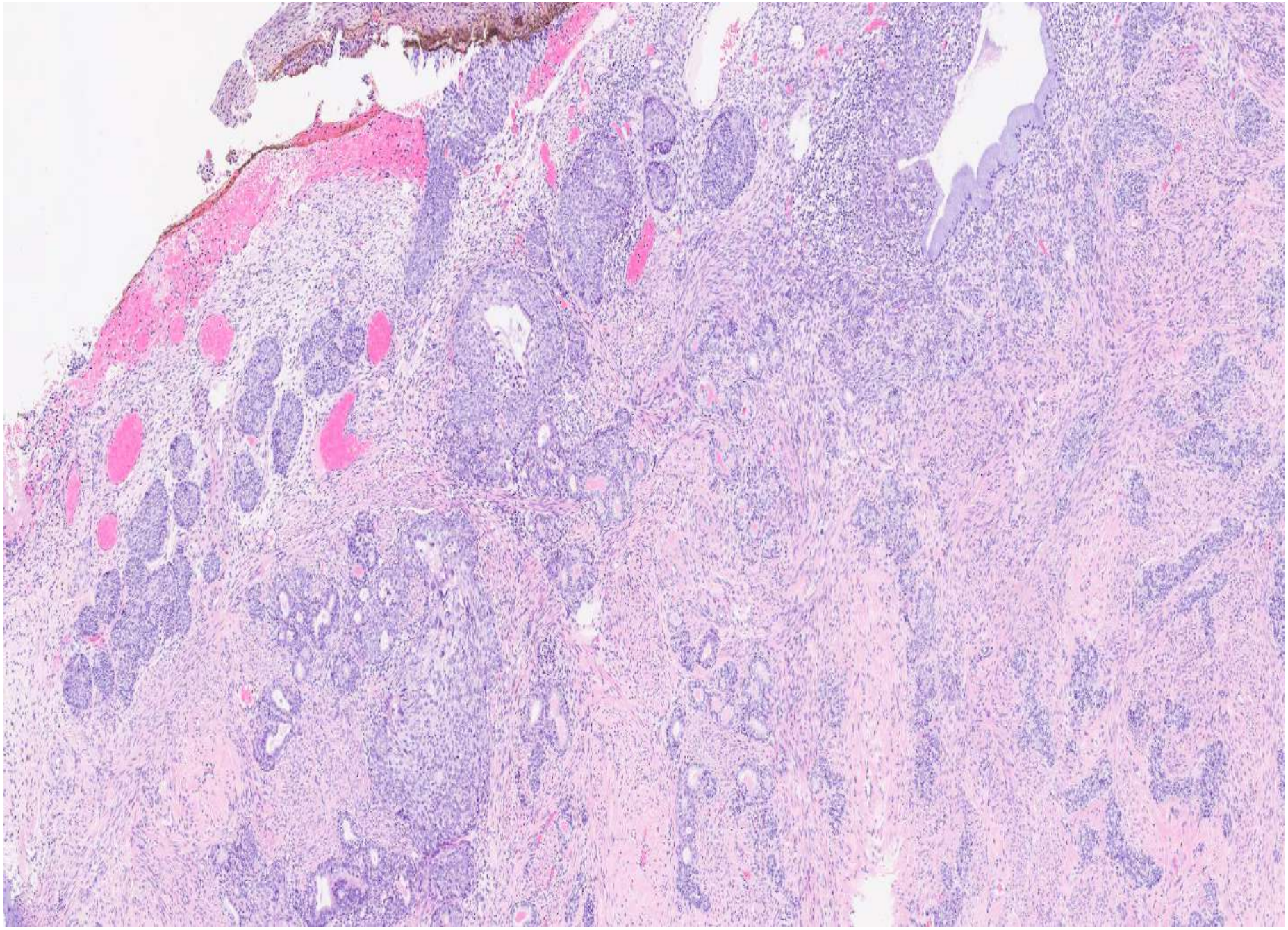

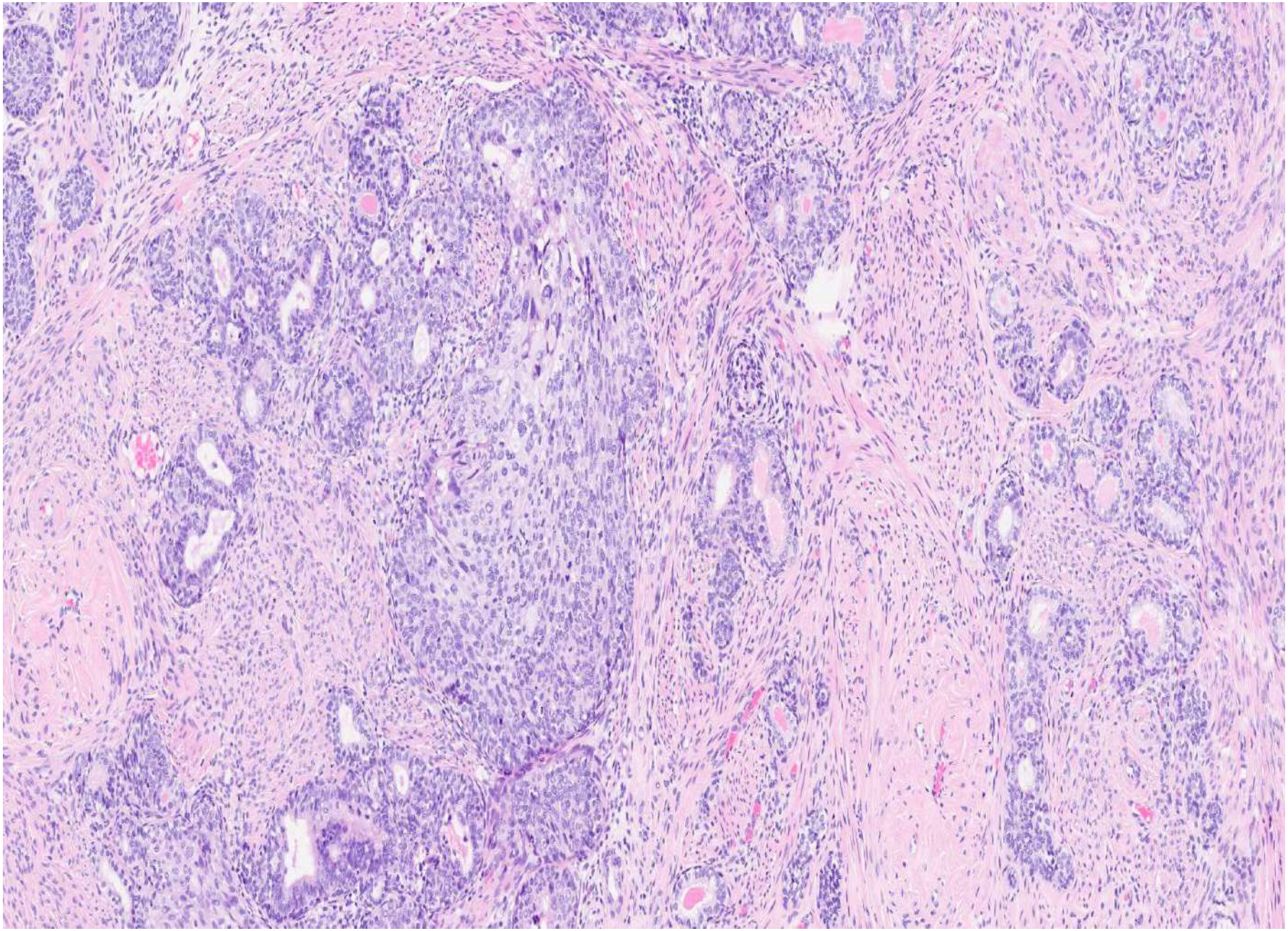

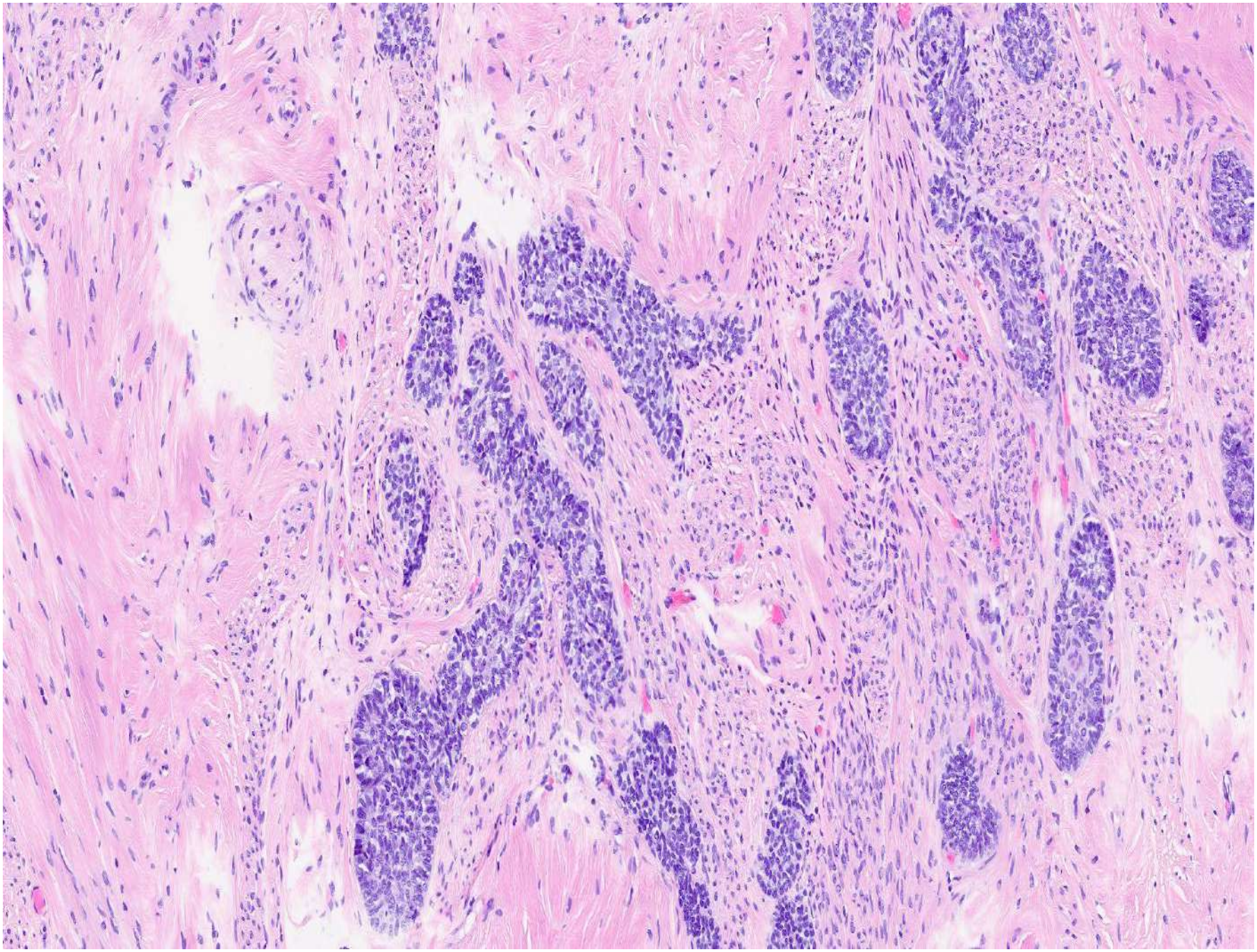

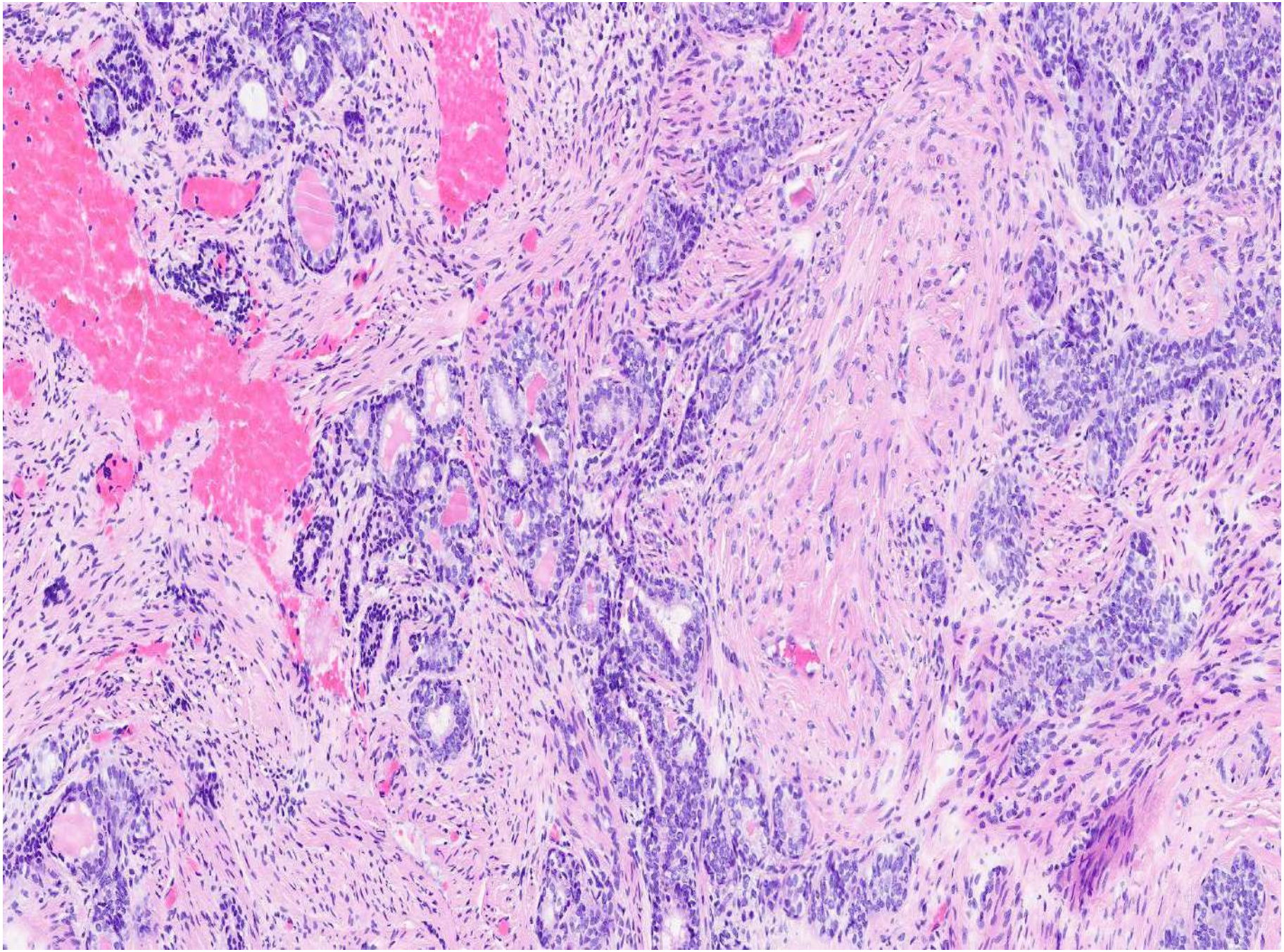

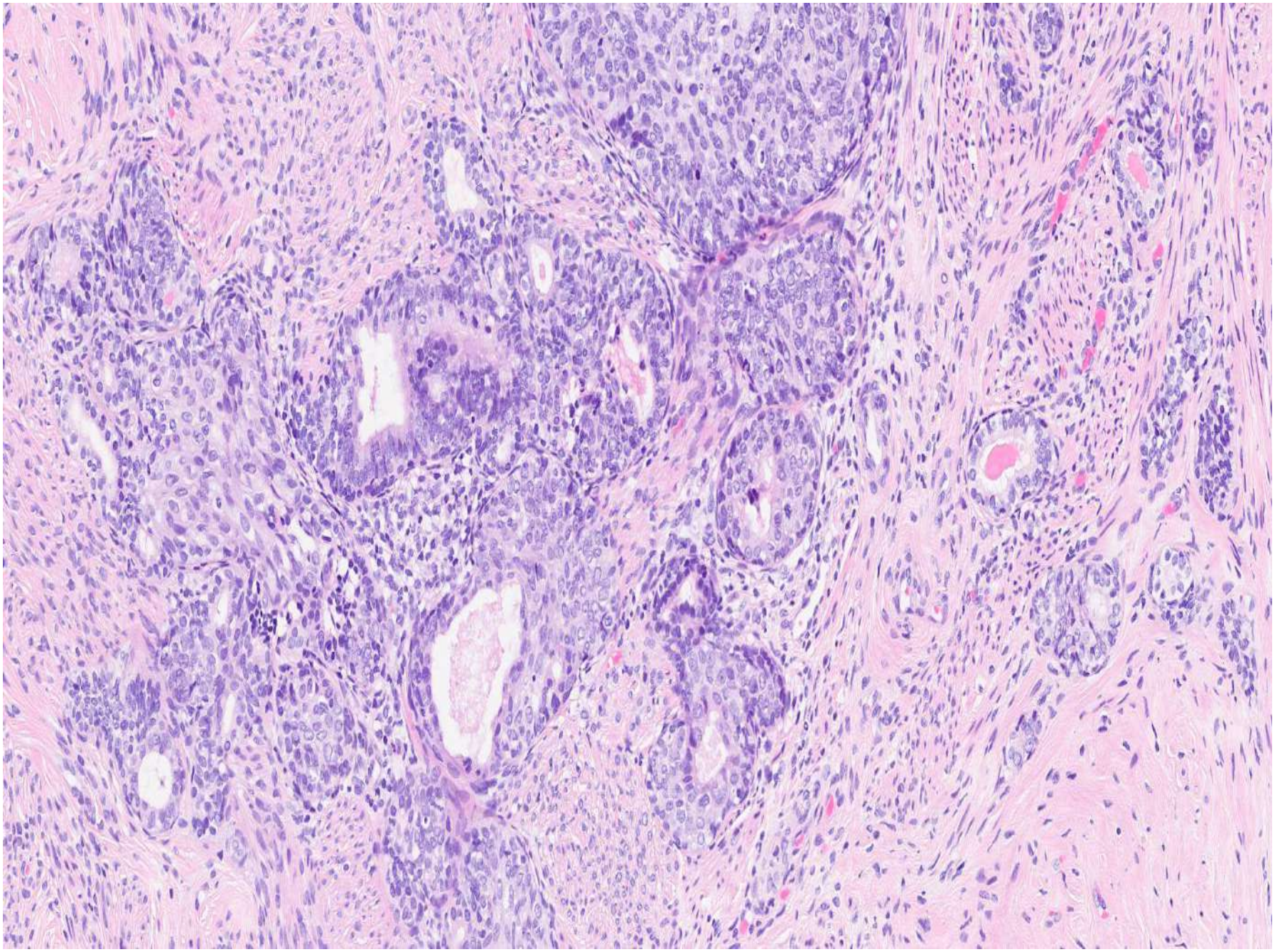

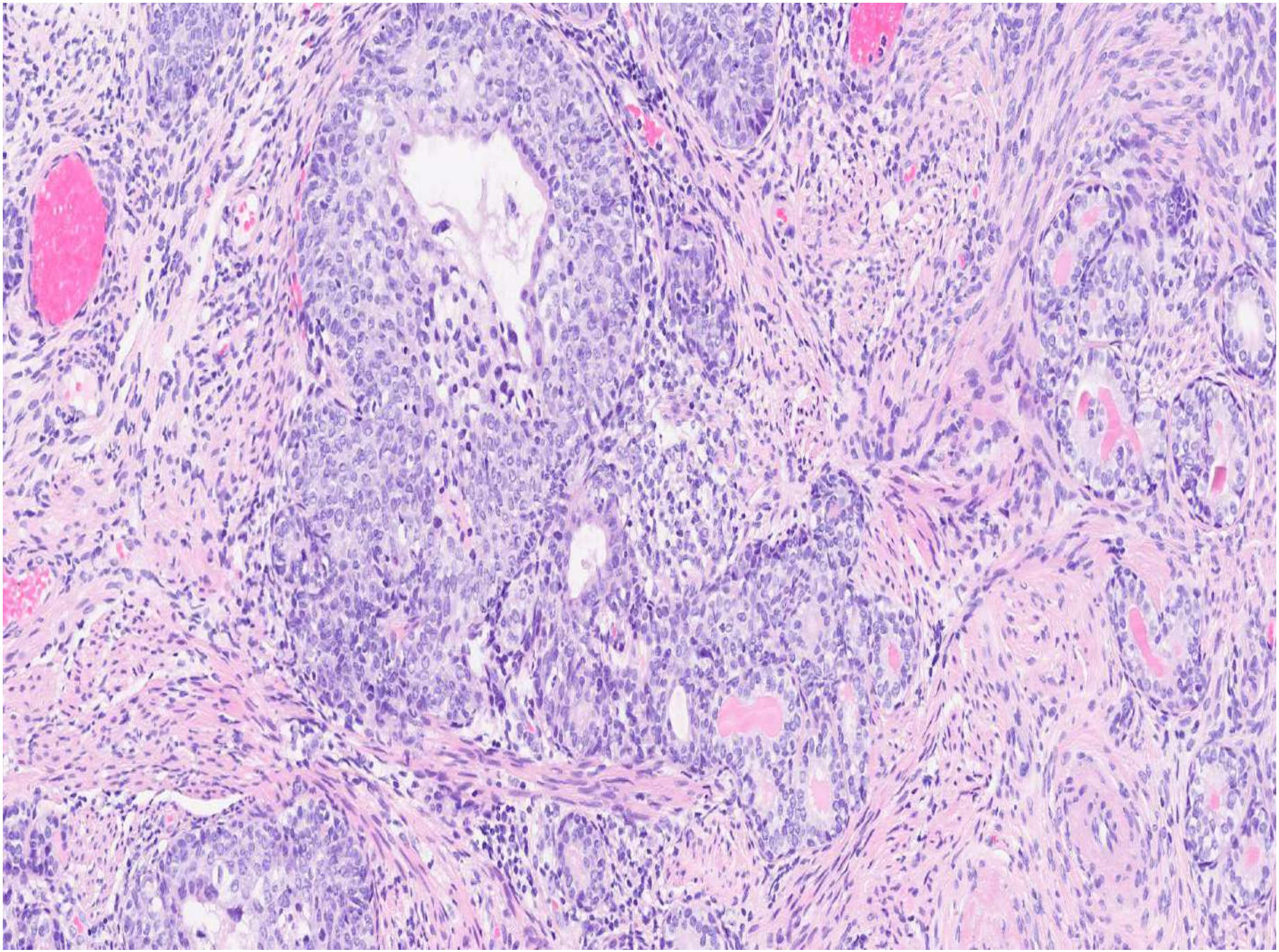

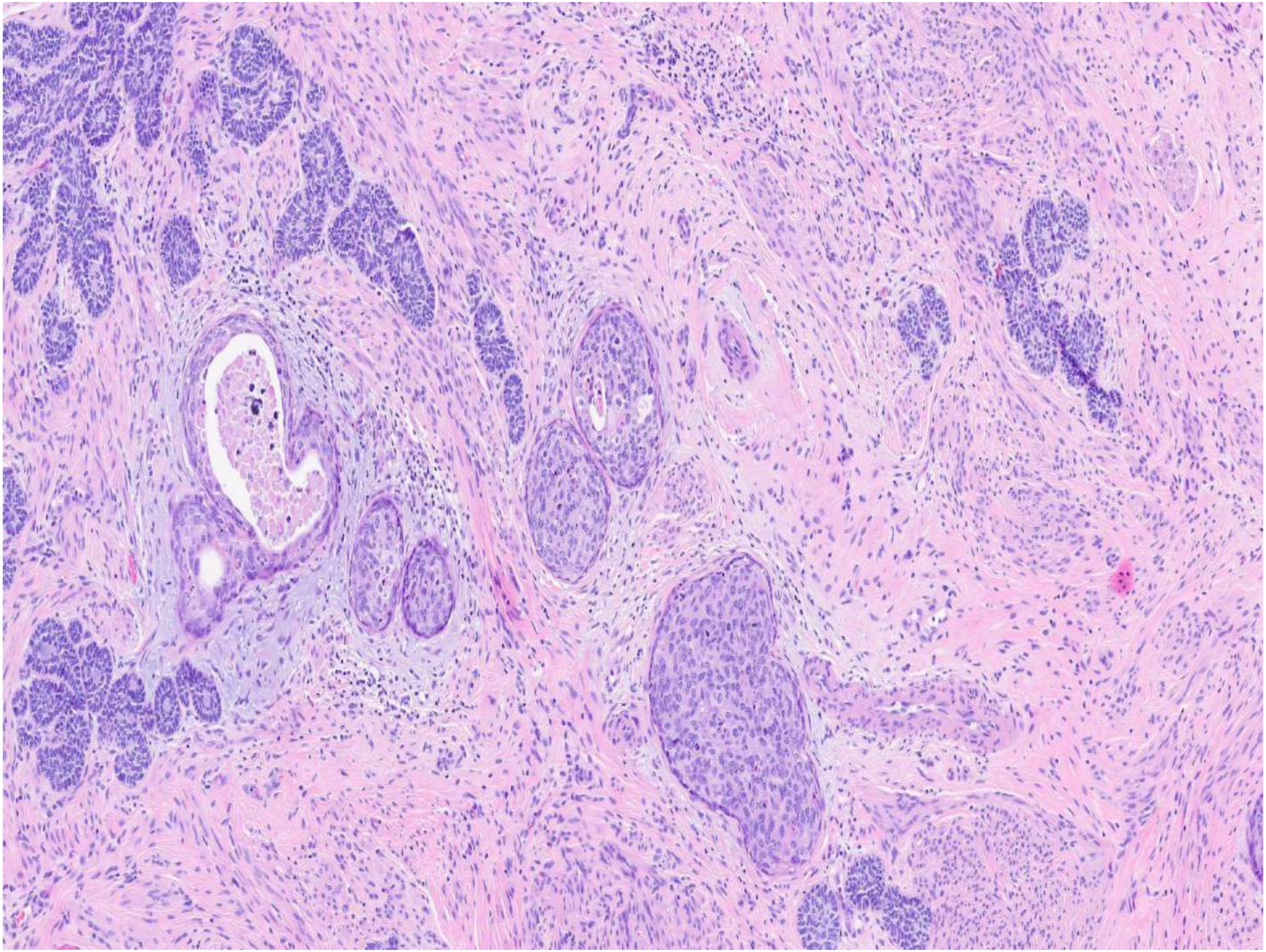

p16

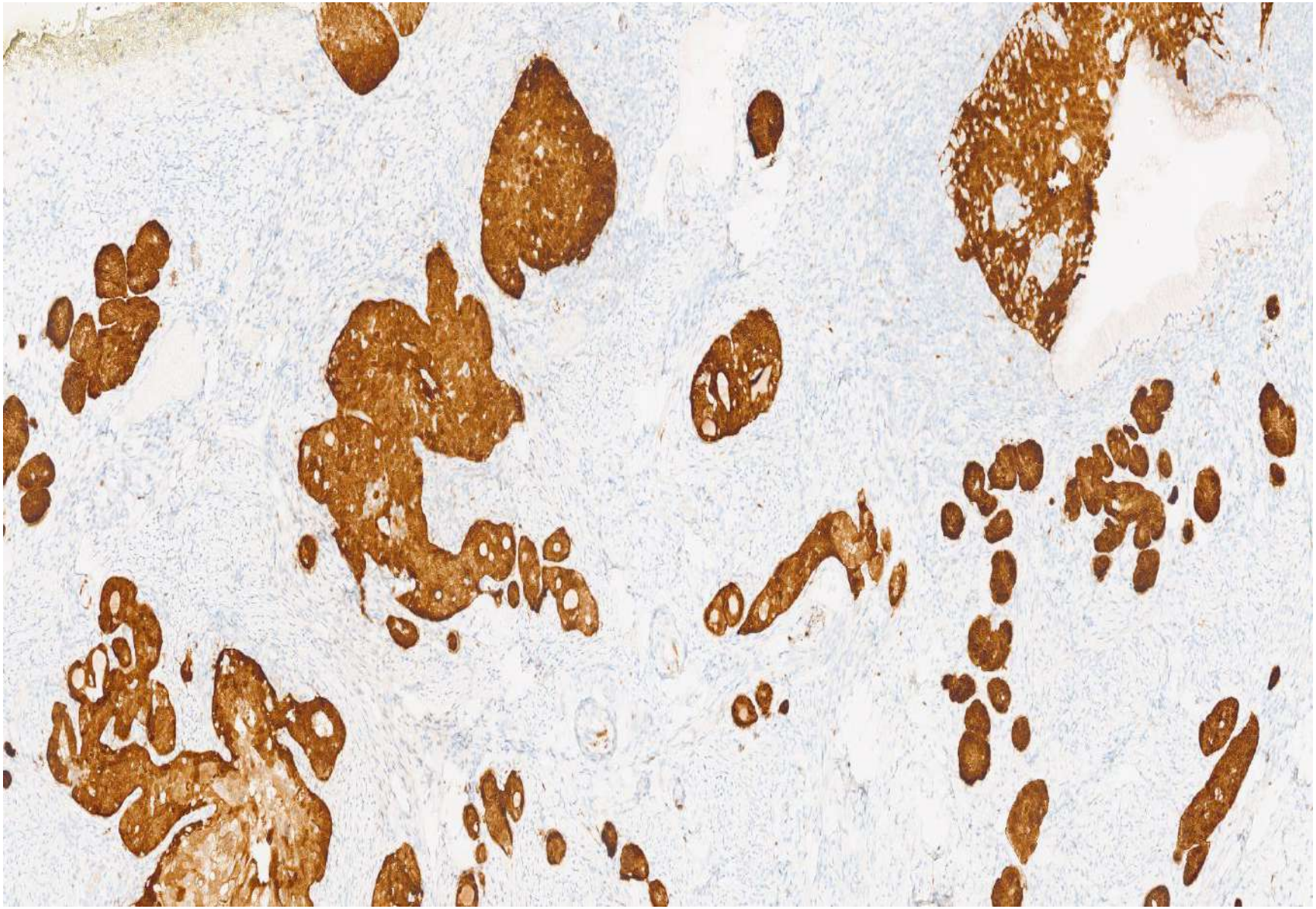

NKX3.1

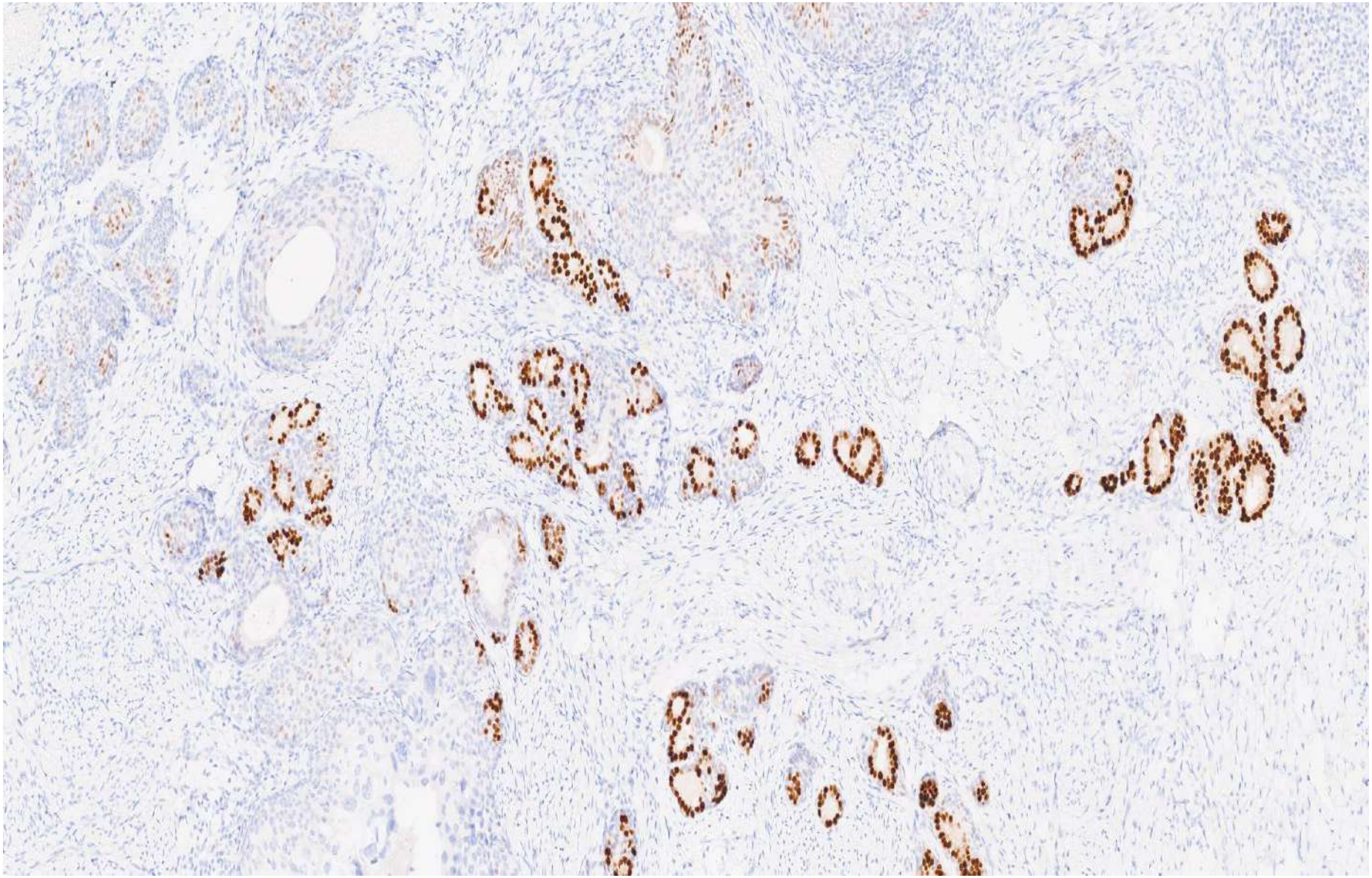

MIB1

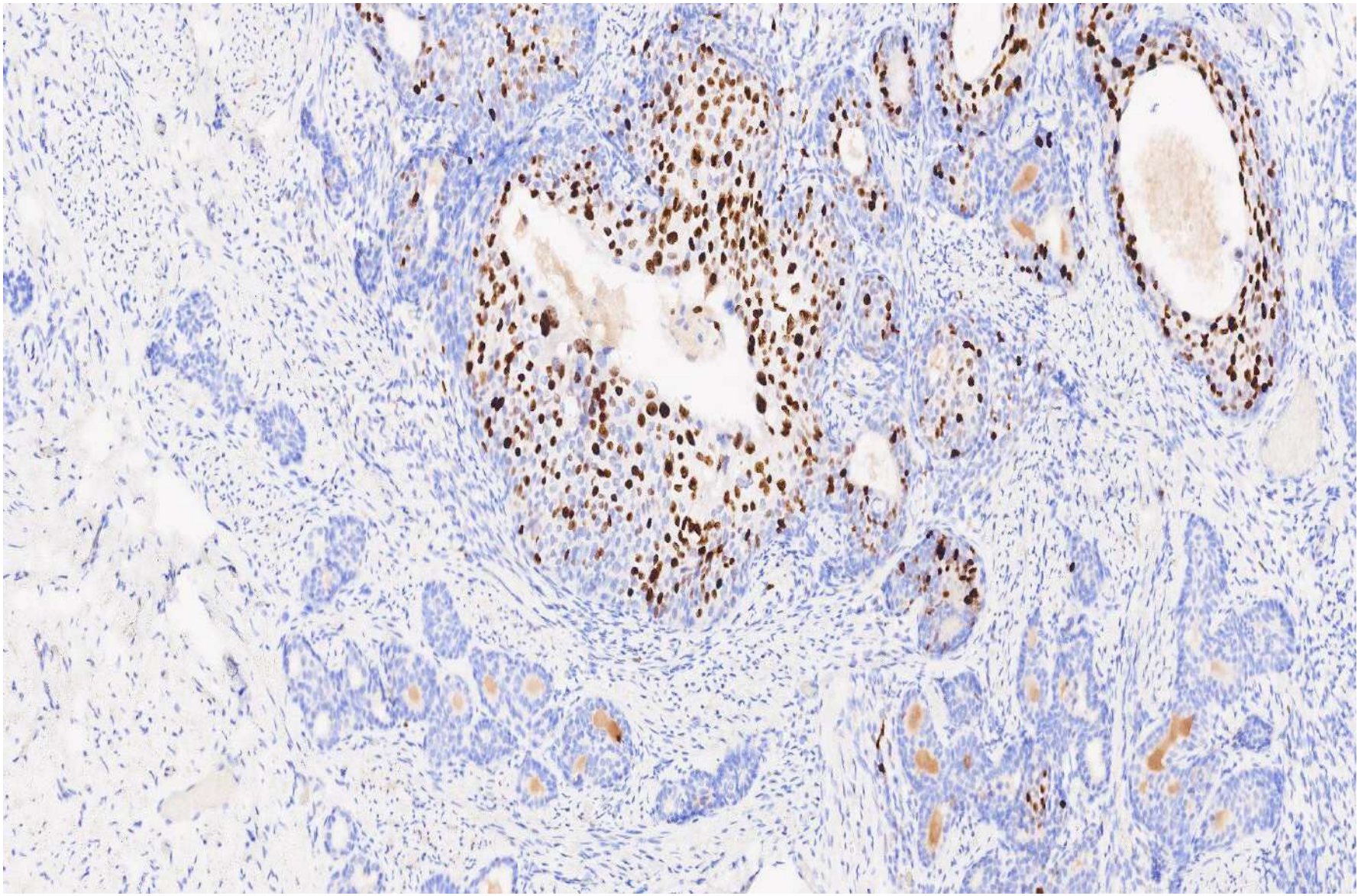

PSAP

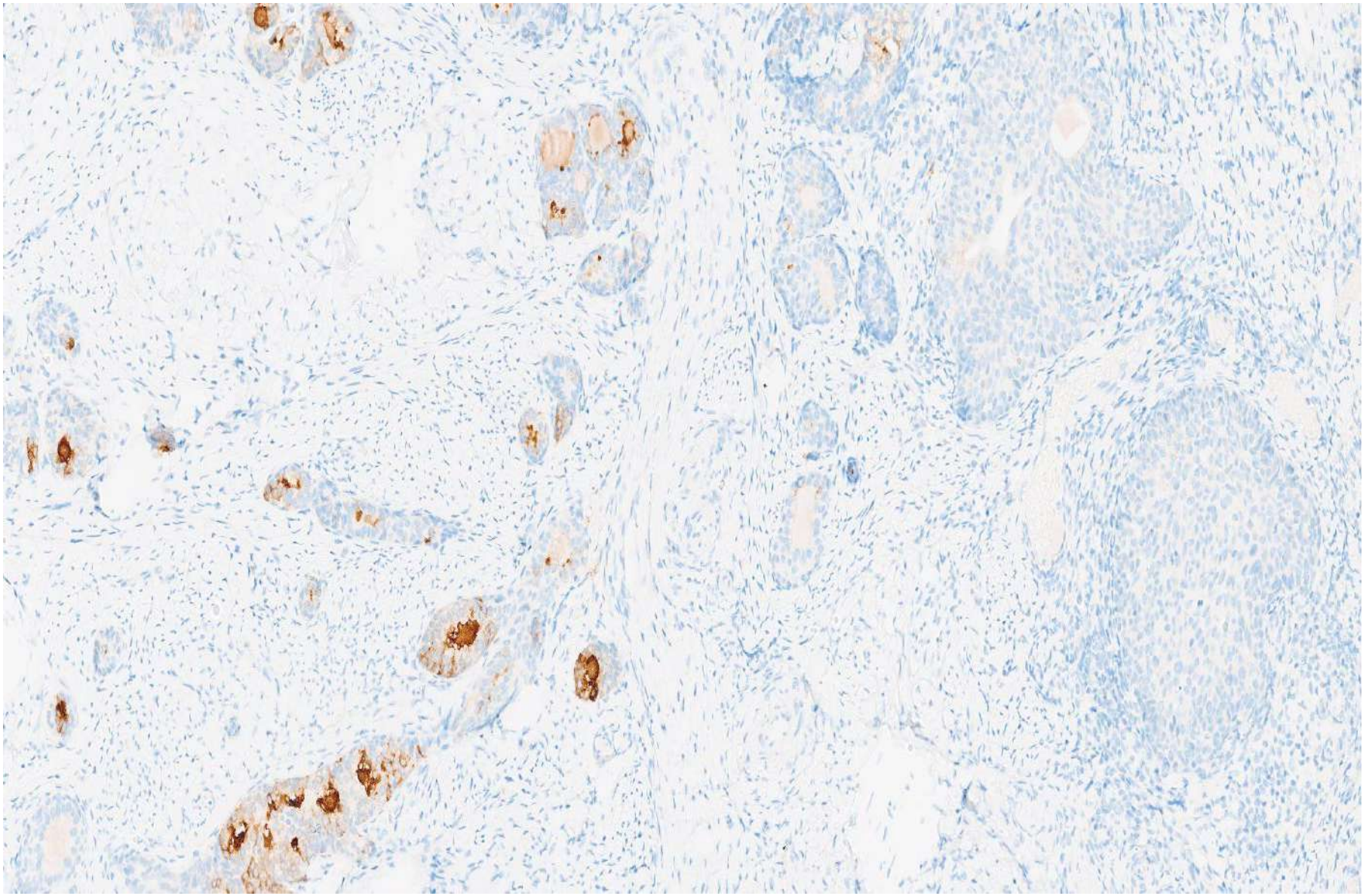

DIAGNOSIS: PMID 37991261

ORIGINAL ARTICLE

Cervical Adenoid Basal Carcinoma With High-grade Squamous Component

True Mixed Carcinoma or Colonization of Adenoid Basal Carcinoma by High-grade Squamous Intraepithelial Lesion?

Karen L. Talia, MBBS(Hons), FRCPA and W.Glenn McCluggage, FRCPath†*

PMID 37991261

- Adenoid basal carcinoma (ABC) often associated with HSIL and/ or SCC
- ABC and HSIL/ SCC may be clearly separate or intermingled
- Do cases where the two components are intermingled represent mixed carcinomas or involvement of ABC by HSIL
- 9 cases with an admixture of ABC and a high-grade squamous lesion
- In most cases (7 of 9), the high-grade squamous component appeared to replace and expand the nests of ABC, sometimes with a residual cuff of ABC cells
- Propose that these represent colonisation of ABC by HSIL rather than mixed carcinomas; these cases were all small (IA1, IA2, IB1) and confined to the cervix with unremarkable follow-up
- Other cases represented true mixed carcinomas; 1 of 2 cases was advanced stage at diagnosis and the other was IB1
- May have management implications
- MAY BE MISDIAGNOSED AS MIXED SCC AND ADENOID BASAL CARCINOMA

TRUE MIXED ABC AND SCC

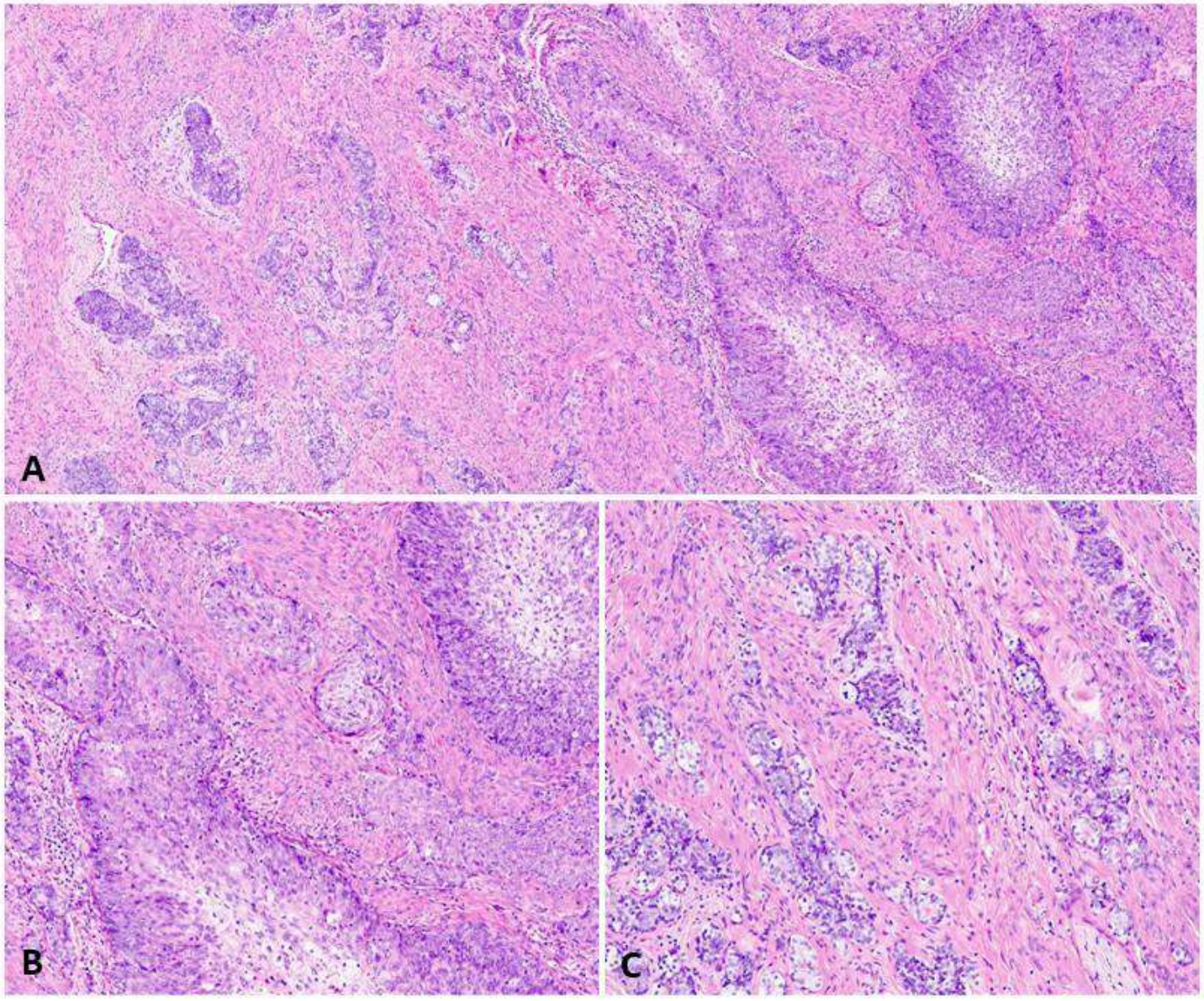

ADENOID BASAL HYPERPLASIA

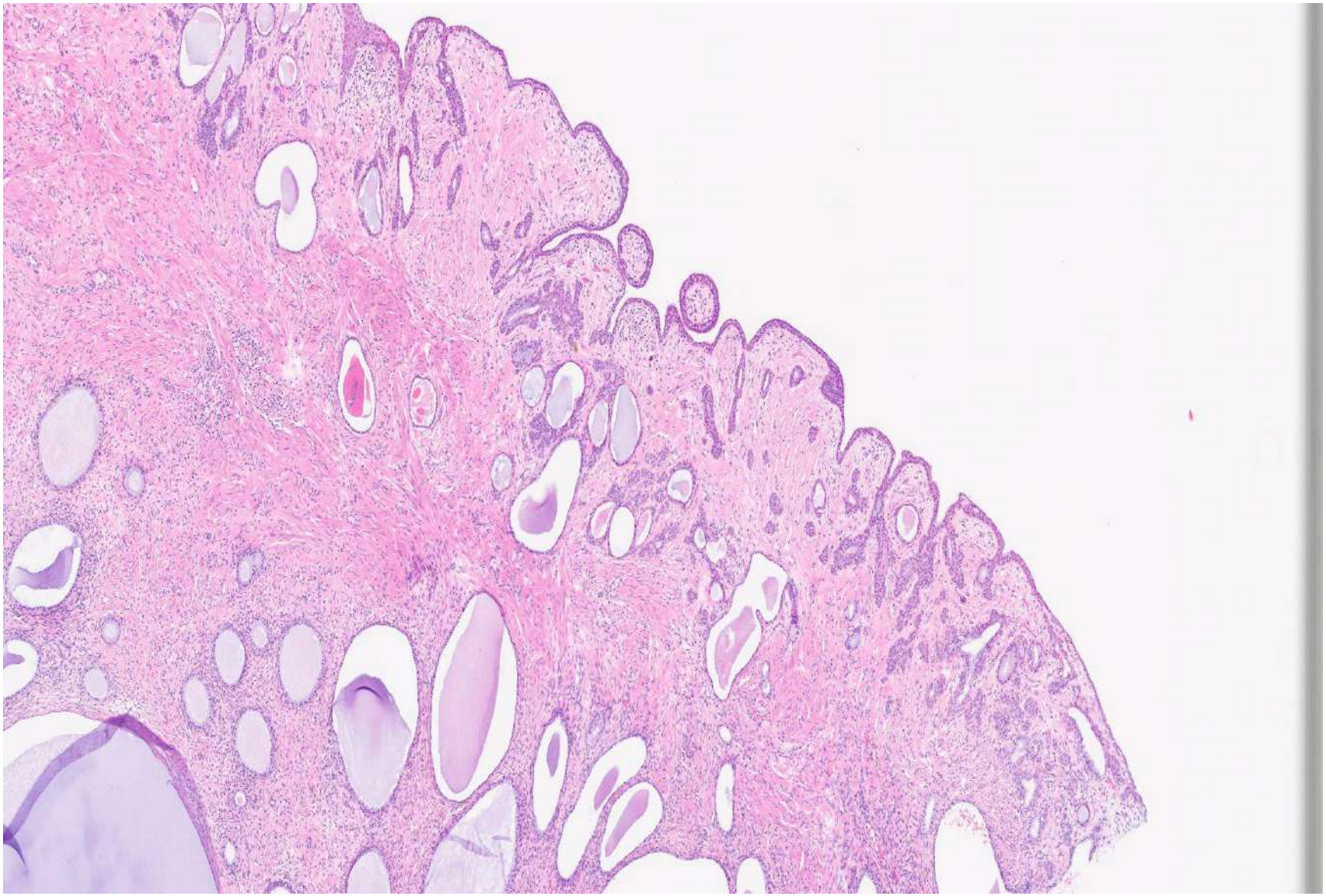

ADENOID BASAL HYPERPLASIA

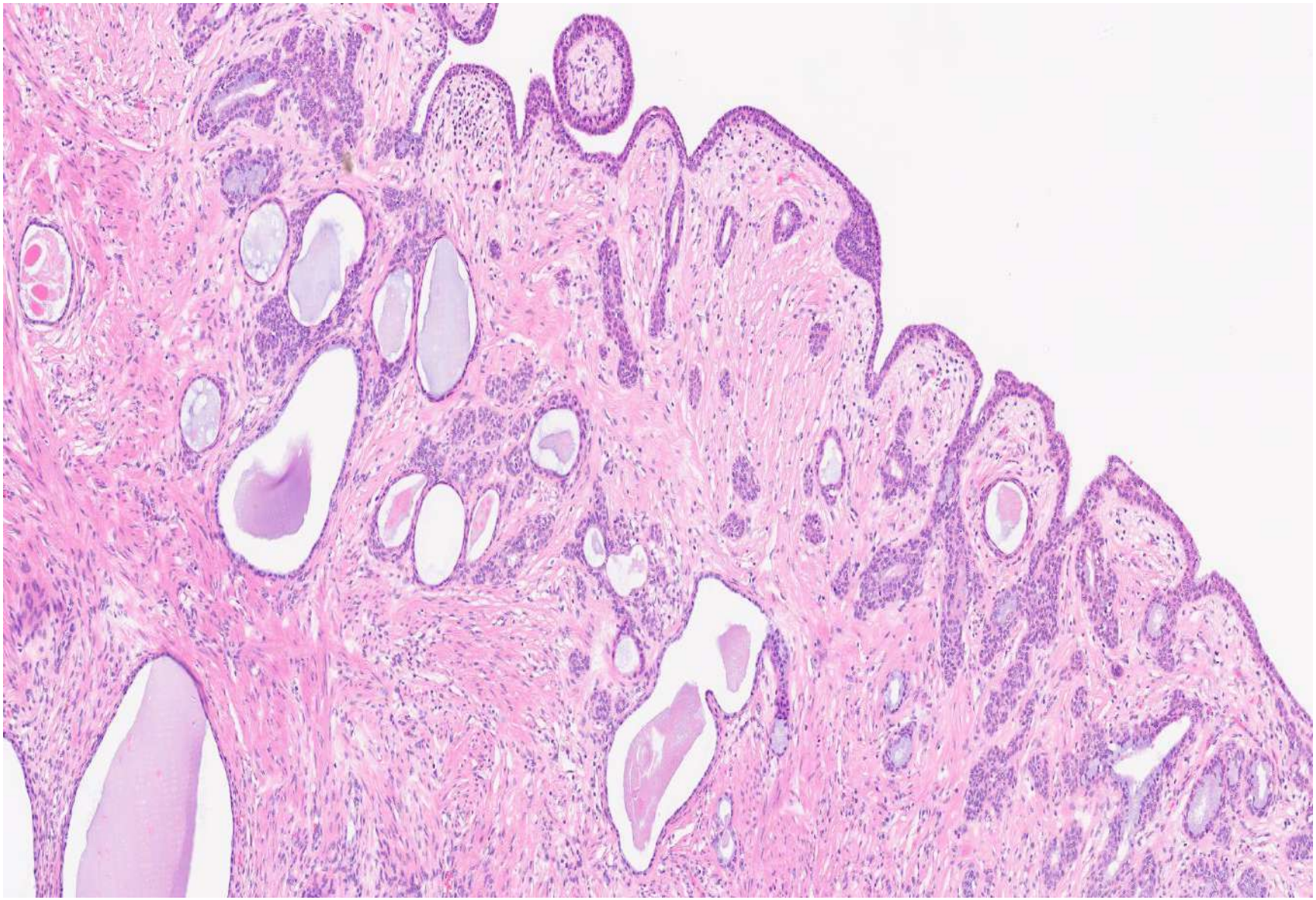

CASE 4

- F40
- LLETZ for persistent low-grade smears

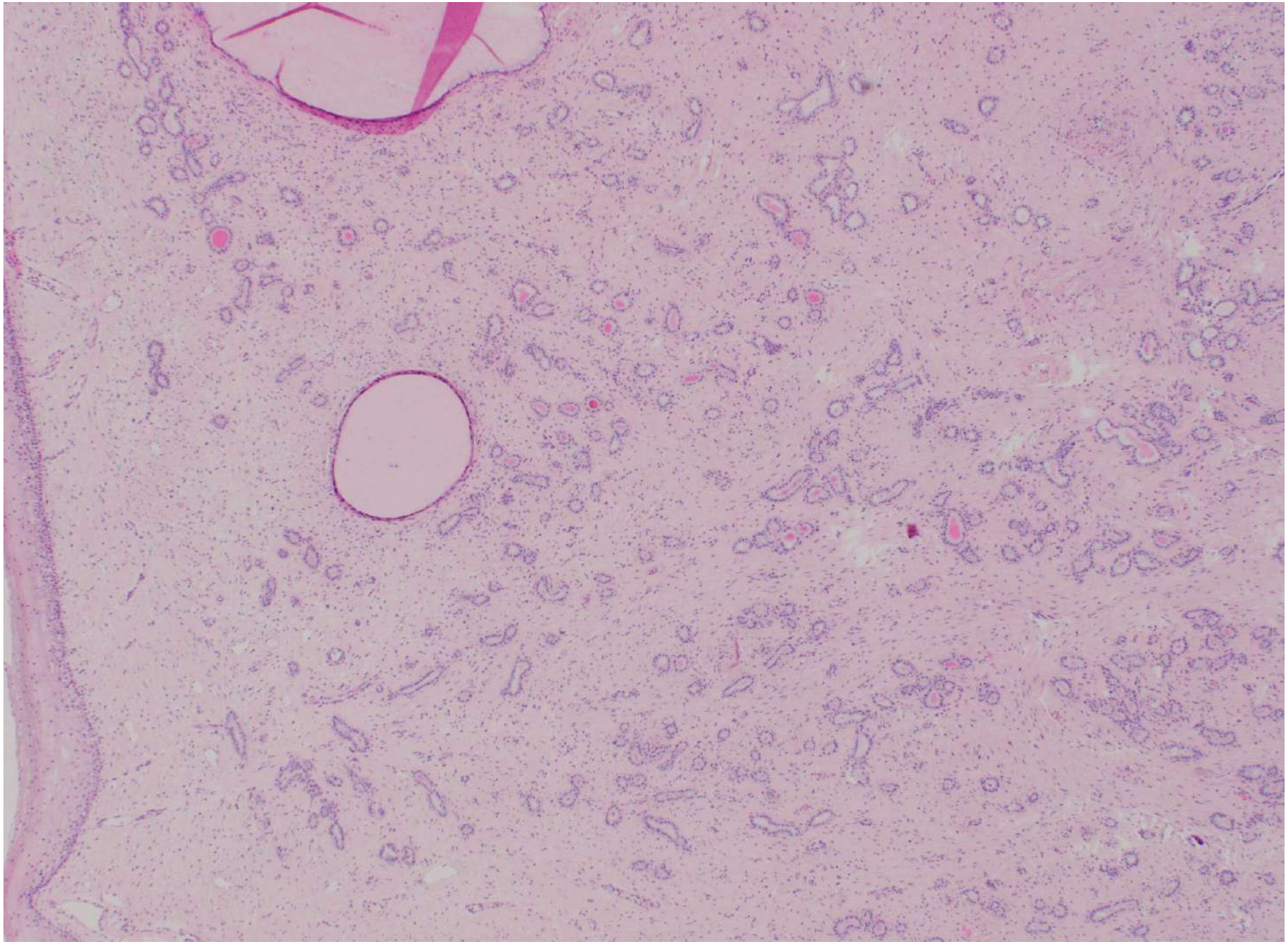

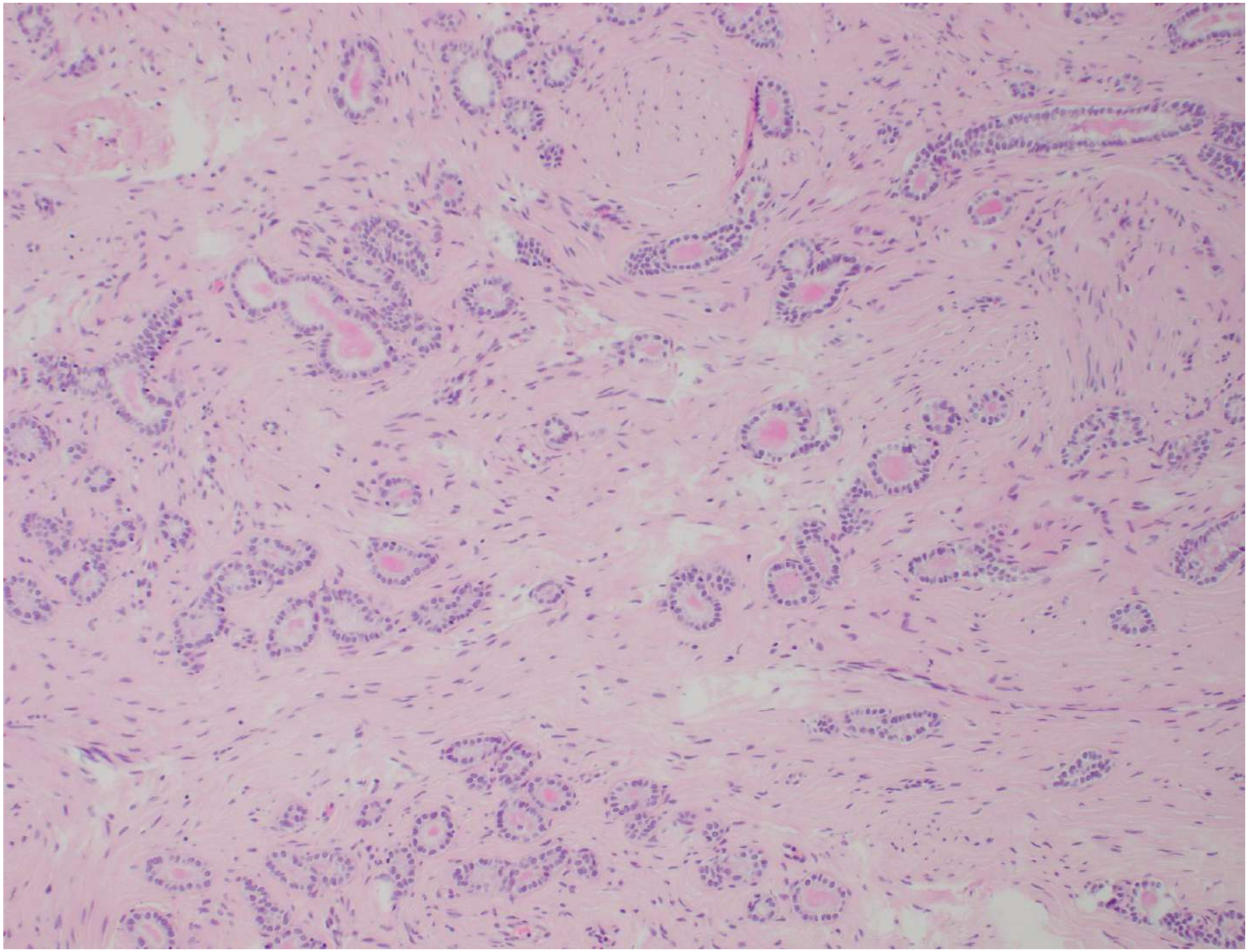

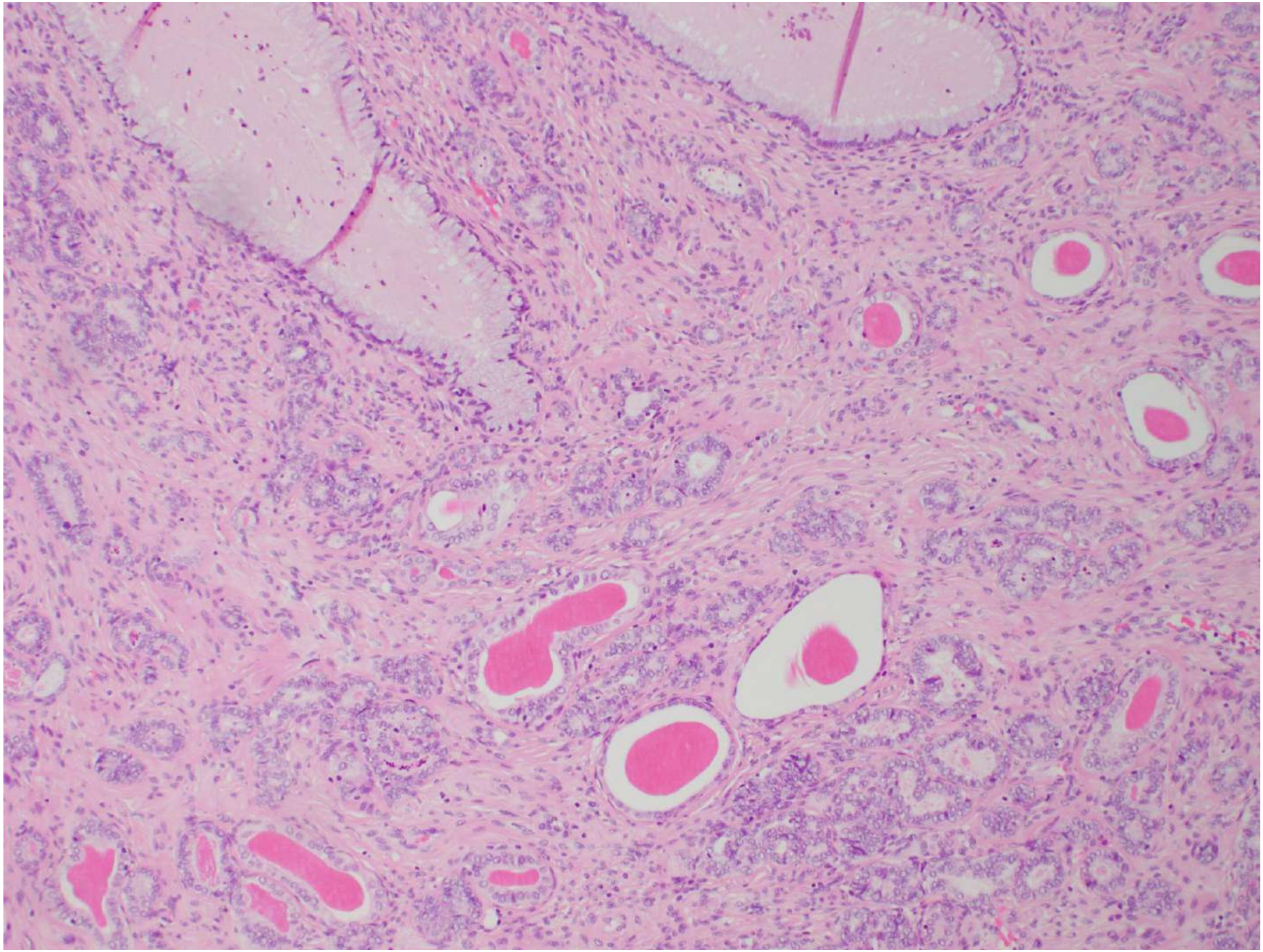

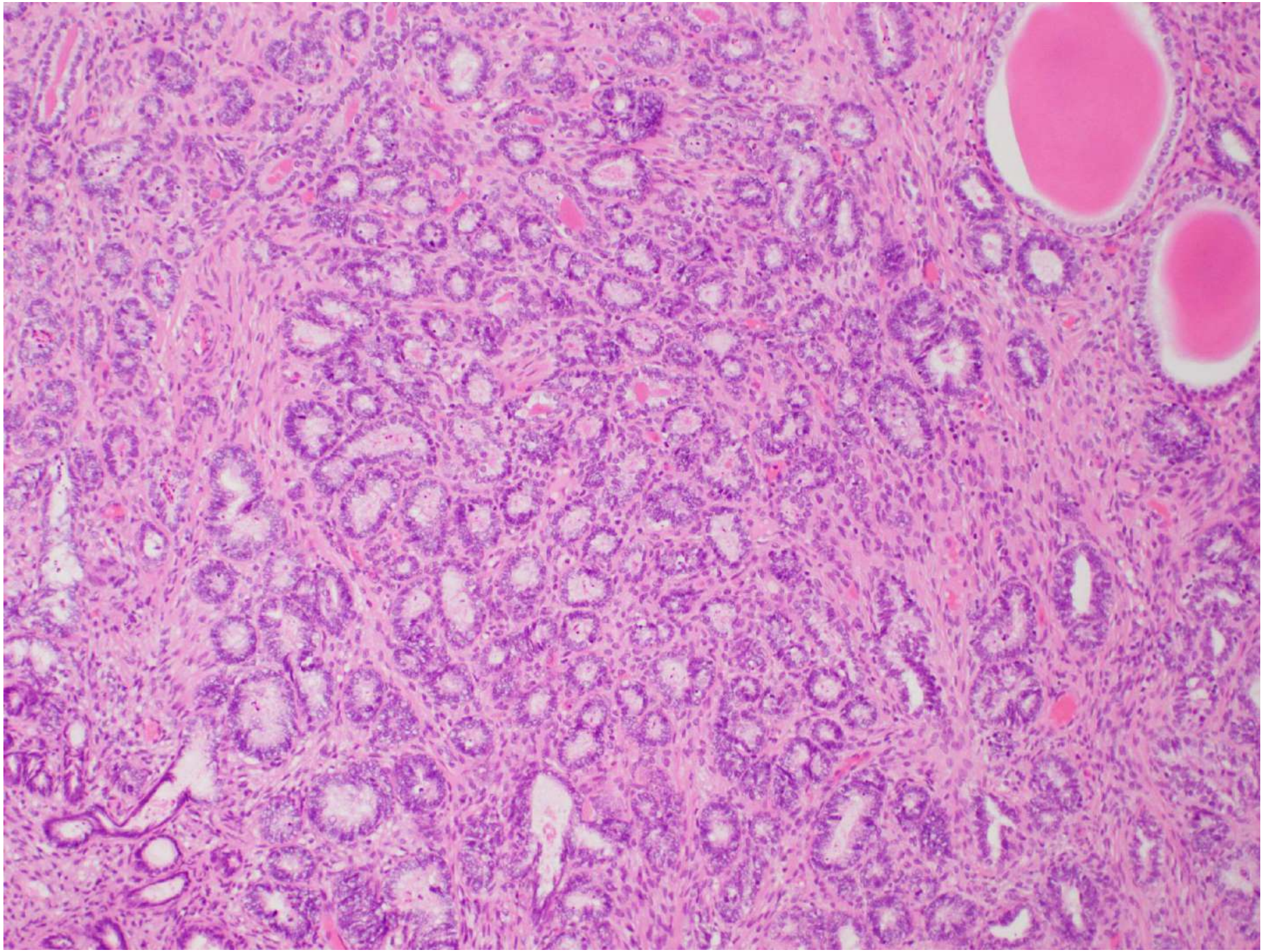

GATA3

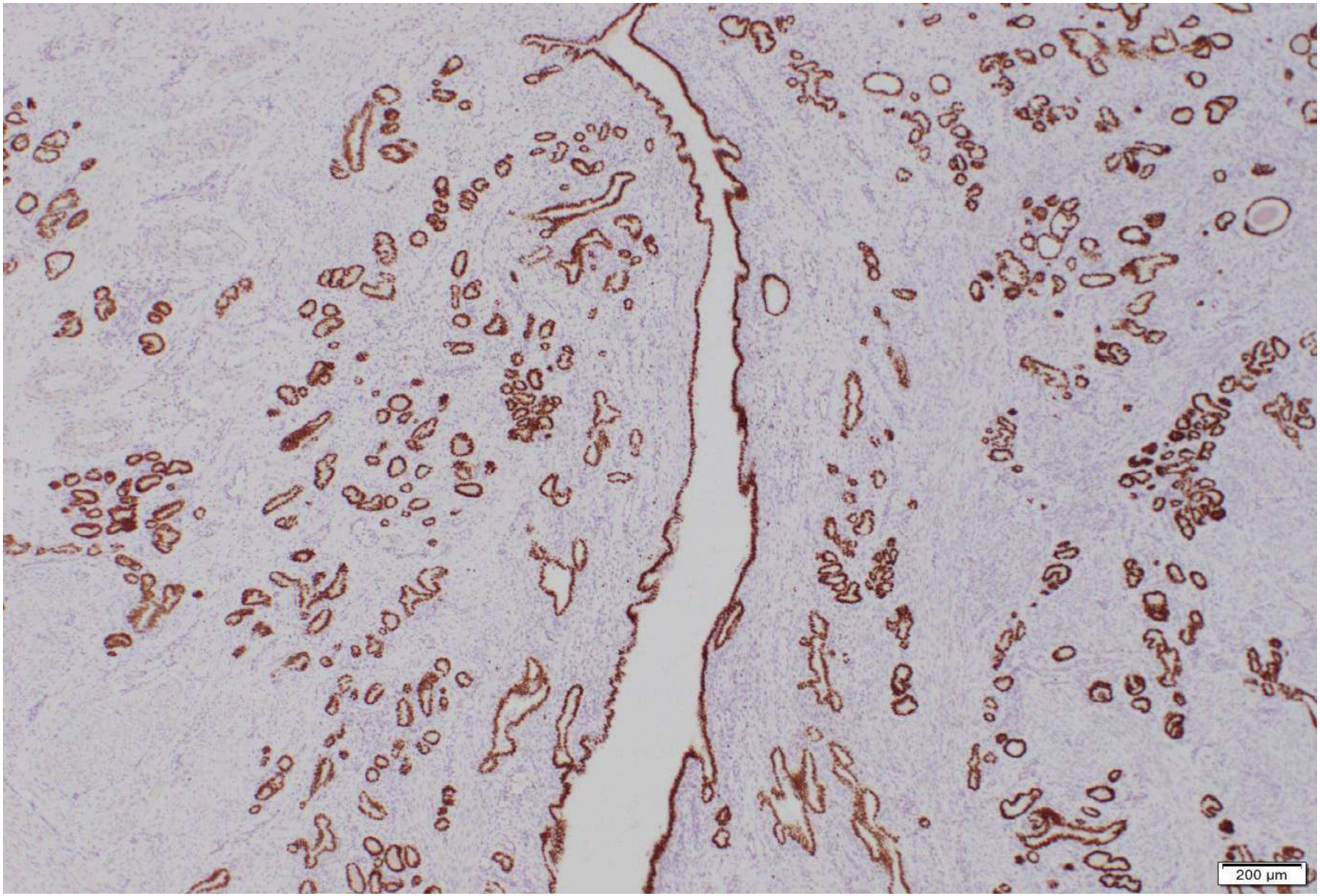

DIAGNOSIS

- Florid mesonephric hyperplasia cervix
- MAY BE MISDIAGNOSED AS MORPHOLOGICALLY WELL-DIFFERENTIATED MESONEPHRIC ADENOCARCINOMA

CERVIX- MESONEPHRIC REMNANTS AND HYPERPLASIA

- Relatively common (lateral walls); usually lobular architecture and often “linear” pattern
- Arbitrary distinction between “normal” and “hyperplasia” (6 mm)
- Hyperplasia- lobular, diffuse or ductal patterns described
- Usually beneath normal endocervical glands but diffuse hyperplasia can involve entire cervix
- **Diffuse mesonephric hyperplasia may be very difficult to distinguish from mesonephric adenocarcinoma**

MESONEPHRIC REMNANTS

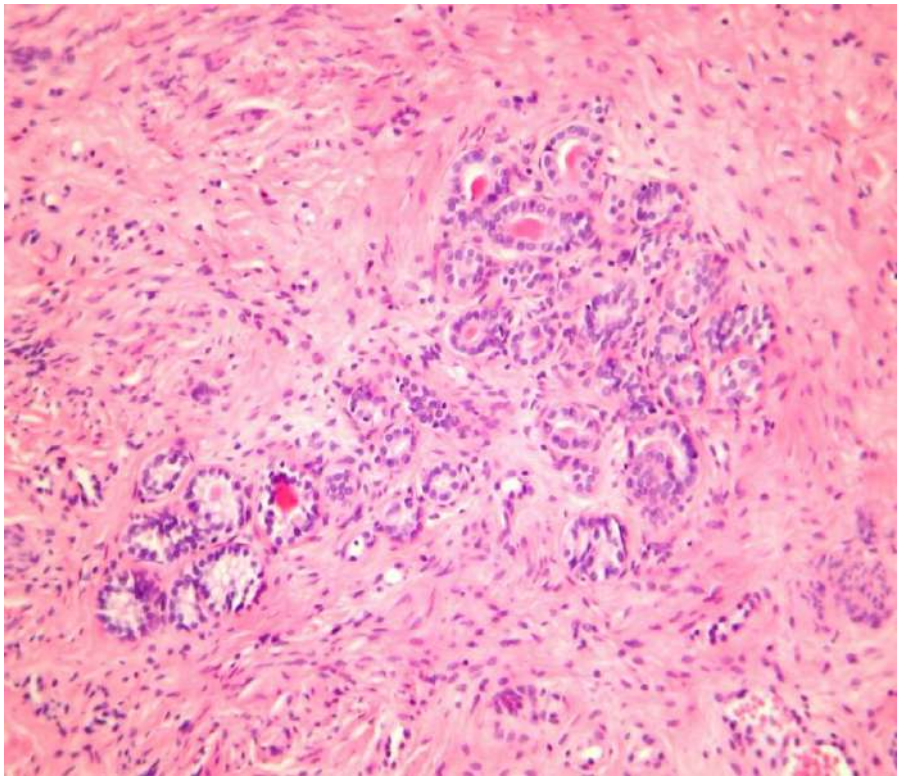

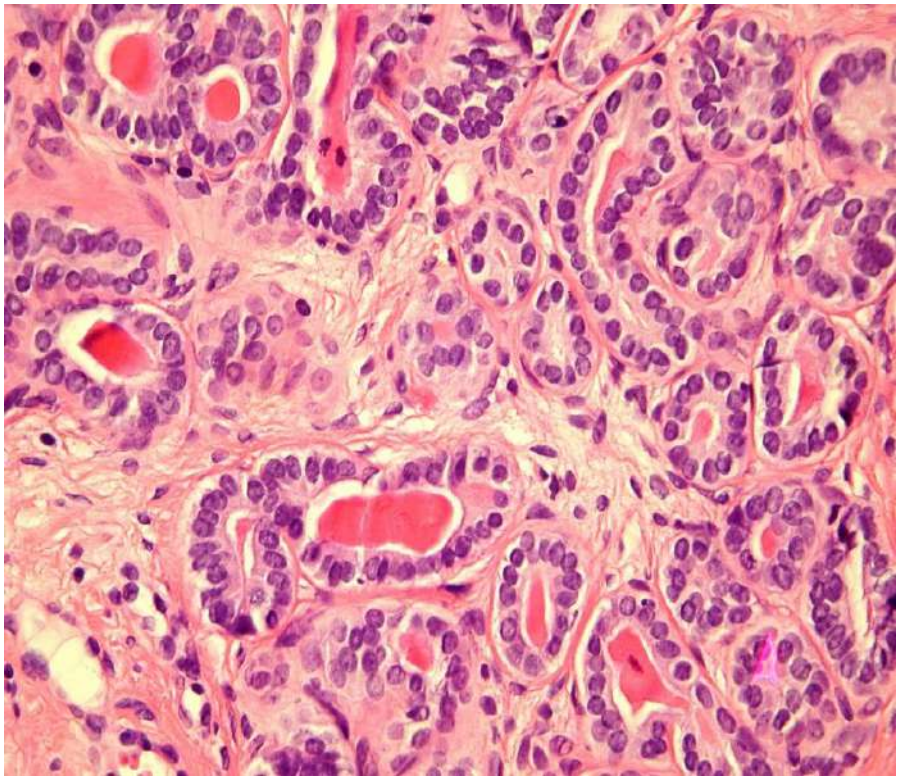

LOBULAR MESONEPHRIC HYPERPLASIA

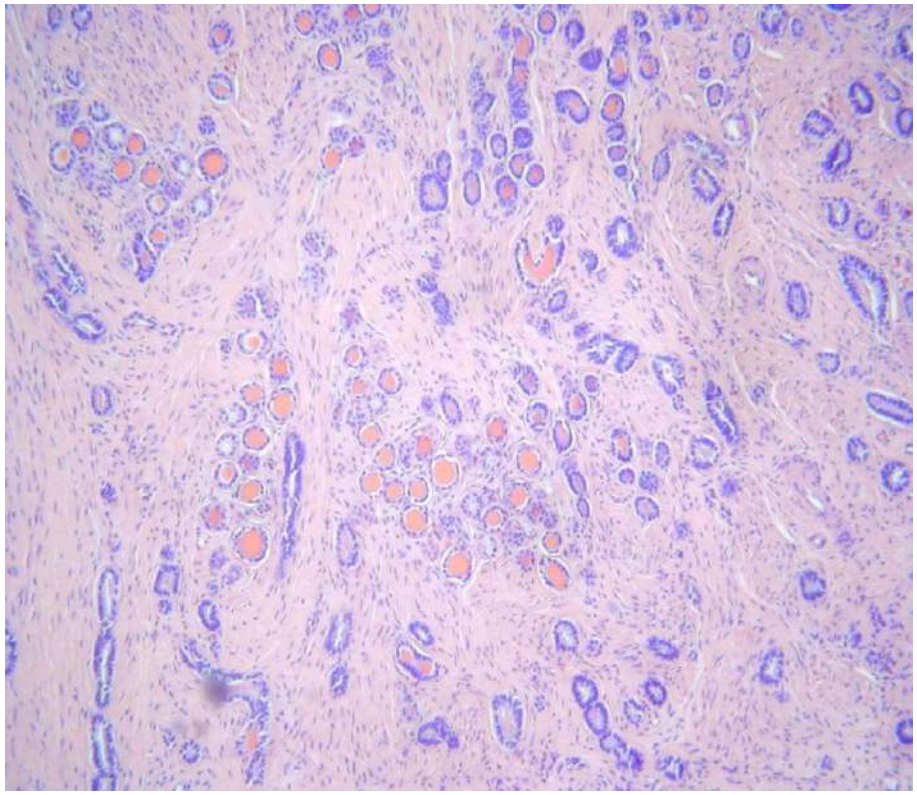

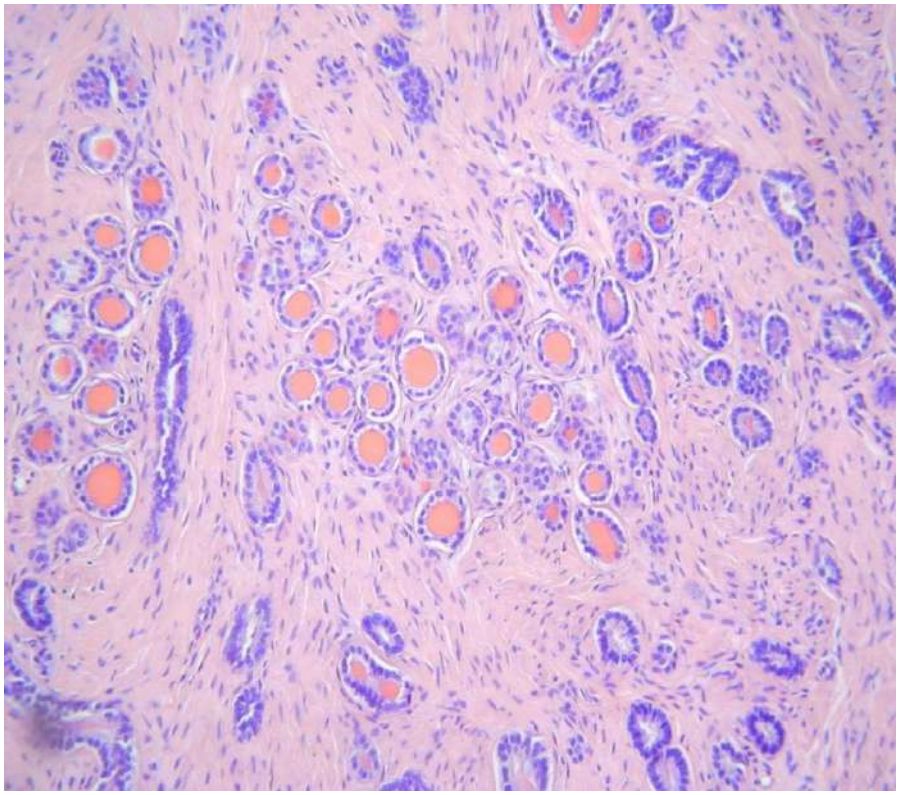

FLORID DIFFUSE MESONEPHRIC HYPERPLASIA

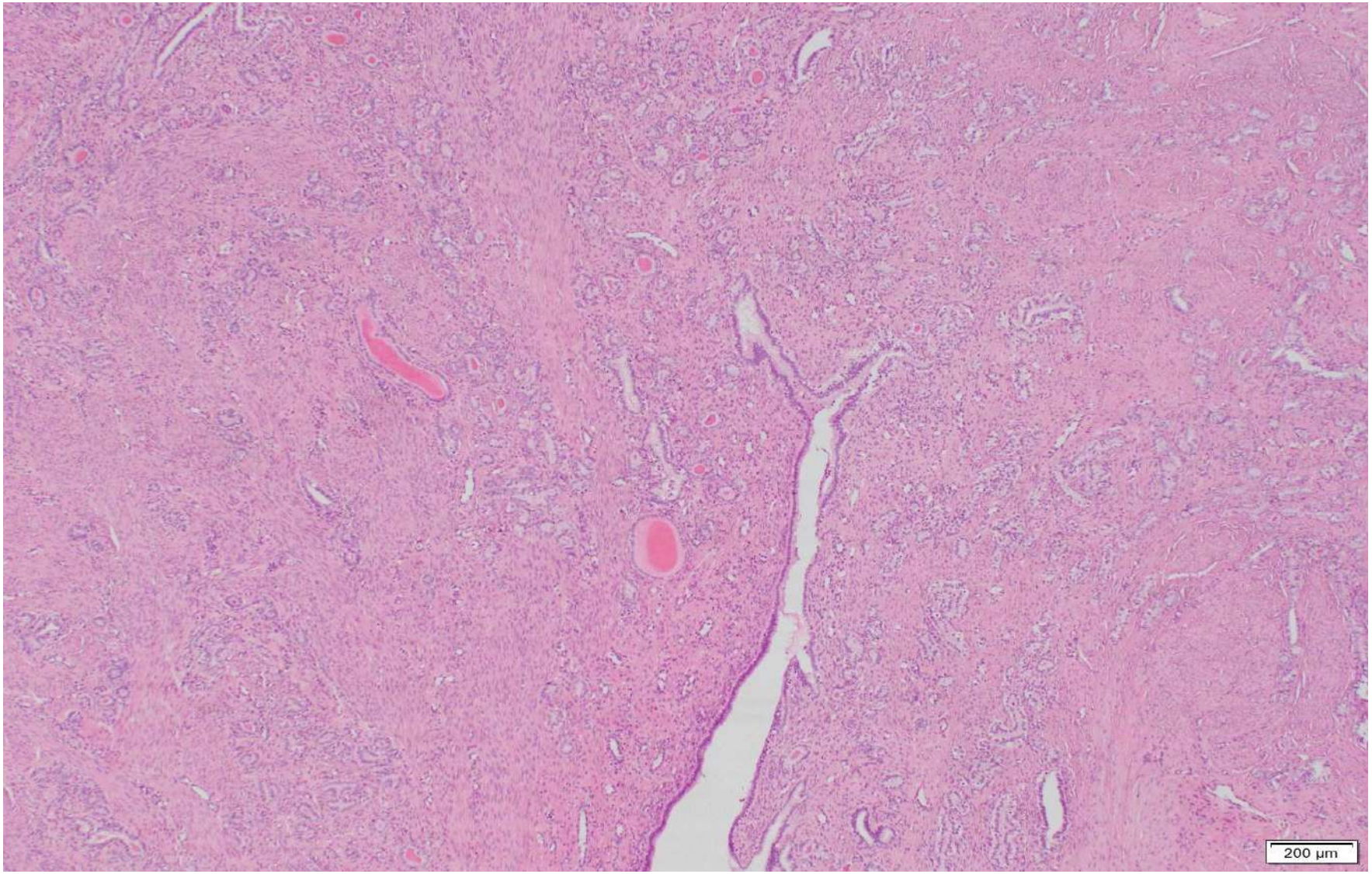

FLORID DIFFUSE MESONEPHRIC HYPERPLASIA

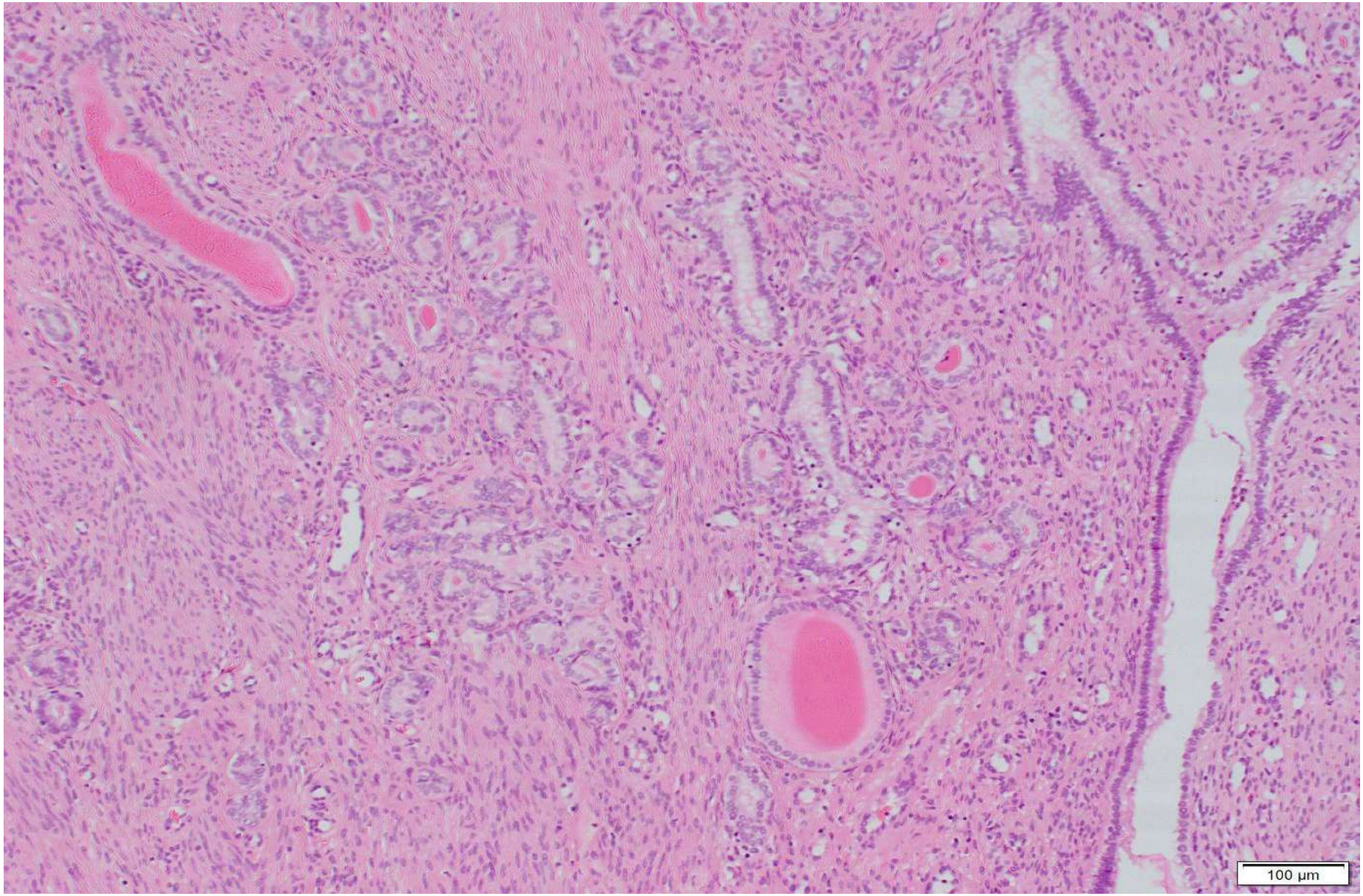

DUCTAL MESONEPHRIC REMNANTS

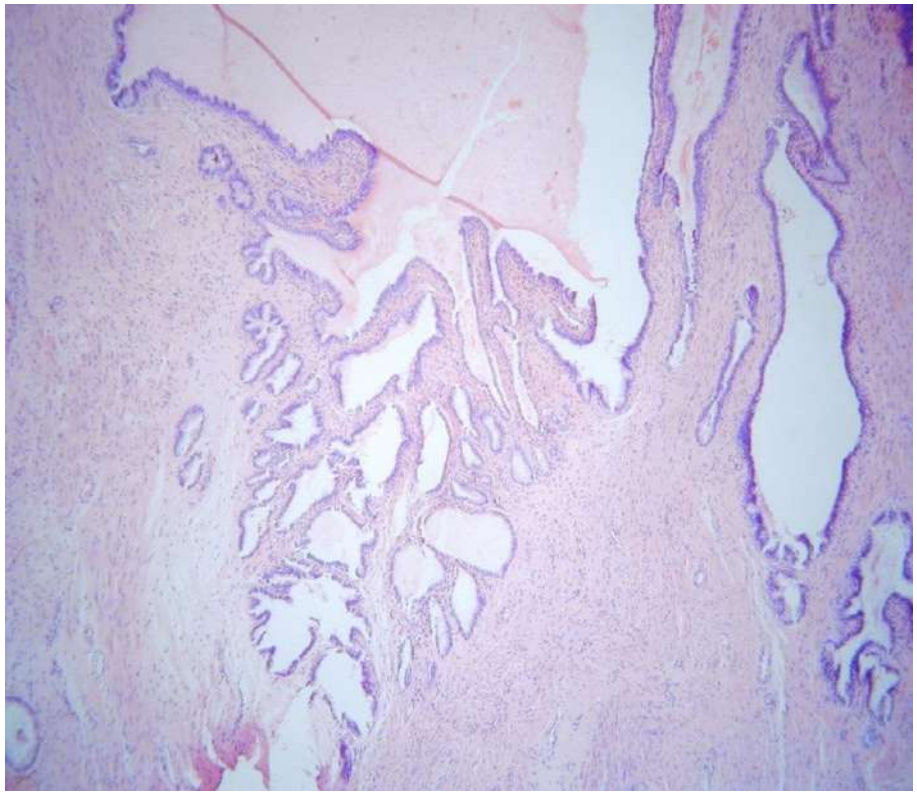

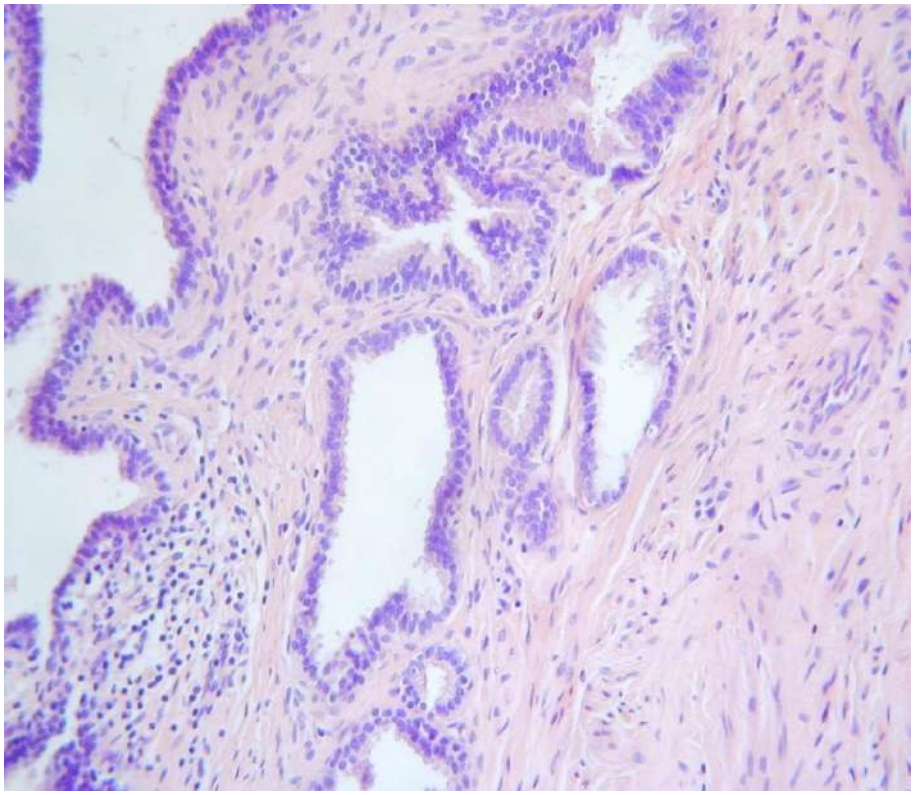

IMMUNOHISTOCHEMISTRY OF CERVICAL MESONEPHRIC REMNANTS

- Often luminal CD10 positive (not reliable)
- Vimentin positive
- GATA3 positive (RELIABLE MARKER OF BENIGN MESONEPHRIC PROLIFERATIONS)
- ER and PR “flat” negative (may be useful)
- PAX8 positive (not useful in distinction from Mullerian lesions)

IMMUNOHISTOCHEMISTRY OF MESONEPHRIC REMNANTS

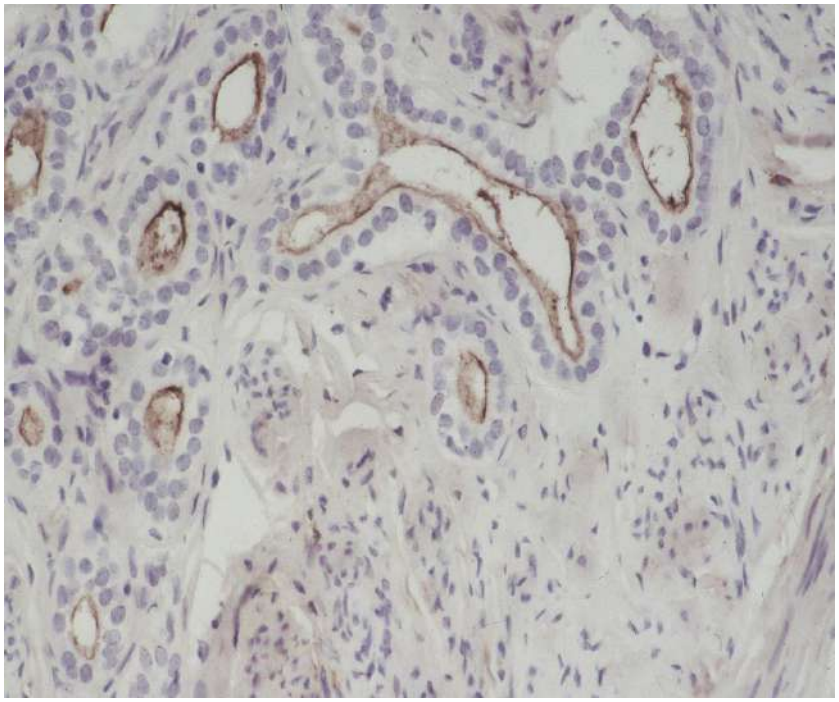

CD10

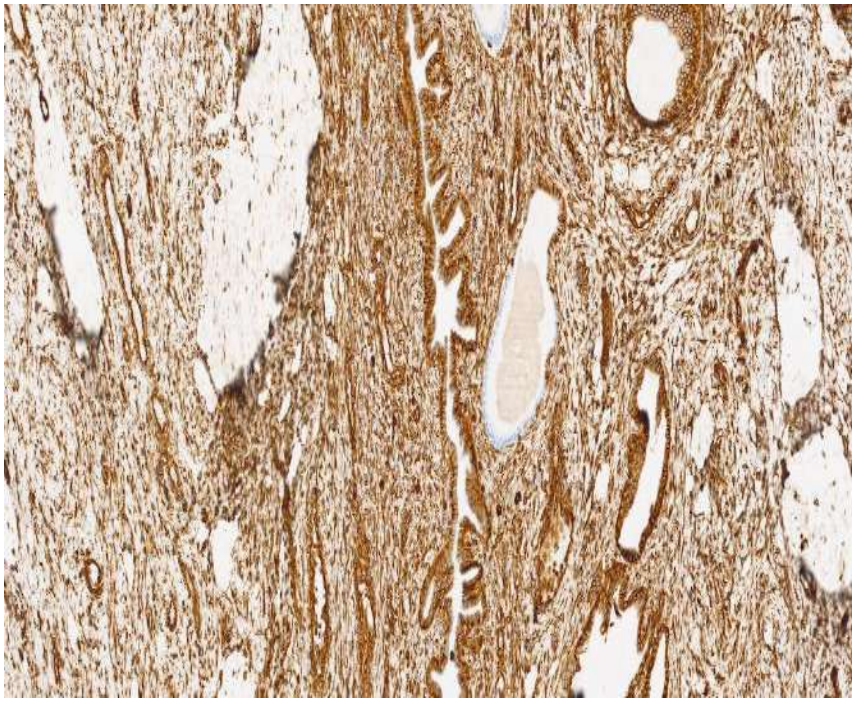

vimentin

DUCTAL MESONEPHRIC REMNANTS

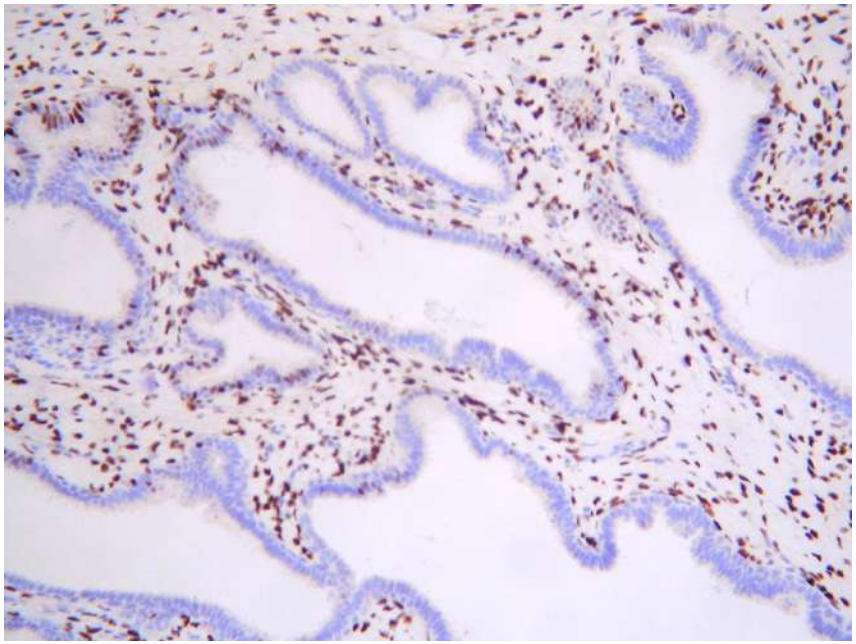

ER

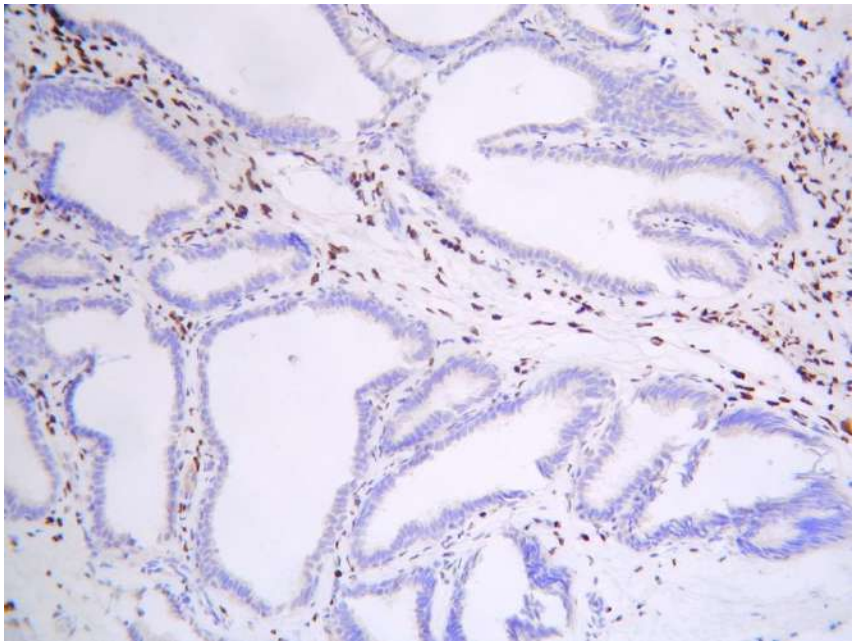

PR

DIFFERENTIATION BETWEEN DIFFUSE MESONEPHRIC HYPERPLASIA AND MESONEPHRIC ADENOCARCINOMA

- mass lesion versus incidental microscopic finding
- lobular pattern suggests hyperplasia
- more crowding, destructive stromal invasion, nuclear atypia and mitotic activity in carcinoma
- various different architectural patterns more in keeping with mesonephric adenocarcinoma
- sometimes vascular and perineural infiltration and extension beyond cervix in adenocarcinoma
- OCCASIONALLY IMPOSSIBLE OR VERY DIFFICULT MORPHOLOIGCALLY
- demonstration of *KRAS* or *NRAS* mutation may be useful in confirming adenocarcinoma (no mutations in mesonephric hyperplasia- PMID 28703285)

CASE 5

- F35
- Repeat LLETZ following LLETZ with CIN III at margins

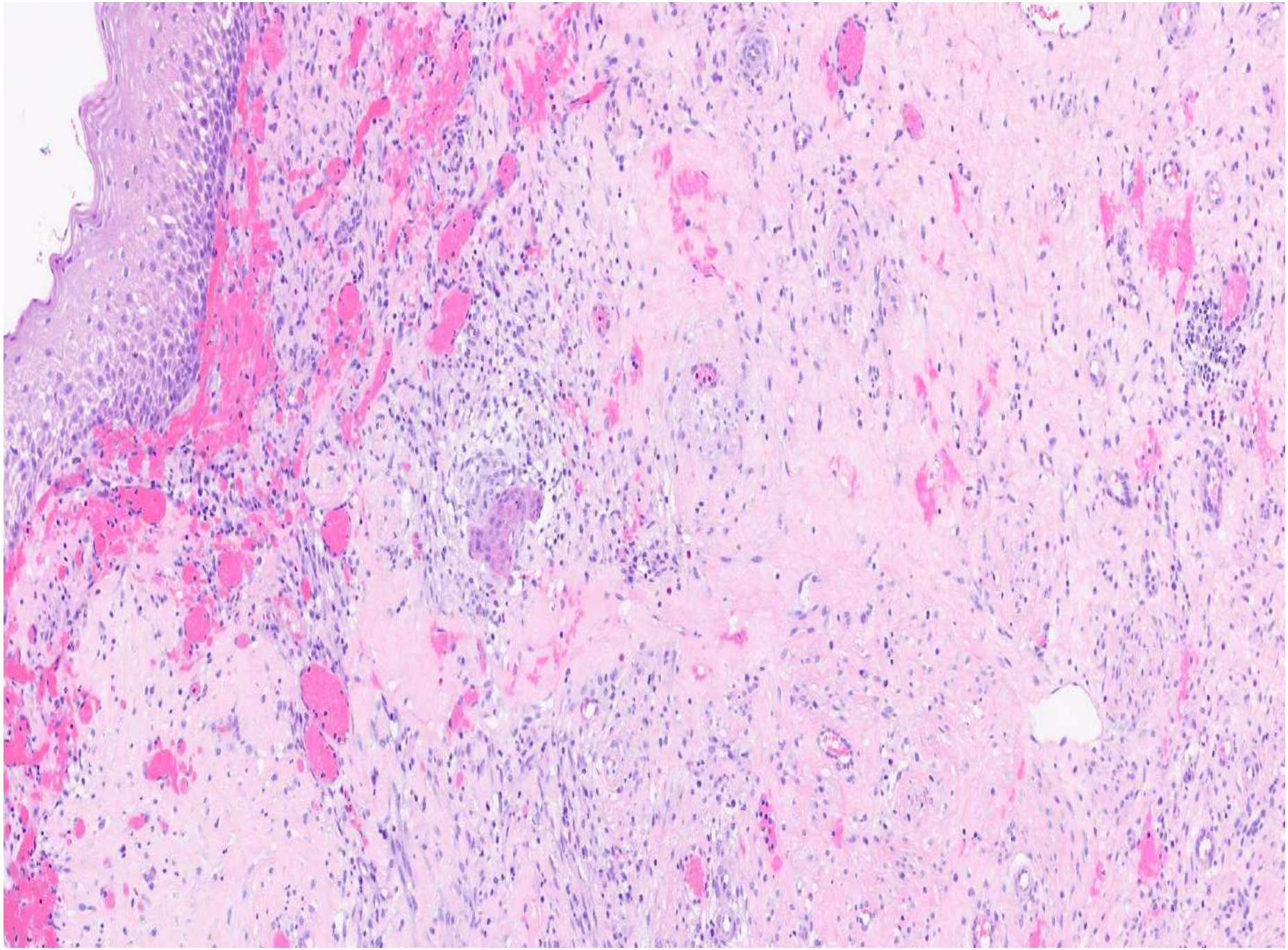

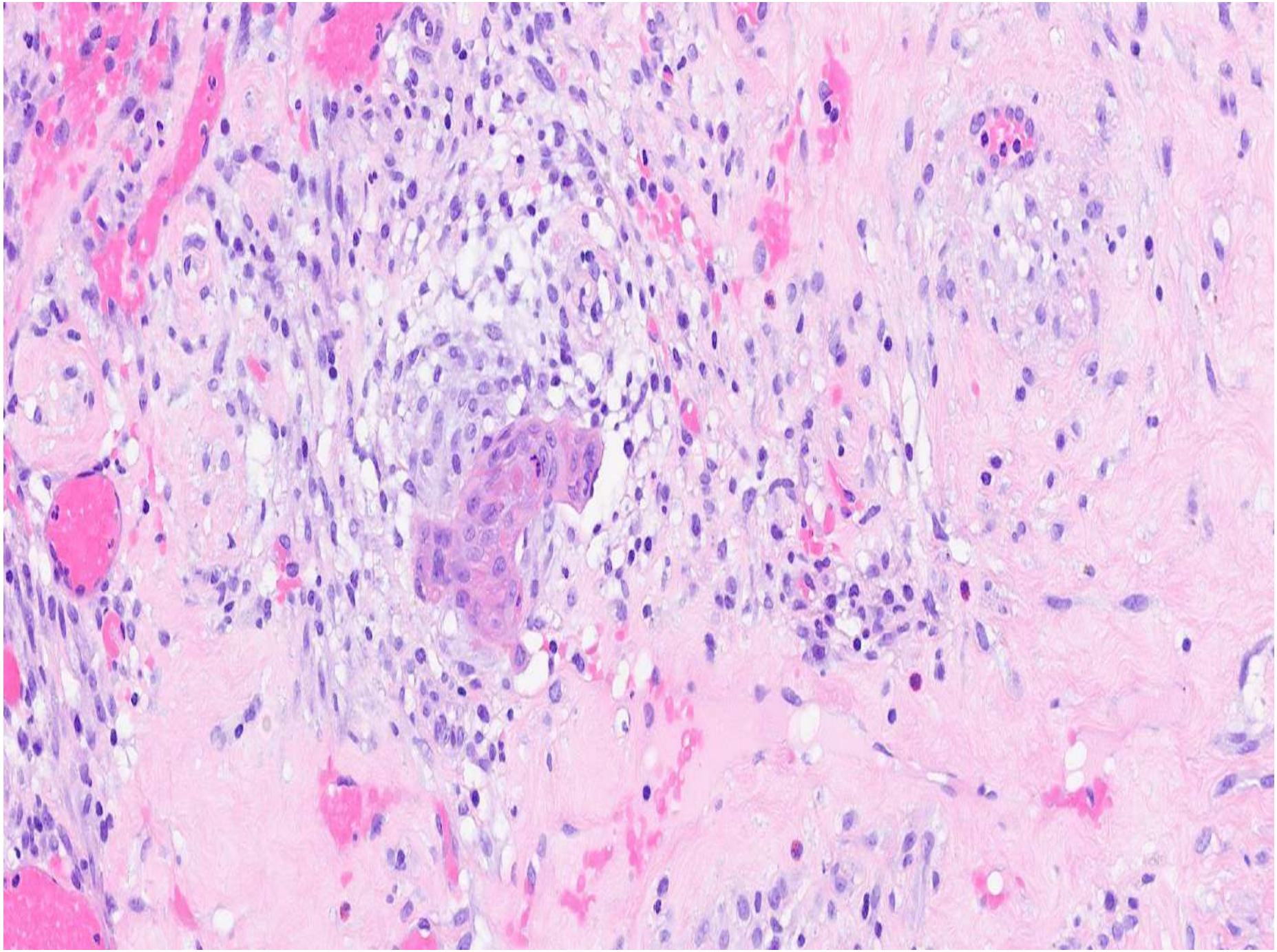

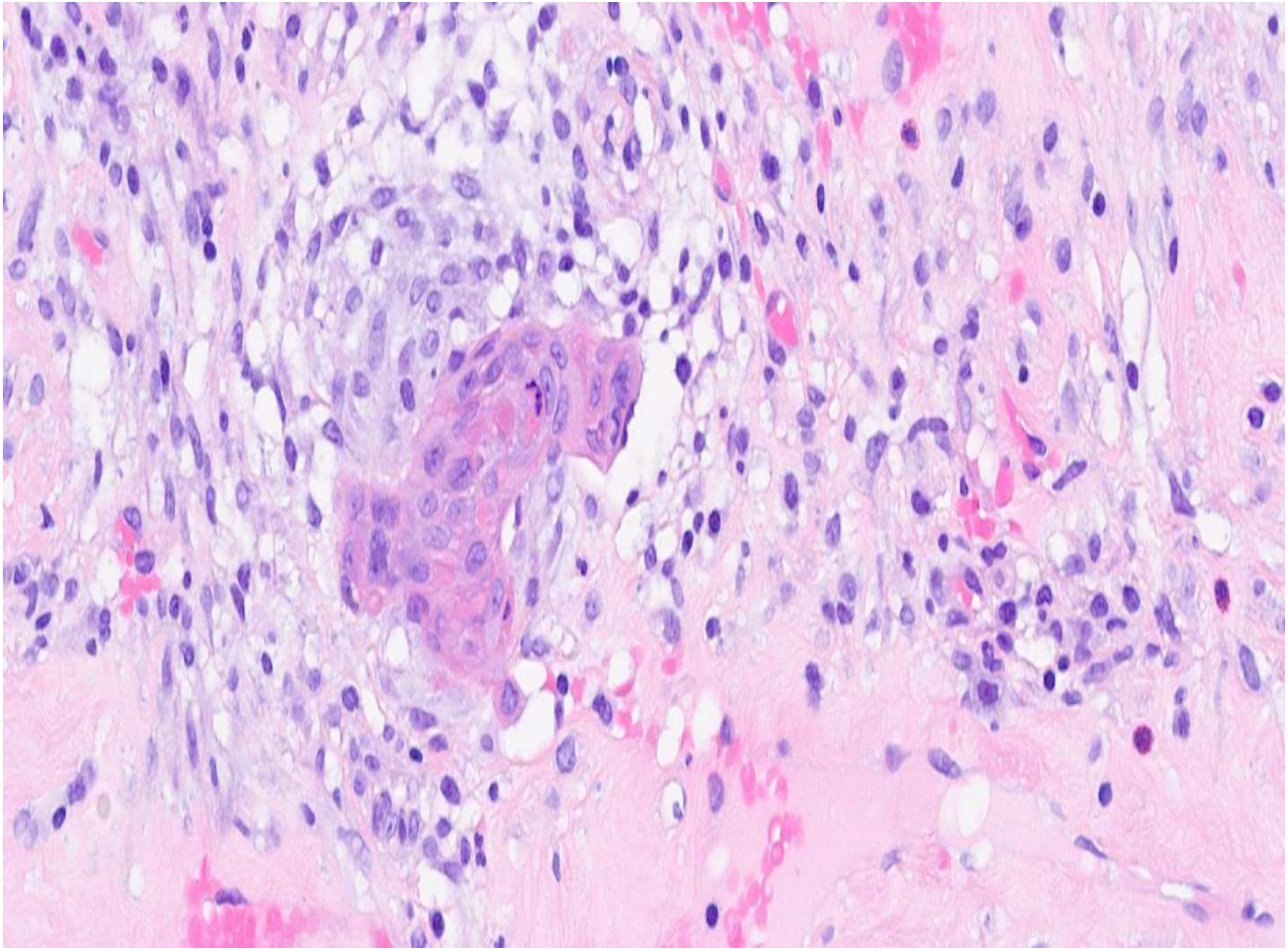

ORIGINAL DIAGNOSIS

- No residual CIN
- Single small focus of squamous cell carcinoma (FIGO IA1)

DIAGNOSIS- PSEUDOINVASION FOLLOWING CERVICAL BIOPSY- PMID 21896582

Downloaded from jcp.bmj.com on November 17, 2011 - Published by group.bmj.com

Original article

Pseudoinvasion of benign squamous epithelium following cervical biopsy: a pseudoneoplastic phenomenon mimicking invasive squamous carcinoma

David P Boyle, W Glenn McCluggage

PSEUDOINVASION FOLLOWING CERVICAL BIOPSY- PMID 21896582

- Pseudoneoplastic lesion following biopsy or loop excision which may mimic squamous cell carcinoma
- Typically, hypereosinophilic appearance
- May be associated granulation-type reaction and/ or haemosiderin and/ or histiocytes and multinucleate giant cells
- Sometimes in spaces which may mimic LVSI
- p16 may be useful
- MAY BE MISDIAGNOSED AS SMALL INVASIVE SQUAMOUS CELL CARCINOMA

PSEUDOINVASION FOLLOWING CERVICAL BIOPSY- PMID 21896582

Figure 2 (A) The nests of squamous cells are surrounded by inflammatory cells, including multinucleate giant cells. (B) Some of the nests of squamous epithelium are surrounded by clefts representing retraction artefact but simulating lymphovascular invasion.

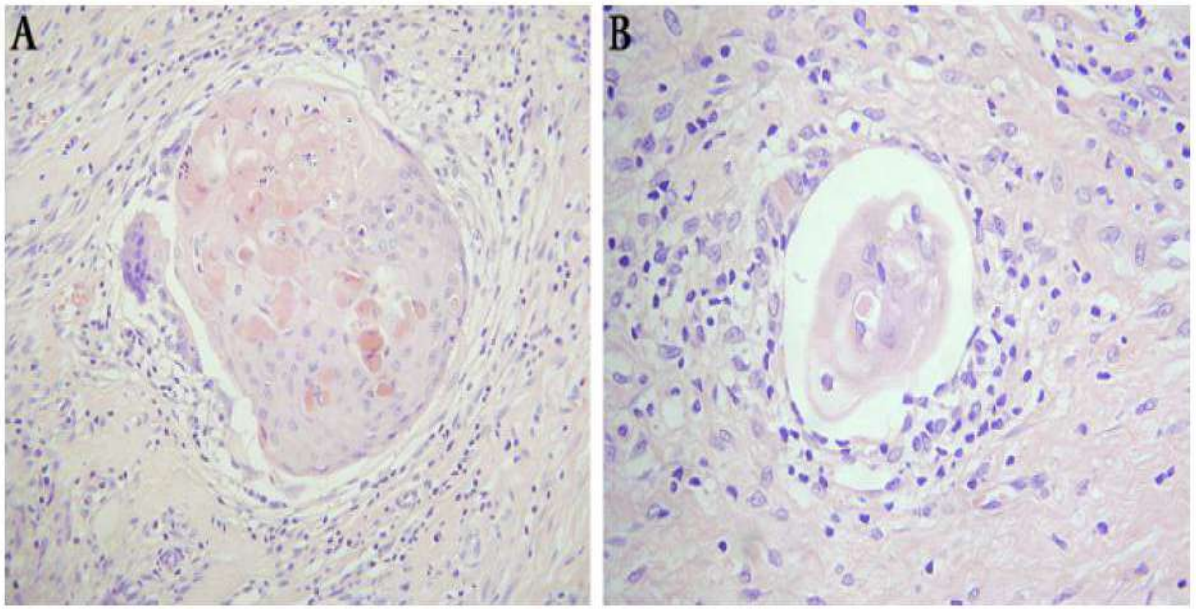

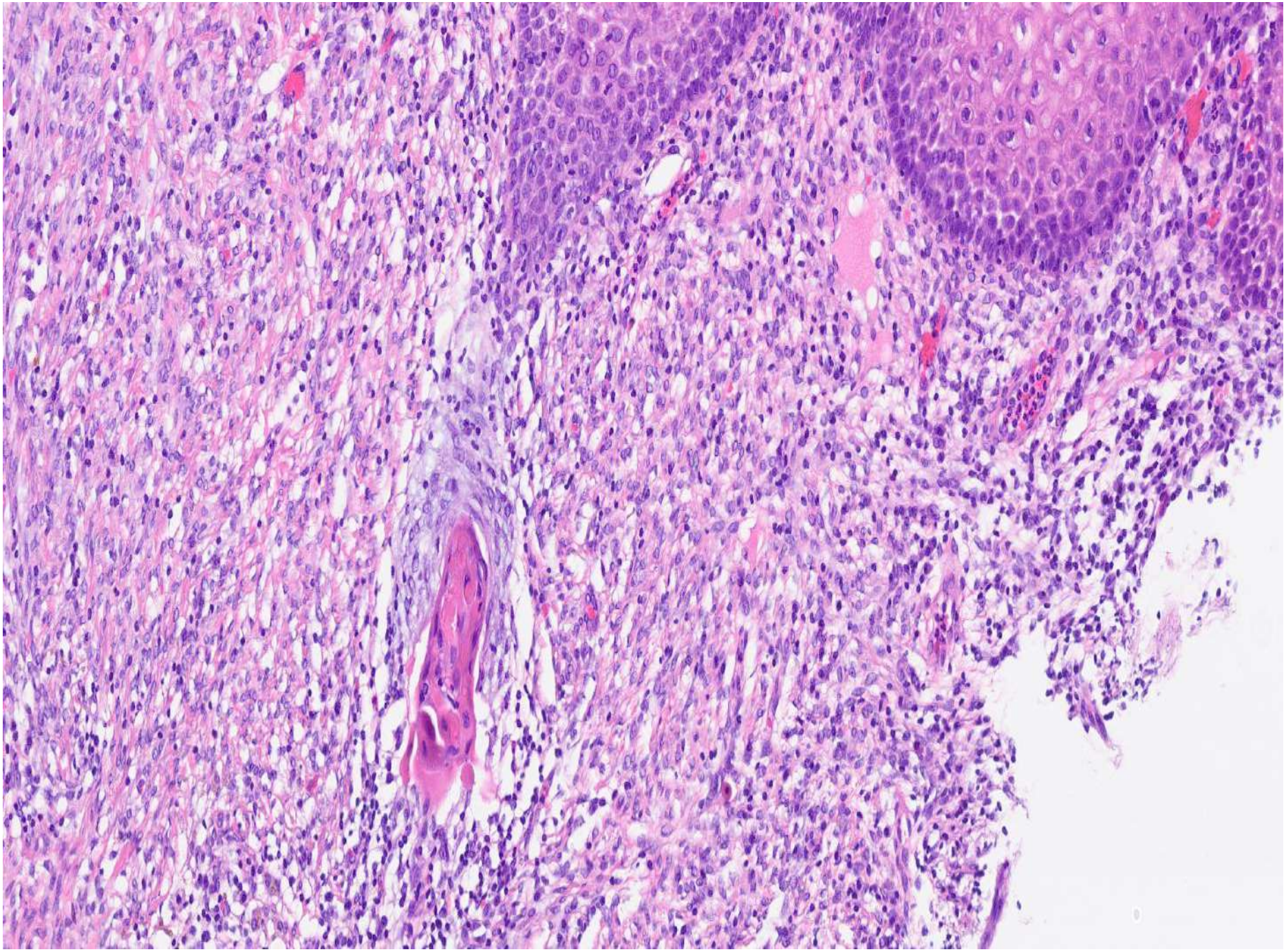

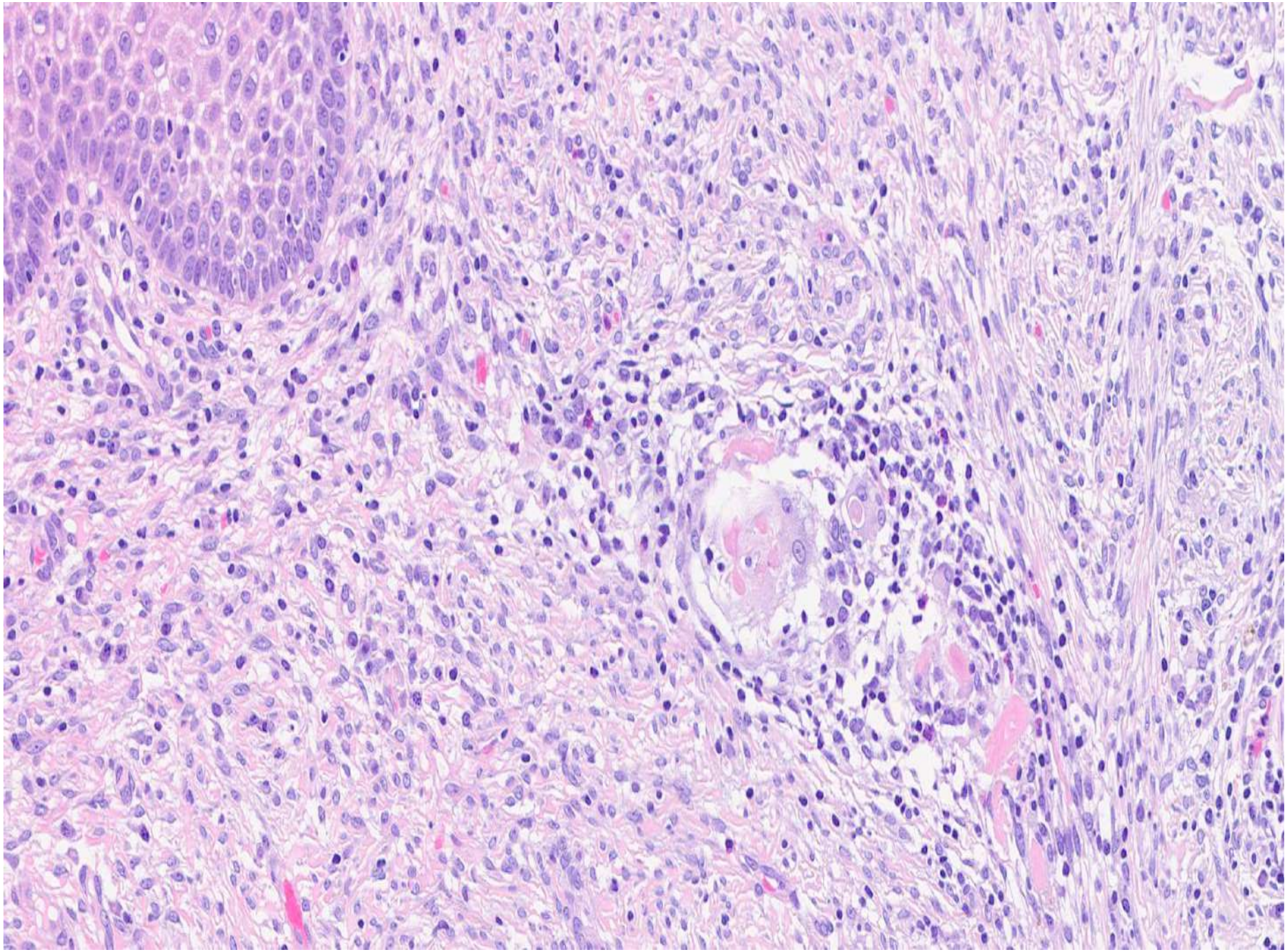

PSEUDOINVASION IN CONDYLOMA FOLLOWING CERVICAL BIOPSY

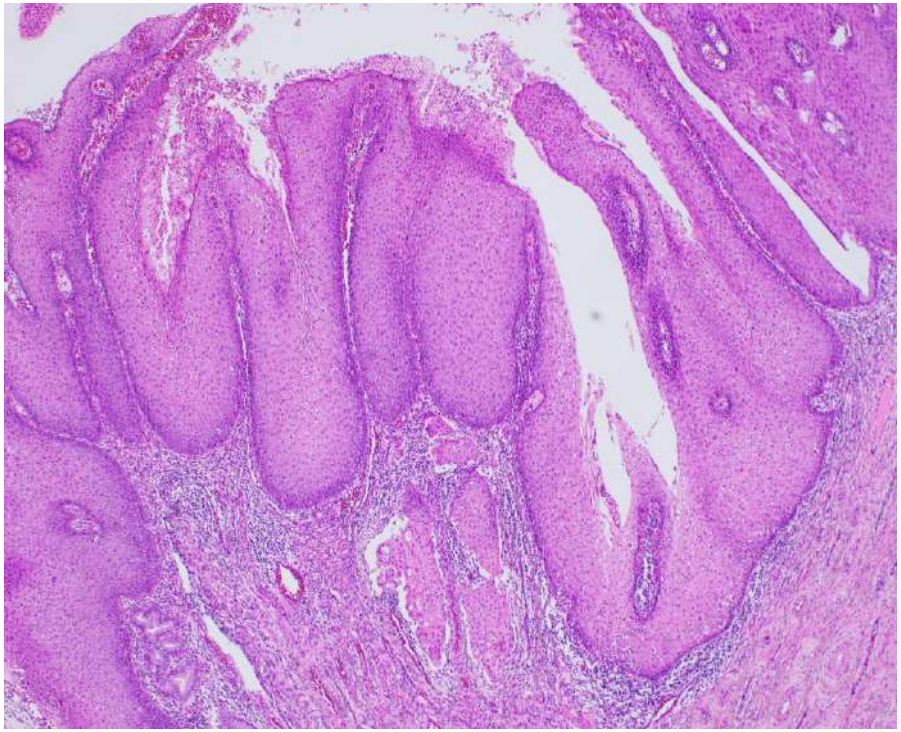

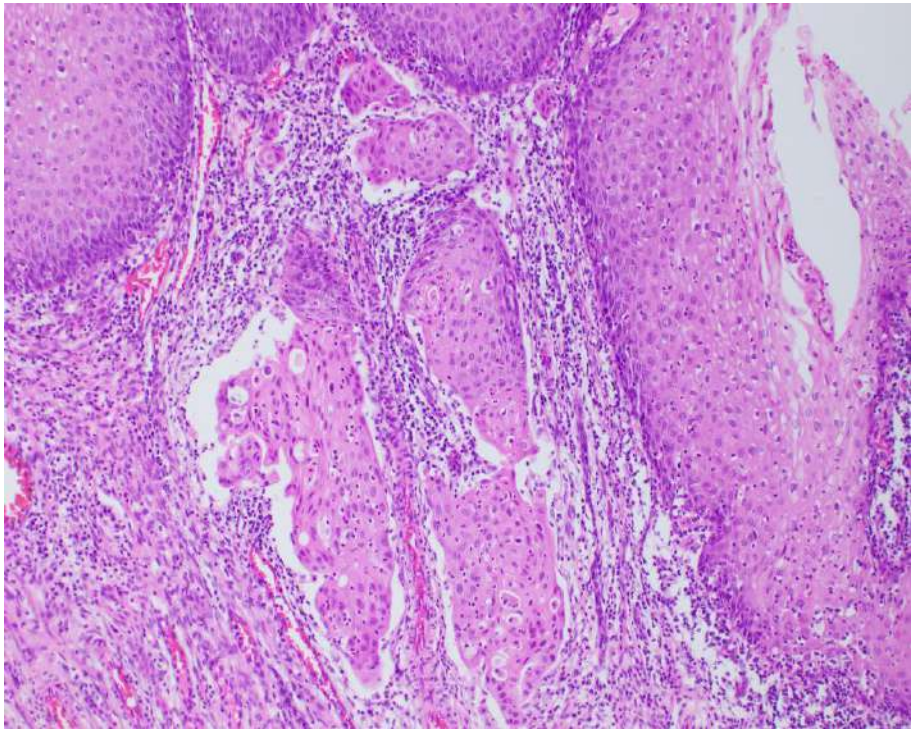

CASE 6

- F41
- Wart-like lesion on surface of cervix
- Punch biopsy reported as squamous cell carcinoma
- LLETZ performed

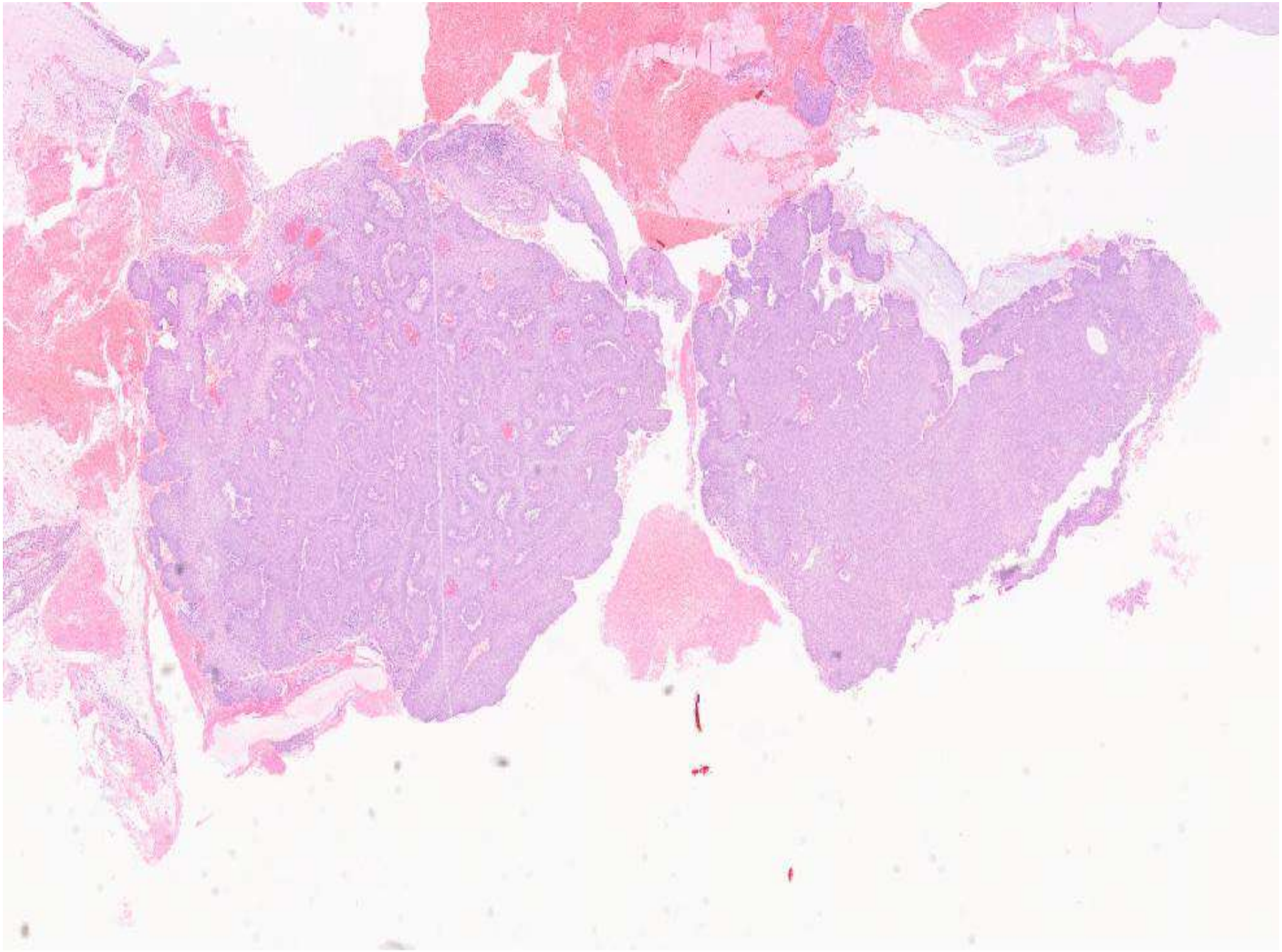

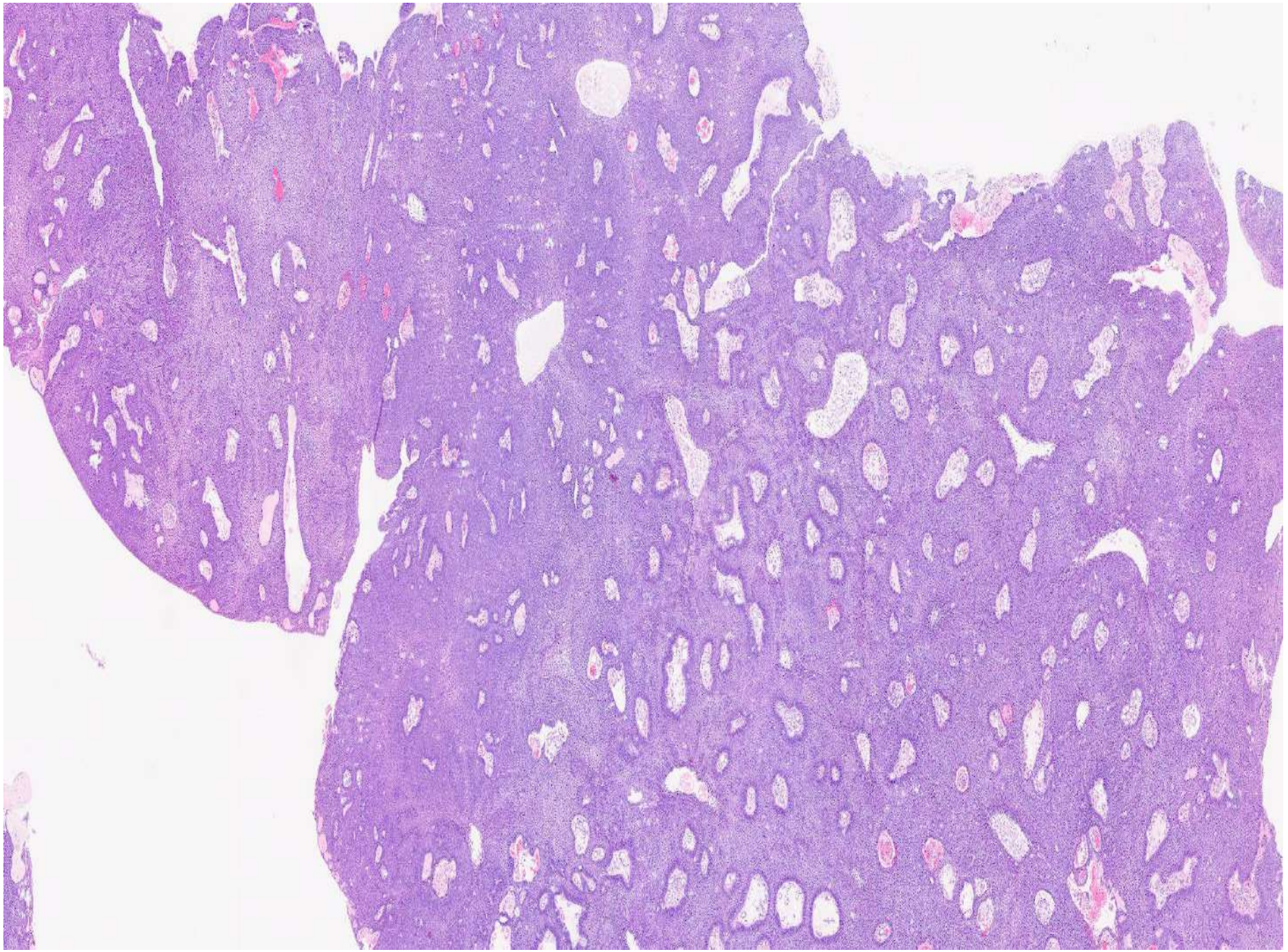

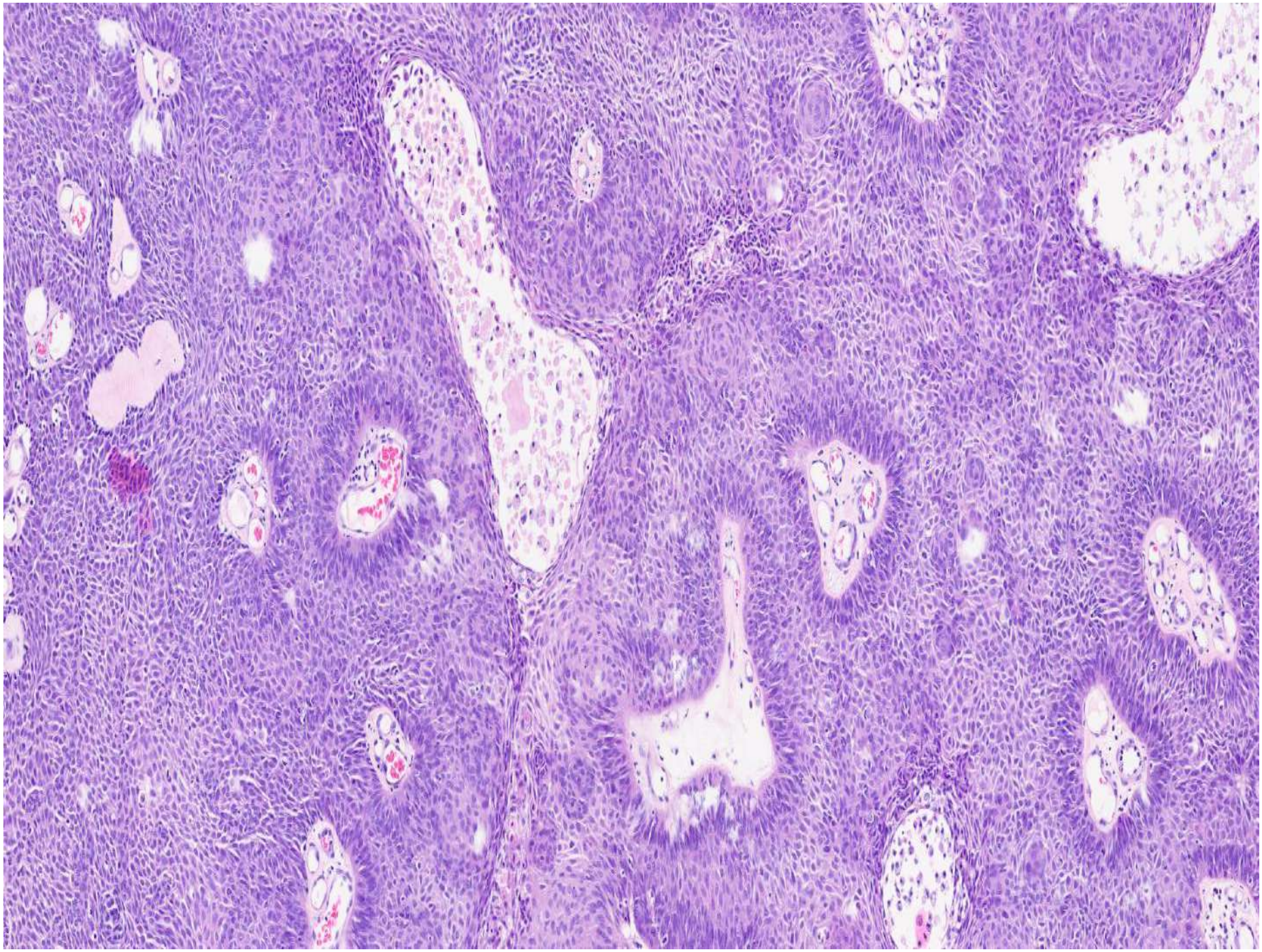

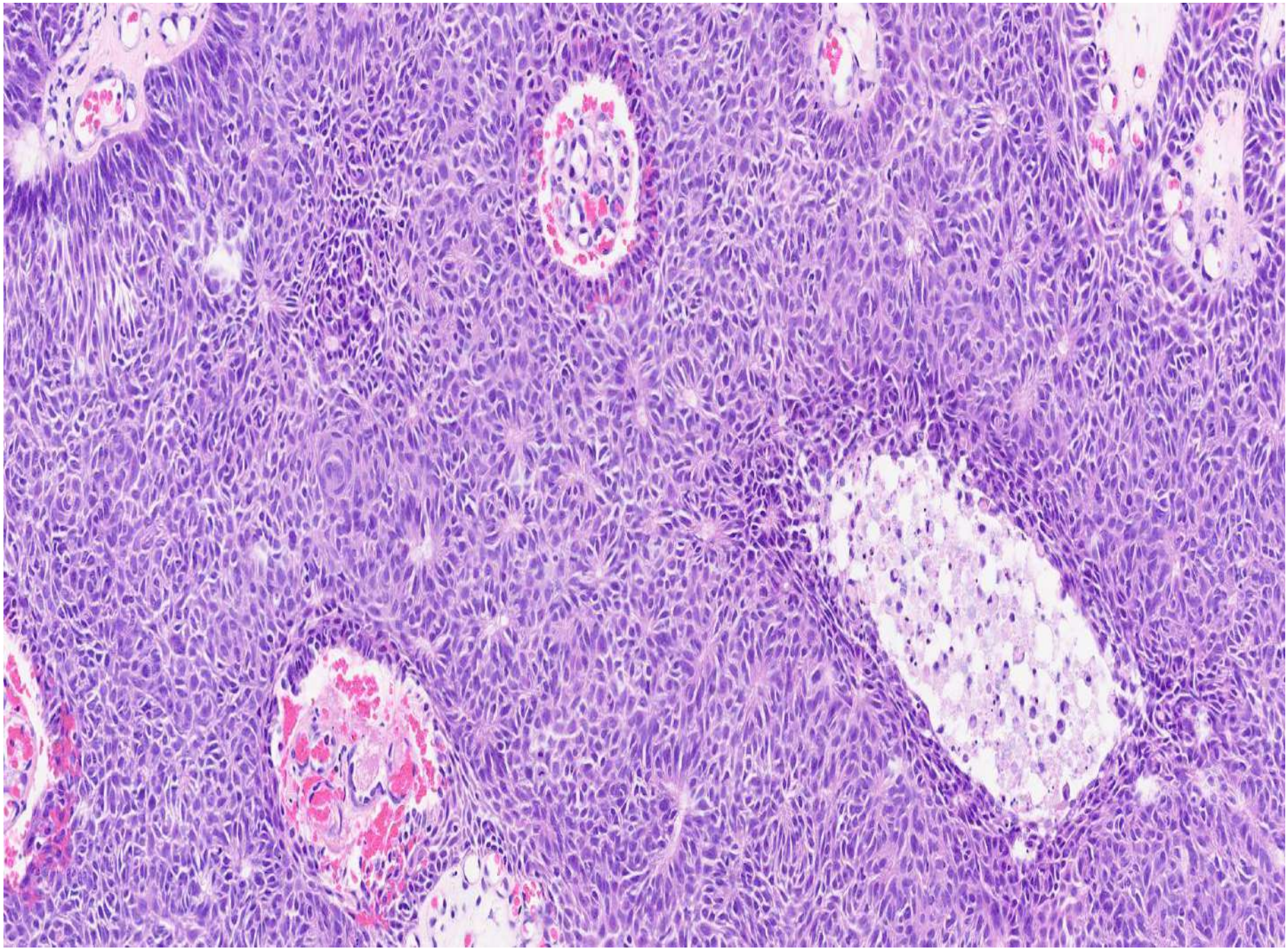

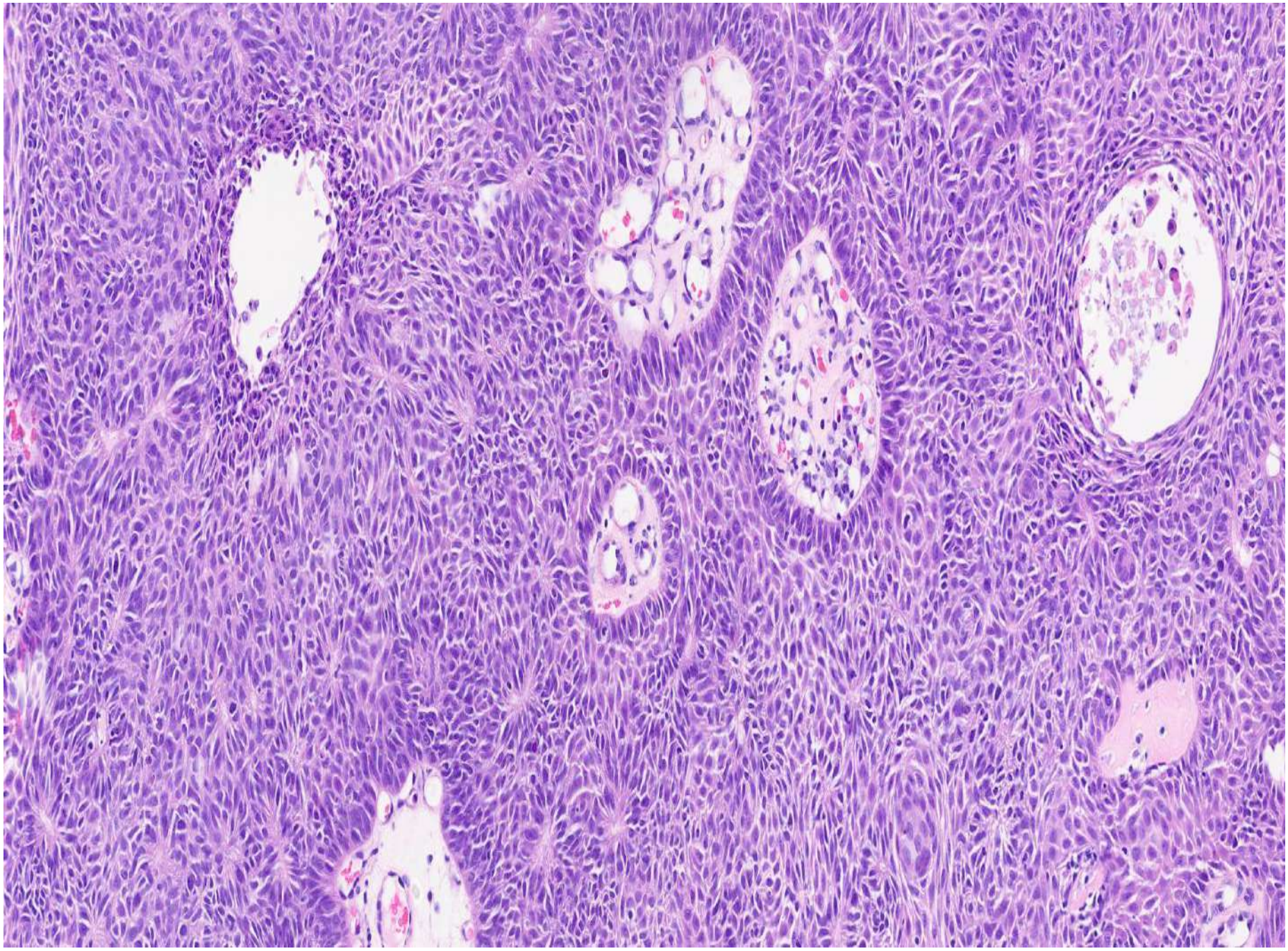

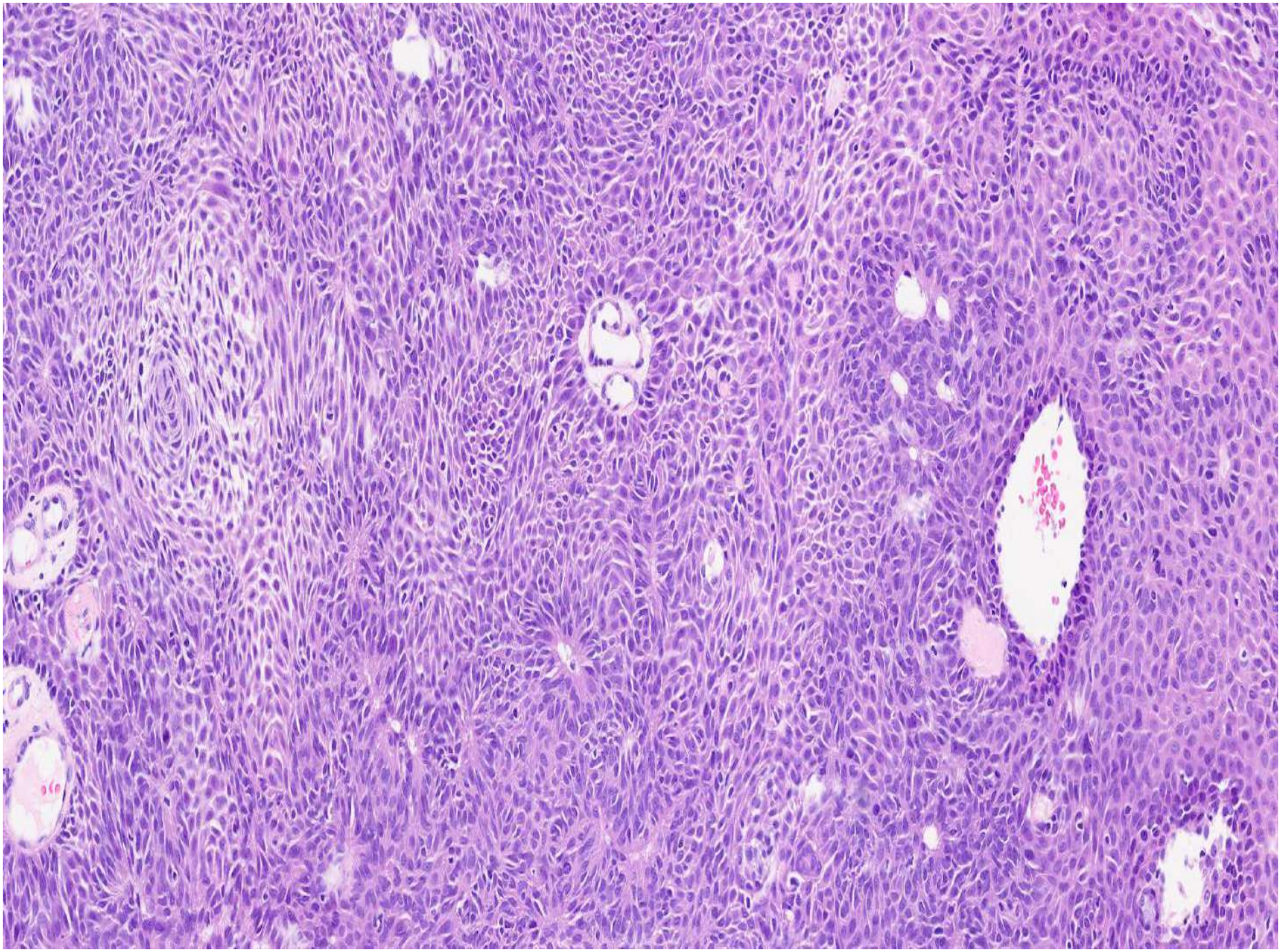

p16

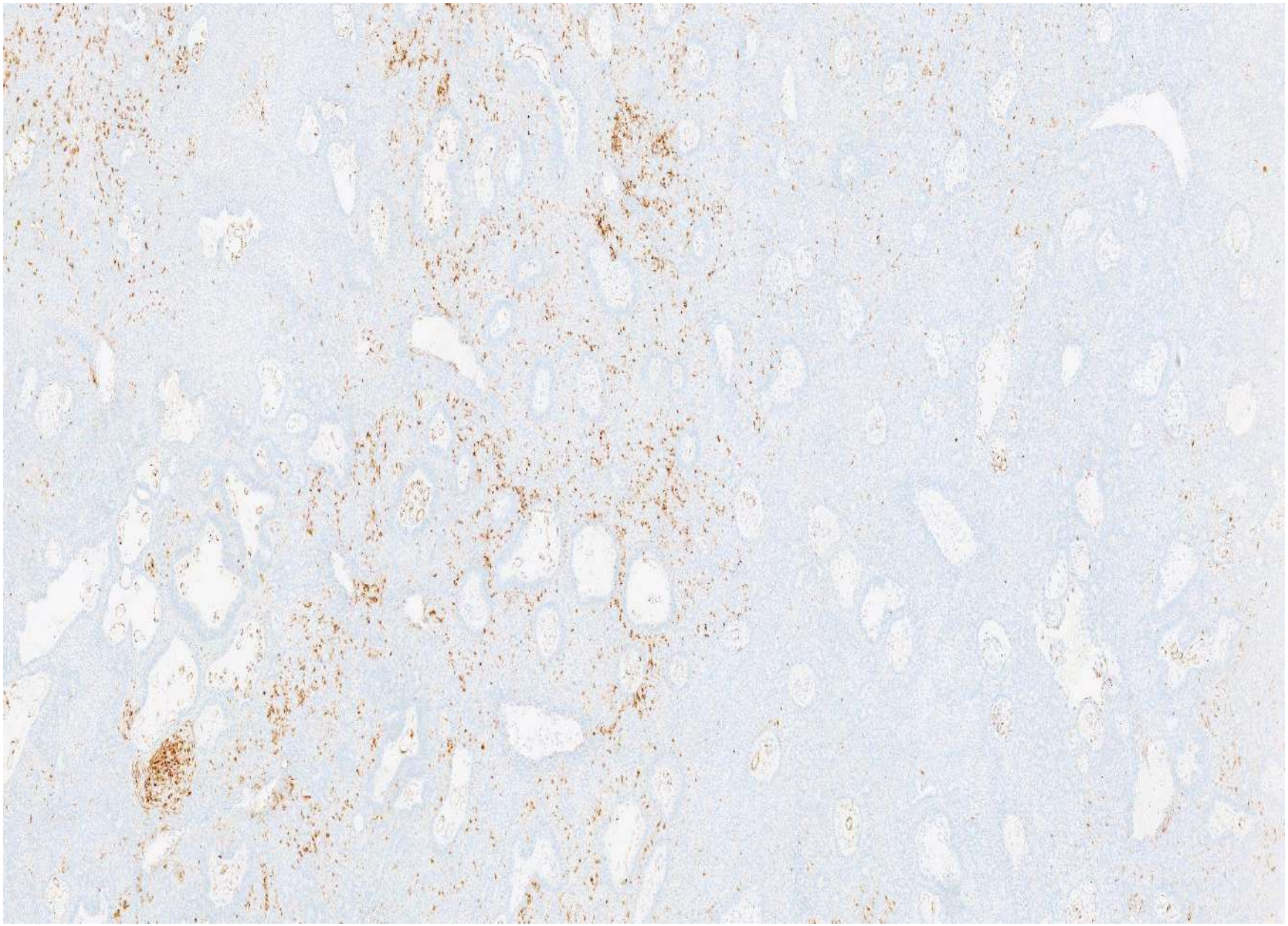

MIB1

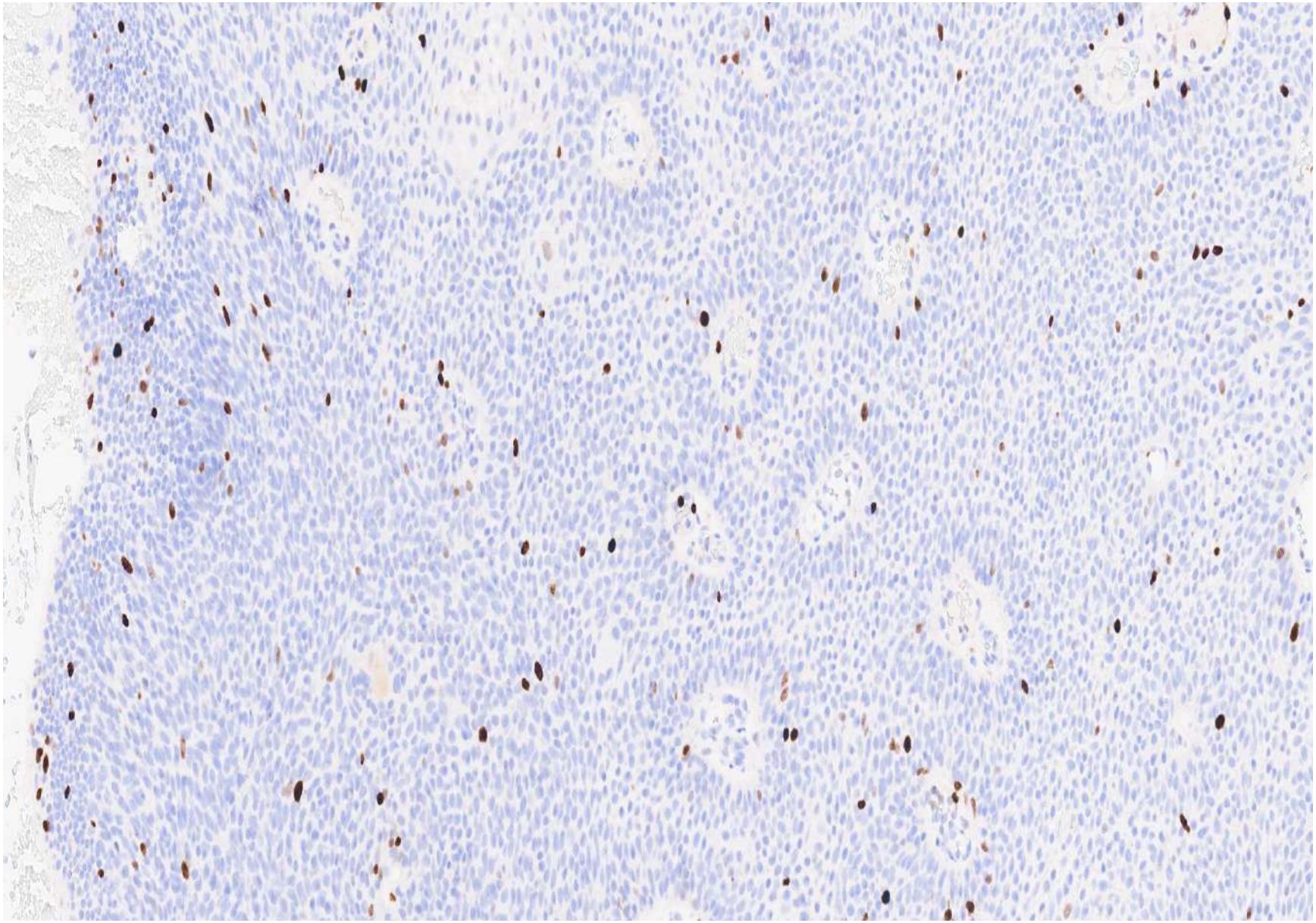

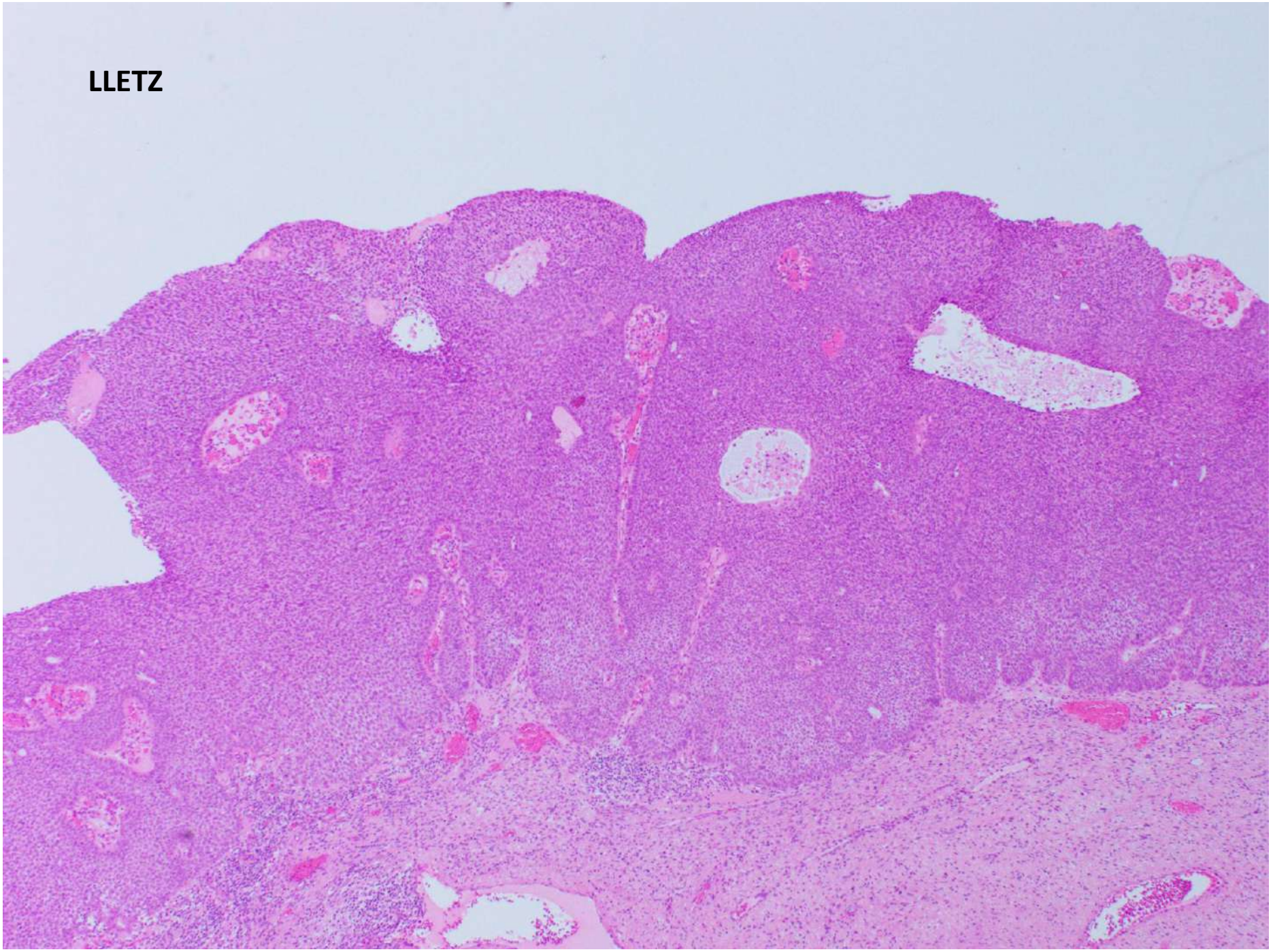
LLETZ

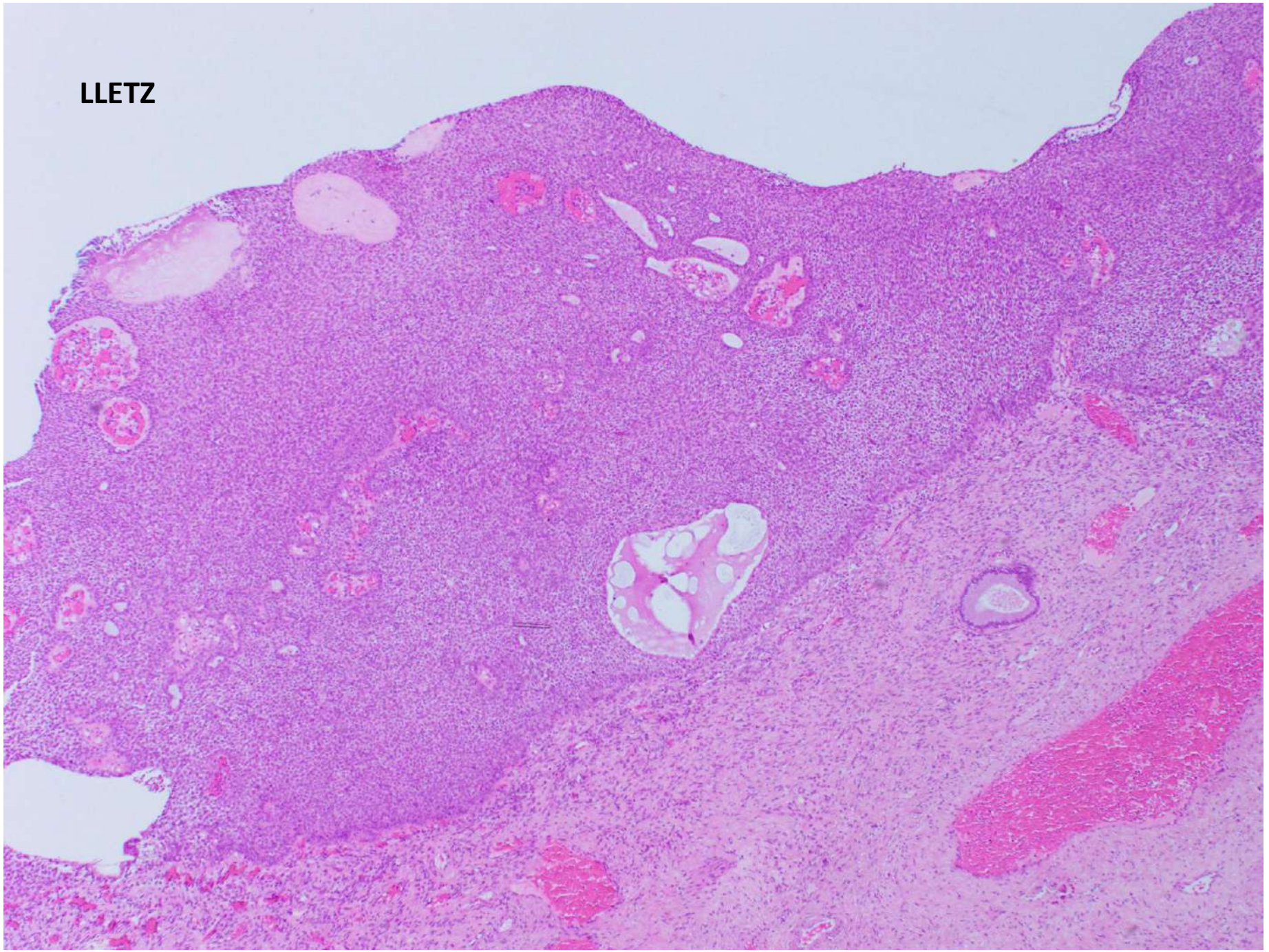
LLETZ

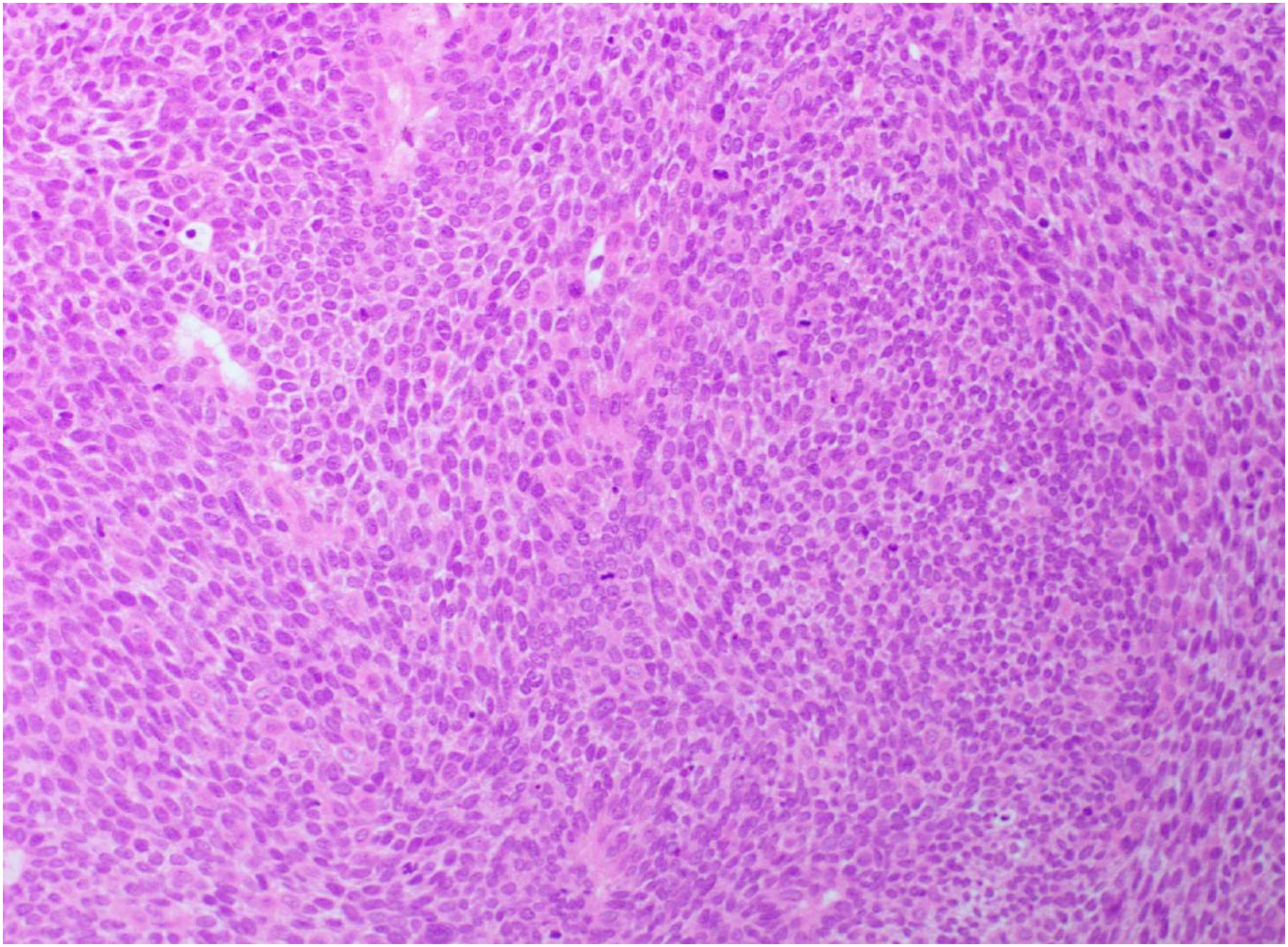

DIAGNOSIS: PMID 27792064

ORIGINAL ARTICLE

Seborrheic Keratosis-like Lesions of the Cervix and Vagina

Report of a New Entity Possibly Related to Low-risk Human Papillomavirus Infection

Karen L. Talia, FRCPA, MBBS and W. Glenn McCluggage, FRCPath†*

DIAGNOSIS- SEBORRHOEIC KERATOSIS-LIKE LESION

- AJSP (PMID 27792064)
- 7 cases (age 41-70)
- 3 cervix, 2 upper vagina, 1 cervix and vagina, 1 undetermined
- morphology-plaque-like or “stuck-on”- but this is often not appreciable on a biopsy
- interconnecting trabeculae; basaloid appearance; squamous eddies; peripheral palisading; basement membrane-like material
- limited follow-up- benign
- can be misdiagnosed as SCC (argument for doing p16 on all newly diagnosed cervical SCC, although some HPV independent cervical SCCs exist)
- EXAMPLE OF NEW ENTITIES STILL OUT THERE
- MAY BE MISDIAGNOSED AS SQUAMOUS CELL CARCINOMA

ANOTHER CASE

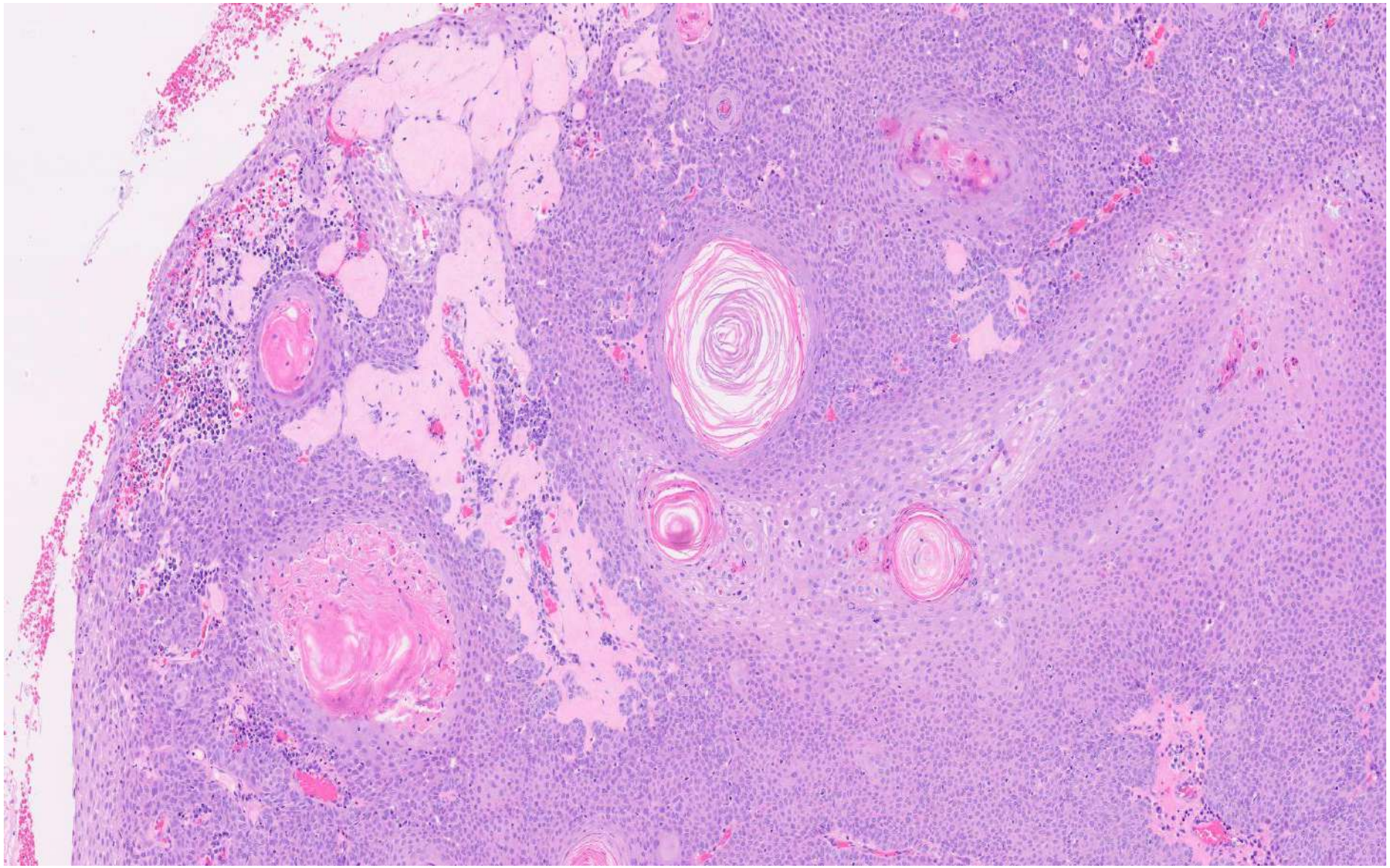

ANOTHER CASE

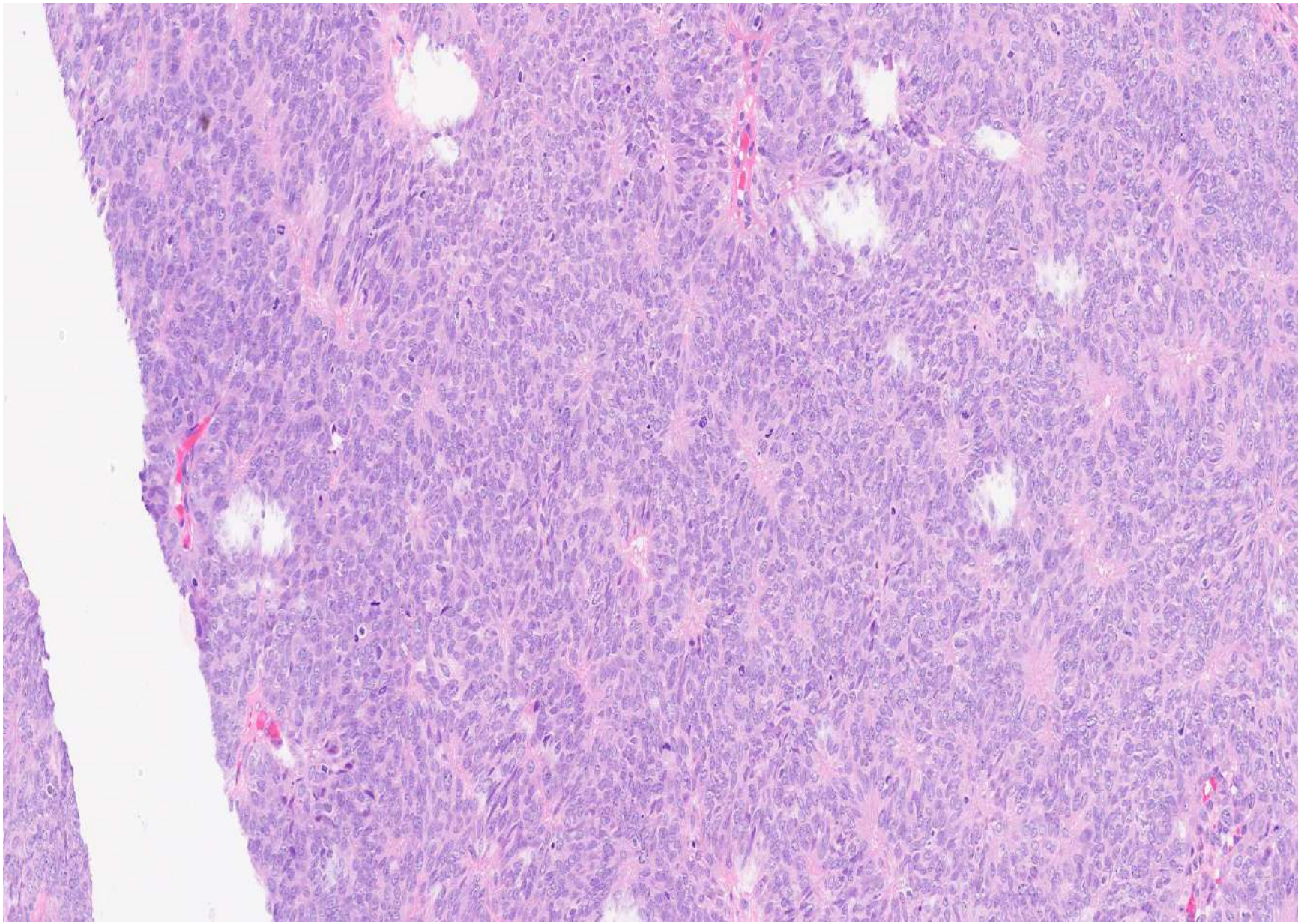

ANOTHER CASE

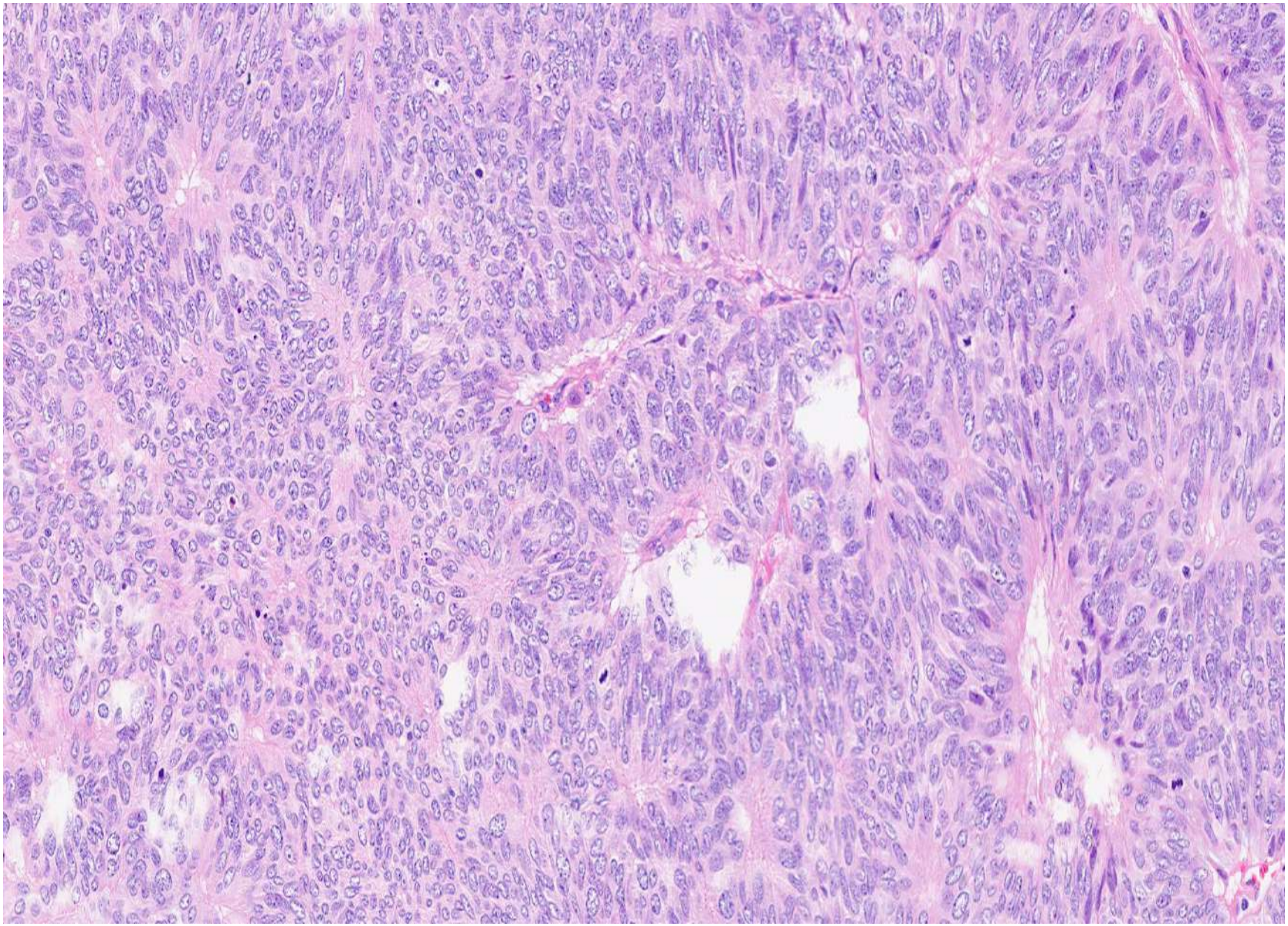

ANOTHER CASE

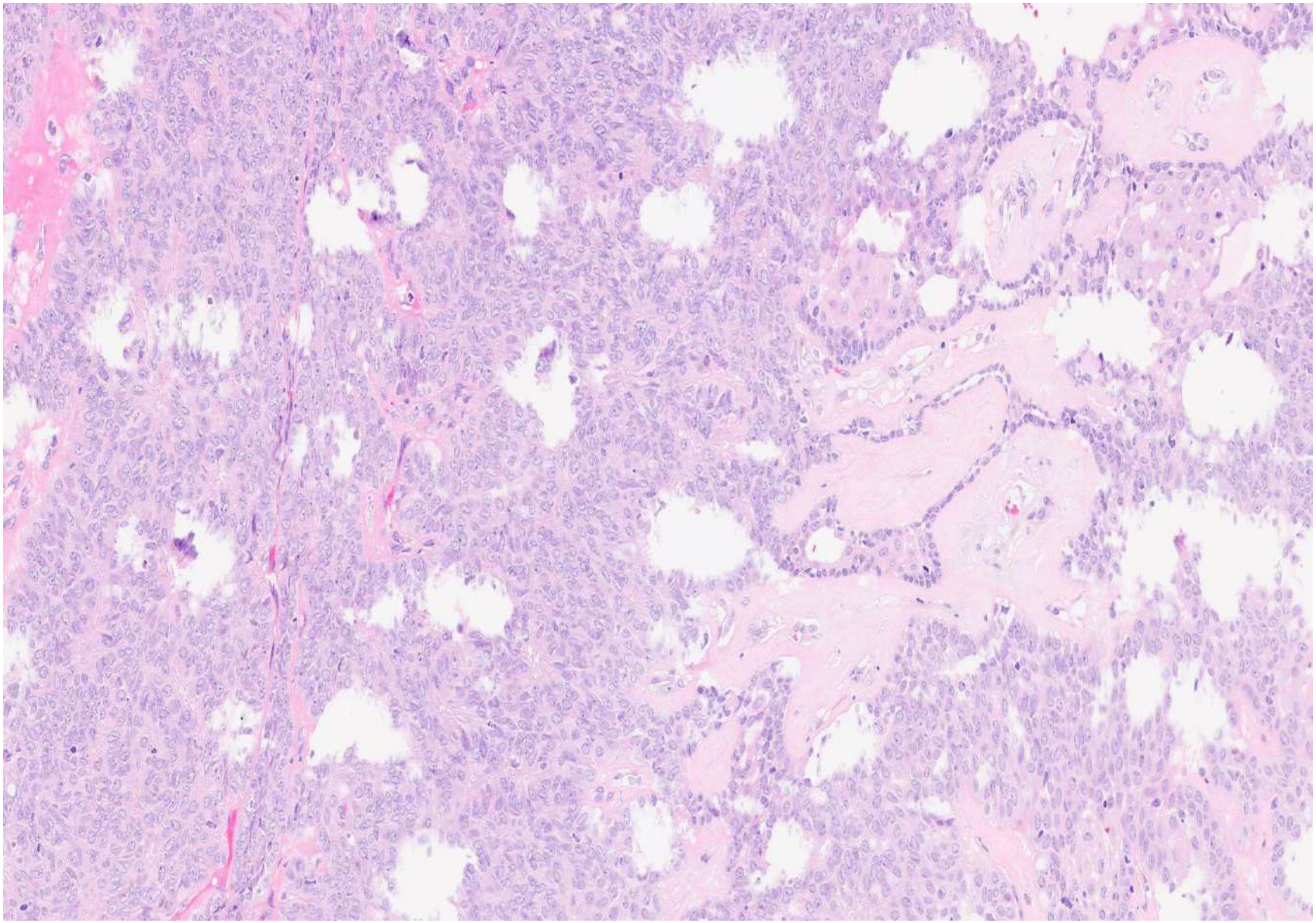

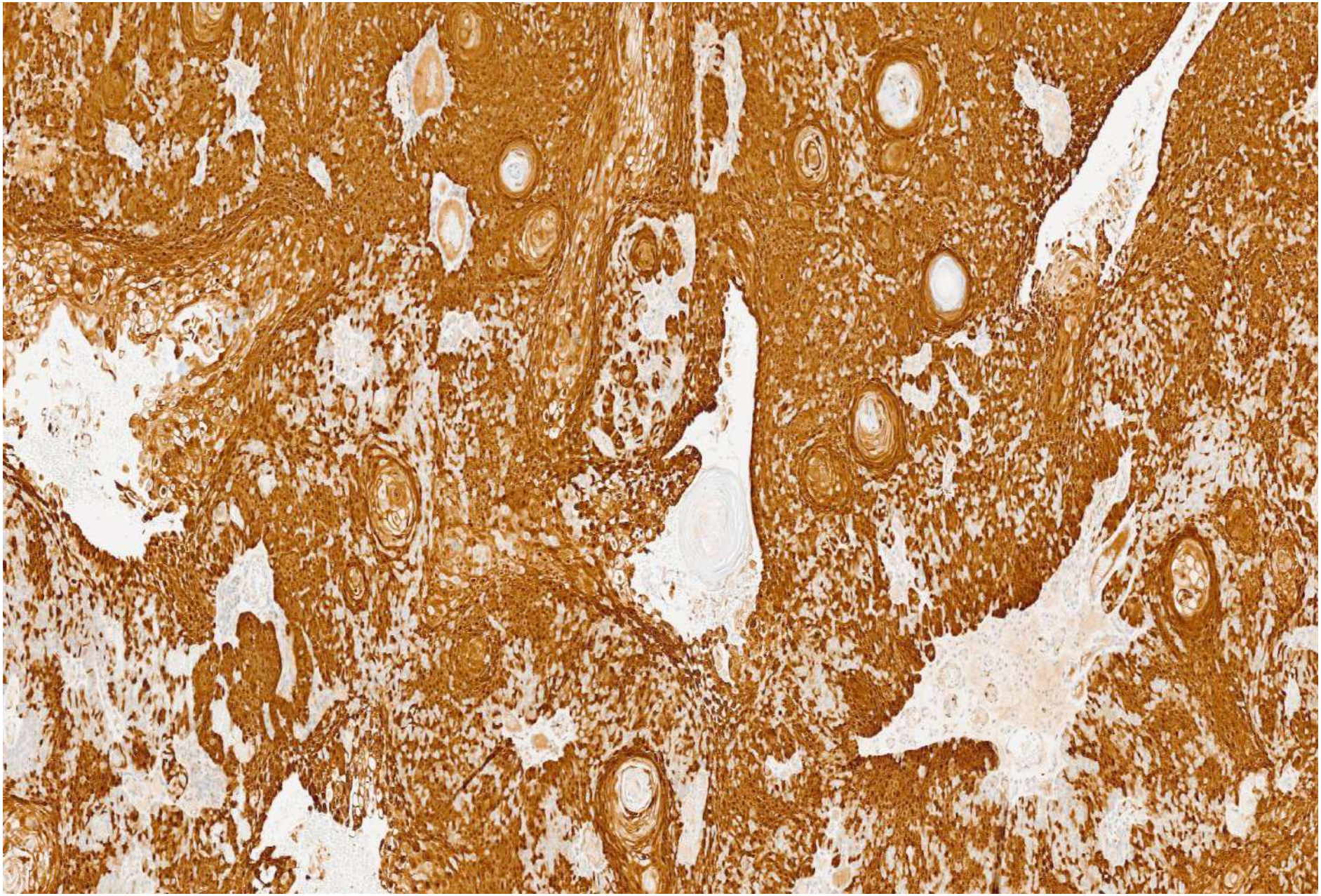

p16

PMID 40387309

ORIGINAL ARTICLE

HPV42

A Common Low-Risk HPV Type Associated With Distinctive Cervicovaginal and Cutaneous Neoplasia

Karen L. Talia, David Hawkes, PhD,†‡§ Gloria Zhang, MD,‖ Jackie Jamison, DRCPath,¶ Jennifer Shanks, MSc,¶ Bin Yang, MD, PhD,‖ Robert Soslow, MD,‖ and W. Glenn McCluggage#*

PMID 40387309

- 17 cases of SKLL
- 13 HPV42-associated (sometimes with other HPV types)
- 2 cases with high-grade areas and block-type p16
- example of unusual tumour type associated with a specific HPV type

PMID 35538210

USCAP

www.nature.com/modpathol

ARTICLE

Check for updates

Association of HPV42 with digital papillary adenocarcinoma and the use of in situ hybridization for its distinction from acral hidradenoma and diagnosis at non-acral sites

Chad Vanderbilt[1], Thomas Brenn[2], Andrea P. Moy[1], Gordon Harloe[3], Charlotte Ariyan[4], Edward Athanasian[4] and Klaus J. Busam[1]✉

© The Author(s), under exclusive licence to United States & Canadian Academy of Pathology 2022

CASE 7

- F 35
- LLETZ for CIN III/ HSIL



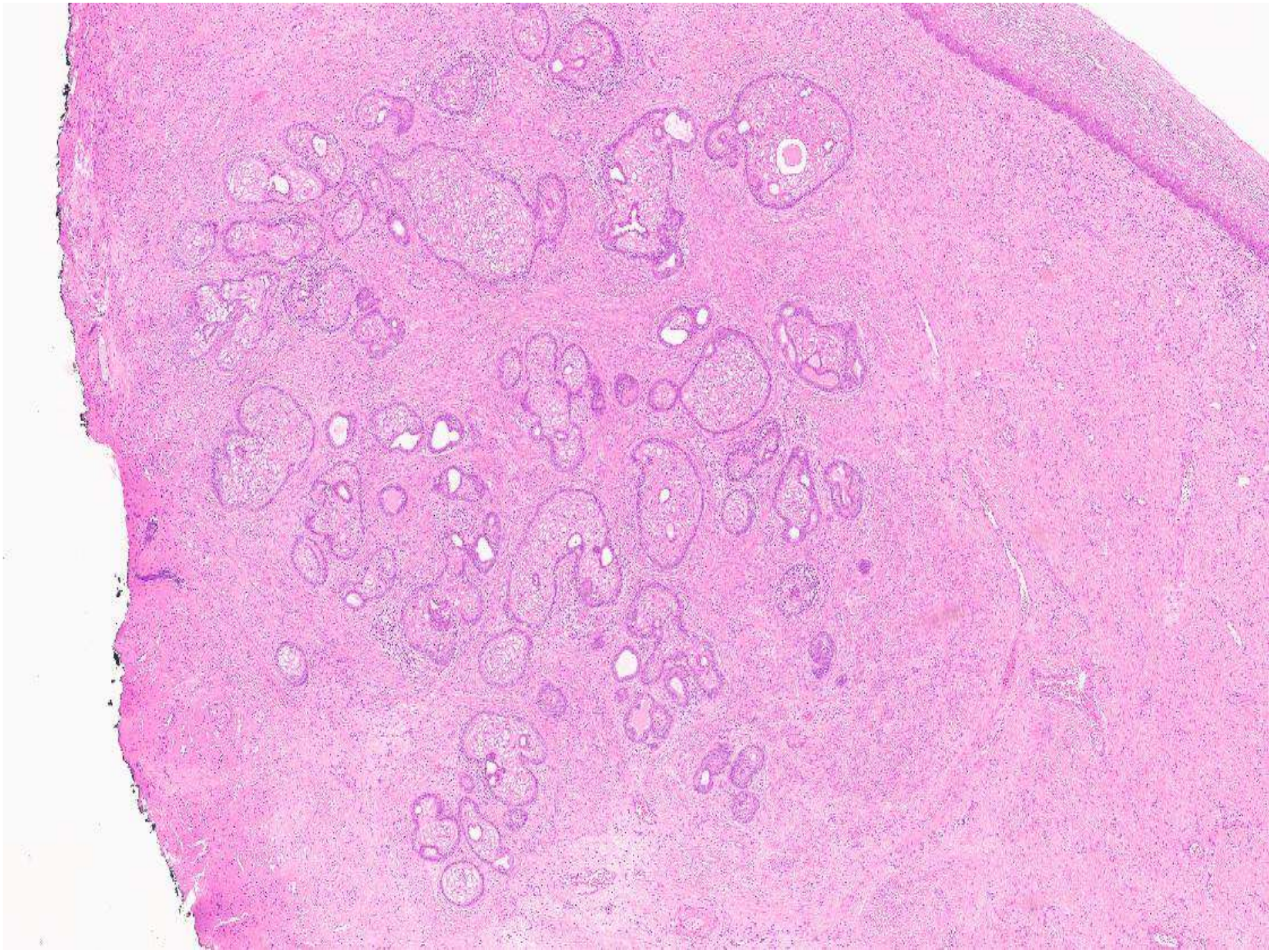

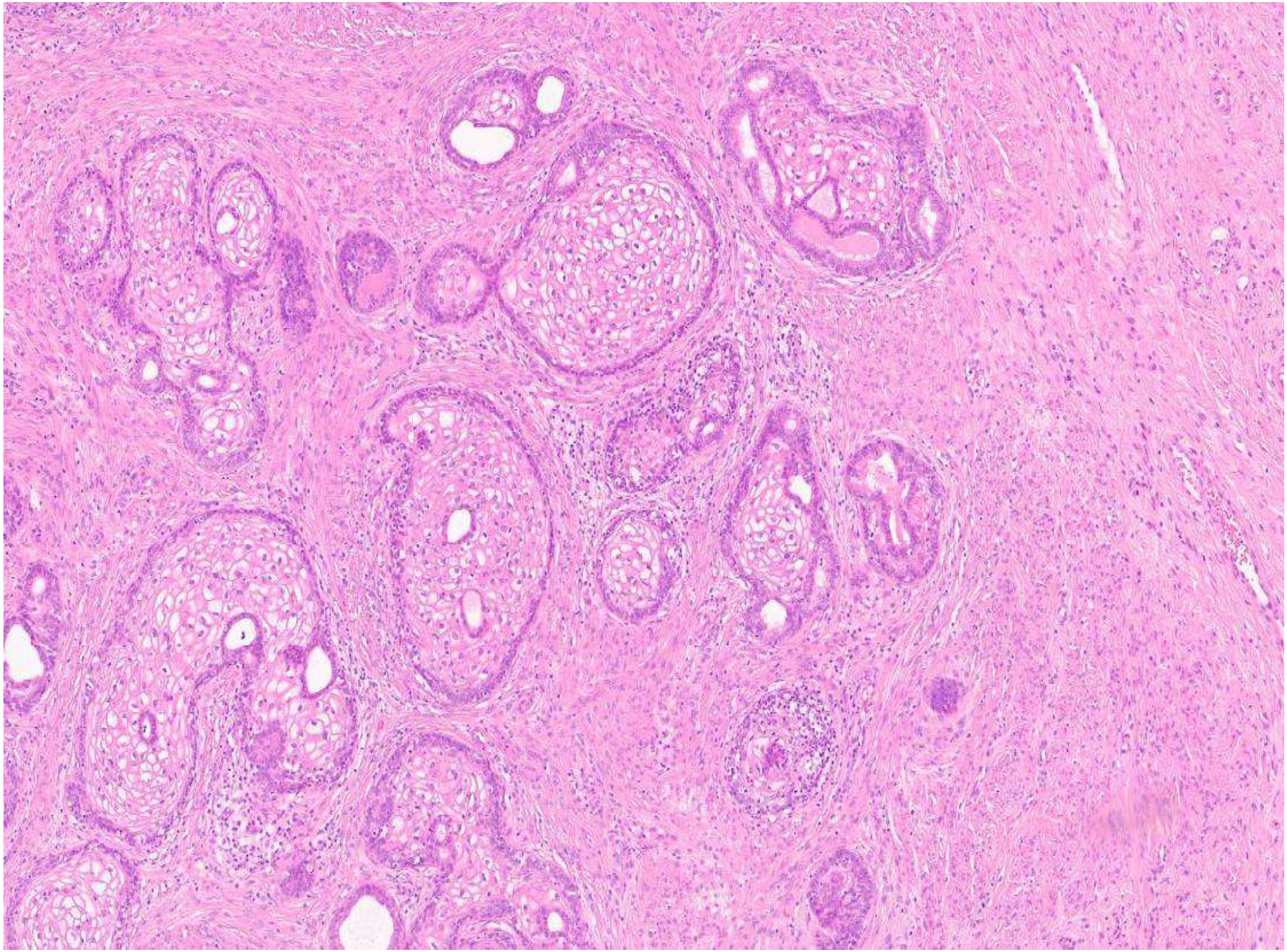

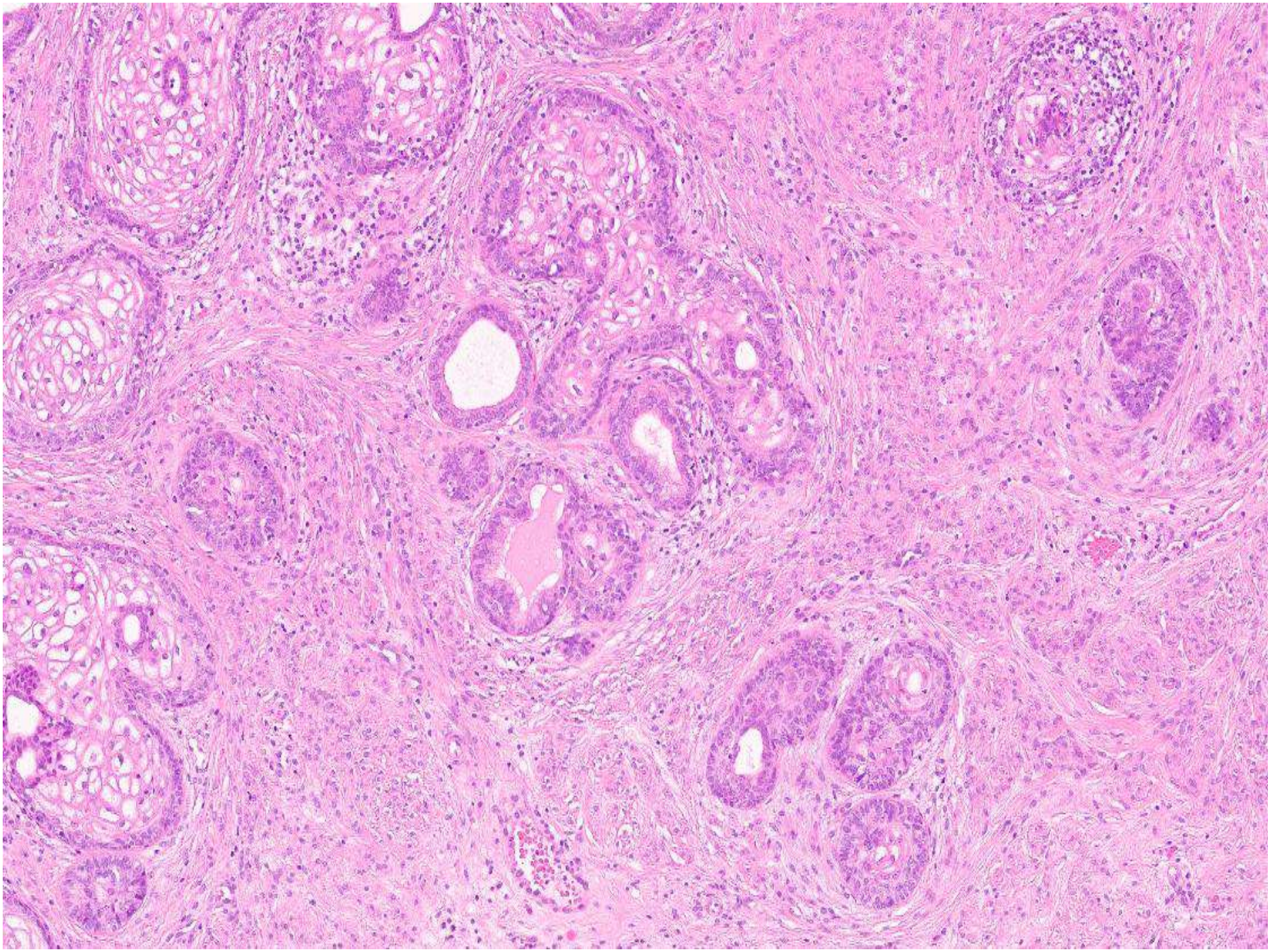

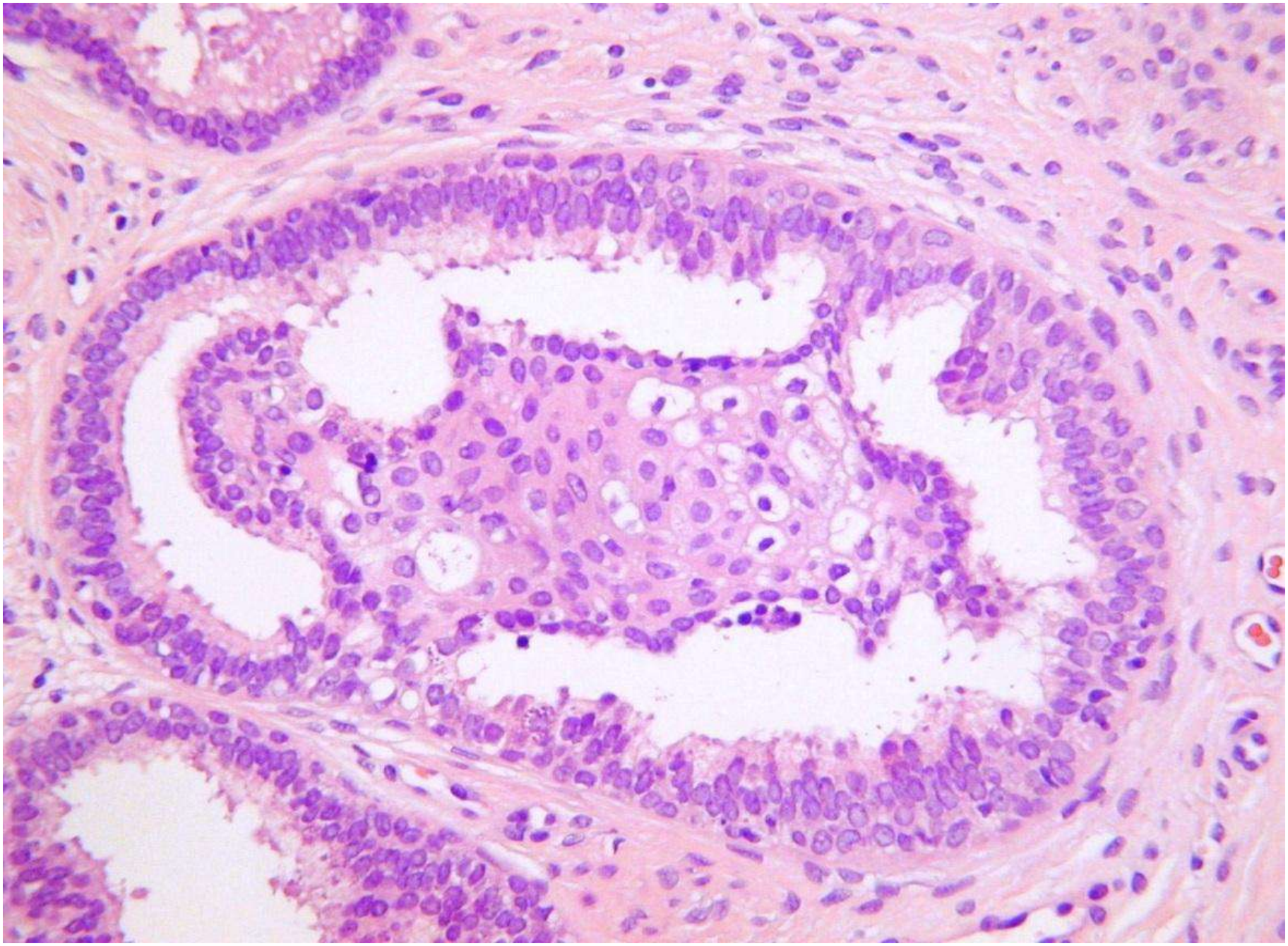

DIAGNOSIS- “ECTOPIC” PROSTATIC TISSUE IN CERVIX

- AJSP 2006;30;209-215
- usually incidental microscopic finding
- ? developmental anomaly, ? metaplasia of endocervical glands (but usually in ectocervical stroma)
- positive with PSA and PSAP (often focal; can be negative; PSAP more likely to be positive than PSA)
- positive with NKX3.1
- MAY BE MISDIAGNOSED AS ADENOCARCINOMA

IMMUNOHISTOCHEMISTRY

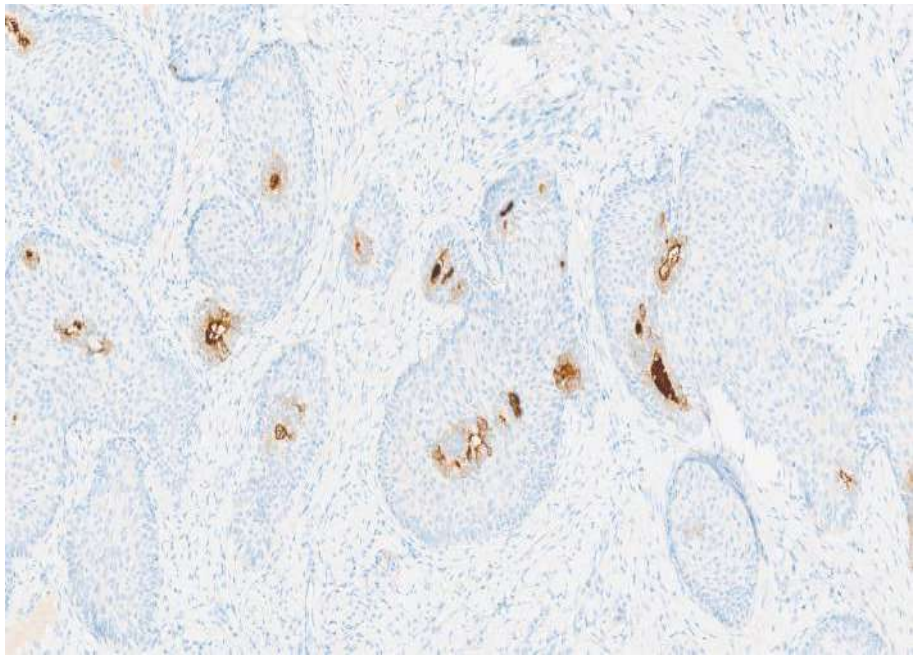

PSAP

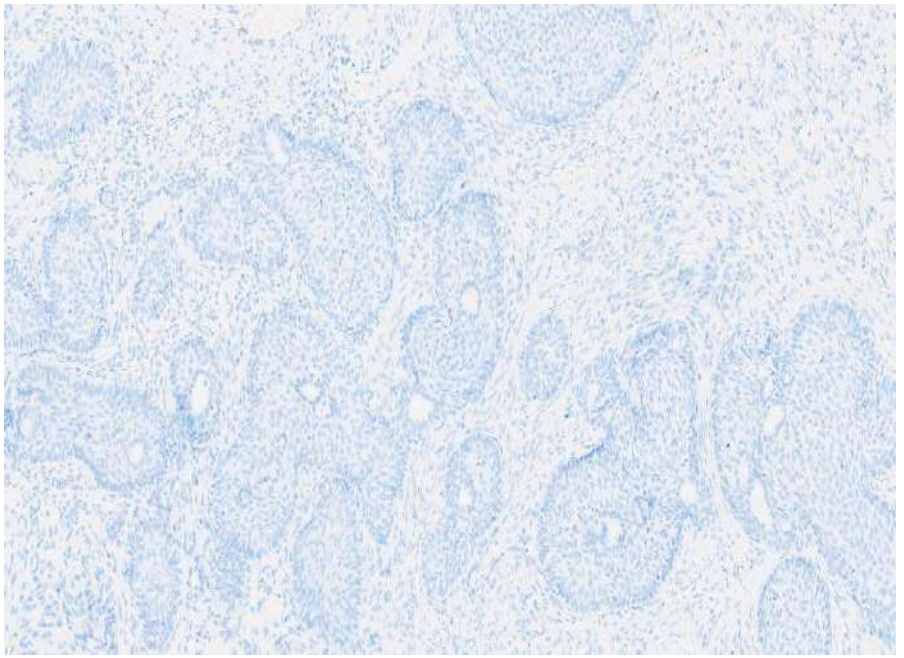

PSA

NKX3.1

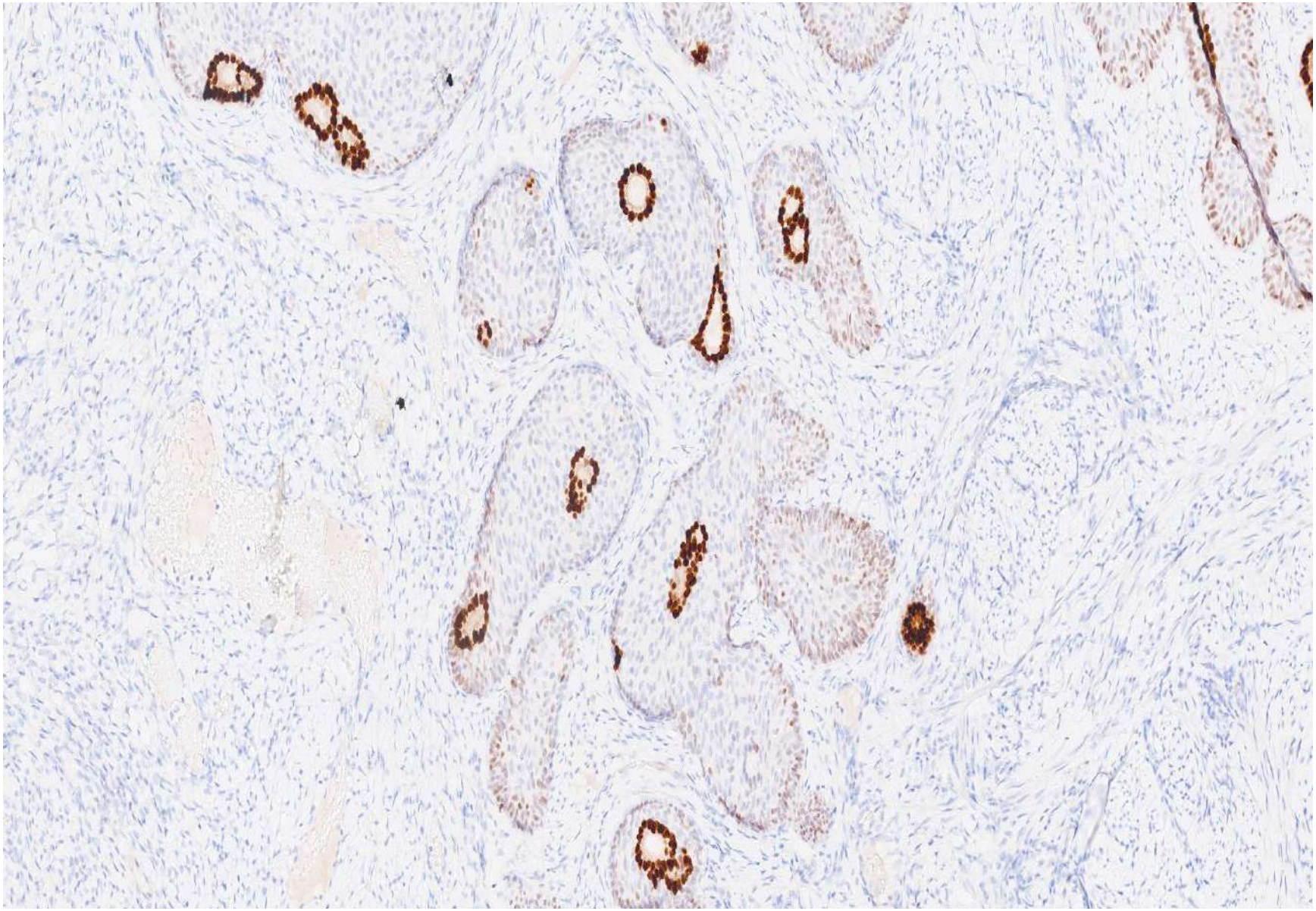

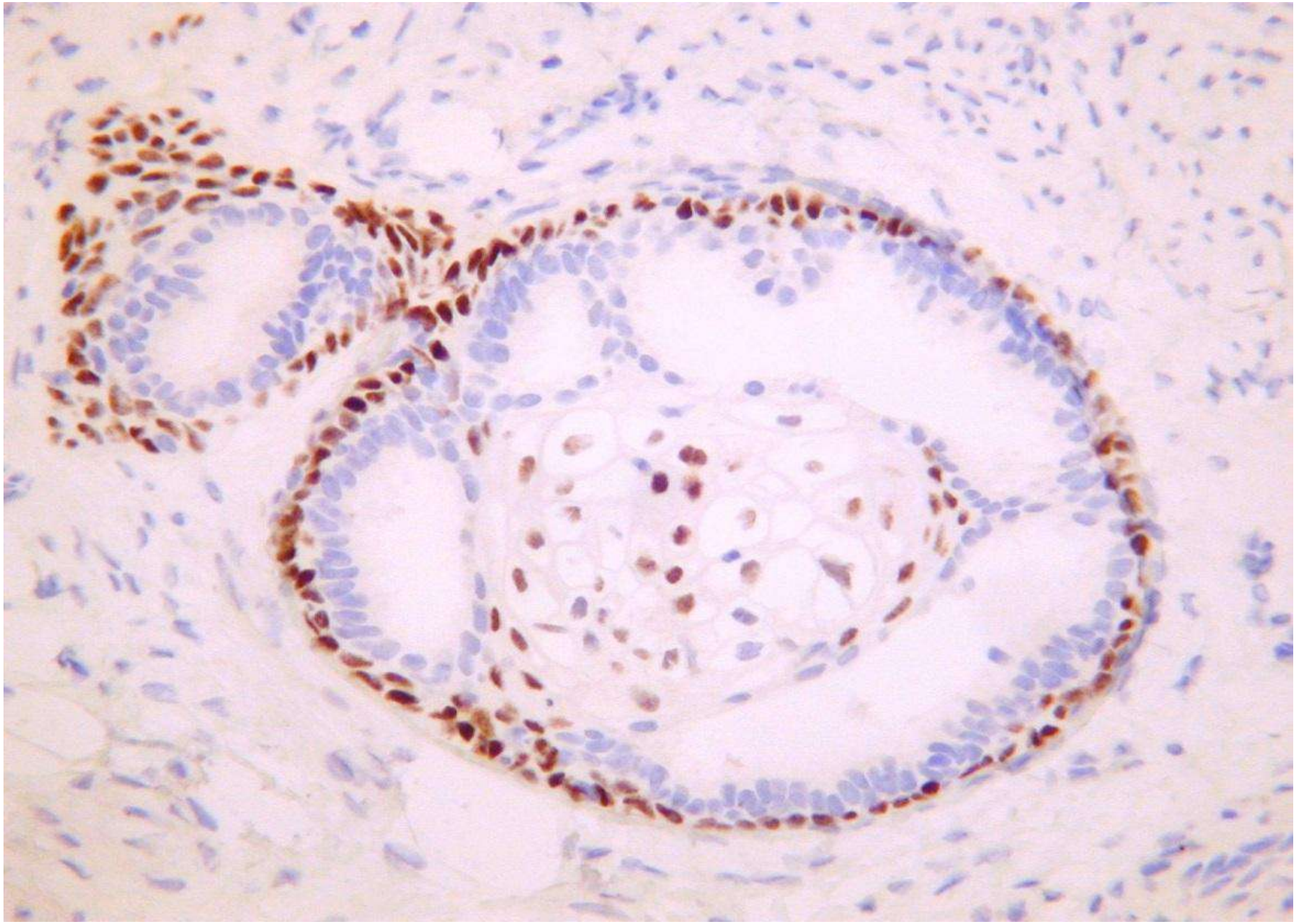

p63

ECTOPIC PROSTATIC TISSUE CERVIX

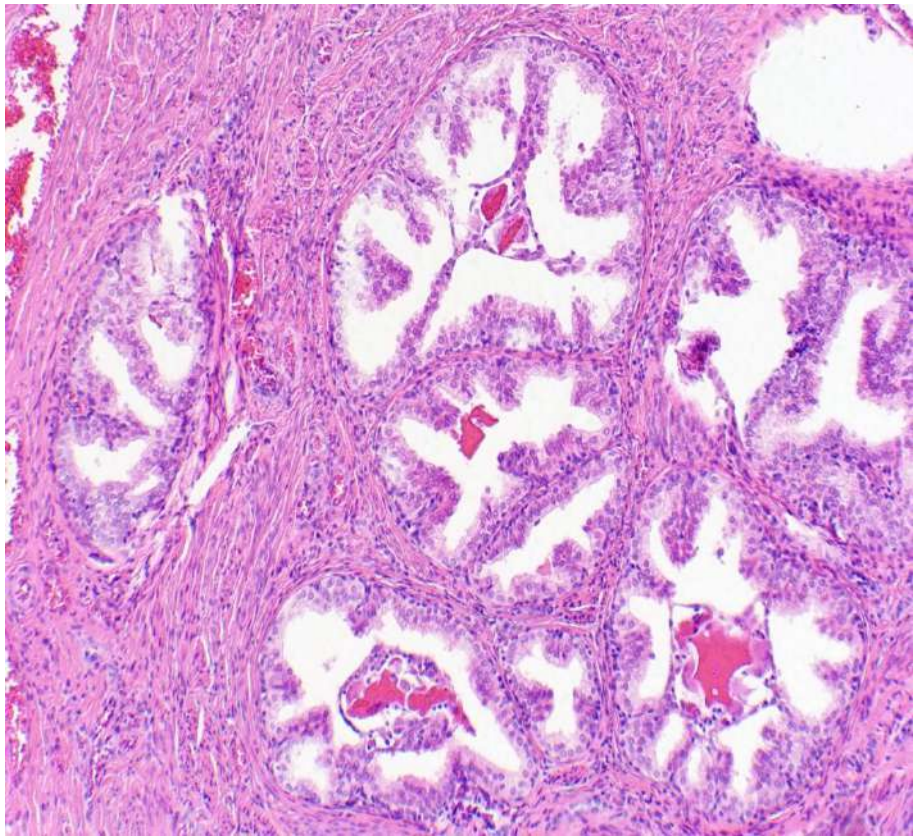

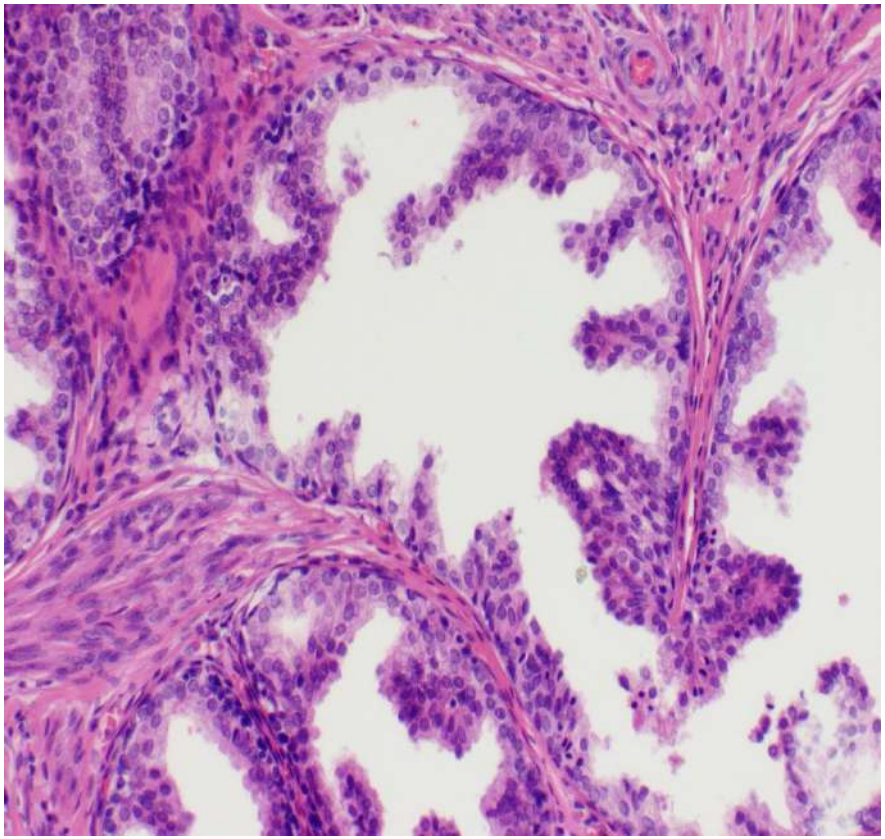

PMID: 17592267

ORIGINAL ARTICLE

Tubulo-squamous Polyp

A Report of Ten Cases of a Distinctive Hitherto Uncharacterized Vaginal Polyp

W. Glenn McCluggage, FRCPath and Robert H. Young, MD†*

Abstract: We report 10 cases of a morphologically distinct vaginal polyp which has hitherto not been characterized. The polyps occurred in women aged 39 to 78 years (most were postmenopausal) and were from 1.0 to 3.0 cm. Most of whose

Key Words: vagina, polyp, immunohistochemistry, prostatic acid phosphatase, prostate-specific antigen, differential diagnosis

(*Am J Surg Pathol* 2007;31:1013–1019)

TUBULOSQUAMOUS POLYP OF VAGINA (AJSP 2007;31;1013-1019)

- characteristic vaginal polyp
- mostly in upper vagina

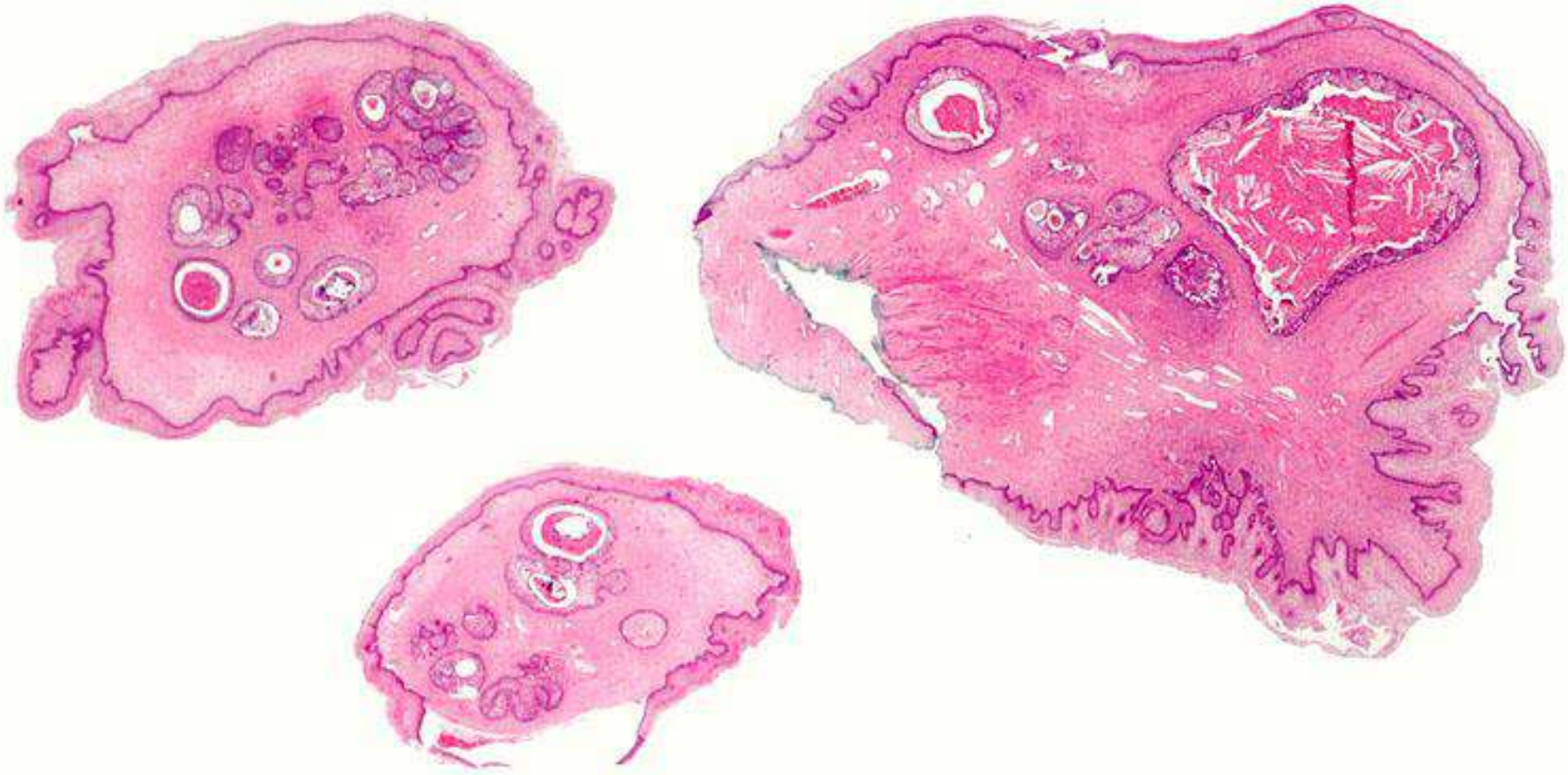



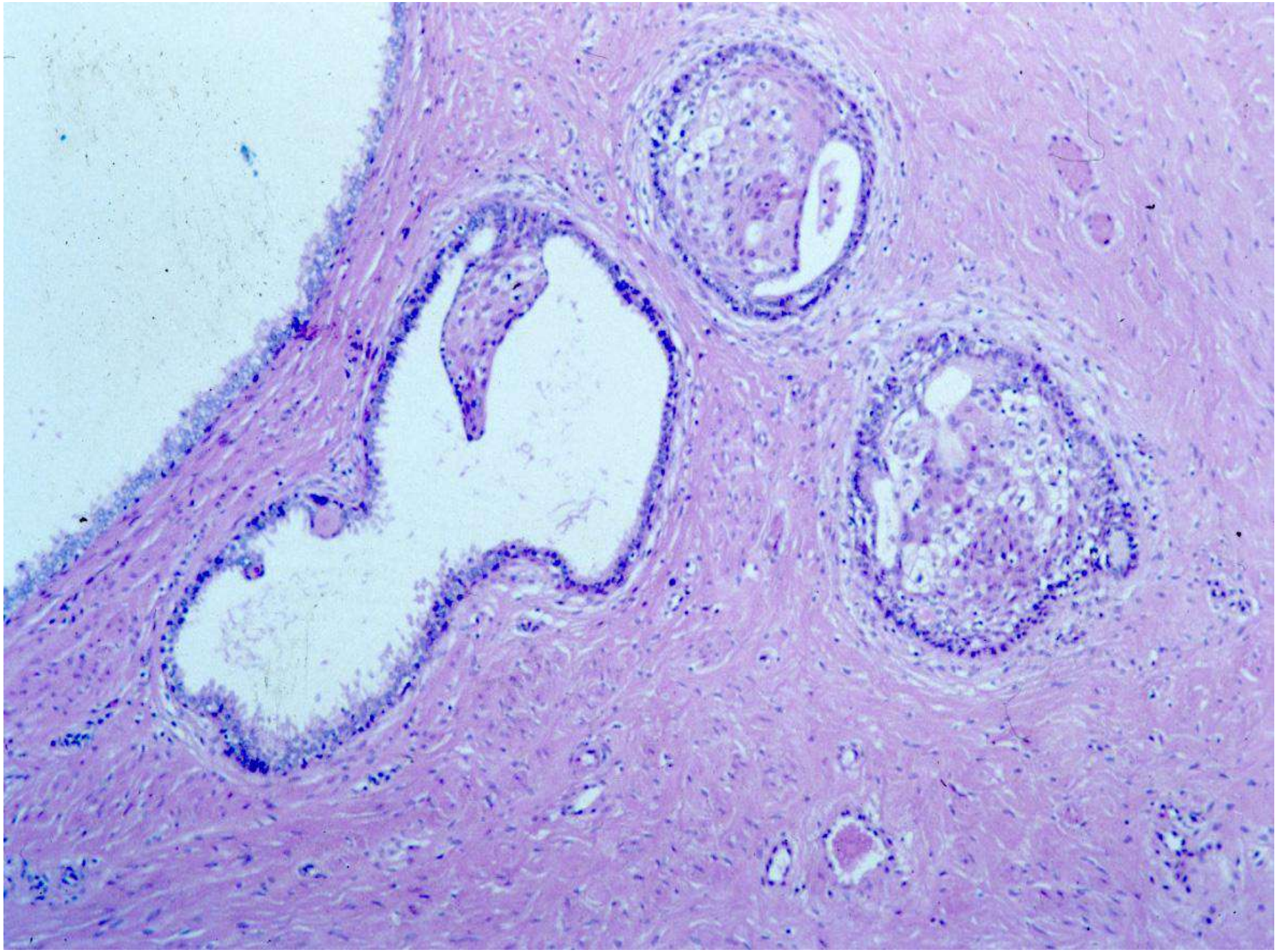

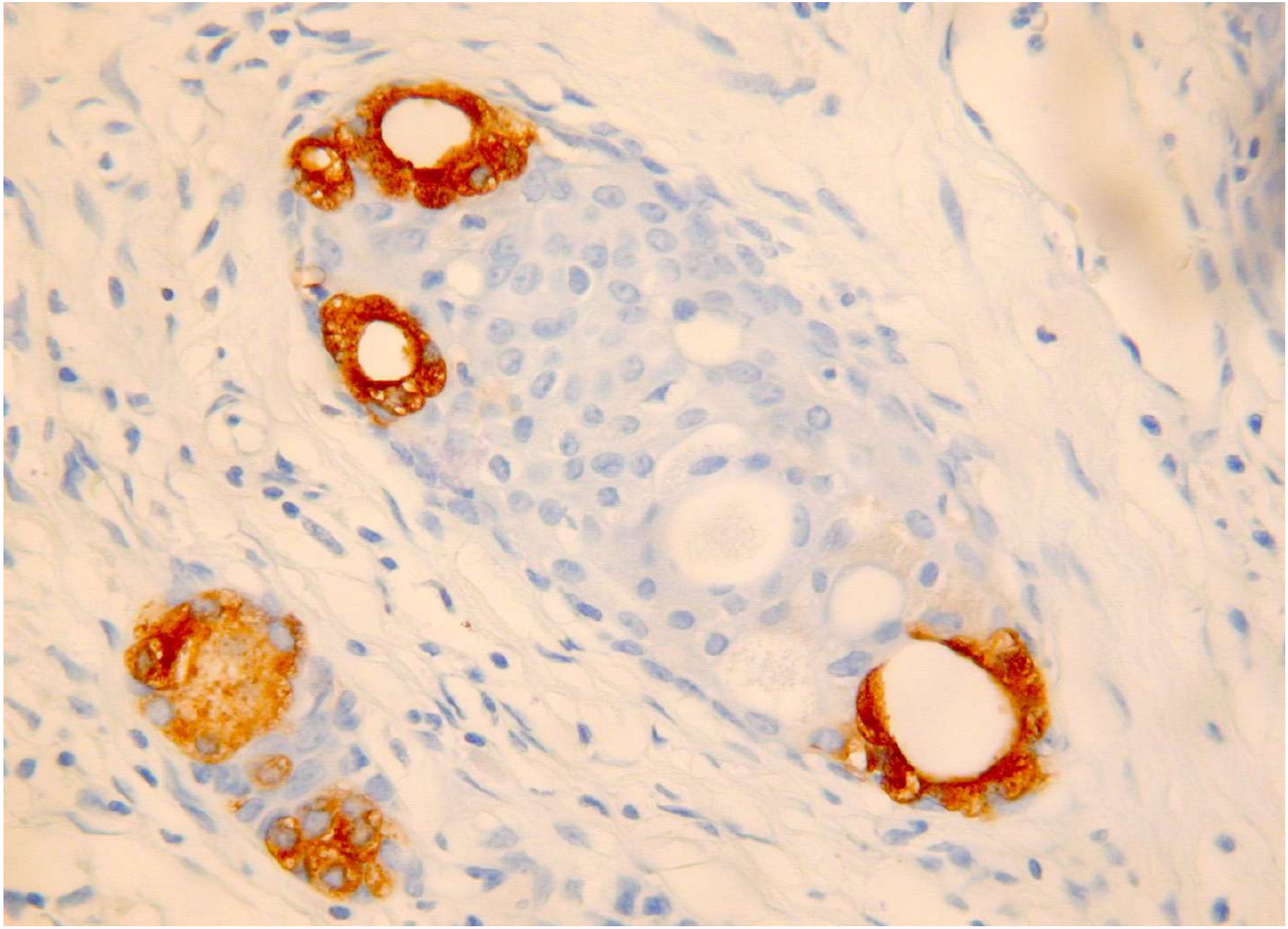

PSAP

NKX3.1 IN TUBULOSQUAMOUS POLYP

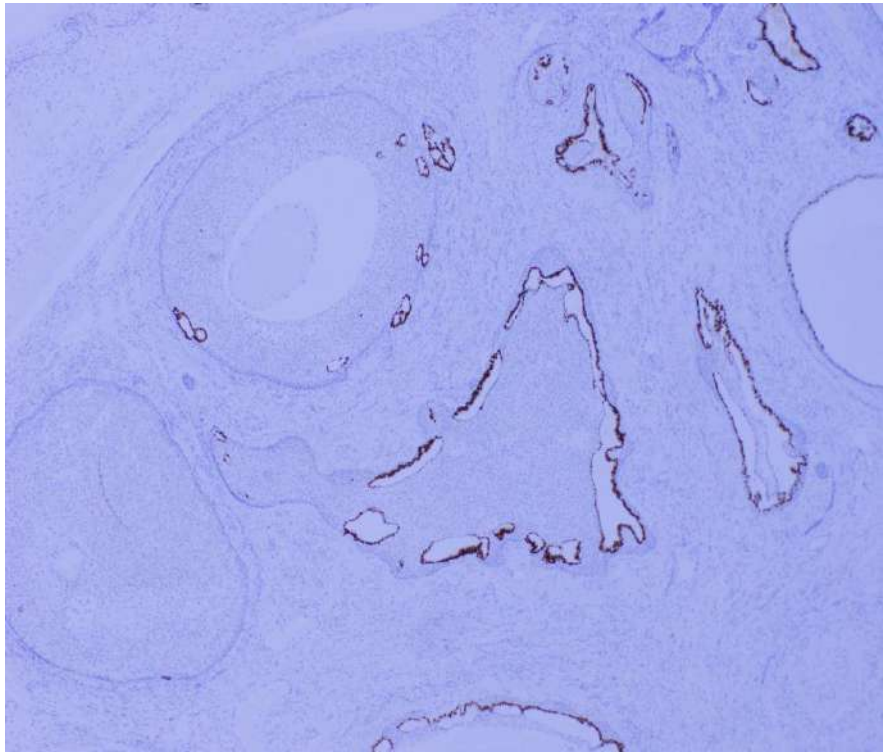

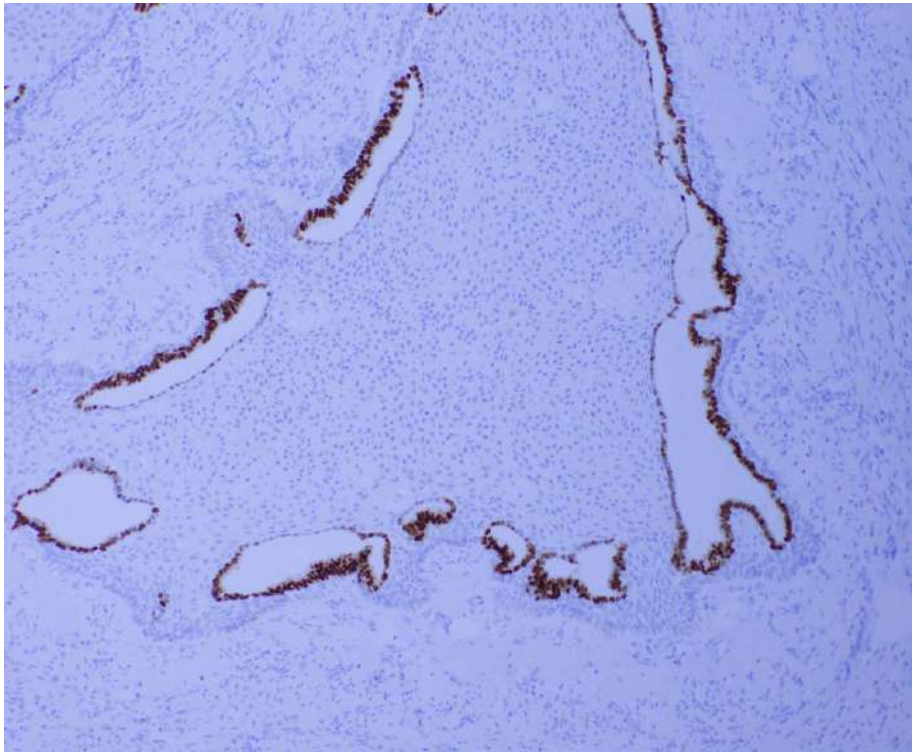

PMID 21979599

International Journal of Gynecological Pathology
30:605–612, Lippincott Williams & Wilkins, Baltimore
© 2011 International Society of Gynecological Pathologists

Original Article

Misplaced Skene's Glands: Glandular Elements in the Lower Female Genital Tract That Are Variably Immunoreactive With Prostate Markers and That Encompass Vaginal Tubulosquamous Polyp and Cervical Ectopic Prostatic Tissue

Paul Kelly, F.R.C.Path., Hilary A. McBride, F.I.B.M.S., Kathryn Kennedy, F.I.B.M.S., Lynette E. Connolly, F.I.B.M.S., and W.Glenn McCluggage, F.R.C.Path.

UNIFYING THEORY

- IJGP 2011;30;605-612 (PMID 21979599)
- vaginal tubulosquamous polyp and ectopic prostatic tissue in cervix are same lesion
- probably derived from paraurethral Skene's glands (female equivalent of prostatic glands in male)
- occasionally also see in vulva

PMID: 32282346

ORIGINAL ARTICLE

Prostatic Metaplasia of the Vagina and Uterine Cervix

An Androgen-associated Glandular Lesion of Surface Squamous Epithelium

William J. Anderson, MBChB,† David L. Kolin, MD, PhD,† Grace Neville, MB BCh,† David A. Diamond, MD,‡ Christopher P. Crum, MD,† Michelle S. Hirsch, MD, PhD,† and Sara O. Vargas, MD*†*

PMID: 32282346

- Patients with androgen excess; mainly male to female transgender patients receiving exogenous testosterone; also various congenital disorders associated with androgen excess
- May involve cervix or vagina
- Proposed term “androgen associated prostatic metaplasia”
- In many cases, glands involve basal layer of squamous epithelium suggesting that they arise in-situ here

PMID: 34664289

Histopathology

Histopathology 2022, 80, 946–953. DOI: 10.1111/his.14587

Surface prostatic metaplasia, transitional cell metaplasia and superficial clusters of small basophilic cells in the uterine cervix: prevalence in gender-affirming hysterectomies and comparison with benign hysterectomies from cisgender women

Emily R McMullen-Tabry,[1] Andrew P Sciallis[2] & Stephanie L Skala[2,3]

[1]*Grand Traverse Pathology, PLLC, Traverse City, MI, USA,* [2]*Department of Pathology, and* [3]*Rogel Cancer Center, University of Michigan, Ann Arbor, MI, USA*

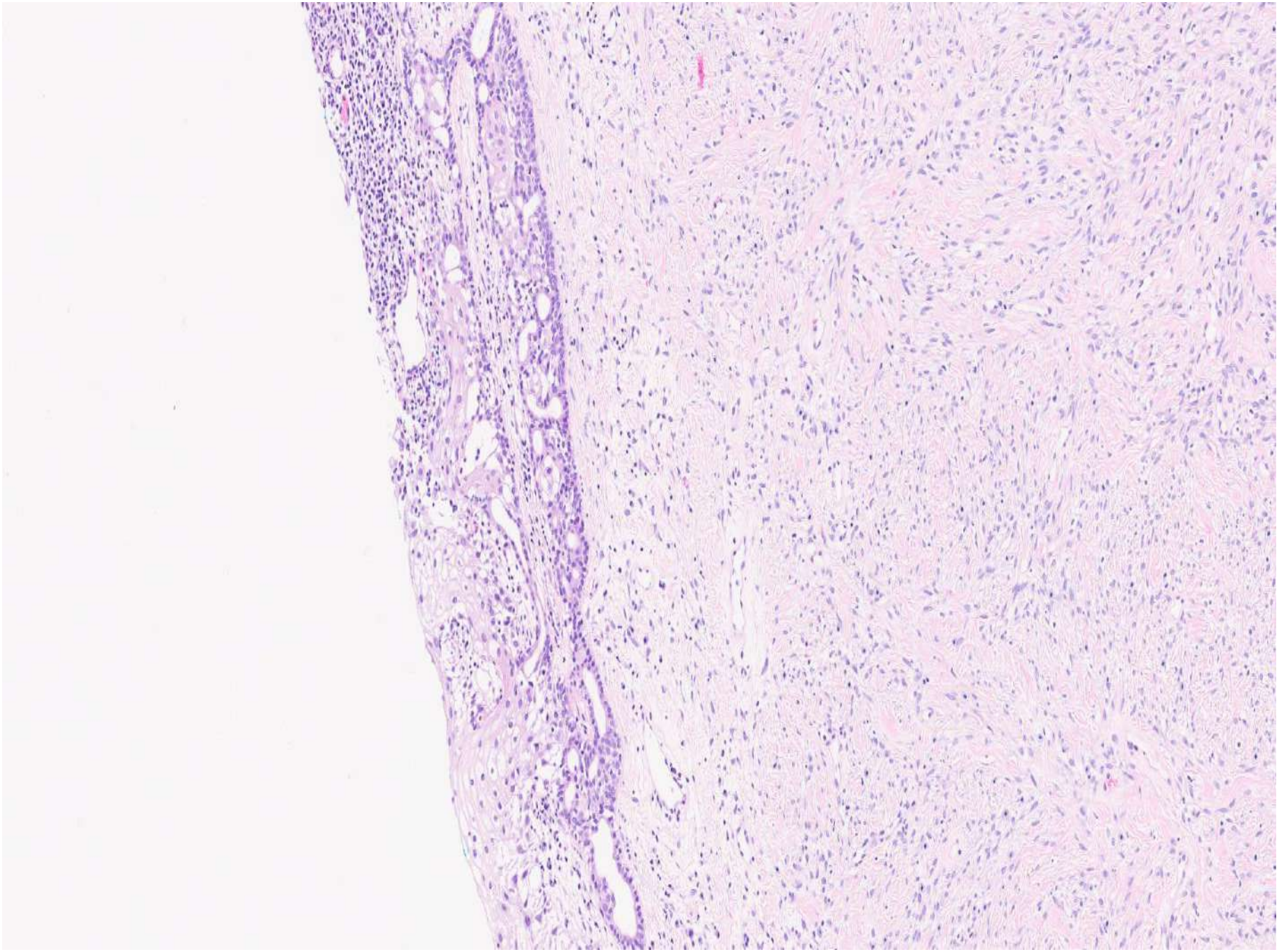

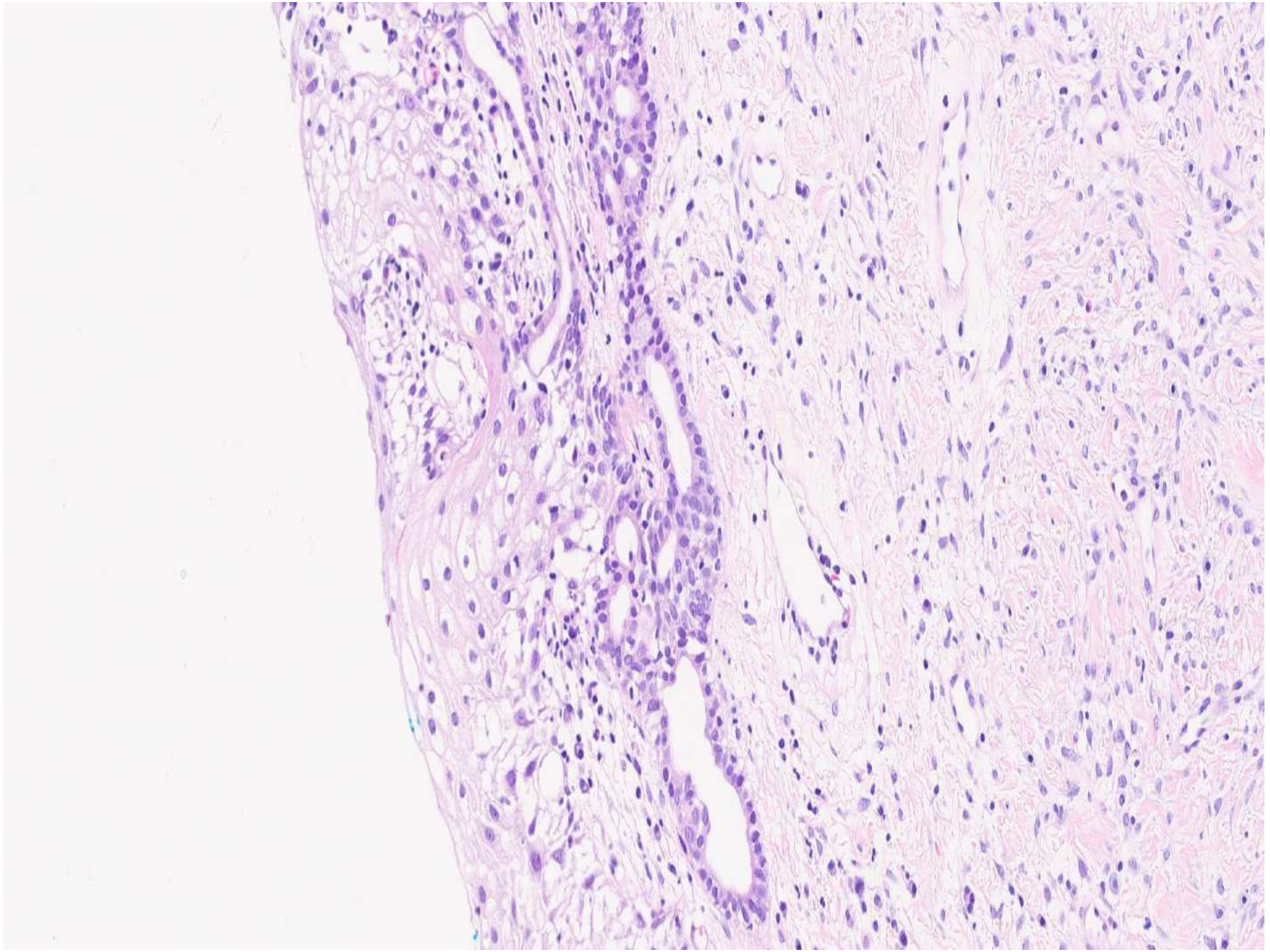

NKX3.1

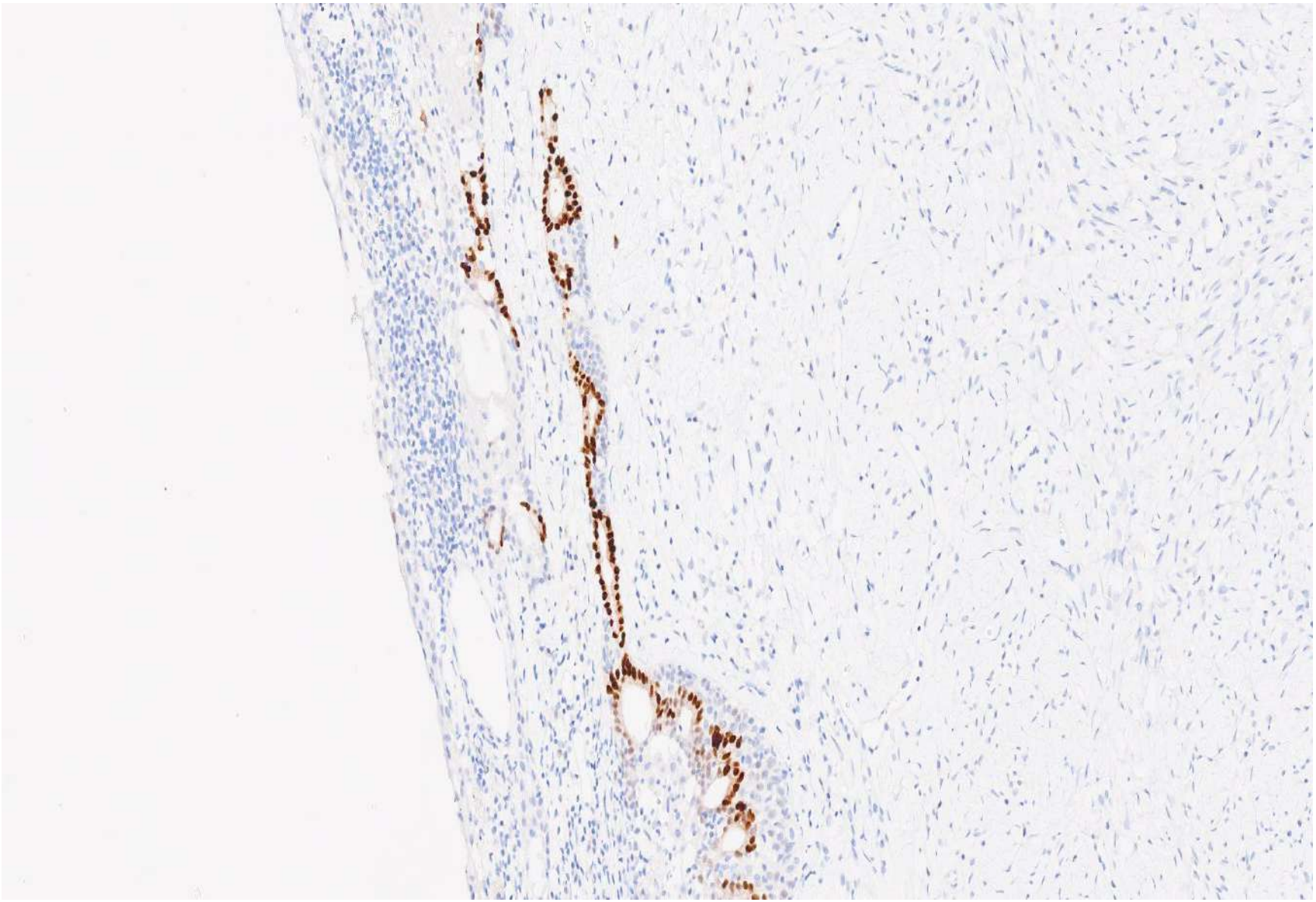

QUESTIONS ?