The British Association of Gynaecological Pathologists

bsccp The British Society for Colposcopy and Cervical Pathology

Lecturer – Dr Jonathan Crook

Dr Jonathan Crook is a consultant histopathologist at University College London Hospitals. He subspecialises in gynaecological pathology and is a BAGP meeting secretary.



The British Association of Gynaecological Pathologists

bsccp The British Society for Colposcopy and Cervical Pathology

Basic Cervical Histopathology Course

- Cervical adenocarcinoma, precursors and mimics
- Dr Jonathan Crook
- University College London Hospitals
- 25/02/25

The British Association of Gynaecological Pathologists

bsccp | The British Society for Colposcopy and Cervical Pathology

Speaker disclosures

- I have no financial conflicts of interest to disclose

Poll

- How are cervical adenocarcinomas primarily classified?
  - HPV status
  - Molecular subtype
  - Silva pattern
  - Microscopic features
  - Grade

Overview

- Precursors
  - CGIN
  - SMILE
- Adenocarcinoma
  - HPV-associated
  - HPV-independent
- Mimics

High grade CGIN

- Cervical glandular neoplasia in situ
- Also known as AIS (adenocarcinoma in-situ)
- Vast majority are HPV-associated
- Features:
  - Abrupt transition from normal to dysplastic epithelium
  - Hyperchromatic, enlarged, pseudostratified nuclei
  - Often mucin depletion
  - Mitoses (apical) and karyorrhectic debris
  - Sometimes goblet cells or cilia

CGIN

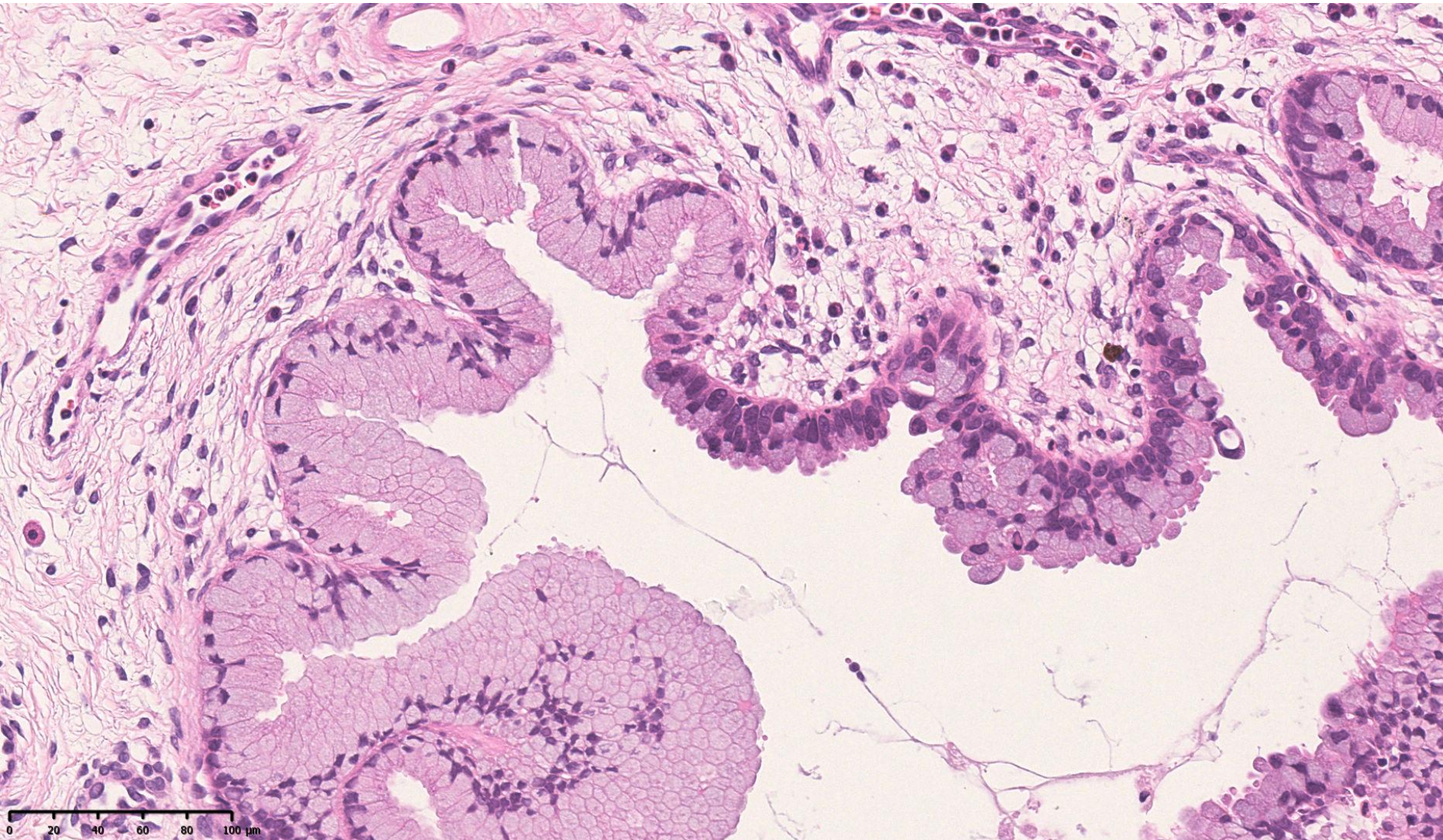

CGIN

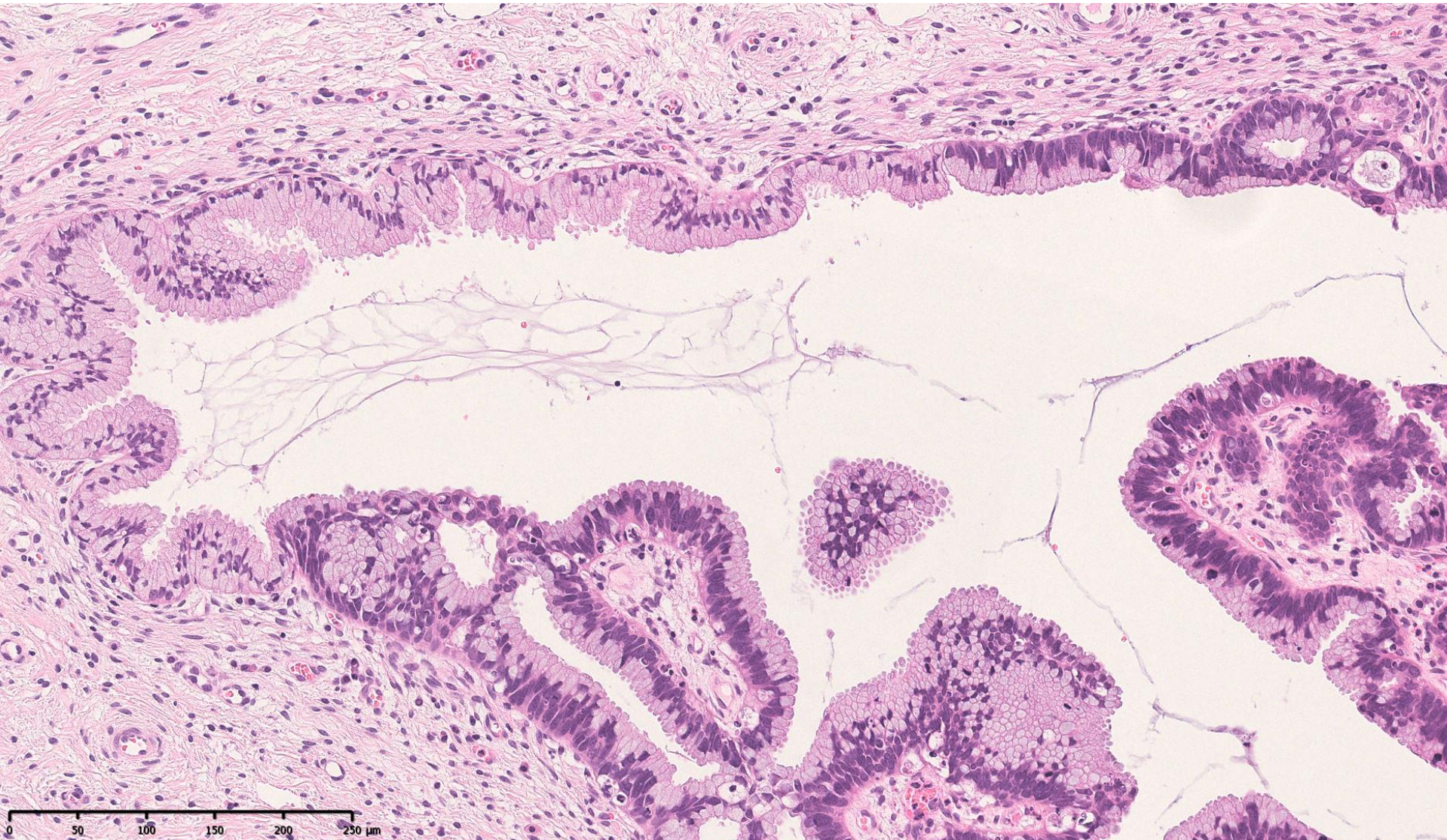

SMILE – stratified mucin-producing intraepithelial lesion

- Rare HPV-associated precursor lesion
- Thought to be derived from reserve cells
- Invasive counterpart: ISMC (invasive mucin-producing carcinoma)
- Usually managed similarly to CGIN
- Features:
  - Stratified epithelium
  - Mucin vacuoles throughout entire epithelial thickness
    - Causes spacing out of nuclei
  - Nuclear hyperchromasia, pleomorphism

SMILE – stratified mucin-producing intraepithelial lesion

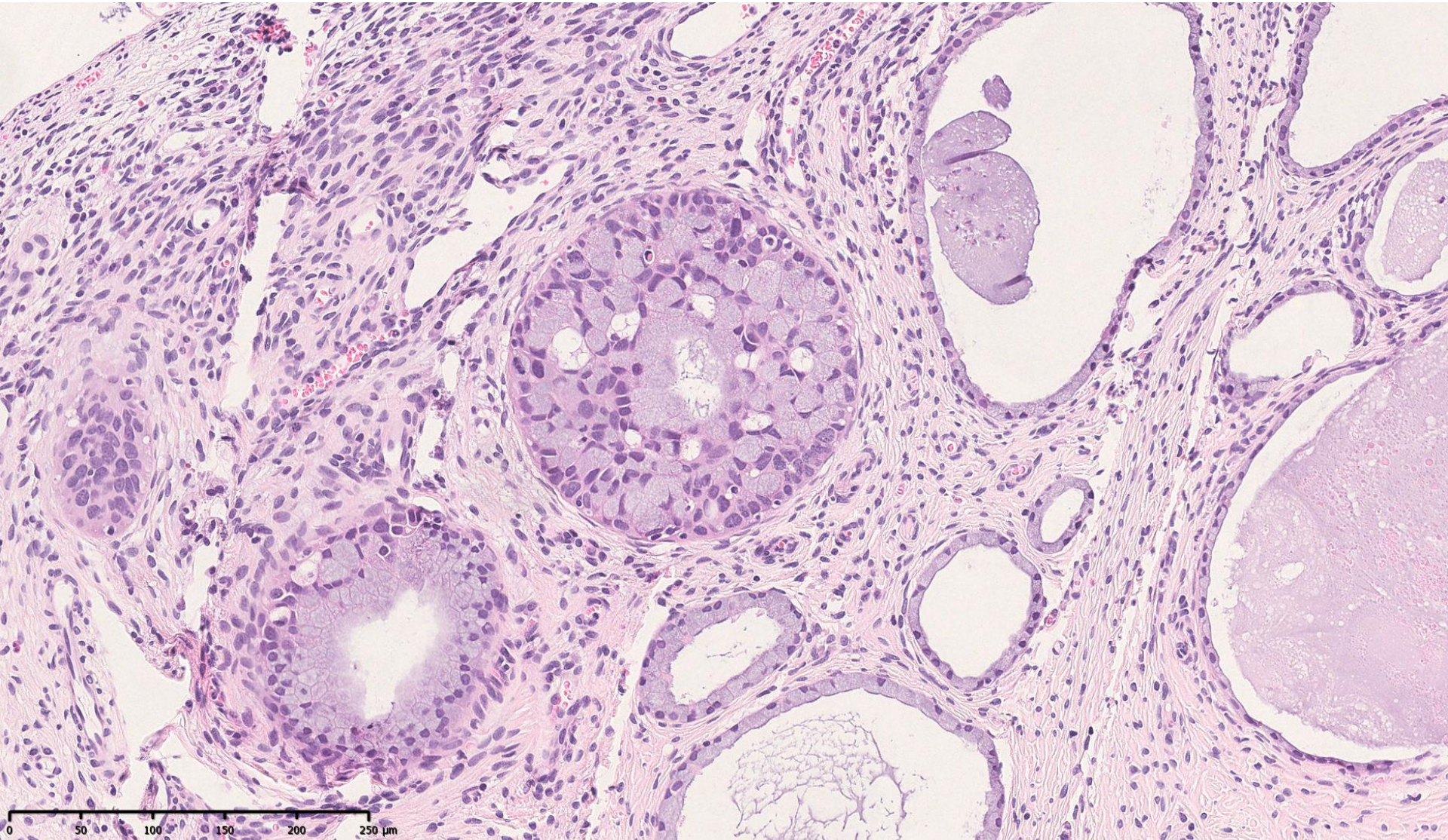

SMILE – stratified mucin-producing intraepithelial lesion

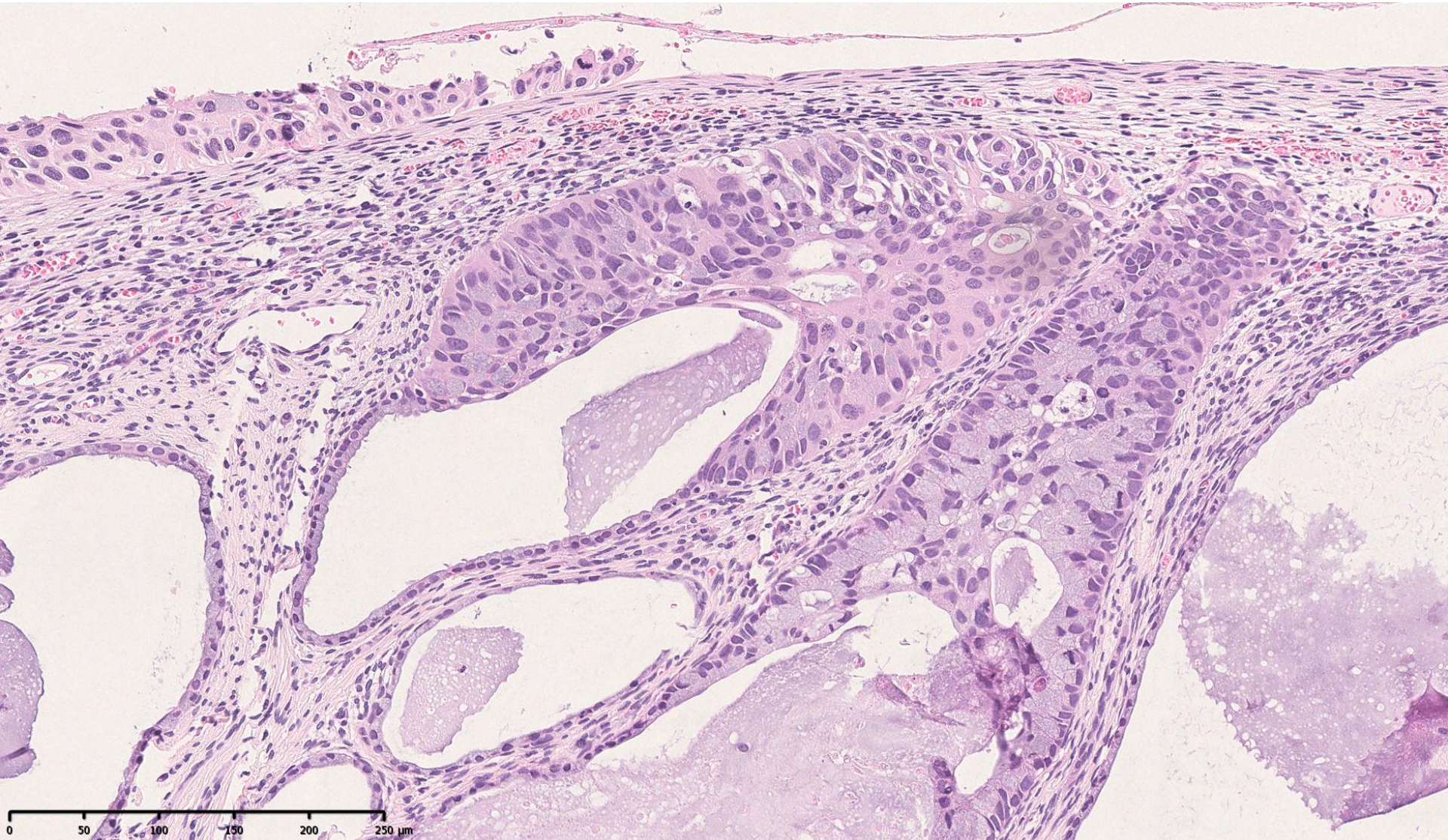

Adenocarcinoma overview

- Less common than cervical SCC
  - Adenocarcinoma represents 10-20% of cervical cancers
- Worse prognosis than SCC
- Proportion of adenocarcinoma cases is increasing relative to SCC

Adenocarcinoma

- HPV-associated
  - More common (~85%)
  - Younger age at presentation (mean early 40s)
  - Better prognosis
- HPV-independent
  - More rare (~15%)
  - Older age at presentation (mean 50s)
  - Worse prognosis
- Distinguish using p16 IHC, HPV genotyping or in-situ hybridisation

HPV-associated adenocarcinoma

- Presentation: cervical mass or ulceration
- Types
  - Usual type (75%)
    - Mucinous cytoplasm in <50% of cells
  - Mucinous type
    - Mucinous cytoplasm in >=50% of cells
    - Subtypes
      - Mucinous NOS adenocarcinoma
      - Intestinal adenocarcinoma
      - Signet-ring cell adenocarcinoma
      - Stratified mucin-producing carcinoma (ISMC)
- General features
  - Apical mitoses
  - Karyorrhexis
  - Enlarged, hyperchromatic nuclei
  - p16 diffusely over-expressed

Grading

- Grade 1
  - <= 10% solid growth
- Grade 2
  - 11-50% solid growth
- Grade 3
  - >50% solid growth
- Notes
  - Upgrade if marked and extensive (>50%) nuclear atypia
  - Only for HPV-associated adenocarcinomas
  - Mixed evidence

Silva pattern

- Only for HPVA adenocarcinomas
- Pattern A (non-destructive invasion)
  - Well demarcated, rounded glands
  - No LVSI
- Pattern B (early / focally destructive invasion)
  - Focally infiltrative glands
  - Focally desmoplastic stroma
  - No solid growth
  - +/- LVSI
- Pattern C (diffusely destructive invasion)
  - Diffusely infiltrative glands
  - Extensive desmoplastic stroma
  - Solid growth
  - +/- LVSI

Silva pattern

	Total	Pattern A	Pattern B	Pattern C
No. Pts	1319	253	262	804
LVI	543 (41%)	0	53 (20%)	490 (61%)
With LN mets	191 (14%)	0	14 (5%)	177 (22%)
With stage information	1102	224	241	637
Stage I	981 (89%)	222 (99%)	233 (97%)	526 (83%)
Stage II–IV	119 (11%)	2 (1%)	6 (3%)	111 (17%)
With F/U	776	201	216	359
F/U in months, mean (range)	62 (3–392)	62 (3–252)	69 (5–392)	55 (3–258)
With recurrences	77 (10%)	0	7 (3%)	70 (19%)
DOD	42 (5%)	0	3 (1%)	39 (11%)

DOD indicates dead of disease; F/U, follow-up; LN, lymph node.

Alvarado-Cabrero I, Parra-Herran C, Stolnicu S, Roma A, Oliva E, Malpica A. The Silva Pattern-based Classification for HPV-associated Invasive Endocervical Adenocarcinoma and the Distinction Between In Situ and Invasive Adenocarcinoma: Relevant Issues and Recommendations From the International Society of Gynecological Pathologists. Int J Gynecol Pathol. 2021 Mar 1;40(Suppl 1):S48-S65. doi: 10.1097/PGP.0000000000000735. PMID: 33570863; PMCID: PMC7969170.

HPV-associated adenocarcinoma, usual type

- Precursor: HGCGIN
- Most common subtype
- Mucinous epithelium in <50% of tumour
- Villoglandular variant
  - Rare
  - Good prognosis
  - Low grade

HPV-associated adenocarcinoma, usual type

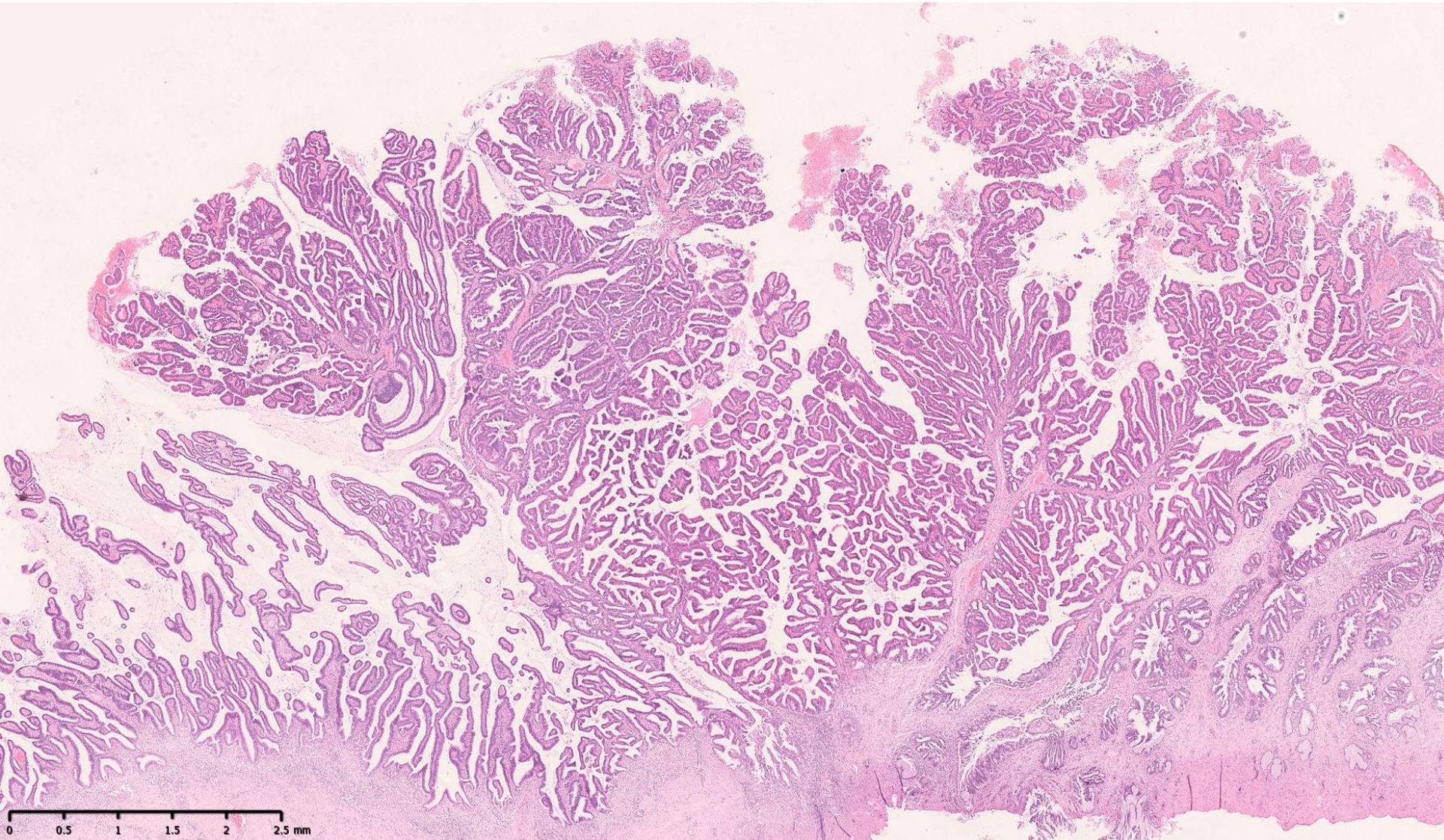

HPV-associated adenocarcinoma, usual type

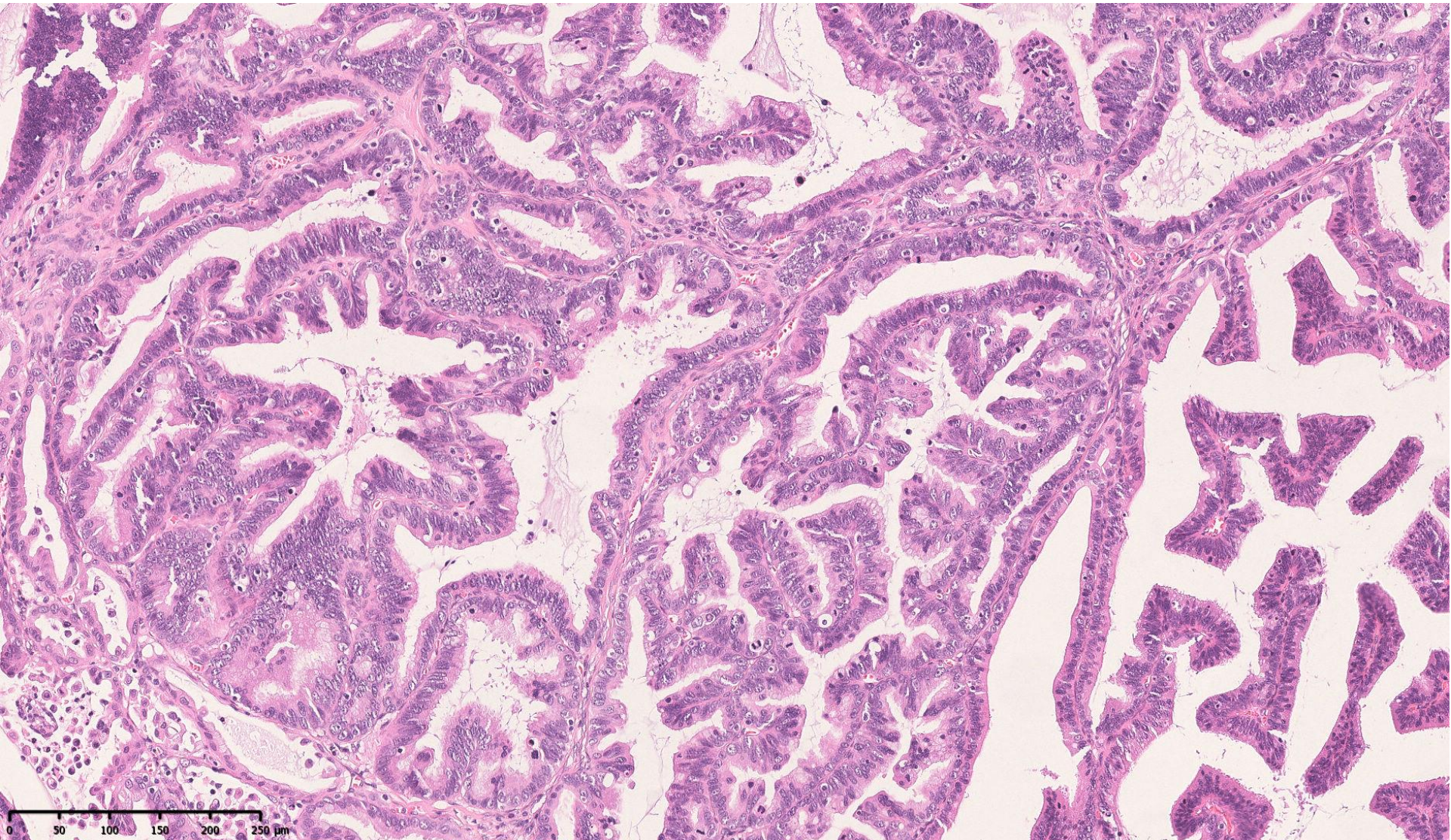

HPV-associated adenocarcinoma, usual type

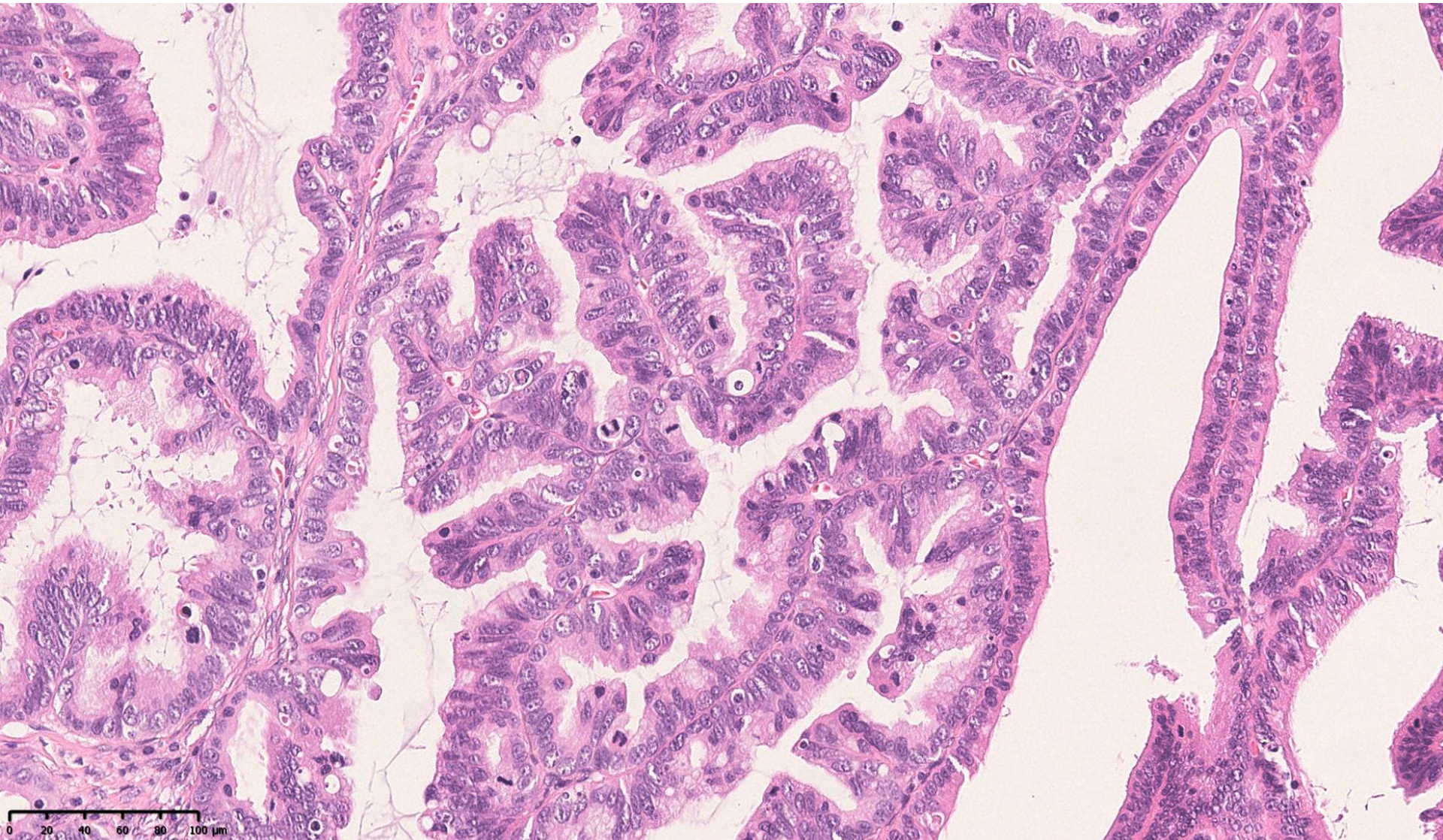

ISMC – invasive stratified mucin-producing carcinoma

- Subtype of HPV-associated adenocarcinoma
- Invasive counterpart to SMILE
- Seems to arise from cervical reserve cells
- Worse prognosis compared to other HPVA subtypes

ISMC – invasive stratified mucin-producing carcinoma

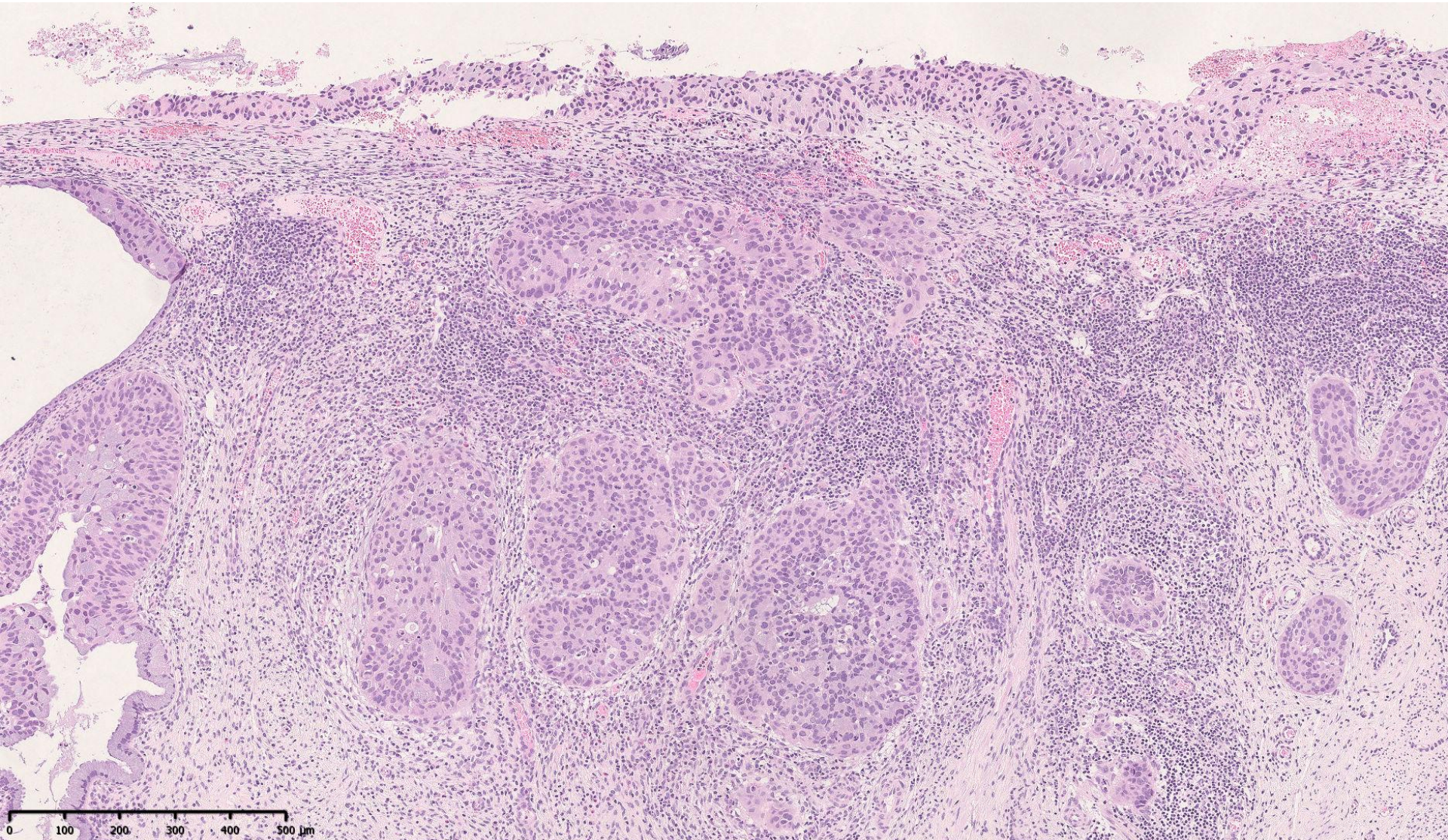

ISMC – invasive stratified mucin-producing carcinoma

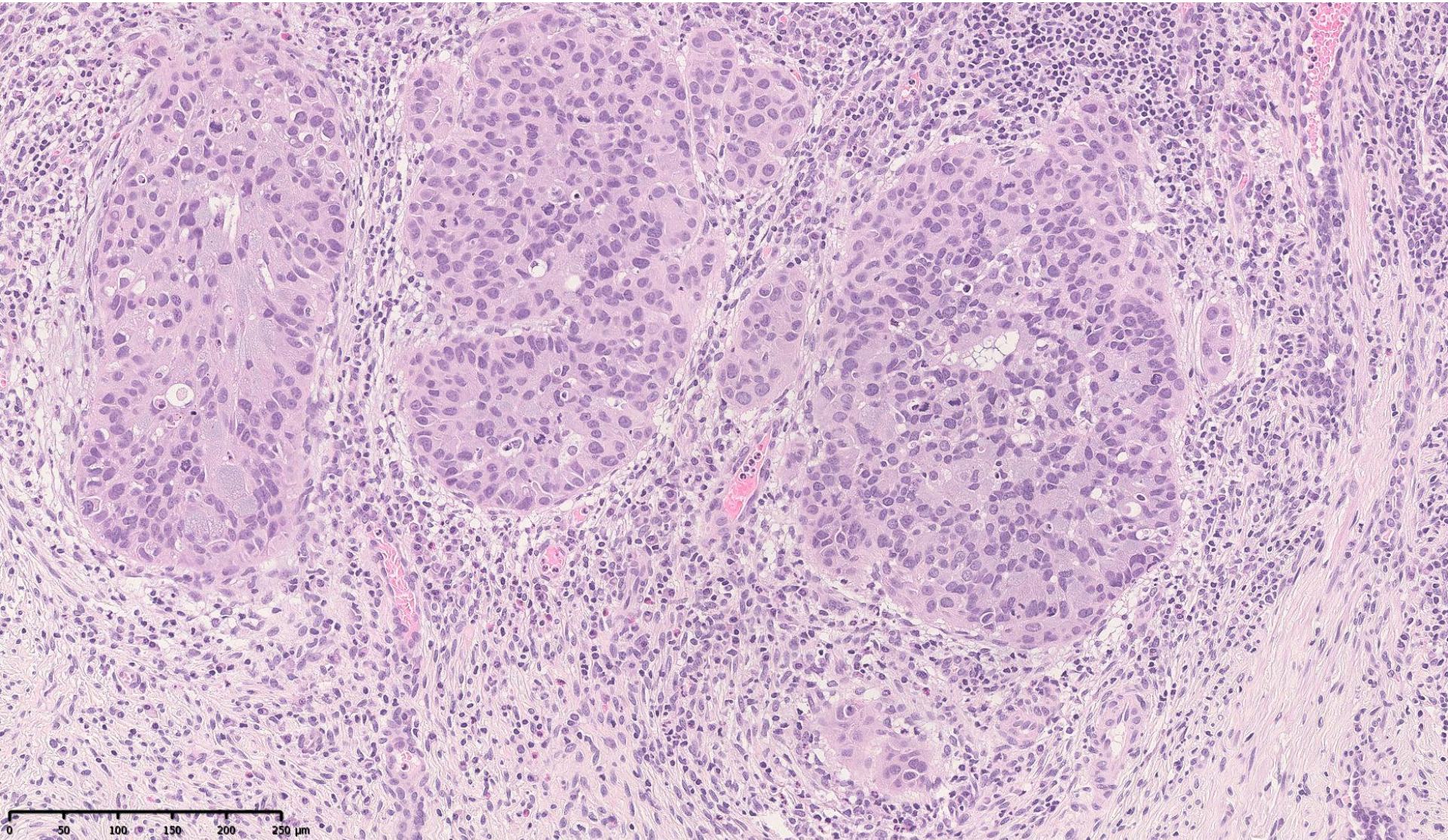

ISMC p16

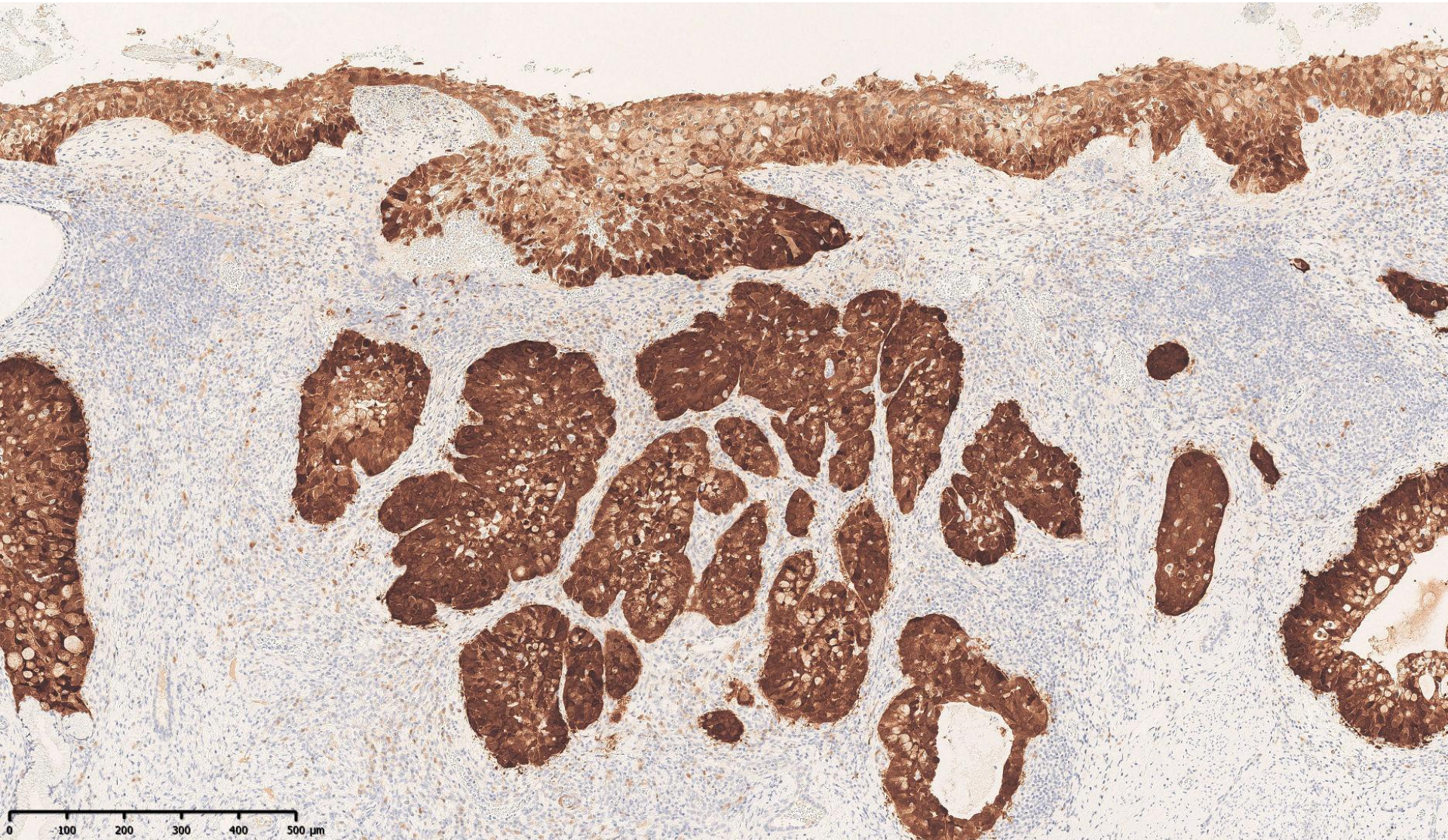

HPV-independent adenocarcinoma

- Types
  - Gastric type
  - Mesonephric carcinoma
  - Clear cell carcinoma
  - Endometrioid carcinoma

HPV-independent adenocarcinoma, gastric type

- Clinical: Bleeding, watery vaginal discharge
- Worse prognosis than HPV-associated adenocarcinoma
- Other terminology
  - “Adenoma malignum”
  - “Minimal deviation adenocarcinoma”
- Precursor
  - (Atypical) LEGH (lobular endocervical glandular hyperplasia)
- Association with Peutz-Jegher’s syndrome
- Not graded
- Features
  - Clear-eosinophilic cytoplasm
  - Prominent cellular borders
  - Neutral mucins – pink on ABPAS
  - IHC: often p53m and PAX2 loss
  - Gastric immunomarkers: HIK1083, MUC6

HPV-independent adenocarcinoma, gastric type

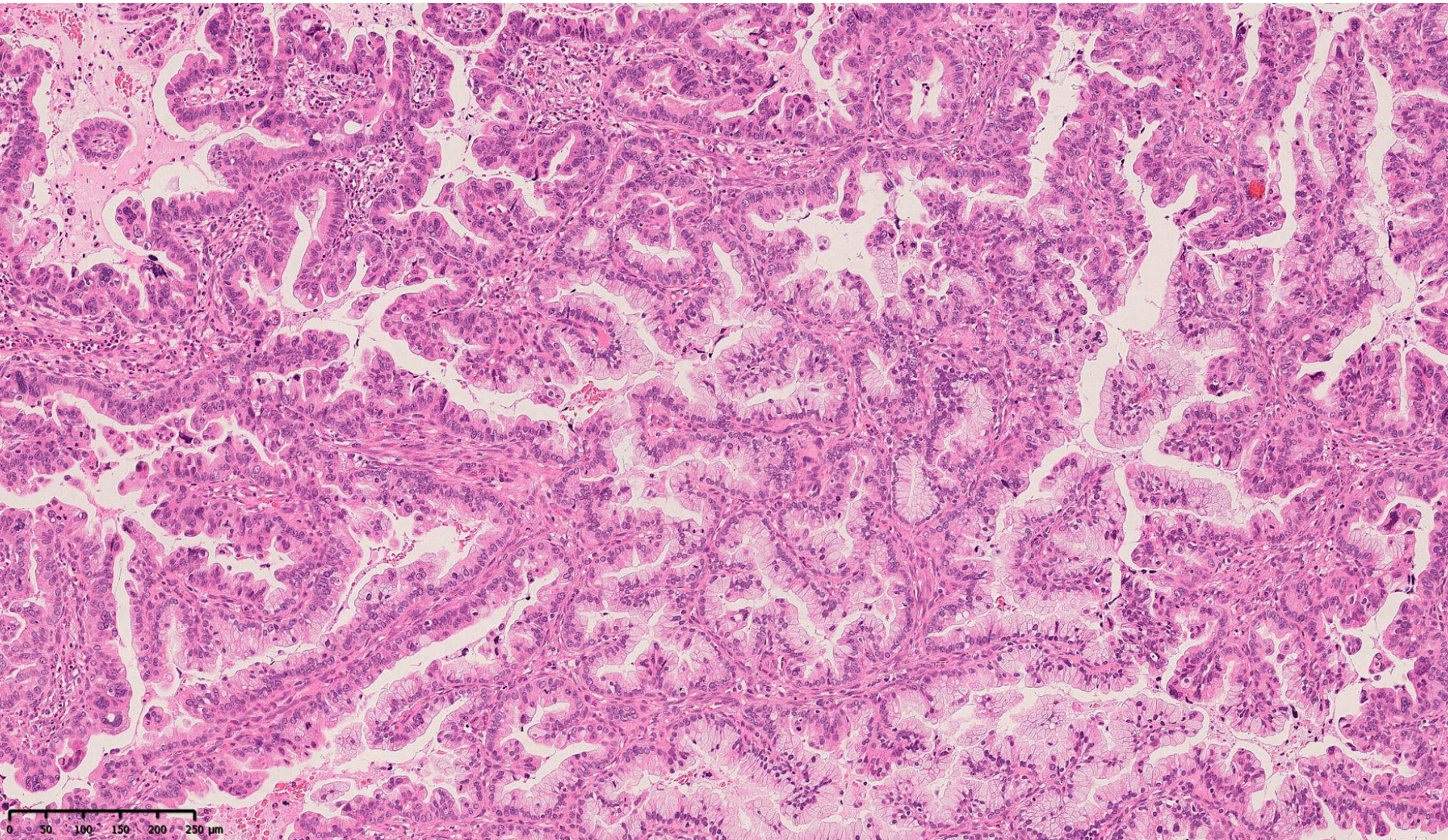

HPV-independent adenocarcinoma, gastric type

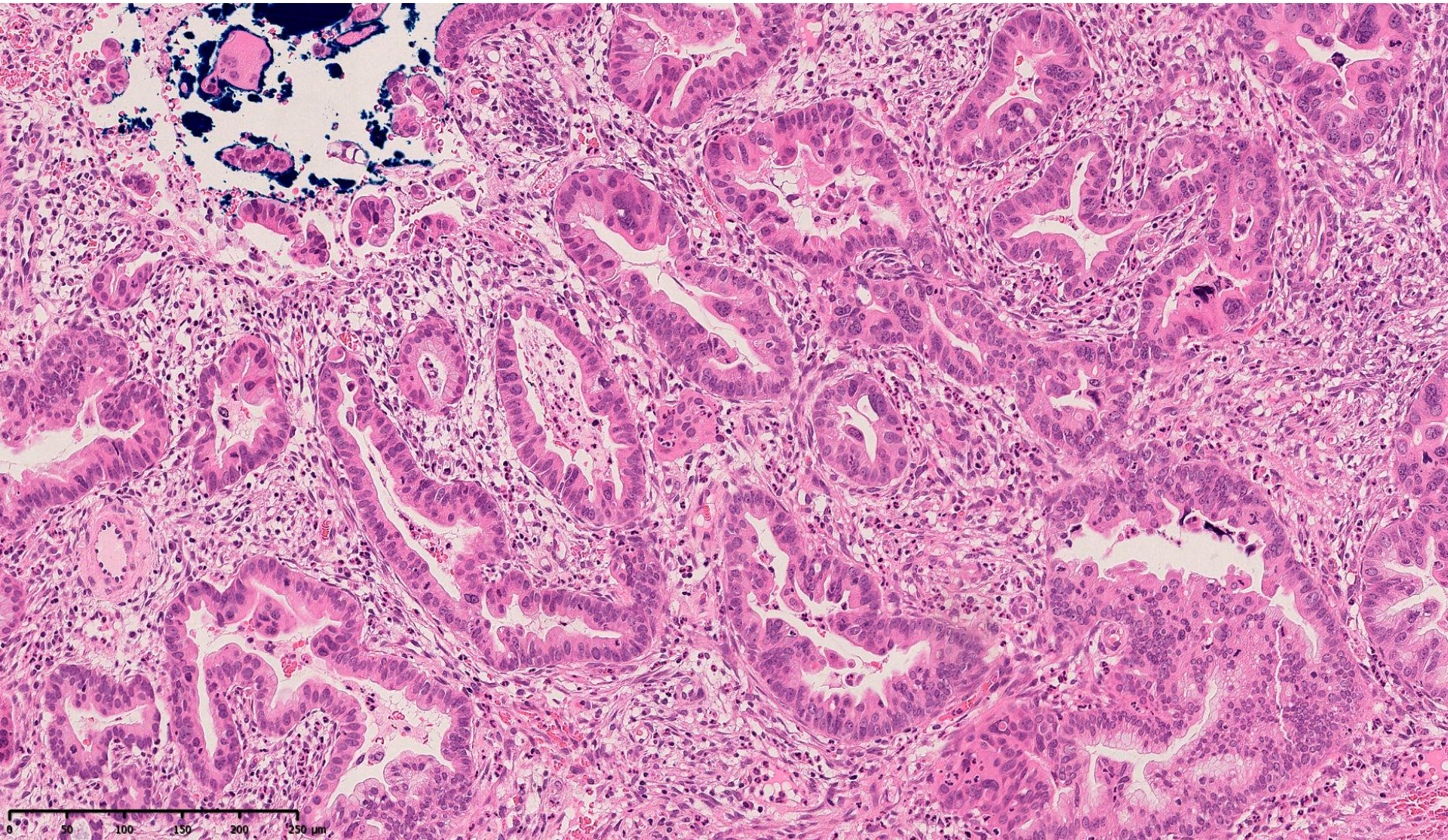

HPV-independent adenocarcinoma, gastric type

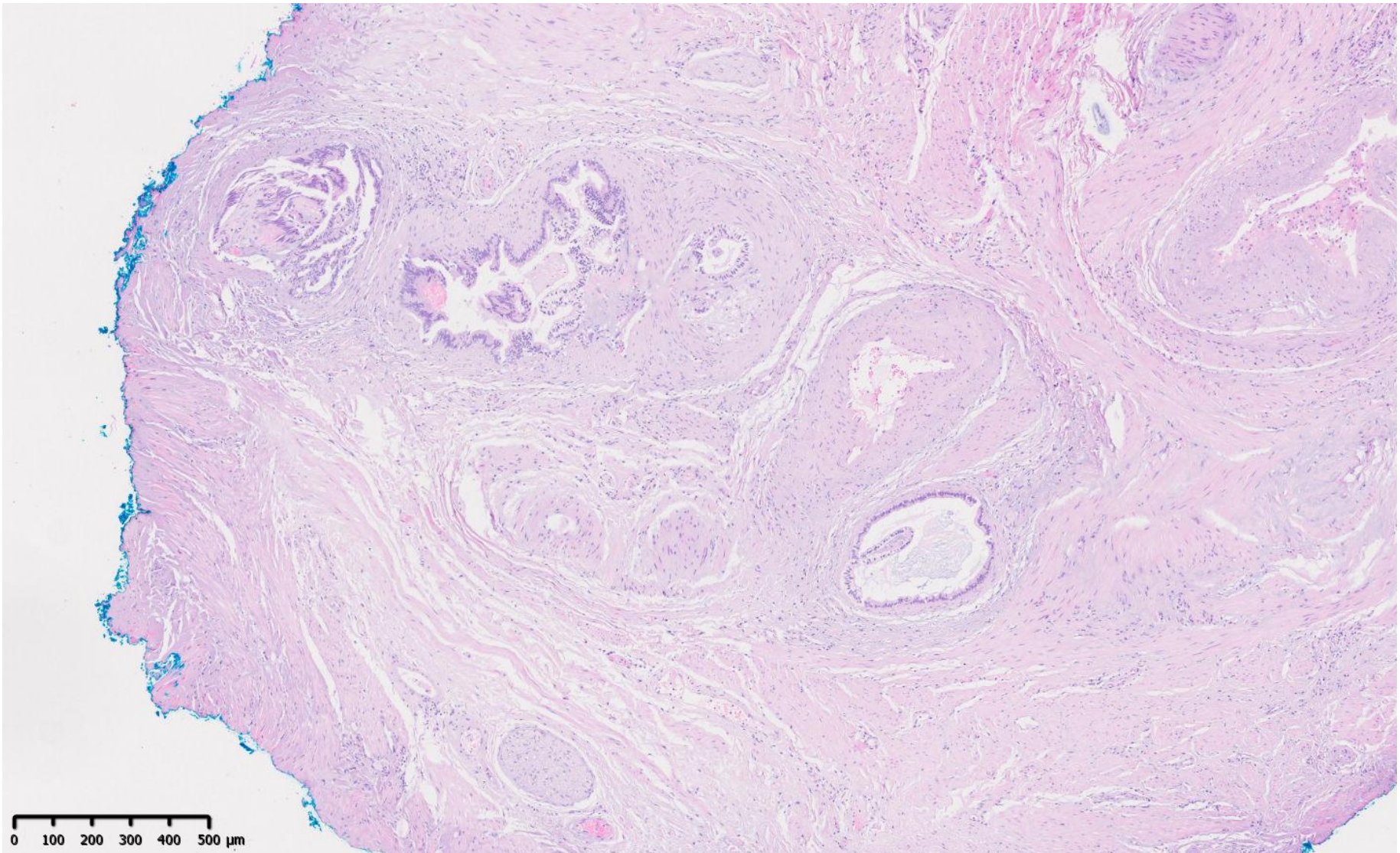

HPV-independent adenocarcinoma, gastric type

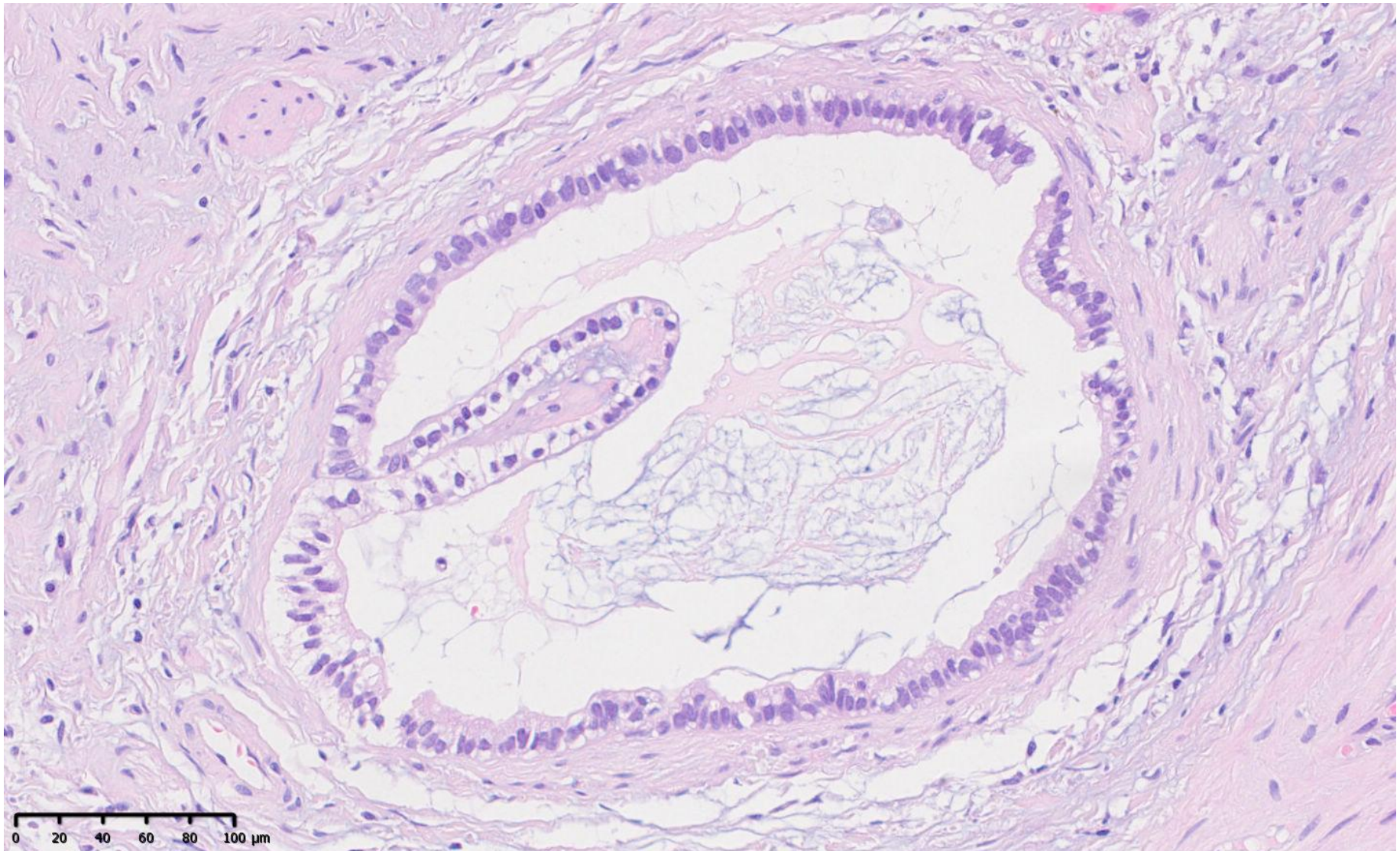

HPV-independent adenocarcinoma, gastric type

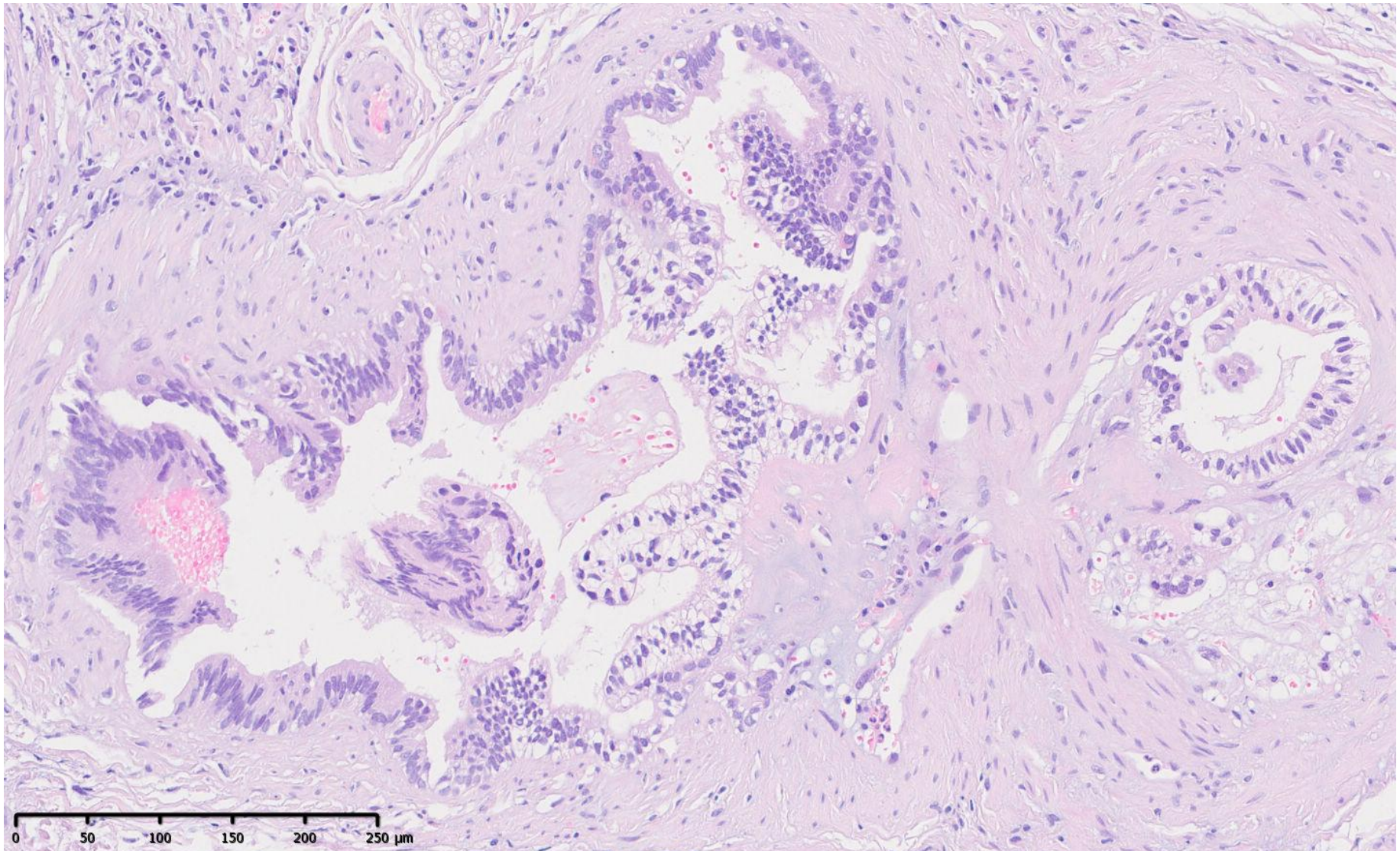

LEGH

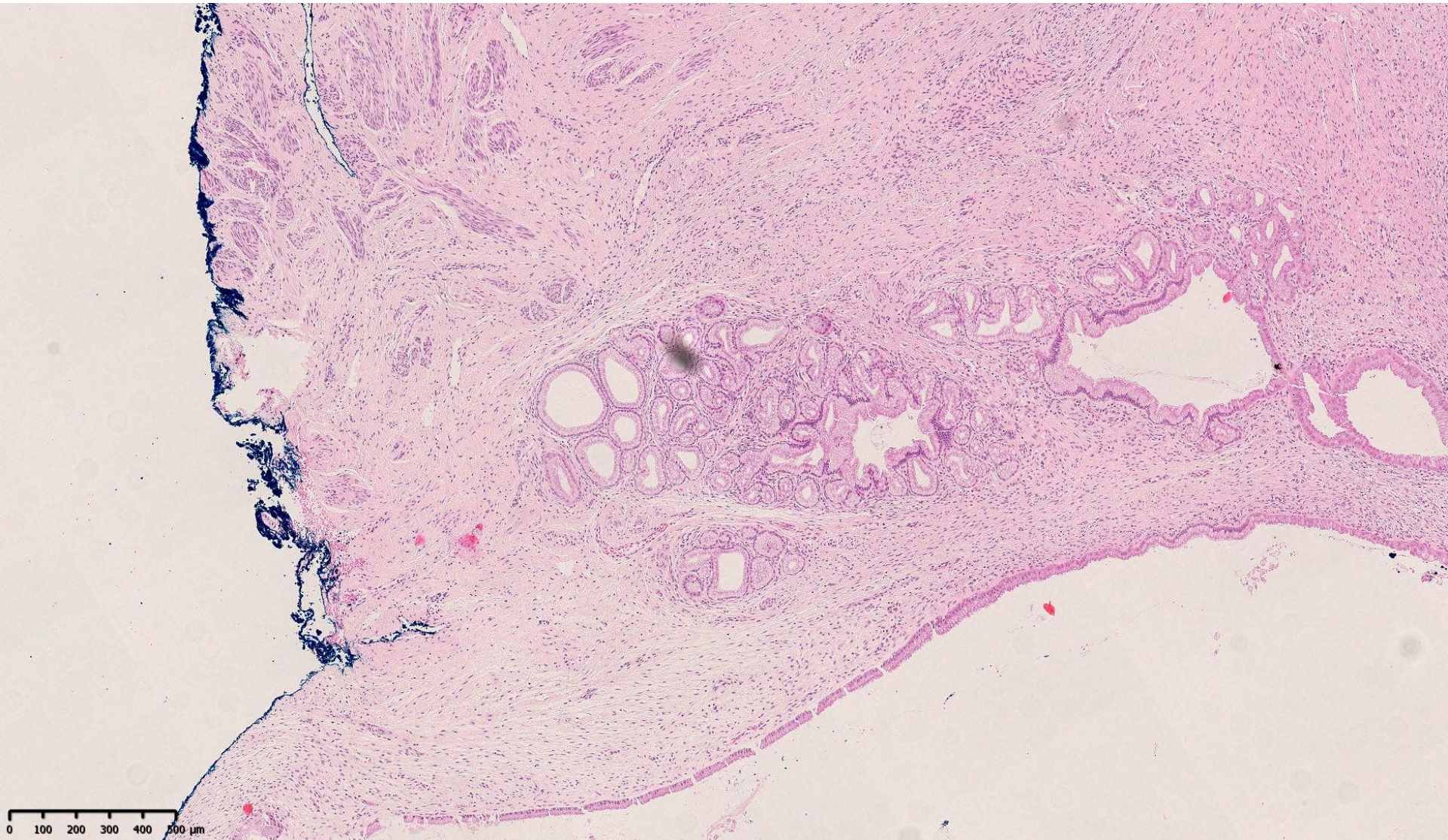

LEGH

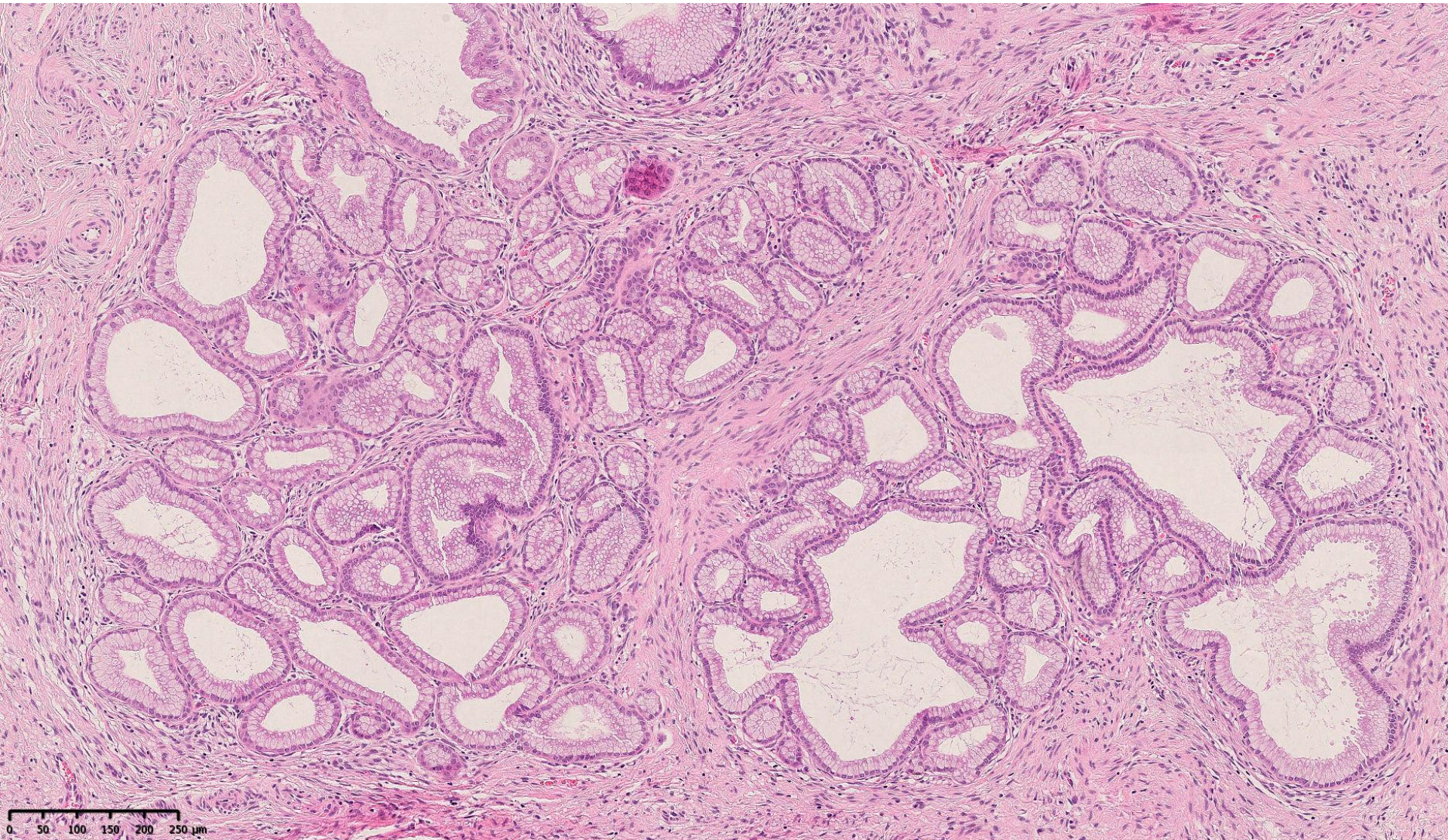

HPV-independent adenocarcinoma, mesonephric type

- Rare
- Associated with mesonephric remnants / hyperplasia
- Features
  - Often a variety of architectural patterns
    - Classically tubular with eosinophilic secretions
    - Ductal (pseudoendometrioid)
    - Others
  - Can have sarcomatous component
  - IHC: GATA3+, CD10+ (luminal), TTF1+/-, ER-/PR-
- Aggressive. Poor prognosis compared to HPVA adenocarcinoma

HPV-independent adenocarcinoma, mesonephric type

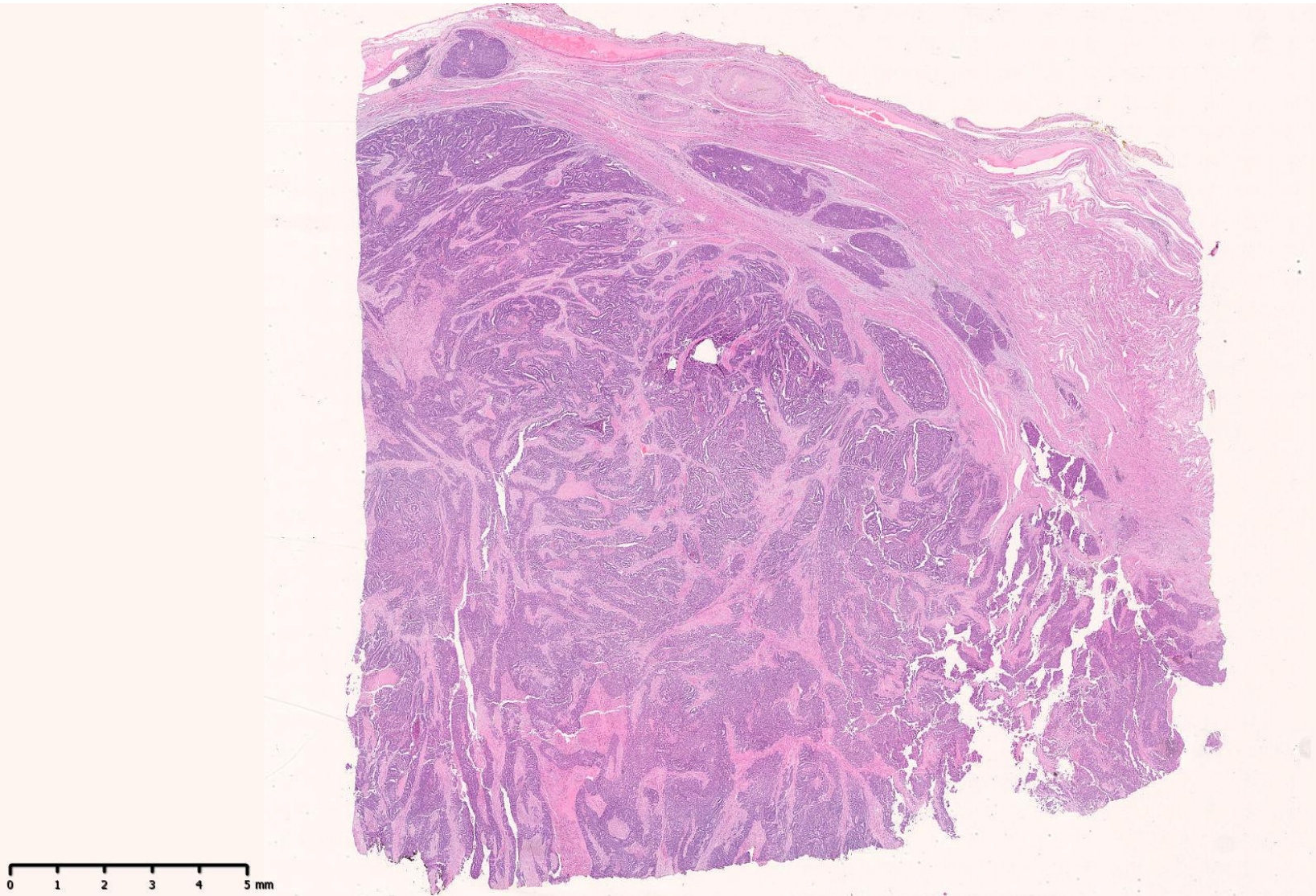

HPV-independent adenocarcinoma, mesonephric type

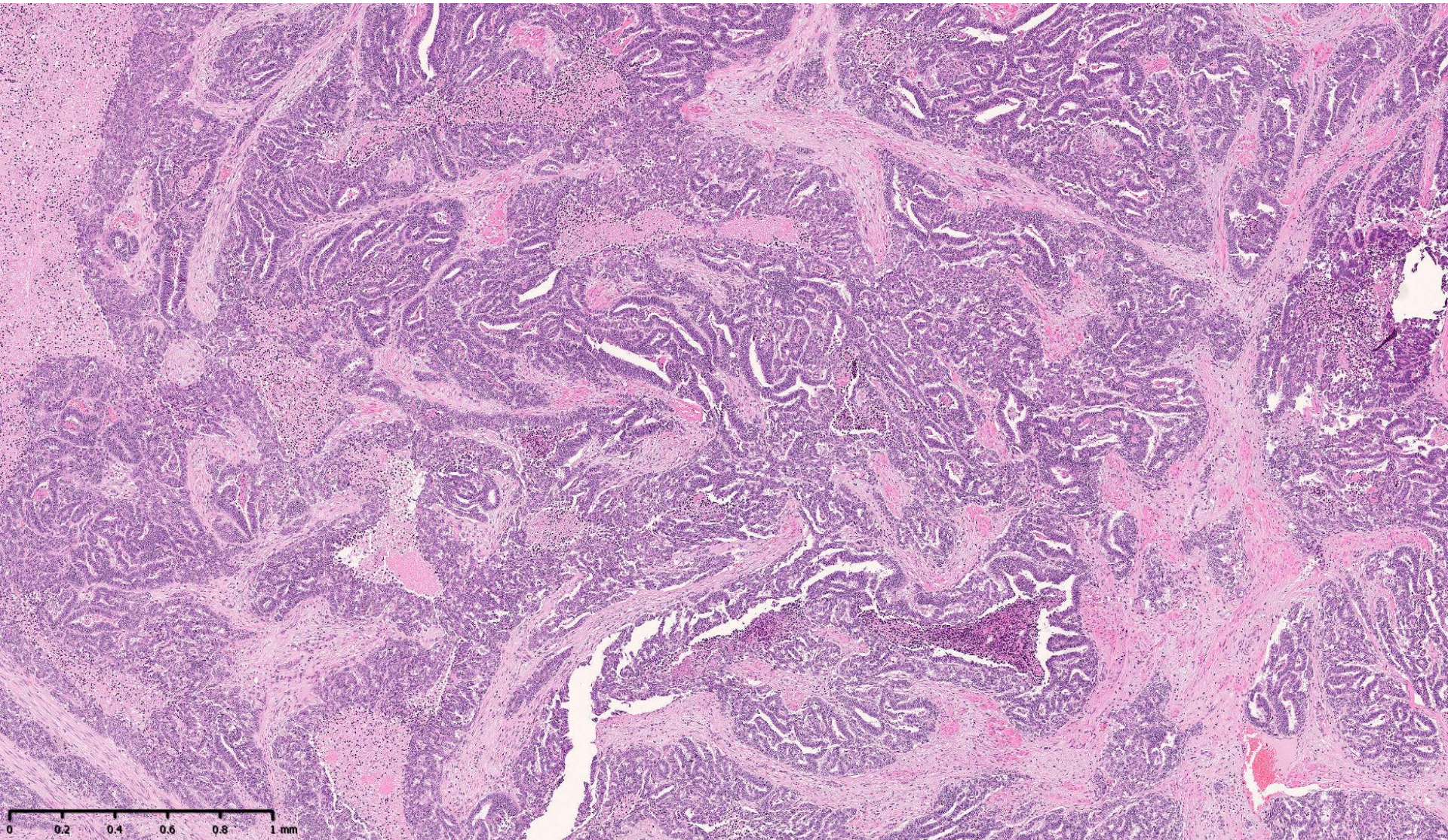

Mimics

- Microglandular hyperplasia
- Tuboendometrioid metaplasia
- Mesonephric hyperplasia
- Others
  - Tunnel clusters
  - Endometriosis
  - Diffuse laminar endocervical hyperplasia
  - Ectopic prostatic tissue

Microglandular hyperplasia

- Benign, non-neoplastic lesion
- Usually incidental finding
- Usually reproductive aged women, associated with progesterone
- Crowded mucinous glands

Microglandular hyperplasia

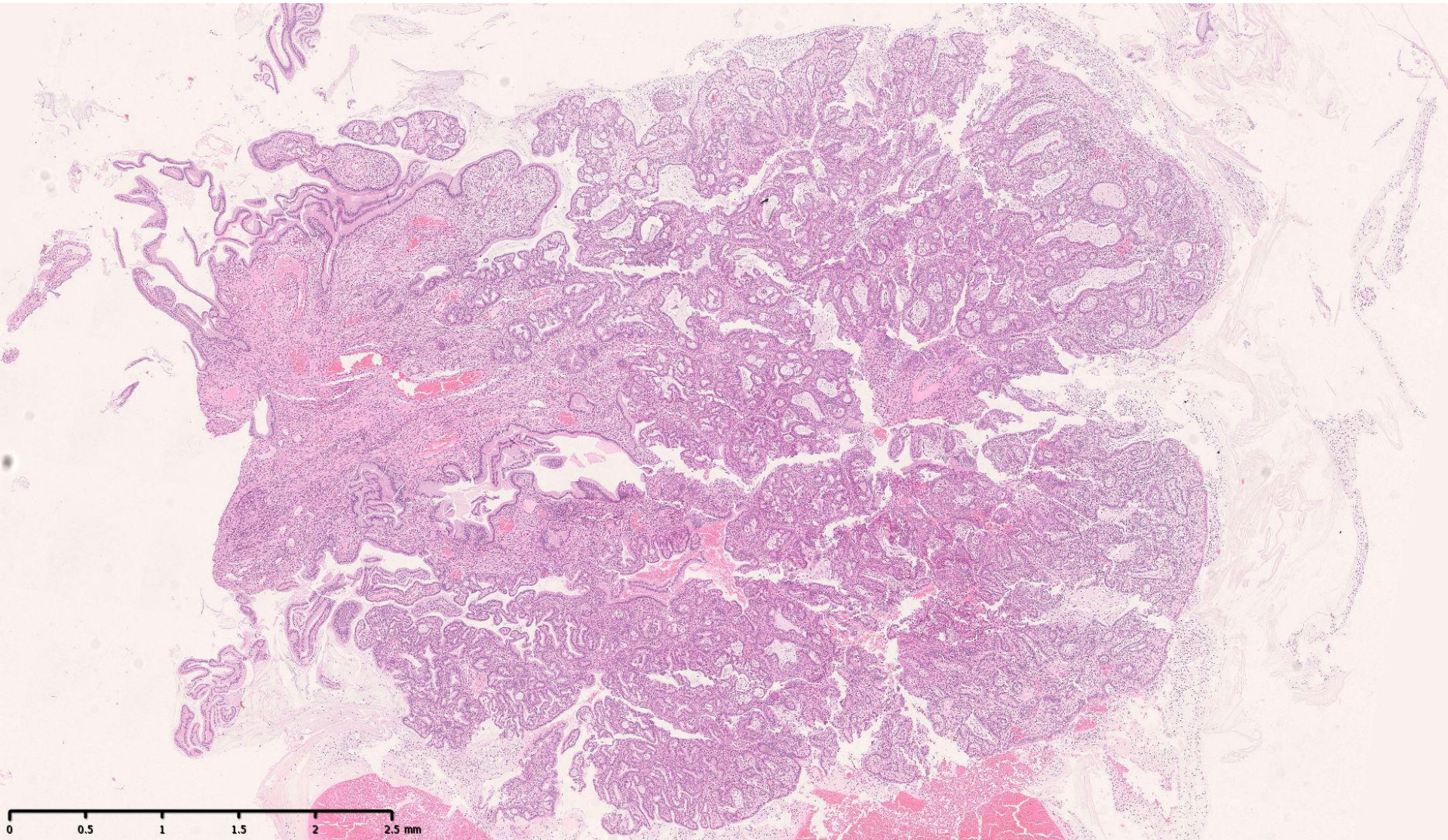

Microglandular hyperplasia

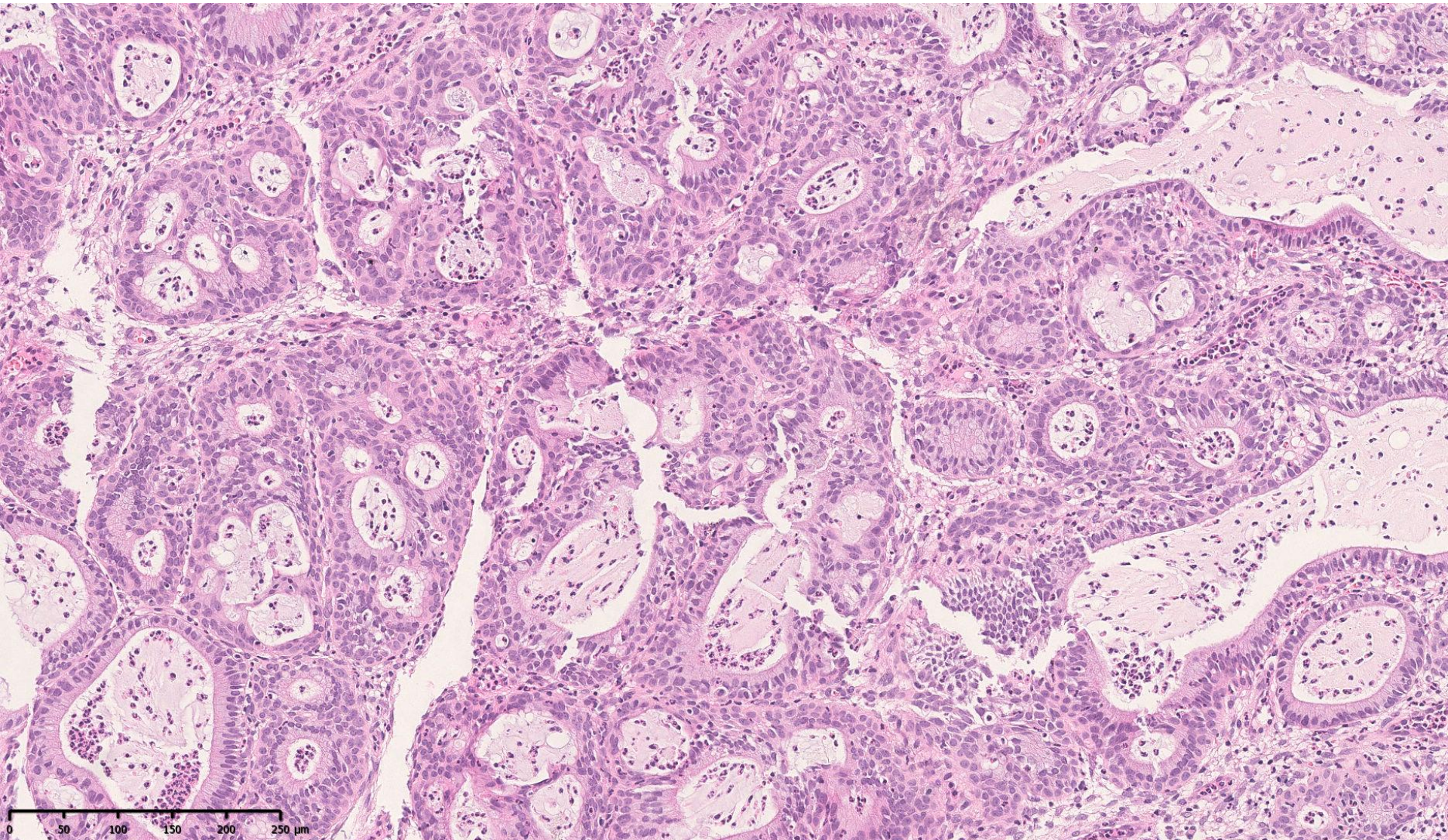

Tuboendometrioid metaplasia

- Metaplastic change from endocervical epithelium to tubal or endometrial type epithelium
- Associated with previous cervical excisions
- May be confused with CGIN
  - IHC can help if unsure
    - ER positive, p16 patchy, BCL2 positive

Tuboendometrioid metaplasia

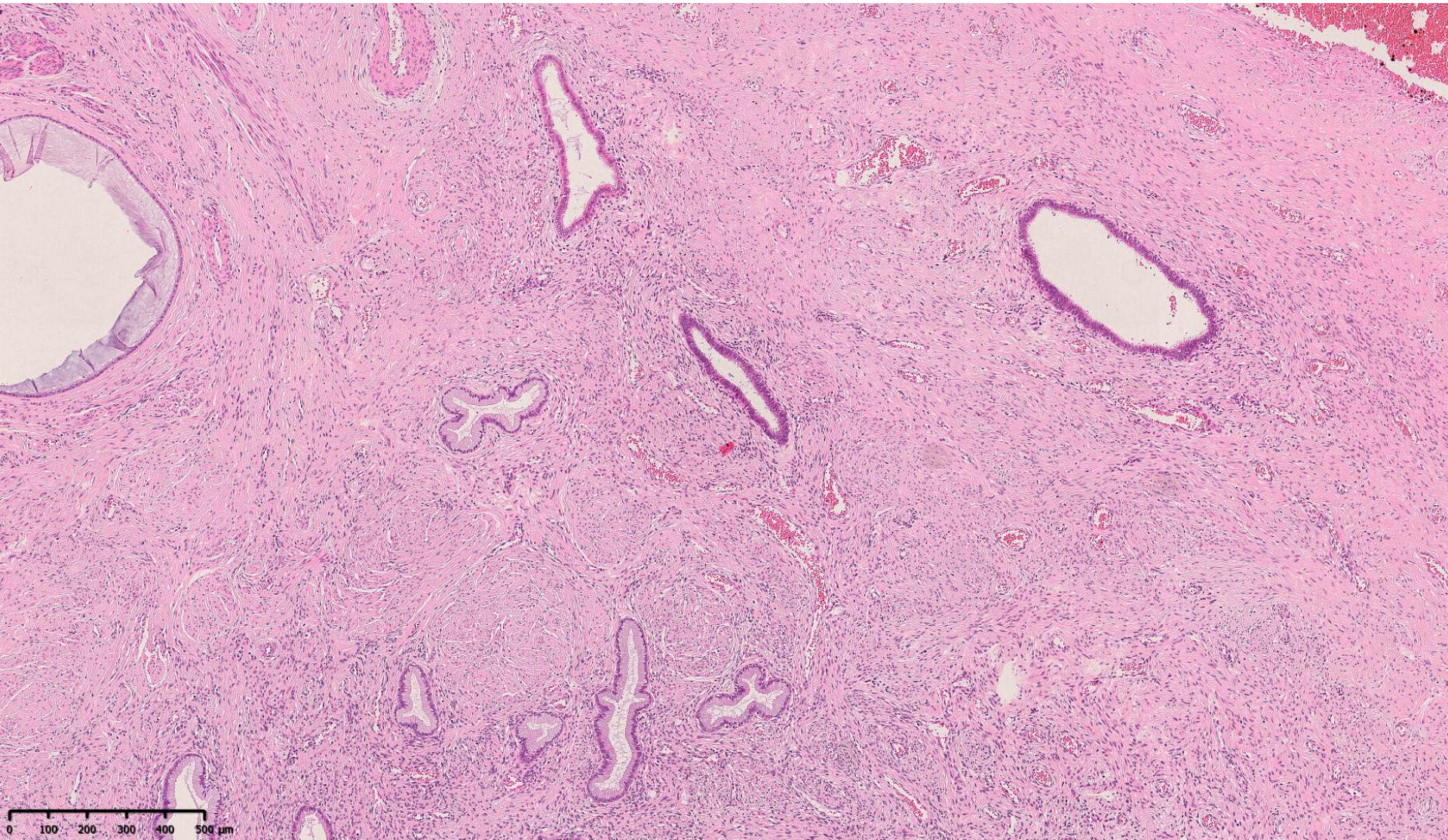

Tuboendometrioid metaplasia

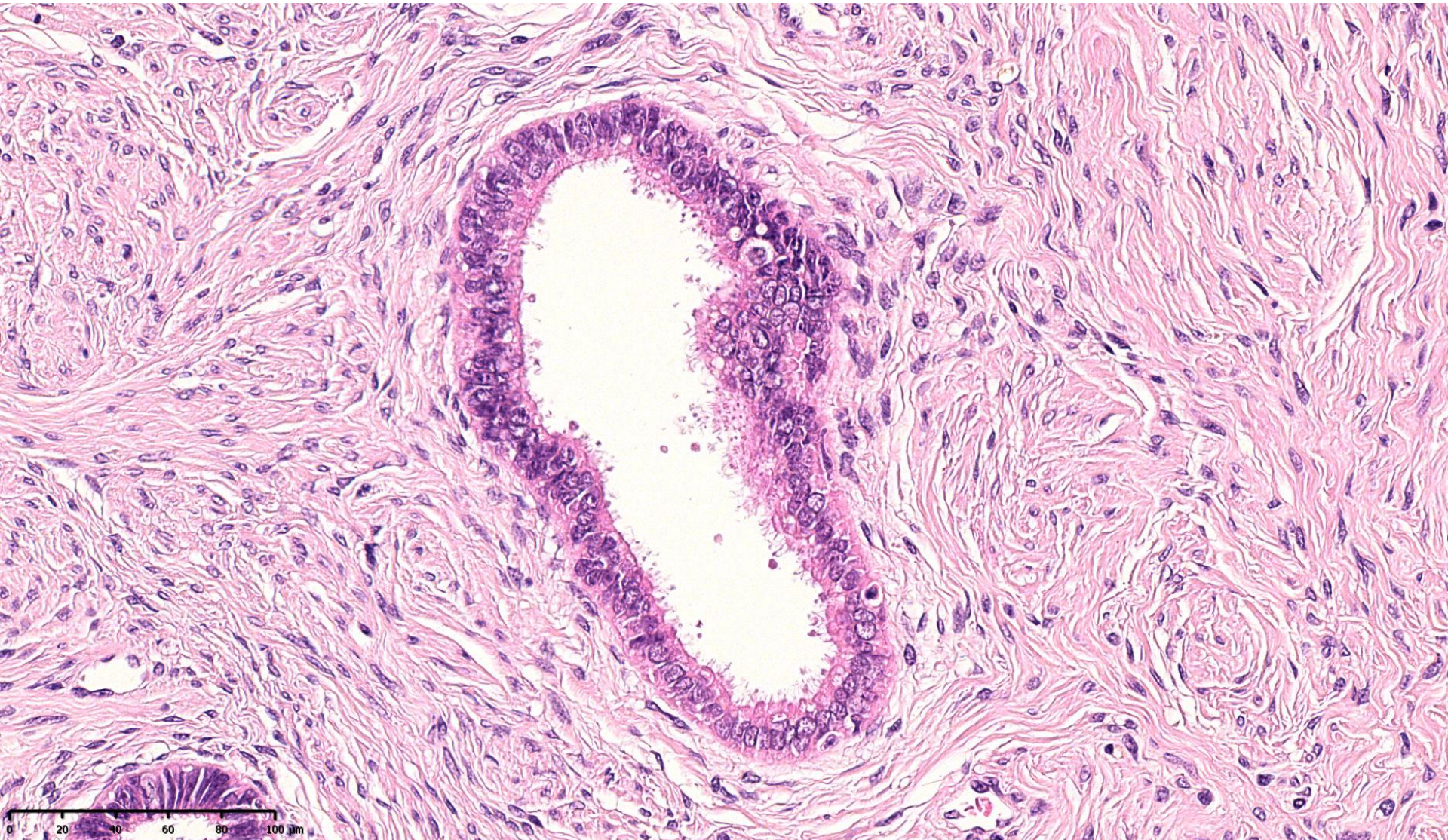

Mesonephric remnants and hyperplasia

- Benign, non-neoplastic lesion
- Usually incidental finding
- Derived from the mesonephric duct
- Usually found in lateral walls of cervix

Mesonephric hyperplasia



Mesonephric hyperplasia

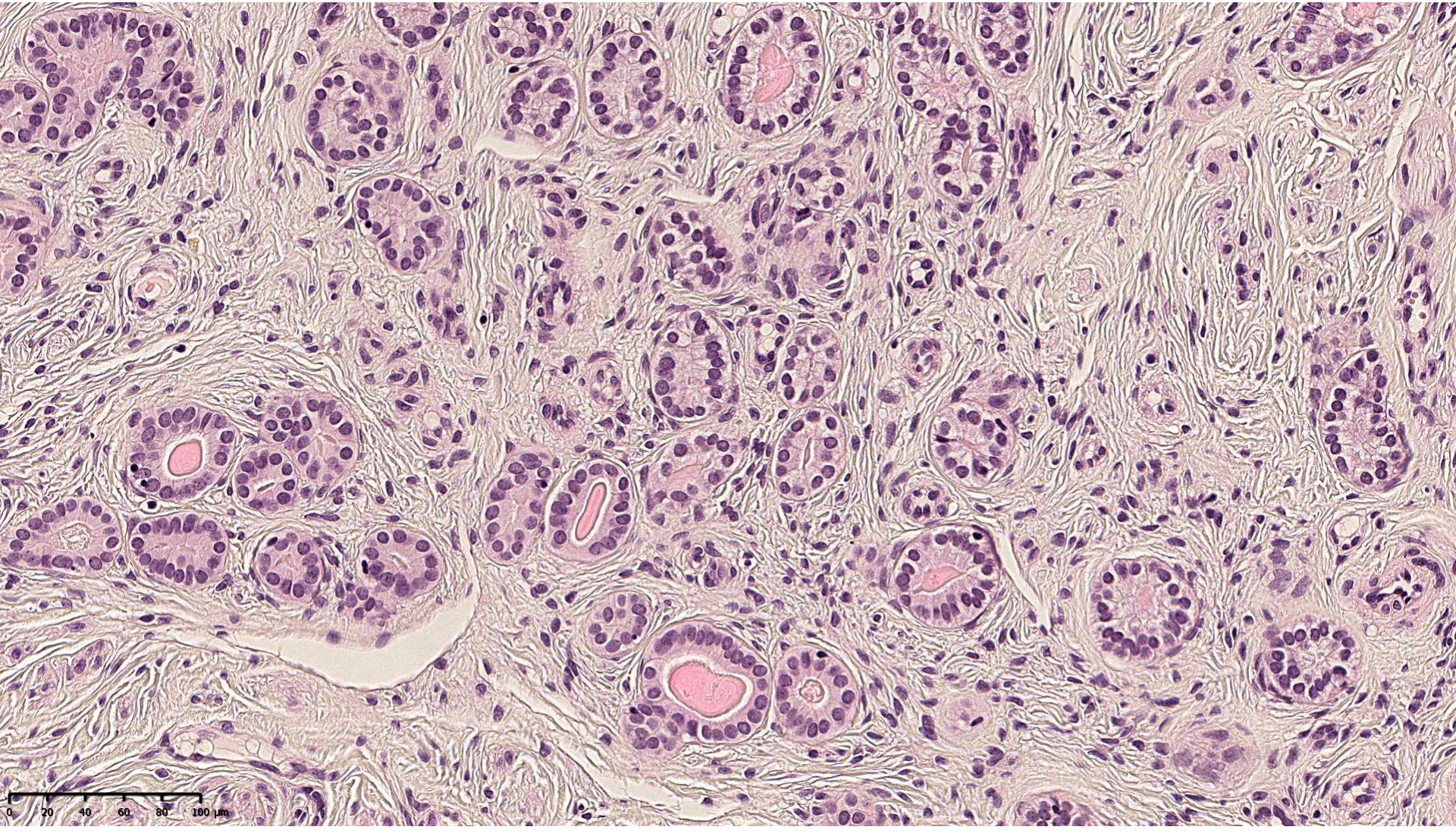

Poll

- Which of these tumours are HPV-associated?
  - Mesonephric carcinoma
  - ISMC (invasive stratified mucin-producing carcinoma)
  - Clear cell carcinoma
  - Gastric type adenocarcinoma

Poll

- What terminology has replaced “adenoma malignum”?
  - HPV-independent adenocarcinoma, gastric type
  - Mucinous adenocarcinoma
  - Minimal deviation adenocarcinoma
  - Mesonephric carcinoma

Poll

- Which has worse prognosis?
  - HPV-associated adenocarcinoma
  - HPV-independent adenocarcinoma

Summary

- Cervical adenocarcinoma
  - HPV-associated
    - Usual type (75%)
    - Mucinous type
      - Subtypes
        - » Mucinous NOS adenocarcinoma
        - » Intestinal adenocarcinoma
        - » Signet-ring cell adenocarcinoma
        - » Stratified mucin-producing carcinoma (ISMC)
  - HPV-independent
    - Gastric type
    - Mesonephric carcinoma
    - Clear cell carcinoma
    - Endometrioid carcinoma

Questions?