The British Association of Gynaecological Pathologists

21st Annual Meeting in Collaboration with ISGyP

5th and 6th June 2025

- Case based discussion – unusual cervical cases
- Dr Ciarán Ó Riain
- St. James's Hospital, Dublin
- 6th June 2025

The British Association of Gynaecological Pathologists

Speaker disclosures

- ❑ I have no financial conflicts of interest to disclose









Case 1

Uterine Cervix Biopsy

H&E and P16

45 Year Old

Clinical History Provided:

‘Cervix mass. No smear in >10 years.’

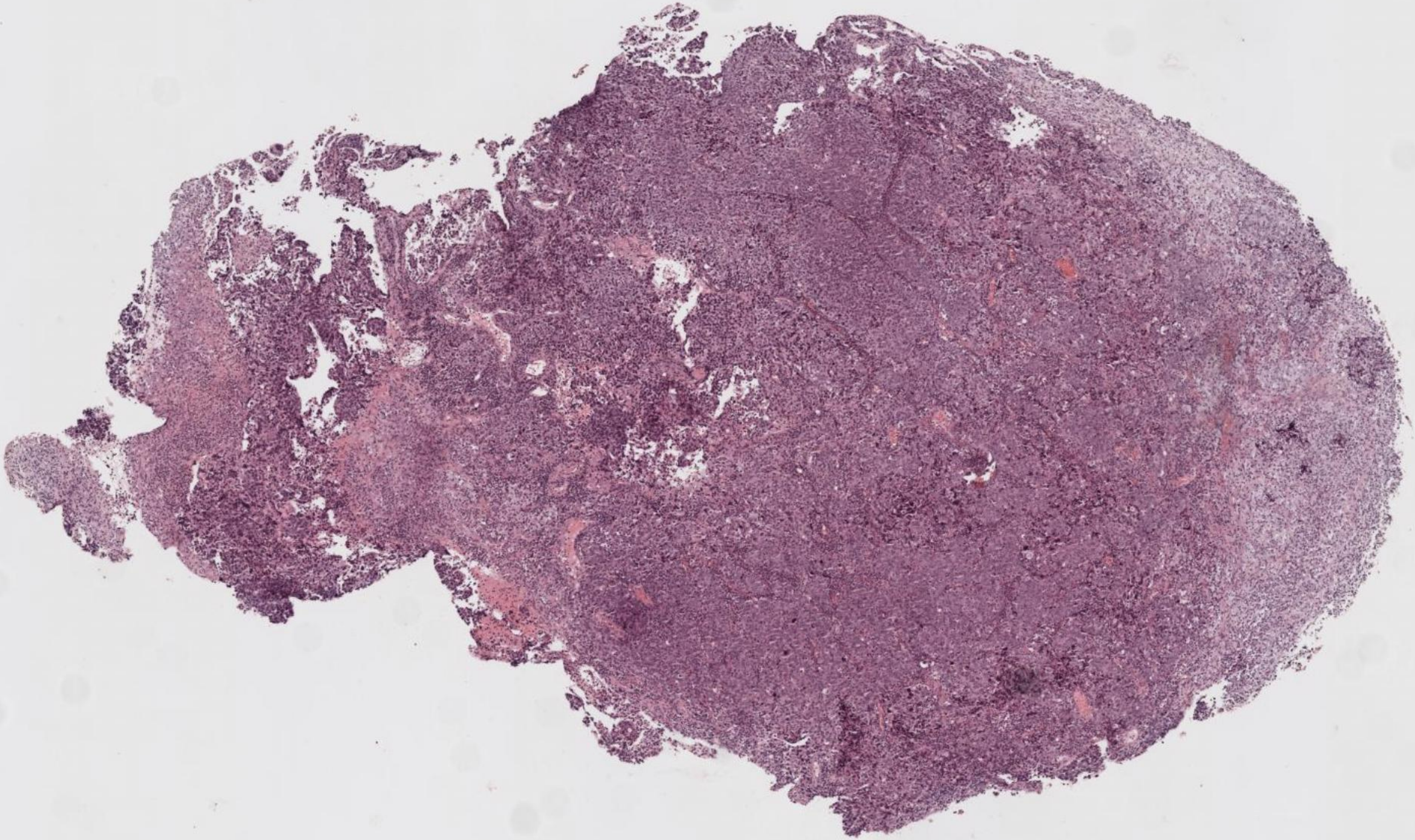

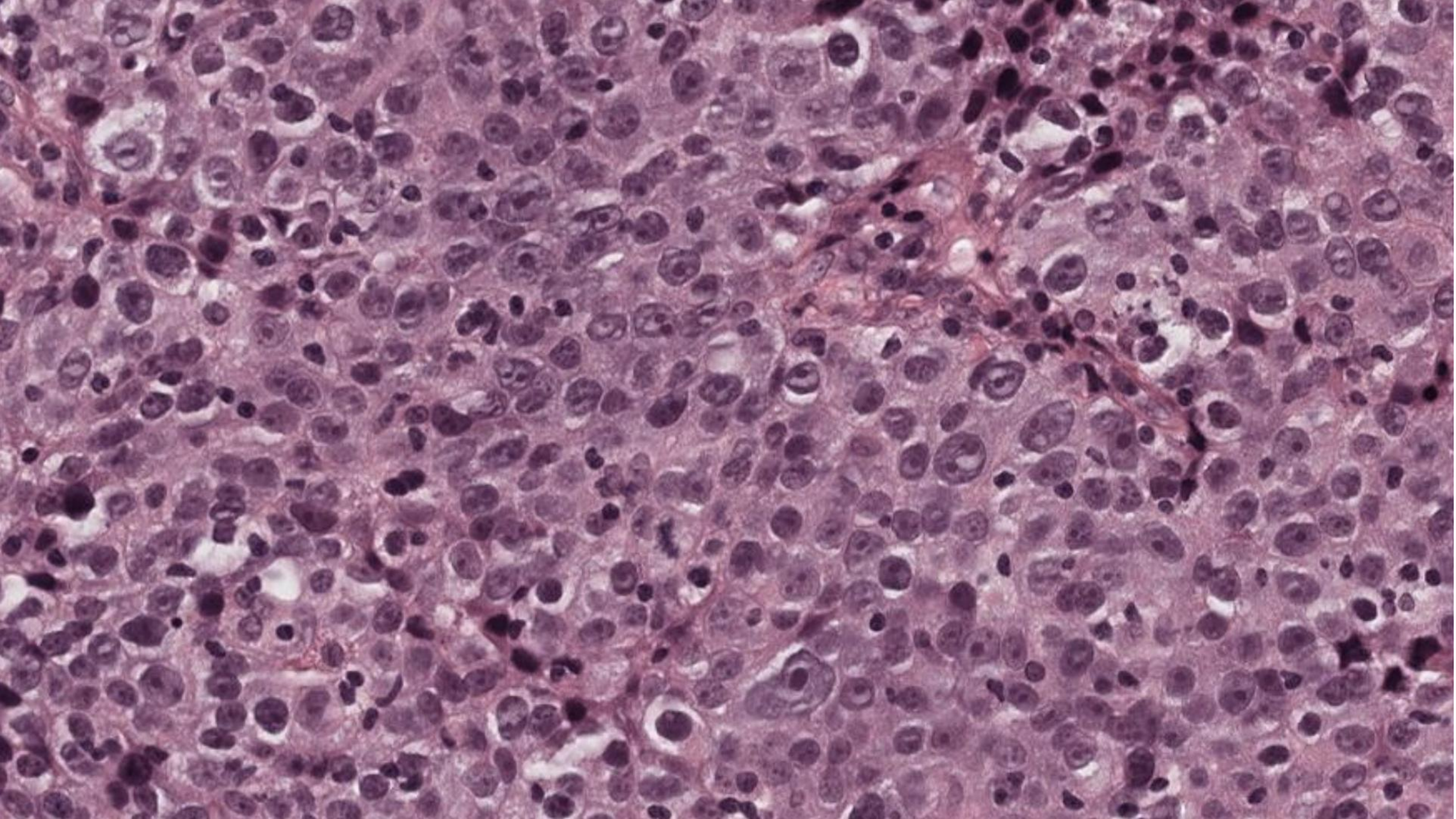

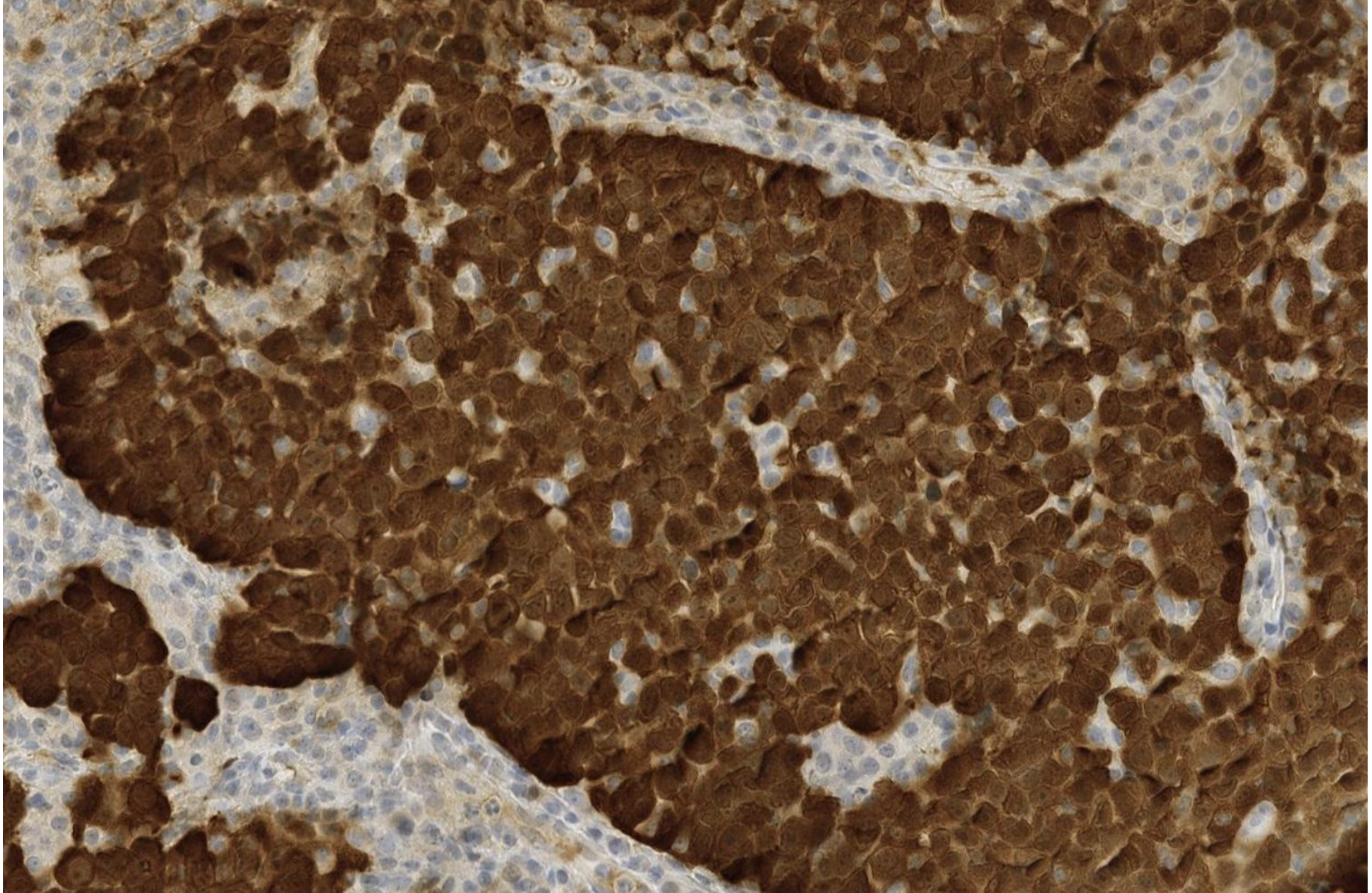

Case 1

Uterine Cervix Biopsy

H&E and P16

45 Year Old

Clinical History Provided:

‘Cervix mass. No smear in >10 years. Ascites.’

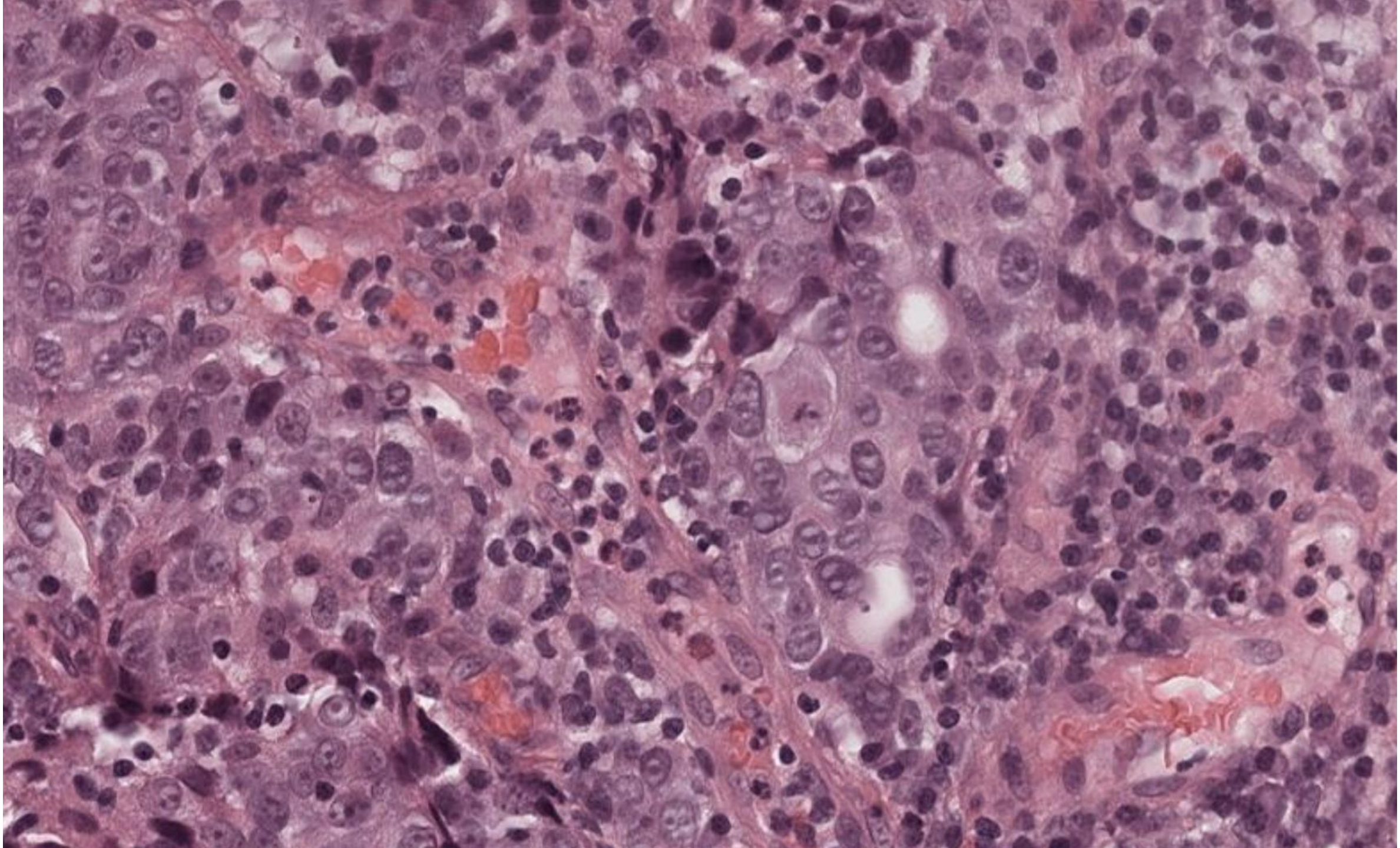

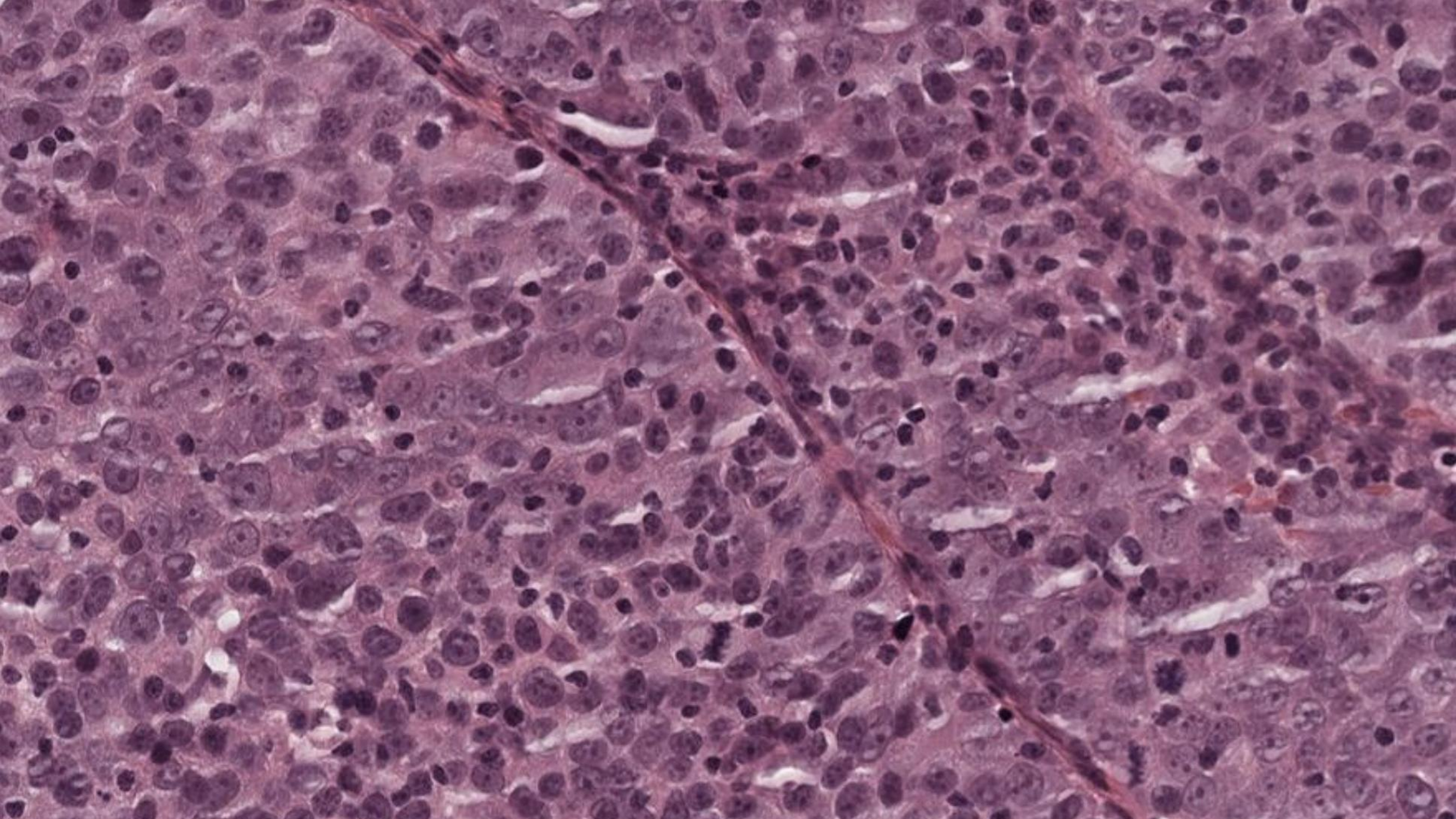

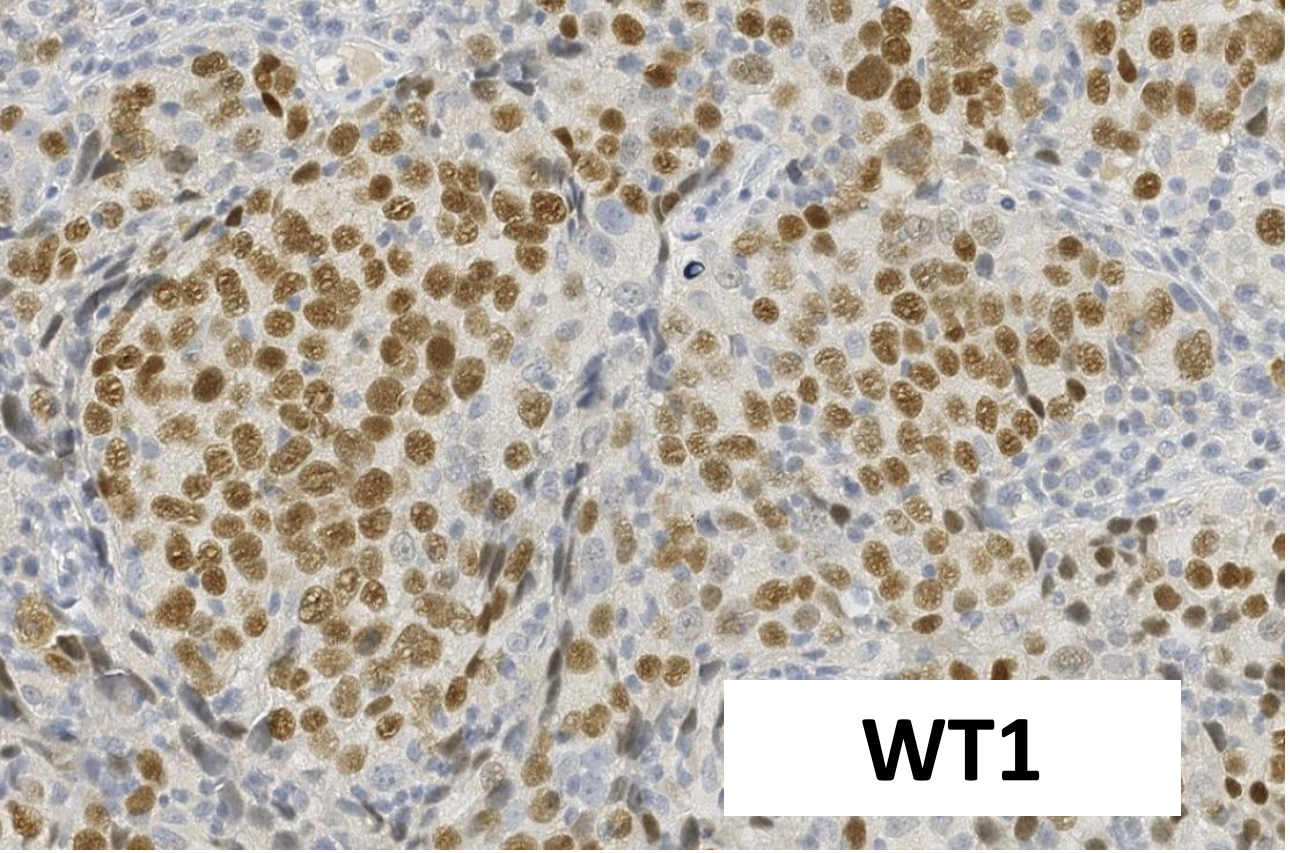
WT1

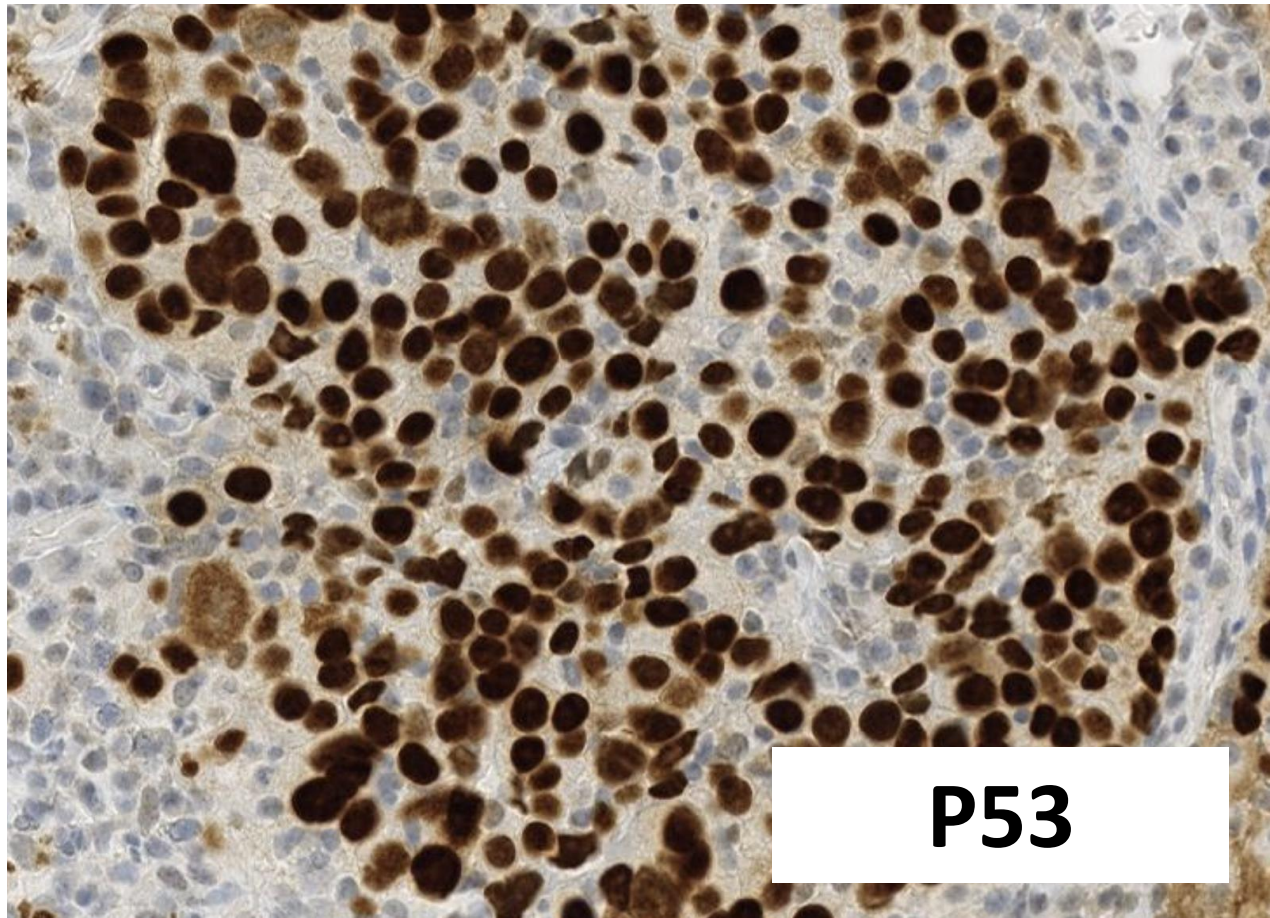
P53

Case 2

Uterine Cervix Biopsy

H&E and P16

70 Year Old

Clinical History Provided:

‘Incidental finding cervical polyp’

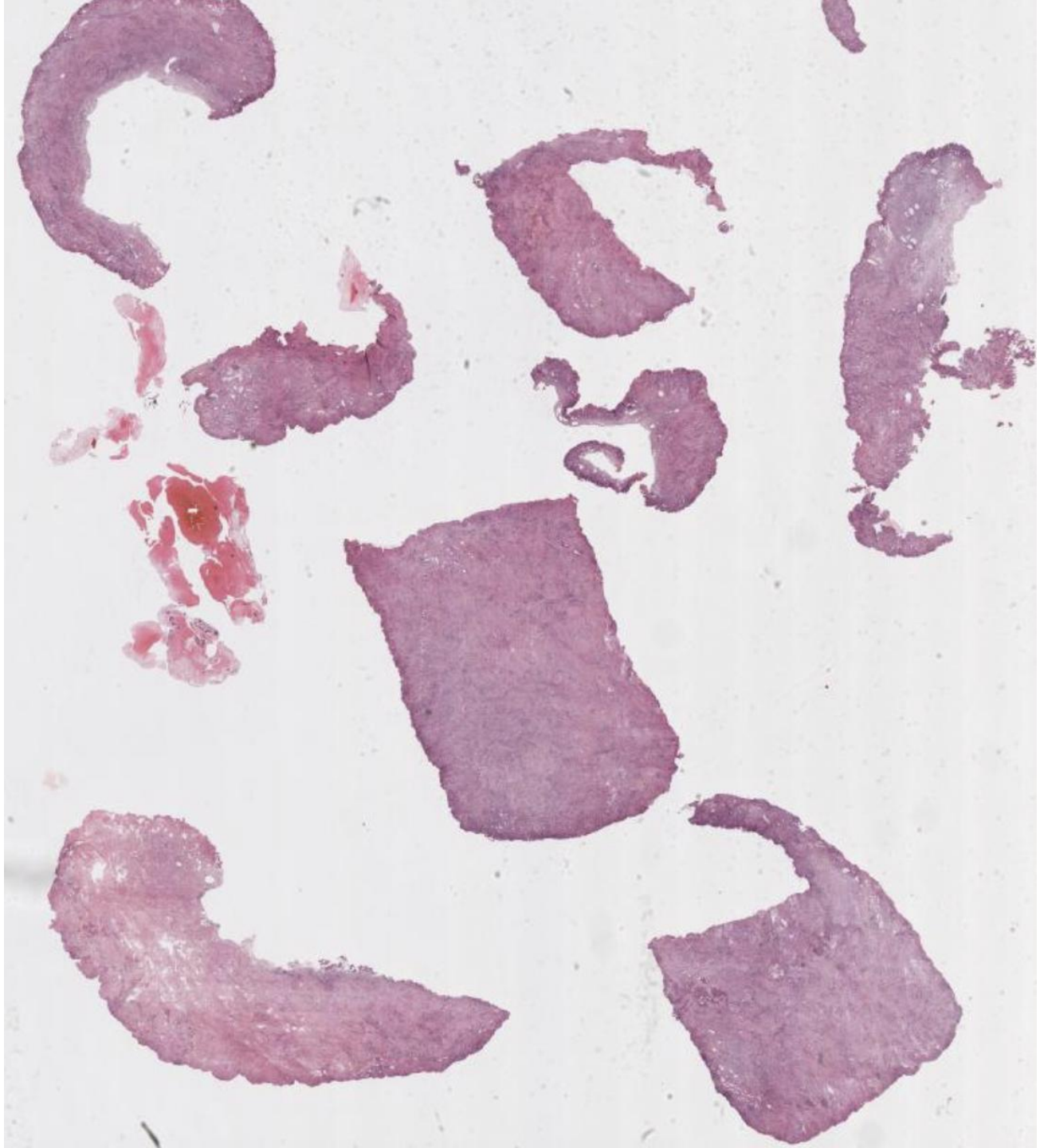

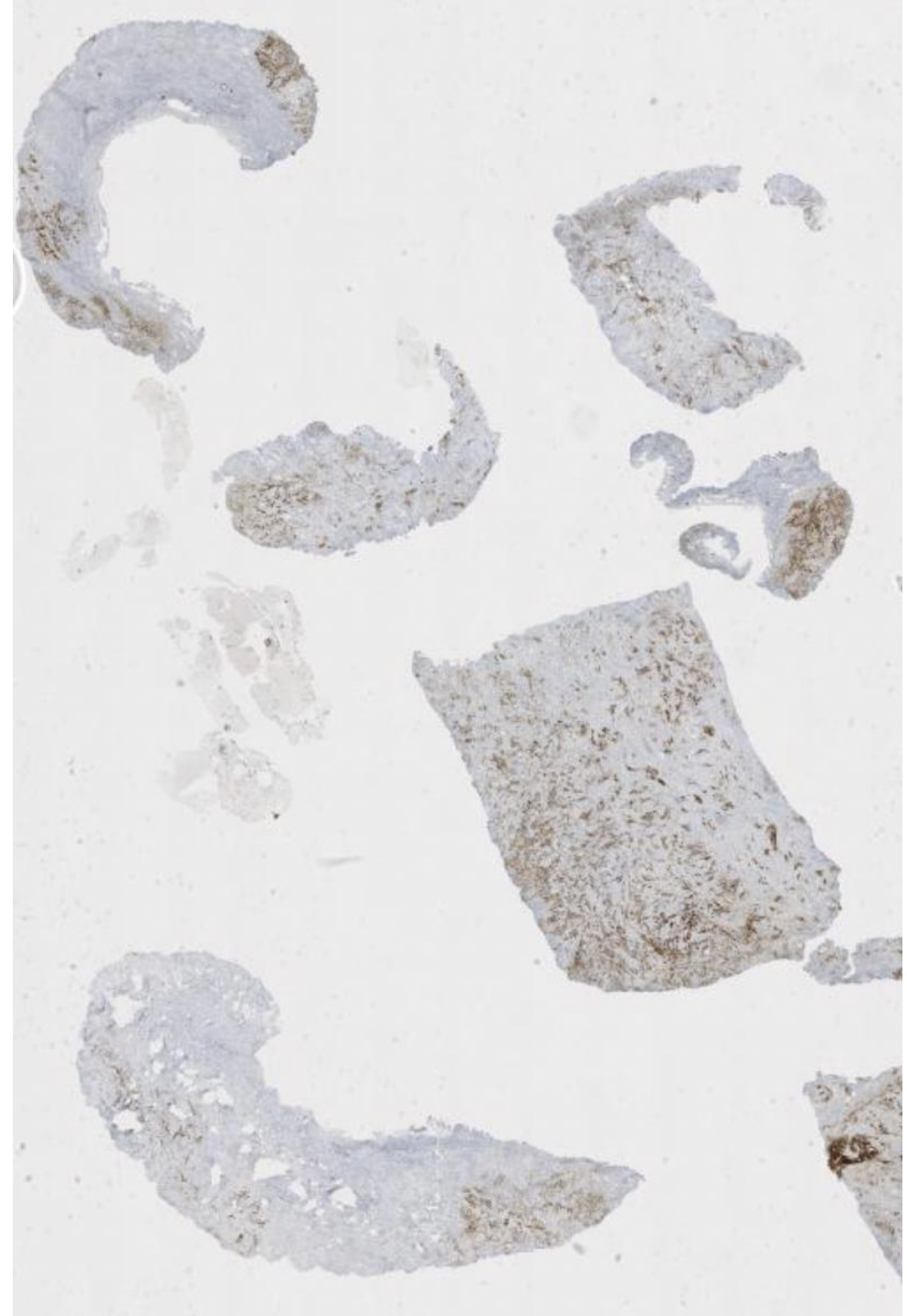

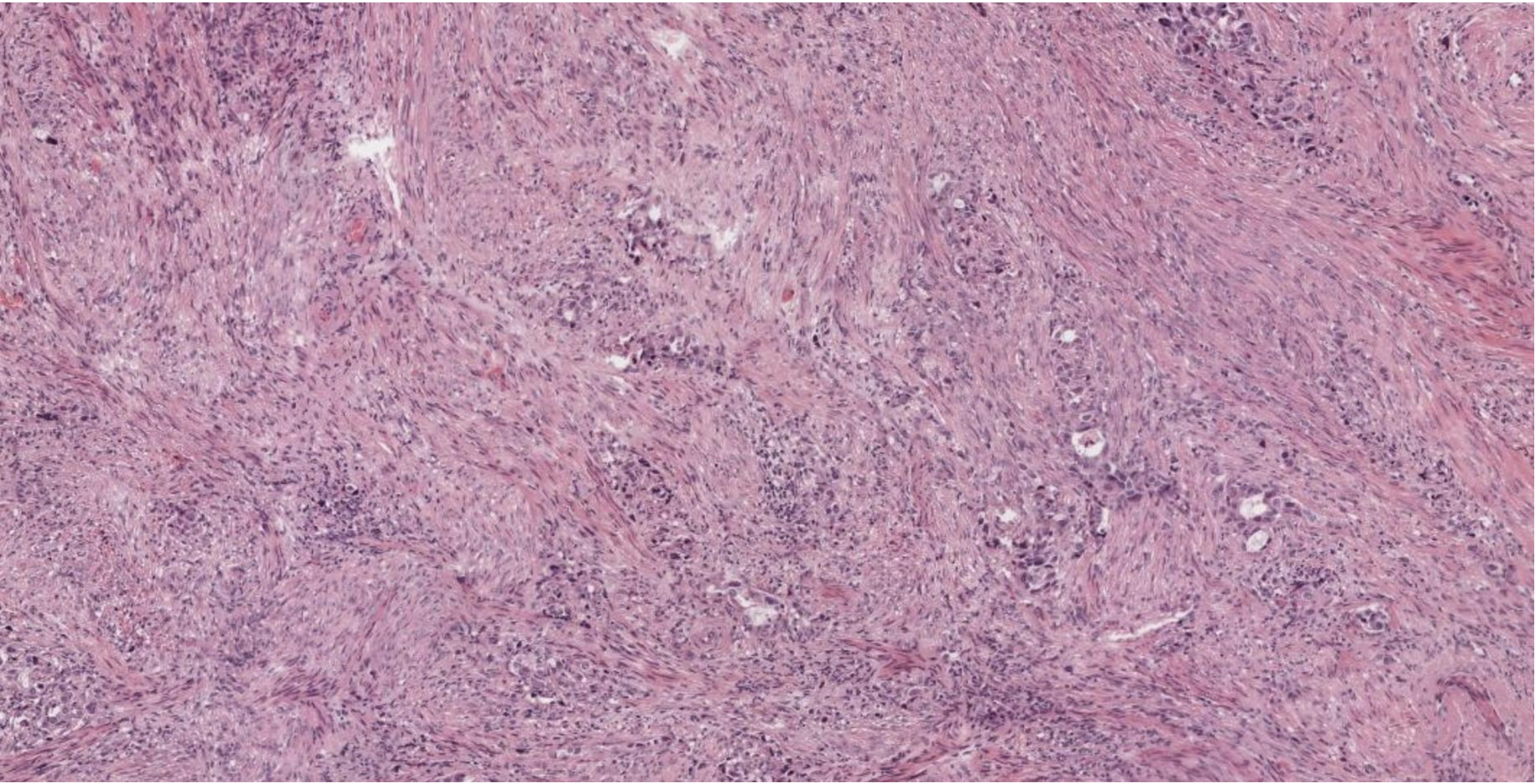

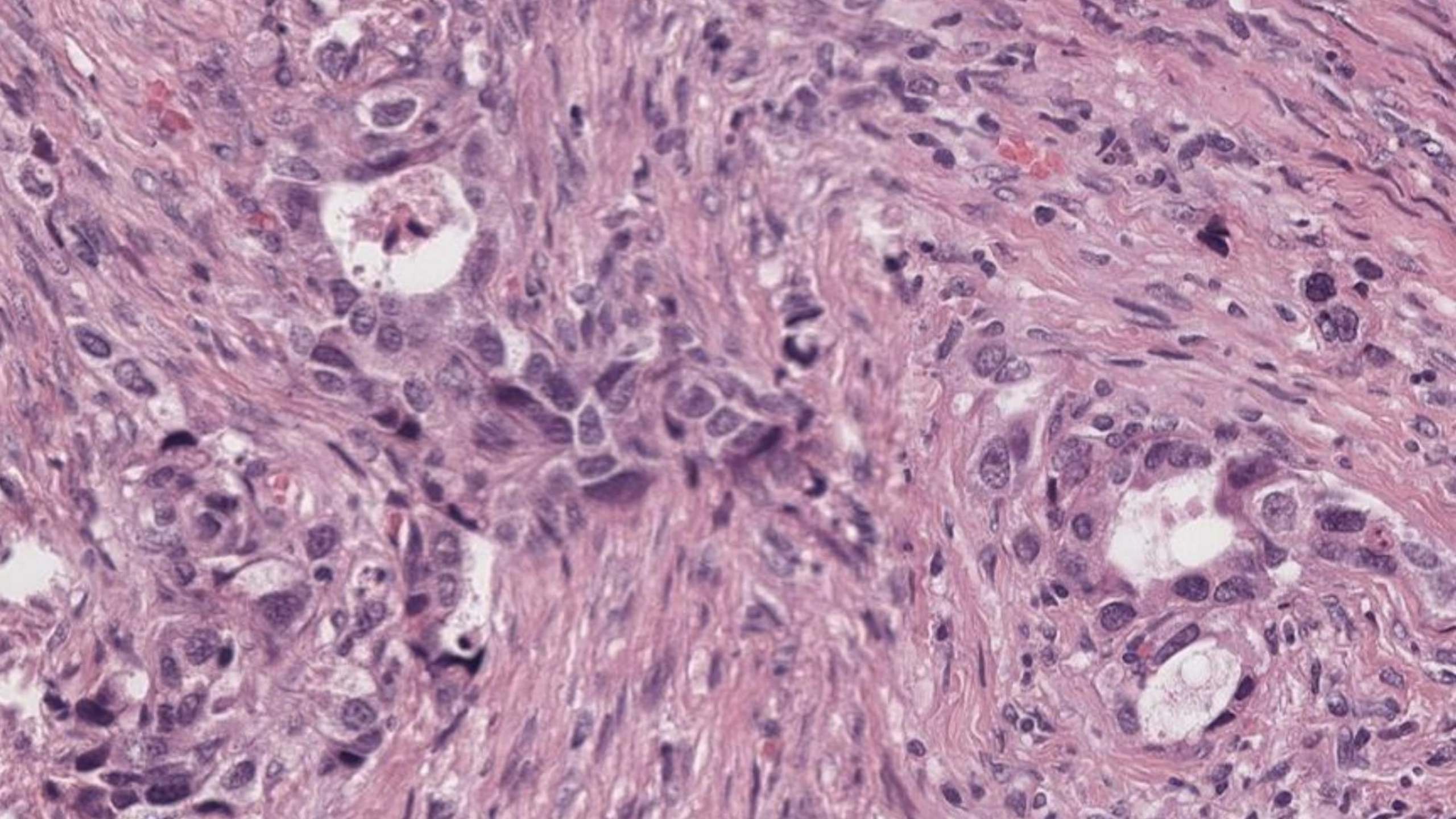

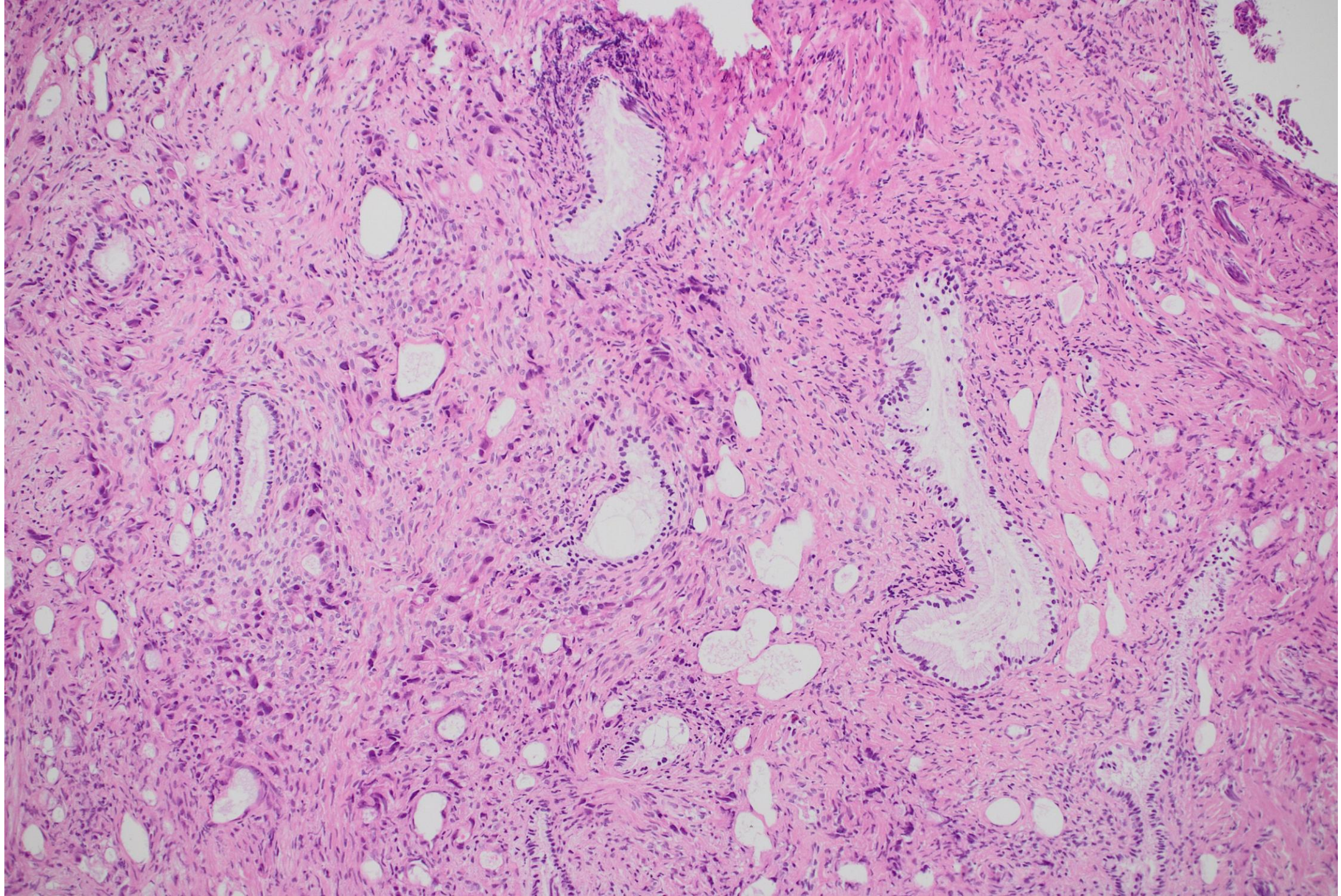

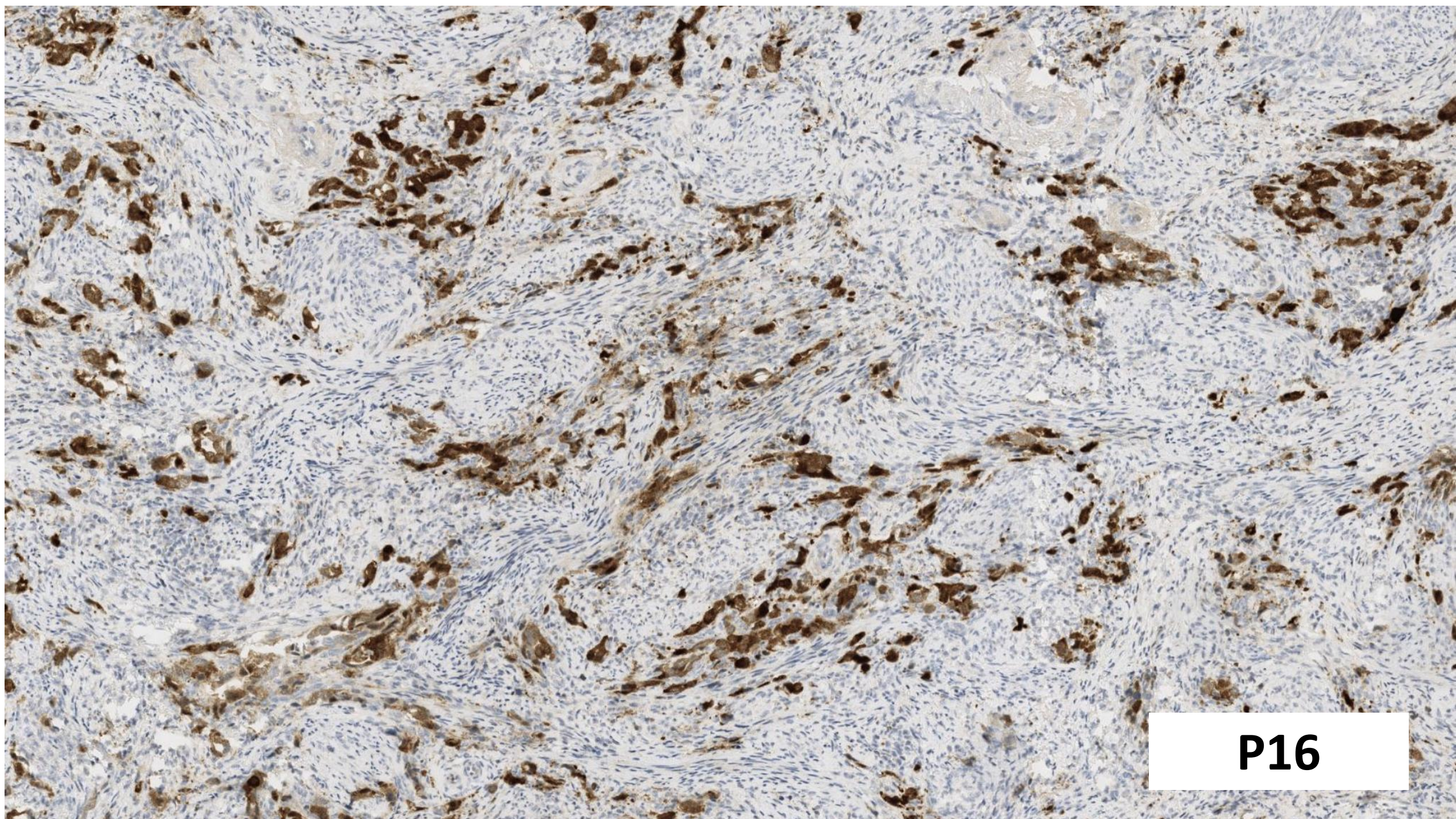
P16

- Referred from Hospital X to Gynaecology MDT as P16 positive Endocervical Adenocarcinoma

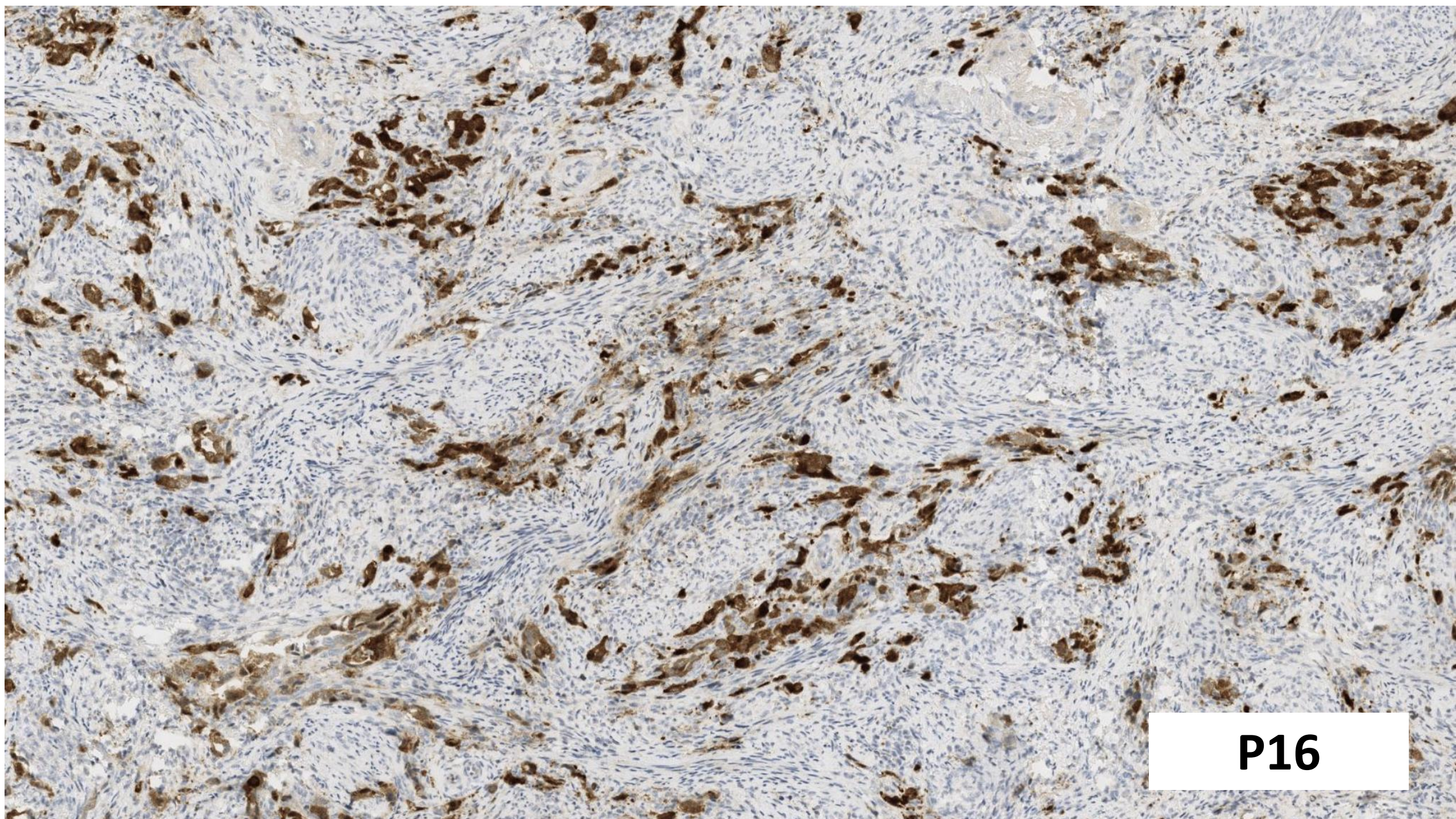
P16

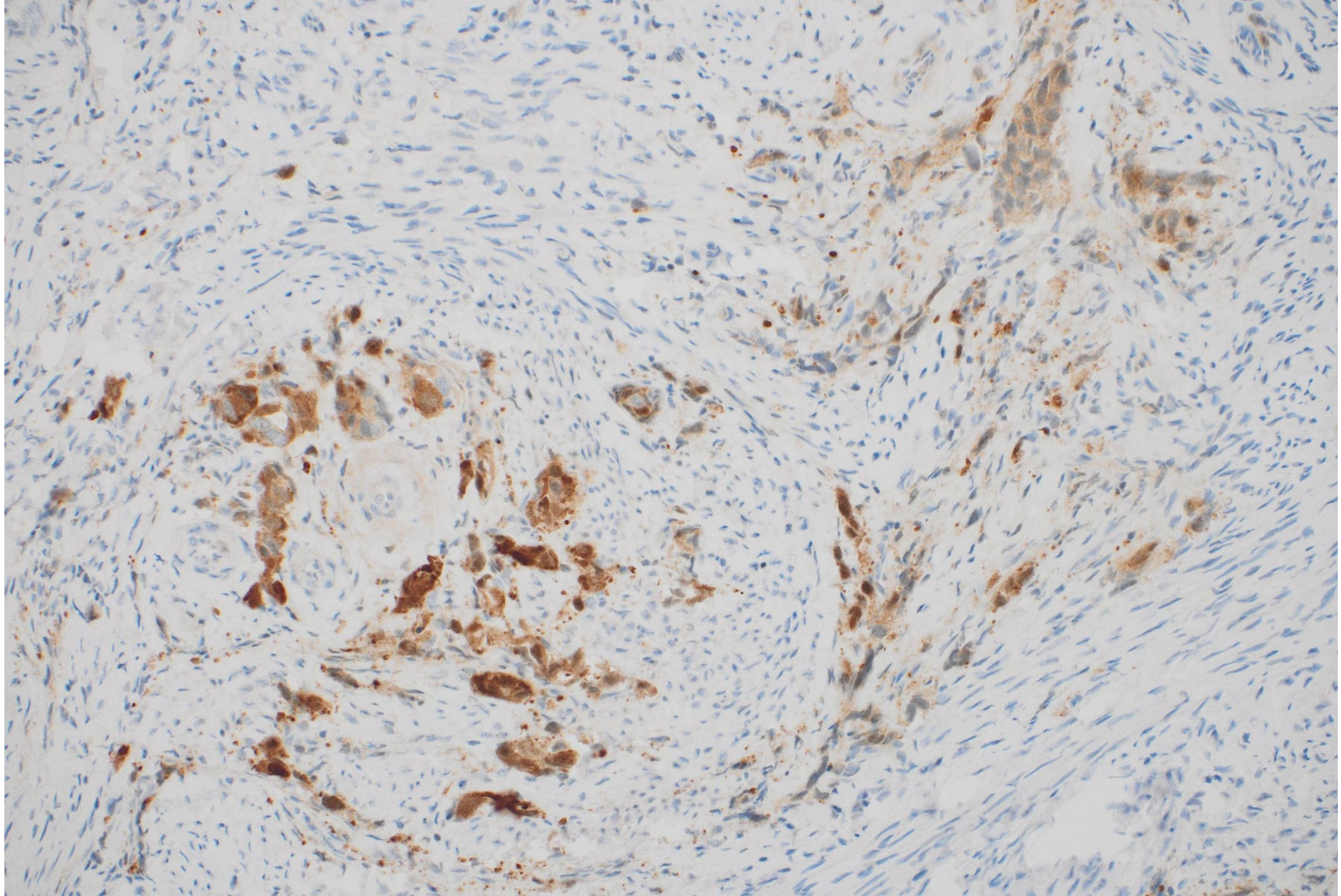

- Referred from Hospital X to Gynaecology MDT as P16 positive Endocervical Adenocarcinoma

- Notes for MDT meeting: History of Oesophageal Adenocarcinoma 1 year ago at Hospital Y

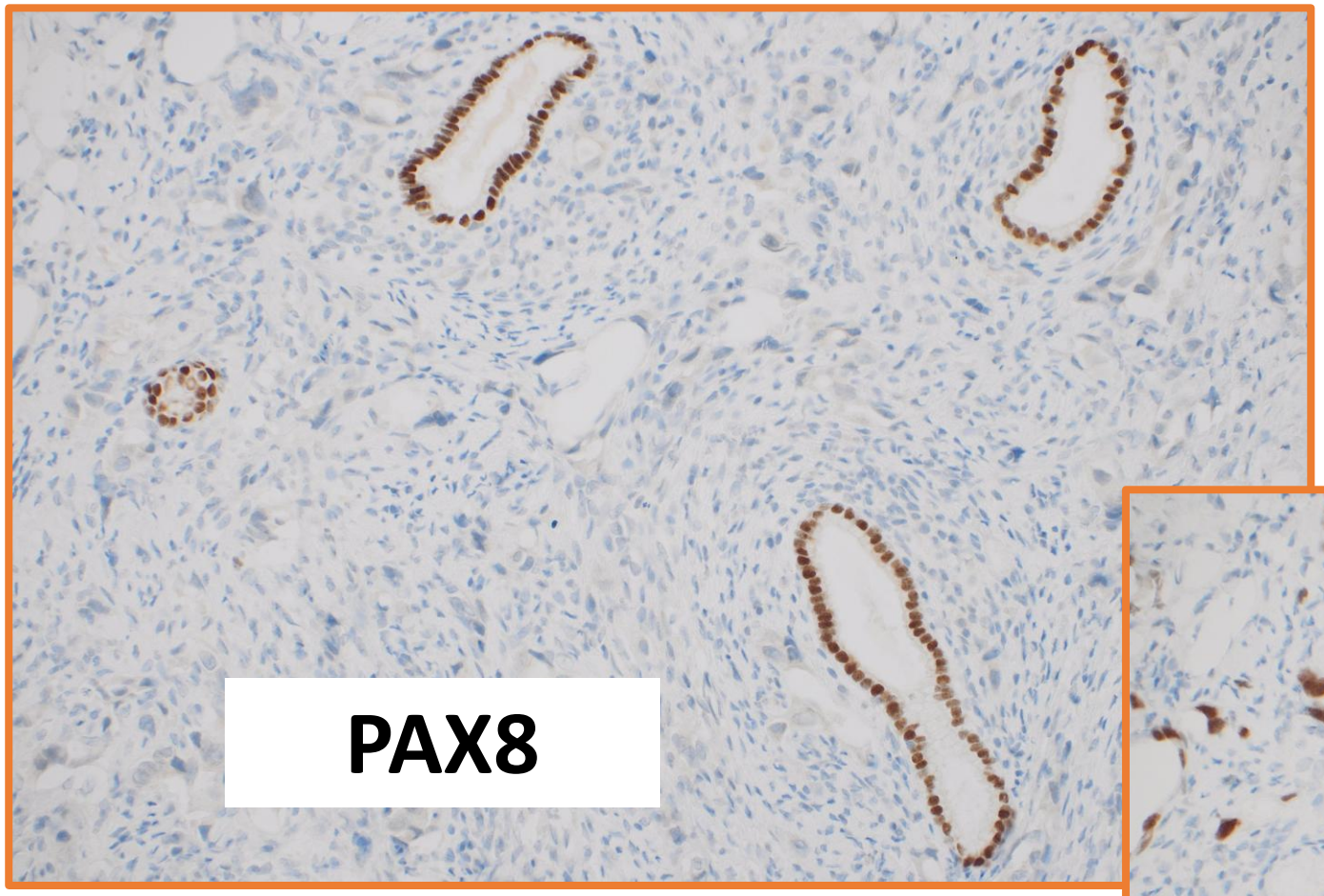
PAX8

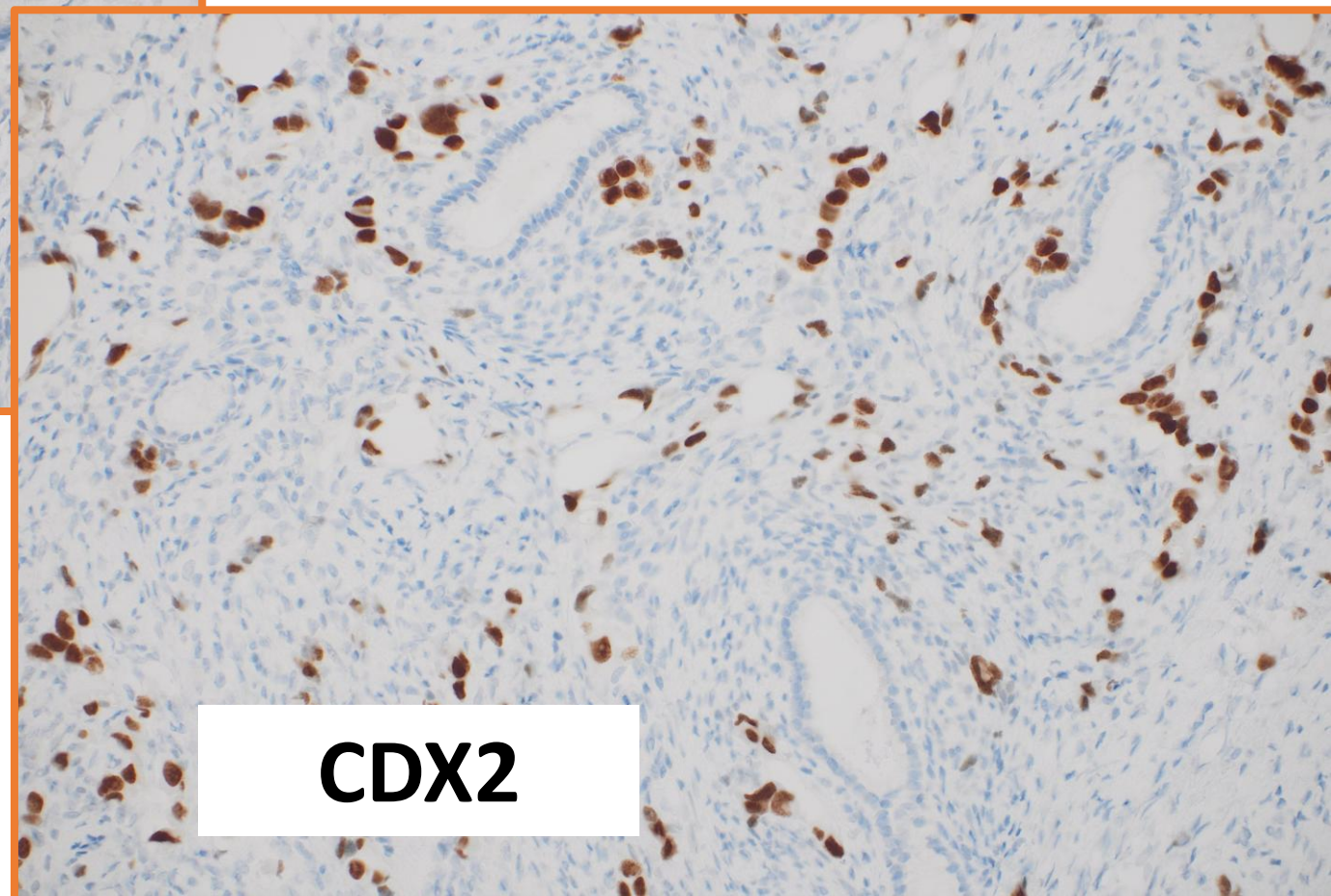
CDX2

- Referred from Hospital X to Gynaecology MDT as P16 positive Endocervical Adenocarcinoma
- Notes for MDT meeting: History of Oesophageal Adenocarcinoma 1 year ago at Hospital Y
- No cervical mass; subtle peritoneal thickening
- Oesophagectomy slides retrieved

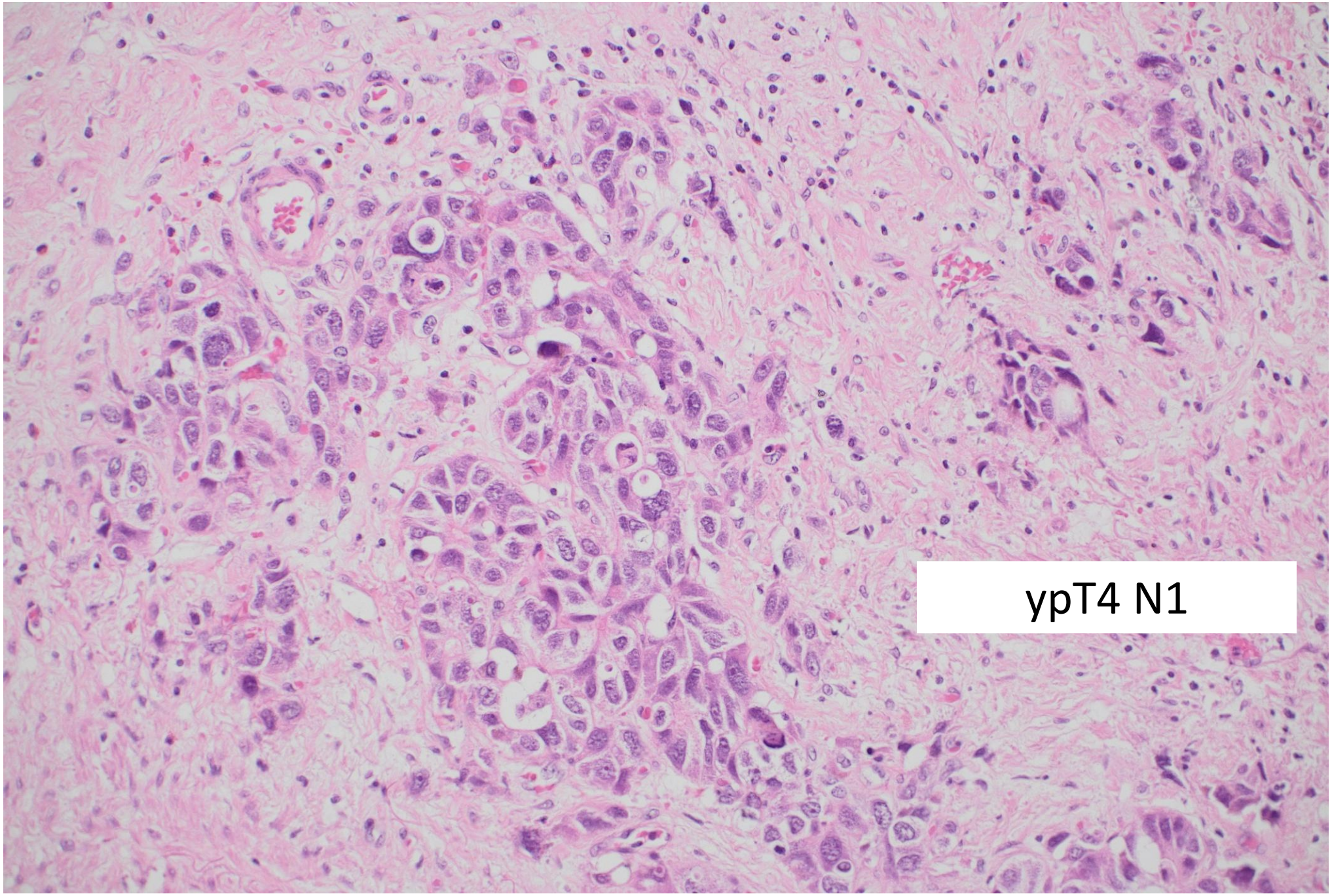
ypT4 N1

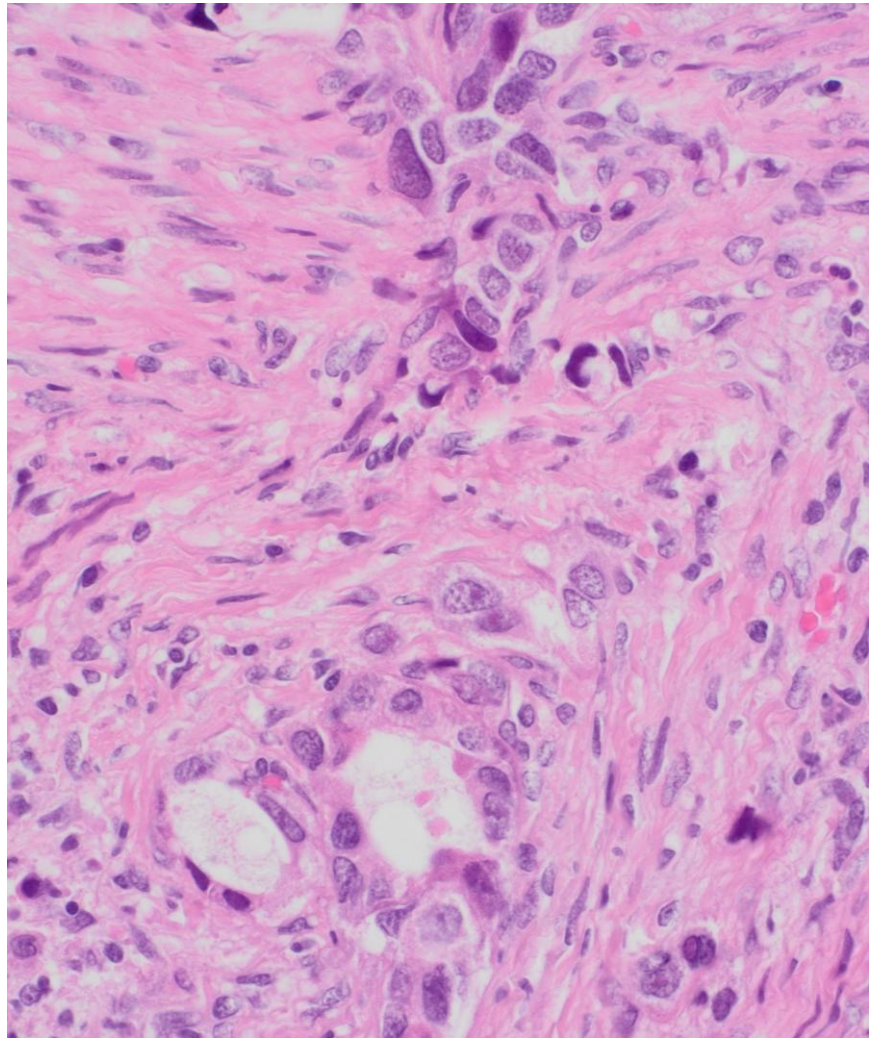

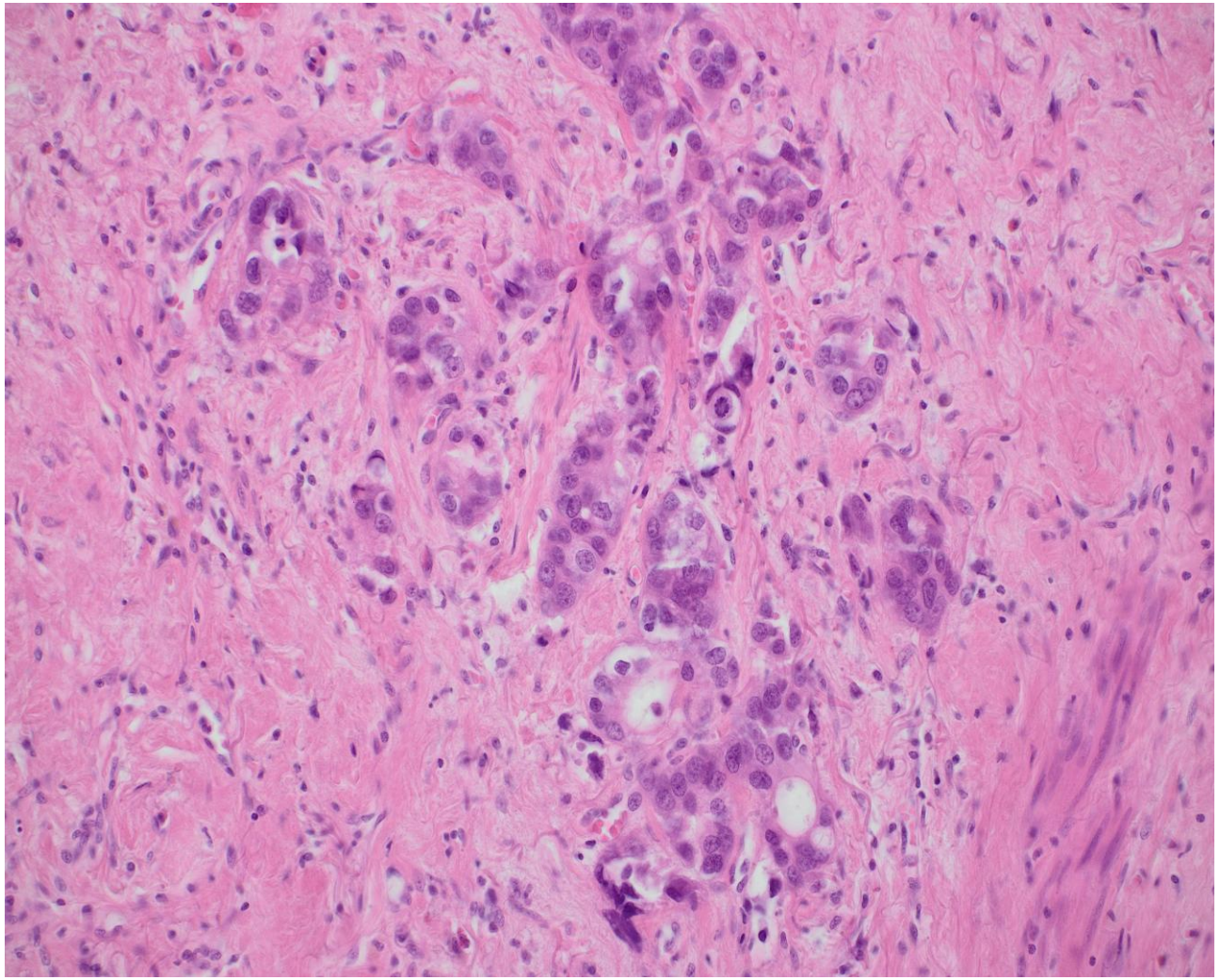

- Referred to Medical Oncology at Hospital Y

Unusual entities often instantly recognisable as challenging

Unusual entities often instantly recognisable as challenging

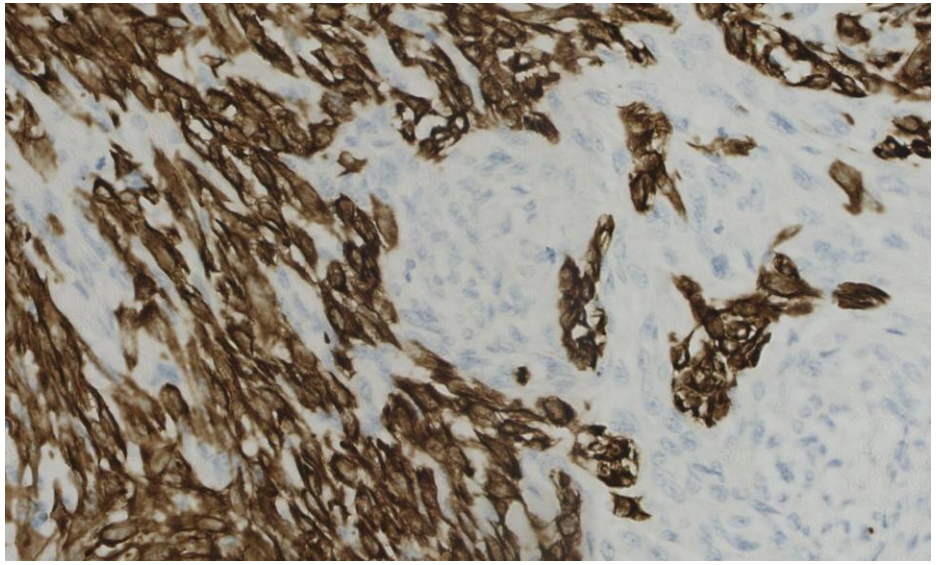

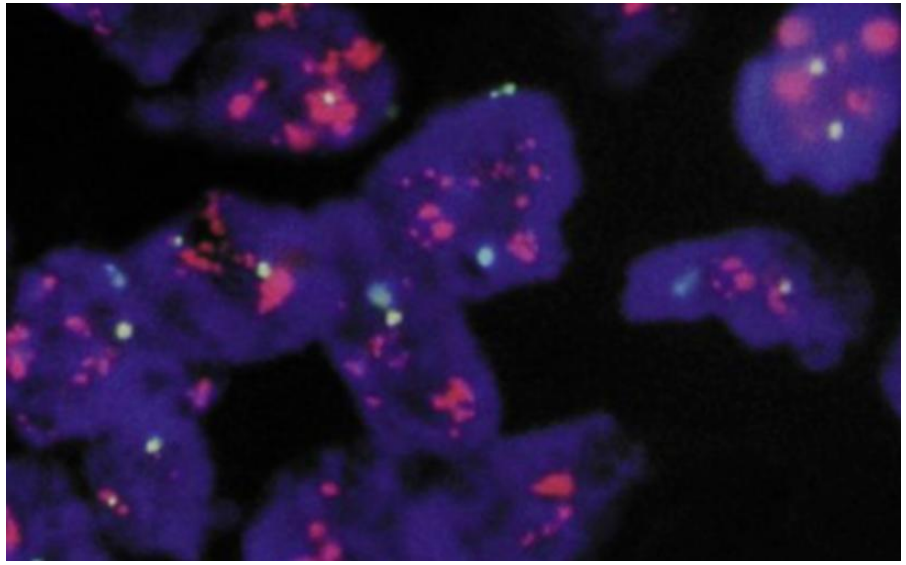

Unusual entities often instantly recognisable as challenging

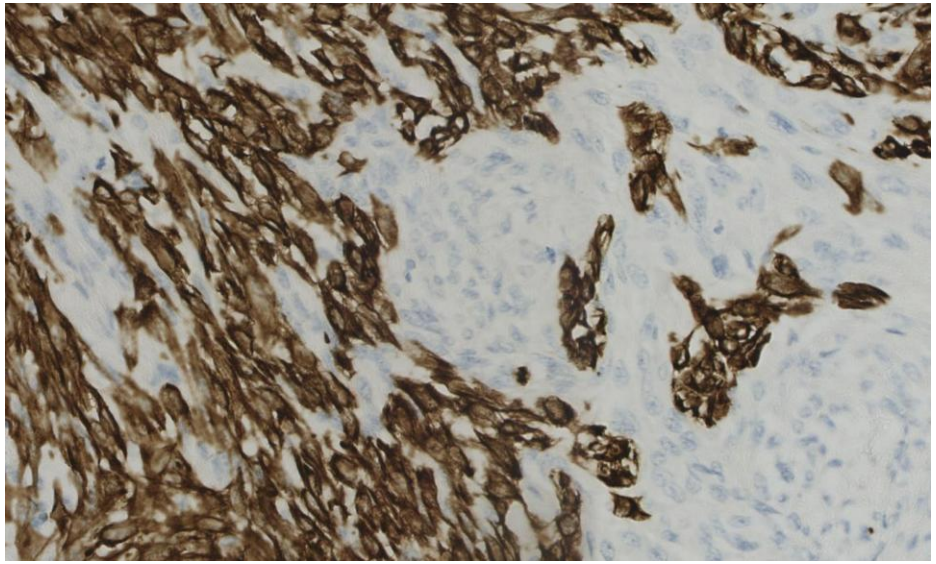

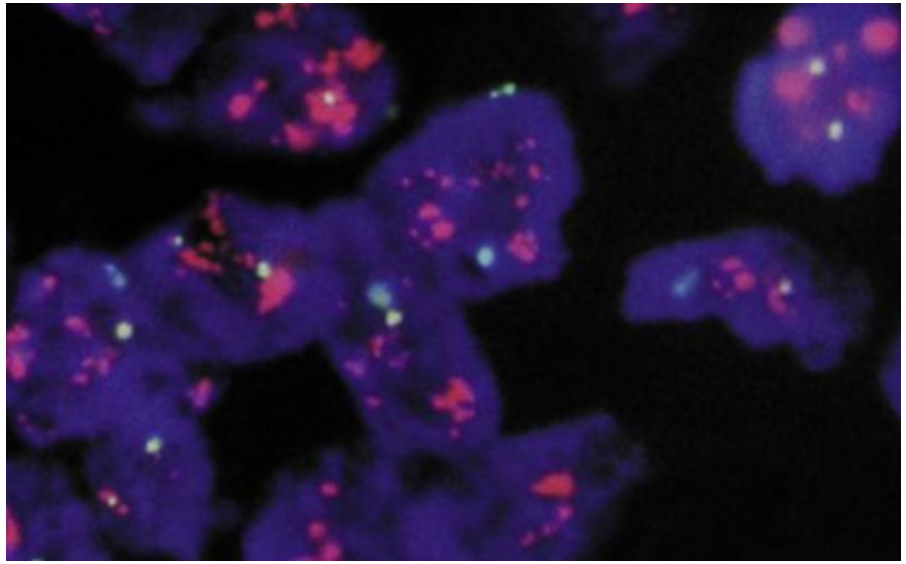



Mimics…

Metastatic Carcinomas in the Cervix Mimicking Primary Cervical Adenocarcinoma and Adenocarcinoma In Situ

Report of a Series of Cases

McCluggage, W. Glenn FRCPath; Hurrell, Daniel P. MD; Kennedy, Kathryn FIBMS

Author Information

The American Journal of Surgical Pathology 34(5):p 735-741, May 2010. | ***DOI:*** 10.1097/PAS.0b013e3181d6b8fd

Virchows Arch (2013) 463:23–29
DOI 10.1007/s00428-013-1436-y

ORIGINAL ARTICLE

Secondary malignancies of the uterine cervix: a potential diagnostic pitfall

Gian Franco Zannoni · Valerio Gaetano Vellone · Marco Petrillo · Guido Fadda · Esther Diana Rossi · Giovanni Scambia · Arnaldo Carbone

- 144 Cases
- 65% Endometrial Carcinoma
- 16% Tubo-ovarian Carcinoma

Secondary Involvement of the Uterine Cervix by Nongynecologic Neoplasms

A Detailed Clinicopathologic Analysis

Gulisa Turashvili, MD, PhD,† Wesley R. Samore, MD,‡ Esther Oliva, MD,‡ Olga Ioffe, MD,§ Robert Riddell, MBBS,† Kay J. Park, MD,* and Lars-Christian Horn, MD‖*

(*Am J Surg Pathol* 2020;44:1699–1711)

Metastases to the gynecologic tract most commonly involve ovaries and vagina (~80%).[1] Secondary involvement of the cervix is most frequently due to contiguous extension of endometrial carcinomas or drop metastases from adnexal carcinomas.[2,3] Nongynecologic metastases to the cervix are exceedingly uncommon, accounting for <2% of metastases to the gynecologic tract.[1,4] The most common nongynecologic primary sites of origin include the gastrointestinal tract and breast.

Secondary Involvement of the Uterine Cervix by Nongynecologic Neoplasms

A Detailed Clinicopathologic Analysis

Gulisa Turashvili, MD, PhD,† Wesley R. Samore, MD,‡ Esther Oliva, MD,‡ Olga Ioffe, MD,§ Robert Riddell, MBBS,† Kay J. Park, MD,* and Lars-Christian Horn, MD‖*

(*Am J Surg Pathol* 2020;44:1699–1711)

Metastases to the gynecologic tract most commonly involve ovaries and vagina (~80%).[1] Secondary involvement of the cervix is most frequently due to contiguous extension of endometrial carcinomas or drop metastases from adnexal carcinomas.[2,3] Nongynecologic metastases to the cervix are exceedingly uncommon, accounting for <2% of metastases to the gynecologic tract.[1,4] The most common nongynecologic primary sites of origin include the gastrointestinal tract and breast.

Secondary Involvement of the Uterine Cervix by Nongynecologic Neoplasms

A Detailed Clinicopathologic Analysis

Gulisa Turashvili, MD, PhD,† Wesley R. Samore, MD,‡ Esther Oliva, MD,‡ Olga Ioffe, MD,§ Robert Riddell, MBBS,† Kay J. Park, MD,* and Lars-Christian Horn, MD‖*

(*Am J Surg Pathol* 2020;44:1699–1711)

- 47 cases (39 carcinoma; remainder lymphoma and melanoma)
- 69% from gastrointestinal tract
- Frequently mimic primary cervical tumour
- **13% initially misdiagnosed as cervical primary**

Morphologic Clues

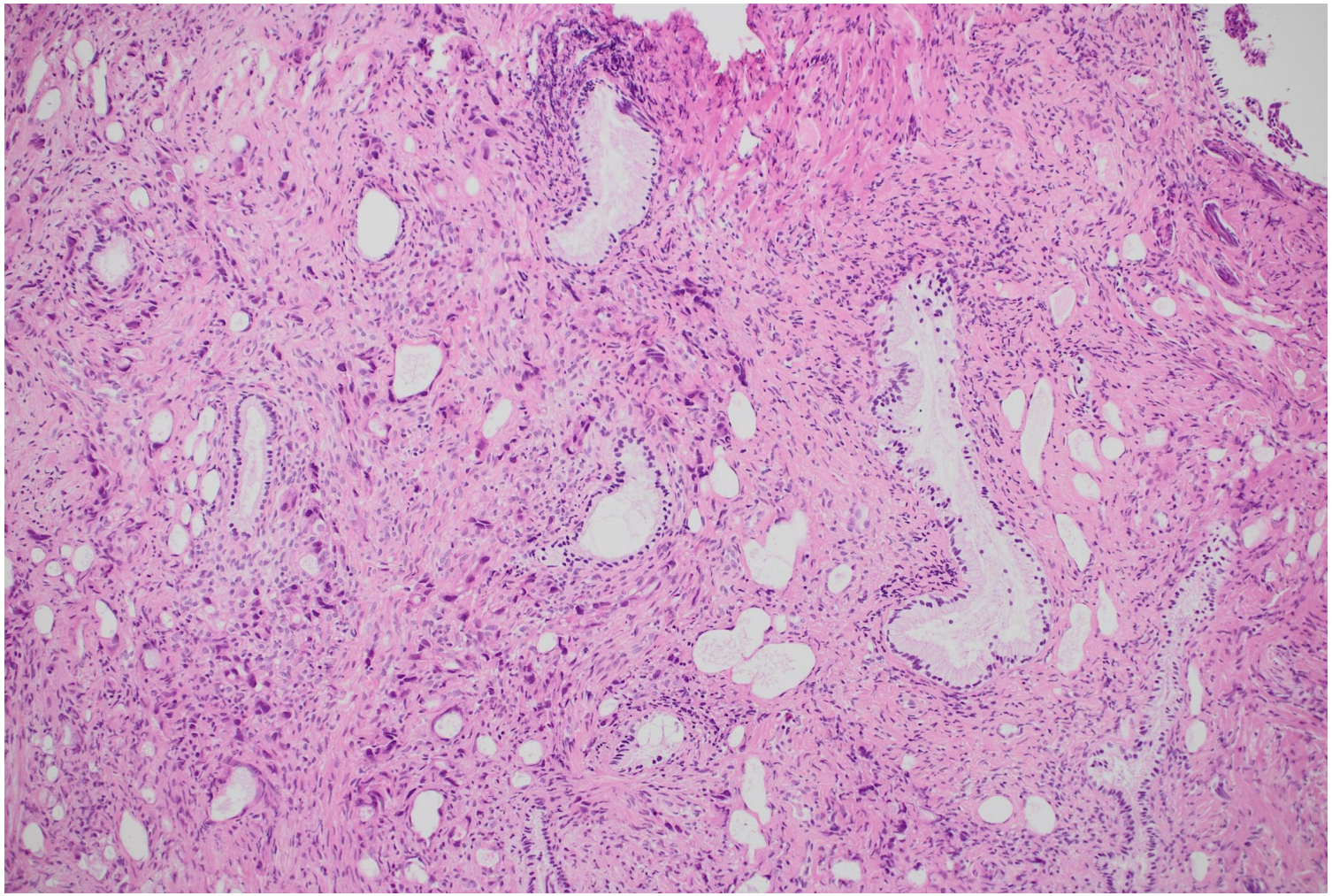

High Level of Suspicion



Awareness of Typical Features of Cervical Adenocarcinoma

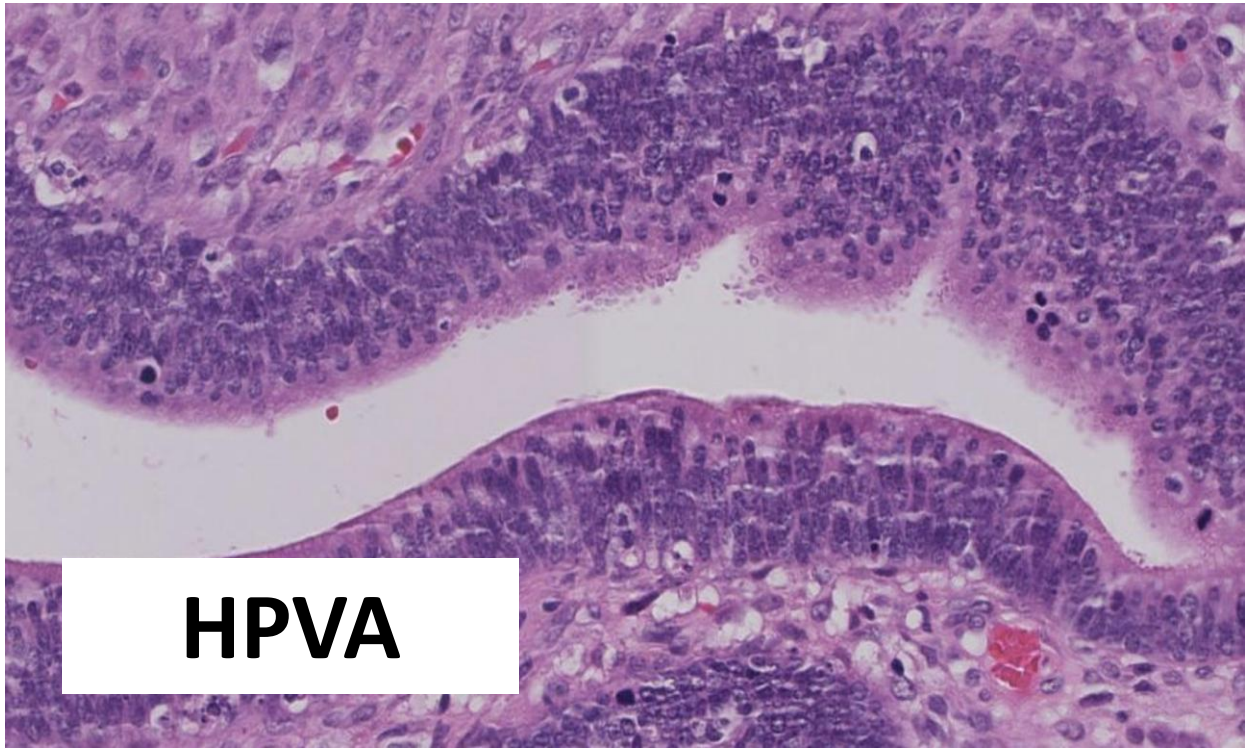

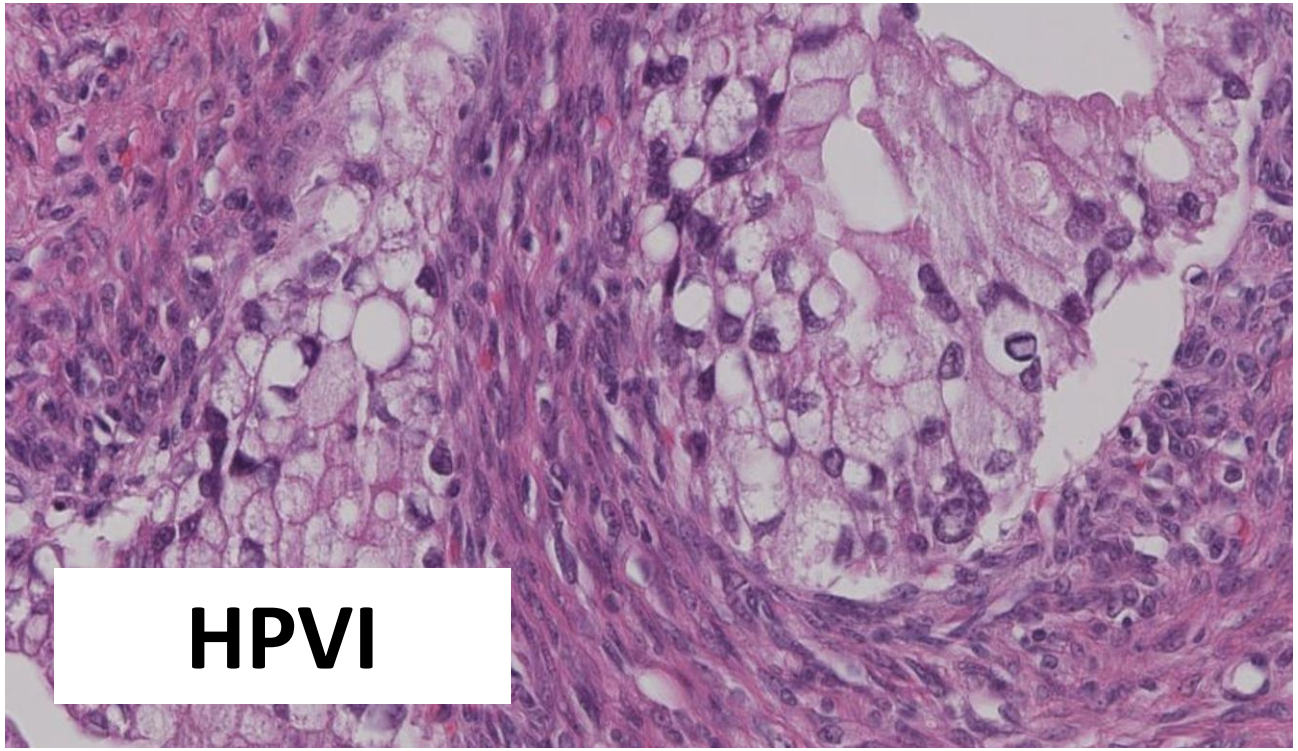

Case 3

Unilateral Salpingo-Oophorectomy

H&E

45 Year Old

Clinical History Provided:

Unilateral Ovarian Mass

Case 4

Bilateral Salpingo-Oophorectomy

H&E

45 Year Old

Clinical History Provided:

Bilateral Ovarian Masses

Awareness of Typical Features of Cervical Adenocarcinoma

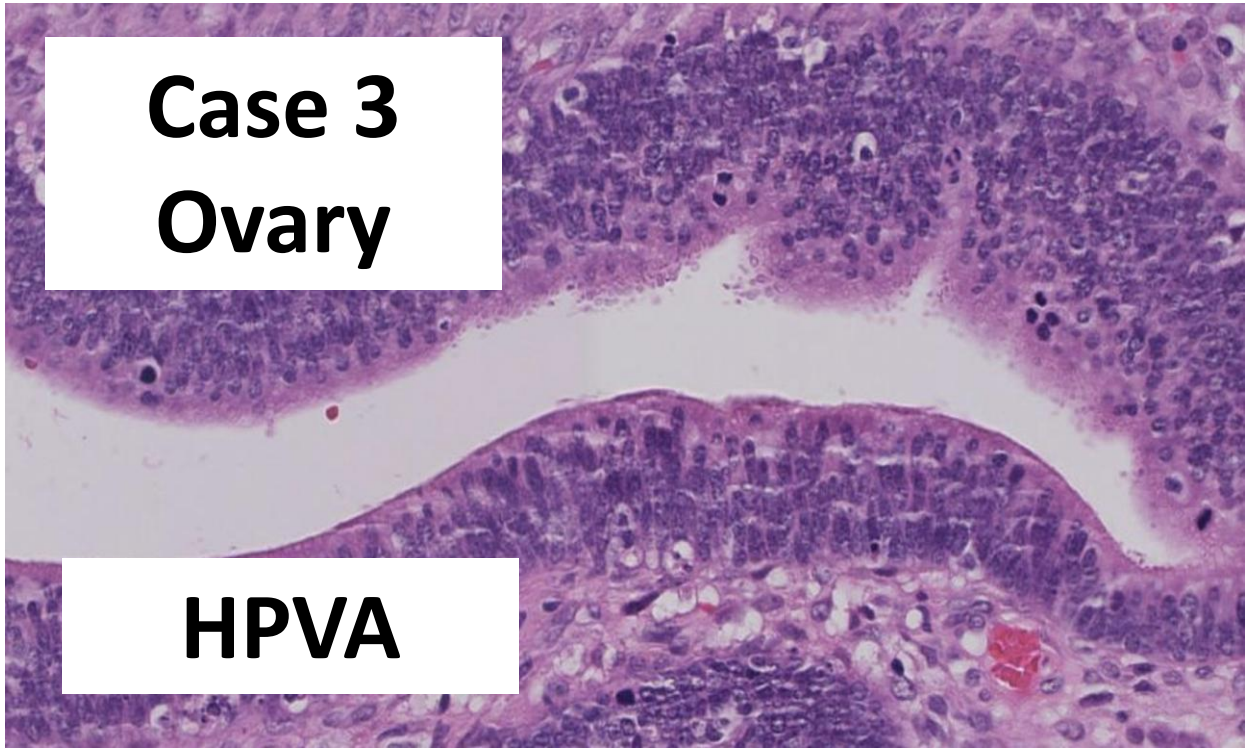

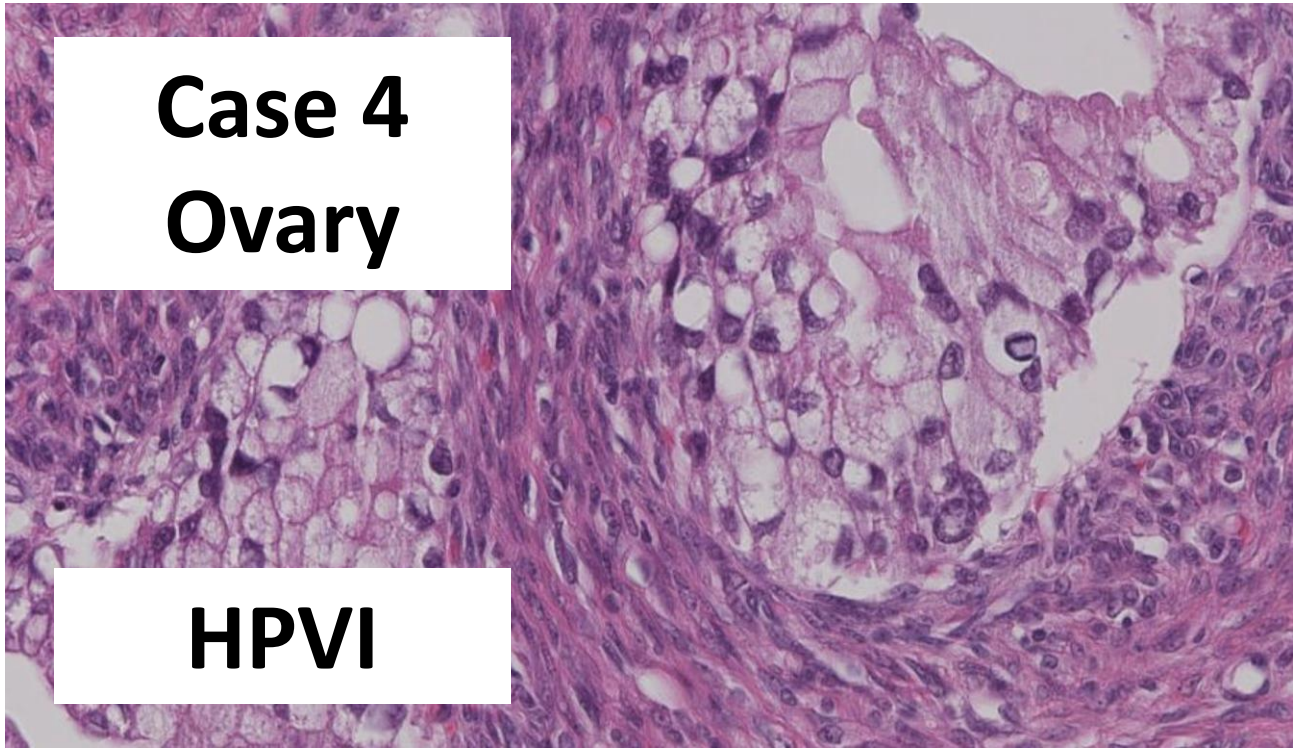

Awareness of Typical Features of Cervical Adenocarcinoma

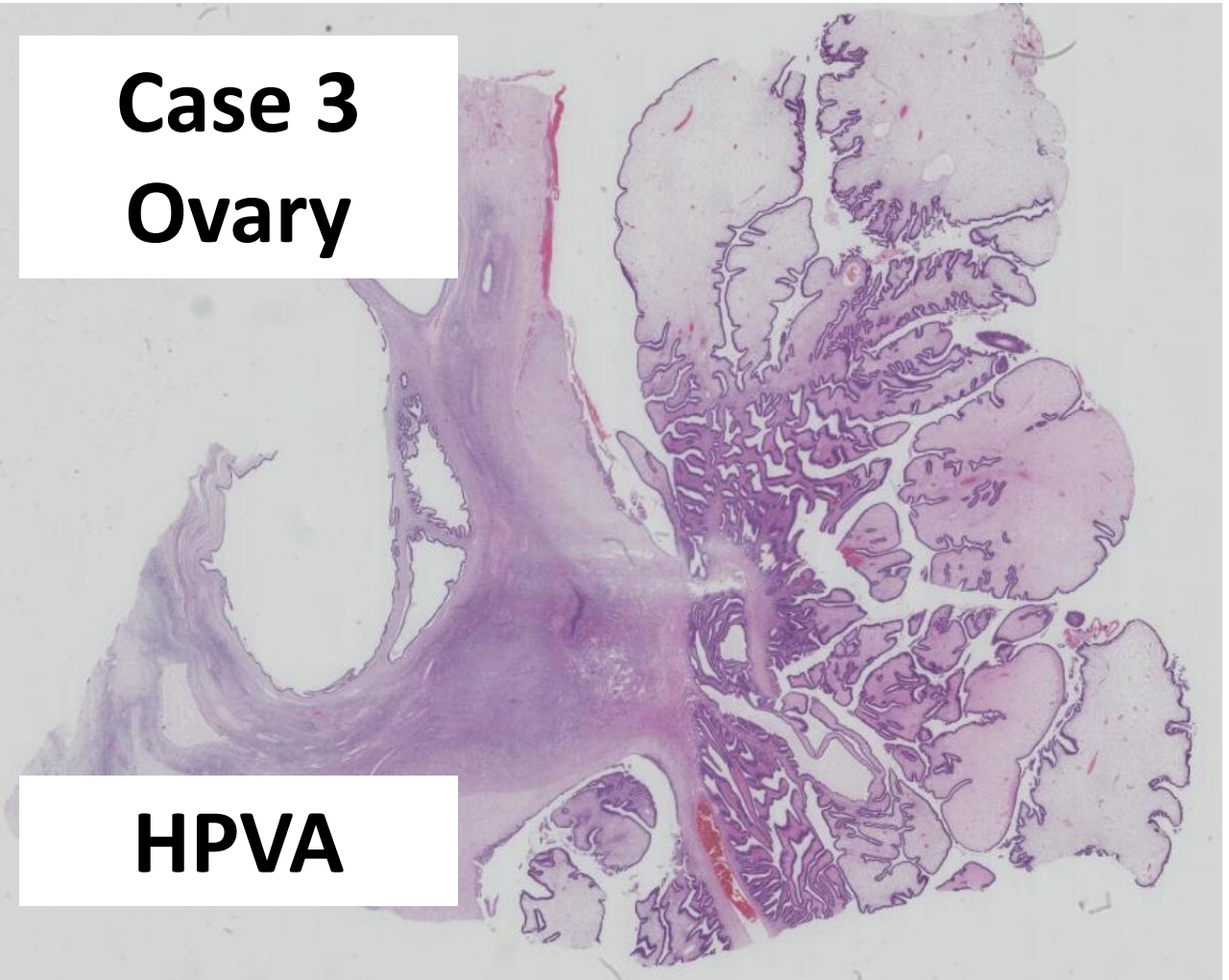

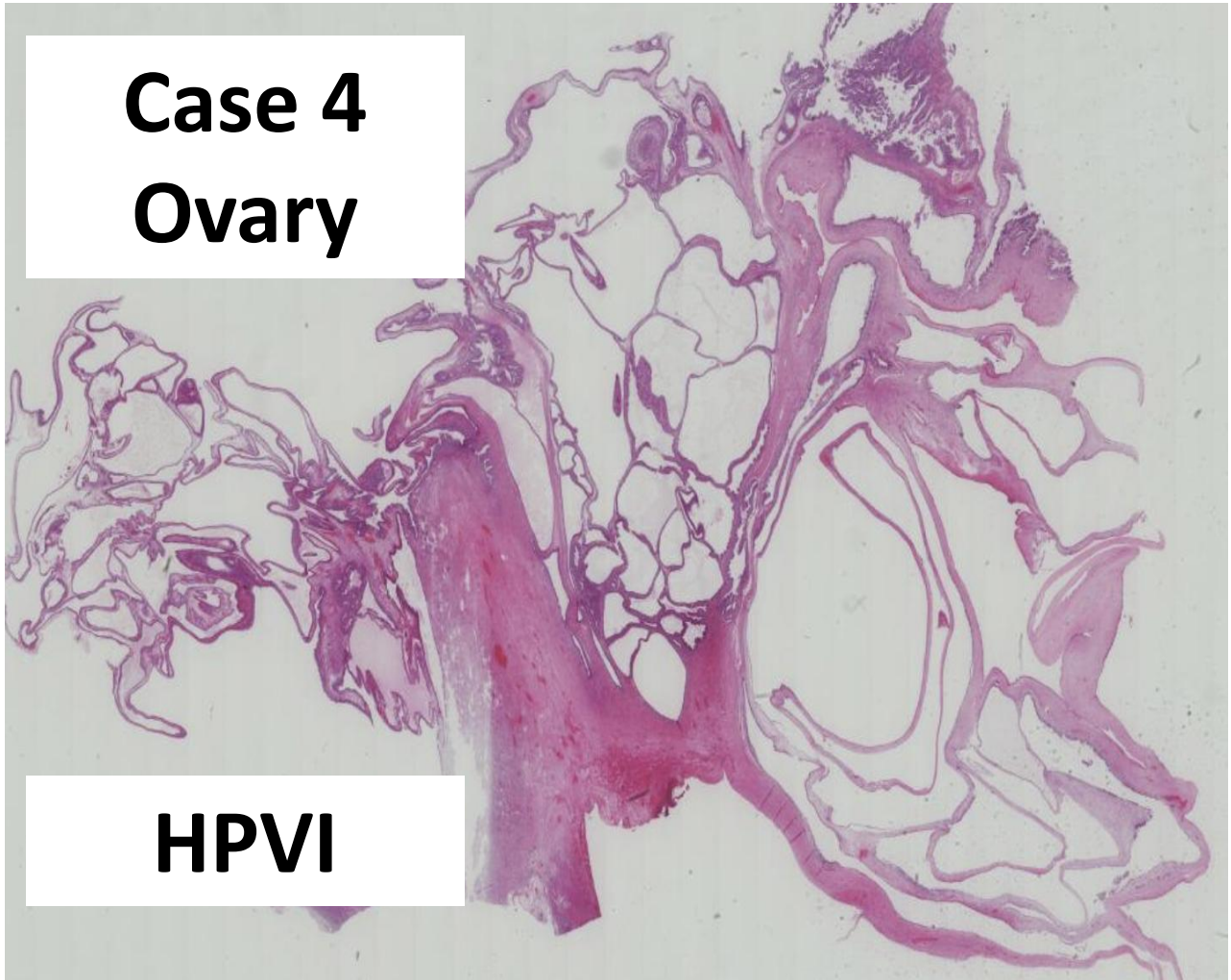

Endocervical Adenocarcinomas With Ovarian Metastases

Analysis of 29 Cases With Emphasis on Minimally Invasive Cervical Tumors and the Ability of the Metastases to Simulate Primary Ovarian Neoplasms

Ronnett, Brigitte M. MD[*†]; Yemelyanova, Anna V. MD[*]; Vang, Russell MD[*†]; Gilks, C. Blake MD[‡]; Miller, Dianne MD[§]; Gravitt, Patti E. PhD[‖]; Kurman, Robert J. MD[*†]

Author Information

The American Journal of Surgical Pathology 32(12):p 1835-1853, December 2008. | ***DOI:*** 10.1097/PAS.0b013e3181758831

Conclusion

- **Think of metastases (to and from cervix)**
- **P16 pitfalls**
- **High level of suspicion required**
- **Microscopic, clinical and imaging features most important**
- **Vital for treatment and prognosis**

All May Not Be As It Seems

