The British Association of Gynaecological Pathologists

Lecturer – Prof. Koen Van de Vijver



Prof. Koen Van de Vijver is a surgical pathologist with a keen interest in the diagnosis and treatment of cancers of the female genital tract and the breast. Most of his activities involve diagnostic work, teaching, and clinico-pathologic research. His research is mainly focused on the molecular analysis of ovarian neoplastic diseases. He is co-author of more than 150 peer-reviewed A1 publications, including New England Journal of Medicine, Nature Medicine and Journal of Clinical Oncology.

In 2011-2012 he completed a full year fellowship with prof. dr. Esther Oliva in Gynaecological Pathology at Massachusetts General Hospital, Harvard Medical School, Boston (USA). After working as a consultant histopathologist in the Netherlands Cancer Institute in Amsterdam (NL), he became Professor of Gynaecological Pathology at Ghent University (Belgium) in 2018. He serves on several guidelines panels and subspecialized gynaecological and breast pathology working groups. Currently, he is a council member of the BAGP, councillor of the International Collaboration on Cancer Reporting (ICCR), and President of the Belgian Society of Pathology (BSP).

The British Association of Gynaecological Pathologists

Vulvo-Vaginal Update Course

- Title: HPV associated lesions (including depth of invasion)
- Speaker: Koen Van de Vijver
- Affiliation: Ghent University Hospital, Belgium
- Date: November 29, 2024

The British Association of Gynaecological Pathologists

Speaker Disclosures

I have the following to disclose:

Consulting fees (advisory role) paid to my institution by Roche, Owkin, GlaxoSmithKline (GSK), Exact Sciences and AstraZeneca.

No personal benefits.

All of these outside the scope of my presentations.

Classification of vulvar neoplasia

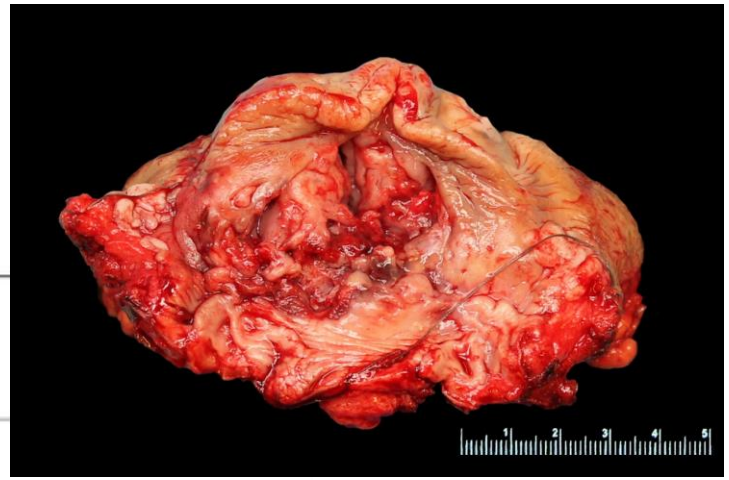

Major classification schemes proposed for squamous precursor lesions of the vulva over time.

1958	1976 ISSVD	1986 ISSVD	2004 ISSVD[a] 2003 WHO[a]	2005 Bethesda-like	2012 LAST 2014 WHO 2015 ISSVD
CIS	Mild atypia	VIN I	–[a]	LG-VIL	LSIL
				• Condyloma • VIN 1	• VIN 1 • Condyloma • Mild dysplasia • Koilocytic atypia
	Moderate atypia	VIN II	uVIN	HG-VIL	HSIL
			• VIN 2 • VIN 3	• VIN 2–3 • dVIN	• VIN 2–3 • Moderate/severe dysplasia • Bowen disease • Bowenoid dysplasia • CIS
	Severe atypia or CIS	VIN III, severe atypia or VIN III, CIS			
–	–	VIN III, differentiated type	dVIN		dVIN[b]

CIS, carcinoma *in situ*; dVIN, differentiated type VIN; HG-VIL, high-grade vulvar intraepithelial lesion; HSIL, high-grade squamous intraepithelial lesion; ISSVD, International Society for the Study of Vulvovaginal Disease; LAST, Lower Anogenital Squamous Terminology; LG-VIL, low-grade vulvar intraepithelial lesion; LSIL, low-grade squamous intraepithelial lesion; uVIN, usual type VIN; VIN, vulvar intraepithelial neoplasia; WHO, World Health Organization.

2020 WHO

HPV- associated

HPV- independent

In situ and Invasive Carcinoma of the Vulva (VSCC)

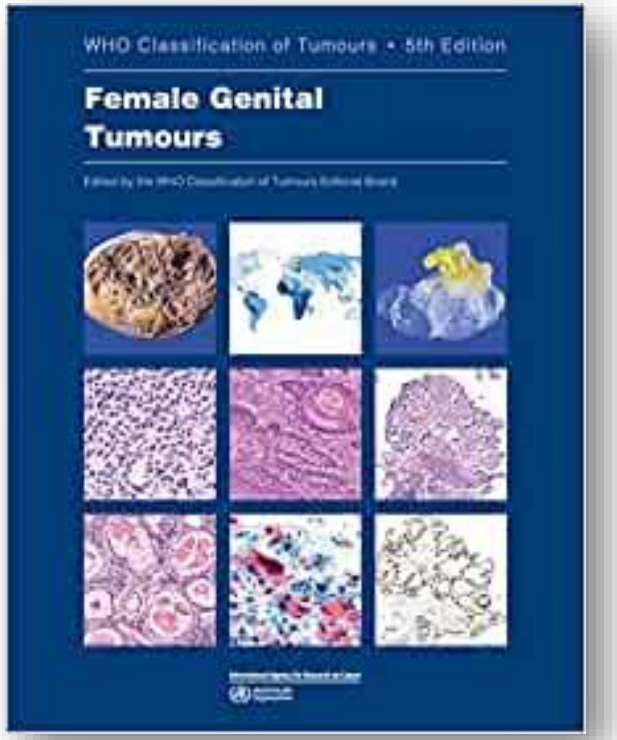

WHO 2020

Vulvar squamous cell carcinoma

10.1.2: Squamous cell tumours and precursors

- 10.1.2.1: Squamous intraepithelial lesions, HPV-associated
- 10.1.2.2: Vulvar intraepithelial neoplasia, HPV-independent
- 10.1.2.3: Squamous cell carcinoma, HPV-associated
- 10.1.2.4: Squamous cell carcinoma, HPV-independent
- 10.1.2.6: Squamous cell carcinoma NOS

LSIL – low-grade squamous intraepithelial lesion



- Mainly limited to condyloma accuminata
- Flat LSIL / flat condyloma in vulva = rare
- HPV 6 and HPV 11 most prevalent subtypes
- Verruca vulgaris: nongenital genotypes (HPV 2 most common)
- Giant condyloma = Buscke-Löwenstein tumour
  (immunosuppression, locally aggressive, potential for malignancy)

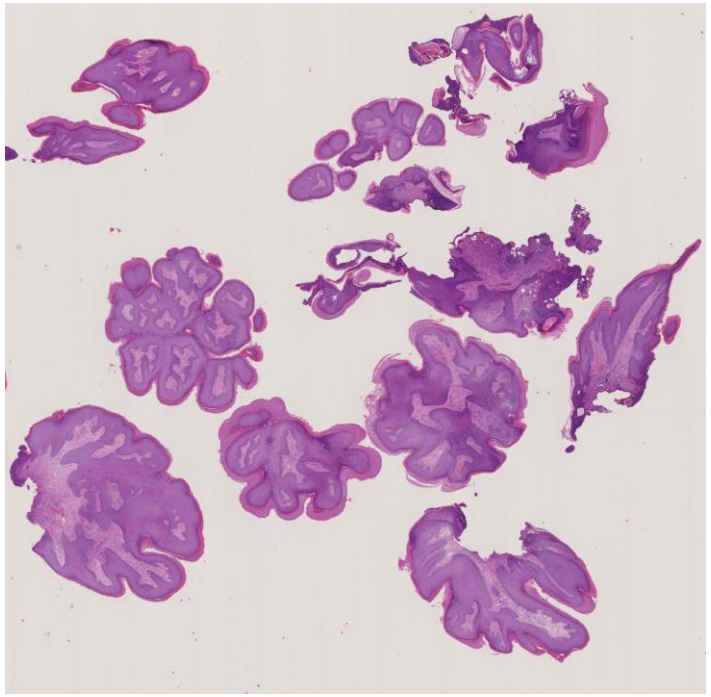

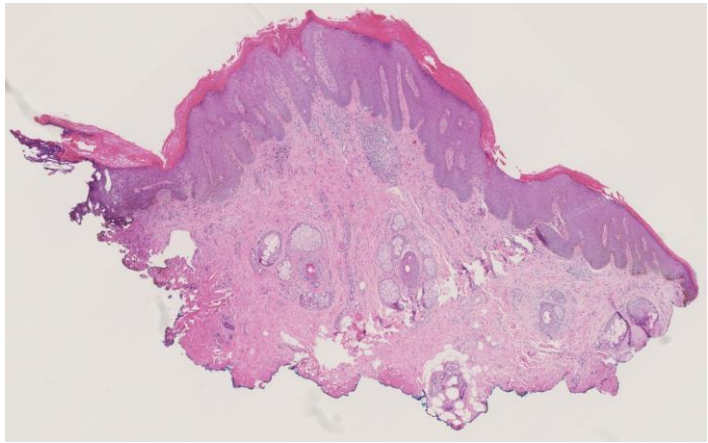

LSIL – low grade squamous intraepithelial lesion



- papillomatous, thick rete ridges, prominent dermal capillaries
- acanthosis, hypergranulosis, parakeratosis
- basal hyperplasia
- variable HPV cytopathic effect (koilocytosis)
- no cytologic background atypia
- if present, mitoses limited to lower 1/3th

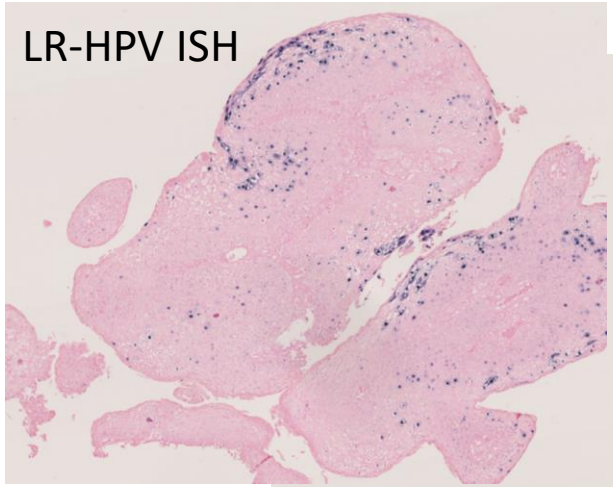

High-grade HPV-pos versus HPV-neg precursors

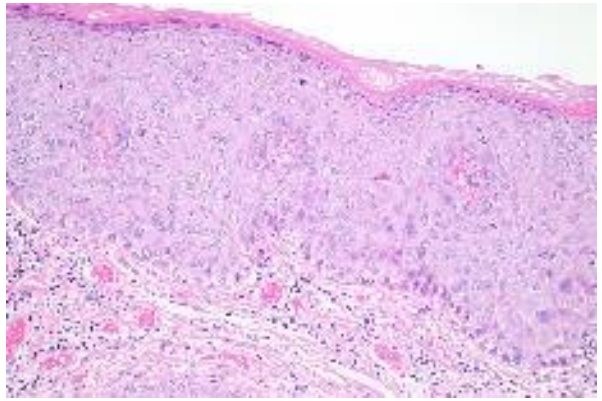

HPV-associated SIL

- >80-90% of all high grade VIN
- younger (age 40-60y)
- smokers
- prior cervical dysplasia
- multifocal
- less aggressive: <10% progression
- histology: warty, basal

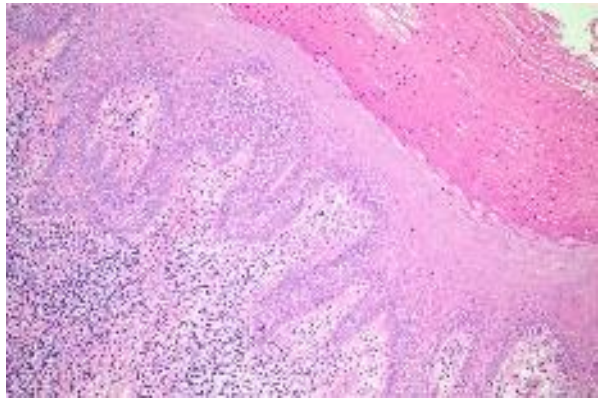

HPV-independent VIN

- <10-20% of all VIN
- older (age 70+y)
- lichen sclerosus
- other vulvar dermatoses? smoking?
- unifocal
- more aggressive: >75% progression
- histology: keratinizing

Dramatic differences in outcomes



Blake Gilks

BAGP 2018

VIN

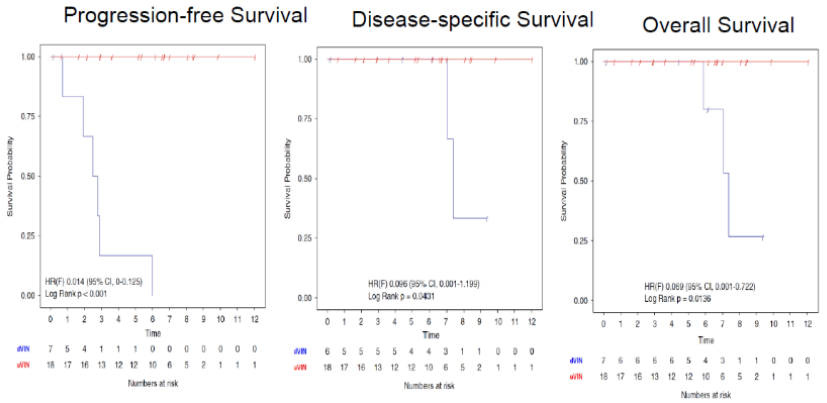

McAlpine, Gilks - Int J Gyne Ca, 2017

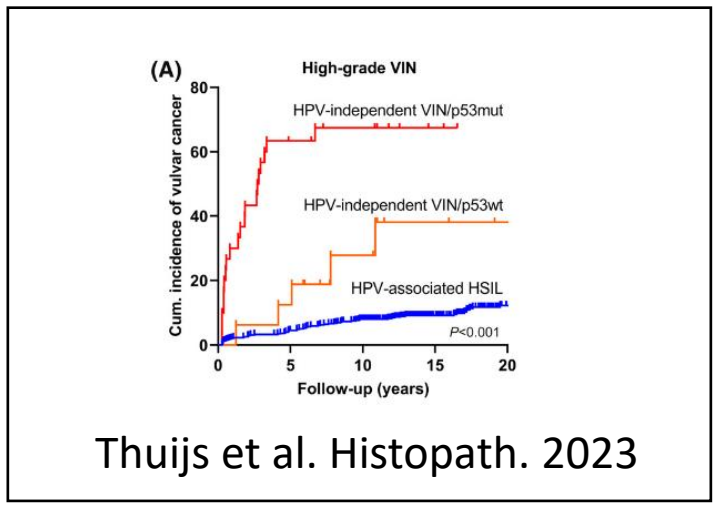

Thuijs et al. Histopath. 2023

VSCC

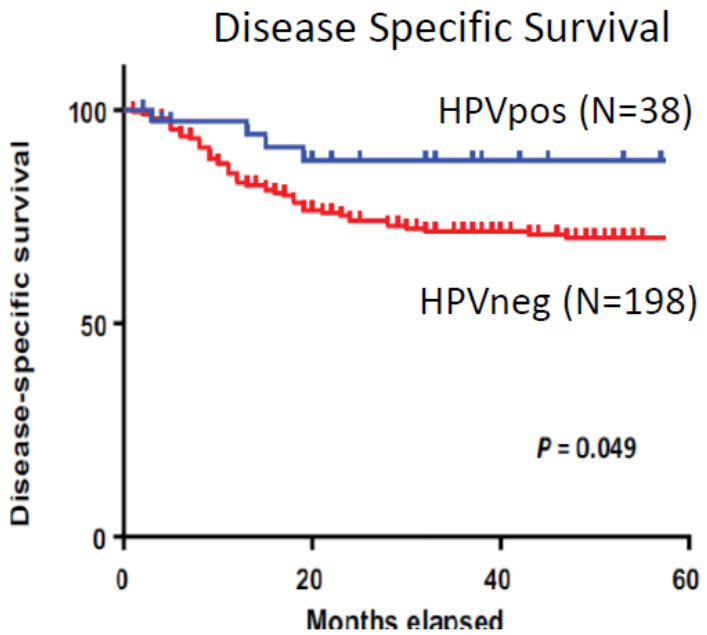

Nooij et al. CCR 2018

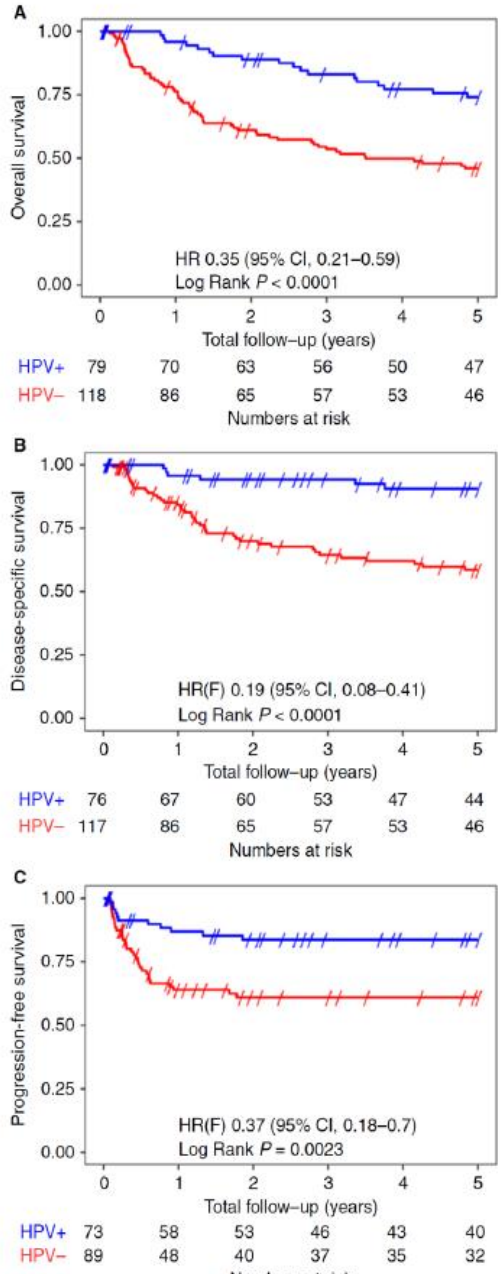

McAlpine, Histopathology 2017

HPV-pos versus HPV-neg precursors

H&E criteria do not distinguish reliably HPV+ versus HPV-
Morphology is misleading in 20% to 25% of cases !

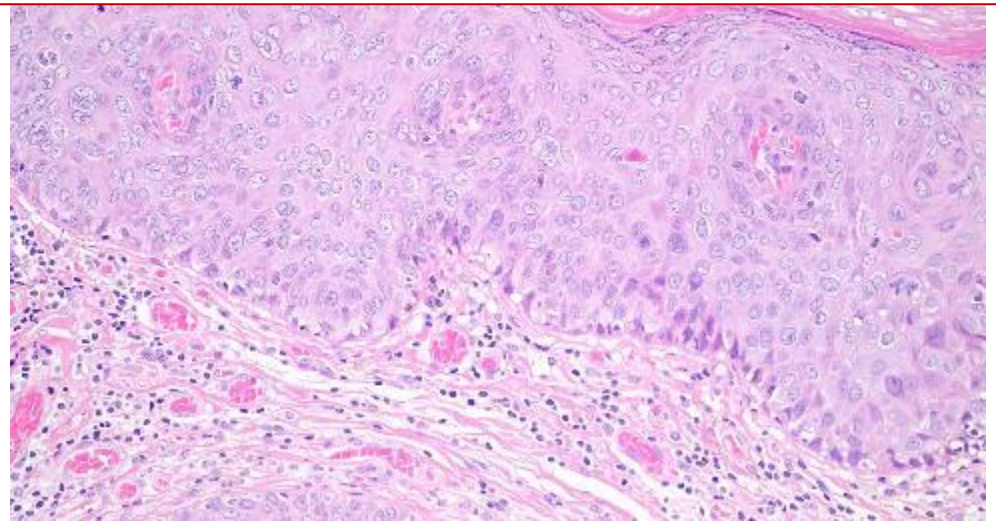

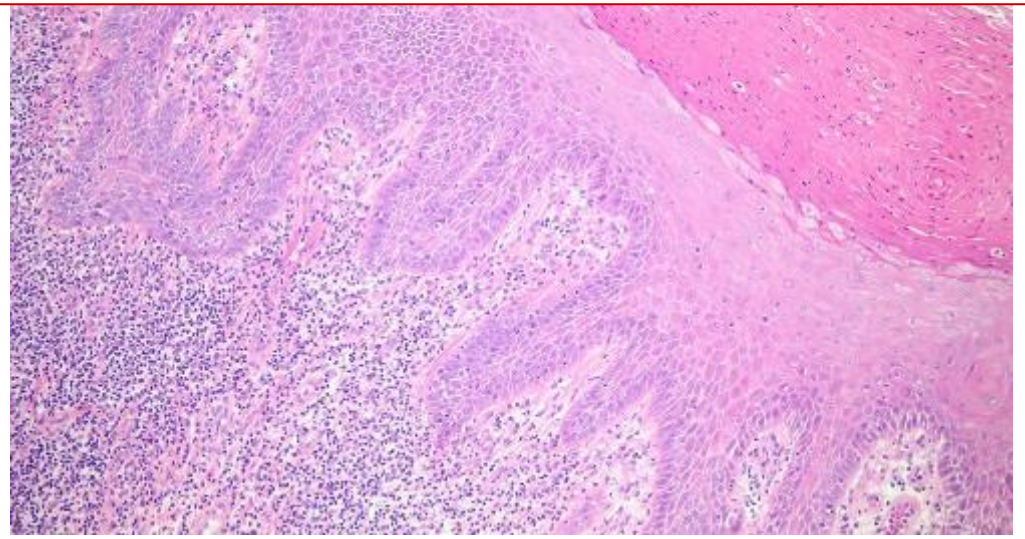

HPV-associated

- HSIL
- VIN-2 or -3
- usual type VIN (uVIN)

HPV-independent

- differentiated VIN (dVIN)
- ~~VIN-3~~
- ~~simplex VIN~~

HPV-pos versus HPV-neg precursors

HPV-associated

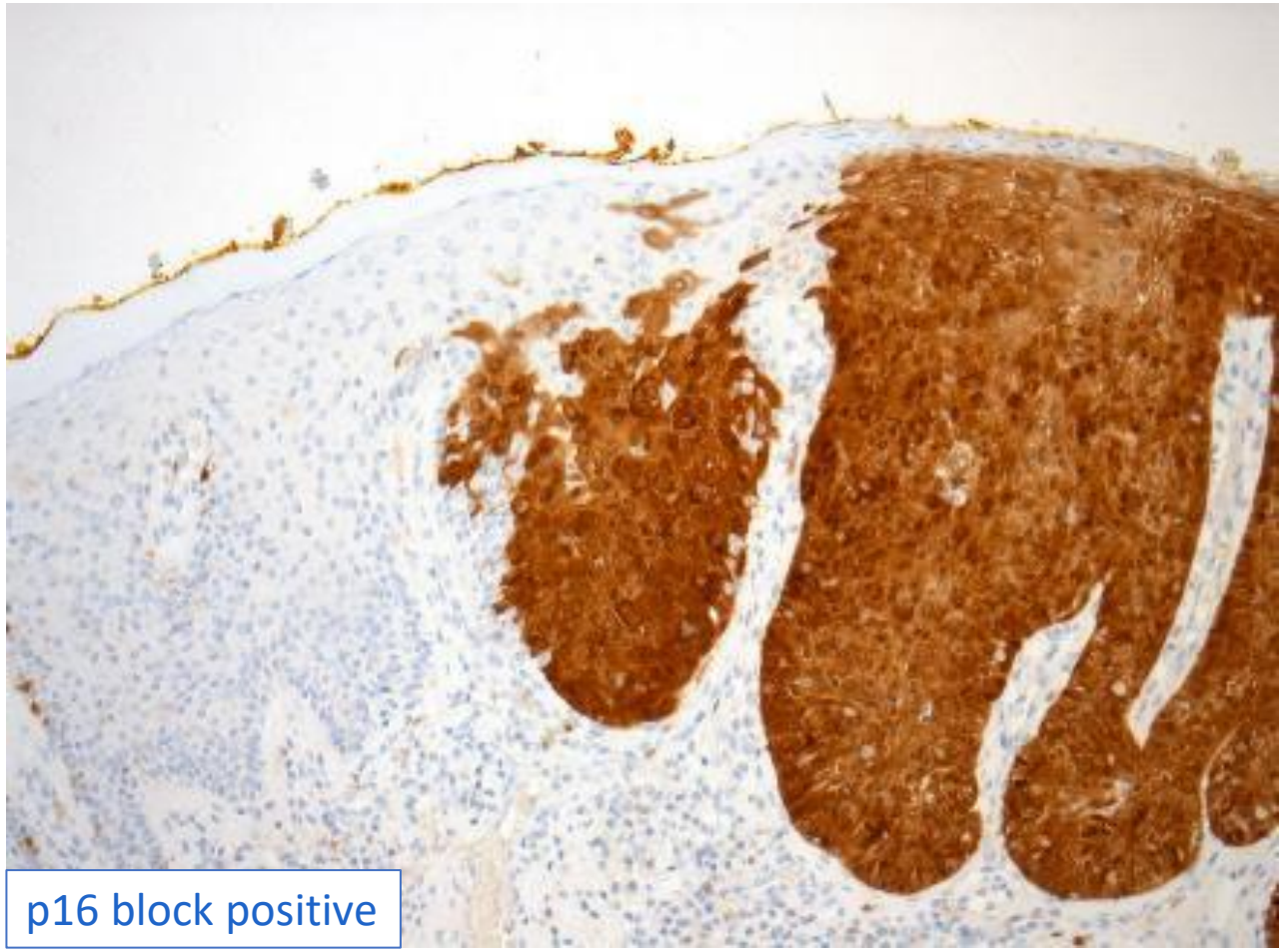

p16 block positive

HPV-independent

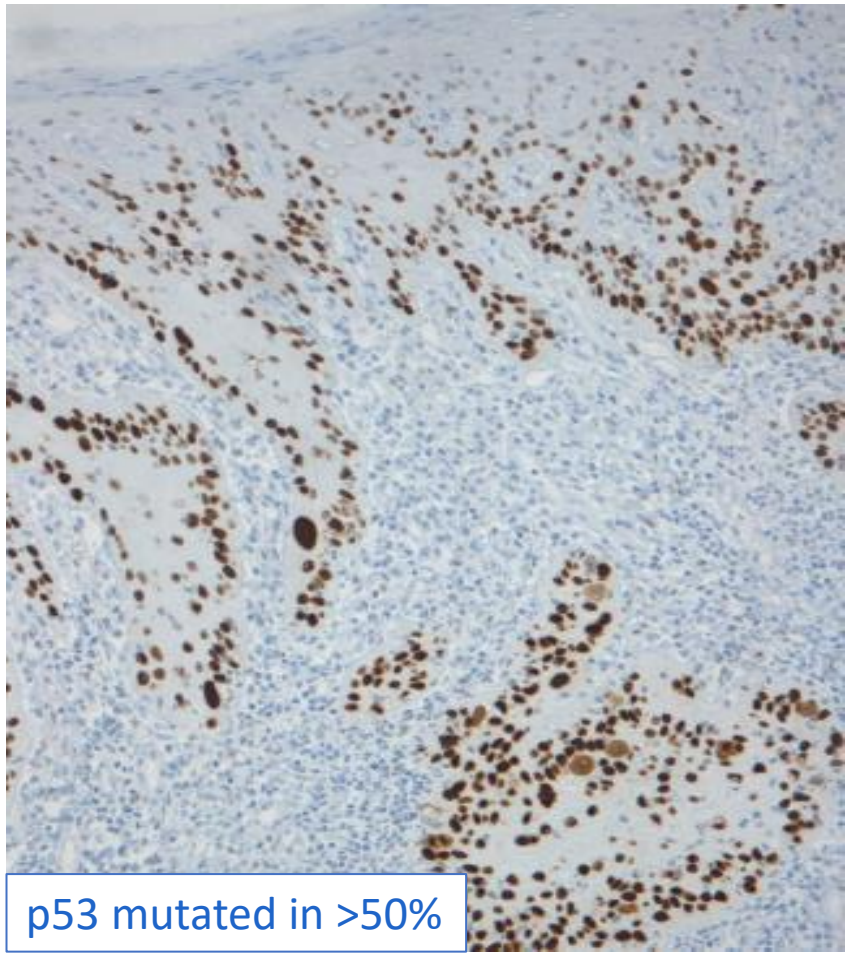

p53 mutated in >50%

Immunohistochemistry

HPV+ SCC by p16 IHC

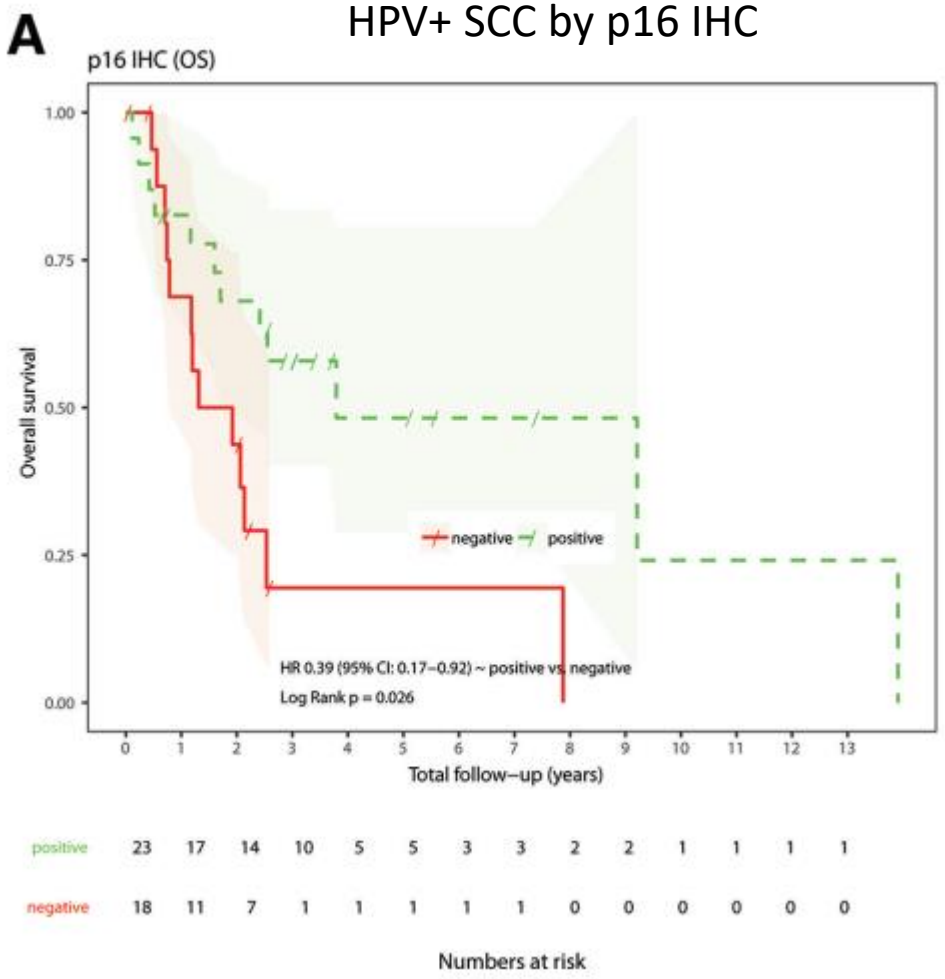

Proctor L, et al. Int J Gynecol Cancer 2019

Genomic Characterization of Vulvar (Pre)cancers Identifies Distinct Molecular Subtypes with Prognostic Significance

Linda S. Nooij[1,2], Natalja T. ter Haar[1], Dina Ruano[1], Natalia Rakislova[3], Tom van Wezel[1], Vincent T.H.B.M. Smit[1], Baptist J.B.M.Z. Trimbos[2], Jaume Ordi[3], Mariette I.E. van Poelgeest[2], and Tjalling Bosse[1]

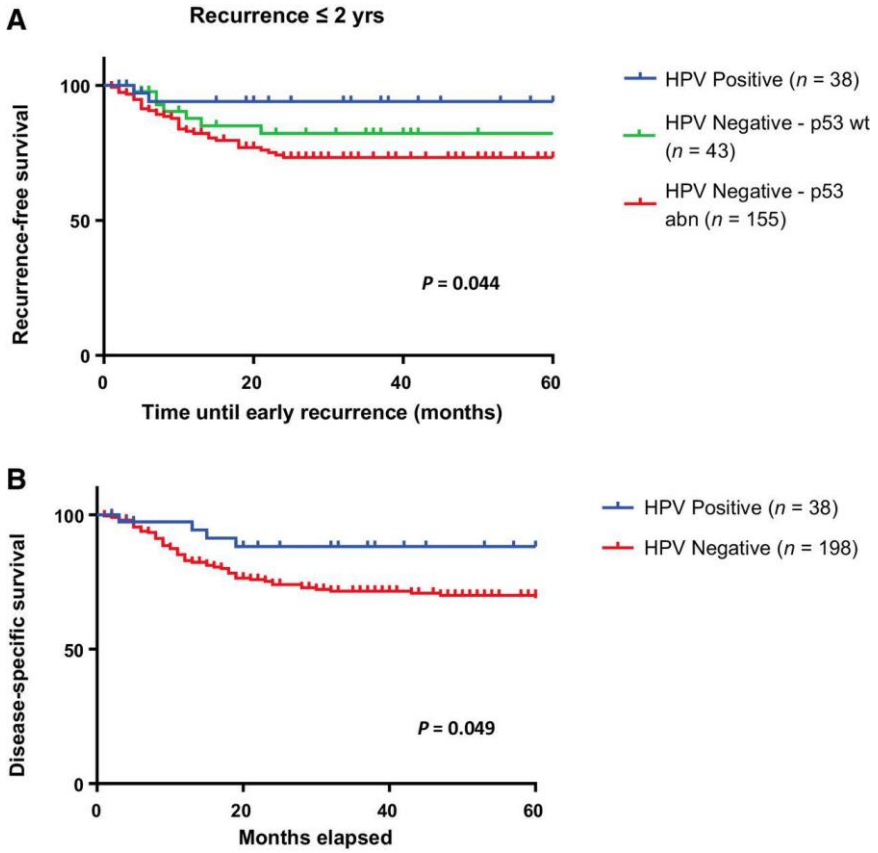

Clin Cancer Res. 2017;23(22):6781-6789.

Molecular subclassification of vulvar lesions

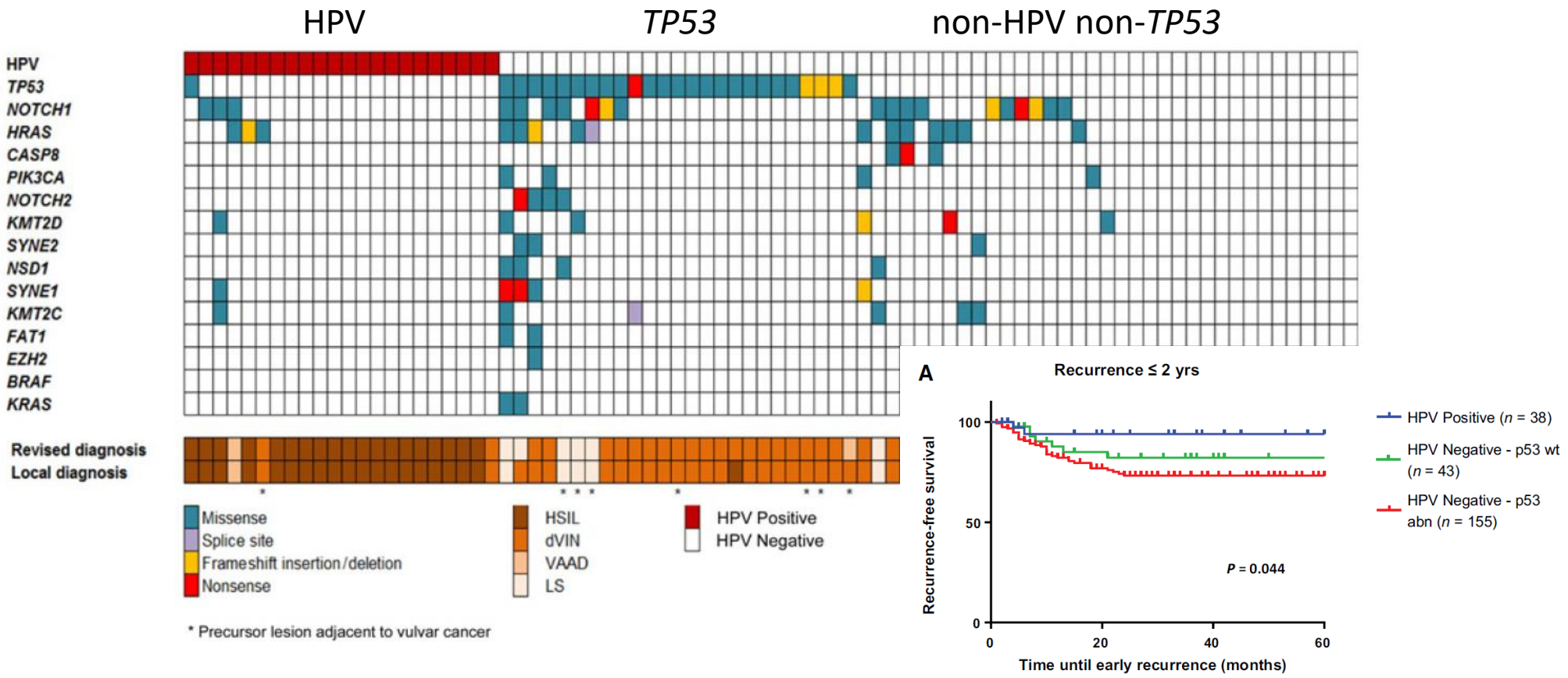



Tjalling Bosse

BAGP 2018

Nooij LS, et al. Genomic Characterization of Vulvar (Pre)cancers Identifies Distinct Molecular Subtypes with Prognostic Significance. Clin Cancer Res. 2017 Nov 15;23(22):6781-6789.

Cancer driver mutations in VSCC

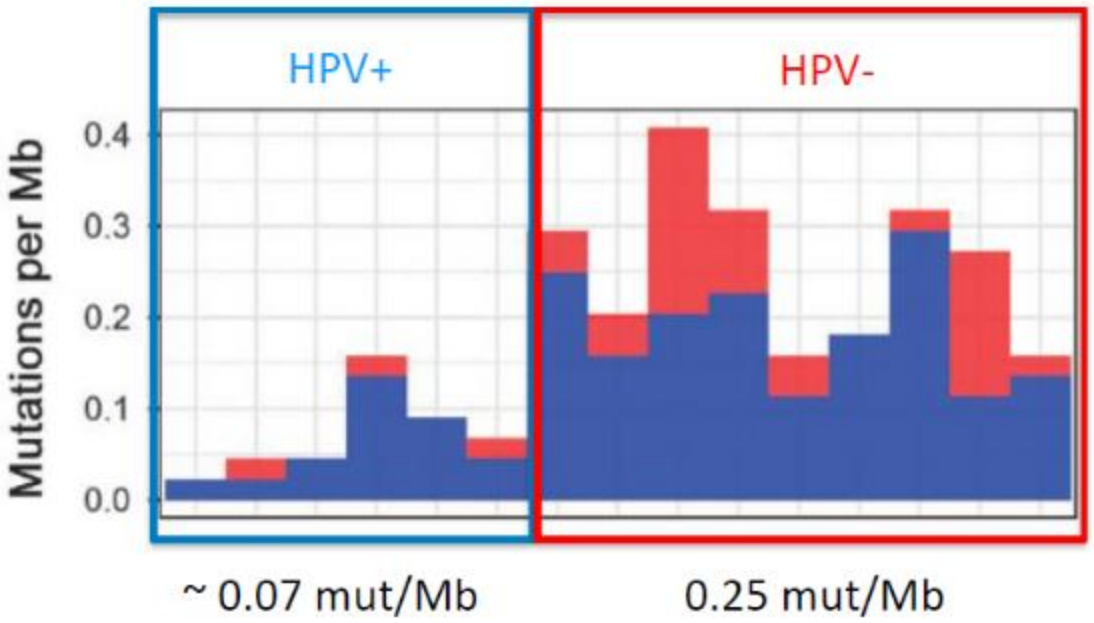

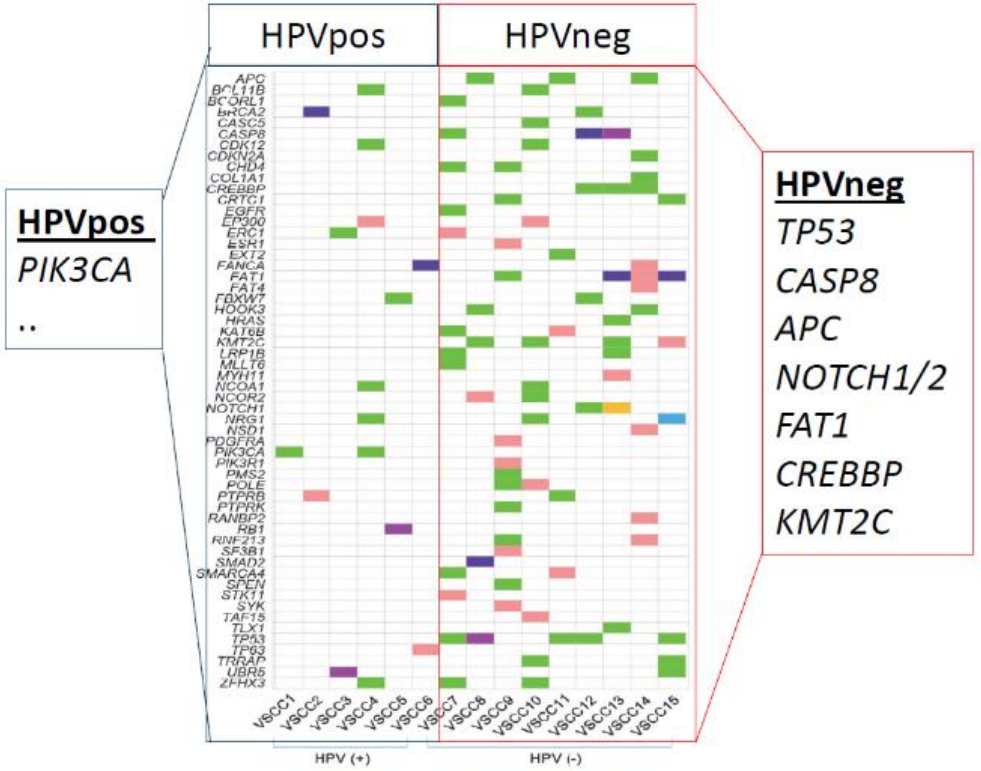

Han et al., Exp Mol Med 2018

Mutational burden indicates HPV status can separate VSCC in two distinct molecular entities

Han et al., Exp Mol Med 2018

Reproducible by IHC but pitfalls !!

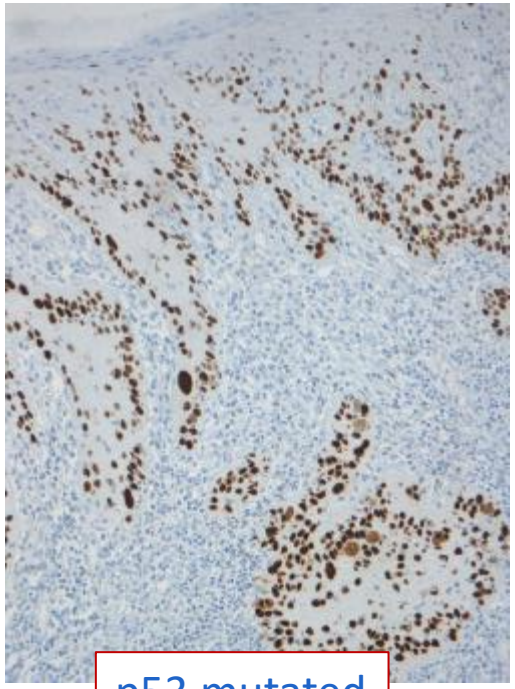

p53 mutated



p16 block positive

Molecular subclassification of vulvar squamous cell carcinoma: reproducibility and prognostic significance of a novel surgical technique

Emily F Thompson [1], Lynn Hoang,[2] Anne Kathrin Höhn,[3] Andrea Palicelli,[4] Karen L Talia,[5] Nairi Tchrakian,[1,6] Janine Senz,[7] Rosebud Rusike,[8] Suzanne Jordan,[8] Amy Jamieson [9], Jutta Huvila,[10] Jessica N McAlpine,[11] C Blake Gilks [2], Michael Höckel,[12] Naveena Singh,[13] Lars-Christian Horn[3]

Int J Gynecol Cancer 2022;32:977–985. doi:10.1136/ijgc-2021-003251

HIGHLIGHTS

⇒ Vulvar squamous cell carcinoma can routinely be subclassified into one of three molecular subtypes.
⇒ There is excellent interobserver diagnosis of molecular subtypes of vulvar squamous cell carcinoma.
⇒ No survival differences are seen in this cohort of patients uniformly treated by vulvar field resection surgery.

Mod Pathol 36 (2023) 100145

MODERN PATHOLOGY

USCAP UNITED STATES AND CANADIAN ACADEMY OF PATHOLOGY Creating a Better Pathologist

Journal homepage: https://modernpathology.org/

Research Article

Classification of Vulvar Squamous Cell Carcinoma and Precursor Lesions by p16 and p53 Immunohistochemistry: Considerations, Caveats, and an Algorithmic Approach

Hang Yang[a], Noorah Almadani[b], Emily F. Thompson[a], Basile Tessier-Cloutier[c], Julia Chen[d], Julie Ho[a,e], Janine Senz[f], Melissa K. McConechy[g], Christine Chow[e], Monica Ta[e], Angela Cheng[e], Anthony Karnezis[h], Jutta Huvila[i], Jessica N. McAlpine[j], Blake Gilks[a,e], Amy Jamieson[j], Lynn N. Hoang[a,e,*]

MODERN PATHOLOGY

USCAP UNITED STATES AND CANADIAN ACADEMY OF PATHOLOGY Creating a Better Pathologist

Journal homepage: https://modernpathology.org/

Research Article

Classification of Vulvar Squamous Cell Carcinoma and Precursor Lesions by p16 and p53 Immunohistochemistry: Considerations, Caveats, and an Algorithmic Approach

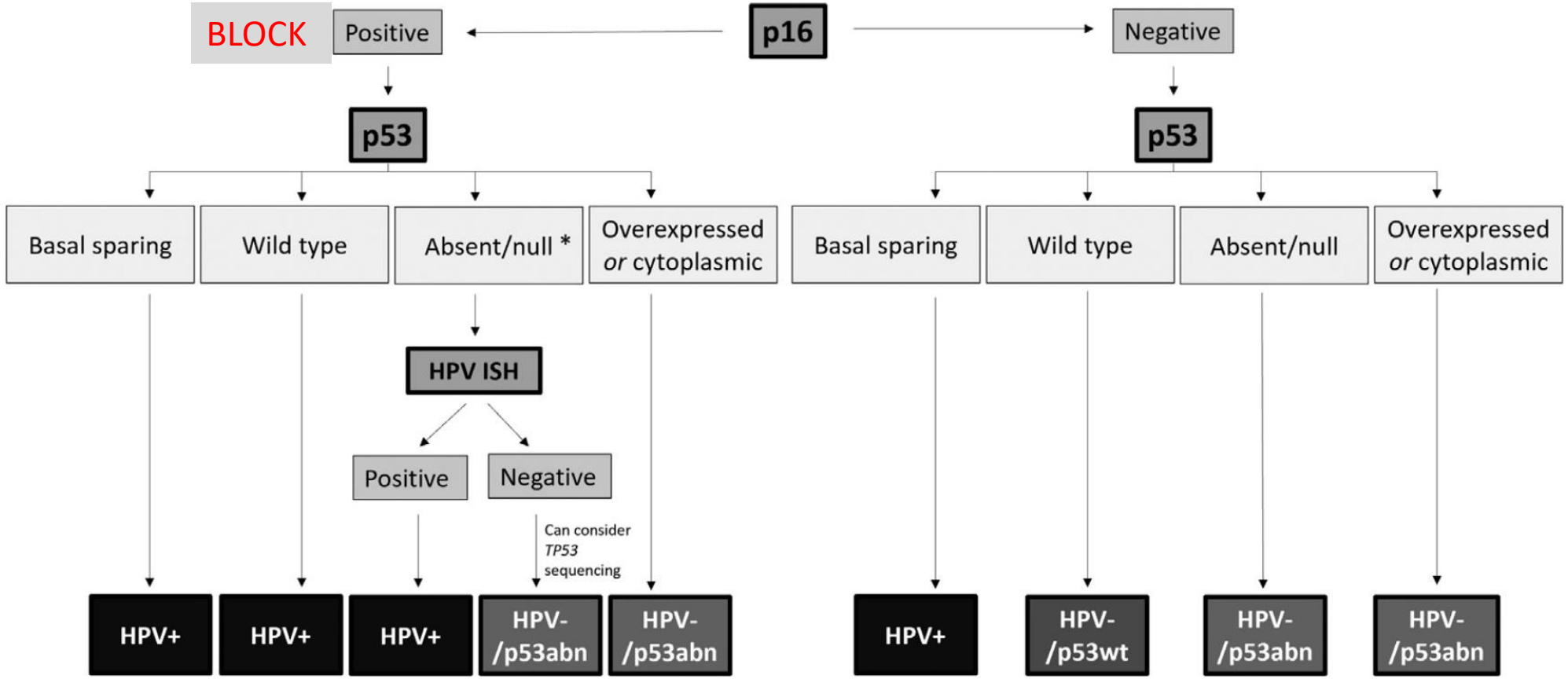

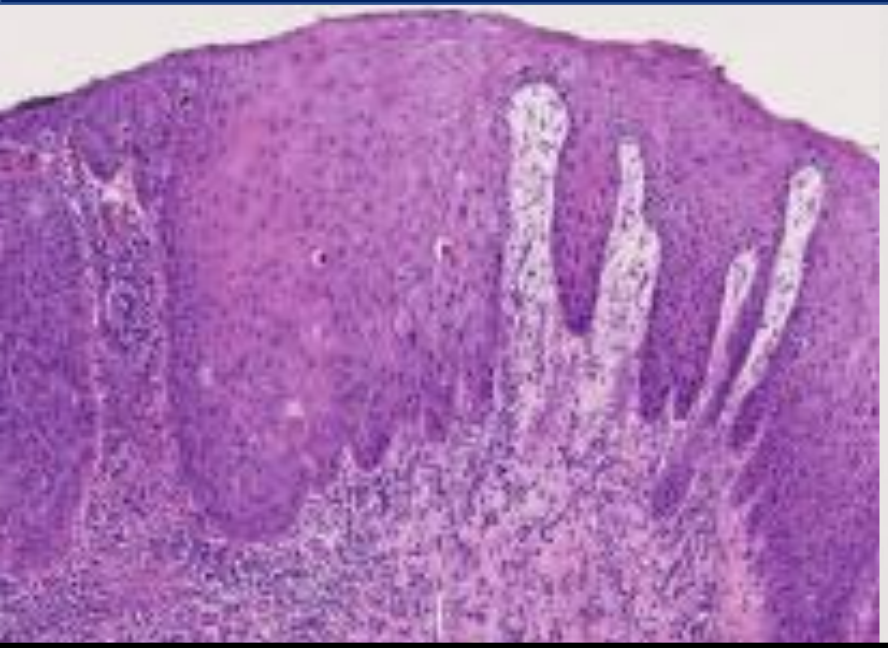

Morphology looks like
HPV-associated:
basaloid, broad papillae,
dysplasia up to upper layers

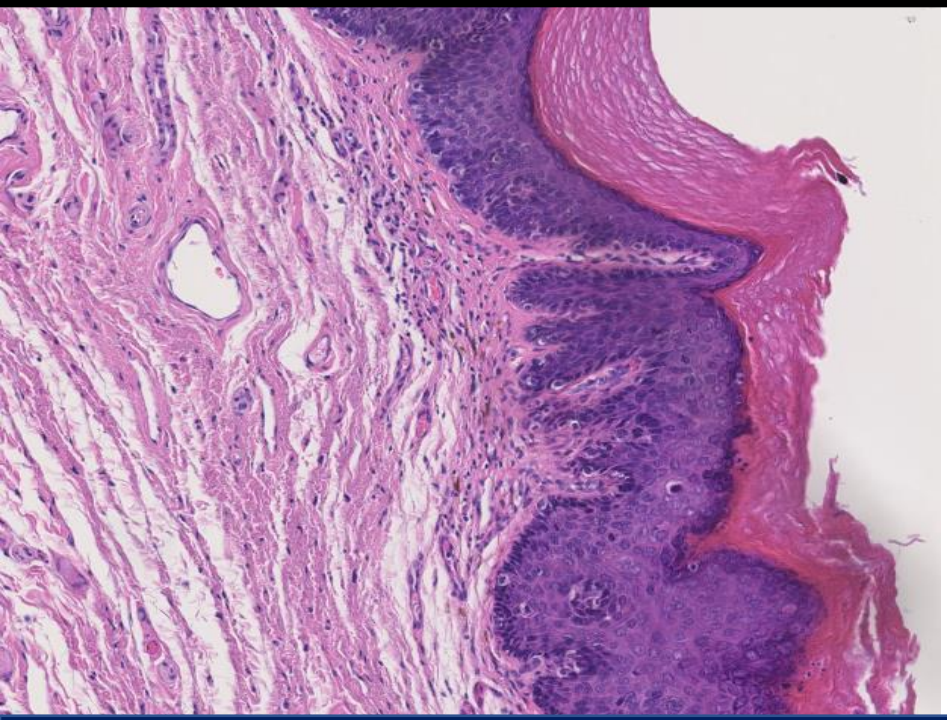

Morphology looks like
HPV-independent:
verrucous, sharp papillae
focal atrophy, basal atypia

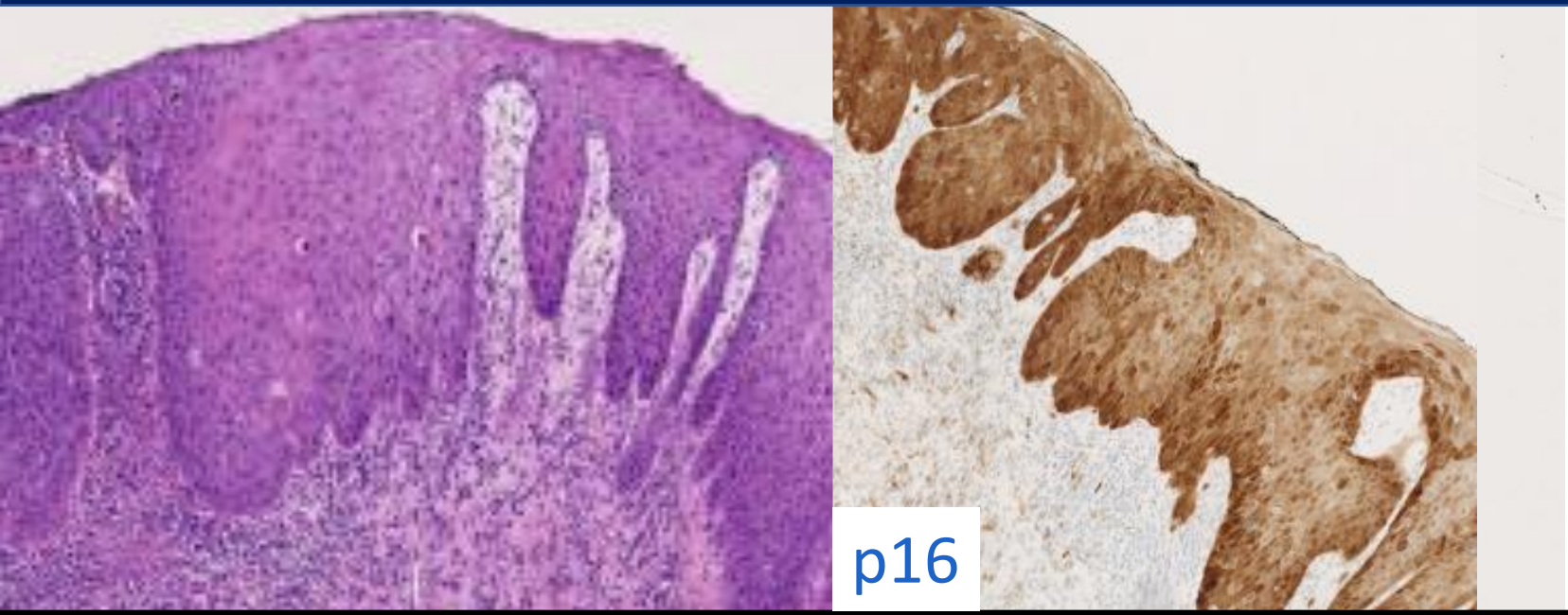

p16: block type

→ HPV-associated

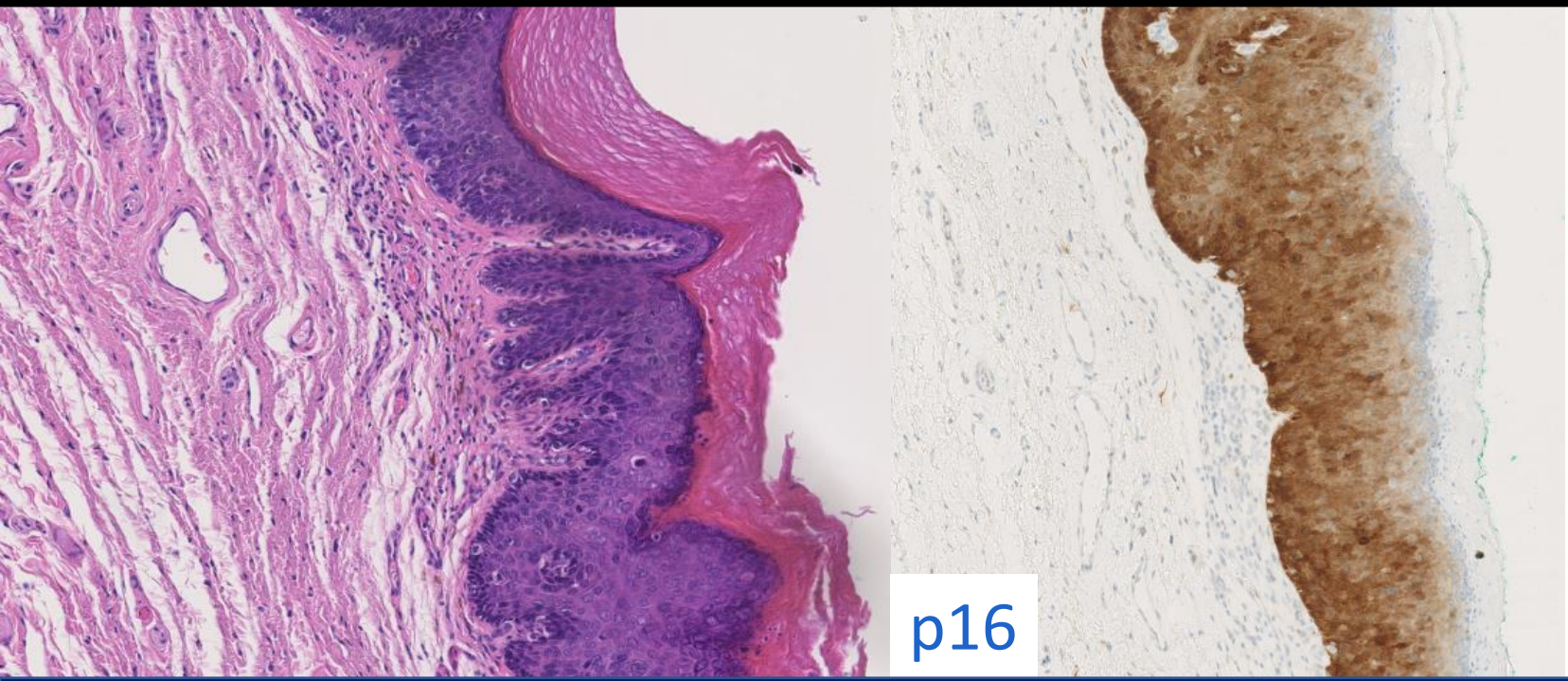

p16: block type

→ HPV-associated

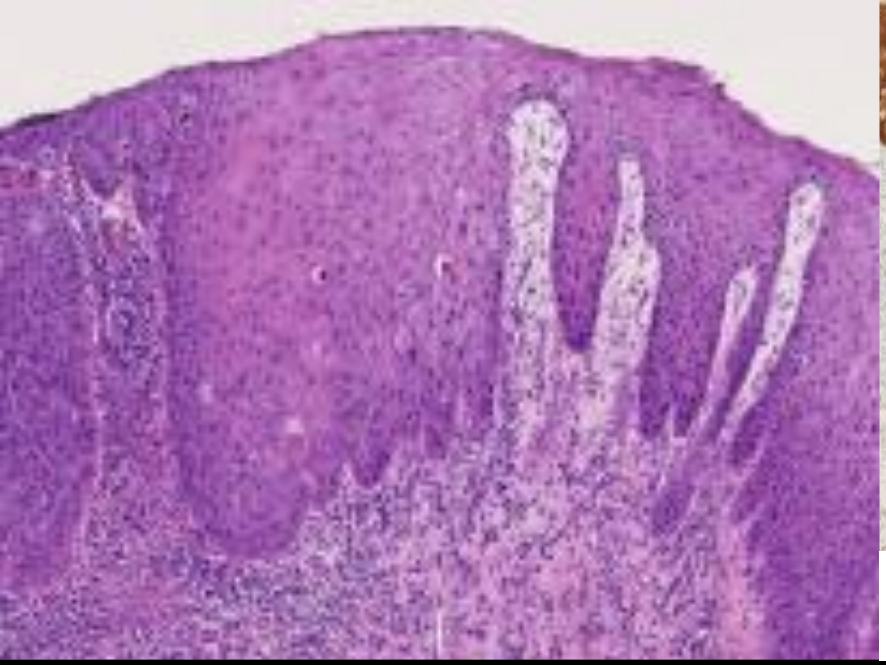

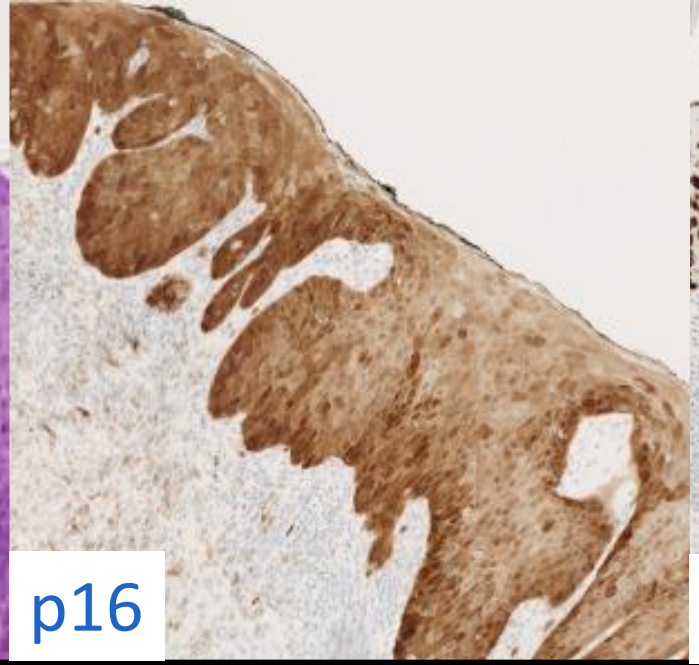
p16

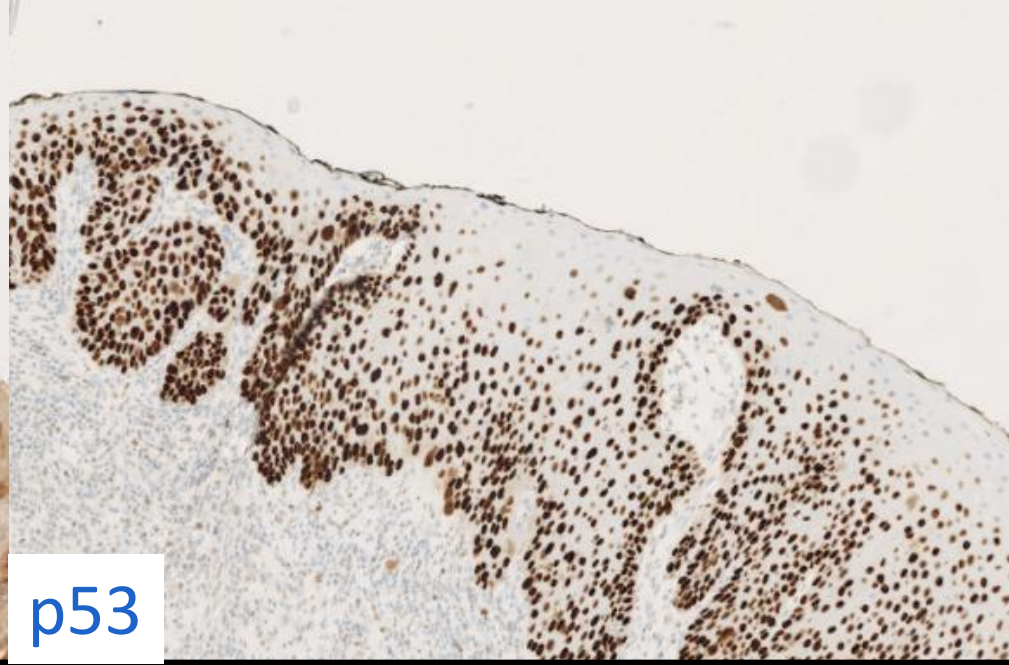
p53

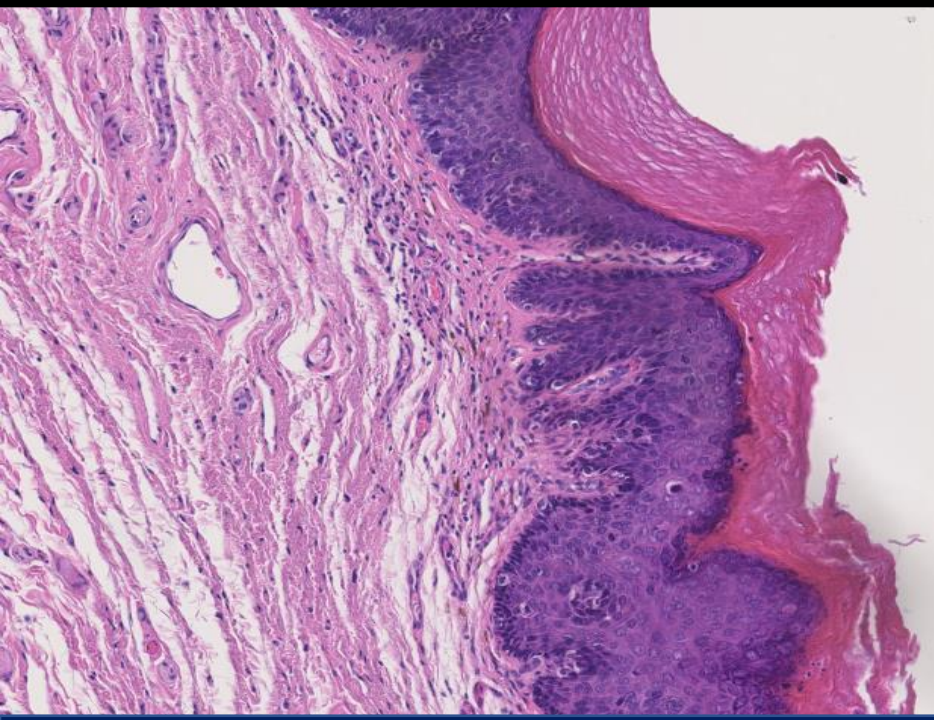

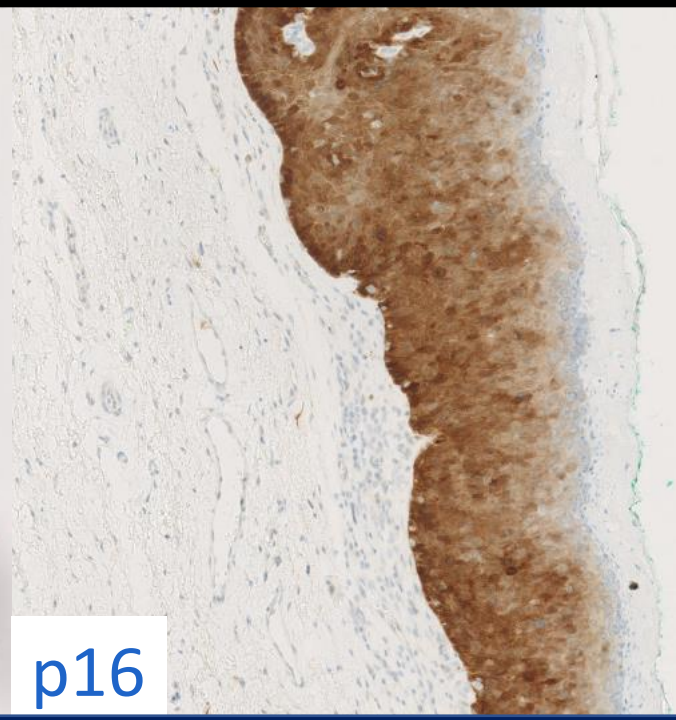
p16

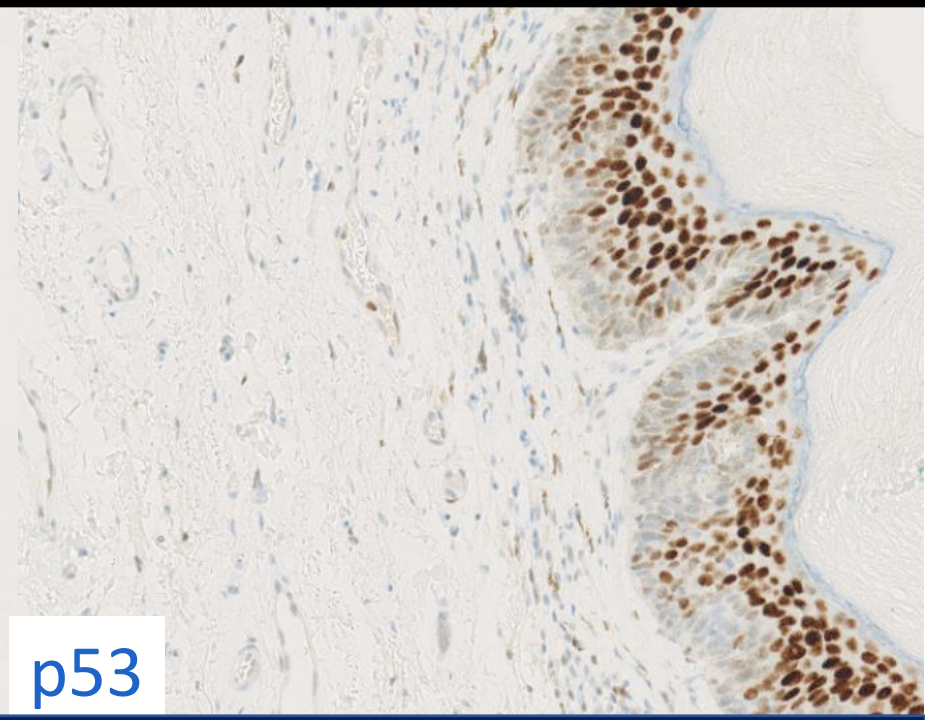
p53



***TP53*mut causes upregulated p16-stress factor**

= HPV-independent

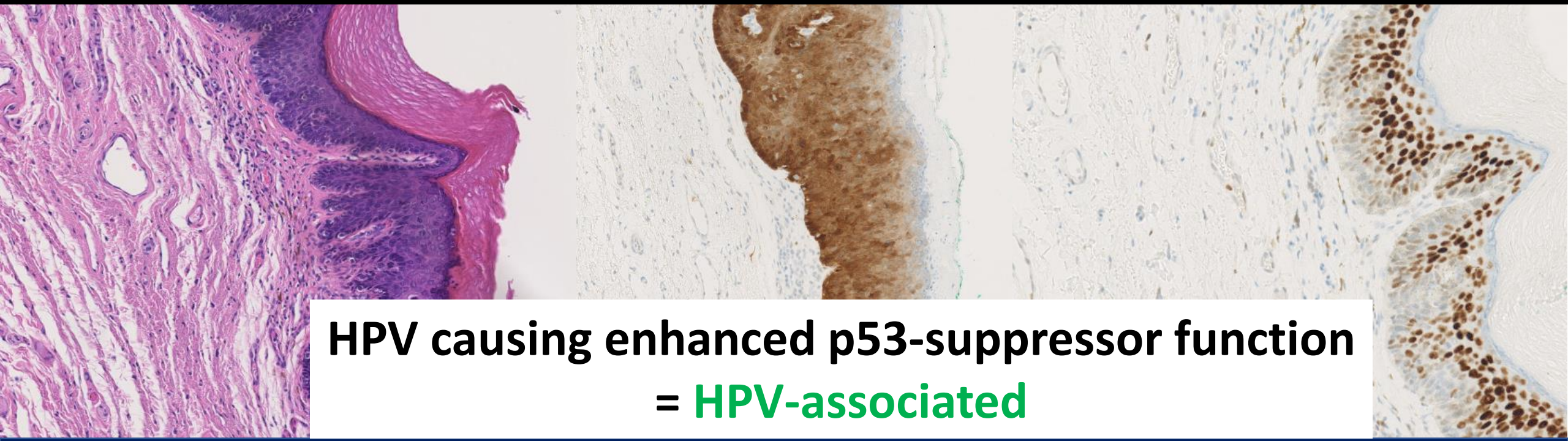

HPV causing enhanced p53-suppressor function

= HPV-associated

The British Association of Gynaecological Pathologists

https://www.thebagp.org/resources/bagp-guidance-documents/

THE BRITISH ASSOCIATION OF GYNAECOLOGICAL PATHOLOGISTS

Interpretation of p16 Immunohistochemistry In Lower Anogenital Tract Neoplasia

Authors: Naveena Singh[1], C Blake Gilks[2], Richard Wing-Cheuk Wong[3], W Glenn McCluggage[4], C Simon Herrington[5]

THE BRITISH ASSOCIATION OF GYNAECOLOGICAL PATHOLOGISTS

Interpretation of p53 Immunohistochemistry In Tubo-Ovarian Carcinoma: Guidelines for Reporting

Author: Martin Köbel[1]

Co-authors: W Glenn McCluggage[2], C Blake Gilks[3], Naveena Singh[4]

Histopathology

Histopathology 2024, **84**, 301–314. DOI: 10.1111/his.15050

High-grade vulvar intraepithelial neoplasia: comprehensive characterization and long-term vulvar carcinoma risk

Nikki B Thuijs,[1,2] Marc van Beurden,[3] Sylvia Duin,[1,2] Daniëlle A M Heideman,[1,2,4] Johannes Berkhof,[5] Renske D M Steenbergen[1,2] & Maaike C G Bleeker[1,2]

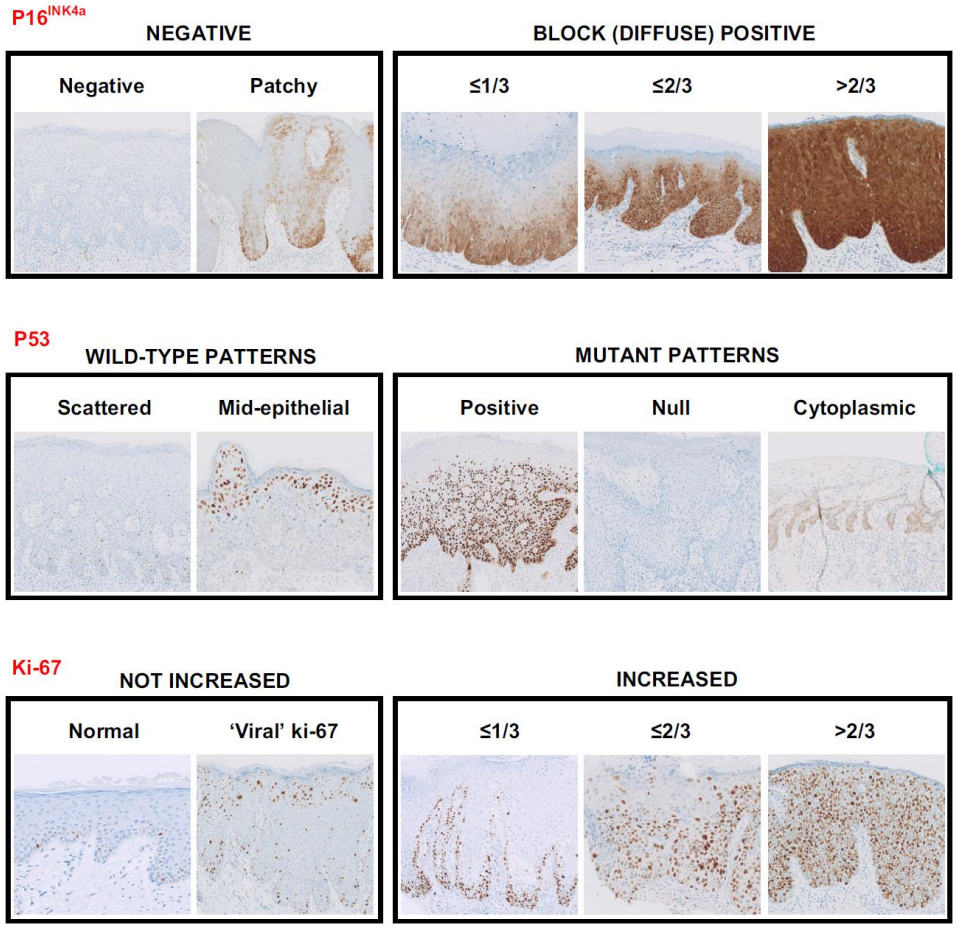

Classification by HPV status



Fullfils the need for tailored approach

→ at diagnosis: CORE-element in the pathology report HPV / molecular profiling

MARGIN status of VIN

Gynecologic Oncology 154 (2019) 266–275

Contents lists available at ScienceDirect

Gynecologic Oncology

journal homepage: www.elsevier.com/locate/ygyno

2019

Margin status revisited in vulvar squamous cell carcinoma

N.C. te Grootenhuis [a,1], A.W. Pouwer [b,1], G.H. de Bock [c], H. Hollema [d], J. Bulten [e], A.G.J. van der Zee [a], J.A. de Hullu [b], M.H.M. Oonk [a,*]

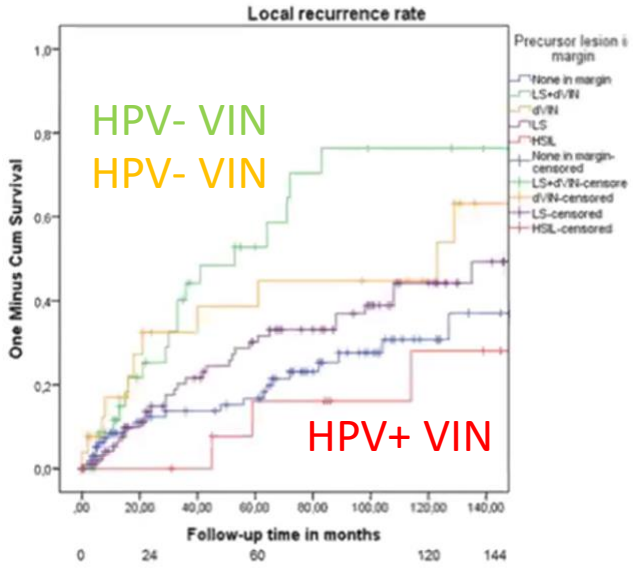

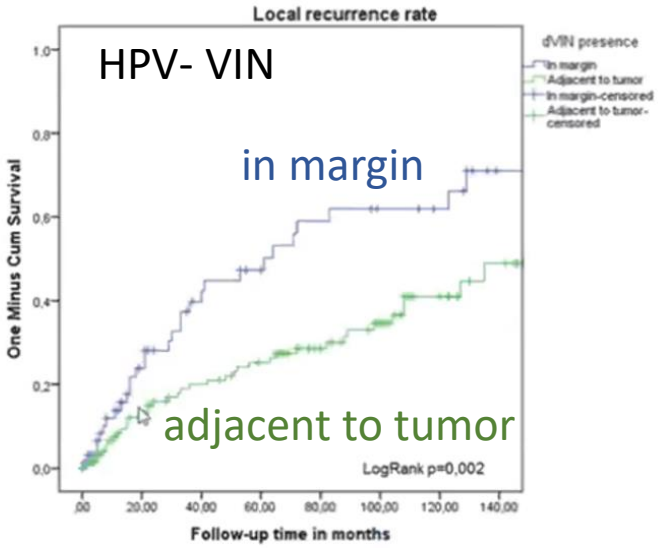

Significance of p53 and presence of differentiated vulvar intra-epithelial neoplasia (dVIN) at resection margin in early stage human papillomavirus-independent vulvar squamous cell carcinoma

Int J Gynecol Cancer. 2022

Emily F Thompson [1], Kathryn Shum,[1] Richard W C Wong,[2] Giorgia Trevisan,[3] Janine Senz,[1] Jutta Huvila,[4] Samuel Leung,[1] David G Huntsman,[1,5] C Blake Gilks [5], Jessica N McAlpine,[6] Lynn Hoang,[5] Amy Jamieson [6]



Mod Pathol 36 (2023) 100010

MODERN PATHOLOGY

USCAP UNITED STATES AND CANADIAN ACADEMY OF PATHOLOGY

Journal homepage: https://modernpathology.org/

Research Article

p53-Abnormal "Fields of Dysplasia" in Human Papillomavirus–Independent Vulvar Squamous Cell Carcinoma Impacts Margins and Recurrence Risk

Emily F. Thompson [a], Richard W.C. Wong [b], Giorgia Trevisan [c], Basile Tessier-Cloutier [a], Noorah Almadani [d], Julia Chen [e], Angela Cheng [f], Anthony Karnezis [g], Melissa K. McConechy [h], Amy Lum [i], Janine Senz [i], Jessica N. McAlpine [j], David G. Huntsman [f,h,i], Blake Gilks [a,f], Amy Jamieson [j], Lynn N. Hoang [a,f,*]

In situ and Invasive Carcinoma of the Vulva (VSCC)

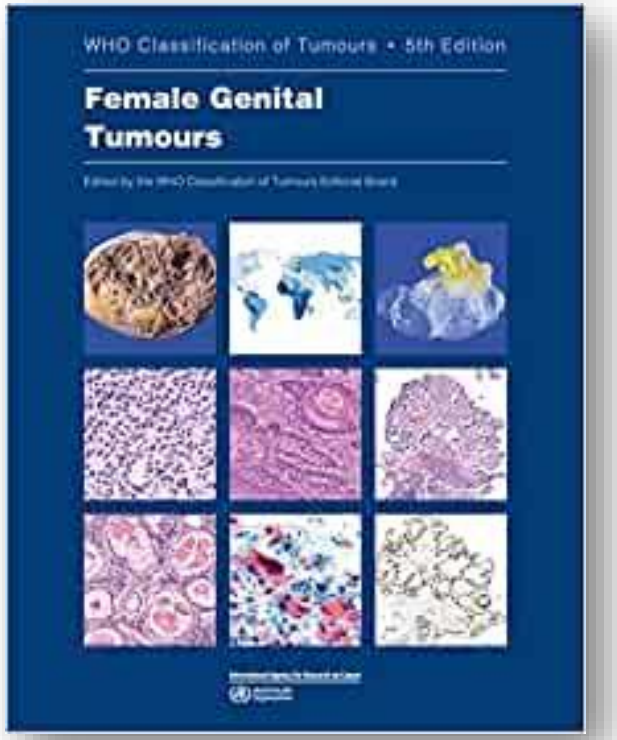

WHO 2020

Patients with HPV-independent vulvar squamous cell carcinomas have been shown to experience worse outcomes compared to HPV-associated VSCC.

However, current vulvar squamous cell carcinoma treatment guidelines are not (yet) stratified by HPV (and *TP53* status) and do not address management of high risk in-situ lesions at resection margins.

HPV: not only prognostic, also predictive

VSCC outcomes- practice pattern dependent?

1985-1995
more radical, en bloc resections

1995-2005
shift to less radical/local radical

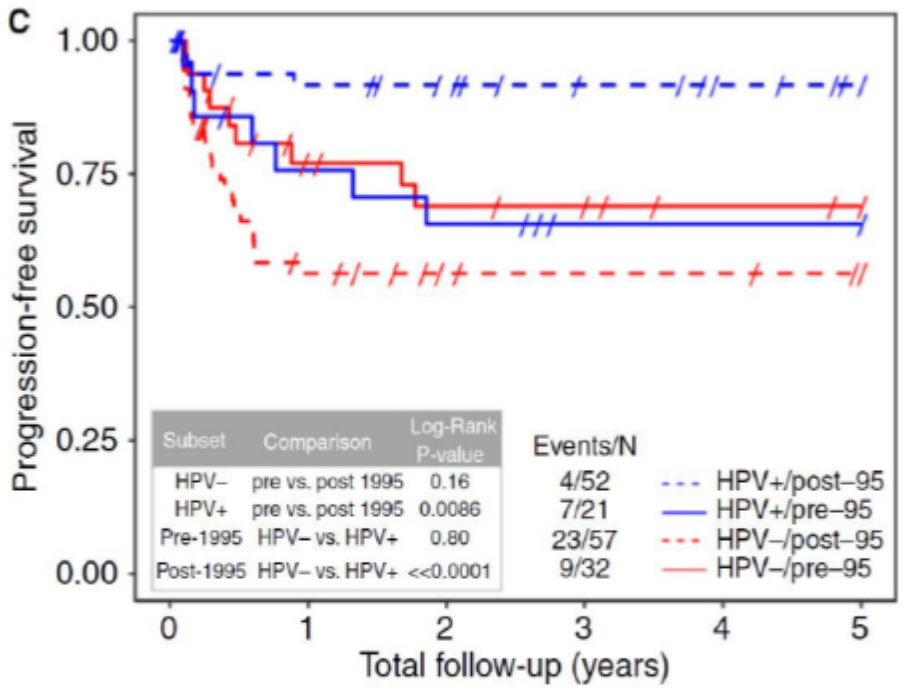

Less radical current practice-p16 pos

Radical *en bloc* era

Less radical current practice-p16 neg

Role for surgery appears to be different in HPV+ vs HPV- disease ....

Higher rate recurrences in HPV-independent disease and changing composition of pelvic exenterations

McAlpine, Karnezis -Histopathology, 2017

HPV: not only prognostic, also predictive

Original article

INTERNATIONAL JOURNAL OF GYNECOLOGICAL CANCER

Association of human papilloma virus status and response to radiotherapy in vulvar squamous cell carcinoma

Lily Proctor,[1] Lien Hoang,[2] Jocelyn Moore,[3] Emily Thompson,[2] Samuel Leung,[4] Divya Natesan,[5] Junzo Chino,[5] Blake Gilks,[2] Jessica N McAlpine[1]

► Additional material is published online only. To view please visit the journal online (http://dx.doi.org/10.1136/ijgc-2019-000793).

[1]Obstetrics and Gynecology, University of British Columbia, Vancouver, British Columbia, Canada

HIGHLIGHTS

- p16-associated vulvar squamous cell carcinoma demonstrated a significantly improved overall survival and progression-free survival.
- In women treated with definitive radiotherapy, p16 positivity was associated with improved overall survival and progression-free survival.
- Among patients who received sensitizing chemotherapy, p16 positivity was associated with improved overall survival and progression free-survival.

Classification by HPV status



Fullfils the need for tailored approach

→ at diagnosis: CORE-element in the pathology report
HPV / molecular profiling

→ for surgery:
Tailor extent of surgical treatment

→ for oncotherapy:
Targeted treatment in recurrent/metastatic setting

Carcinoma of the vulva (VSCC): measurements = combination of gross & microscopy

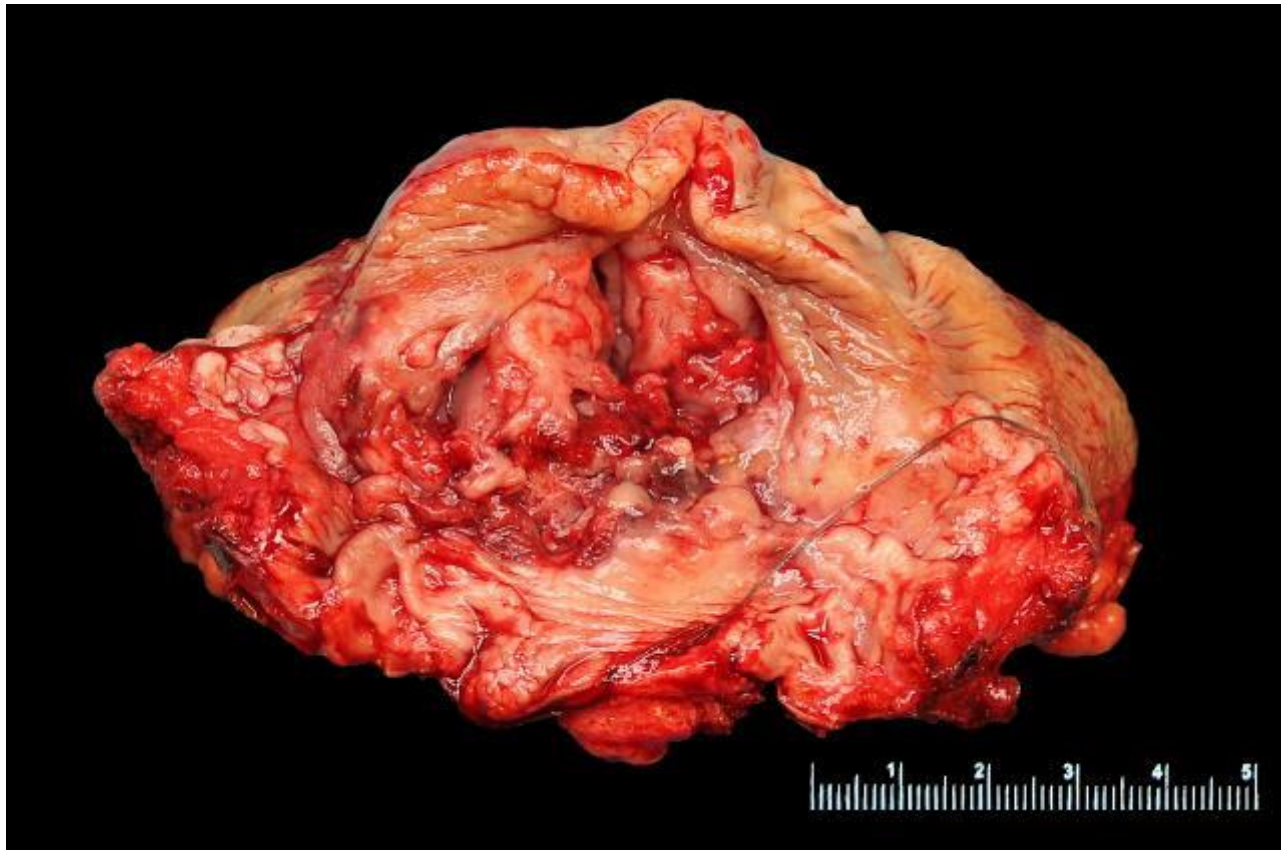



Carcinoma of the vulva (VSCC): measurements = combination of gross & microscopy

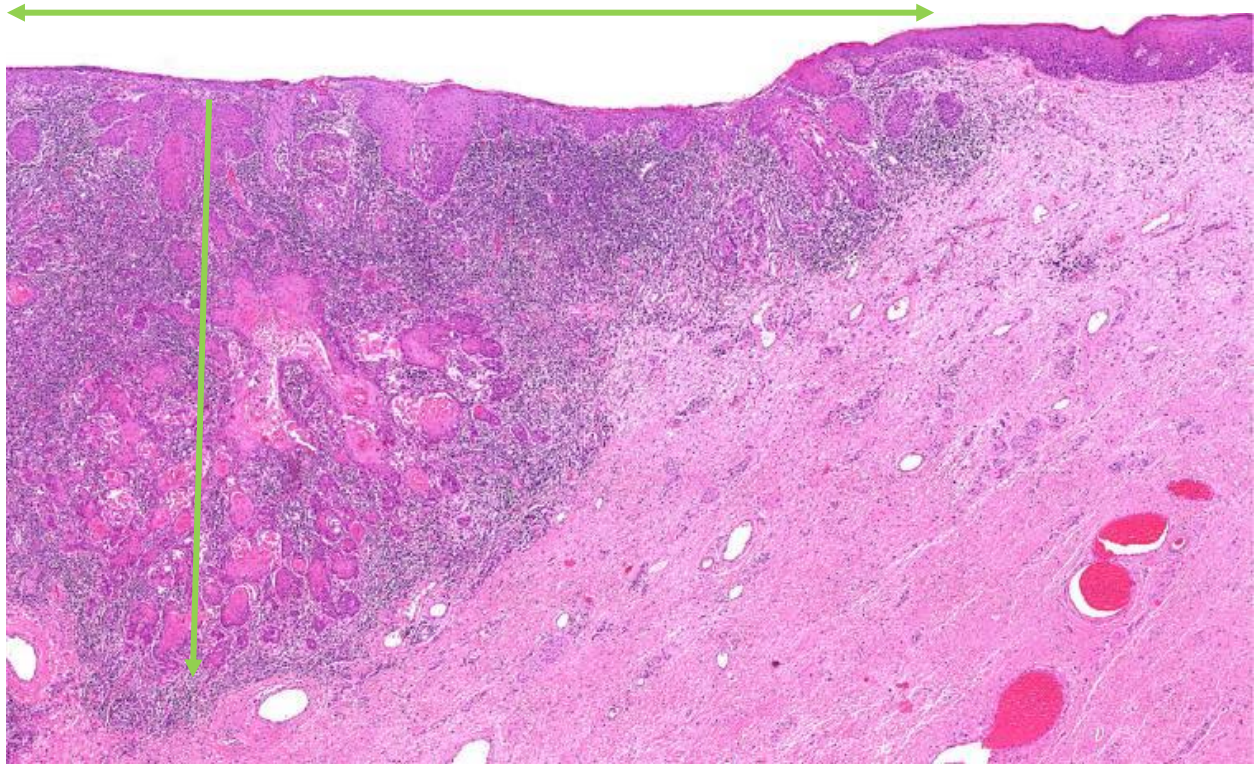

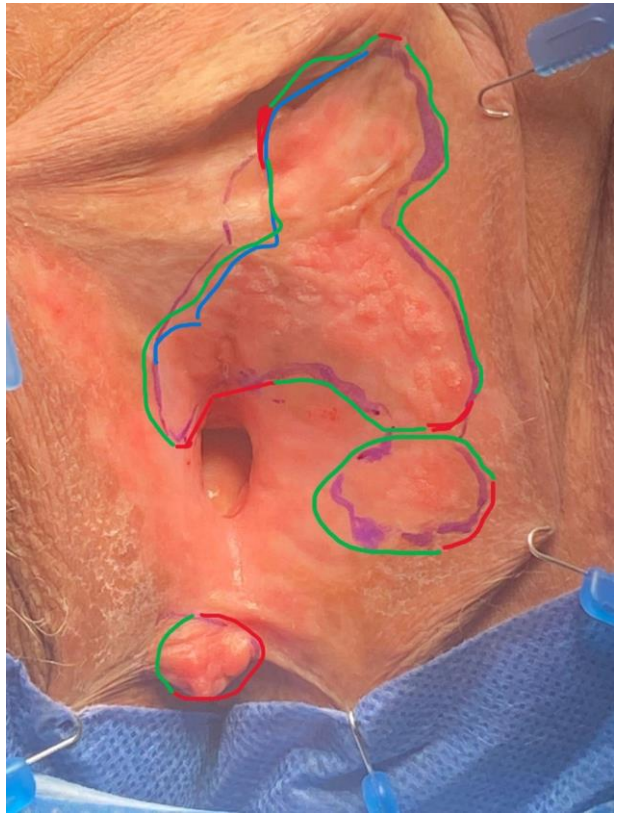

Carcinoma of the vulva (VSCC)

measuring invasion depth (1 mm)

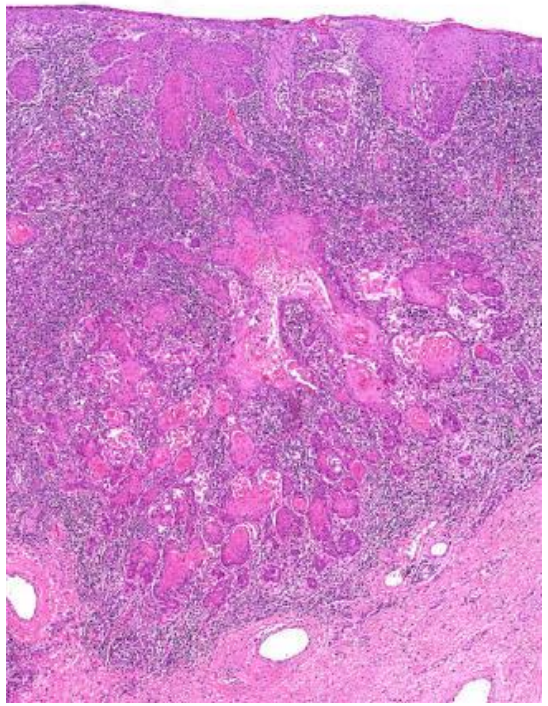

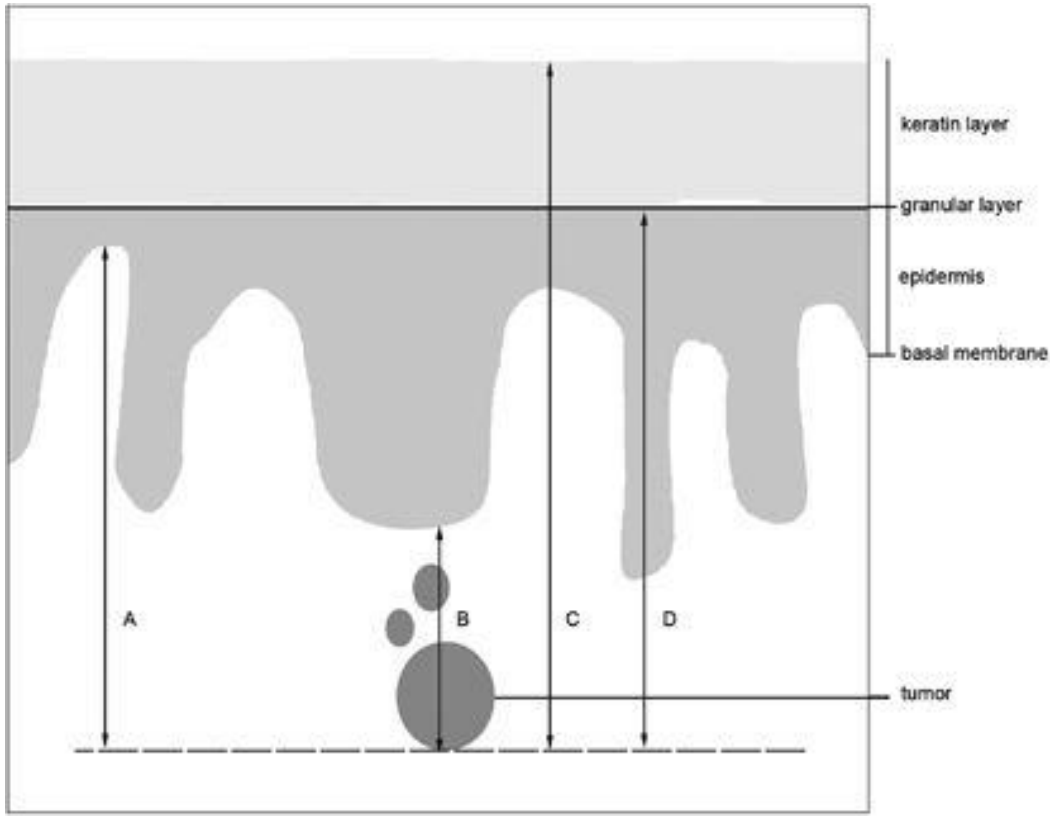

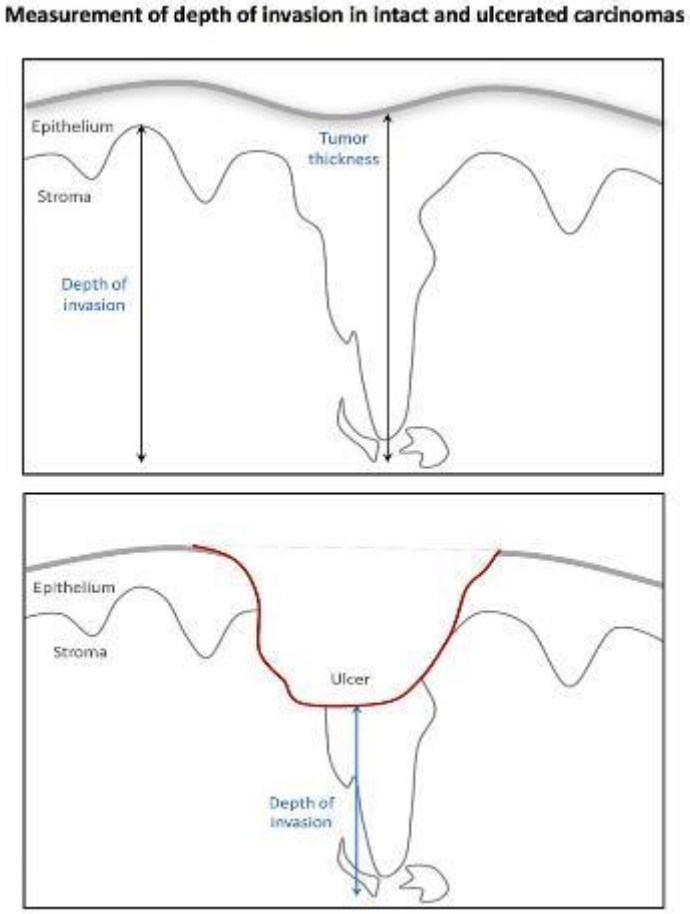

measurement A = FIGO 2009
measurement C = thickness of tumor

measuring depth of invasion

2015

Modern Pathology (2015) 28, 295–302

An alternative way to measure the depth of invasion of vulvar squamous cell carcinoma in relation to prognosis

Loes CG van den Einden[1], Leon FAG Massuger[1], Johanna K Jonkman[1], Peter Bult[2], Joanne A de Hullu[1] and Johan Bulten[2]

[1]Department of Obstetrics and Gynaecology, Radboud University Medical Center, Nijmegen, The Netherlands and [2]Department of Pathology, Radboud University Medical Center, Nijmegen, The Netherlands

Depth of invasion is an important prognostic factor for patients with vulvar squamous cell carcinoma. The aim of this study was to identify the most optimal method of measuring the depth of invasion in relation to the individual outcome in patients with vulvar squamous cell carcinoma. Data of 175 consecutive patients with a primary vulvar squamous cell carcinoma with known lymph node status, treated in the Radboud University Medical Center, the Netherlands (2000–2010), were stored in a database. At pathology review of 148 (85%) cases, depth of invasion was measured using the conventional and alternative methods. Clinical and pathological characteristics of patients with a change in FIGO stage were compared with those without a change in stage. In 148 vulvar squamous cell carcinoma patients, the median depth of invasion was shown to be decreased from 5.5 mm (range 1.1–20) using the conventional method to 3.6 mm (range 0.2–20) using the alternative method ($P<0.05$). This led to a change in the FIGO stage in 13 of the 148 (9%) patients and a change in depth of invasion from 3.5 to 0.2 mm in one patient (1%) with FIGO stage IIIA. Of all 69 stage 1B patients, 13 (19%) were downstaged to stage IA. The downstaged patients developed less recurrences (15% vs 39%) and had a higher disease-specific survival (100% vs 84%) compared with the patients who remained FIGO stage IB. Using the alternative method for measuring the depth of invasion in tumors of vulvar squamous cell carcinoma patients, 19% of the patients with a FIGO stage IB tumor might be treated without groin surgery resulting in less treatment-related morbidity. The results are promising but more prospective data on a higher number of patients are necessary.

Modern Pathology (2015) **28**, 295–302; doi:10.1038/modpathol.2014.103; published online 5 September 2014

Histopathology

Histopathology 2019, 75, 413–420. DOI: 10.1111/his.13883

Measuring the depth of invasion in vulvar squamous cell carcinoma: interobserver agreement and pitfalls

Anne-Floor W Pouwer,[1] Peter Bult,[2] Irene Otte,[2] Michiel van der Brand,[2] Judith van der Horst,[3] Laurette J V Harterink,[2] Koen K van de Vijver,[4] Esther Guerra,[5] Riena P Aliredjo,[3] Steven L Bosch,[6] Johanna M M Grefte,[7] Saskia Zomer,[8] Harry Hollema,[9] Barry de Heus,[9] Saphira Satumalaij,[9] Patricia C Ewing-Graham,[10] Joanna IntHout,[11] Joanne A de Hullu[1] & Johan Bulten[2]

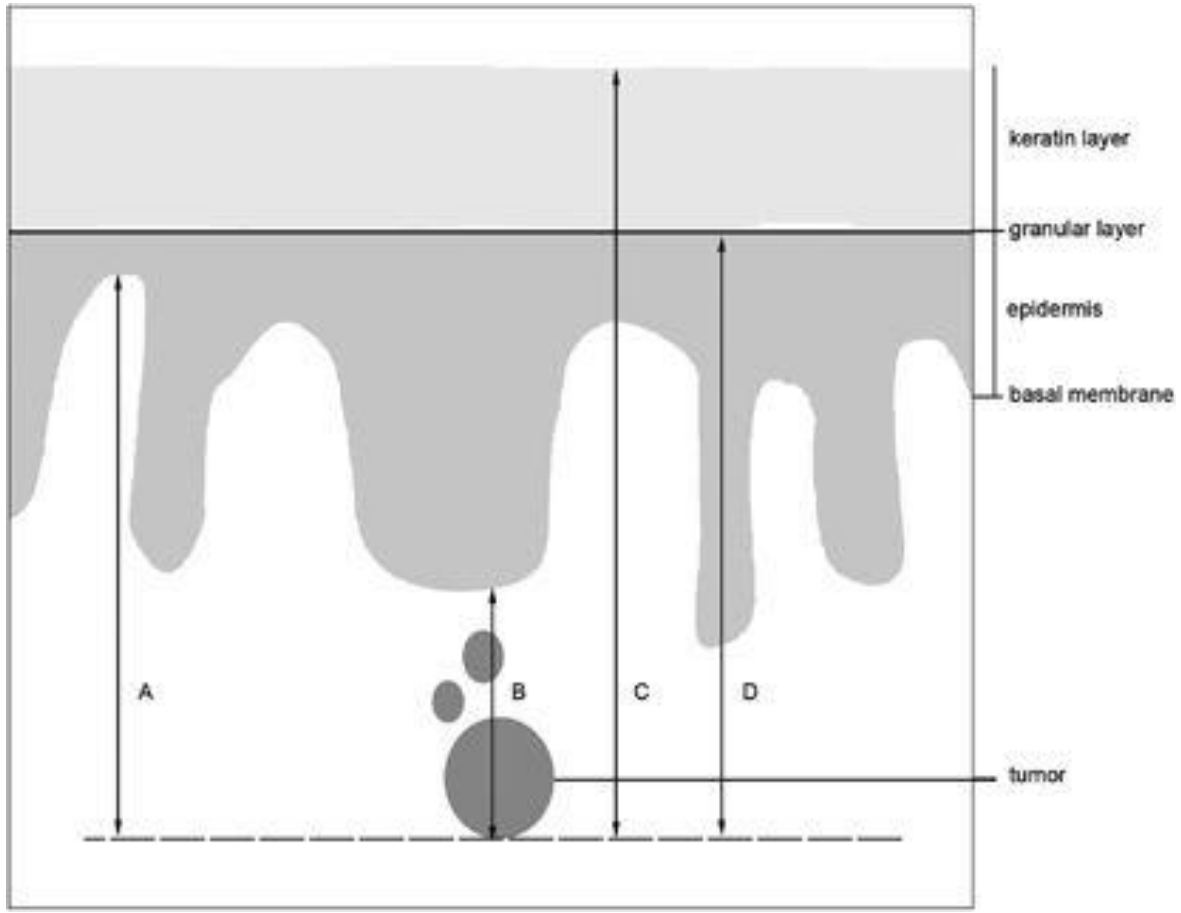

DOI: 10.1002/ijgo.13880

SPECIAL ARTICLE

International Journal of Gynecology Obstetrics FIGO WILEY

FIGO staging for carcinoma of the vulva: 2021 revision

Alexander B. Olawaiye[1] | Joseph Cotler[2] | Mauricio A. Cuello[3] | Neerja Bhatla[4] | Aikou Okamoto[5] | Sarikapan Wilailak[6] | Chittaranjan N. Purandare[7] | Gerhard Lindeque[8] | Jonathan S. Berek[9] | Sean Kehoe[10,11]

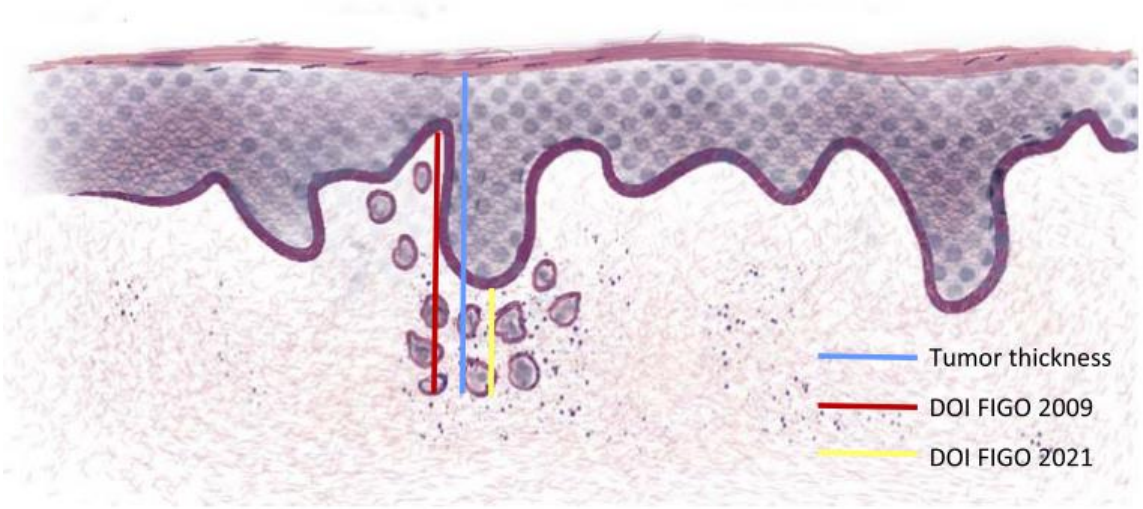

3 | IMPORTANT NOTATIONS AND CHANGES

Depth of invasion is measured from the basement membrane of the deepest, adjacent, dysplastic, tumor-free rete ridge (or nearest dysplastic rete peg) to the deepest point of invasion.[10,11]

1. Lymph node positivity should reflect the consensus utilized in cervical cancer staging, which is micrometastasis and macrometastasis.[12]
2. Individual tumor cells (ITC) will not count toward lymph node metastasis.
3. Allow incorporation of cross-sectional imaging findings into vulvar cancer staging similar to cervical cancer.[12]
4. This staging is to be used for all morphological types of vulvar cancer and not just the most common squamous cell carcinoma. The only exception to this is vulvar melanoma.
5. Documentation regarding the HPV status of the carcinoma of the vulva (HPV-associated or HPV-independent) is strongly recommended. This is assessed by p16 block-type immunoreactivity and/or positive molecular testing for HPV.[13]

The British Association of Gynaecological Pathologists

BRITISH GYNAECOLOGICAL CANCER SOCIETY

2021 FIGO Staging System for Vulvar Cancer: Summary and comparison with 2009 FIGO Staging System

Authors: Brian Rous[1] Raji Ganesan[2] Asma Faruqi[3], Michael Eden[2], Sudha Sundar[4] Andy Nordin[5] W Glenn McCluggage[6]
[1]Cambridge University Hospitals NHS Trust, [2]Birmingham Women's Hospital, UK, [3]Barts Health NHS Trust, [4] Pan Birmingham Cancer Centre [5]Clinical Advisor for National Cancer Registration and Analysis Service (NCRAS) [6]Royal Group of Hospitals Trust, Belfast

Sponsored by

Carcinoma of the Vulva Histopathology Reporting Guide

ICCR

Family/Last name | Date of birth DD – MM – YYYY

Given name(s)

Patient identifiers | Date of request DD – MM – YYYY | Accession/Laboratory number

Elements in **black text** are CORE. Elements in grey text are NON-CORE.

SCOPE OF THIS DATASET

☐ indicates multi-select values ◯ indicates single select values

The Royal College of Pathologists
Pathology: the science behind the cure

Original research



OPEN ACCESS

European Society of Gynaecological Oncology Guidelines for the Management of Patients with Vulvar Cancer - Update 2023

Maaike H M Oonk,[1] François Planchamp ,[2] Peter Baldwin,[3] Sven Mahner,[4] Mansoor Raza Mirza,[5] Daniela Fischerová ,[6,7] Carien L Creutzberg,[8] Eugénie Guillot,[9] Giorgia Garganese,[10,11] Sigurd Lax,[12,13] Andres Redondo,[14] Alina Sturdza,[15] Alexandra Taylor ,[16] Elena Ulrikh ,[17] Vincent Vandecaveye ,[18] Ate van der Zee, Linn Wölber,[19] Diana Zach,[20,21] Gian Franco Zannoni ,[10,11] Ignacio Zapardiel [14]

Does "One Size Fits All"? Rethinking FIGO Depth of Invasion Measurements in Vulvar Cancer

IJGP 2024

Maaike C.G. Bleeker, M.D., Tjalling Bosse, M.D., Koen K. van de Vijver, M.D., Joost Bart, M.D., Hugo Horlings, M.D., Trudy G.N. Jonges, M.D., Nicole C.M. Visser, M.D., Loes F.S. Kooreman, M.D., Johan Bulten, M.D., and Patricia C. Ewing-Graham, M.B.Ch.B.

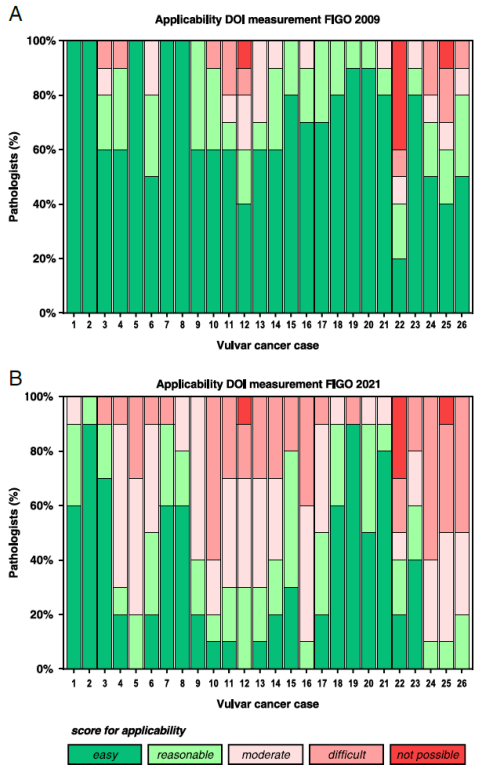

FIG. 2. Applicability of FIGO 2009 (A) and FIGO 2021 (B) method for DOI measurement in vulvar cancers. DOI indicates depth of invasion; FIGO, International Federation of Gynecology and Obstetrics.

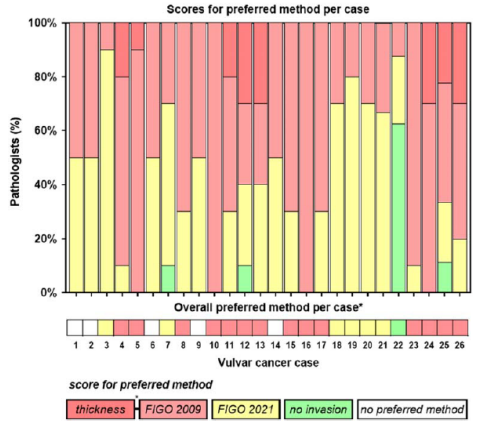

FIG. 3. Preferred method for depth of invasion measurement in vulvar cancers. FIGO indicates International Federation of Gynecology and Obstetrics.

26 cases, 10 pathologists

preferred method:
- FIGO2009 in 14 cases
- FIGO 2023 in 6 cases

no preference in 20% of cases

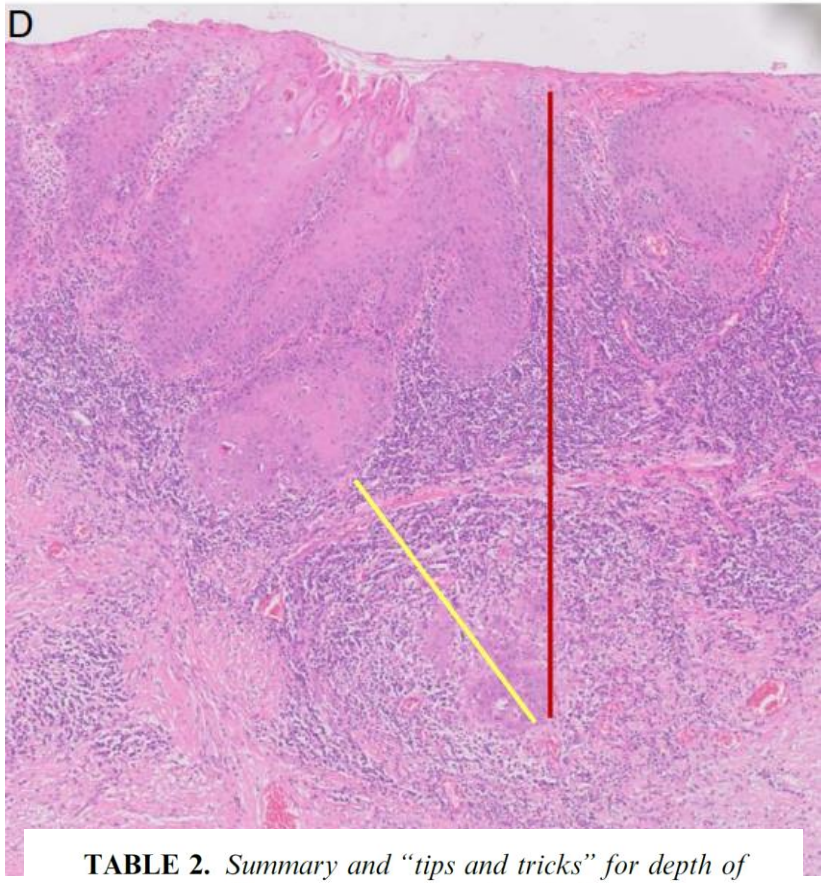

TABLE 2. *Summary and "tips and tricks" for depth of invasion measurement methods*

Method of DOI measurement	FIGO 2009	FIGO 2021
Applicability of DOI measurement method	Good	Moderate
Tumor thickness may be an alternative	yes	no
Where there is a limited amount of tumor ("few islands off the coast") and clear distinction with precursor	no	yes
Where the origin of the tumor is uncertain ("starting point") and unclear distinction with precursor	yes	no

DOI indicates depth of invasion; FIGO, International Federation of Gynecology and Obstetrics.

Let’s work together!

Some real cases!

Case 1

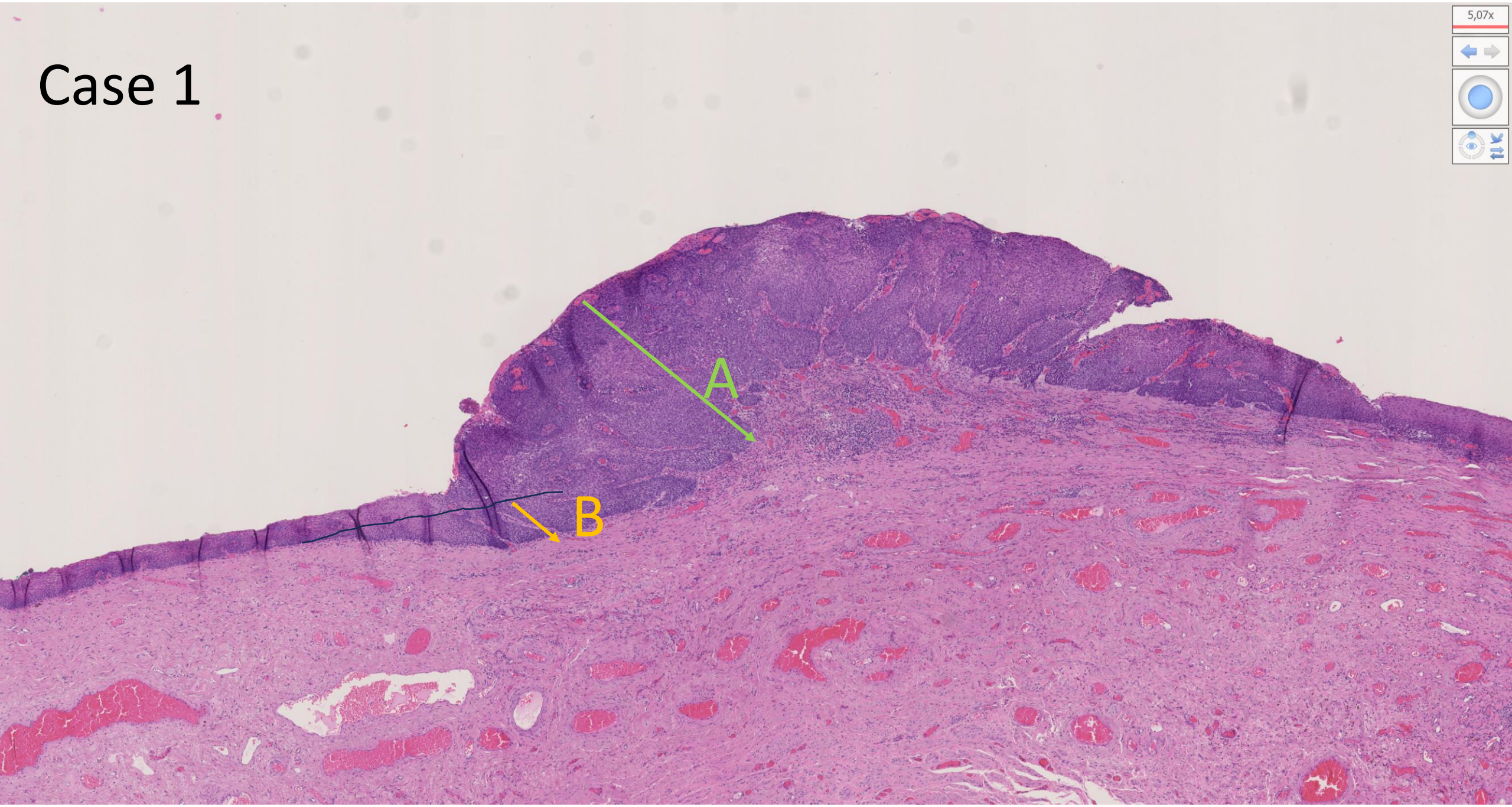

Case 2

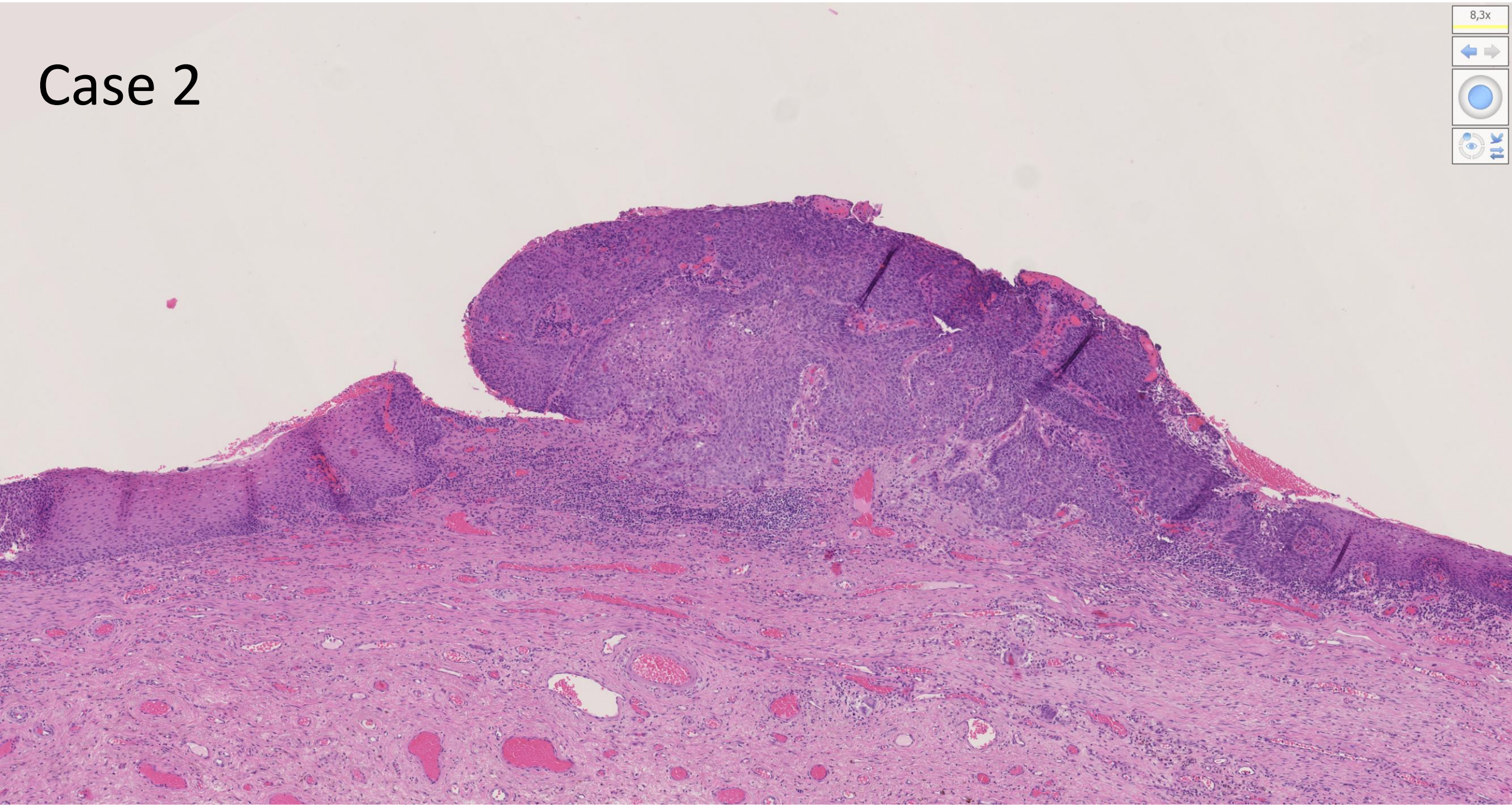

Case 2

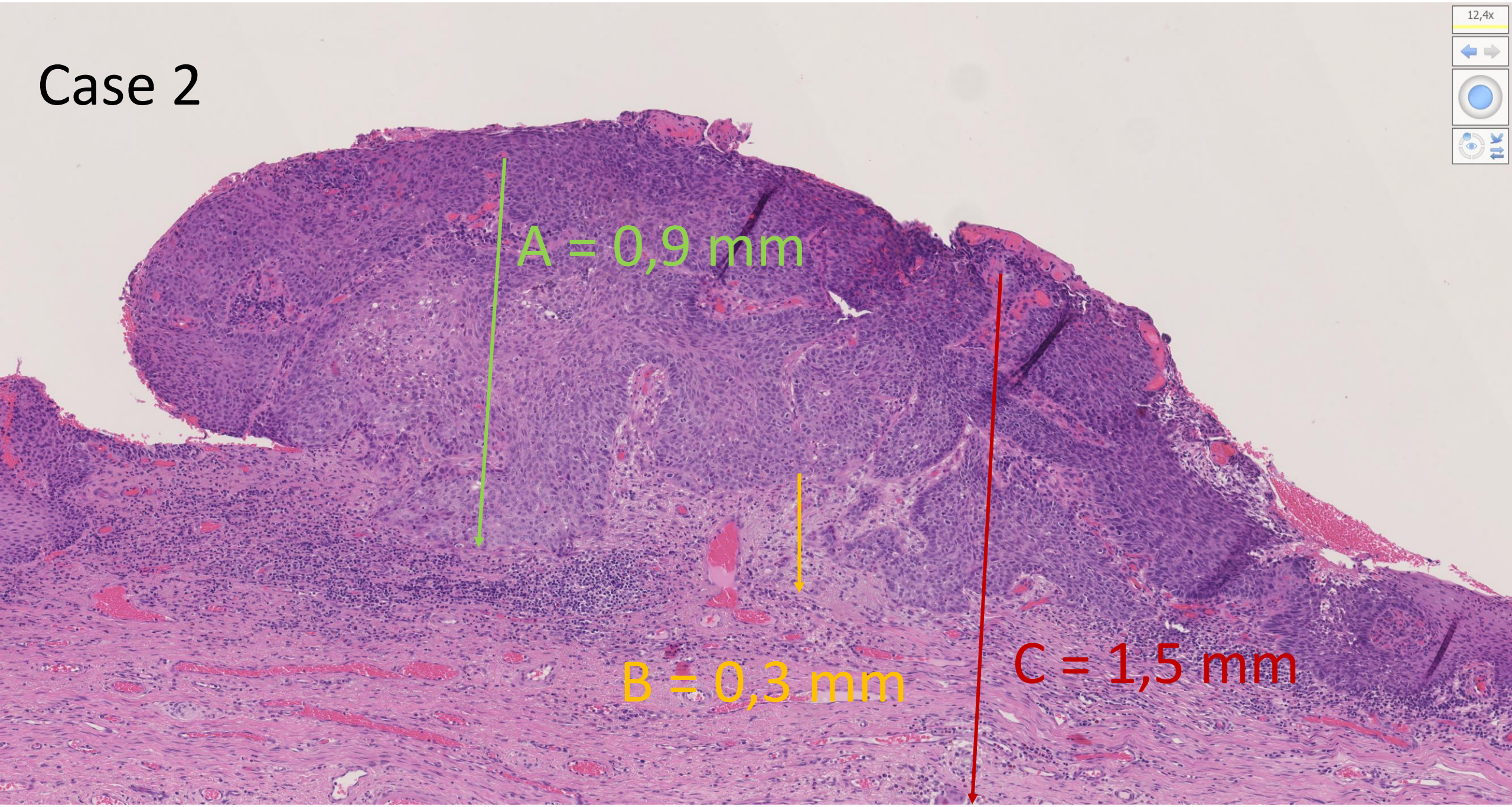

Case 3

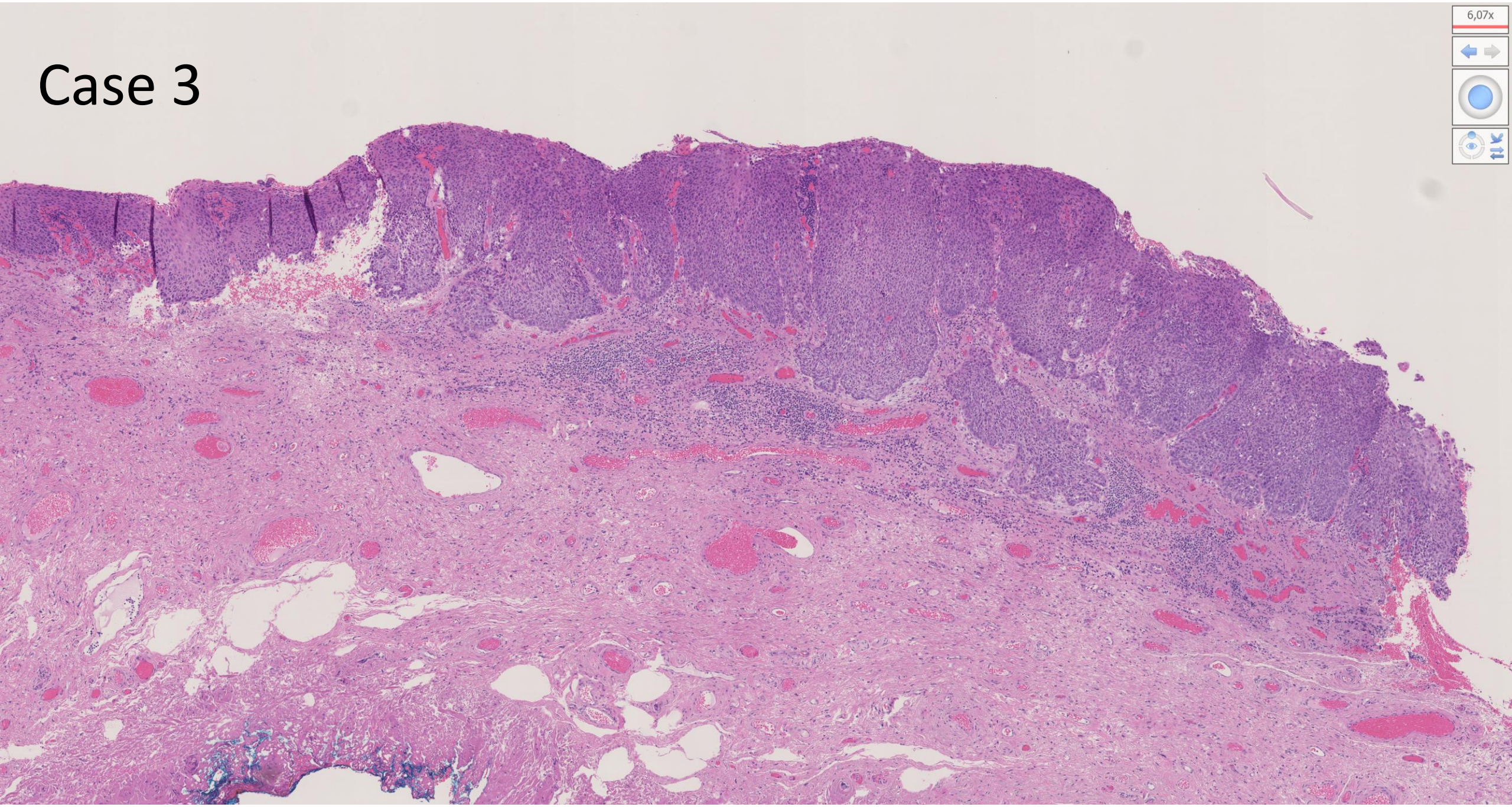

Case 3

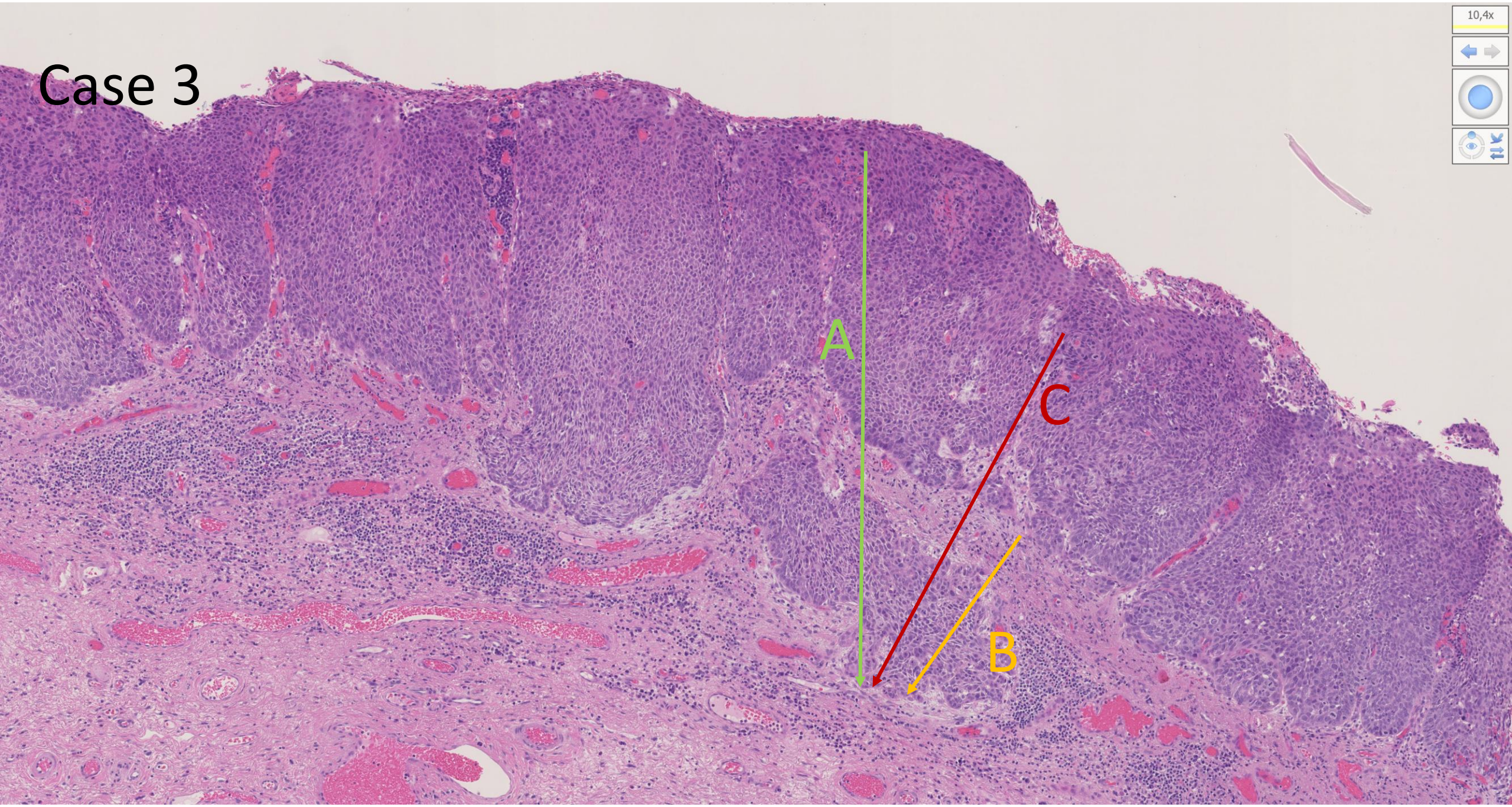

Case 4

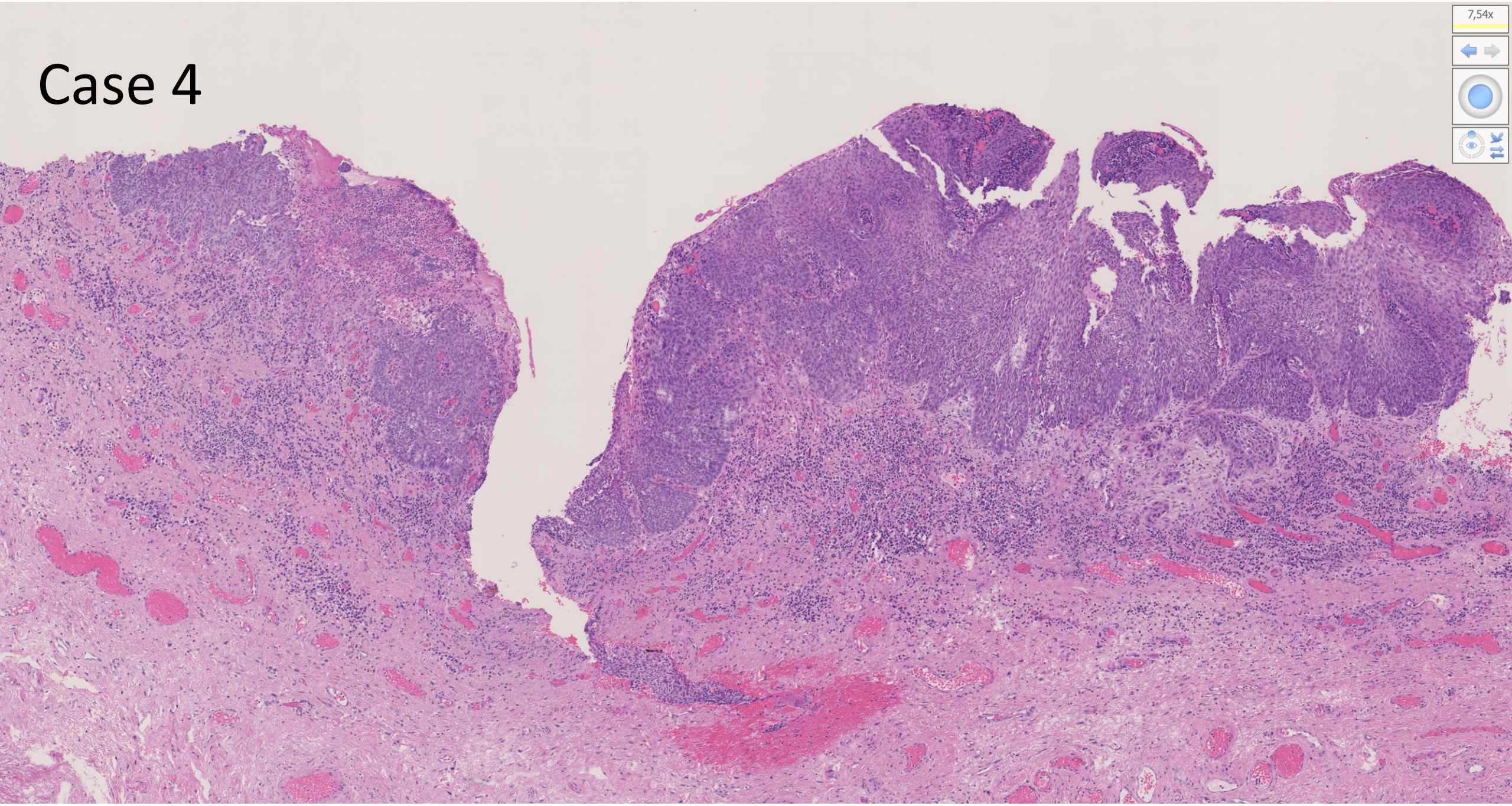

Case 4

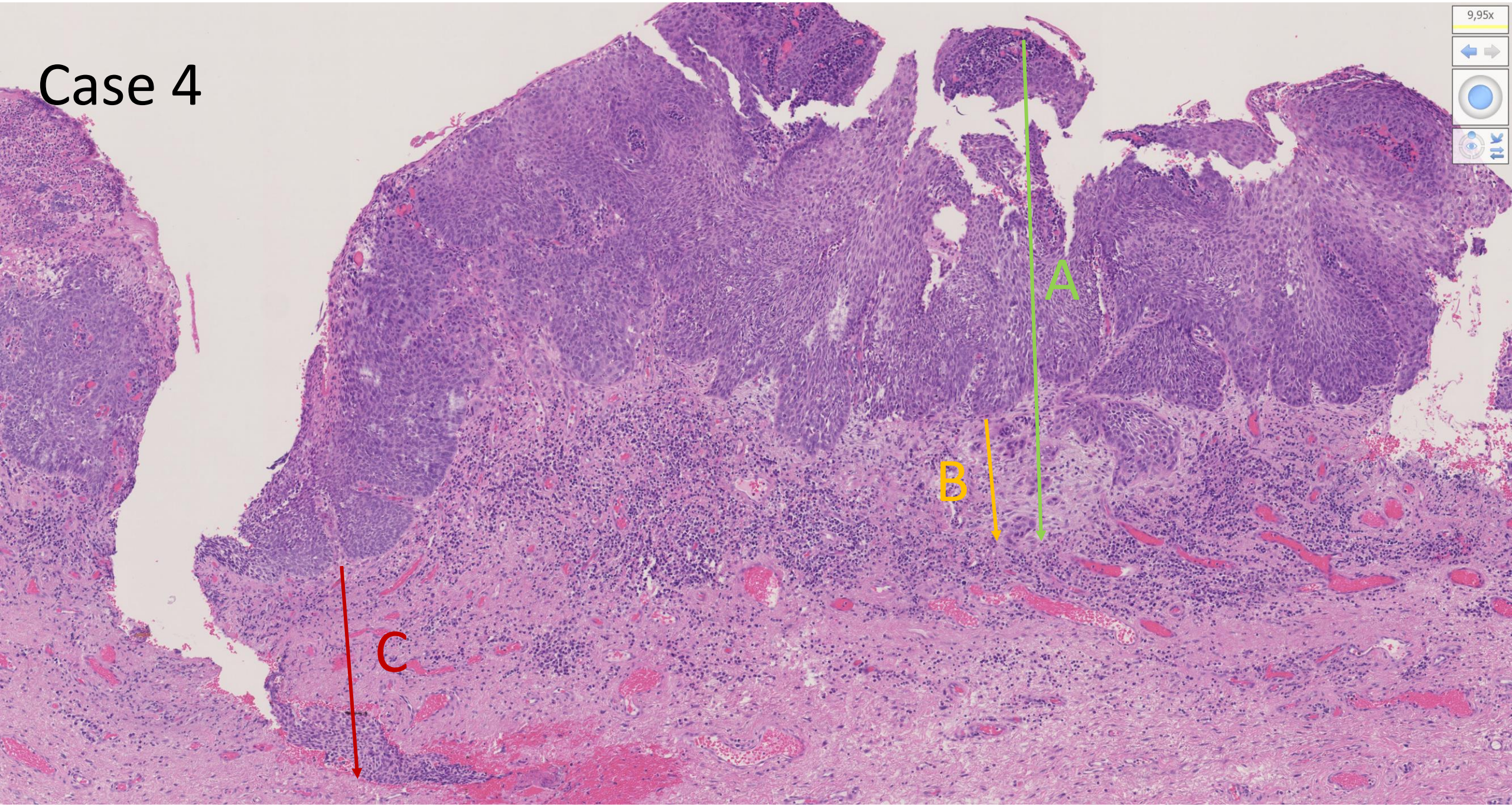

Case 5

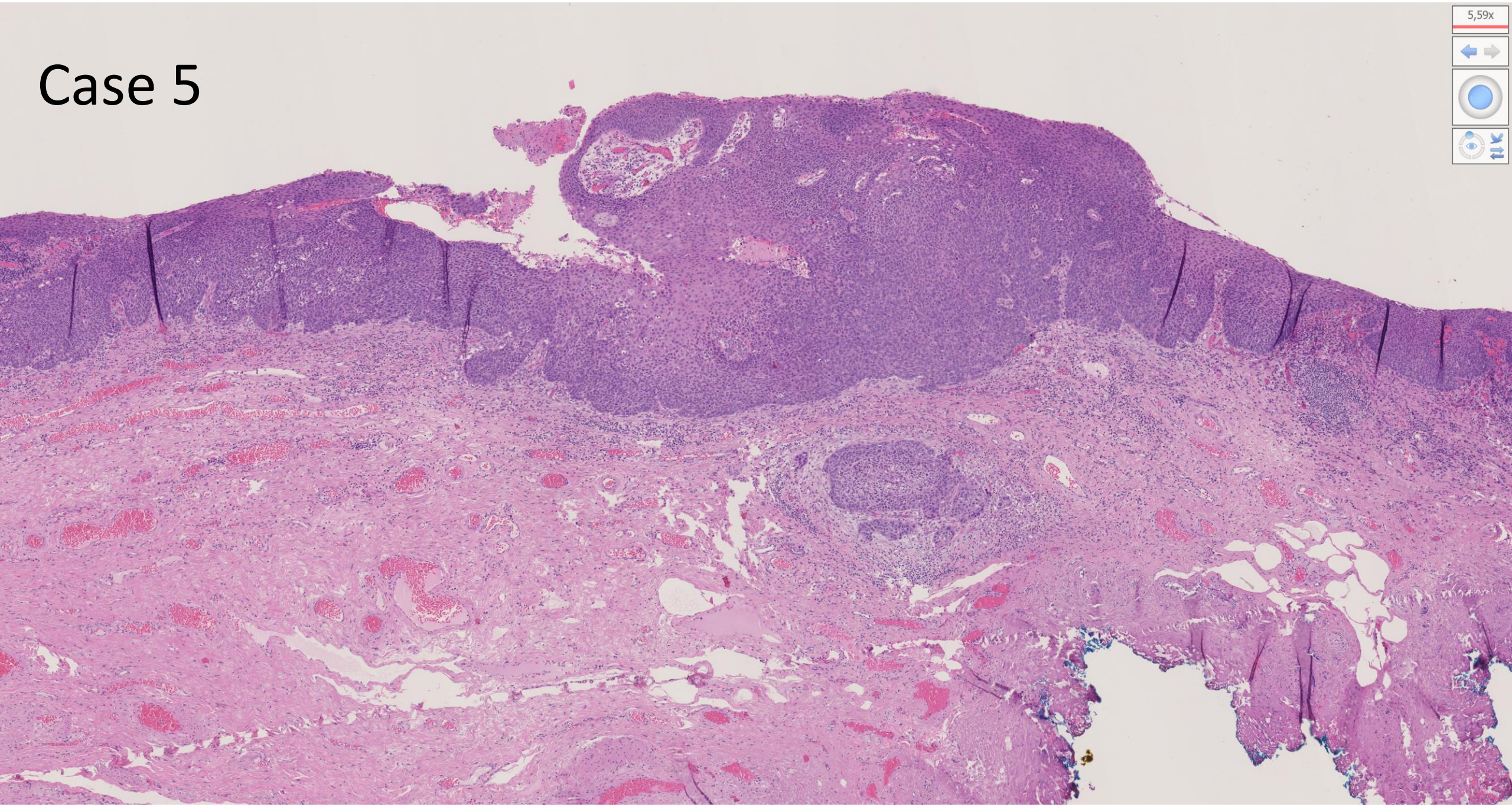

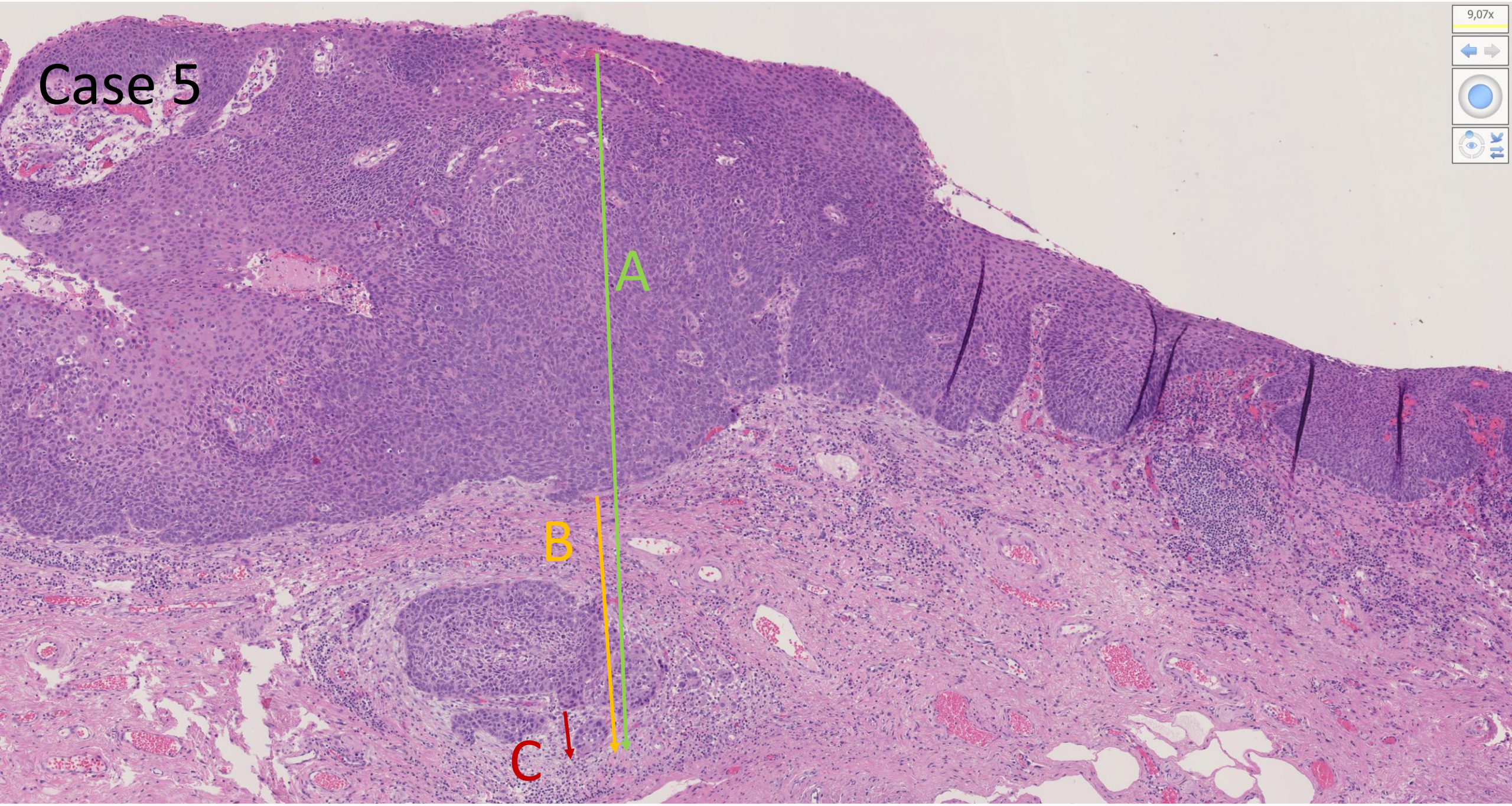
Case 5
A
B
C
9,07x

Case 6

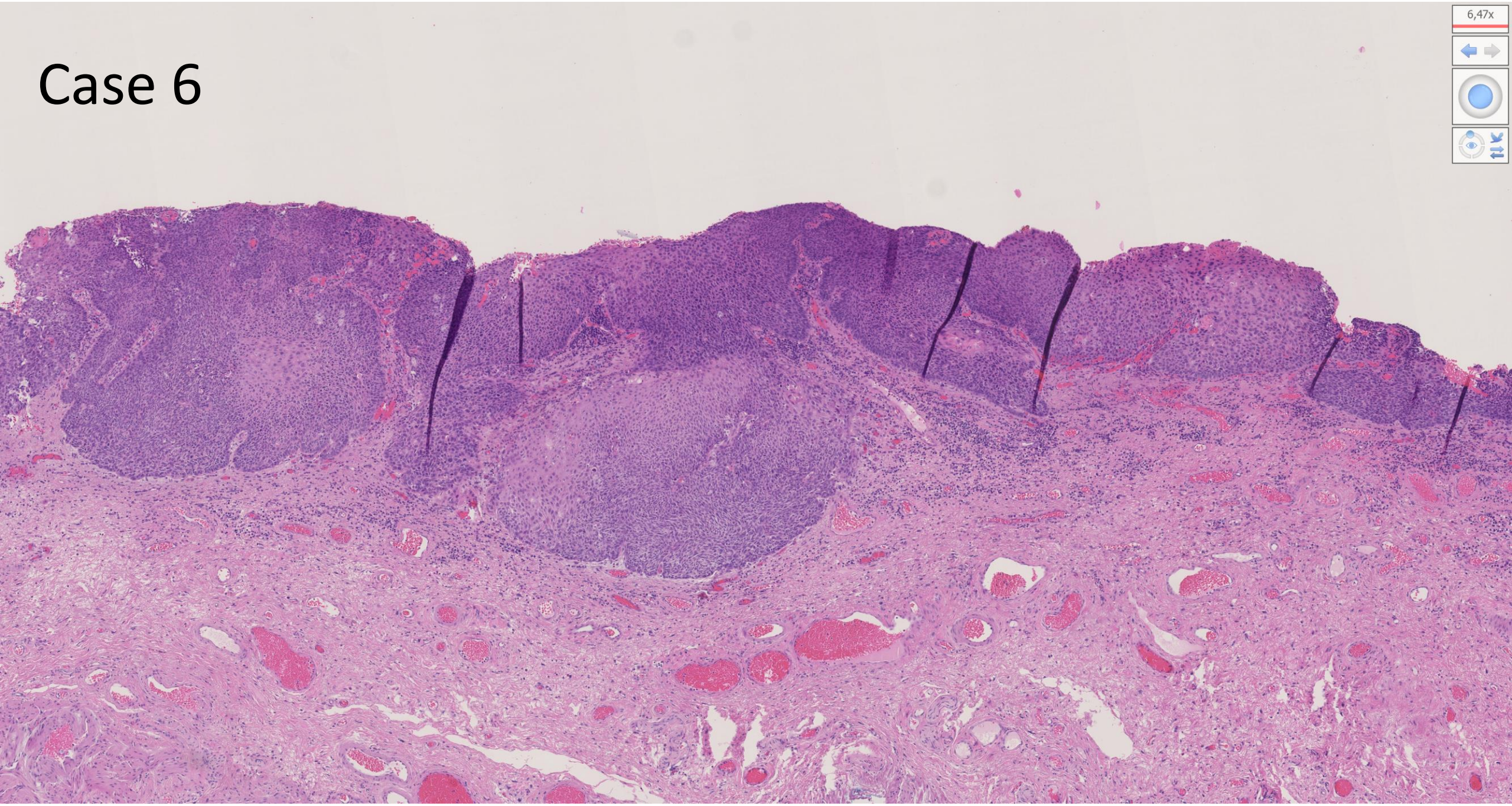

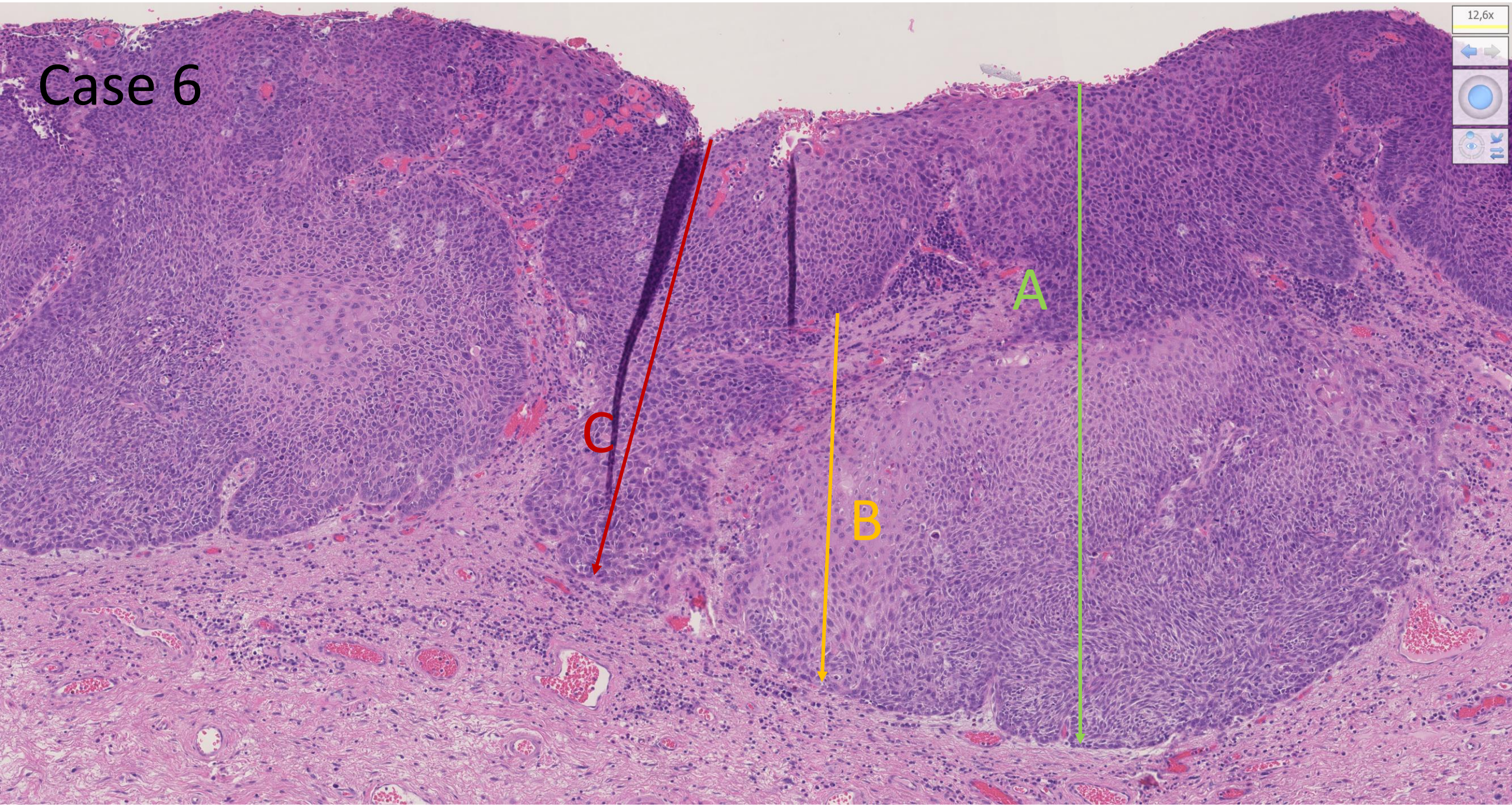
Case 6
A
B
C
12,6x

Thank you !

