The British Association of Gynaecological Pathologists

Lecturer – Dr William Rickaby

Dr William Rickaby is a Consultant Dermatopathologist at University College London Hospitals NHS Foundation Trust.

Dr Rickaby undertook his pathology training in London. He subsequently completed a two-year clinical fellowship in dermatopathology at St John's Institute of Dermatology, London, working under Dr Eduardo Calonje. He has worked as a Consultant Dermatopathologist at St John's Institute of Dermatology and at Queen Elizabeth University Hospital, Glasgow, before returning to UCLH.

His main areas of interest are melanocytic tumour pathology, squamous cell carcinoma, and clinicopathological correlation of inflammatory dermatoses. He sits on the steering committee of the UKKCC (UK Keratinocyte Collaborative Committee) whose aim is to create a national biobank of cutaneous SCC for research. He speaks regularly at national and international meetings, including the British Association of Dermatologists Annual Meeting. He holds the International Diploma in Dermatopathology (ICDP-UEMS) and the Royal College of Pathologists' Diploma in Dermatopathology.



The British Association of Gynaecological Pathologists

Vulvo-Vaginal Update Course

- Case-Based Discussion of Inflammatory Dermatosis
- Dr William Rickaby
- Consultant Dermatopathologist, UCLH
- 29th November 2024

The British Association of Gynaecological Pathologists

Speaker disclosures

- ❑ I have no financial conflicts of interest to disclose

Female 73 years

Genital plaques and discomfort

Erythematous vulva with heaped up edges and vesicles around the periphery



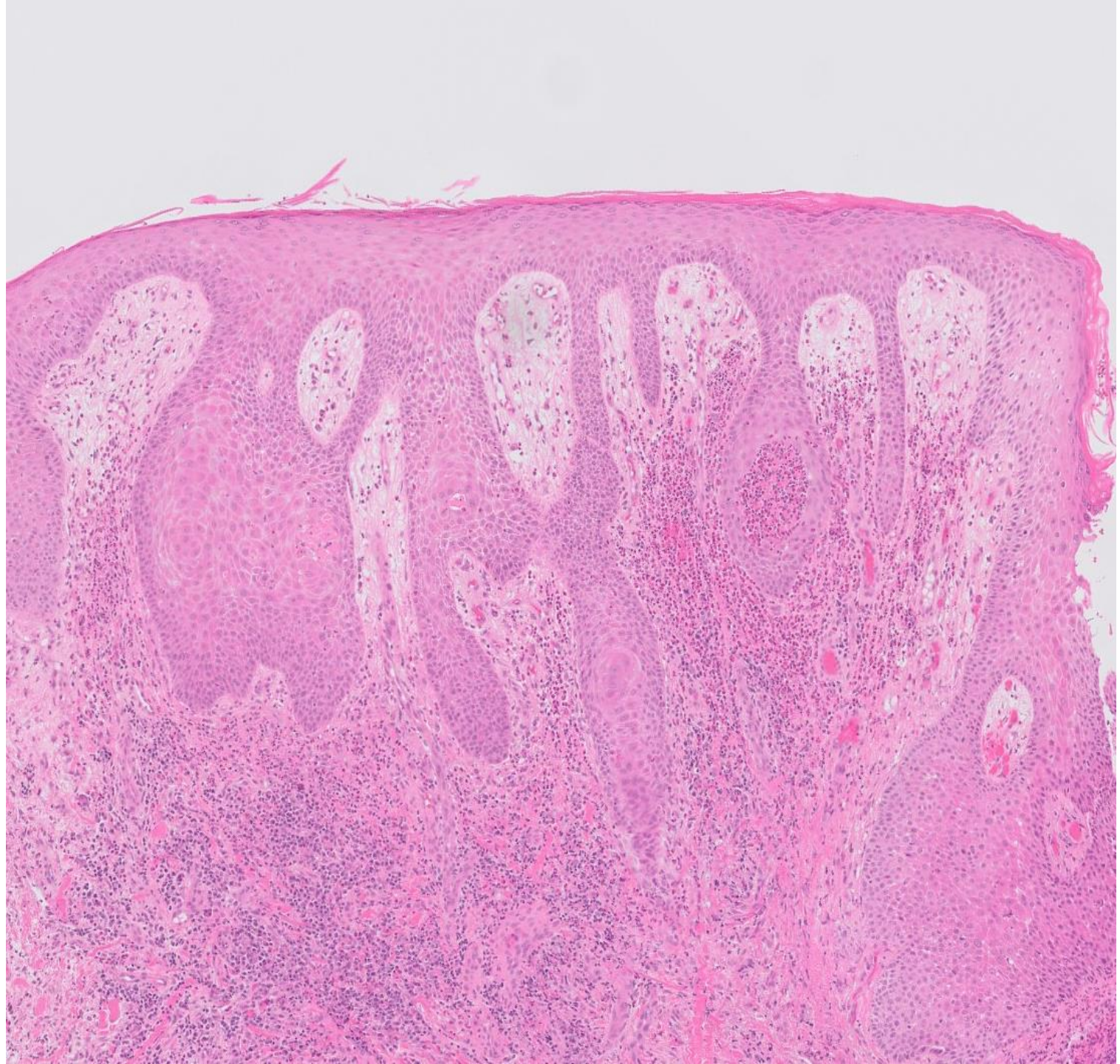

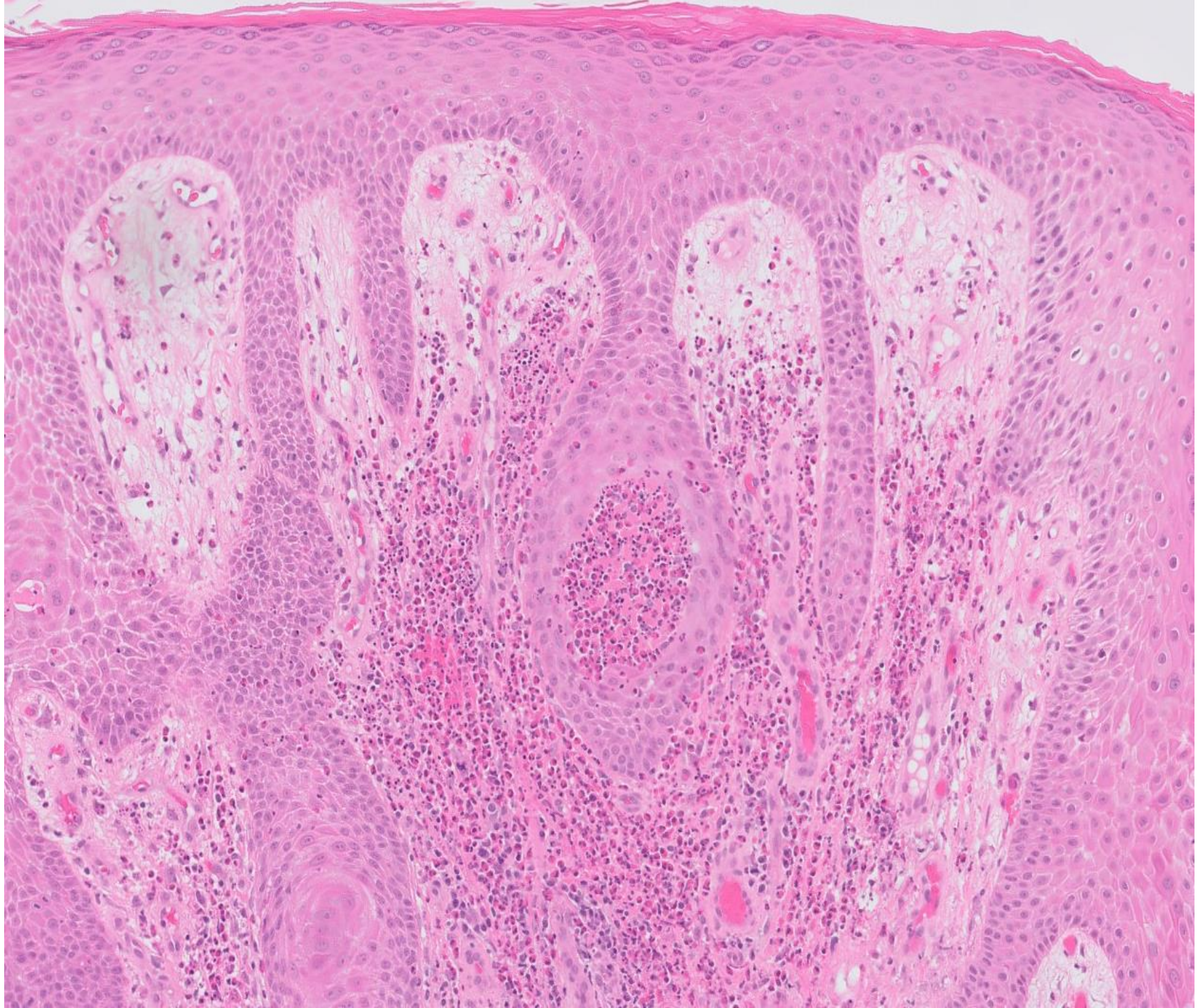

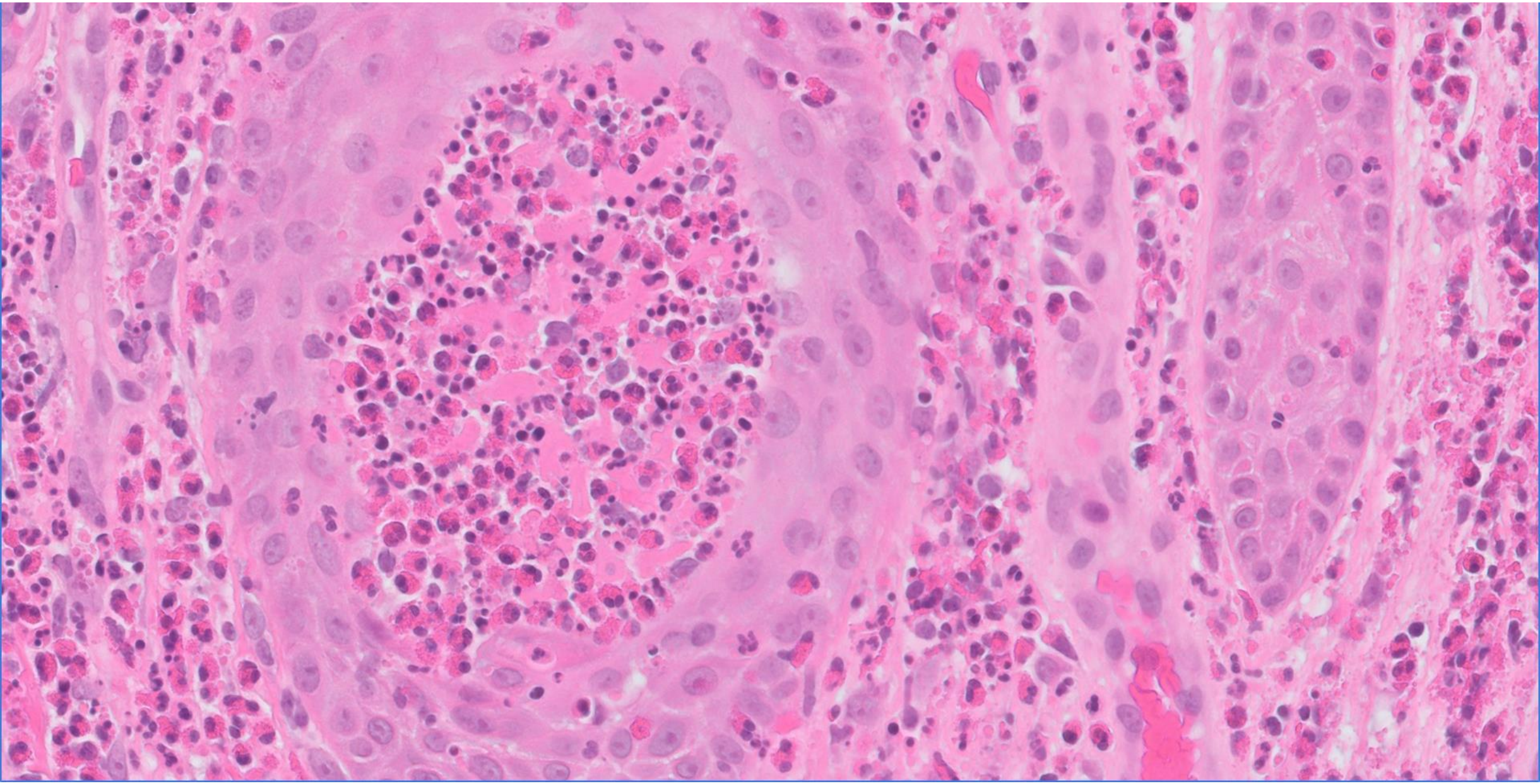

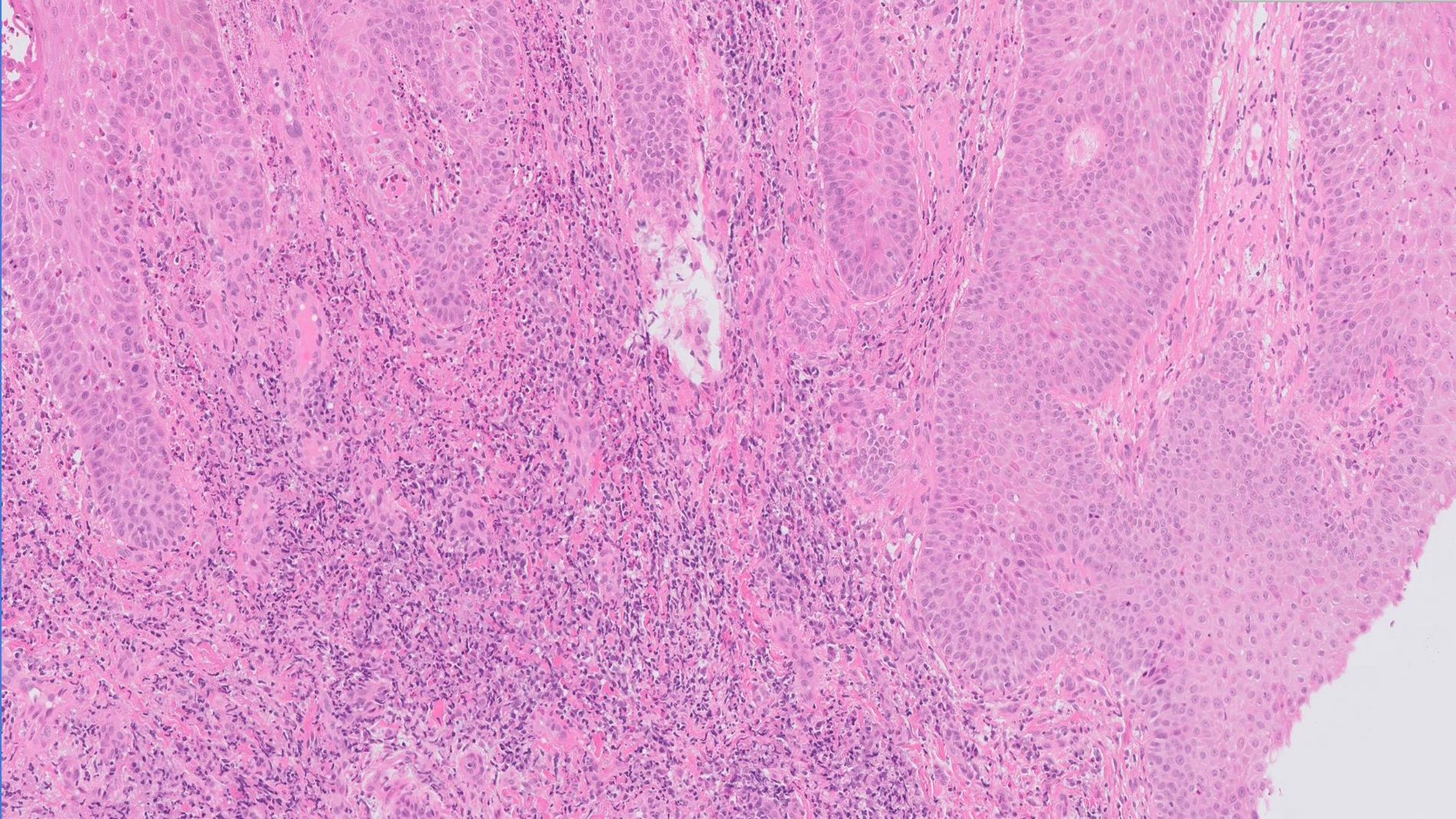

Identify the most likely diagnosis:

A. Eczematous dermatitis
B. Pemphigus vegetans
C. Fungal infection
D. Acantholytic dermatosis of the genitocrural area

- more extensive disease over 6 months
- bilateral discharging groin lesions and perianal lesions
- thickened erythematous slightly eroded plaques perianal margin, natal cleft, groin and vulval skin
- painful and discharging
- two small ulcers buccal mucosa

- Clinical query
  - *Malignancy*
  - *Necrolytic migratory erythema*
  - *Psoriatic process*
  - *Paraneoplastic process*
  - *Extramammary Paget's*
  - *Crohn's?*

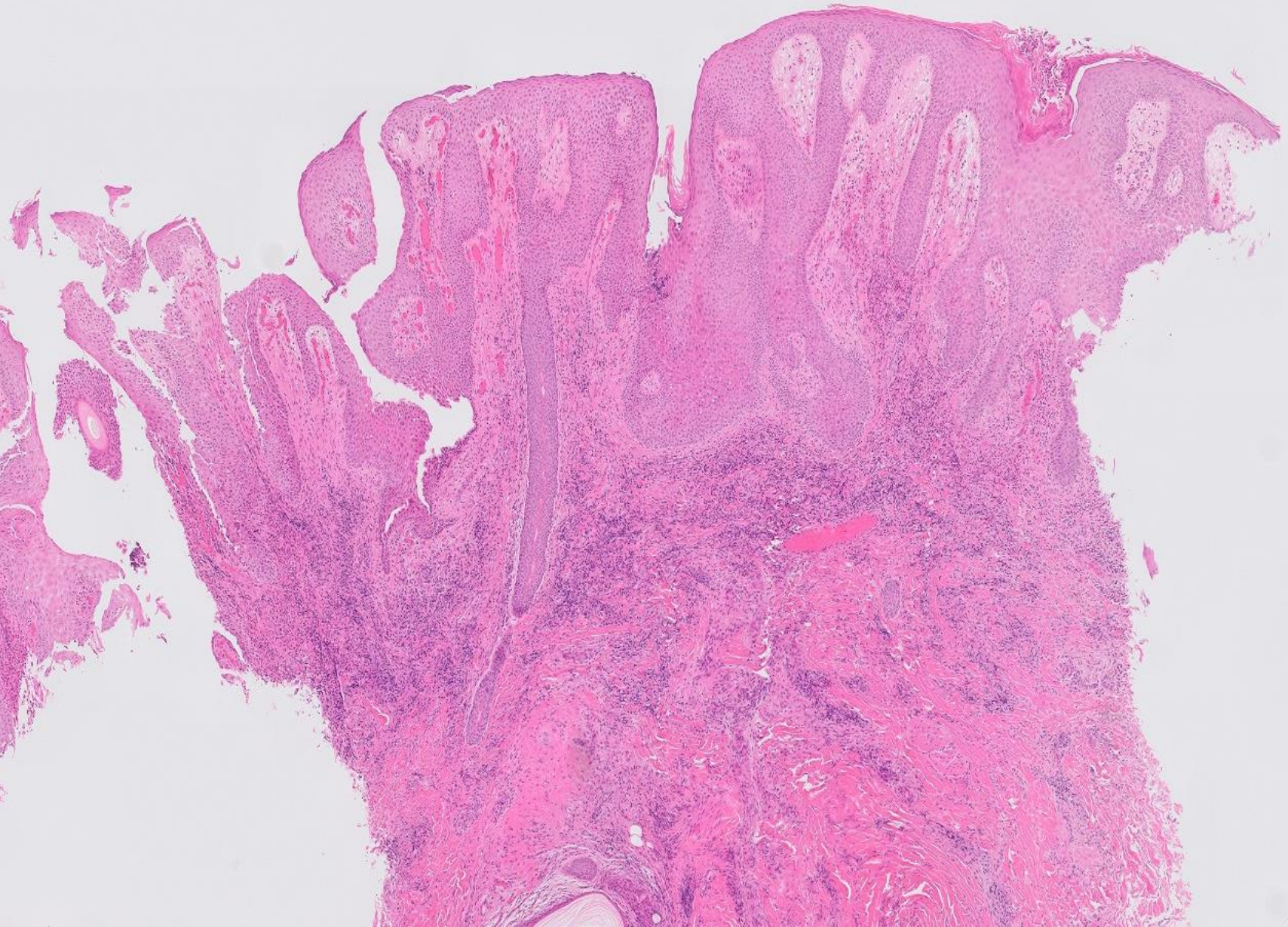

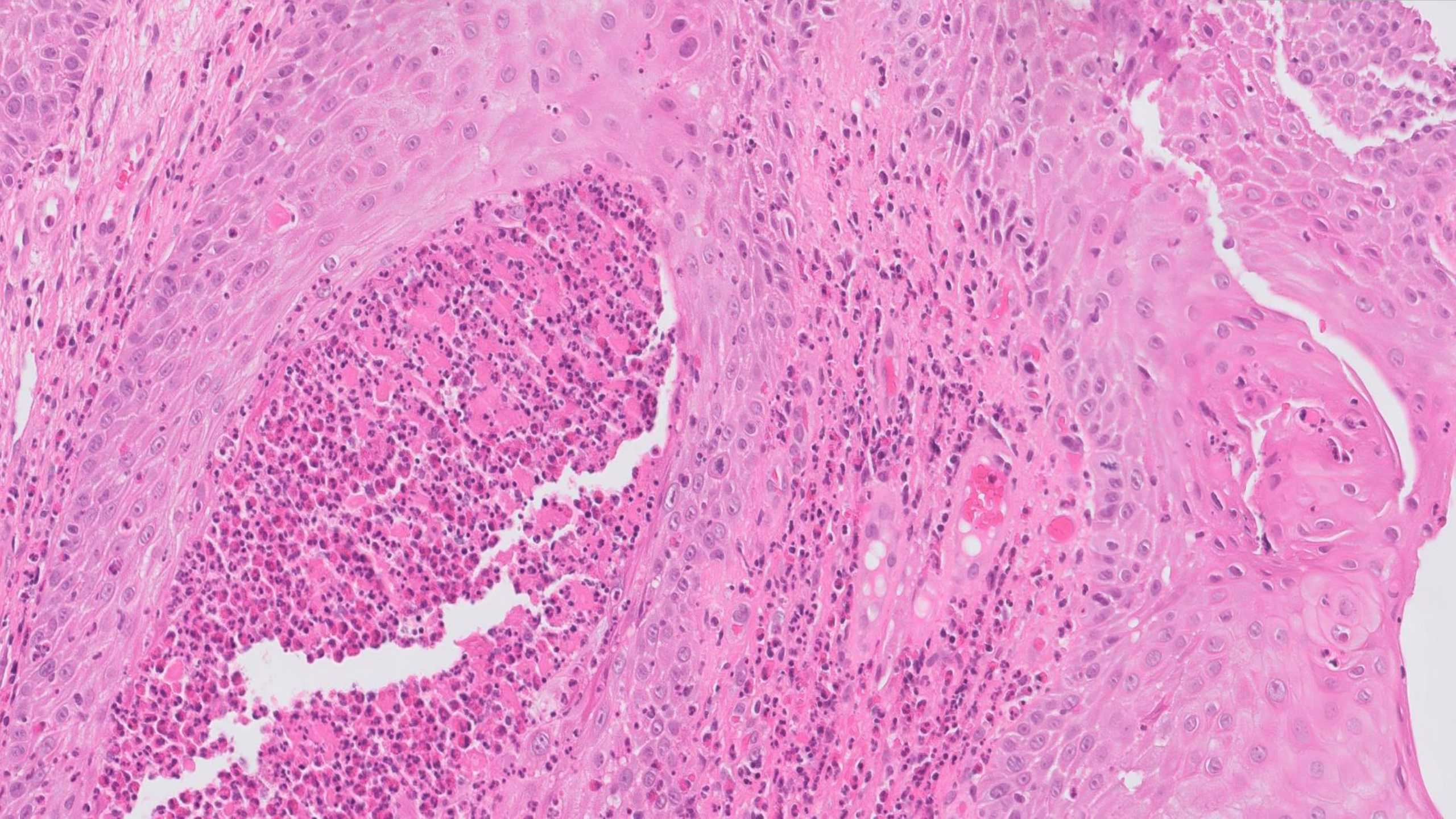

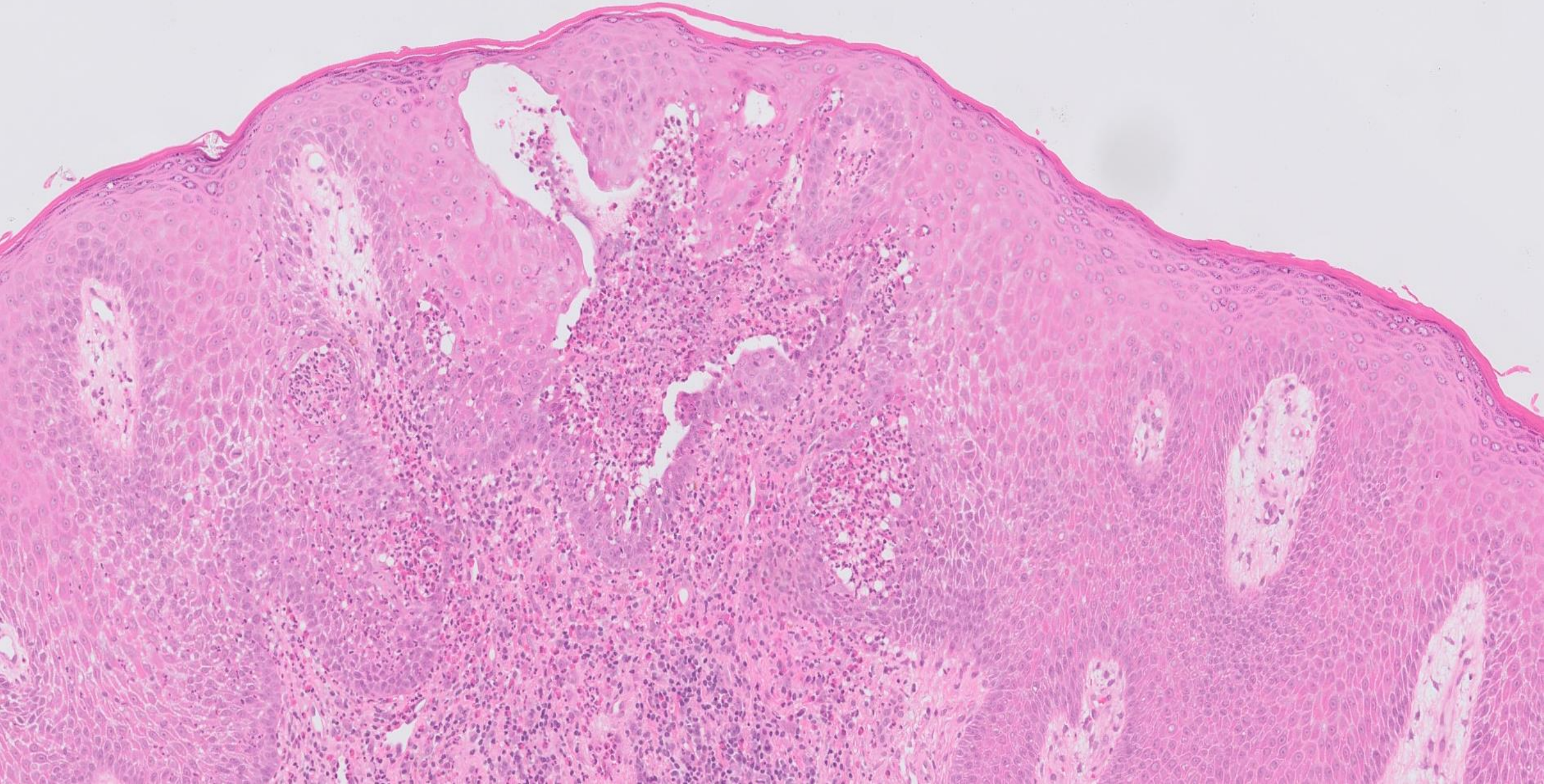

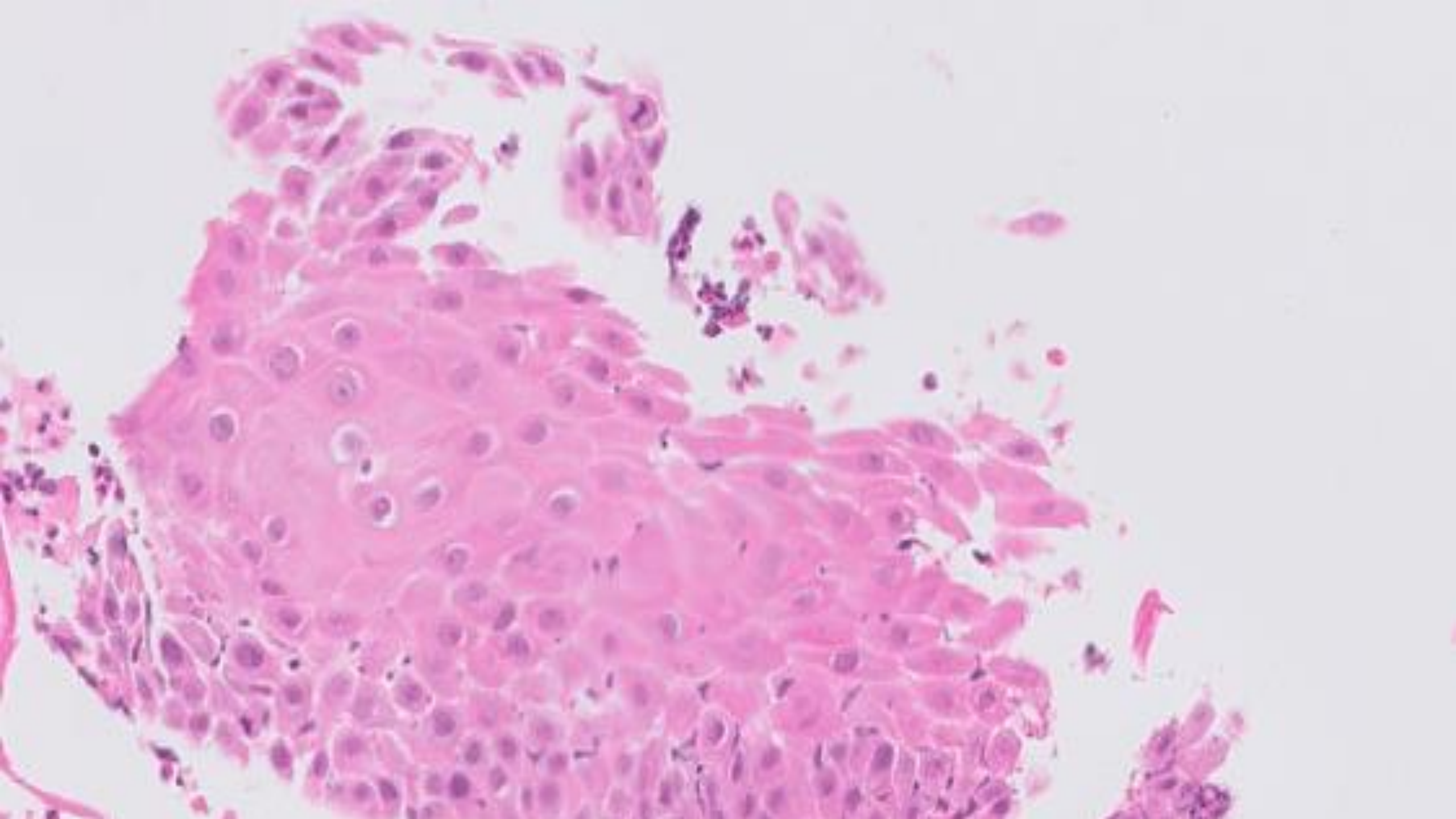

Identify the most likely diagnosis:

A. Eczematous dermatitis
B. Pemphigus vegetans
C. Fungal infection
D. Acantholytic dermatosis of the genitocrural area

- PAS stain
  - Negative
- Direct IMF:
  - Intercellular IgG and C3

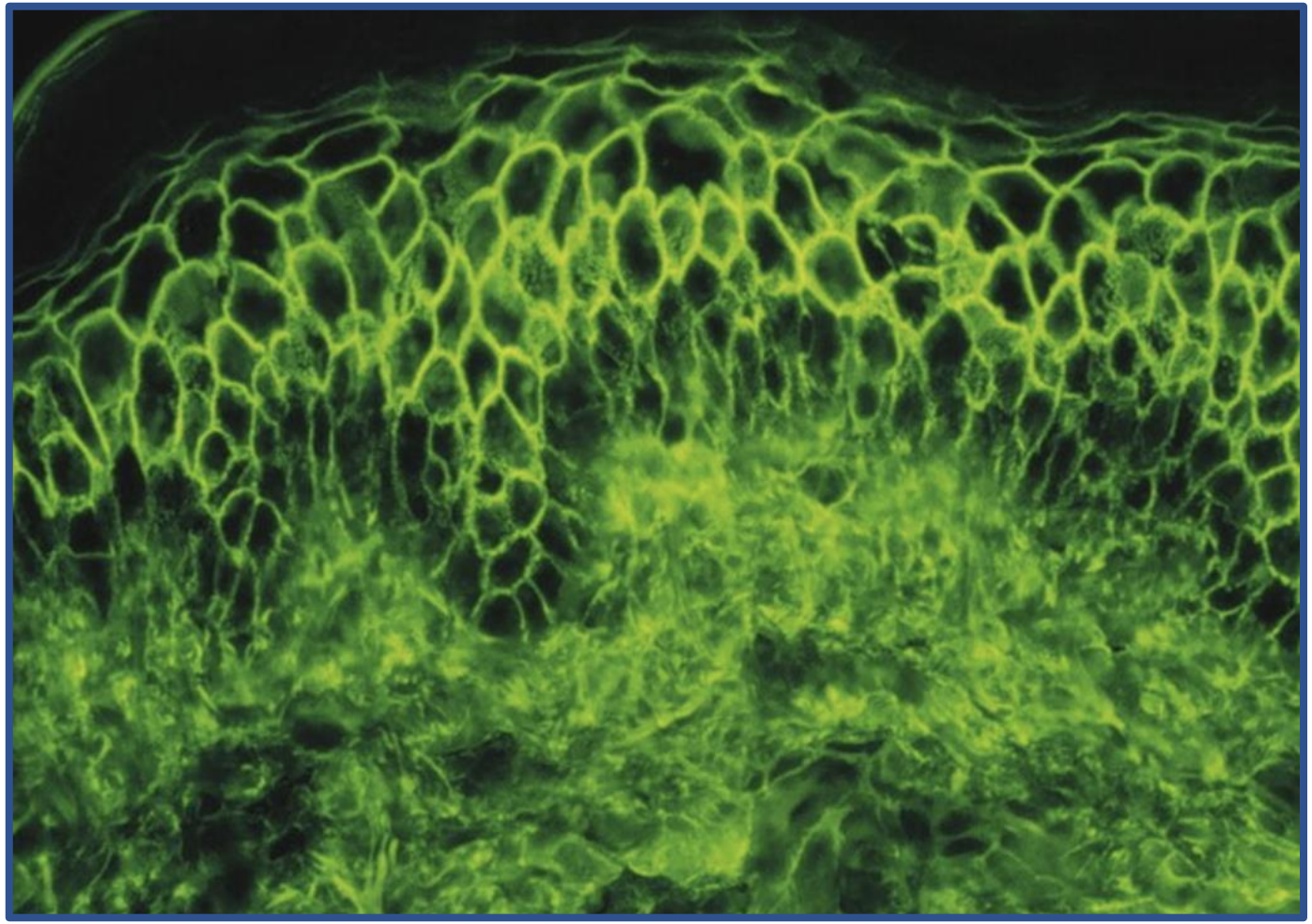

- B. Pemphigus vegetans
  - variant of pemphigus vulgaris
  - easily missed because acantholysis is typically focal/mild
  - characteristic histological features

Pemphigus vegetans

- rare subtype of pemphigus vulgaris
- 1-2% of all pemphigus vulgaris
- anogenital involvement common
- 50-70yrs most commonly
  - although wide age range from childhood through to elderly
- mimic wide range of dermatological diseases
  - condylomas
  - malignancy

Pemphigus vegetans





- vegetative plaques
- typically affects big folds (axillary, inframammary, groin, intergluteal)
- can occur exclusively genital sites

- Hallopeau
  - grouped annular pustules that heal into vegetative plaques
  - centrifugal expansion
  - better prognosis
  - +/- oral
- Neumann
  - flaccid bullae and erosions evolving into papillomatous vegetative plaques
  - more severe
  - may be more refractory to treatment
  - oral usually involved



Pemphigus vegetans

- Oral involvement common
  - 60-80%
  - Neumann
  - erosions/ulcers
  - verrucous plaques vermillion border of lips
  - cerebriform tongue





Immunofluorescence

- Direct IMF
  - same as pemphigus vulgaris
  - **intraepidermal IgG and C3**

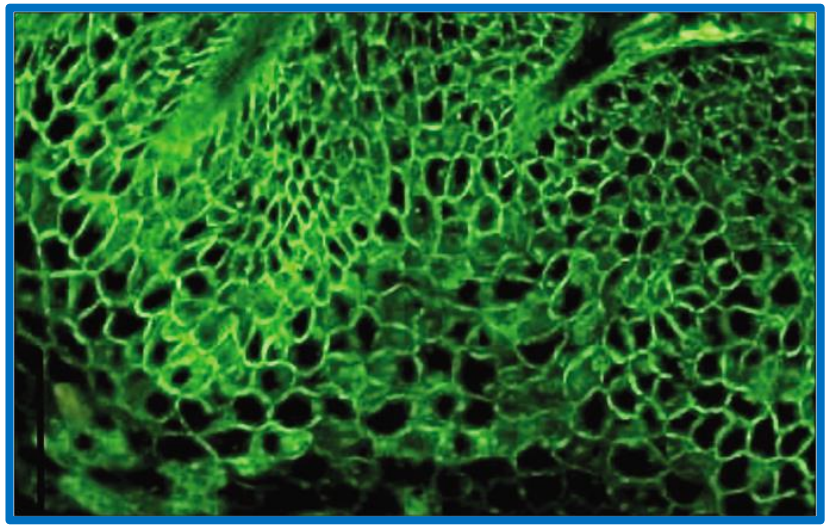

Differential dx: -

- pyodermatitis/pyostomatitis vegetans
  - clinically and histologically look similar to pemphigus vegetans
  - associated with inflammatory bowel disease
  - negative DIF
- lichen simplex chronicus/spongiotic dermatitis
- fungal infection
- scabies

Histology

- pseudoepitheliomatous hyperplasia
- **eosinophilic microabscesses (+/- neutrophils, +/- acantholytic cells)**
- spongiosis
- acantholysis focal/mild
- mixed inflammation in dermis

- ***Acantholysis may be minimal or masked by exuberant epidermal proliferation***

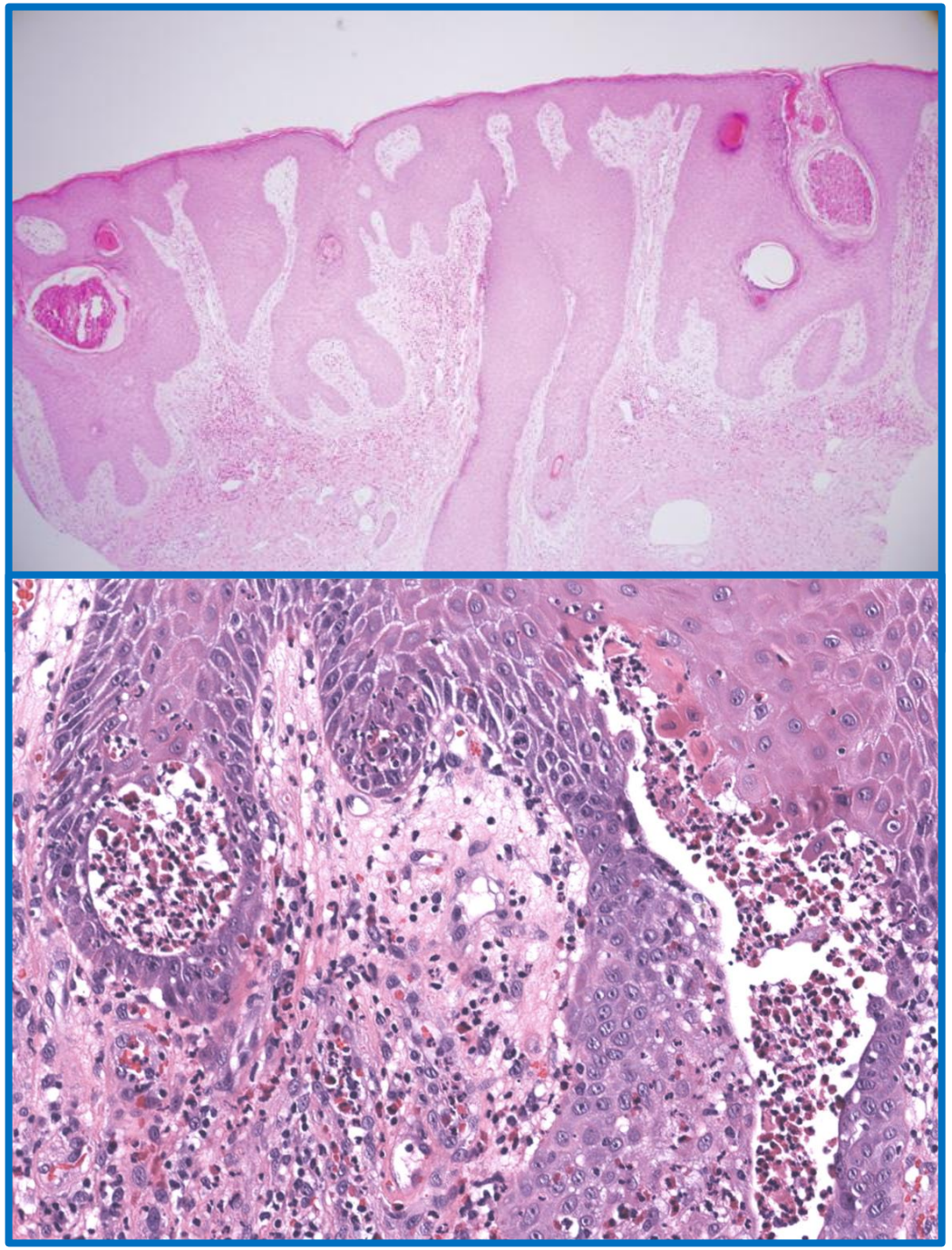

Acantholytic disorders affecting genital sites

- Greek akantha, a thorn or prickle, and lysis, a loosening
- separation of the keratinocytes at their desmosomal junctions
- “falling apart” - intra-epidermal blister

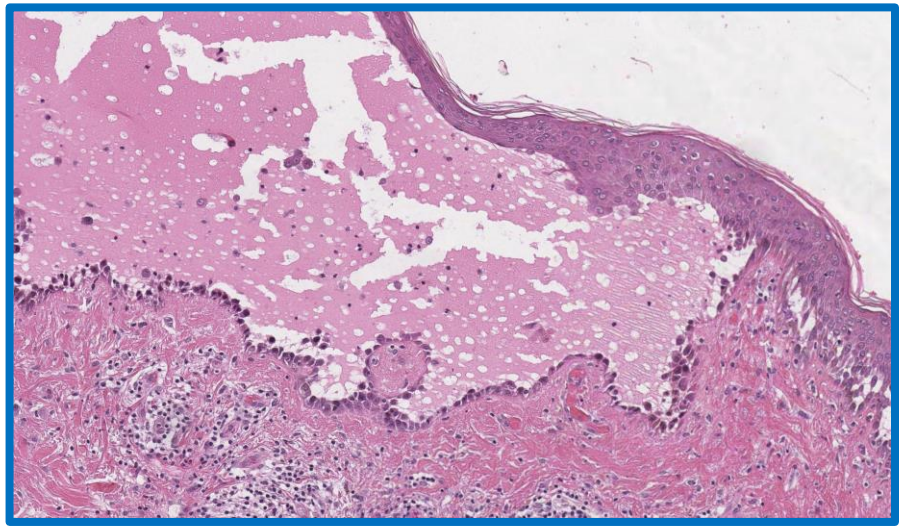

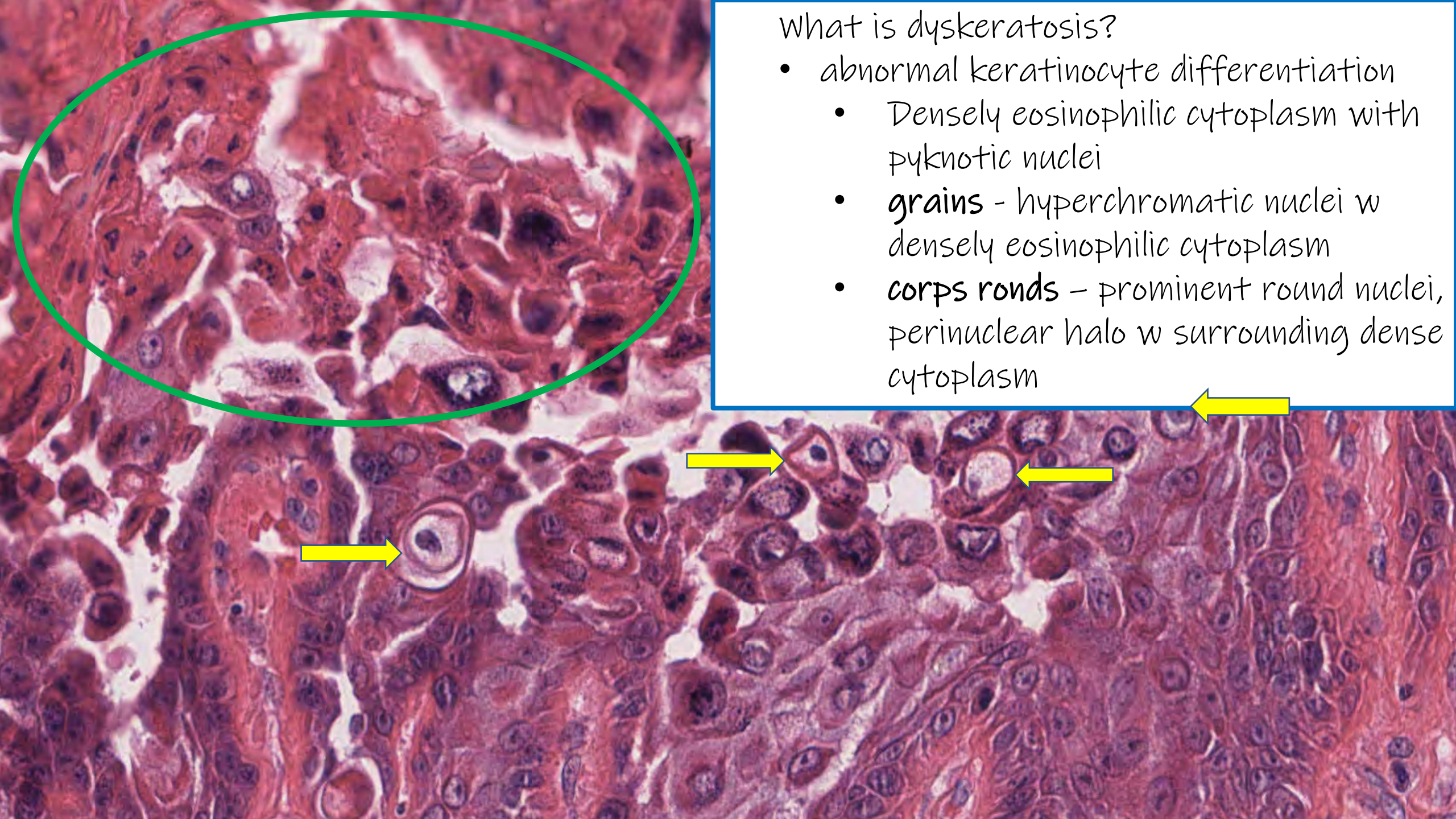

What is dyskeratosis?

- abnormal keratinocyte differentiation
  - Densely eosinophilic cytoplasm with pyknotic nuclei
  - **grains** - hyperchromatic nuclei w densely eosinophilic cytoplasm
  - **corps ronds** – prominent round nuclei, perinuclear halo w surrounding dense cytoplasm

Acantholytic disorders affecting genital sites

- ?acantholytic
- r/o other conditions (acantholysis secondary phenomenon)
- consider acantholytic disease (acantholysis is predominant pattern)
- ?dyskeratosis or not

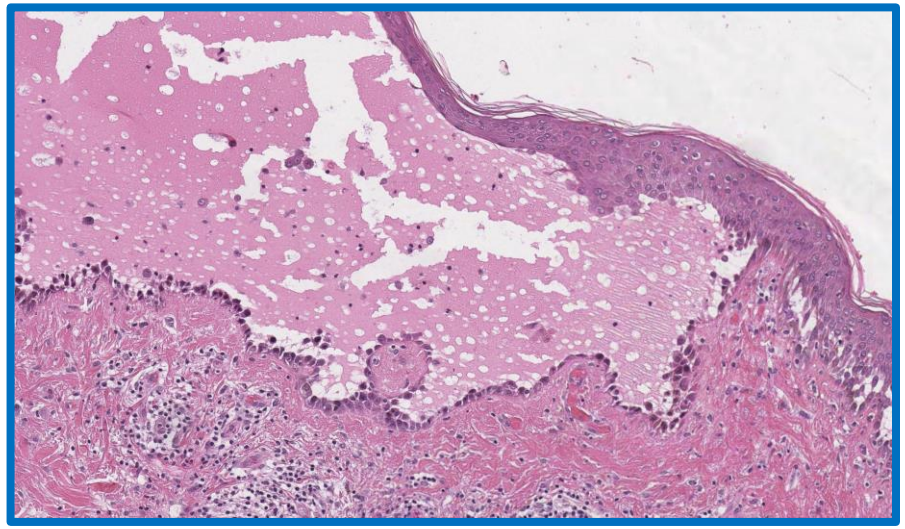

?Acantholytic process

- Pemphigus vulgaris / vegetans
- Darier
- Hailey-Hailey
- Acantholytic dermatosis of the genitocrural area
- Warty dyskeratoma

- *Spongiotic dermatitis*
- *Herpes*
- *Squamous dysplasia*

Exclude other processes

- **Oedema – spongiotic dermatitis**
  - marked intercellular oedema, reticular degeneration of epidermis with vesicle formation
  - may be a few detached cells
  - acanthosis, hyperkeratosis, ‘wet’ scale

  - *eczematous process*
  - *contact dermatitis*
    - *soaps, detergents, perfume, spermicide, latex, sanitary products, vagisil*
  - *superficial fungal infection*
    - *PAS stain*
  - *drug*

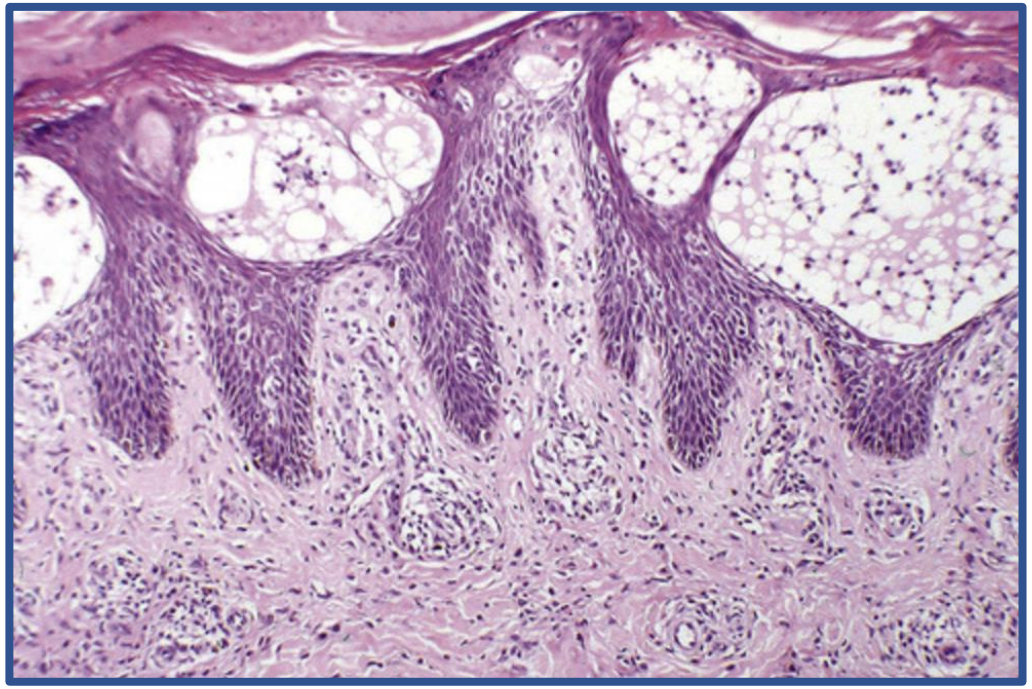

Exclude other processes

- **Ballooning degeneration - herpes**
  - swelling and separation of virus-infected cells

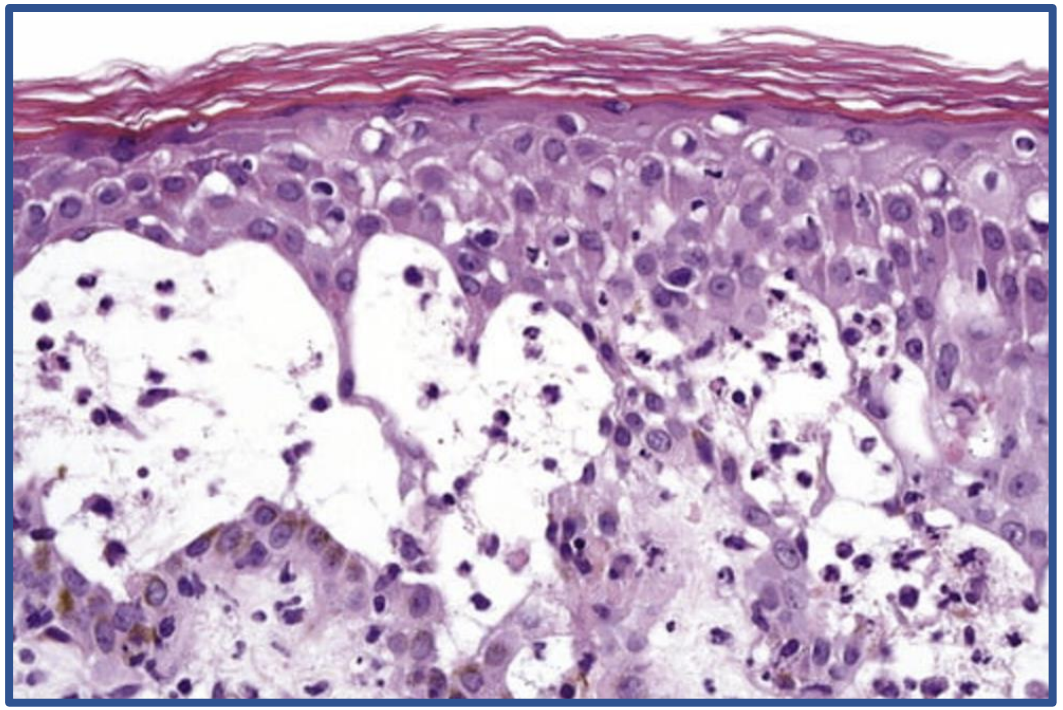

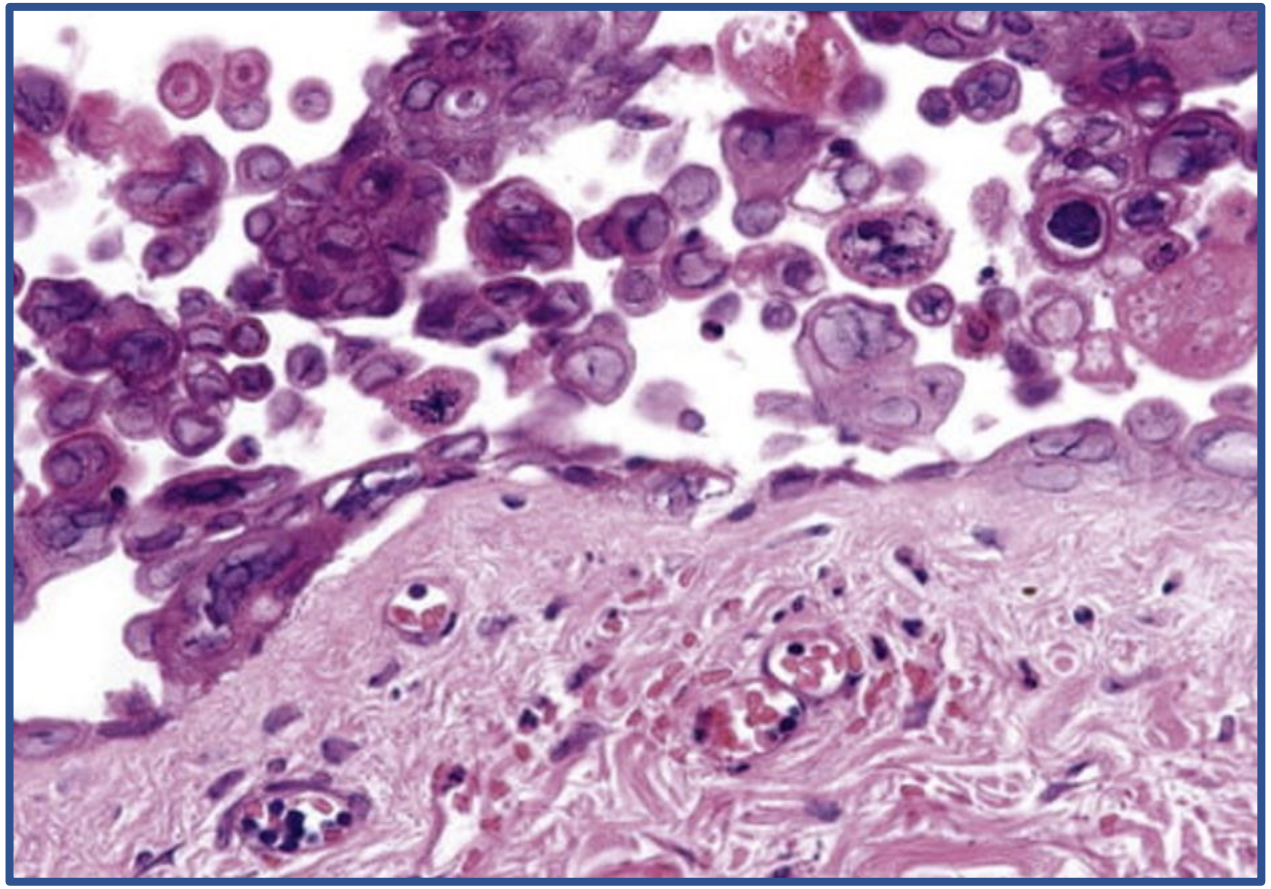

- Margination, Moulding & Multinulceation

Acantholytic disorders affecting vulva/vagina

- Immunobullous
  - **Pemphigus vulgaris**
    - **Pemphigus vegetans**
- Acantholytic dermatosis with dyskeratosis
  - **Darier's**
  - **Hailey-Hailey**
- Other
  - **Acantholytic dermatosis of genitocrural area**
  - **Warty dyskeratoma**



Pemphigus vulgaris

- rare acquired immunobullous disorder of skin and mucosa
  - 0.1-0.7 per 100 000
  - 40 -60 year men and women
- localized/limited involvement to extensive involvement at multiple sites
- oral cavity - initial site 70%
- painful mucosal erosions and/or flaccid bullae involve oral/nasal mucosa





Pemphigus vulgaris

- Skin: scalp, face, axillae, groin
- round-to-oval bulla
- short duration
  - erosions & superficial ulcer
- Nikolsky sign - positive





Pemphigus vulgaris – genital

- generally occurs in patients with extensive involvement at other sites
- vulval lesions - 22-51% of cases
- labia majora > minora > vagina

- concurrently with other sites
- ***may occur when other sites in remission***
- ***rarely genital lesions can be sole manifestation***

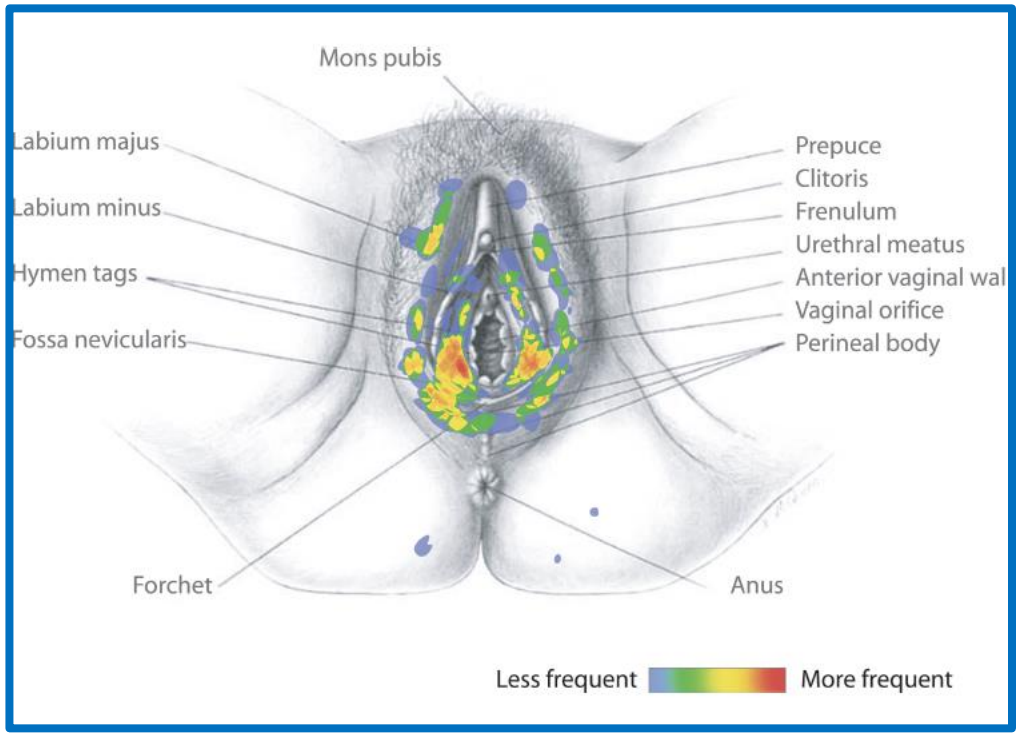

Pemphigus vulgaris – genital

- erosions and ulceration
- **intact blisters rarely seen at genital sites**
- usually non-itchy but can be burning and pain

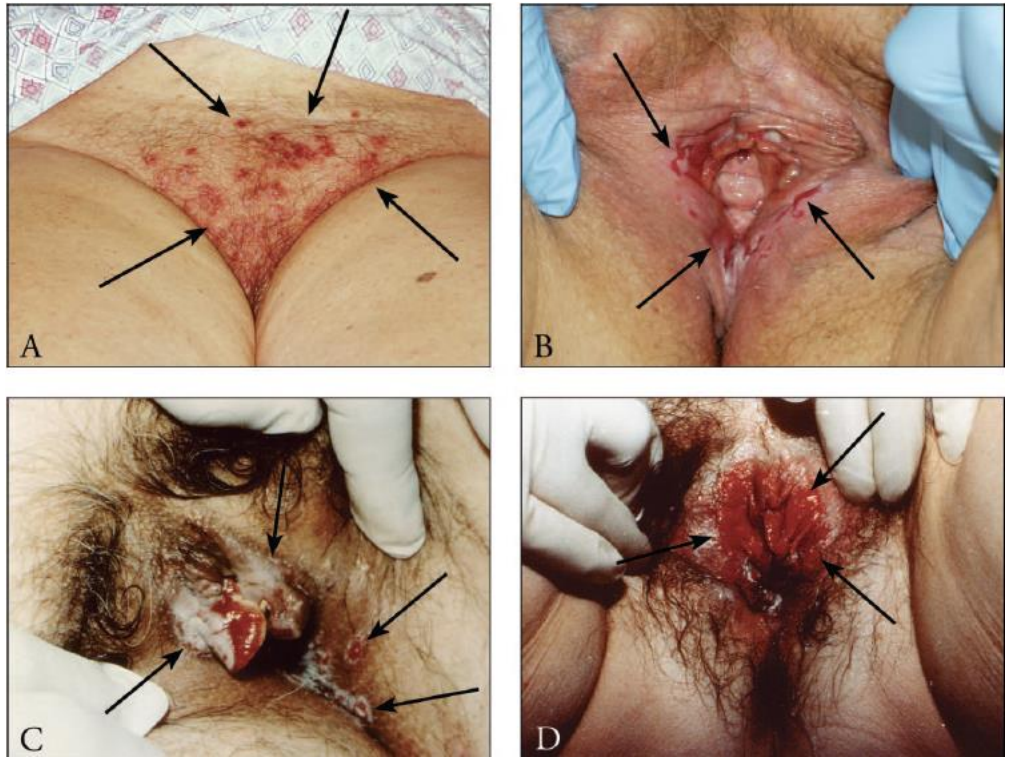

Pemphigus vulgaris - treatment

- before the advent of systemic corticosteroids, grave prognosis with a mortality rate of about 90%
- with the use of systemic corticosteroids and other immunosuppressive agents (cyclophosphamide, azathioprine, dapsone), the mortality rate is less than 10%

Pemphigus vulgaris - histology

- suprabasal clefting and acantholysis
- epidermis and adnexal epithelium
- tombstones – basal cells aligned to floor of blister
- no brightly eosinophilic dyskeratotic cells
- mild/moderate mixed inflammatory infiltrate superficial dermis
  - neutrophils
  - eosinophils

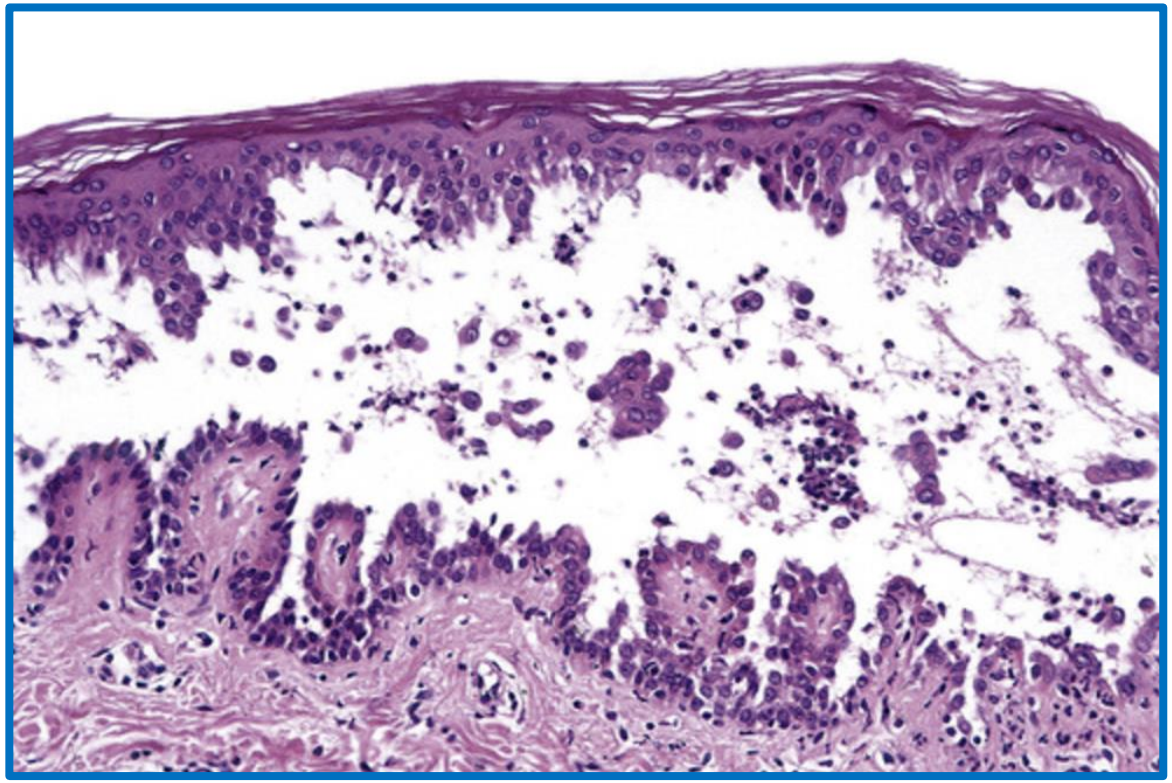

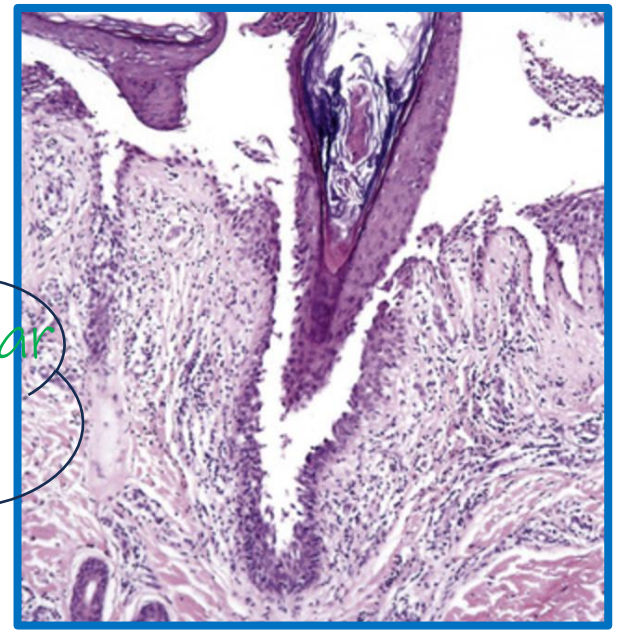

?involvement of follicular epithelium - think pemphigus or Darier

Pemphigus vulgaris

- autoantibodies directly damage desmosomes
- resultant keratinocyte separation and blister formation

- direct IMF
  - honeycomb pattern
  - intercellular IgG and C3

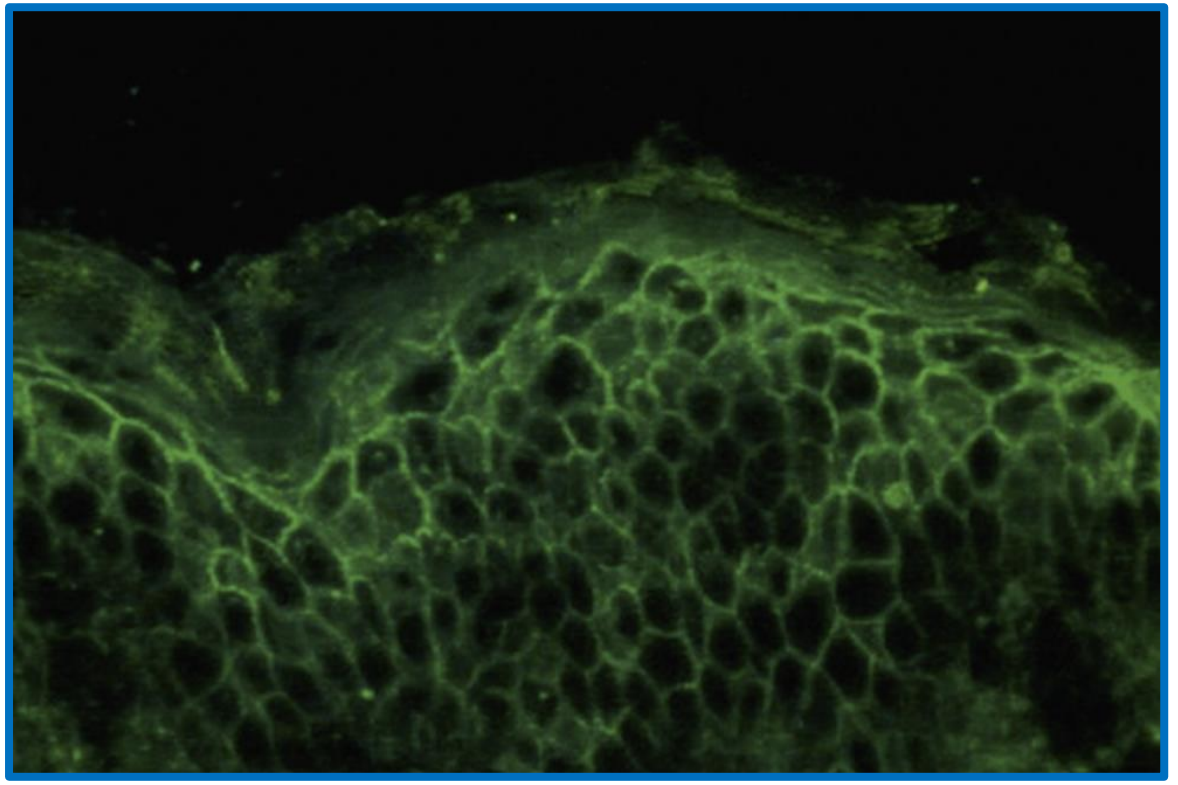

Acantholytic disorders affecting genital sites

- Immunobullous
  - **Pemphigus vulgaris**
    - **Pemphigus vegetans**
- Acantholytic dermatosis with dyskeratosis
  - **Darier**
  - **Hailey-Hailey**
- Other
  - **Acantholytic dermatosis of genitocrural area**
  - **Warty dyskeratoma**



Darier disease

- autosomal dominant
- typically presents puberty
- can appear in later life
- mutation in calcium pump protein, *ATP2A2*





- numerous hyperkeratotic papules over trunk
  - "sandpaper feel"
- seborrhoeic distribution (chest, neck, back, ears, groin) – diff dx seborrhoeic dermatitis
- frequently involves vulva
- odour
- worsened by heat, stress and sunlight
- palmar pitting
- thin dystrophic nails



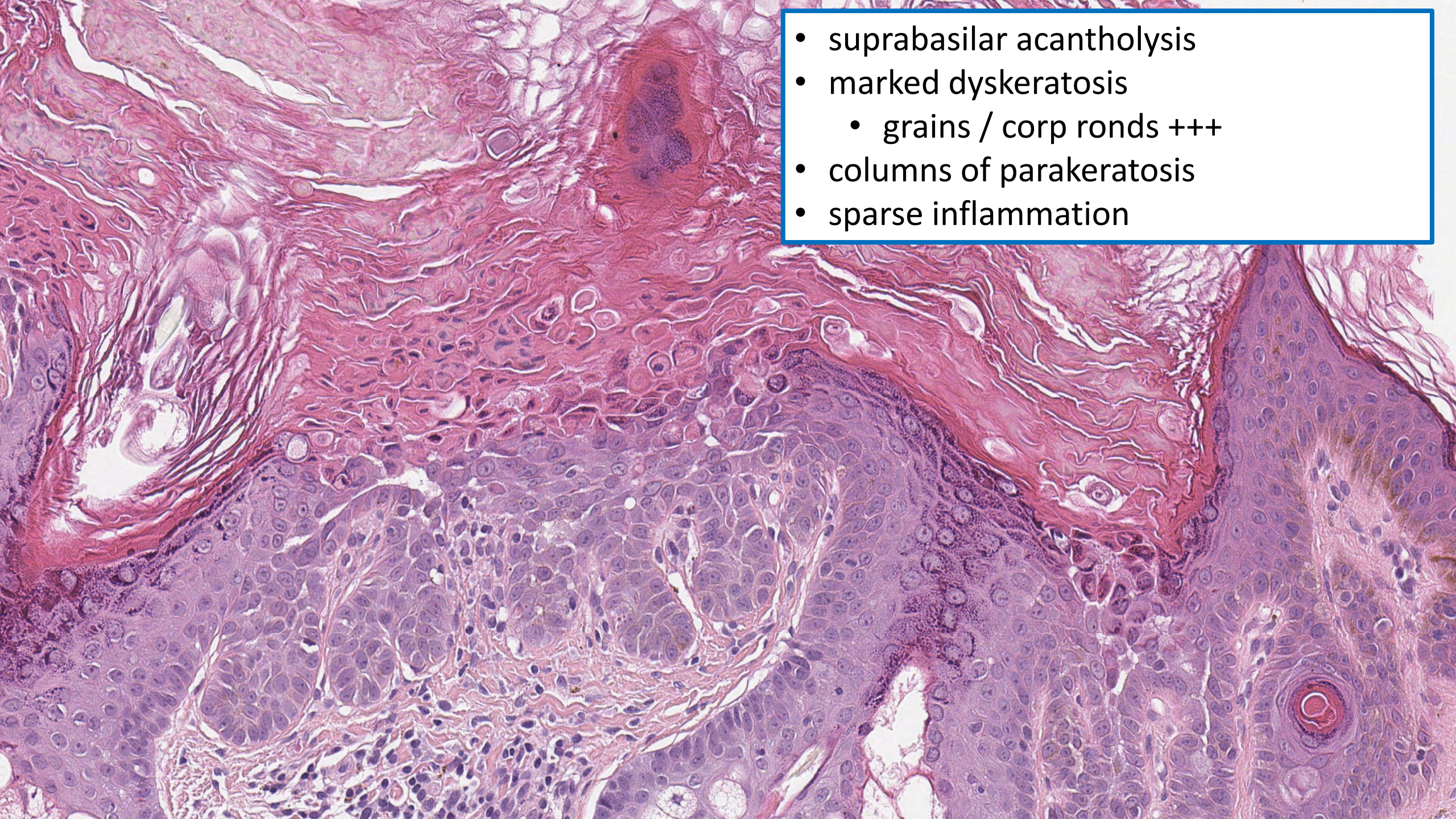
• suprabasilar acantholysis
• marked dyskeratosis
• grains / corp ronds +++
• columns of parakeratosis
• sparse inflammation

Hailey-Hailey disease

- *benign familial pemphigus*
- autosomal dominant
- mutation in calcium pump, *ATP2C1*
- weakened intracellular junctions
- typically presents in second to fourth decades
- tends to improve with age
- frequent remissions and relapses

Hailey-Hailey disease

- flexural and intertriginous zones
- neck, axillae, inframammary region, inguinal fold, perianal & genital region
- pruritic eruption initially that spread centrifugally
- crust with peripheral vesicles
- foul odour
- resolution with hypopigmentation but no scarring
- white streaks in nail in 70%

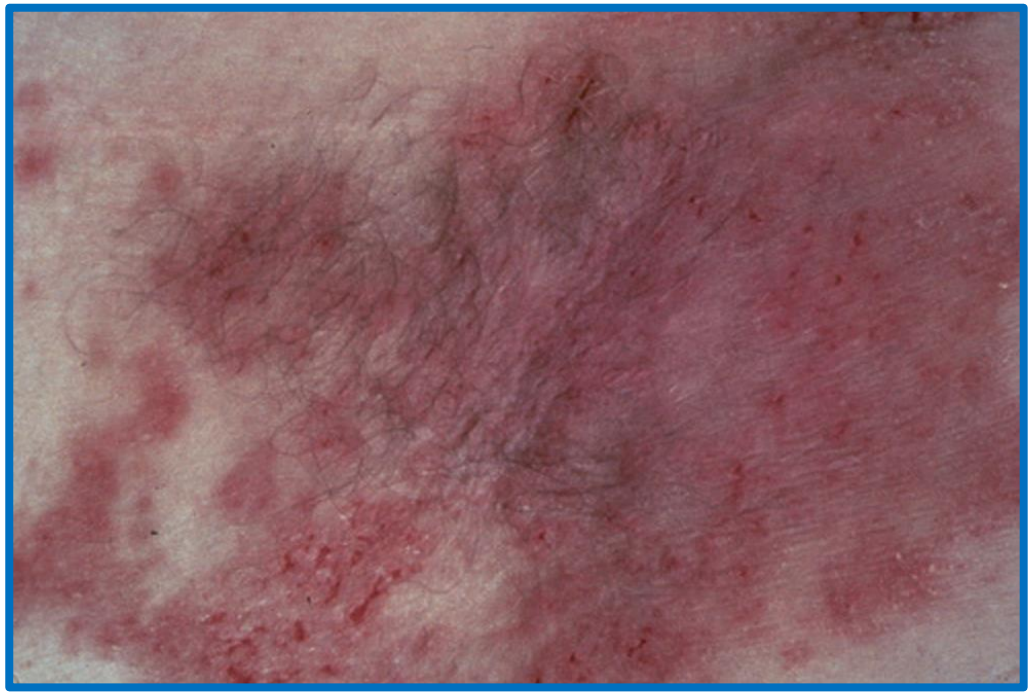




• diffuse intra-epidermal acantholysis
• typically involves, at least, half of epidermis above suprabasilar cleft
• ”dilapidated brick wall”
• typically mild dyskeratosis
• few corps ronds and grains
• marked surface crust
• acanthosis

- early lesions can mimic spongiotic dermatitis

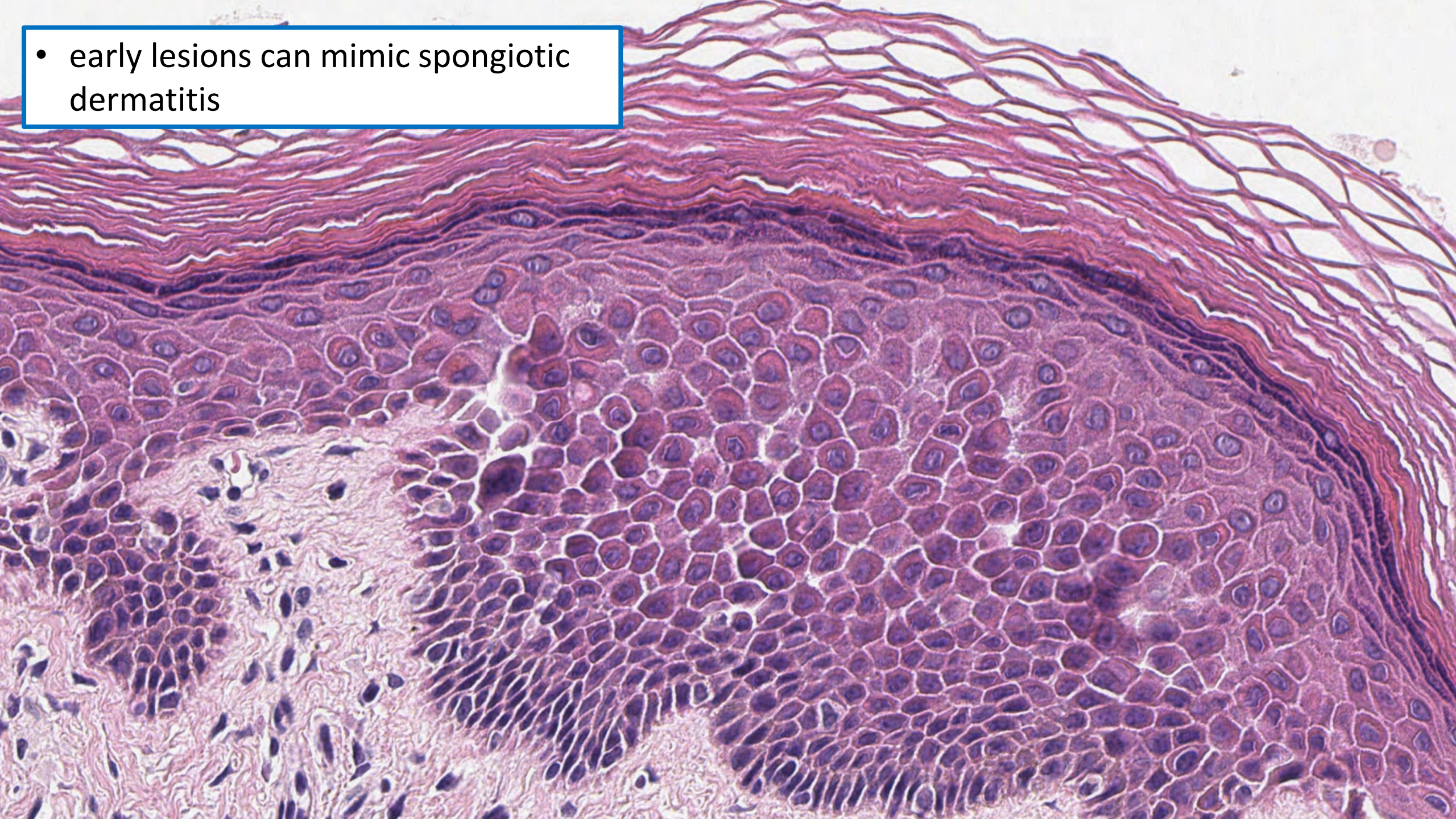

Acantholytic disorders affecting genital sites

- Immunobullous
  - **Pemphigus vulgaris**
    - **Pemphigus vegetans**
- Acantholytic dermatosis with dyskeratosis
  - **Hailey-Hailey**
  - **Darier**
- Other
  - **Acantholytic dermatosis of genitocrural area**
  - **Warty dyskeratoma**



Acantholytic dermatosis of the genitocrural area

- *Papular acantholytic dyskeratosis of the vulva/vulvocrural area & papular genitocrural acantholysis*
- isolated phenomenon on the genitocrural region
- by definition, no evidence of similar lesions elsewhere on the body

- predominantly in young or middle-aged females
- solitary or grouped white papules vulva & perianal area
- may extend to thigh & perineurium
- less commonly white plaques

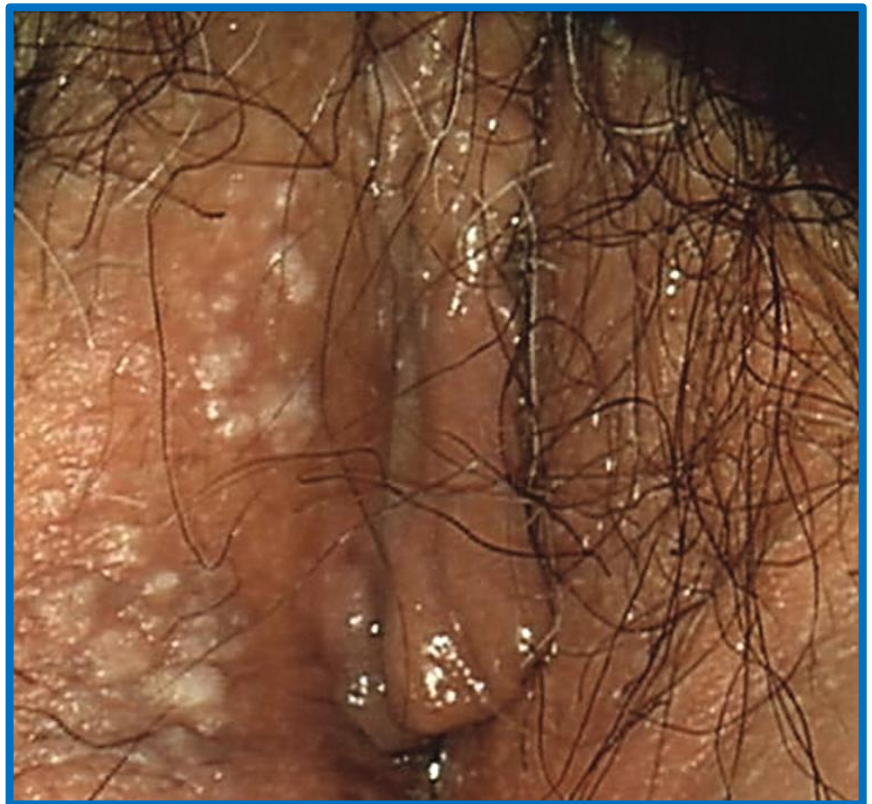





Acantholytic dermatosis of the genitocrural area

- Aetiology – unknown
  - ?moist environment plays a role
  - ?infection play a role
  - ?genetic mosaicism – localized variant of Darier or Hailey Hailey

- acantholysis +/- dyskeratosis (typically focal)
- typically minimal or no inflammation
- DIF is negative

- **Consider if eruptive genitocrural papules –**
  - **acantholysis / dyskeratosis on histology**
  - **no lesions elsewhere**
  - **negative DIF**

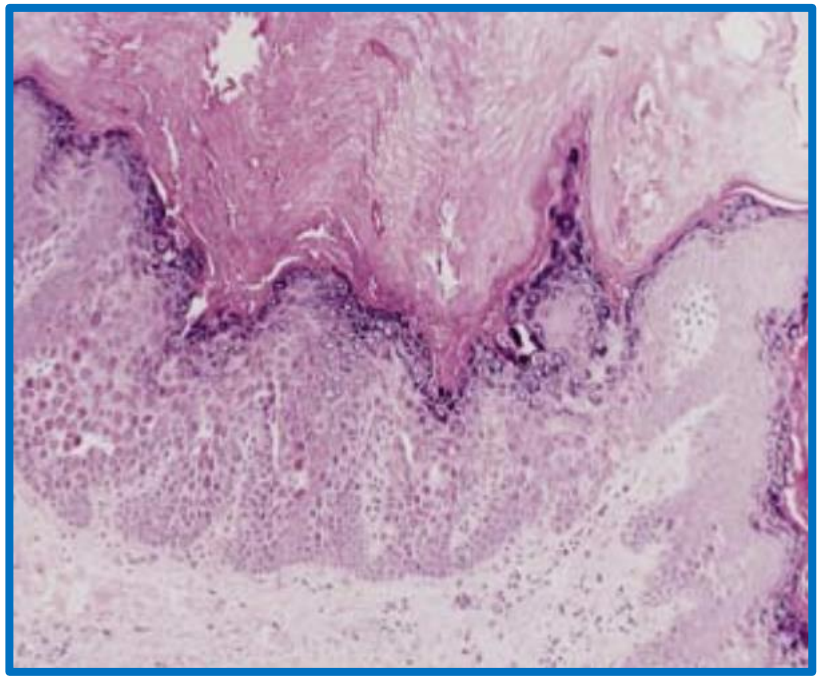

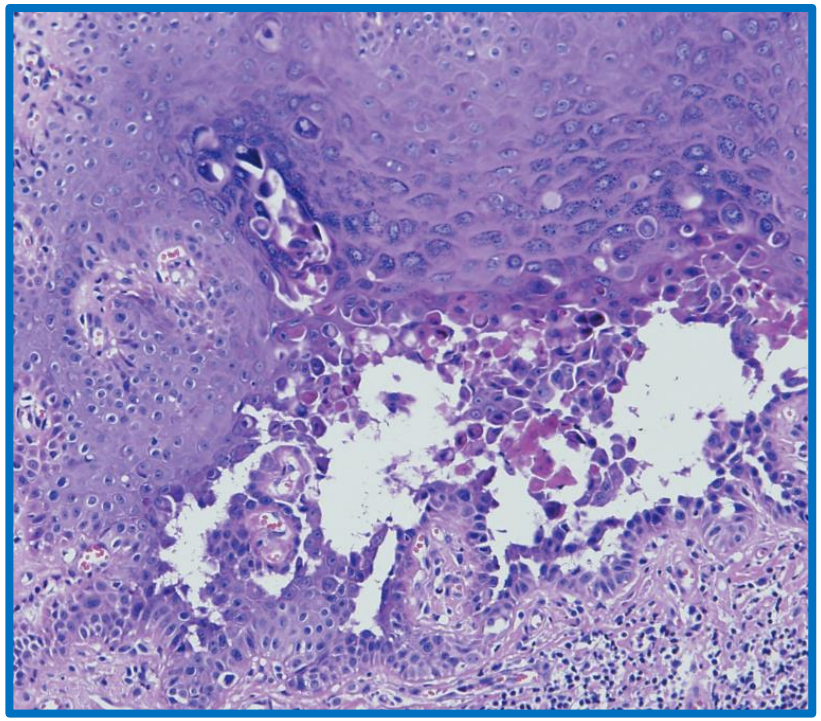

Warty dyskeratoma

- **solitary** persistent nodule
- hyperkeratotic & umbilicated
- head and neck of middle-aged adults
- can occur on genital sites
- warty dyskeratoma with a cystic presentation has also been described in the vulva

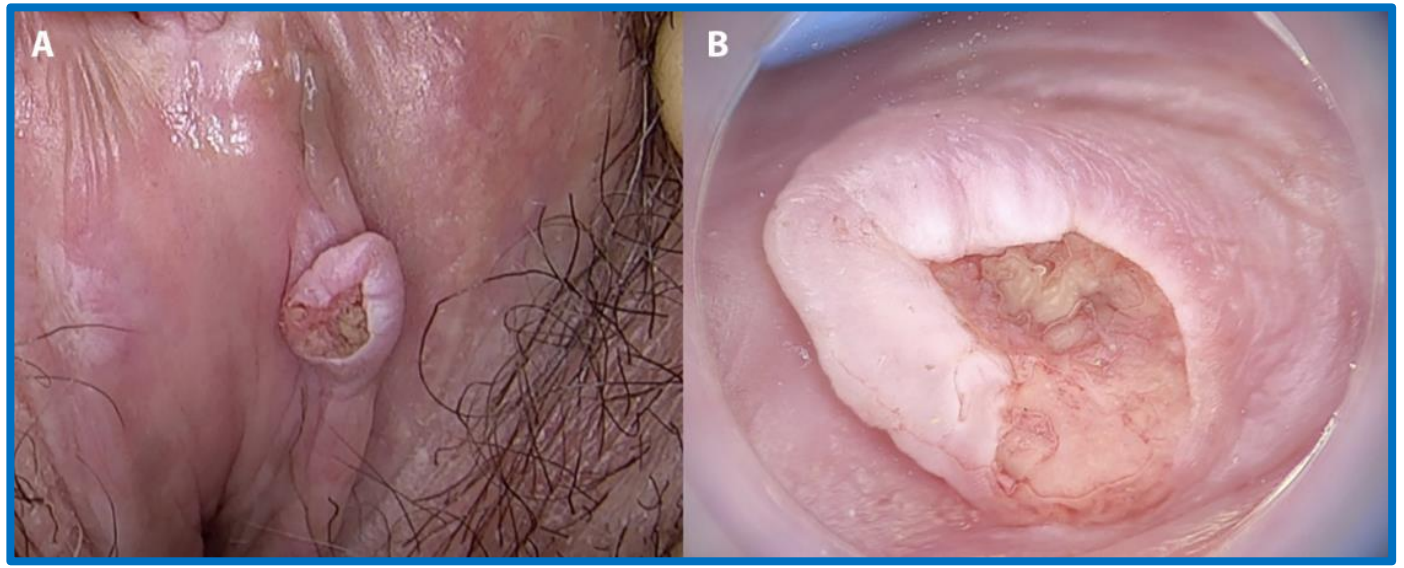



Warty dyskeratoma

- circumscribed keratin-filled

"cup-shape" invagination

- acantholysis and suprabasal clefting
- dyskeratosis prominent
- dermal papillae may protrude within the suprabasal clefts

- ***single lesion, not a rash***

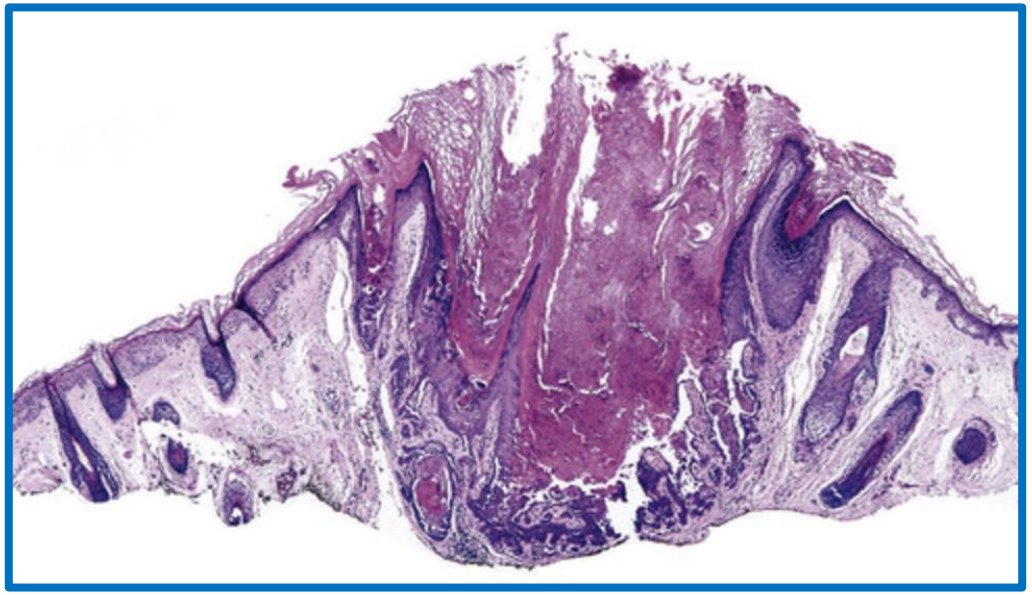

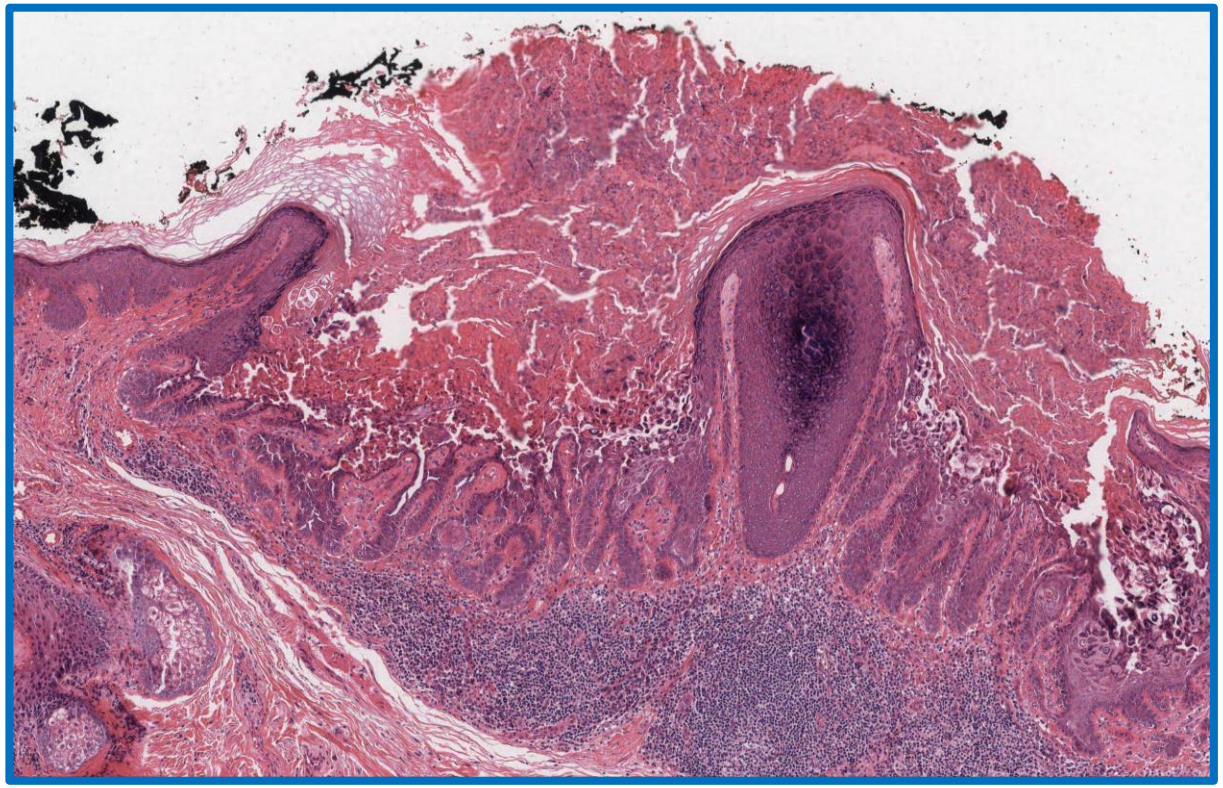

Summary & key points

- case of pemphigus vegetans
  - rare subtype of pemphigus vulgaris
  - large vegetative plaques
  - genital involvement common
- high index of suspicion
  - acantholysis typically focal/mild
  - epidermal hyperplasia with microabscess
  - perform IMF (IgG and C3)

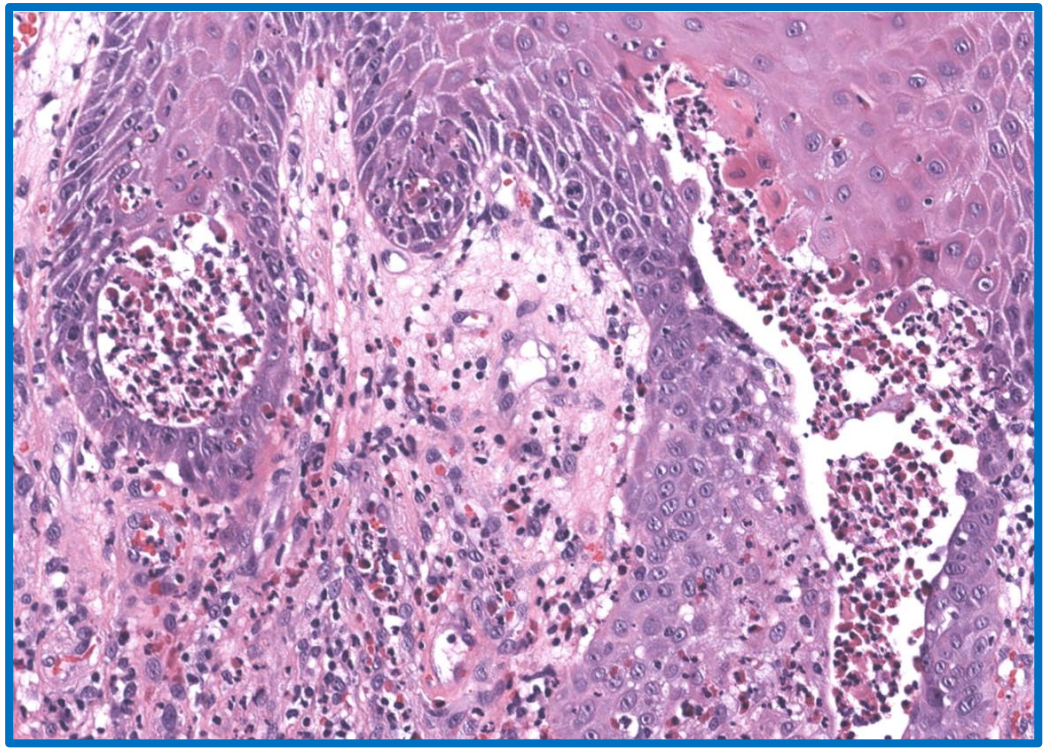

Summary

- reviewed acantholytic disorders affecting genital sites
  - ?acantholysis
  - ?dyskeratosis
  - ?IMF positive or negative
  - correlate with clinical picture

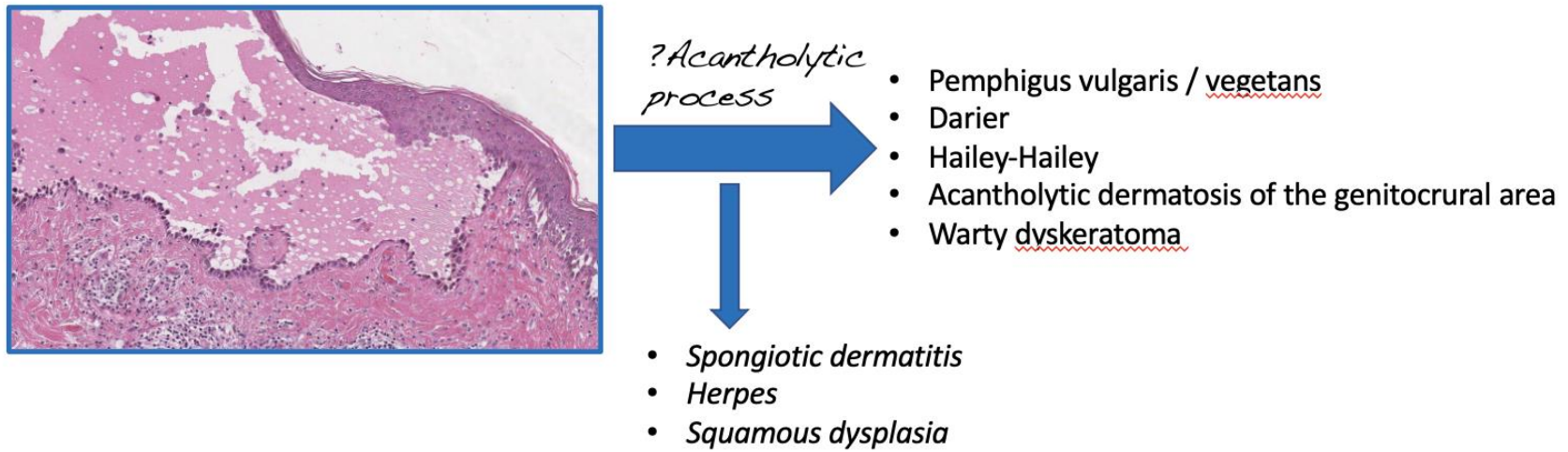

References

- Kuriachan, Diana, Suresh, Rakesh, Janardhanan, Mahija, Savithri, Vindhya, Oral Lesions: The Clue to Diagnosis of Pemphigus Vulgaris, *Case Reports in Dentistry*, 2015, 593940, 3 pages, 2015.
- Dessinioti, E. Soura, C. Kittas, C. Antoniou, White papules on the anogenital area, *Clinical and Experimental Dermatology*, Volume 39, Issue 6, 1 August 2014, Pages 766–768,
- Roh MR, Choi YJ, Lee KG. Papular acantholytic dyskeratosis of the vulva. J Dermatol. 2009 Jul;36(7):427-9.
- Kerr PE, Murphy MJ. Warty (follicular) dyskeratoma on the mons pubis. Int J Womens Dermatol. 2017 Jul 26;3(3):154-156. doi: 10.1016/j.ijwd.2017.07.003. PMID: 28831426; PMCID: PMC5555285.
- Calonje, J., E. et al. *McKee's Pathology of the Skin*. Elsevier eBooks+, (5th Edition). Elsevier - OHCE, 2019
- Hoang MP, Selim MA, et al. Vulvar Pathology. Springer. 2015.
- Biswas A. Inflammatory dermatopathology. Cambridge. 2020.
- *CED (2016) 41, pp312–327*
- *JDDG;2010 • 8:179–183*
- *Ann Dermatol 23(S3) S310∼S313, 2011*
- *Actas Dermosifiliogr. 2018;**109(10)**:920*
- Vaccari S, Rapparini L, Misciali C, Dika E. Vulvar Acantholytic Warty Dyskeratoma. Dermatol Pract Concept. 2024;14(2):e2024124.
- Evruke I, Ugurlucan FG, Erdem BY, Sari SO. Diagnosis and management of vulvar Darier disease: A case report. Case Rep Womens Health. 2023 Sep 16;39:e00545.

Thank you