The British Association of Gynaecological Pathologists

21st Annual Meeting in Collaboration with ISGyP

5th and 6th June 2025

- Molecular integration into diagnosis of uterine sarcoma – a case presentation
- Katherine Vroobel
- The Royal Marsden Hospital
- 5th June 2025

The British Association of Gynaecological Pathologists

Speaker disclosures

I have no financial conflicts of interest to disclose

52F

Imaging: 15cm lesion massively expanding the uterus

Hysterectomy + BSO

Macro: ill-defined cream myometrial lesion prolapsing into cavity

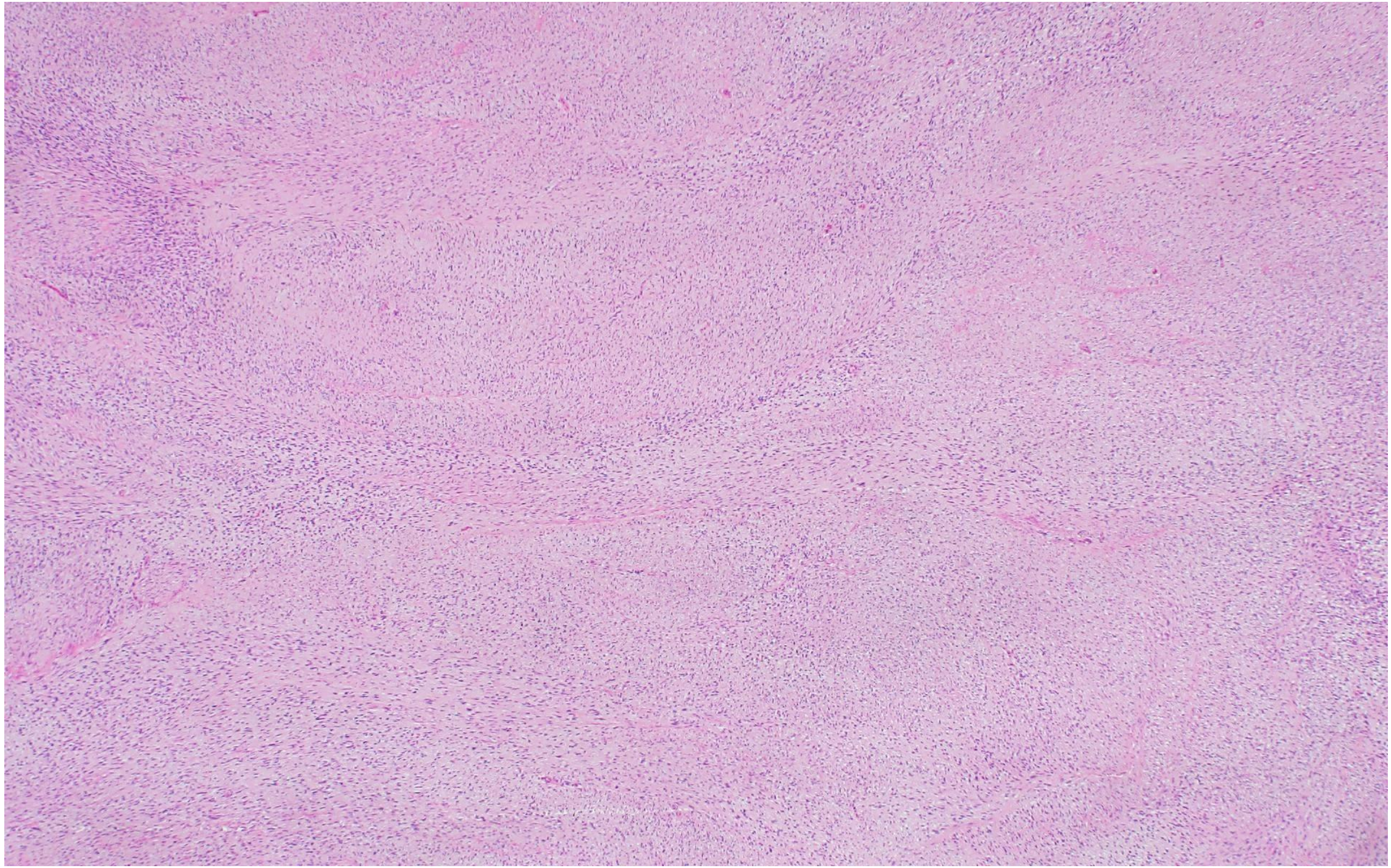

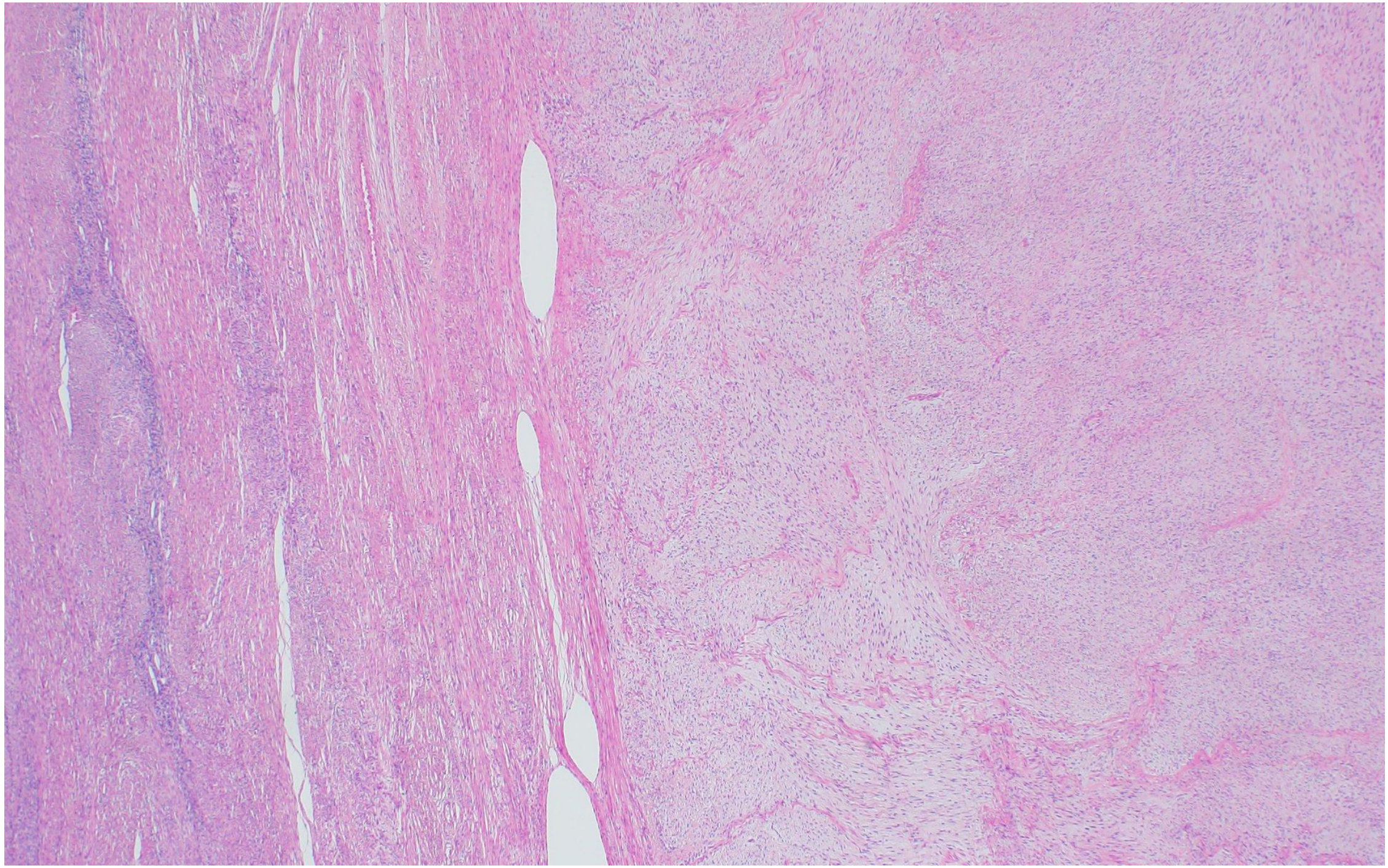

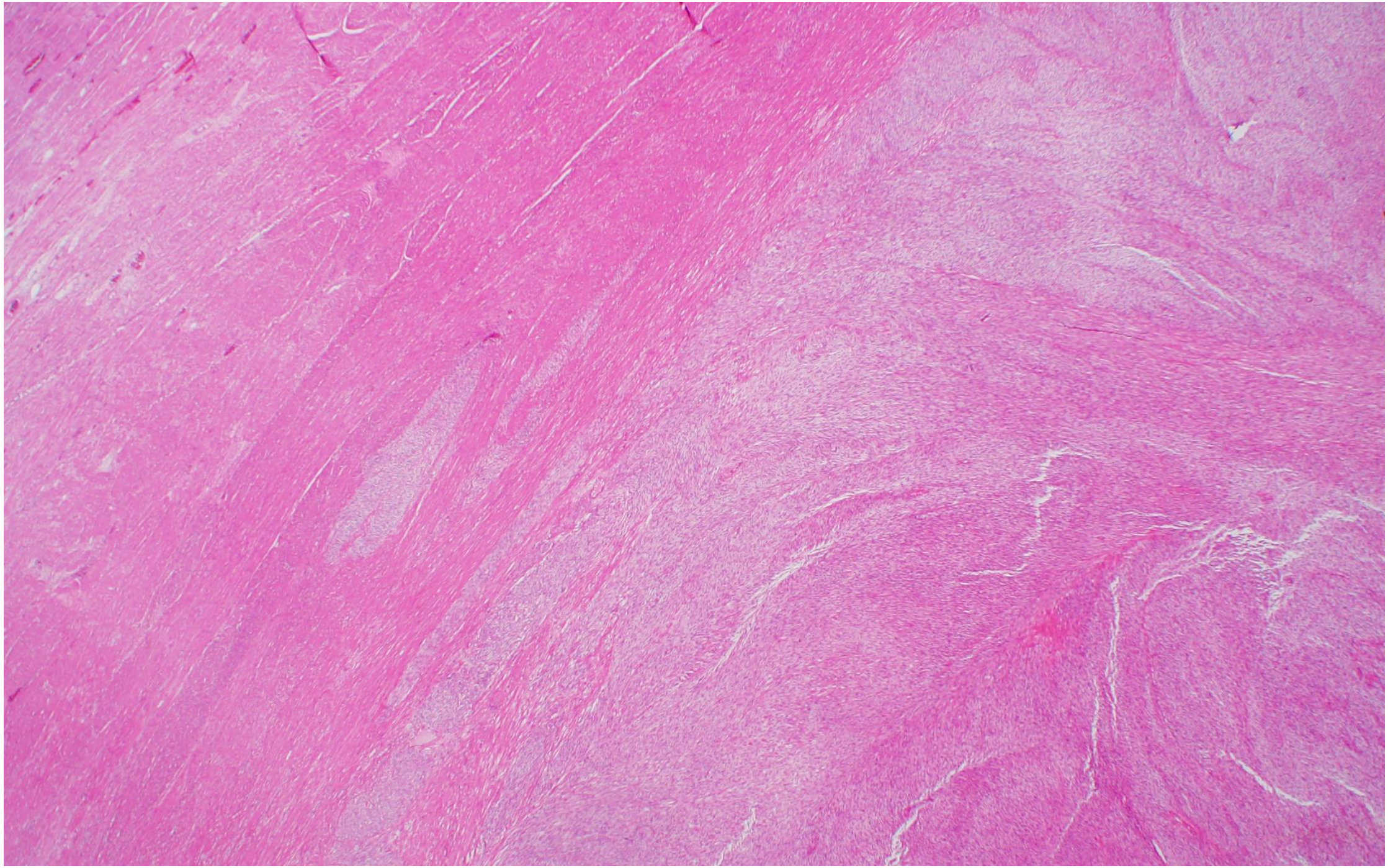

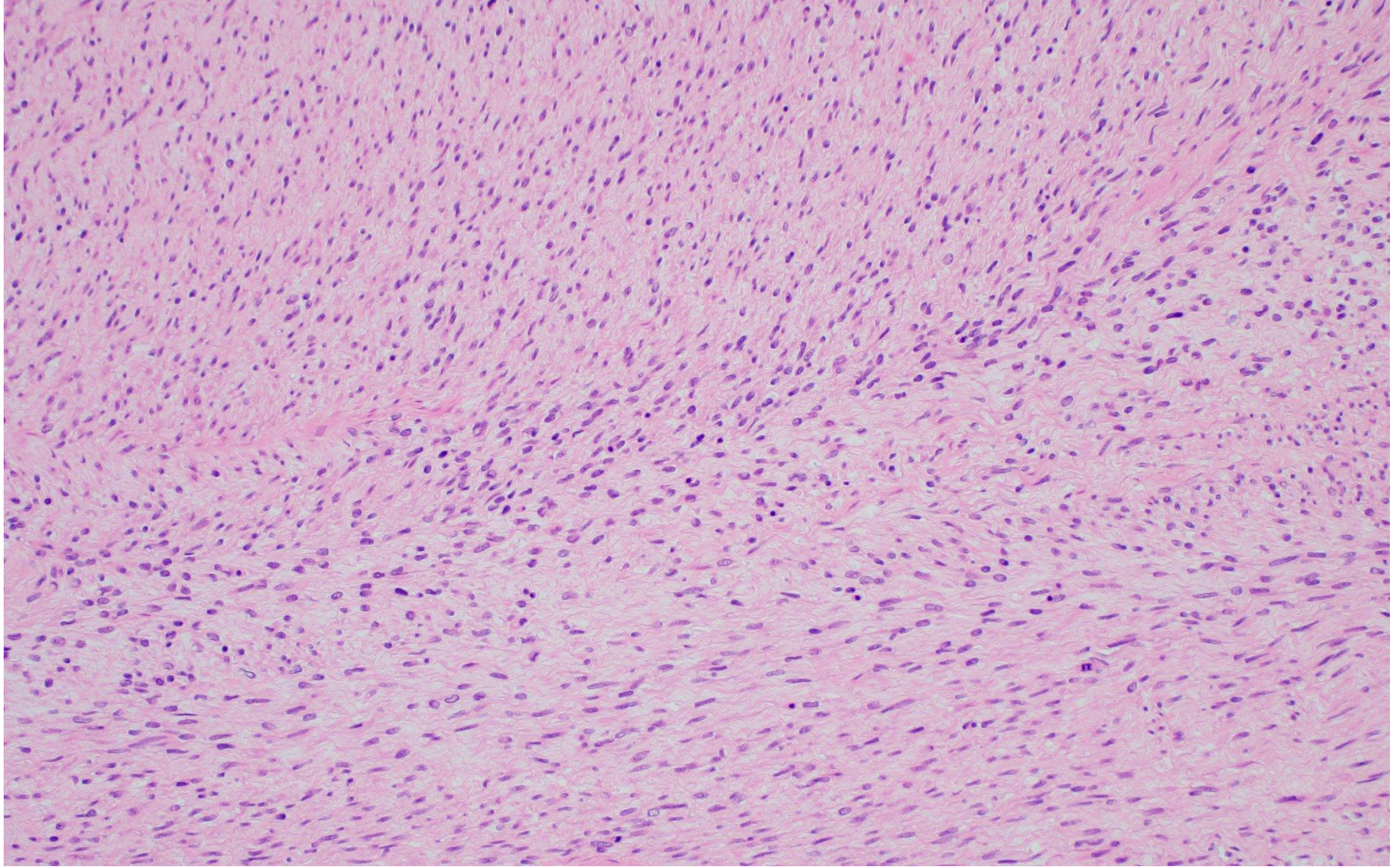

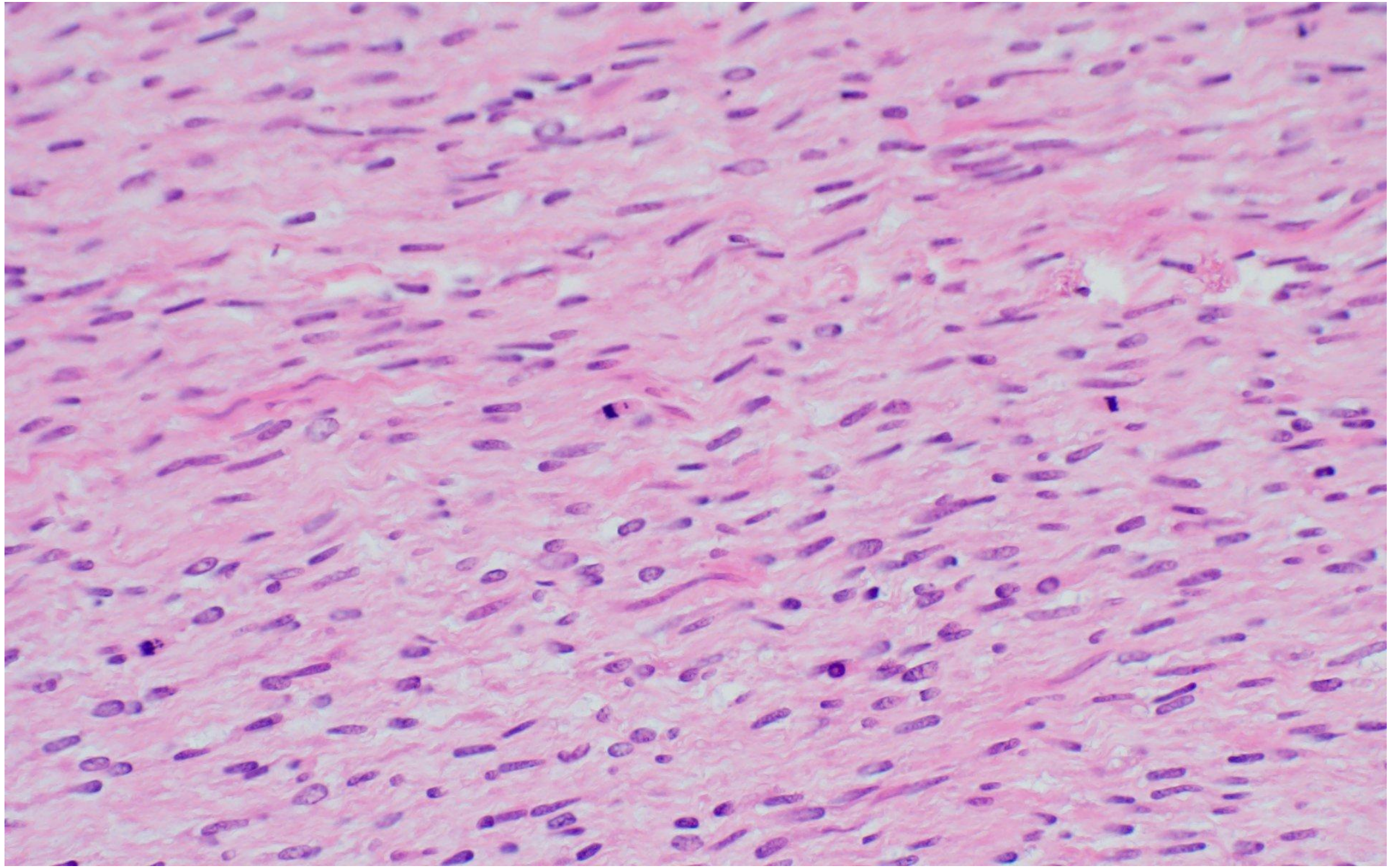

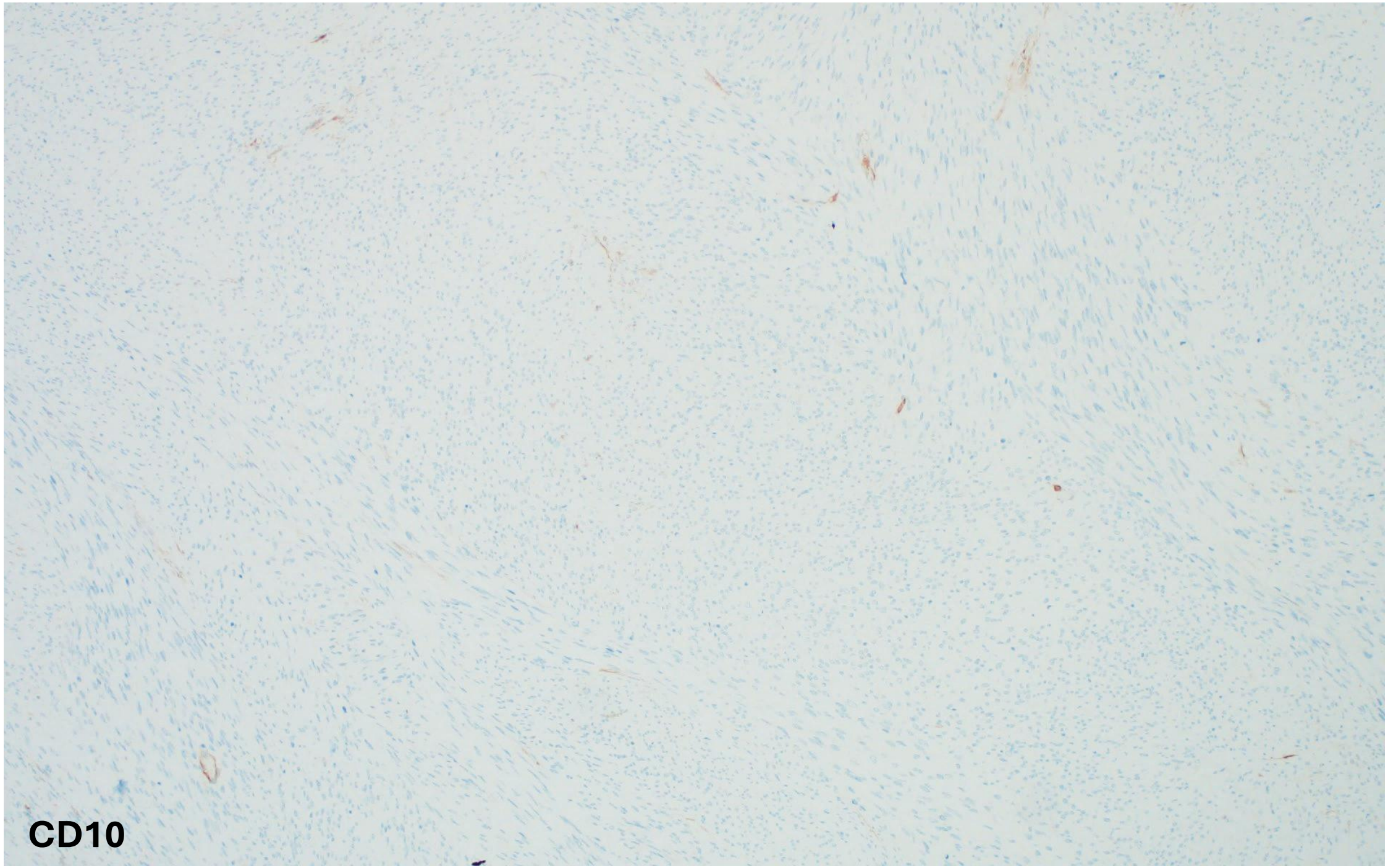
CD10

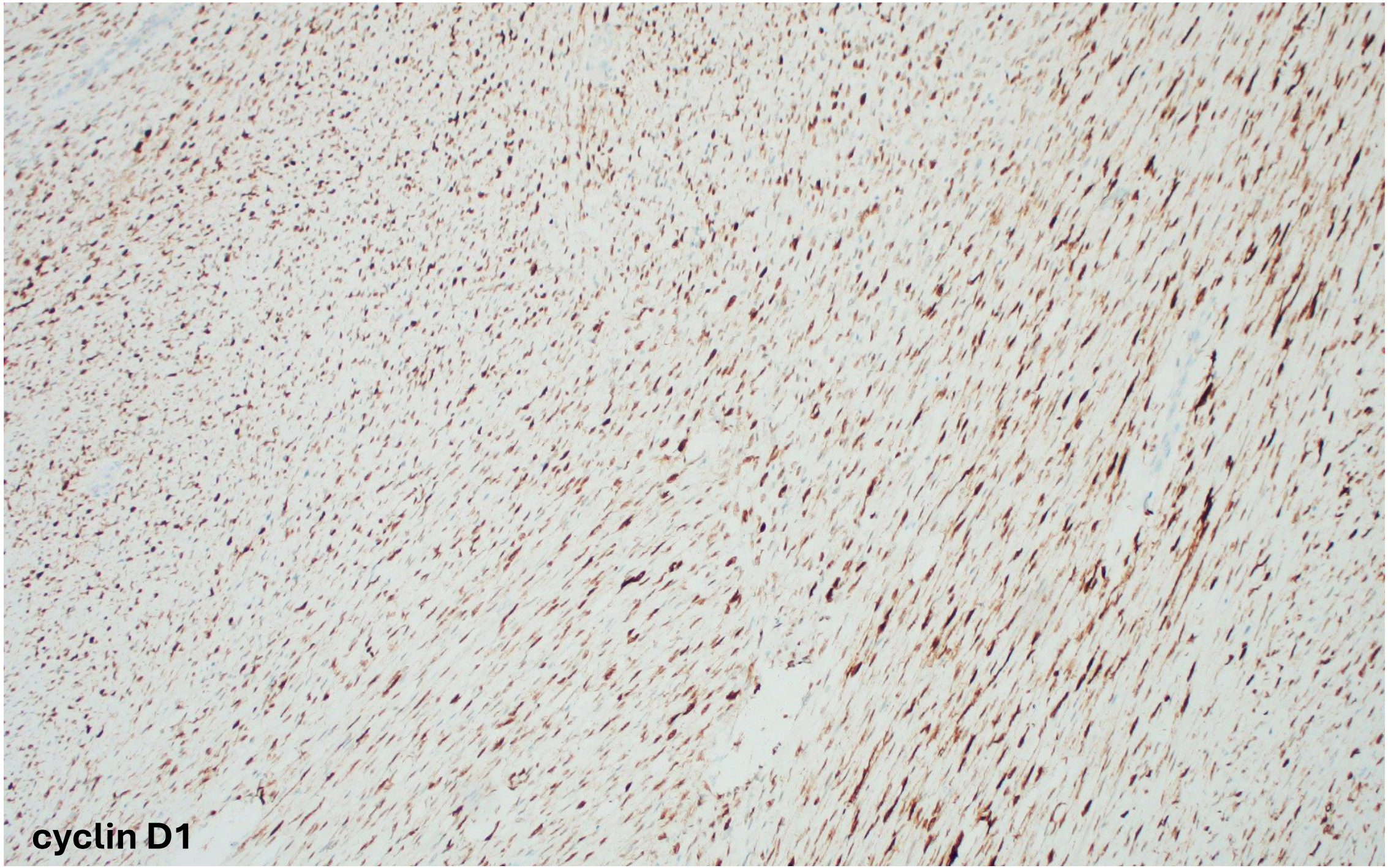
cyclin D1


ER

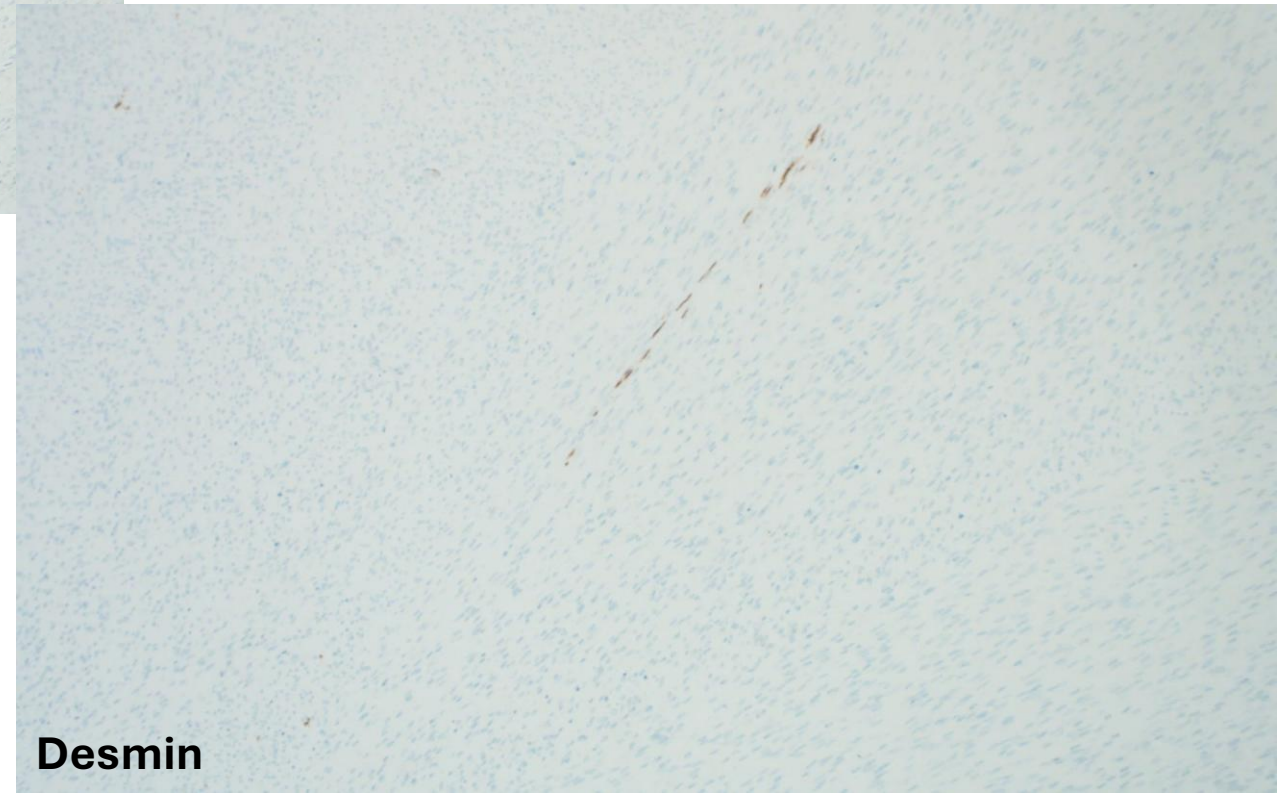
Desmin

Summary

- Uniform/monomorphic tumour
- No myxoid change
- No necrosis
- High mitotic rate (up to 21/10hpf)
- Very focal LVI (not pictured)
- IHC: positive for cyclin D1. Negative for smooth muscle markers/ER/CD10/WT1/CD34/CD117/melanocytic markers/ALK/BCOR
- Ki67 ~30%

Summary

- Uniform/monomorphic tumour
- No myxoid change
- No necrosis
- High mitotic rate (up to 21/10hpf)
- Very focal LVI (not pictured)
- IHC: positive for cyclin D1. Negative for smooth muscle bmarkers/ER/CD10/WT1/CD34/CD117/melanocytic markers/ALK/BCOR

Initial conclusion: High grade uterine sarcoma

RNA-based next-generation sequencing (Illumina Trusight)

EPC1::*KDM2B* fusion

Literature review

- At time of reporting, only one case of *EPC1*::*KDM2B* fusion described (Teramura *et al* 2020, PMID 32825119)
  - Spindle cell sarcoma of knee in 42F
  - “Low-grade spindle cell sarcoma with fibromyxoid stroma”

- Now one further reported case but in **low-grade** ESS (no further information provided, Dundr *et al* 2025 PMID 40419088)

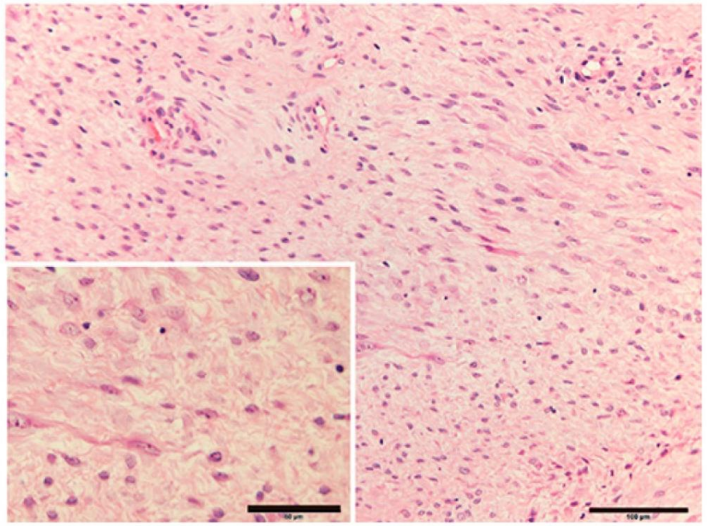

Significance and implications of this fusion

- *EPC1*
  - Part of histone acetyltransferase complex (epigenetic changes via histone acetylation)
  - Involved in fusions in both LG and HGESS
    - *EPC1*::*PHF1* – LGESS
    - *EPC1*::*EZH2* – whorling and collagen plaques suggestive of LGESS
    - *EPC1*::*SUZ12*, *EPC1*::*BCOR* – associated with high mitotic activity and necrosis
    - *EPC1*::*BCORL* – spindled cells, high mitotic rate
    - *EPC1*::*EED* – epithelioid morphology, necrosis, low mitotic rate

Significance and implications of this fusion

- *KDM2B*
  - Histone demethylase interacting closely with BCOR to enact epigenetic changes
  - Previously only reported in one instance of uterine sarcoma **with low-grade** morphology (*KDM2B*::*CREBBP*)
  - In soft tissue, appear indistinguishable from *BCOR* altered sarcomas (Motoi *et al* 2023, PMID 37634866)
  - In a subset of paediatric CNS tumours, those with *YWHAE*::*NUTM2* or *KDM2B* rearrangements had similar appearances to the *BCOR* ITD cases but clustered with extra-CNS sarcomas with *BCOR* ITD by DNA methylation (Tauziede-Espariat *et al* 2021, PMID 34717763)

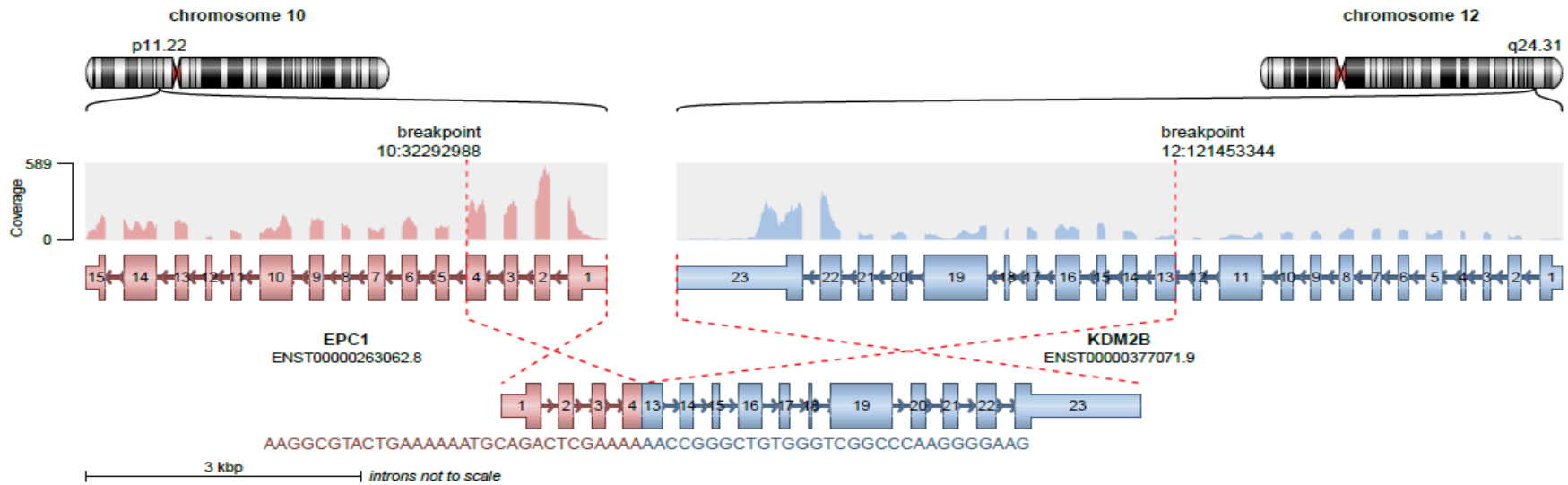

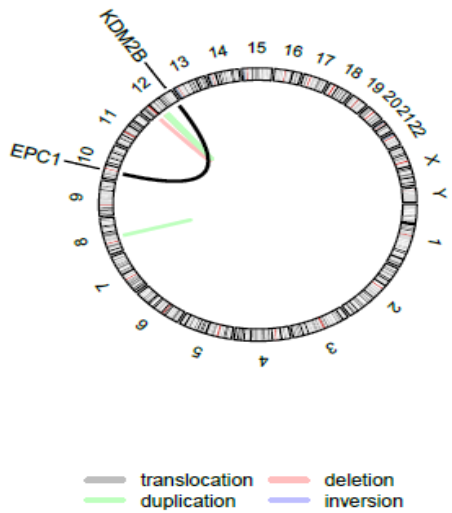

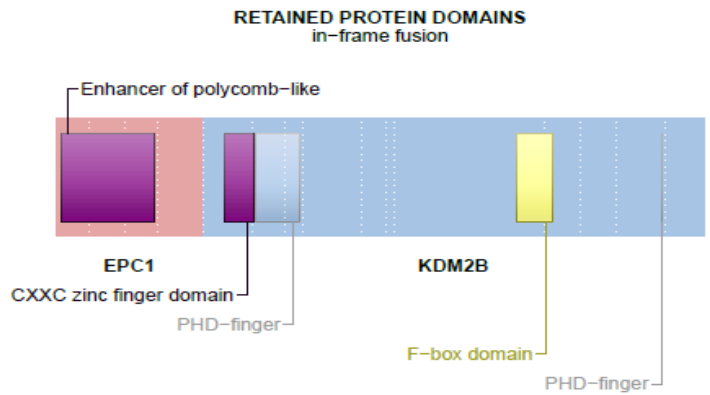

SUPPORTING READ COUNT

Split reads = 2
Discordant mates = 13

Final diagnosis

High-grade endometrial stromal sarcoma with *EPC1*::*KDM2B* fusion

Follow-up – 16 months later

12mm lesion left upper lobe of lung

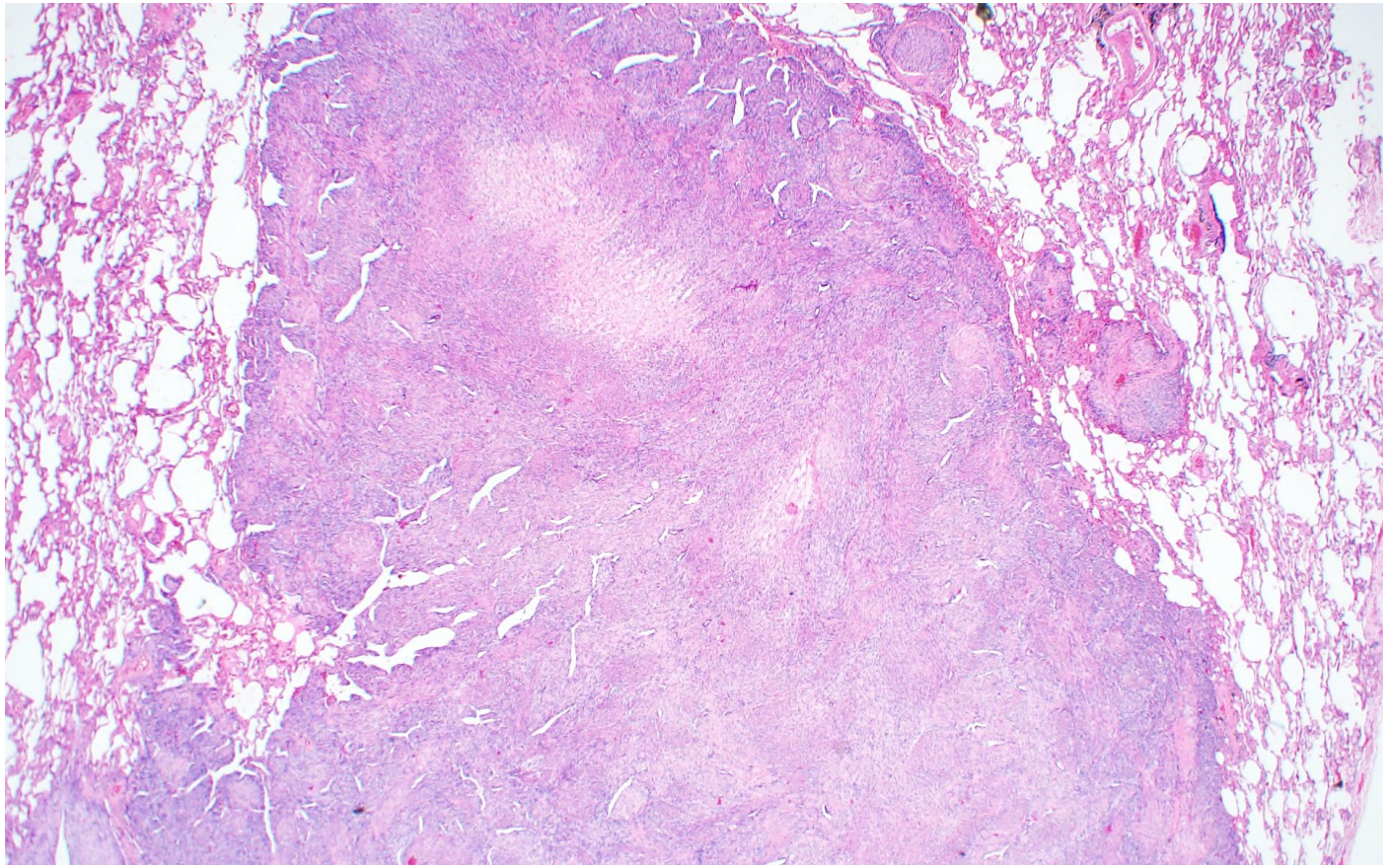

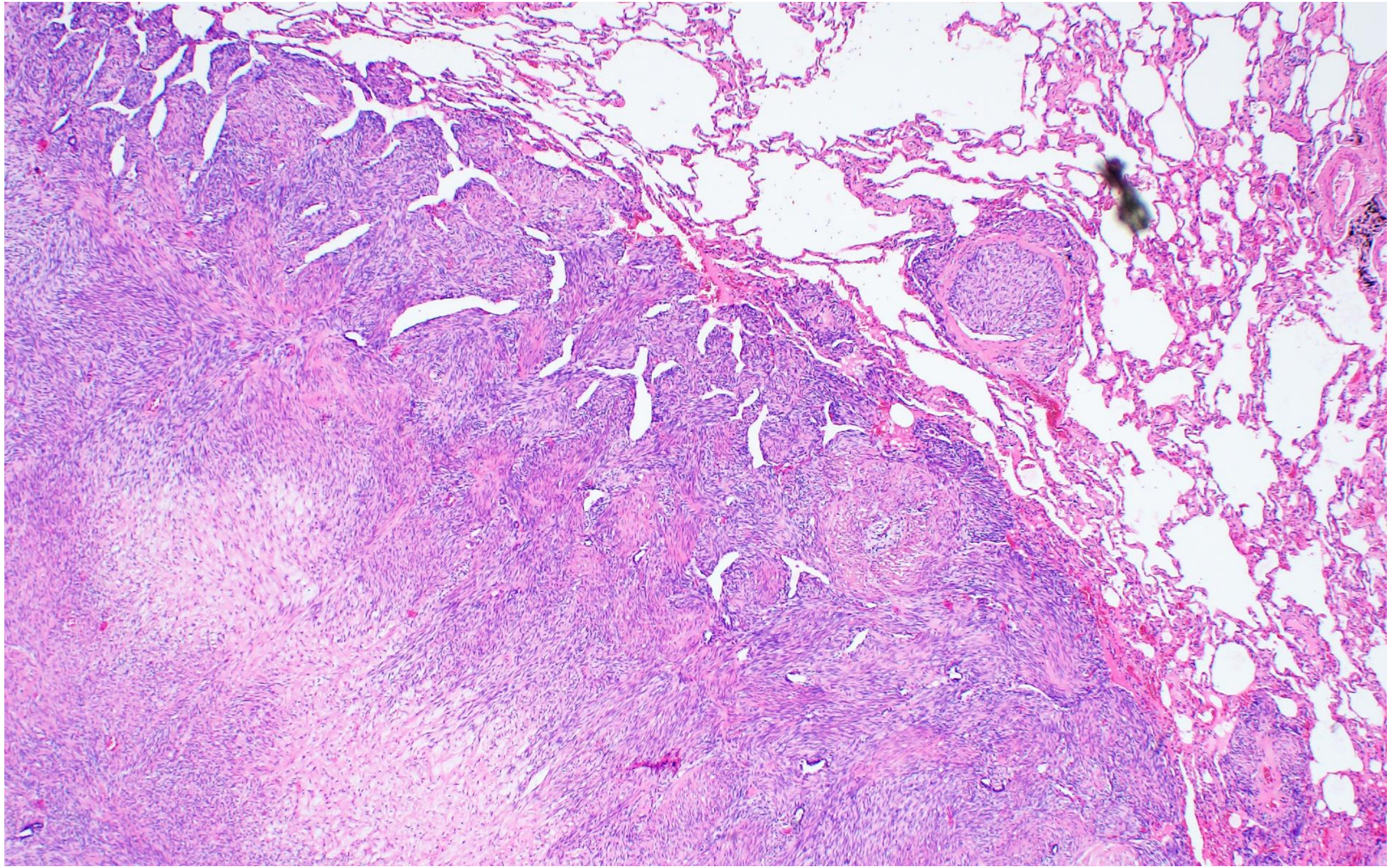

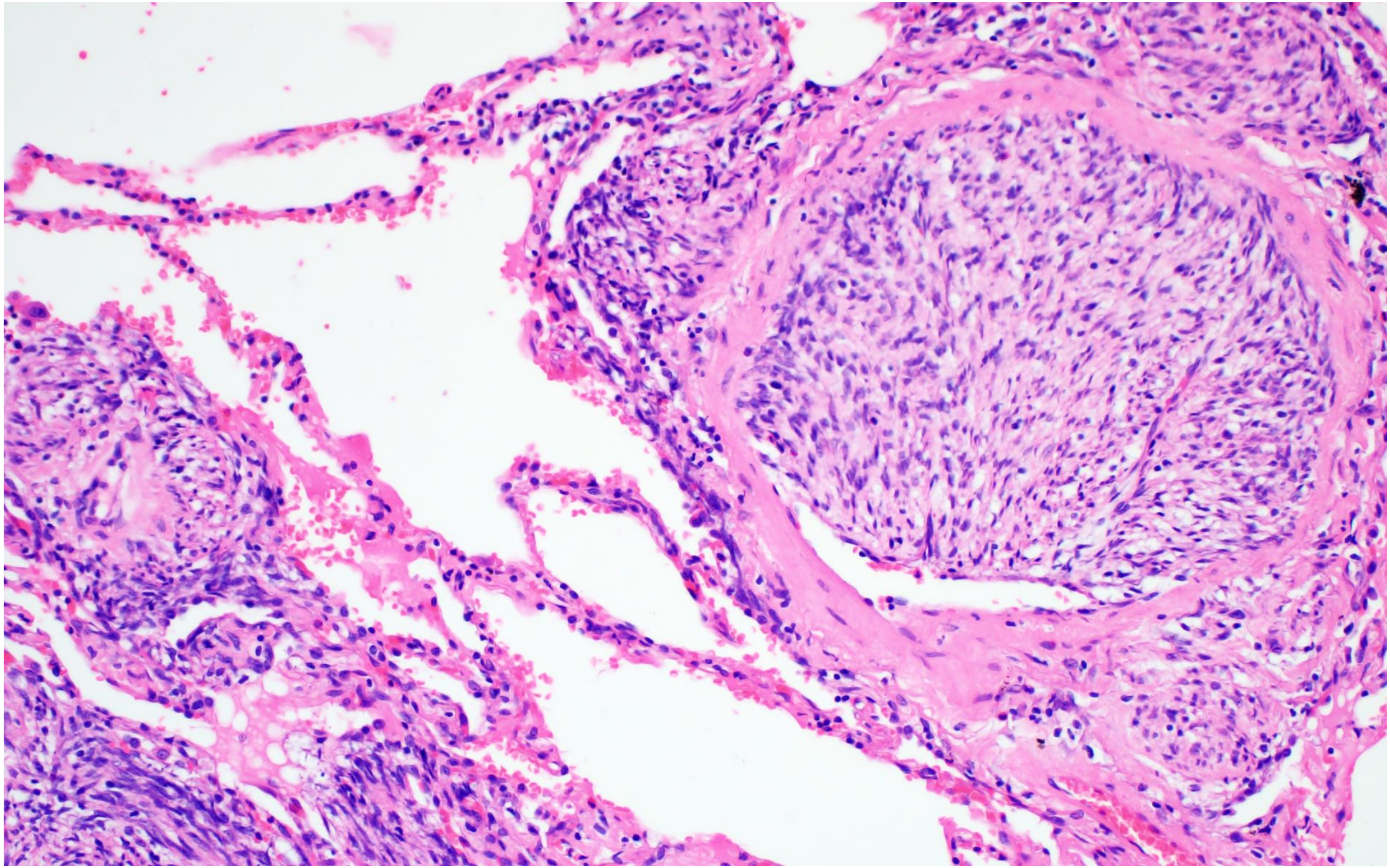

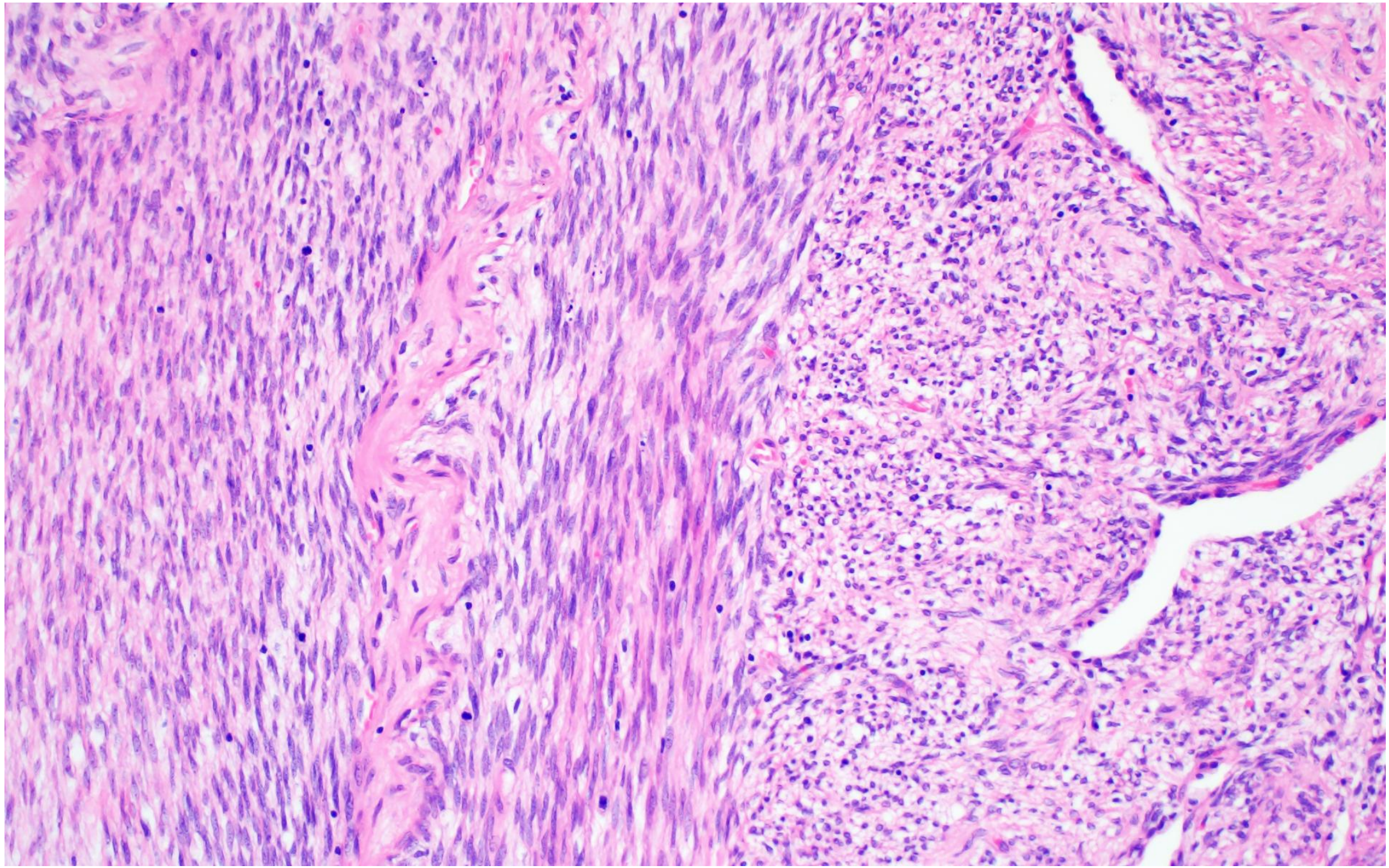

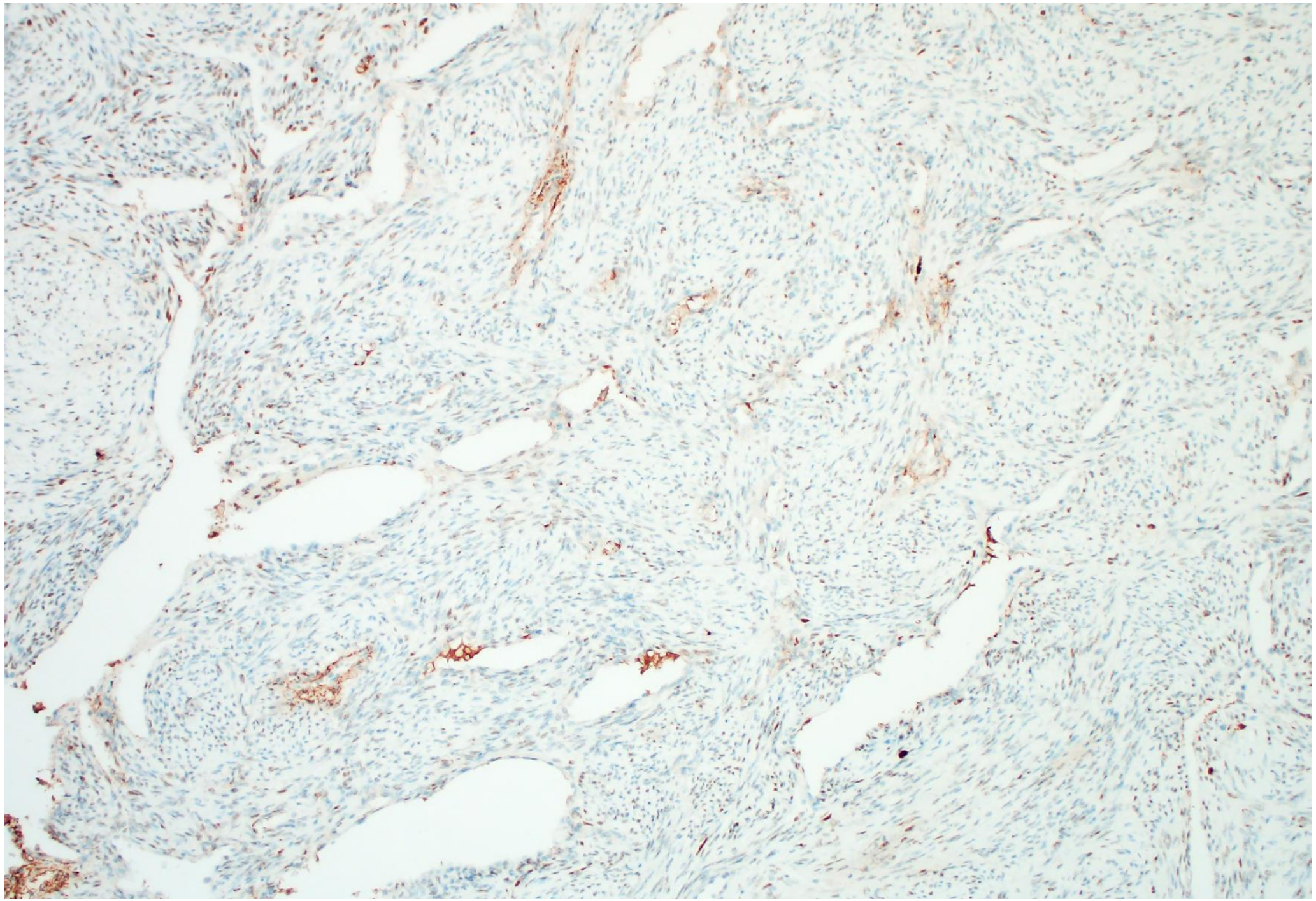

9 months after this

Omental and sigmoid deposits

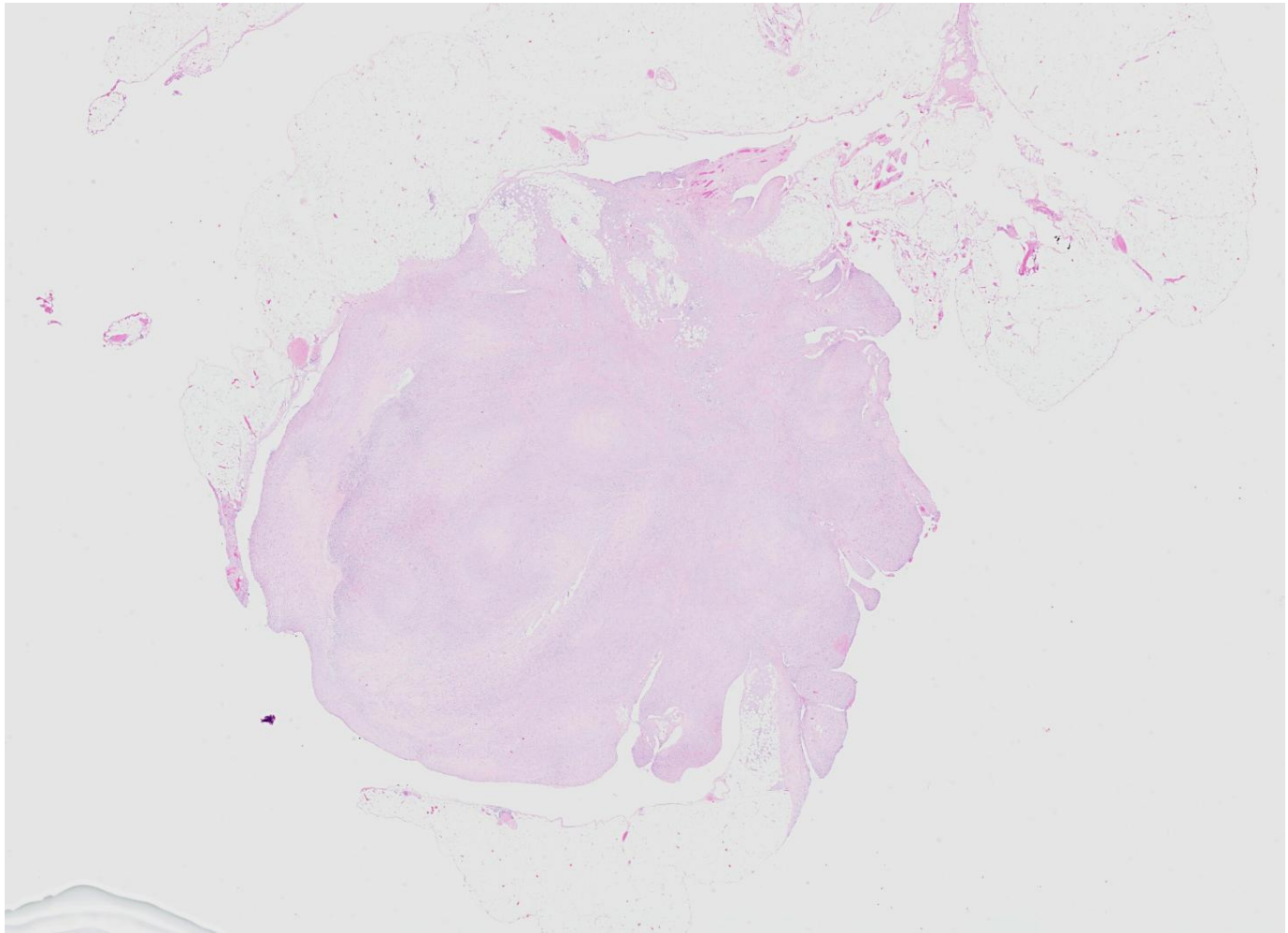

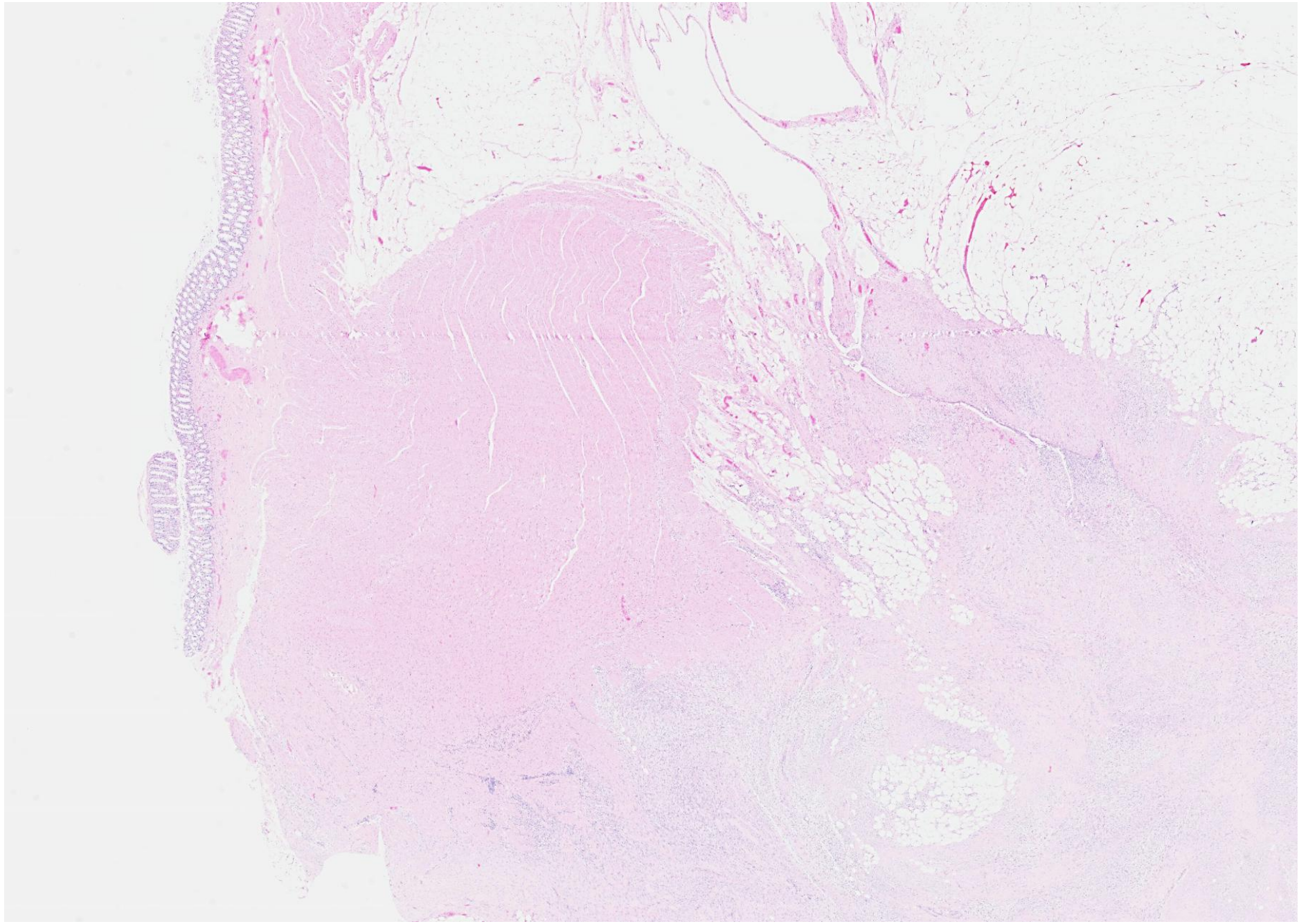

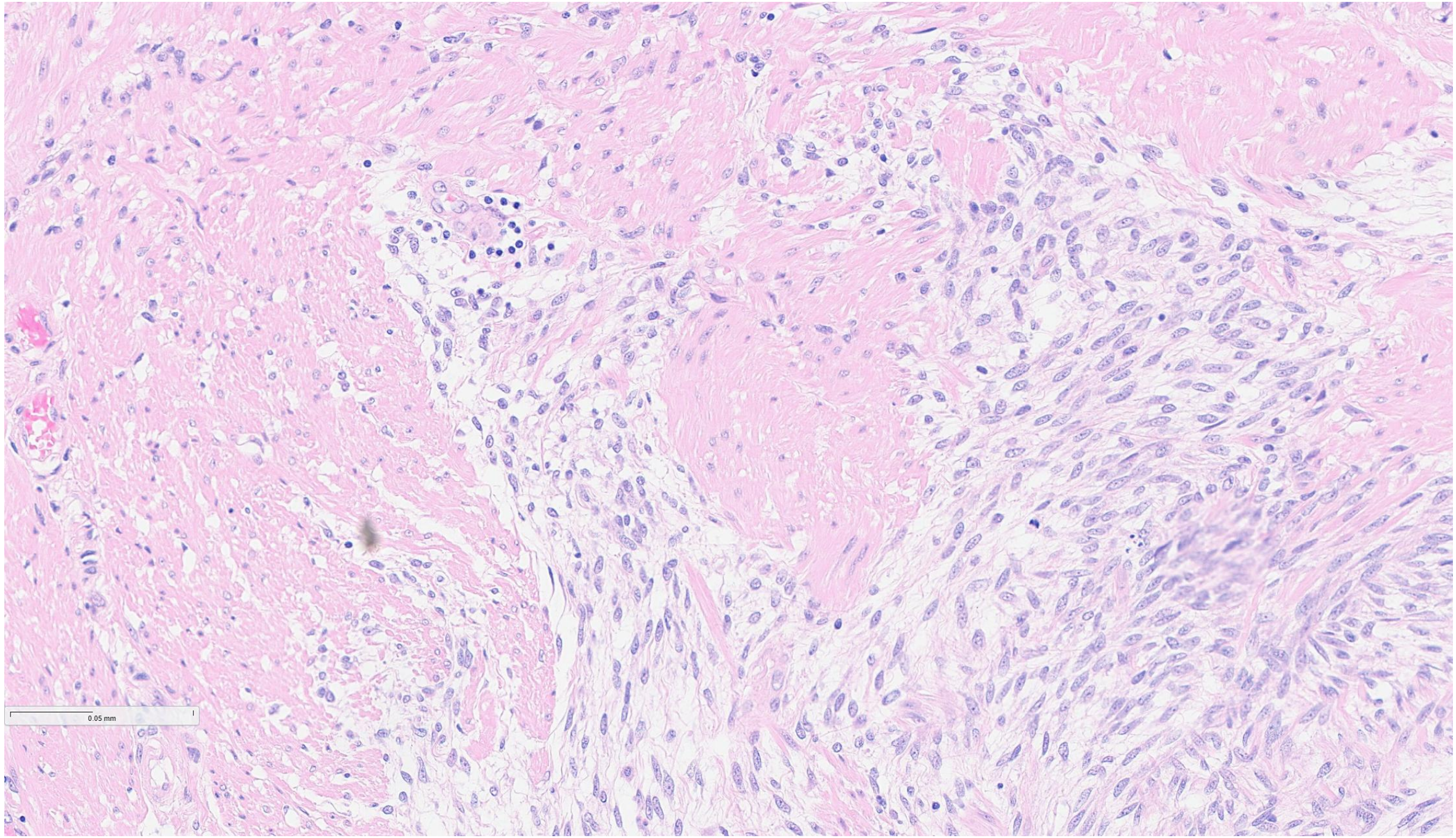
0.05 mm

Take home messages

- Rapid expansion in knowledge of molecular landscape of endometrial mesenchymal tumours
- Interpret molecular data in context of gene function, implications at other sites
- Integration of all clinicopathological aspects is crucial (morphology, molecular, behaviour).