The British Association of Gynaecological Pathologists

Manchester University NHS Foundation Trust

Mesenchymal Case Based Discussion

Dr Tom Pilkington, 5th June 2025

Clinical History

78F, endometrial biopsy

- PMB
- USS: 9.8cm fibroid, increased in size since last scan
- Friable tissue obtained from endometrium

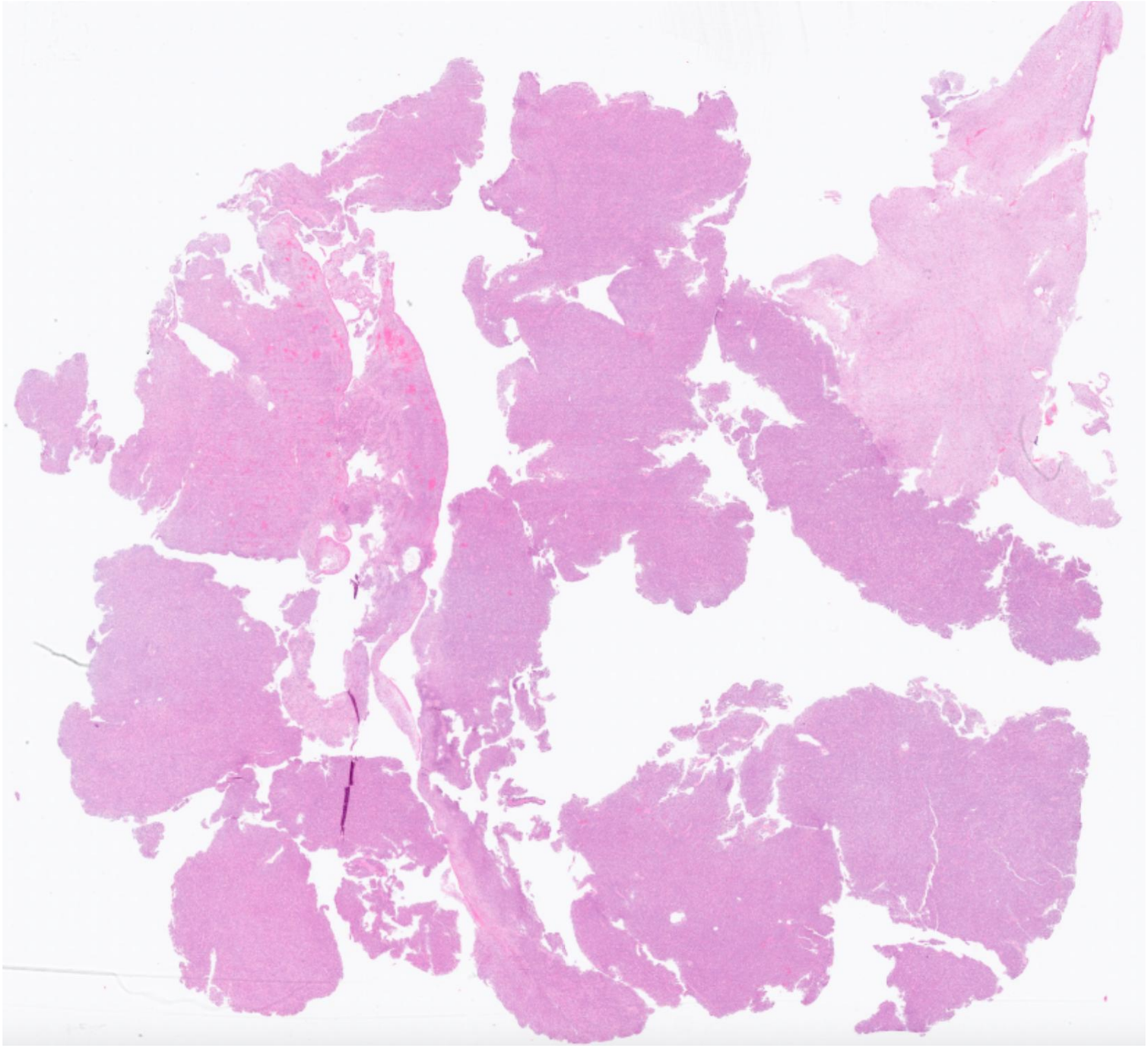

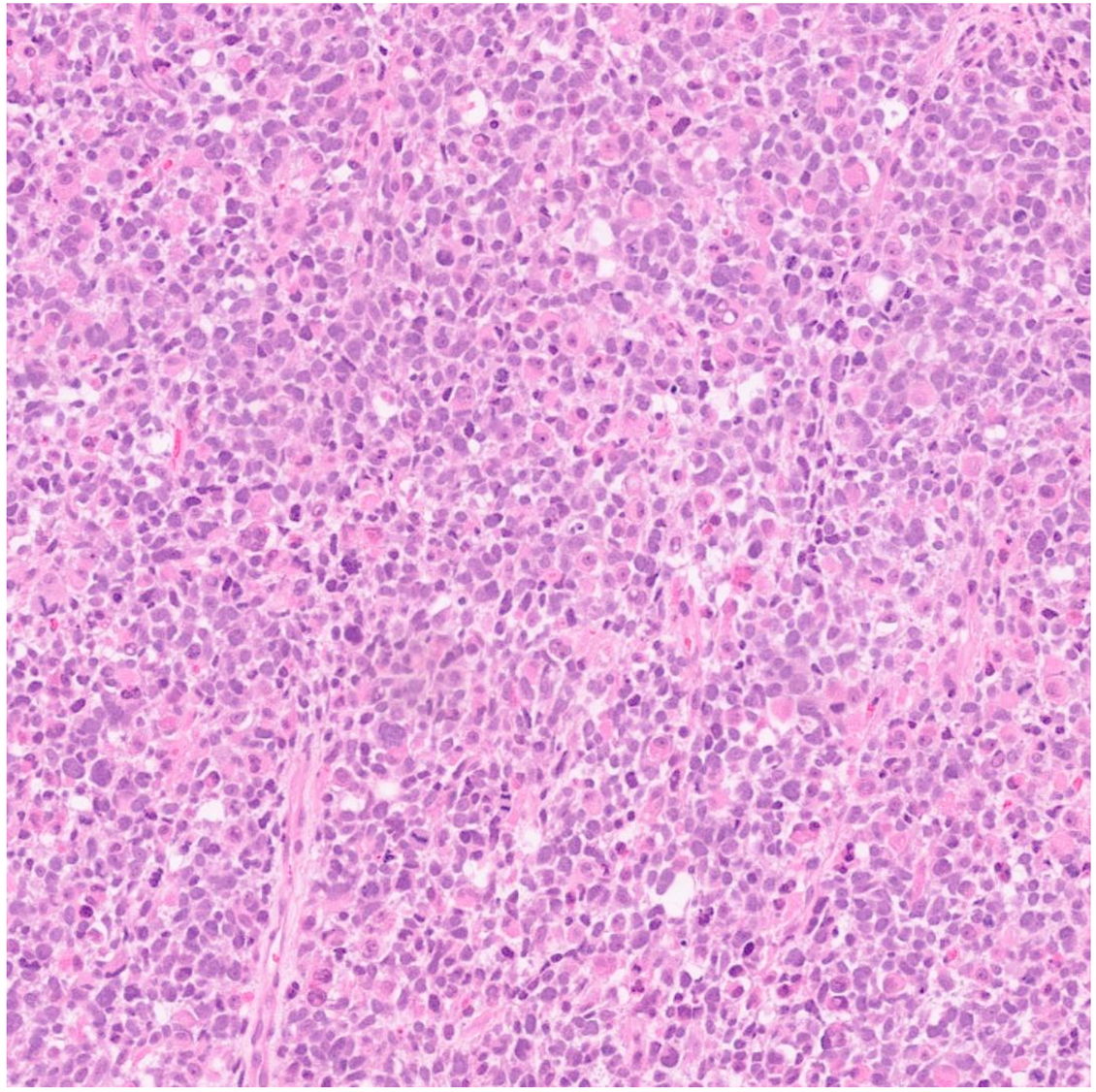

Solid/diffuse architecture

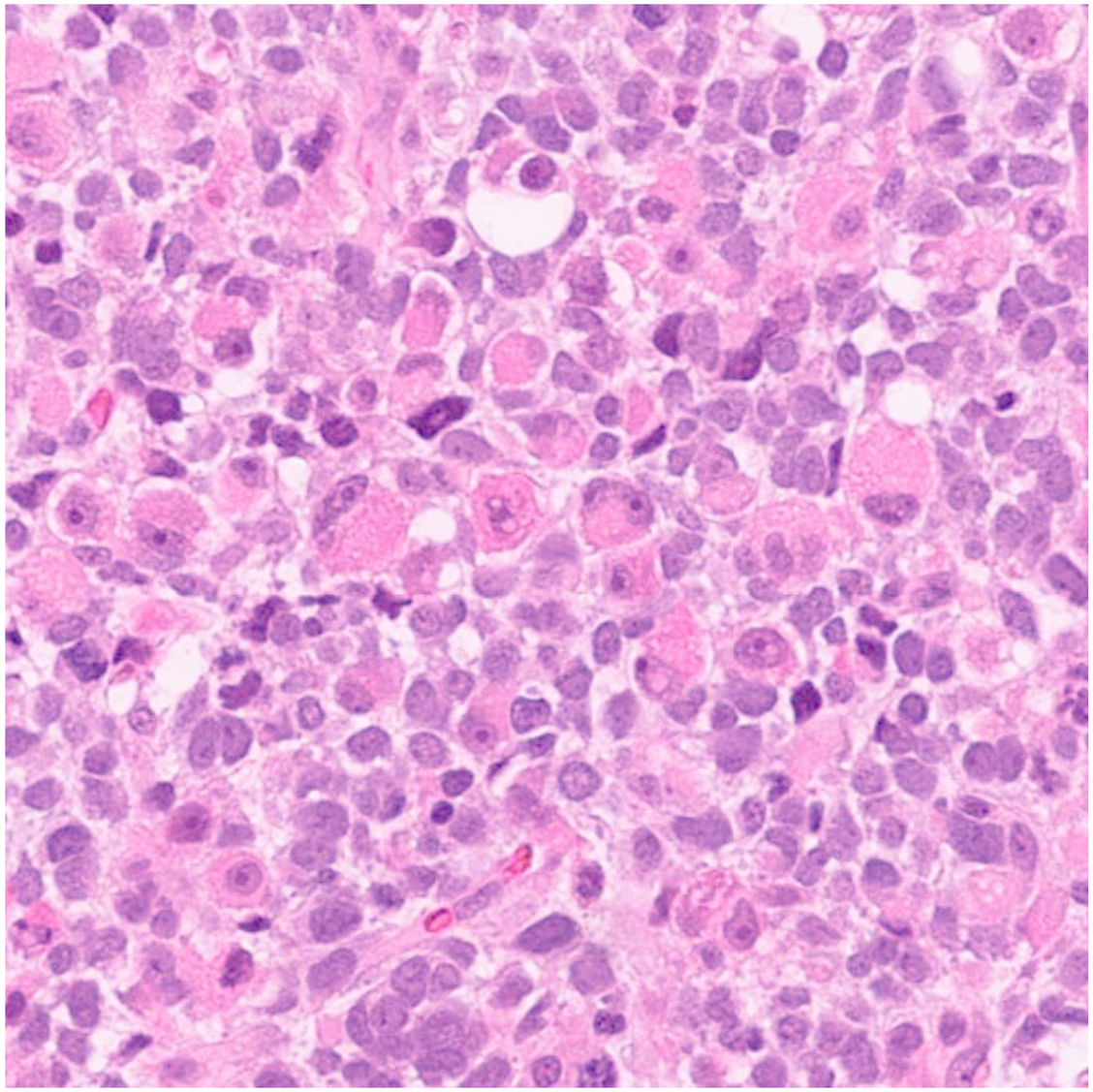

Focal rhabdoid appearance

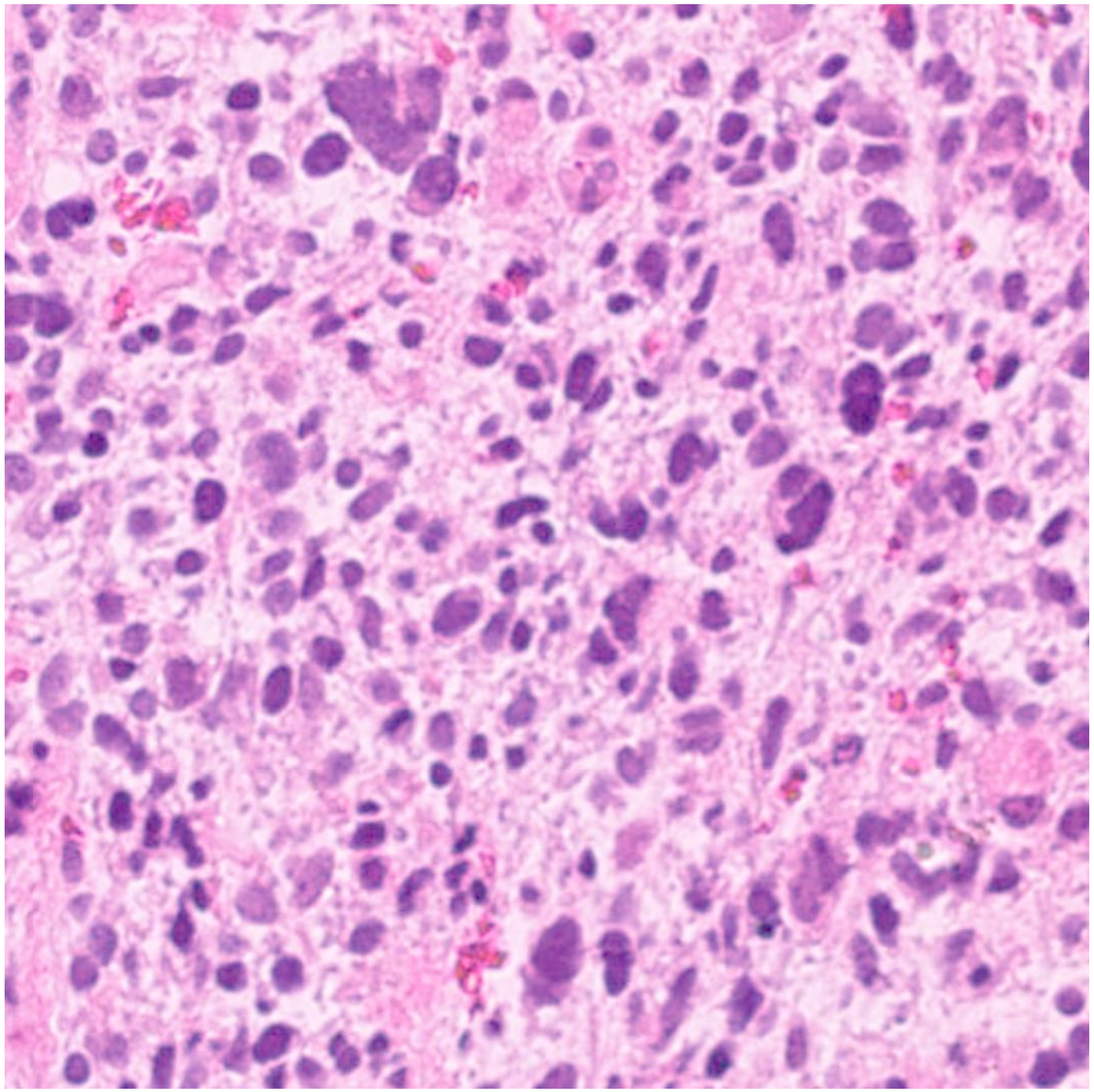

Marked atypia

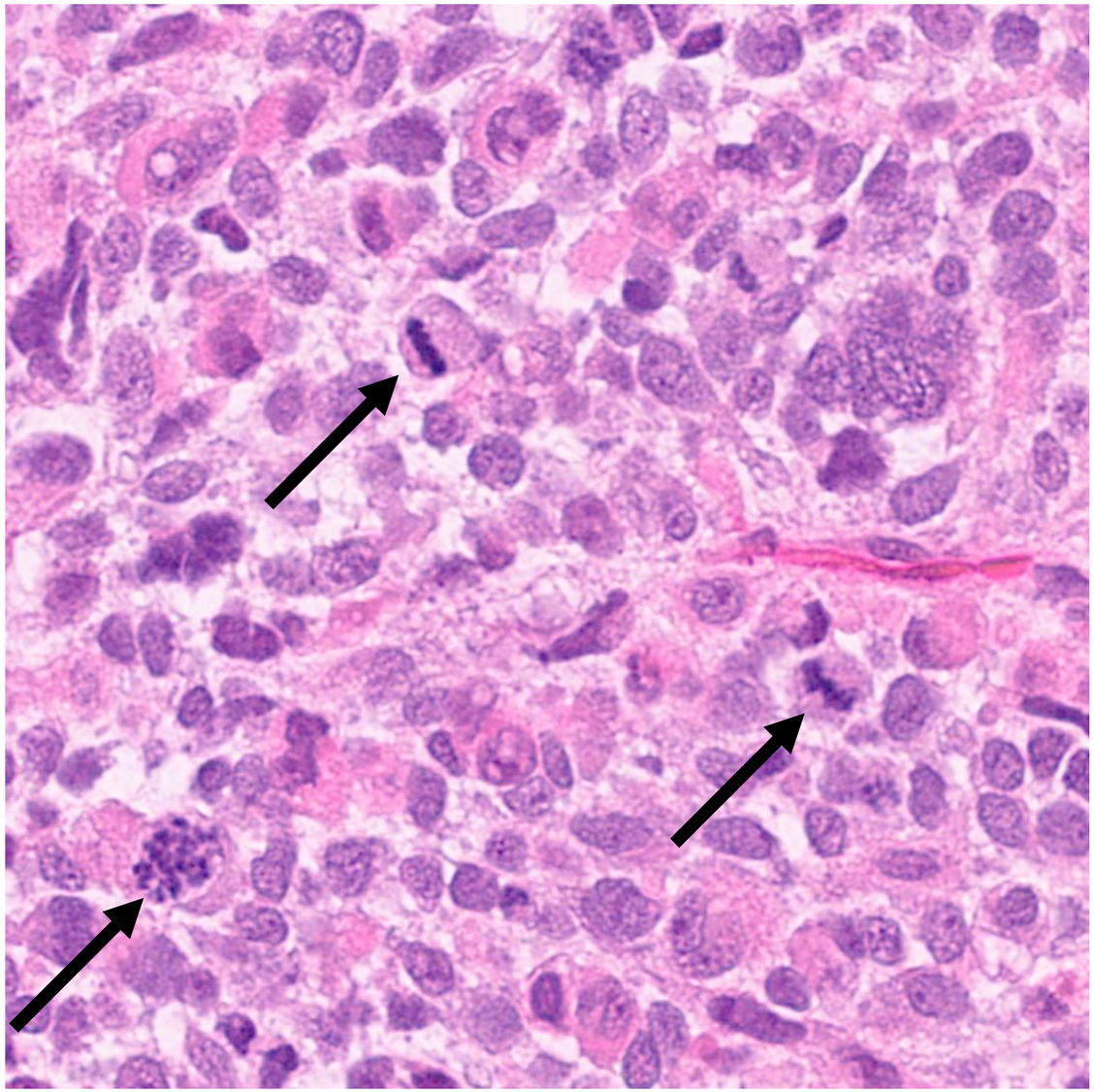

Abundant mitotic activity

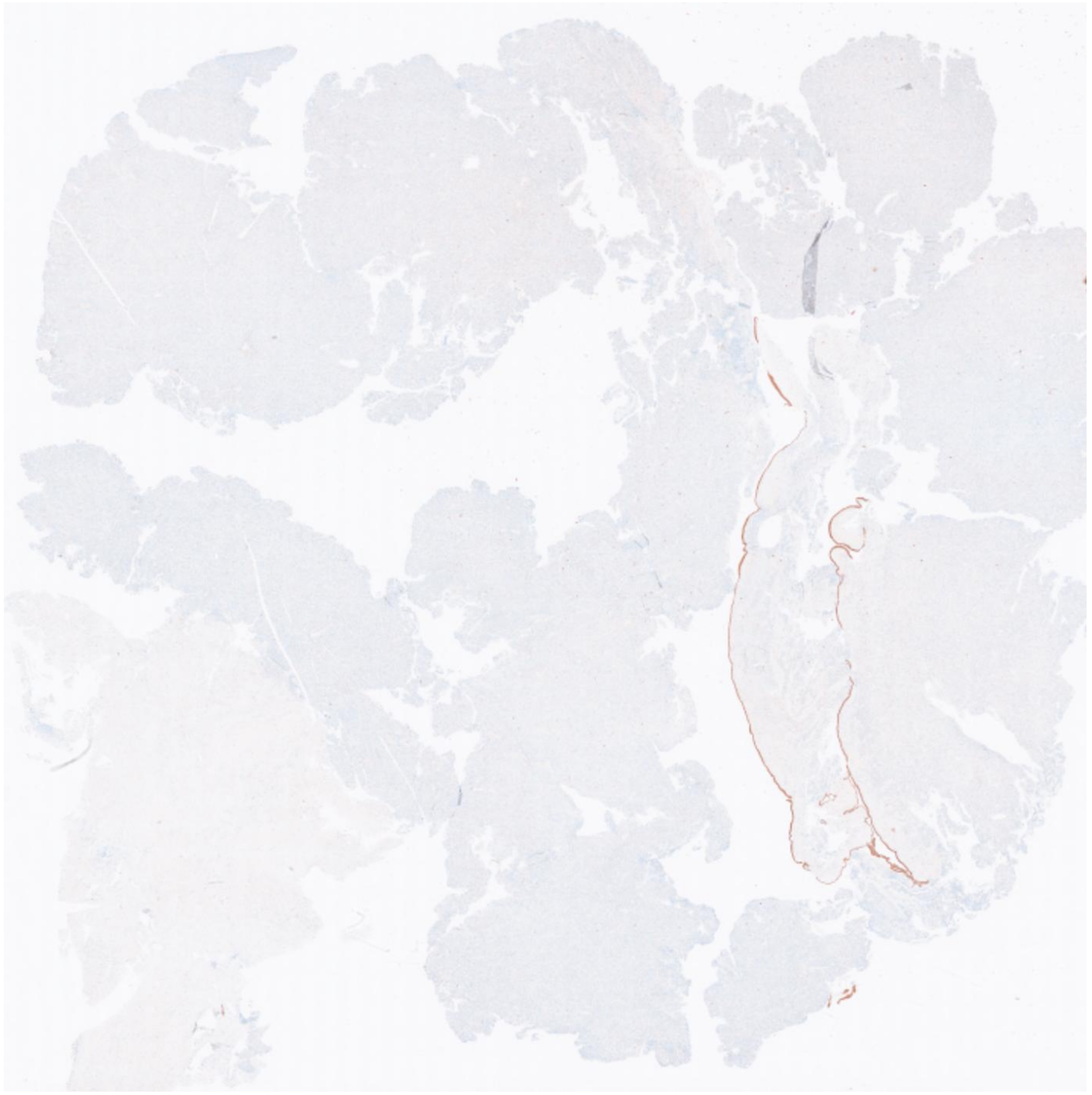

AE1/3



SMA (+ caldesmon)

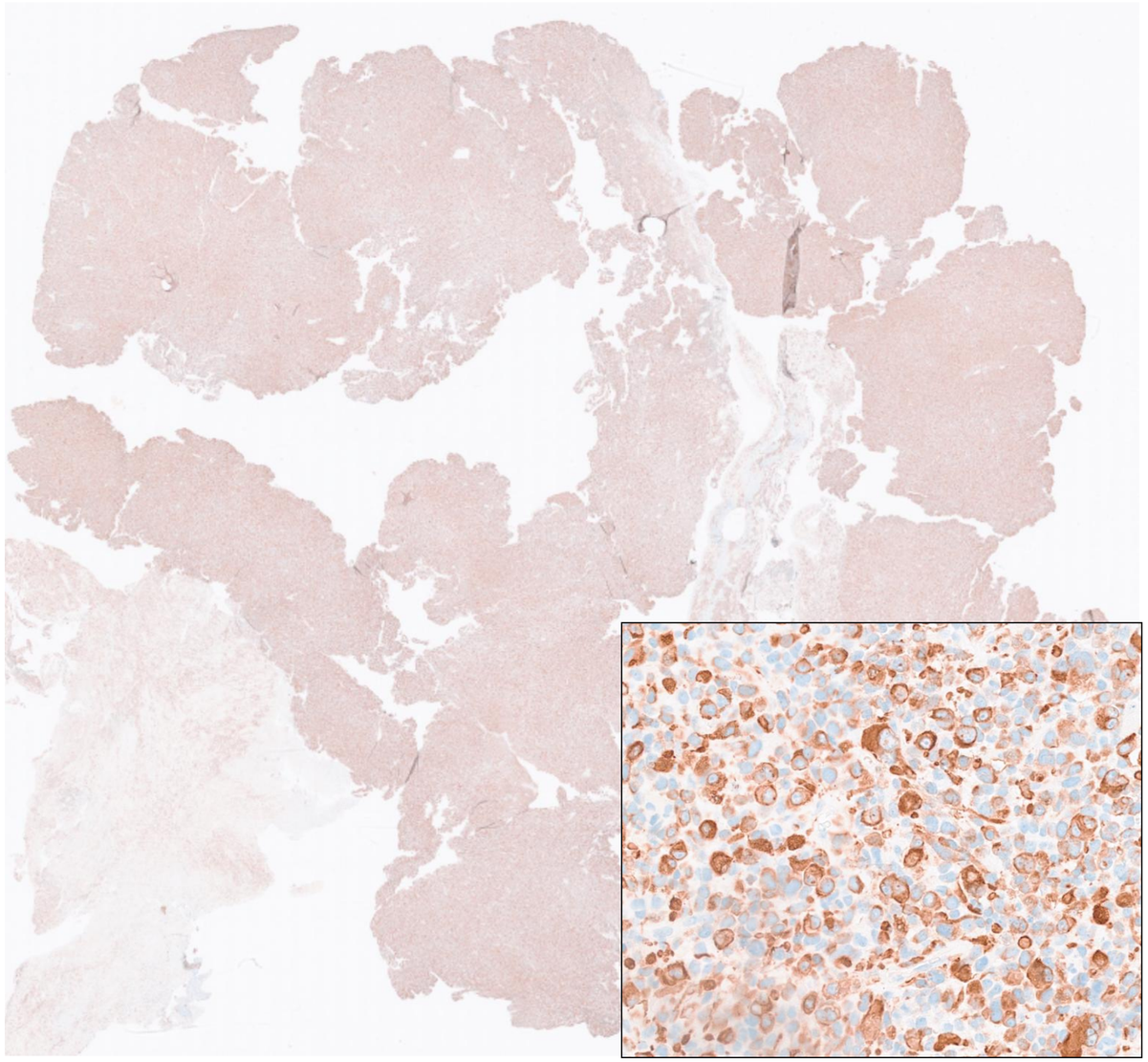

Desmin

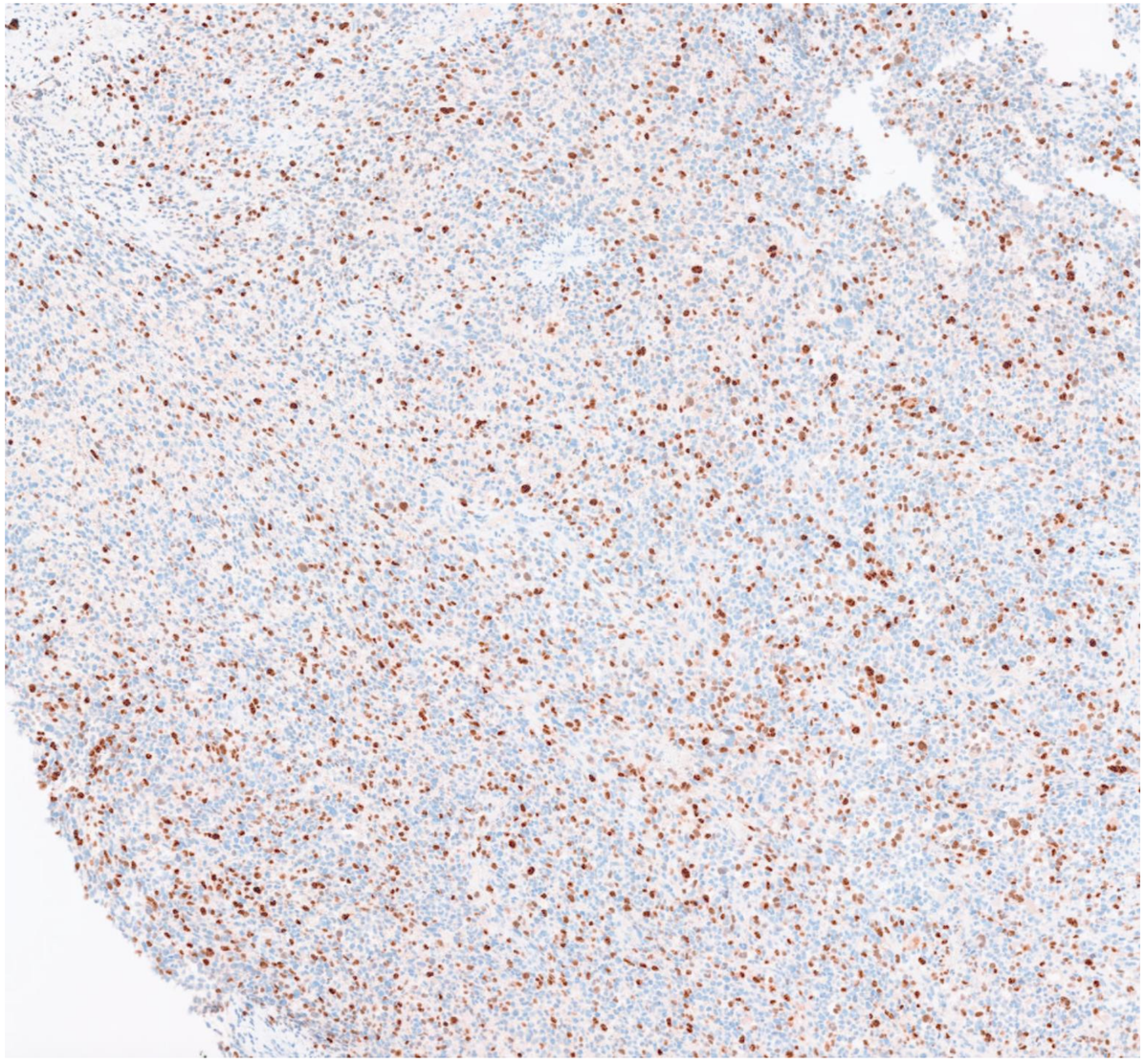

Myogenin (+ myoD1)

Immunohistochemistry

78F, endometrial biopsy

- p53 null
- ER/PR negative
- Patchy CD10
- SOX10 negative
- INI1 and BRG1 retained

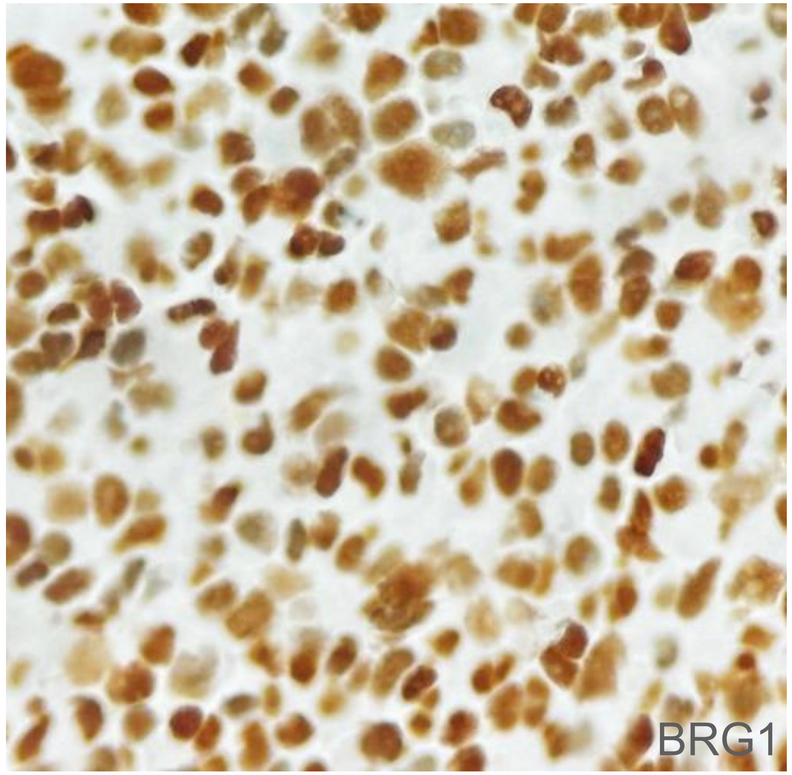

Diagnosis

78F, endometrial biopsy

Not sure!

High grade sarcoma with widespread rhabdomyoblastic differentiation

Let’s take a diversion!

Different case 1 - 61F, hysterectomy

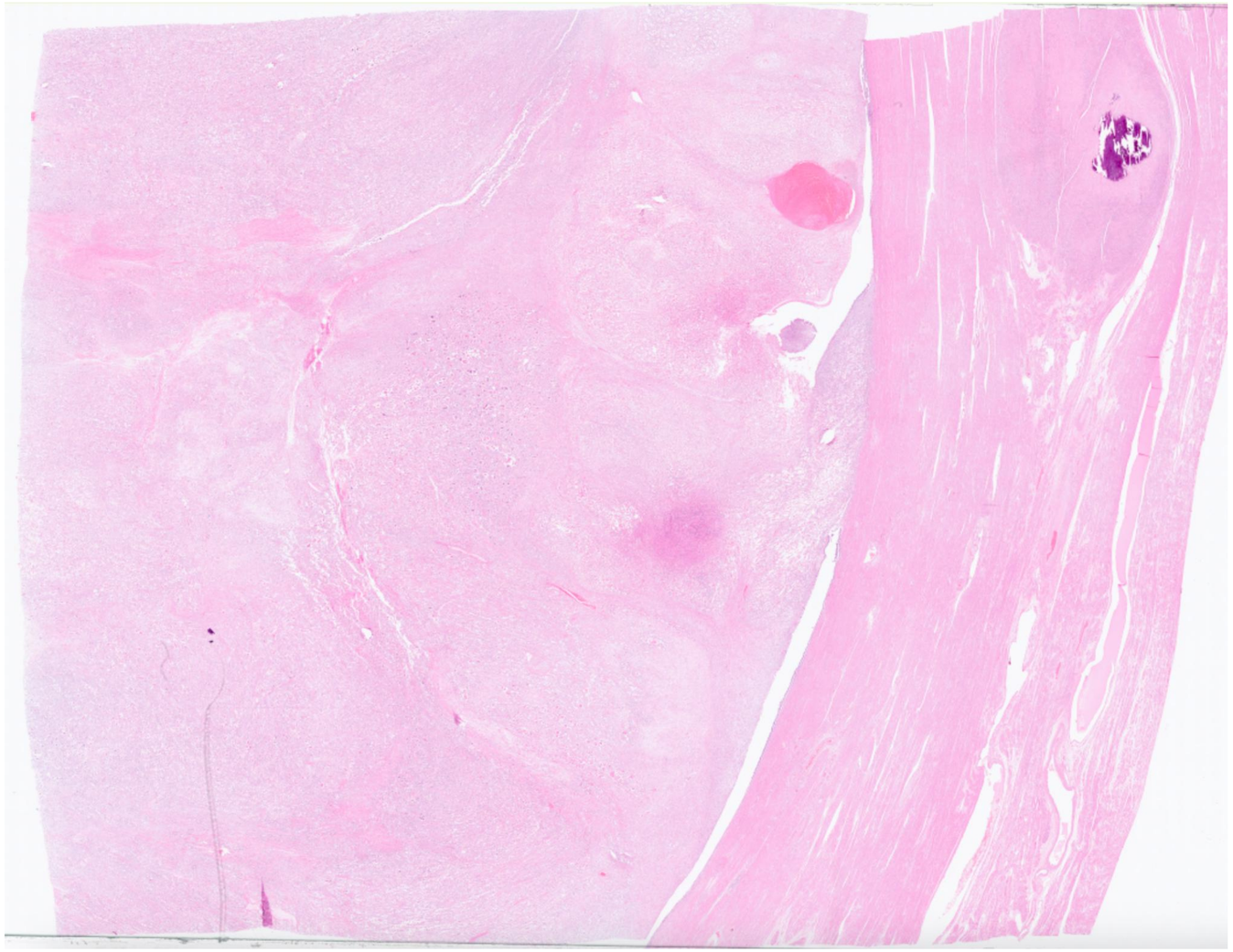

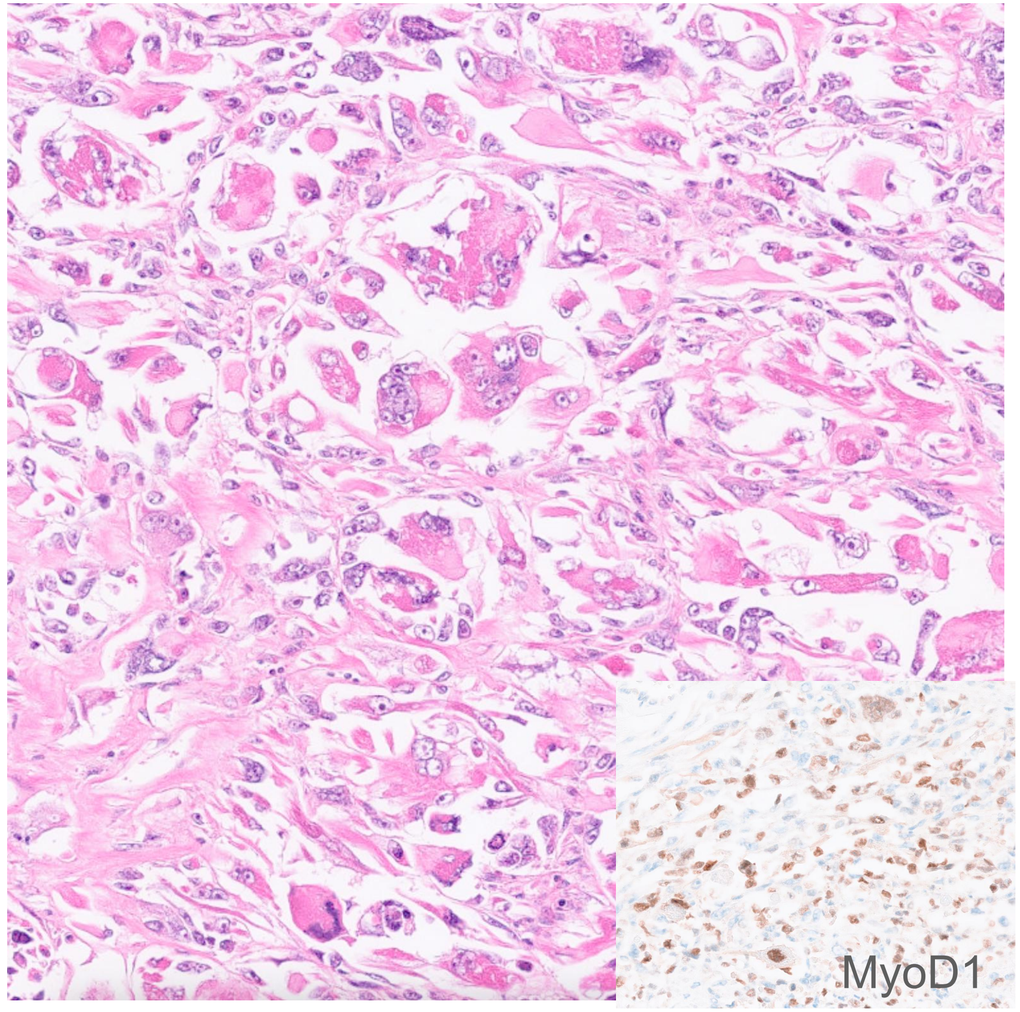

>95% sarcoma with rhabdomyoblastic differentiation

Different case 1 - 61F, hysterectomy



Cytokeratins almost entirely negative

Different case 1 - 61F, hysterectomy

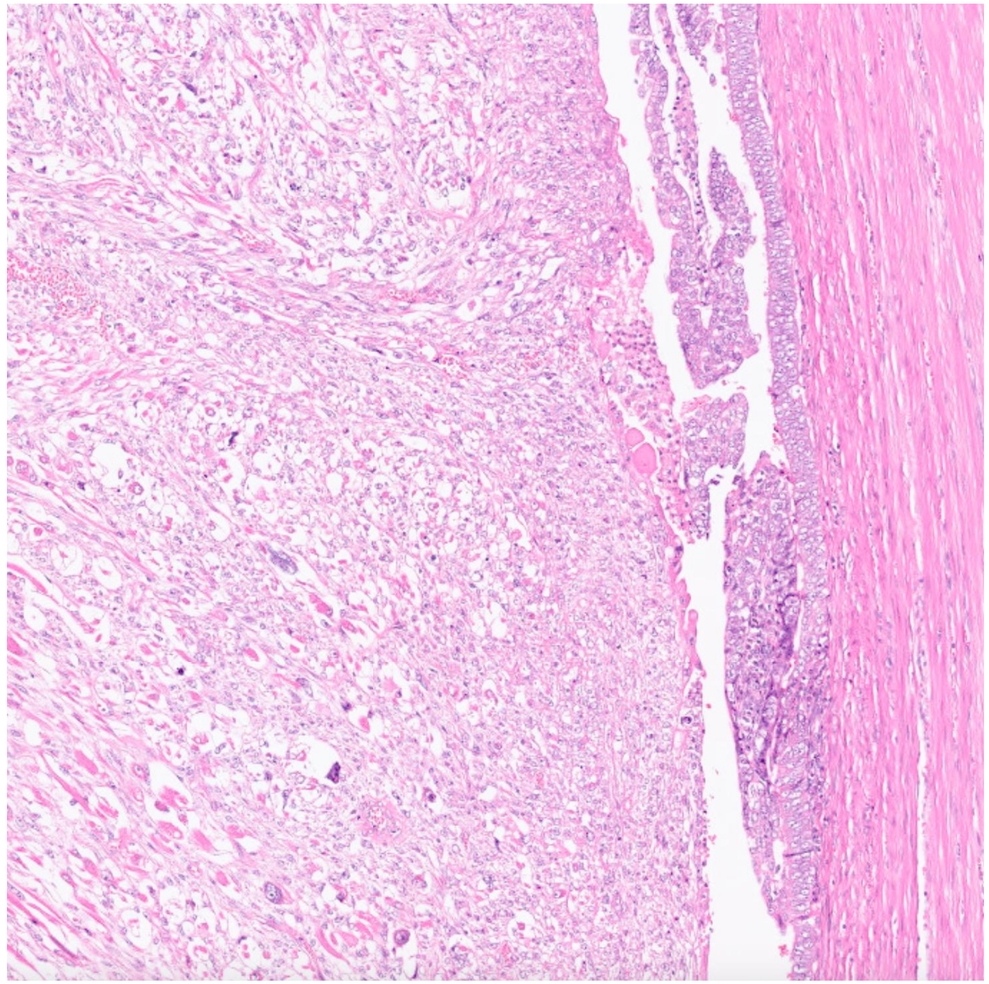

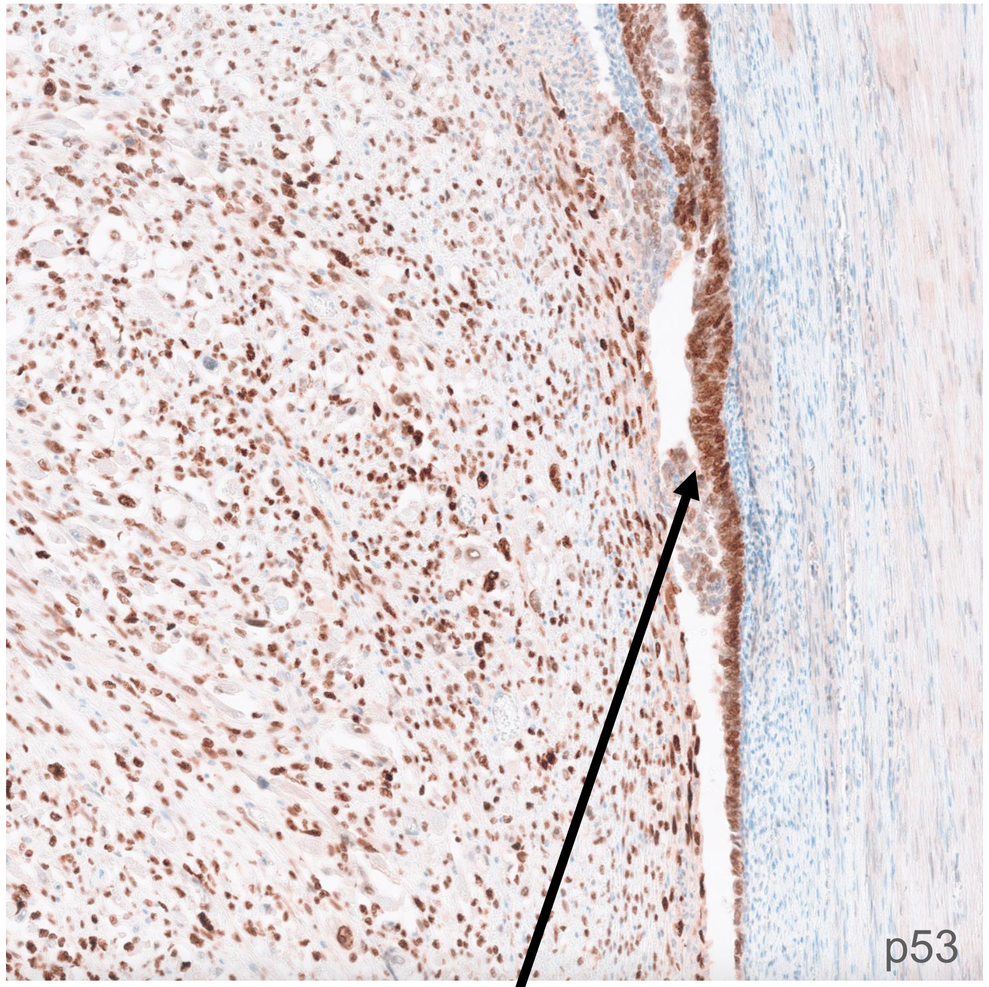

Focal EIC-like epithelial component

Malignant epithelial component present -> carcinosarcoma

Let’s continue the diversion with another different case!

Different case 2 - 57F, hysterectomy

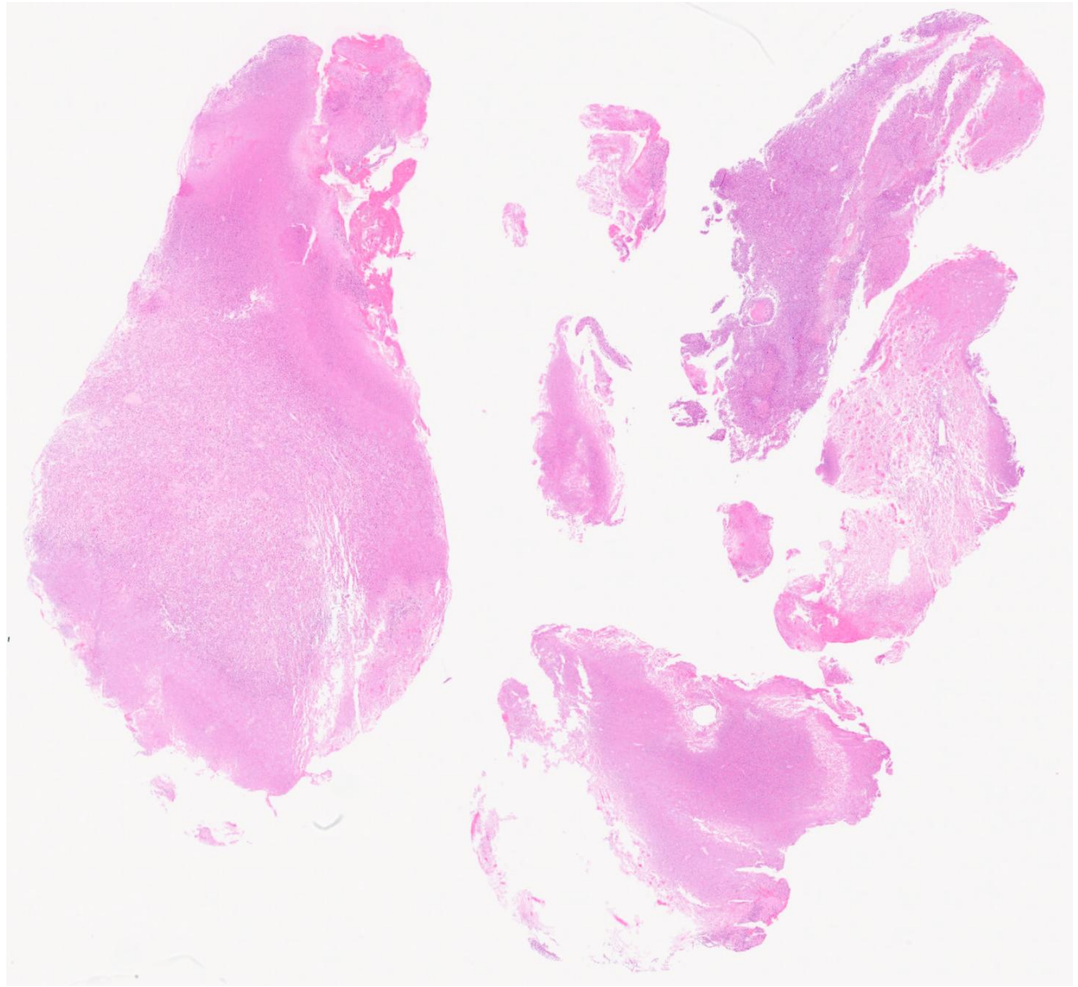

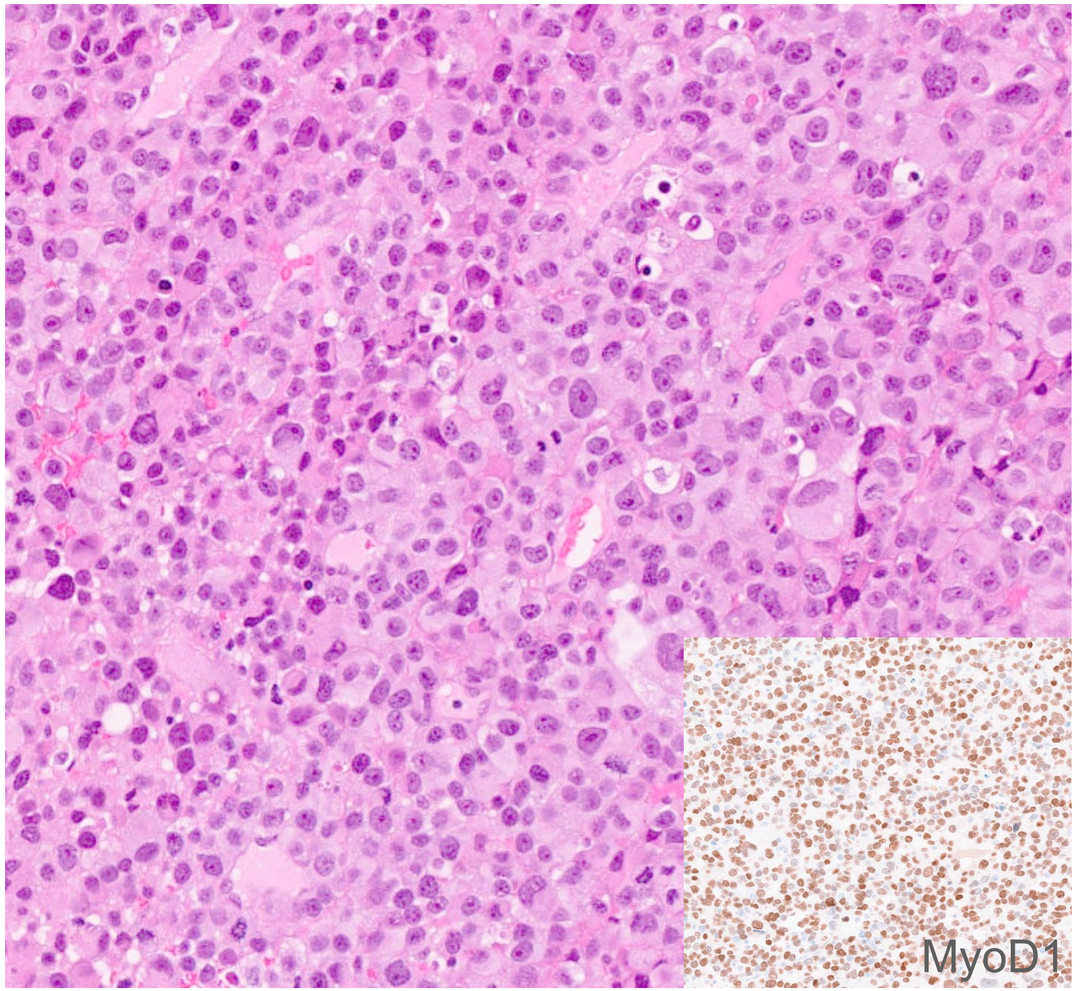

Different case 2 - 57F, hysterectomy

Immunohistochemistry

- Myogenin/MyoD1 positive
- p53 null
- ER/PR rare weak positivity
- Patchy CD10
- SOX10 negative
- INI1 and BRG1 retained

Different case 2 - 57F, hysterectomy

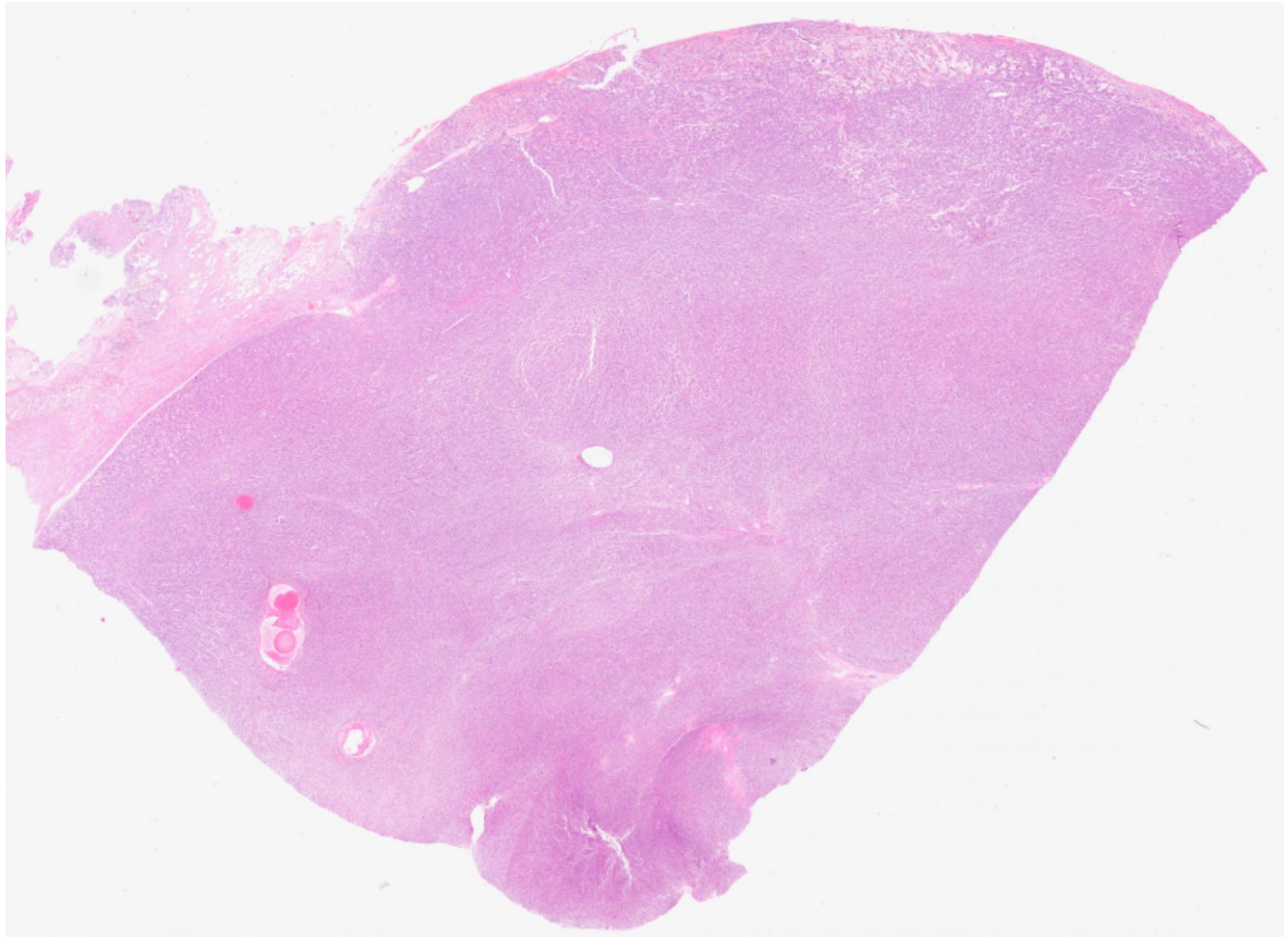

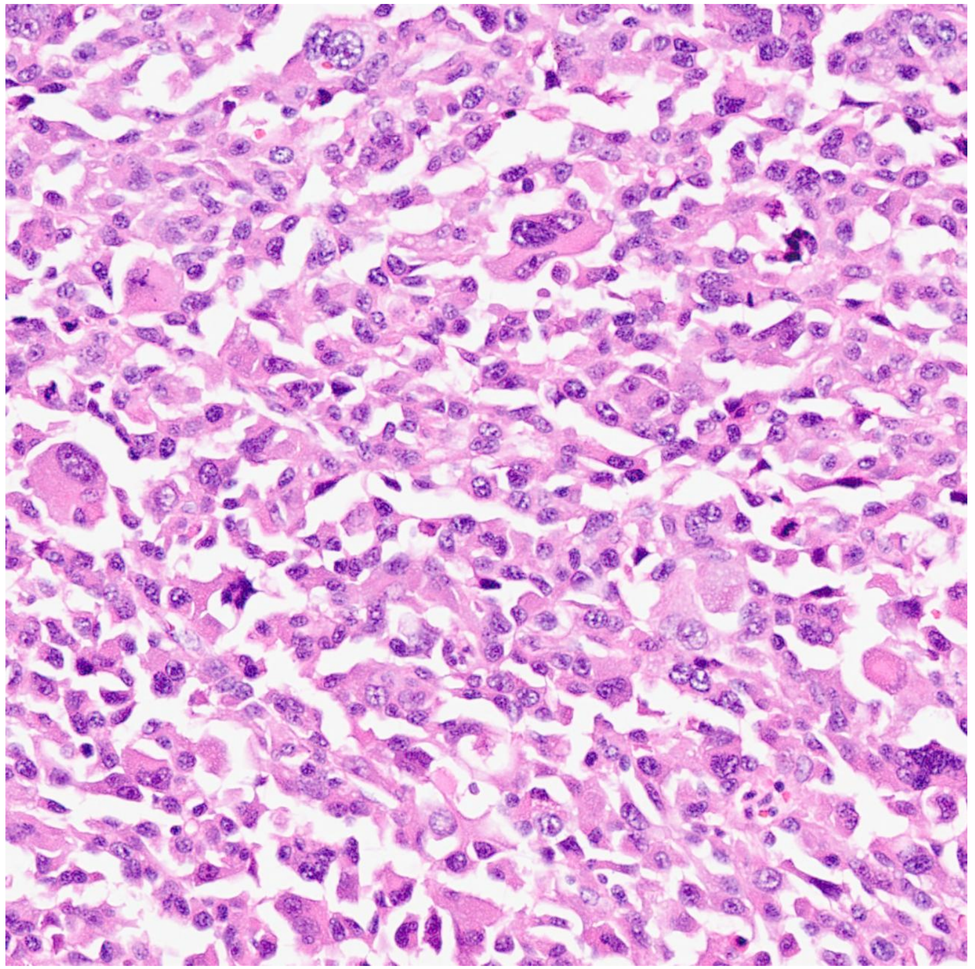

Extensively sampled and no epithelial component identified -> pleomorphic rhabdomyosarcoma

Different case 2 - 57F, hysterectomy

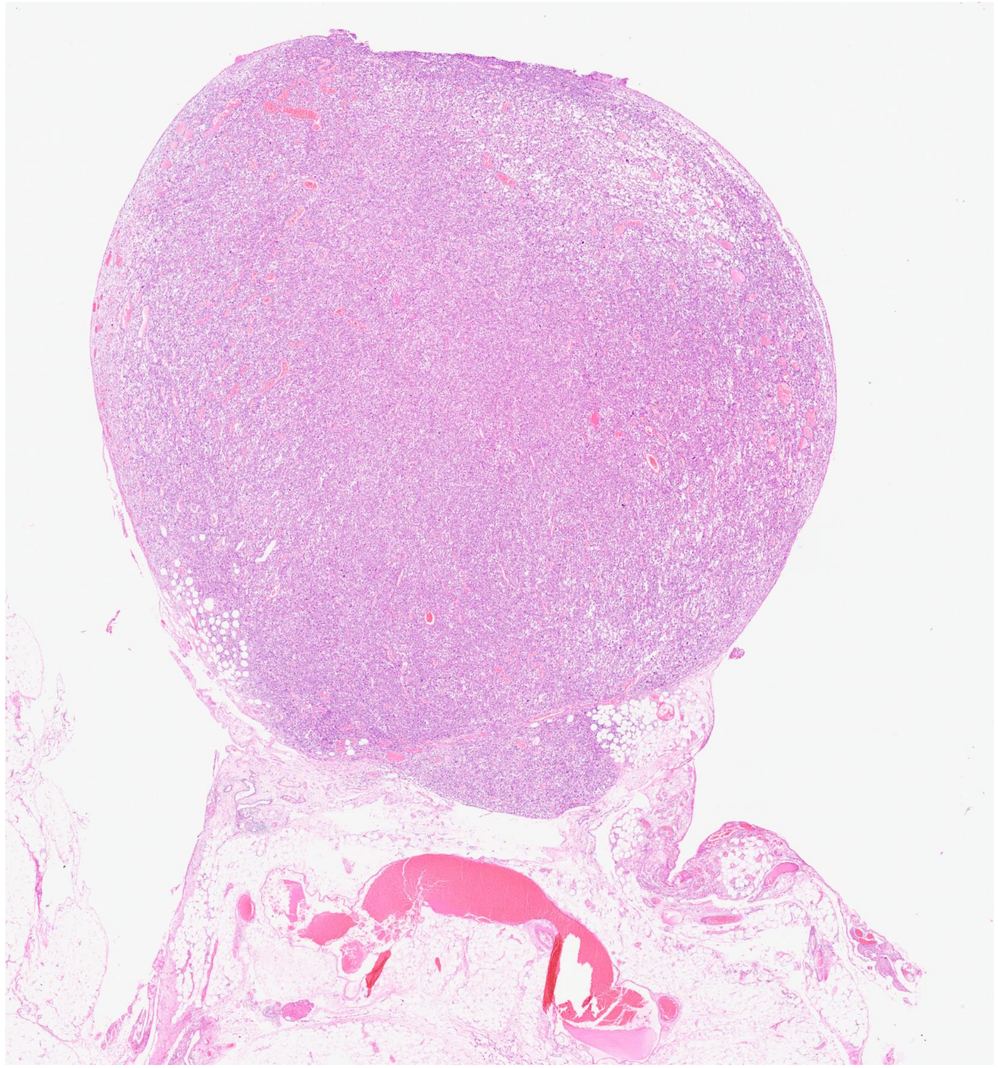

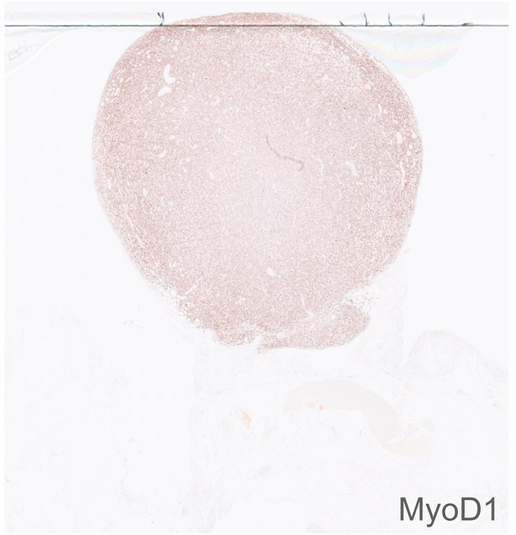

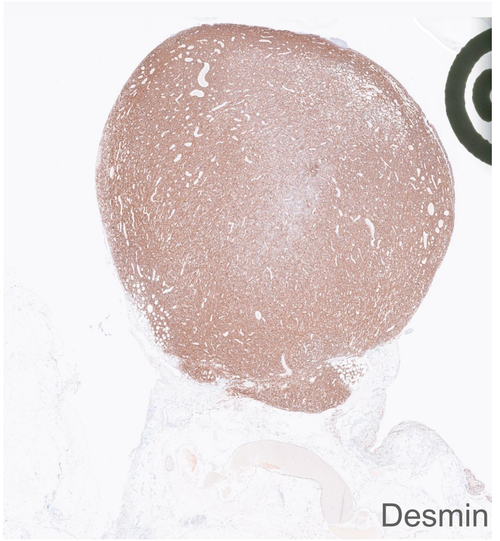

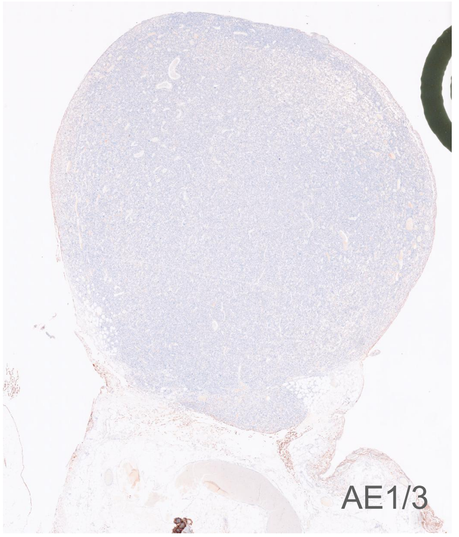

DDx for pleomorphic rhabdomyoblasts

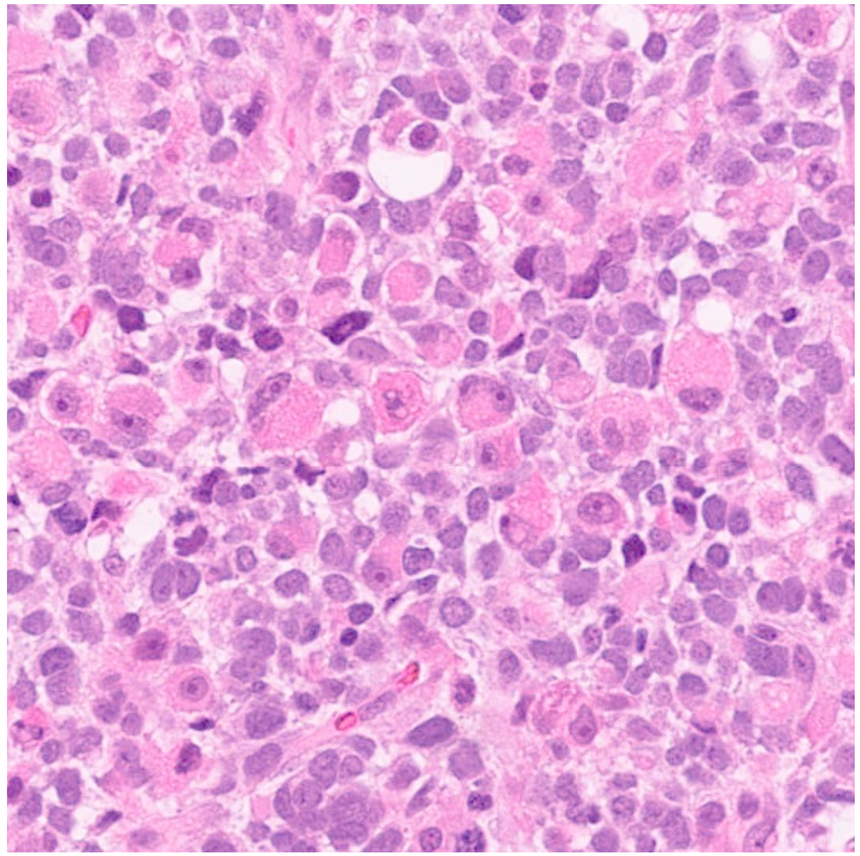

- Carcinosarcoma
- Adenosarcoma with high grade sarcomatous overgrowth
- Pleomorphic rhabdomyosarcoma

… anything else?

Back to our case!

MDT Discussion

- Histo: high grade sarcoma with rhabdomyoblastic differentiation (?carcinosarcoma/adenosarcoma ?pleomorphic rhabdomyosarcoma)
- Imaging: 10cm necrotic uterine mass, liver surface deposit, multiple lung mets
- Outcome: Hysterectomy for symptom relief



Resection

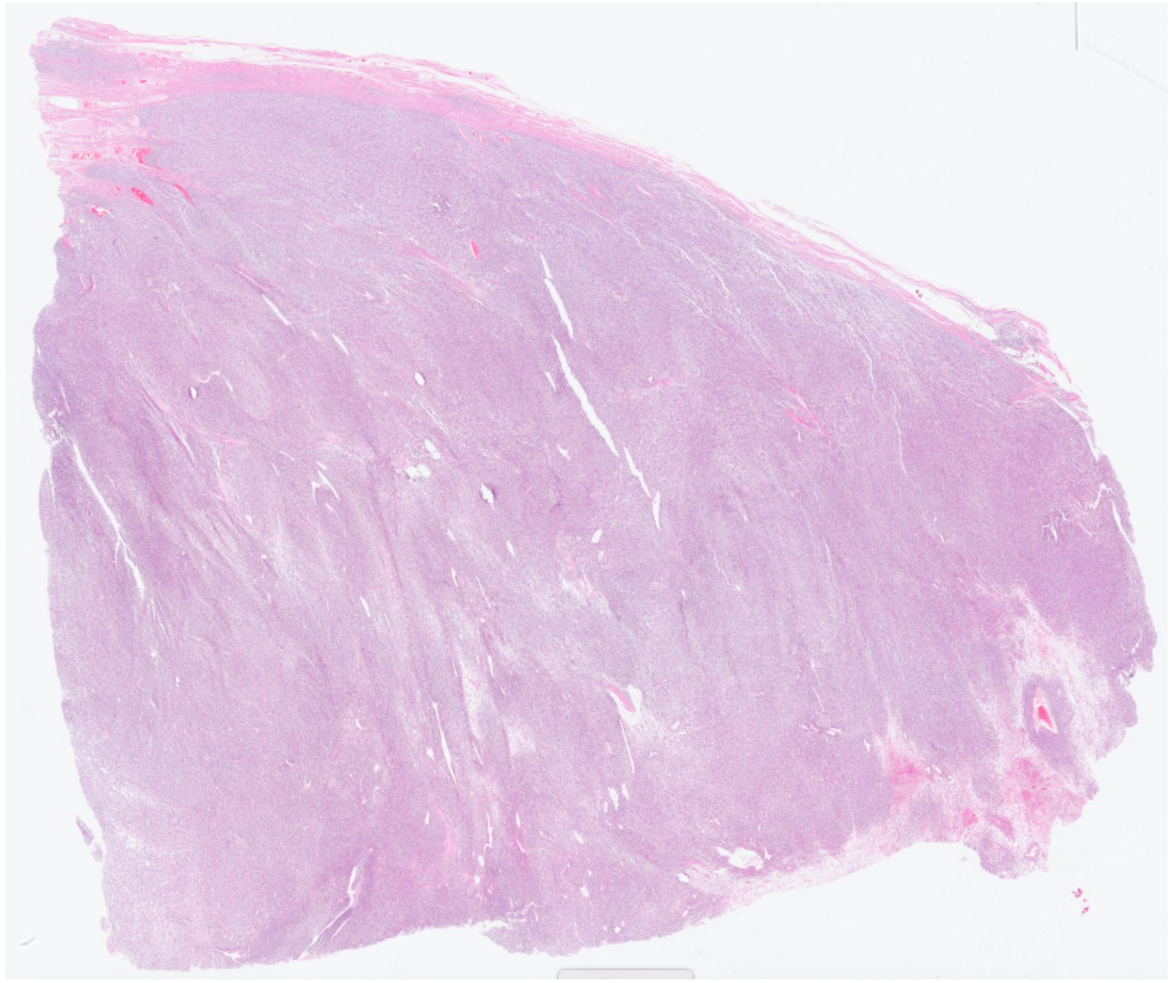

Majority comprises pleomorphic rhabdomyoblasts

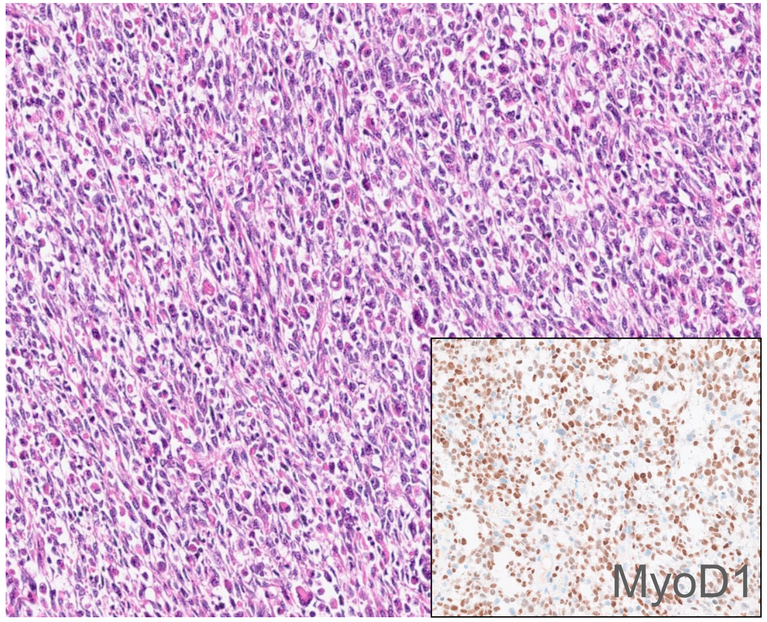

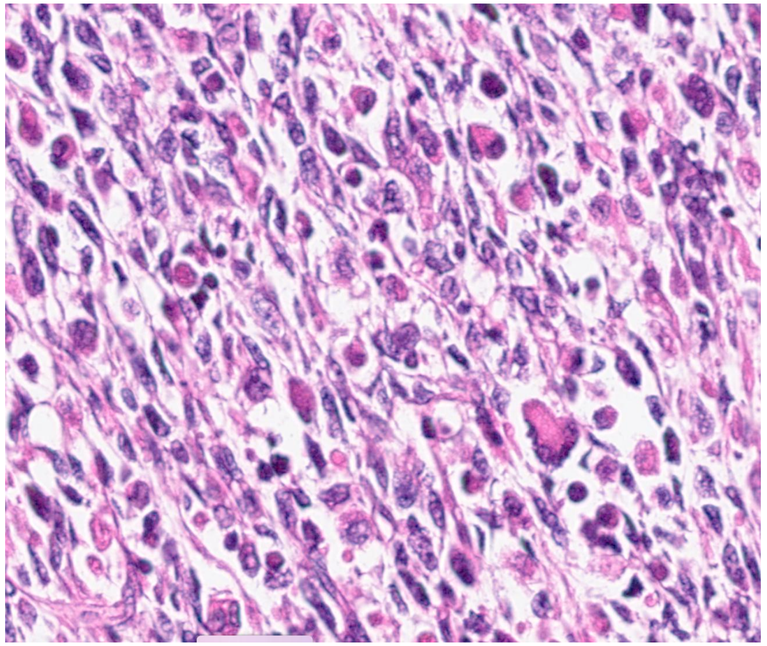

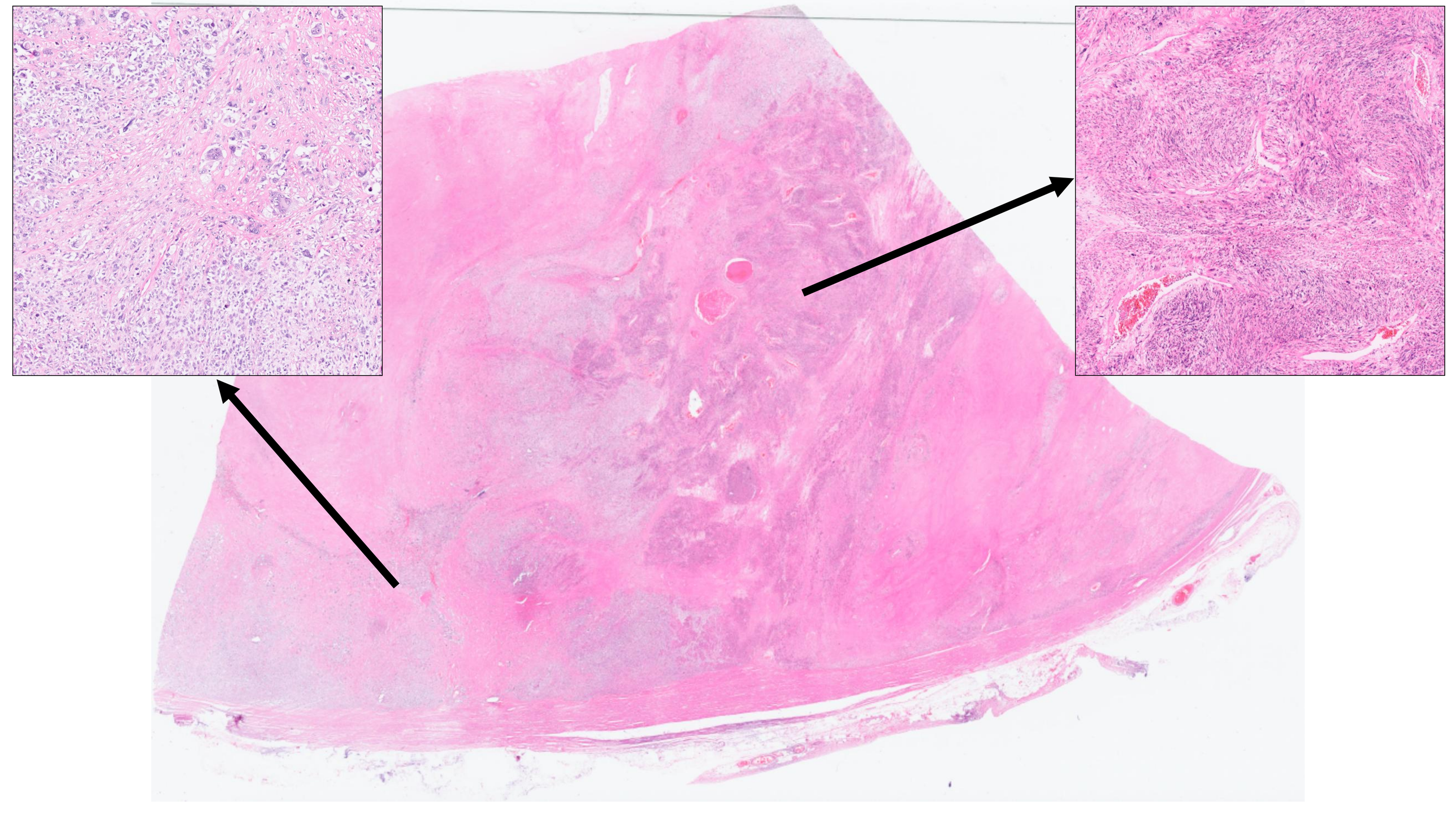

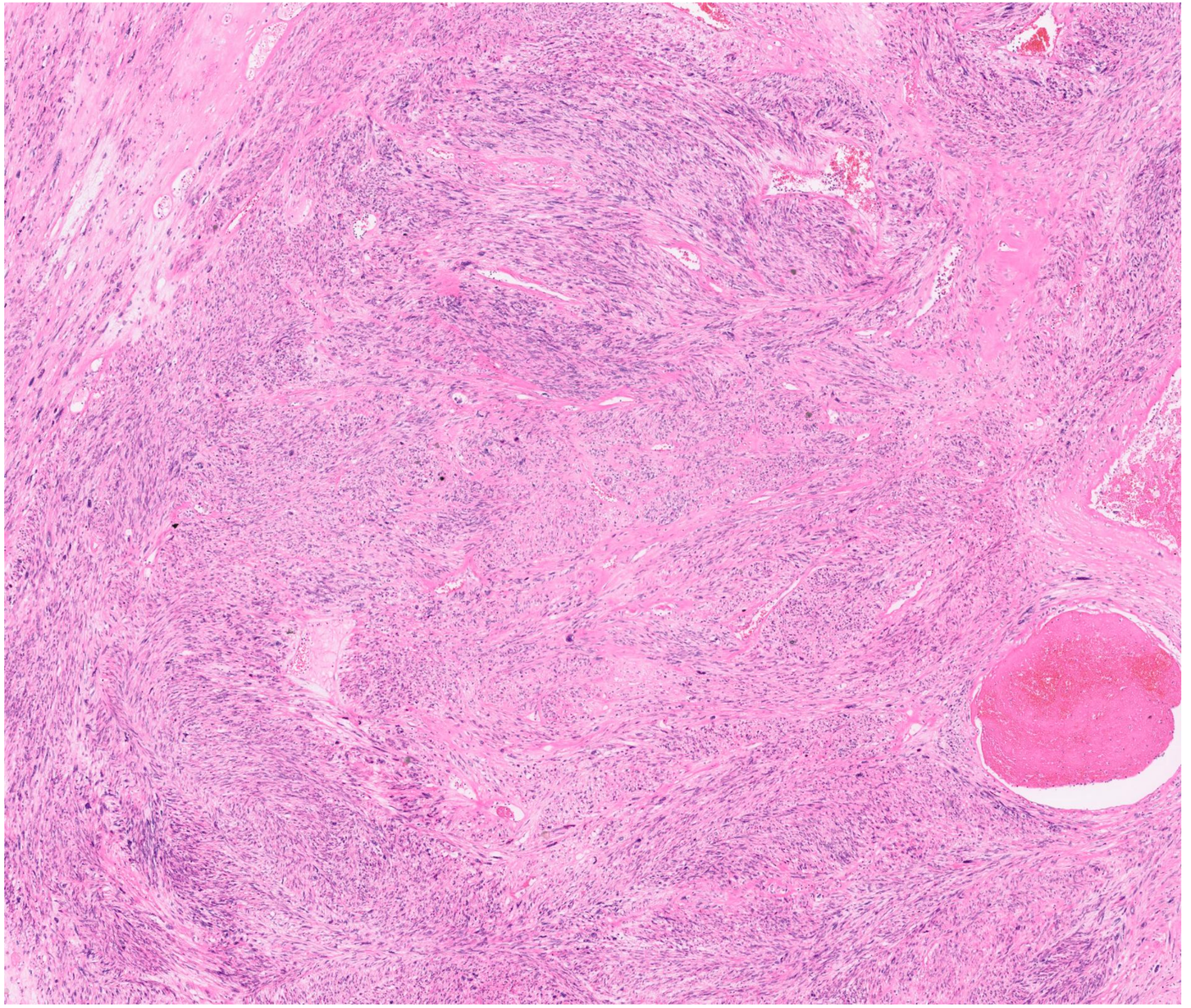

Morphologically smooth muscle

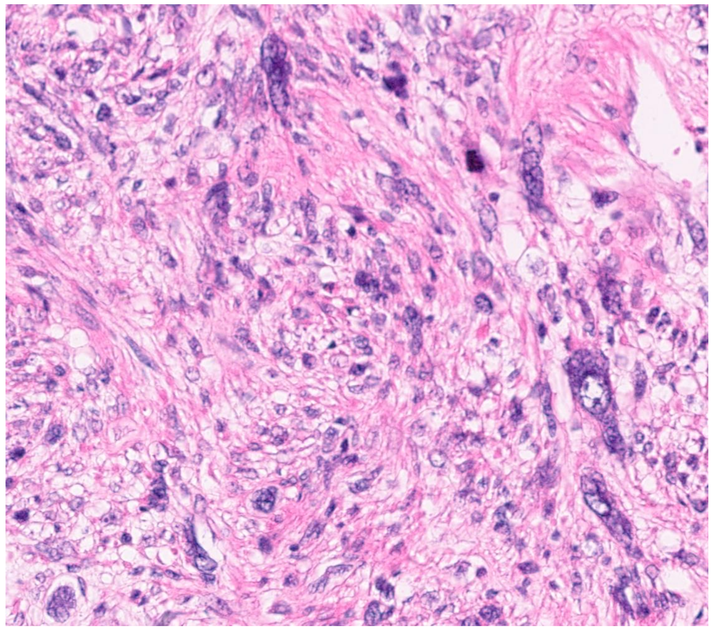

Severe cytological atypia
Mitoses >10 per 10 HPF

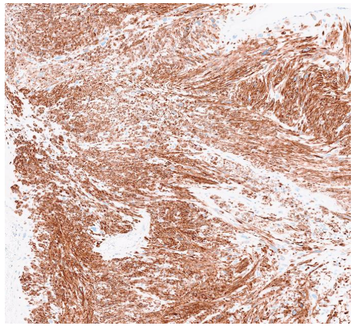

Desmin

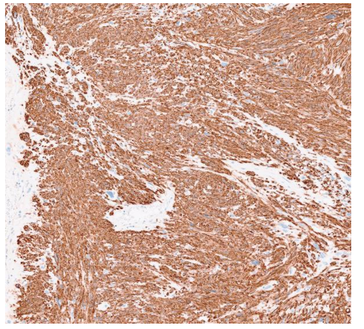

Caldesmon

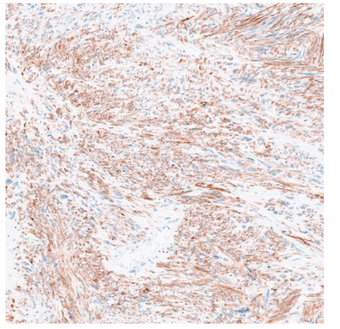

SMA

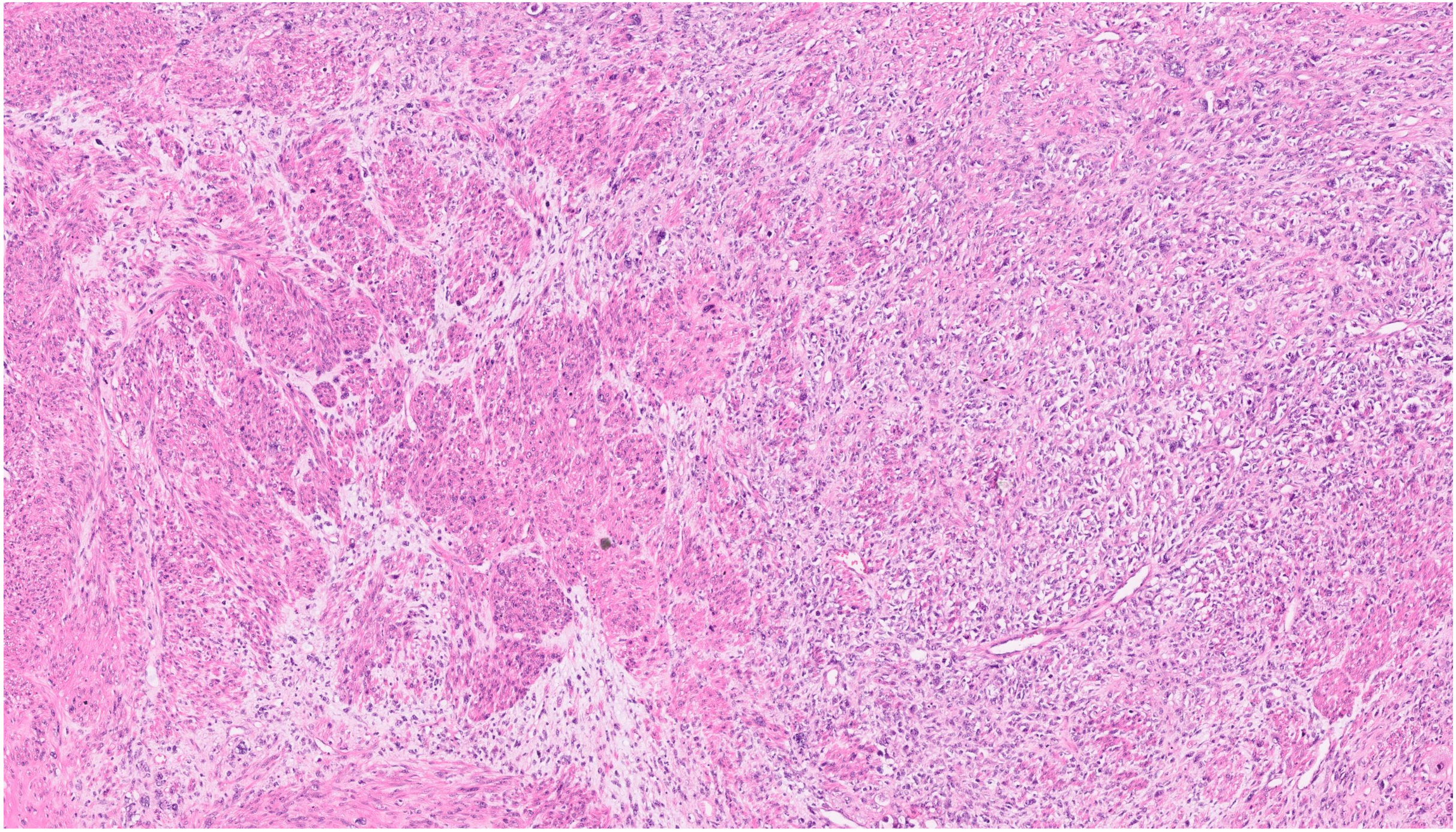

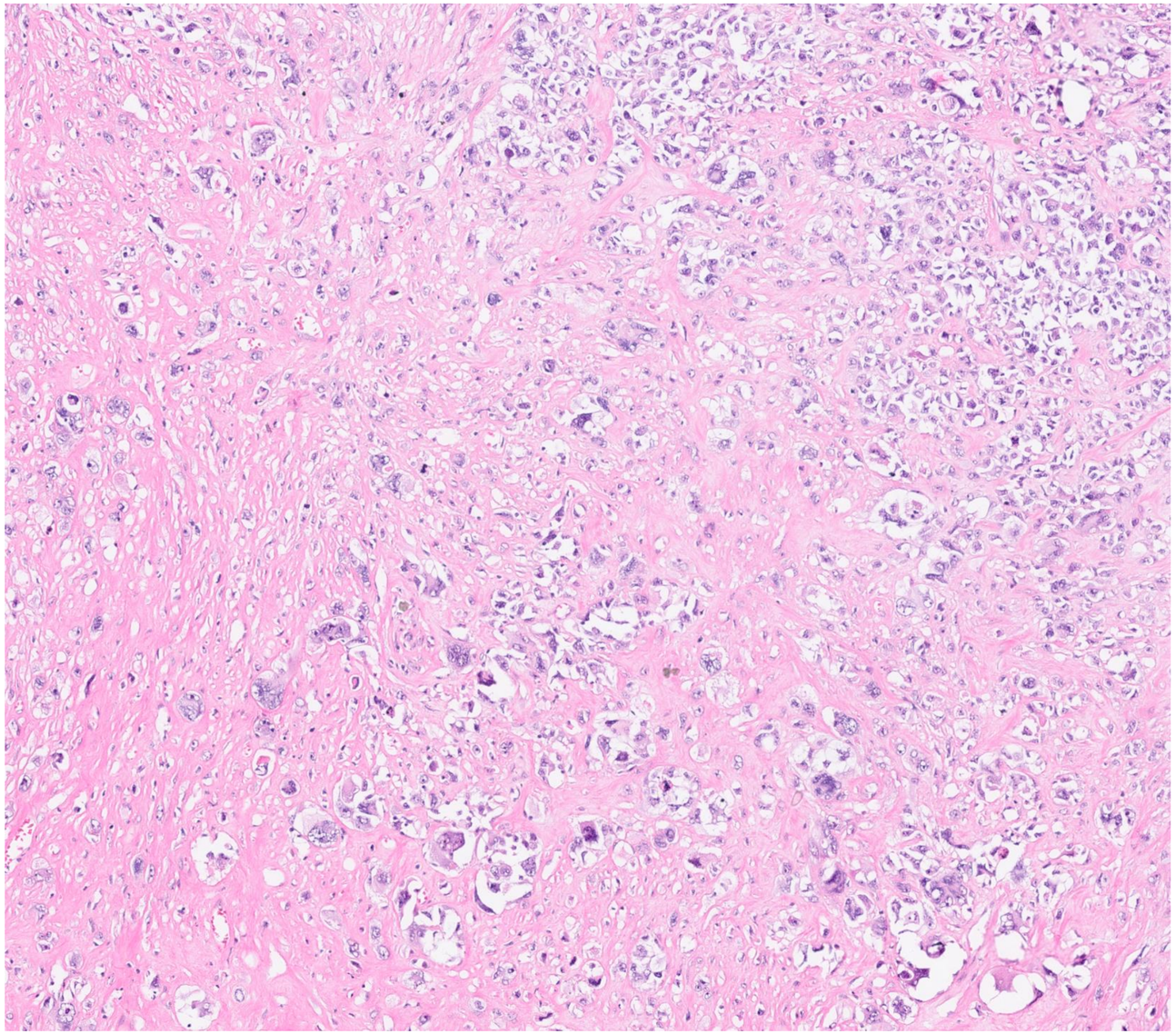

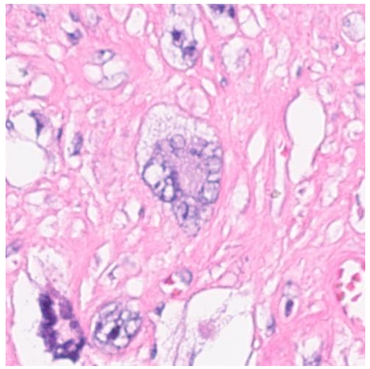

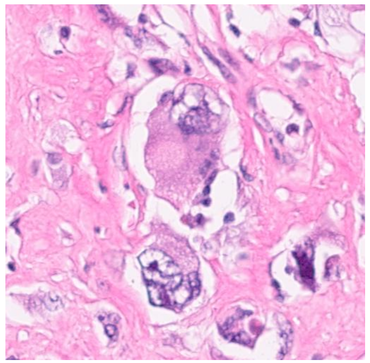

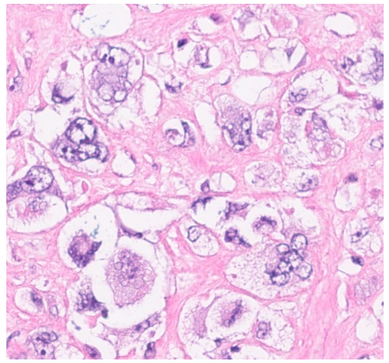

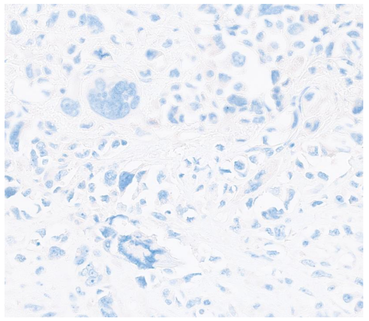

Desmin

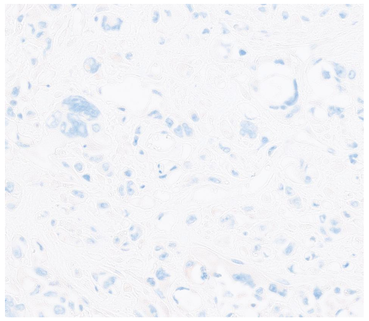

Caldesmon

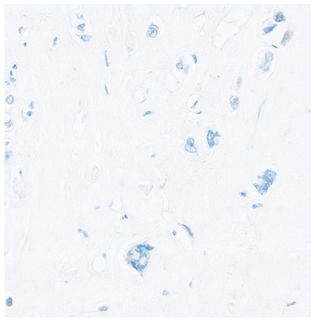

SMA

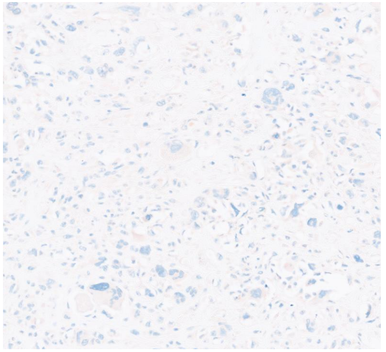

Myogenin

“Malignant fibrous histiocytoma”-like areas

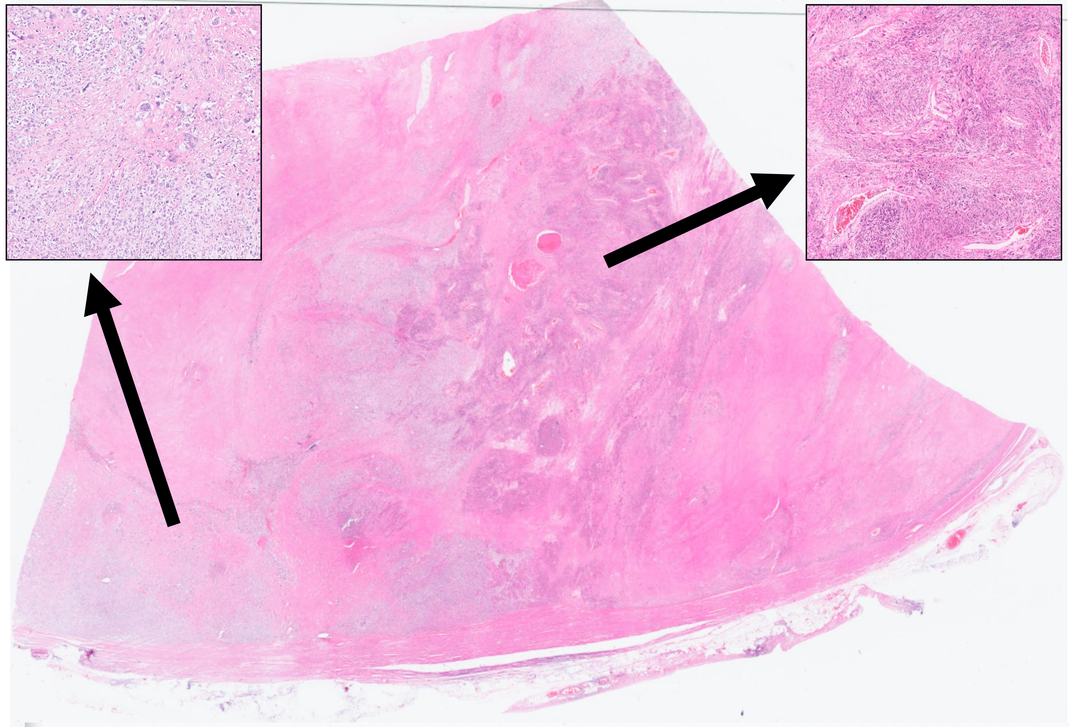


SMA

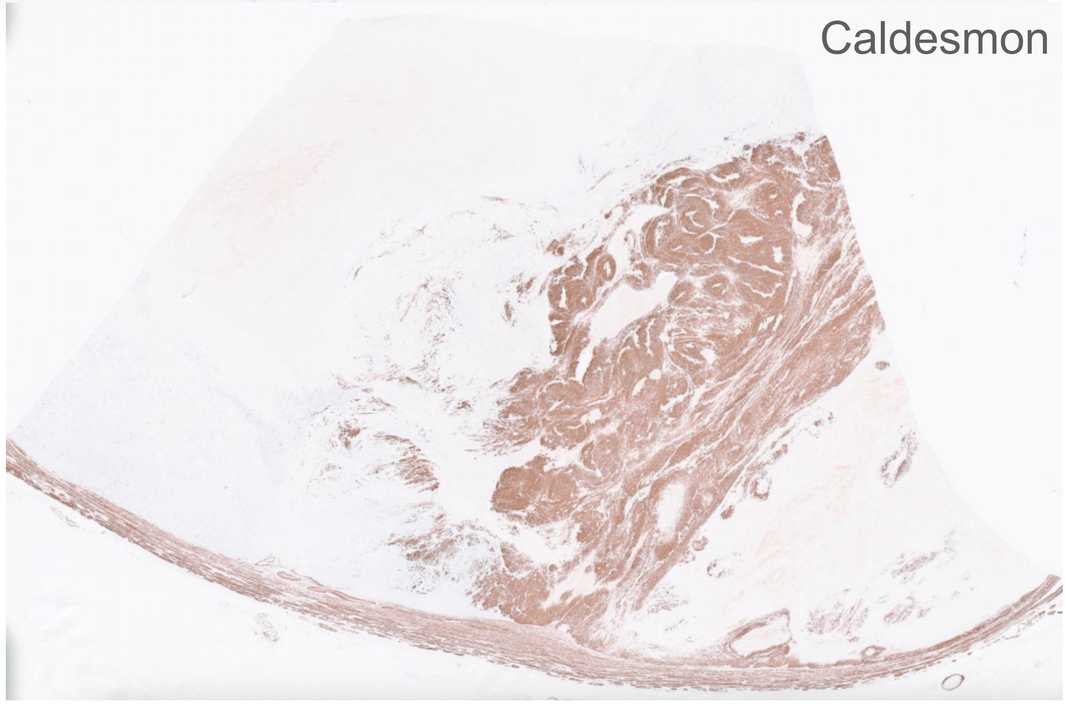
Caldesmon

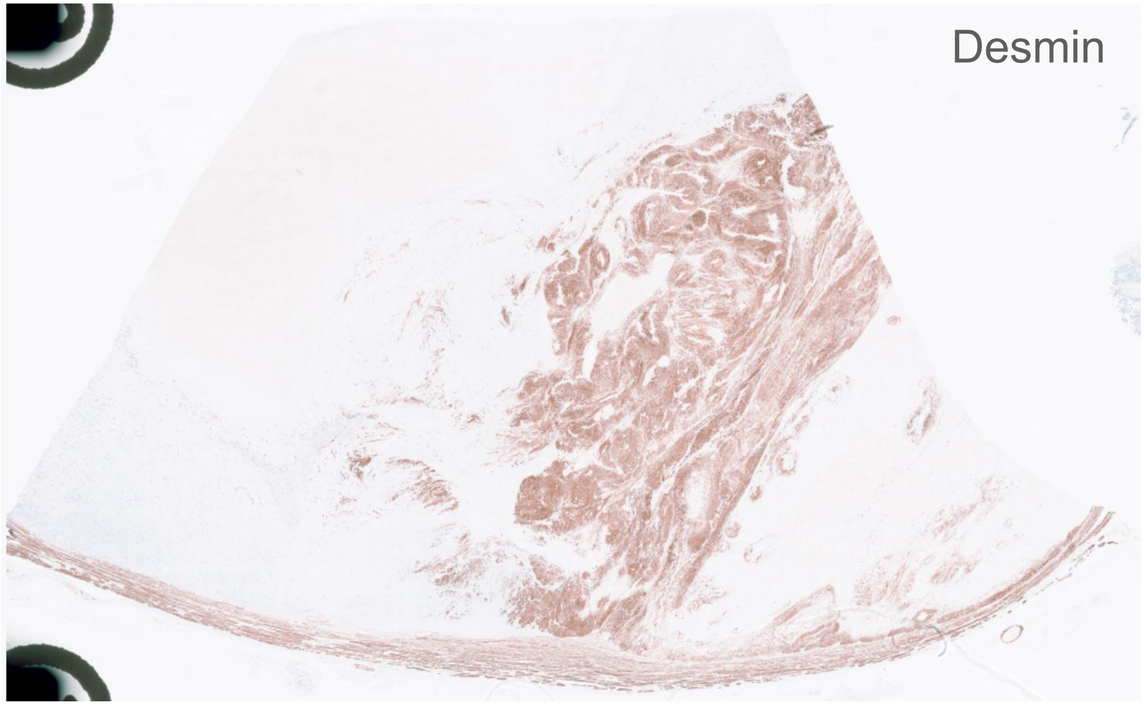
Desmin

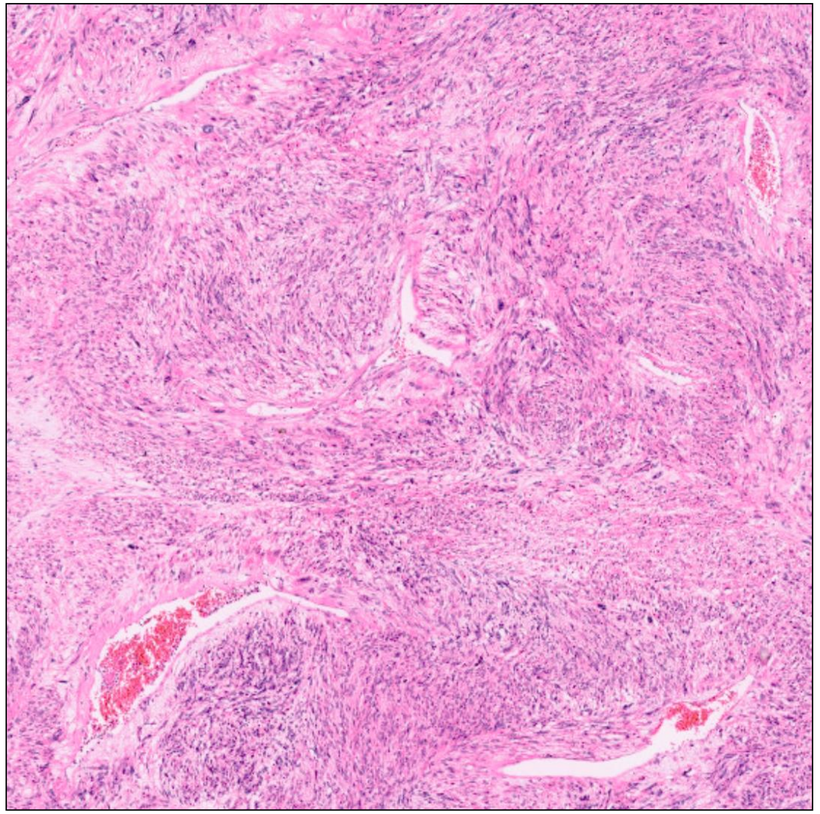

Leiomyosarcoma

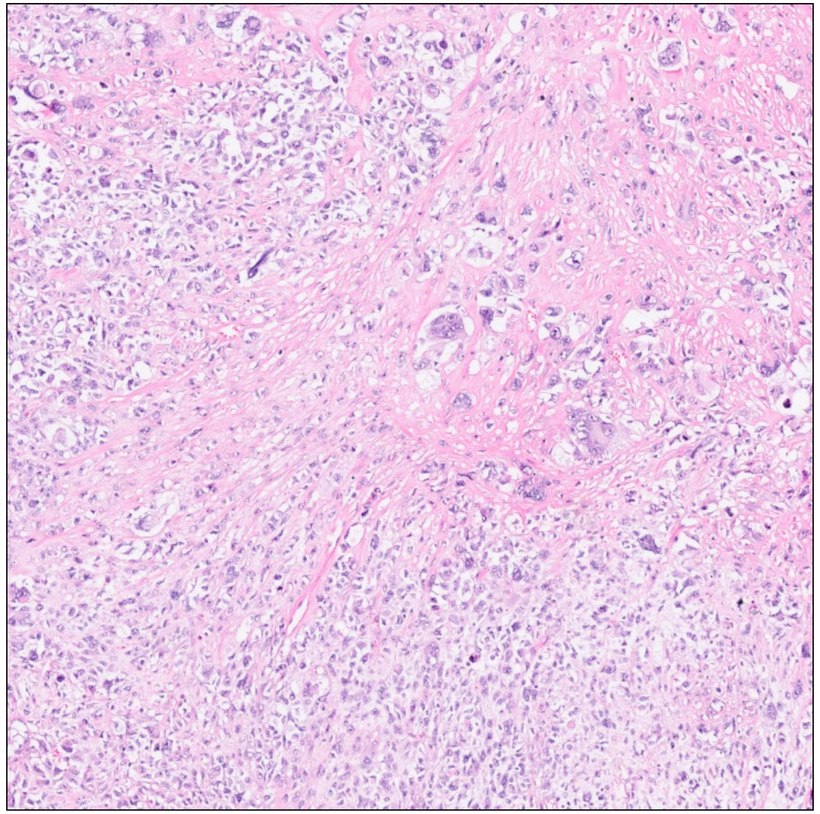

Dedifferentiated component

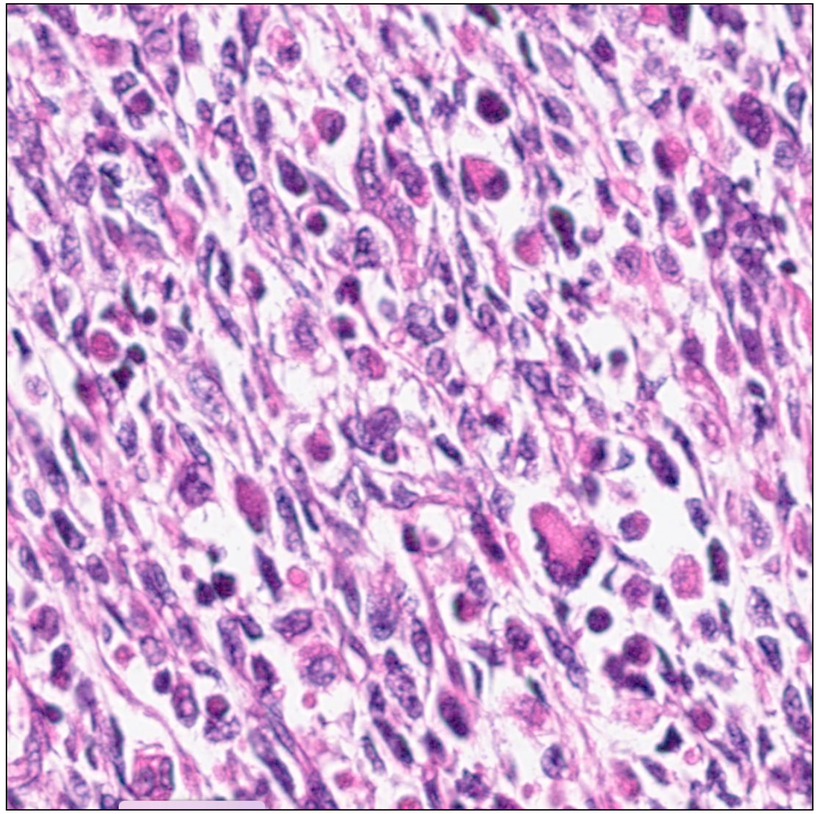

Rhabdomyosarcoma

How to bring it all together?

Diagnosis

78F, endometrial biopsy

Dedifferentiated leiomyosarcoma with extensive heterologous rhabdomyoblastic differentiation

Dedifferentiated leiomyosarcoma

General Points

- ~2-5% uterine leiomyosarcomas
- Dedifferentiated component lacks morphological and immunohistochemical evidence of smooth muscle differentiation

  All three smooth muscle markers negative (SMA, desmin, caldesmon)

- Heterologous differentiation regarded as a form of dedifferentiation
- p53, ATRX, Rb and p16 alterations common, INI1/BRG1 retained
- Significantly shorter 5 year disease-specific (46% vs 36%) and disease-free (42% vs 8%) survival than conventional LMS

Chapel DB, Maccio L, Bragantini E, et al. Dedifferentiated leiomyosarcoma of the uterus: a clinicopathologic and immunohistochemical analysis of 23 cases. Histopathology. 2023 May;82(6):812-825.

	Age	Size (cm)	Heterologous element	Initial Stage	Recurrence	Outcome	Heterologous Element in Primary or Metastasis?
Tran et al (2012)	80	11.4	Osteosarcoma, chondrosarcoma, liposarcoma	III	Present	DOD (24 months)	Metastasis
Rawish et al (2012)	48	18	Osteosarcoma	I	Present	AWD (8 months)	Metastasis
Parikh et al (2015)	60	20	Osteosarcoma	I	-	Lost to follow-up	Primary
	38	12.5	Osteosarcoma	III	-	Lost to follow-up	Primary
Yu et al (2022)	63	11.7	Osteosarcoma	-	Present	DOD (7.5 months)	Metastasis
	40	NA	Osteosarcoma, chondrosarcoma	-	Present	DOD (18 months)	Metastasis
	48	12	Osteosarcoma	-	Present	DOD (6.5 months)	Metastasis
	55	9	Osteosarcoma	-	Absent	DOD	Metastasis
	52	20	Osteosarcoma	-	Present	AWD (36 months)	Metastasis
	61	18	Osteosarcoma	-	Present	DOD (17 months)	Primary
	53	16	Osteosarcoma	-	Absent	DOD (3.5 months)	Primary
	62	18	Osteosarcoma	-	-	-	Primary
	43	17	Osteosarcoma	-	Present	AWD (32 months)	Metastasis
	52	18.8	Osteosarcoma	-	Present	AWD (28 months)	Metastasis
Sadiq et al (2021)	68	4	Chondrosarcoma	I	-	-	Primary
Grant et al (2022)	69	9	**Rhabdomyosarcoma**	III	-	AWD (6 months)	Primary
	81	16	Osteosarcoma	I	-	AWD (8 months)	Primary
Boyraz et al (2023)	58	8	**Rhabdomyosarcoma**	I	Present	-	Metastasis
Chapel et al (2023)	46	12.1	Osteosarcoma	II	Present	DOD (31 months)	-
	63	11.7	Osteosarcoma	IV	Present	DOD (16 months)	-
	52	20	Osteosarcoma, chondrosarcoma	IV	Present	DOD (10 months)	-
Kim et al (2024)	60	-	Chondrosarcoma	I	Present	AWD (93 months)	Metastasis
	55	27.8	**Rhabdomyosarcoma**	I	Present	-	Metastasis
	51	8.9	**Rhabdomyosarcoma**	III	Absent	NED (15 months)	Primary
	51	8.3	Chondrosarcoma	III	Present	-	Metastasis
	63	23	Chondrosarcoma	IV	Present	-	Primary
Zhao et al (2024)	54	7.5	Chondrosarcoma, **rhabdomyosarcoma**	I	-	-	Primary
Our case	**78**	**20**	**Rhabdomyosarcoma**	**IV**	**Present**	**DOD (3.5 months)**	**Primary**

Modified from: Kim S, et al. Dedifferentiated Leiomyosarcoma of the Uterine Corpus with Heterologous Component: Clinicopathological Analysis of Five Consecutive Cases from a Single Institution and Comprehensive Literature Review. Diagnostics (Basel). 2024 Jan 10;14(2):160.

Outcome

- Clinically FIGO stage IVB (palliative procedure)

- Died ~8 weeks post-surgery

Summary

What I learnt from this case…

- Pleomorphic rhabdomyoblasts can be seen in a range of both mesenchymal and mixed epithelial-mesenchymal tumours
- Dedifferentiation as a phenomenon in uterine LMS
  - Requires absence of morphological and immunohistochemical evidence of smooth muscle differentiation
  - Heterologous elements can predominate
  - Associated with aggressive behaviour

Wide sampling may be required to identify the diagnostic features

Manchester University
NHS Foundation Trust

Thank you for listening!

Any questions?

Thanks to:

- Dr A Haider and Dr P Shenjere (GMOSS input)
- Dr D Baishnab (carcinosarcoma case)