The British Association of Gynaecological Pathologists

bsccp | The British Society for Colposcopy and Cervical Pathology



Tanya Alan FRCPath

Consultant Gynaecological Histopathologist at University College London Hospital.

Lead histopathologist for the cervical screening service and CSPL (Cervical Screening Programme Lead) for UCLH.

Reporting gynae cytology at the Cervical Screening London laboratory.

The British Association of Gynaecological Pathologists

bsccp | The British Society for Colposcopy and Cervical Pathology

Basic Cervical Histopathology Course

- Cancer audit - histopathology
- Dr Tanya Alan
- University College London Hospital NHS Trust, London
- 26.02.25

The British Association of Gynaecological Pathologists

bsccp | The British Society for Colposcopy and Cervical Pathology

Speaker disclosures

I have no financial conflicts of interest to disclose

National invasive cervical cancer audit - GOV.UK (www.gov.uk)

(updated 29.09.21, applies to cases diagnosed from 01.10.21

previous editions of guidance available online)

Cervical screening: disclosure of audit results toolkit - GOV.UK (www.gov.uk)

Cervical screening: invasive cervical cancer audit 2016 to 2019 - GOV.UK (www.gov.uk)

Purpose of invasive cervical cancer audit

The purpose of audits is to:

- monitor quality and effectiveness of the NHS CSP
- compare the screening histories of individuals who develop cervical cancer with those who do not
- identify areas of good practice and show where quality improvements might be made
- support learning and development for organisations and the NHS CSP
- make sure people are given information about their screening history review (if they wish to receive it)

All parties in the NHS Cervical Screening Programme must follow the same national protocol for auditing cases of invasive cancer.

Organisations providing screening services take responsibility for undertaking nationally required audits of screening histories in a timely way, and for offering screening participants disclosure of their audit results in line with nationally published guidance and the screening service specifications.

Process of invasive cervical cancer audit

- The diagnosing organisation is responsible for co-ordinating the audit data collection – usually histological diagnosis.
- A review of all records connected to an individual's cervical screening history from the past 10 years should be undertaken (cervical screening test, colposcopy attendance, histology samples).
- The CSPL at the diagnosing organisation is responsible for co-ordinating the audit by organising and collating the review results (local policy in line with national guidance).
- Cases should be reviewed based on the guidance in place at the time the case was diagnosed.
- The review is undertaken in line with requirements set out in NHS CSP guidance and is for education and audit purposes. It is not undertaken as a medico-legal review, which is a different approach and would be done to a different set of standards.

Histological slide review

Lead consultant in cervical histology

The lead consultant in cervical histology in laboratories holding histology cases is responsible for:

- co-ordinating the required cervical histology reviews or identifying a co-ordinator to do this on their behalf
- making sure that an appropriately experienced pathologist or consultant biomedical scientist who has not previously authorised the specimen report, where possible, undertakes the reviews (SQAS will provide support in identifying a location for a review to take place when this is not possible due to very small numbers of staff)
- reporting outcome of reviews in the required timeframe to the requesting CSPL (audit to be completed within 6 months from diagnosis, review and disclosure to be completed within 12 months from diagnosis)

Histological slide review

- Includes cervical biopsies and cervical excisions.
- The screening history of the individual will help indicate when and where an individual was referred for colposcopy and therefore when and where histology specimens were likely to have been taken.
- All relevant histology samples taken over the 10 years before diagnosis must be reviewed, with the exception of the diagnostic sample and any samples taken after the diagnostic sample.
- Best practice is for the reviewer not to have reported the specimen originally. The reviewer must have access to the original report.
- The review prepared for the gynaecological cancer MDT meeting as part of the NHS CSP audit of invasive cervical cancers may be used – providing the above criteria is met.
- Only existing slides should be reviewed. There is no need to cut new sections.
- The review should also include a macroscopic examination of any blocks if there is any suggestion that all pieces have not been cut into or where there is a clear discrepancy found in the review.

External reviews not required

There is no longer a requirement to arrange for external reviews of cytology, histology samples, or colposcopy cases for routine audit purposes. However, SQAS may request that additional reviews are completed outside of the audit process. This might be:

- where there are potential concerns about quality of care
- to investigate unusual themes arising from the audit results

SECTION D HISTOLOGY

STUDY ID: EX/QAX/2022/1361

HISTOLOGY HISTORY

PART D1. CANCER DIAGNOSIS

Laboratory name	Specimen ID	Date of Specimen DD	MM	YYYY	Type of Specimen Codes 1 to 8	Evidence of TZ sampling? (Y/N/NA)	Pathological Diagnosis (Up to three diagnosis are allowed per specimen)			Excision status	If complete excision: Distance to closest margin	If incomplete excision: Excision margin (1)	Margin involved by	Excision margin (2)	Margin involved by	Excision margin (3)	Margin involved by	If invasive: Lymphovascular space invasion (Y/N/NA)
The Princess Alexandra Hospital					3.LLETZ (loop)	Y	4.Squam carcinoma-NOS		2.3 CIN3	2.Incomplete		1.Ecto	2.CIN					N

Provisional Pathological FIGO Stage (2018): 1A2 (Codes 1A to 1B+)

Number of histology specimens found for this woman. Enter **X** if NONE: 2

PART D2. PRE DIAGNOSTIC COLPOSCOPIC SPECIMENS-HISTORY (most recent first)

Laboratory name	Specimen ID	Date of Specimen DD	MM	YYYY	Type of Specimen Codes 1 to 9	Evidence of TZ sampling? (Y/N/NA)	Pathological Diagnosis (Up to three diagnosis are allowed per specimen)			Excision status	If complete excision: Distance to closest margin	If incomplete excision: Excision margin	Margin involved by	Excision margin	Margin involved by	Excision margin	Margin involved by	If invasive: Lymphovascular space invasion (Y/N/NA)	Eligible for review
The Princess Alexandra Hospital					1.Cervix Biopsy	Y	2.1 CIN1		2.3 CIN3	3.NA									Y

Day # between 1 and 31

Page 1

CERVICAL SCREENING AUDIT

SECTION F

SECTION F HISTOLOGY REVIEW PRE DIAGNOSTIC SAMPLE

STUDY ID: EX/QAX/2022/1361

PART F1 ORIGINAL **SPECIMEN DETAILS**

Laboratory name	Date of Original Sample DD	MM	YYYY	Type of Specimen Codes 1 to 8	Original Pathological Diagnosis (Up to three diagnosis per specimen are allowed)			Specimen ID	Eligible for review
The Princess Alexandra Hospital				1.Cervix Biopsy	2.1 CIN1	2.3 CIN3	0		Y

PART F2 HISTOLOGY REVIEW RESULTS (please enter one line per reviewer)

Slide not available for review | Details

1 — In how many pieces was the specimen received ?

Biopsy size (Length x Width x Depth) in mm: 5 x [ ] x [ ]

Page 1

Review type 1.First 2.External	Date of Review DD	MM	YYYY	Type of Specimen Codes 1 to 8	Evidence of TZ sampling? (Y/N/NA)	Pathological Diagnosis (Up to three diagnosis are allowed)			Excision status	If complete excision: Distance to closest margin	If incomplete excision: Excision margin	Margin involved by	Excision margin	Margin involved by	Excision margin	Margin involved by	If invasive: Lymphovascular space invasion (Y/N/NA)	Additional features
1.First	18	4	2023	1.Cervix Biopsy	Y	2.3 CIN3	2.1 CIN1											

PART F4. **Disclosure classification** following review

Management	Reason 1 (Please only include for 'satisfactory with learning' and 'unsatisfactory' classification)	Reason 2 (Please only include for 'satisfactory with learning' and 'unsatisfactory' classification)	Reason 3 (Please only include for 'satisfactory with learning' and 'unsatisfactory' classification)	Other (Please only include for 'satisfactory with learning' and 'unsatisfactory' classification)
Satisfactory				

The Princess Alexandra Hospital NHS
NHS Trust

Princess Alexandra Hospital
Hamstel Road
Harlow, Essex
CM20 1QX
Tel: 01279 827094

Mr Ghazi / Ms Antoniades
Consultant Gynaecologist / Lead Colposcopist
Princess Alexandra Hospital
Hamstel Road
Harlow
CM20 1QX

Date:

Ref: SA/CF

Dear Mr Ghazi / Ms Antoniades

Re: Cervical cancer audit for

The above audit is now completed. The audit has been carried out in accordance with the Public Health England guidance 'National invasive cervical cancer audit', last updated September 2021. See below, for a summary of the review outcome process.

REVIEW RESULT

Section A – personal and cancer details	
Date of diagnosis of cancer	
Stage of tumour (FIGO 2018)	1A2
Histology type	HPV-associated squamous cell carcinoma
Treatment received	Loop biopsy cervix, knife cone biopsy cervix, bilateral sentinel lymph node excision

Section B – Cytology history: 2 samples	
Open Exeter Screening Database	
	Borderline change in squamous Cells (HPV) – HPV Positive, Suspend recall pending referral
	Negative, Routine Screening

Section C – Colposcopy 2 episodes
Colposcopist opinion was of CIN 2, loop biopsy performed
Colposcopist opinion was of low grade changes, punch biopsy performed

Section D – Histology History: 2 specimens	
Laboratory database	
	Loop biopsy cervix - Squamous cell carcinoma
	Cervical Punch – CIN 1 and CIN 3

Section E – Cytology review.		
Date/slide number	**Original report**	**Review result**
	Borderline changes in squamous cells, HR HPV positive	High-grade(severe) Disclosure classification: Satisfactory with learning points. Comments:
		Hyperchromatic crowded groups (HCGs) LMP 6 days ago
	Negative	Borderline changes in squamous cells Disclosure classification: Satisfactory with learning points. Comments: Low abnormal cell numbers (less than 50 cells in a liquid-based cytology (LBC) sample) Borderline changes on review in the absence of any definite dyskaryotic changes One group of cells only (surepath case so reviewed at Gateshead)

Section F – Histology review.		
Date/slide number	**Original report**	**Review result**
	Punch biopsy of cervix containing CIN1 and CIN3	Punch biopsy of cervix containing CIN1 and CIN3 Disclosure classification: Satisfactory

SUMMARY
To summarise, this is a case of screen detected cervical cancer.

There were two screening tests on record for . The first, in 2019, had been reported as negative. The most recent, in 2022, contained HR HPV and was reported as 'borderline changes in squamous cells'. She was referred for colposcopic examination, where the impression was of low grade CIN and a punch biopsy was performed. The punch biopsy contained CIN1 and CIN3, so a loop biopsy was performed.

The loop biopsy contained HPV-associated squamous cell carcinoma which measured 10.5mm in horizontal dimension and invaded to a depth of 3.5mm. Lymphovascular invasion was not identified. Carcinoma was <1mm from the ectocervical and deep lateral margins.

A knife cone biopsy was performed at UCLH and this contained CIN1 (clear margins). Bilateral sentinel lymph node excision was negative (0/1 right, 0/1 left).

She is now under observation.

Review findings
Cytology
Both cytology samples were eligible for review. Review of the 2019 sample indicated borderline changes in squamous cells. Review of the 2022 sample indicated severe dyskaryosis. Qualifying comments were provided by reviewers as documented above in the summary table.
Disclosure classification: satisfactory with learning points

Histology
One sample was eligible for review (punch biopsy cervix). Review findings were in agreement with the original report.
Disclosure classification: satisfactory

There were no colposcopic episodes eligible for review.

If you have any questions regarding this case or the review process, please do not hesitate to contact me. If feedback to the patient and/or relatives is required I will be available.

Yours sincerely

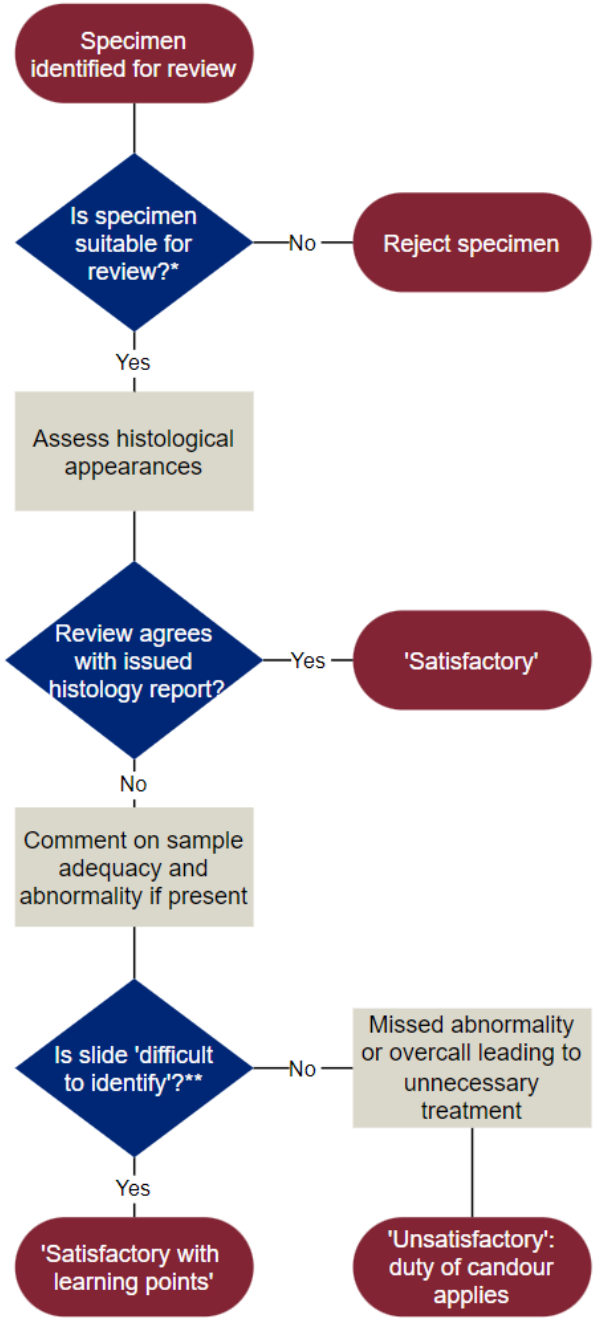

* Slides may become technically inadequate for diagnostic use - for example a broken slide, 'dry back' of mountant with age or air bubbles. An unsuitable slide does not necessarily reflect the technical quality of the slide at the original time of reporting, but may well materially affect the review process.

** Bear in mind knowledge at the time of the original report

Cervical histology slide review classifications

Satisfactory

A ‘satisfactory’ classification is one which, on review, agrees with original pathology report and no material differences are found that would have affected management at the time of the original report.

Cervical histology slide review classifications

Satisfactory with learning points

This classification, on review, shows minor differences or learning points that would not have materially affected the report and management at the time of the original report, but which are of educational value.

This includes issues such as:

- under or over use of stains, levels, or other ancillary techniques
- inappropriate use of stains, levels, or other ancillary techniques
- clarity of pathological information could have been better
- inappropriate stage based on pathology report information (which would have been clarified and resolved at colposcopy multi-disciplinary team (MDT) meeting discussion)
- a difficult case where there is acceptable and appropriate professional disagreement
- the specimen is not considered to be satisfactory for diagnostic purposes, for example does not contain appropriate tissue
- a low grade or negative lesion called high grade (for both cervical intraepithelial neoplasia (CIN) and cervical glandular intraepithelial neoplasia (CGIN)

Cervical histology slide review classifications

Unsatisfactory

This classification, on review, has significant differences identified that would have affected patient management at the time of the original report.

Reasons for an unsatisfactory classification may include:

- a high grade lesion called low grade or negative (for both cervical intraepthelial neoplasia (CIN) and cervical glandular intraepithelial neoplasia (CGIN))
- missed invasive cancer (of any size, type or stage)
- undercall of an invasive lesion as not invasive
- overcall of a non-invasive lesion as invasive
- incorrect tumour classification that would have resulted in different management, for example, sarcoma, lymphoma, missed small cell carcinoma, non-identification of metastatic disease

‘We suggest that all situations where the outcome of the screening history review is ‘satisfactory with learning points’ or ‘unsatisfactory’ are recorded on organisational reporting systems.’

‘Unsatisfactory’ classifications fall under duty of candour.

Audit classifications of ‘unsatisfactory’ must be agreed as such by at least 2 senior consultants who are actively reporting histology for the NHS CSP and meet the standards set out for the programme.

Any questions?

