The British Association of Gynaecological Pathologists

# Lecturer – Dr Jason Wong



- BAGP President
- Lead for gynaecological pathology at Ipswich Hospital, ESNEFT, UK
- Former organiser of the UK Gynaecological Pathology EQA scheme
- Former member of ISGyP LiVE working group

The British Association of Gynaecological Pathologists

# Basic Cervical Histopathology Course

- Normal histology and cut up issues for LLETZ/Cone biopsies
- Dr Jason Wong
- Ipswich Hospital, ESNEFT
- 26th February 2025

The British Association of Gynaecological Pathologists

# Speaker disclosures

- ❑ I have no financial conflicts of interest to disclose

# Biopsies

- Adequacy:
- To be called normal, a biopsy must be:
  - Technically adequate
  - Include epithelium of interest
  - >2mm

# LLETZ

- How to recognise the transformation zone
- Other histological features
- How my BMSs cut up a LLETZ
- Why you might ink a LLETZ
- Reporting of margin status

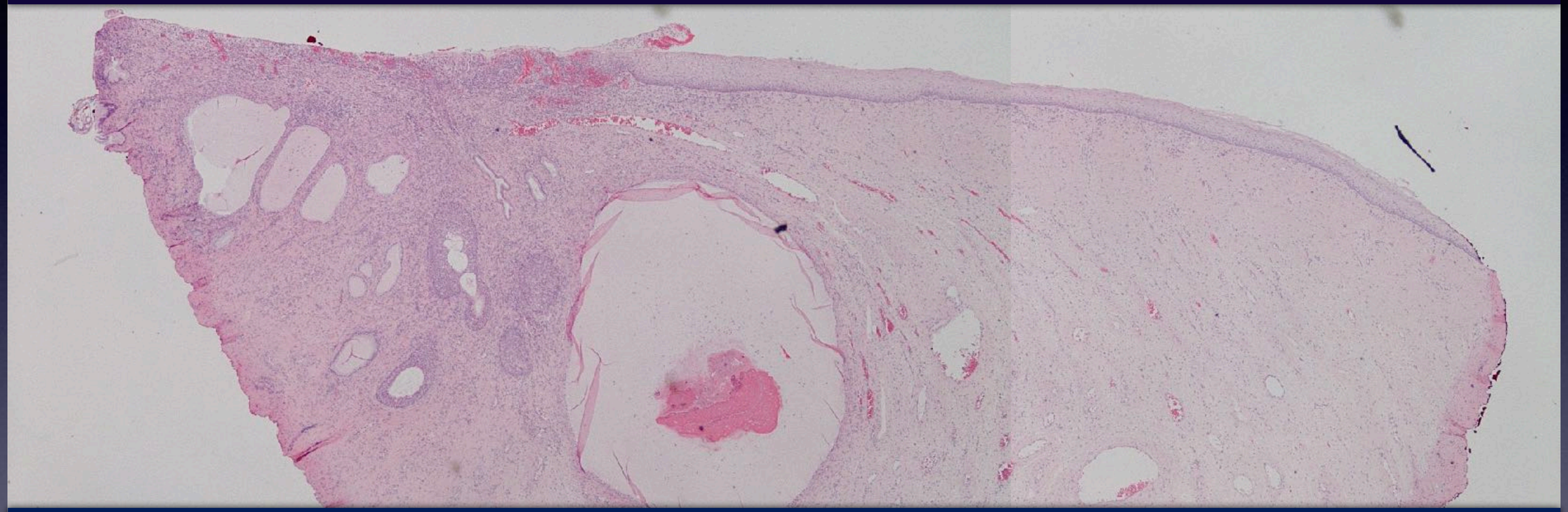

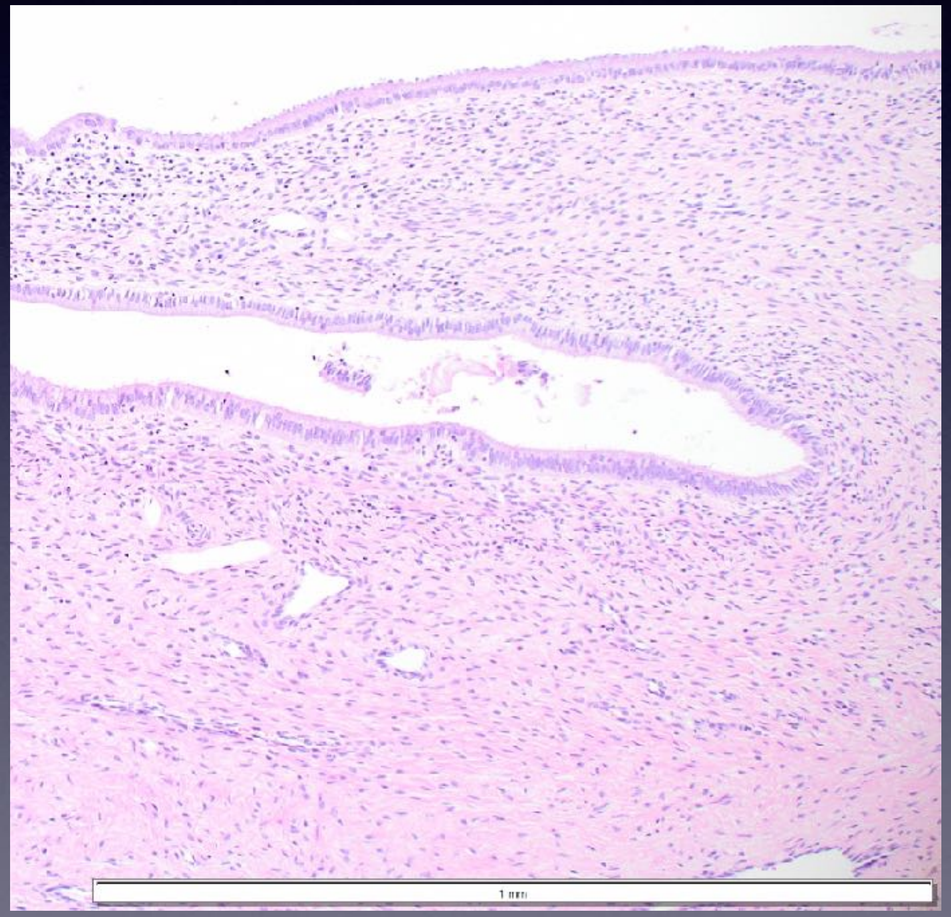
1 mm

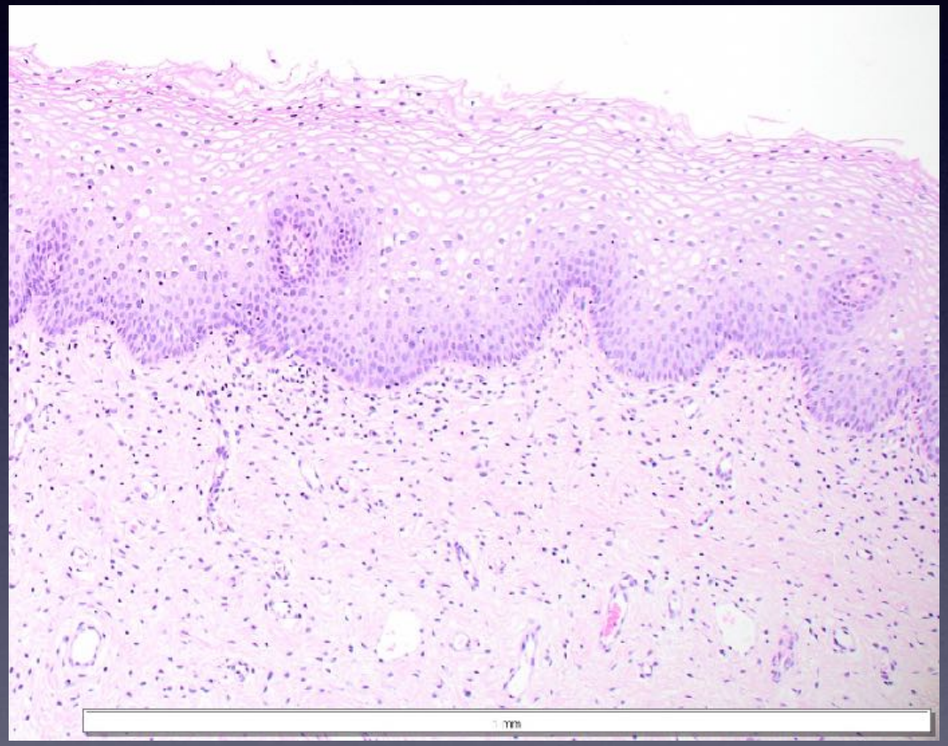
1 mm

# How do you recognise the Transformation Zone?

- “I have been reviewing cases for the colp MDT and I am finding a lot of variation in what is acceptable for reporting the presence of transformation zone”

# Case 1

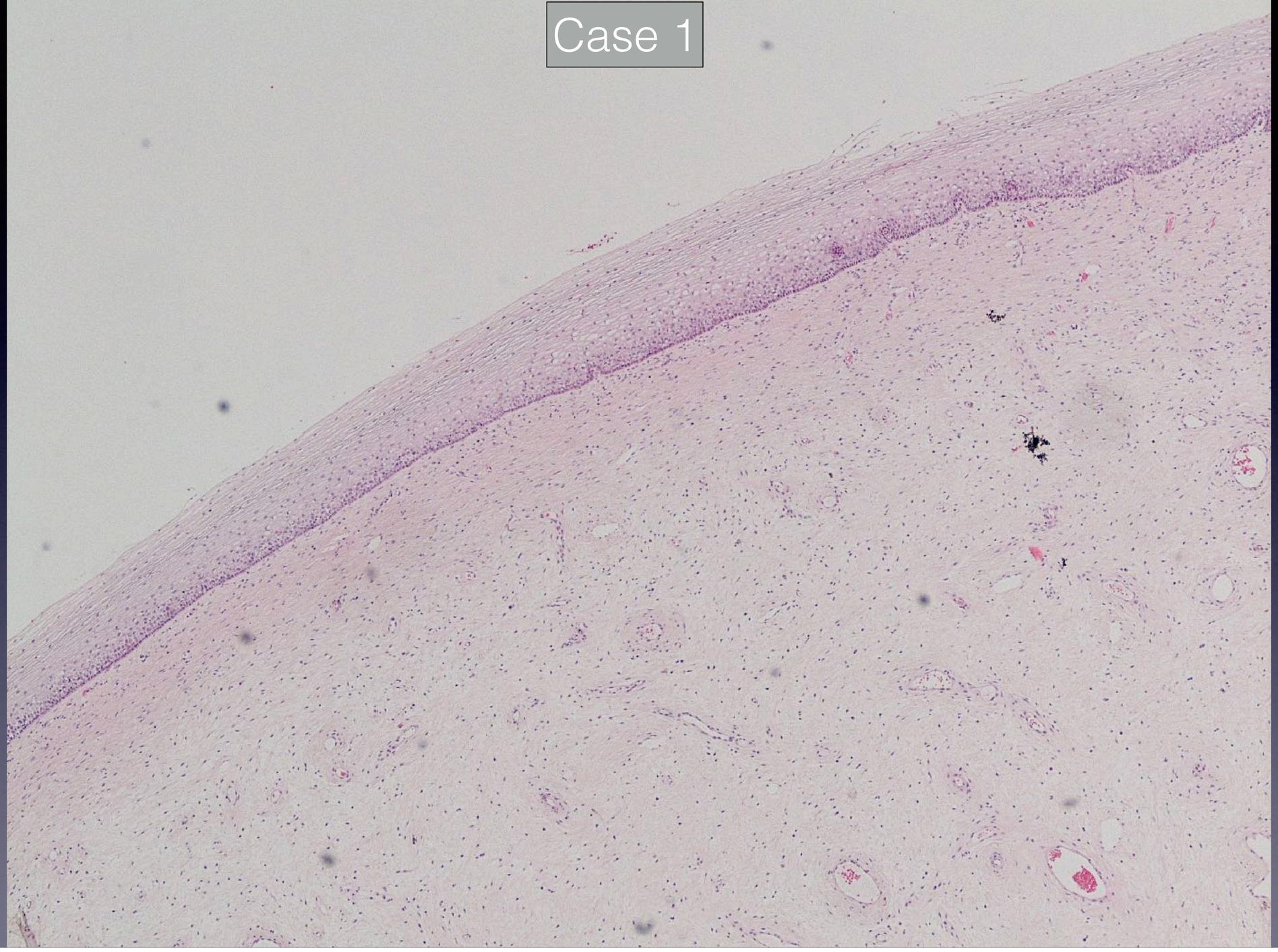

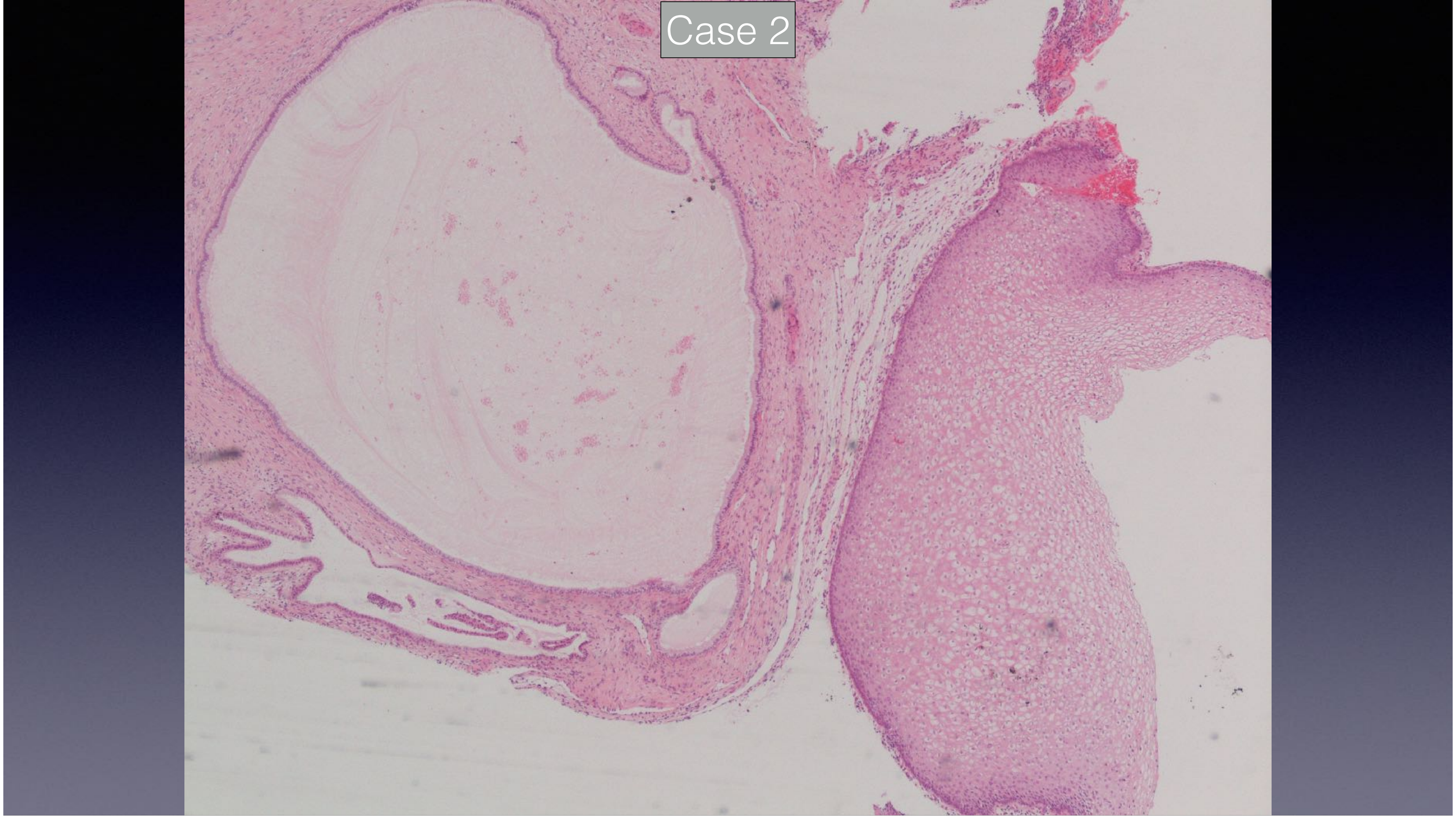
Case 2


Case 3

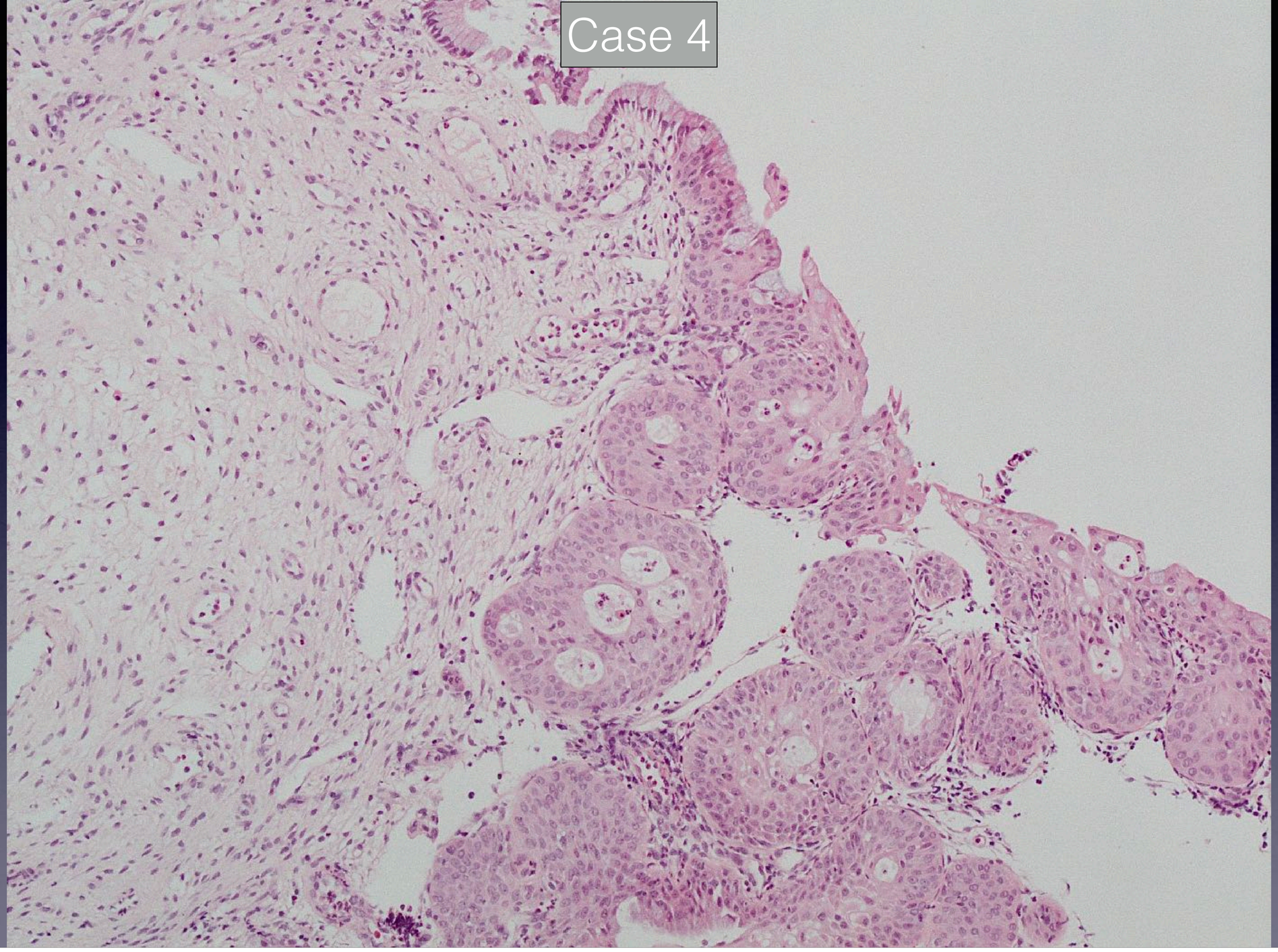
Case 4

# Audit of the histological definition of cervical transformation zone

**P Mukonoweshuro, A Oriowolo, M Smith**
Department of Histopathology, Level 4, Derriford Hospital, Plymouth PL6 8DH, UK;
pinini@doctors.org.uk

*J Clin Pathol* 2005;**58**:670–672

(A) Surface squamous epithelium in continuity with surface columnar epithelium (squamo–columnar junction) only.

(B) Surface squamous epithelium with surface columnar epithelium or stromal gland/crypt, or both.

(C) Surface squamous epithelium only.

(D) Surface columnar epithelium only.

(E) Surface columnar epithelium with squamous (metaplastic) epithelium in gland/crypt.

**Table 1** Questionnaire results

| Option/s | Responses | % |
|---|---|---|
| A | 13 | 15.9 |
| B | 46 | 56.1 |
| C | 0 | 0 |
| D | 0 | 0 |
| E | 2 | 2.4 |
| All | 1 | 1.2 |
| None | 5 | 6.1 |
| Combinations* | 15 | 18.3 |
| Total | 82 | 100 |

*See table 2.

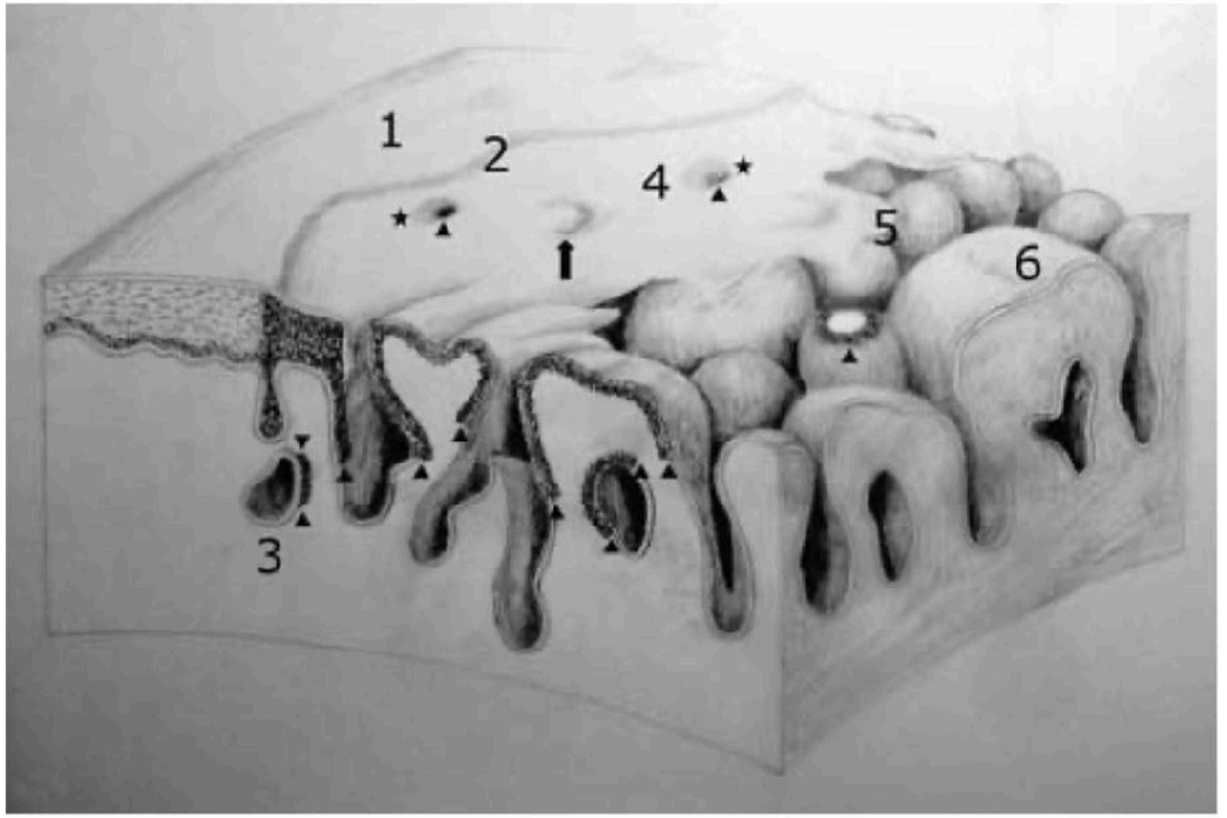


**FIG. 1.** Schematic illustration of the human cervix with types of epithelium, transformation zone, original, and new squamocolumnar junction (SCJ). The original squamous epithelium (1) is a

*International Journal of Gynecological Pathology*
00:1–6, Lippincott Williams & Wilkins, Baltimore
Copyright © 2017 by the International Society of Gynecological Pathologists

Original Article

# Defining the Cervical Transformation Zone and Squamocolumnar Junction: Can We Reach a Common Colposcopic and Histologic Definition?

Olaf Reich, M.D., Sigrid Regauer, M.D., W.G. McCluggage, M.D., Christine Bergeron, M.D., and Charles Redman, M.D.

| Definition | Agreed [n (%)] |
|---|---|
| The TZ is where squamous metaplasia occurs. It extends from the original nonkeratinizing squamous epithelium of the ectocervix to the mucin-producing columnar epithelium of the endocervix. The columnar epithelium underneath the metaplastic epithelium is part of the TZ | 11 (32) |
| The TZ is where squamous metaplasia occurs. It extends from the original nonkeratinizing squamous epithelium to the mucin-producing columnar epithelium of the cervix. The columnar epithelium underneath the metaplastic epithelium is *not* part of the TZ | 10 (29) |
| The TZ is the zone in which transformation *will potentially* occur. It is characterized by the presence of metaplastic squamous epithelium, which may extend not only across the ectocervix but also to within the cervical canal (10) | 3 (9) |
| The TZ is the zone between the original and current SCJ and the area around that junction where the epithelium is thinnest (3) | 1 (3) |
| The TZ consists of surface squamous epithelium in continuity with surface columnar epithelium (SCJ) (11) | 1 (3) |

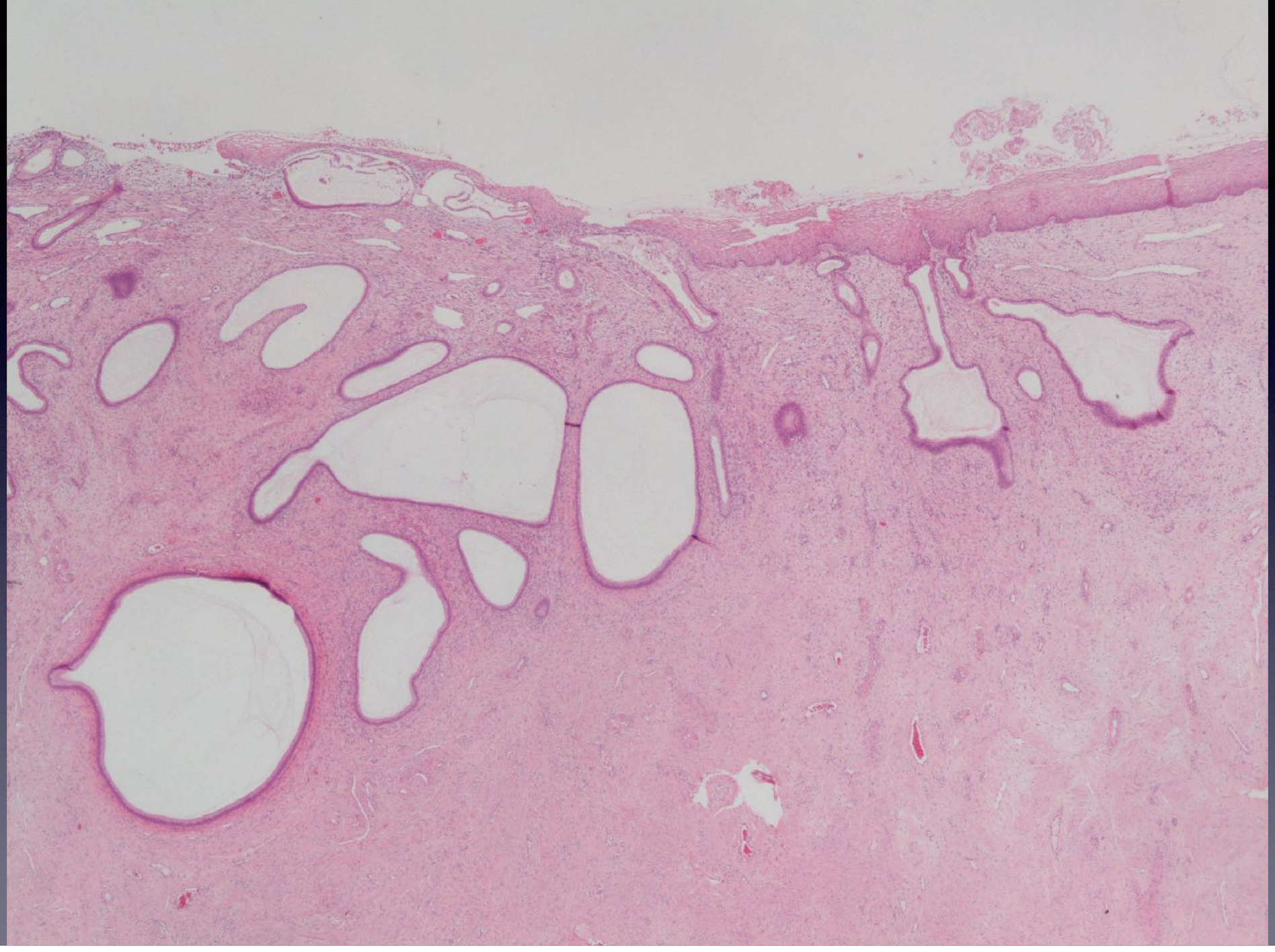

# LLETZ

- How to recognise the transformation zone
- Other histological features
  - Microglandular hyperplasia
  - Mesonephric remnants
  - Decidua
- How my BMSs cut up a LLETZ
- Why you might ink a LLETZ
- Reporting of margin status

# Microglandular hyperplasia

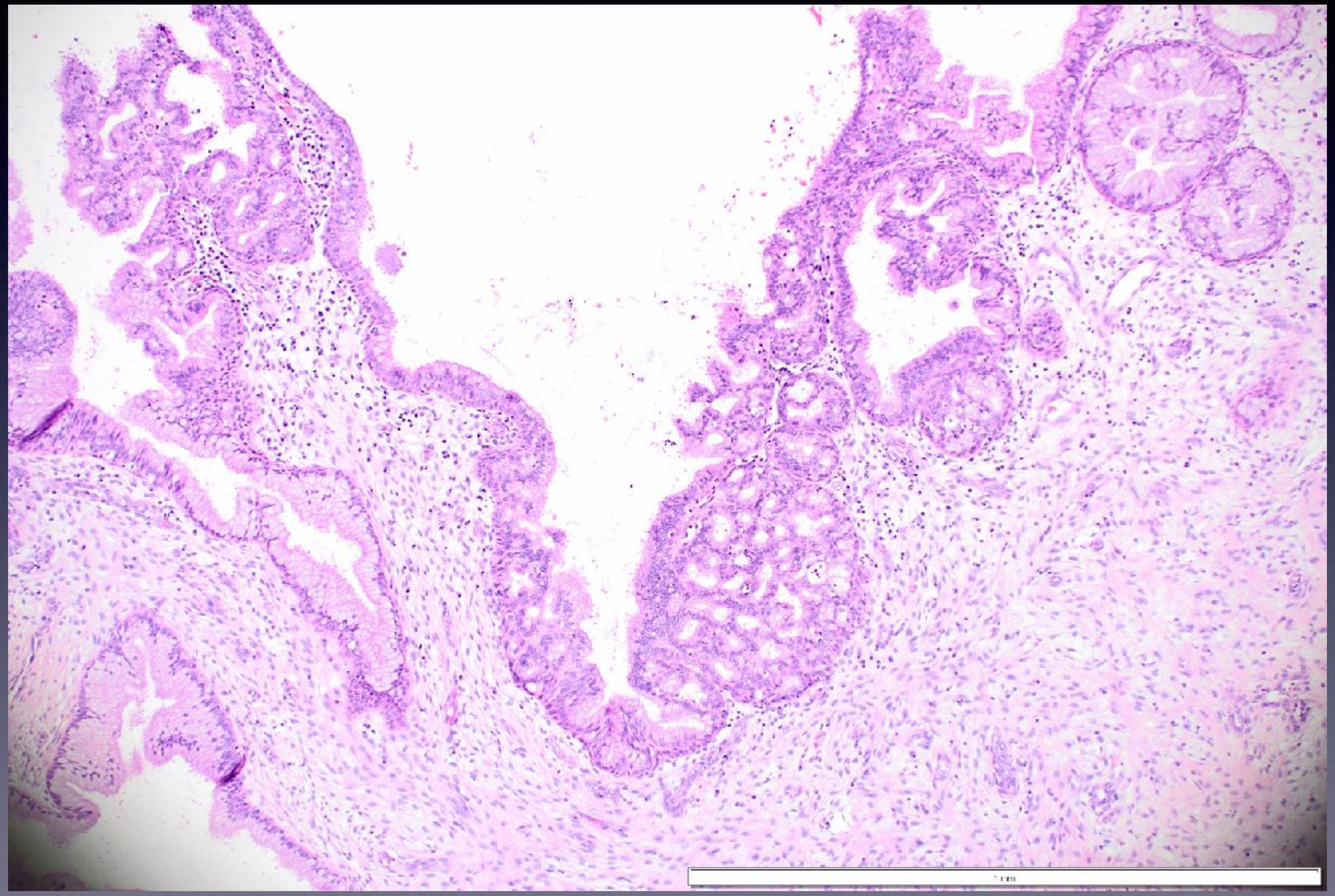

# Microglandular hyperplasia

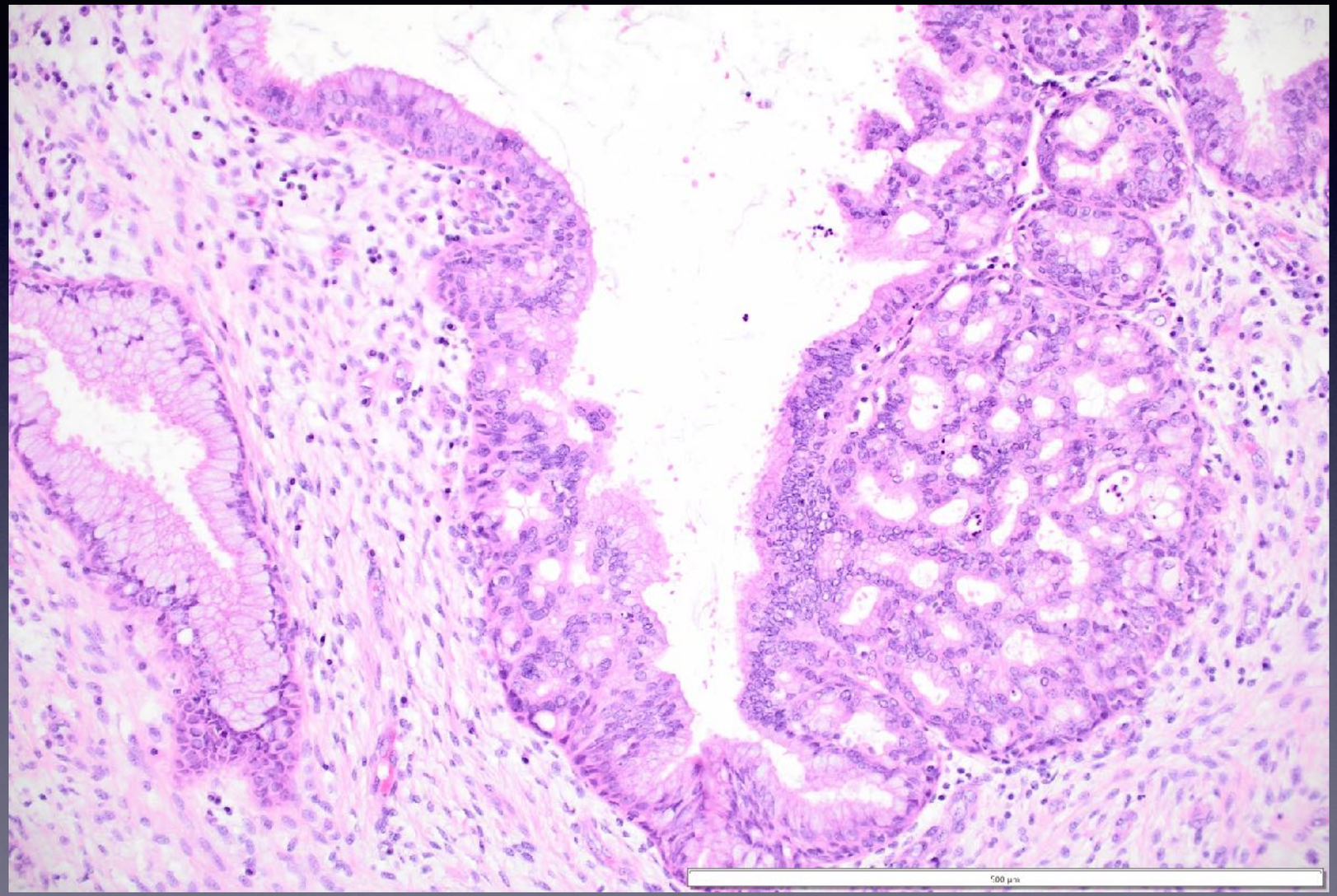

# Microglandular hyperplasia

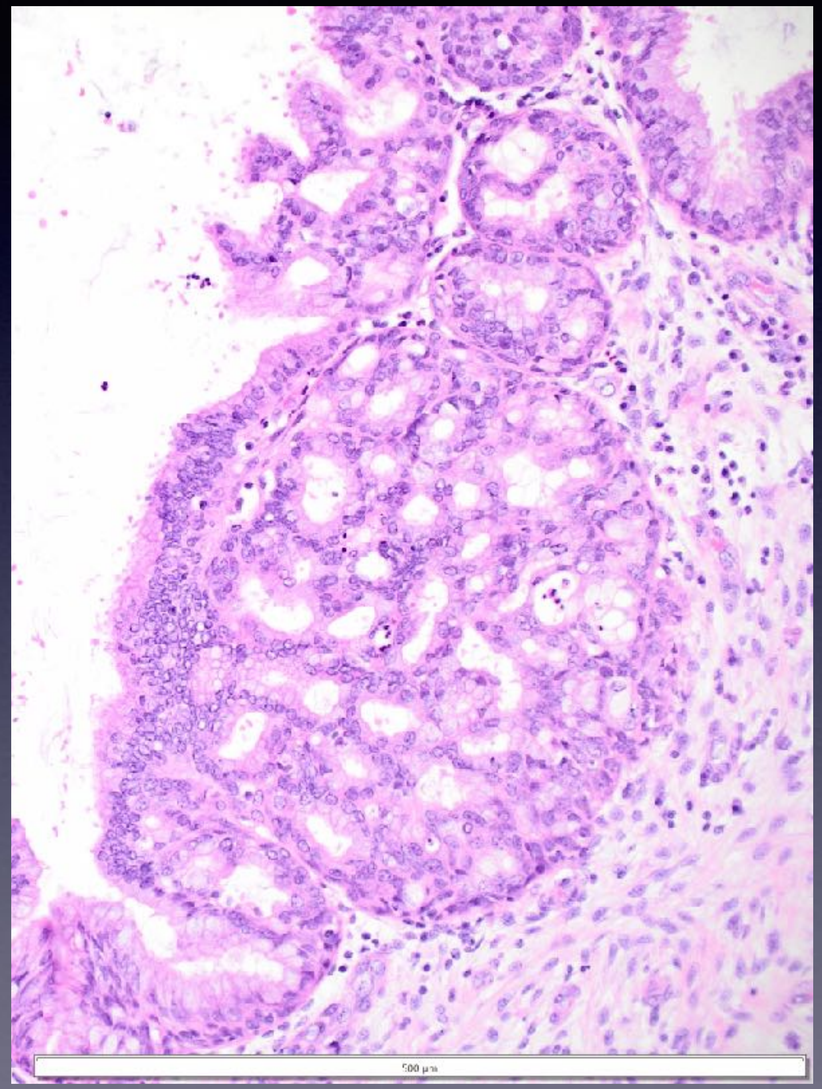


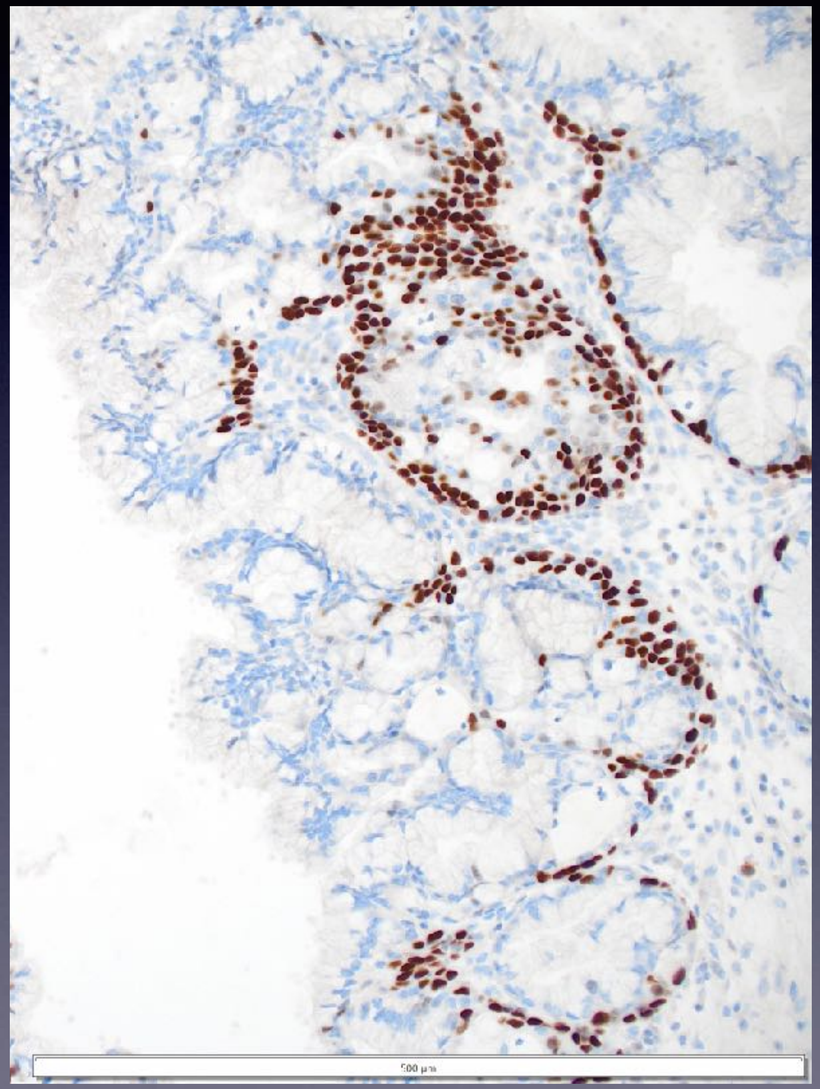

# Microglandular hyperplasia

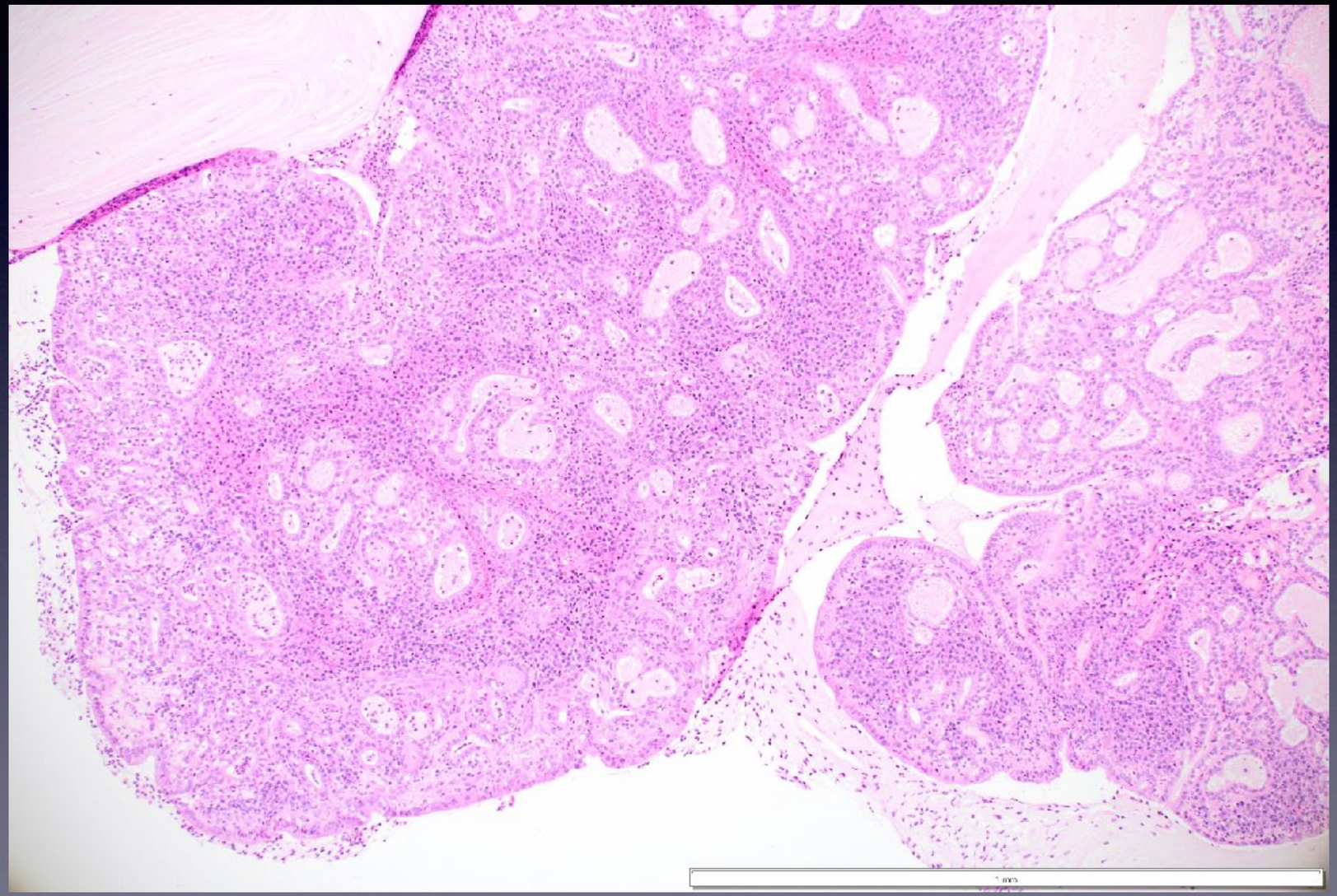

# Microglandular hyperplasia

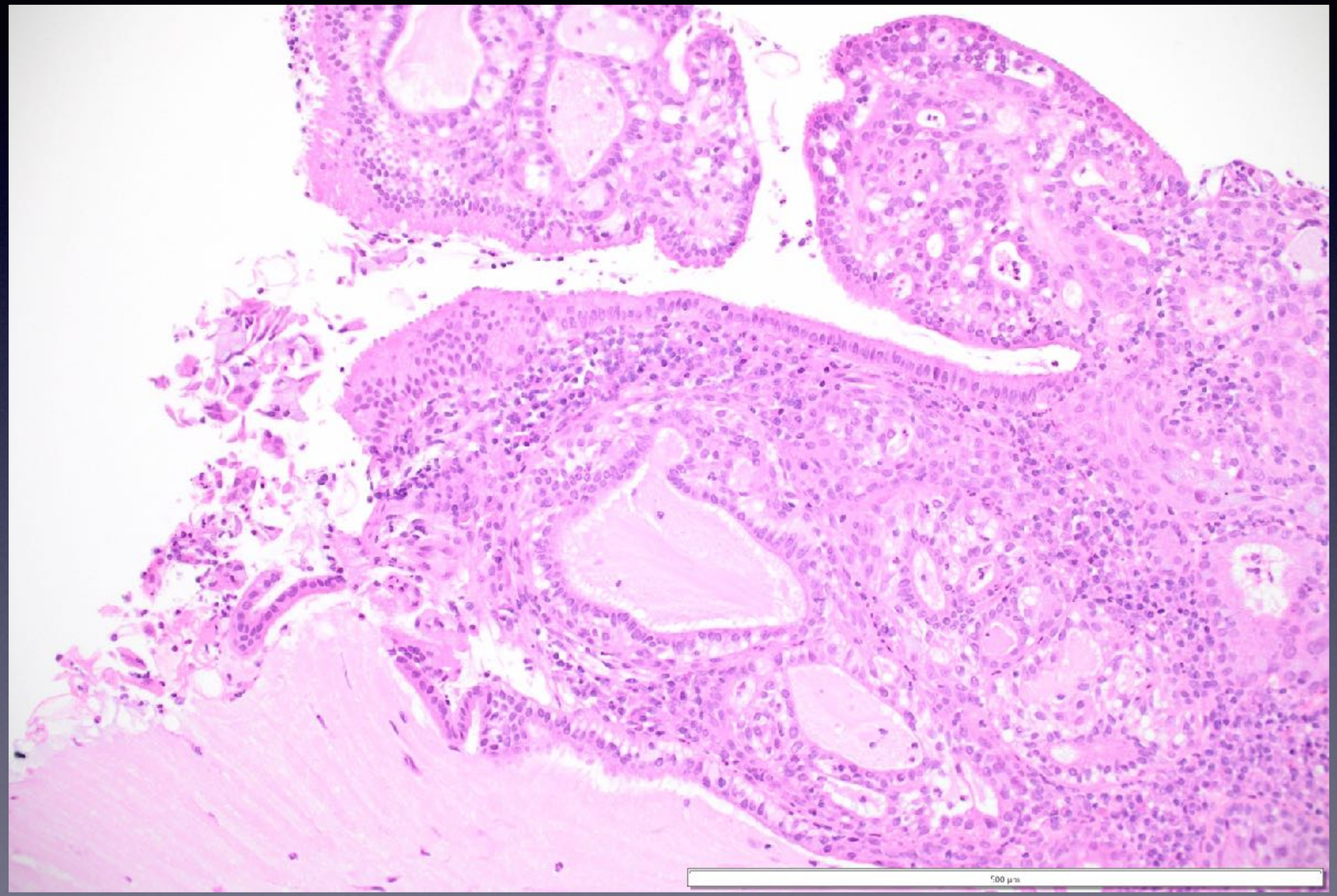

# Mesonephric remnants

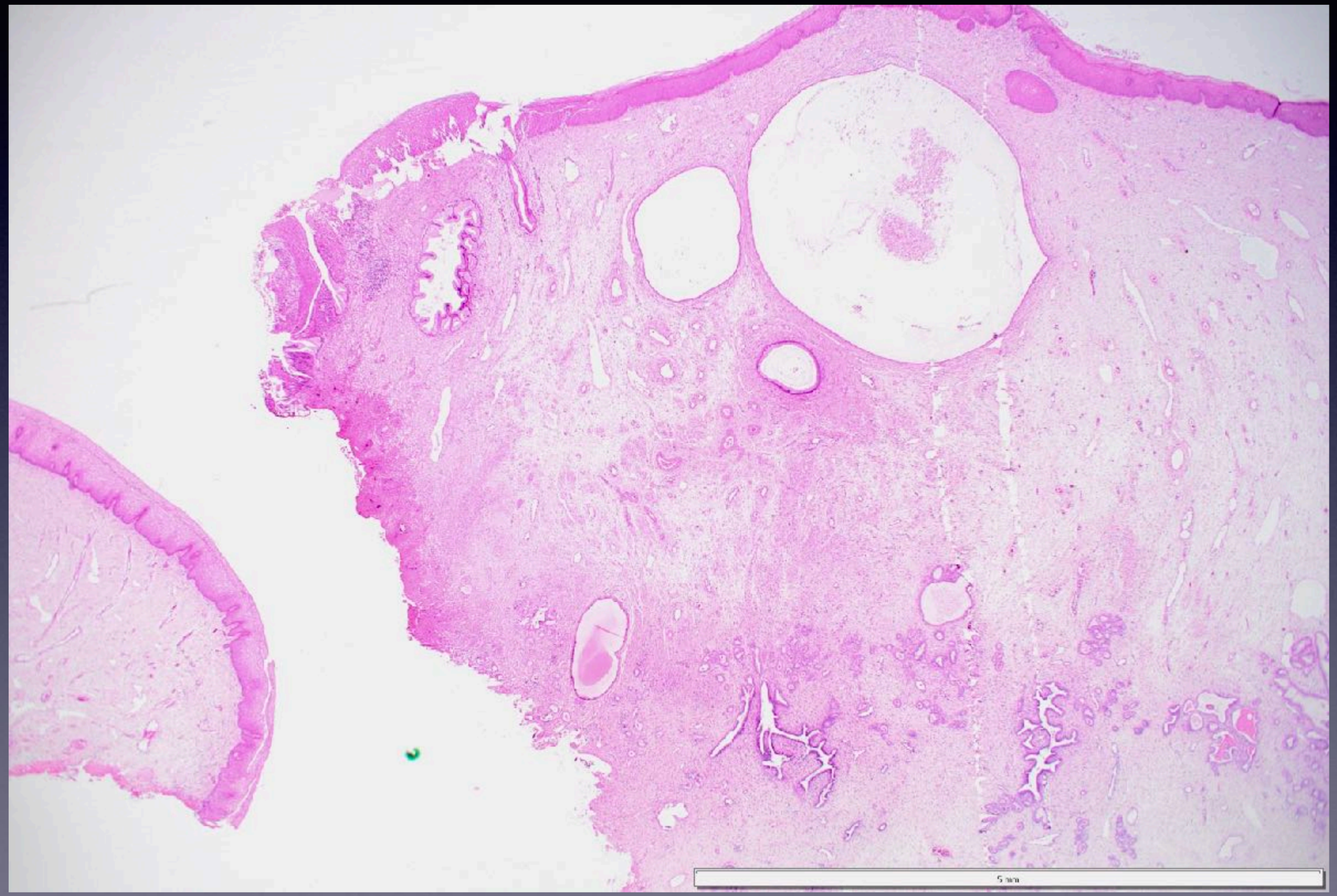

# Mesonephric remnants

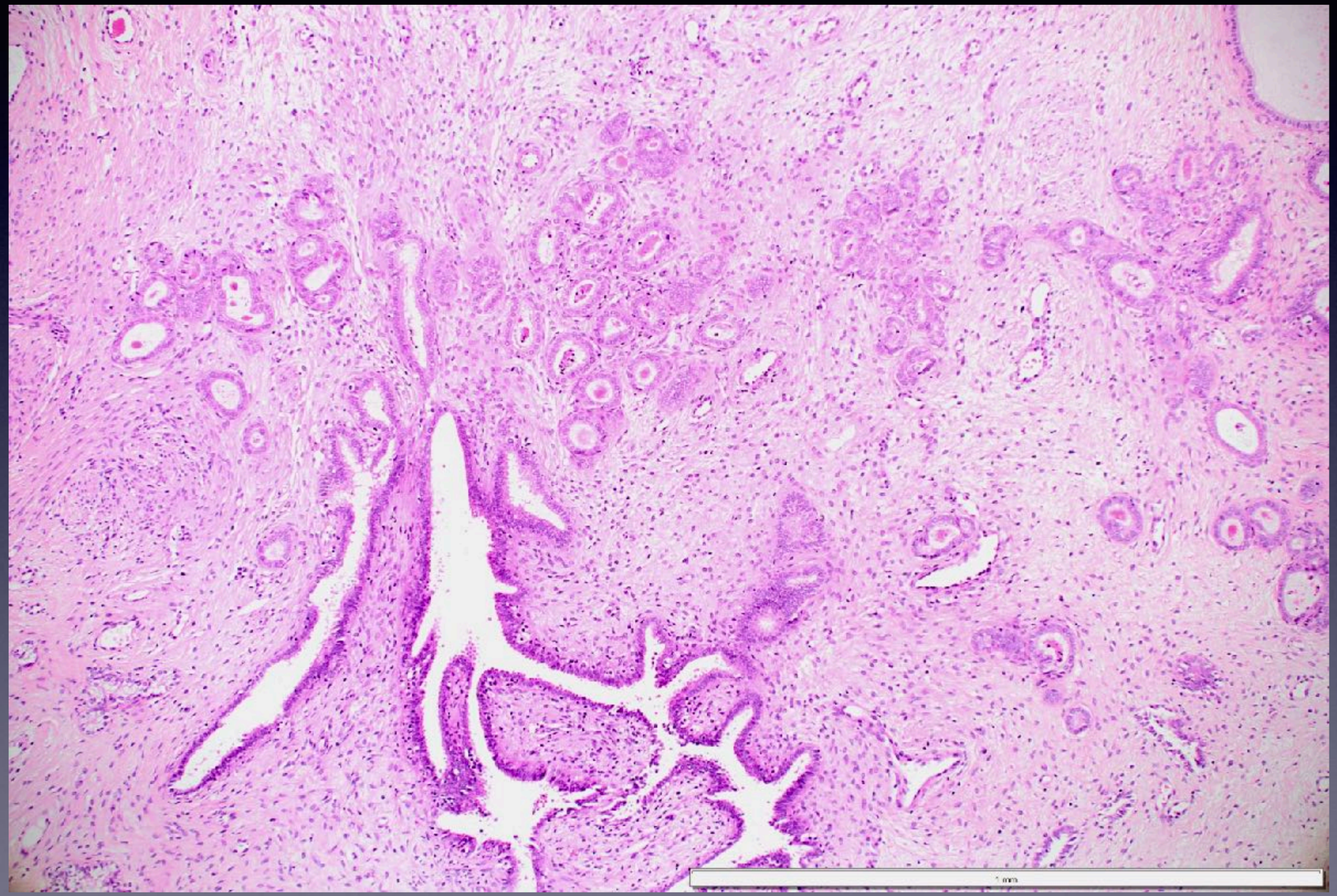

# Mesonephric remnants

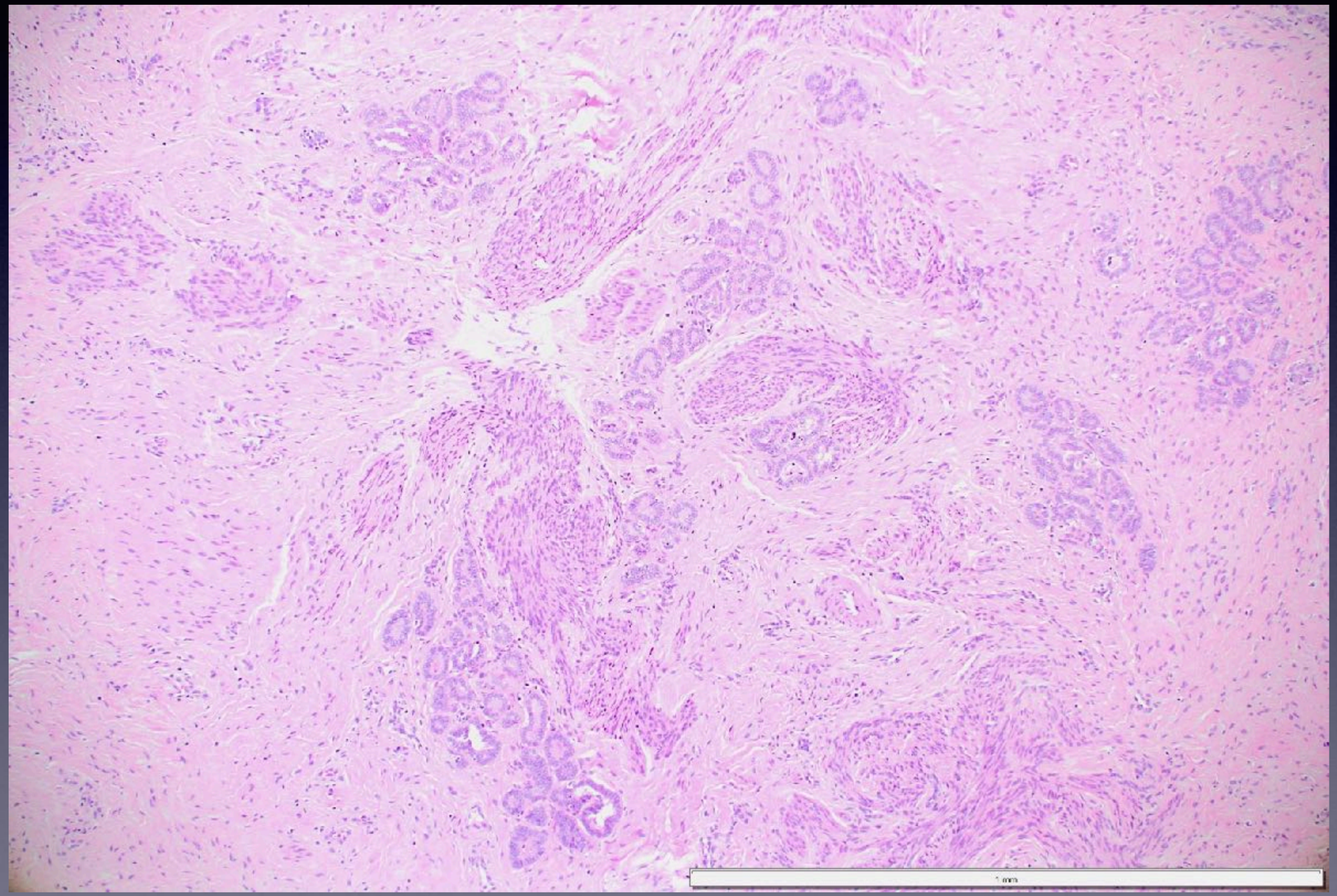

# Decidua

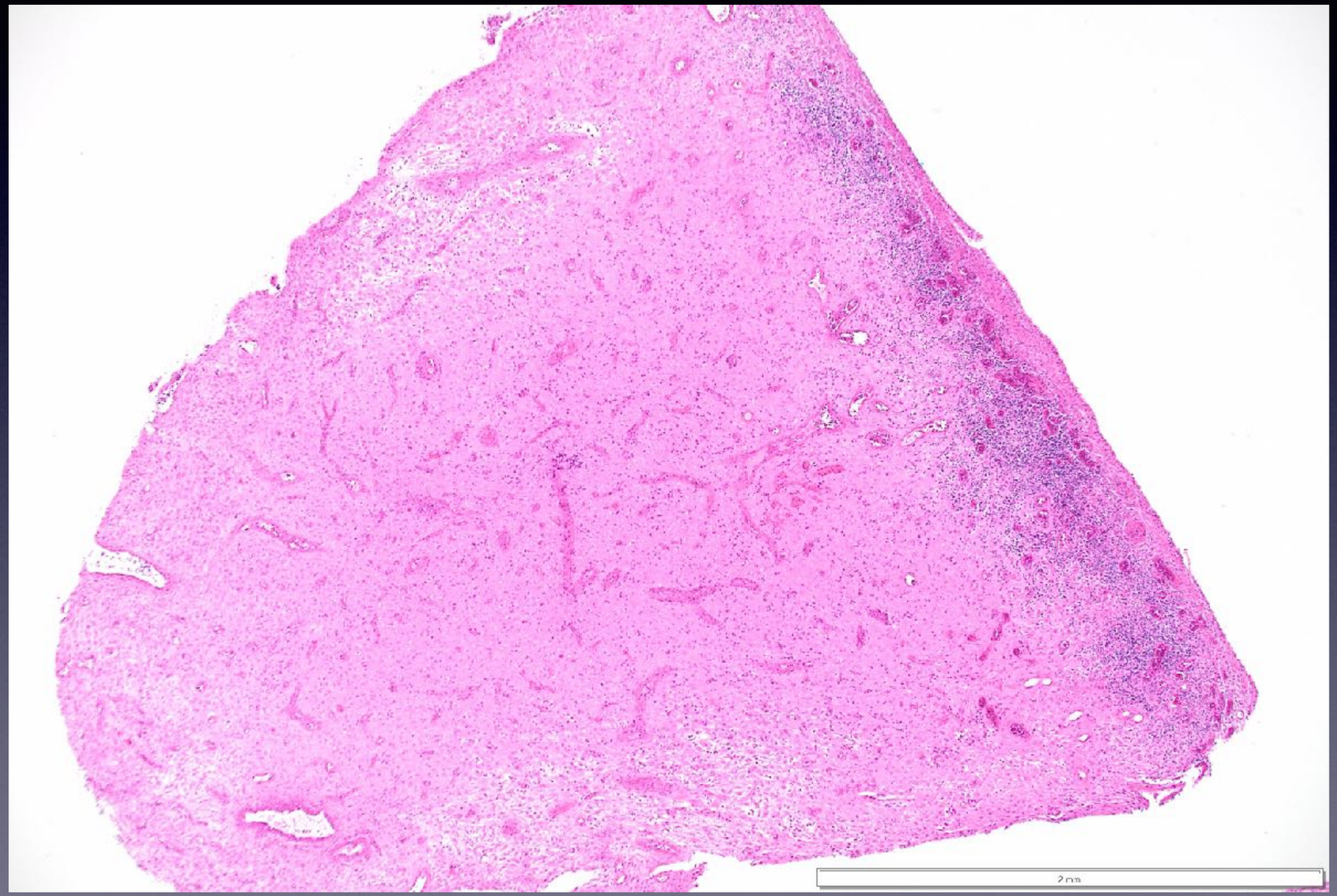

# Decidua

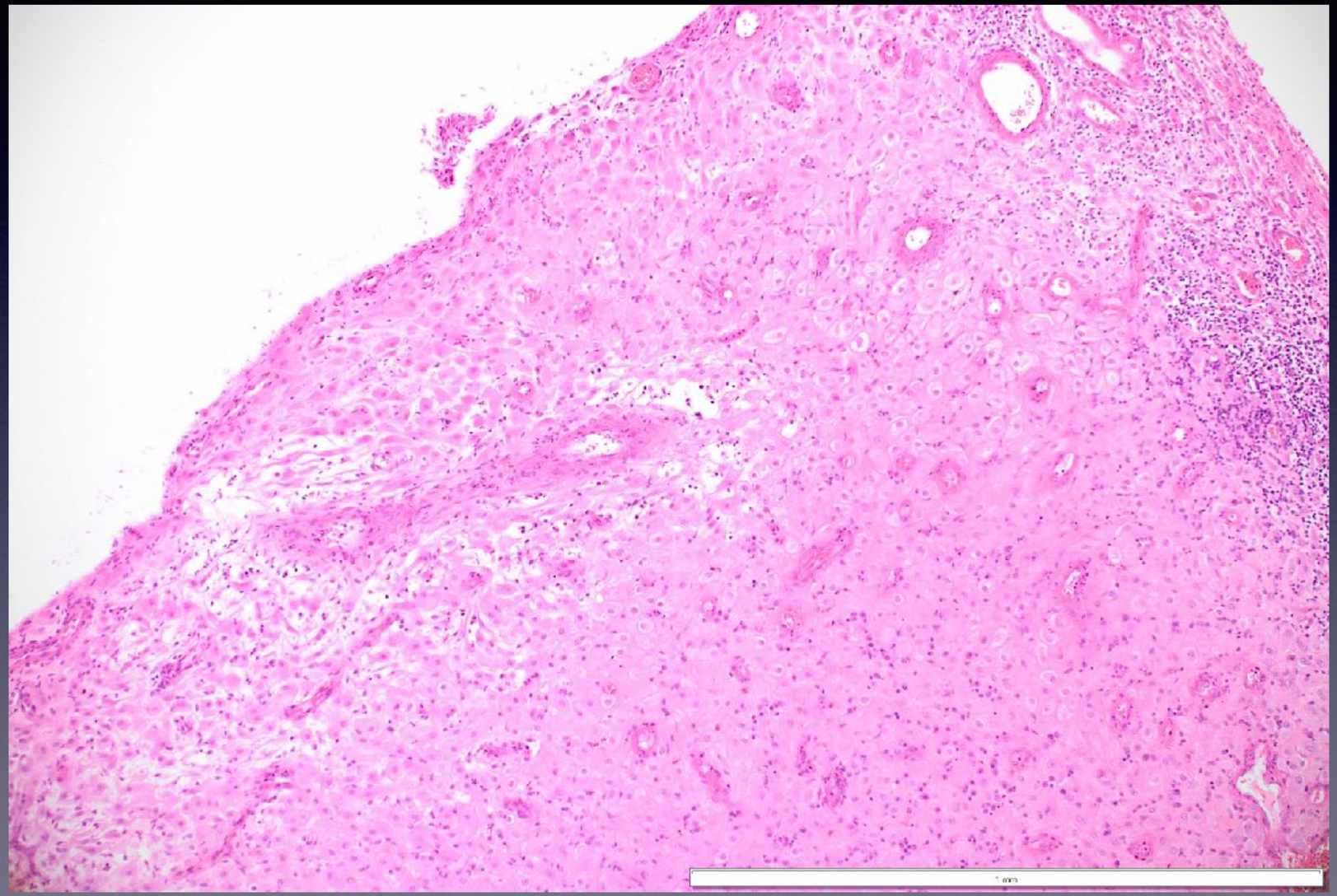

# LLETZ

- How to recognise the transformation zone
- Other histological features
- How my BMSs cut up a LLETZ
- Why you might ink a LLETZ
- Reporting of margin status

# TRIMMING LLETZ SPECIMENS – AGED 49 YEARS OR LESS

**STEP 1**

INK THE ECTOCERVICAL MARGIN – LIPSTICK RED

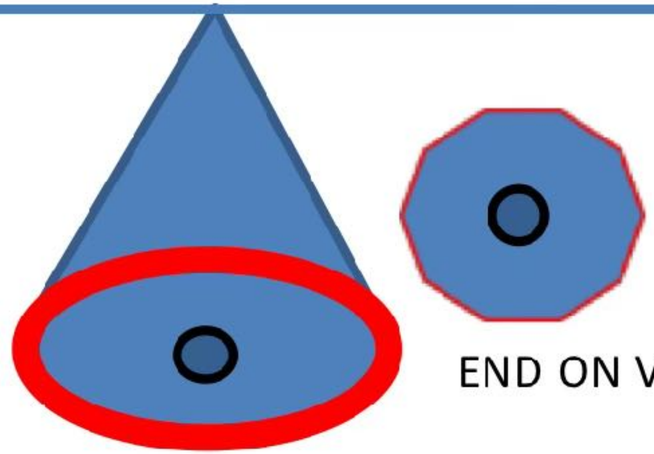

END ON VIEW

**STEP 2**

SLICE AT 2- 3 MM INTERVALS

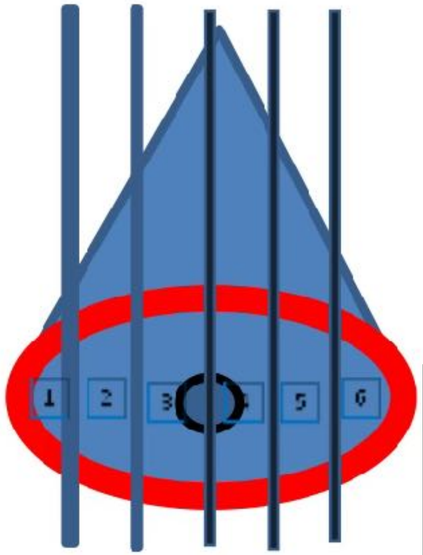


The Royal College of Pathologists
Pathology: the science behind the cure

**Tissue pathways for gynaecological pathology**

**February 2023**

# How my BMSs cut up a LLETZ

- Opening or probing an intact loop or cone biopsy may damage the surface epithelium and must be avoided
- Look for any surface lesions
- Measure in 3 dimensions - know what you're measuring



- Depth of excision - Parameter for colposcopic performance

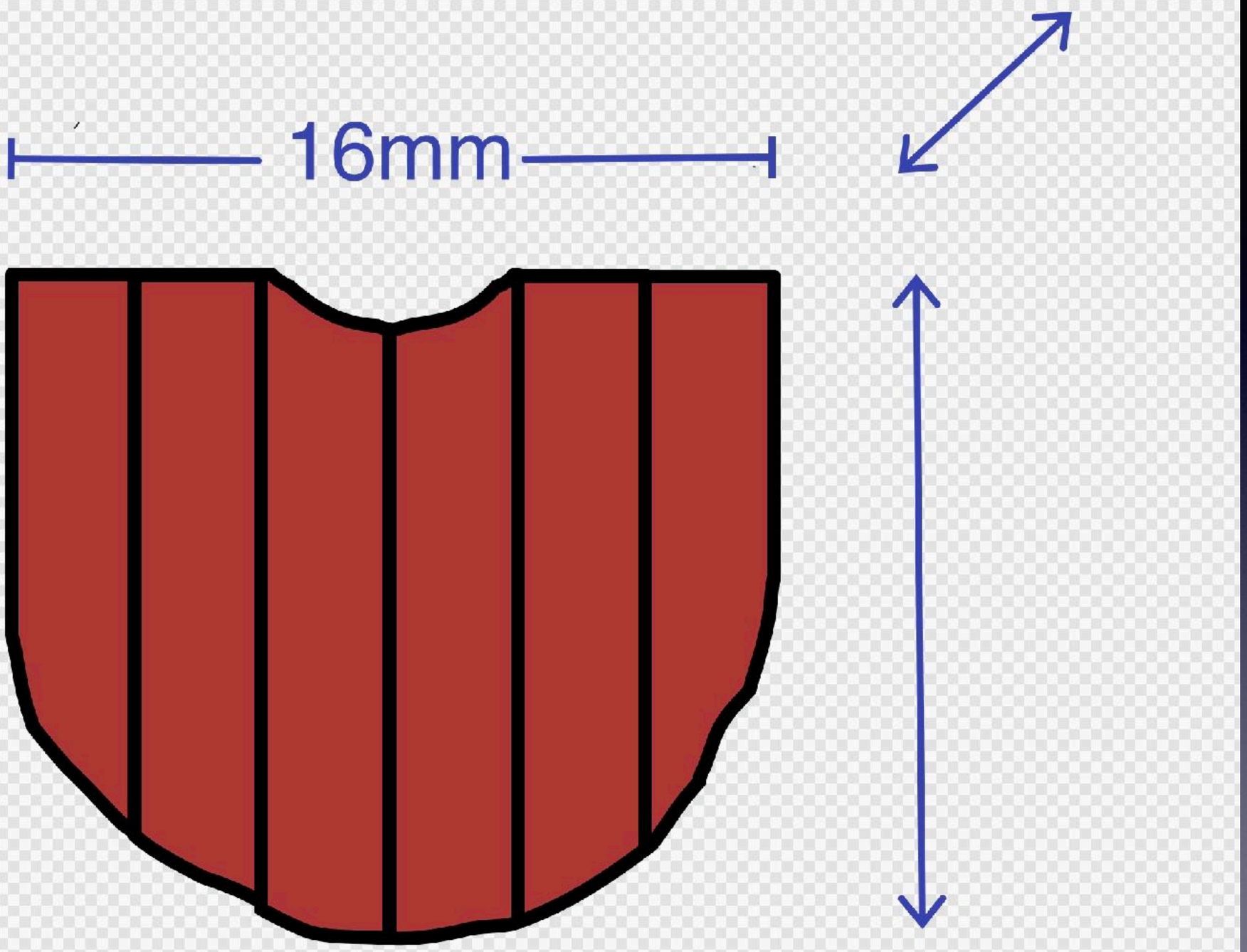
16mm







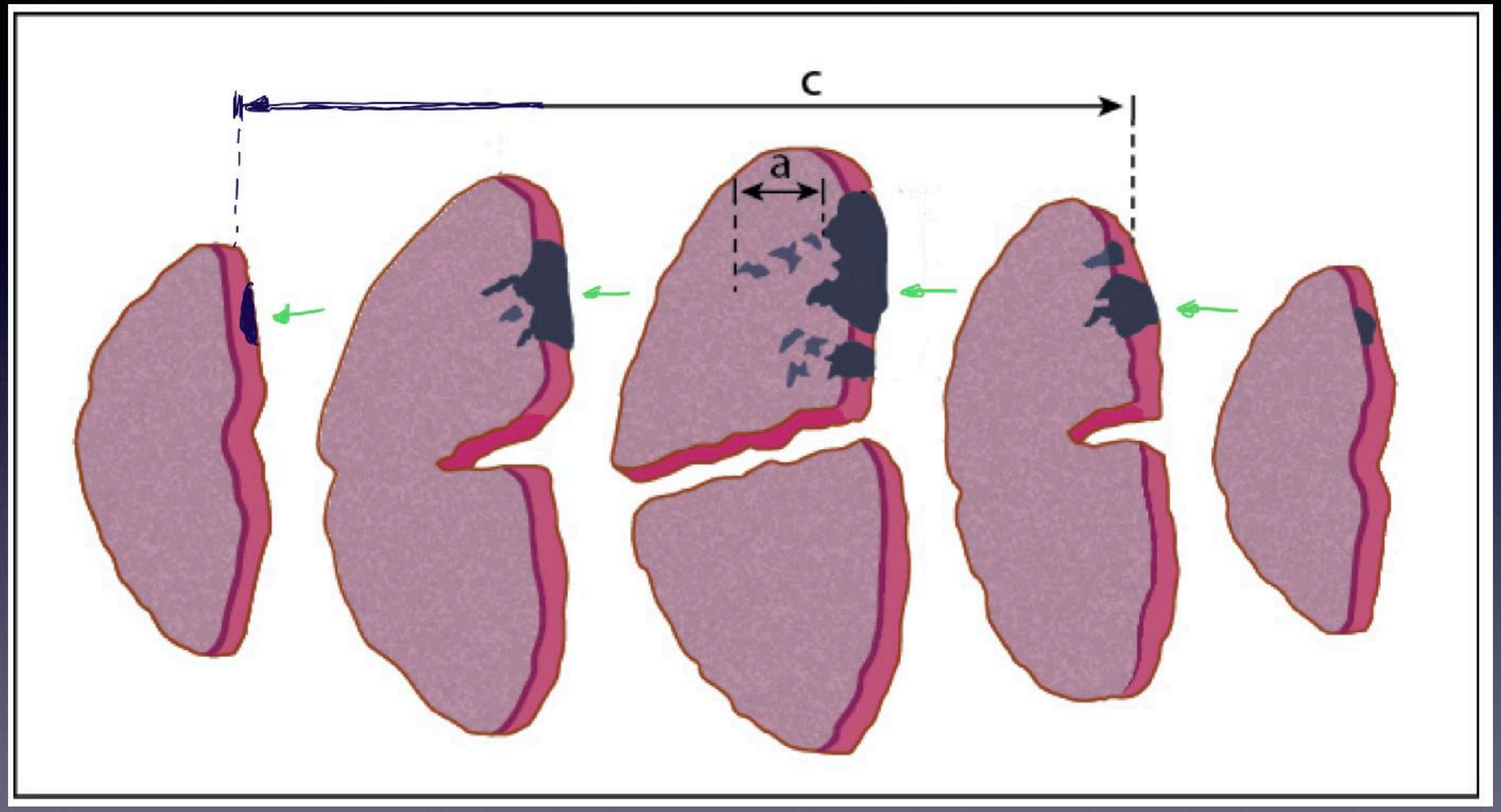


Modified from

**To reference this dataset please use the following citation:** Park KJ, Alvarado-Cabrero I, Duggan MA, Kiyokawa T, Mills AM, Ordi J, Otis CN, Plante M, Stolnicu S, Talia KL, Wiredu EK, Lax SF, McCluggage WG (2021). *Carcinoma of the Cervix Histopathology Reporting Guide*. International Collaboration on Cancer Reporting; Sydney, Australia. ISBN: 978-1-922324-24-5.

“Place each slice of tissue in a single cassette.

**This is very important when assessing invasion if present.”**

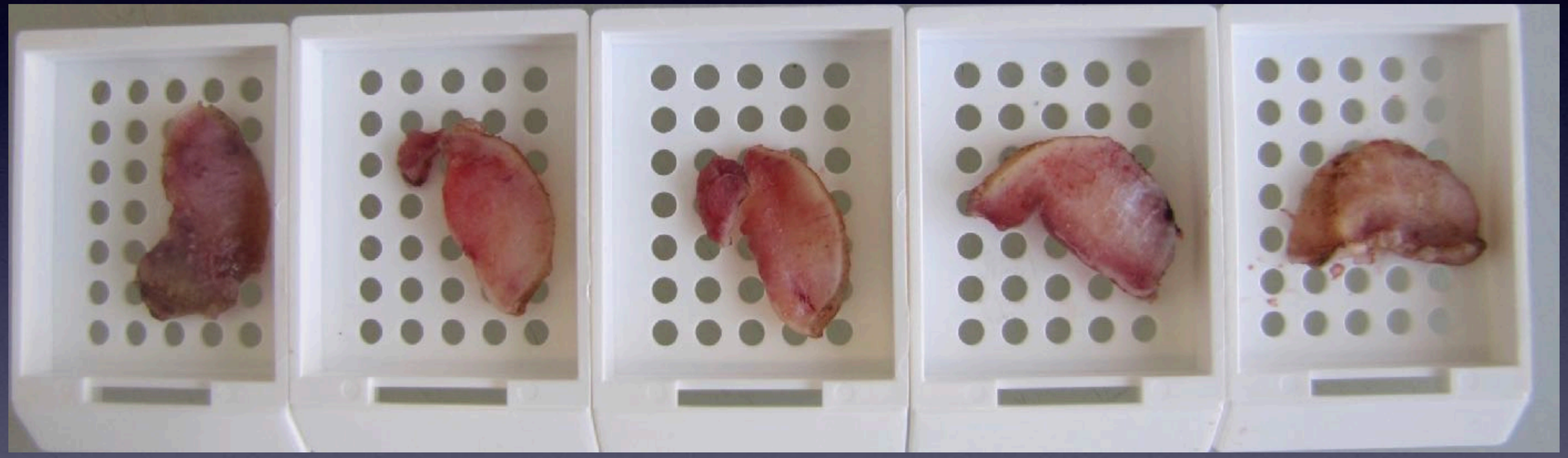

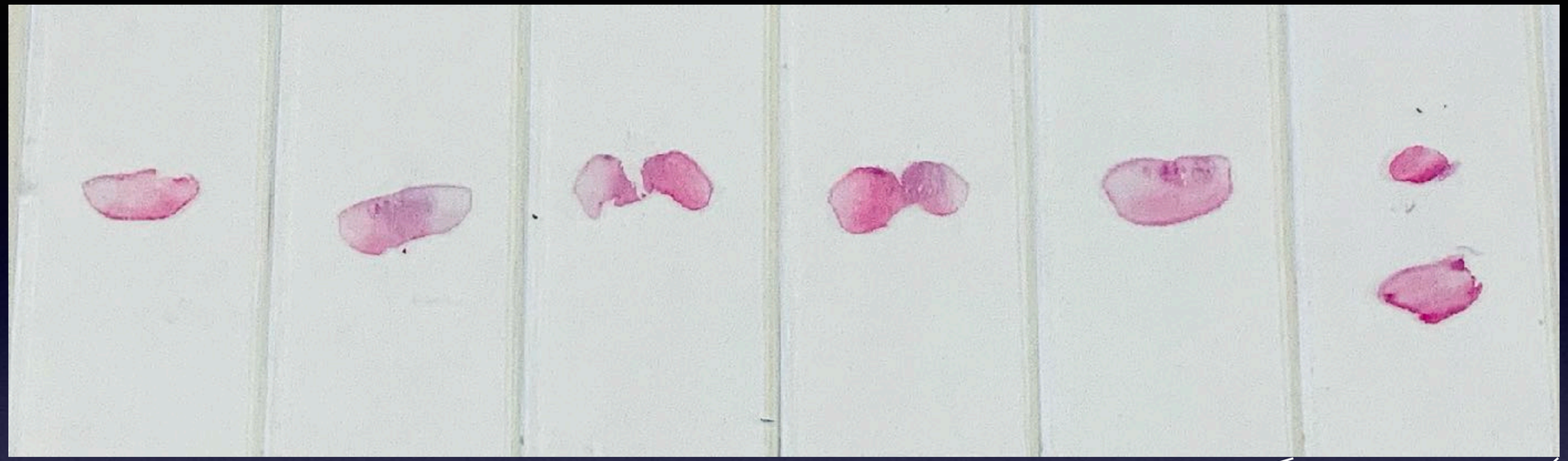

MDSF = Margin down, shallow first

# How not to do it

- Clinical: ?Invasive Disease
- Macro: "2 pieces of brown tissue, the larger up to 17mm in maximum dimension"

# How not to do it

- Clinical: ?Invasive Disease
- Macro: "2 pieces of brown tissue, the larger up to 17mm in maximum dimension"



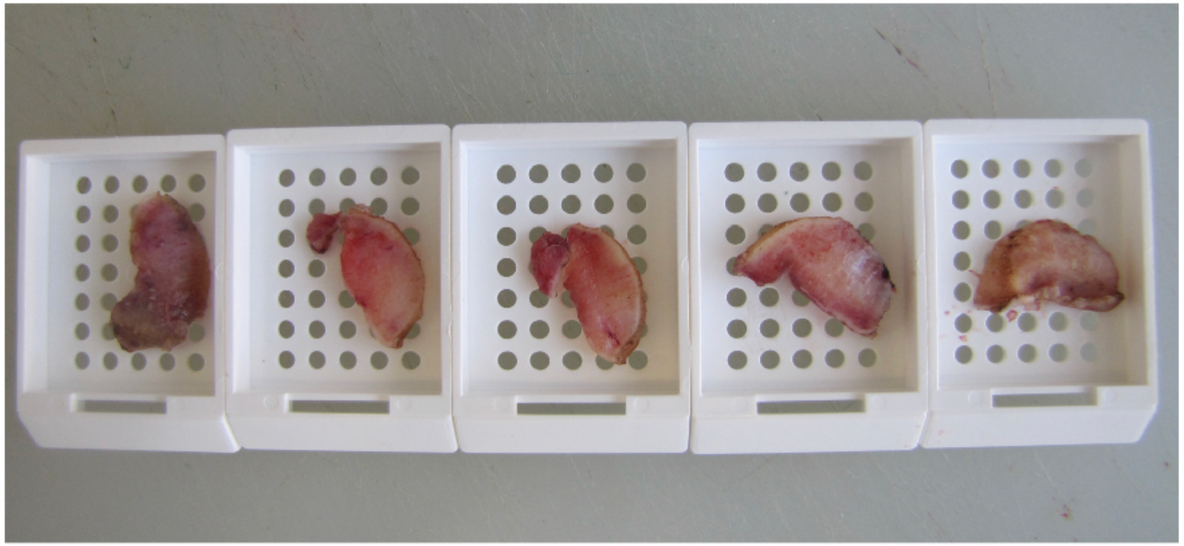

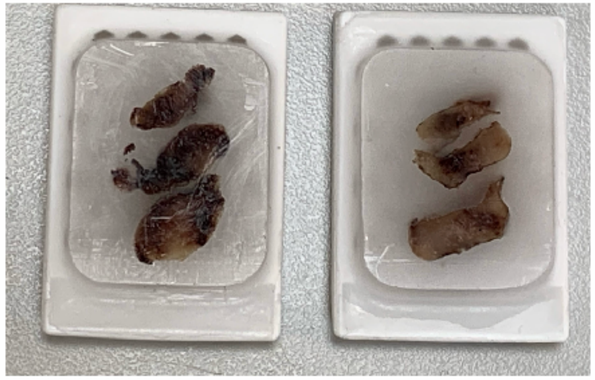

# LLETZ

- How to recognise the transformation zone
- Other histological features
- How my BMSs cut up a LLETZ
- Why you might ink a LLETZ
- Reporting of margin status

# Why might you ink a LLETZ?

NOT to identify the true margin

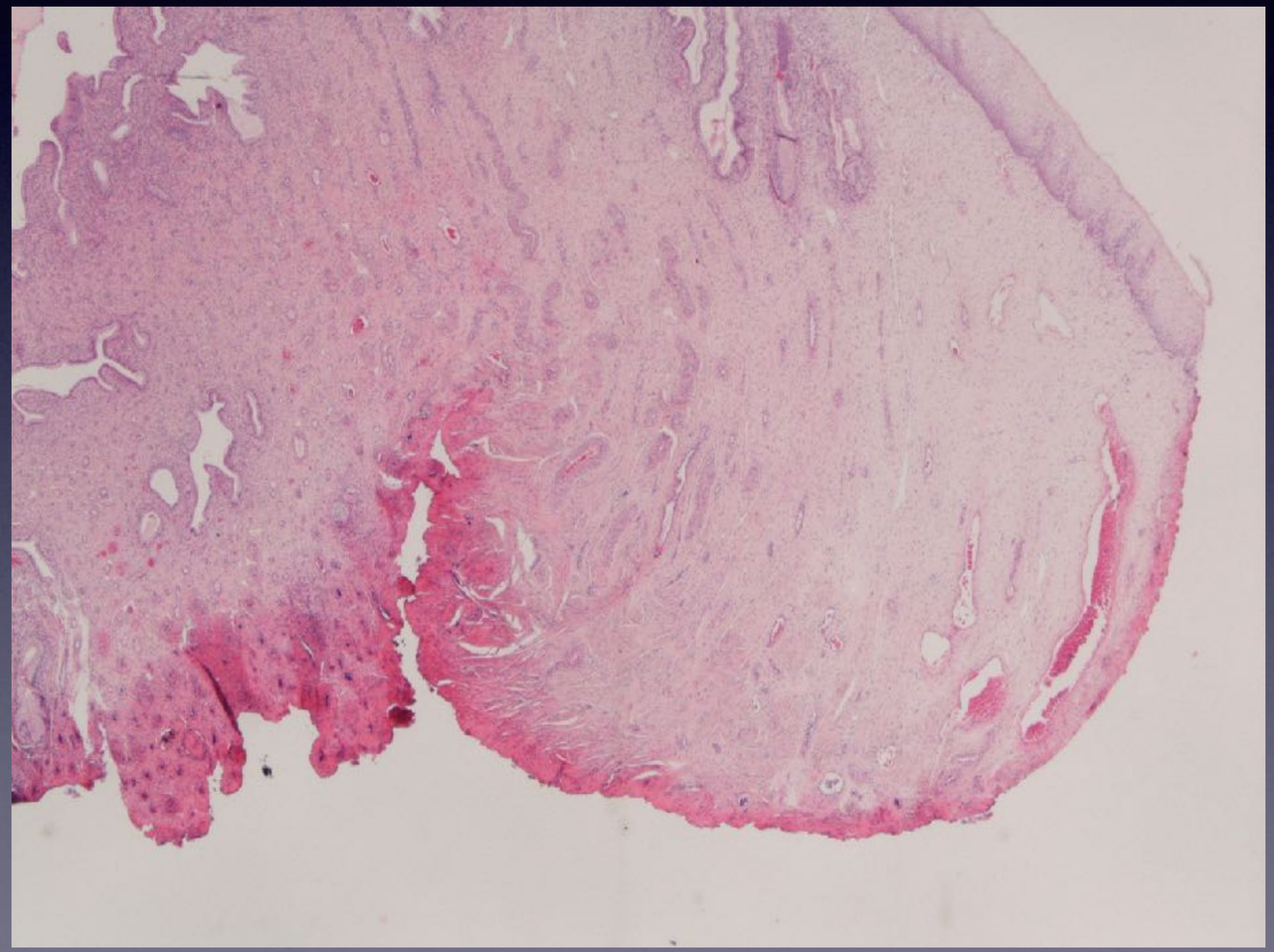

# 1. “to assist the embedder”









# Why might you ink a LLETZ?

## 2. Confirm identity of margins

- Ectocervical and endocervical refer to direction of margin, not the type of epithelium at the margin

# Margins

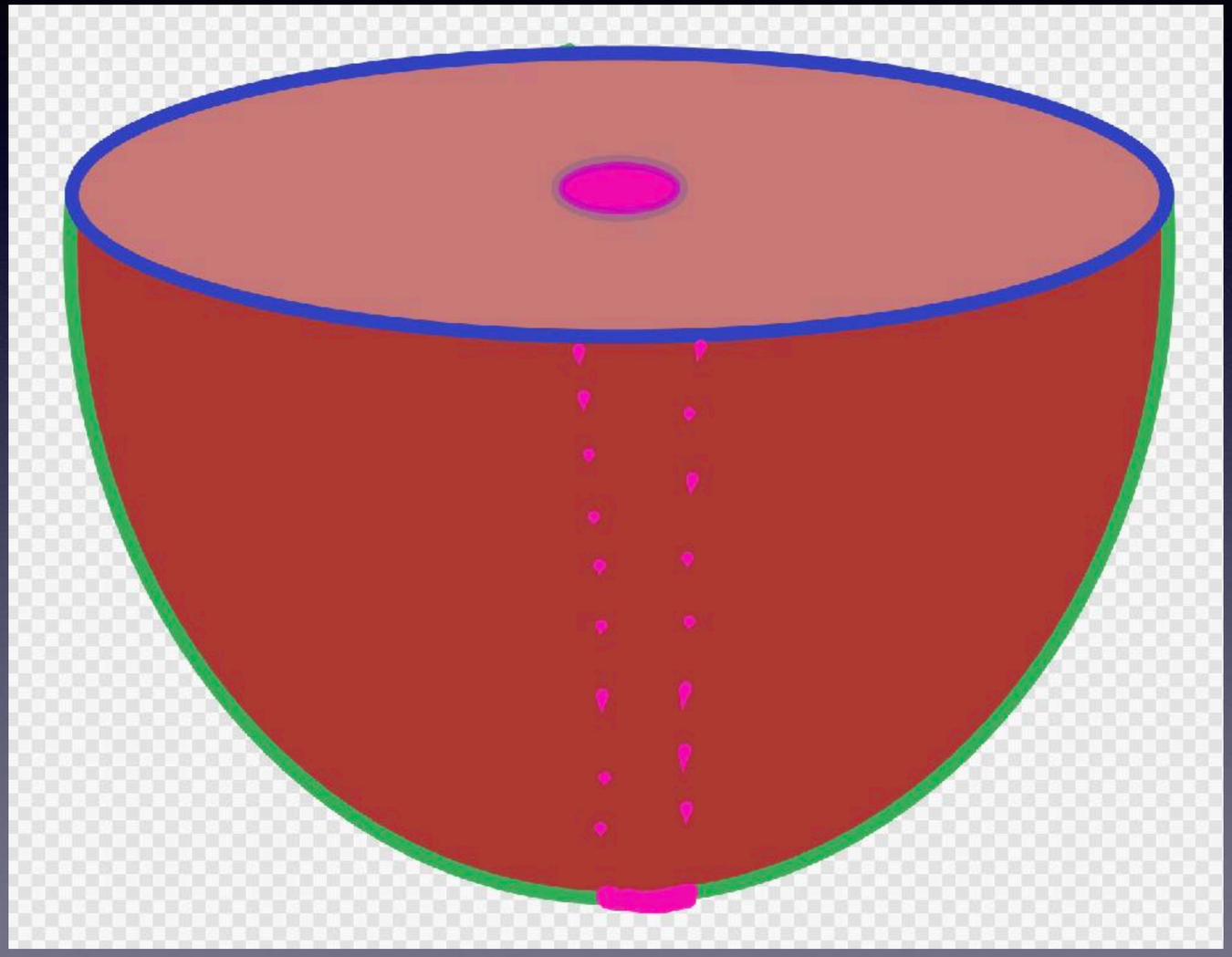

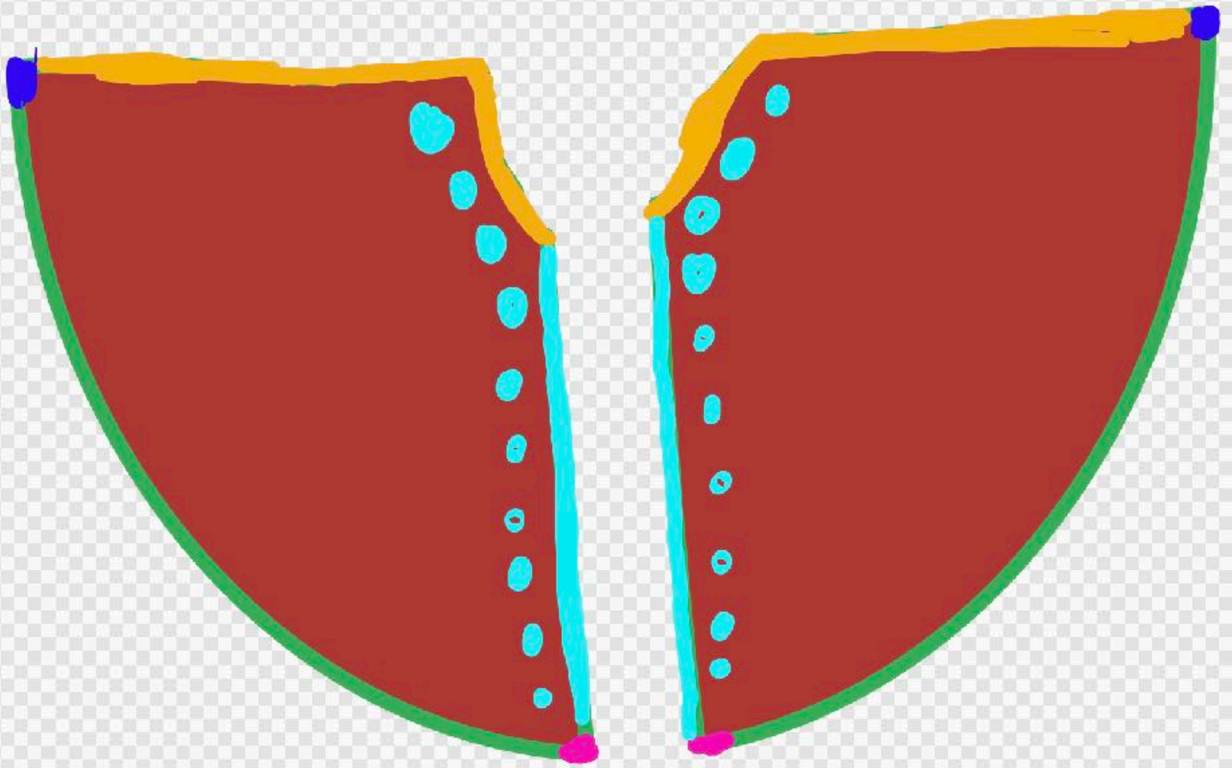

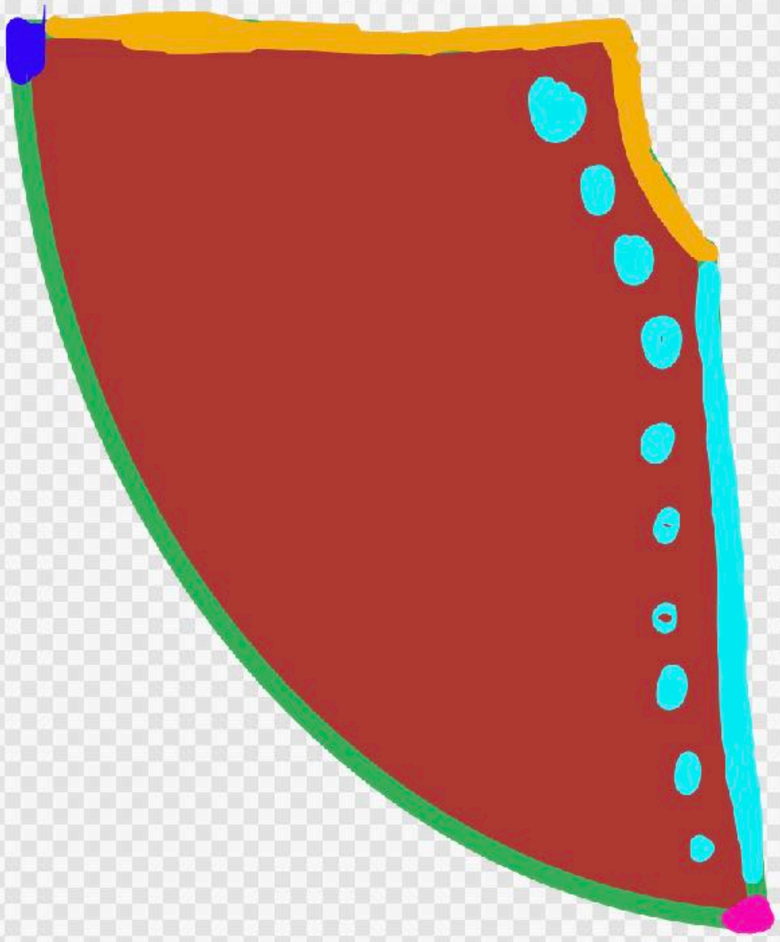

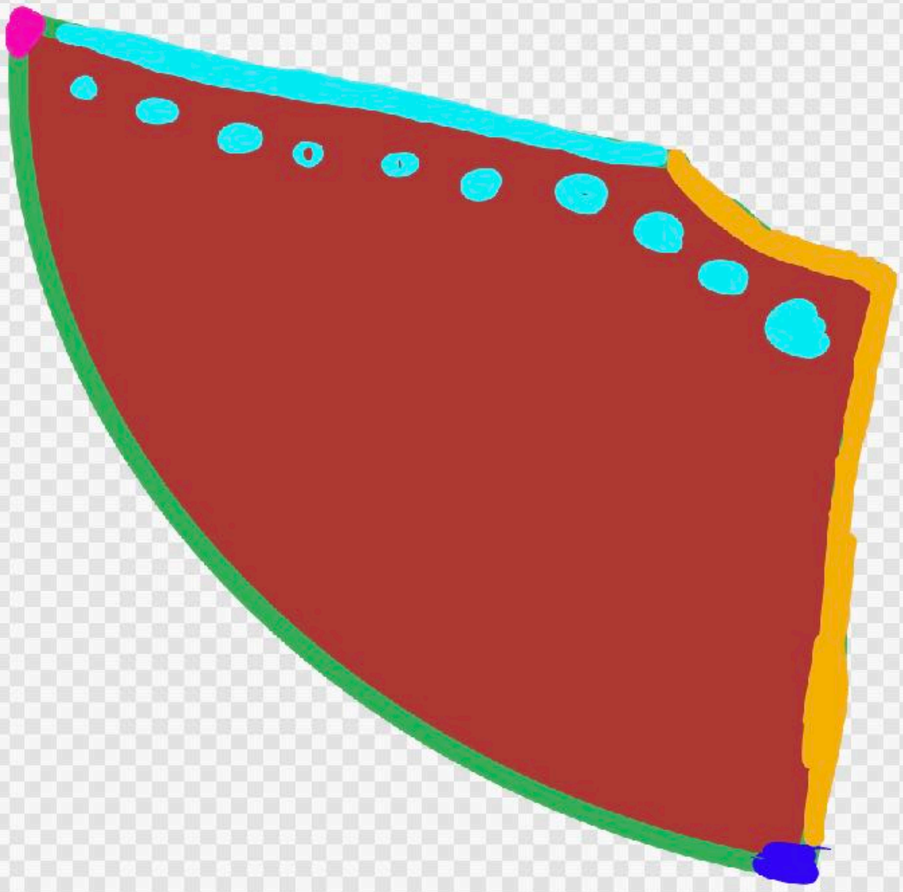





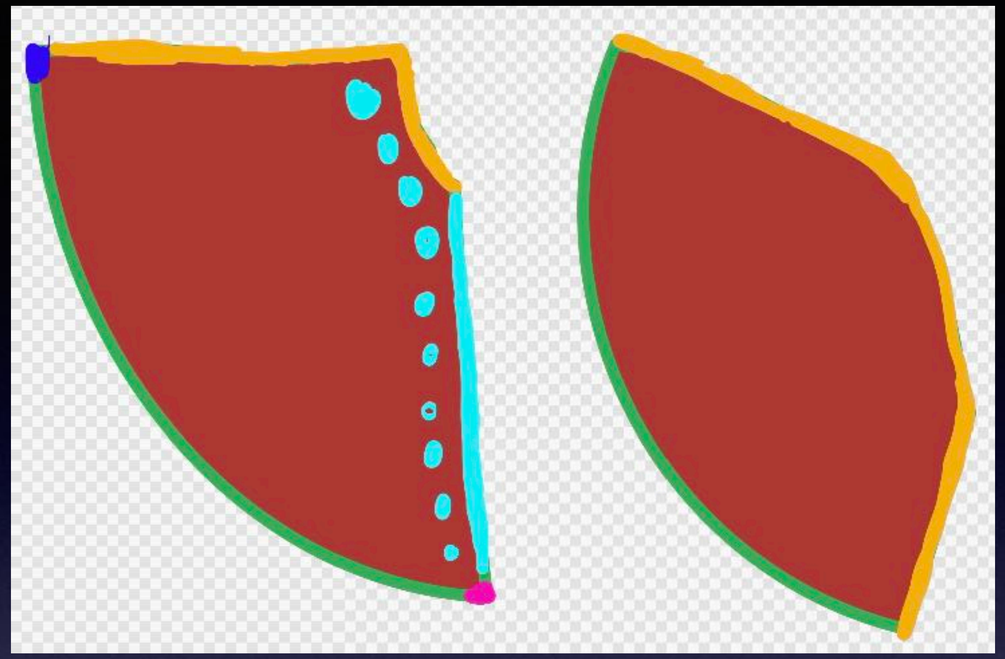

Use
Symmetry

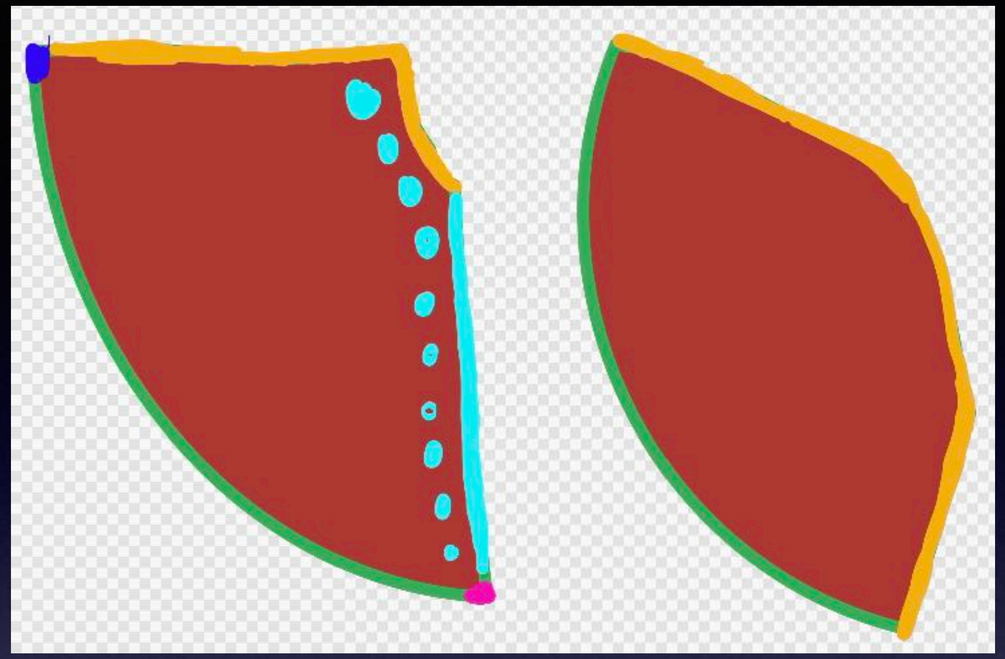

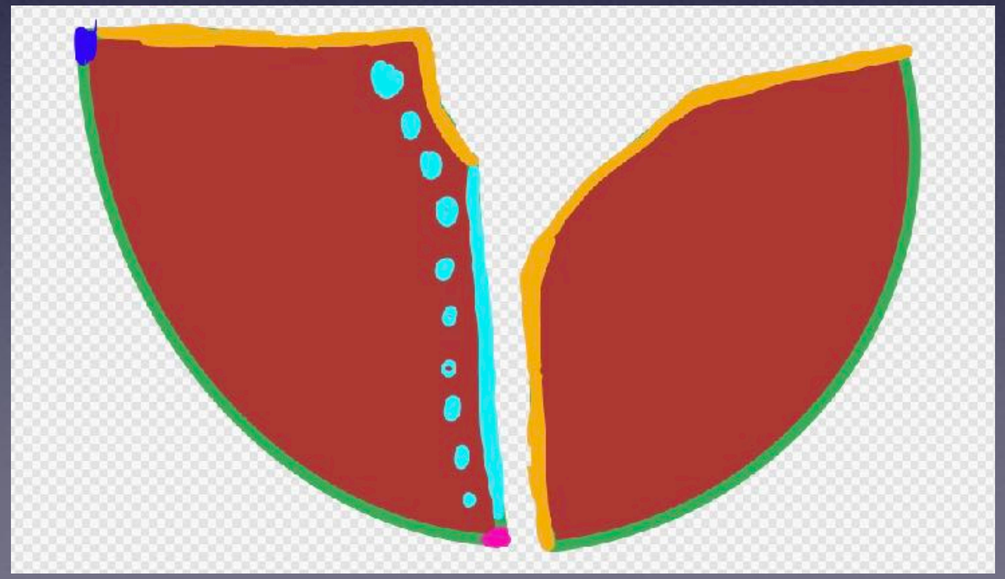

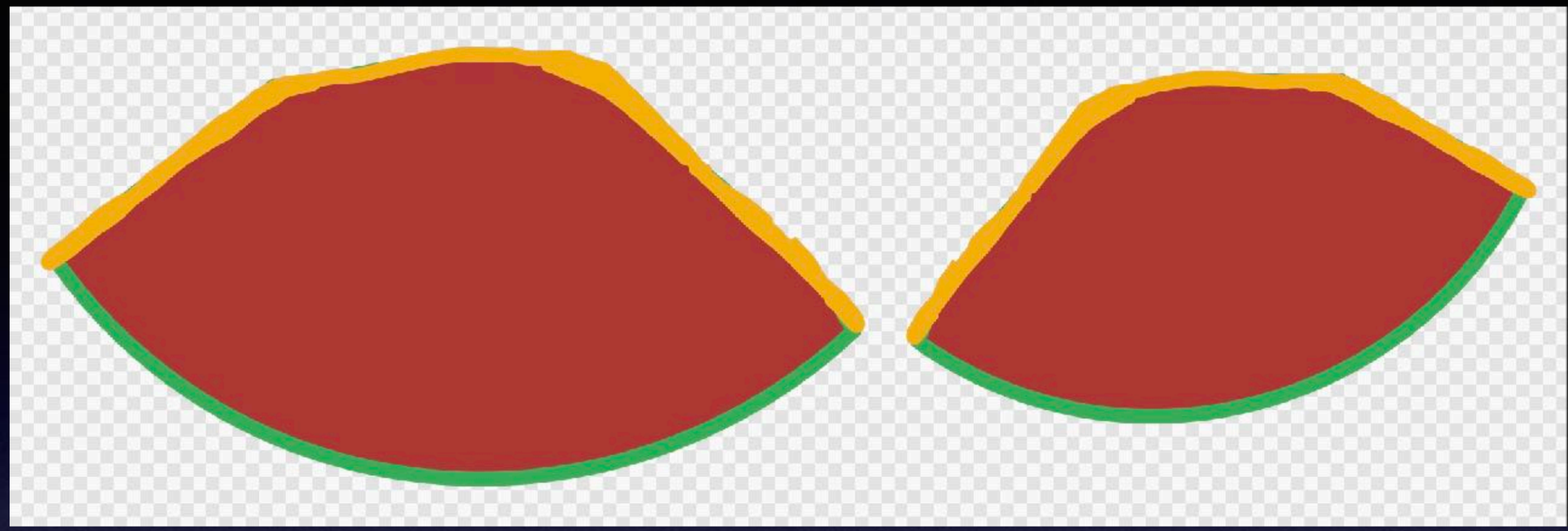

Look at the Adjacent slice

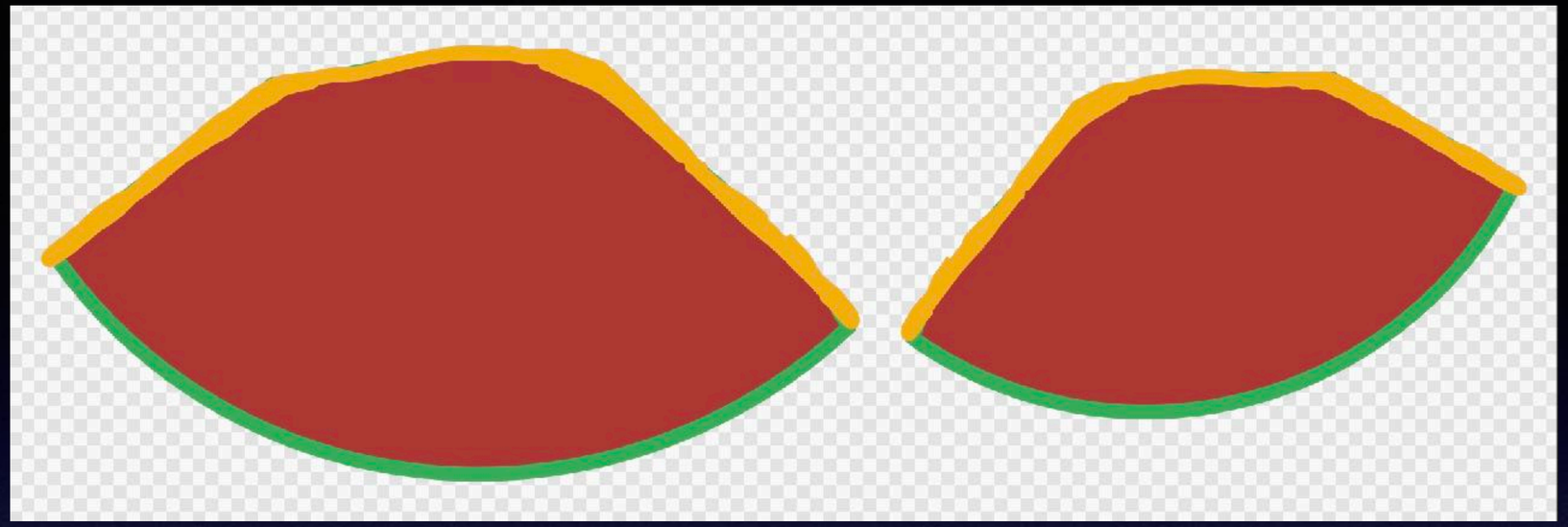

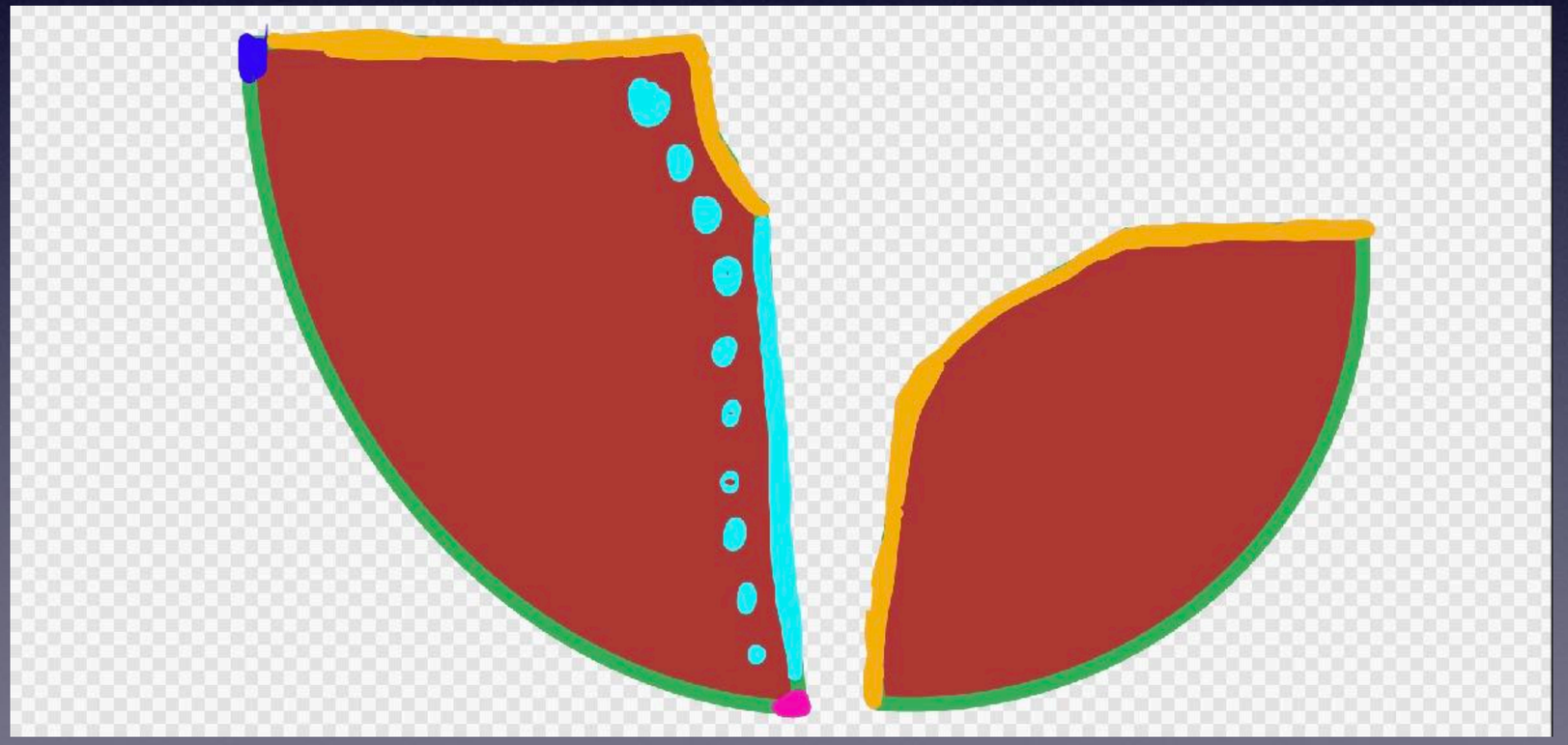

- Ectocervical and endocervical refer to direction of margin
  - not the type of epithelium at the margin

- You can usually work out which margin is which

# Why might you ink a LLETZ?

## 2. Confirm identity of margins

- “Inking the ectocervical rim can be useful when orientating individual slices…”


30
40
50


½ m m
10
20
30
40



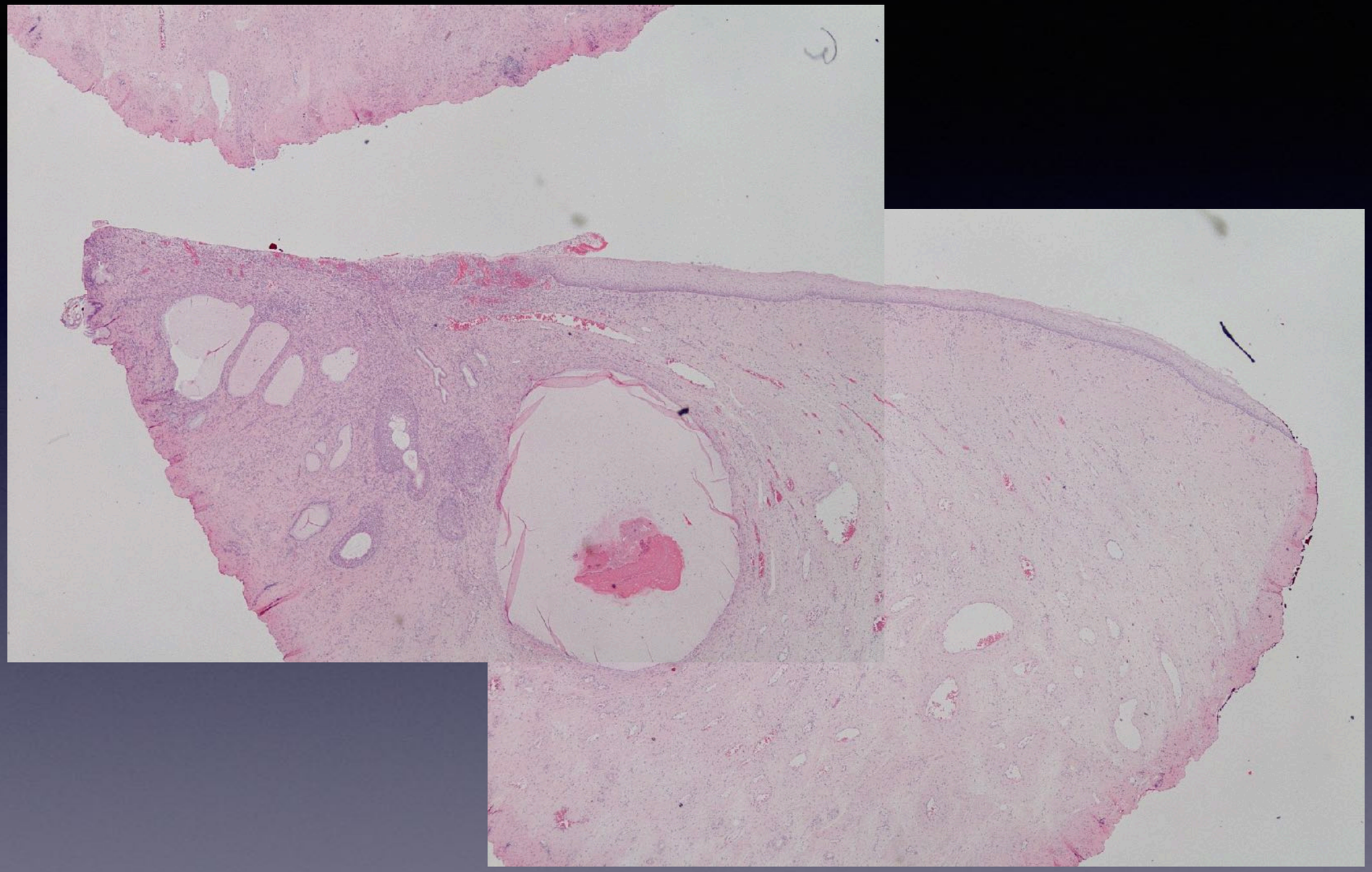


S21 · 17165
1
S21 · 17165
2
S21 · 17165
3
S21 · 17165
4
S21 · 17165
5
S21 · 17165
6

# LLETZ

- How to recognise the transformation zone
- Other histological features
- How my BMSs cut up a LLETZ
- Why you might ink a LLETZ
- Reporting of margin status




High grade CIN extending to the deep lateral or endocervical margins

- results in a higher incidence of recurrence
- does not justify routine repeat excision if:
  - no evidence of glandular abnormality
  - no evidence of invasive disease
  - the individual is <50 years

Therefore

Individuals <50 years
with CIN at the deep lateral or endocervical margin
**You do not need to examine extra levels or turn end blocks**

# Reporting of Margin status

- To assess true margin, may need to:
  - Levels, or
  - Turn end blocks

# TRIMMING LLETZ SPECIMENS – AGED 50 YEARS OR OVER

**STEP 1**

INK THE ECTOCERVICAL MARGIN – LIPSTICK RED

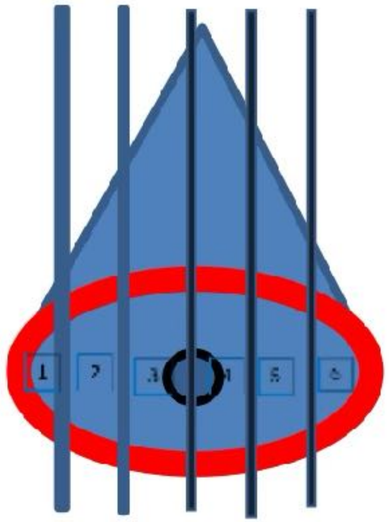

**STEP 2**

SLICE AT 2 - 3 MM INTERVALS

**STEP 3**

END BLOCKS TRIM RADIALLY

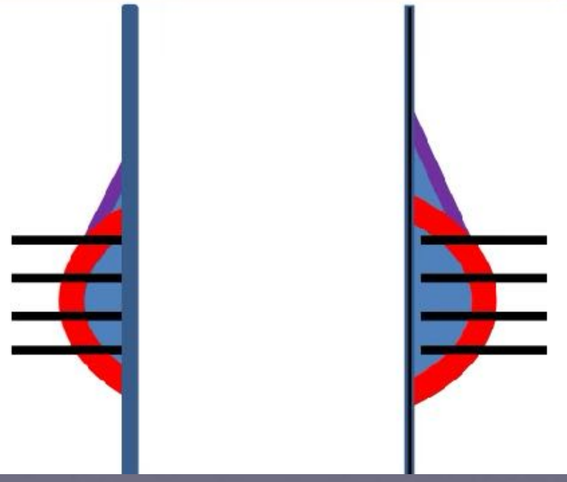

The Royal College of Pathologists
Pathology: the science behind the cure

**Tissue pathways for gynaecological pathology**

**February 2023**

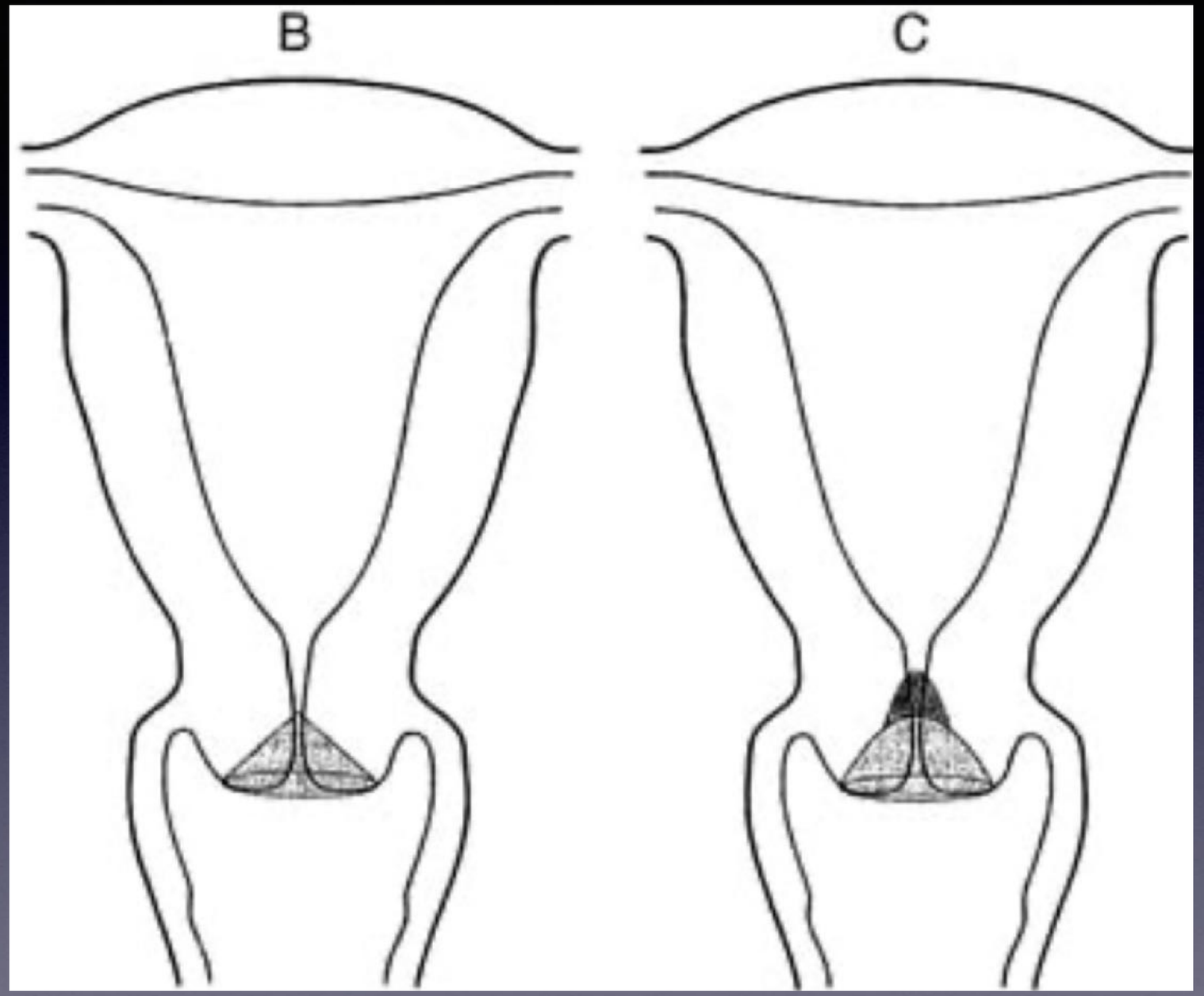


*This chapter should be cited as follows:*
Connor, J, Hartenbach, E, *Glob. libr. women's med.*, *(ISSN: 1756-2228)* 2008; DOI 10.3843/GLOWM.10228

# Summary

- How to recognise the transformation zone
- Other histological features
- How my BMSs cut up a LLETZ
- Why you might ink a LLETZ
- Reporting of margin status