The British Association of Gynaecological Pathologists

Dr. Anjelica Hodgson



- Gynecologic Pathologist at Toronto General Hospital
- Assistant Professor with University of Toronto
- Trained at University of Toronto and Memorial Sloan Kettering Cancer Center
- Practices full spectrum of oncologic gynecologic pathology
- Current academic interests focused around tumour classification and prognostication for a variety of gynecologic neoplasms

The British Association of Gynaecological Pathologists

Everyday Dilemmas in Gynaecological Pathology

Non-mucinous borderline tumours including implants

Anjelica Hodgson MD FRCPC DABP
Toronto General Hospital and University of Toronto

March 7th, 2025

The British Association of Gynaecological Pathologists

Speaker disclosures

Nothing relevant to disclose

Ovarian borderline tumours

"Intermediate" category

histologically and **behaviour-wise**

PMID 12819402

Ovarian borderline tumours (non-mucinous)

Serous borderline tumour

*
Account for vast majority of all borderline ovarian epithelial neoplasms

Seromucinous borderline tumour

Endometrioid borderline borderline tumour

Clear cell borderline tumour

Borderline Brenner tumour

WHO 2020

Serous borderline tumour

- Occurs across a wide age range
- Most will be confined to the ovary/stage I
- Atypical proliferative serous tumour, serous tumour of low malignant potential, non-invasive low grade serous carcinoma NOT recommended
- Often protracted clinical course; with progression to (low grade) serous carcinoma, recurrences and deaths from disease 10 years or more from original diagnosis

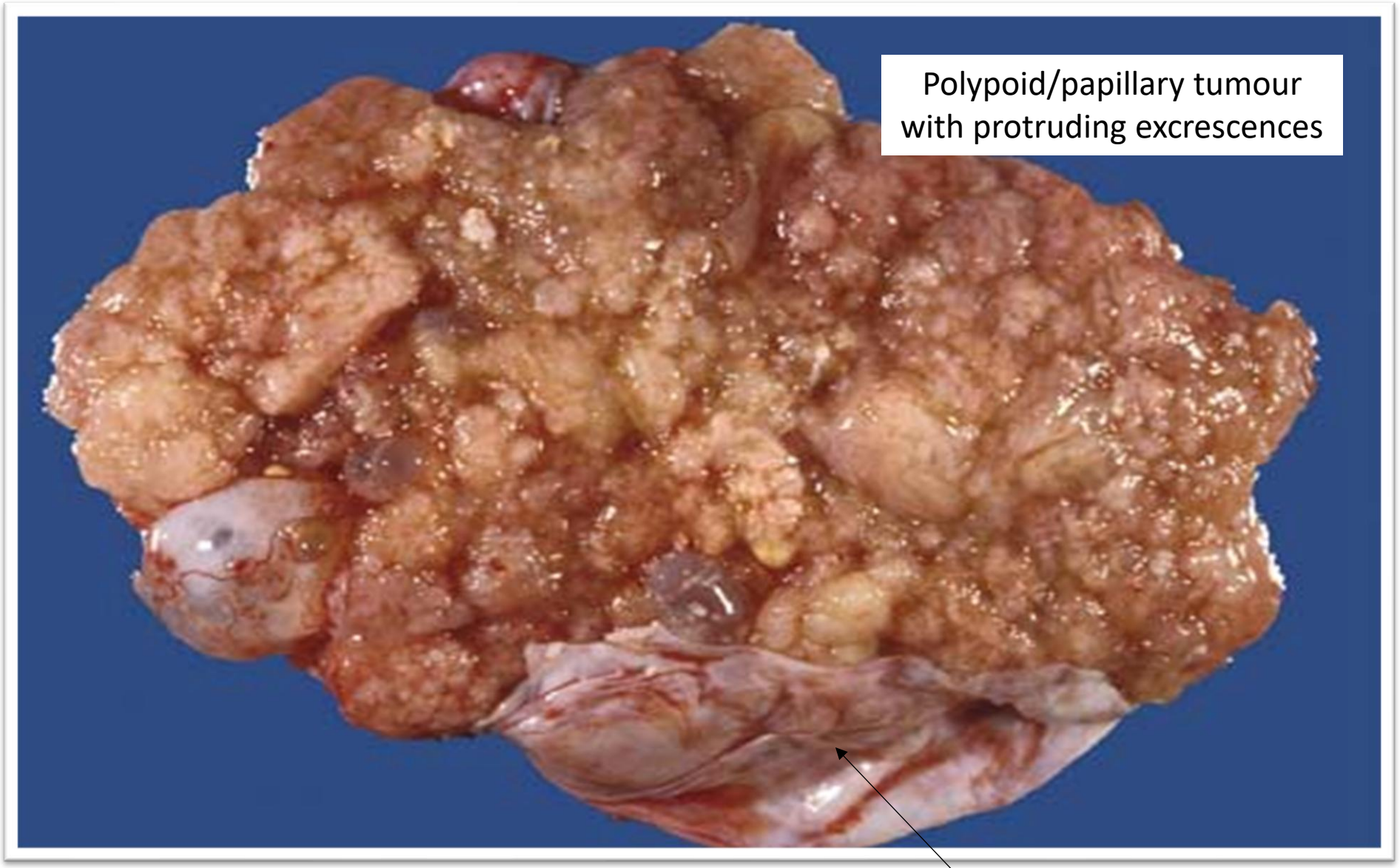
Polypoid/papillary tumour
with protruding excrescences
Ovarian surface

Intracystic growth

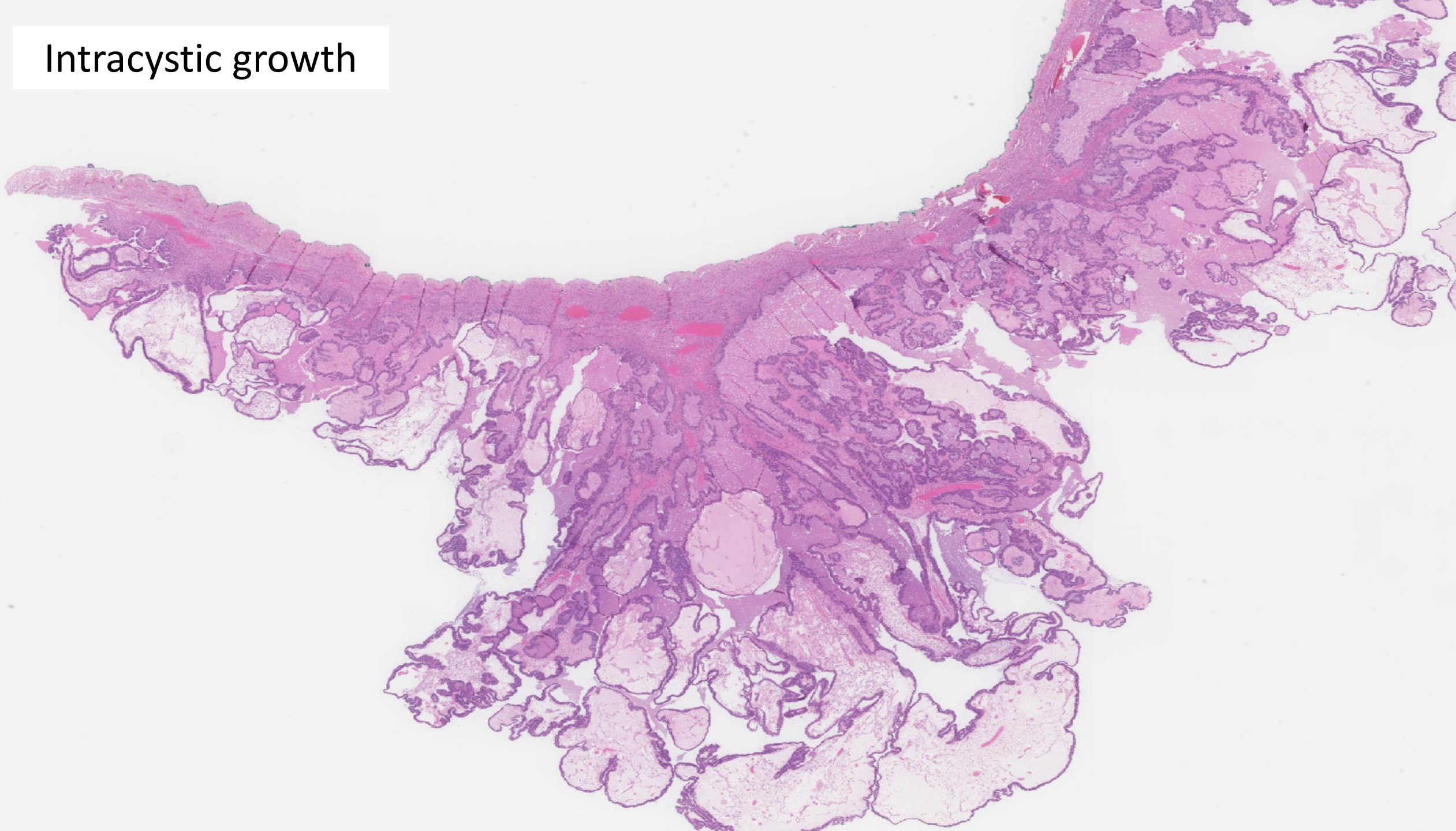

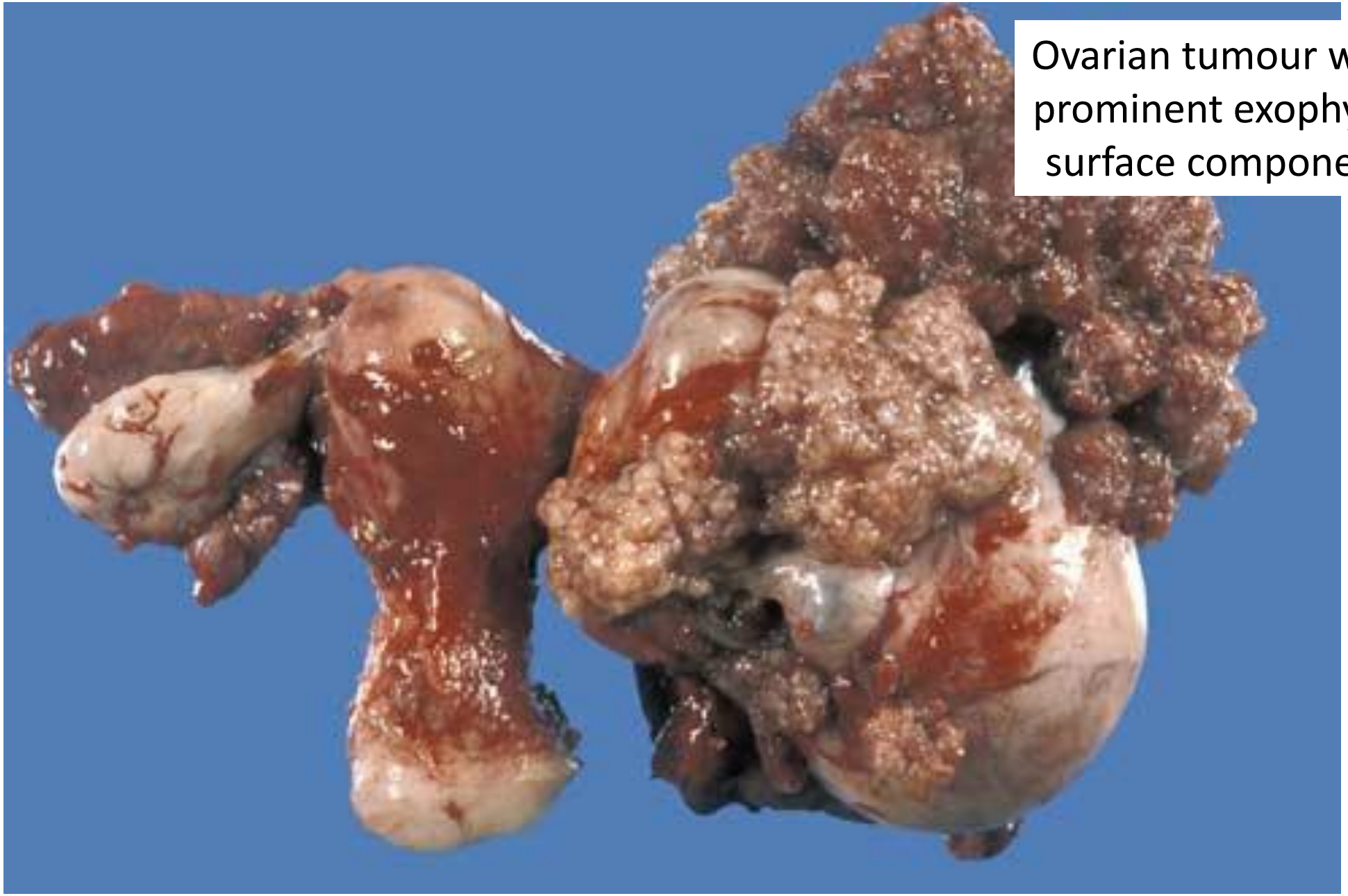

Ovarian tumour with prominent exophytic surface component

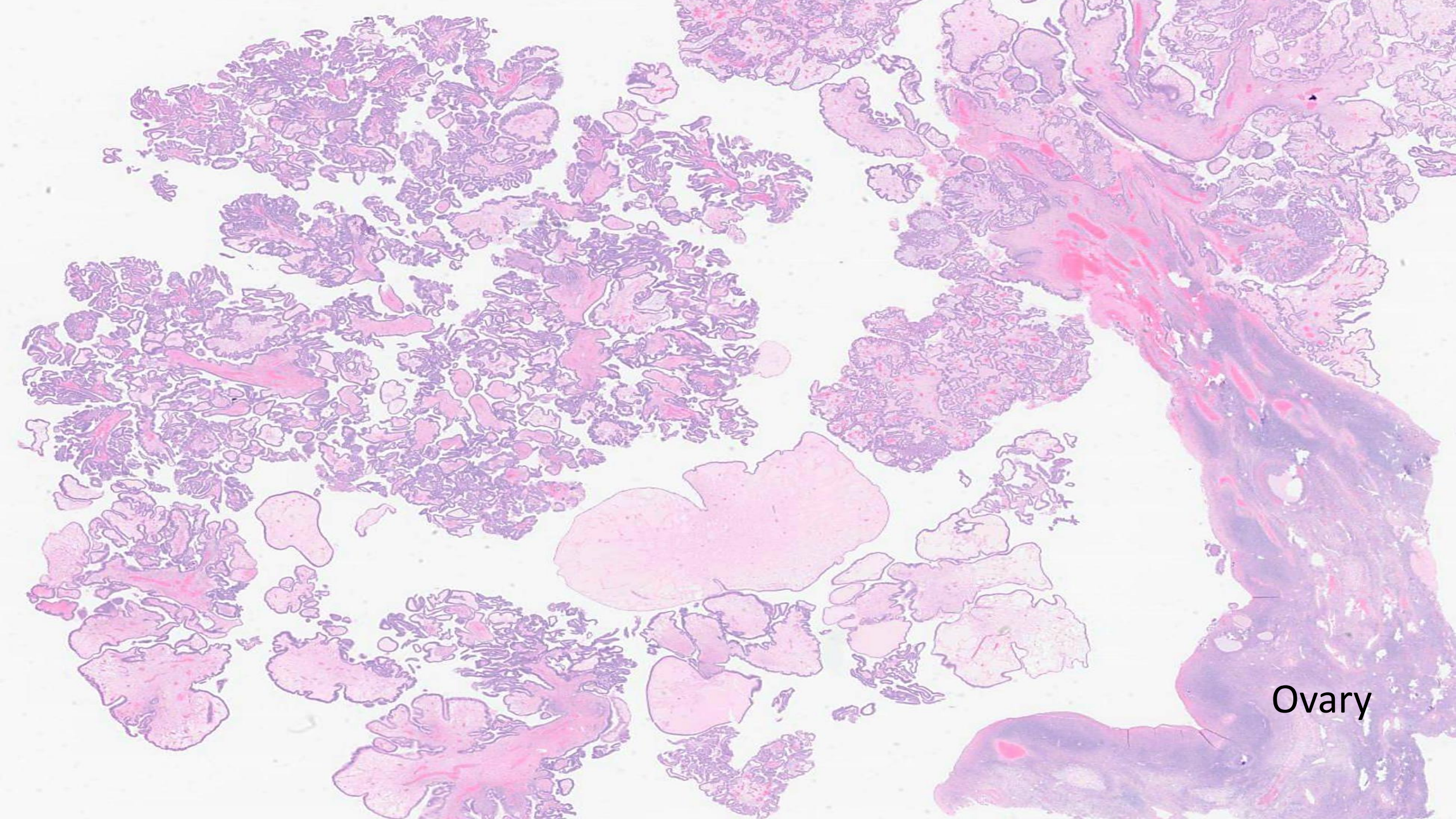
Ovary

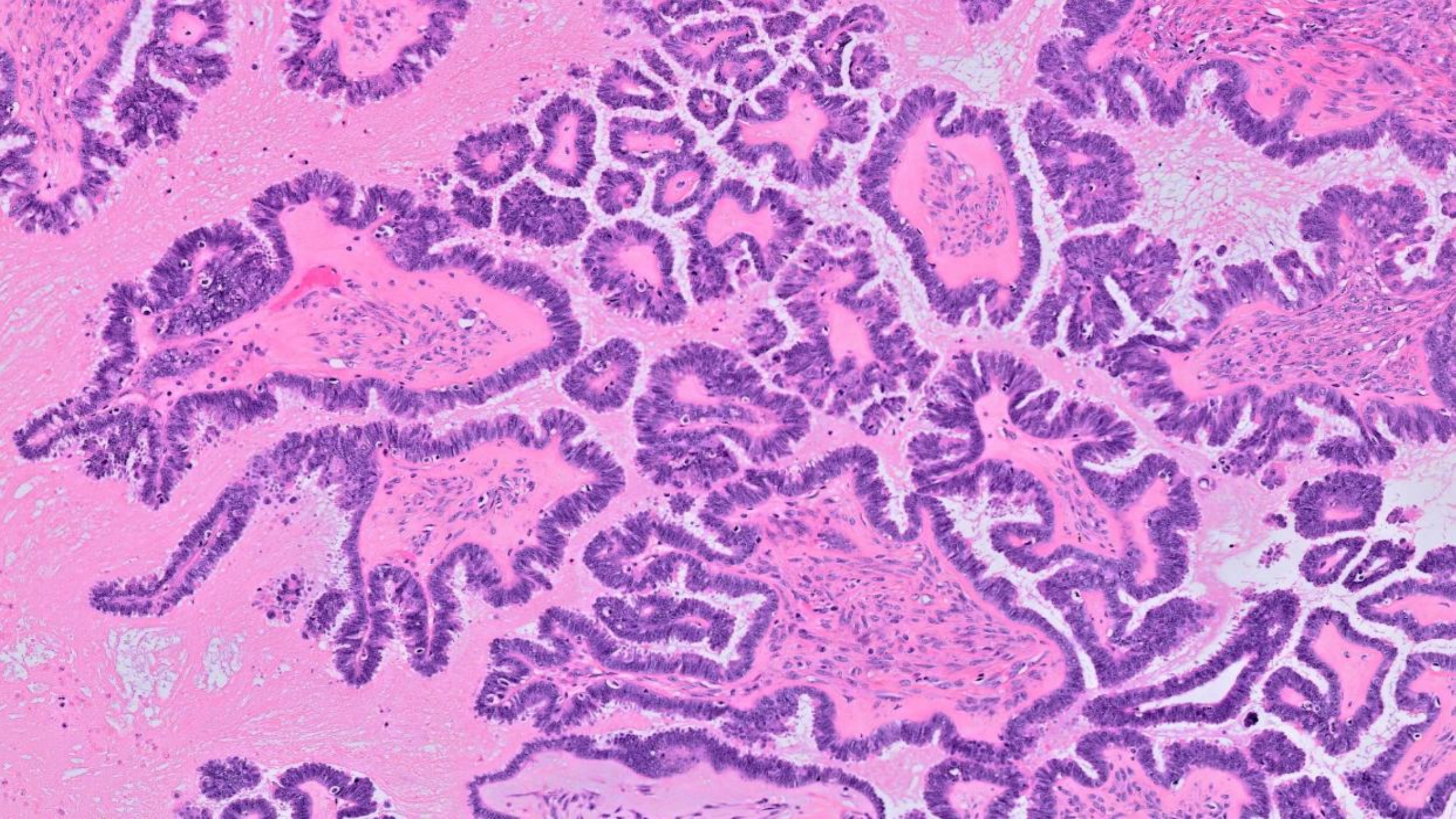

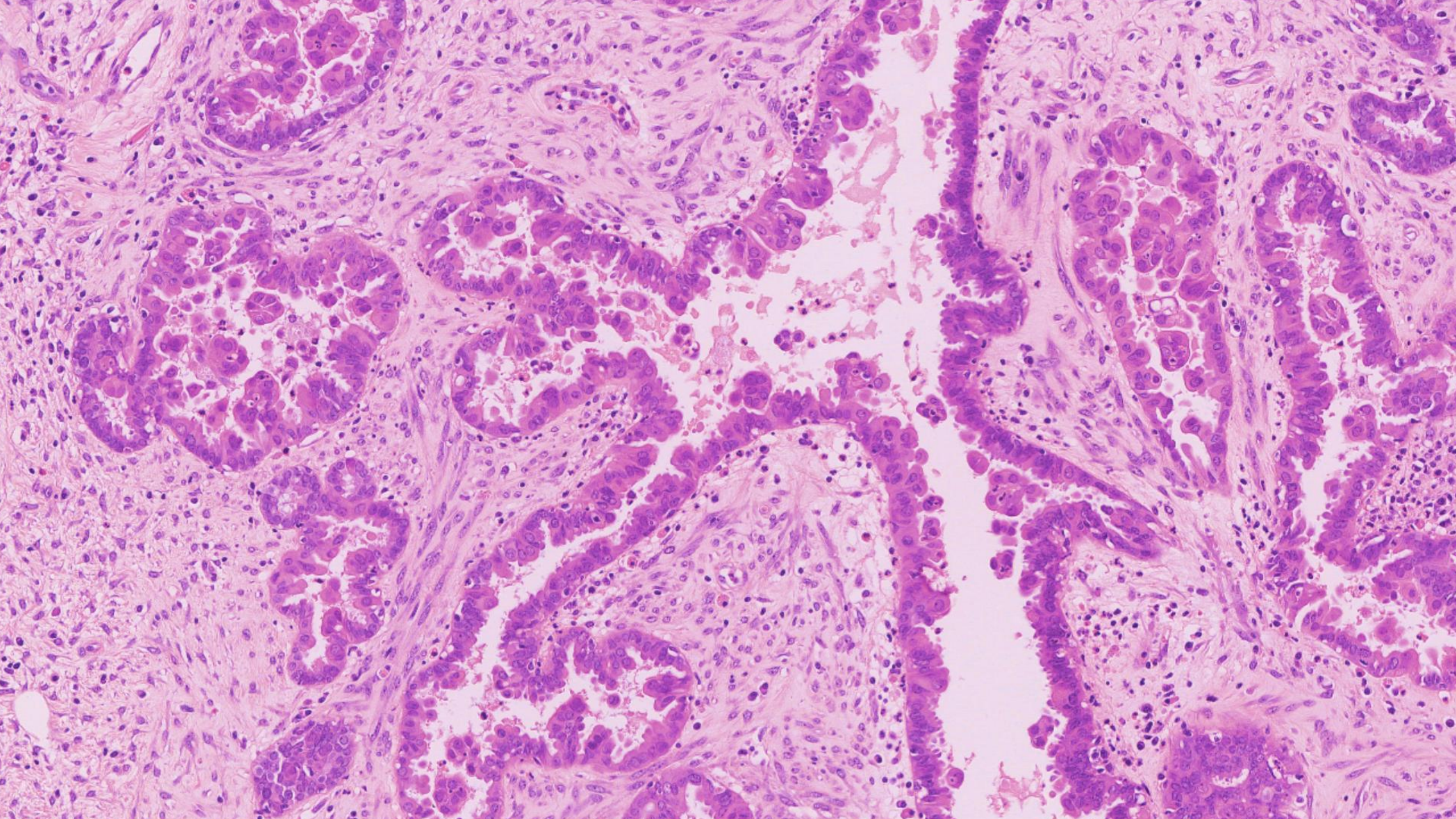

Selected everyday dilemmas

- Dealing with:
  - threshold for serous cystadenoma/adenofibroma vs. serous borderline tumour
  - micropapillary/cribriform architecture
  - microinvasion vs. microinvasive carcinoma
  - implants
  - lymph node involvement
  - low grade serous neoplasia in core biopsy material

Threshold for serous cystadenoma/adenofibroma vs. serous borderline tumour

- Minimal criteria for diagnosis of borderline tumour?

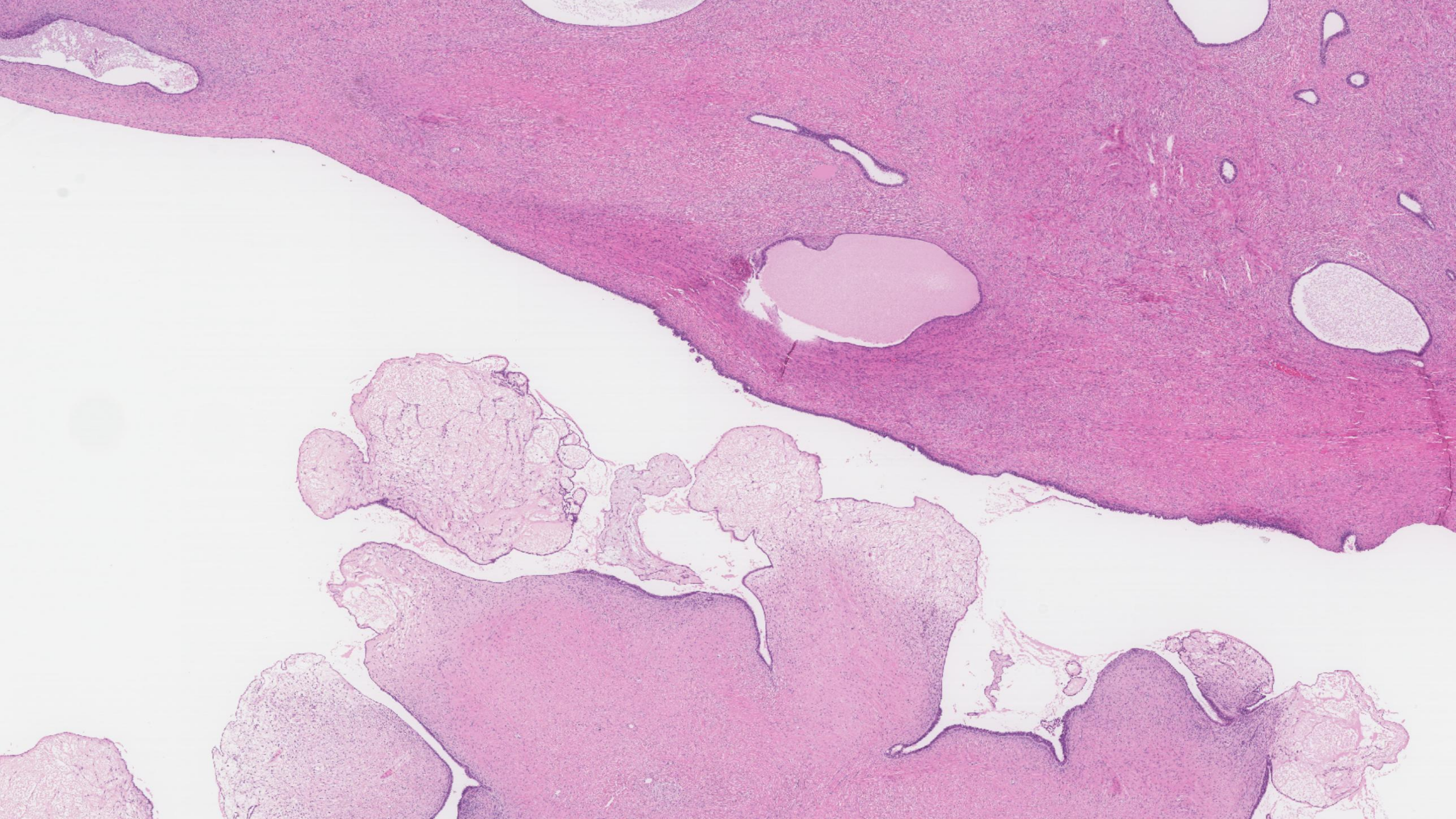

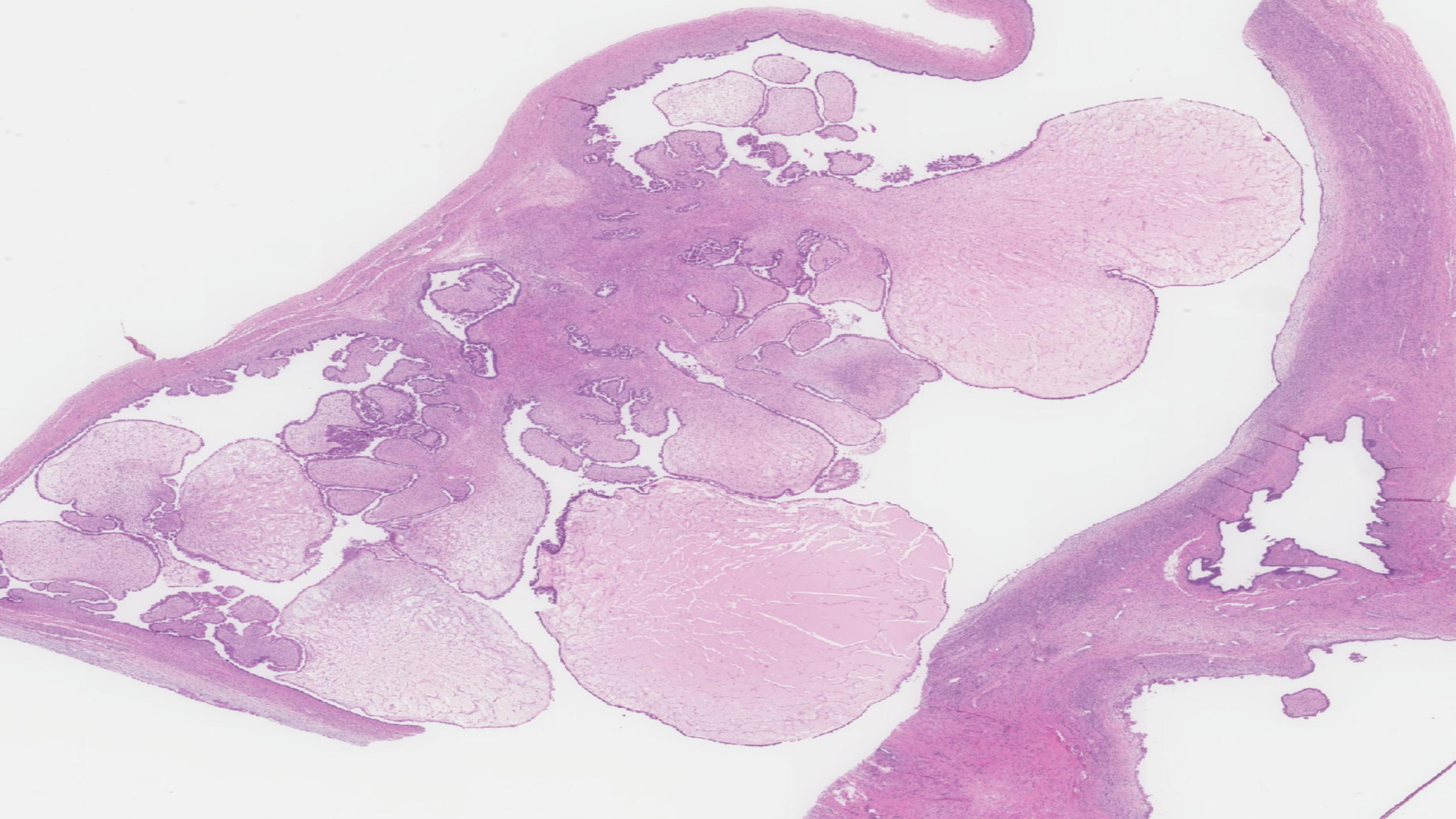

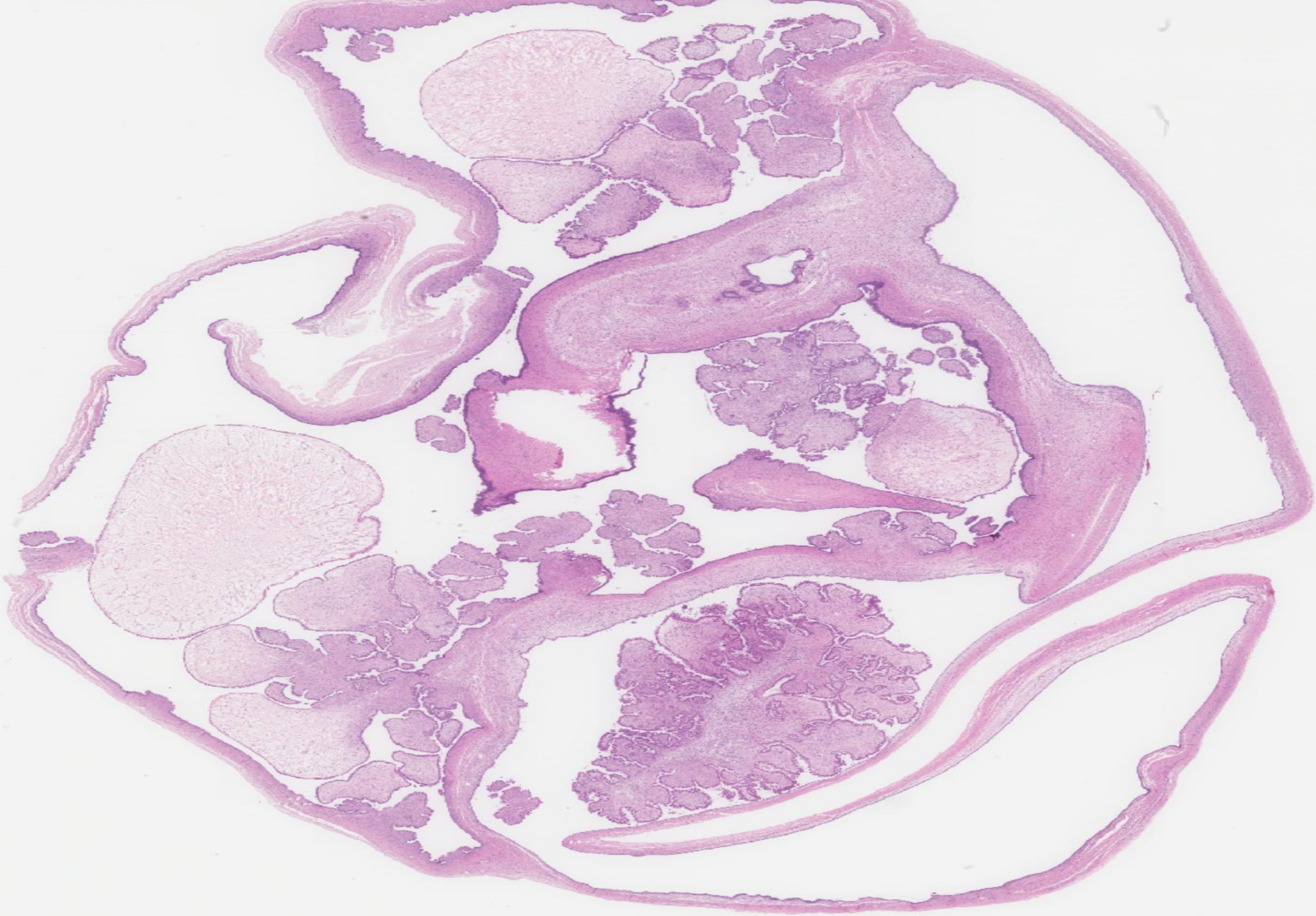

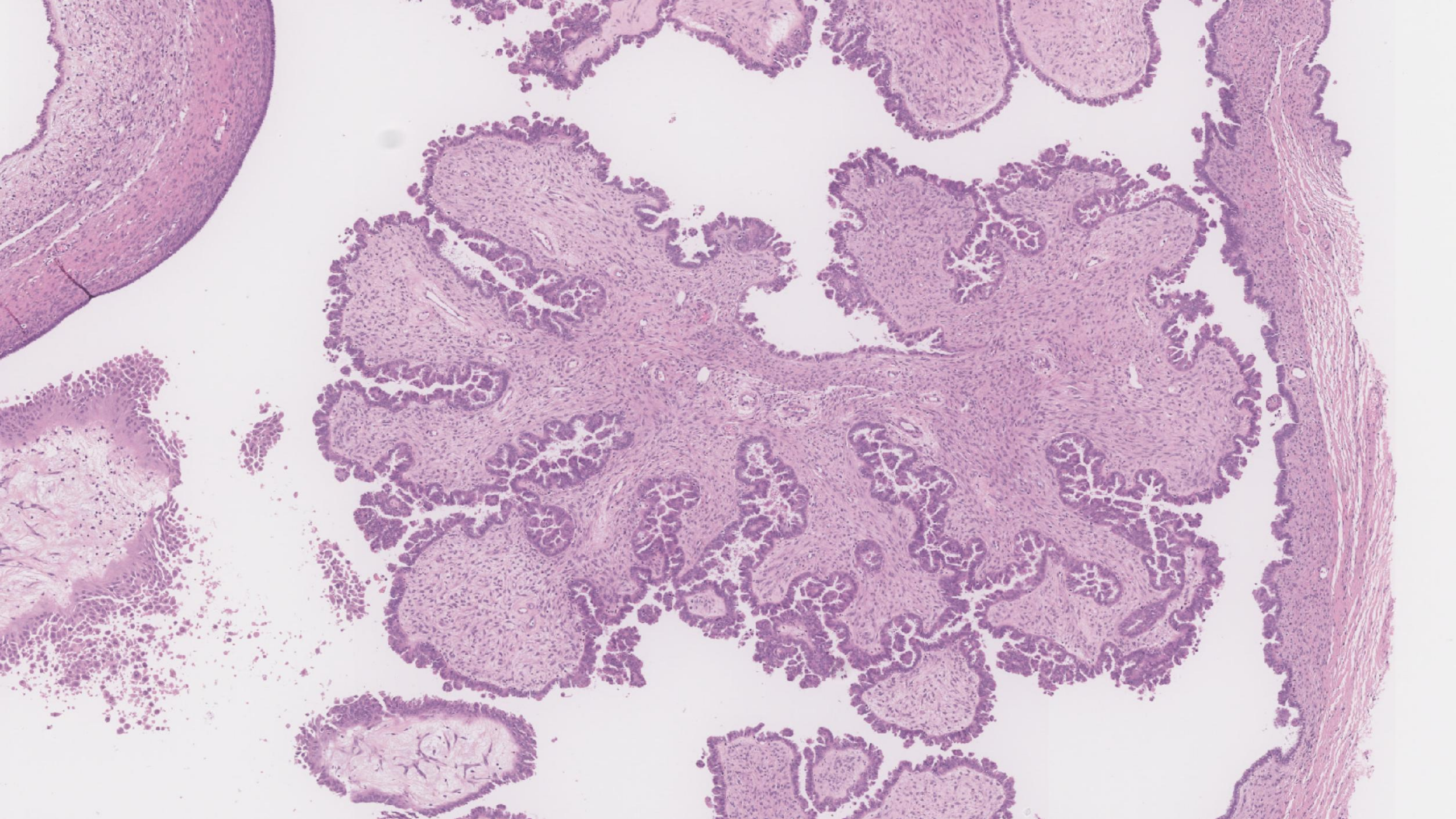

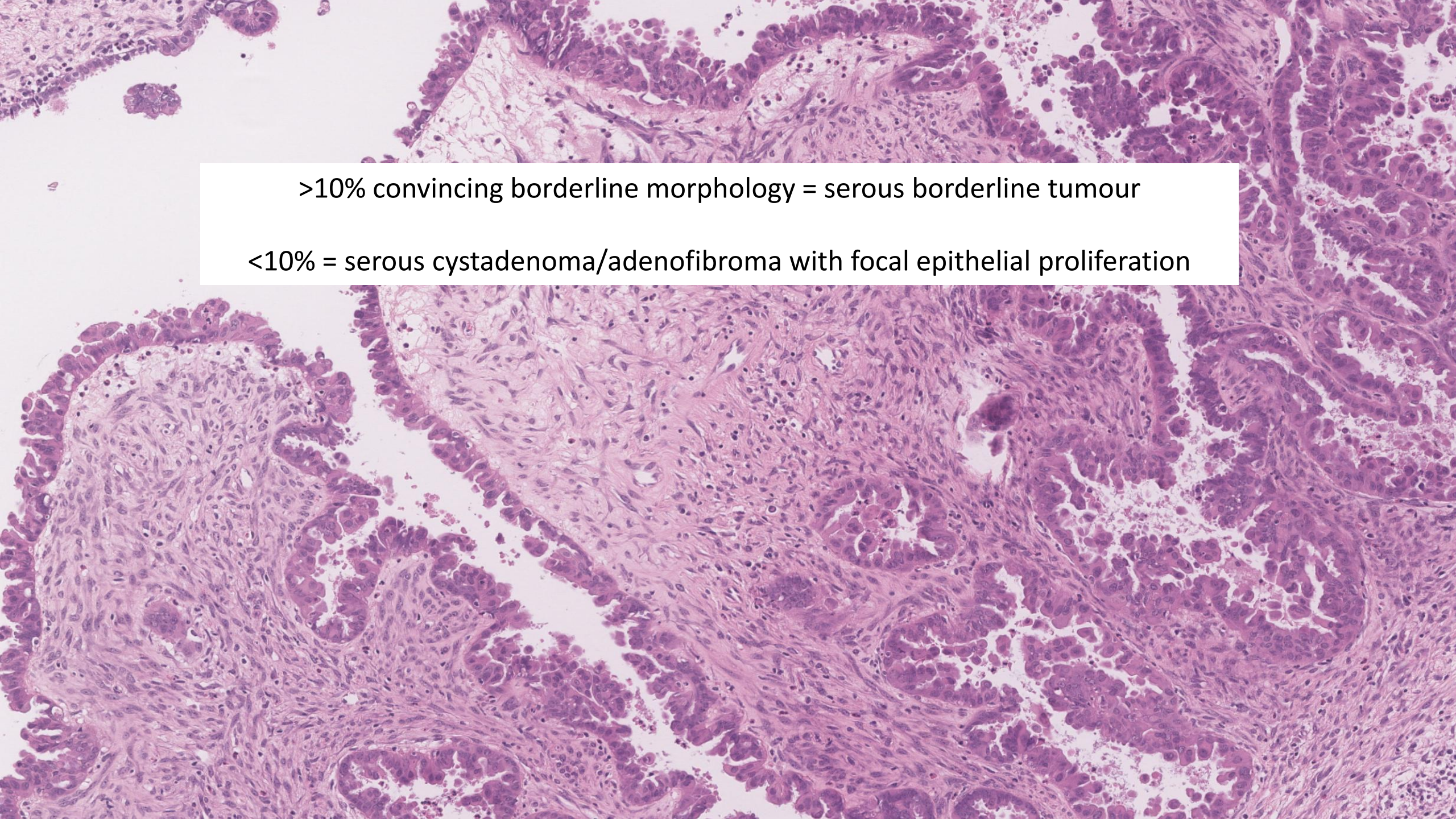
>10% convincing borderline morphology = serous borderline tumour
<10% = serous cystadenoma/adenofibroma with focal epithelial proliferation

Micropapillary/cribriform architecture

- Less than 10% of all serous borderline tumours
- Compared to typical serous borderline tumour:
  - + advanced stage
  - + invasive implants (extra-ovarian low grade serous carcinoma)
  - + subsequent low grade serous carcinoma (specifically in otherwise stage I disease)
- So how do we recognize it?

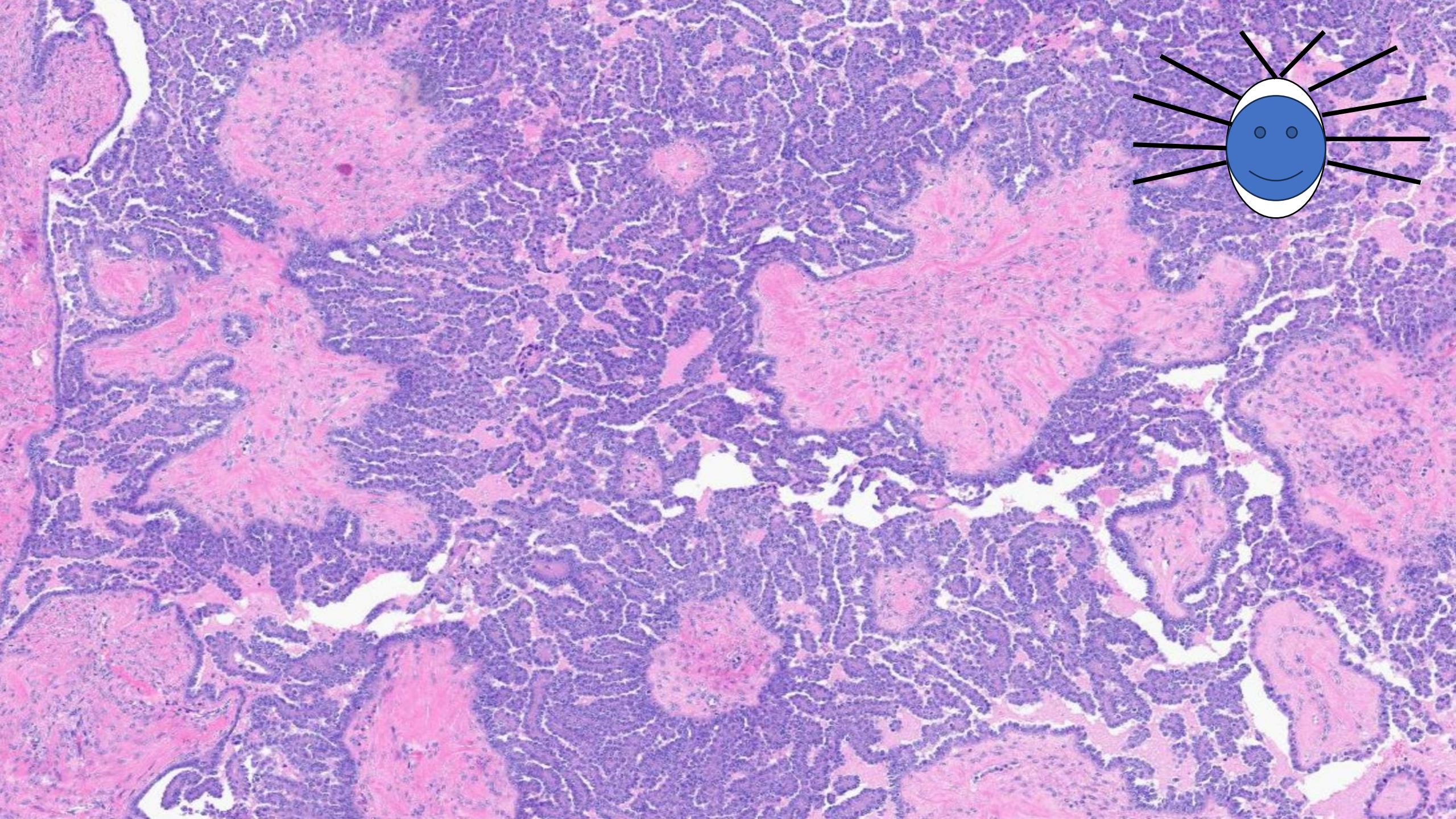

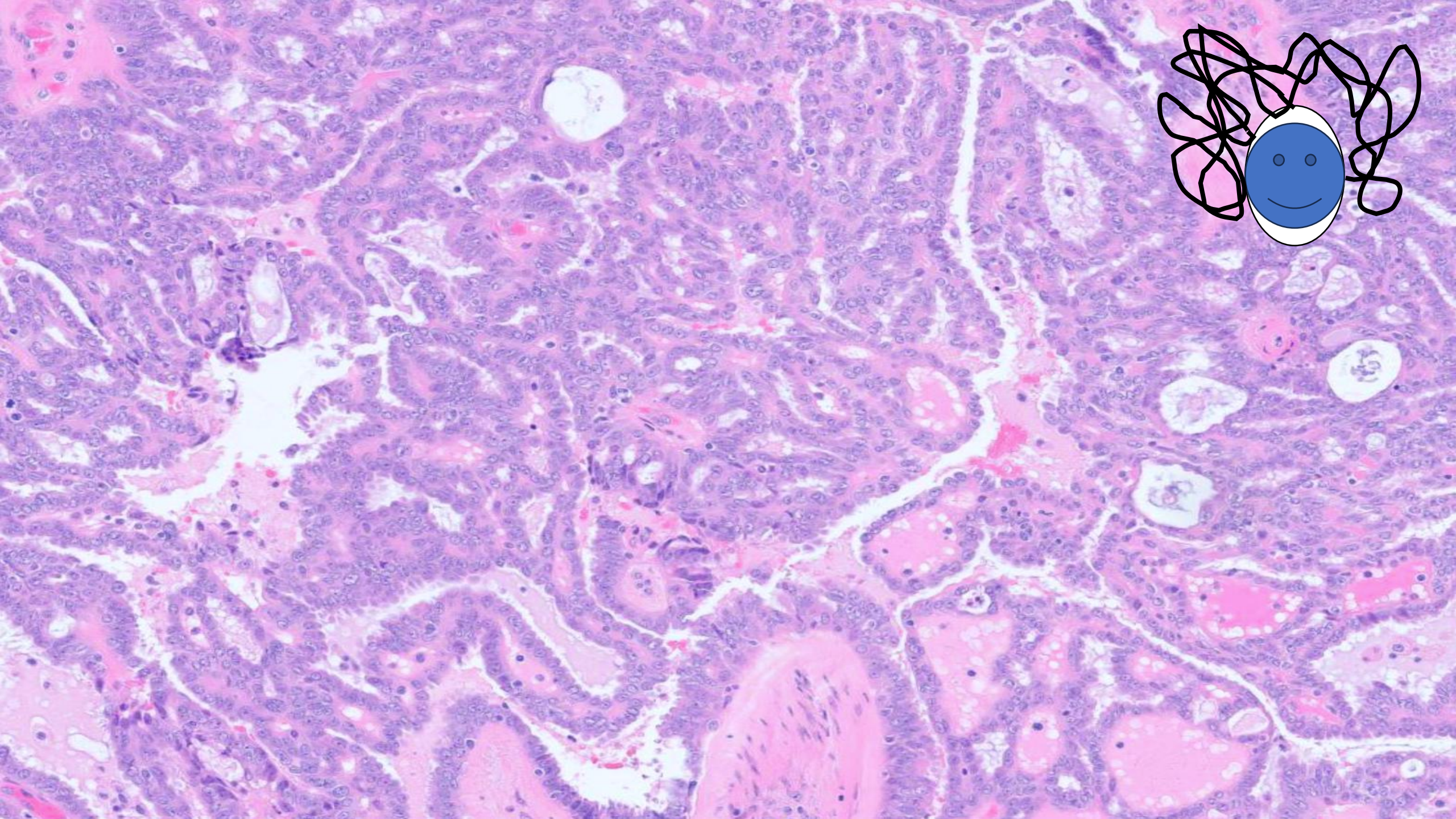

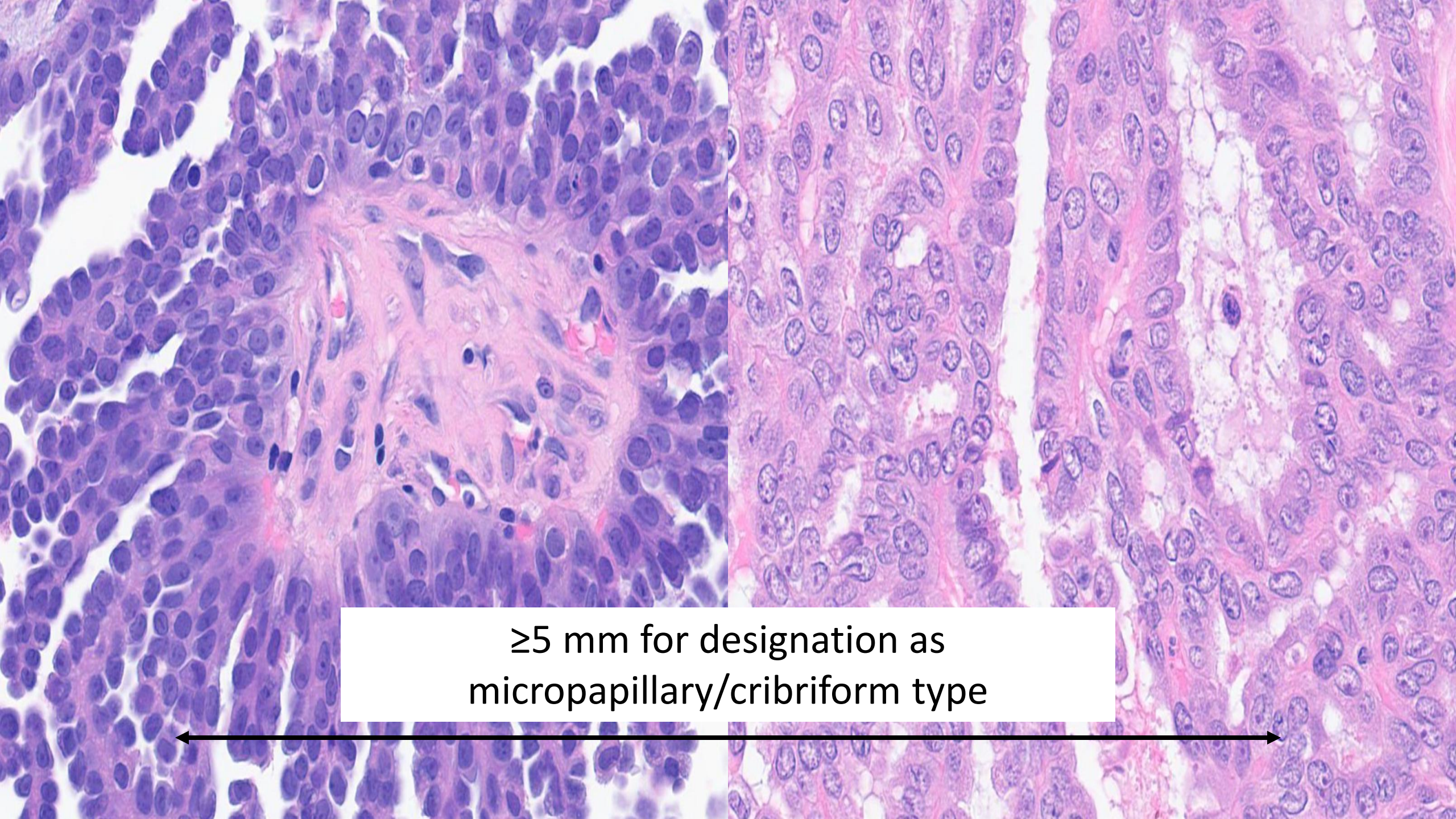
≥5 mm for designation as
micropapillary/cribriform type

Microinvasion vs. microinvasive carcinoma

- Various definitions and size cutoffs used in the literature
  - < 5 mm = current quantitative definition
- Microinvasion type morphology: not entirely clear but no specific clinical significance in most studies
- Microinvasive carcinoma morphology: unclear clinical significance due to limited data but, significantly more frequent in micropapillary type
  - Overt low grade serous carcinoma (≥5 mm) identified in ~30% of cases with increased sampling up to 2 blocks/cm tumour size

PMID 28248817
PMID 30480646

Microinvasion –
eosinophilic cell pattern

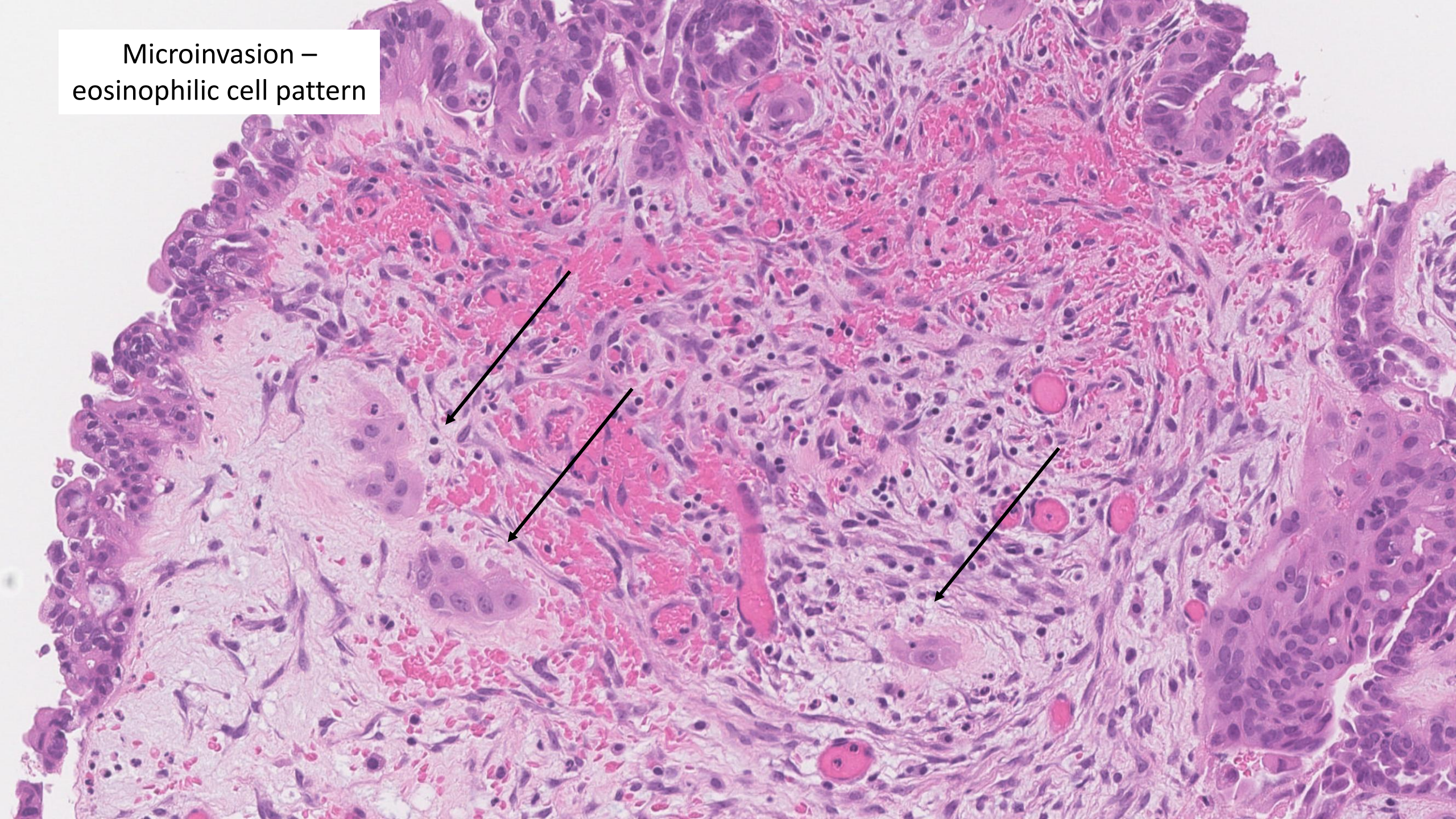

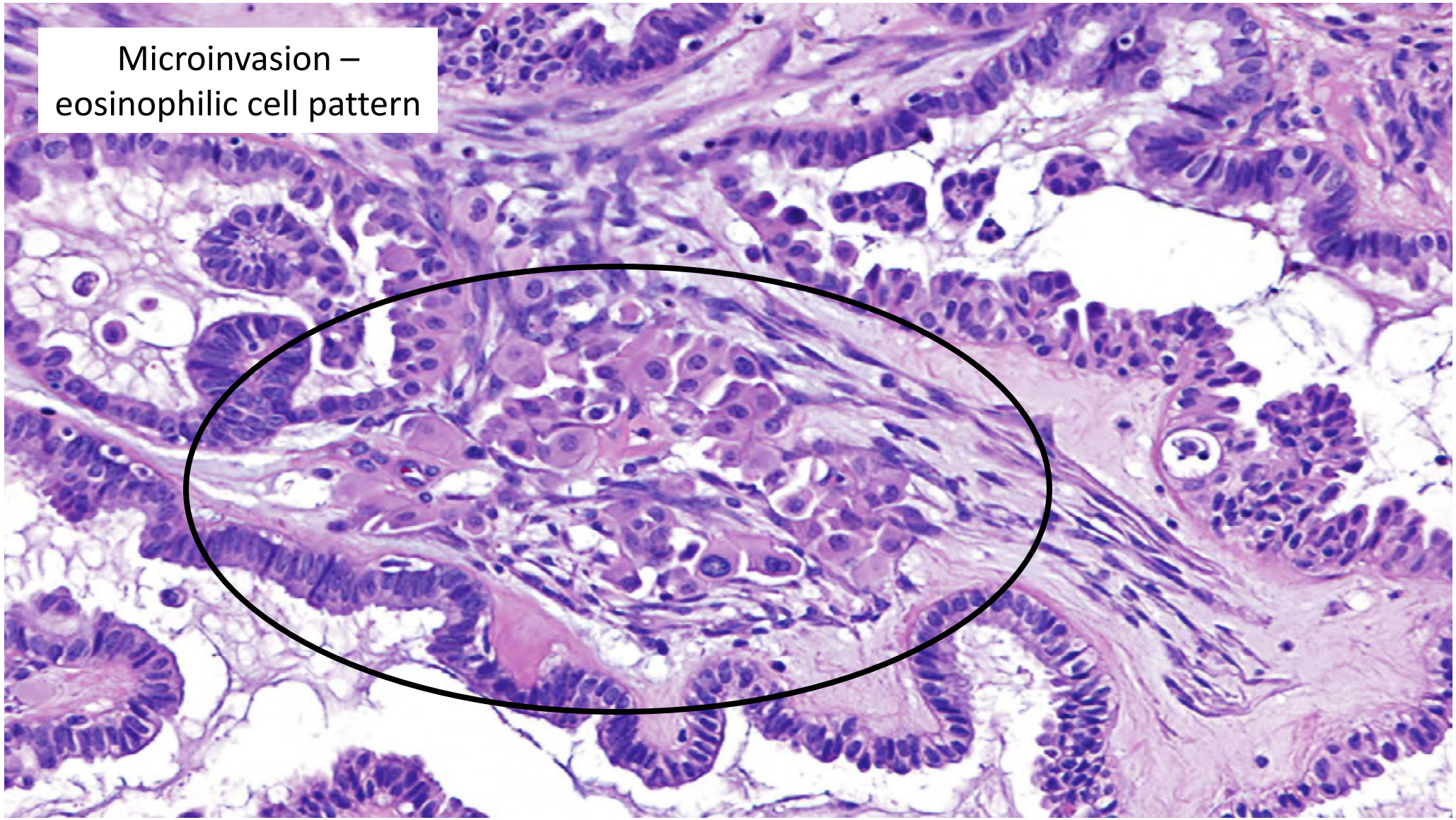
Microinvasion –
eosinophilic cell pattern

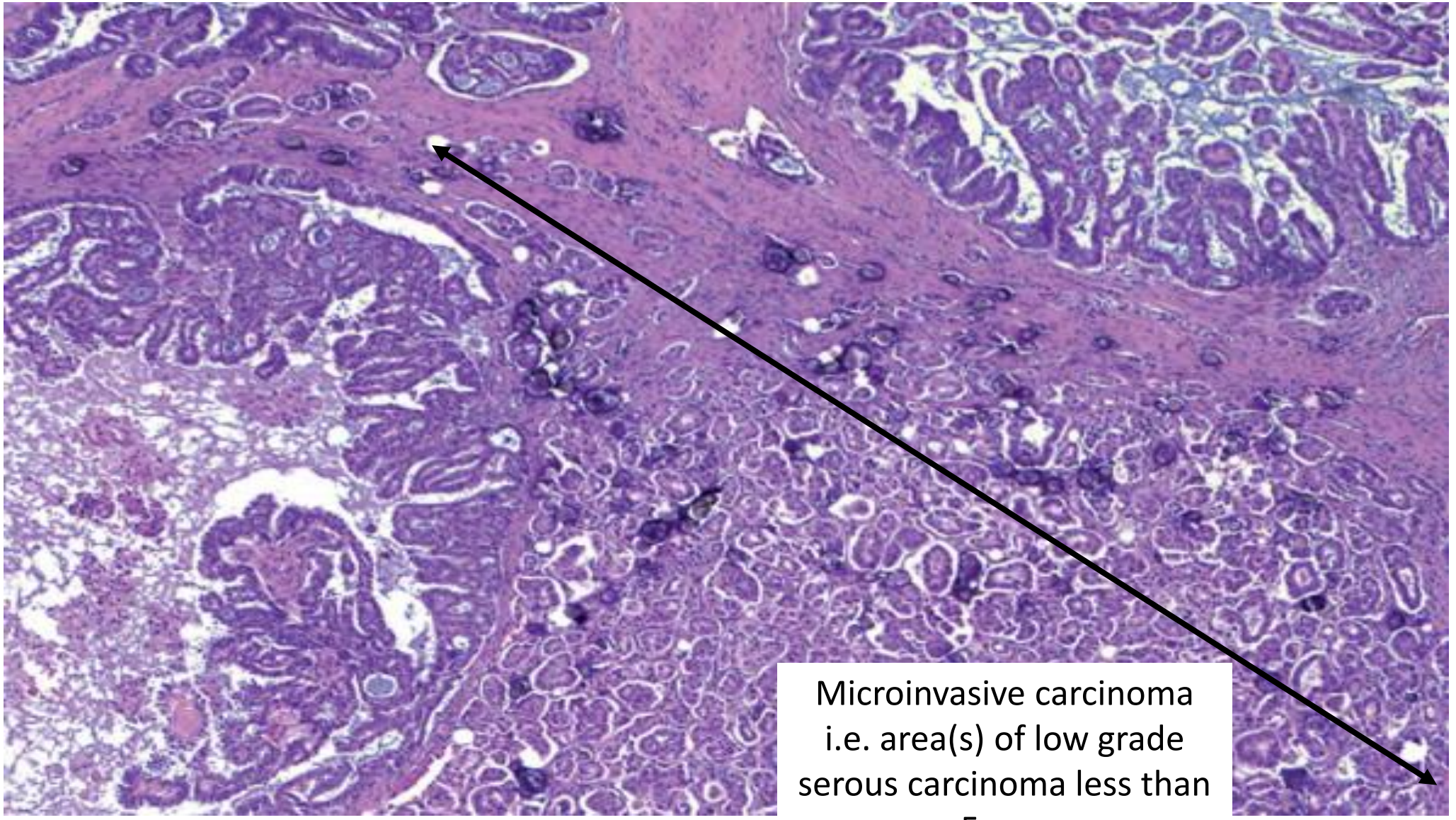
Microinvasive carcinoma
i.e. area(s) of low grade
serous carcinoma less than
5 mm

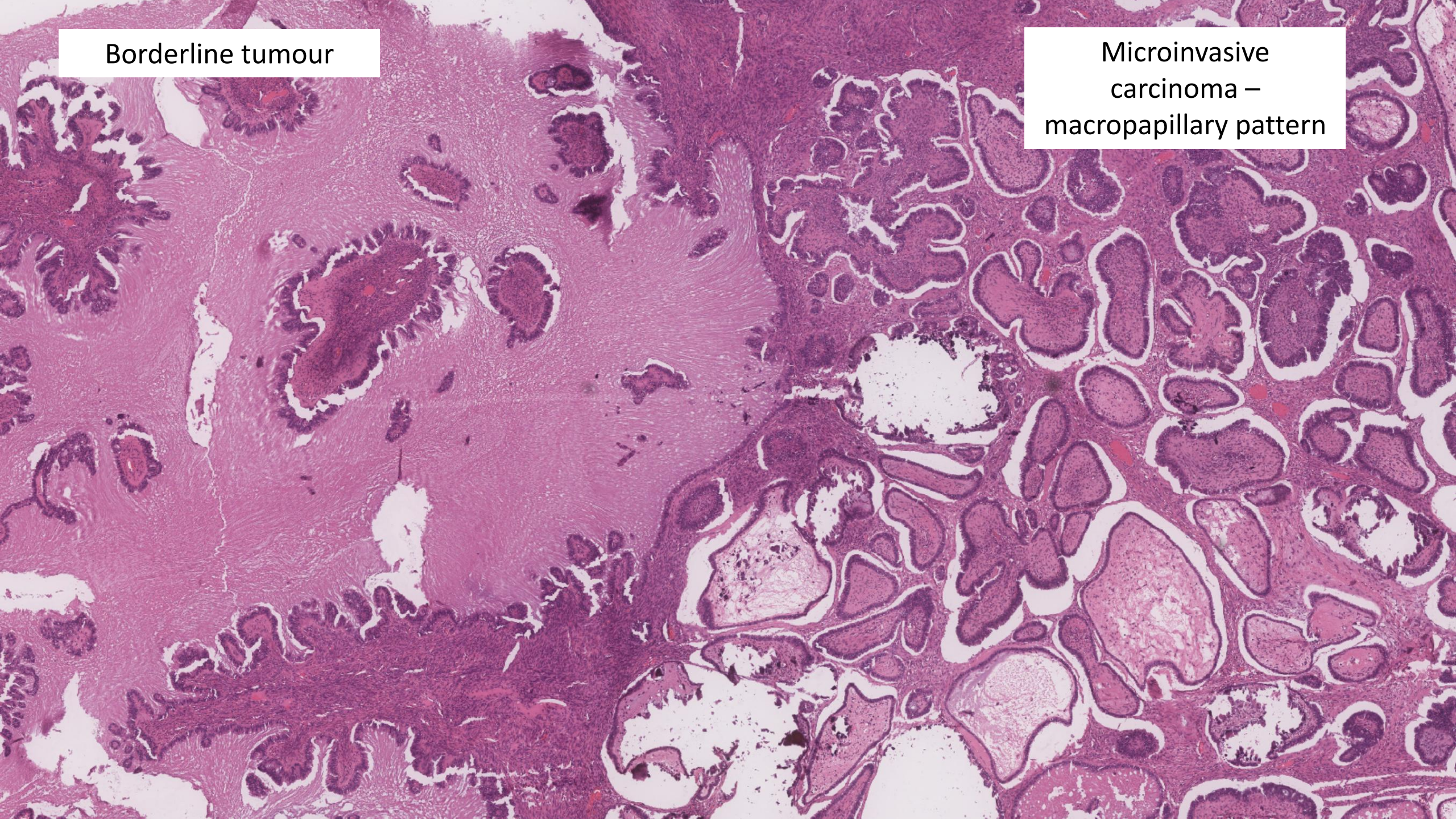
Borderline tumour
Microinvasive carcinoma – macropapillary pattern

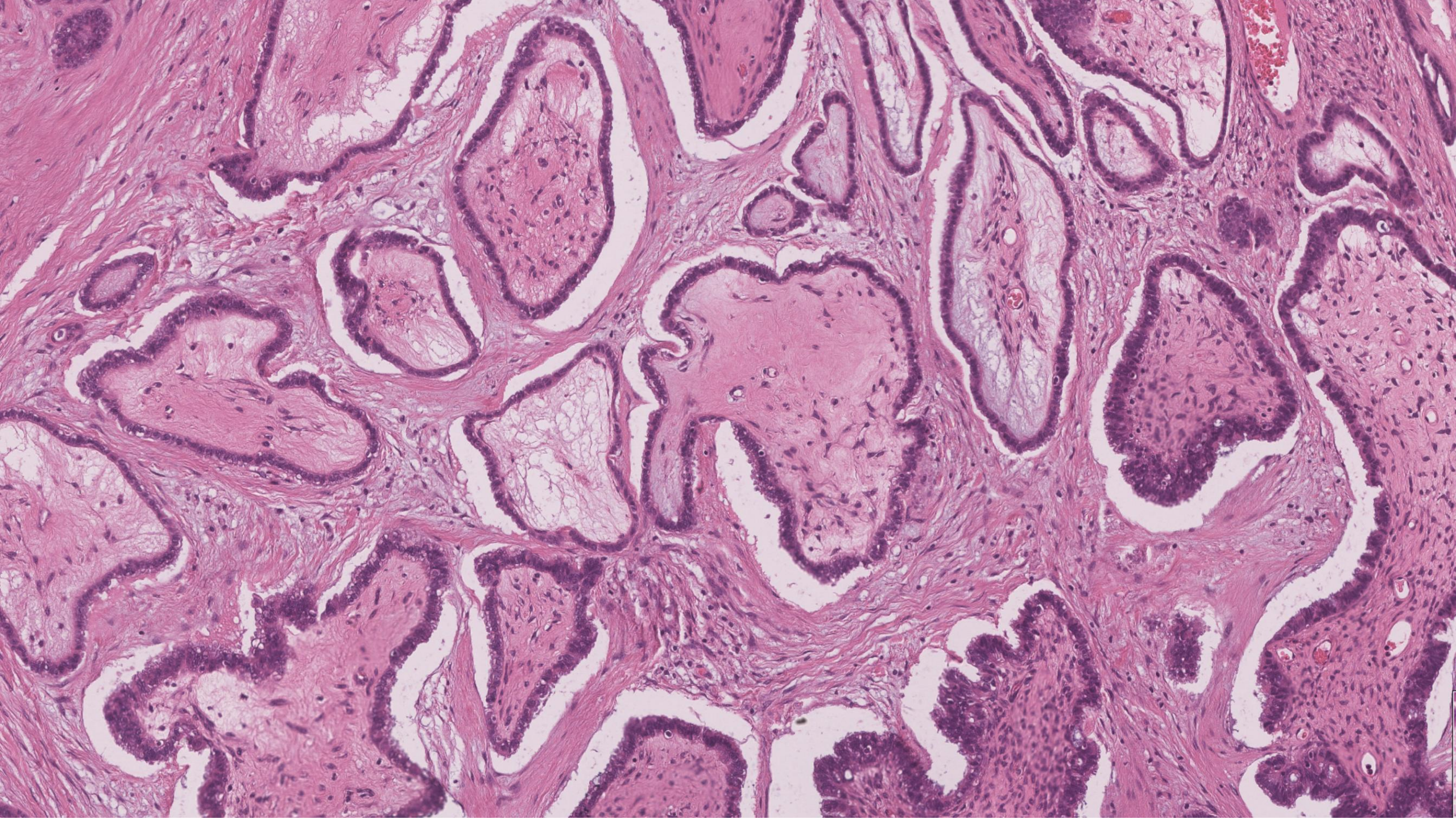

Implants

"Non-invasive" involvement of extra-ovarian tissue by borderline tumour

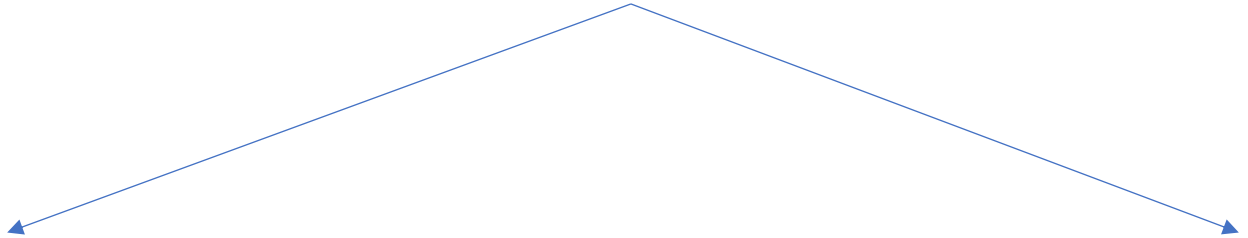

Epithelial implant

Desmoplastic implant

No clinical reason to distinguish between these (but your jurisdiction may recommend/require it for reporting), but important to know allowable spectrum

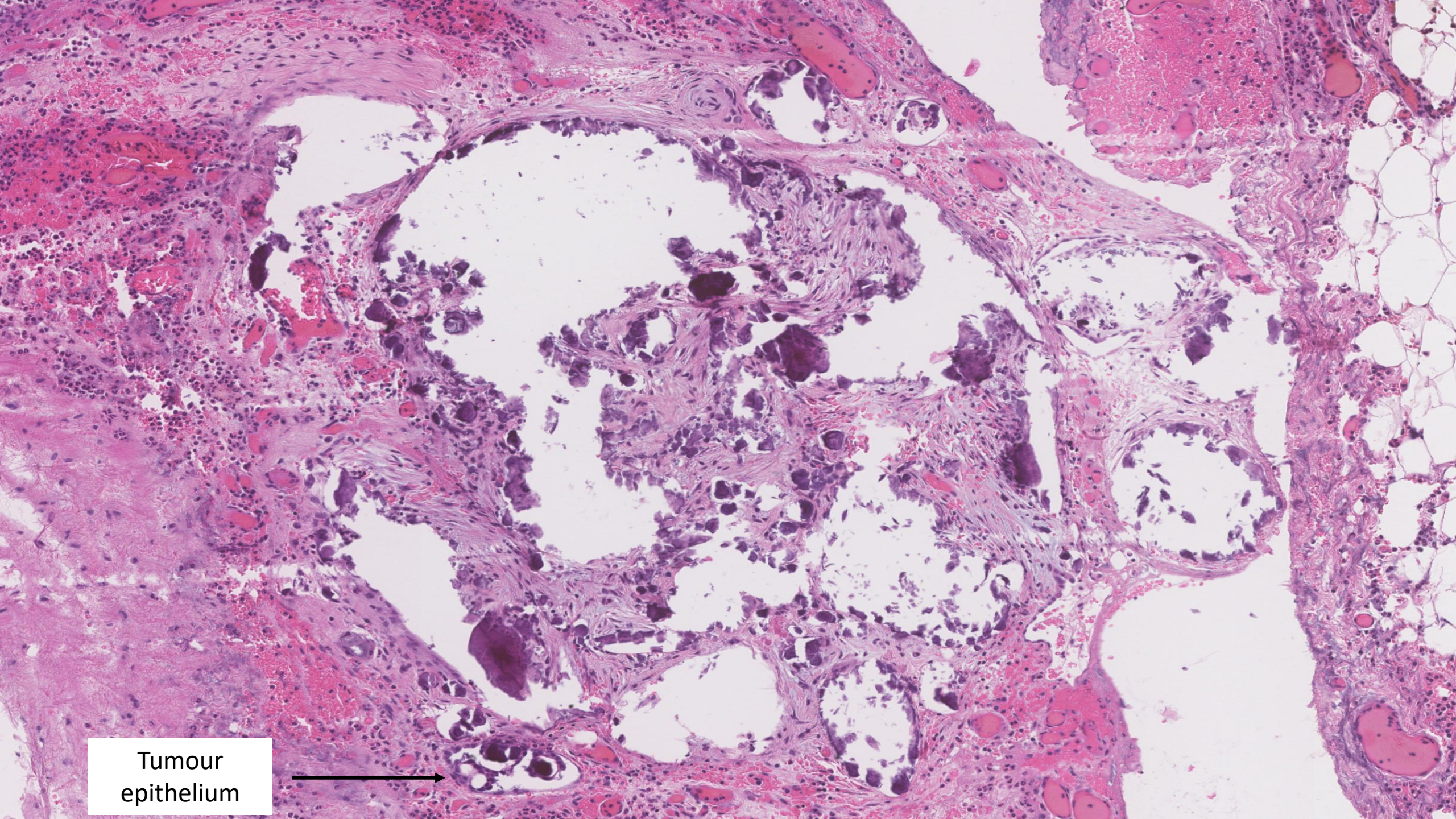
Tumour
epithelium

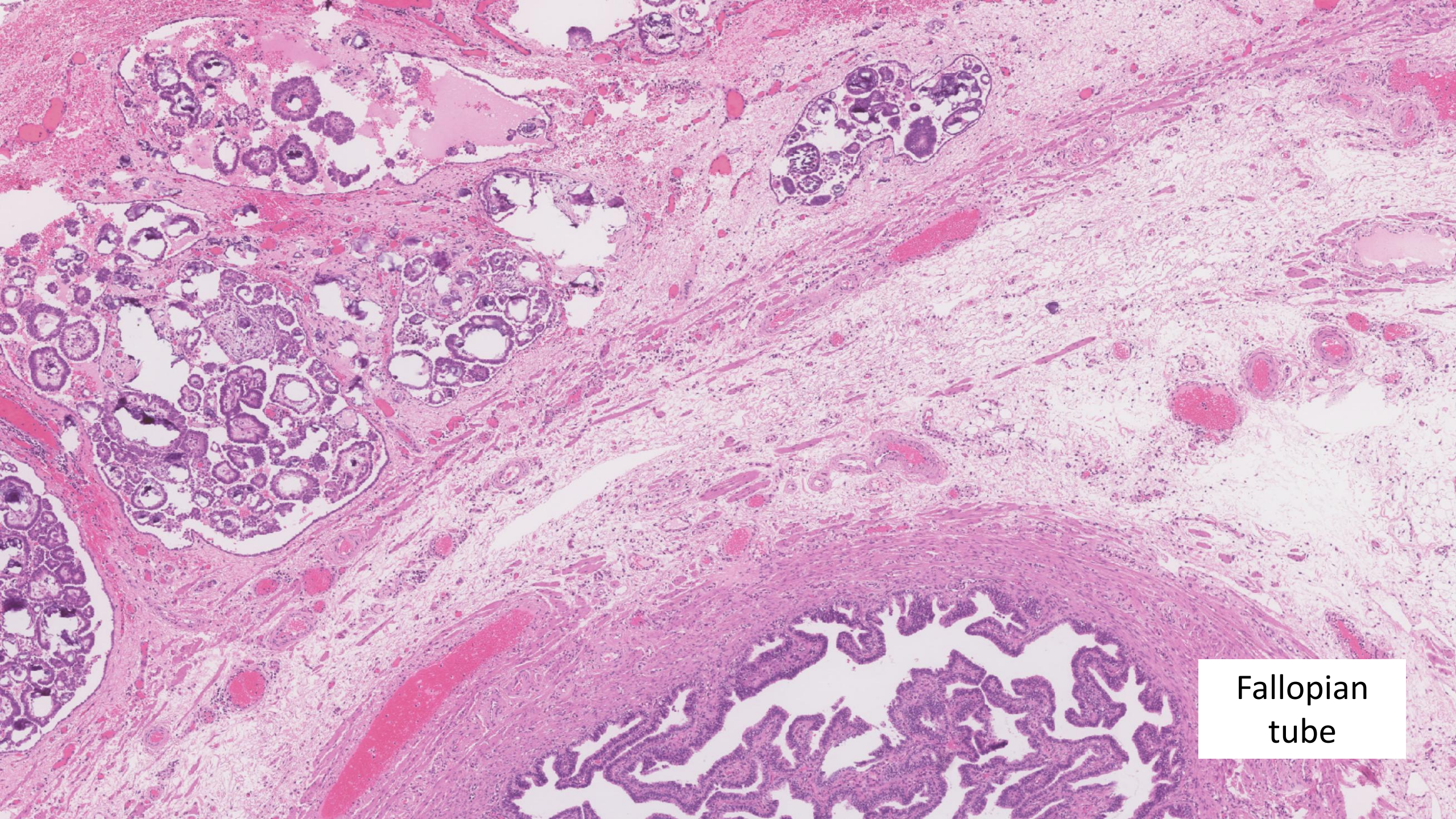
Fallopian tube

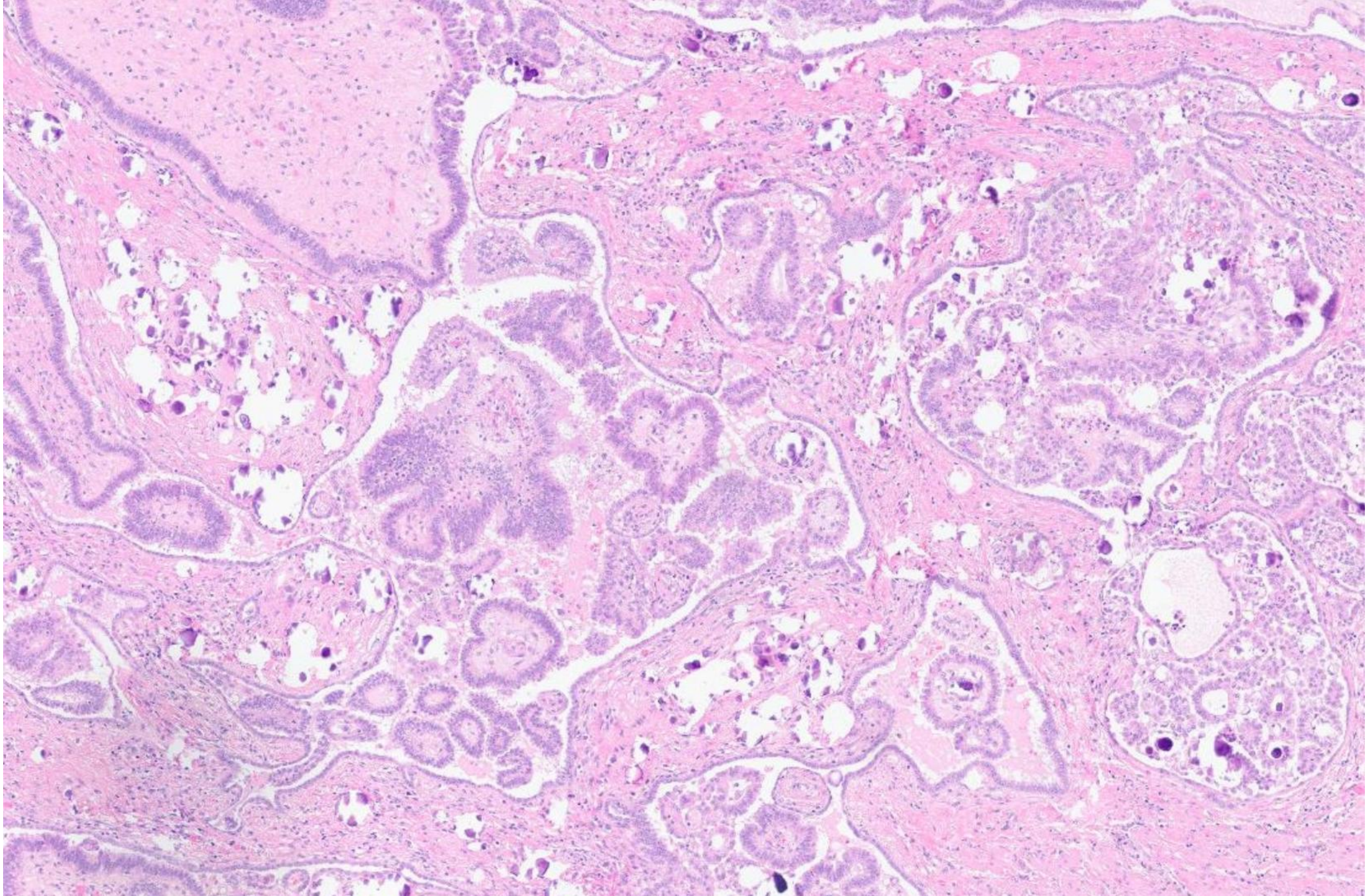

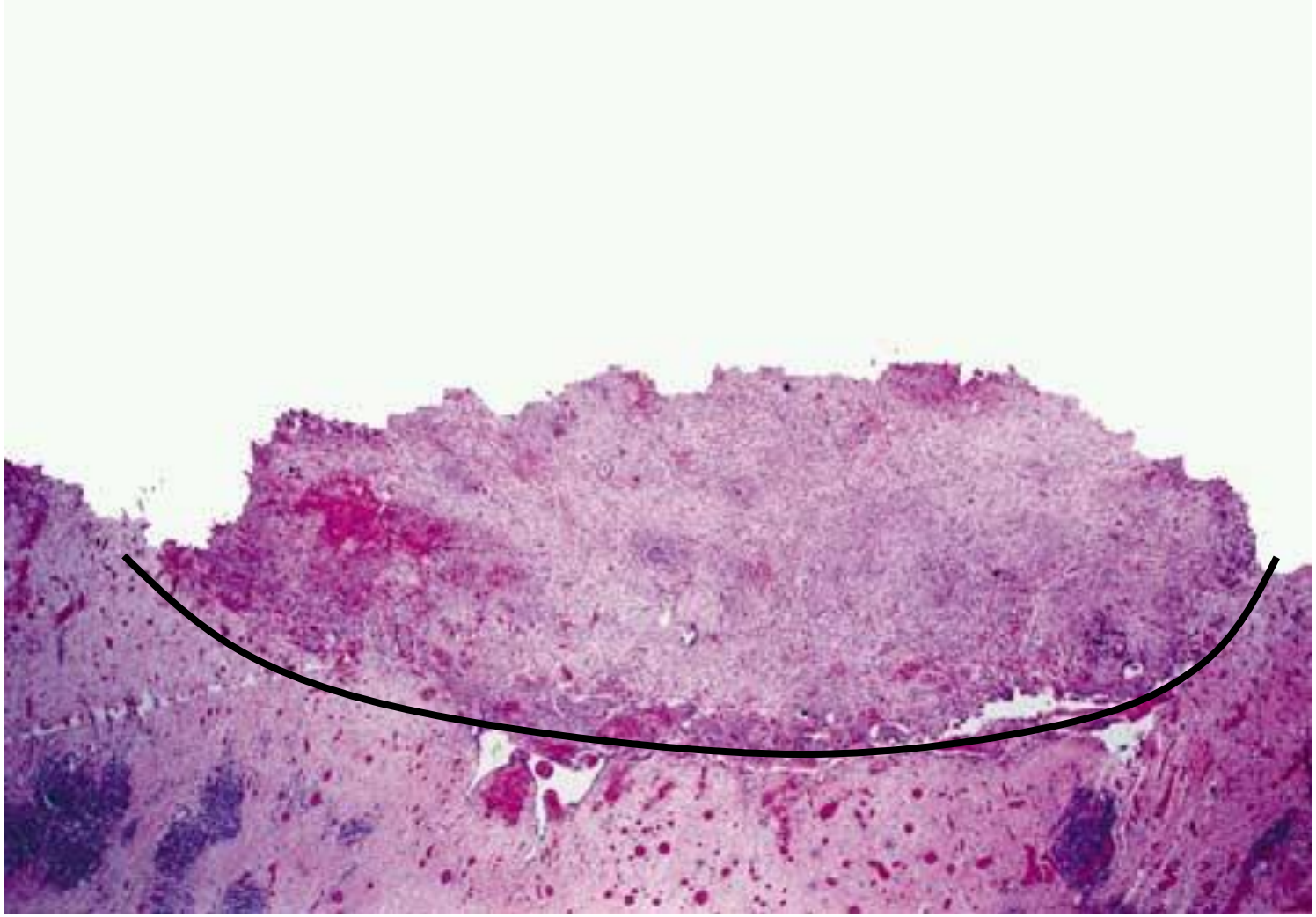

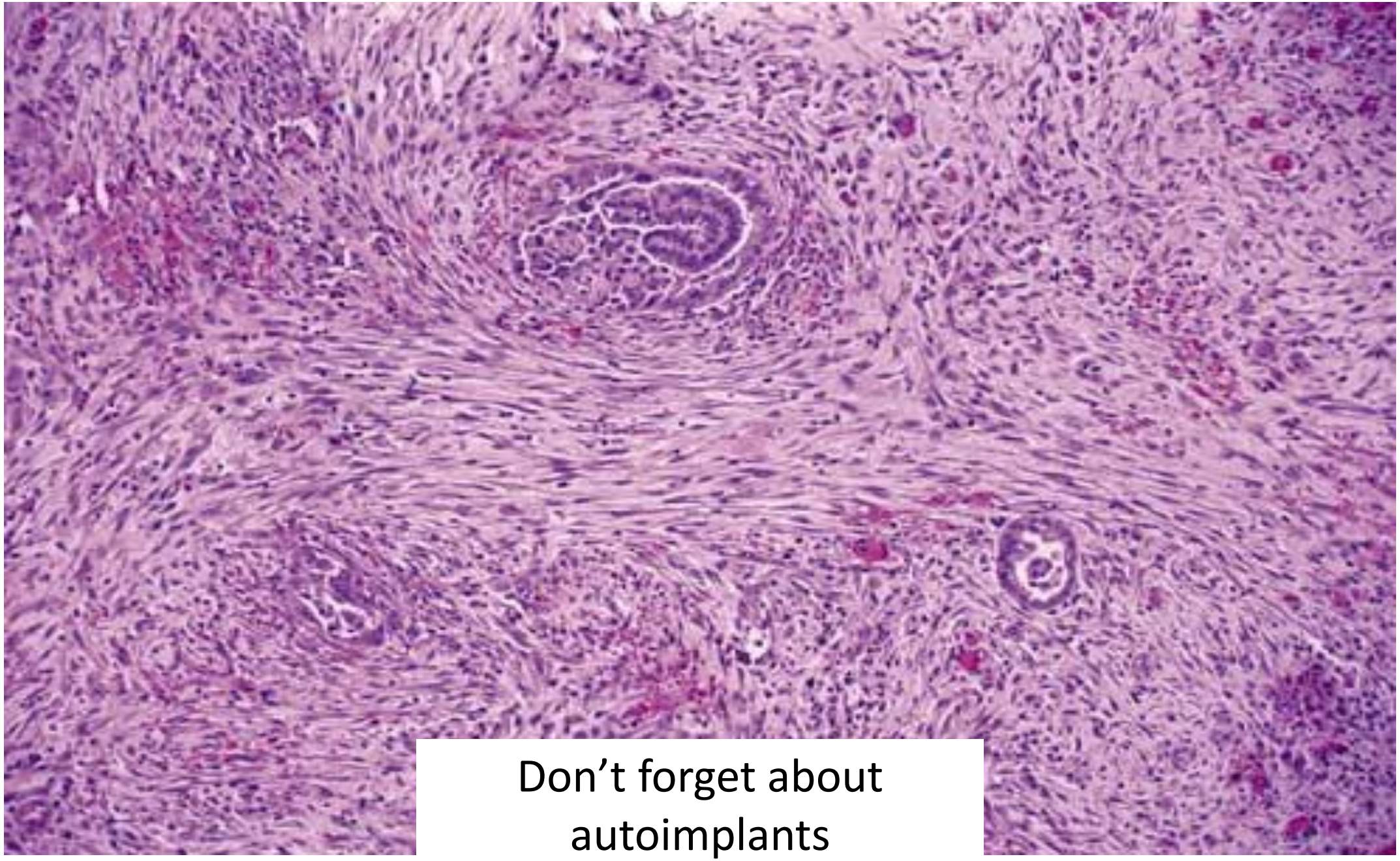

Don’t forget about autoimplants

What about “invasive implants”?

- Varying definitions over the years
- Invariably defined by underlying tissue destructive, either overt or subtle
  - Epithelial component predominates
  - Most commonly micropapillary/cribriform architecture, with stromal retraction/clear surrounding spaces
  - Disruption/obliteration of normal architecture
- Designated as extra-ovarian low grade serous carcinoma

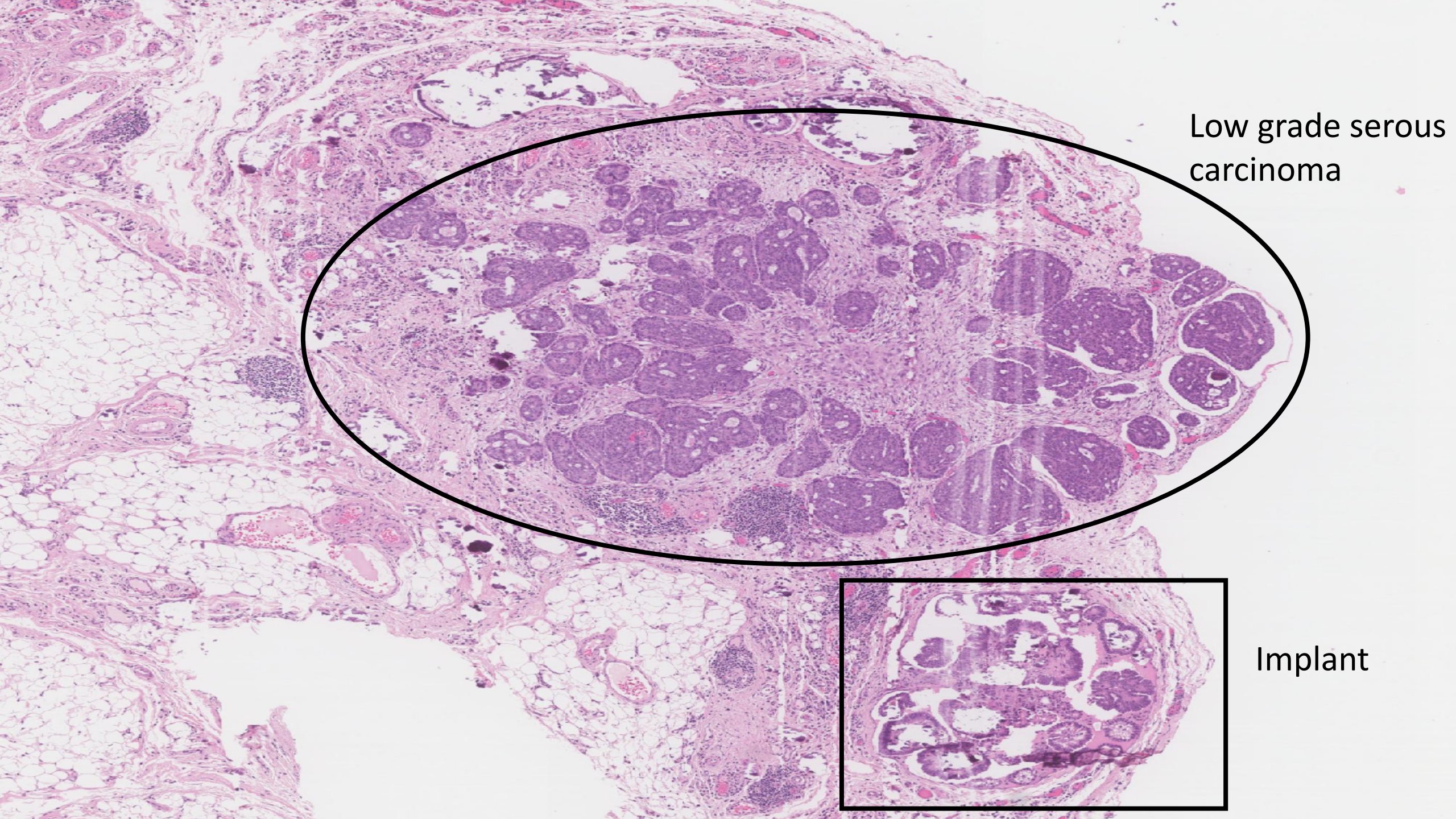
Low grade serous carcinoma
Implant

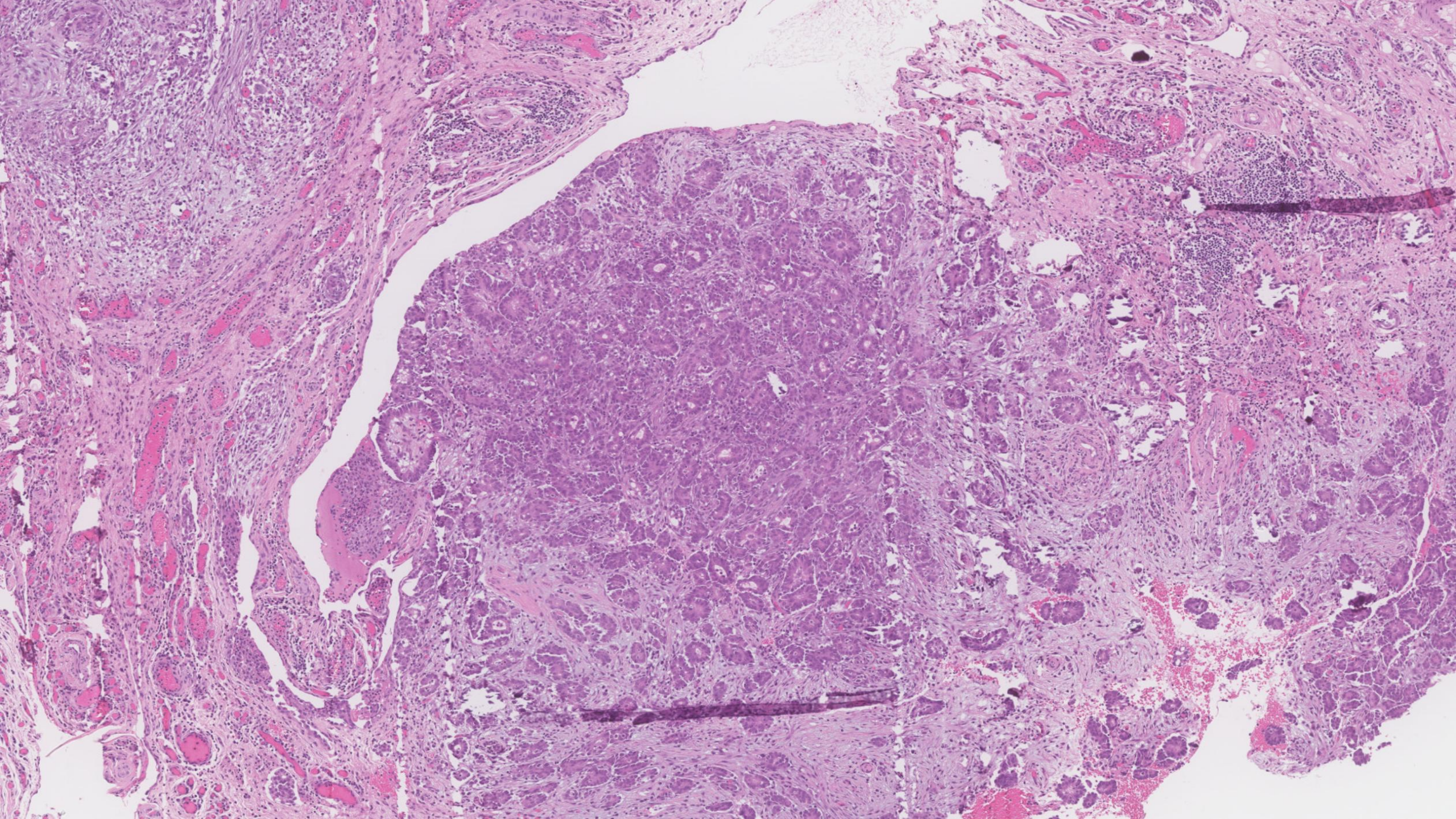

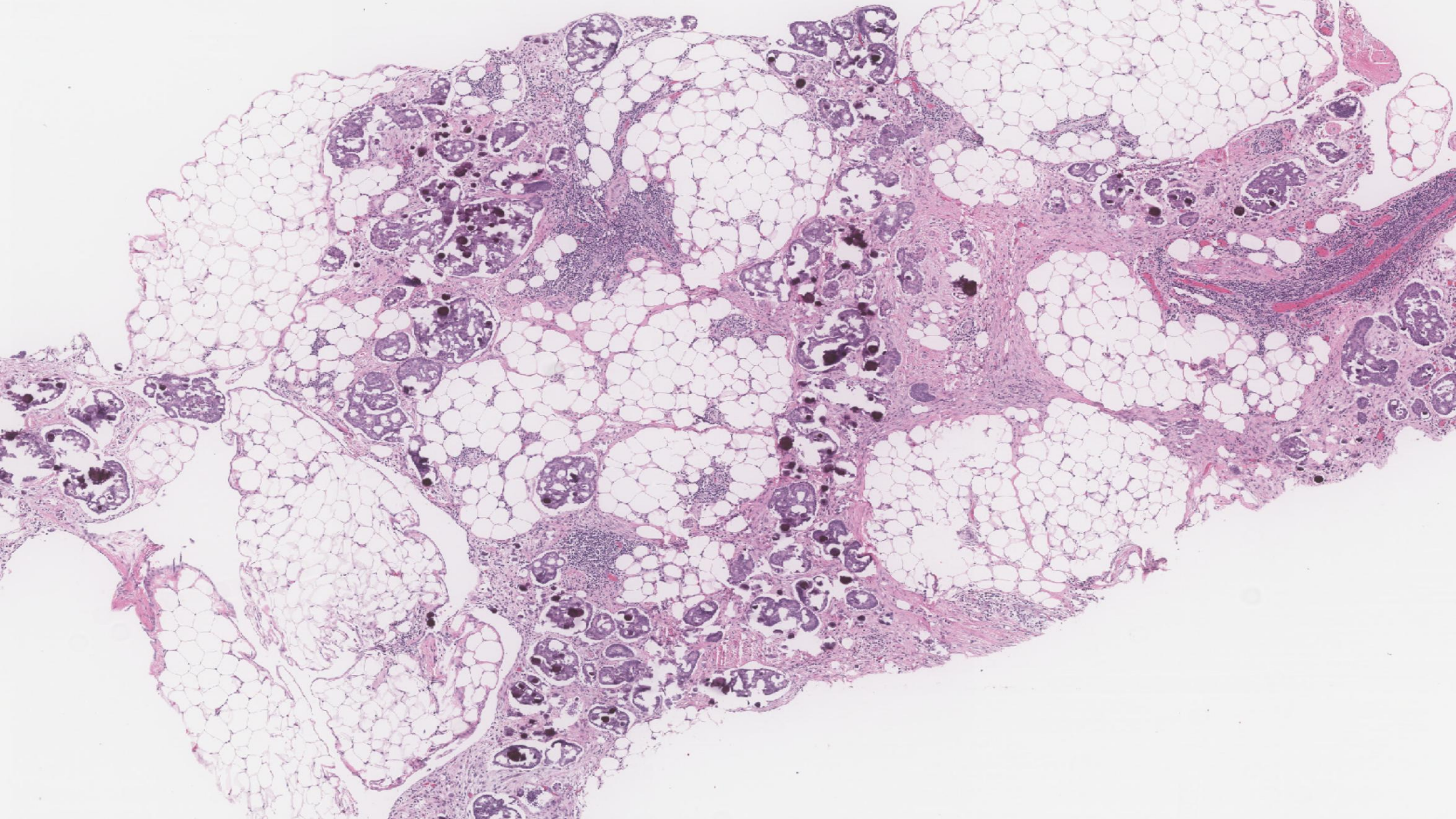

Indeterminate implants?

- Appropriate terminology, in the context of significant difficulty in distinguishing (non-invasive) implants from invasive implants (low grade serous carcinoma)
- BUT, use sparingly
- Submit additional sections, if possible, and seek help from colleagues/specialist

Lymph node involvement

1a. Lymph node involvement by serous borderline tumour ≠ “metastatic carcinoma”

1b. Lymph nodes can be involved by the entire spectrum of low grade serous neoplasia

2. Lymph node involvement by serous borderline tumour as well as low grade serous carcinoma warrants a designation of pN1 (or pM1, if involved lymph node(s) outside of abdominal cavity)

Pelvic lymph node

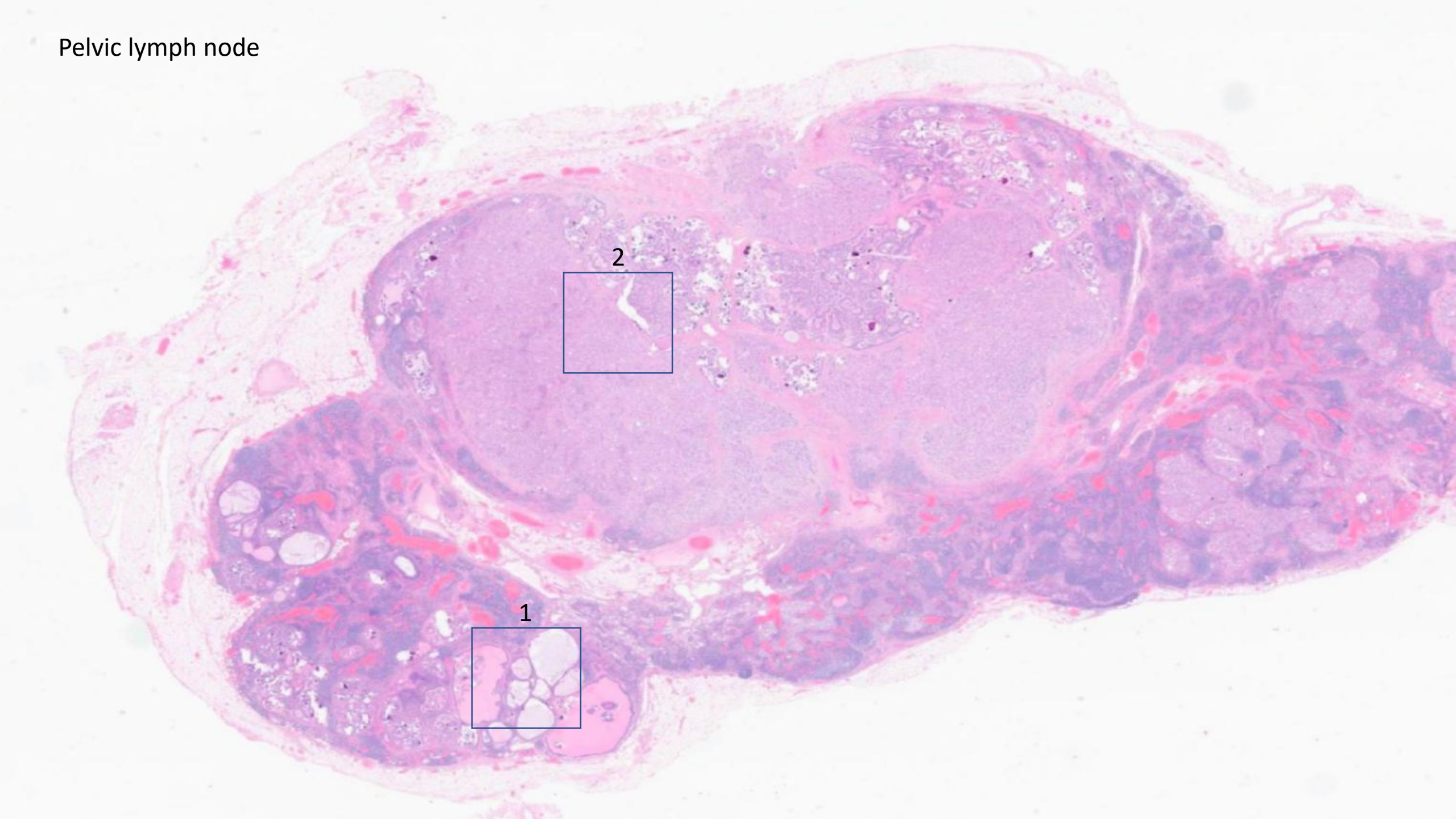

1

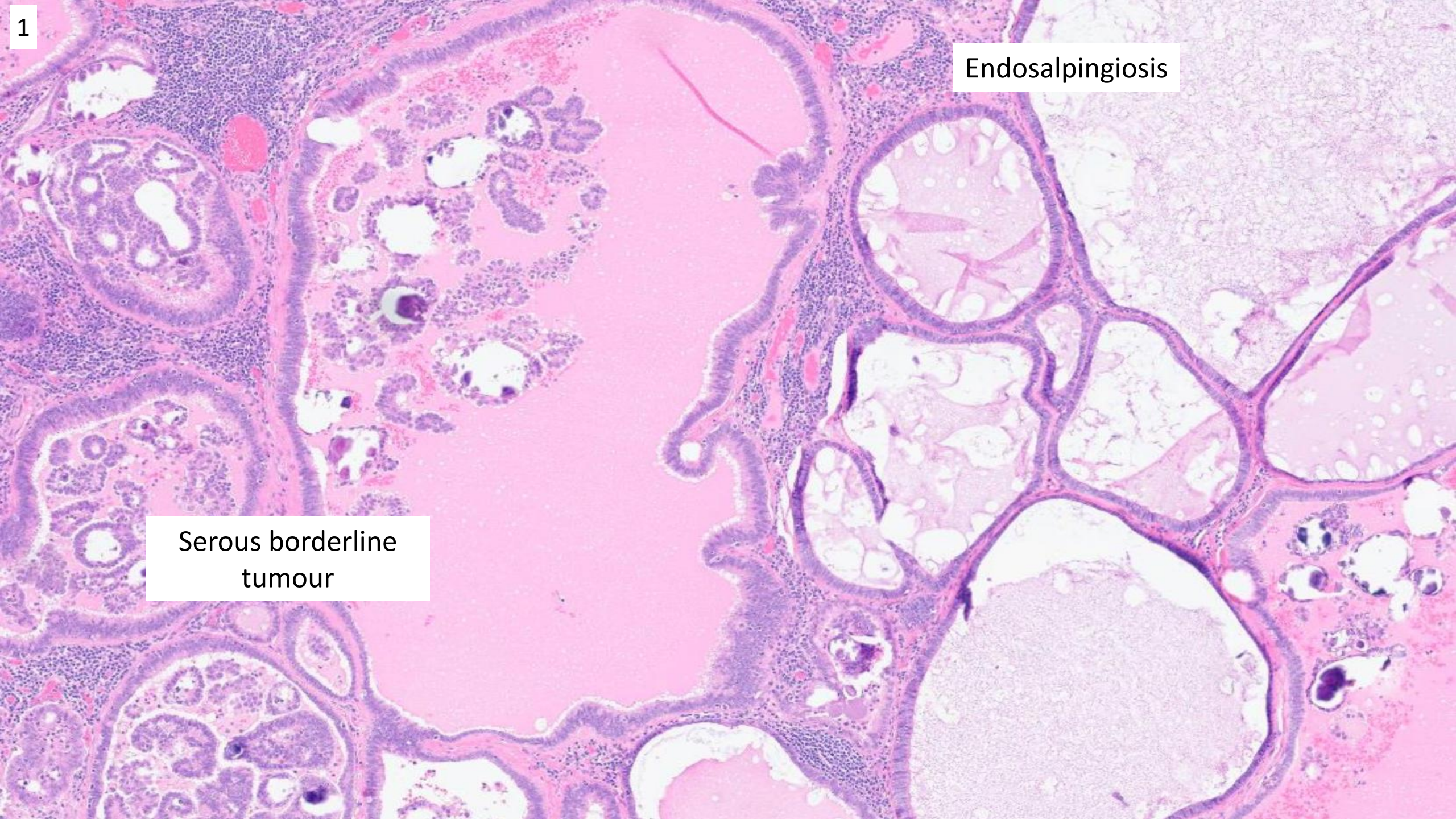

2

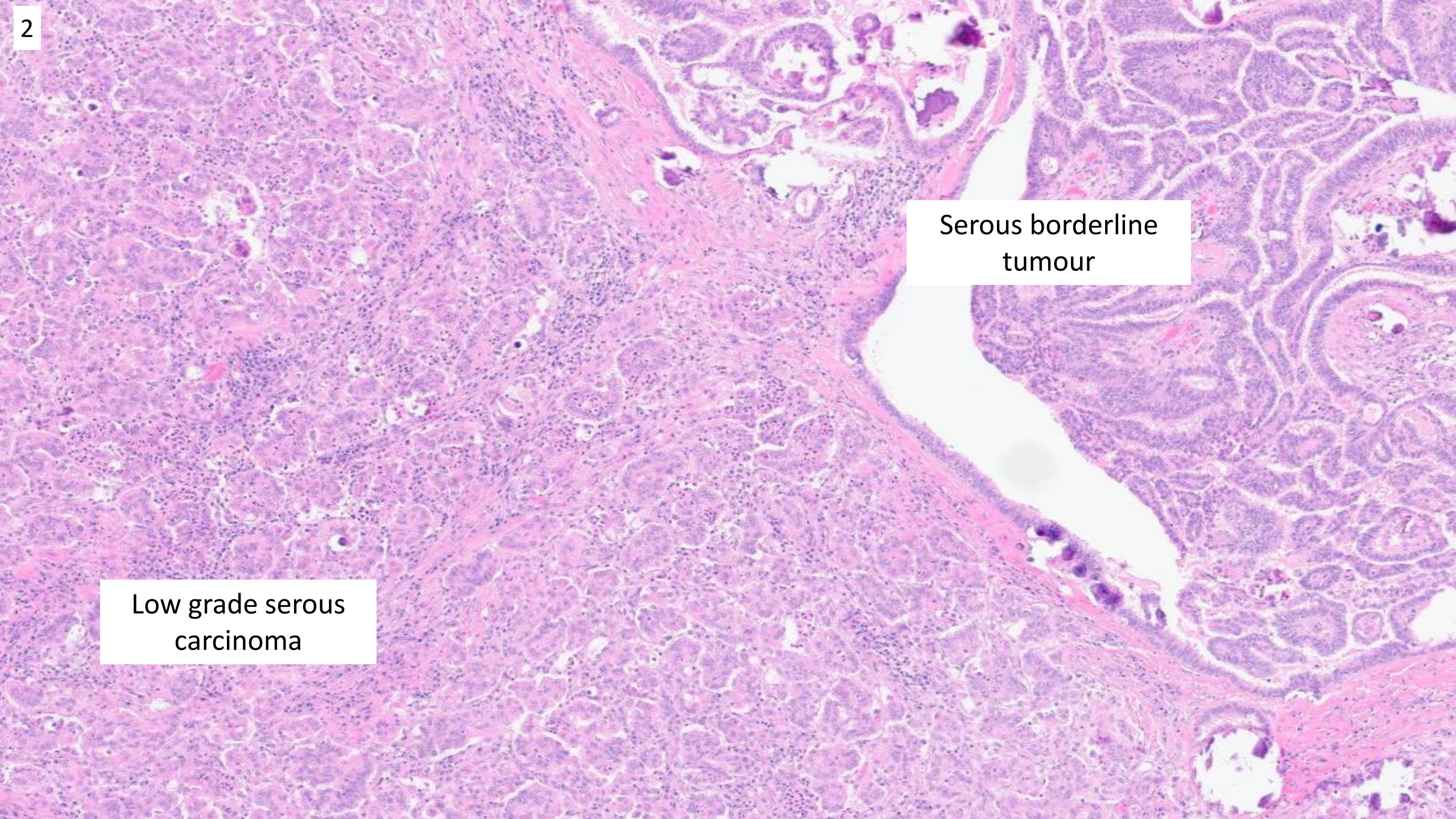

Low grade serous neoplasia in core biopsy material

Don’t forget that not everything is “metastatic carcinoma” – consider borderline tumour/implant

Neck lymph node biopsy

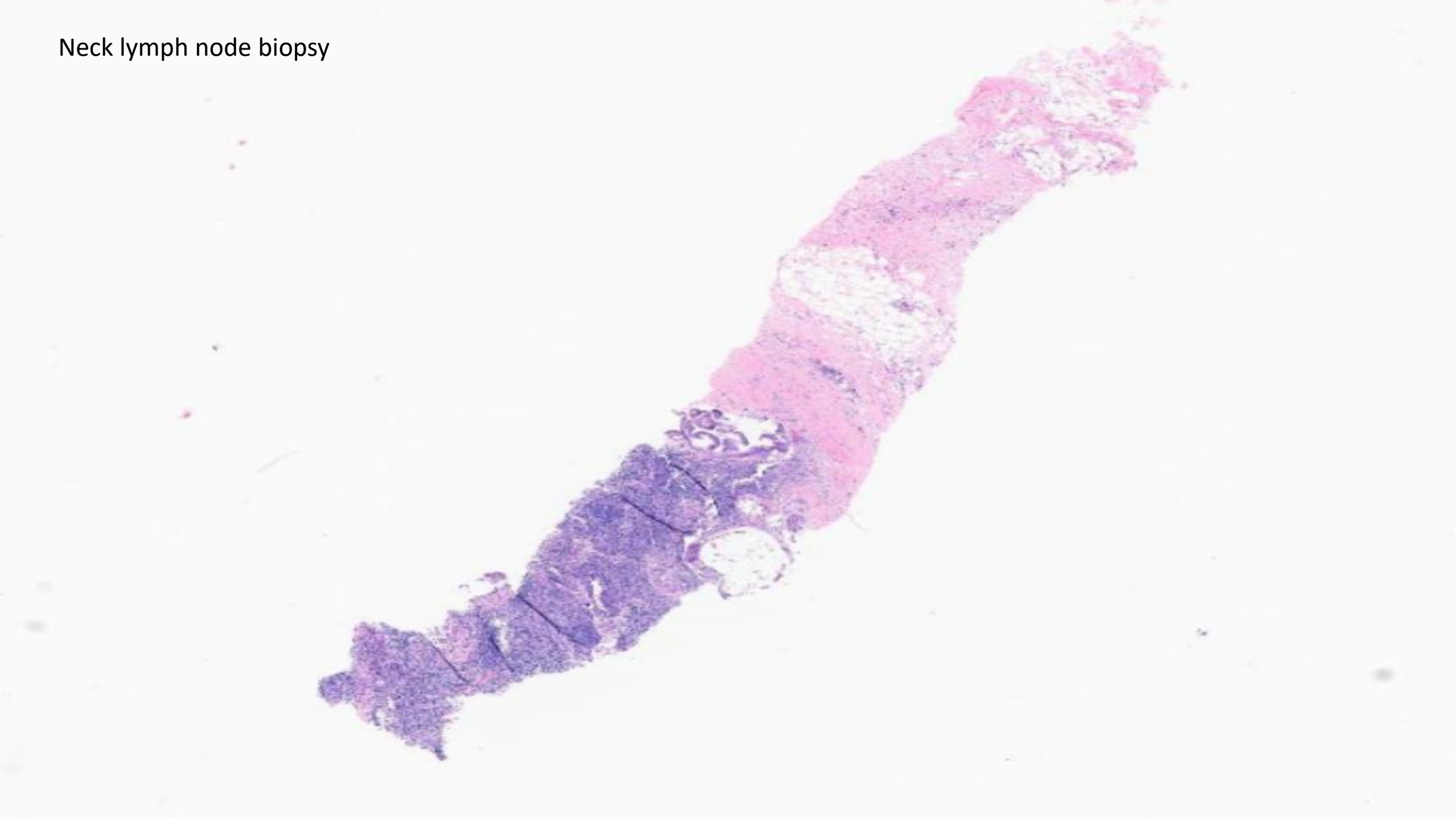

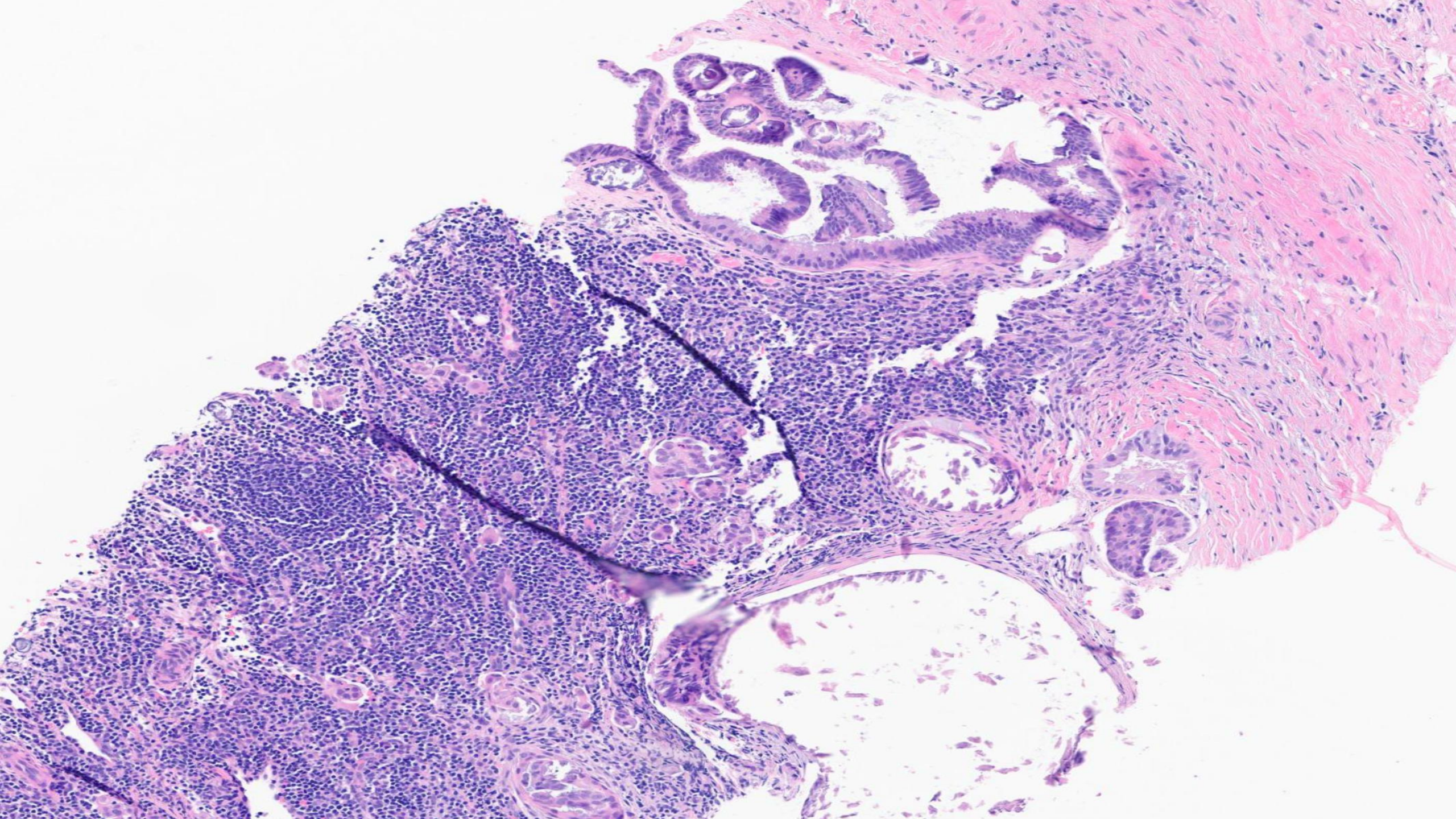

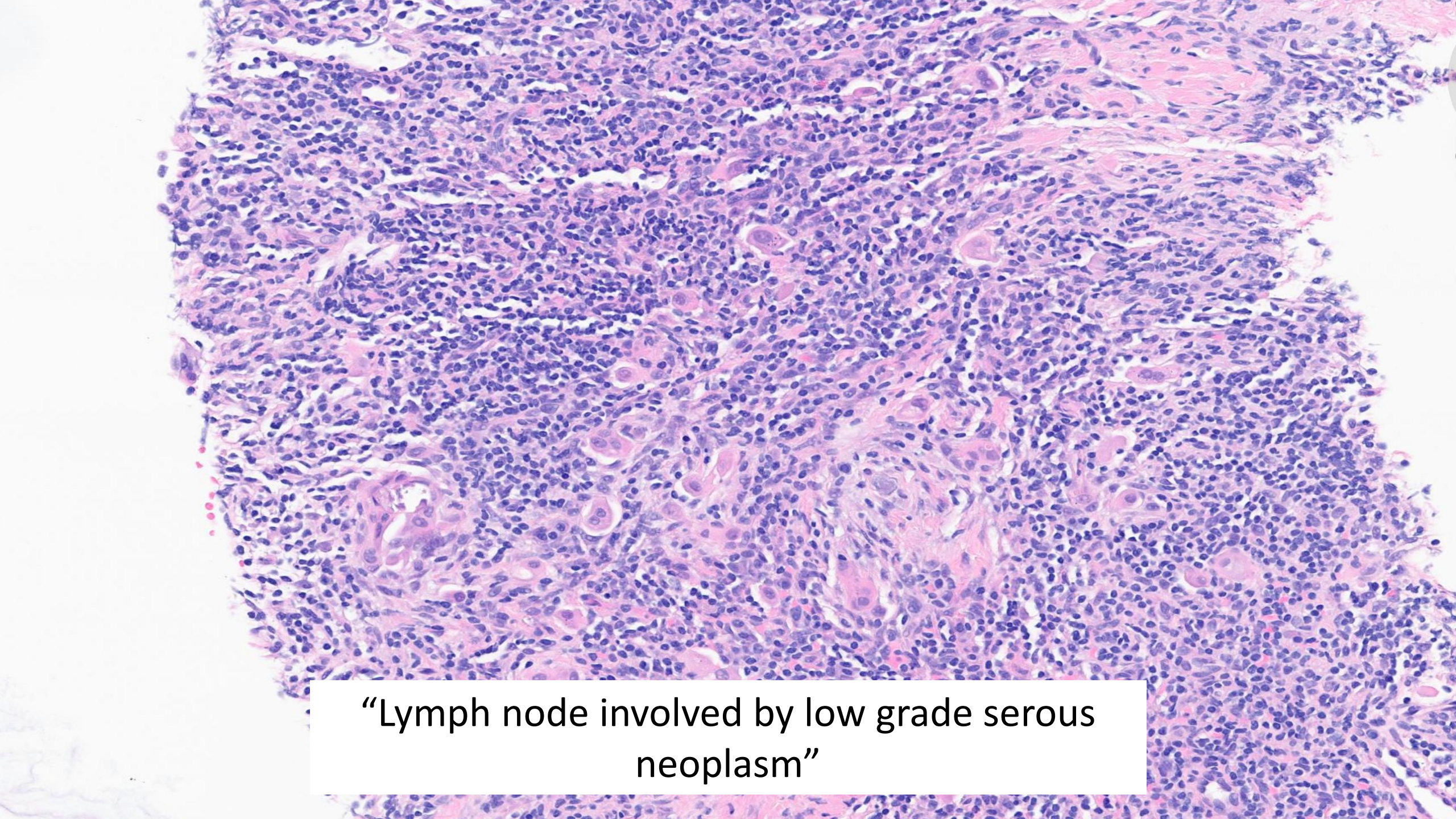

“Lymph node involved by low grade serous neoplasm”

Omental biopsy

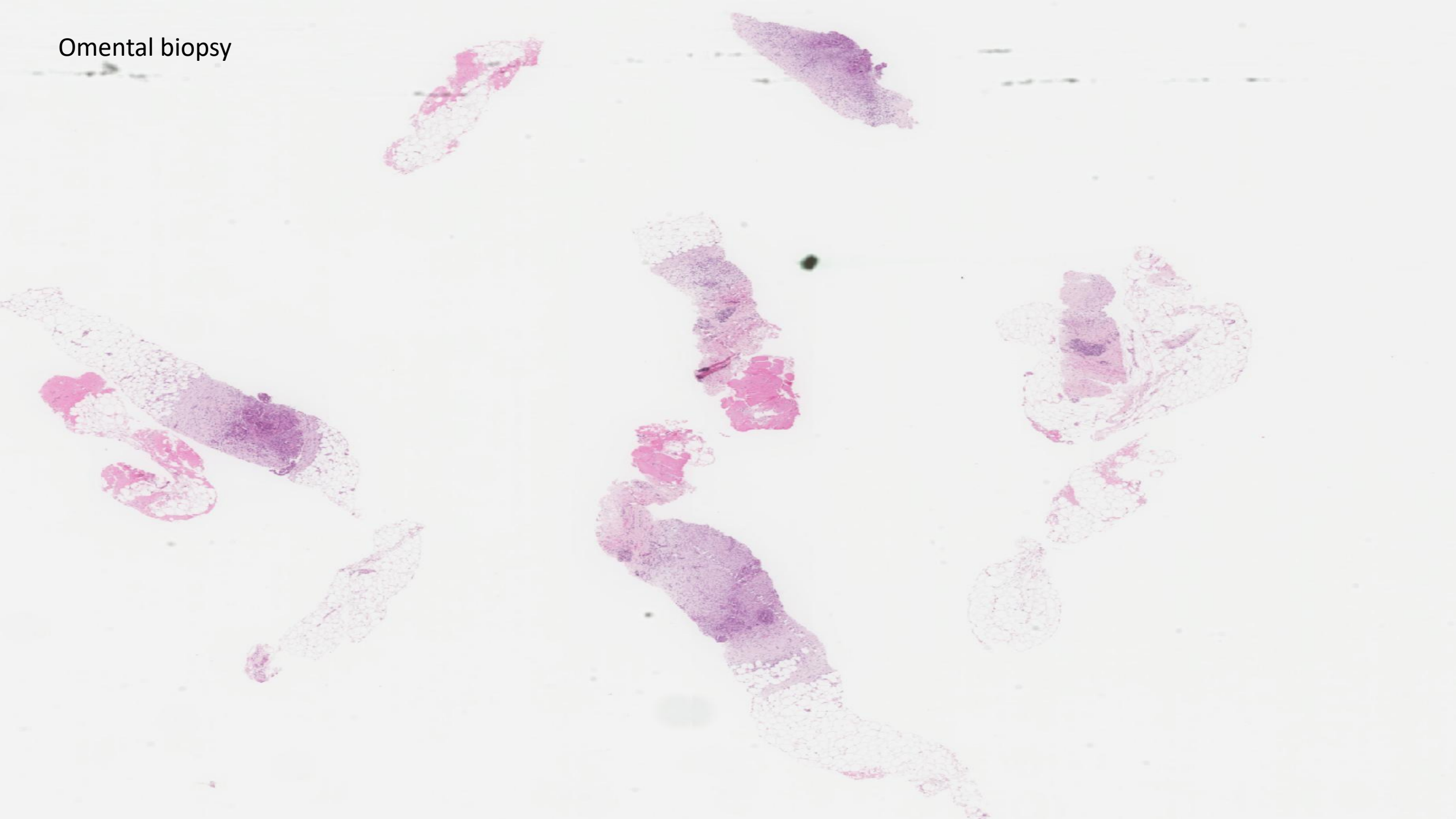

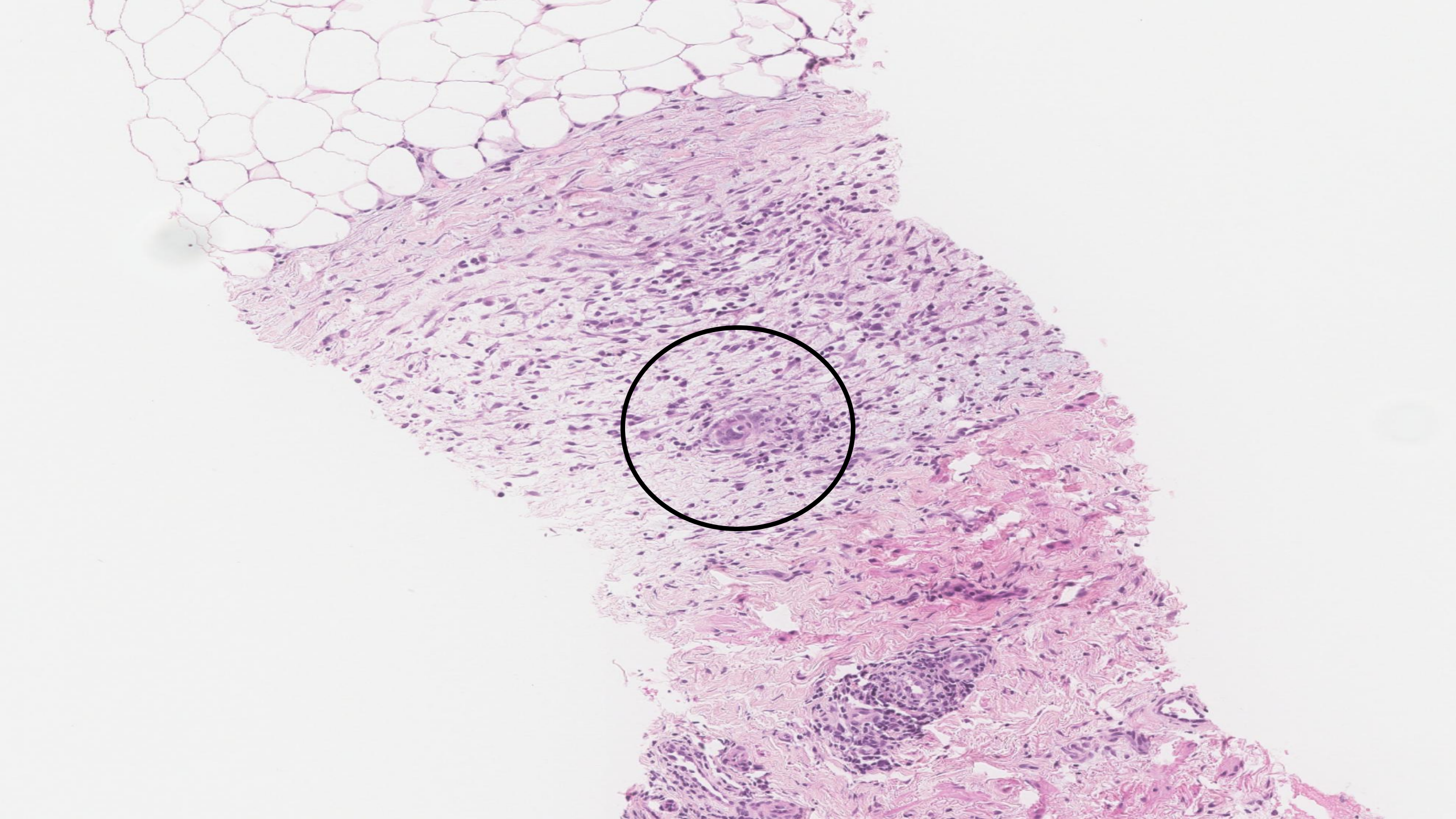

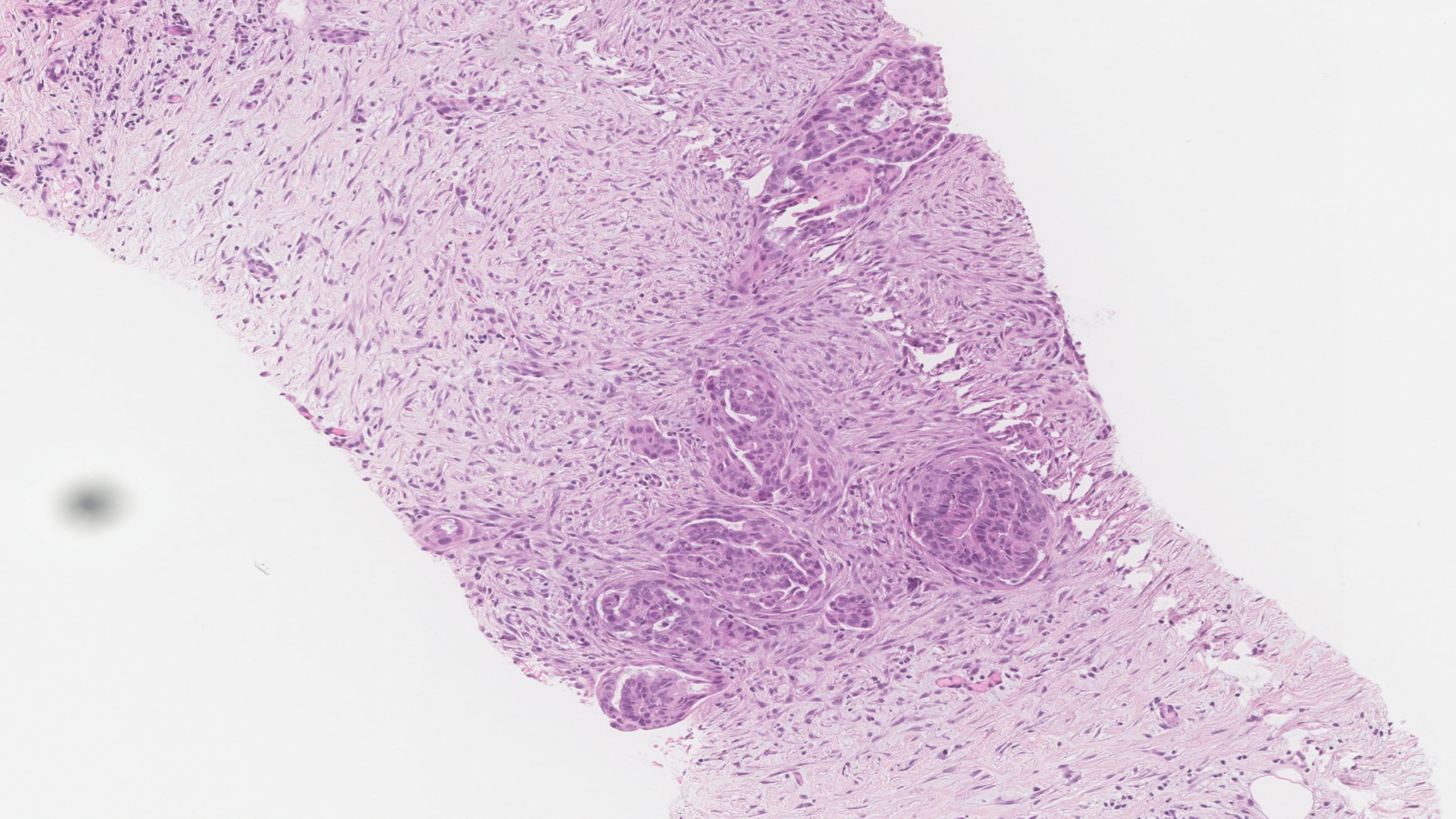

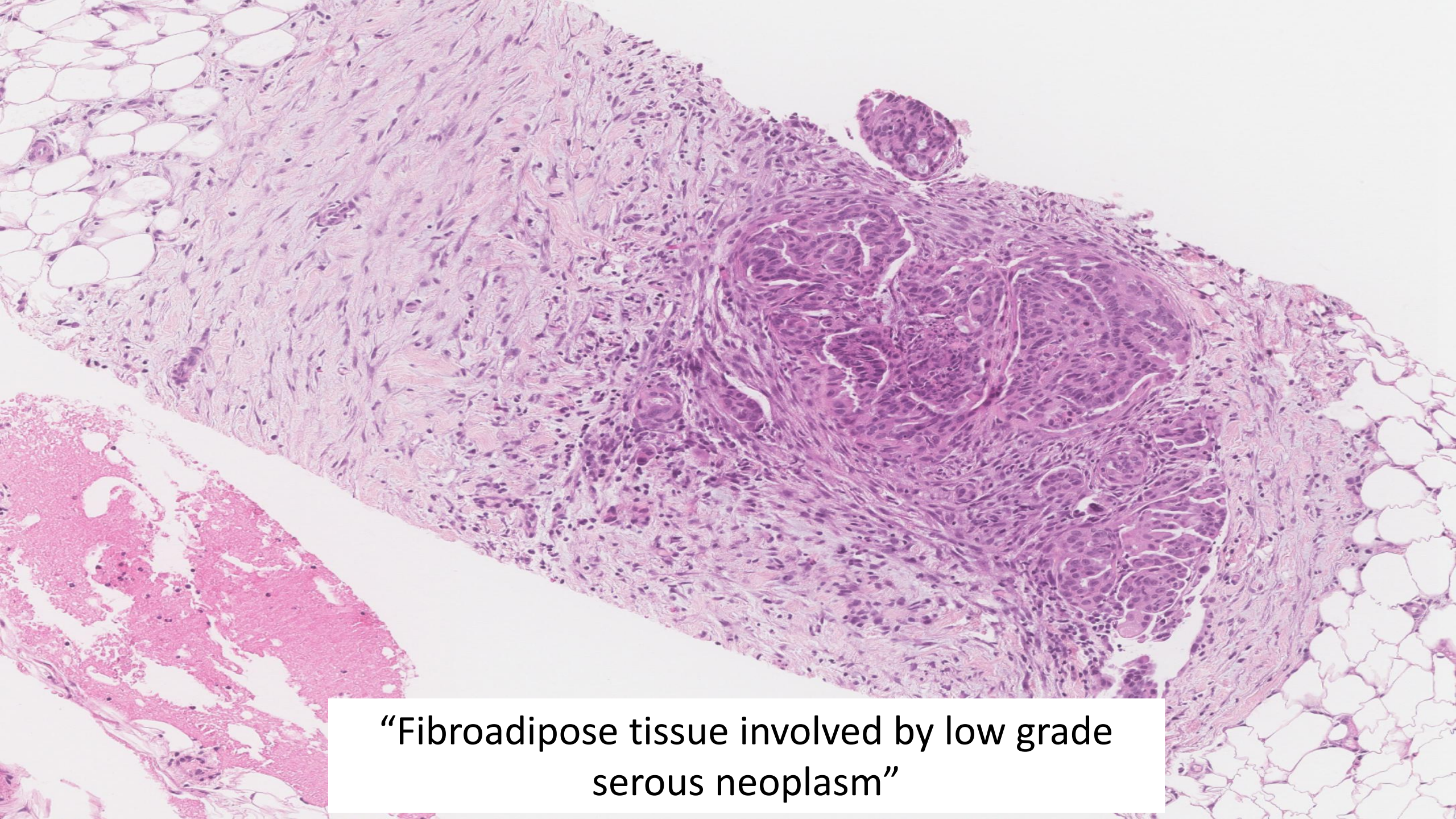

"Fibroadipose tissue involved by low grade serous neoplasm"

Review of selected everyday dilemmas – Serous borderline tumours

- Dealing with:
  - **Threshold for serous cystadenoma/adenofibroma vs. serous borderline tumour** – use common sense, 10% cut off; if on “borderline of borderline”, submit more sections
  - **micropapillary/cribriform architecture** – use strict qualitative and quantitative criteria
  - **microinvasion vs. microinvasive carcinoma** – recognize morphological differences, submit more sections
  - **implants** – understand the morphological spectrum and significance
  - **lymph node involvement** – spectrum of low grade serous neoplasia including borderline tumour can be seen in lymph nodes (including nodes in the inguinal area, chest, neck etc.)
  - **low grade serous neoplasia in core biopsy material** – use “low grade serous neoplasm” as a diagnostic term, when/if required



Thank you!