ISGyP Sponsored Educational Program

- **Classification of Vulva Squamous Cell Carcinoma**

- **C. Blake Gilks**

- **University of British Columbia, Vancouver Canada**

ISGyP Sponsored Educational Program

- **This narrated lecture was recorded on: September 1, 2020**
- **I have no financial conflicts of interest to disclose**





Vulval squamous cell carcinoma

- Two pathways: HPV-associated and HPV-independent



Vulvar squamous cell carcinoma

10.1.2: Squamous cell tumours and precursors

10.1.2.1: Squamous intraepithelial lesions, HPV-associated

10.1.2.2: Vulvar intraepithelial neoplasia, HPV-independent

10.1.2.3: Squamous cell carcinoma, HPV-associated

10.1.2.4: Squamous cell carcinoma, HPV-independent

10.1.2.6: Squamous cell carcinoma NOS



HPV-associated vulvar squamous cell carcinoma

HSIL (VIN3) a.k.a. usual high-grade VIN

Invasive squamous cell carcinoma (basaloid or warty type)



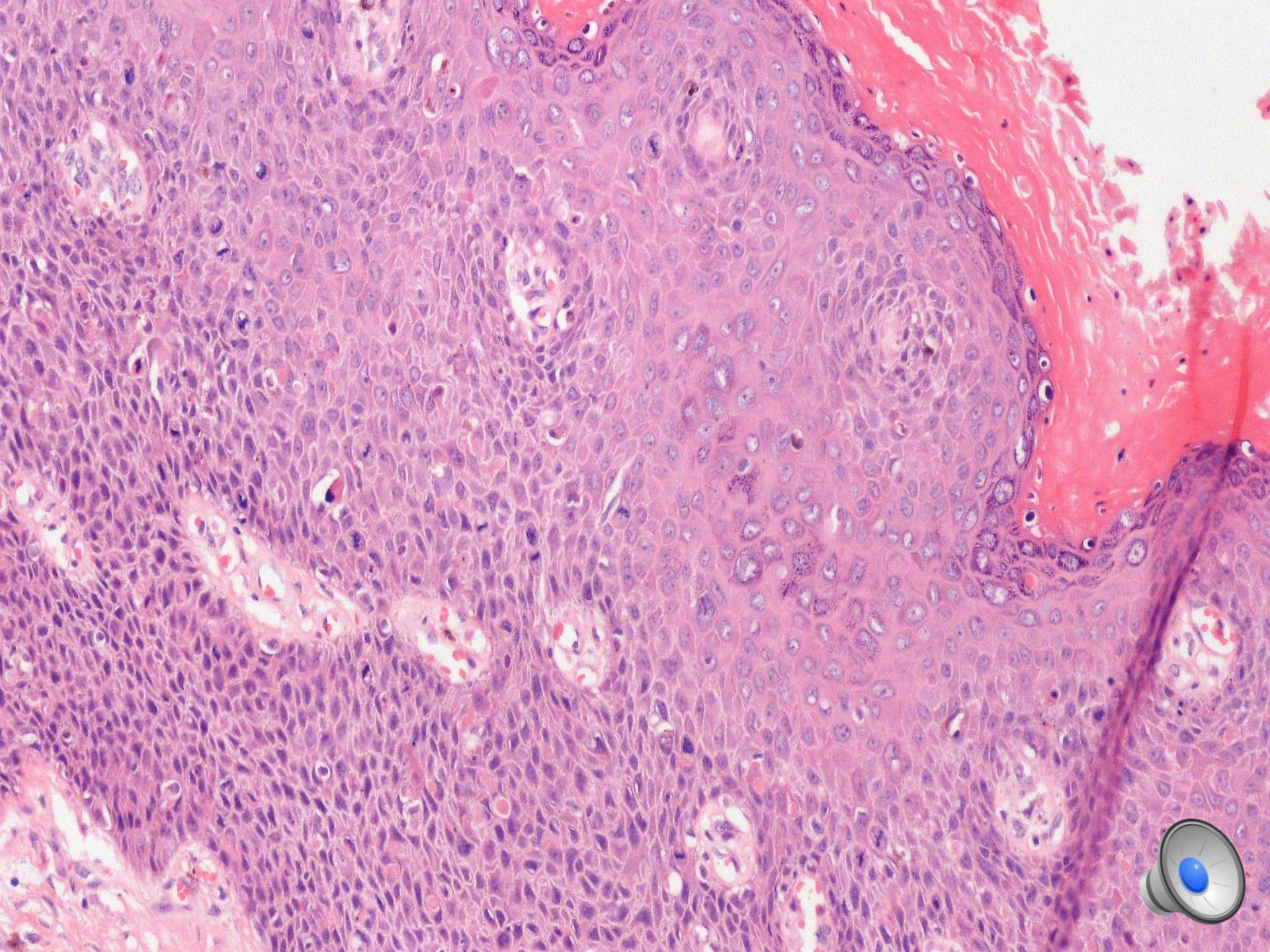

HPV-independent vulvar squamous cell carcinoma

dVIN (differentiated VIN), often in setting of lichen sclerosis

Invasive squamous cell carcinoma (well-differentiated keratinizing type)



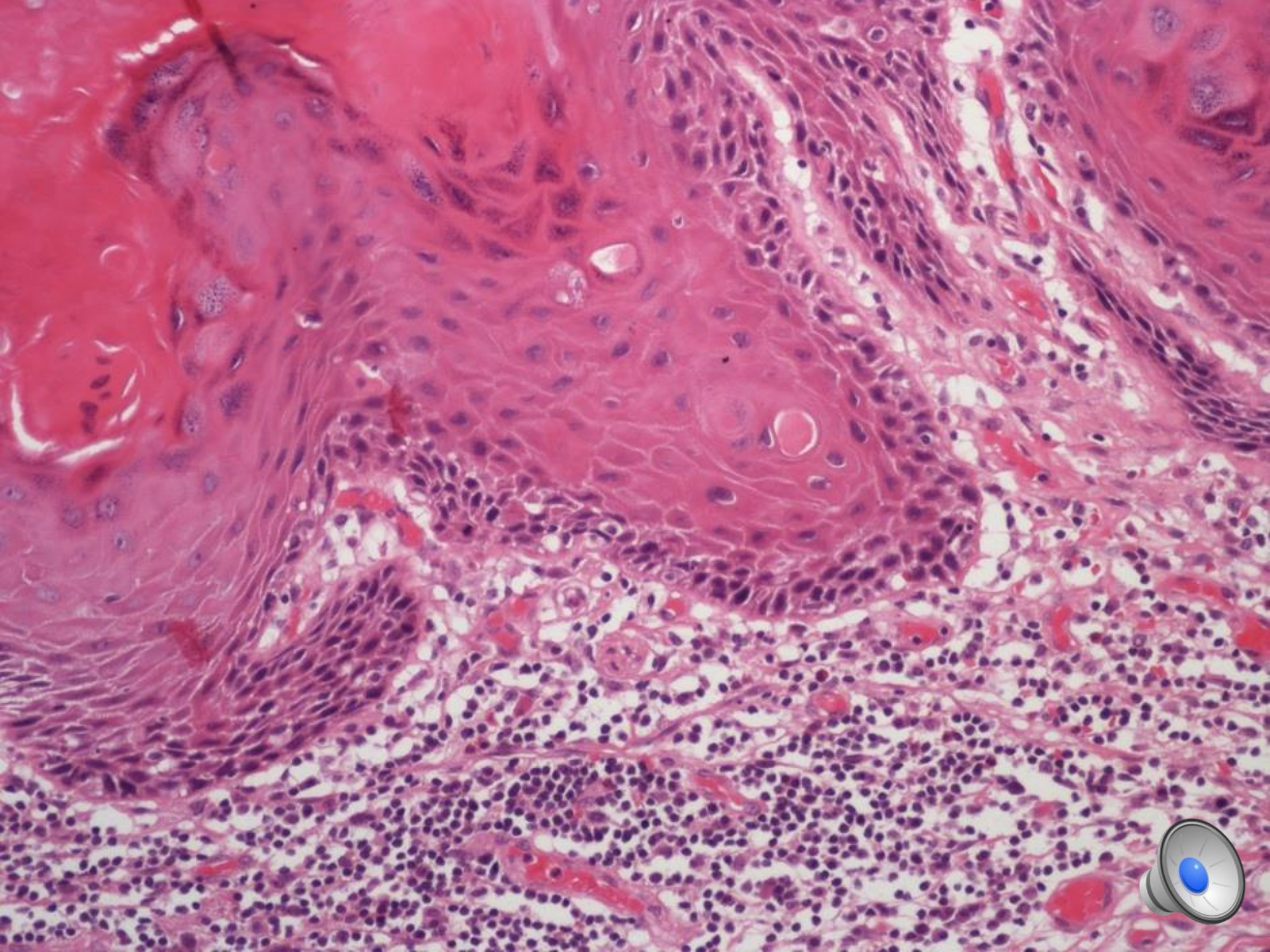

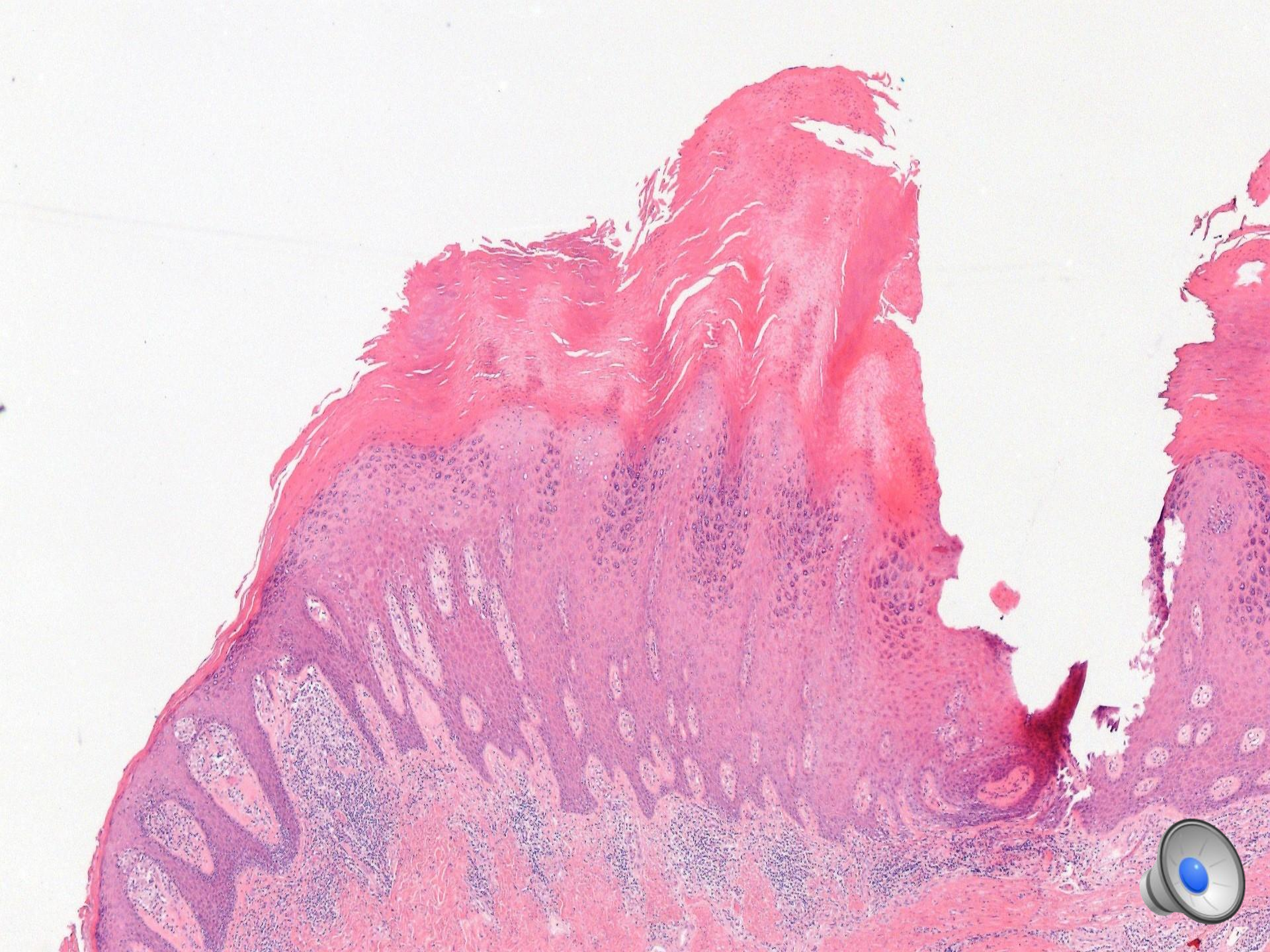

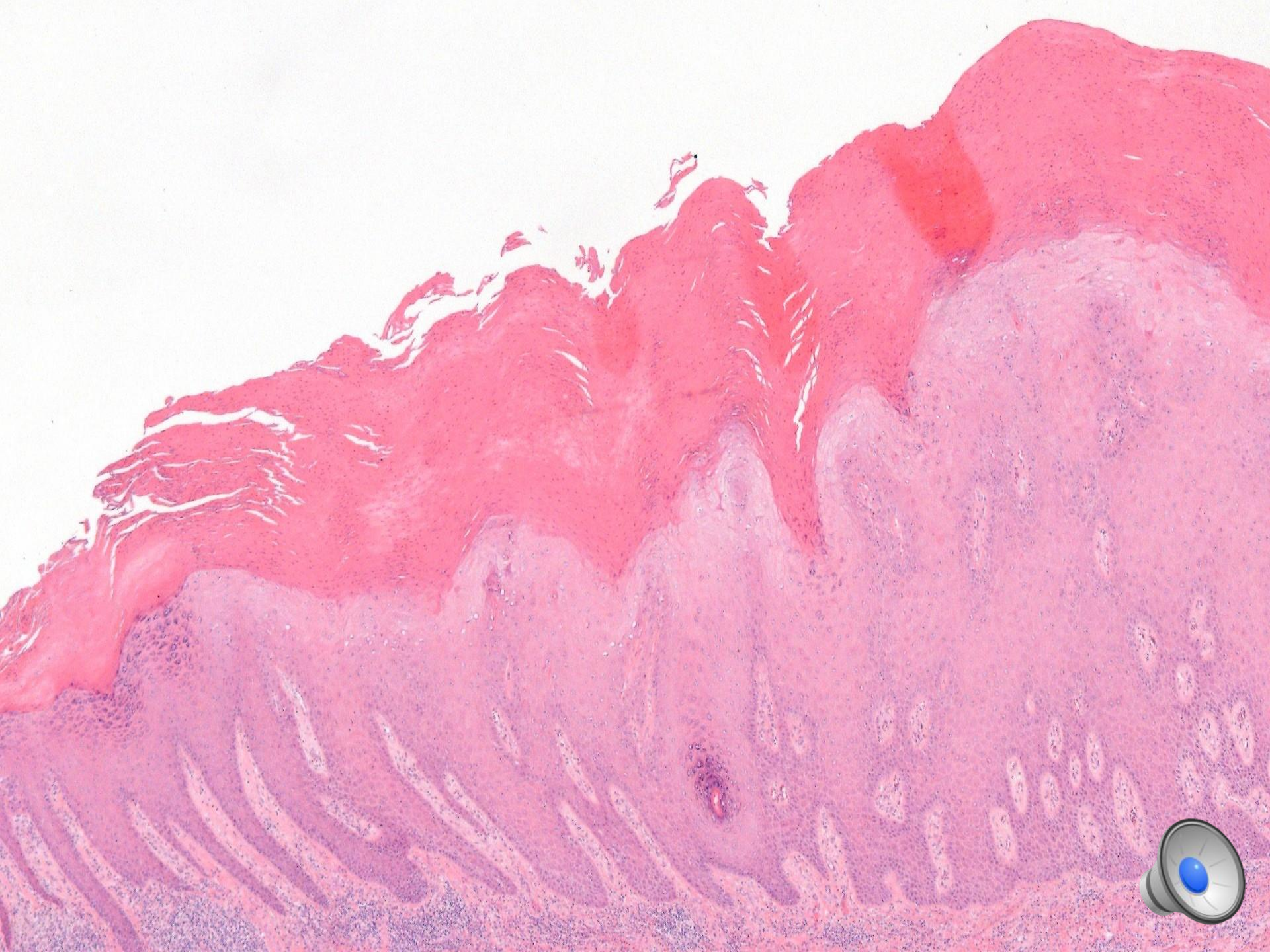



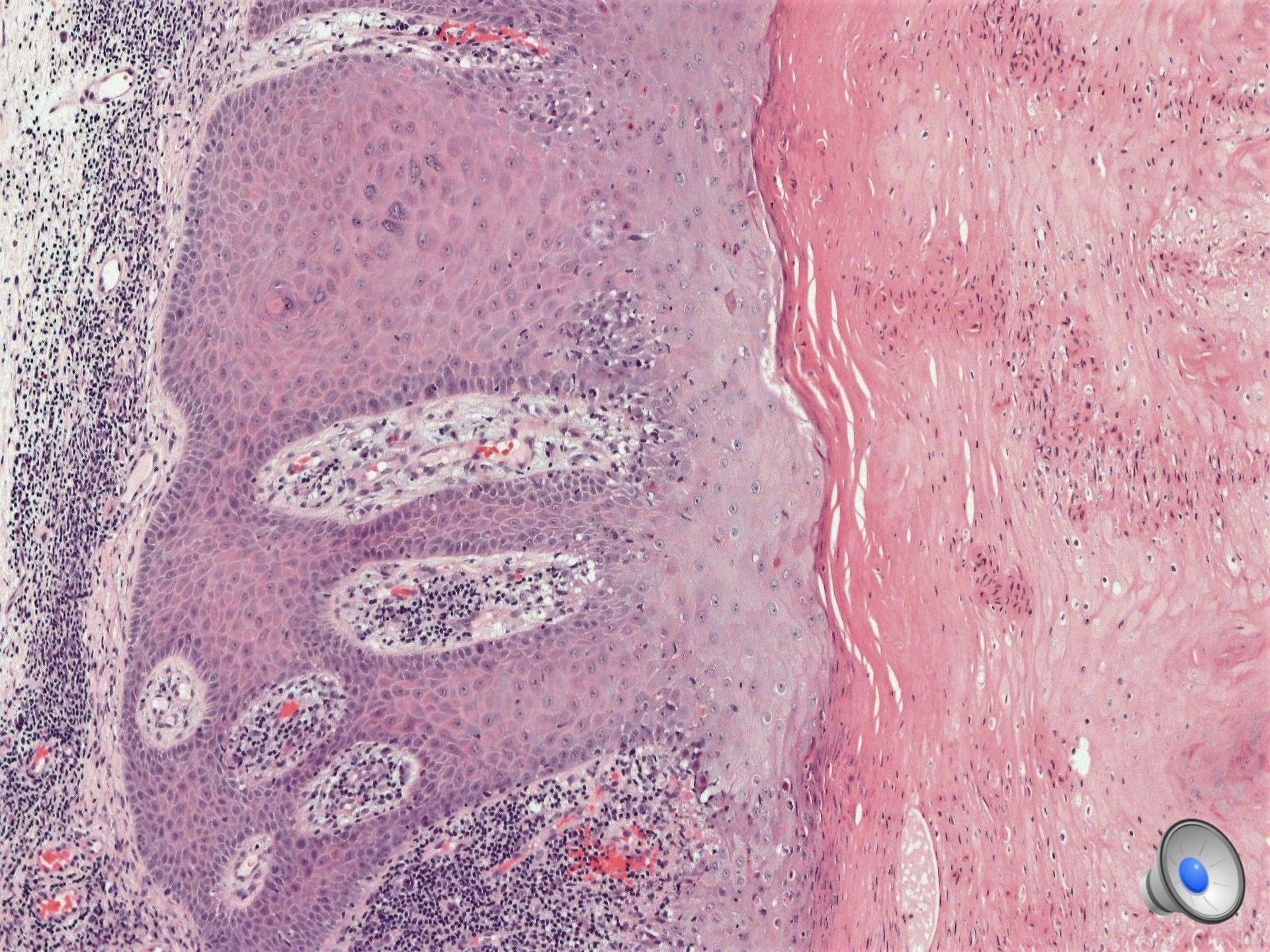

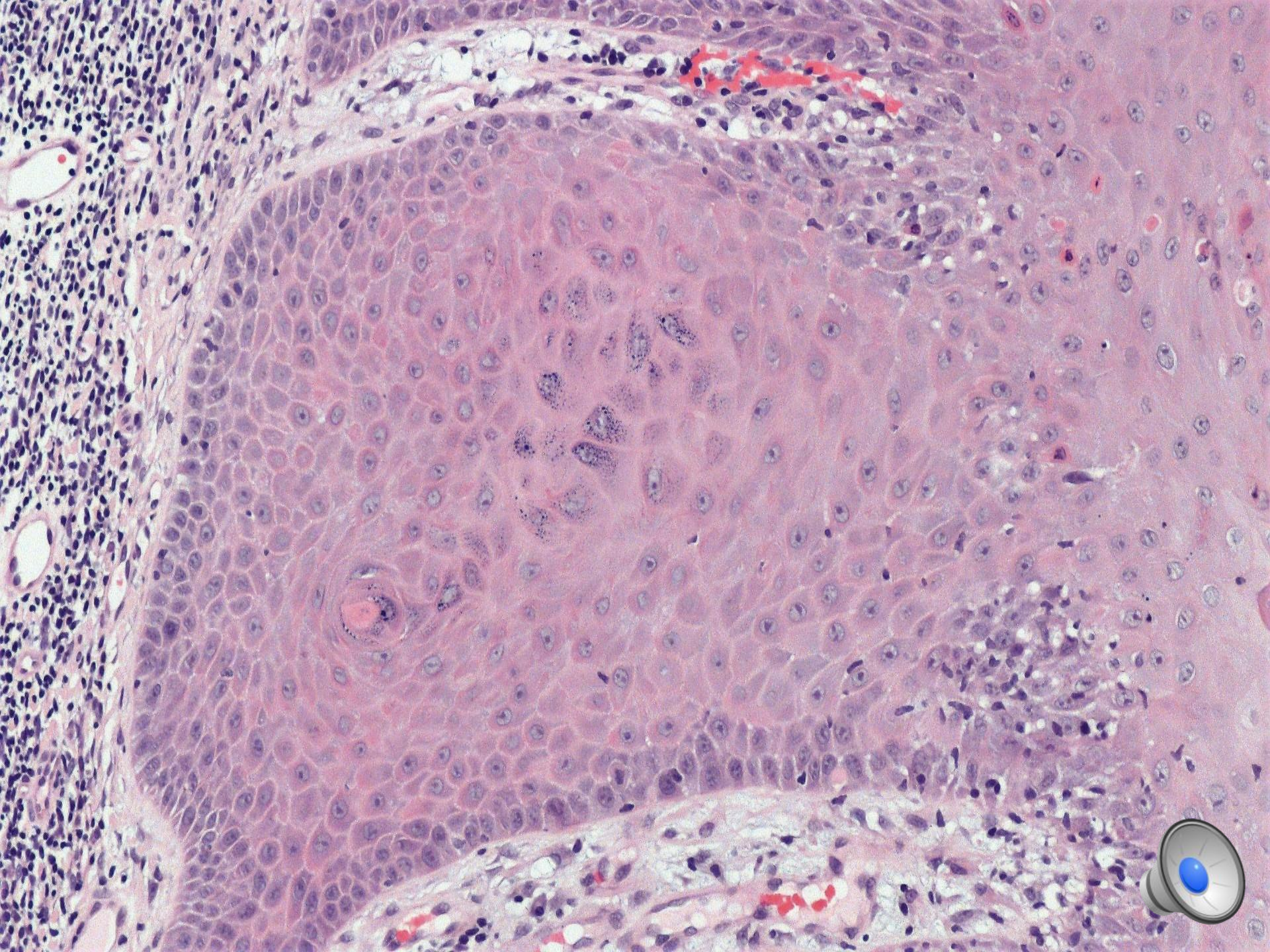

HPV-Independent VIN

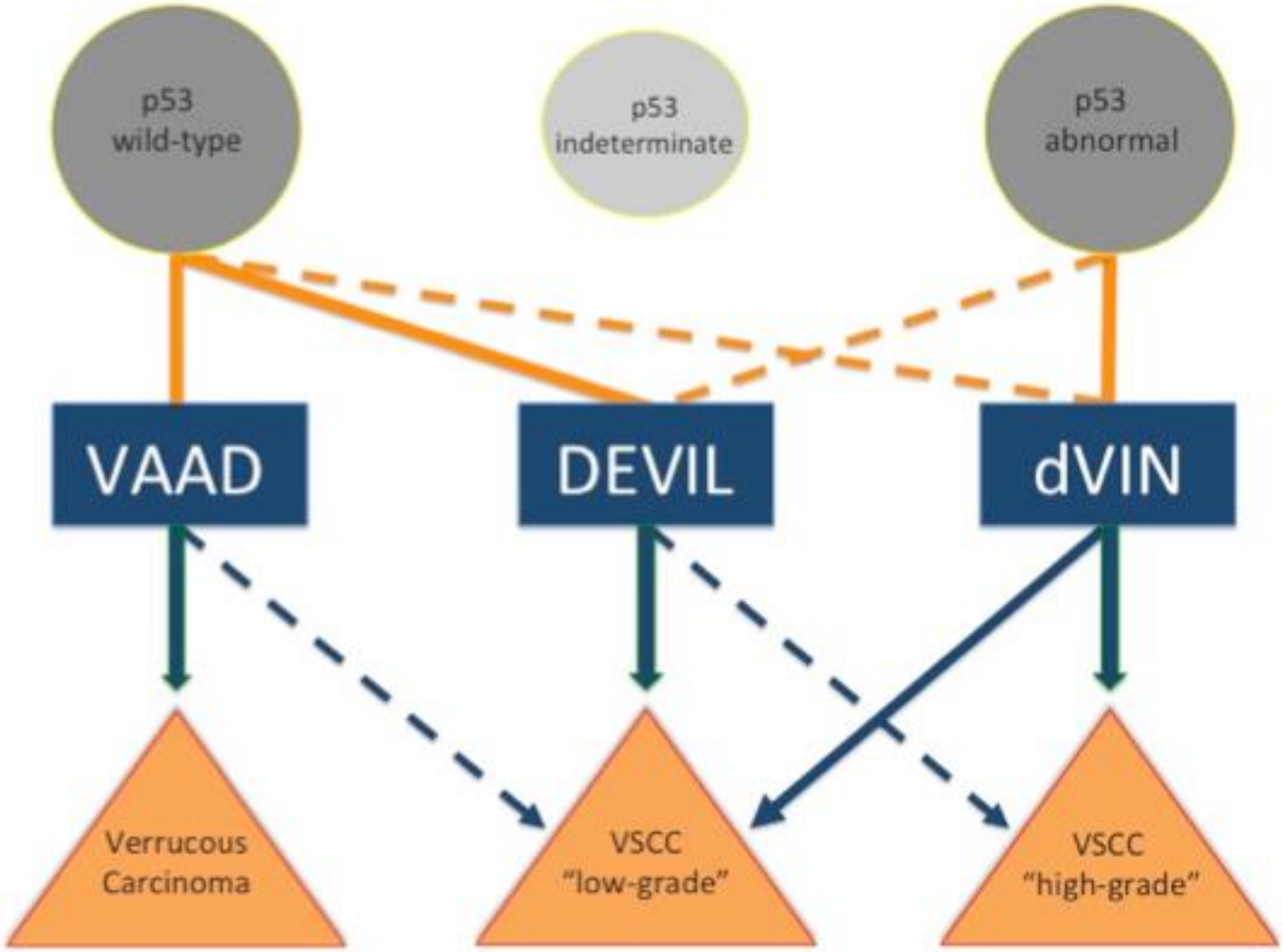

Outline of Presentation

- WHY classify VSCC as HPVA and HPVI
- HOW to classify VSCC as HPVA and HPVI
- WHAT to include in your surgical pathology reports



	HPV	Non-HPV
Age	Fourth to sixth decade	Sixth to ninth decade
Etiology	Oncogenic viral infection	Chronic inflammation (lichen sclerosis)
Precursor	HSIL (VIN3), usual type	dVIN
Biomarker expression	p16 overexpression	Abnormal p53 expression
Outcome	Favorable	Less favorable (more likely to have nod mets, recur local



October 2017, no biopsies taken

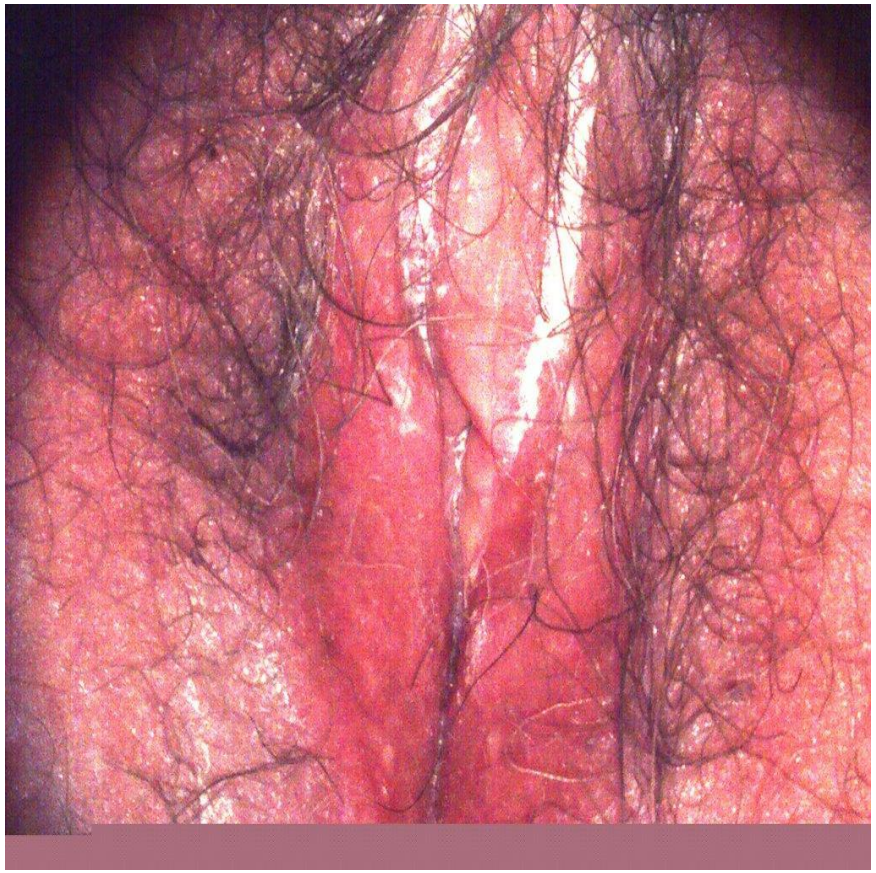

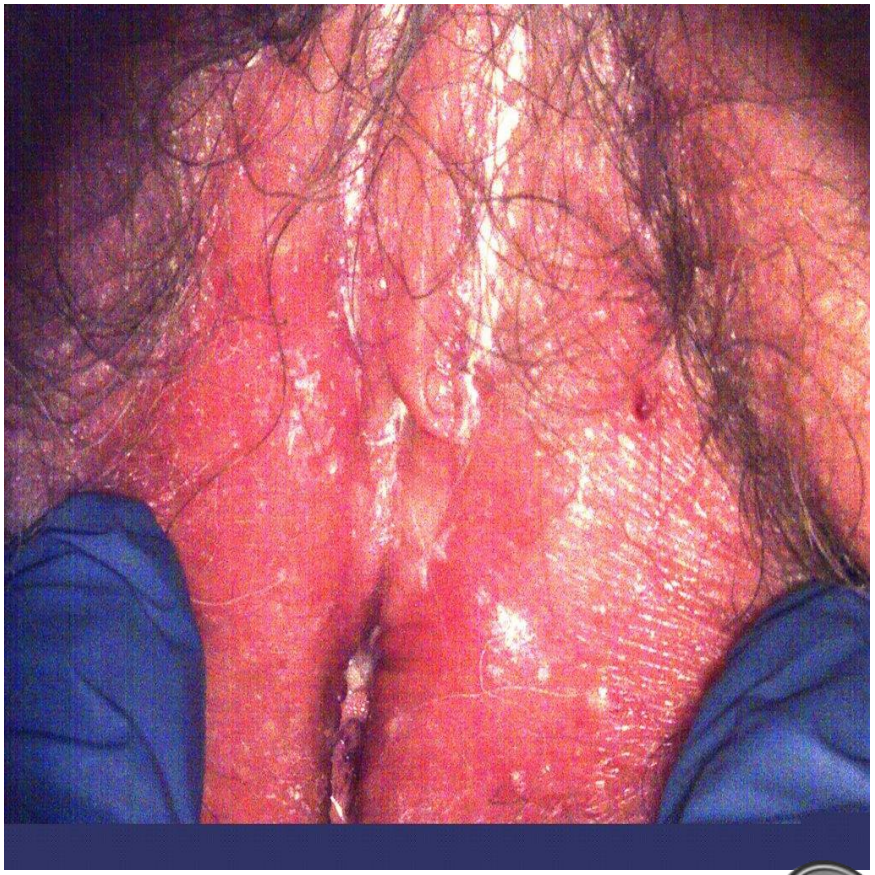

Jan 2018 (3 mo since last seen), VSCC

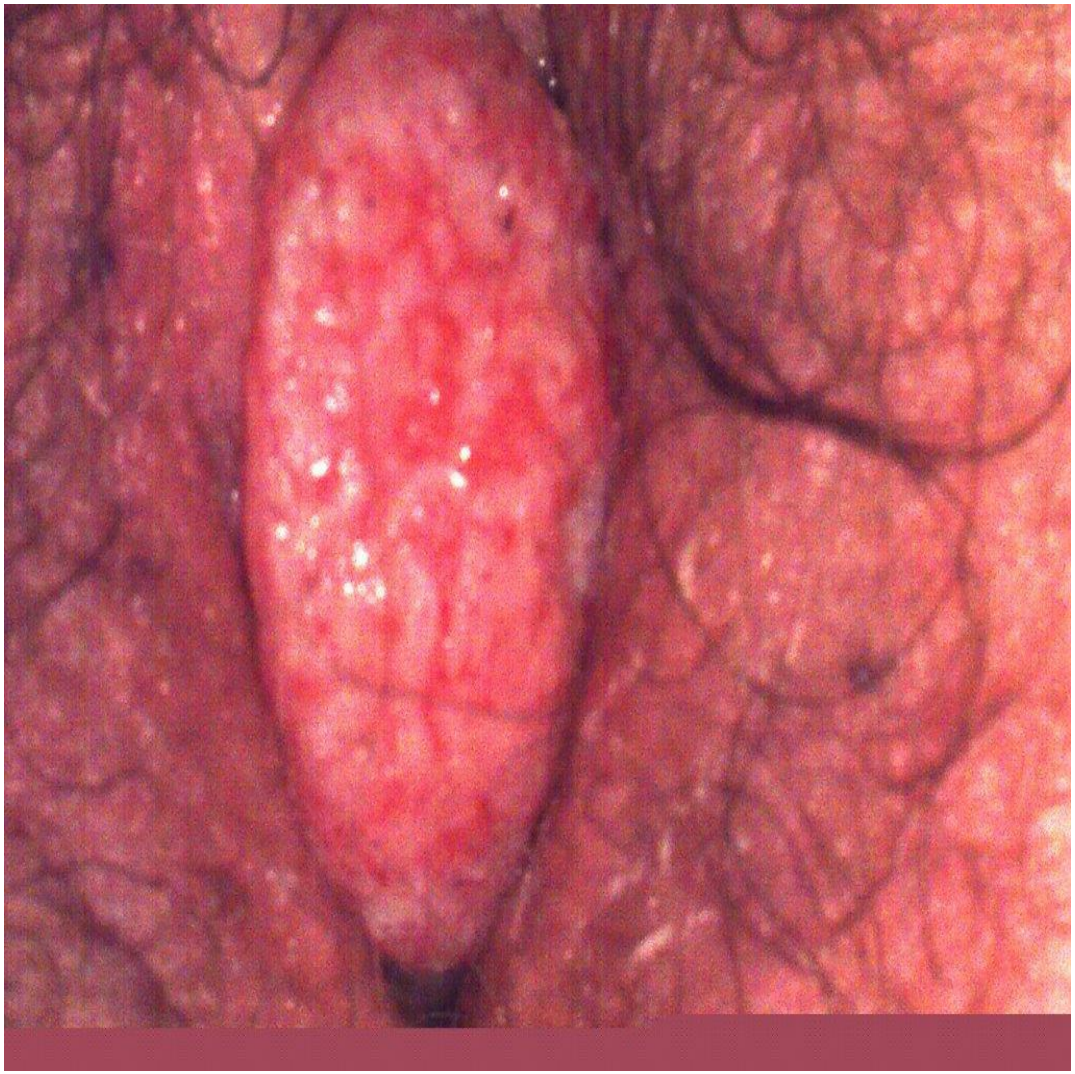

Diagnosis

- Well differentiated keratinizing SCC arising in a background of dVIN



Prognostic Significance of HPV Status

- **Prognostic: worse prognosis for HPV-negative tumours**
  - Ansink *Gynecol Oncol* 1994
  - Monk *Obstet Gynecol* 1995
  - van de Nieuwenhof *Cancer Epidemiol Biomarkers Prev* 2005
  - Lindell *Gynecol Oncol* 2010
  - Dong *AJSP* 2015
  - *Lee *Gynecol Oncol* 2016
  - Hay *J Low Genit Tract Dis* 2016
  - *Allo, Clarke, unpublished
  - McAlpine *Histopathol* 2017, in press
- **Not prognostic**
  - Pinto *Gynecol Oncol* 2004
  - Santos *AJSP* 2006
  - Alonso *Gynecol Oncol* 2011



Prognosis

Histopathology

Histopathology 2017, **71**, 238–246. DOI: 10.1111/his.13205

Human papillomavirus (HPV)-independent vulvar squamous cell carcinoma has a worse prognosis than HPV-associated disease: a retrospective cohort study

Jessica N McAlpine,[1] Samuel C Y Leung,[2] Angela Cheng,[3] Dianne Miller,[1] Aline Talhouk,[3] C Blake Gilks[4] & Anthony N Karnezis[3]

[1]*Division of Gynecologic Oncology, Department of Gynecology and Obstetrics, University of British Columbia,* [2]*Department of Pathology and Laboratory Medicine, Genetic Pathology Evaluation Centre, University of British Columbia,* [3]*Department of Pathology and Laboratory Medicine, University of British Columbia and BC Cancer Agency, and* [4]*Department of Pathology and Laboratory Medicine, University of British Columbia and Vancouver General Hospital, Vancouver, BC, Canada*

- Retrospective analysis of 217 VSCC patients
- p16 IHC used as surrogate for HPV infection
- Cases from 1985 – 1995 (more radical surgery) and 1995 – 2005 (less radical surgery)
- HPV status only associated with survival in later cohort
- Did more conservative surgery lead to worse outcomes?



Prognosis

Histopathology

Histopathology 2017, **71**, 238–246. DOI: 10.1111/his.13205

Human papillomavirus (HPV)-independent vulvar squamous cell carcinoma has a worse prognosis than HPV-associated disease: a retrospective cohort study

Jessica N McAlpine,[1] Samuel C Y Leung,[2] Angela Cheng,[3] Dianne Miller,[1] Aline Talhouk,[3] C Blake Gilks[4] & Anthony N Karnezis[3]

[1]*Division of Gynecologic Oncology, Department of Gynecology and Obstetrics, University of British Columbia,* [2]*Department of Pathology and Laboratory Medicine, Genetic Pathology Evaluation Centre, University of British Columbia,* [3]*Department of Pathology and Laboratory Medicine, University of British Columbia and BC Cancer Agency, and* [4]*Department of Pathology and Laboratory Medicine, University of British Columbia and Vancouver General Hospital, Vancouver, BC, Canada*

- Retrospective analysis of 217 VSCC patients
- p16 IHC used as surrogate for HPV infection
- Cases from 1985 – 1995 (more radical surgery) and 1995 – 2005 (less radical surgery)
- HPV status only associated with survival in later cohort
- Did more conservative surgery lead to worse outcomes?

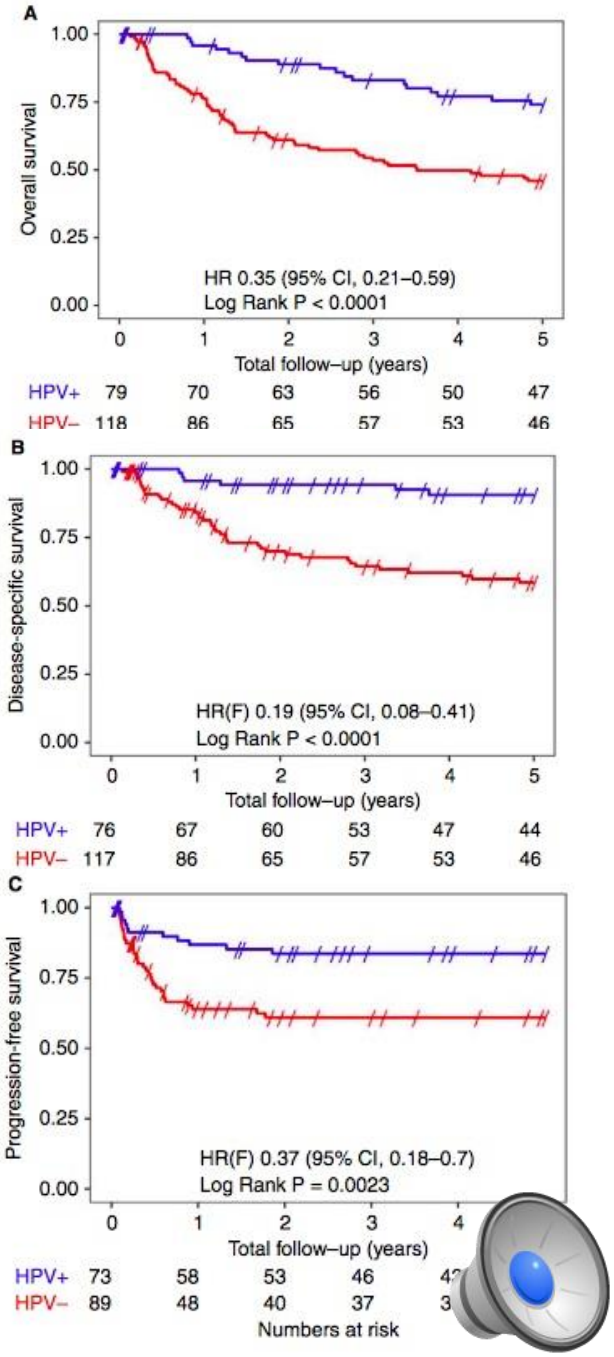

Survival by p16 Status and Surgical Era

Disease specific survival

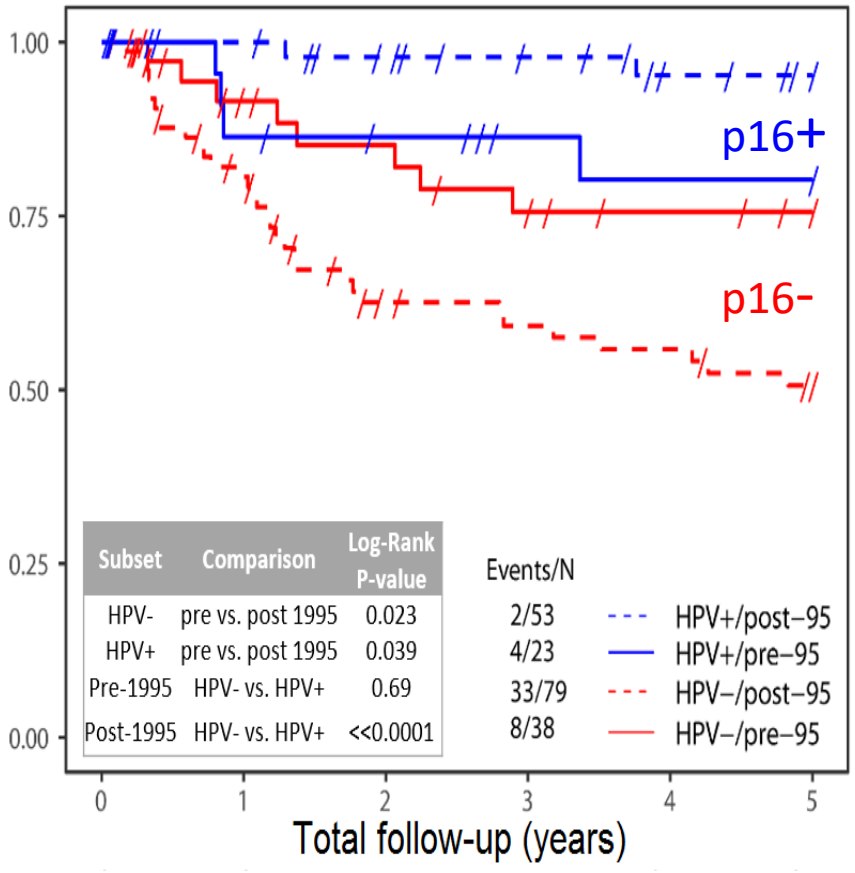

Current practice

Radical *en bloc*

Current practice



Other Morphological variants of HPV-independent VSCC



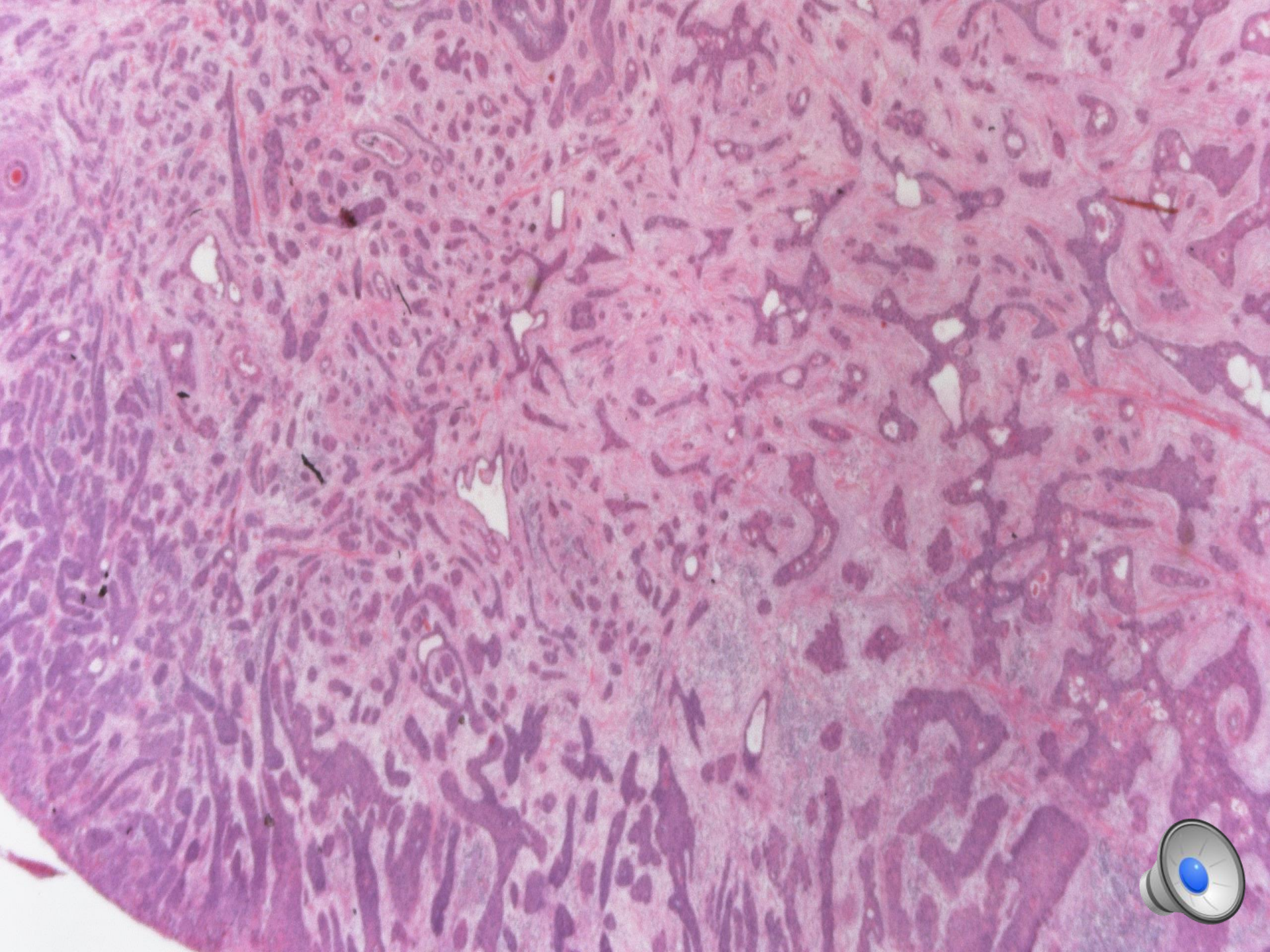

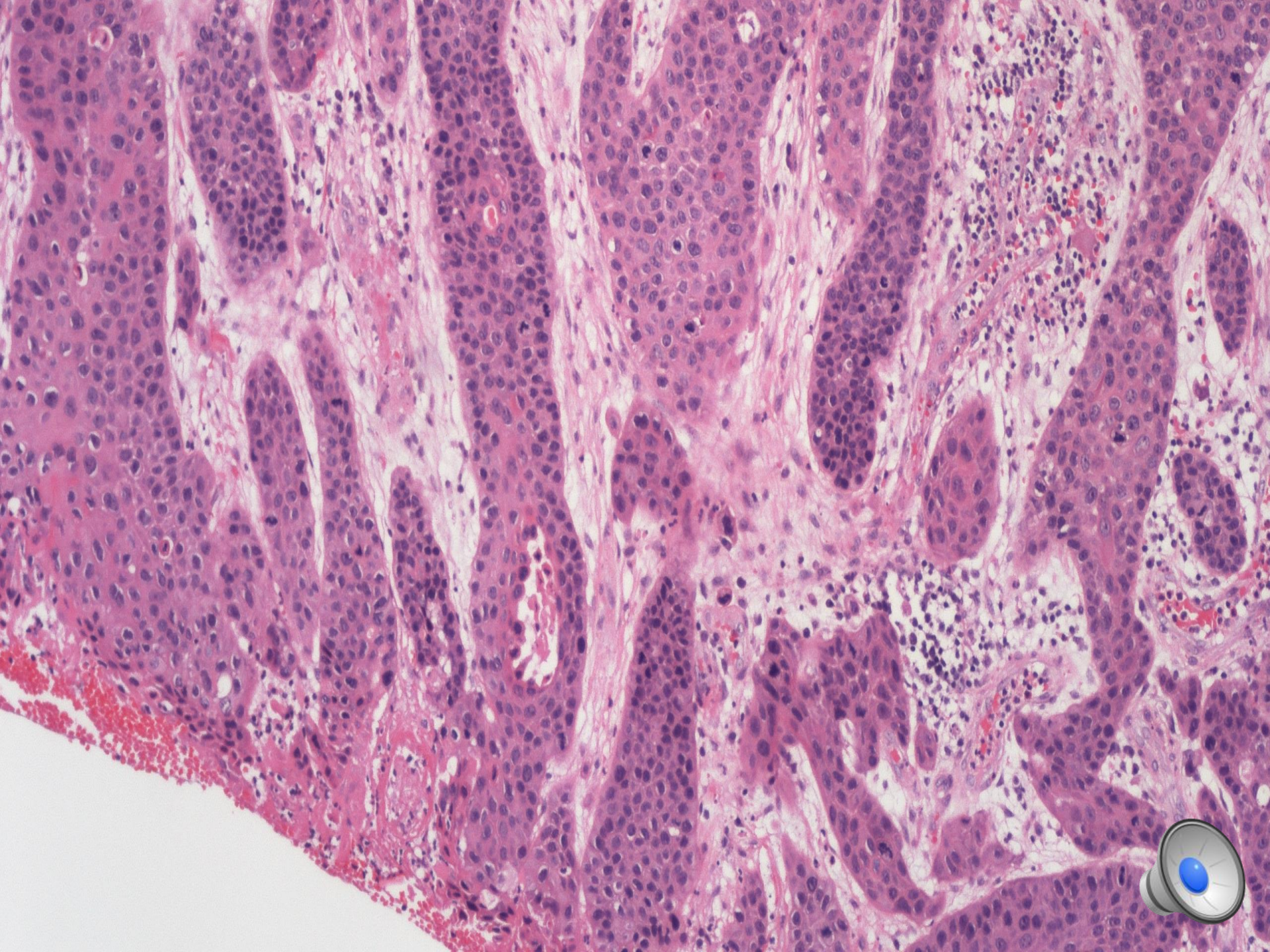

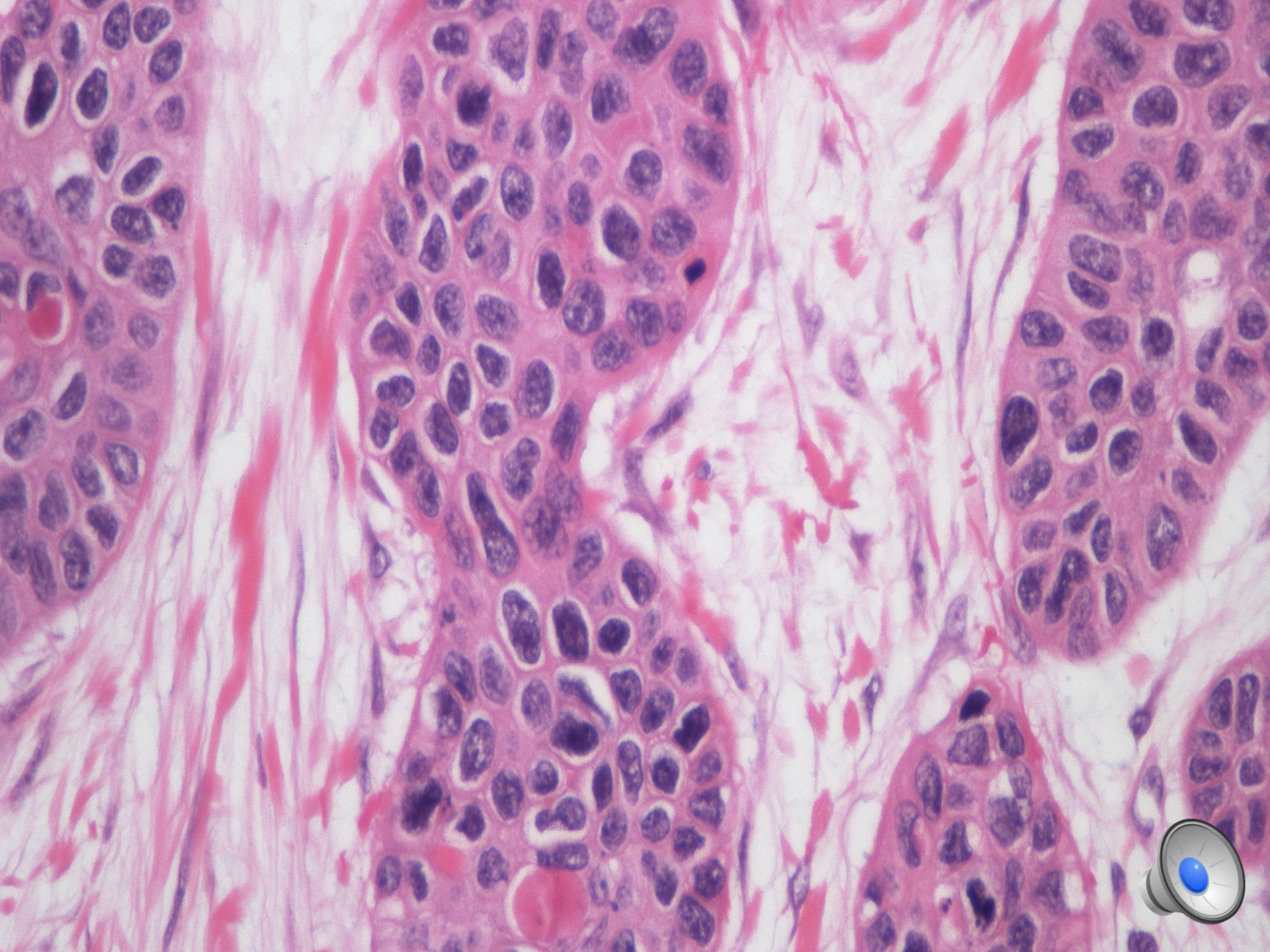

VSCC with fibromyxoid stroma

- Infiltrative rather than pushing margin
- Worse prognosis (not clear whether this is independent of HPV status)



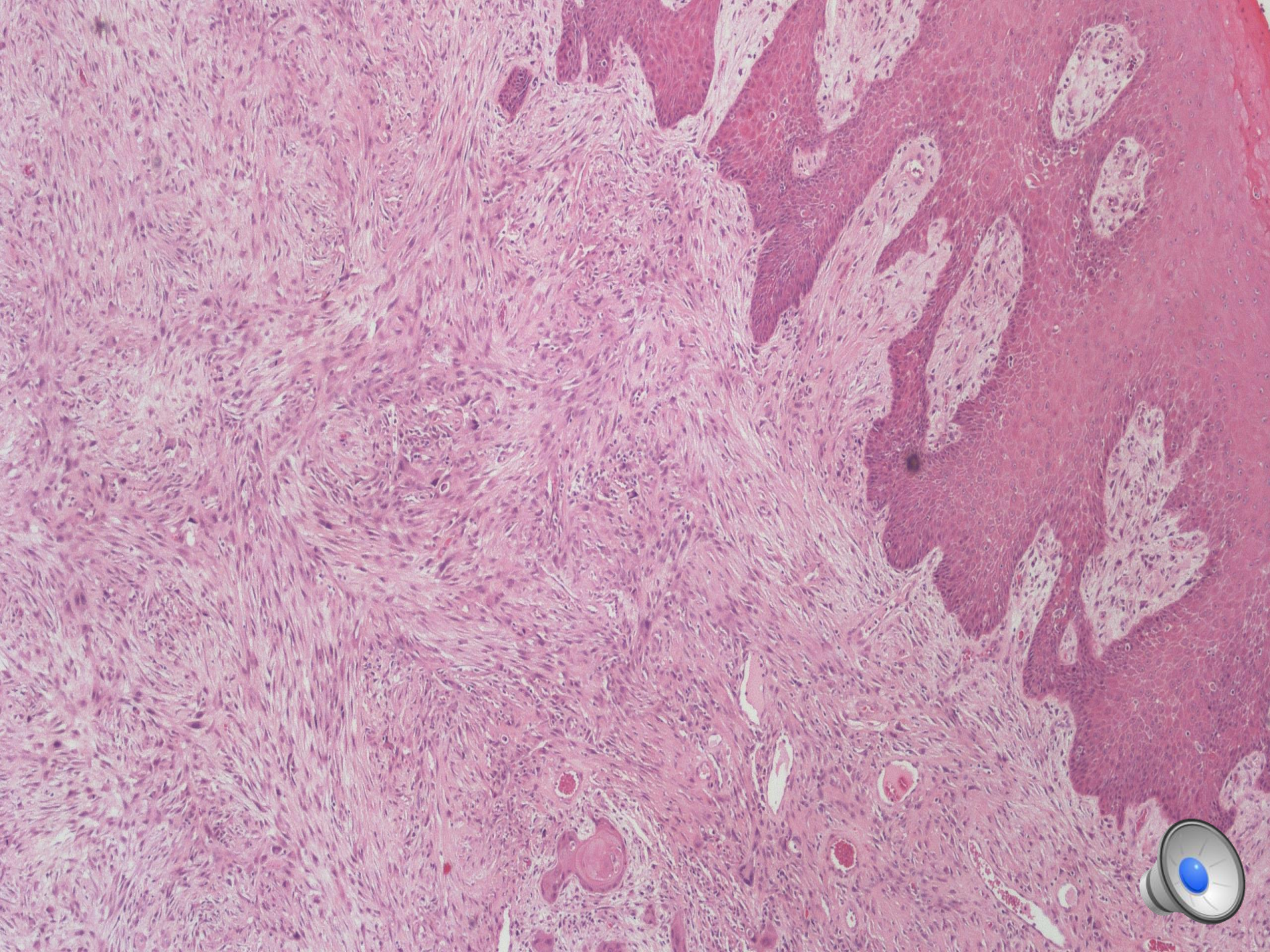

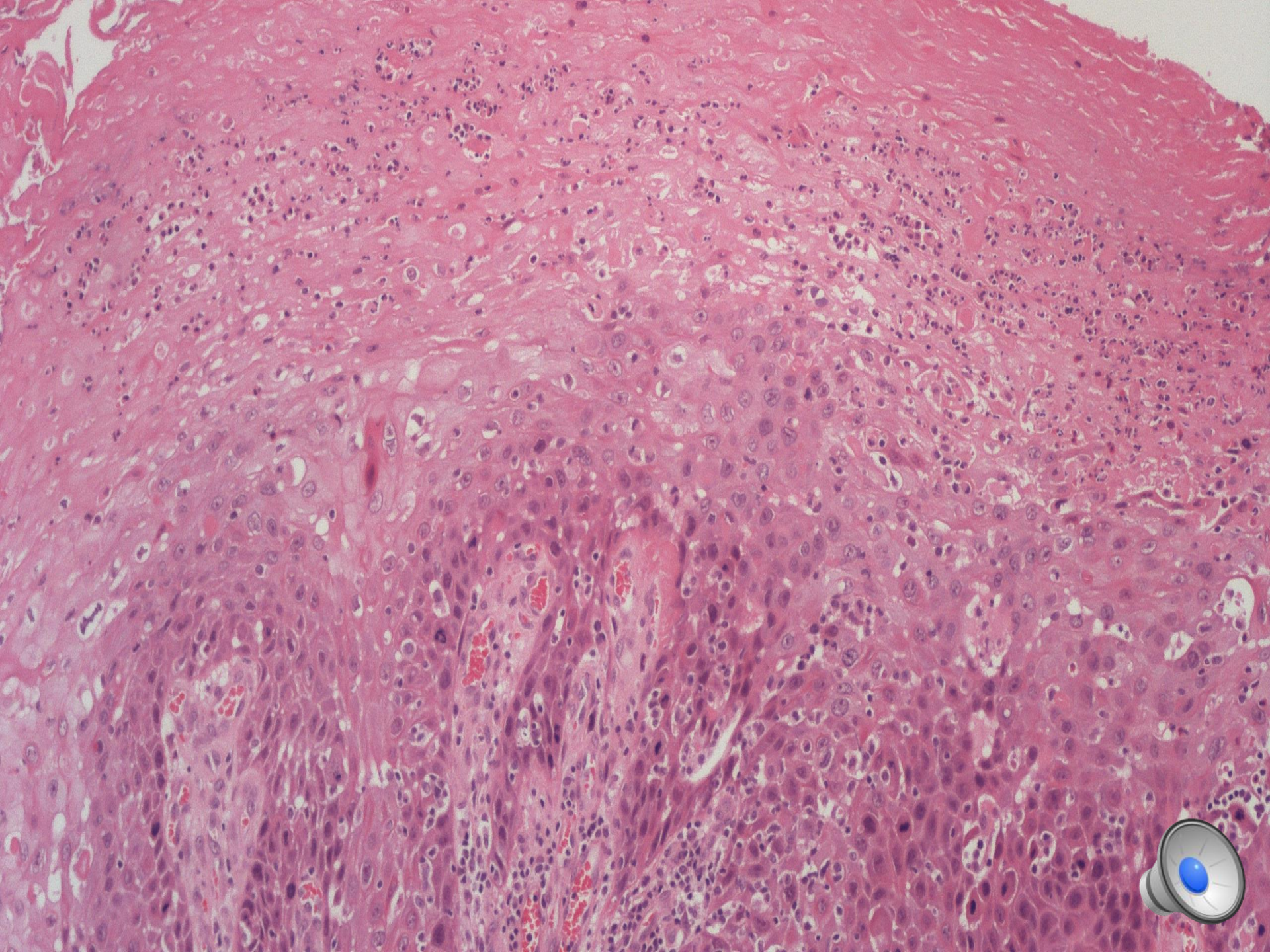

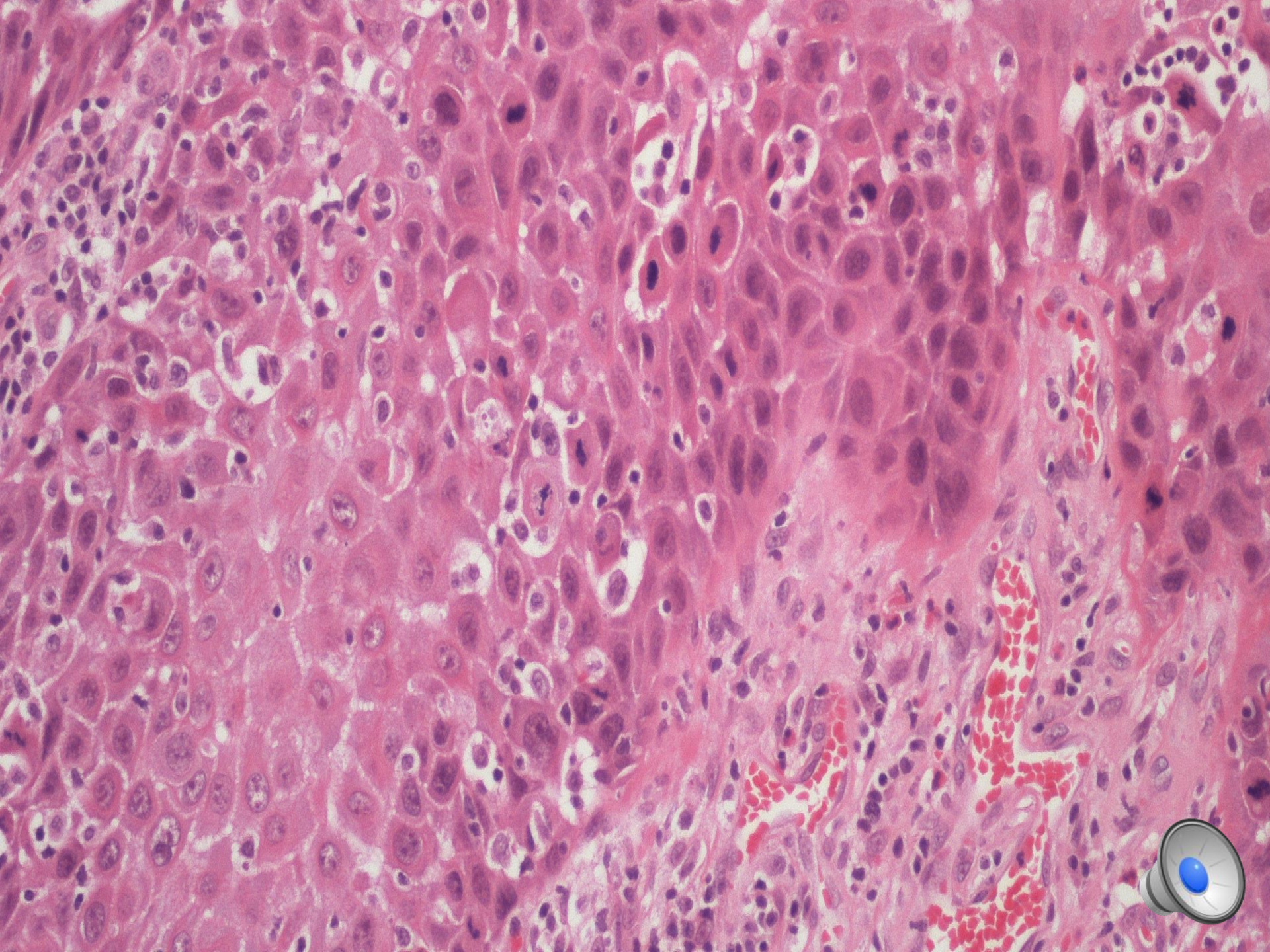

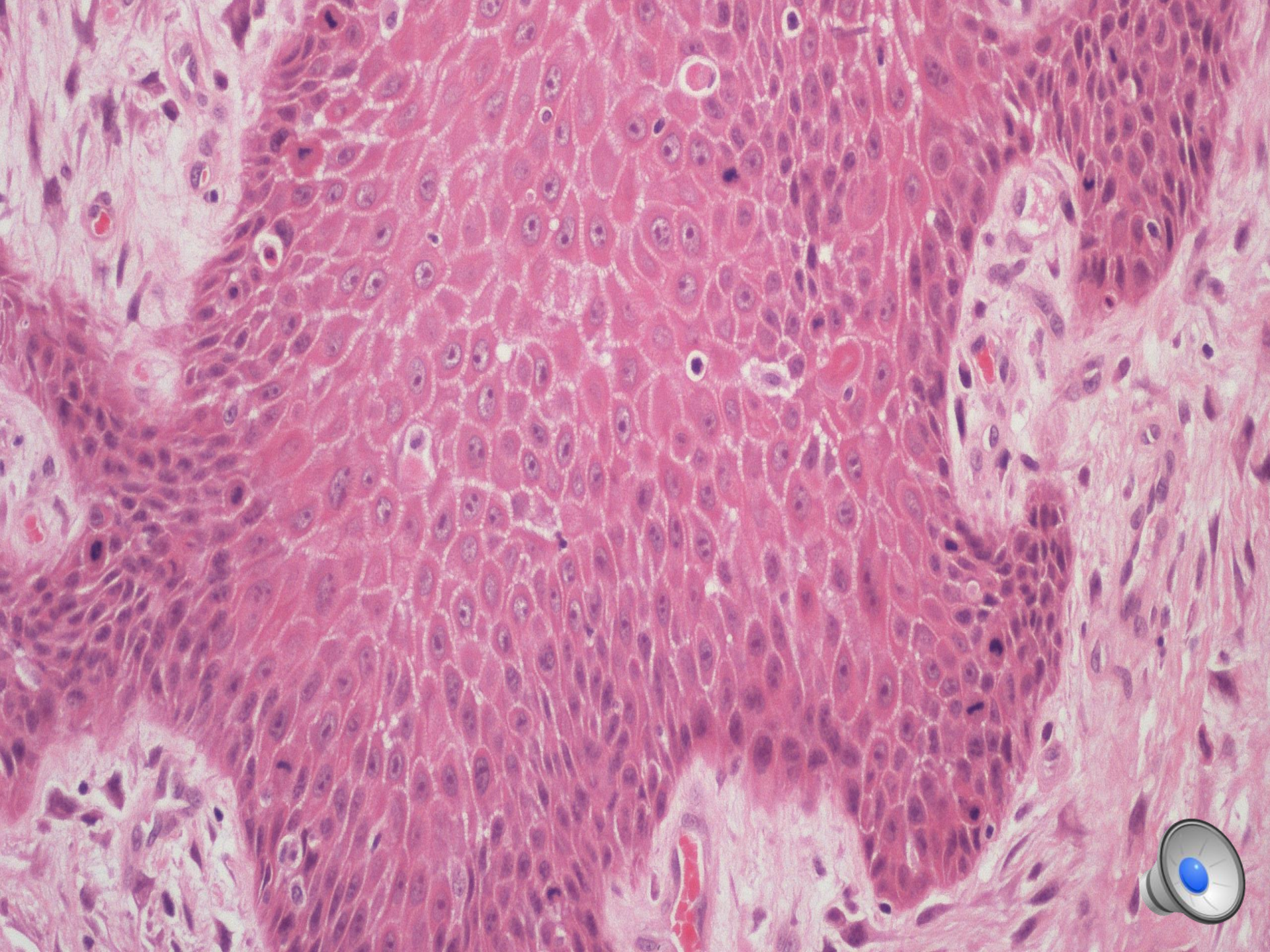

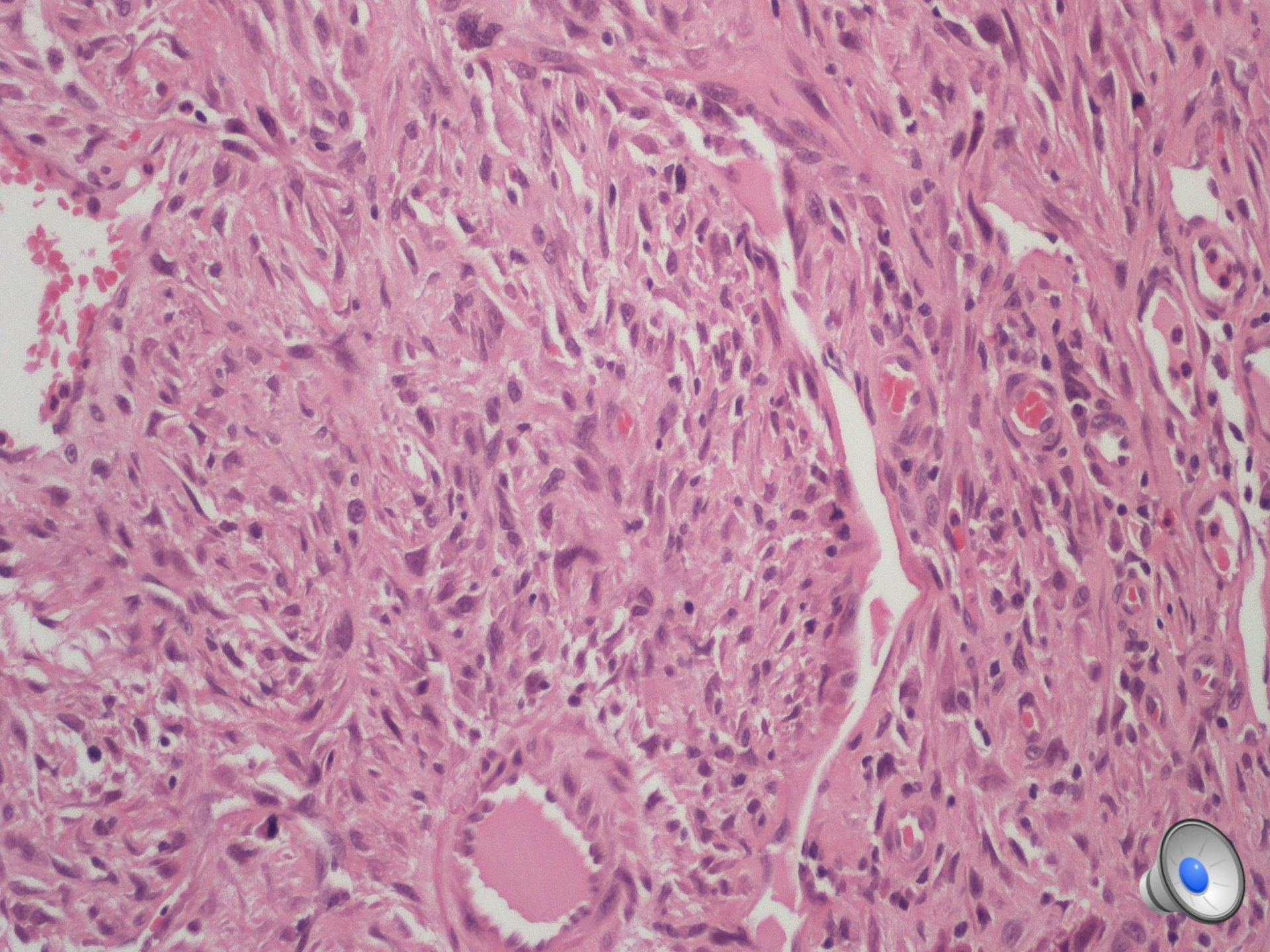

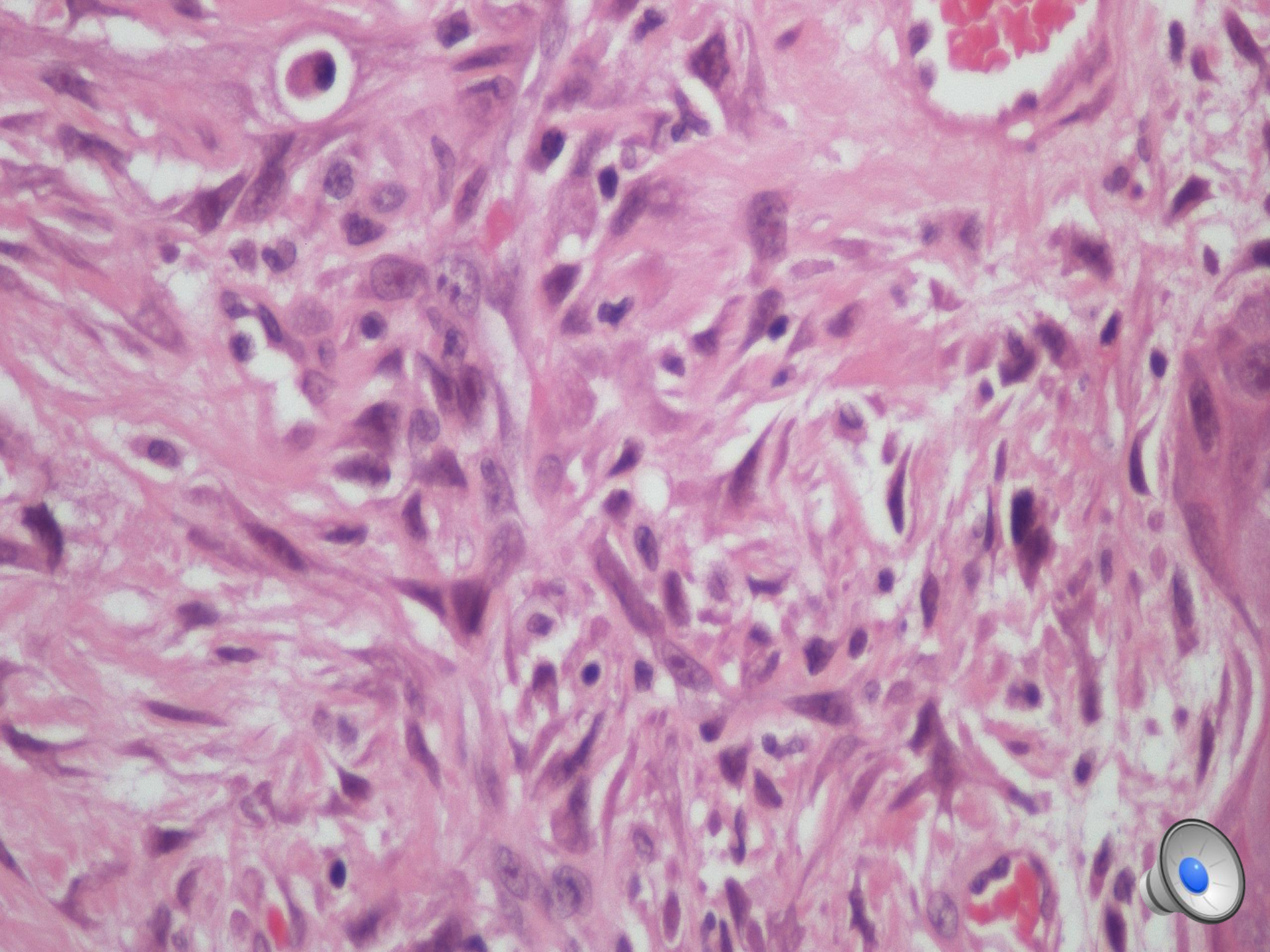

Sarcomatoid VSCC

- Worse prognosis (not clear whether this is independent of HPV status)



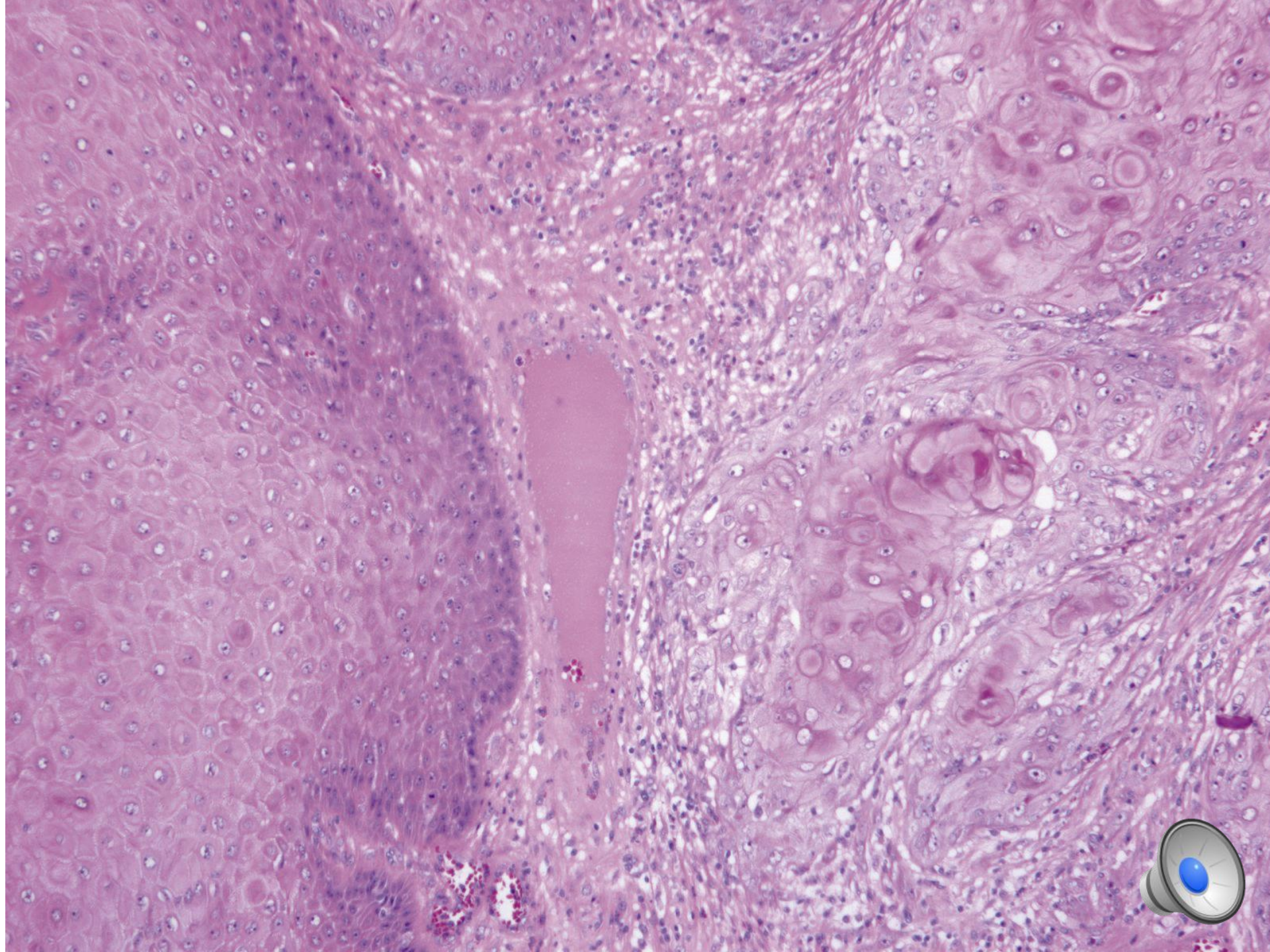

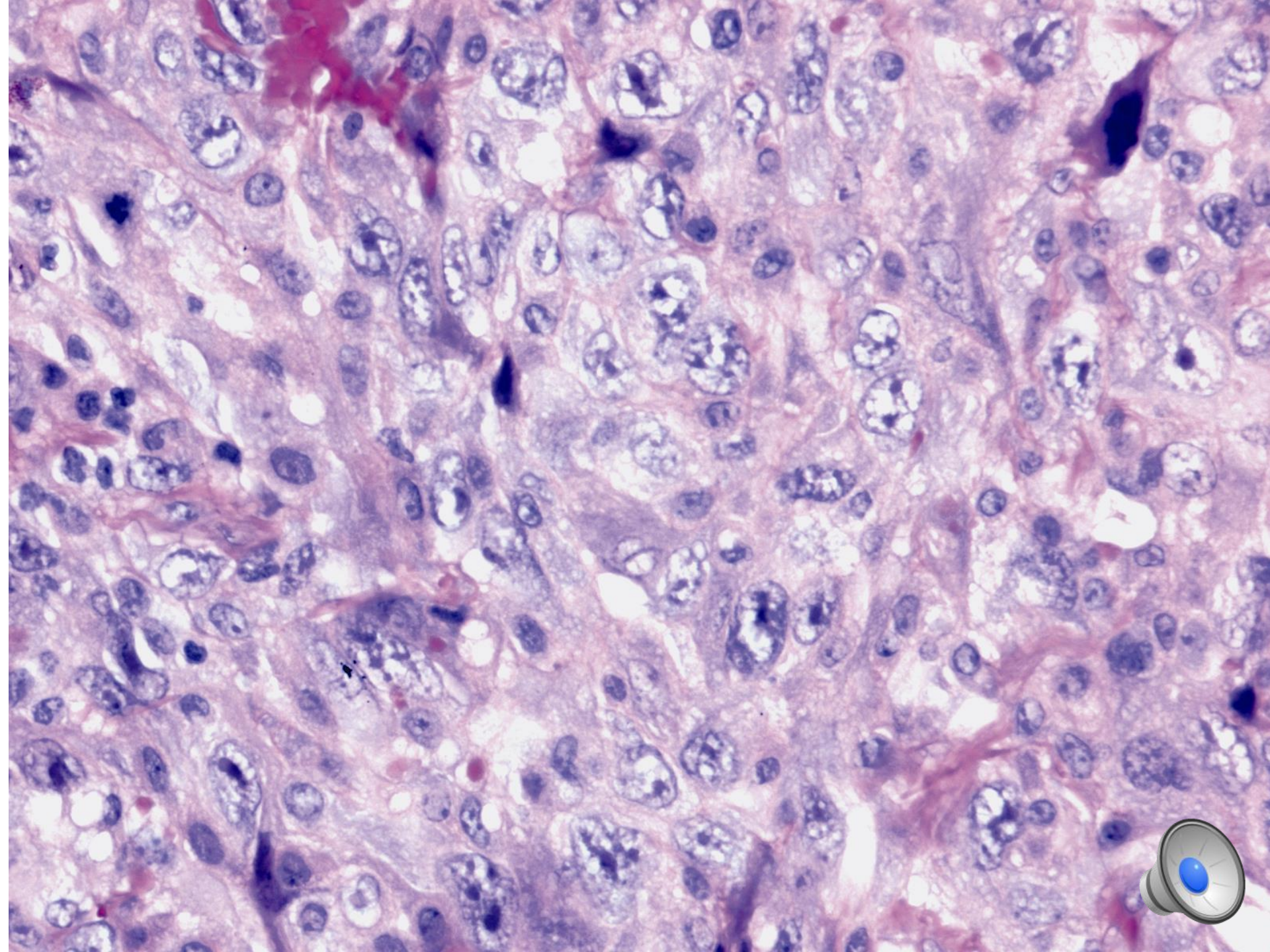

Outline

- WHY classify VSCC as HPVA and HPVI
- HOW to classify VSCC as HPVA and HPVI
- WHAT to include in your surgical pathology reports



Predict HPV

Predict non-HPV

H&E

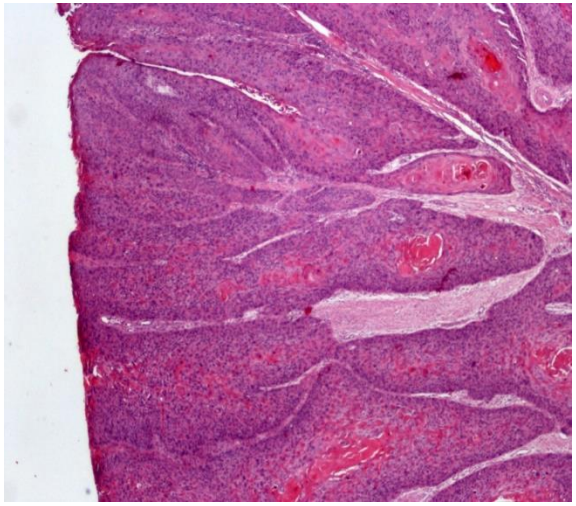

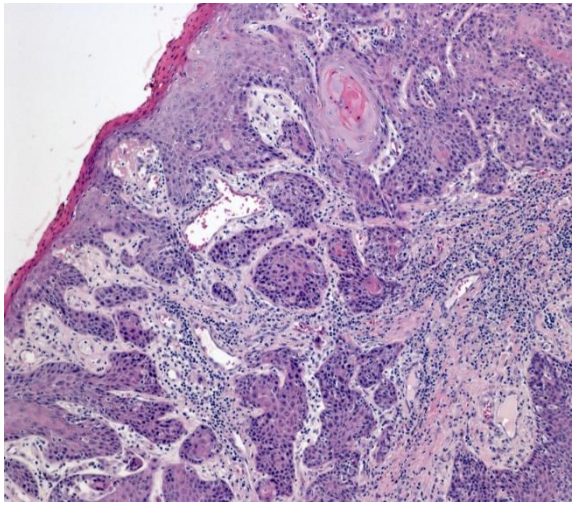

p16

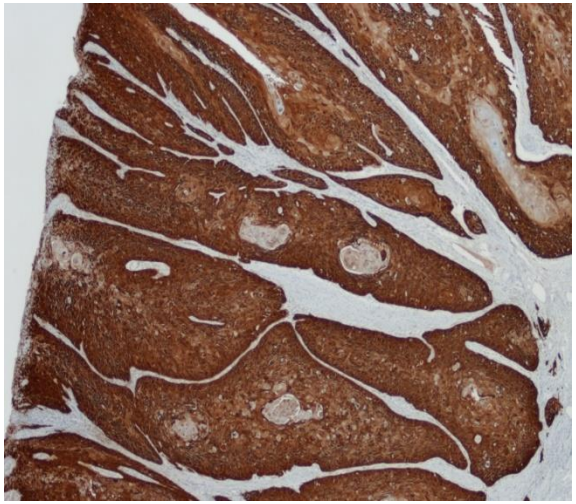



~80% concordance between morphology & IHC

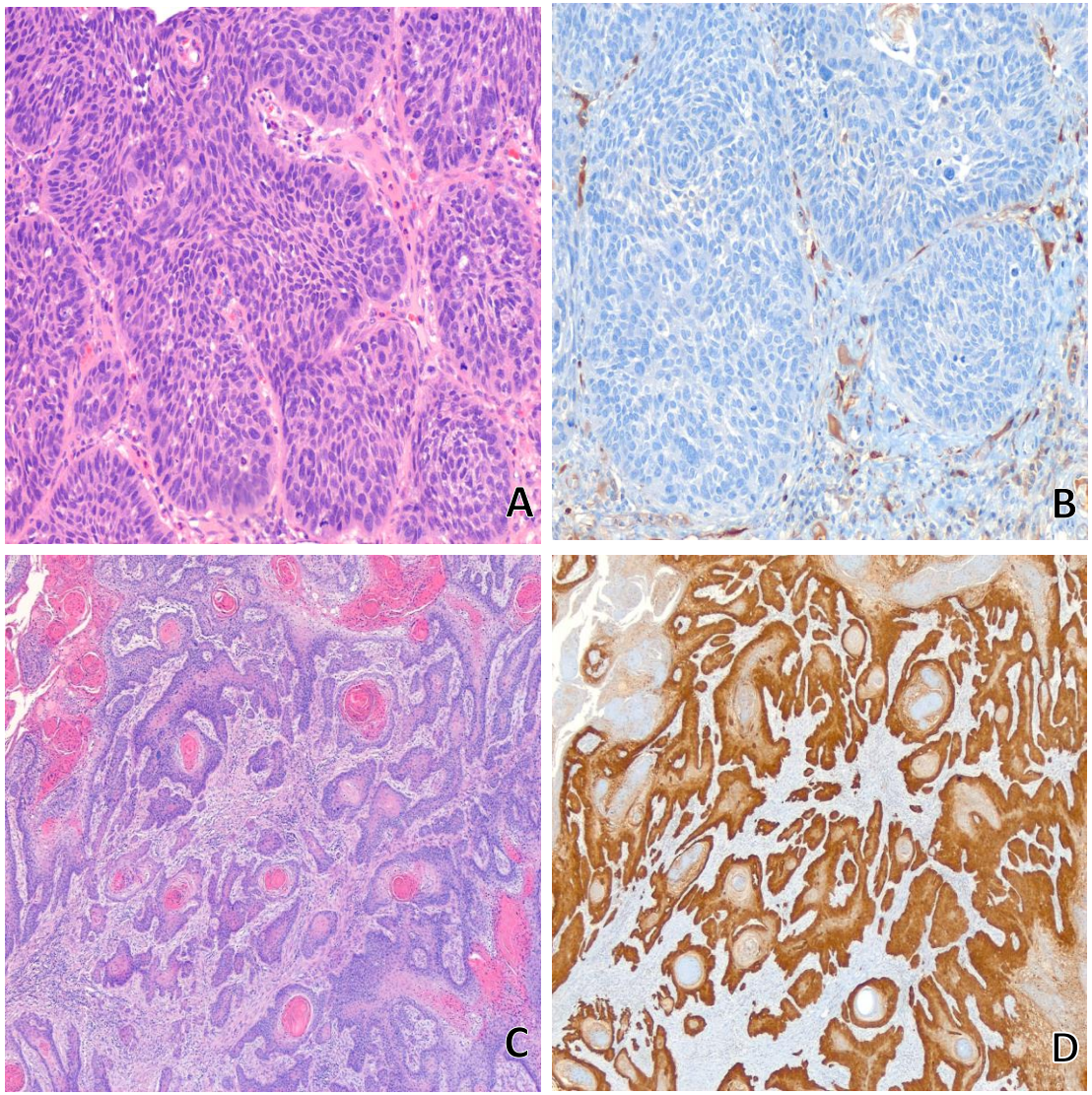

Two cases where morphological assessment and p16 IHC yielded discrepant results.

Table 3: Cases with discrepant p16 IHC and HPV PCR results

Case	Age (yr)	VIN	Inv SCC	p16	HPV PCR	HPV *in situ*	Other information	Final HPV subclassification
1	81	dVIN	WDK	+	-	-		HPV-Independent
2	79	dVIN	WDK	+	-	-		HPV-Independent
3	41	HSIL	Basaloid	+	-	+	Prev. CIN	HPV-Associated
4	76	dVIN	WDK	-	+	-		HPV-Independent
5	74	Not present	WDK	-	+	-	LS	HPV-Independent

VIN – vulvar intraepithelial neoplasia, Inv SCC – invasive squamous cell carcinoma, HPV PCR – Human Papilloma Virus polymerase chain reaction, dVIN – differentiated VIN, WDK – well-differentiated keratinizing, HSIL – high grade squamous intraepithelial lesion, CIN – cervical intraepithelial neoplasia, LS – lichen sclerosus



Conclusions

- Morphology leads to incorrect assessment of HPV status in 15-20% of cases
- p16 IHC: sensitivity of 100% and specificity of 98.4%
- HPV PCR can give false positive results



Recommended approach to assessment of HPV status

- Clinical information (age, results of cervical cytology), morphology, and p16 IHC taken into account in determining HPV status (with p16 accorded more weight than the other variables)
- HPV RNA ISH can be used in the uncommon cases that are indeterminate based on clinical/histopathological/p16 results



Outline

- WHY classify VSCC as HPVA and HPVI
- HOW to classify VSCC as HPVA and HPVI
- WHAT to include in your surgical pathology reports
- - Depth of invasion
- - Distance to resection margins



Depth of Invasion

- The depth of invasion of squamous cell carcinoma is defined as the measurement in millimeters from the epithelial-stromal junction of the adjacent, most superficial dermal papilla to the deepest point of invasion.[2,3] This parameter is important for tumor staging, especially for small tumors.

- Invasion < 1mm: less than 1% chance of nodal metastasis
-



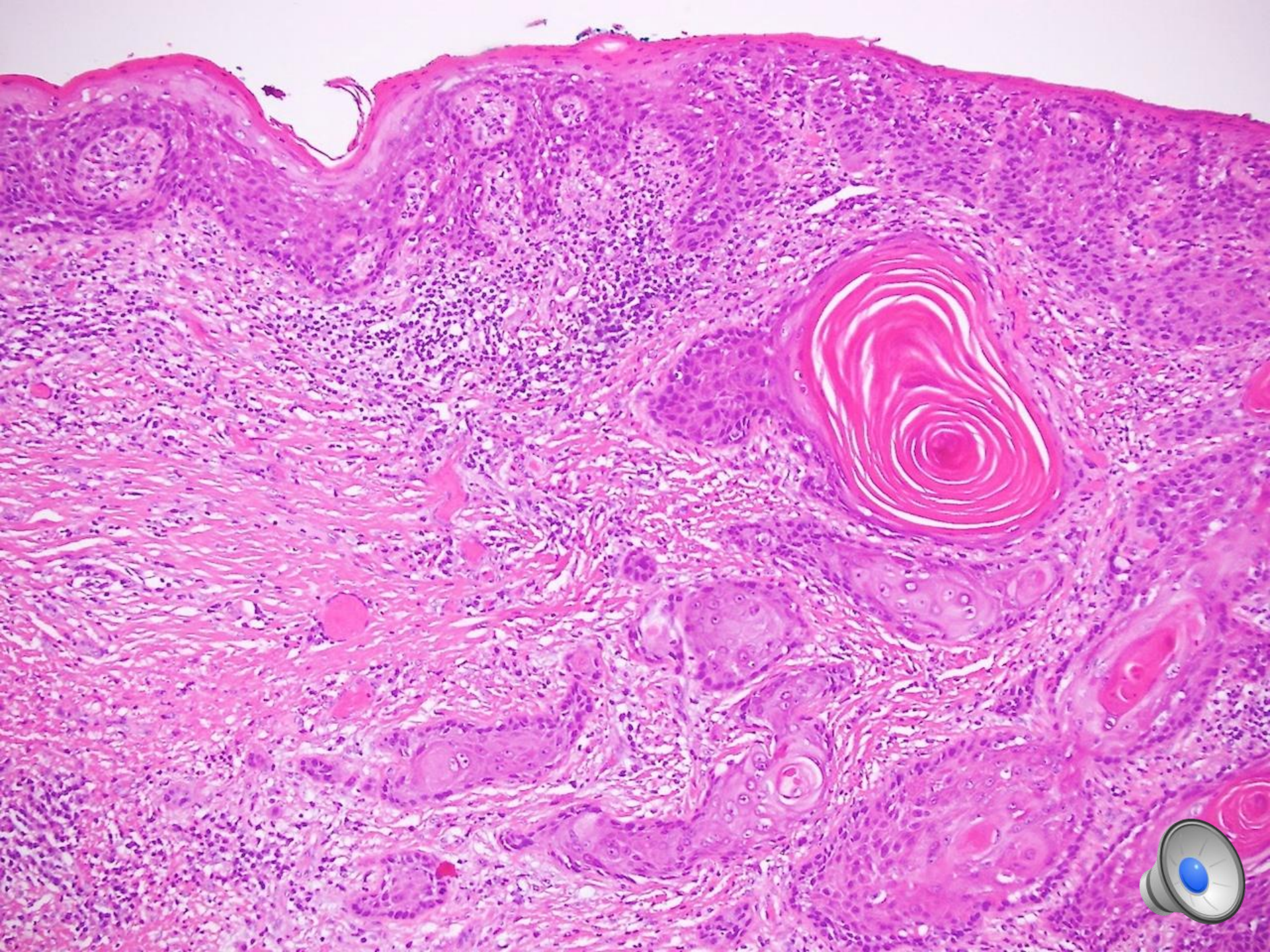

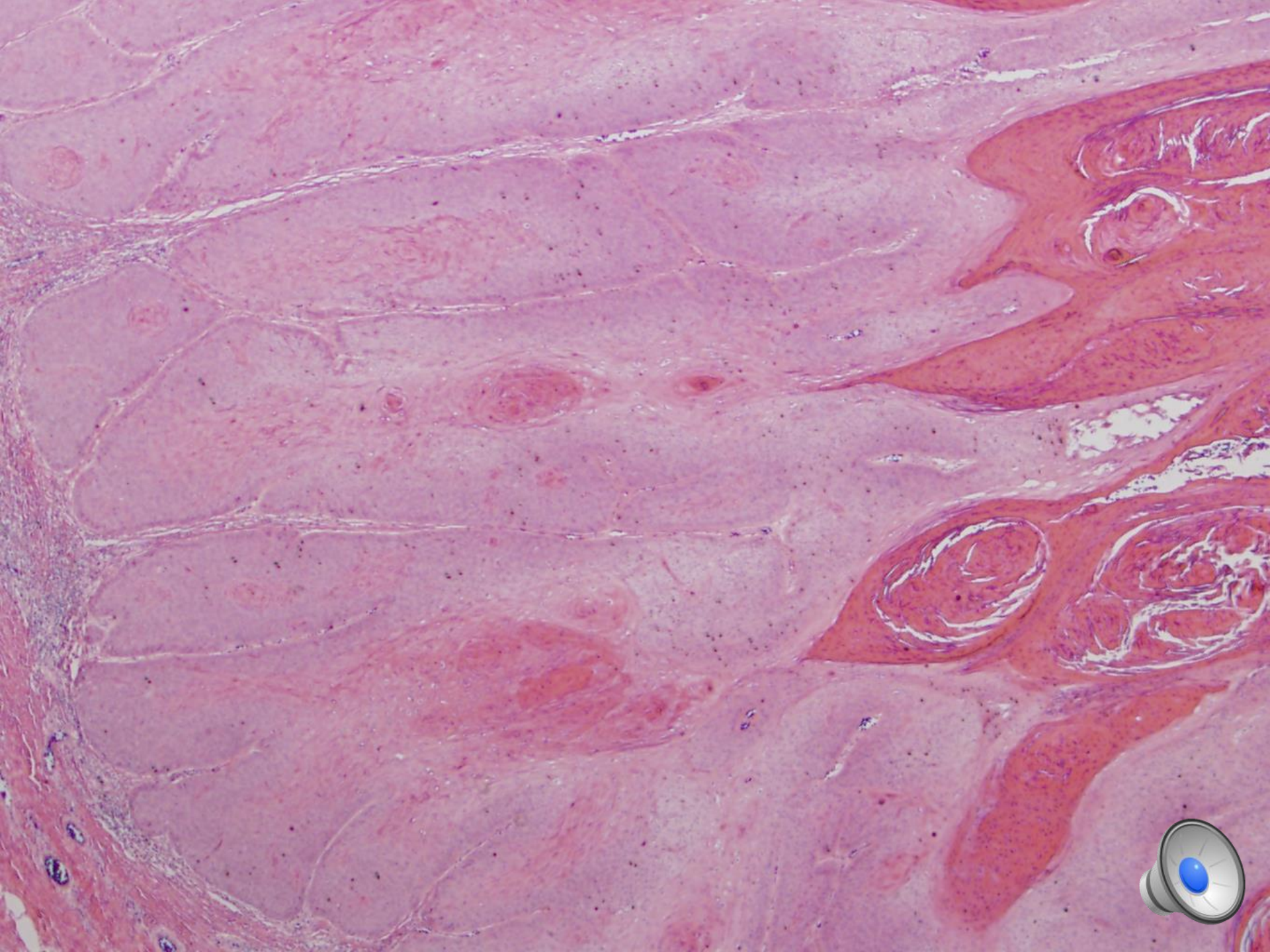

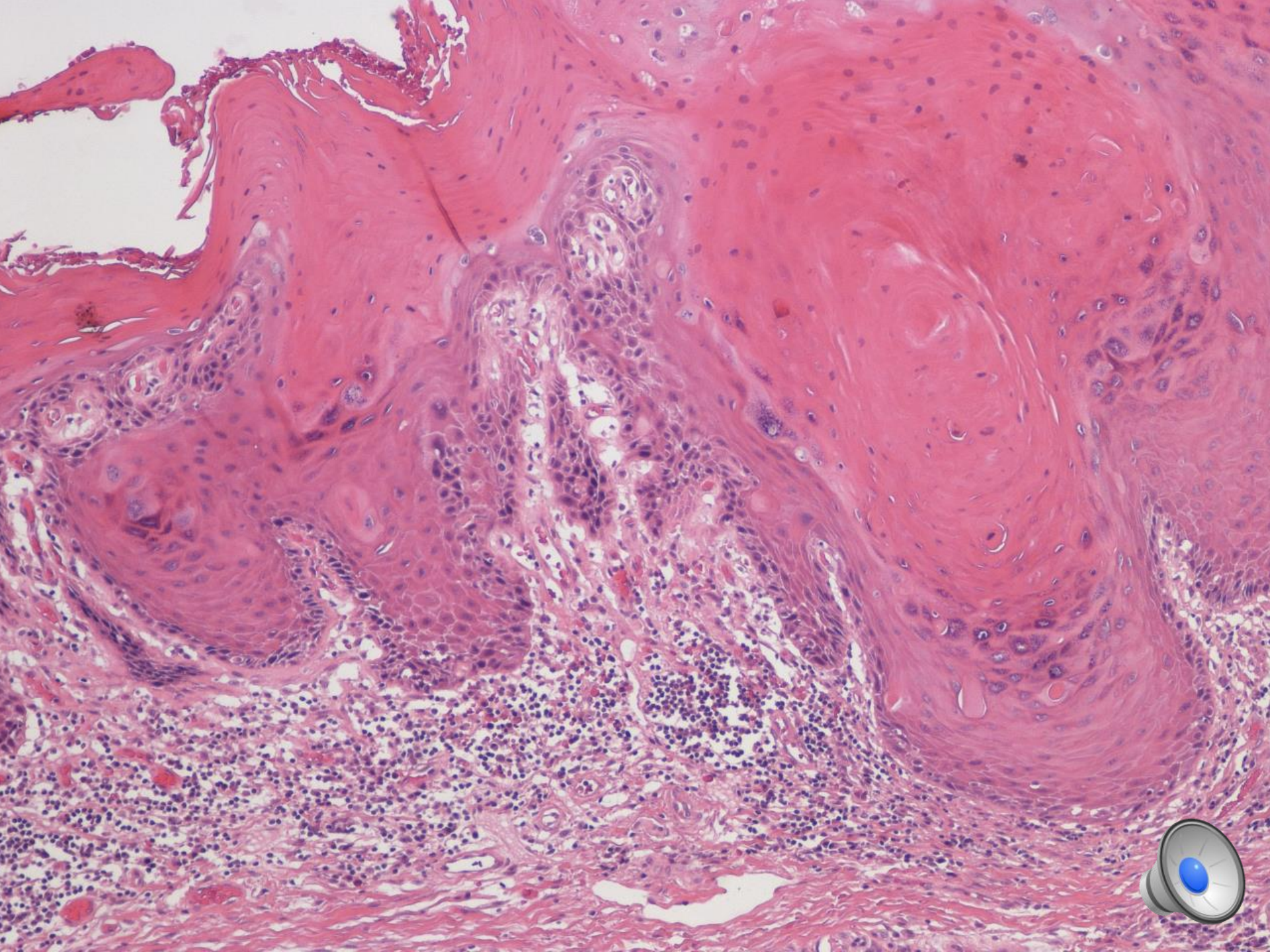

Assessment of Resection Margins

- Peripheral Margin (select all that apply)
- ___ Cannot be assessed (explain): _____
- ___ Uninvolved by invasive carcinoma
- + Distance of invasive carcinoma from margin (millimeters): ___ mm
- + Specify location: _____
- ___ Involved by invasive carcinoma
- Specify location(s), if possible: _____



- Kortekaas KE, Van de Vijver KK, van Poelgeest MIE, et al. Practical Guidance for Measuring and Reporting Surgical Margins in Vulvar Cancer. *Int J Gynecol Pathol*. 2020;39(5):420-427.



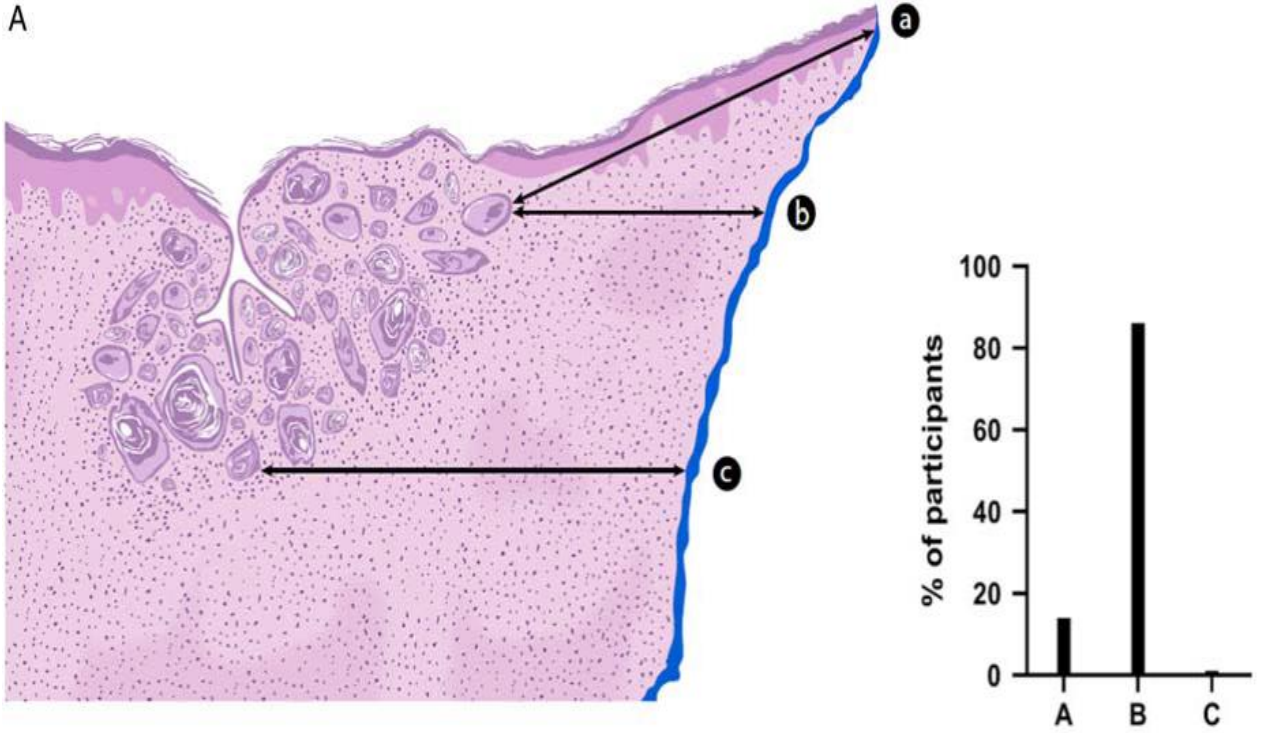
A
a
b
c
100
80
60
40
20
0
% of participants
A
B
C


B
a
b
100
80
60
40
20
0
% of participants
A
B

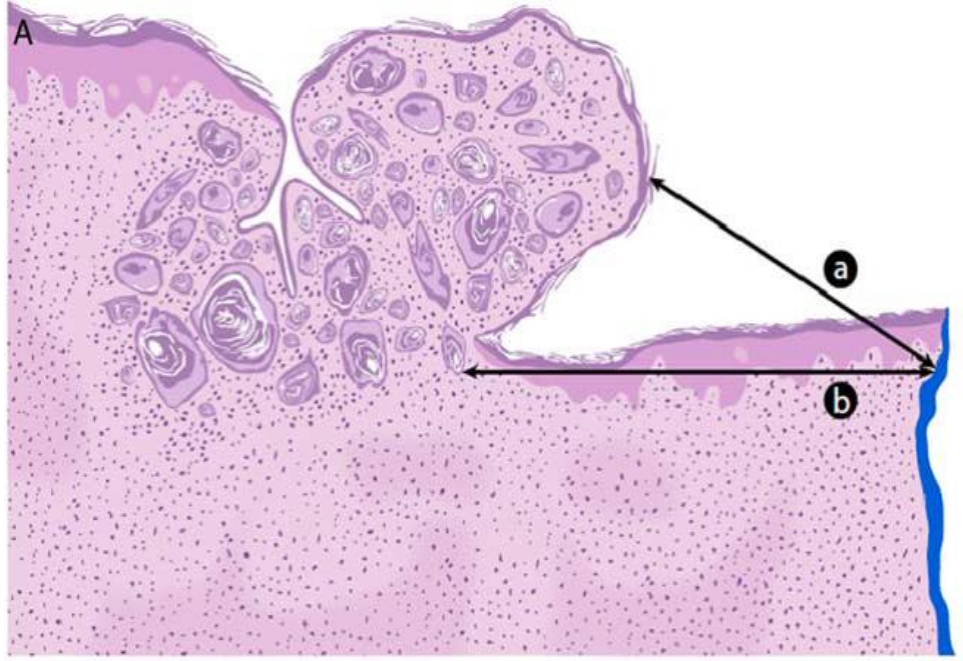
A
a
b

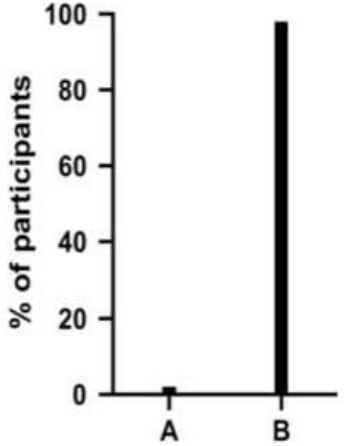
100
80
60
40
20
0
% of participants
A
B

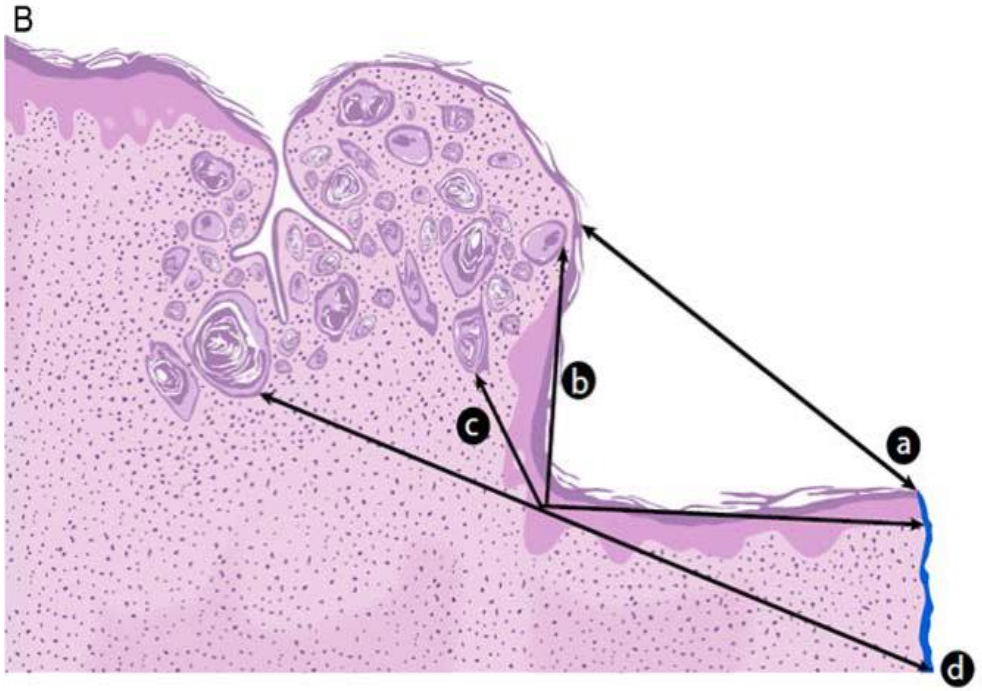
B
a
b
c
d

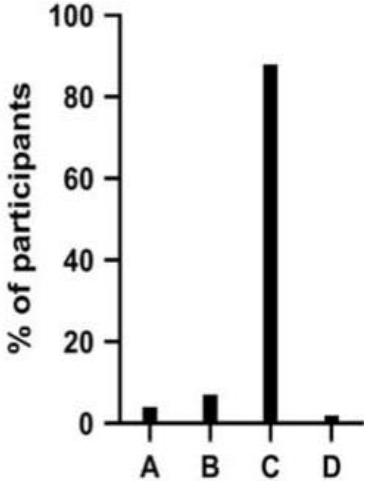
100
80
60
40
20
0
% of participants
A
B
C
D



Recommendations

- Minimum distance from the peripheral edge of invasive VSCC to margin
- This distance should run through tissue and preferably be in a straight line



Summary

- VSCC is now classified into HPV-associated and HPV-independent types; the latter has a worse prognosis
- This classification is done based on clinical findings, morphology and p16 IHC
- Interpretation of p16 staining is facilitated if you choose a section with in situ disease

