Interpretation and reporting terminology for mismatch repair immunohistochemistry in gynaecological cancers

Introduction

Mismatch repair (MMR) immunohistochemistry (IHC) is now used as a diagnostic, hereditary cancer screening, molecular classification and predictive biomarker in a range of tumour types. Within gynaecological pathology, its current routine role is most clearly established in endometrial carcinoma, where MMR status is required for Lynch syndrome (LS) screening, contributes to molecular classification and risk stratification, and may inform eligibility for some immune checkpoint inhibitor (ICI) therapies. This document provides guidance on MMR IHC in gynaecological cancers, with the detailed practical recommendations focused on endometrial cancer (EC).

MMR IHC is supported by national and international guidance for specific clinical purposes, including Lynch syndrome screening in endometrial carcinoma, molecular classification of endometrial carcinoma, and assessment of MMR/MSI status in the context of ICI therapy. Those sources should be regarded as the primary reference for their specific clinical, genetic or treatment recommendations. The present document is not intended to replace NICE, FIGO, ESGO/ESTRO/ESP, CAP or local laboratory guidance. Instead, it is intended to supplement these sources by addressing practical issues that arise in UK diagnostic practice but are not always covered in detail elsewhere.

The recommendations that follow are pragmatic and consensus-based and are intended to bring together multiple sets of BAGP guidance into a single document. For several of the scenarios discussed, including unusual staining patterns, subclonal loss, discordance with microsatellite instability (MSI) or germline testing, testing of non-endometrial gynaecological tumours and the wording of reporting comments, published evidence is limited. The guidance therefore reflects the collective experience of pathologists involved in MMR testing for gynaecological malignancy and is intended to support consistent, safe and clinically useful practice rather than to impose a prescriptive standard.

This document is aimed primarily at pathologists and laboratory teams undertaking, reporting or referring MMR IHC, but may also be useful to oncologists, clinical geneticists, genetic counsellors, multidisciplinary teams (MDTs), molecular pathology laboratories and service leads. Because treatment indications, national funding arrangements and genomic testing pathways may change, clinical eligibility for treatment and referral pathways for genetic assessment should always be confirmed against current local and national guidance at the time of testing.

Background

Biology of mismatch repair

Before a cell divides, it must replicate its DNA accurately so that each daughter cell receives an appropriate copy of the genome. The fidelity of eukaryotic DNA replication is maintained by three linked processes (1):

- Nucleotide selectivity by the replicative DNA polymerases, principally polymerases ε and δ;
- Exonucleolytic proofreading of newly synthesised DNA by the 3'-5' exonuclease activity of these polymerases;
- Replication-coupled/post-replicative correction of residual mispairs by the MMR system.

The main replication errors corrected by MMR are base-base mismatches and insertion/deletion loops, the latter occurring particularly in repetitive DNA sequences such as short tandem repeats (STRs) or microsatellites. These repetitive regions are prone to polymerase slippage and can escape proofreading, making them particularly dependent on the MMR system.

The MMR pathway involves mismatch-recognition complexes including MSH2-MSH6 and MSH2-MSH3, and downstream repair complexes including MLH1-PMS2, which coordinate excision of the error-containing strand, resynthesis and ligation (2). Loss of MMR function leads to accumulation of genomic alterations, including indels within microsatellites, producing MSI and a heavily mutated genome which can result in a cancer (3). MMR deficiency (MMRd) and high microsatellite instability (MSI-H) are therefore closely related and are often considered together in clinical pathways, although MMR immunohistochemistry and molecular MSI testing assess different biological readouts and are not completely interchangeable (4, 5).

Lynch syndrome

LS is an autosomal dominant cancer predisposition syndrome caused by a constitutional pathogenic variant in an MMR gene (*MLH1*, *MSH2*, *MSH6* or *PMS2*) or an *EPCAM* deletion leading to *MSH2* silencing. Tumours typically become MMRd after somatic inactivation of the remaining functional allele. Alongside colorectal cancer, EC is one of the core LS-associated cancers and is often the sentinel malignancy in affected women; pooled data suggest that LS accounts for approximately 3% of unselected ECs (6-9).

The molecular classification of endometrial carcinoma

The Cancer Genome Atlas (TCGA) reframed EC as four molecular groups:

- *POLE* ultramutated/*POLE*mut;
- MSI hypermutated/MMRd;
- Copy-number high/p53-abnormal;
- Copy-number low/no specific molecular profile (NSMP).

Clinically applicable classifiers such as ProMisE use MMR IHC, p53 IHC and targeted *POLE* sequencing to approximate these TCGA groups in routine practice, with reproducible prognostic information that complements histotype and grade. In this framework, MMRd is not simply an LS-screening result but one of the defining molecular classes of endometrial carcinoma, relevant to risk stratification, trial stratification and treatment selection (10-13).

Mismatch repair deficiency and response to immune checkpoint inhibitors

MMRd tumours have impaired repair of DNA replication errors and therefore tend to accumulate a high burden of somatic genomic variants, including frameshift variants in microsatellite regions. Some of these mutations generate abnormal proteins (neoantigens), which can increase tumour immunogenicity and provide a biological rationale for sensitivity to immune checkpoint inhibition.

Immune checkpoint inhibitors, particularly anti-PD-1/PD-L1 monoclonal antibodies, block inhibitory immune pathways and can restore or enhance anti-tumour T-cell responses. Early tissue-agnostic studies of PD-1 blockade showed that MMRd/MSI-H status enriched for clinical benefit, and this has subsequently been supported by EC-specific studies of agents such as pembrolizumab and

dostarlimab. MMR/MSI status is therefore useful both as a molecular diagnostic marker – including for LS screening – and as a predictive biomarker for benefit from immune checkpoint inhibition.

However, response is not universal. MMR/MSI results should be interpreted alongside tumour histotype, stage, prior treatment, clinical context and the intended treatment regimen (14-19).

Mismatch repair deficiency in endometrial carcinoma

Approximately one quarter to one third of ECs are characterised by MMRd, although the frequency varies substantially by histological subtype (6, 7, 20-22). MMRd is most common in endometrioid carcinomas, particularly high-grade endometrioid carcinomas, and in undifferentiated or dedifferentiated carcinomas, while it is less common in clear cell carcinoma and carcinosarcoma and rare in serous carcinoma (23).

In most cases, MMRd EC is sporadic/somatic, most commonly caused by *MLH1* promoter hypermethylation with epigenetic silencing of *MLH1* (21); other sporadic mechanisms include double-somatic inactivation of MMR genes (24).

A minority of cases of MMRd EC are caused by LS, which accounts for approximately 3% of all ECs (6, 7). In LS, the patient usually carries a constitutional pathogenic variant in an MMR gene, most commonly *MLH1*, *MSH2*, *MSH6* or *PMS2*, or an *EPCAM* deletion causing *MSH2* silencing (21); tumour development follows somatic inactivation of the remaining functional allele, leading to MMRd, MSI and increased cancer risk, especially in the colorectum and endometrium.

Mismatch repair deficiency in cervical carcinoma

MMRd is uncommon in cervical carcinoma. In a recent cohort of 508 cervical cancers, only 1% were MMRd by IHC, although 3 of the 5 MMRd tumours were neuroendocrine carcinomas, suggesting possible enrichment in this rare subtype (25). In adenocarcinoma, MMRd has been reported in approximately 3% of cases overall; in a 617-case series, MMRd was identified in 3.0% of HPV-associated and 5.5% of HPV-independent adenocarcinomas, with enrichment in clear cell adenocarcinoma, although numbers were small (26). The mechanisms of MMRd in cervical carcinoma are less well characterised than in EC and OC, but reported patterns include MSH2/MSH6 loss, MLH1/PMS2 loss, isolated MSH6 loss and isolated PMS2 loss. Cervical carcinoma is not generally regarded as a core LS-associated tumour, although rare LS-associated cervical adenocarcinomas, including clear cell carcinoma, have been reported; LS therefore appears to account for only a very small proportion of cervical carcinomas overall (27).

Mismatch repair deficiency in vulval and vaginal carcinoma

Data on MMRd in vulval and vaginal carcinoma are limited. In usual vulval squamous cell carcinoma, MMRd appears to be rare; a recent whole-exome sequencing study of 60 vulval squamous cell carcinomas, with MMR IHC performed, found all tumours to be MMR-proficient (MMRp) (28). Older small studies of vulval carcinoma also do not support MMRd as a major pathway in vulval carcinogenesis (29). Robust data for vaginal carcinoma are lacking, and reported rates from very small mixed gynaecological cancer cohorts should be interpreted cautiously. The mechanisms and LS contribution are therefore not well defined, but LS is not currently considered a common cause of vulval or vaginal carcinoma. Rare vulval sebaceous-type neoplasms may occur in the setting of Muir-Torre syndrome, but this is distinct from usual vulval squamous carcinoma.

Mismatch repair deficiency in uterine mesenchymal tumours

MMRd is uncommon in true uterine mesenchymal tumours but can occur in a small subset of leiomyosarcomas. In one IHC survey, abnormal MMR protein expression was identified in 2/20 leiomyosarcomas (10%), while adenosarcomas, low-grade endometrial stromal sarcomas, high-grade

endometrial stromal sarcomas/undifferentiated endometrial sarcomas and rhabdomyosarcomas in that series showed intact MMR expression; the same study also reported abnormal MMR protein expression in 4/67 uterine carcinosarcomas (6.0%) (30). Broader sarcoma sequencing studies similarly suggest that MMRd is rare overall, around 1-2% of sarcomas, but may be enriched in unclassified or undifferentiated sarcomas (31). Mechanistically, MMRd in mesenchymal tumours may be sporadic/somatic or hereditary; sarcoma is a rare manifestation of LS, particularly in *MSH2* carriers, but the proportion of gynaecological sarcomas attributable to LS is not well established (32).

Mismatch repair deficiency in ovarian carcinoma

MMRd is less common in ovarian carcinoma (OC) than in EC but is present in a clinically important minority of cases. Across epithelial ovarian carcinoma overall, MMRd is reported in approximately 6-7% of cases by IHC, while MSI-H is reported in approximately 10-13%, with variation according to histological subtype, cohort selection and testing method. MMRd is most strongly associated with ovarian endometrioid carcinoma, occurring in approximately 12-14% of cases in pooled and large histotype-specific series, and is less common in clear cell carcinoma, generally around 2-7%; it is uncommon in serous and mucinous carcinomas, while mixed endometrioid/clear cell and rare undifferentiated and dedifferentiated ovarian carcinomas may also show MMRd, although data for these subtypes are limited (33-38).

The mechanisms of MMRd in OC include both hereditary and sporadic/somatic causes: LS-associated OC arises in patients with a constitutional pathogenic variant in an MMR gene, followed by somatic inactivation of the remaining allele, while sporadic mechanisms include *MLH1* promoter hypermethylation and double-somatic MMR gene inactivation.

LS accounts for only a small proportion of ovarian carcinomas overall, approximately 1-2%, but is enriched in endometrioid and clear cell ovarian carcinomas; in unselected complete germline-testing series, germline pathogenic MMR variants are reported in approximately 2% of endometrioid, 1% of clear cell and less than 1% of high-grade serous ovarian carcinomas. Among ovarian carcinomas already shown to be MMRd, however, the proportion attributable to LS is much higher, with germline pathogenic MMR variants identified in approximately 47-50% of MMRd cases in systematic review and molecular series (33-36, 39-41).

Testing for mismatch repair deficiency

Detection of MMRd is usually undertaken by IHC for MMR proteins or by MSI testing.

MMR IHC assesses whether nuclear expression of MLH1, PMS2, MSH2 and MSH6 is retained in tumour cells. IHC has advantages:

- It is generally cheaper and more widely accessible for pathologists than MSI testing;
- It allows correlation with morphology and recognition of heterogeneous or subclonal MMRd;
- It is, in principle, not affected by the purity of the tumour sample, and so does not present the risk of false negative results in low-purity samples that is seen with MSI testing;
- Indicates the likely affected MMR gene/protein pair, helping triage *MLH1* promoter methylation testing and germline/somatic testing.

A two-antibody screen (PMS2 and MSH6) may be used with reflex staining as required.

MSI testing detects length changes in selected microsatellites, usually by polymerase chain reaction (PCR) which assesses a defined set of microsatellites. It is performed on tumour DNA, ideally with tumour enrichment and, for some assays, matched normal DNA.

In colorectal cancer, IHC and PCR-based MSI are largely interchangeable for detecting MMRd. In EC, however, IHC should be the routine first-line test: studies report high but imperfect IHC/MSI concordance (94% [655/696] in EC in Stelloo et al. (42); 98.2% [322/328] in a predominantly EC gynaecologic cohort in Smithgall et al. (43)), and contemporary CAP guidance recommends MMR IHC over MSI-PCR/NGS in EC (5). PCR-MSI may be falsely negative or reported as MSI-low/MSS in EC because shifts can be subtle; Wu et al found minimal microsatellite shift in 52% (26/50) of MSI-high ECs, and MSH6-deficient tumours are a particular risk: germline *MSH6* carriers can have discordant IHC/MSI results, and seven of eight LS tumours classified MSS by either MSI assay in one recent study had isolated MSH6 loss (44-46). MSI testing should therefore be reserved for selected situations, e.g. equivocal or heterogeneous IHC or resolution of discordant and results and requires appropriate validation and expertise.

Next-generation sequencing (NGS)-based MSI assays are increasingly used in place of PCR-based approaches. They assess instability across multiple microsatellite loci within targeted or comprehensive genomic panels and may provide MSI status alongside other genomic information from the same tumour DNA extract. Reported concordance with MMR IHC is generally high but assay-, threshold- and tumour-type-dependent: Ali-Fehmi et al. reported a final discordance rate of 0.31% (590/191,767) across a very large solid-tumour cohort after pathology review (47), and Kang et al. reported substantial concordance between NGS-based MSI/MMR assessment and IHC in EC (κ=0.91) (48). However, a recent TSO500-based study found lower NGS-MSI/IHC concordance in EC than in CRC (85% vs 99%), with most discordant cases being IHC-MMRd/NGS-MSS (49), supporting the view that NGS-MSI in EC requires tumour-type-specific validation, careful cut-off selection and review/confirmation of borderline or discordant results, particularly in isolated MSH6 loss or atypical/subclonal IHC patterns.

Indications for mismatch repair testing in gynaecological cancers

Endometrial carcinoma

MMR IHC testing is well established in EC. The principal indications are Lynch syndrome screening, molecular classification and risk stratification, and prediction of response to immune checkpoint inhibition.

- **Screening for LS**
  LS is present in approximately 3% of unselected ECs and EC is often the sentinel malignancy in affected women. Identification of LS has implications for the patient, including colorectal surveillance, aspirin chemoprevention where appropriate, risk-reducing surgery and management of future cancer risk, and also enables cascade testing of relatives.
  Universal tumour testing is preferred to selection by age, family history or histological subtype, since clinical criteria miss a substantial proportion of LS-associated ECs. NICE recommends testing for LS in all patients diagnosed with EC using MMR IHC. Cases showing MLH1 loss or combined MLH1/PMS2 loss should undergo reflex *MLH1* promoter methylation testing; if *MLH1* promoter hypermethylation is not detected, germline testing should be offered. Cases showing MSH2 loss, MSH6 loss or isolated PMS2 loss should be referred for germline testing. The risk of LS is substantial in MMRd tumours not explained by *MLH1* promoter hypermethylation; in the PETALS study, LS was identified in 16/49 patients with MMRd EC after exclusion of *MLH1*-hypermethylated tumours (6, 50, 51).
- **Molecular classification**
  MMR status is one of the four clinically applicable molecular classes of EC, alongside *POLE*-mutated, p53-abnormal and no specific molecular profile (NSMP) tumours. MMR IHC is

therefore not only a Lynch syndrome screening test but also part of the molecular classification of EC. Current FIGO and ESGO/ESTRO/ESP guidance recommends integration of molecular class with stage, histotype, grade, lymphovascular space invasion (LVSI) and other clinicopathological factors for risk stratification and treatment planning.
MMRd ECs are generally regarded as an intermediate-prognosis molecular subgroup, although outcomes are heterogeneous and depend on the full clinicopathological context. The molecular class may influence MDT management decisions and should therefore be available where possible before definitive management decisions are made. In selected settings, trial data suggest that:

- MMRd tumours do not derive the same clear benefit from added chemotherapy as p53-abnormal tumours;
- Benefit from adjuvant radiotherapy may vary by molecular class;
- MMRd tumours have a higher rate of LVSI which is, itself, associated with nodal metastatic disease.

Known or suspected LS may influence management where ovarian preservation, fertility-sparing treatment or risk-reducing surgery is being considered. The main surgical implication is that ovarian preservation is not recommended in patients with germline *MLH1*, *MSH2*, *MSH6* or *PMS2* pathogenic variants, and LS carriers should be counselled regarding risk-reducing hysterectomy and bilateral salpingo-oophorectomy after completion of childbearing. From a medical perspective, there is evidence that MMRd status is associated with lower responses to hormone-based fertility-sparing treatment.
The TCGA classification requires assessment of the MMR status of all cases for identification of the MMRd molecular subtype of EC, with important management implications; such tumours are less likely to respond to conservative treatment with progesterone, show a high likelihood of lymphovascular space invasion justifying a sentinel or other nodal procedure, and more likely to respond well to radiotherapy, whereas chemotherapy may not have significant survival benefit in these tumours (52-58).

- **Predictive testing for patients with advanced or recurrent EC**
  Across many cancer types, MMR status is associated with sensitivity to immune checkpoint inhibition. In EC, MMR status is now an important predictive biomarker and may affect access to specific systemic therapies, although some currently recommended regimens apply irrespective of MMR status. In the UK, NICE-recommended immune checkpoint inhibitor therapies for EC are detailed in *Table 1*.

NICE guidance	MMR status	Treatment	Treatment setting
TA1064 (59)	MMRd/MSI-H	Dostarlimab with platinum-based chemotherapy	First line for primary advanced or recurrent disease
TA779 (60)[1]	MMRd/MSI-H	Dostarlimab monotherapy	Advanced or recurrent disease that has progressed during or after platinum-based therapy
TA914 (61)	MMRd/MSI-H	Pembrolizumab monotherapy	Advanced or recurrent disease that has progressed during or after platinum-based therapy
TA1117 (62)	MMRp/microsatellite stable (MSS)	Dostarlimab with platinum-containing chemotherapy	First line for primary advanced or recurrent disease

[1] NICE states that further evidence is being collected and that dostarlimab is available through the Cancer Drugs Fund until NICE reviews the guidance.

NICE guidance	MMR status	Treatment	Treatment setting
TA1092 (63)	Any	Pembrolizumab with carboplatin and paclitaxel	First line for primary advanced or recurrent disease
TA904 (64)	Any	Pembrolizumab with lenvatinib	Advanced or recurrent disease that has progressed during or after platinum-based therapy

Table 1: *NICE recommendations for immune checkpoint inhibitor therapy in EC, stratified by MMR and MSI status, correct as of May 2026*

Ovarian carcinoma

The role of routine MMR IHC testing in OC is less well established than in EC, and there is currently no NICE recommendation for universal MMR IHC screening for LS in all OC. Nevertheless, MMRd occurs in a clinically important minority of OC, particularly endometrioid carcinoma, and a substantial proportion of MMRd OC are associated with LS.

To align with the RCPath dataset for histopathological reporting of carcinomas and borderline tumours of the ovaries, fallopian tubes and peritoneum (65), MMR IHC should be performed at diagnosis in ovarian endometrioid and clear cell carcinomas, as well as mixed, dedifferentiated and undifferentiated OC. MMR IHC should also be performed when the patient's personal or family history raises the possibility of LS.

Routine MMR IHC is not currently recommended for other ovarian carcinoma subtypes in the absence of these features, but it may be requested on a case-by-case basis, particularly where the result may affect genetic referral, clinical trial eligibility or systemic treatment options.

Other gynaecological cancers

Routine MMR IHC testing is not currently recommended for all cervical, vulval, vaginal or uterine mesenchymal tumours, because MMRd is uncommon and the evidence base is limited. Testing may nevertheless be appropriate in selected cases, including unusual histological subtypes, tumours diagnosed at a young age, tumours arising in patients with a personal or family history suggestive of LS, synchronous or metachronous LS-associated cancers, sebaceous-type vulval neoplasms raising the possibility of Muir-Torre syndrome, and recurrent or metastatic disease where immune checkpoint inhibitor therapy or clinical trial entry is being considered.

In all gynaecological cancers, MMR/MSI testing may be requested by oncologists to assess likely benefit from immune checkpoint inhibition, support clinical trial entry, or inform individualised systemic treatment decisions. In the UK, routine NICE-approved MMR-directed immunotherapy pathways in gynaecological cancer are currently centred on EC, but MMRd remains a biologically important and potentially actionable finding in other tumour types.

Interpretation of mismatch repair immunohistochemistry

Normal mismatch repair protein expression

MMR protein expression in normal tissues is seen as nuclear staining (**Figure 1** and **Figure 2**). The staining is generally uniform but may be of variable intensity, with more rapidly proliferating cells showing more intense staining. In cancer cells, generally characterised by higher proliferation rates relative to normal tissue, the staining intensity is typically strong, and generally stronger than that seen in the background stroma, normal glands or inflammatory cells that serve as an internal control (**Figure 3** and **Figure 4**).

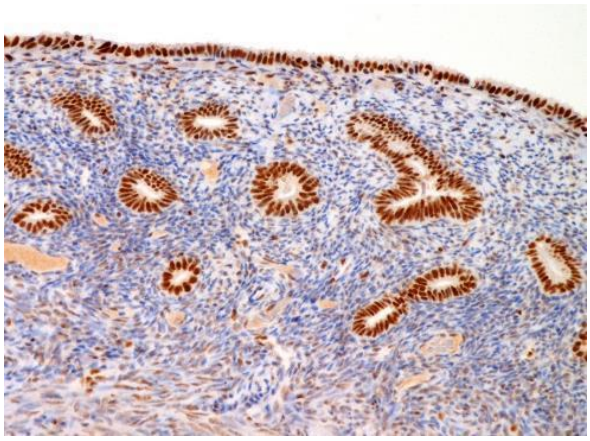

Figure 1: *MMR protein expression in normal inactive endometrium (PMS2).*

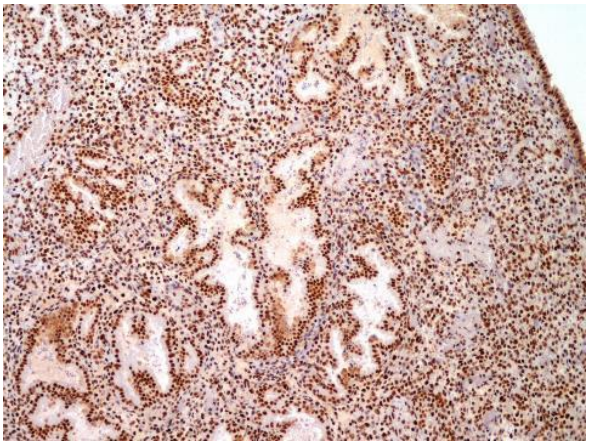

Figure 2: *MMR protein expression in secretory endometrium (MSH2).*

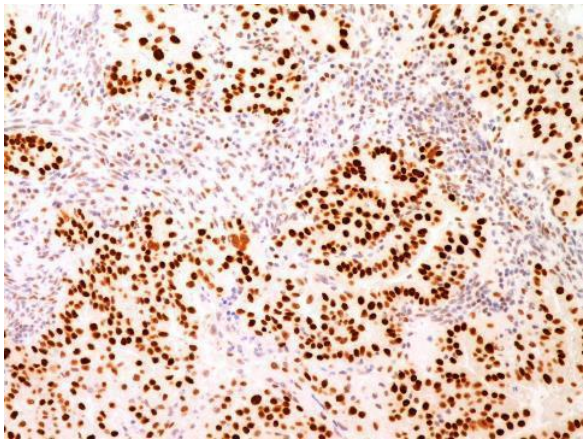

Figure 3: *MMR protein expression in EC (PMS2).*

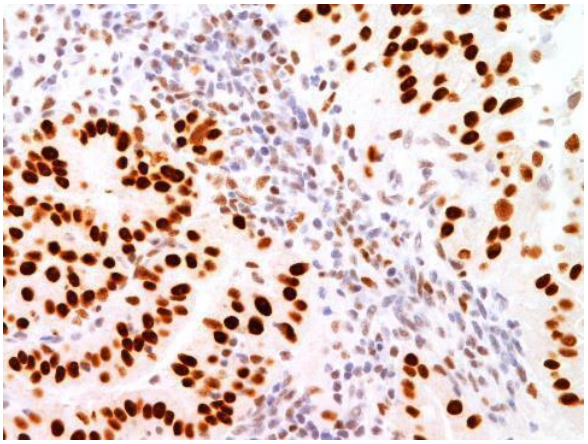

Figure 4: *Note the stronger intensity in tumour cells as compared to stromal cells (same area as **Figure 3**).*

Abnormal mismatch repair protein expression

MMRd is usually detected by IHC as loss of nuclear expression of one or more MMR proteins in tumour cells, with retained staining in internal non-neoplastic control cells. The four main MMR proteins assessed in routine practice function as heterodimers: MLH1 pairs with PMS2, and MSH2 pairs with MSH6. PMS2 is dependent on MLH1 for stable expression, and MSH6 is dependent on MSH2 for stable expression. In contrast, MLH1 and MSH2 may remain detectable when PMS2 or MSH6 is lost, respectively, because they can form alternative heterodimers with other MMR proteins.

The four typical abnormal MMR IHC patterns are therefore:

- Loss of MLH1 and PMS2, usually reflecting underlying MLH1 inactivation, most commonly through *MLH1* promoter hypermethylation in EC, but also seen with *MLH1* pathogenic variants or other *MLH1* alterations;
- Loss of MSH2 and MSH6, usually reflecting underlying MSH2 inactivation, including *MSH2* pathogenic variants or *EPCAM* deletion causing *MSH2* silencing;
- Isolated loss of MSH6, usually reflecting underlying *MSH6* abnormality;
- Isolated loss of PMS2, usually reflecting underlying *PMS2* abnormality, although rare *MLH1* abnormalities can produce this pattern.

Unusual, subclonal or discordant staining patterns may occur, however.

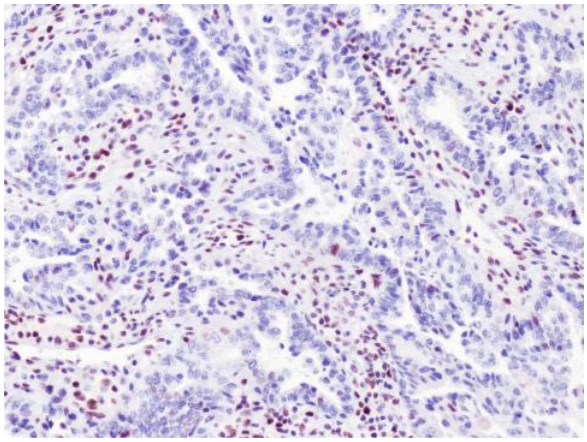

Figure 5: *Loss of MSH6 expression in an EC. The presence of nuclear staining in internal controls (as shown by stromal cells) is essential for the interpretation of abnormal MMR expression.*

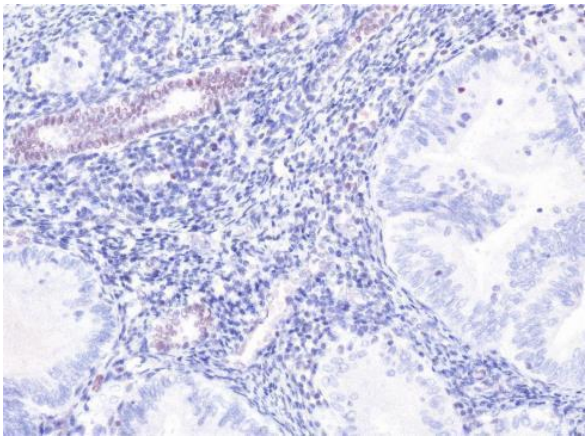

Figure 6: *Loss of MSH6 expression in another case of EC. While the stromal cells exhibit minimal staining in this area, the presence of weak nuclear staining in non-neoplastic endometrial glands (upper left) allows this interpretation to be made.*

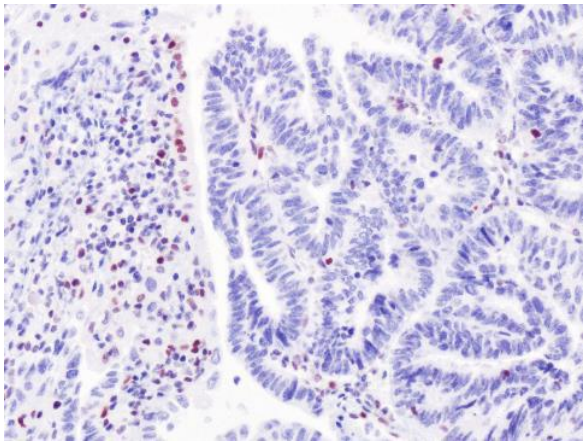

Figure 7: *Loss of MSH6 expression in an EC (right), in contrast to the variable nuclear staining in the non-neoplastic epithelium, stromal cells and lymphocytes (left).*

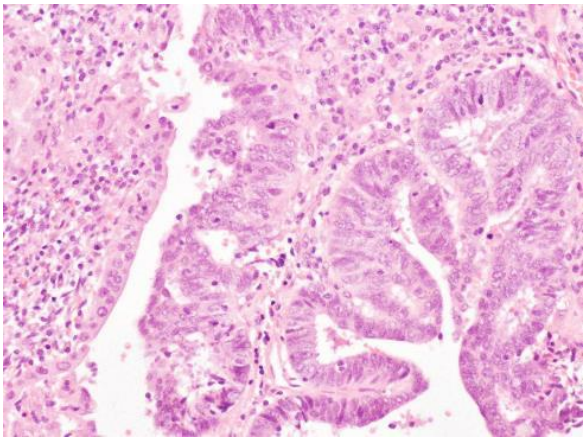

Figure 8: *Histology of the EC from the same area as Figure 7.*

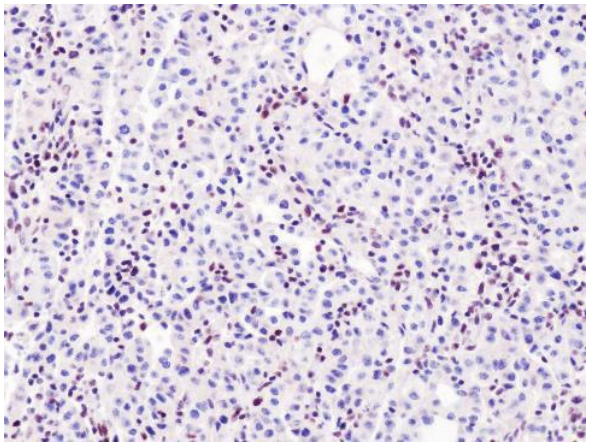

Figure 9: *Loss of MSH2 expression in an EC. The presence of admixed lymphocytes with positive nuclear staining may sometimes obscure the tumour nuclei.*

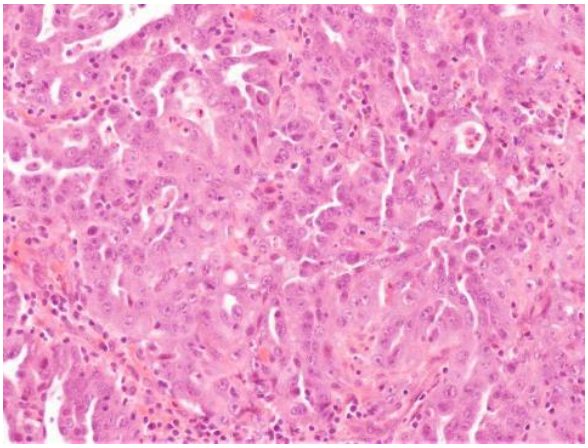

Figure 10: *Histology of the EC from the same area as Figure 9.*

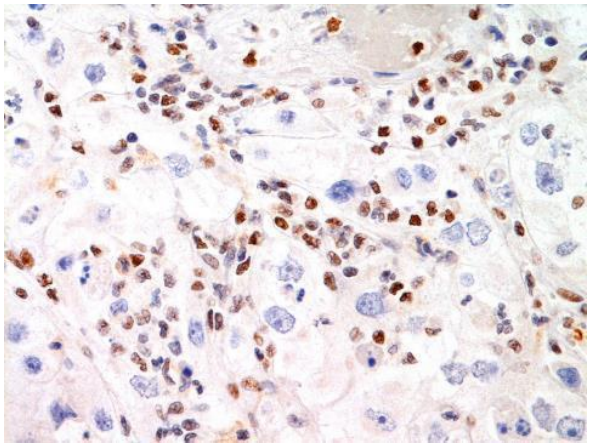

Figure 11: *Loss of MSH2 expression in a high-grade EC. At high power it can be appreciated that nuclear staining is limited to the lymphocytes whereas the tumour nuclei are negative.*

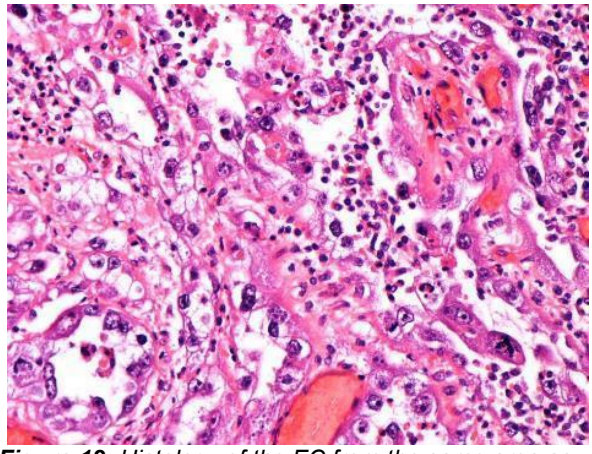

Figure 12: *Histology of the EC from the same area as Figure 11.*

Challenges and pitfalls in mismatch repair immunohistochemistry interpretation

Poor fixation

MMR IHC is fixation-sensitive. Poor fixation is a common problem in pathological reporting of EC and frequently results in absent staining with one or more MMR IHC stains. It is vital that well-fixed areas are examined when reporting MMR IHC, to avoid erroneous interpretation of one or more stains as showing loss of expression. For this reason, MMR IHC should be preferentially carried out on biopsies, with the added advantage that this vital information is available at the time of diagnosis of EC. If a resection specimen needs to be used, a block showing minimal autolytic changes should be selected.

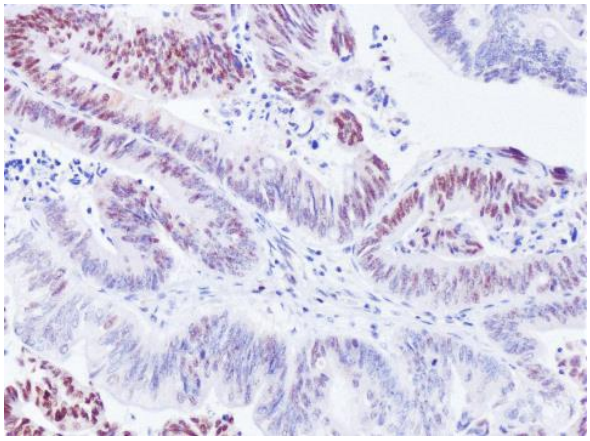

Figure 13: *Patchy expression of MSH6 in an EC. Note the lack of nuclear staining in stromal cells in this area, which would signify the possibility of suboptimal fixation. A gradation of staining intensity may be observed in such areas.*

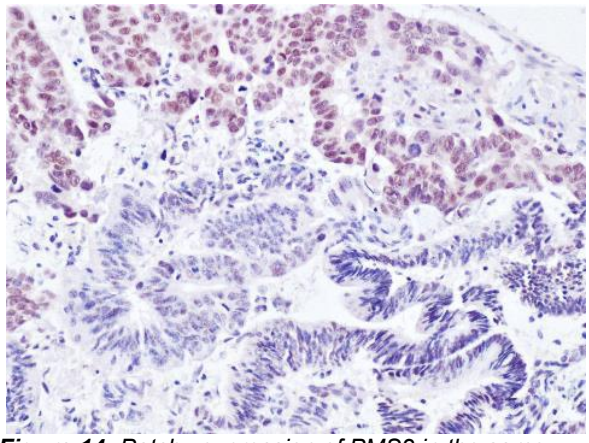

Figure 14: *Patchy expression of PMS2 in the same case of EC as Figure 13. While the appearance may resemble subclonal loss of expression, this area is not interpretable due to the lack of valid internal controls in the vicinity of tumour cells lacking expression.*

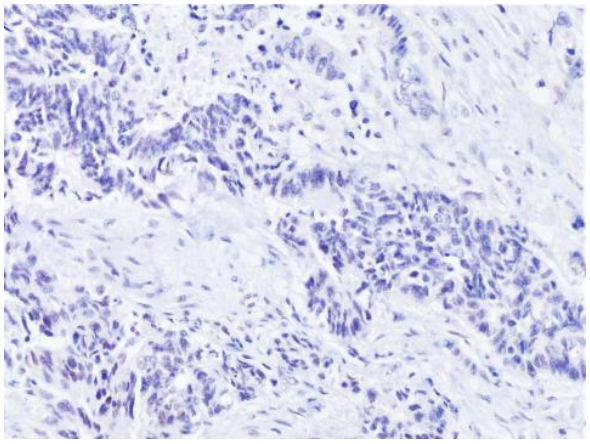

Figure 15: *In this area (PMS2 for same case of EC as Figure 13), there is complete absence of staining for PMS2 in both tumour cells and stromal cells. This area is non-interpretable for the lack of valid internal controls, likely representing a poorly fixed area with antigen degradation.*

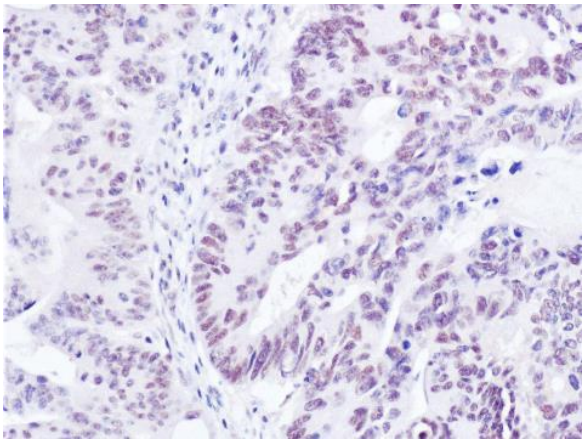

Figure 16: *In another area (PMS2 for same case of EC as Figure 13), there is weak to moderate nuclear staining in the tumour cells, together with scanty faint staining in the stromal cells as internal controls. This is interpreted as retained expression. The patchy staining in this case probably represents an artefact related to suboptimal fixation instead of genuine subclonal expression.*

Weak or focal expression in the presence of MMRd

Very weak or very focal MMR expression can occur in the presence of a defective MMR protein and similarly weak or focal MSH6 expression may be seen in the presence of an *MSH2* variant. As the expression of MMR proteins is generally strong and diffuse relative to the internal controls, the presence of very weak or focal expression in tumour nuclei coupled with significantly stronger staining in the internal controls should be reported as MMRd. In cases where the internal control staining is weak and of similar intensity as the focal weak staining observed in tumour nuclei, MMR expression could be reported as equivocal. Repeating the staining on a different section or on a biopsy rather than the hysterectomy specimen may be able to solve some of these issues.

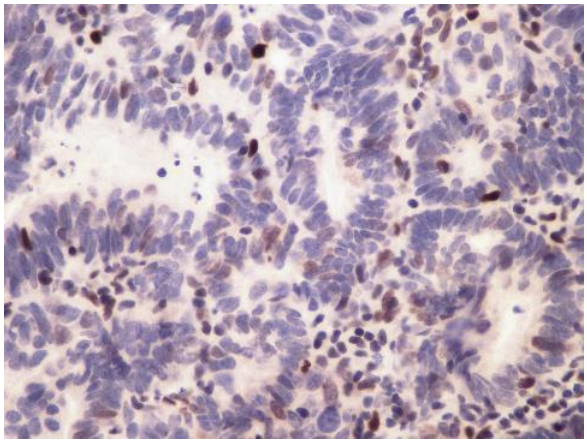

Figure 17: *Focal weak staining for MSH6 in tumour nuclei is observed in this EC. MSH2 is lost in this case (not shown).*

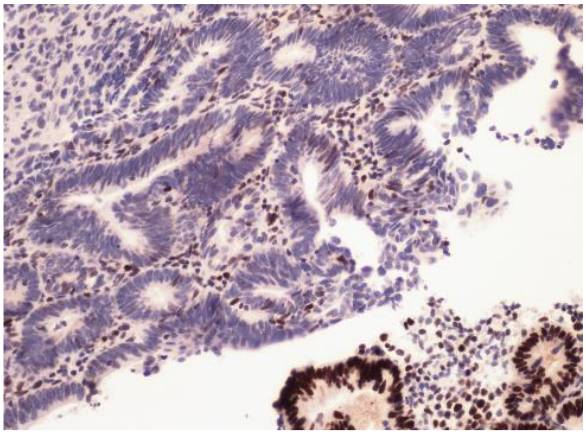

Figure 18: *At low power magnification (same case as* ***Figure 17****), the majority of tumour nuclei are negative for MSH6, in contrast to the stronger nuclear staining in stromal cells and non-neoplastic epithelium. This case should be interpreted as abnormal/loss of MSH6 expression despite focal weak staining in some tumour nuclei.*

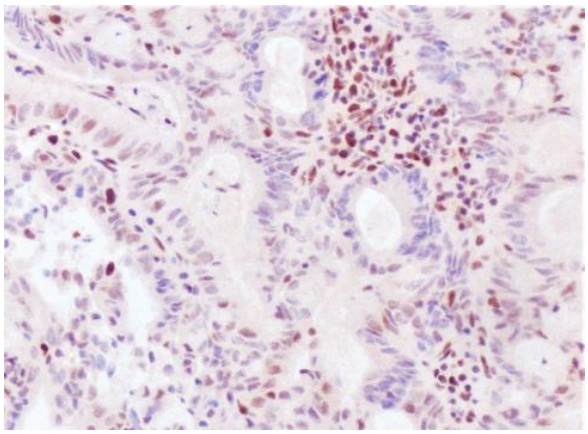

Figure 19: *Focal weak nuclear staining for MLH1 is observed in the tumour cells of this EC, with stronger staining present in the immediately adjacent stromal cells.*

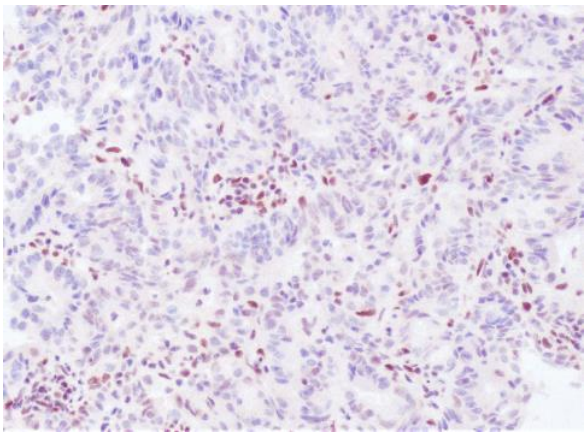

Figure 20: *Another area (same case as* ***Figure 19****) demonstrates that most tumour nuclei are negative while the positively stained, immediately adjacent stromal cells have an overall stronger intensity, supporting the interpretation of abnormal MMR expression. This case was confirmed as having a germline MLH1 variant.*

Subclonal mismatch repair deficiency

Subclonal loss of MMR protein expression refers to complete nuclear loss of one or more MMR proteins in a discrete tumour cell population, adjacent to tumour areas with retained nuclear expression. This pattern usually shows an abrupt transition between retained and lost expression. It should be distinguished from weak, patchy or variable staining, and from fixation artefact. A diagnosis of true subclonal loss should only be made when appropriate non-neoplastic internal control cells, such as stromal cells, inflammatory cells or benign epithelium, show retained nuclear staining in the same area as the tumour cells showing loss. Fixation-related artefact typically affects tumour and internal control cells together and often shows a gradual reduction or ‘gradient’ of staining, whereas genuine subclonal loss usually shows an abrupt interface.

The pattern and approximate extent of subclonal loss should be reported, for example: “subclonal loss of MLH1 and PMS2 involving approximately X% of tumour.” There is no universally accepted minimum threshold for reporting subclonal MMR loss. A pragmatic threshold of approximately 10% of tumour showing subclonal loss has been suggested for uniform classification of ECs as MMRd in

molecular subtyping contexts, but this has not been explicitly endorsed as a consensus reporting threshold. Convincing smaller foci should not necessarily be ignored; where the focus is extremely small, a comment may be added to indicate that the clinical significance is uncertain.

Most well-characterised examples of subclonal MLH1/PMS2 loss in EC appear to represent an acquired, sporadic event, usually heterogeneous *MLH1* promoter hypermethylation occurring during tumour evolution or progression. In such cases, the tumour area showing MLH1/PMS2 loss may show greater *MLH1* promoter methylation and/or MSI than adjacent tumour with retained MMR protein expression. However, subclonal MMR loss should not automatically be assumed to be sporadic or artefactual. Subclonal loss has also been described in *POLE*-mutated EC and in LS-associated EC, and a small proportion of cases may harbour an underlying germline MMR pathogenic variant.

Acquired or secondary subclonal MSH6 loss is also recognised. This may occur in tumours that are already hypermutated or MMRd, including both sporadic and hereditary MMRd tumours, and has been linked in some cases to instability or frameshift alteration in a coding microsatellite/polycytosine tract within the *MSH6* gene. Subclonal MSH6 loss may be seen in association with complete MLH1/PMS2 loss and may be accompanied by variable or subclonal MSH2 expression. Similar secondary MMR abnormalities may also occur in the presence of pathogenic *POLE* exonuclease domain variants. Where subclonal MSH6 loss accompanies an otherwise clear MMR abnormality, such as complete MLH1/PMS2 loss, the primary abnormal pattern should be reported, with the subclonal MSH6 loss described in a comment. Isolated subclonal MSH6 loss should be treated more cautiously, as LS may be identified in a minority of such cases.

The diagnostic, prognostic and therapeutic implications of subclonal MMR loss remain incompletely understood. These cases should be reported as abnormal/subclonal rather than simply interpreted as MMR-proficient, because:

- A minority of cases with subclonal loss harbour germline MMR pathogenic variants and may represent LS;
- Binary reporting as ‘intact’ or ‘lost’ may miss clinically relevant MMR abnormalities;
- The behaviour of these tumours with respect to molecular classification, prognosis and response to immune checkpoint inhibition remains uncertain.

For EC molecular classification, subclonal MMR loss should be interpreted alongside *POLE* status, p53 status and the full clinicopathological context.

Where *MLH1* promoter methylation testing is undertaken to establish the aetiology of subclonal MLH1/PMS2 loss, the request should clearly state that the MMR loss is subclonal. The laboratory should be provided with the overall tumour cellularity and an estimate of the proportion of tumour showing subclonal loss. Where feasible, the area showing loss should be marked for macrodissection, so that testing is enriched for the MMR-deficient component. If enrichment of the subclonal area is not possible, *MLH1* promoter methylation results should be interpreted cautiously, because testing a whole section may dilute a methylation signal confined to a small tumour subclone (42, 66-72).

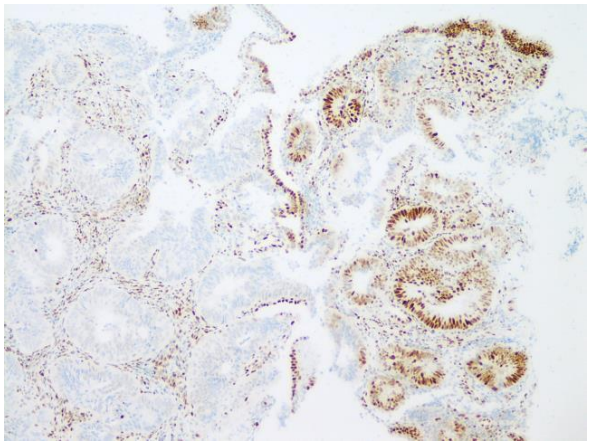

Figure 21: *Subclonal expression of MLH1 in part of this EC (right) with loss of staining in other foci (left). Note that stromal cells show positive staining throughout the entire area. This pattern may occur in ECs with MLH1 promoter hypermethylation. The percentage of cells showing loss of expression should be reported to the laboratory undertaking MLH1 promoter methylation testing; if macrodissection is possible, it should be undertaken to enrich for the cells showing loss of expression.*

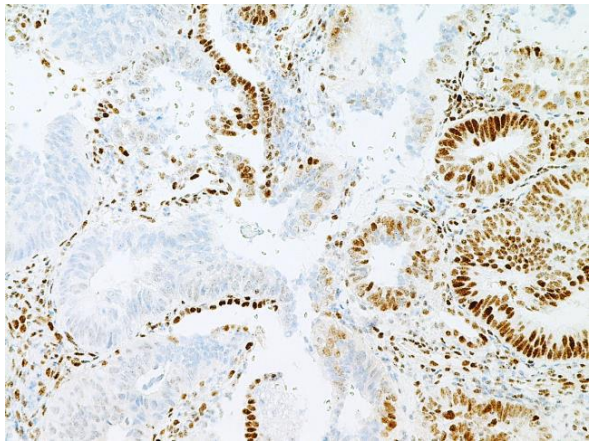

Figure 22: *High power view of subclonal MLH1 expression from the same tumour area as* ***Figure 21****.*

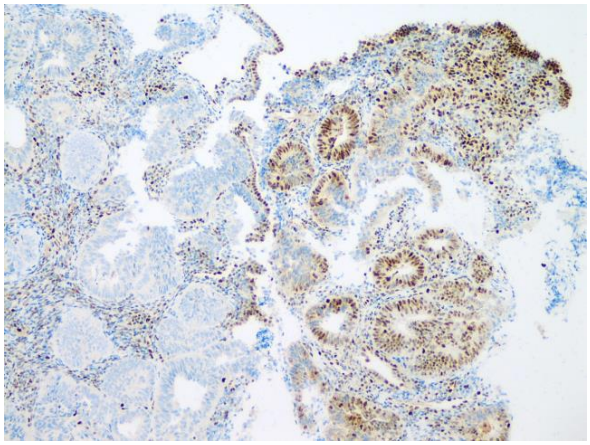

Figure 23: *Subclonal expression of PMS2 in the same case as* ***Figure 21****, demonstrating a similar pattern to that observed with MLH1.*

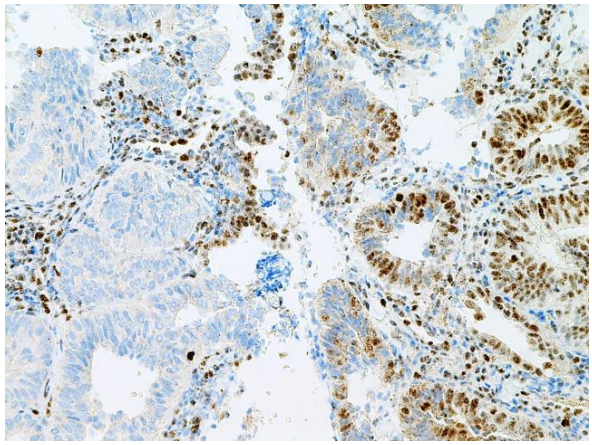

Figure 24: *High power view of subclonal PMS2 expression from the tumour area in* ***Figure 23****.*

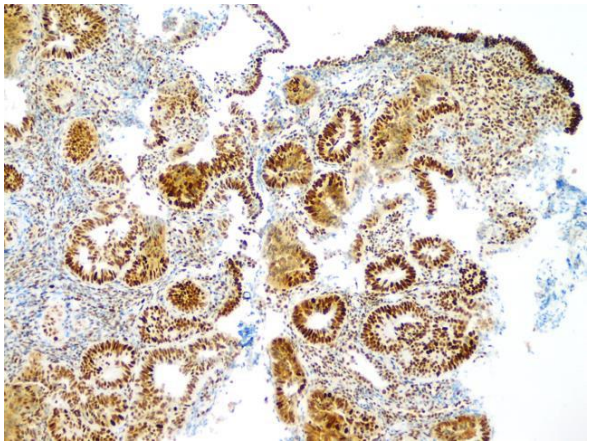

Figure 25: *Normal expression of MSH6 in the same case as* ***Figure 21****.*

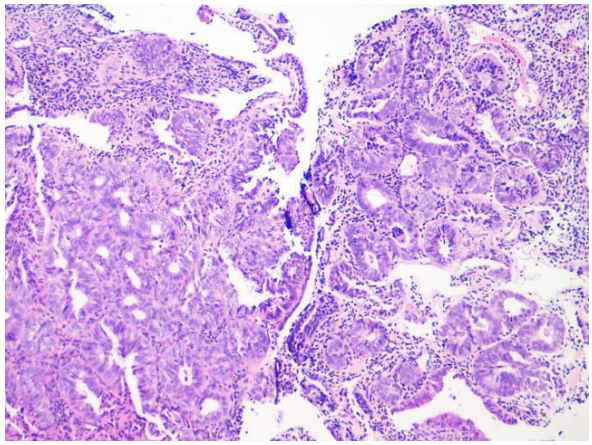

Figure 26: *Histology of the same tumour area as* ***Figure 21****.*

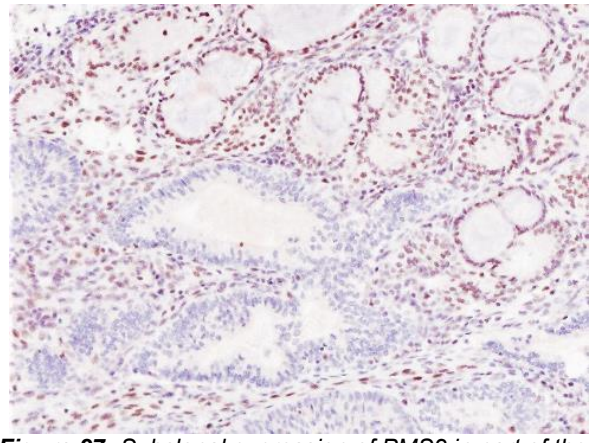

Figure 27: *Subclonal expression of PMS2 in part of the tumour (upper) with absence of nuclear staining in other areas (lower). Note the positive staining of stromal cells in both areas which enables its distinction from artefactual weak staining.*

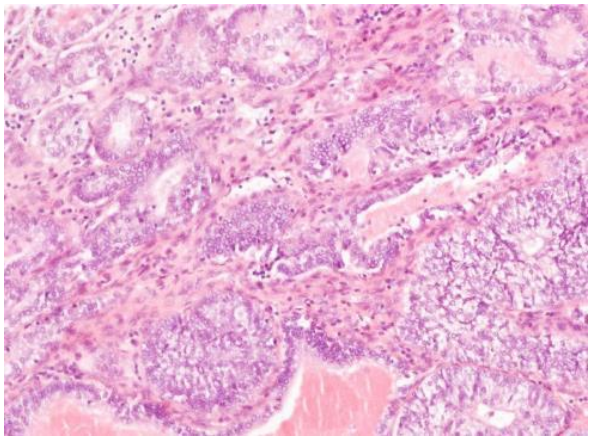

Figure 28: *Histology of the same tumour area as* ***Figure 27****.*

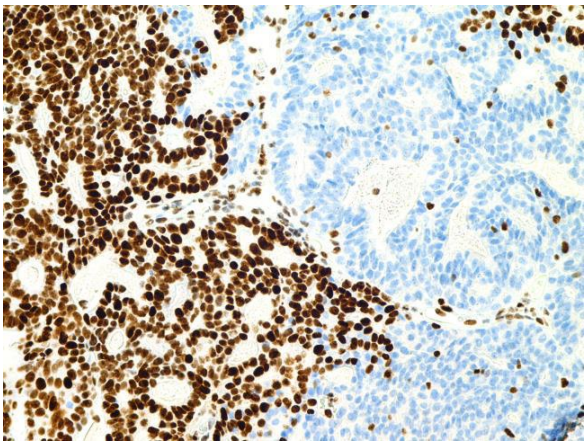

Figure 29: *Subclonal expression of MSH6 in part of this EC (left) coexisting with an area of negative staining (right). Note the positive staining of stromal cells among the negative tumour cells.*

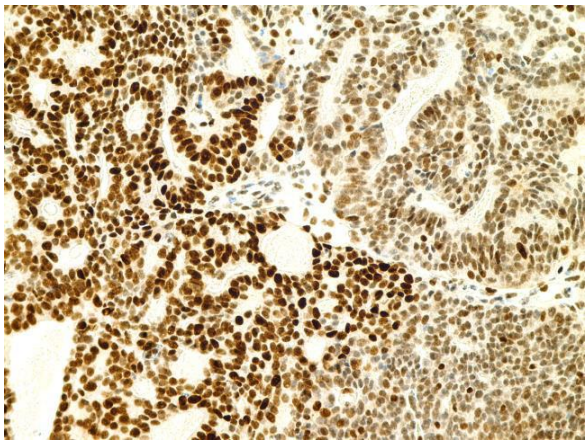

Figure 30: *Expression of MSH2 in the same tumour area as* ***Figure 29****.*

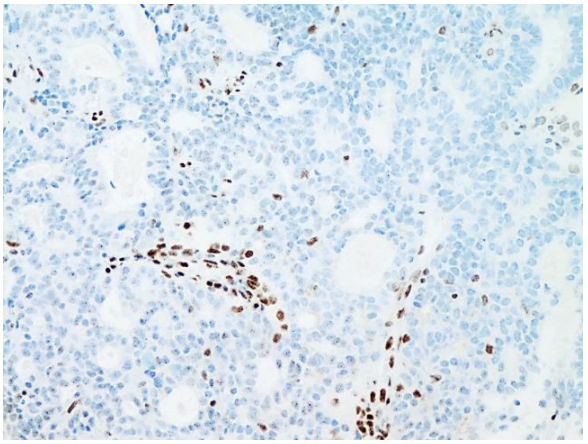

Figure 31: *Loss of expression of MLH1 in the same tumour area as* ***Figure 29****. Note that even the area with retained MSH6 shows loss of MLH1. This may signify the loss of MSH6 as a secondary event arising from an underlying MLH1 defect.*

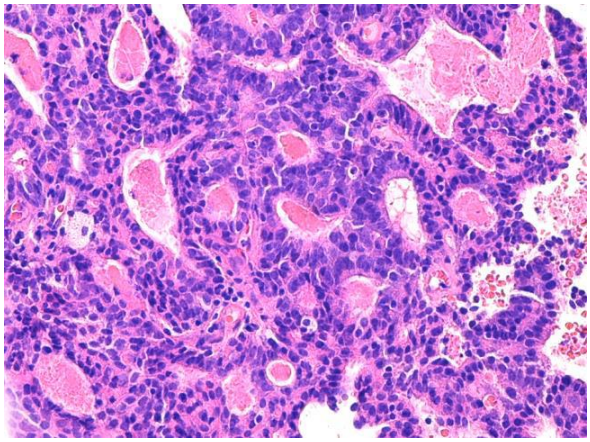

Figure 32: *Histology of the same tumour area as* ***Figure 29****.*

Punctate nuclear staining

A subset of MLH1-deficient tumours may show punctate or dot-like nuclear staining, particularly when stained with the VENTANA/Roche MLH1 M1 clone. This pattern can be mistaken for retained expression, but it should not be interpreted as intact MLH1 expression; in the presence of appropriate internal positive controls it should be reported as MLH1 loss/abnormal MMR expression. The pattern is a recognised clone-associated staining artefact/pitfall described in the literature (73-75). While this specific punctate nuclear pattern is best documented for MLH1 M1, other non-specific or non-nuclear artefactual staining patterns may occur with other MMR antibodies and should not be interpreted as retained nuclear expression.

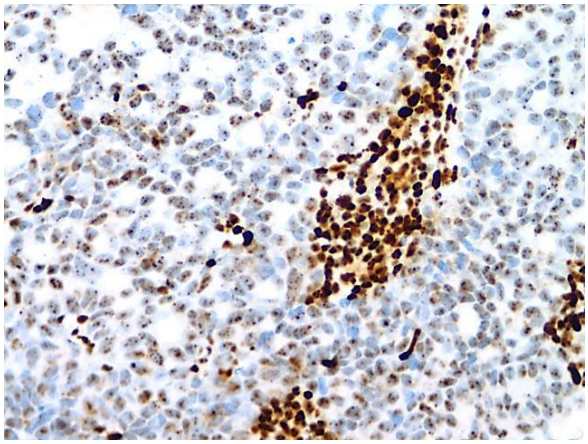

Figure 33: *Punctate nuclear staining for MLH1 in an EC. This pattern of staining has been recognised as an artefact which may be specific to certain antibody clones. This case should be reported as abnormal MMR expression.*

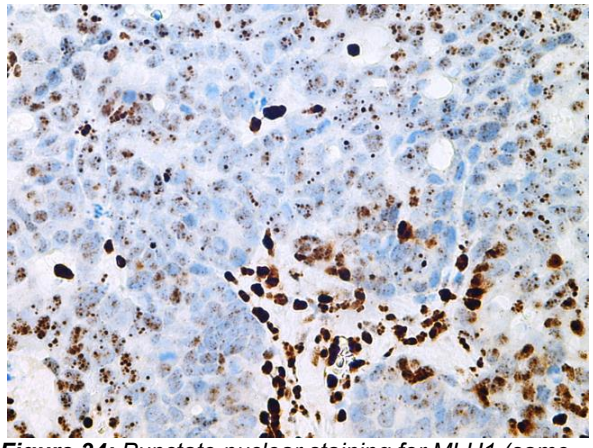

Figure 34: *Punctate nuclear staining for MLH1 (same case as* ***Figure 33****).*

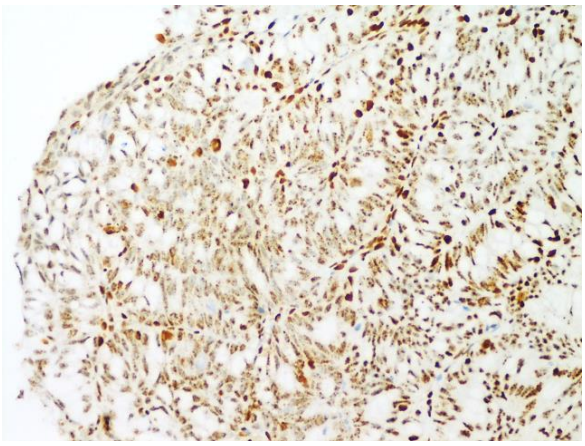

Figure 35: *Punctate nuclear staining for MLH1 may closely resemble intact expression at low power, as shown in this EC.*

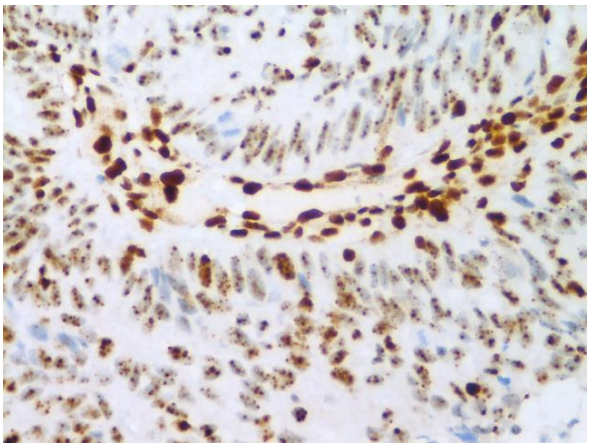

Figure 36: *At high power (same case as* ***Figure 35****), the dot-like staining in the tumour nuclei can be distinguished from the homogeneous nuclear staining in stromal cells.*

Cytoplasmic staining

The MMR proteins are localised to the nucleus. In some cases, possibly related to technical reasons, there is relatively conspicuous cytoplasmic or membranous staining in the absence of nuclear staining. In such cases, it is the absence of nuclear staining which is key; they should be reported as abnormal.

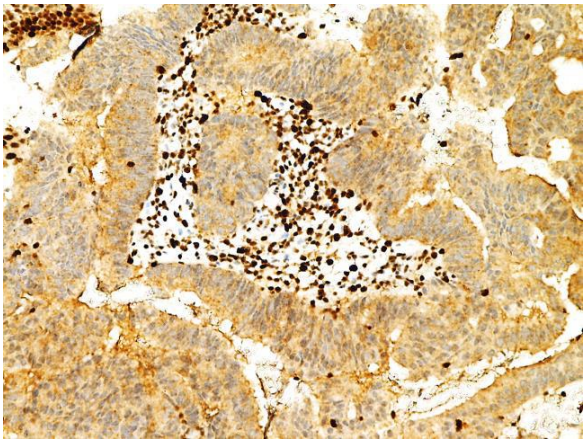

Figure 37: *Cytoplasmic staining for PMS2 in an EC. Note the absence of nuclear staining in tumour cells in contrast to the positive staining of stromal cells.*

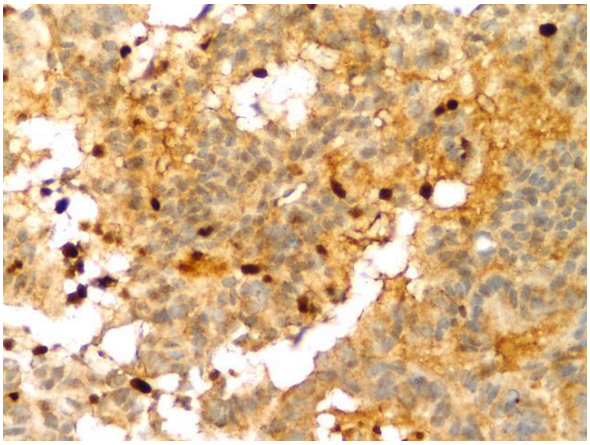

Figure 38: *Membrane accentuation may sometimes be encountered in cytoplasmic staining (PMS2; same case as Figure 37).*

Complex patterns of loss

Although the four patterns of MMRd described earlier (either completely or as a subclonal phenomenon) are the typical manifestations of MMRd, more complex patterns can occasionally be seen.

A superadded somatic defect can be seen in any MMRd, resulting in unusual MMR IHC patterns. This is usually as a result of secondary *MLH1* promoter hypermethylation, but more unusual phenomena can be observed. For example, cases with a germline *MSH6* variant can show MSH2 loss on IHC, which may be due to concurrent *MSH3* loss by other mechanisms (76).

Discordance with microsatellite instability or germline testing

No test for MMRd or LS is fully sensitive and specific. MMR IHC and MSI testing assess related but different consequences of MMR dysfunction: IHC assesses nuclear expression of the MMR proteins, whereas MSI testing detects instability at selected microsatellite loci. High but imperfect concordance is therefore expected. As described above, MMR IHC should remain the preferred first-line approach, with MSI testing reserved for selected situations such as equivocal, heterogeneous or otherwise discordant results.

MMR IHC is also a valuable screen for LS, but it is not a definitive germline test. Abnormal MMR IHC may reflect sporadic *MLH1* promoter hypermethylation or double-somatic MMR gene inactivation rather than LS; in the PETALS study, LS was identified in 16/132 IHC-MMRd ECs overall, and in 16/49 after excluding *MLH1*-hypermethylated tumours. Conversely, retained MMR protein expression does not completely exclude LS. Clinical concern for a familial cancer syndrome, including young age, multiple LS-associated tumours or a suggestive personal or family history, should therefore prompt further investigation even when MMR IHC is reassuring (50, 51, 77).

Recommended reporting terminology in endometrial carcinoma

The following table contains recommended reporting terminology for various scenarios encountered when reporting MMR IHC. It also includes recommended actions which should be taken for each result. The BAGP now recommends that *POLE* variant testing be undertaken in all ECs.

MMR IHC and *MLH1* promoter methylation result	**Recommended report text**	**Recommended actions**
Normal **MLH1, PMS2, MSH2 and MSH6 tested**	The tumour cells show normal nuclear staining for MLH1, PMS2, MSH2 and MSH6. There is no immunohistochemical evidence of mismatch repair deficiency. This is an MMR-proficient (MMRp) neoplasm which is expected to show microsatellite stability (MSS). **Action required: None, but referral to clinical genetics services should still be considered if there is a strong family or personal history.**	No action, unless there is a strong family or personal history of cancer
Normal **Only MSH6 and PMS2 tested**	The tumour cells show normal nuclear staining for PMS2 and MSH6. There is no immunohistochemical evidence of mismatch repair deficiency. This is an MMR-proficient (MMRp) neoplasm which is expected to show microsatellite stability (MSS). **Action required: None, but referral to clinical genetics services should still be considered if there is a strong family or personal history.**	No action, unless there is a strong family or personal history of cancer
Abnormal **MLH1 and PMS2 loss** ***MLH1* promoter methylation pending**	The tumour cells show loss of expression of the mismatch repair proteins MLH1 and PMS2 (with normal nuclear staining for MSH2 and MSH6). There is immunohistochemical evidence of mismatch repair deficiency. This is an MMR-deficient (MMRd) neoplasm which is expected to show microsatellite instability (MSI). *MLH1* promoter methylation and *POLE* variant testing are in progress. This pattern of mismatch repair deficiency may be either sporadic or due to Lynch or related syndromes – the result of testing for *MLH1* promoter methylation will provide further information. **Action required: Await the results of *MLH1* promoter methylation testing.**	*MLH1* promoter methylation testing Ensure *POLE* variant testing is underway

MMR IHC and *MLH1* promoter methylation result	Recommended report text	Recommended actions
Abnormal **MSH2 and MSH6 loss**	The tumour cells show loss of expression of the mismatch repair proteins MSH2 and MSH6 (with normal nuclear staining for MLH1 and PMS2). There is immunohistochemical evidence of mismatch repair deficiency. This is an MMR-deficient (MMRd) neoplasm which is expected to show microsatellite instability (MSI). *POLE* variant testing is in progress. Although not diagnostic, this pattern of mismatch repair deficiency is associated with Lynch and related syndromes. **Action required: This patient should be referred to clinical genetics services or undergo germline testing through mainstreaming.**	Germline testing for Lynch syndrome, either by referral to clinical genetics services or through mainstreaming Ensure *POLE* variant testing is underway
Abnormal **MSH6 loss**	The tumour cells show loss of expression of the mismatch repair protein MSH6 (with normal nuclear staining for MLH1, MSH2 and PMS2). There is immunohistochemical evidence of mismatch repair deficiency. This is an MMR-deficient (MMRd) neoplasm which is expected to show microsatellite instability (MSI). *POLE* variant testing is in progress. Although not diagnostic, this pattern of mismatch repair deficiency is associated with Lynch and related syndromes. **Action required: This patient should be referred to clinical genetics services or undergo germline testing through mainstreaming.**	Germline testing for Lynch syndrome, either by referral to clinical genetics services or through mainstreaming Ensure *POLE* variant testing is underway
Abnormal **PMS2 loss**	The tumour cells show loss of expression of the mismatch repair protein PMS2 (with normal nuclear staining for MLH1, MSH2 and MSH6). There is immunohistochemical evidence of mismatch repair deficiency. This is an MMR-deficient (MMRd) neoplasm which is expected to show microsatellite instability (MSI). *POLE* variant testing is in progress. Although not diagnostic, this pattern of mismatch repair deficiency is associated with Lynch and related syndromes. **Action required: This patient should be referred to clinical genetics services or undergo germline testing through mainstreaming.**	Germline testing for Lynch syndrome, either by referral to clinical genetics services or through mainstreaming Ensure *POLE* variant testing is underway

MMR IHC and *MLH1* promoter methylation result	**Recommended report text**	**Recommended actions**
***MLH1* promoter hypermethylation absent**	*MLH1* promoter hypermethylation has not been detected. While this mismatch repair deficiency could be sporadic, this finding raises the possibility that it is due to Lynch or related syndromes. **Action required: This patient should be referred to clinical genetics services or undergo germline testing through mainstreaming.**	Germline testing for Lynch syndrome, either by referral to clinical genetics services or through mainstreaming
***MLH1* promoter hypermethylation present**	*MLH1* promoter hypermethylation has been detected. This finding indicates that the mismatch repair deficiency is likely sporadic rather than due to Lynch or related syndromes. **Action required: None, but referral to clinical genetics services should still be considered if there is a strong family or personal history.**	No action, unless there is a strong family or personal history of cancer
Abnormal **MLH1 and PMS2 loss** ***MLH1* promoter methylation not tested**	The tumour cells show loss of expression of the mismatch repair proteins MLH1 and PMS2 (with normal nuclear staining for MSH2 and MSH6). There is immunohistochemical evidence of mismatch repair deficiency. This is an MMR-deficient (MMRd) neoplasm which is expected to show microsatellite instability (MSI). *MLH1* promoter methylation has not been tested. This pattern of mismatch repair deficiency may be either sporadic or due to Lynch or related syndromes. **Action required: Testing for *MLH1* promoter methylation is recommended. If this is not performed, the patient should be referred to clinical genetics services or undergo germline testing through mainstreaming.**	*MLH1* promoter methylation testing Ensure *POLE* variant testing is underway

MMR IHC and *MLH1* promoter methylation result	**Recommended report text**	**Recommended actions**
Abnormal **Subclonal loss of MLH1 and PMS2**	The tumour cells show subclonal loss of expression of the mismatch repair proteins MLH1 and PMS2 (with normal nuclear staining for MSH2 and MSH6). There is immunohistochemical evidence of mismatch repair deficiency, but it is subclonal rather than being present in the entire tumour. *MLH1* promoter methylation and *POLE* variant testing are in progress. This pattern of mismatch repair deficiency is likely to be sporadic, but it is possible that it is due to Lynch or related syndromes. The significance of this finding in terms of eligibility for immune checkpoint inhibitor therapy is not fully established. **Action required: Await the results of *MLH1* promoter methylation testing.**	*MLH1* promoter methylation testing Ensure *POLE* variant testing is underway
Abnormal **MLH1 and PMS2 loss with subclonal loss of MSH6**	The tumour cells show loss of expression of the mismatch repair proteins MLH1 and PMS2. There is also subclonal loss of expression of MSH6. There is normal nuclear staining for MSH2. There is immunohistochemical evidence of mismatch repair deficiency. This is an MMR-deficient (MMRd) neoplasm which is expected to show microsatellite instability (MSI). *MLH1* promoter methylation and *POLE* variant testing are in progress. This pattern of mismatch repair deficiency is likely to be sporadic, but it is possible that it is due to Lynch or related syndromes. **Action required: Await the results of *MLH1* promoter methylation testing, but this patient should be referred to clinical genetics services or undergo germline testing through mainstreaming.**	Germline testing for Lynch syndrome, either by referral to clinical genetics services or through mainstreaming *MLH1* promoter methylation testing Ensure *POLE* variant testing is underway

MMR IHC and *MLH1* promoter methylation result	Recommended report text	Recommended actions
Abnormal **Subclonal loss of MSH6**	The tumour cells show subclonal loss of expression of the mismatch repair protein MSH6 (with normal nuclear staining for MLH1, MSH2 and PMS2). There is immunohistochemical evidence of mismatch repair deficiency, but it is subclonal rather than being present in the entire tumour. *POLE* variant testing is in progress. This finding raises the possibility of Lynch and related syndromes, although its significance is not fully established. The significance of this finding in terms of eligibility for immune checkpoint inhibitor therapy is not fully established. **Action required: This patient should be referred to clinical genetics services or undergo germline testing through mainstreaming.**	Germline testing for Lynch syndrome, either by referral to clinical genetics services or through mainstreaming Ensure *POLE* variant testing is underway

Broader issues in mismatch repair testing

Which sample should I use for mismatch repair immunohistochemistry?

MMR IHC should be performed on well-fixed tissue containing viable invasive tumour and same-section internal positive controls. In EC, diagnostic biopsy or curettage material is generally preferred when adequate, because fixation is often better, interpretation is usually easier, and the result is available earlier for LS triage, molecular classification and clinical management. Paired-sample studies show high concordance between biopsy/curettage and hysterectomy specimens (78, 79).

If the biopsy or curettage is scanty, poorly fixed, necrotic or lacks valid internal controls, a better-fixed hysterectomy or resection block should be used.

MMR status is usually concordant between primary and recurrent/metastatic EC. Concordance has generally been reported at 92-93%, with most discordances showing subclonal MMRd patterns (especially involving MLH1) in the primary tumour. Routine repeat testing on the metastasis is not required when the primary tumour shows a clear, clonal result. Repeat testing of recurrent or metastatic disease should be considered when the primary tumour showed subclonal or heterogeneous MMR loss, since metastatic disease may have originated from either the MMRp or MMRd subclones in the primary. Repeat testing may also be considered when the tested block did not represent all relevant tumour components, when the primary result was equivocal or failed, or when the result will influence eligibility for immune checkpoint inhibitor therapy (72, 80-82).

Can mismatch repair immunohistochemistry be performed on atypical hyperplasia/endometrial intraepithelial neoplasia?

If EC is present, MMR IHC should be performed on the carcinoma rather than on atypical hyperplasia/endometrial intraepithelial neoplasia (AH/EIN). AH/EIN and associated carcinoma often show concordant MMR expression, particularly in LS-associated cases, but discordant results occur, especially in some tumours with *MLH1* promoter hypermethylation or heterogeneous/subclonal MMRd (83, 84).

Undertaking MMR IHC on samples containing only AH/EIN is not recommended. If testing is undertaken on such a sample, however, the result should be reported with caution. In particular, retained MMR expression in AH/EIN does not exclude the possibility of MMR deficiency in a subsequent or unsampled carcinoma.

For AH/EIN without coexisting carcinoma, there is no established role for routine MMR IHC as LS screening, because reported detection rates for MMRd and LS are low. Testing may be considered in selected patients with strong clinical or family history, very young age, or in fertility-sparing/conservative treatment contexts, where MMRd may have predictive significance (85-87).

Should I use two- or four-stain mismatch repair immunohistochemistry?

This approach is based on the heterodimer biology of the MMR proteins: MLH1 loss is usually accompanied by PMS2 loss, and MSH2 loss by MSH6 loss, while isolated PMS2 or MSH6 loss is also captured by the initial screen. Its advantages are reduced slide numbers, tissue use, cost and reporting time.

A meta-analysis estimated that at least 98.9% of MMRd cases would be detected by a PMS2/MSH6-first algorithm, but rare isolated MLH1 or MSH2 loss patterns have been reported (88, 89).

Reflex MLH1 and/or MSH2 staining should be performed when PMS2 and/or MSH6 is lost, weak, subclonal, equivocal or uninterpretable. A full four-antibody panel should also be used for unusual staining patterns, poor internal controls, discordant clinical/molecular findings, or when there is strong clinical concern despite an apparently normal two-stain result.

I have a case of MLH1 loss or combined MLH1 and PMS2 loss: do I need to do *BRAF* variant testing?

No. *BRAF* variant testing does not have a role in the routine work-up of MLH1/PMS2-deficient EC.

In colorectal carcinoma, BRAF V600E is strongly associated with sporadic *MLH1* promoter hypermethylation and can be used in LS triage pathways. This association is tumour-type specific. *BRAF* variants are rare in EC and should not be used as a substitute for *MLH1* promoter methylation testing. Cases with MLH1 loss or combined MLH1/PMS2 loss should undergo *MLH1* promoter methylation testing (90).

Does *MLH1* promoter hypermethylation completely exclude Lynch syndrome?

No, but it usually strongly supports a sporadic cause of MMR deficiency. In most ECs with MLH1/PMS2 loss, detection of tumour *MLH1* promoter hypermethylation indicates sporadic epigenetic silencing of *MLH1*, and germline testing is not routinely required in the absence of additional clinical concern.

However, *MLH1* promoter hypermethylation does not absolutely exclude LS or related constitutional mechanisms. Rare patients with constitutional *MLH1* promoter hypermethylation/epimutation, and rare LS-associated tumours with *MLH1* promoter hypermethylation, have been described. Referral to clinical genetics should still be considered where there is young age at diagnosis, multiple LS-spectrum tumours, a strong family history, unusual clinical features, or MMRd non-neoplastic glands (91, 92).

What does loss of expression in non-neoplastic endometrial glands mean?

MMR-deficient non-neoplastic endometrial glands are benign-appearing isolated or clustered glands showing loss of one or more MMR proteins, with appropriate retained staining in surrounding internal control cells. This finding has been reported in 47-70% of patients with LS, and the pattern of loss usually matches the germline MMR gene involved (93-96).

This finding may be a useful clue to underlying LS, particularly when seen adjacent to an MMRd tumour. This phenomenon has not been described in endometrial samples from patients without LS, aside from a case of EC with double somatic variants in *MLH1* (95). It should not, however, be treated as diagnostic in isolation. Technical artefact, poor fixation and tangential or scanty glandular staining should be excluded before reporting it.

There is currently no consensus on reporting of the presence or absence of MMRd non-neoplastic glands in every case. If the finding is convincing, it is reasonable to mention it in the report, particularly if it supports referral to clinical genetics or explains concern despite otherwise equivocal findings.

How should I report MMR IHC on cytology cell blocks without valid internal controls? Can I rely on external tissue control alone?

MMR IHC can be attempted on cytology cell blocks, but interpretation is more challenging than in biopsy or resection material. Jacobi et al. (97) demonstrated high concordance of 85% in MMR status between cytology and surgical specimens for colorectal cancer and EC, but also highlighted interpretation challenges which might contribute to an inconclusive result: limited numbers of tumour cells, focal staining in cells which are indefinite for tumour, tumour staining heterogeneity, and lack of internal control staining (97).

Same-section internal positive controls are essential for definitive interpretation. An external control confirms that the staining run has worked, but it does not confirm antigen preservation in the cell block being assessed. If tumour cells are negative and there are no valid internal positive controls, the result should be reported as uninterpretable or inconclusive rather than as loss of expression, even if the external control tissue has stained appropriately. Other scenarios that may warrant a diagnosis of inconclusive MMR status include cell block sections with very low tumour cell content, those with difficulty distinguishing between tumour and non-tumour cells, or those displaying focal and faint nuclear staining in few tumour cells.

If tumour cells show convincing diffuse nuclear staining but there are no internal positive controls, the report may state that the staining pattern favours retained expression, but that definitive interpretation is limited by the absence of internal controls. Repeat testing on a biopsy or surgical specimen should be recommended if available.

Should an endometrial carcinoma with subclonal MMR deficiency be considered MMRp or MMRd from the perspective of systemic therapy?

An EC with convincing subclonal loss of one or more MMR proteins should not be classified simply as MMR-proficient. It should be reported as an abnormal result, using terminology such as ‘MMRd with subclonal loss’ or ‘subclonal MMR deficiency’, specifying the protein(s) lost and the approximate extent of the abnormal subclone (42, 69-72, 98).

From the perspective of systemic therapy, this is best regarded as an abnormal/subclonal MMR result, rather than straightforward MMRp. However, the predictive significance of subclonal MMRd for immune checkpoint inhibitor therapy is not fully established, and these cases were not specifically addressed as a distinct predictive subgroup in the major clinical trials. The clinically relevant question is whether the tumour population requiring treatment, particularly recurrent or metastatic disease, is MMRd (5, 71, 72, 98).

A recurrence or metastasis may arise from either the MMRd or MMRp component of a subclonal primary tumour. Therefore, if immune checkpoint inhibitor therapy is being considered and suitable recurrent or metastatic tissue is available, repeat MMR IHC on that tissue should be considered (80-82).

If additional molecular testing is undertaken, the area showing MMR protein loss should be macrodissected where feasible. This is particularly important for small subclones, because testing a whole section may dilute an MSI or *MLH1* promoter hypermethylation signal arising from the MMRd component (5, 42, 69, 71, 72, 98).

If the recurrent or metastatic tumour shows clonal MMR loss, it can be regarded as MMRd for systemic therapy purposes. If recurrent or metastatic disease is MMRp despite subclonal MMR loss in

the primary tumour, the case should be discussed in an MDT setting, because treatment eligibility and expected benefit may depend on local criteria, trial protocol, treatment regimen and the full molecular context (5, 72).

How should I report mismatch repair immunohistochemistry in mixed endometrial carcinomas?

Most mixed ECs show concordant MMR expression between tumour components, but discordant patterns can occur. Care should be taken not to mistake fixation artefact, sampling differences or subclonal loss for true component-specific discordance (22, 69, 99).

When different components show different MMR expression patterns, the report should describe the result for each component where possible. If any bona fide malignant component shows convincing loss of MMR protein expression with valid internal controls, the tumour should be regarded as MMRd overall for LS screening and molecular classification purposes, while the heterogeneity should be clearly stated.

For immune checkpoint inhibitor eligibility, repeat testing on recurrent or metastatic disease may be helpful if the primary tumour is mixed, subclonal or heterogeneous and suitable metastatic tissue is available.

How do *POLE* results affect interpretation of mismatch repair immunohistochemistry?

POLE variant status does not change the interpretation or reporting of MMR IHC. A pathogenic *POLE* exonuclease domain variant can coexist with MMR deficiency, and has been reported in 4.7-9.2% of MMRd EC. Most such tumours appear to have sporadic MMR deficiency, although rare cases associated with LS have been reported (7, 100).

MMR IHC should therefore be reported in the usual way, and LS triage should proceed according to the MMR IHC pattern and *MLH1* promoter methylation result, irrespective of POLE status. For prognostic molecular classification, tumours with both pathogenic *POLE* variant and MMR deficiency should be handled according to the local multiple-classifier algorithm; in most EC classifiers, *POLE*-mutated status has prognostic precedence, but this does not remove the genetic implications of abnormal MMR IHC.

When should I suspect constitutional mismatch repair deficiency?

Constitutional mismatch repair deficiency (CMMRD) is rare and is caused by biallelic pathogenic variants affecting an MMR gene. It usually presents with childhood or adolescent malignancies, particularly haematological, brain and gastrointestinal tumours, but rare adult presentations, including with EC, have been described (101, 102).

A possible clue is apparent loss of an MMR protein in both tumour cells and normal cells, producing a pattern that may resemble a failed stain because there are no internal positive controls for that protein. Before suggesting CMMRD, technical failure, poor fixation and staining error must be excluded. Preserved internal control staining for the other MMR proteins and the clinical history may help.

Preserved nuclear staining does not completely exclude CMMRD, particularly with some hypomorphic or missense variants. If CMMRD is suspected, the report should describe the staining pattern, state that the result is not conventionally interpretable for the affected protein, and recommend clinical

genetics referral. MSI testing, tumour sequencing, tumour mutational burden assessment and germline testing may be useful depending on local pathways (101-103).

Are isolated MSH2 loss or isolated MLH1 loss possible? Would a PMS2/MSH6 two-stain screen miss these cases?

Yes, rare cases with isolated MSH2 loss, isolated MLH1 loss, combined loss of MSH2 and MLH1, and other unusual combinations have been reported. A meta-analysis estimated that such unexpected patterns account for approximately 1.1% of reported cases and are more common in gastrointestinal than gynaecological tumours (88, 104).

The biological basis is not always clear. Some cases may reflect technical or interpretative issues, antibody clone or epitope effects, fixation problems, treatment effects, benign germline polymorphisms affecting antibody binding, or unusual somatic or germline events (104, 105).

Despite this small risk, a validated PMS2/MSH6-first algorithm remains highly sensitive. If staining is weak, subclonal, unusual, discordant with morphology or molecular results, or if there is strong clinical concern, a full four-antibody panel and/or additional molecular/genetic investigation should be performed.

What should I do if *MLH1* promoter methylation, MSI testing or NGS fails because of low tumour content or limited tissue?

MMR IHC can often be interpreted in small samples if there is viable tumour and valid same-section internal control staining. Molecular tests are more vulnerable to low tumour cellularity, low DNA quantity, necrosis, poor fixation and sampling of the wrong tumour component.

For *MLH1* promoter methylation, MSI or NGS testing, the request should identify a tumour-rich, well-fixed block and, where possible, a marked area for macrodissection. For subclonal MLH1/PMS2 loss, the report or request should state that the loss is subclonal and estimate the percentage of tumour showing loss, because testing a whole section may dilute a methylation or MSI signal confined to a subclone.

If MLH1/PMS2 loss is present but *MLH1* promoter methylation testing fails or cannot be performed, the report should state that methylation status is unavailable rather than implying a sporadic cause. Repeat testing on another block or referral for germline/somatic testing should be considered according to local pathways and clinical context (24, 69, 71, 72).

Does normal MMR IHC exclude Lynch syndrome?

No. Normal MMR IHC is reassuring, but it is not a definitive germline test. MMR IHC is a tumour screening test and, like all screening tests, can produce false-negative and false-positive results. Clinical concern for LS or another familial cancer syndrome should therefore prompt clinical genetics referral or further investigation even when tumour MMR IHC is normal. Relevant factors include young age, multiple LS-associated tumours, a known familial pathogenic variant, or a strong personal/family history (50, 106).

References

1. Kunkel TA, Erie DA. Eukaryotic Mismatch Repair in Relation to DNA Replication. Annu Rev Genet. 2015;49:291-313.
2. Li GM. Mechanisms and functions of DNA mismatch repair. Cell Res. 2008;18(1):85-98.
3. Boland CR, Goel A. Microsatellite instability in colorectal cancer. Gastroenterology. 2010;138(6):2073-87 e3.

4. Guyot D'Asnieres De Salins A, Tachon G, Cohen R, Karayan-Tapon L, Junca A, Frouin E, et al. Discordance between immunochemistry of mismatch repair proteins and molecular testing of microsatellite instability in colorectal cancer. ESMO Open. 2021;6(3):100120.
5. Bartley AN, Mills AM, Konnick E, Overman M, Ventura CB, Souter L, et al. Mismatch Repair and Microsatellite Instability Testing for Immune Checkpoint Inhibitor Therapy: Guideline From the College of American Pathologists in Collaboration With the Association for Molecular Pathology and Fight Colorectal Cancer. Arch Pathol Lab Med. 2022;146(10):1194-210.
6. Ryan NAJ, Glaire MA, Blake D, Cabrera-Dandy M, Evans DG, Crosbie EJ. The proportion of endometrial cancers associated with Lynch syndrome: a systematic review of the literature and meta-analysis. Genet Med. 2019;21(10):2167-80.
7. Post CCB, Stelloo E, Smit V, Ruano D, Tops CM, Vermij L, et al. Prevalence and Prognosis of Lynch Syndrome and Sporadic Mismatch Repair Deficiency in Endometrial Cancer. J Natl Cancer Inst. 2021;113(9):1212-20.
8. Bartosch C, Clarke B, Bosse T. Gynaecological neoplasms in common familial syndromes (Lynch and HBOC). Pathology. 2018;50(2):222-37.
9. Dominguez-Valentin M, Sampson JR, Seppala TT, Ten Broeke SW, Plazzer JP, Nakken S, et al. Correction: Cancer risks by gene, age, and gender in 6350 carriers of pathogenic mismatch repair variants: findings from the Prospective Lynch Syndrome Database. Genet Med. 2020;22(9):1569.
10. Cancer Genome Atlas Research N, Kandoth C, Schultz N, Cherniack AD, Akbani R, Liu Y, et al. Integrated genomic characterization of endometrial carcinoma. Nature. 2013;497(7447):67-73.
11. Talhouk A, McConechy MK, Leung S, Li-Chang HH, Kwon JS, Melnyk N, et al. A clinically applicable molecular-based classification for endometrial cancers. Br J Cancer. 2015;113(2):299-310.
12. Talhouk A, McConechy MK, Leung S, Yang W, Lum A, Senz J, et al. Confirmation of ProMisE: A simple, genomics-based clinical classifier for endometrial cancer. Cancer. 2017;123(5):802-13.
13. Kommoss S, McConechy MK, Kommoss F, Leung S, Bunz A, Magrill J, et al. Final validation of the ProMisE molecular classifier for endometrial carcinoma in a large population-based case series. Ann Oncol. 2018;29(5):1180-8.
14. Le DT, Uram JN, Wang H, Bartlett BR, Kemberling H, Eyring AD, et al. PD-1 Blockade in Tumors with Mismatch-Repair Deficiency. N Engl J Med. 2015;372(26):2509-20.
15. Le DT, Durham JN, Smith KN, Wang H, Bartlett BR, Aulakh LK, et al. Mismatch repair deficiency predicts response of solid tumors to PD-1 blockade. Science. 2017;357(6349):409-13.
16. O'Malley DM, Bariani GM, Cassier PA, Marabelle A, Hansen AR, De Jesus Acosta A, et al. Pembrolizumab in Patients With Microsatellite Instability-High Advanced Endometrial Cancer: Results From the KEYNOTE-158 Study. J Clin Oncol. 2022;40(7):752-61.
17. Oaknin A, Gilbert L, Tinker AV, Brown J, Mathews C, Press J, et al. Safety and antitumor activity of dostarlimab in patients with advanced or recurrent DNA mismatch repair deficient/microsatellite instability-high (dMMR/MSI-H) or proficient/stable (MMRp/MSS) endometrial cancer: interim results from GARNET-a phase I, single-arm study. J Immunother Cancer. 2022;10(1).
18. Mirza MR, Chase DM, Slomovitz BM, dePont Christensen R, Novak Z, Black D, et al. Dostarlimab for Primary Advanced or Recurrent Endometrial Cancer. N Engl J Med. 2023;388(23):2145-58.
19. Eskander RN, Sill MW, Beffa L, Moore RG, Hope JM, Musa FB, et al. Pembrolizumab plus chemotherapy in advanced or recurrent endometrial cancer: overall survival and exploratory analyses of the NRG GY018 phase 3 randomized trial. Nat Med. 2025;31(5):1539-46.
20. Jumaah AS, Al-Haddad HS, Salem MM, McAllister KA, Yasseen AA. Mismatch repair deficiency and clinicopathological characteristics in endometrial carcinoma: a systematic review and meta-analysis. J Pathol Transl Med. 2021;55(3):202-11.
21. Capasso I, Perrone E, Duranti S, Giannarelli D, Nero C, Cordisco EL, et al. Are all mismatch repair deficient endometrial cancers created equal? A large, retrospective, tertiary center experience. Eur J Cancer. 2025;220:115344.
22. Haight PJ, Esnakula A, Riedinger CJ, Suarez AA, Gillespie J, Patton A, et al. Molecular characterization of mixed-histology endometrial carcinoma provides prognostic and therapeutic value over morphologic findings. NPJ Precis Oncol. 2025;9(1):41.
23. Addante F, d'Amati A, Santoro A, Angelico G, Inzani F, Arciuolo D, et al. Mismatch Repair Deficiency as a Predictive and Prognostic Biomarker in Endometrial Cancer: A Review on Immunohistochemistry Staining Patterns and Clinical Implications. Int J Mol Sci. 2024;25(2).
24. Kaya M, Post CCB, Tops CM, Nielsen M, Crosbie EJ, Leary A, et al. Molecular and Clinicopathologic Characterization of Mismatch Repair-Deficient Endometrial Carcinoma Not Related to MLH1 Promoter Hypermethylation. Mod Pathol. 2024;37(3):100423.

25. van den Berg MC, Berg HF, Stokowy T, Hoivik EA, Woie K, Engerud H, et al. Expression patterns of mismatch repair proteins in cervical cancer uncover independent prognostic value of MSH-2. Int J Gynecol Cancer. 2024;34(7):993-1000.
26. Wu YW, Wei LJ, Yang X, Liang HY, Cai MY, Luo RZ, et al. Clinicopathological and immune characterization of mismatch repair deficient endocervical adenocarcinoma. Oncologist. 2024;29(10):e1302-e14.
27. Nakamura K, Nakayama K, Minamoto T, Ishibashi T, Ohnishi K, Yamashita H, et al. Lynch Syndrome-Related Clear Cell Carcinoma of the Cervix: A Case Report. Int J Mol Sci. 2018;19(4).
28. Ordi O, Saco A, Penuelas N, Blanco-Irazuegui O, Pino MD, Carreras-Dieguez N, et al. Whole-Exome Sequencing of Vulvar Squamous Cell Carcinomas Reveals an Impaired Prognosis in Patients With TP53 Mutations and Concurrent CCND1 Gains. Mod Pathol. 2024;37(10):100574.
29. Kwasniewska A, Postawski K, Gozdzicka-Jozefiak A, Zdunek M, Korobowicz E, Miturski R. Immunohistochemical detection of hMLH1 and hMSH2 proteins in vulvar carcinoma. Int J Mol Med. 2005;15(6):955-61.
30. Hoang LN, Ali RH, Lau S, Gilks CB, Lee CH. Immunohistochemical survey of mismatch repair protein expression in uterine sarcomas and carcinosarcomas. Int J Gynecol Pathol. 2014;33(5):483-91.
31. Doyle LA, Nowak JA, Nathenson MJ, Thornton K, Wagner AJ, Johnson JM, et al. Characteristics of mismatch repair deficiency in sarcomas. Mod Pathol. 2019;32(7):977-87.
32. de Angelis de Carvalho N, Niitsuma BN, Kozak VN, Costa FD, de Macedo MP, Kupper BEC, et al. Clinical and Molecular Assessment of Patients with Lynch Syndrome and Sarcomas Underpinning the Association with MSH2 Germline Pathogenic Variants. Cancers (Basel). 2020;12(7).
33. Rambau PF, Duggan MA, Ghatage P, Warfa K, Steed H, Perrier R, et al. Significant frequency of MSH2/MSH6 abnormality in ovarian endometrioid carcinoma supports histotype-specific Lynch syndrome screening in ovarian carcinomas. Histopathology. 2016;69(2):288-97.
34. Leskela S, Romero I, Cristobal E, Perez-Mies B, Rosa-Rosa JM, Gutierrez-Pecharroman A, et al. Mismatch Repair Deficiency in Ovarian Carcinoma: Frequency, Causes, and Consequences. Am J Surg Pathol. 2020;44(5):649-56.
35. Crosbie EJ, Ryan NAJ, McVey RJ, Lalloo F, Bowers N, Green K, et al. Assessment of mismatch repair deficiency in ovarian cancer. J Med Genet. 2021;58(10):687-91.
36. Atwal A, Snowsill T, Dandy MC, Krum T, Newton C, Evans DG, et al. The prevalence of mismatch repair deficiency in ovarian cancer: A systematic review and meta-analysis. Int J Cancer. 2022;151(9):1626-39.
37. Mitric C, Salman L, Abrahamyan L, Kim SR, Pechlivanoglou P, Chan KKW, et al. Mismatch-repair deficiency, microsatellite instability, and lynch syndrome in ovarian cancer: A systematic review and meta-analysis. Gynecol Oncol. 2023;170:133-42.
38. Tessier-Cloutier B, Kommoss FKF, Kolin DL, Nemejcova K, Smith D, Pors J, et al. Dedifferentiated and Undifferentiated Ovarian Carcinoma: An Aggressive and Molecularly Distinct Ovarian Tumor Characterized by Frequent SWI/SNF Complex Inactivation. Mod Pathol. 2024;37(1):100374.
39. Vierkoetter KR, Ayabe AR, VanDrunen M, Ahn HJ, Shimizu DM, Terada KY. Lynch Syndrome in patients with clear cell and endometrioid cancers of the ovary. Gynecol Oncol. 2014;135(1):81-4.
40. Bennett JA, Pesci A, Morales-Oyarvide V, Da Silva A, Nardi V, Oliva E. Incidence of Mismatch Repair Protein Deficiency and Associated Clinicopathologic Features in a Cohort of 104 Ovarian Endometrioid Carcinomas. Am J Surg Pathol. 2019;43(2):235-43.
41. Kim SR, Oldfield L, Tone A, Pollett A, Pedersen S, Wellum J, et al. Comprehensive molecular assessment of mismatch repair deficiency in Lynch associated ovarian cancers using next generation sequencing panel. Int J Gynecol Cancer. 2024;34(2):267-76.
42. Stelloo E, Jansen AML, Osse EM, Nout RA, Creutzberg CL, Ruano D, et al. Practical guidance for mismatch repair-deficiency testing in endometrial cancer. Ann Oncol. 2017;28(1):96-102.
43. Smithgall MC, Remotti H, Hsiao SJ, Mansukhani M, Liu-Jarin X, Fernandes H. Investigation of discrepant mismatch repair immunohistochemistry and microsatellite instability polymerase chain reaction test results for gynecologic cancers using next-generation sequencing. Hum Pathol. 2022;119:41-50.
44. Wu X, Snir O, Rottmann D, Wong S, Buza N, Hui P. Minimal microsatellite shift in microsatellite instability high endometrial cancer: a significant pitfall in diagnostic interpretation. Mod Pathol. 2019;32(5):650-8.
45. van der Werf-'t Lam AS, Terlouw D, Tops CM, van Kan MS, van Hest LP, Gille HJP, et al. Discordant Staining Patterns and Microsatellite Results in Tumors of MSH6 Pathogenic Variant Carriers. Mod Pathol. 2023;36(9):100240.

46. Sowter P, Gallon R, Hayes C, Phelps R, Borthwick G, Prior S, et al. Detection of Mismatch Repair Deficiency in Endometrial Cancer: Assessment of IHC, Fragment Length Analysis, and Amplicon Sequencing Based MSI Testing. Cancers (Basel). 2024;16(23).
47. Ali-Fehmi R, Krause HB, Morris RT, Wallbillich JJ, Corey L, Bandyopadhyay S, et al. Analysis of Concordance Between Next-Generation Sequencing Assessment of Microsatellite Instability and Immunohistochemistry-Mismatch Repair From Solid Tumors. JCO Precis Oncol. 2024;8:e2300648.
48. Kang N, Zhang X, Wang Z, Dai Y, Lu S, Su W, et al. Validation of a one-step genomics-based molecular classifier for endometrial carcinoma in a large Chinese population. Pathol Res Pract. 2024;254:155152.
49. Nero C, Salvatore L, Duranti S, Anderson G, Mastrantoni L, Karimi M, et al. Concordance Analysis of Microsatellite Instability via NGS and Mismatch Repair Deficiency via IHC in Endometrial and Colorectal Cancer. Target Oncol. 2026;21(2):285-97.
50. Ryan NAJ, McMahon R, Tobi S, Snowsill T, Esquibel S, Wallace AJ, et al. The proportion of endometrial tumours associated with Lynch syndrome (PETALS): A prospective cross-sectional study. PLoS Med. 2020;17(9):e1003263.
51. Testing strategies for Lynch syndrome in people with endometrial cancer. London; 2020 28 October 2020. Report No.: HTG557.
52. Concin N, Matias-Guiu X, Cibula D, Colombo N, Creutzberg CL, Ledermann J, et al. ESGO-ESTRO-ESP guidelines for the management of patients with endometrial carcinoma: update 2025. Lancet Oncol. 2025;26(8):e423-e35.
53. Berek JS, Matias-Guiu X, Creutzberg C, Fotopoulou C, Gaffney D, Kehoe S, et al. FIGO staging of endometrial cancer: 2023. J Gynecol Oncol. 2023;34(5):e85.
54. Leon-Castillo A, de Boer SM, Powell ME, Mileshkin LR, Mackay HJ, Leary A, et al. Molecular Classification of the PORTEC-3 Trial for High-Risk Endometrial Cancer: Impact on Prognosis and Benefit From Adjuvant Therapy. J Clin Oncol. 2020;38(29):3388-97.
55. Horeweg N, Nout RA, Jurgenliemk-Schulz IM, Lutgens L, Jobsen JJ, Haverkort MAD, et al. Molecular Classification Predicts Response to Radiotherapy in the Randomized PORTEC-1 and PORTEC-2 Trials for Early-Stage Endometrioid Endometrial Cancer. J Clin Oncol. 2023;41(27):4369-80.
56. Crosbie EJ, Ryan NAJ, Arends MJ, Bosse T, Burn J, Cornes JM, et al. The Manchester International Consensus Group recommendations for the management of gynecological cancers in Lynch syndrome. Genet Med. 2019;21(10):2390-400.
57. McMeekin DS, Tritchler DL, Cohn DE, Mutch DG, Lankes HA, Geller MA, et al. Clinicopathologic Significance of Mismatch Repair Defects in Endometrial Cancer: An NRG Oncology/Gynecologic Oncology Group Study. J Clin Oncol. 2016;34(25):3062-8.
58. Chung YS, Woo HY, Lee JY, Park E, Nam EJ, Kim S, et al. Mismatch repair status influences response to fertility-sparing treatment of endometrial cancer. Am J Obstet Gynecol. 2021;224(4):370 e1- e13.
59. National Institute for Health and Care Excellence. Dostarlimab with platinum-based chemotherapy for treating primary advanced or recurrent endometrial cancer with high microsatellite instability or mismatch repair deficiency. London: National Institute for Health and Care Excellence; 2025 22 May 2025. Report No.: TA1064.
60. National Institute for Health and Care Excellence. Dostarlimab for previously treated advanced or recurrent endometrial cancer with high microsatellite instability or mismatch repair deficiency. London: National Institute for Health and Care Excellence; 2022 16 March 2022. Report No.: TA779.
61. National Institute for Health and Care Excellence. Pembrolizumab for previously treated endometrial, biliary, colorectal, gastric or small intestine cancer with high microsatellite instability or mismatch repair deficiency. London: National Institute for Health and Care Excellence; 2023 20 September 2023. Report No.: TA914.
62. National Institute for Health and Care Excellence. Dostarlimab with platinum-containing chemotherapy for treating primary advanced or recurrent endometrial cancer with microsatellite stability or mismatch repair proficiency. London: National Institute for Health and Care Excellence; 2025 16 December 2025. Report No.: TA1117.
63. National Institute for Health and Care Excellence. Pembrolizumab with carboplatin and paclitaxel for untreated primary advanced or recurrent endometrial cancer. London: National Institute for Health and Care Excellence; 2025 27 August 2025. Report No.: TA1092.
64. National Institute for Health and Care Excellence. Pembrolizumab with lenvatinib for previously treated advanced or recurrent endometrial cancer. London: National Institute for Health and Care Excellence; 2023 21 June 2023. Report No.: TA904.

65. Vroobel K, Wong J, Arora R. Dataset for histopathological reporting of carcinomas and borderline tumours of the ovaries, fallopian tubes and peritoneum. Clinical guideline; dataset. London: The Royal College of Pathologists; 2026 3 June 2026. Contract No.: G079.
66. Evrard C, Tachon G, Randrian V, Karayan-Tapon L, Tougeron D. Microsatellite Instability: Diagnosis, Heterogeneity, Discordance, and Clinical Impact in Colorectal Cancer. Cancers (Basel). 2019;11(10).
67. Graham RP, Kerr SE, Butz ML, Thibodeau SN, Halling KC, Smyrk TC, et al. Heterogenous MSH6 loss is a result of microsatellite instability within MSH6 and occurs in sporadic and hereditary colorectal and endometrial carcinomas. Am J Surg Pathol. 2015;39(10):1370-6.
68. Pai RK, Plesec TP, Abdul-Karim FW, Yang B, Marquard J, Shadrach B, et al. Abrupt loss of MLH1 and PMS2 expression in endometrial carcinoma: molecular and morphologic analysis of 6 cases. Am J Surg Pathol. 2015;39(7):993-9.
69. Watkins JC, Nucci MR, Ritterhouse LL, Howitt BE, Sholl LM. Unusual Mismatch Repair Immunohistochemical Patterns in Endometrial Carcinoma. Am J Surg Pathol. 2016;40(7):909-16.
70. Scheiderer A, Riedinger C, Kimball K, Kilgore L, Orucevic A. Reporting Subclonal Immunohistochemical Staining of Mismatch Repair Proteins in Endometrial Carcinoma in the Times of Ever-Changing Guidelines. Arch Pathol Lab Med. 2022;146(9):1114-21.
71. Mendoza RP, Wang P, Schulte JJ, Tjota MY, Jani I, Martinez AC, et al. Endometrial Carcinomas With Subclonal Loss of Mismatch Repair Proteins: A Clinicopathologic and Genomic Study. Am J Surg Pathol. 2023;47(5):589-98.
72. Riedinger CJ, Esnakula A, Haight PJ, Suarez AA, Chen W, Gillespie J, et al. Characterization of mismatch-repair/microsatellite instability-discordant endometrial cancers. Cancer. 2024;130(3):385-99.
73. Niu BT, Hammond RFL, Leen SLS, Faruqi AZ, Trevisan G, Gilks CB, et al. Artefactual punctate MLH1 staining can lead to erroneous reporting of isolated PMS2 loss. Histopathology. 2018;73(4):703-5.
74. Zhang Q, Young GQ, Yang Z. Pure Discrete Punctate Nuclear Staining Pattern for MLH1 Protein Does Not Represent Intact Nuclear Expression. Int J Surg Pathol. 2020;28(2):146-52.
75. Loughrey MB, Dunne PD, Coleman HG, McQuaid S, James JA. Punctate MLH1 mismatch repair immunostaining in colorectal cancer. Histopathology. 2019;74(5):795-7.
76. Morak M, Kasbauer S, Kerscher M, Laner A, Nissen AM, Benet-Pages A, et al. Loss of MSH2 and MSH6 due to heterozygous germline defects in MSH3 and MSH6. Fam Cancer. 2017;16(4):491-500.
77. Stinton C, Fraser H, Al-Khudairy L, Court R, Jordan M, Grammatopoulos D, et al. Testing for lynch syndrome in people with endometrial cancer using immunohistochemistry and microsatellite instability-based testing strategies - A systematic review of test accuracy. Gynecol Oncol. 2021;160(1):148-60.
78. Chapel DB, Yamada SD, Cowan M, Lastra RR. Immunohistochemistry for mismatch repair protein deficiency in endometrioid endometrial carcinoma yields equivalent results when performed on endometrial biopsy/curettage or hysterectomy specimens. Gynecol Oncol. 2018;149(3):570-4.
79. Berg HF, Engerud H, Myrvold M, Lien HE, Hjelmeland ME, Halle MK, et al. Mismatch repair markers in preoperative and operative endometrial cancer samples; expression concordance and prognostic value. Br J Cancer. 2023;128(4):647-55.
80. Ta RM, Hecht JL, Lin DI. Discordant loss of mismatch repair proteins in advanced endometrial endometrioid carcinoma compared to paired primary uterine tumors. Gynecol Oncol. 2018;151(3):401-6.
81. Aird JJ, Steel MJ, Chow C, Ho J, Wolber R, Gilks CB, et al. Should you repeat mismatch repair testing in cases of tumour recurrence? An evaluation of repeat mismatch repair testing by the use of immunohistochemistry in recurrent tumours of the gastrointestinal and gynaecological tracts. Histopathology. 2020;76(4):521-30.
82. Chapel DB, Lengyel E, Ritterhouse LL, Lastra RR. Interpretation of Mismatch Repair Protein Immunohistochemistry in Endometrial Carcinoma Should Consider Both Lynch Syndrome Screening and Immunotherapy Susceptibility: An Illustrative Case Report. Int J Gynecol Pathol. 2020;39(3):233-7.
83. Lucas E, Chen H, Molberg K, Castrillon DH, Rivera Colon G, Li L, et al. Mismatch Repair Protein Expression in Endometrioid Intraepithelial Neoplasia/Atypical Hyperplasia: Should We Screen for Lynch Syndrome in Precancerous Lesions? Int J Gynecol Pathol. 2019;38(6):533-42.
84. Chapel DB, Patil SA, Plagov A, Puranik R, Mendybaeva A, Steinhardt G, et al. Quantitative next-generation sequencing-based analysis indicates progressive accumulation of microsatellite

instability between atypical hyperplasia/endometrial intraepithelial neoplasia and paired endometrioid endometrial carcinoma. Mod Pathol. 2019;32(10):1508-20.
85. Vierkoetter KR, Kagami LA, Ahn HJ, Shimizu DM, Terada KY. Loss of Mismatch Repair Protein Expression in Unselected Endometrial Adenocarcinoma Precursor Lesions. Int J Gynecol Cancer. 2016;26(2):228-32.
86. Raffone A, Catena U, Travaglino A, Masciullo V, Spadola S, Della Corte L, et al. Mismatch repair-deficiency specifically predicts recurrence of atypical endometrial hyperplasia and early endometrial carcinoma after conservative treatment: A multi-center study. Gynecol Oncol. 2021;161(3):795-801.
87. Kennedy K, Gaertner-Otto J, Lim E. Rates of dMMR status in endometrial hyperplasia in comparison to MMR related Lynch Syndrome of endometrial cancer: a pilot study. European Journal of Gynaecological Oncology. 2025;46(3):56-61.
88. Aiyer KTS, Doeleman T, Ryan NA, Nielsen M, Crosbie EJ, Smit V, et al. Validity of a two-antibody testing algorithm for mismatch repair deficiency testing in cancer; a systematic literature review and meta-analysis. Mod Pathol. 2022;35(12):1775-83.
89. Niu BT, Hammond RFL, Leen SLS, Gilks CB, Singh N. Two versus four immunostains for Lynch syndrome screening in endometrial carcinoma. Histopathology. 2019;75(3):442-5.
90. Metcalf AM, Spurdle AB. Endometrial tumour BRAF mutations and MLH1 promoter methylation as predictors of germline mismatch repair gene mutation status: a literature review. Fam Cancer. 2014;13(1):1-12.
91. Hitchins MP, Alvarez R, Zhou L, Aguirre F, Damaso E, Pineda M, et al. MLH1-methylated endometrial cancer under 60 years of age as the "sentinel" cancer in female carriers of high-risk constitutional MLH1 epimutation. Gynecol Oncol. 2023;171:129-40.
92. Cazzaniga L, Zanzottera C, Mannucci S, Fava F, Marabelli M, Calvello M, et al. MLH1 promoter hypermethylation and Lynch Syndrome: When to test for constitutional epimutations of MLH1 gene? Tumori. 2025:3008916241312530.
93. Wong S, Hui P, Buza N. Frequent loss of mutation-specific mismatch repair protein expression in nonneoplastic endometrium of Lynch syndrome patients. Mod Pathol. 2020;33(6):1172-81.
94. Hegazy S, Brand RE, Dudley B, Karloski E, Bhargava R, Elishaev E, et al. DNA mismatch repair-deficient non-neoplastic endometrial glands are common in Lynch syndrome patients and are present at a higher density than in the colon. Histopathology. 2021;79(4):573-83.
95. Freitag CE, Chen W, Pearlman R, Hampel H, Stanich PP, Cosgrove CM, et al. Mismatch repair protein status of non-neoplastic uterine and intestinal mucosa in patients with Lynch syndrome and double somatic mismatch repair protein mutations. Hum Pathol. 2023;137:1-9.
96. Hegazy S, Brand RE, Dudley B, Karloski E, Lesnock JL, Elishaev E, et al. Mutation-specific Mismatch Repair-deficient Benign Endometrial Glands in Endometrial Biopsies and Curettings Are a Biomarker of Lynch Syndrome and Associate With Endometrial Carcinoma Development. Am J Surg Pathol. 2023;47(7):835-43.
97. Jacobi EM, Landon G, Broaddus RR, Roy-Chowdhuri S. Evaluating Mismatch Repair/Microsatellite Instability Status Using Cytology Effusion Specimens to Determine Eligibility for Immunotherapy. Arch Pathol Lab Med. 2021;145(1):46-54.
98. Bovolim G, Silva SO, Goncalves BT, Torrezan G, Costa A, De Brot M, et al. Subclonal loss of DNA mismatch repair proteins in endometrial carcinomas: an unusual pattern with distinct molecular characteristics. Int J Gynecol Cancer. 2025;35(8):101951.
99. Kobel M, Meng B, Hoang LN, Almadani N, Li X, Soslow RA, et al. Molecular Analysis of Mixed Endometrial Carcinomas Shows Clonality in Most Cases. Am J Surg Pathol. 2016;40(2):166-80.
100. Moufarrij S, Gazzo A, Rana S, Selenica P, Abu-Rustum NR, Ellenson LH, et al. Concurrent POLE hotspot mutations and mismatch repair deficiency/microsatellite instability in endometrial cancer: A challenge in molecular classification. Gynecol Oncol. 2024;191:1-9.
101. Aronson M, Colas C, Shuen A, Hampel H, Foulkes WD, Baris Feldman H, et al. Diagnostic criteria for constitutional mismatch repair deficiency (CMMRD): recommendations from the international consensus working group. J Med Genet. 2022;59(4):318-27.
102. Gallon R, Brekelmans C, Martin M, Bours V, Schamschula E, Amberger A, et al. Constitutional mismatch repair deficiency mimicking Lynch syndrome is associated with hypomorphic mismatch repair gene variants. NPJ Precis Oncol. 2024;8(1):119.
103. Gallinger S, Aronson M, Shayan K, Ratcliffe EM, Gerstle JT, Parkin PC, et al. Gastrointestinal cancers and neurofibromatosis type 1 features in children with a germline homozygous MLH1 mutation. Gastroenterology. 2004;126(2):576-85.

104. Pan S, Cox H, Willmott J, Mundt E, Gorringe H, Landon M, et al. Discordance between germline genetic findings and abnormal tumor immunohistochemistry staining of mismatch repair proteins in individuals with suspected Lynch syndrome. Front Oncol. 2023;13:1069467.
105. Bosch DE, Yeh MM, Salipante SJ, Jacobson A, Cohen SA, Konnick EQ, et al. Isolated MLH1 Loss by Immunohistochemistry Because of Benign Germline MLH1 Polymorphisms. JCO Precis Oncol. 2022;6:e2200227.
106. Stinton C, Jordan M, Fraser H, Auguste P, Court R, Al-Khudairy L, et al. Testing strategies for Lynch syndrome in people with endometrial cancer: systematic reviews and economic evaluation. Health Technol Assess. 2021;25(42):1-216.