The British Association of Gynaecological Pathologists

Teaching Webinar

- Title: **Precursor lesions of VSCC: Diagnosis, Differential diagnosis and common pitfalls**
- Speaker: Dr Rachna Khera
- Affiliation: Manchester University NHS Foundation Trust
- Date: 11/06/2025

The British Association of Gynaecological Pathologists

Speaker disclosures

I have no financial conflicts of interest to disclose

INTRODUCTION

- Vulval cancer is malignancy that affects skin and structures around the female external genital tract (labia majora, labia minora, clitoris and accessory glands)

- More than 90% of Vulval cancers are invasive SCC

- Rare cancer (<6/100,000 per year, ESMO)

Cases



1,401 new cases of vulval cancer, 2017-2019, UK.

Deaths



469 deaths from vulval cancer, 2017-2019, UK.

Survival



58% survive vulval cancer for 10 or more years, 2013-2017, England.

Preventable cases



69% of vulval cancer cases are preventable, UK, 2015.

	HPVA SCC	HPVI SCC
ETIOLOGY	HIGH RISK HPV INFECTION (HPV 16, 18, 33)	CHRONIC DERMATOSES LIKE LS
AGE GROUP AFFECTED	Younger women (<60 years)	Older women (>60 years)
PRECURSOR LESION	High grade VIN Usual type	Differentiated VIN
BIOMARKER EXPRESSION	P16 abnormal	P16 normal
MORPHOLOGY	Warty/basaloid	keratinizing
PROGNOSIS	Favourable	Less favourable
ASSOCIATED RISK FACTORS	Smoking, immunosuppression	Chronic inflammation and lichen sclerosus
MOLECULAR PATHOGENESIS	Viral oncogenes E6 and E7 inactivate p53 and Rb	Somatic mutation in Tp53 and NOTCH1 etc

Keratinizing
Non-keratinizing
Warty
Basaloid
Verrucous

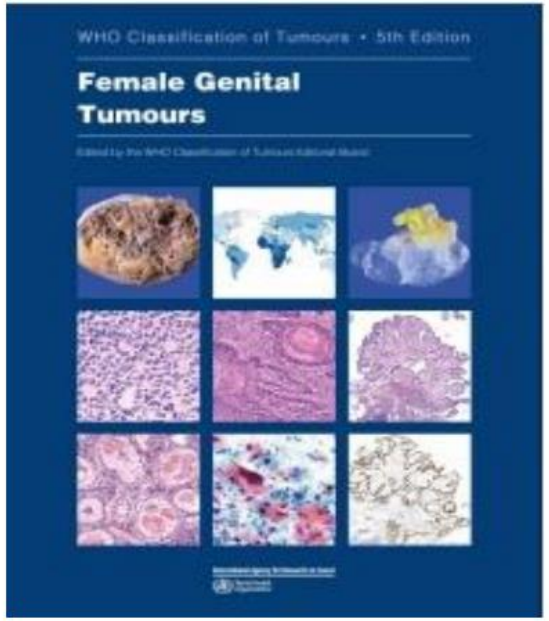

WHO 5TH edition

HPV-ASSOCIATED SCC
HPV-INDEPENDENT SCC

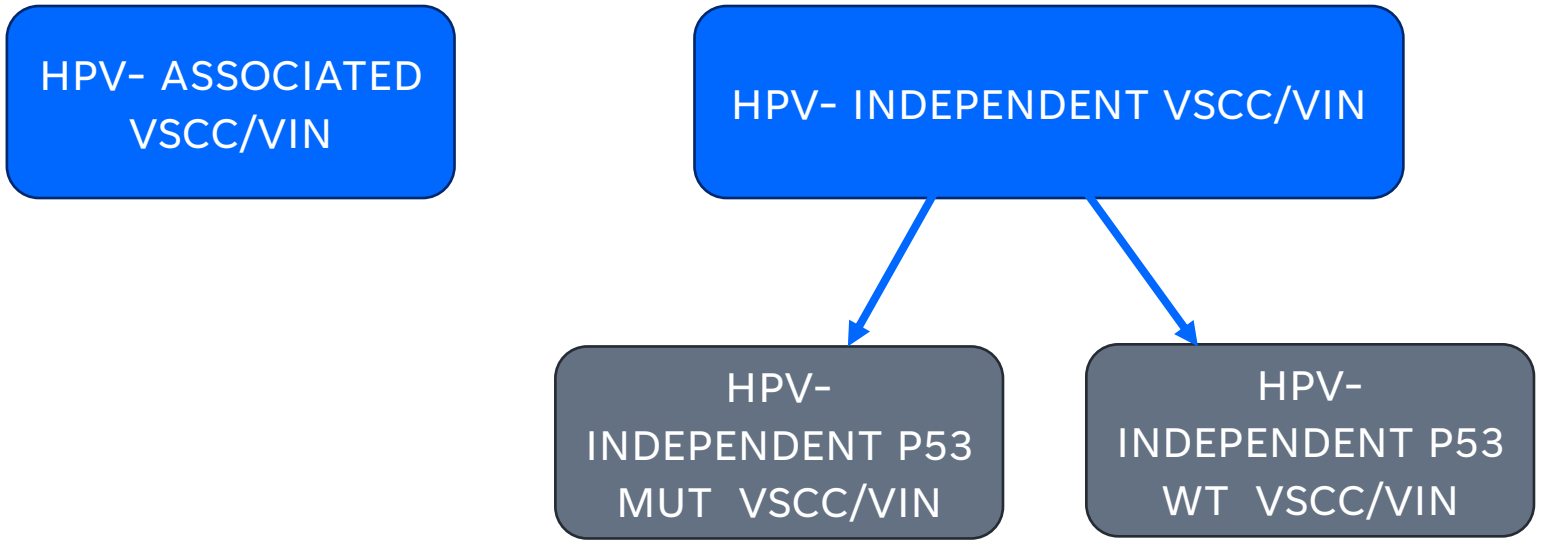

Emerging evidence - HPV-independent VSCC can be further prognostically subclassified using TP53

HPV ASSOCIATED

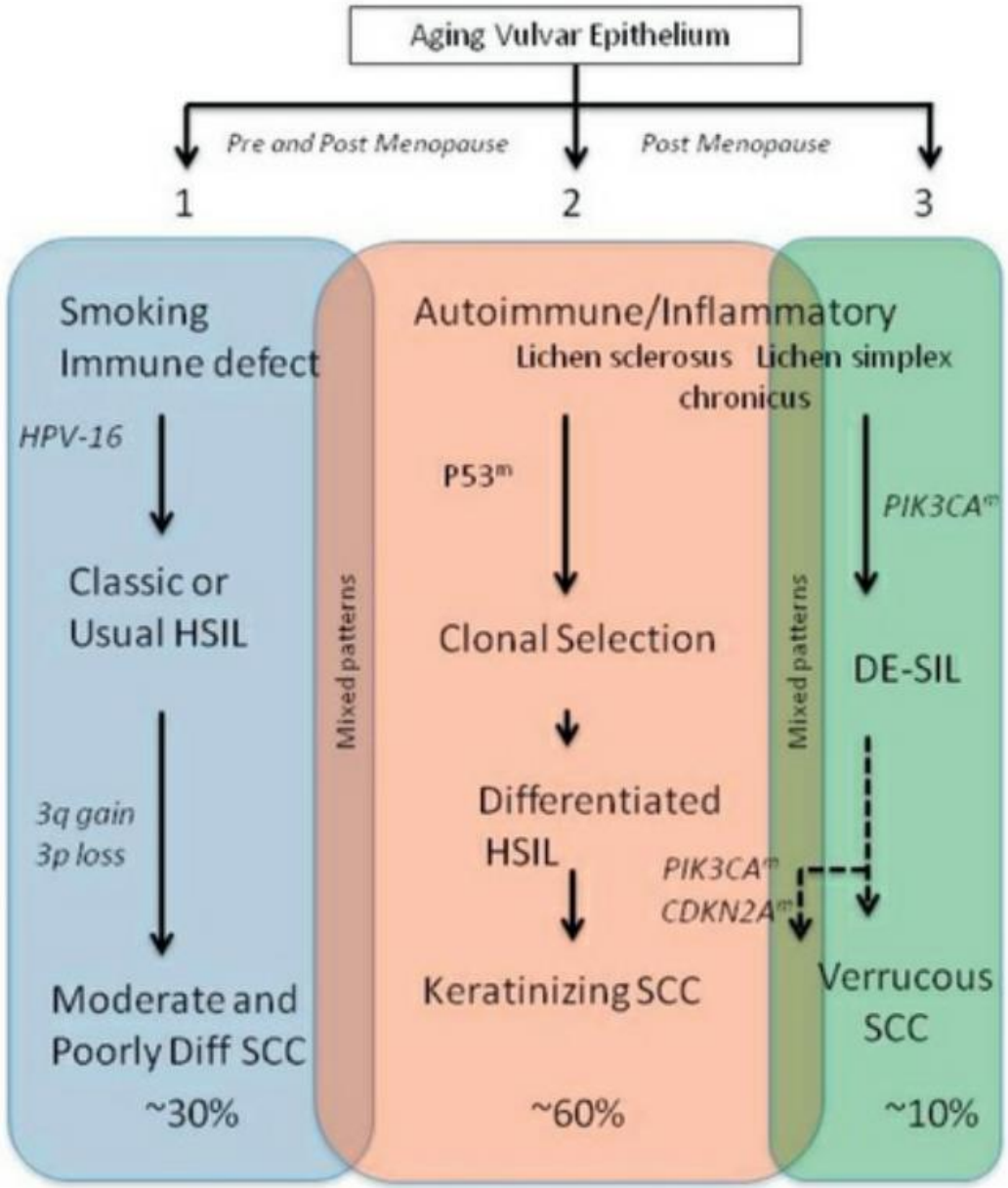

HPV INDEPENDENT

How to tell them apart?

- Although morphology and adjacent in situ lesions can be a clue to HPV status, RCPath and ICCR recommended that **p16 IHC** be used to more accurately subclassify VSCC into 2 major groups (HPVA and HPVI)

  - There is overlap in 20-40% of cases of SCC
  - There is overlap in 5-20% of in-situ lesions

- **Immunohistochemistry for p53** should be always employed to further divide HPVI cases into p53wt and p53 abn groups

Interpretation of p16 Immunohistochemistry In Lower Anogenital Tract Neoplasia

Authors: Naveena Singh[1], C Blake Gilks[2], Richard Wing-Cheuk Wong[3], W Glenn McCluggage[4], C Simon Herrington[5]

[1]Barts Health NHS Trust, London, UK; [2]Vancouver General Hospital [3]Pamela Youde Nethersole Eastern Hospital, Hong Kong, [4]Belfast Health and Social Care Trust, Belfast, UK; [5]University of Edinburgh

Normal/reactive expression patterns in squamous epithelium (Figure 1)

- Normal squamous epithelium generally shows completely absent expression.
- Occasional scattered, weakly staining cells may be seen, especially in immature metaplastic epithelium.
- In reactive conditions positively stained cells may be more numerous and/or stronger staining; these will still be irregularly scattered.

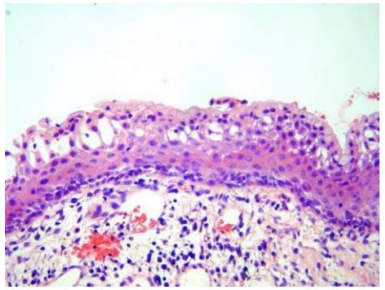

Figure 1a. Immature squamous metaplasia of the cervix.

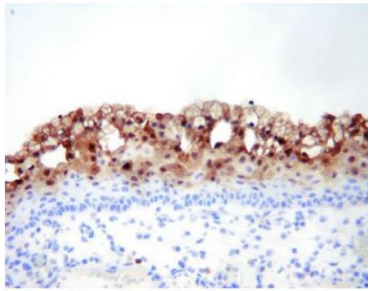

Figure 1b. p16 staining in the immature metaplastic squamous epithelium is typically patchy *with sparing of the basal layer*.

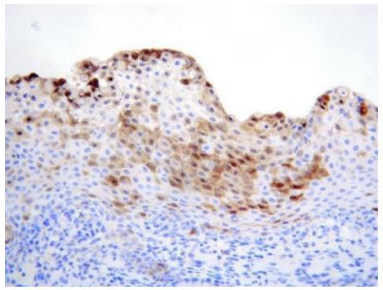

Figure 1c. Patchy p16 staining in normal cervical squamous epithelium.

- ***Abnormal expression in squamous epithelial lesions fulfils ALL of the following (this pattern has been described as BLOCK POSITIVE staining):***
  - Strong and continuous nuclear OR more typically nuclear and cytoplasmic expression in all epithelial cells in the basal and parabasal layers with upward extension
  - Upward extension must involve at least the lower one-third of the epithelial thickness
  - Abnormal expression must extend for at least 6 cells across
  - It is acknowledged that the criteria defining the horizontal and upward extent are arbitrary but these serve to improve specificity

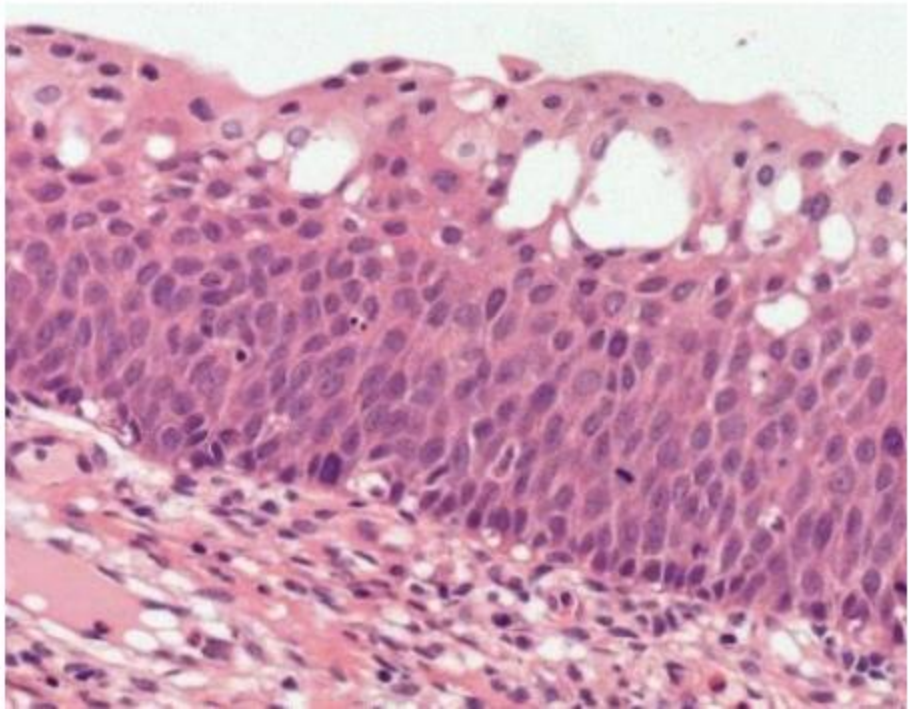

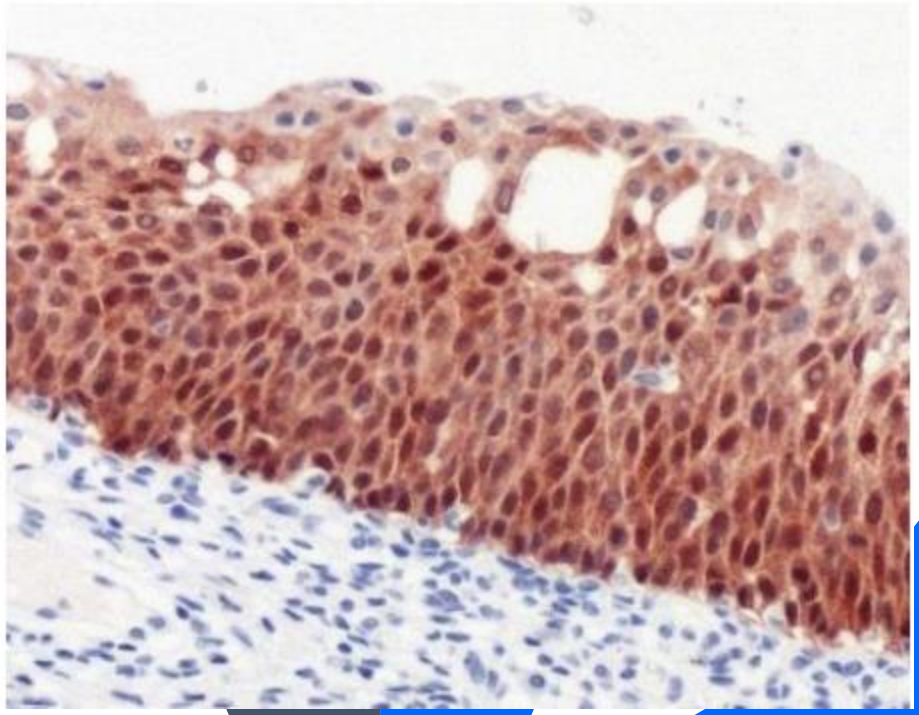

P53 IHC

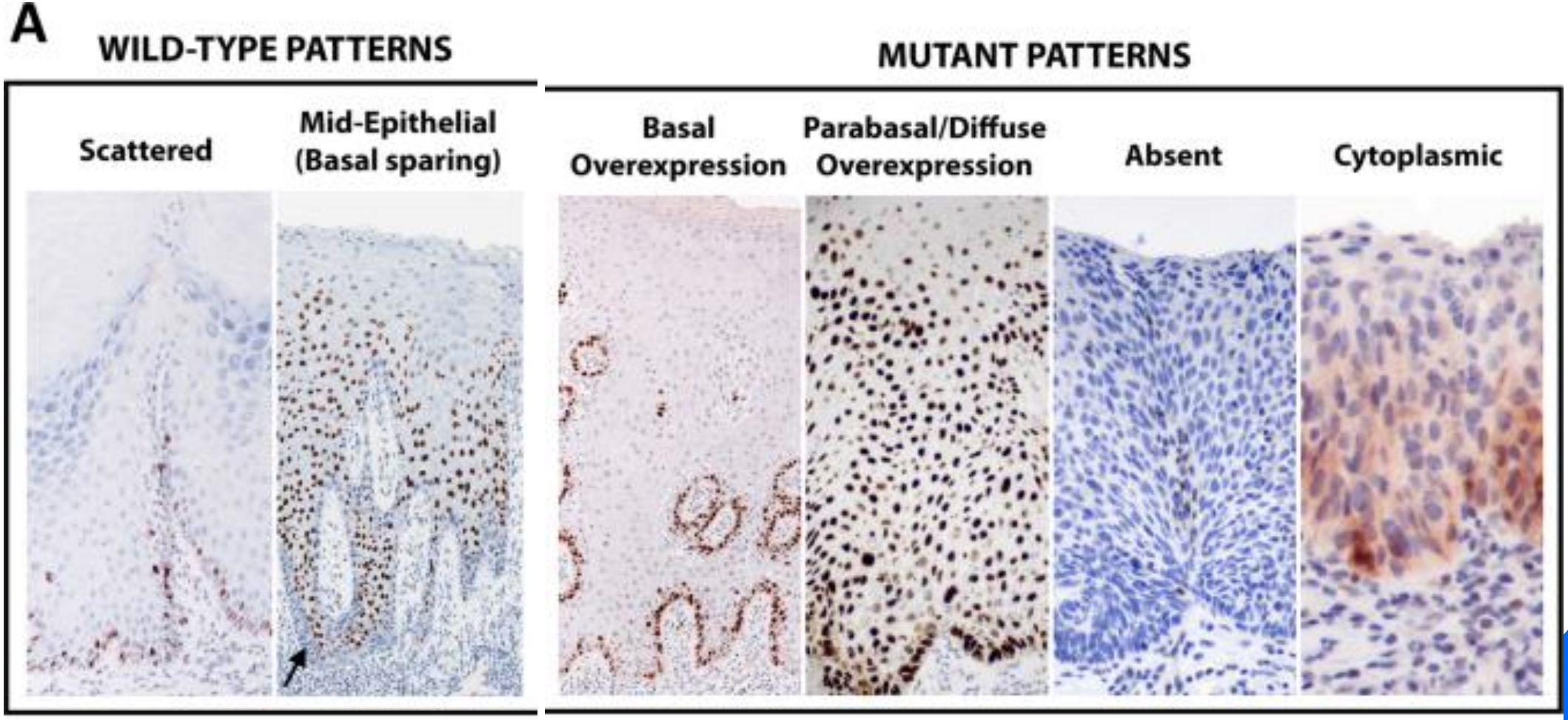

Modern Pathology (2020) 33:1649–1659

Precursors lesions of VSCC

HPV-Associated SIL

- High Grade Squamous Intraepithelial lesion (HSIL)

HPV-Independent VIN

- Differentiated VIN

OTHER SUBTYPES-

- DEVIL
- VAAD

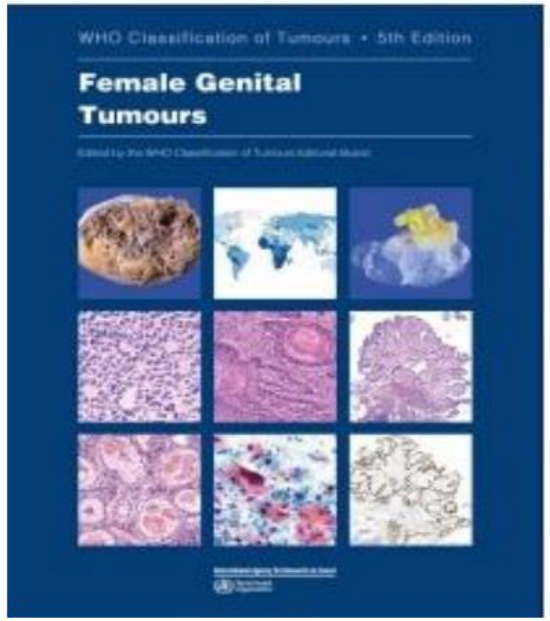

WHO 2020

HSIL, HPV-ASSOCIATED

- Most common form of vulvar cancer precursor i.e most intraepithelial lesions diagnosed in the vulva are HSIL, HPV-associated

- as defined implies an infection by high-risk HPV (HPV 16 is identified in >70% cases)

- HSILs of the vulva typically younger women

- About 60% present with pruritus and irritation; Asymptomatic- significant percentage

- Strong correlation with smoking and immunosuppression, both for classic HSIL and HPV positive vulvar carcinomas



Christopher P. Crum, Alvaro P. Pinto, Scott R. Granter, William A. Peters. Diagnostic Gynecologic and Obstetric Pathology (3rd edition)

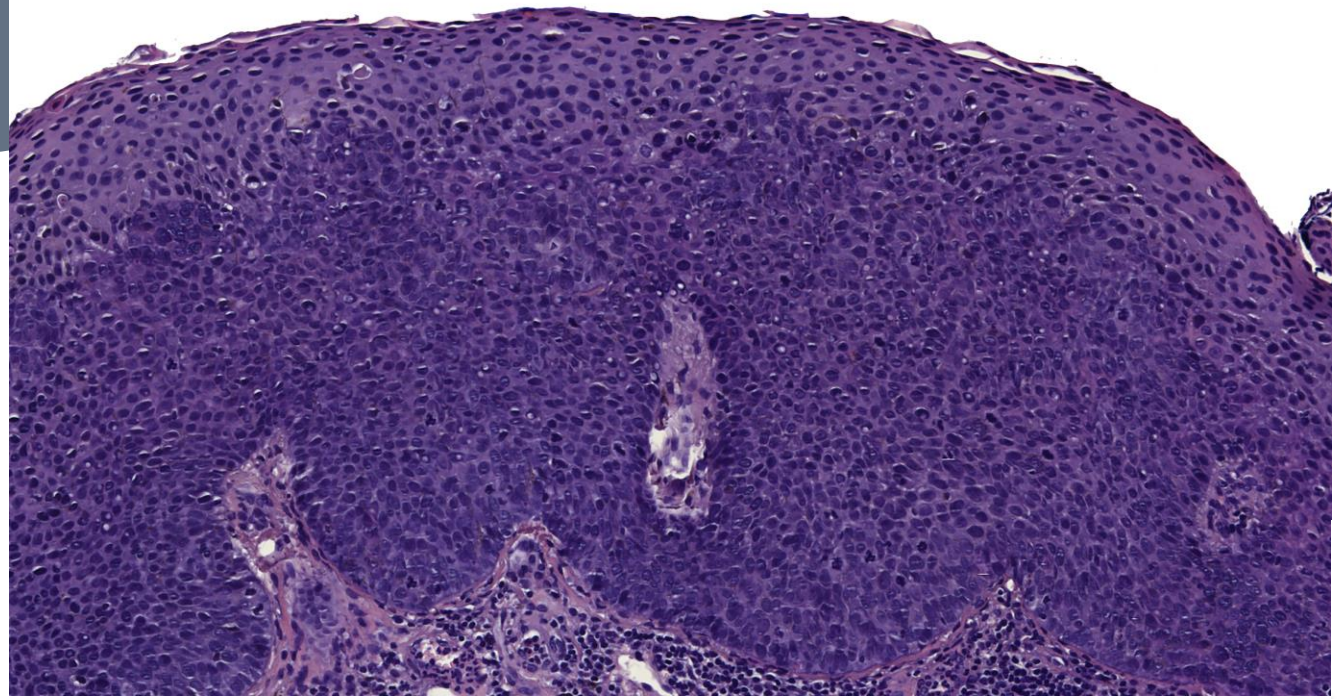

Basaloid

warty

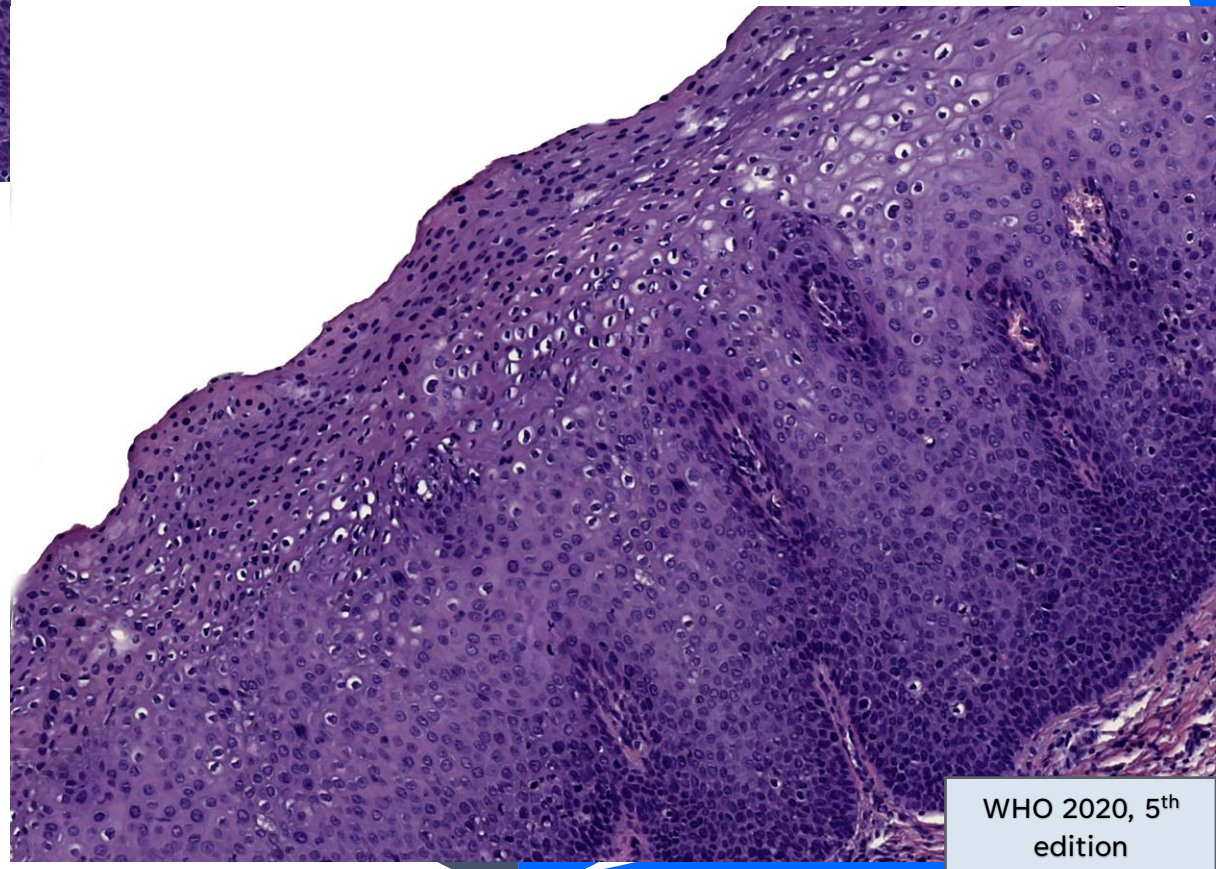

WHO 2020, 5th edition

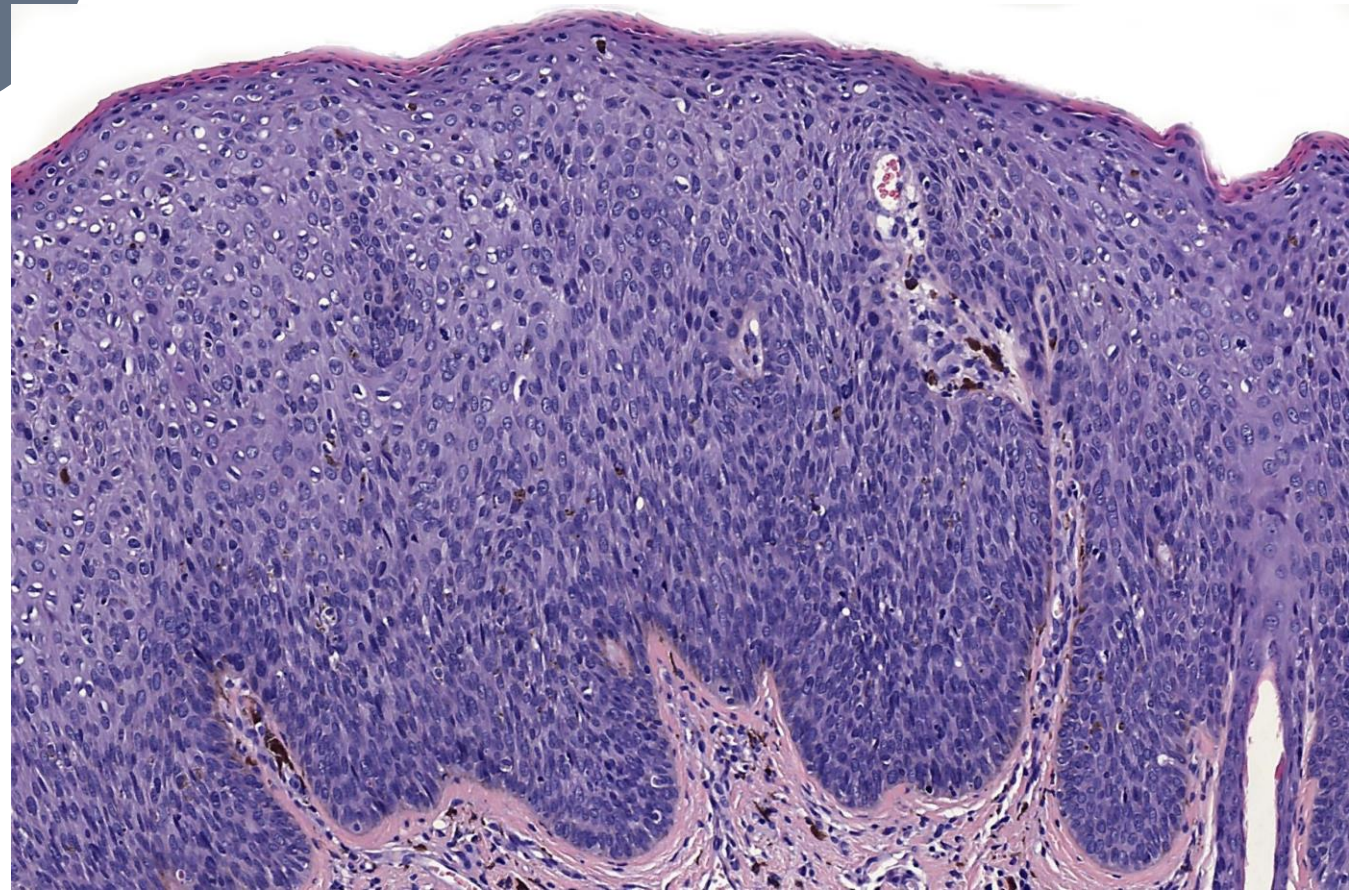

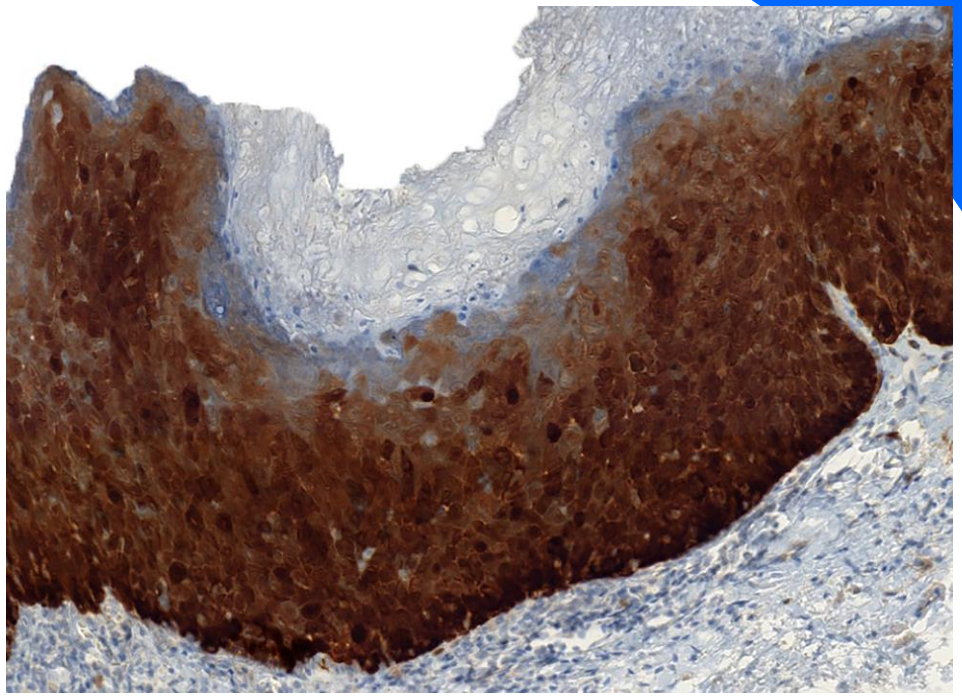

Desirable: p16 block-type immunohistochemistry.

Essential: loss of maturation; nuclear hyperchromasia; high N:C ratios; cytological and architectural atypia; increased mitotic activity, with mitoses in the upper layers of the epidermis.

WHO 2020, 5th edition

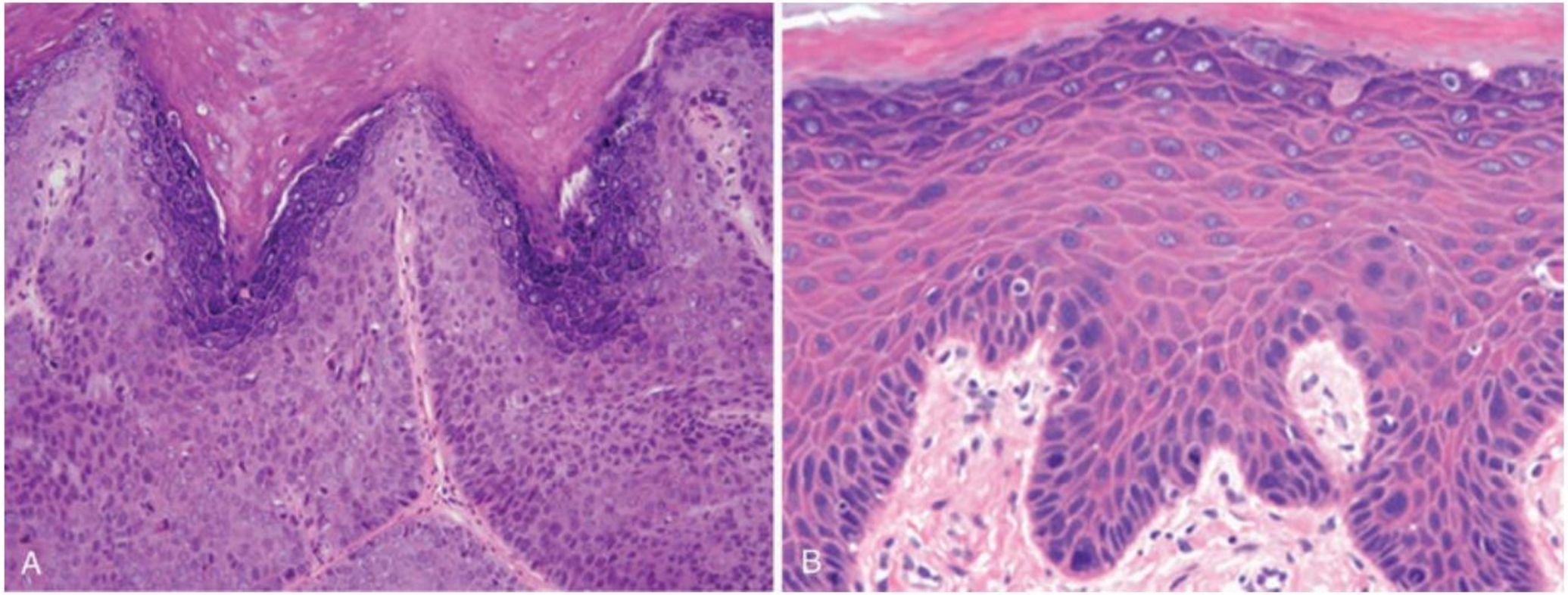

Christopher P. Crum, Alvaro P. Pinto, Scott R. Granter, William A. Peters. Diagnostic Gynecologic and Obstetric Pathology (3rd edition)

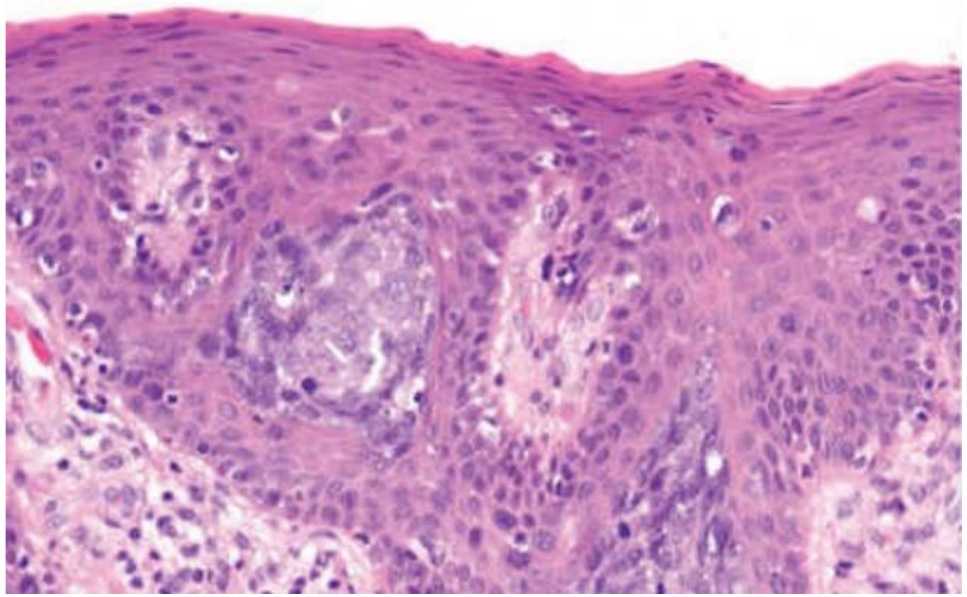

Uncommon variants of classic VIN in which less well-differentiated squamous cells invade the mature squamous epithelium, so-called **pagetoid VIN**. The neoplastic cells form a discrete nesting pattern interposed with normal keratinocytes.

Christopher P. Crum, Alvaro P. Pinto, Scott R. Granter, William A. Peters. Diagnostic Gynecologic and Obstetric Pathology (3rd edition)

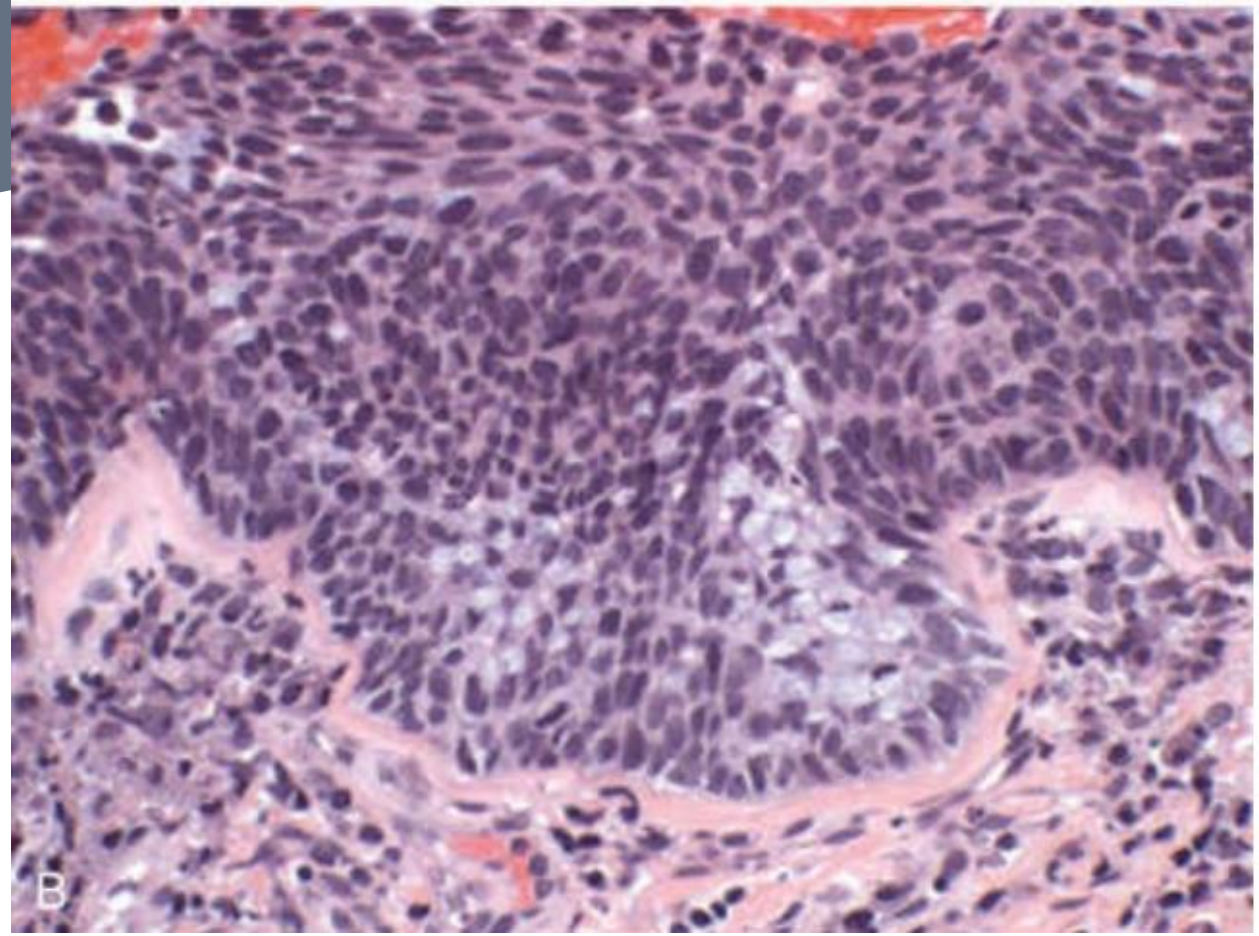

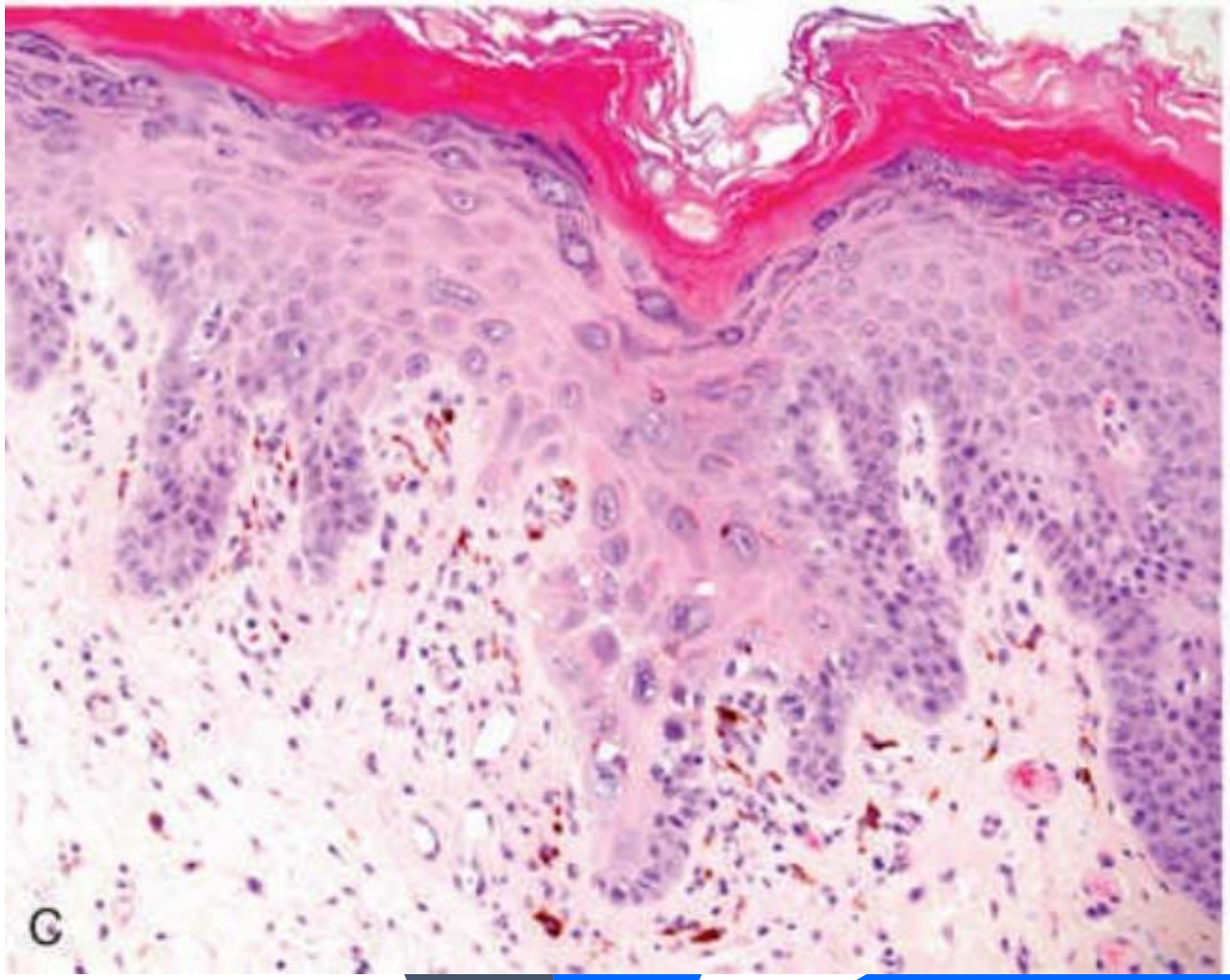

Christopher P. Crum, Alvaro P. Pinto, Scott R. Granter, William A. Peters. Diagnostic Gynecologic and Obstetric Pathology (3rd edition)

P53 IHC patterns in HPV-associated squamous neoplasia

Scattered (wild type)		
Heterogenous staining of varying intensities throughout the tumor		
Markedly reduced (null-like)		
absence or significantly reduced p53 staining in the presence of positive internal control	Single cells	Majority of tumor cells with complete absence of staining with scattered single cells showing strong positive staining
	Clustered	Clustered groups of strongly positive tumor cells in a background of cells with absent staining
	Peripheral	Peripheral strong staining in background of cells with absent staining
Mid-epithelial (basal sparing)		
Basal layer in in situ SCC or peripheral layer in invasive SCC nests showed absence of staining accompanied by strong staining in the parabasal cells	Classic	Absence of staining only in the single basal layer
	Central	Absence of staining in the basal layer as well as variable portions of the parabasal layers

Yang H et al. Mod Pathol. 2023 Jun;36(6):100145.

Mid-epithelial staining with basal sparing
(mimicking overexpression-type staining)

Markedly reduced staining
(mimicking null-type staining)

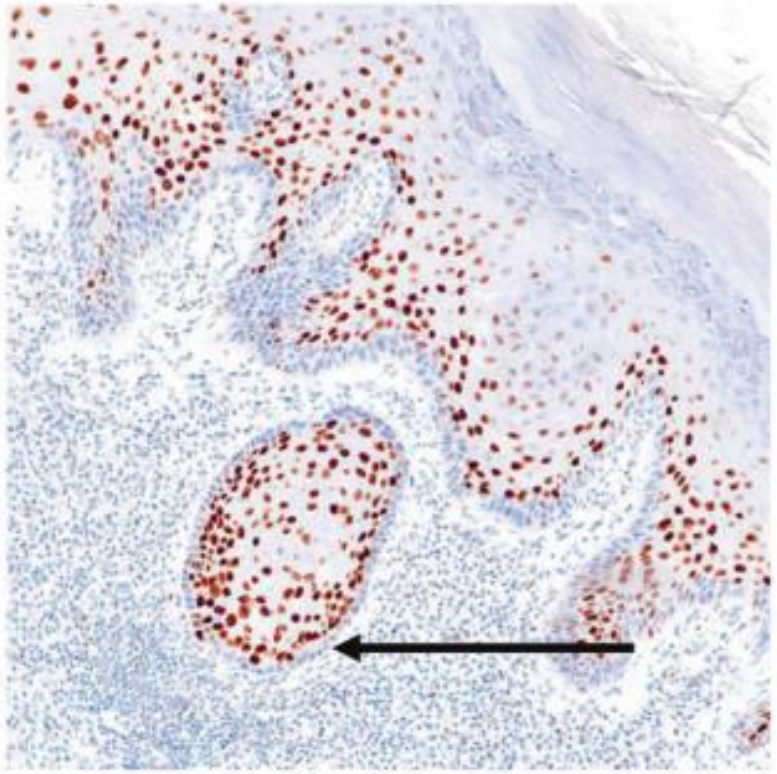

Classic

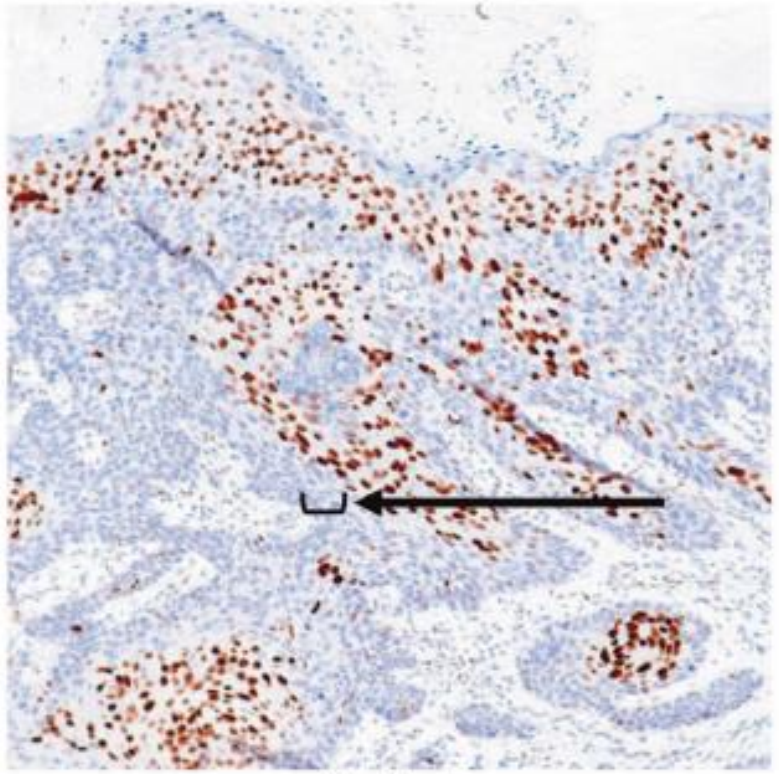

Central

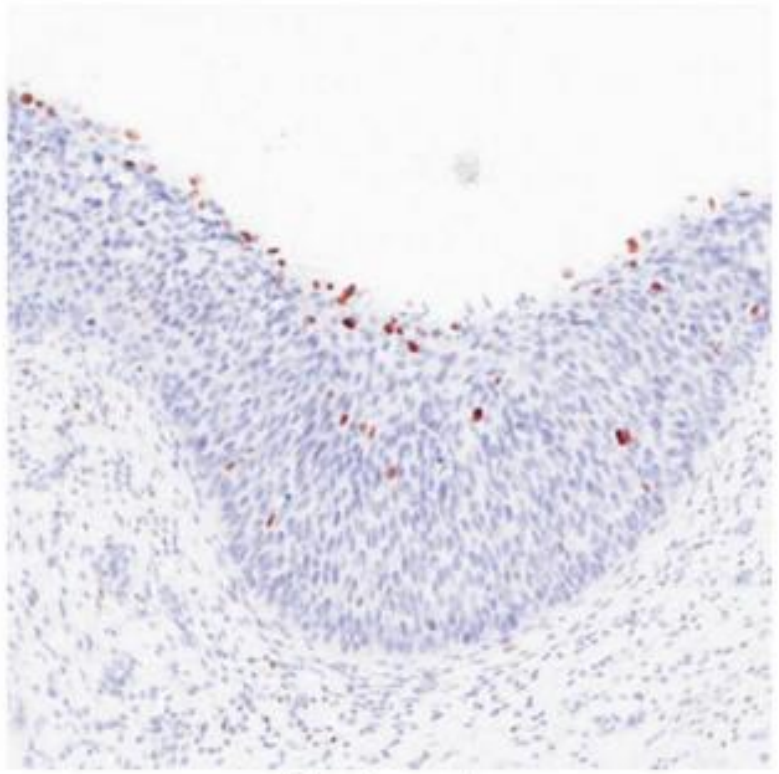

Single cells

HPV Independent VIN

HPVi p53mut

dVIN

HPVi p53wt

DeVIL

VAAD

vLSC

Vulvar aberrant maturation (VAM) ISSVD Terminology
HPVi (p53wt) VaVIN

Parra-Herran, C., Nucci, M.R., Singh, N. et al.. Mod Pathol 35, 1317–1326 (2022)

dVIN

Clinically, dVIN symptoms reflect the underlying dermatosis, so most women report pruritus or pain;

Color, texture, location, size, and focality are variable-

The 3 most common appearances: thick white plaque, a thin pink-red plaque or red glazed patch.

Lesions may be less than 1 cm or extend across the vulva.

The unifying description is any treatment-resistant lesion in a field of dermatosis-affected skin.

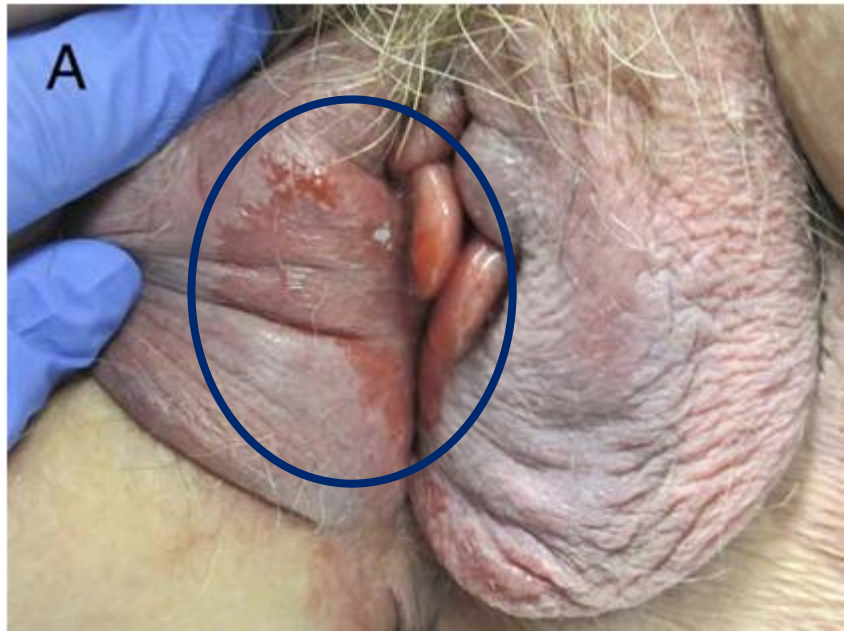

large glazed red patch over bilateral labia minora and right interlabial fold

(Heller et al. J Low Genit Tract Dis 2021;25: 57–70)

Histologic Diagnosis for dVIN

Suboptimal diagnostic reproducibility amongst pathologists

-Lack of consensus on the lower limit of morphologic derangements

-Lack of agreement on the diagnostic utility of individual features

-Suboptimal awareness of its WIDE MORPHOLOGIC SPECTRUM, histologic variants and potential mimics

Adv Anat Pathol 2025;32:4–19)

DVIN CASES **Substantial differences** regarding the

-thickness of the epidermis
-size and shape of the rete ridges
-presence or thickness of parakeratosis or orthokeratosis
-level of intercellular degeneration and maturation of the spinous layer, basal mitotic activity, and atypia

NEAR CONSENSUS- basal atypia is the key diagnostic feature

ISSVD Guideline: Basal atypia

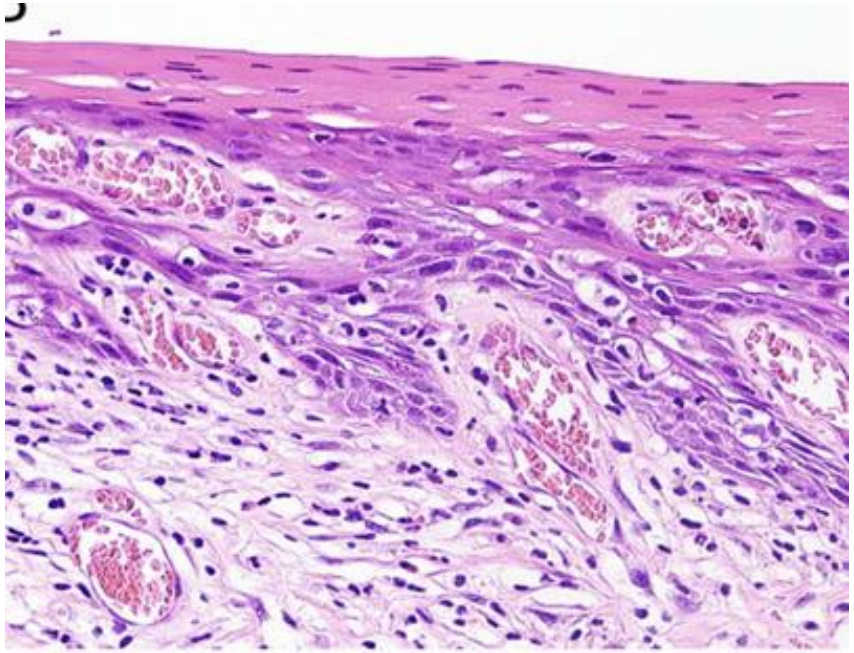

4 factors:

1) **chromatin abnormalities** (usually hyperchromasia with inconspicuous nucleoli, but vesicular chromatin with multiple or enlarged nucleoli may be seen in a small subset)

(2) **nuclear enlargement**

(3) **Pleomorphism**

(4) **Increased mitotic activity;** the presence of **atypical mitotic** figures is useful in excluding reactive processes.

J Low Genit Tract Dis 2021;25: 57–70

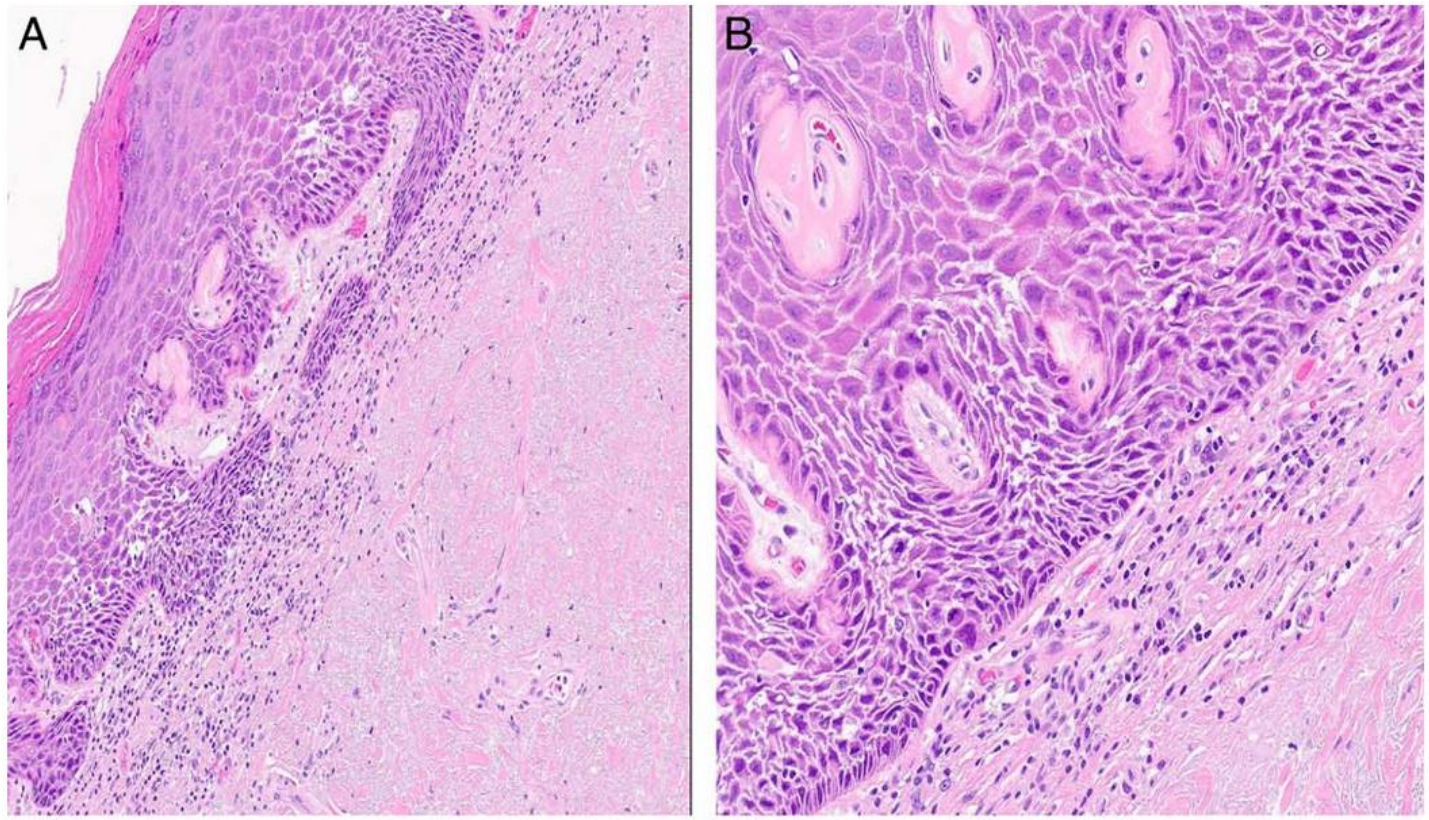

Architectural variants

KERATINIZING (82%):

1. Traditional (50%)

Adv Anat Pathol 2025;32:4–19)

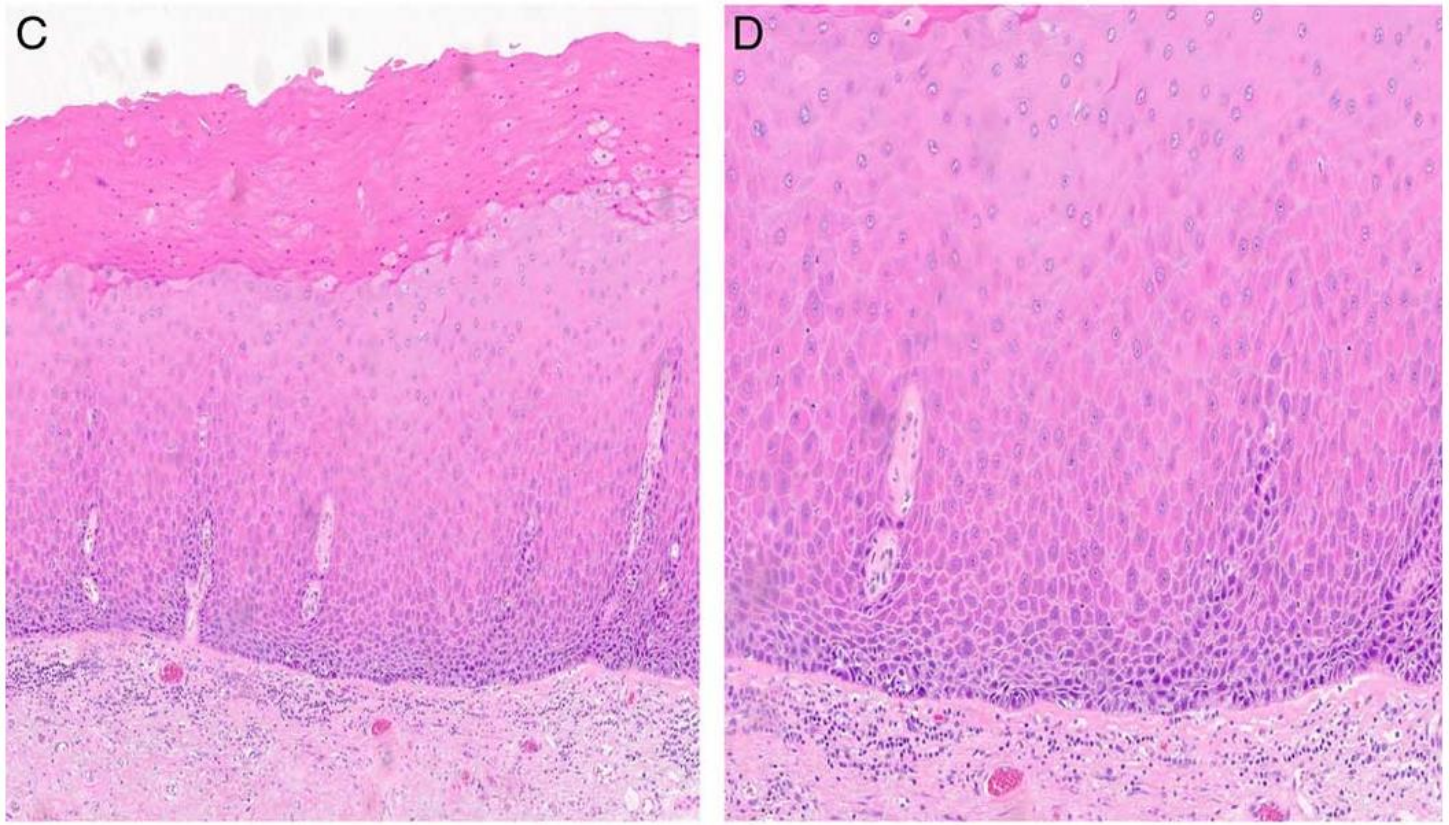

2. Hypertrophic (11%)

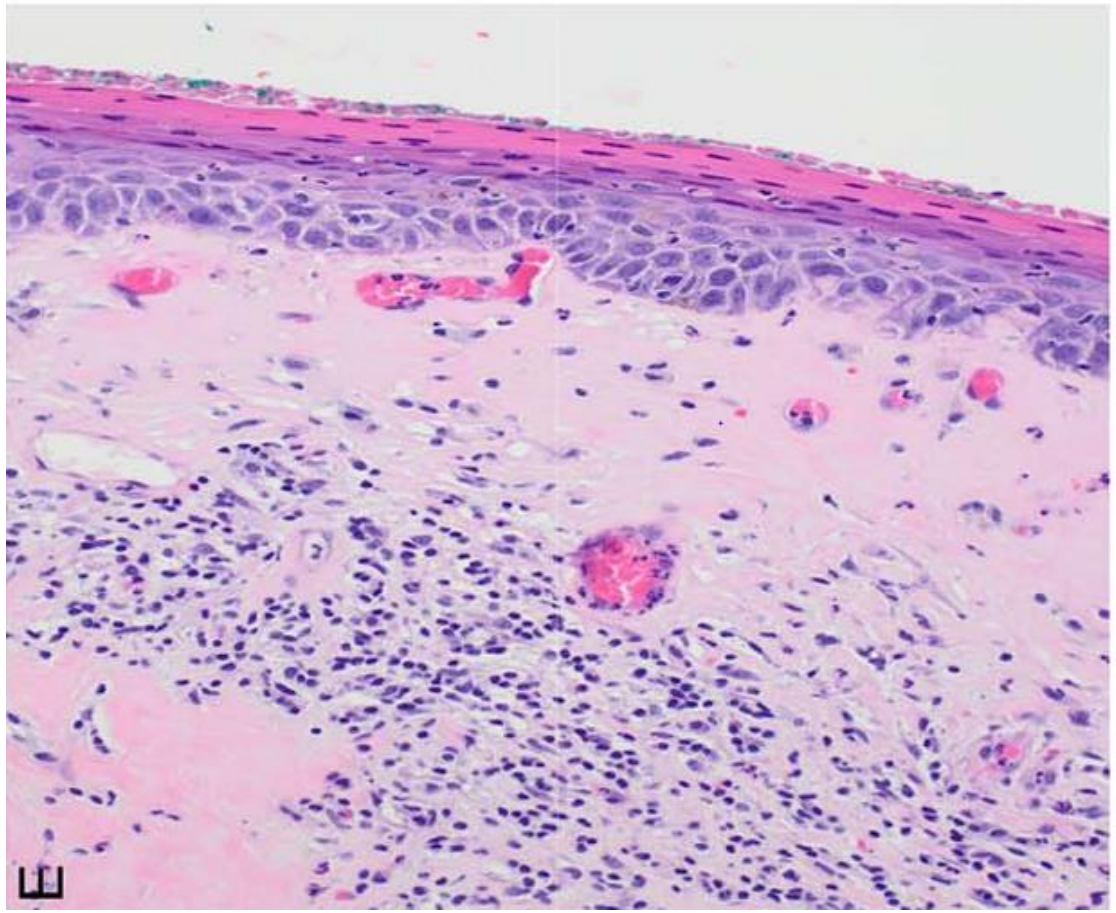

3. Atrophic (11%)

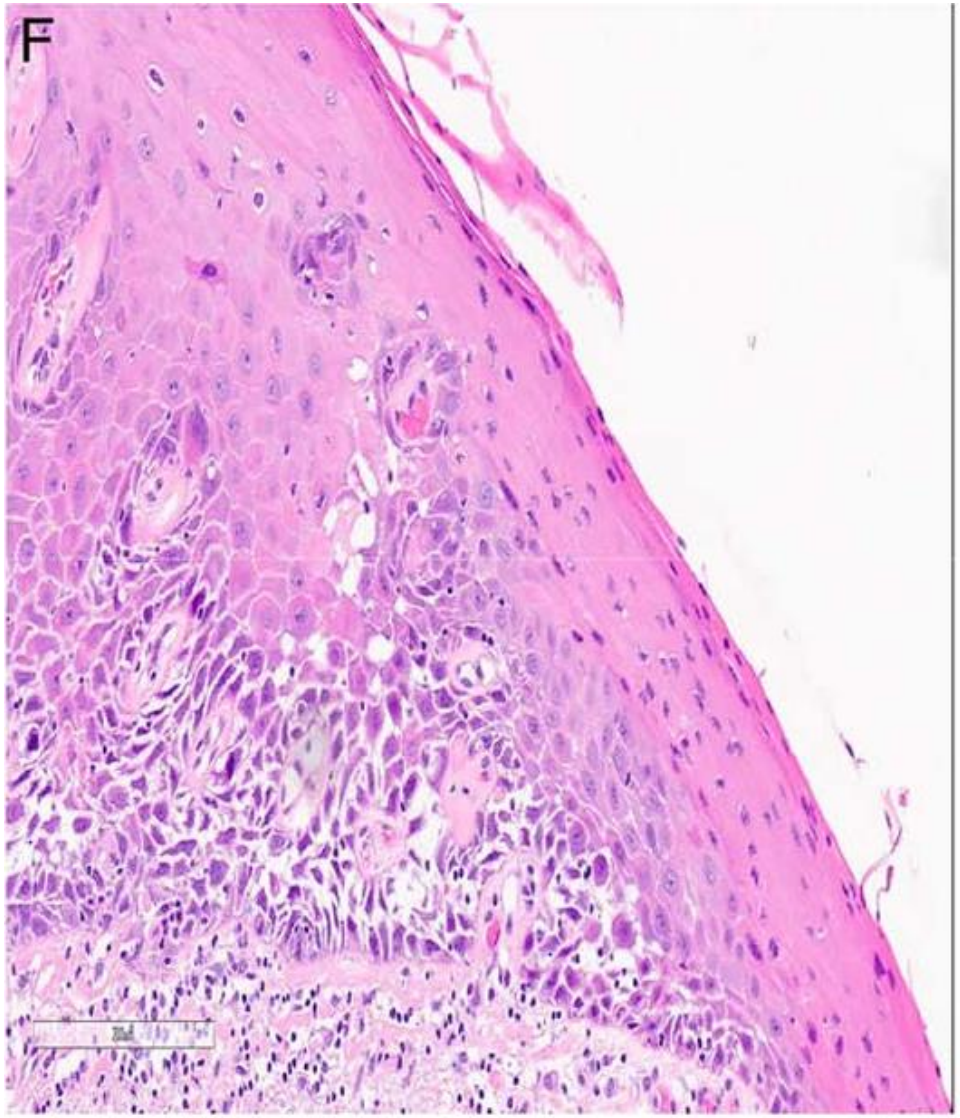

4. Acantholytic (6%)

5. Subtle variant (4%)

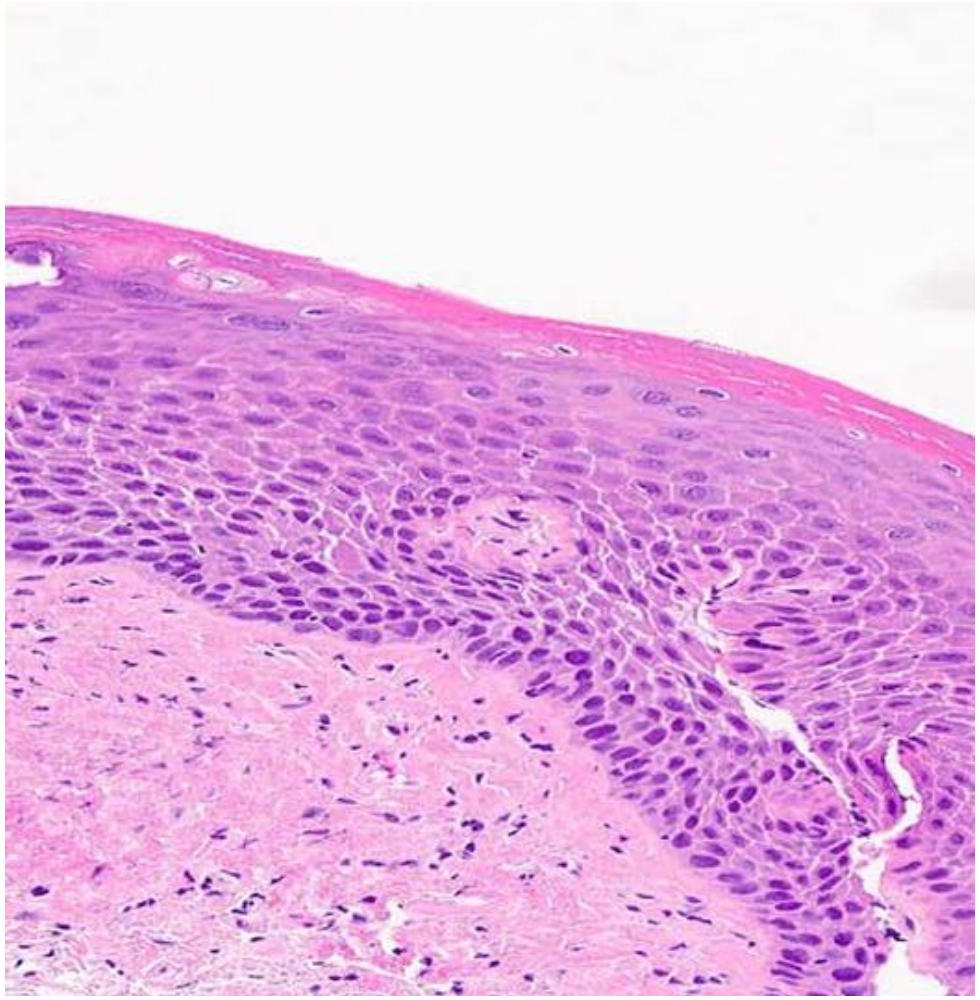



NONKERATINIZING (18%)

Basaloid (9%)

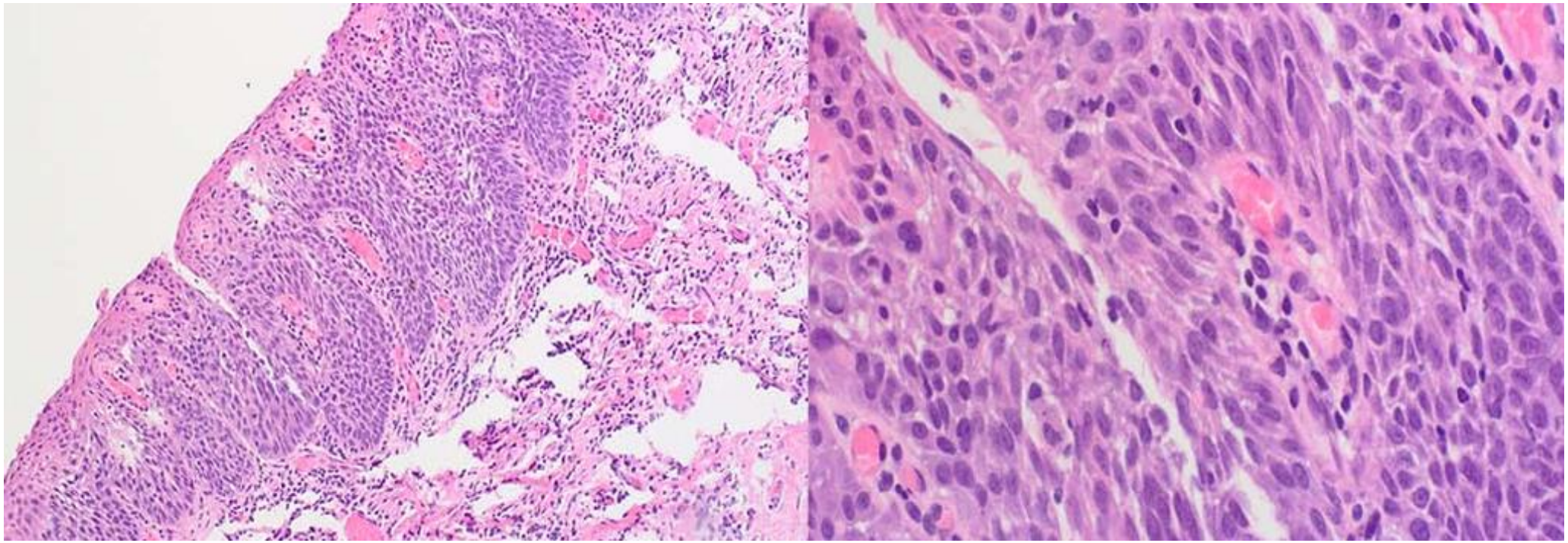

Intermediate (9%)

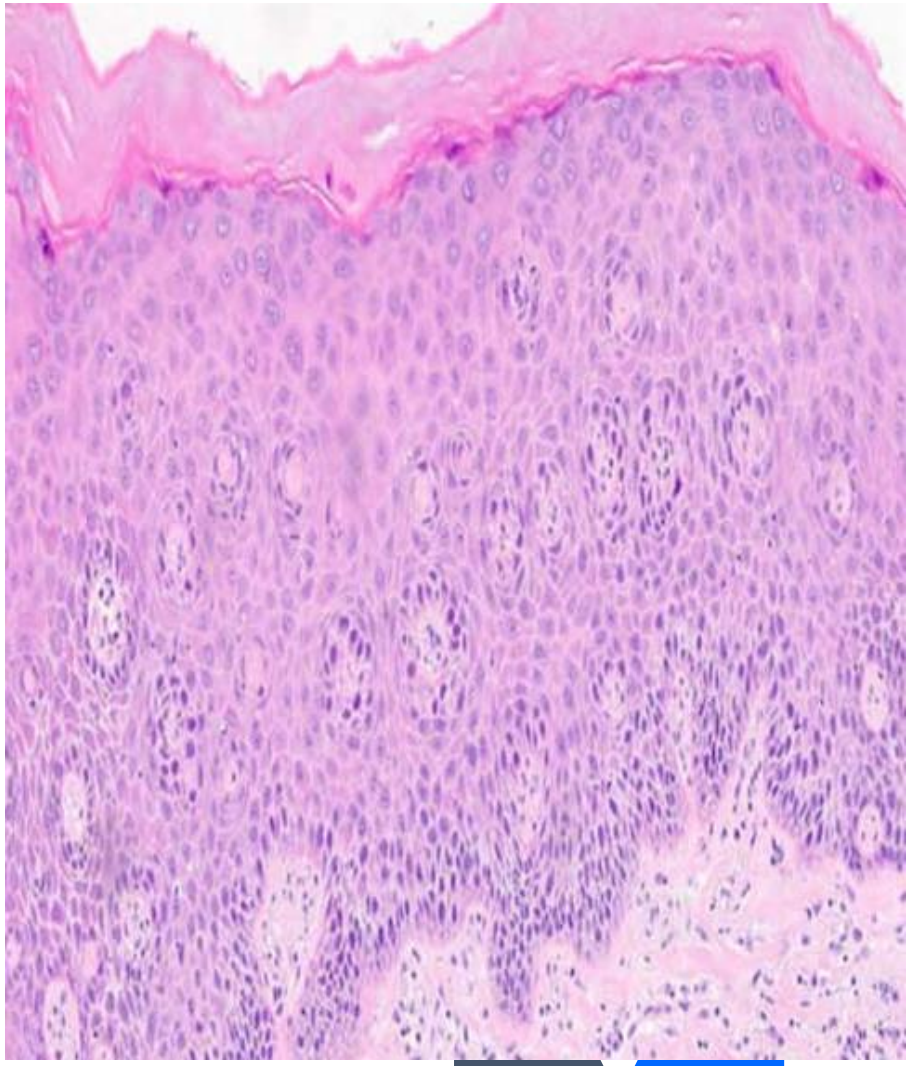

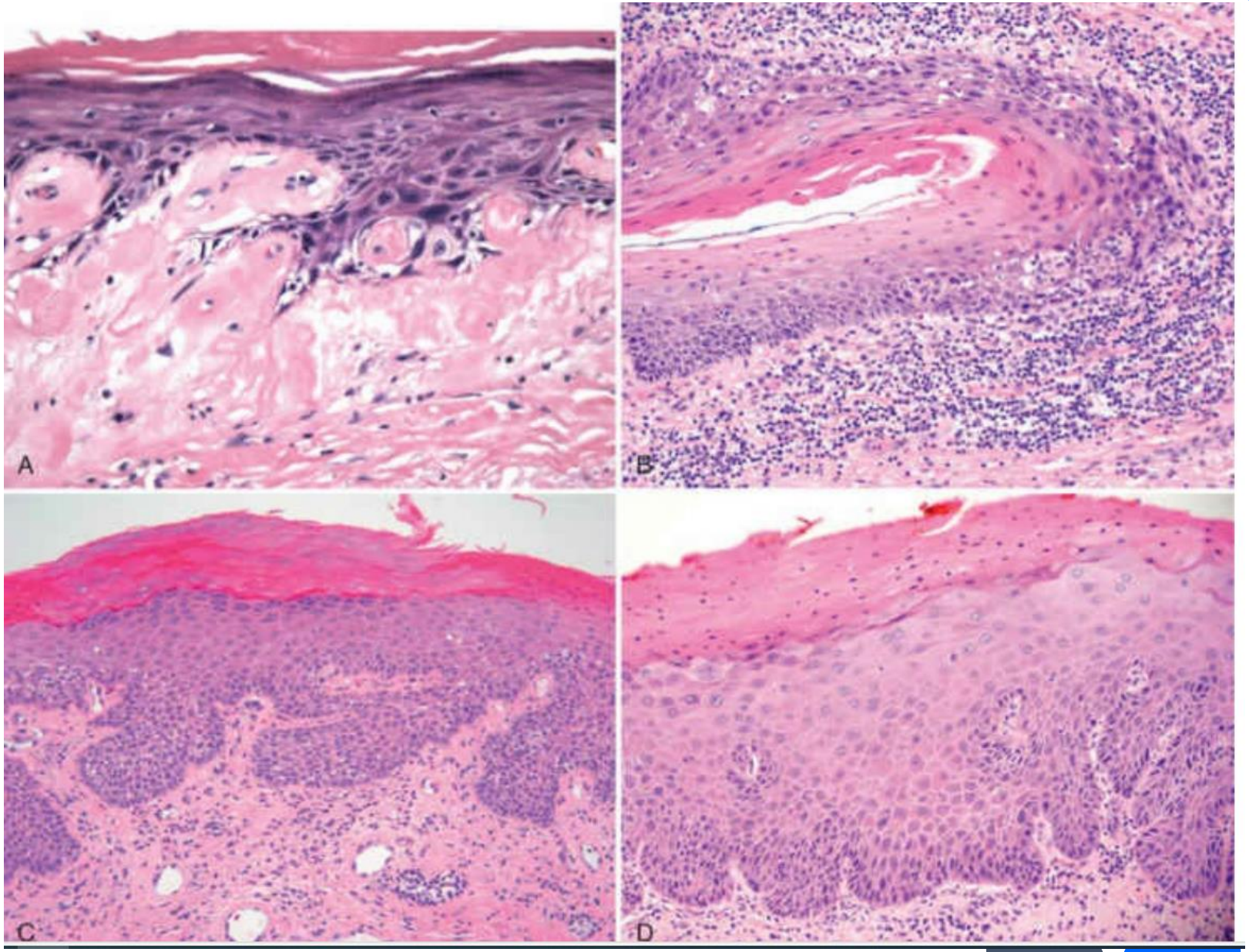

Christopher P. Crum, Alvaro P. Pinto, Scott R. Granter, William A. Peters. Diagnostic Gynecologic and Obstetric Pathology (3rd edition)

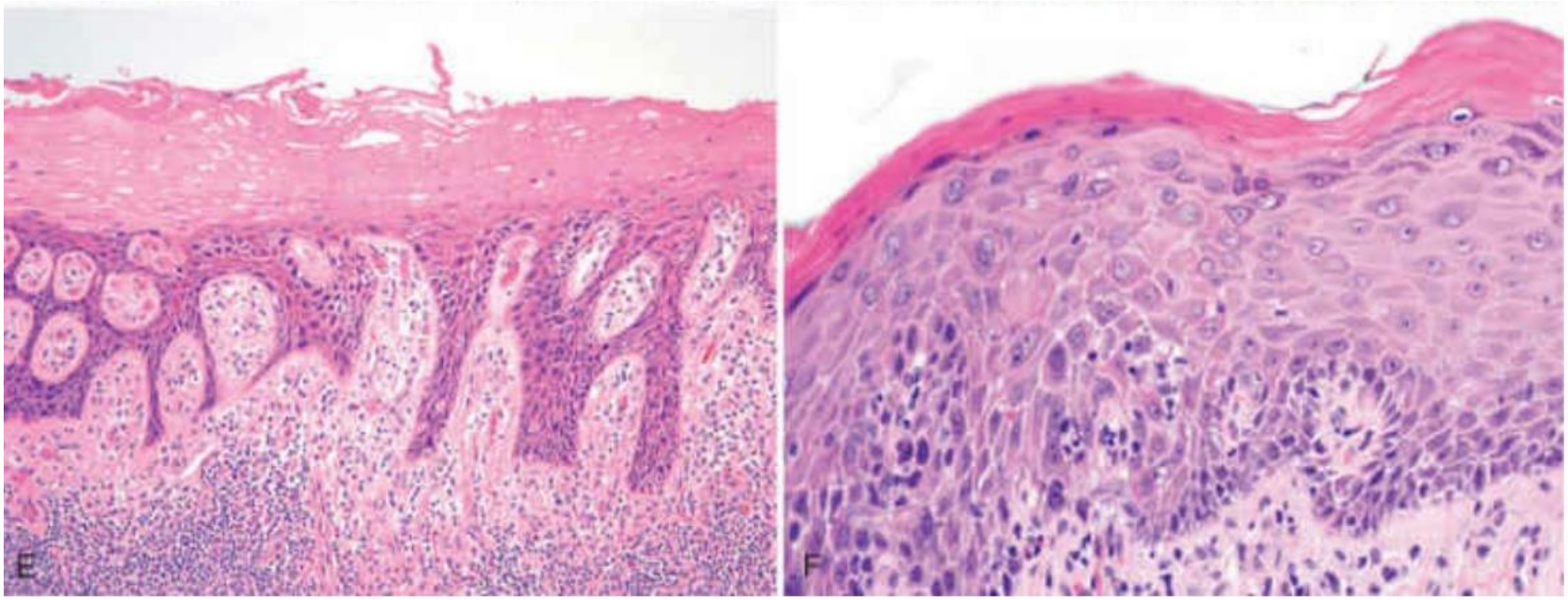

Christopher P. Crum, Alvaro P. Pinto, Scott R. Granter, William A. Peters. Diagnostic Gynecologic and Obstetric Pathology (3rd edition)

DIFFERENTIAL DIAGNOSIS

LICHEN SCLEROSUS WITH REACTIVE ATYPIA VS dVIN

Lichen sclerosus is an interface dermatitis that may exist in sclerotic or nonsclerotic forms.

Accordingly, there may be nuclear derangements of the basal layer cells, especially in the setting of active disease or noncompliance with treatment

Adv Anat Pathol 2025;32:4–19

Adherence to the definition of atypia

Close clinicopathologic correlation

P53 IHC

Adv Anat Pathol 2025;32:4–19

P53 IHC

- Uniformity of staining- most sensitive feature
- Both uniformity of staining and parabasal extension- most specific features

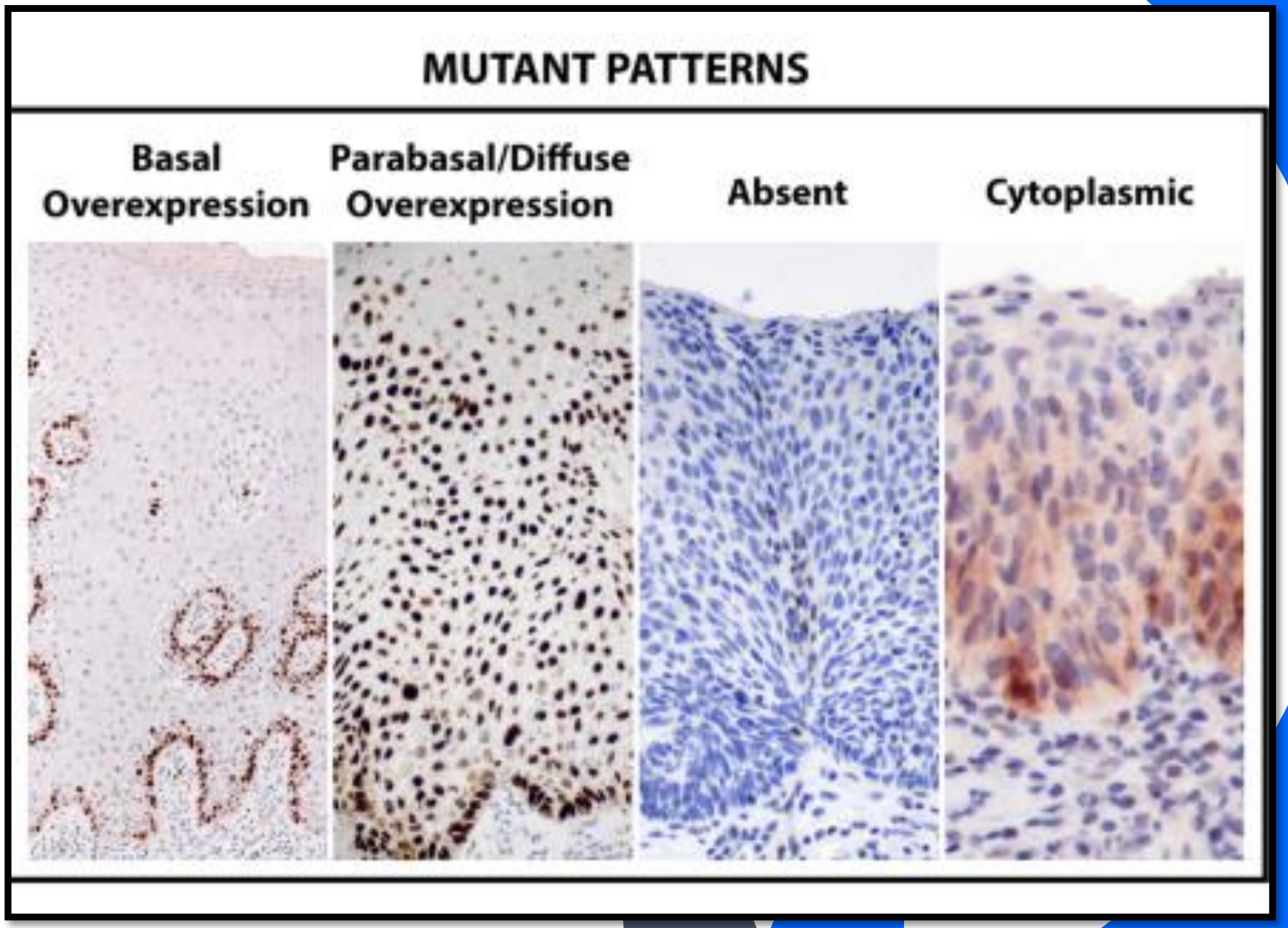

(2021) Histopathology 78, 424–433

HSIL VS DVIN

BIDIRECTIONAL : dVIN like variants of HSIL and HSIL like variants of dVIN

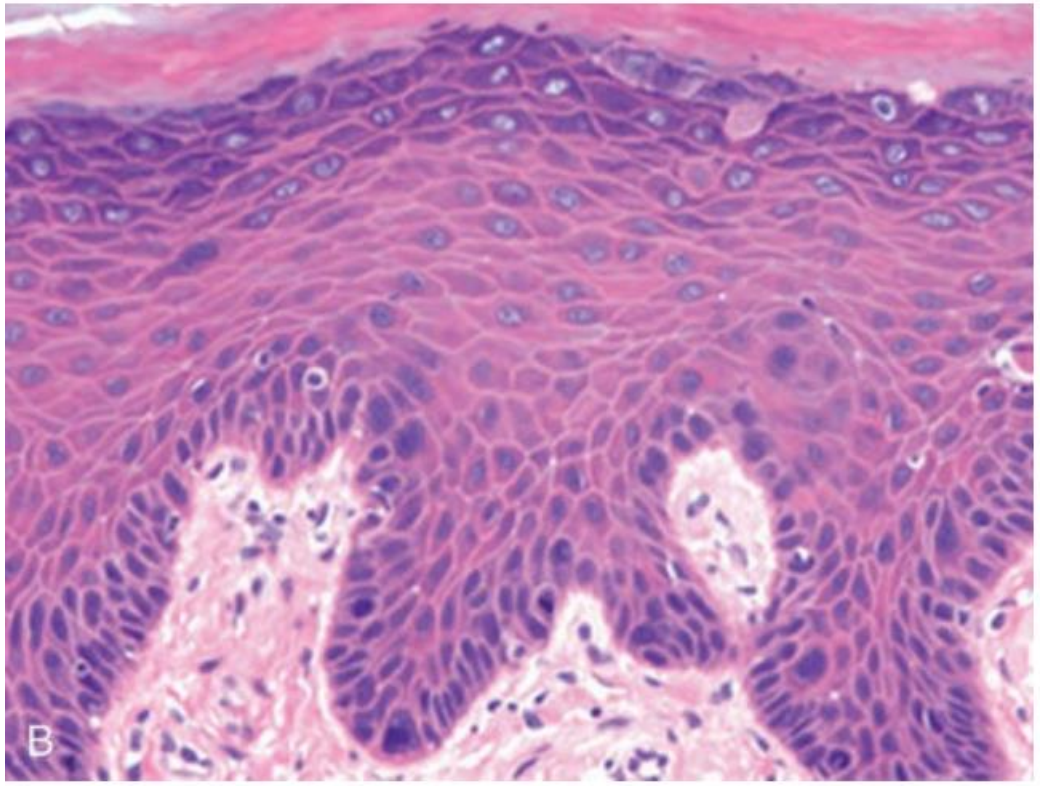

Adv Anat Pathol 2025;32:4–19

dVIN lesions with HSIL-like morphology due to basaloid or “intermediate” morphology.

In both, the undifferentiated areas display a peculiar cellular uniformity that would be somewhat unusual in HSIL (Fig)

However, immunohistochemistry for p16 and p53 is required to resolve this differential diagnosis, and older patient age, concurrent conventional dVIN, and background lichen sclerosus are some factors that should prompt those studies.

Adv Anat Pathol 2025;32:4–19

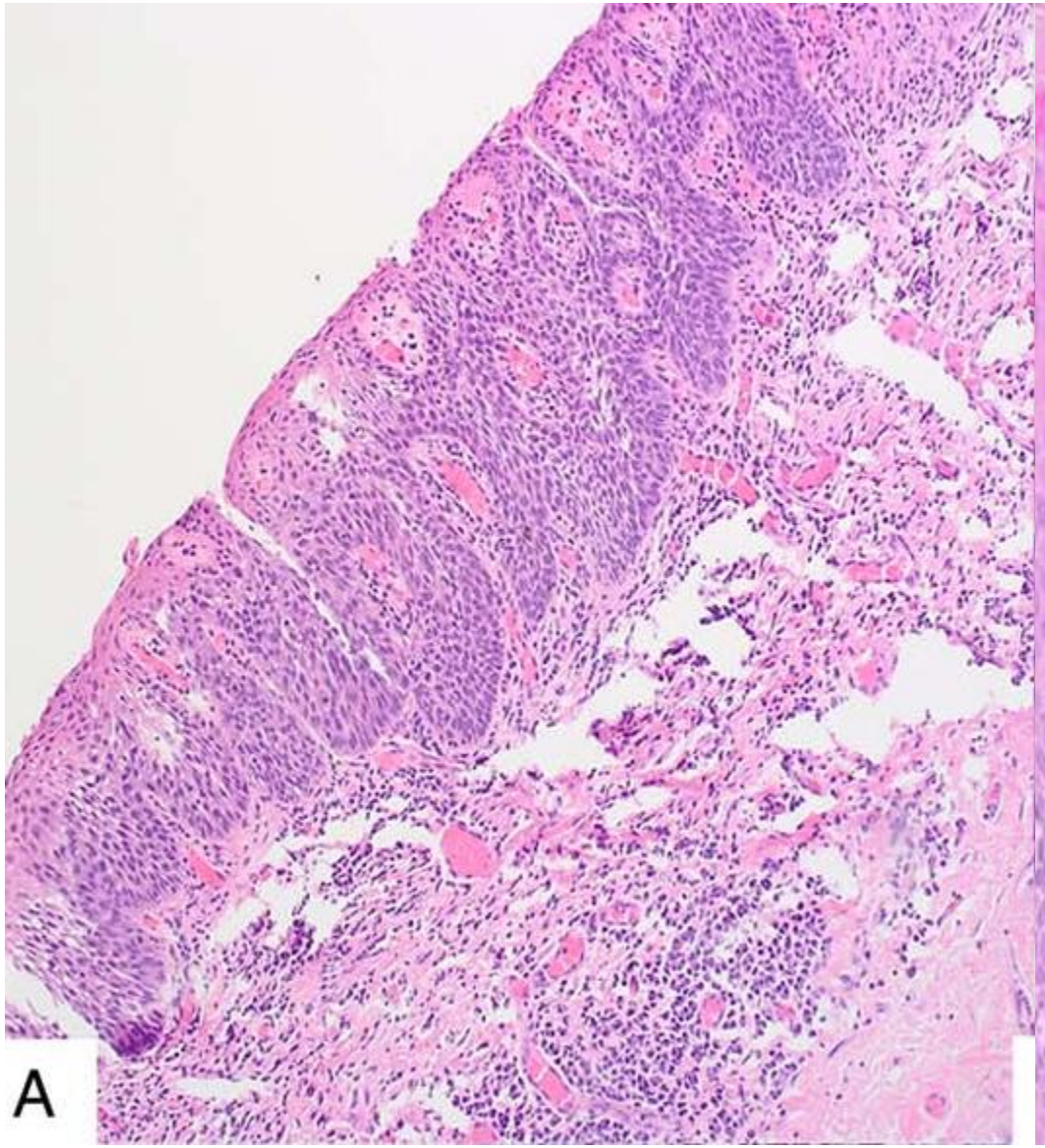
A

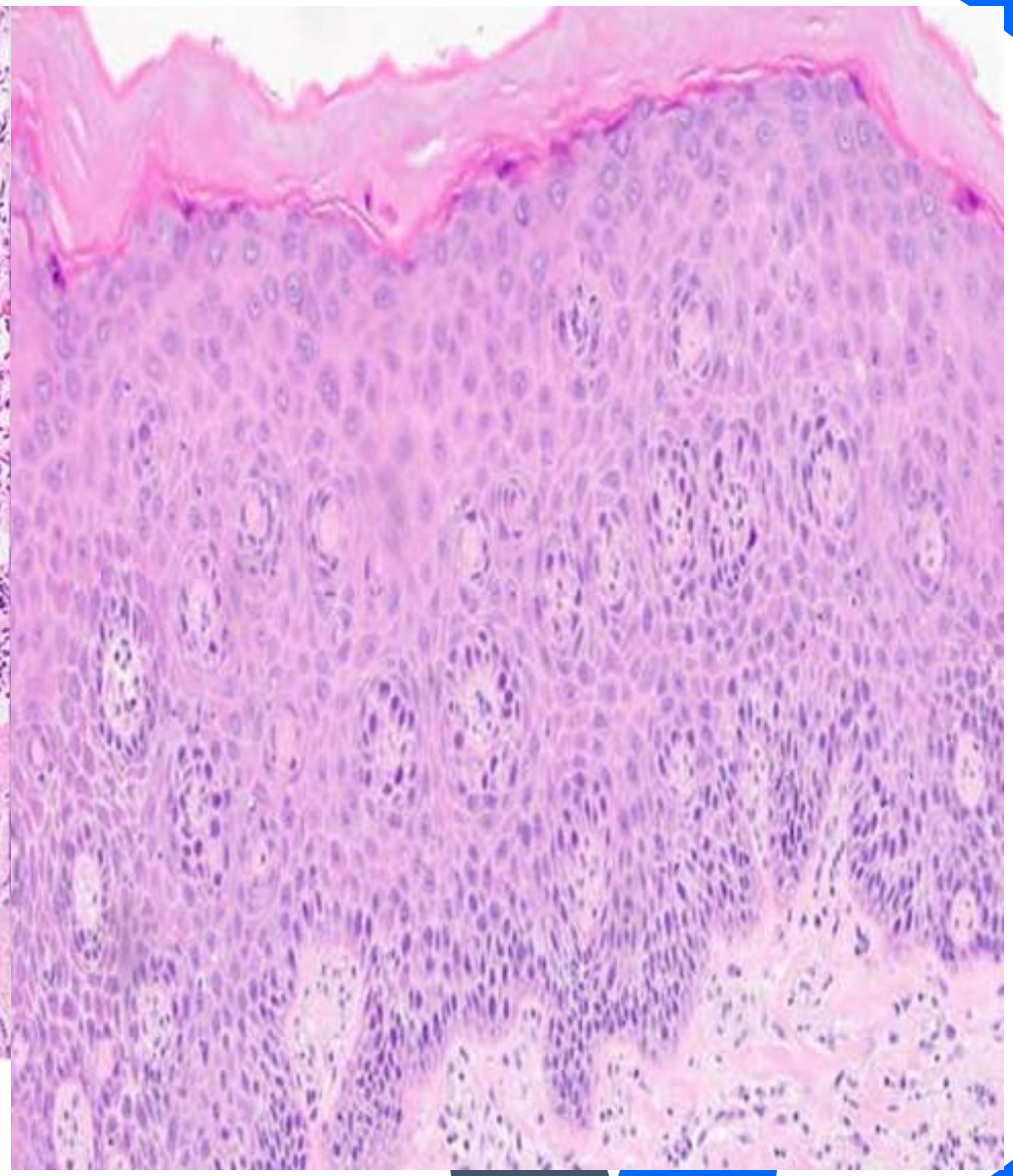

Subtle dVIN Vs normal Epithelium

presence of mild basal atypia, and which are largely devoid of the other supportive morphologic features that are variably seen in the other variants of dVIN (Day et al)

In biopsies- CPC is paramount

In excision- key issue is evaluating margins

Adv Anat Pathol 2025;32:4–19

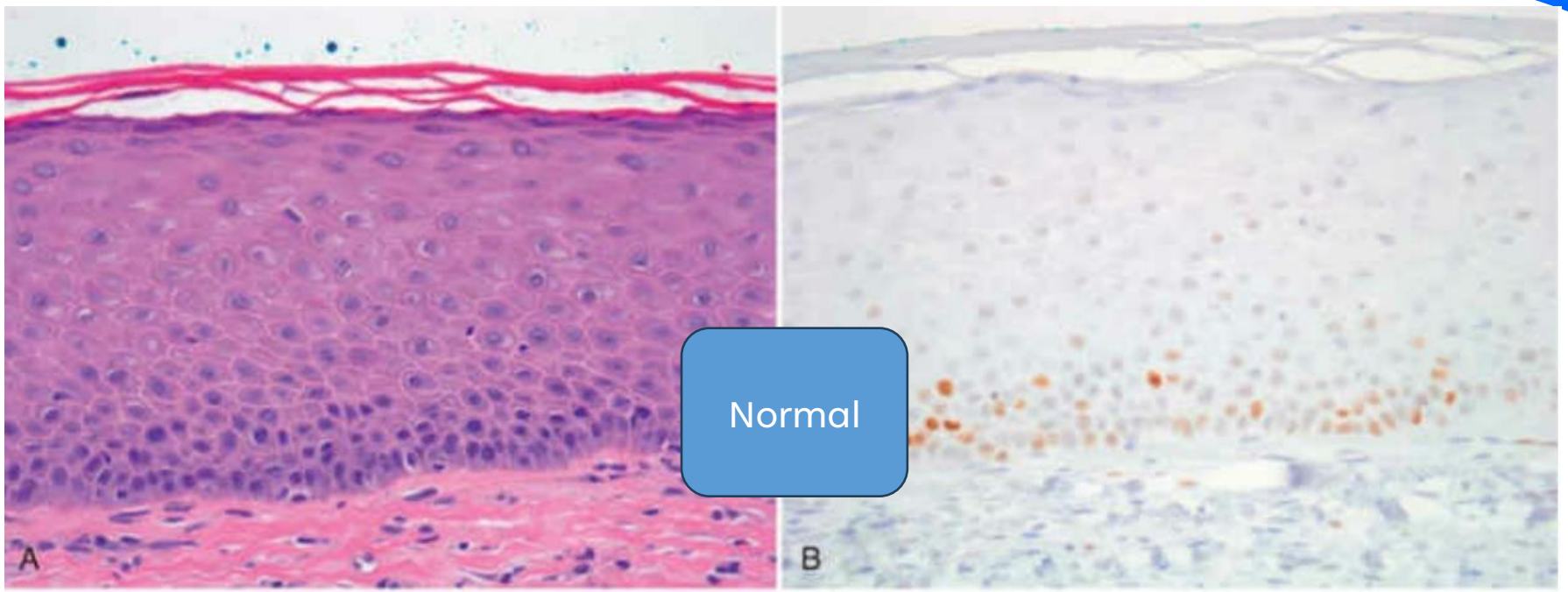

Normal

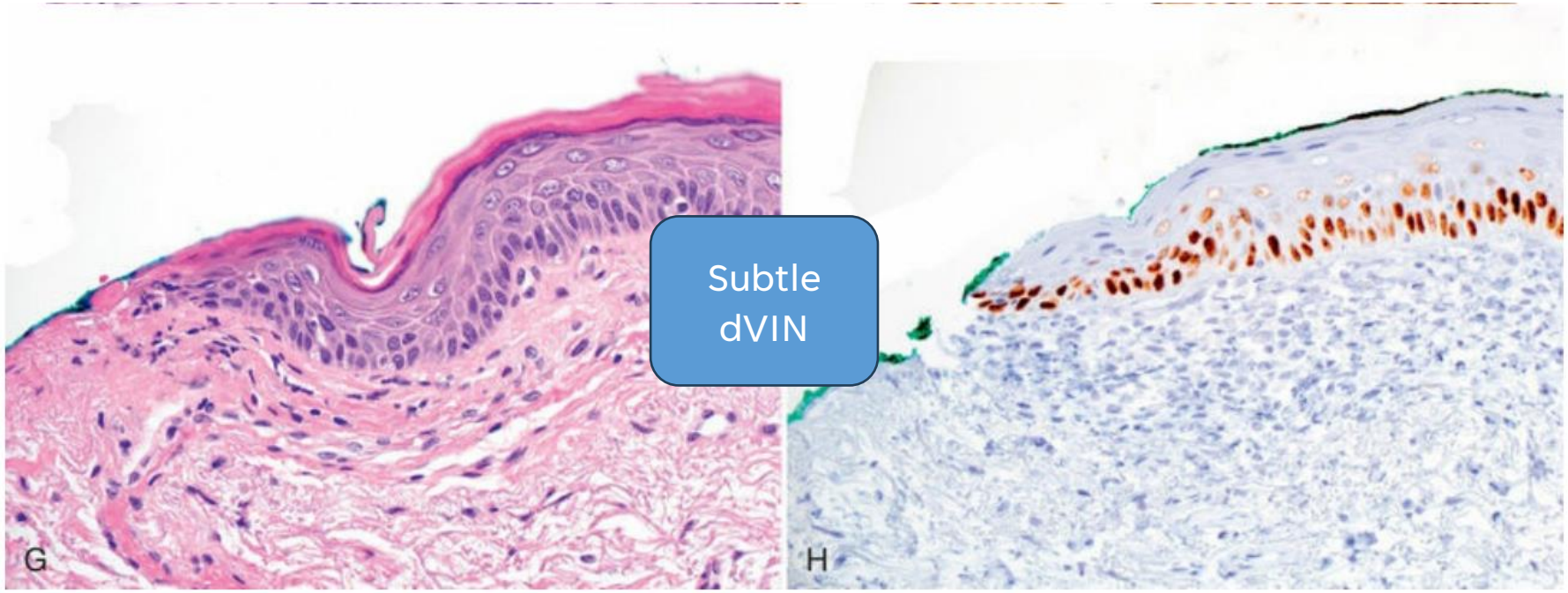

Subtle dVIN

Can dVIN be p53 wild-type?

TABLE 2. Reported Frequencies of p53/*TP53* Abnormalities in dVIN, Inclusive Only of Cases Reported Since the Beginning of 2020

References	Frequency of p53/*TP53* abnormality (%)	Frequency of p53/*TP53* wild-type status (%)	Study modality	No. studied cases
Rakislova et al[48]	69.3	30.7	IHC	186
Day et al[51]	82	18	IHC	153
Zieba et al[68]	53	47	Sequencing	19
Liu et al[86]*	94	6	IHC	16
Tessier-Cloutier et al[49]	85	15	Sequencing	13
Pors et al[45]	86	14	Sequencing	7
Dasguta et al[98]	74	26	IHC	56
Zare et al[99]	95	5	IHC	21
Hofstetter et al[107]	86	14	IHC	29
Roberts et al[52]	50	50	IHC	52
Average	77.4	22.6	NA	552 (total)

*The only p53 wild-type dVIN case was characterized as displaying "markedly reduced p53 staining as compared with adjacent benign squamous epithelium, with a staining pattern that was very close to a null staining pattern."

IHC indicates immunohistochemistry; NA, not applicable.

Adv Anat Pathol 2025;32:4–19

ISSVD accepts p53 wild-type status as still being compatible with their definition of dVIN

WHO classification lists p53 abnormality as a “desirable” (but not “essential”) criterion for HPV independent VIN

-initiating driver event or are acquired as a secondary event???

p53 IHC is a vital component not only in the primary diagnosis of dVIN in biopsies but also in the assessment of the “field of abnormality” as well as the margins around the invasive component in excision specimens.

When a wild-type staining pattern is observed, the diagnostic decision tree should remain centered on traditional morphologic features and/or other putative diagnostic biomarkers

Adv Anat Pathol 2025;32:4–19

Other biomarkers: CK17 and SOX 2

Article

Expression of CK17 and SOX2 in Vulvar Intraepithelial Neoplasia: A Comprehensive Analysis of 150 Vulvar Lesions

Nikki B. Thuijs [1,2,†], Féline O. Voss [1,2,†], Patricia C. Ewing-Graham [3], Shatavisha Dasgupta [3,4], Johannes Berkhof [5], Johan Bulten [6], Koen van de Vijver [7] and Maaike C. G. Bleeker [1,2,*]

Article

Evaluation of Immunohistochemical Markers, CK17 and SOX2, as Adjuncts to p53 for the Diagnosis of Differentiated Vulvar Intraepithelial Neoplasia (dVIN)

Shatavisha Dasgupta [1,*], Senada Koljenović [1], Thierry P. P. van den Bosch [1], Sigrid M. A. Swagemakers [1,2], Nick M. A. van der Hoeven [3,4], Ronald van Marion [1], Peter J. van der Spek [1,2], Helena C. van Doorn [4], Folkert J. van Kemenade [1,†] and Patricia C. Ewing-Graham [1,†]

CK17

NEGATIVE

No expression

Outer rooth sheeth of hair follicle always stains positive

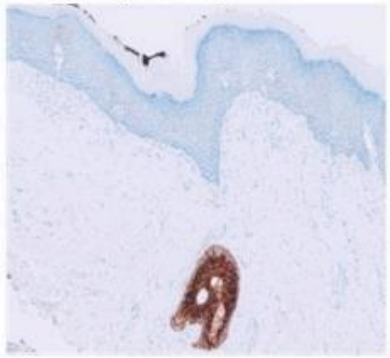

Patchy, moderate

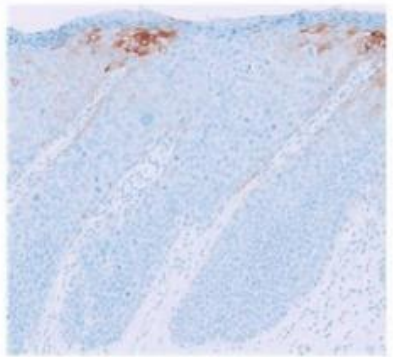

POSITIVE

Diffuse, partial thickness, strong intensity

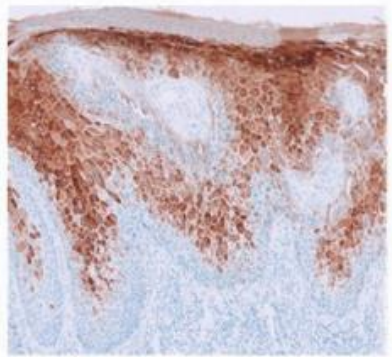

Diffuse, full-epithelial, moderate intensity

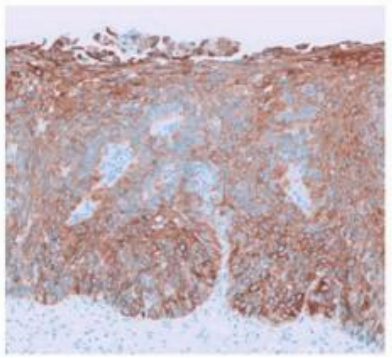

SOX2

NEGATIVE

No expression

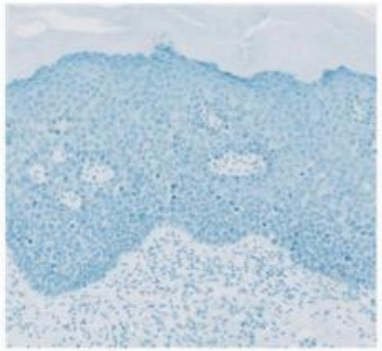

Scattered, weak

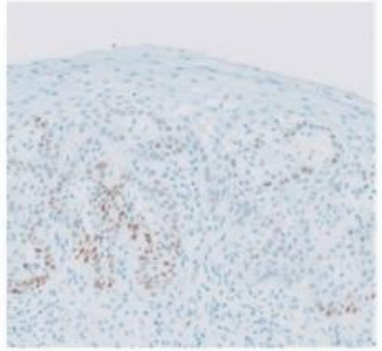

POSITIVE

Diffuse, partial thickness, moderate intensity

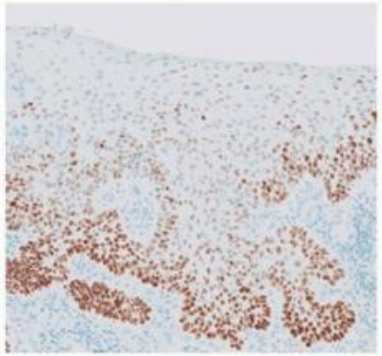

Diffuse, full-epithelial, strong intensity

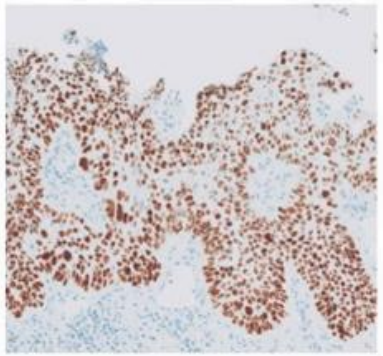

Positive staining is generally defined as strong, full-thickness, or partial-thickness staining, has been reported to be present in 80% to 100% of dVIN cases

Some positive also described in HSIL, LS, LSC- typically focal and superficial or intermediate, partial thickness

GATA 3

-GATA3 demonstrates a distinctive pattern of basal and parabasal loss of expression in ~90% of dVIN cases (loss of expression in >25% of basal cells)

-Similar findings now documented in a small cohort of vaVIN.

-Most benign entities in the differential diagnosis, including LSC and LS, demonstrate retained expression of GATA3 (defined as expression in >75% of basal cells).

The scoring system [pattern 0 (no significant loss of basal layer staining, >75% staining), pattern 1 (25% to 75% staining), and pattern 2 (<25% staining)

Article | Published: 13 February 2018

Differential expression patterns of GATA3 in usual and differentiated types of vulvar intraepithelial neoplasia: potential diagnostic implications

Abha Goyal, Gloria Zhang & Bin Yang

Modern Pathology **31**, 1131–1140 (2018) | Cite this article

2985 Accesses | **23** Citations | **4** Altmetric | Metrics

GATA3 immunohistochemistry as a diagnostic adjunct for differentiated vulvar intraepithelial neoplasia: utility and limitations☆,☆☆

Somaye Y. Zare MD, Elmira Vaziri Fard MD, MPH, Oluwole Fadare MD*

OTHER BIOMARKERS

ORF1p: Positive expression

CK13 : reduced/Loss of expression in dVIN

D2-40 : dVIN shows a more intensive basal staining pattern compared to LS

HPV INDEPENDENT VIN (p53 wt) VIN

Emerging entities with Evolving Nomenclature-

VAAD
DEVIL
vLSC
VAM

HPVip53wt VaVIN

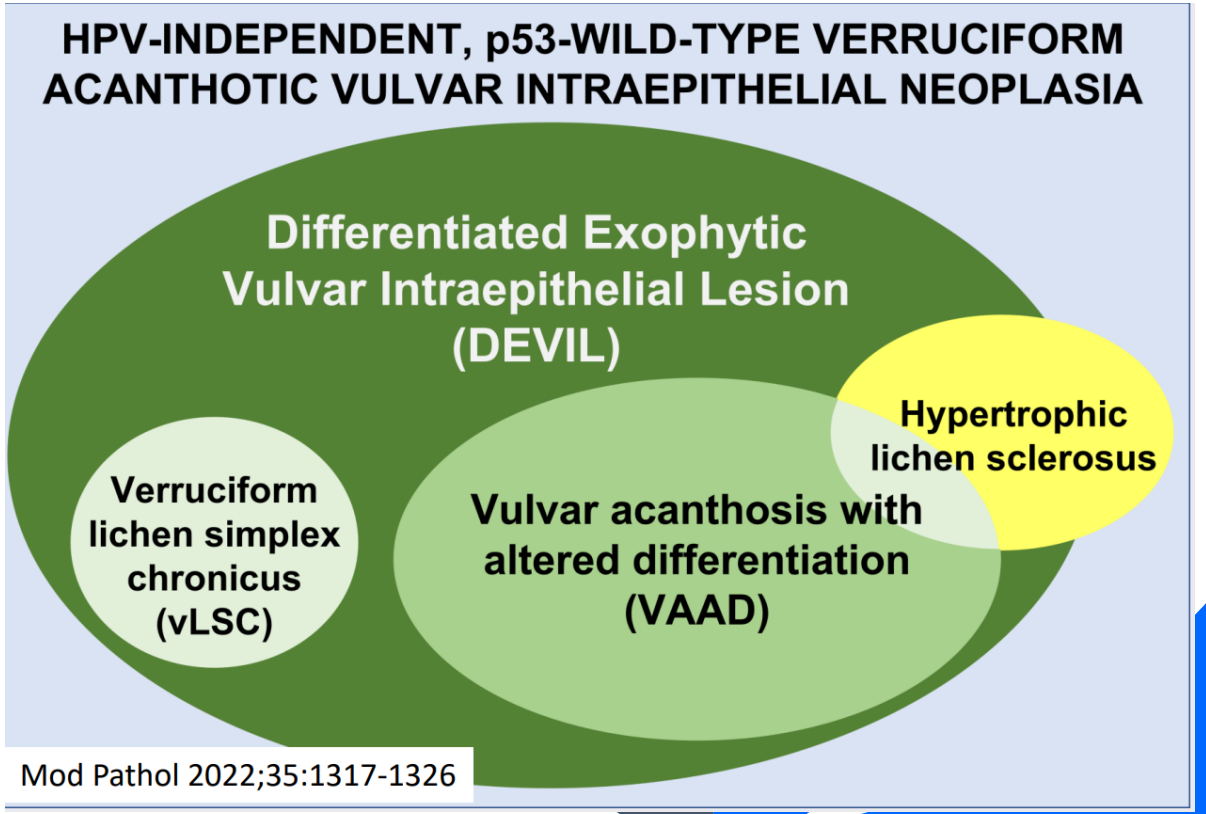

VERRUCIFORM/ACANTHOTIC VULVAR INTRAEPITHELIAL NEOPLASIA

2017 (Nooij et al)- VAAD

2017 (Watkin et al) – DEVIL

ISSVD (2021) - VAM

2021 (Roy et al)-VAAD, DEVIL, and vLSC variants within a spectrum of p53 wild-type, HPV-negative precursor lesions

2022 (Parra-Herran et al) a unifying diagnosis—vaVIN—that would encompass the features common to VAAD, DEVIL, and vLSC

Histomorphologic features

Five key criteria, all of which must be met before a diagnosis is rendered :

1. Acanthosis and/or verruciform architecture
2. Altered squamous differentiation
3. Absence of cytologic atypia
4. Negative or patchy p16 expression
5. Wild-type p53 expression

Parra-Herran C, Nucci MR, Singh N, et al. Mod Pathol. 2022;35:1317–1326.

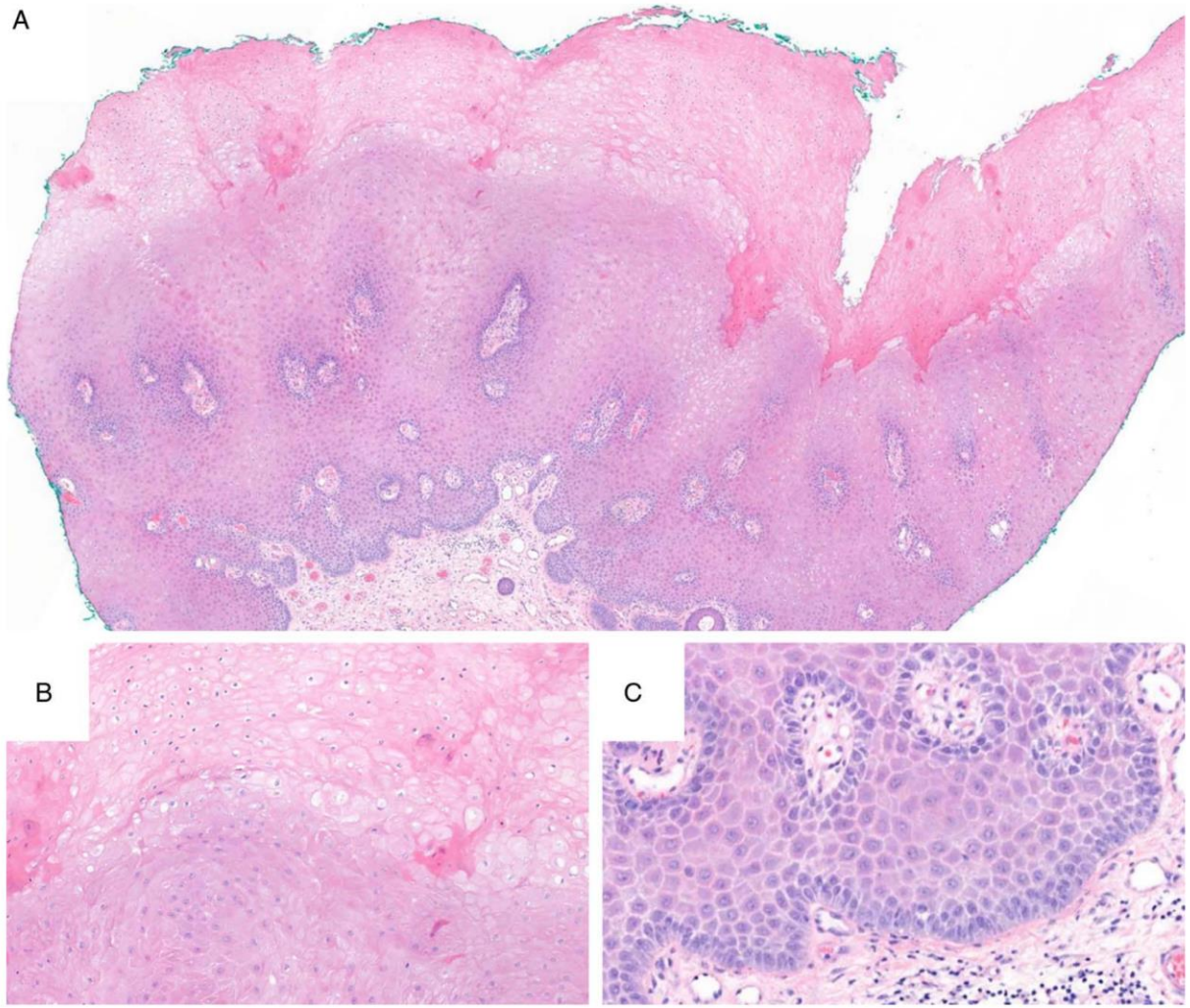

vaVIN
(VAAD variant)

Adv Anat Pathol 2025;32:4–19

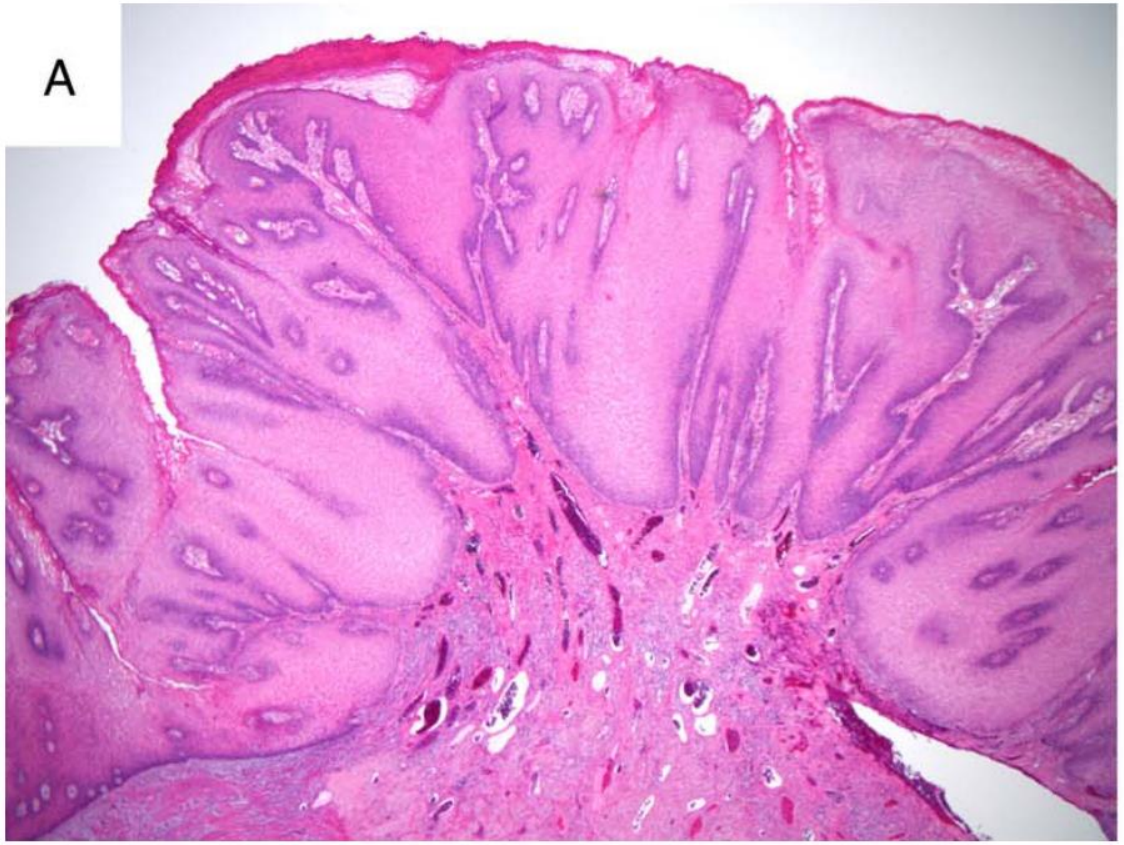

vaVIN
(DEVIL variant)

Adv Anat Pathol 2025;32:4–19

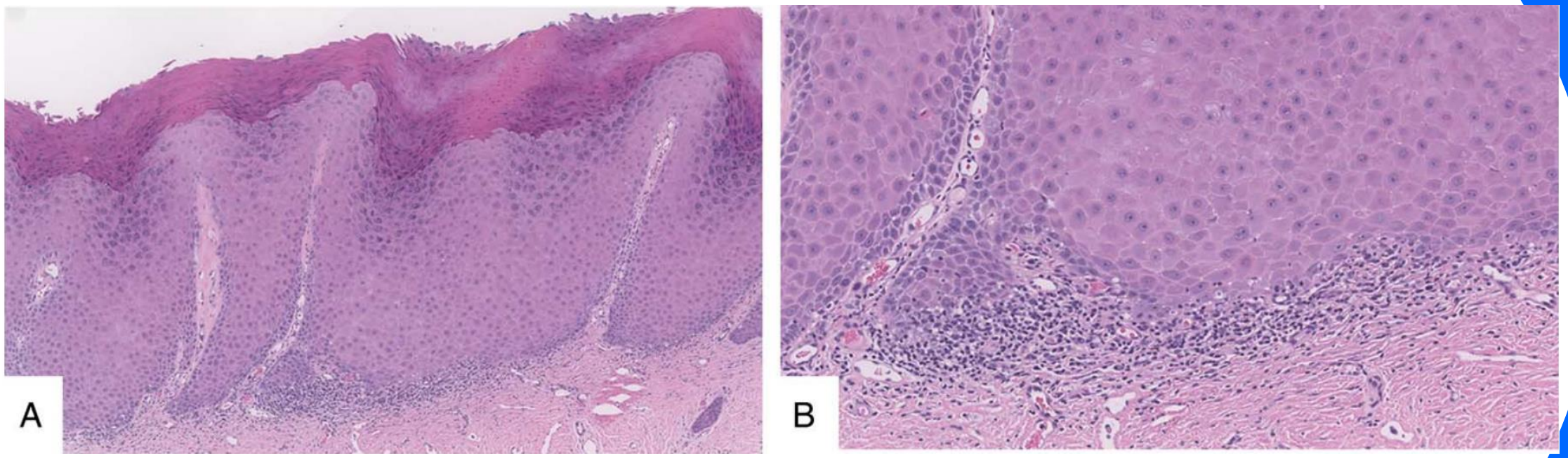

vaVIN
(vLSC variant)

Adv Anat Pathol 2025;32:4–19

Differential diagnosis

1. dVIN: atypia and p53

2. HPV-associated lesions (eg, condyloma acuminatum, HSIL with LSC)

Adv Anat Pathol 2025;32:4–19

3. Vulvar dermatoses (e.g, lichen simplex chronicus, hidradenitis suppurativa, lichen sclerosus).

4. Verrucous Carcinoma

BIOMARKERS

CK17

GATA 3

SOX 2

Histopathology 2024, **84**, 1212–1223. DOI: 10.1111/his.15156

Diagnosis of verruciform acanthotic vulvar intra-epithelial neoplasia (vaVIN) using CK17, SOX2 and GATA3 immunohistochemistry

Eleanor Cook,[1] Koen Van de Vijver[2,*] & Carlos Parra-Herran[1,*]
[1]*Department of Pathology, Brigham and Women's Hospital, Boston, MA, USA and* [2]*University Hospital Ghent, Ghent, Belgium*

Date of submission 27 December 2023
Accepted for publication 27 January 2024

While more studies are needed to confirm the staining patterns in vaVIN, utilization of a panel to include p16, p53, CK17, GATA3, and SOX2 before rendering a diagnosis of vaVIN is strongly recommended, pending access to the stain

Example cases

Case 1

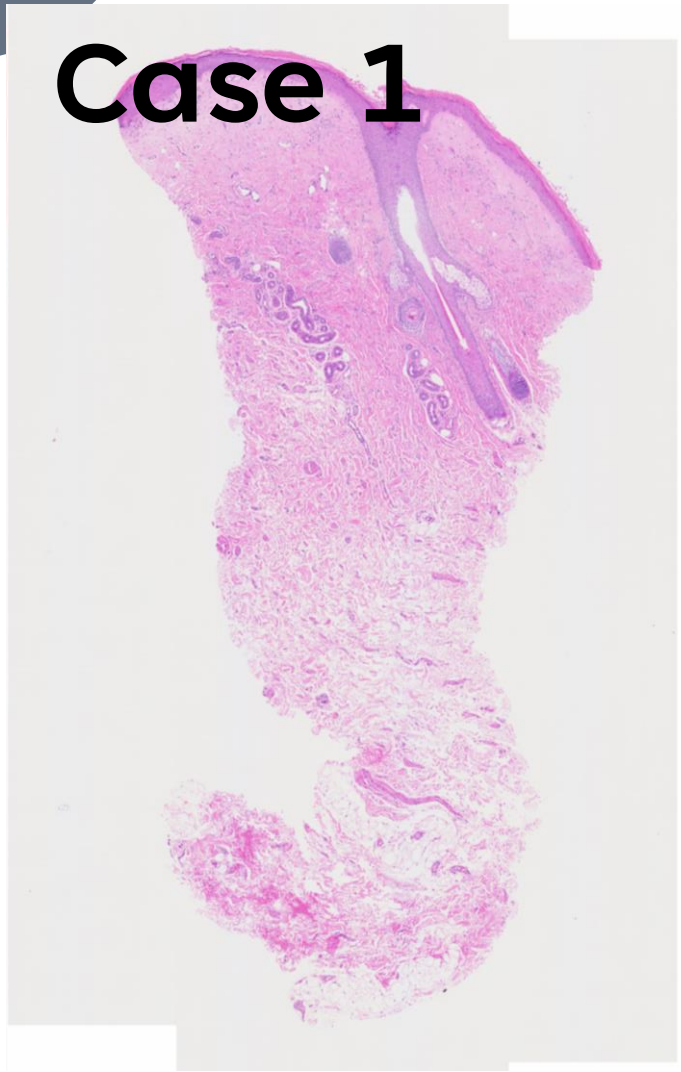

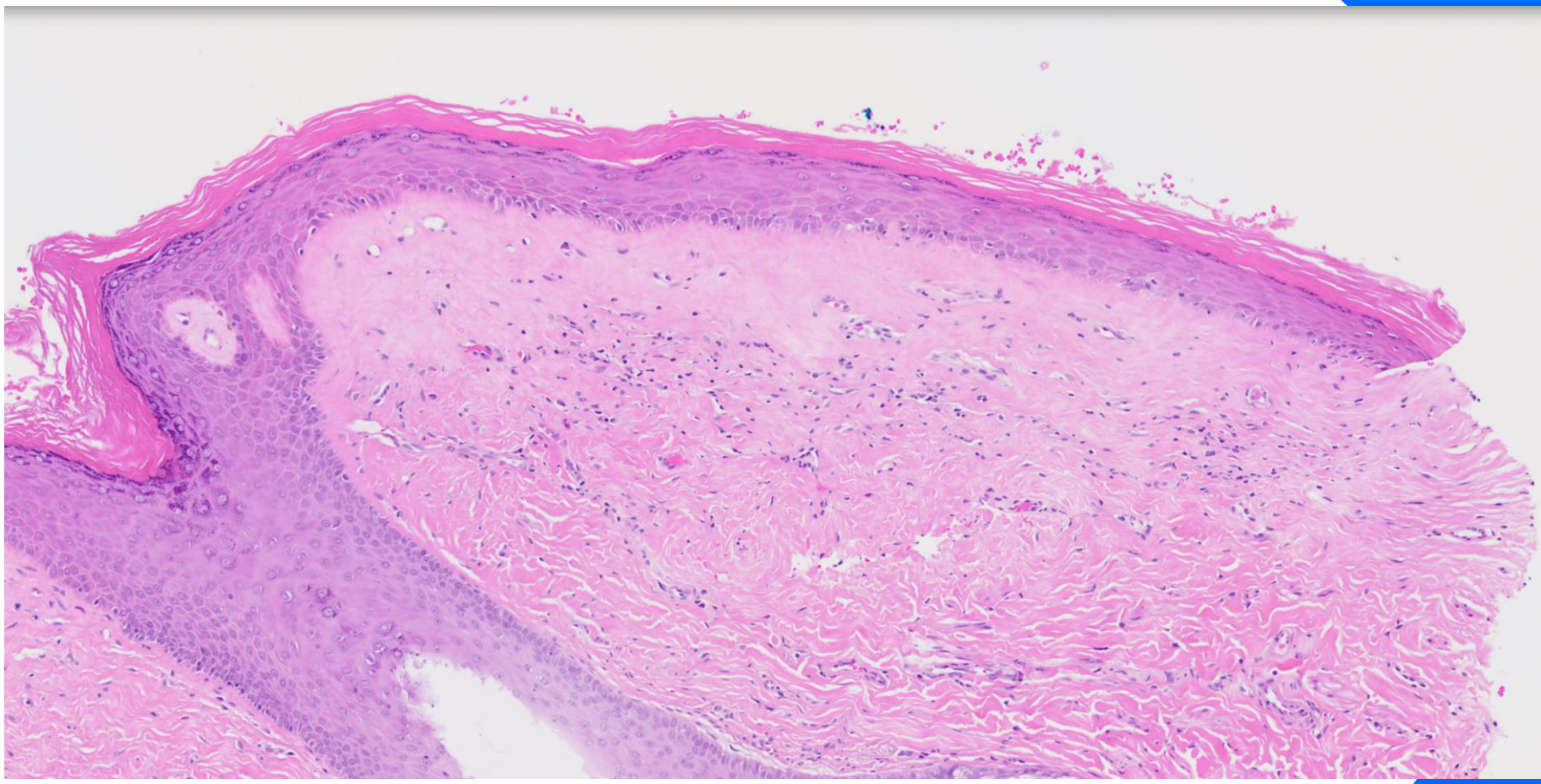

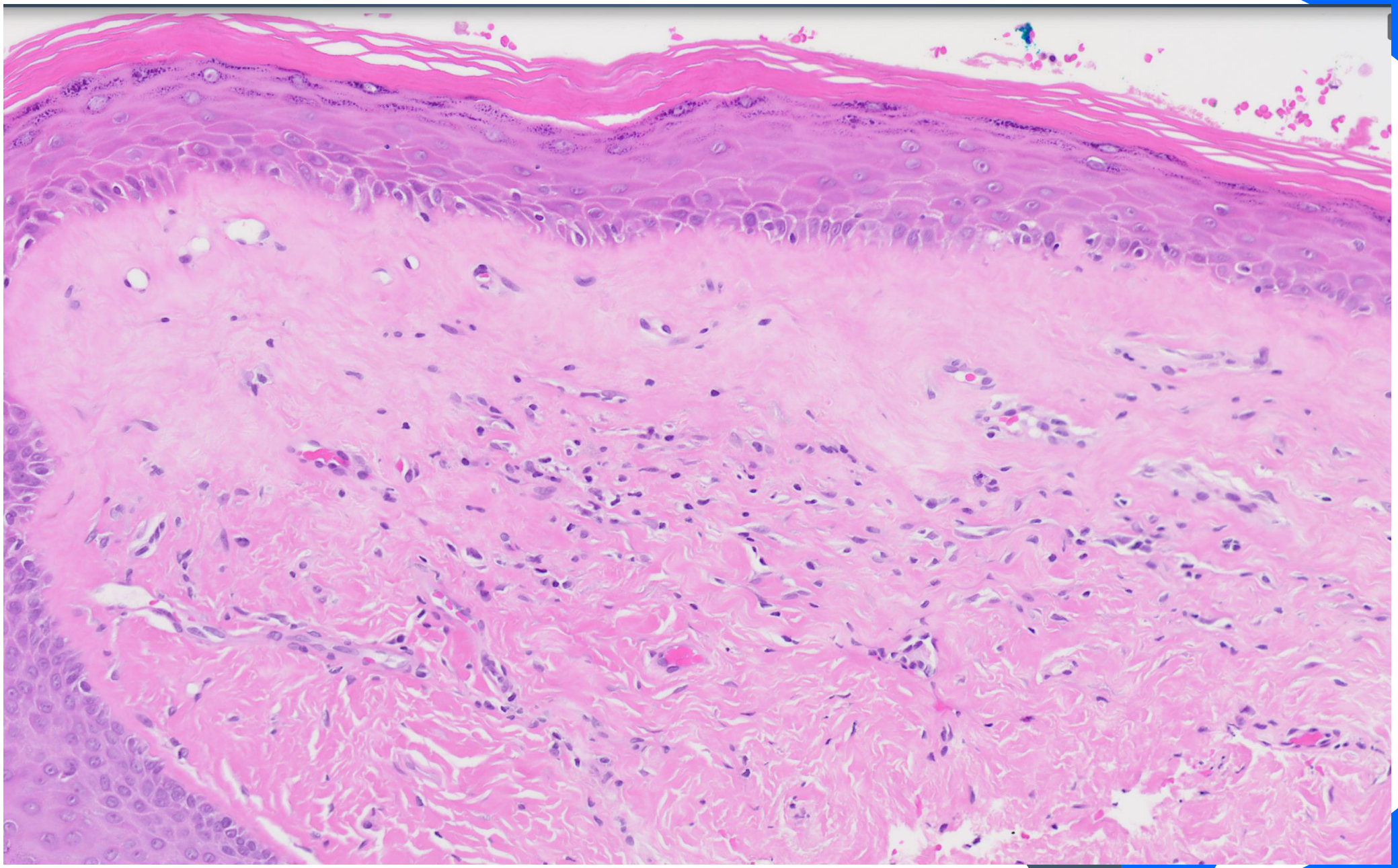

Poll 1

- HSIL, HPV-ASSOCIATED
- DIFFERENTIATED VIN
- VaVIN
- Lichen sclerosus
- DON’T KNOW

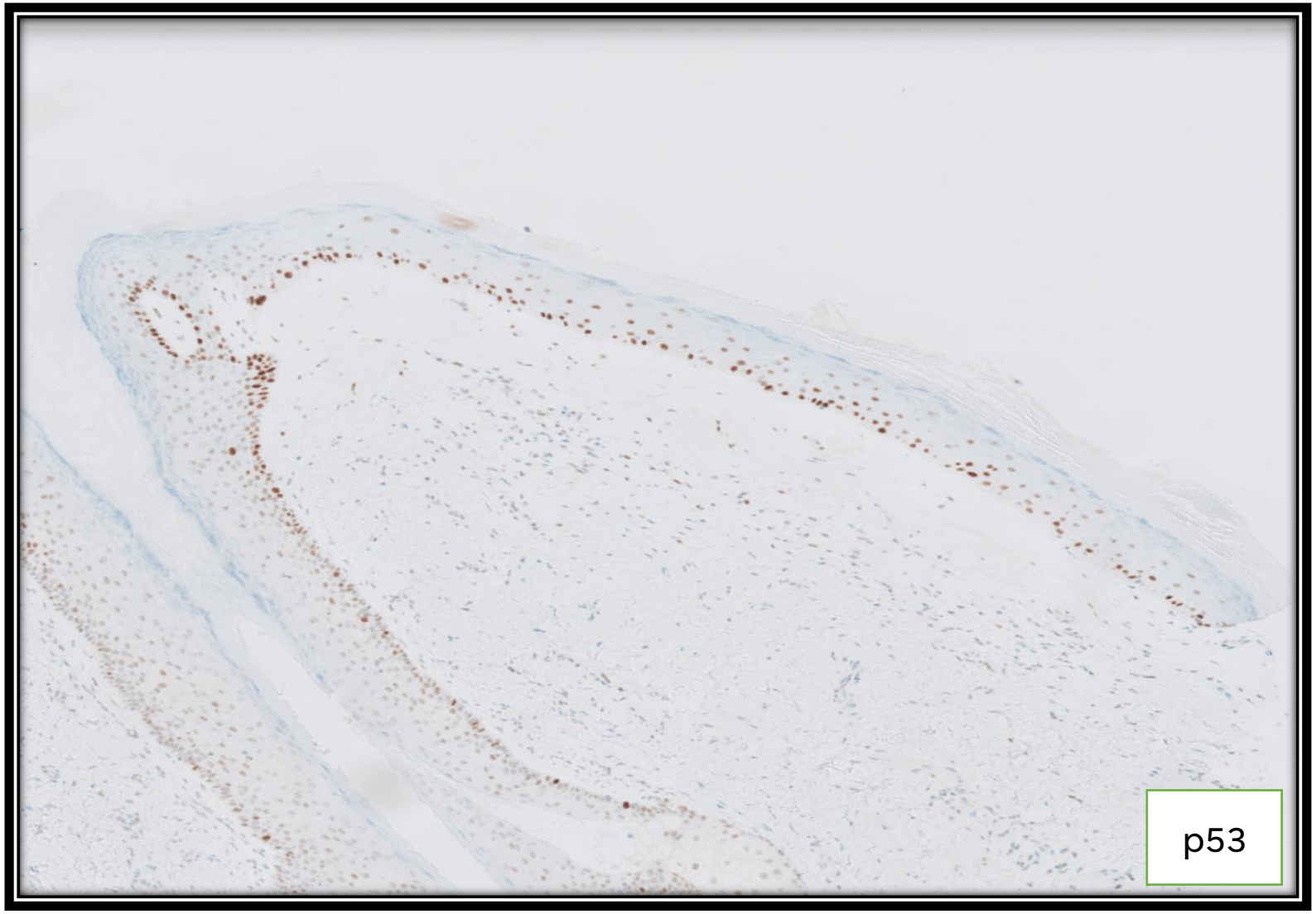

Lichen sclerosus

Case 2

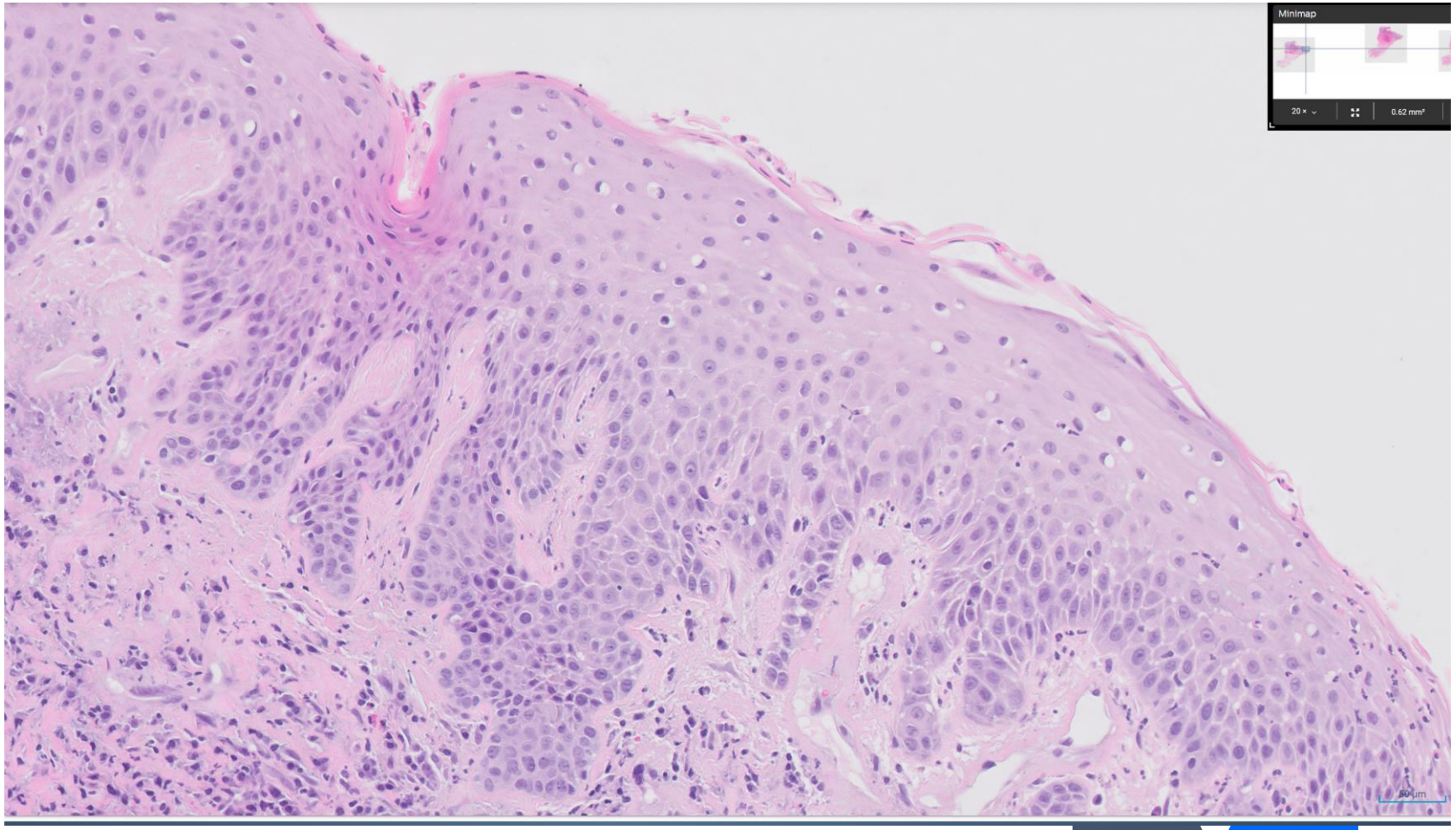

Poll 2

- HSIL (dVIN-like)
- DIFFERENTIATED VIN
- VaVIN
- Lichen sclerosus
- Don’t know

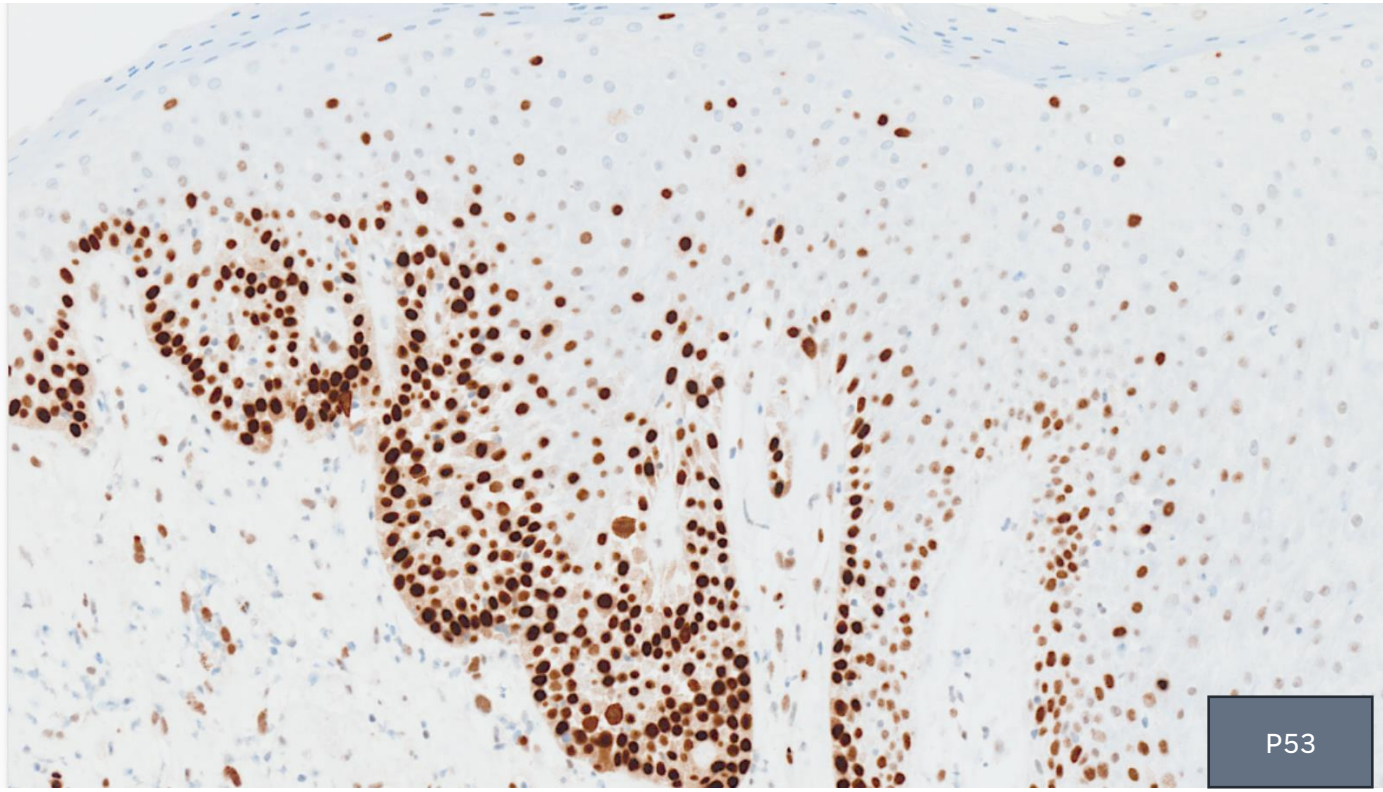

P16- negative (non-block)

dVIN

Case 3

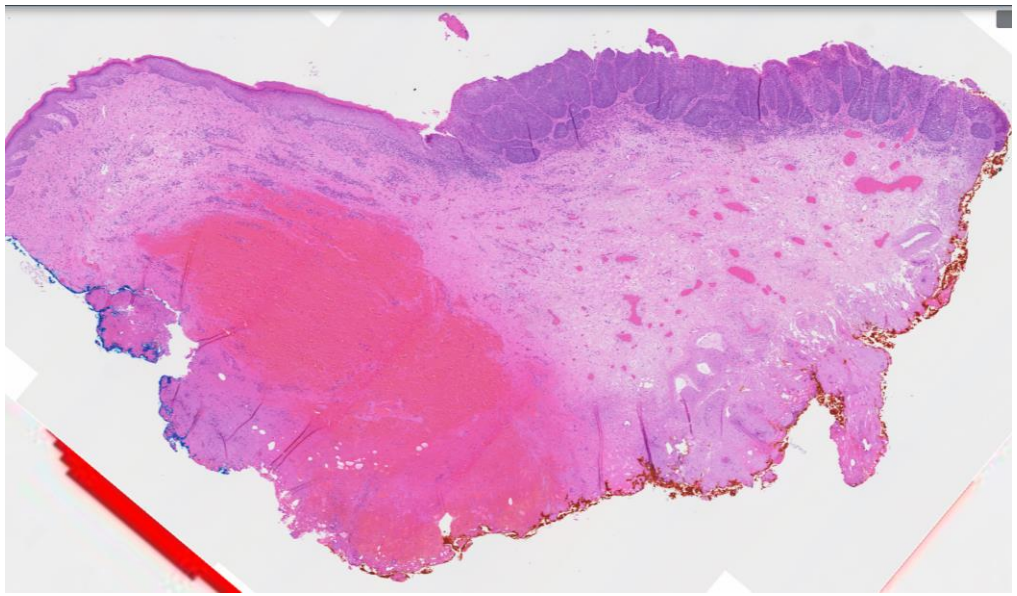

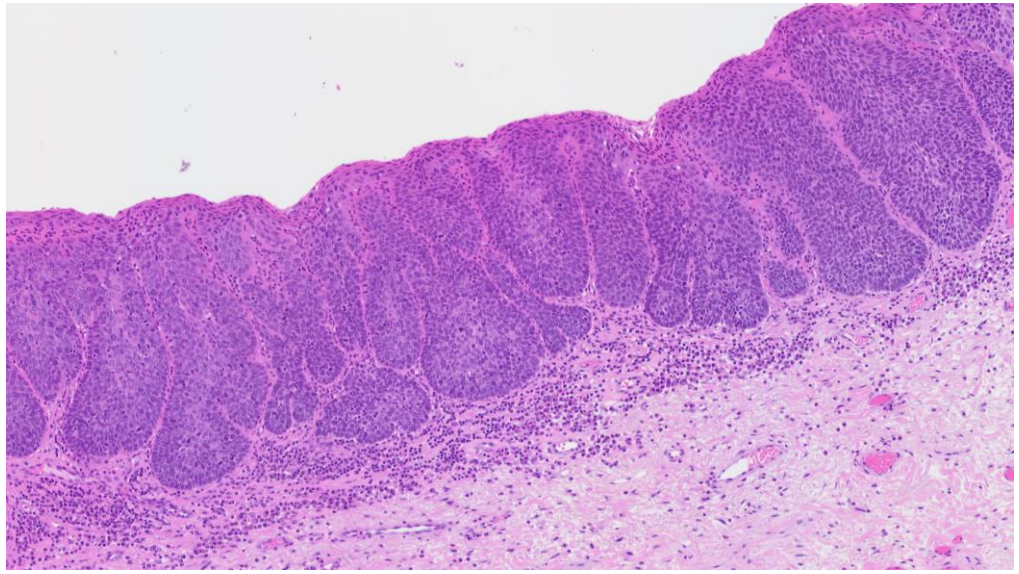

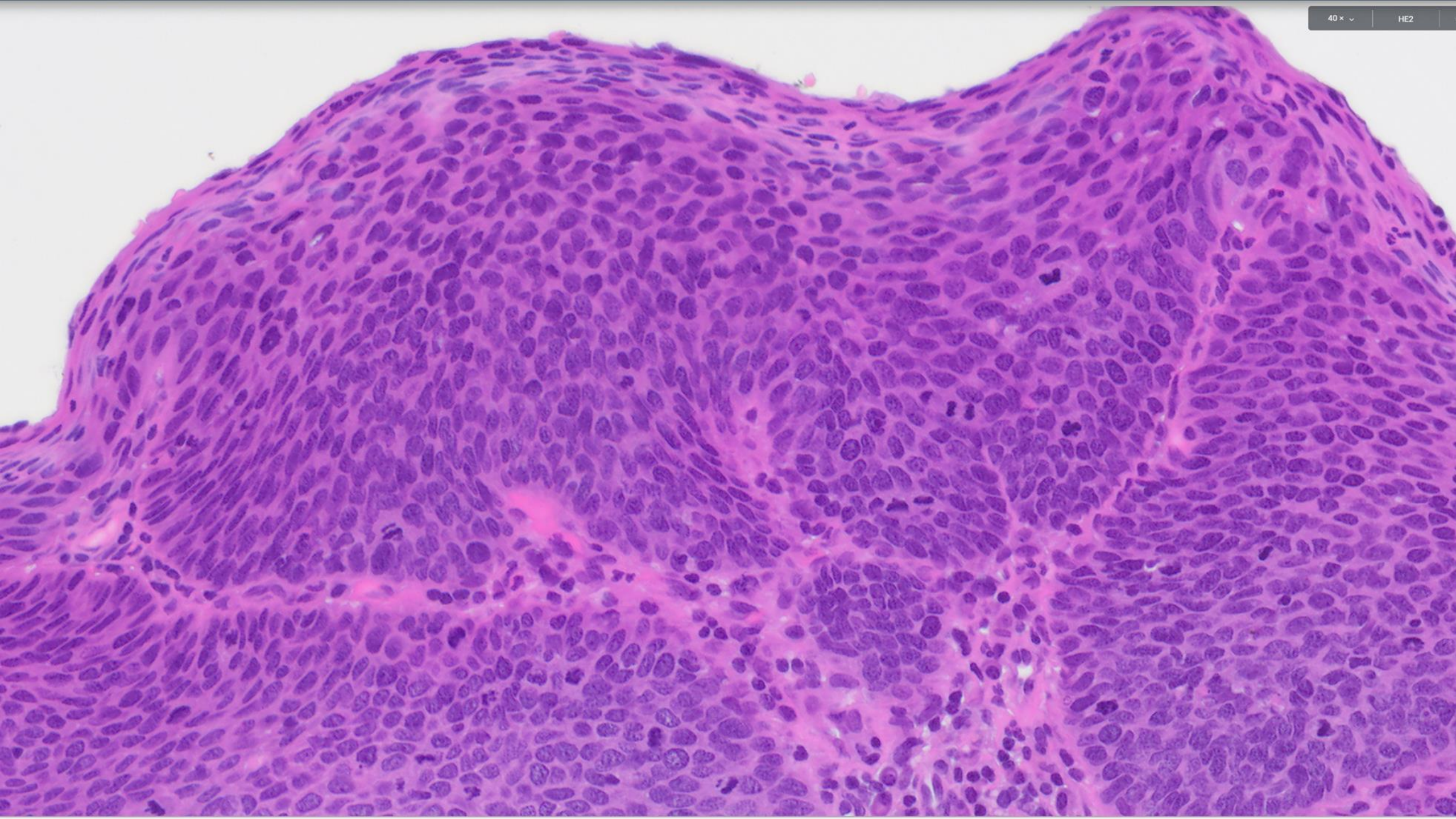
40 ×
HE2

Poll 3

- HSIL, HPV-ASSOCIATED
- DIFFERENTIATED VIN (BASALOID VARIANT)
- VaVIN
- DON’T KNOW

IHC

P16

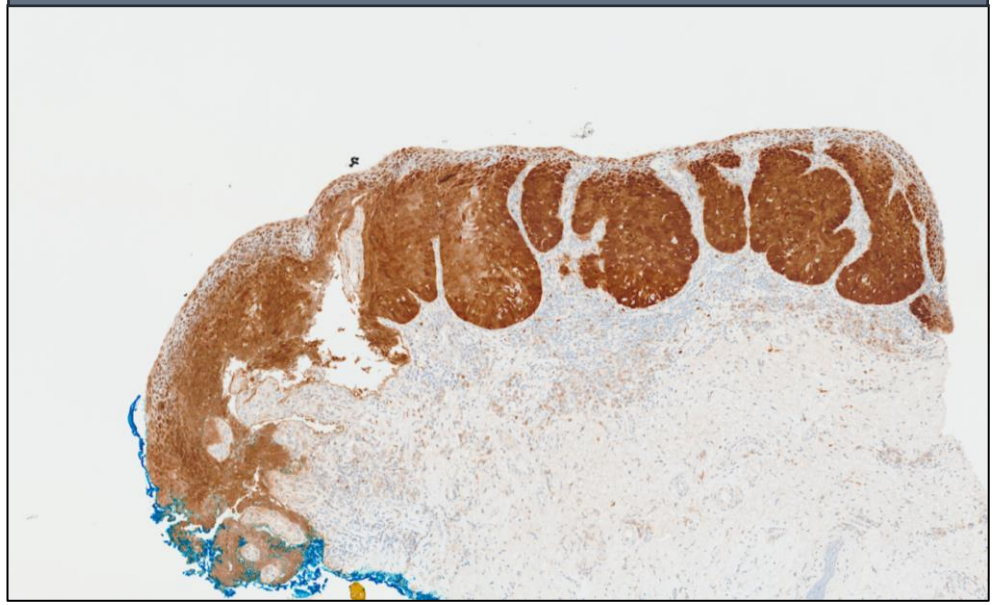

P53

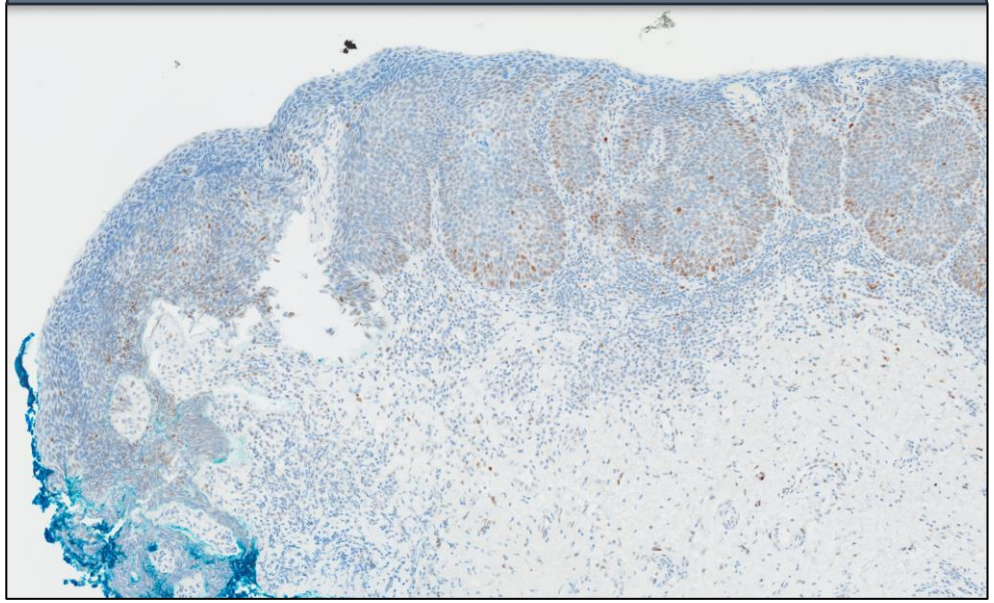

Diagnosis

HIGH GRADE SQUAMOUS INTRAEPITHELIAL LESION (HSIL), HPV-ASSOCIATED

Case 4

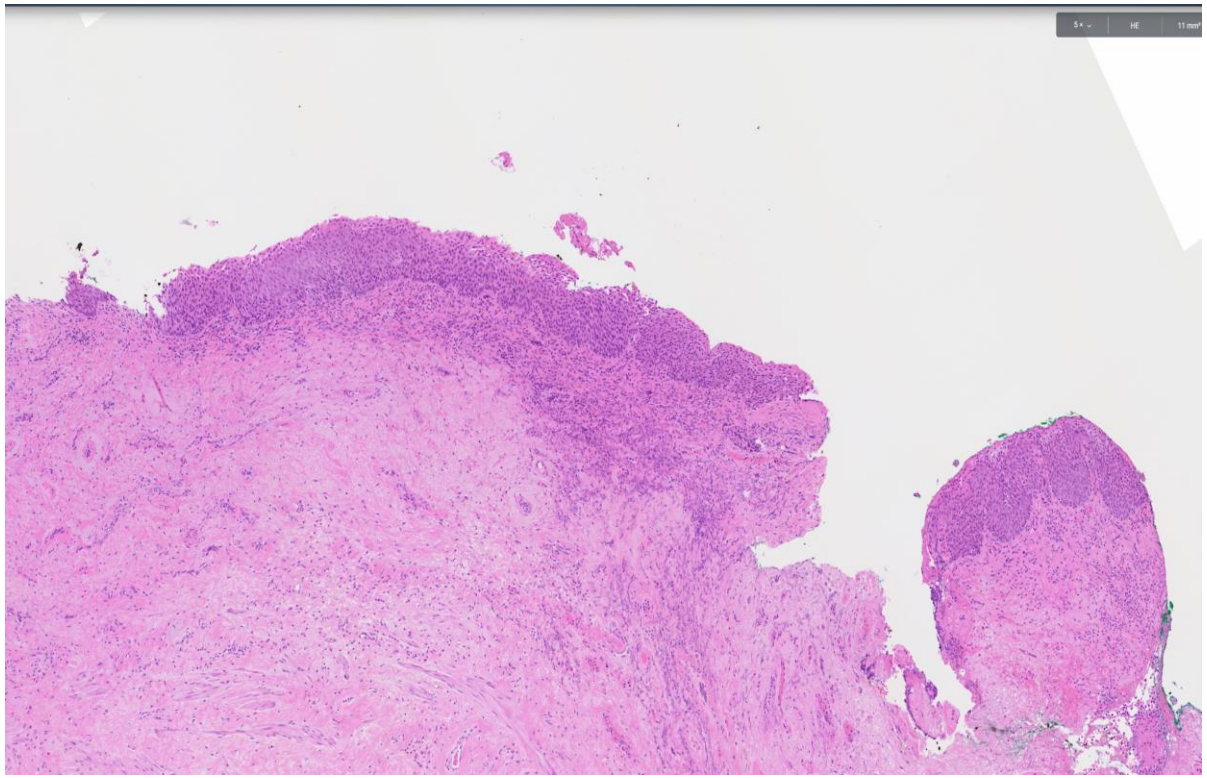

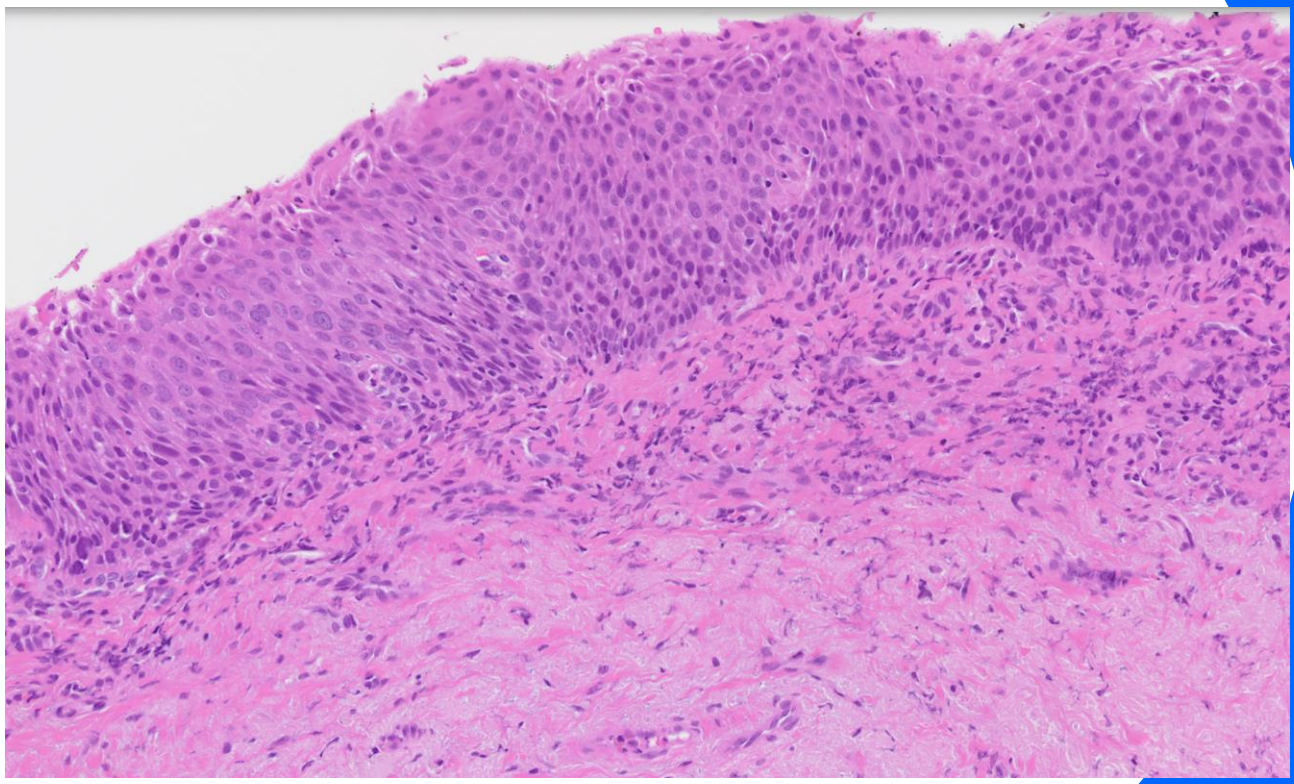

Poll 4

- HSIL, HPV-ASSOCIATED
- DIFFERENTIATED VIN (BASALOID VARIANT)
- VaVIN
- DON’T KNOW

IHC



P16- negative (non-block)

dVIN

Case 5

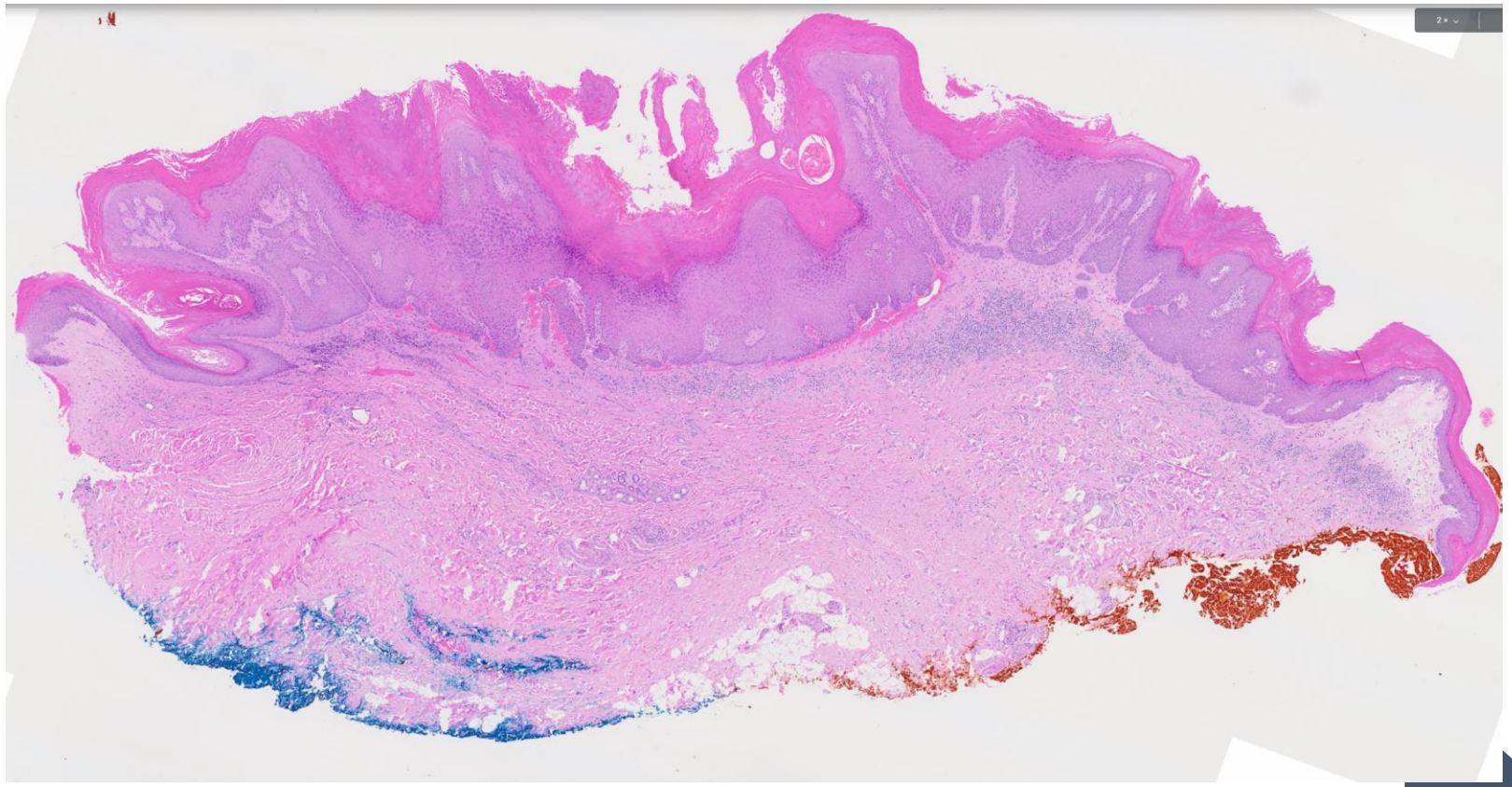

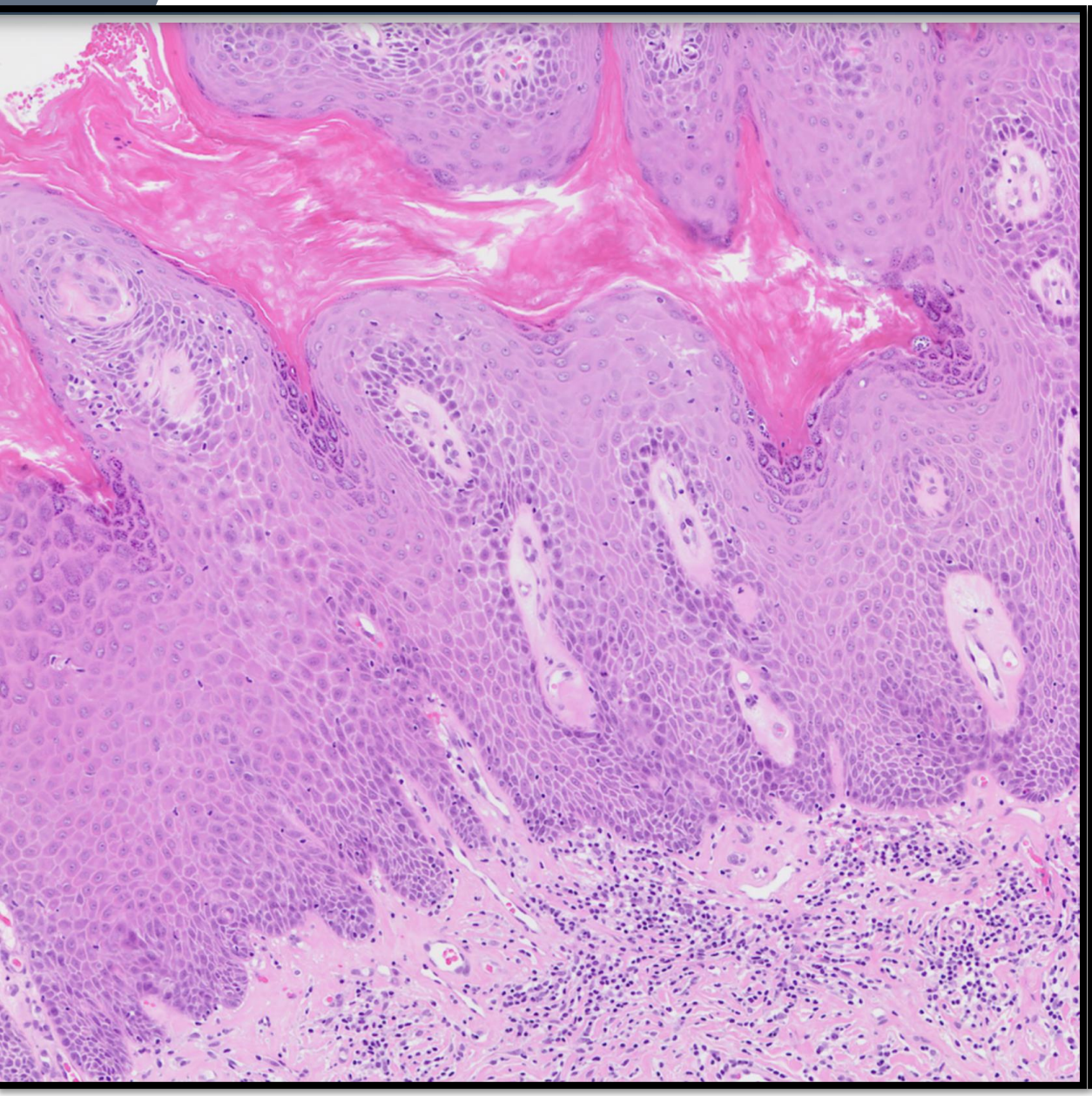

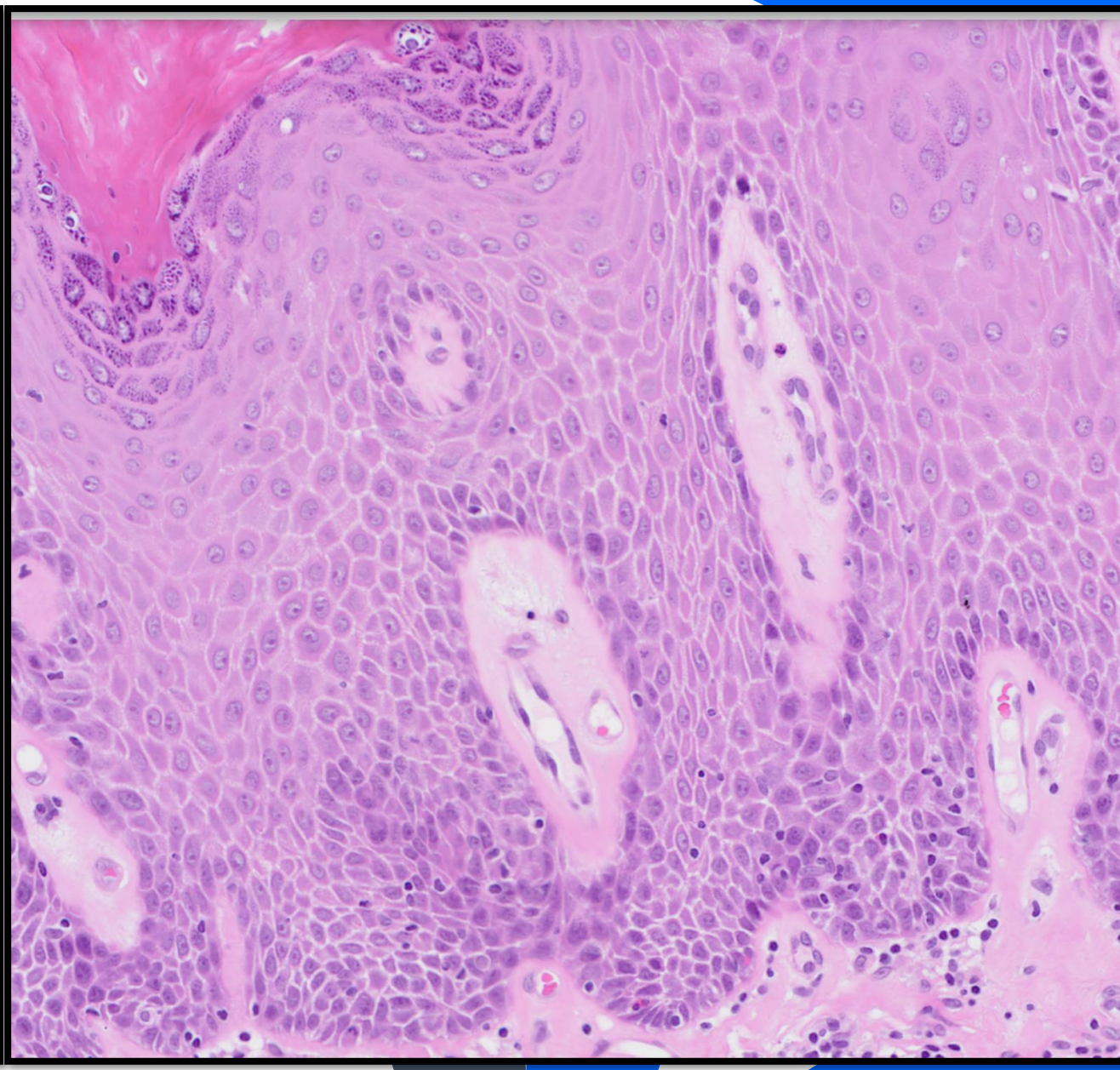

Poll 5

- HSIL (dVIN-like)
- DIFFERENTIATED VIN
- VaVIN
- Lichen sclerosus
- Don’t know

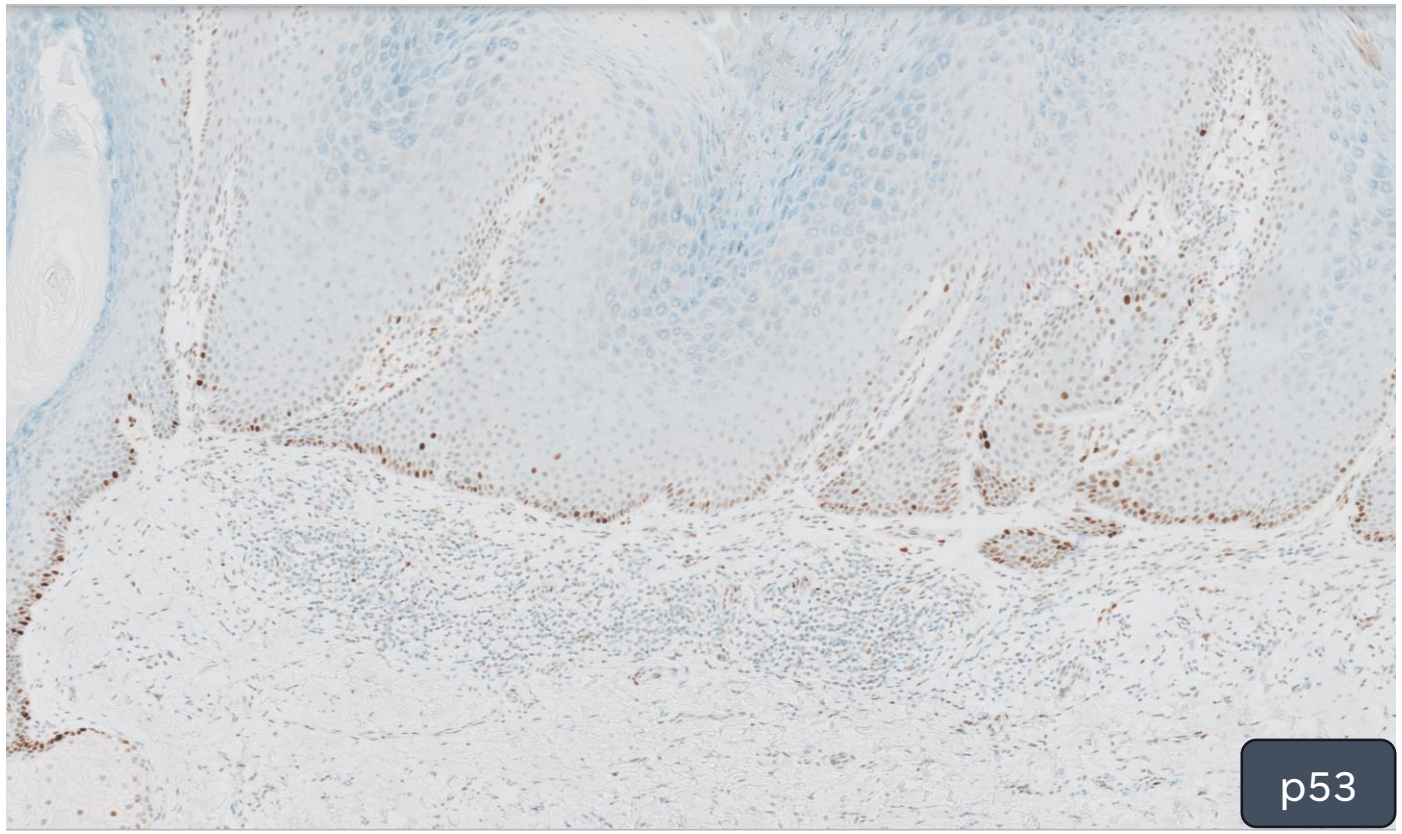

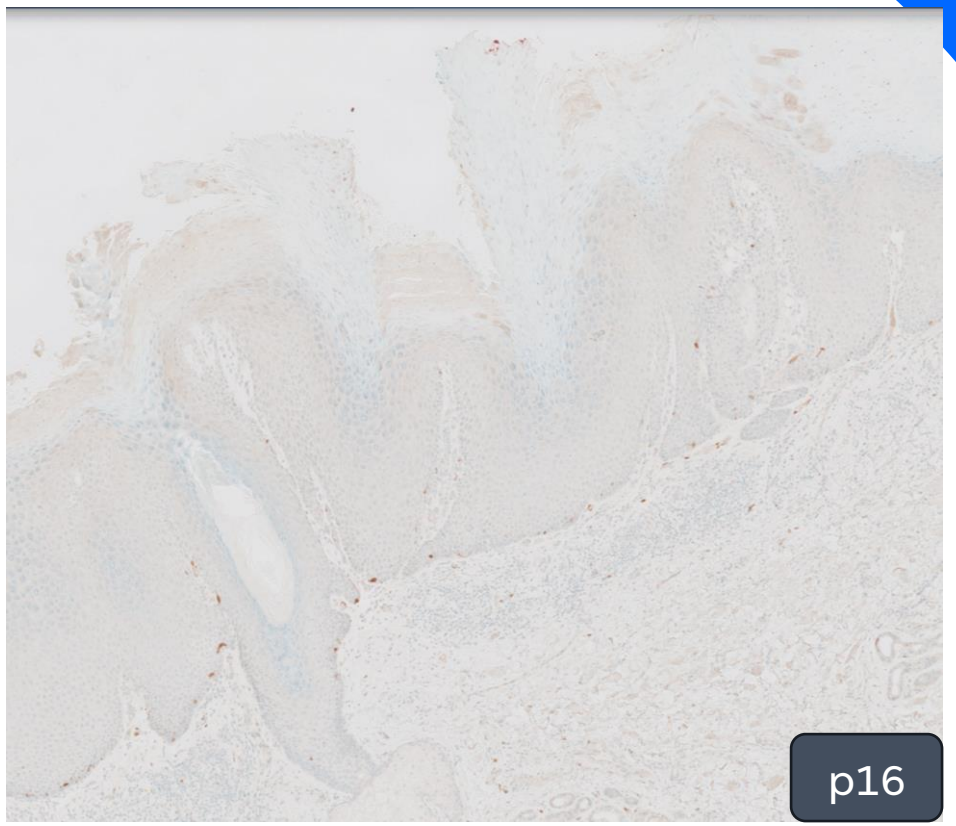

HPVi p53 wt VAVIN

Case 6

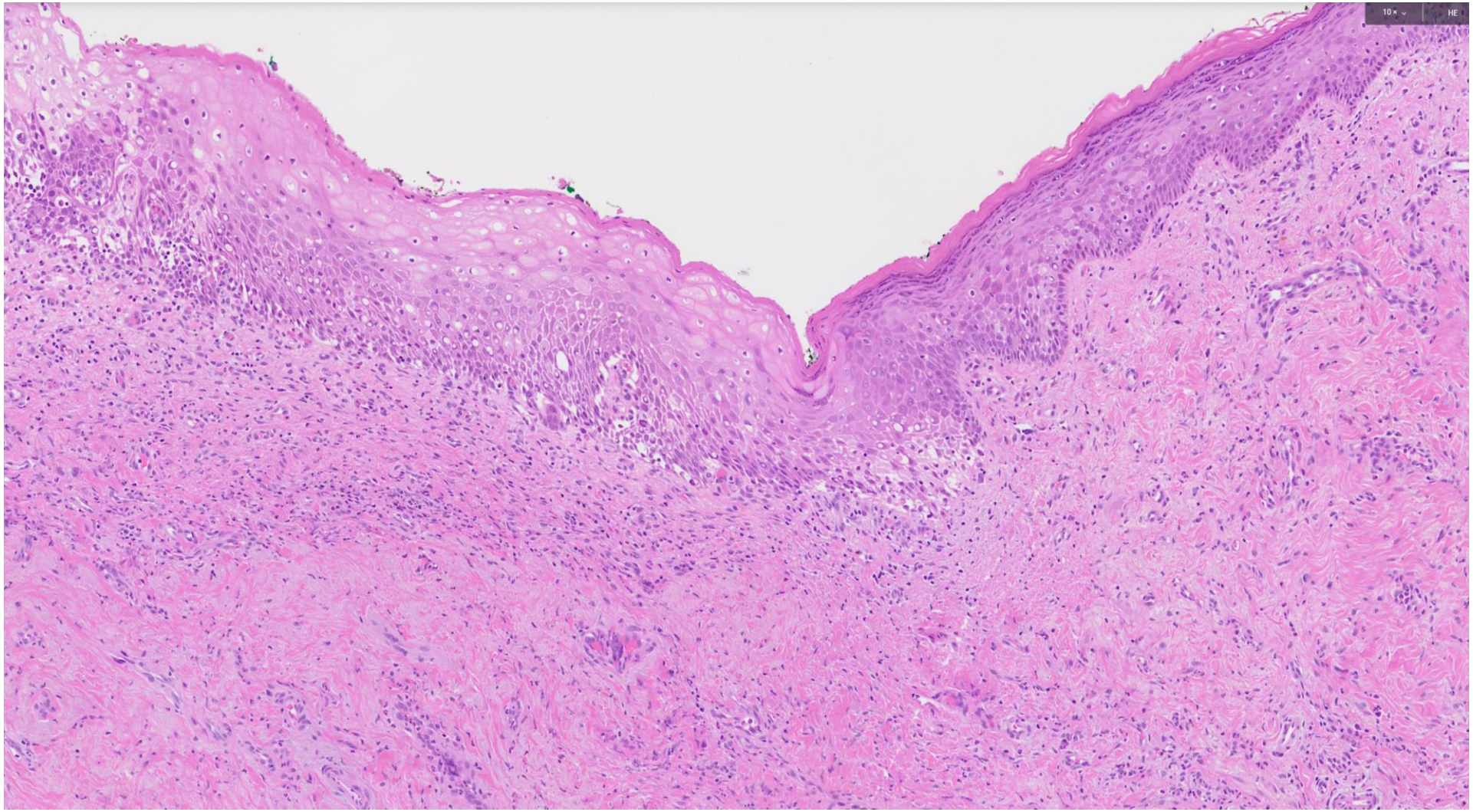

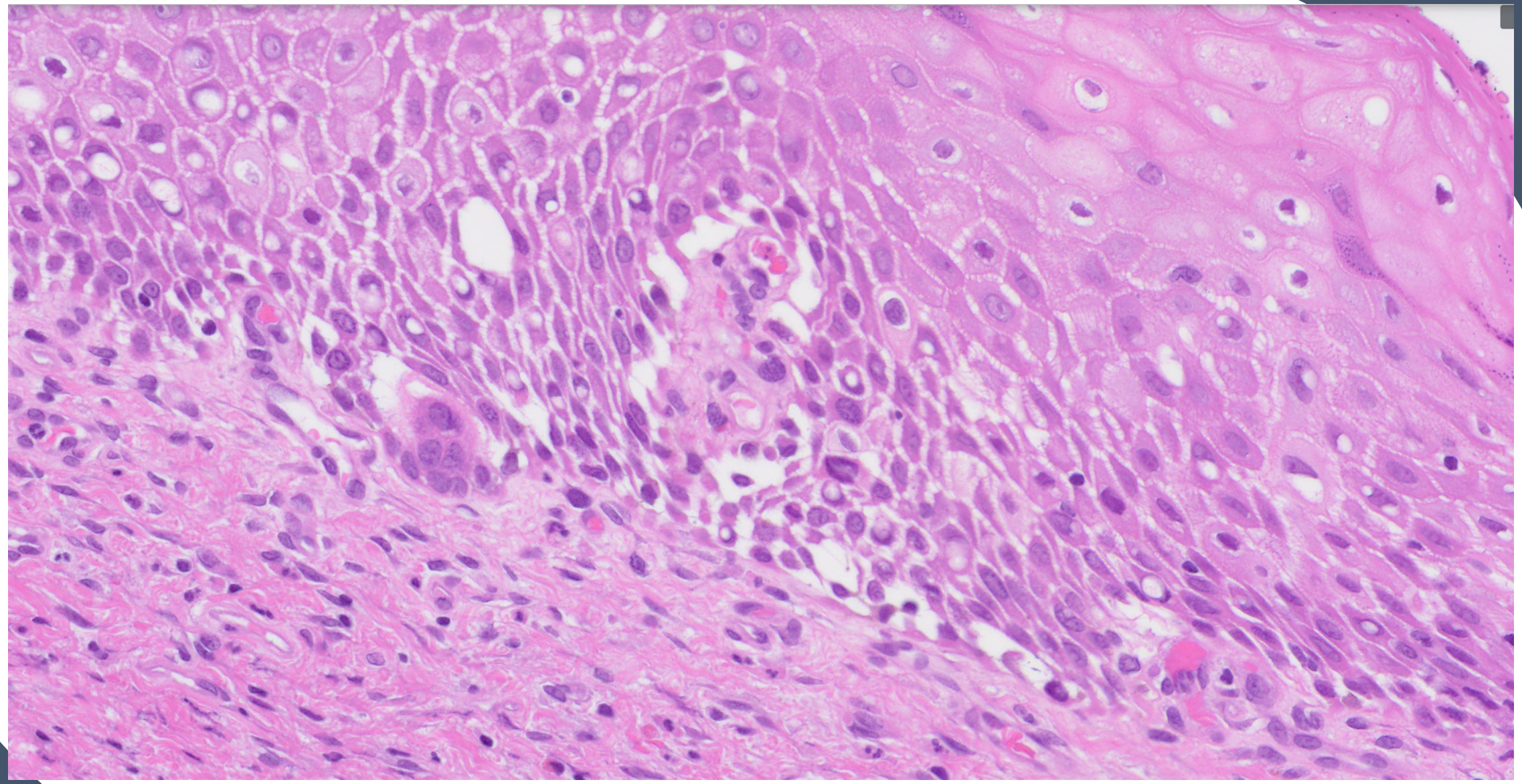

Poll 6

- HSIL (dVIN-like)
- DIFFERENTIATED VIN
- VaVIN
- Lichen sclerosus
- Don’t know



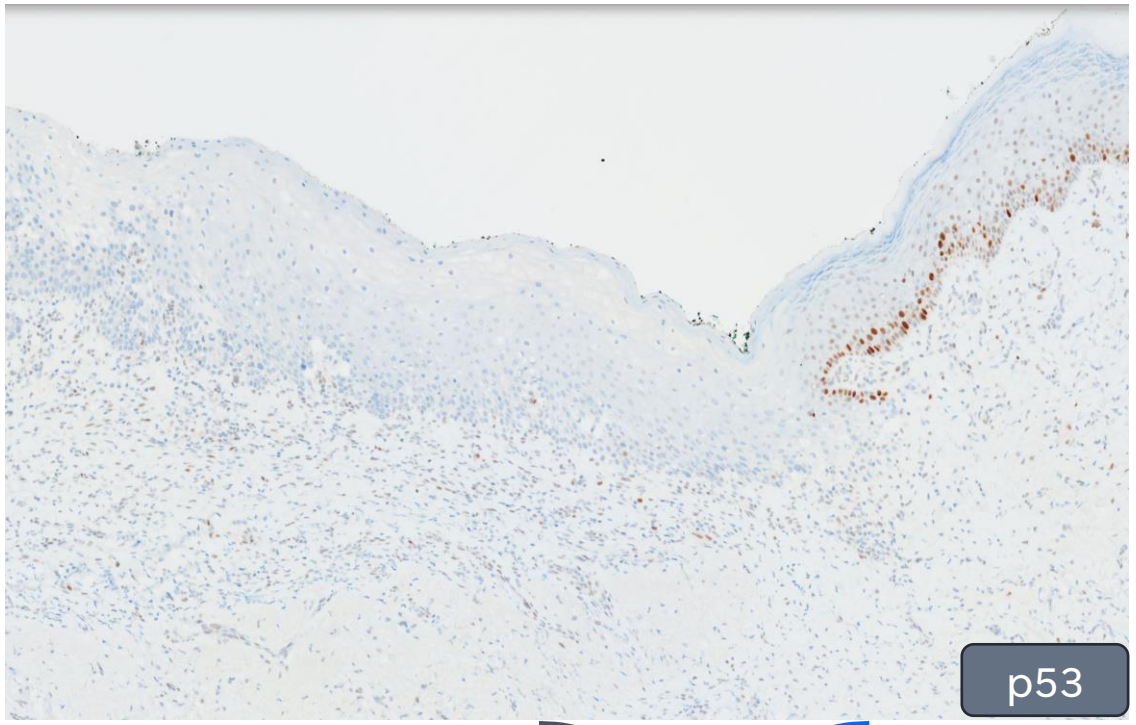

dVIN

Case 7

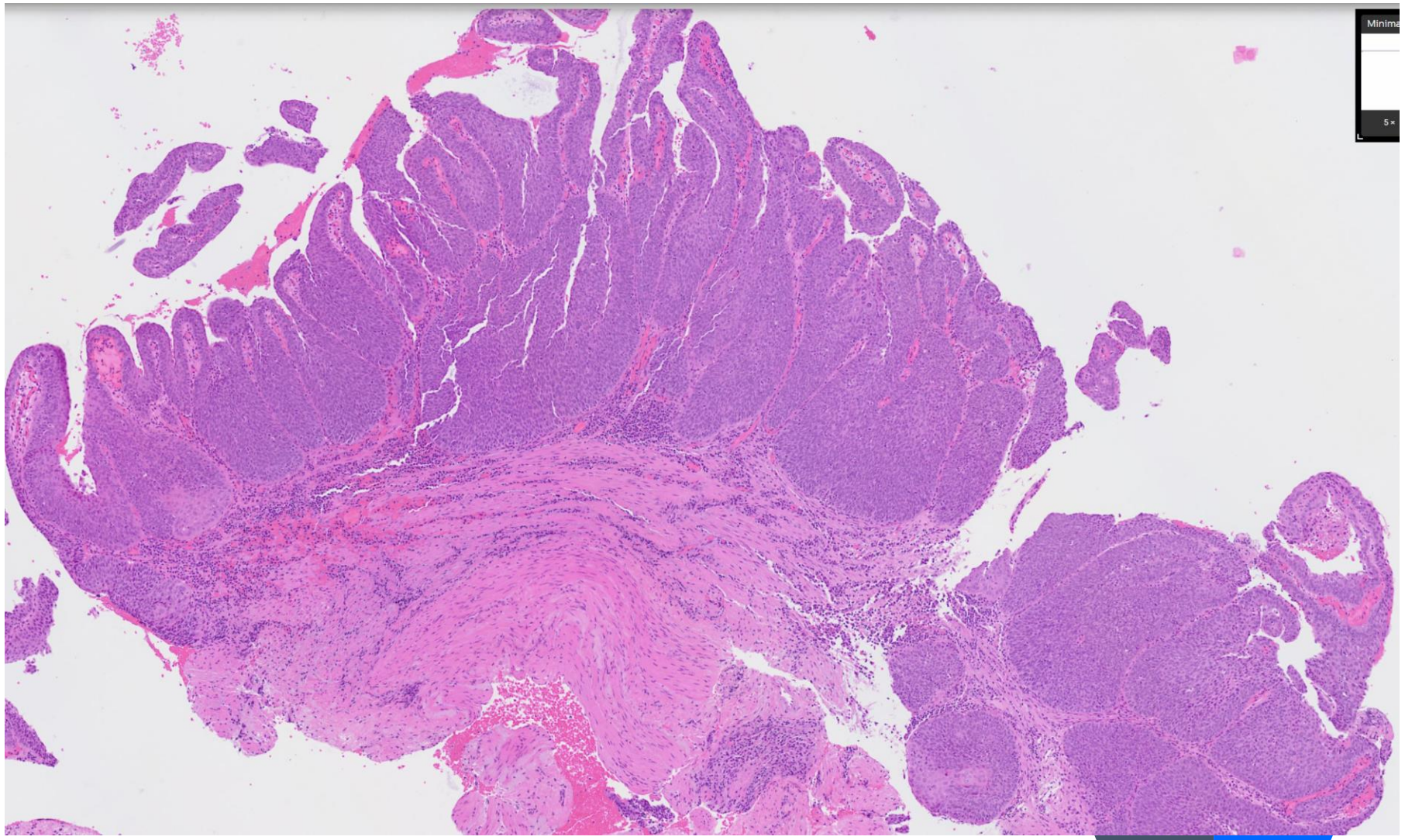

Courtesy Dr Hanioti

Poll 7

- HSIL
- DIFFERENTIATED VIN
- VaVIN
- Lichen sclerosus
- Don’t know

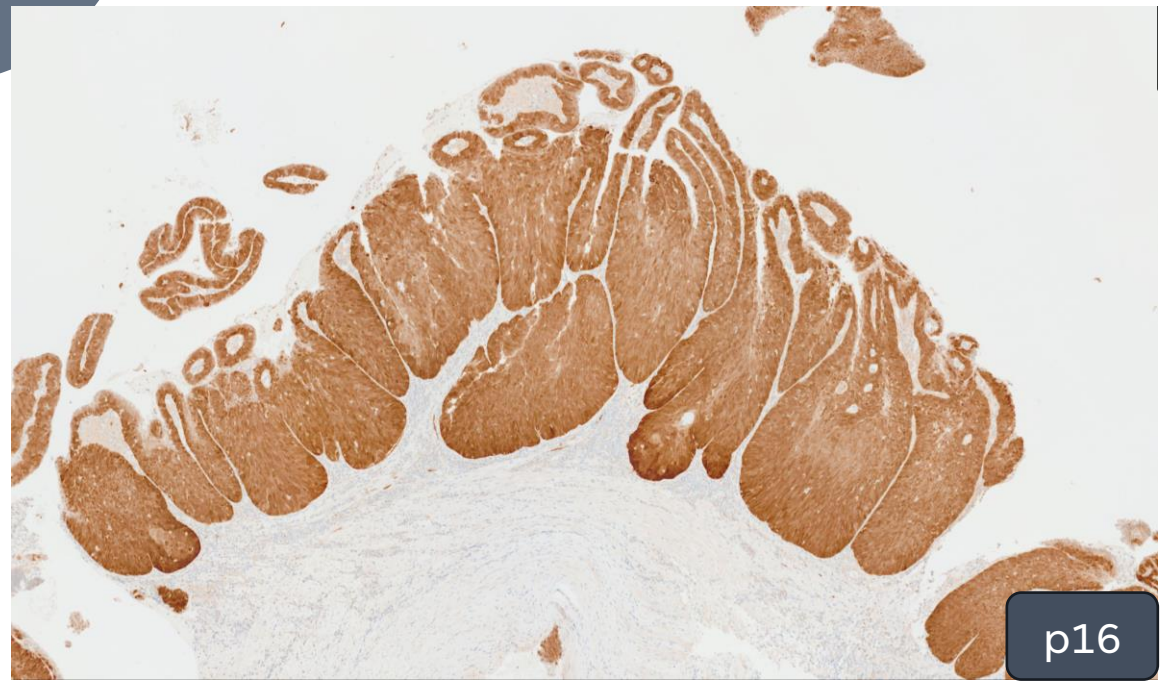

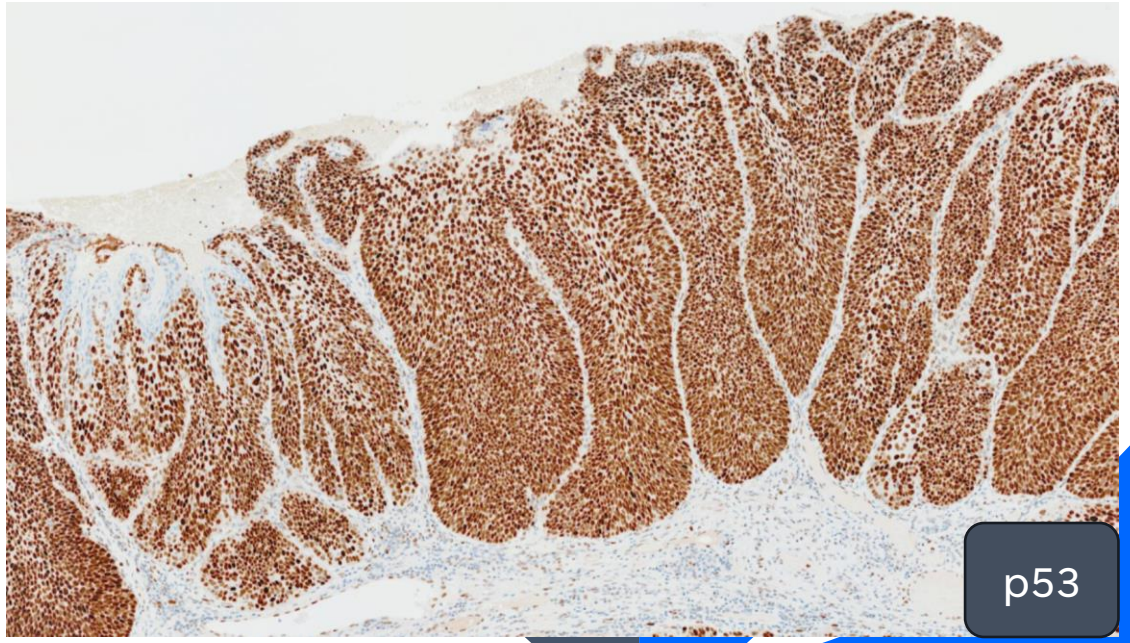

double-positive squamous lesion of the vulva ~ dVIN

MODERN PATHOLOGY

Journal homepage: https://modernpathology.org/

Research Article

Classification of Vulvar Squamous Cell Carcinoma and Precursor Lesions by p16 and p53 Immunohistochemistry: Considerations, Caveats, and an Algorithmic Approach

Hang Yang[a], Noorah Almadani[b], Emily F. Thompson[a], Basile Tessier-Cloutier[c], Julia Chen[d], Julie Ho[a,e], Janine Senz[f], Melissa K. McConechy[g], Christine Chow[e], Monica Ta[e], Angela Cheng[e], Anthony Karnezis[h], Jutta Huvila[i], Jessica N. McAlpine[j], Blake Gilks[a,e], Amy Jamieson[j], Lynn N. Hoang[a,e,*]

CORRESPONDENCE · Volume 36, Issue 10, 100319, October 2023 · *Open Archive*

Download Full Issue

Coexpression of p53 and p16 in Vulvar Squamous Neoplasia

Susanne K. Jeffus · Charles M. Quick

Affiliations & Notes Article Info

Acknowledgements

- Histology lab staff, Gynae path team, Dermpath colleagues at Department of Pathology, LCL
- Dr. Angela Ralte, Gateshead Health Foundation Trust
- Clinical team at LWH







NHS Liverpool Clinical Laboratories

NHS University Hospitals of Liverpool Group

NHS Manchester University NHS Foundation Trust

Thank You