The British Association of Gynaecological Pathologists

Lecturer – Sabrina Croce MD PhD
Institut Bergonié, Bordeaux, France



"I am a medical specialist in Pathological Anatomy at the Bergonié Institute.
After studying medicine in Italy, I obtained my specialist diploma in pathological anatomy in Turin in 2003 (under the direction of Professors Bussolati, Sapino and Papotti), followed by a Master's degree (Master 2) at the University of Louis Pasteur in Strasbourg in 2007.
I worked as a hospital-university assistant and later as a Lecturer-Hospital Practitioner at the University Hospital of Strasbourg until 2010.
In 2010, I joined the Bergonié Institute, where I became a specialist physician at the Cancer Centers Department in the Biopathology division.
My areas of expertise include gynecopathology. After training with Professor Esther Oliva and Professor Robert Young at Massachusetts General Hospital in Boston, I have particularly focused on uterine smooth muscle tumors and gynecological sarcomas, both in diagnostic activities (reviews and opinions in the National RRePS networks) and in research and teaching.
I am a member of the International Society of Gynecopathology and the International Academy of Pathology.
I am co-chair of the Gyn ESP working group"

The British Association of Gynaecological Pathologists

Everyday Dilemmas in Gynaecological Pathology

Assessment of necrosis and mitoses in mesenchymal tumours

Andrea Feu, MD and Sabrina Croce, MD, PhD

Biopathology Dpt Institut Bergonie Bordeaux, France

March 7 2025


Medusa-Caravaggio

Bergonié UNICANCER NOUVELLE-AQUITAINE

Réseau RRePS



The British Association of Gynaecological Pathologists

Speaker disclosures

- ❑ I have no financial conflicts of interest to disclose

Outline

1. Necrosis:
   - Morphologic criteria and issues in smooth muscle tumours of the uterus
   - How to survive in the jungles 'necrosis
   - Necrosis in endometrial stromal sarcomas

2. Mitoses
3. Prognostic value of necrosis and mitoses in smooth muscle tumours
4. Practical cases
5. Conclusions

Outline

1. **Necrosis :**
   - **Morphologic criteria and issues in smooth muscle tumours of the uterus**
     - How to survive in the jungles 'necrosis
   - Necrosis in endometrial stromal sarcomas

2. Mitoses
3. Prognostic value of necrosis and mitoses in smooth muscle tumours
4. Practical cases
5. Conclusions

Necrosis & Mitosis: Critical for Diagnosing Gynecologic Smooth Muscle Tumors"

Diagnostic criteria

Smooth muscle tumours: 3 histotypes

2020 Female Tumours WHO

Spindle / usual

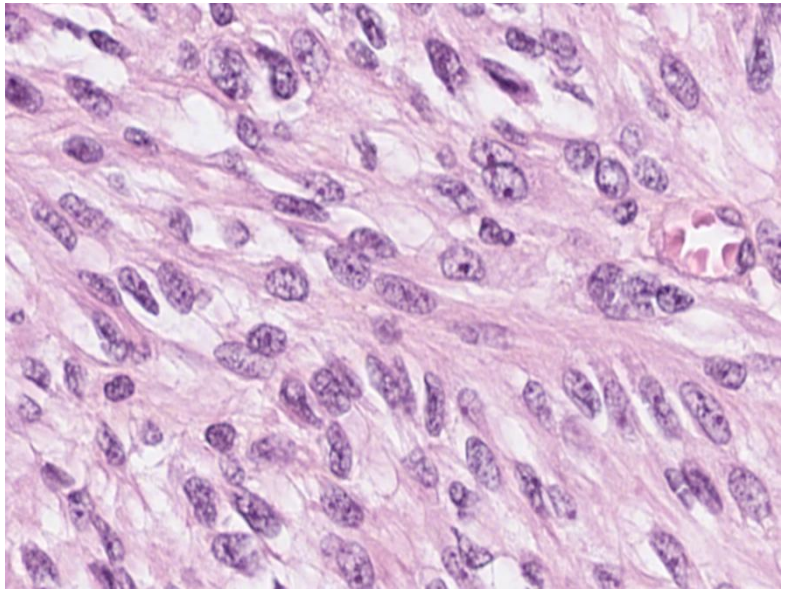

Epithelioid

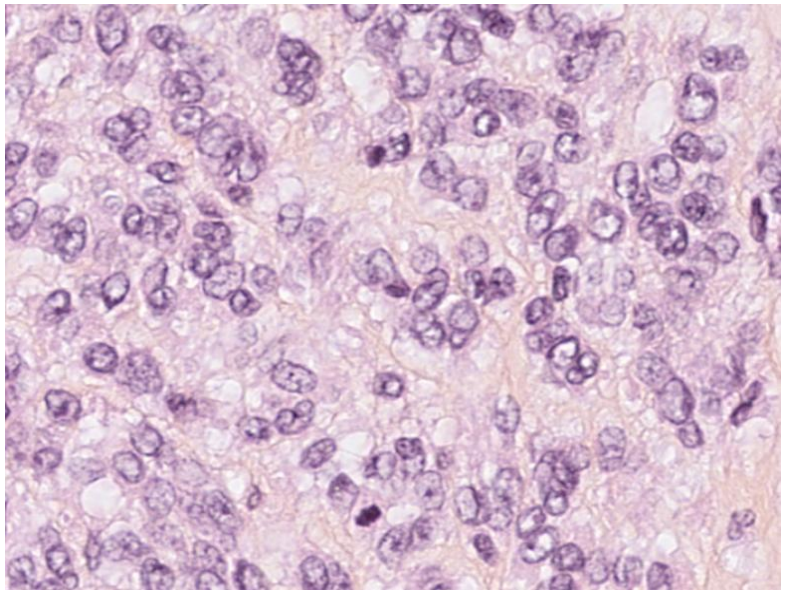

Mixoid

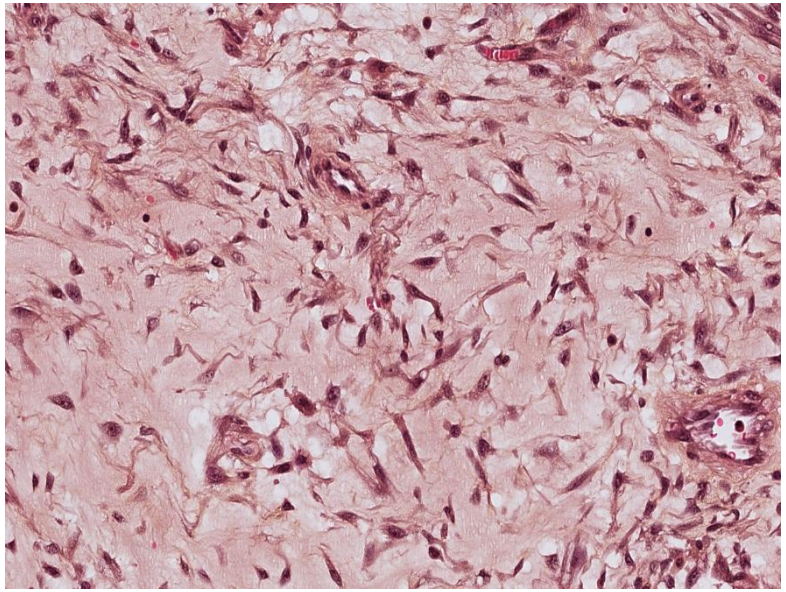

Different diagnostic criteria!!

Different mitotic cut off

2020-WHO diagnostic criteria

Spindle LMS
At least 2/3 features

atypia
Mitosis ≥4 mitoses/mm² (≥10/10HPF)
Tumor cell necrosis

Epithelioid LMS
at least 1/3 features

atypia
Mitosis ≥1,6 mitoses/mm² (≥4/10HPF)
Tumor cell necrosis

Myxoïd LMS
at least 1/4 features

Infiltrative borders
atypia
Mitosis->0,4mitoses/mm² (>1/10HPF)
Tumor cell necrosis

2013

Interobserver Variability in the Interpretation of Tumor Cell Necrosis in Uterine Leiomyosarcoma

Diana Lim, MBBS, FRCPath, FRCPA, Teresa Alvarez, MD,† Marisa R. Nucci, MD,‡ Blake Gilks, MD,§ Teri Longacre, MD,‖ Robert A. Soslow, MD,¶ and Esther Oliva, MD#*

Concordance k: 0,44

(more approaching the fair k (0,21-0,40 fair) than the moderate (0,41-0,60:)

N pathologists	6
N LMS	34
Full agreement	35%
Partial agreement	47%
No consensus	**18%**

Study design limitations:
1 H&E slide only
No clinical data (patient age, hormones)
No macroscopic data
No data about tissue sampling

How to recognize a tumor cell necrosis

Essential criteria:

- Abrupt transition between viable and necrotic cells
- No intervening zone of granulation tissue or hyalinized tissue

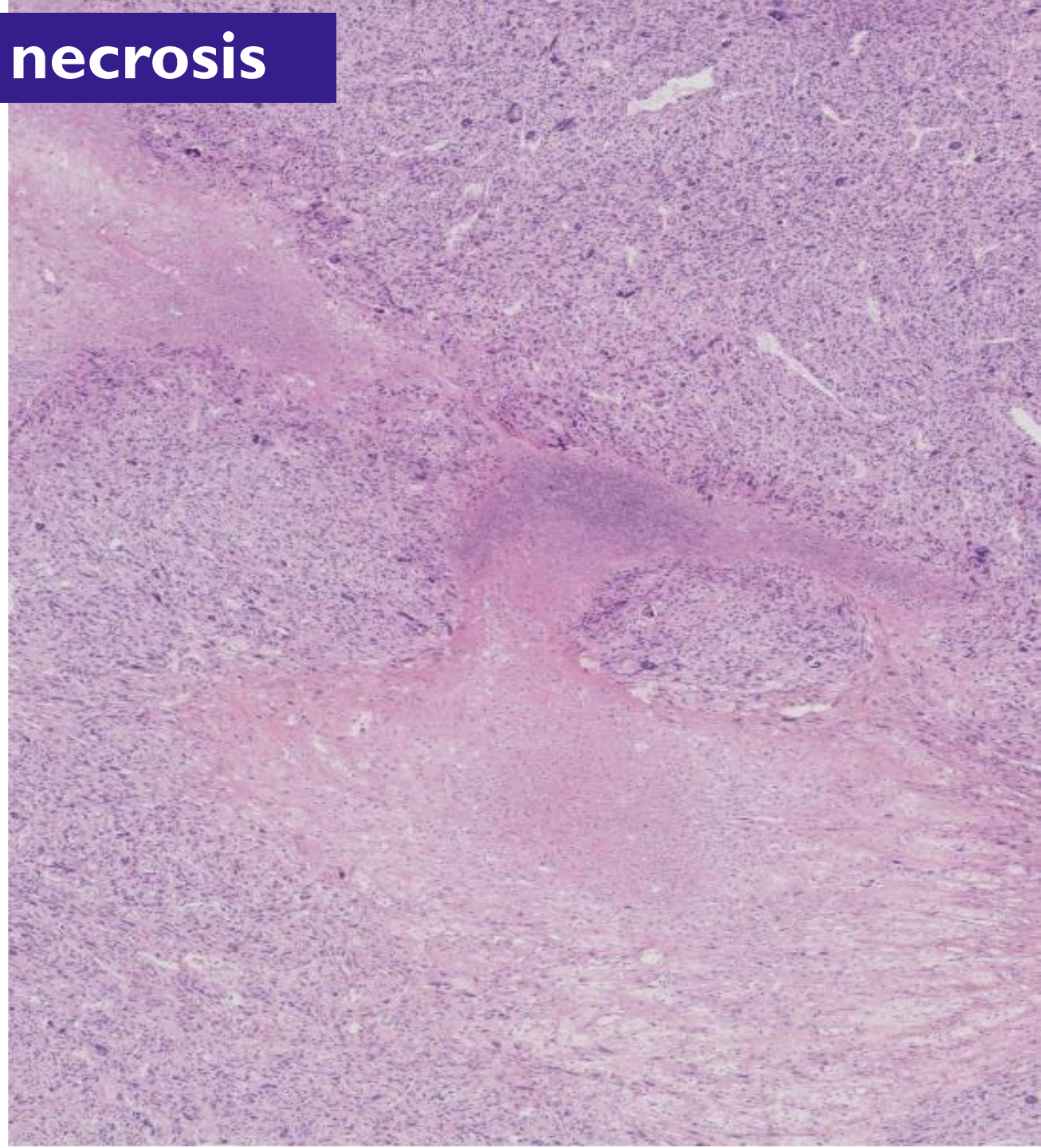

How to recognize a tumor cell necrosis

Essential criteria:

- Abrupt transition between viable and necrotic cells
- No intervening zone of granulation tissue or hyalinized tissue

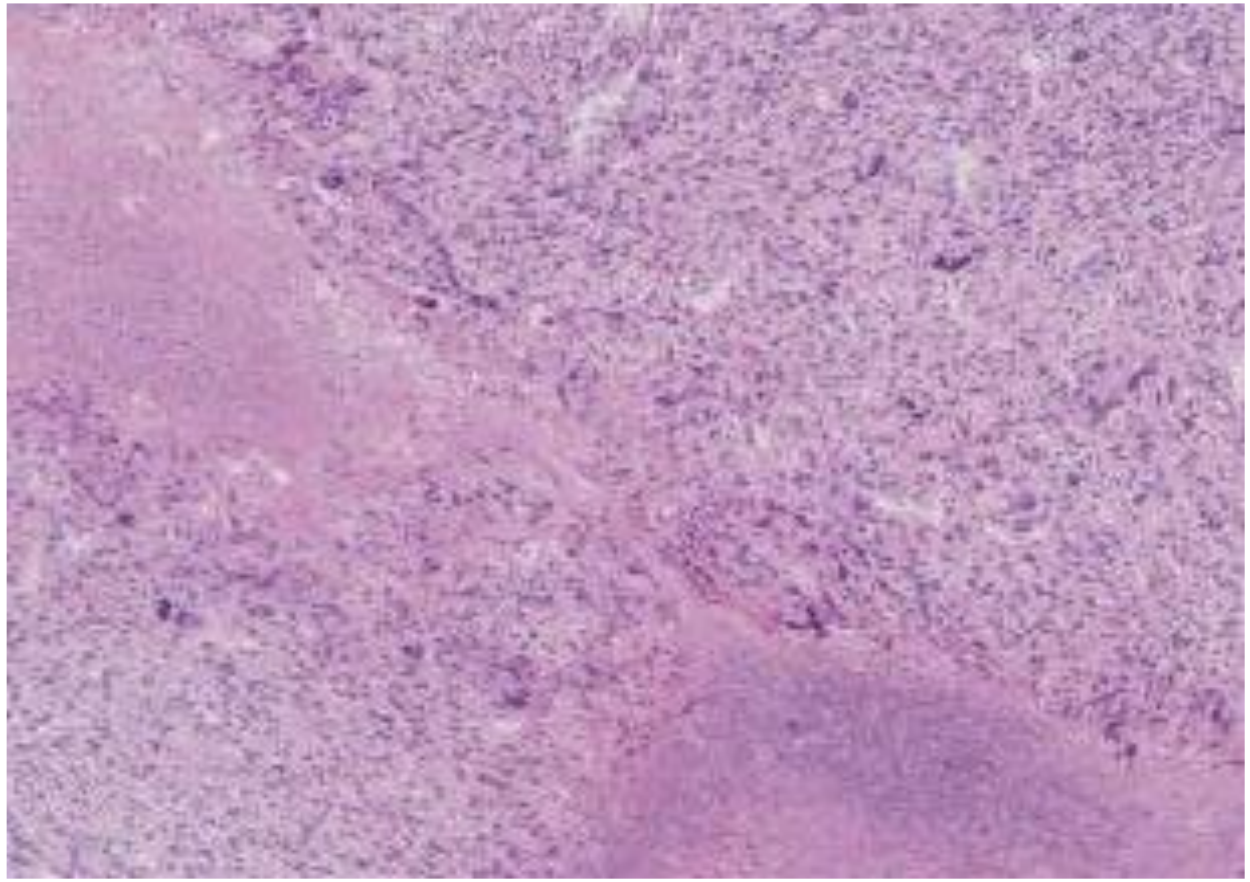

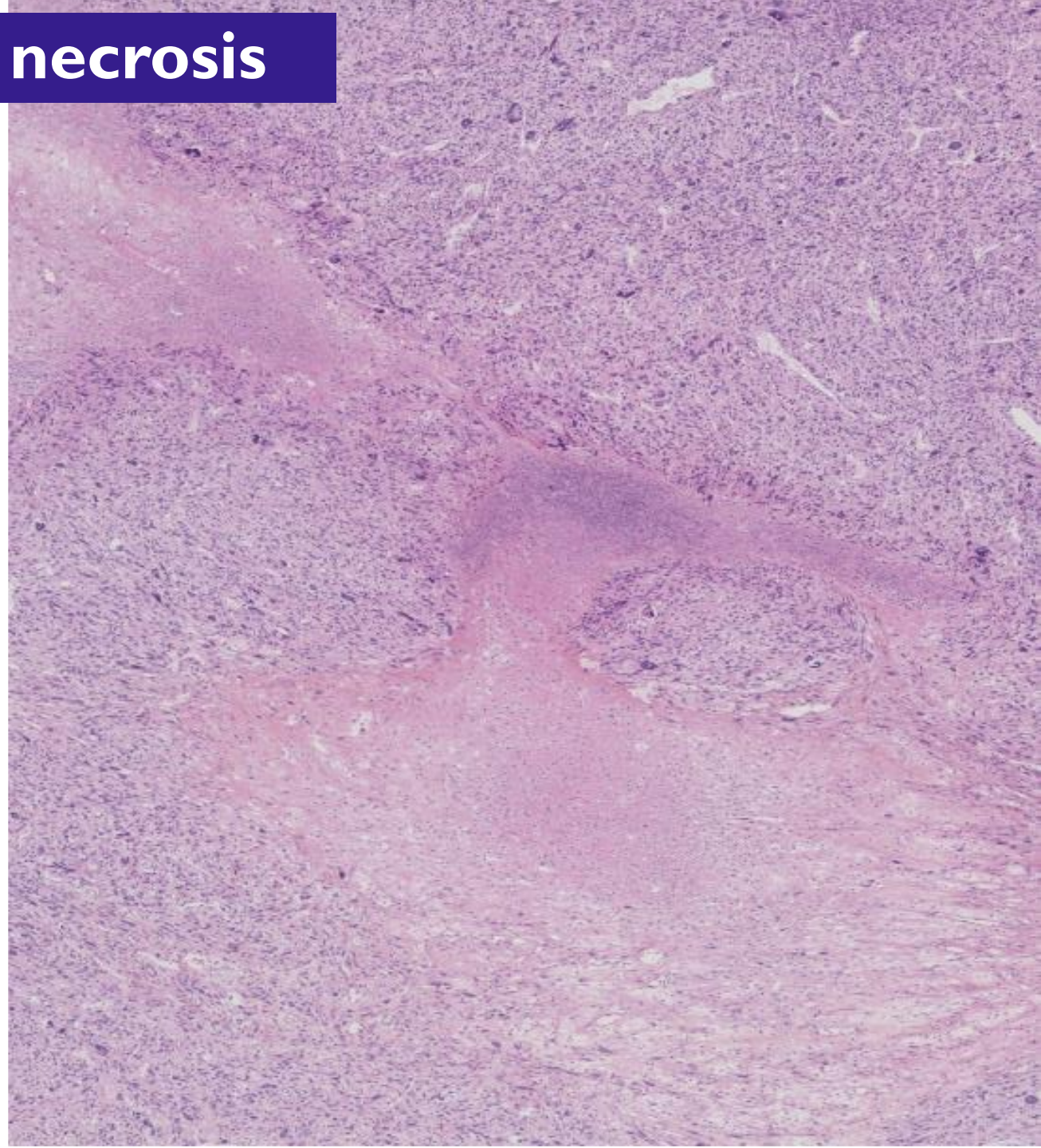

How to recognize a tumor cell necrosis

Essential criteria:

- Abrupt transition between viable and necrotic cells
- No intervening zone of granulation tissue or hyalinized tissue

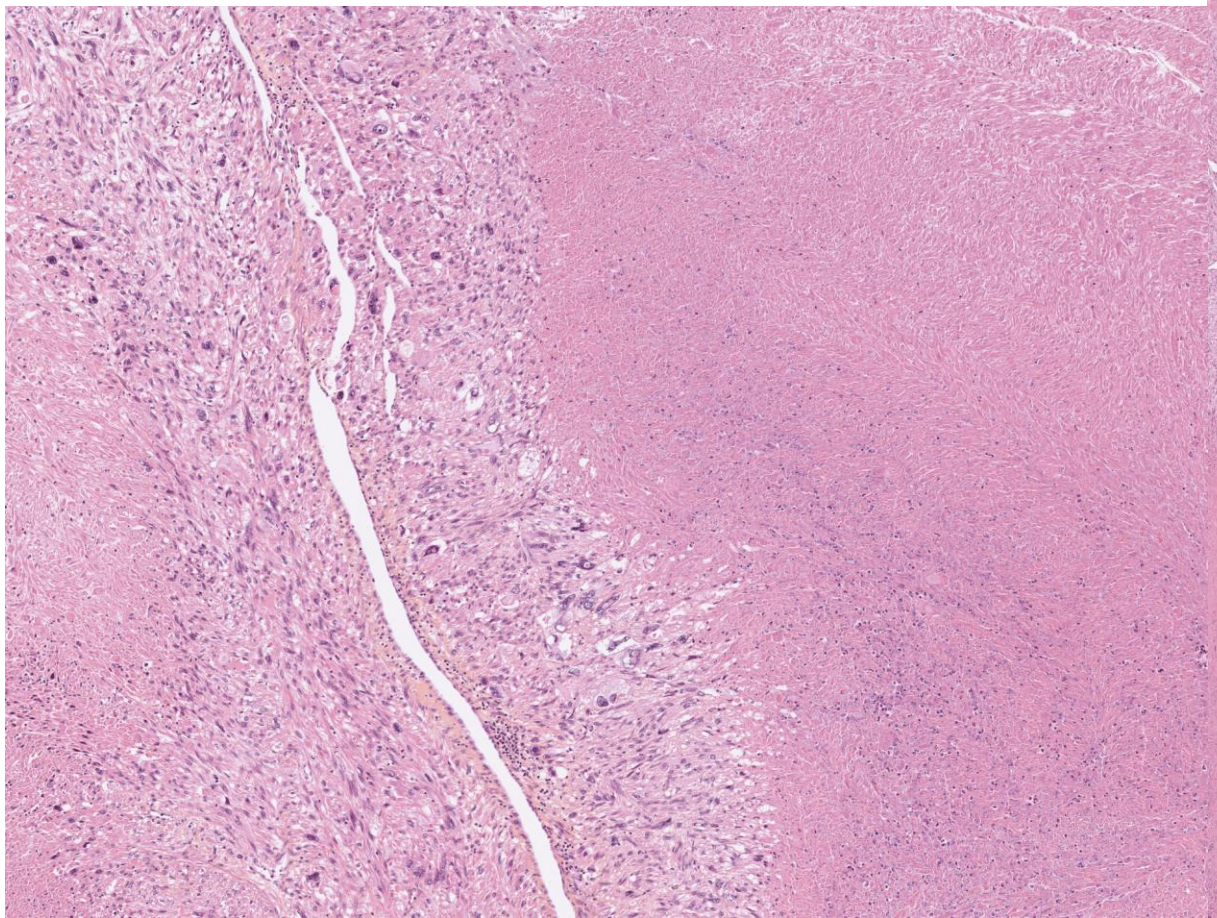

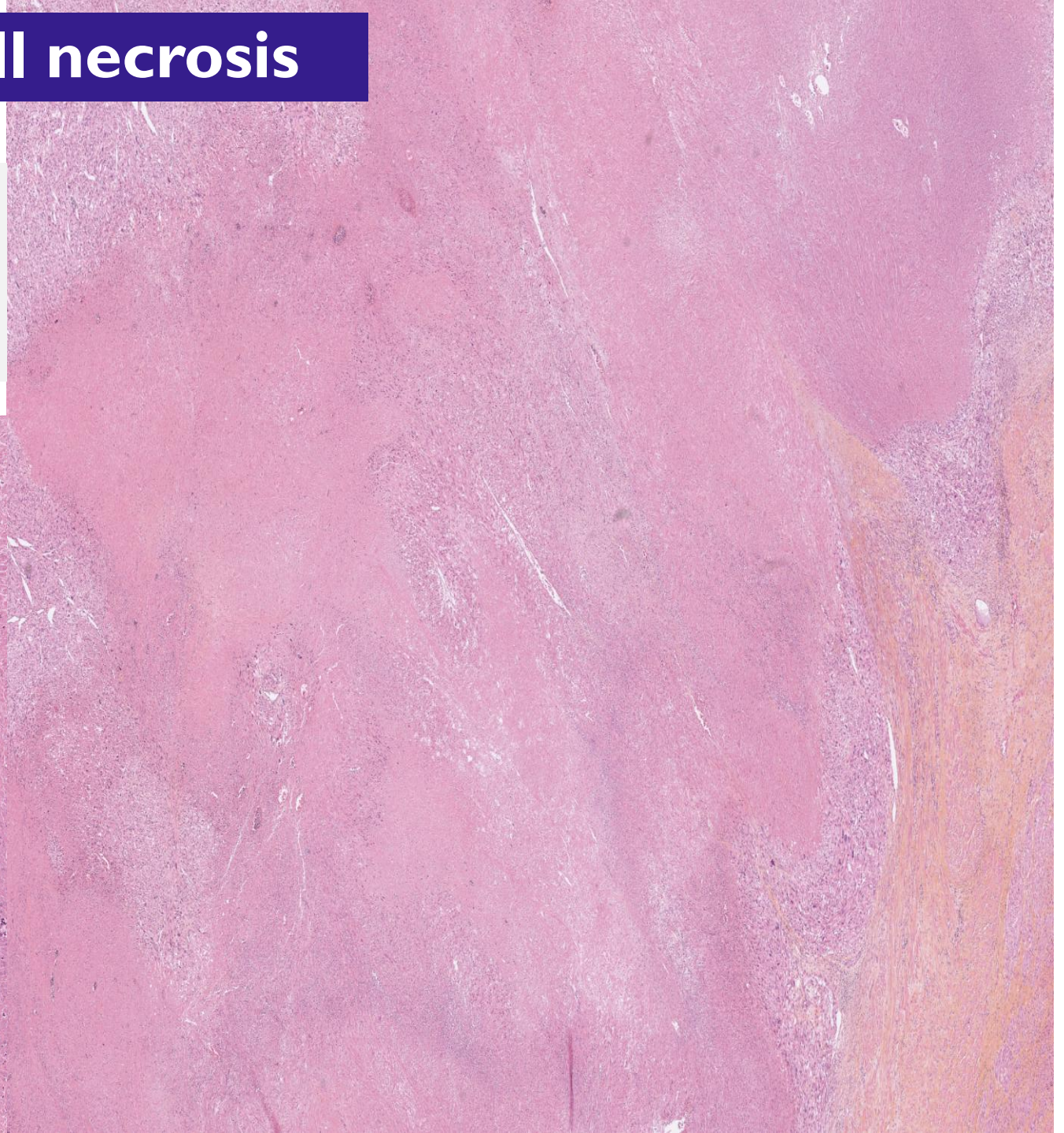

How to recognize a tumor cell necrosis

Non-essential features:

- Ghost outlines of tumor cells
- Peritheliomatous pattern of viable cells

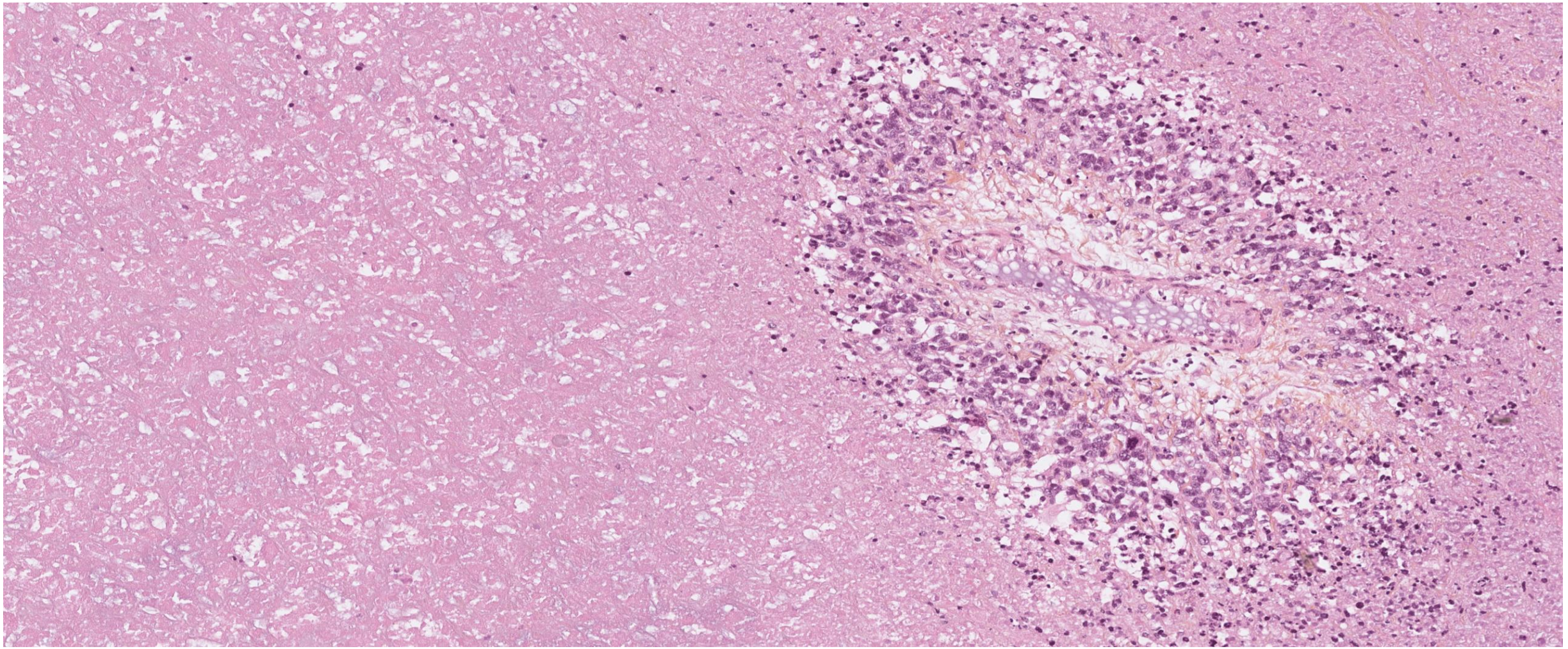

How to recognize a tumor cell necrosis

Non-essential features:

- Ghost outlines of tumor cells
- Peritheliomatous pattern of viable cells

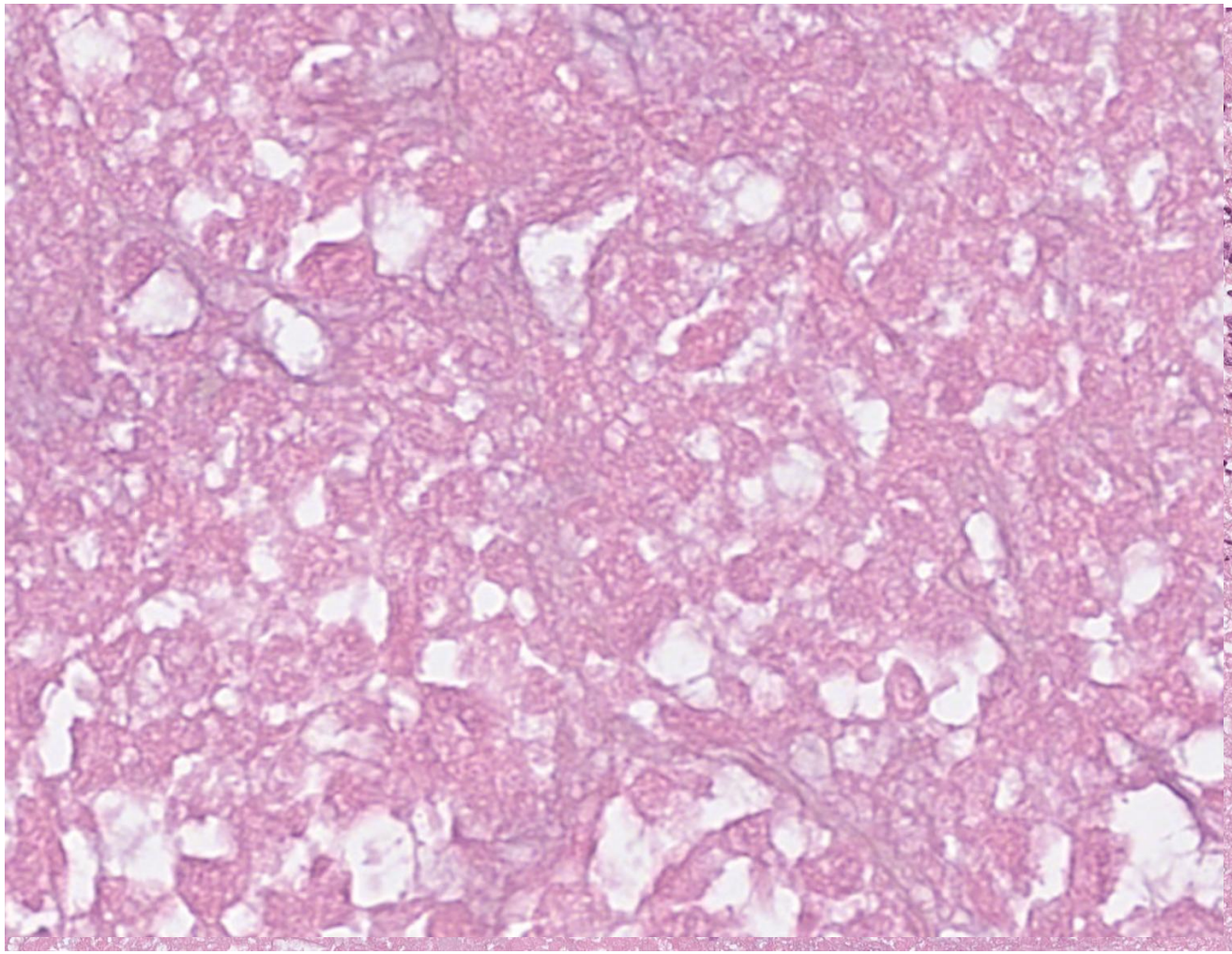

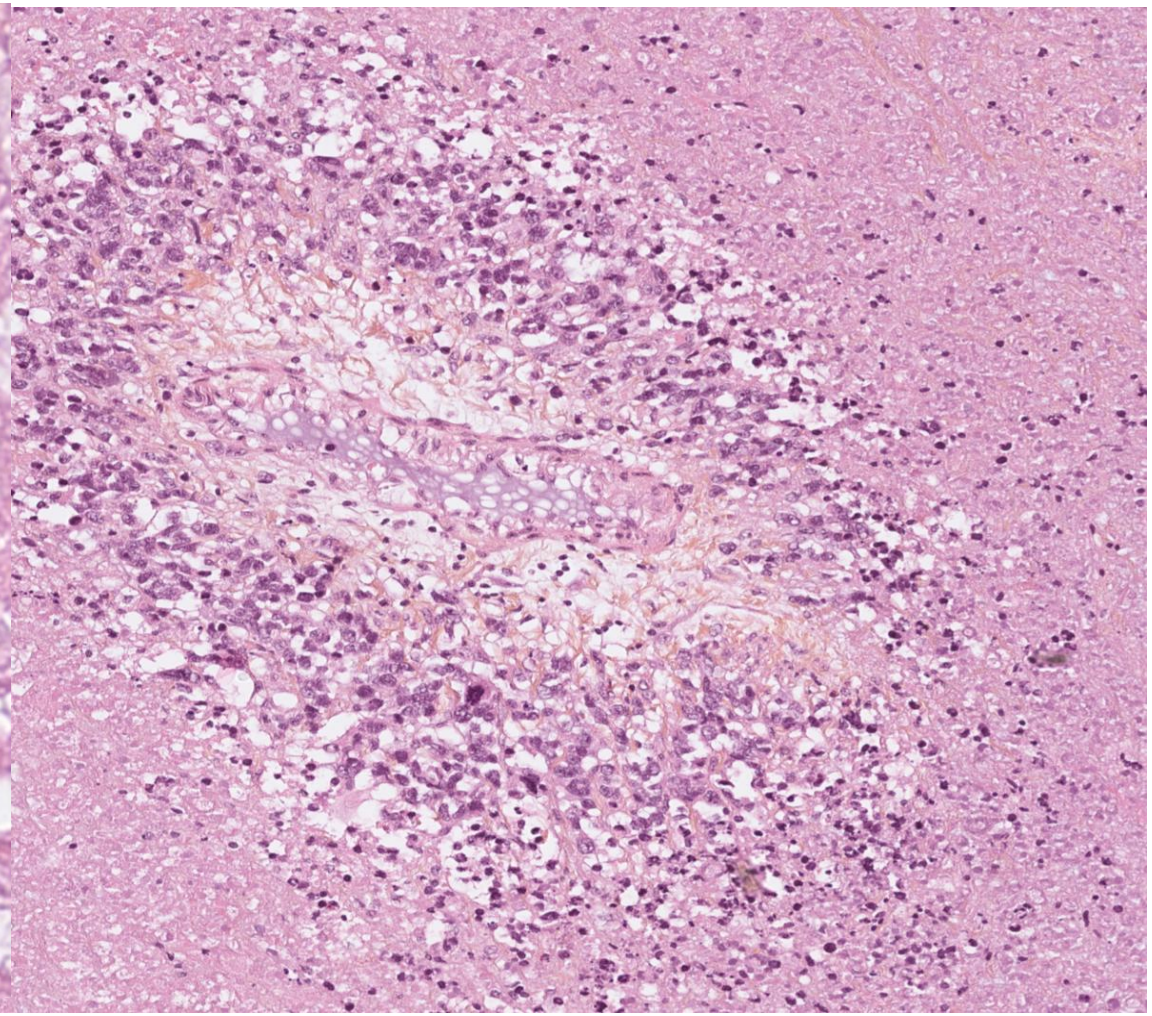

How to recognize ischemic necrosis

General features:

- Unifocal (exception: progestins treatment /apoplectic LM)
- Simple contours
- Granular tissue in the interface with viable cells
- Fibrosis if the necrosis is old
- Absence of perithelioma growth
- Absence of atypical ghost cells



How to recognize ischemic necrosis

General features:

- Unifocal (exception: apoplectic LM)
- Simple contours
- Granular tissue in the interface with viable cells
- Fibrosis if the necrosis is old
- Absence of perithelioma growth
- Absence of atypical ghost cells

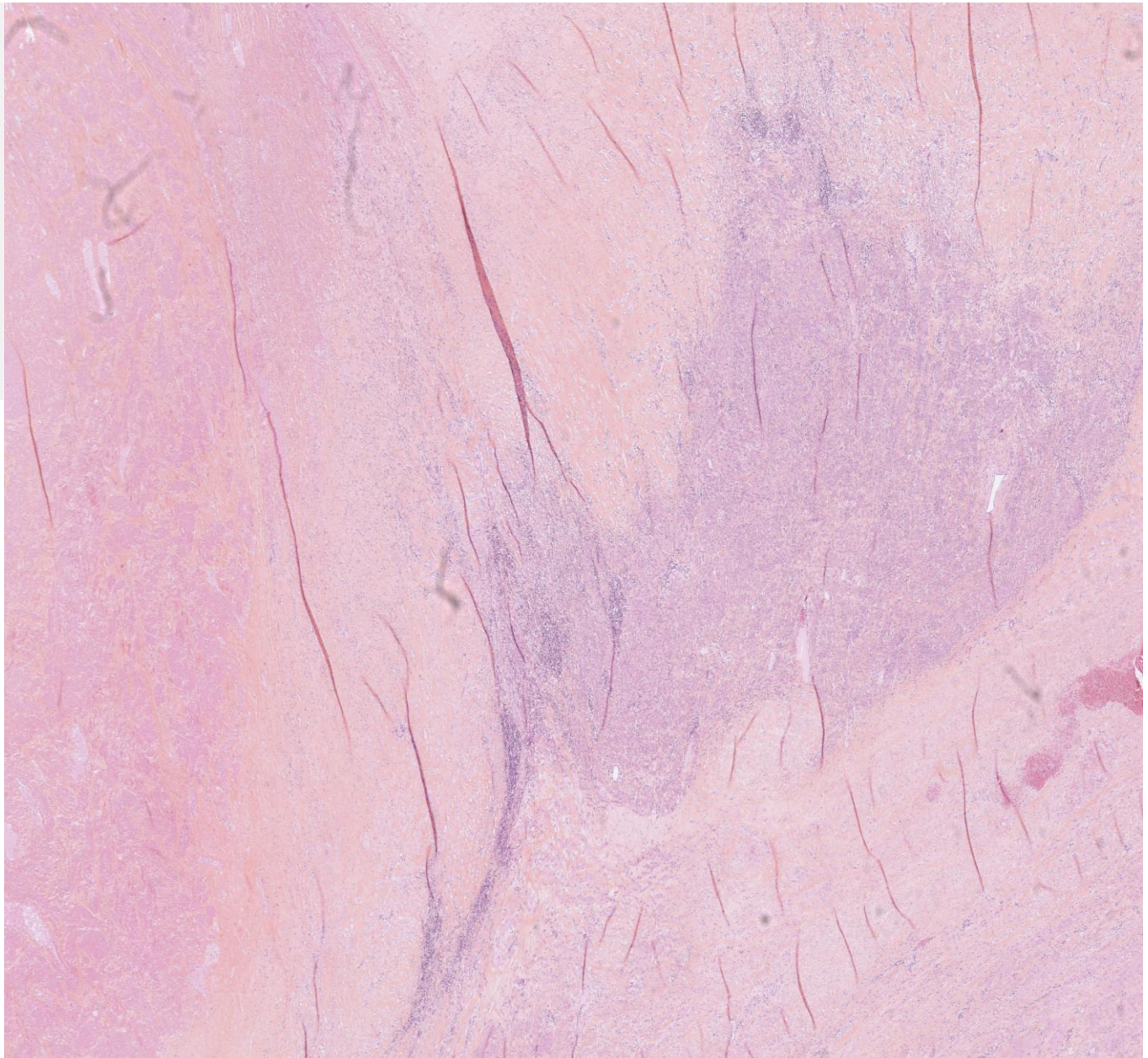

How to recognize ischemic necrosis

General features:

- Unifocal (exception: apoplectic LM)
- Simple contours
- Granular tissue in the interface with viable cells
- Fibrosis if the necrosis is old
- Absence of perithelioma growth
- Absence of atypical ghost cells

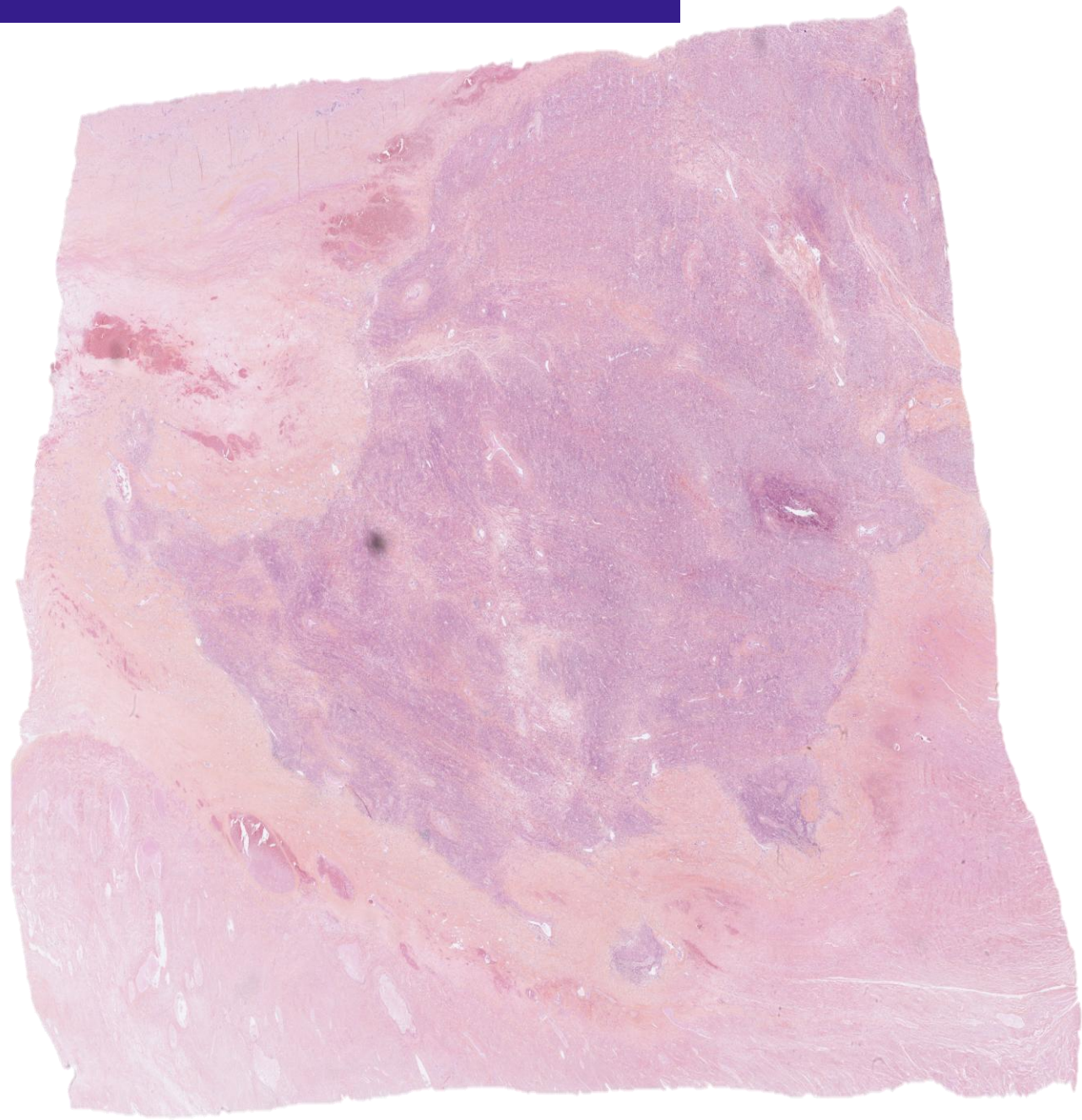

How to recognize ischemic necrosis

General features:

- Unifocal (exception: apoplectic LM)
- Simple contours
- Granular tissue in the interface with viable cells
- Fibrosis if the necrosis is old
- Absence of perithelioma growth
- Absence of atypical ghost cells

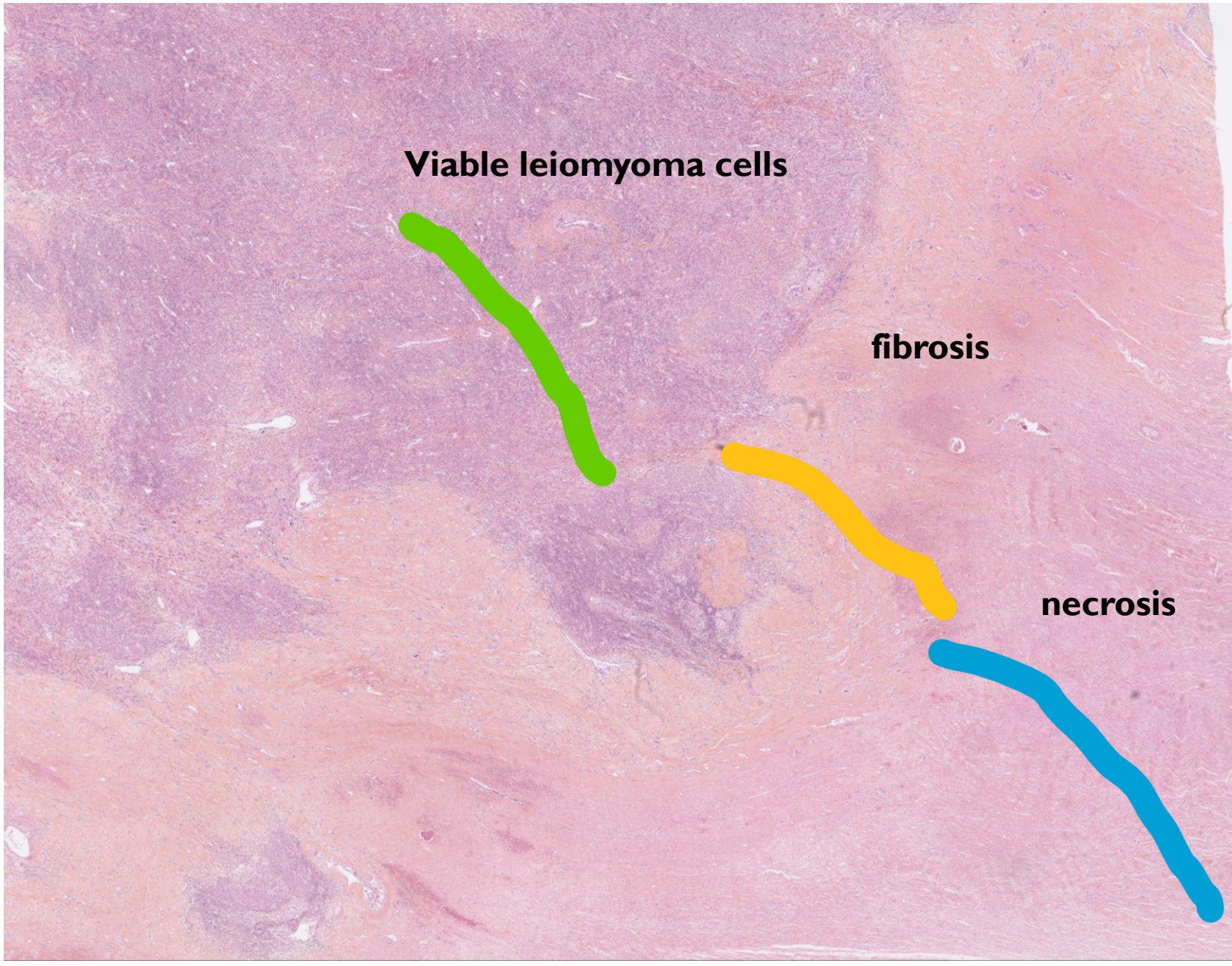

How to recognize ischemic necrosis

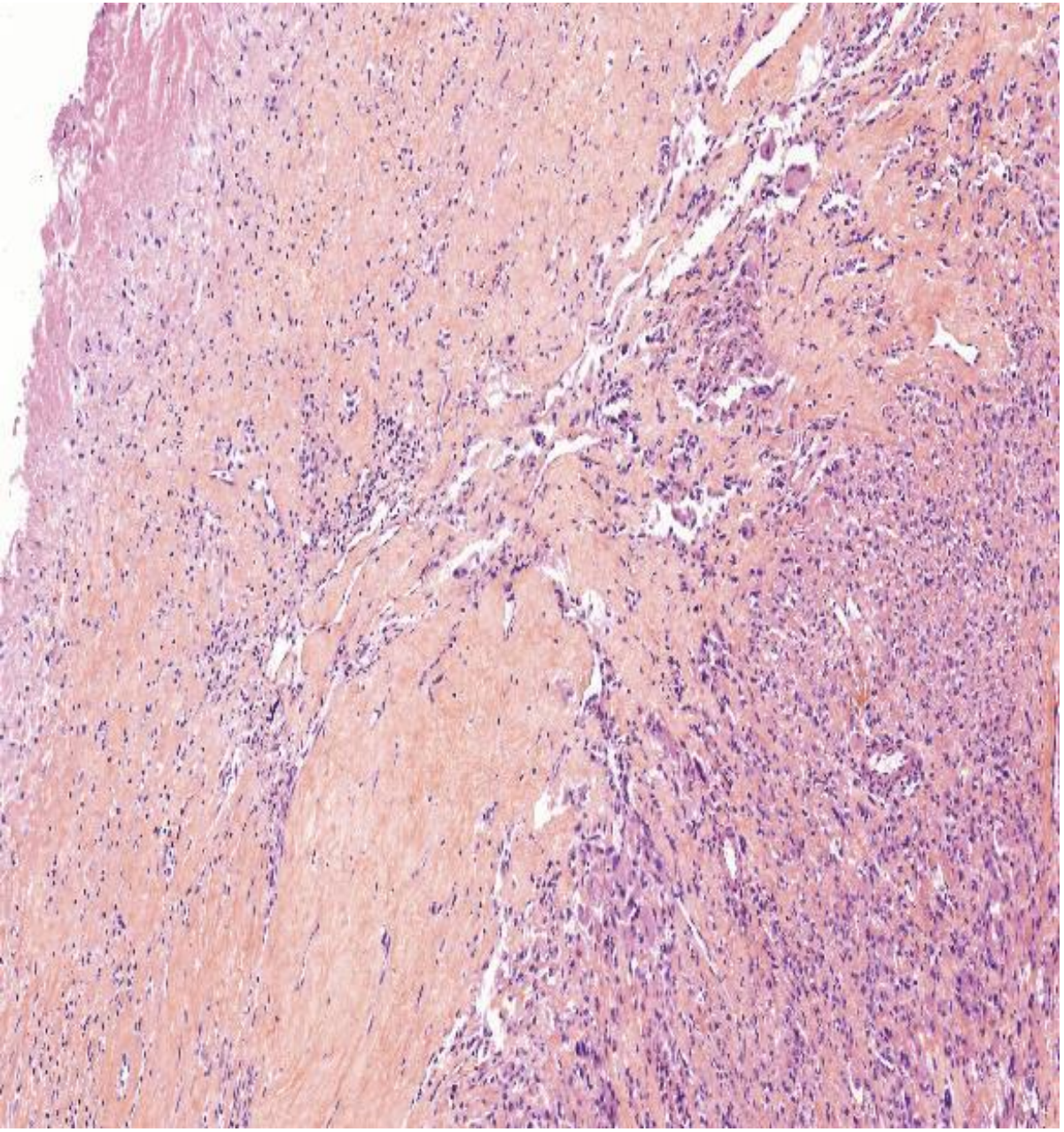

Fibrin wall

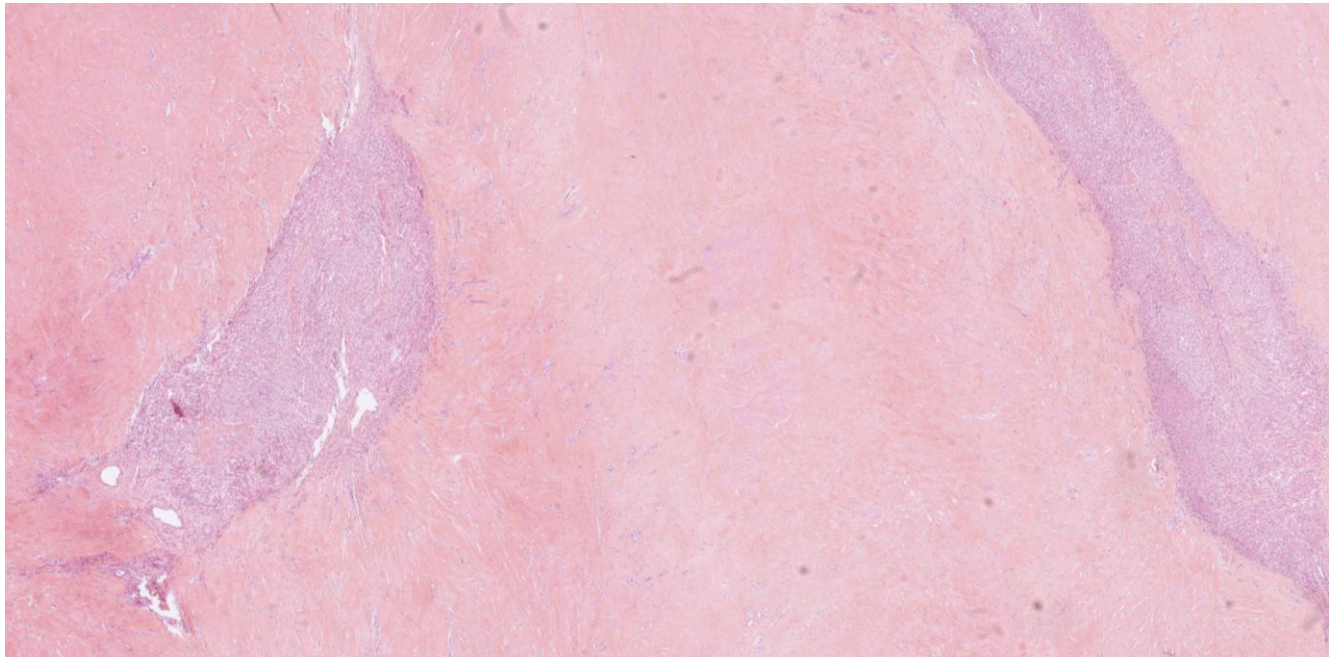

How to recognize ischemic necrosis

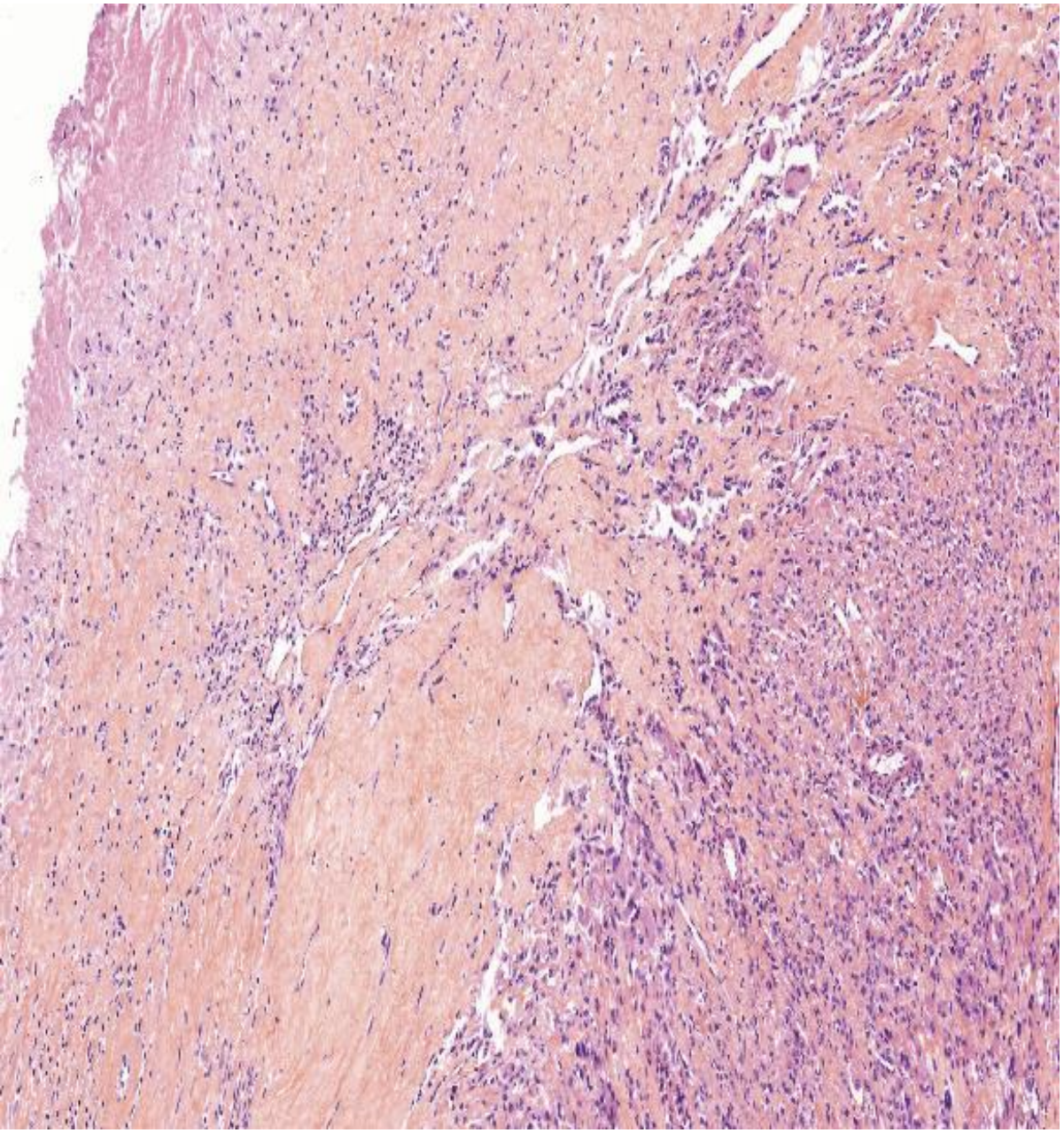

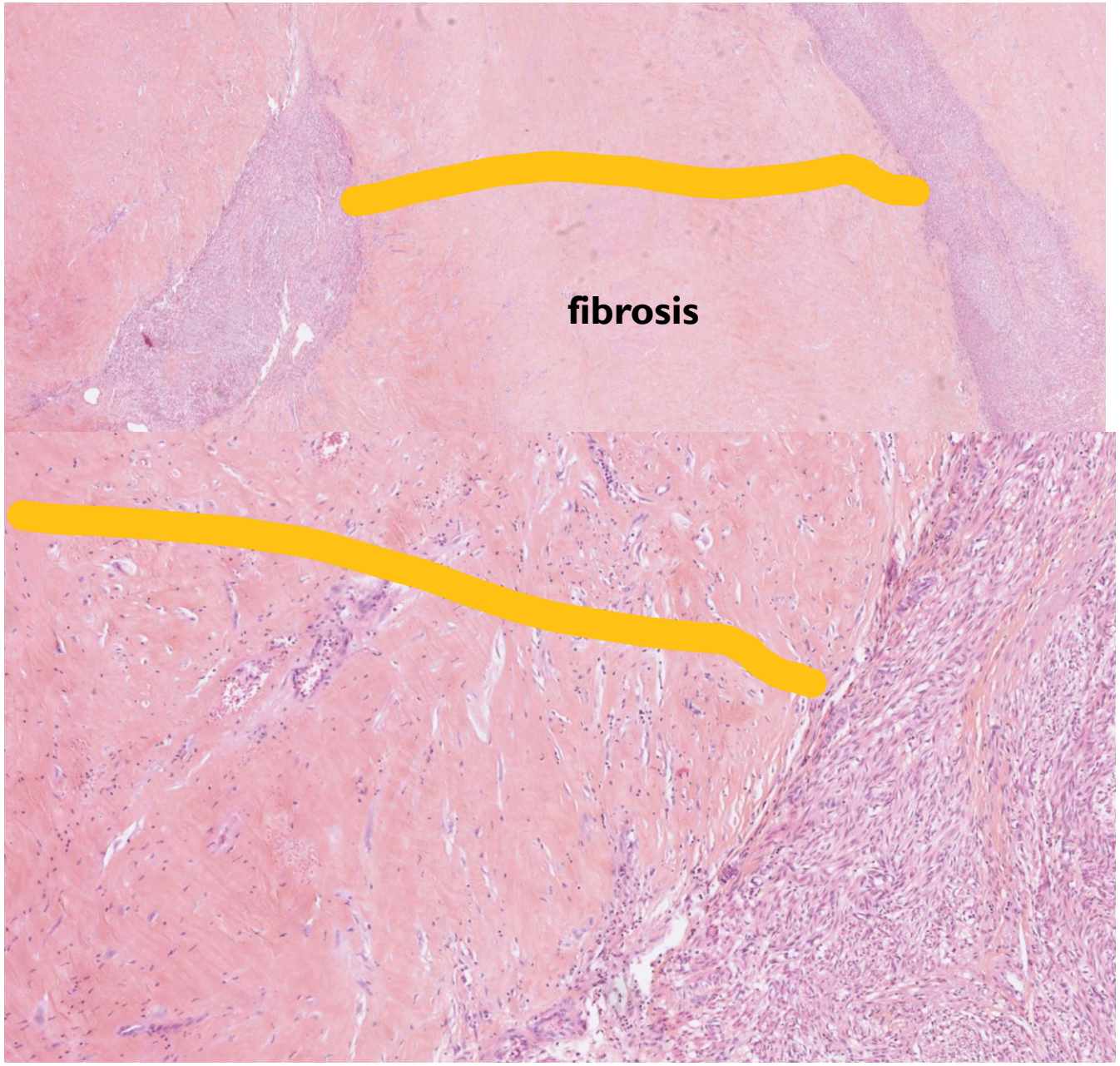

Mimickers of tumor cell necrosis in leiomyoma

Spontaneous ischemia →
- Pregnancy-related
- Spontaneous (hypoxia)

Pharmacologic/ Hormonal Therapy →
- Progestons
- Oral contraceptives
- Gonadotropin-releasing hormone analogs
- Tranexamic acid

Minimally invasive therapy →
- Artery embolization
- Cryotherapy ablation
- Radiophrequency abalation

Mechanical ulceration →
- Submucosal prolapsed leiomyomas

Mimickers of tumor cell necrosis in leiomyoma

Effect of (hormonal) treatment

Original article

Unusual morphological features of uterine leiomyomas treated with progestogens

Clinton Boyd, W Glenn McCluggage

Histological features:

- Large zones of degeneration
- Cystic change
- Edema, myxoid features, hemorrhage or hyalinization
- "Shrunken" appearance
- Bright eosinophilic / epithelioid cytoplasm
- Pyknotic nuclei

Comparative Study > Am J Surg Pathol. 1996 Apr;20(4):427-32.
doi: 10.1097/00000478-199604000-00005.

Histopathologic findings in 107 uterine leiomyomas treated with leuprolide acetate compared with 126 controls

J J Sreenan [1], R A Prayson, C V Biscotti, M H Thornton, K A Easley, W R Hart

Affiliations + expand

PMID: 8604809 DOI: 10.1097/00000478-199604000-00005

International Journal of Surgical Pathology 11(4):339–344, 2003

Unusual Morphologic Features of Uterine Leiomyomas Treated with Gonadotropin-Releasing Hormone Agonists: Massive Lymphoid Infiltration and Vasculitis

G. McClean, MB and W. G. McCluggage, FRCPath

ORIGINAL ARTICLE

Tranexamic Acid-associated Necrosis and Intralesional Thrombosis of Uterine Leiomyomas

A Clinicopathologic Study of 147 Cases Emphasizing the Importance of Drug-induced Necrosis and Early Infarcts in Leiomyomas

Philip P. C. Ip, MBChB, MRCPath, Ka-Wai Lam, MBBS, FRCOG,†*
Ching-Lung Cheung, BSc,‡ Matthew C. W. Yeung, Ting-Chung Pun, MBBS, FRCOG,†*
Queeny K. Y. Chan, MPhil, and Annie N. Y. Cheung, MD, FRCPath**

Mimickers of tumor cell necrosis in leiomyoma

First described by Myles and Hart 1985

ORIGINAL ARTICLE

Apoplectic Leiomyomas

A Morphologic Analysis of 100 Cases Highlighting Unusual Features

Jennifer A. Bennett, MD,† Colleen Lamb, MD,*† and Robert H. Young, MD*†*

Wide Range of Clinical and Pathological Presentations

Age Range: 23-66 years (Mean/median: 41 years)

Progestin Therapy:

- 24/100 known
- 9/100 with endometrial changes
- 2/100 pregnancies

Mimickers of tumor cell necrosis in leiomyoma

Macroscopy

cyst formation (20%)

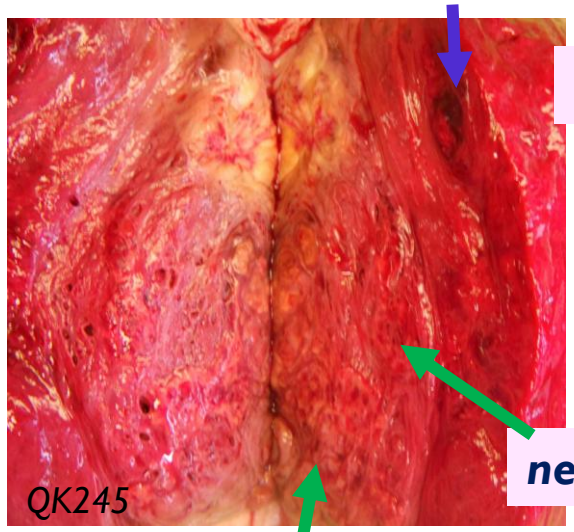

hemorrhage (44%)

necrosis (12%)

softening (18%)

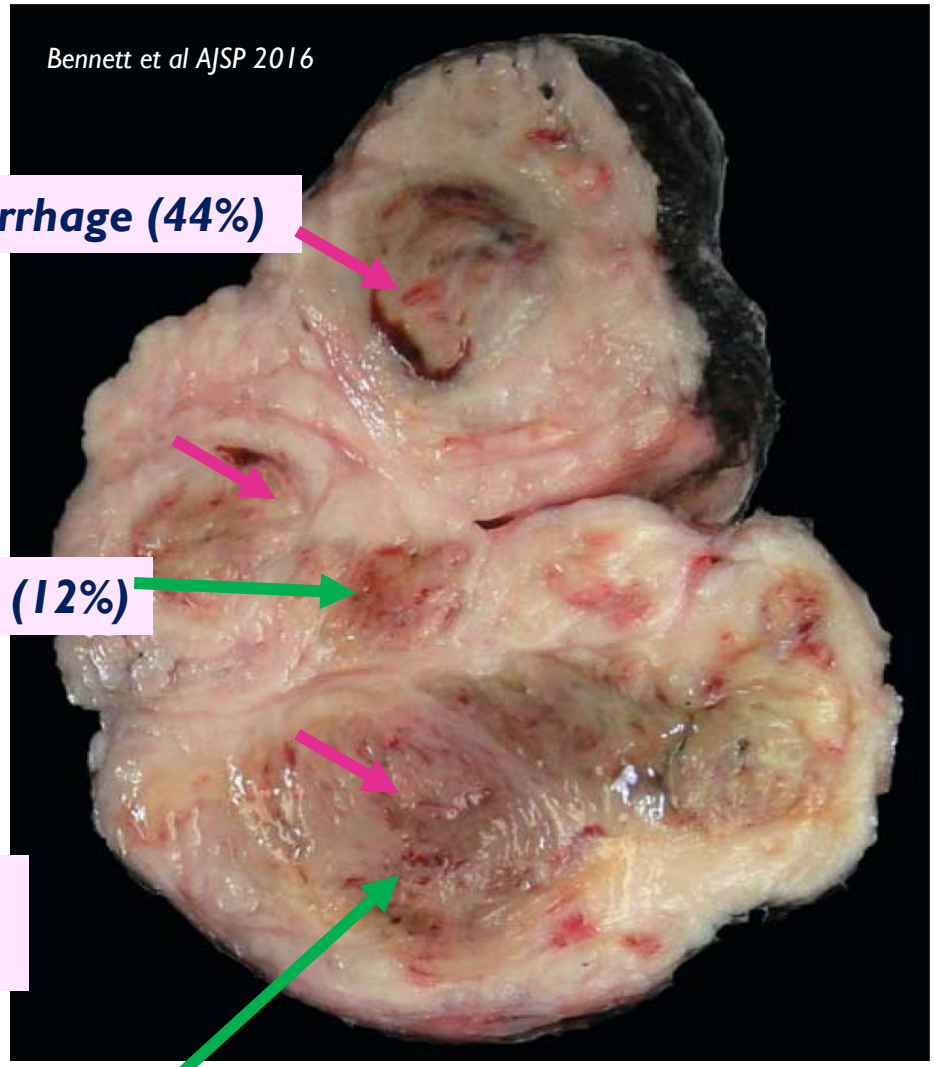

- *"mucinous appearance" (1%)*
- *ill-defined margin (1%)*

discoloration, primarily yellow but rarely green, dark brown, or red (16%)

ORIGINAL ARTICLE

Apoplectic Leiomyomas

A Morphologic Analysis of 100 Cases Highlighting Unusual Features

Jennifer A. Bennett, MD,† Colleen Lamb, MD,*† and Robert H. Young, MD*†*

softening (18%)

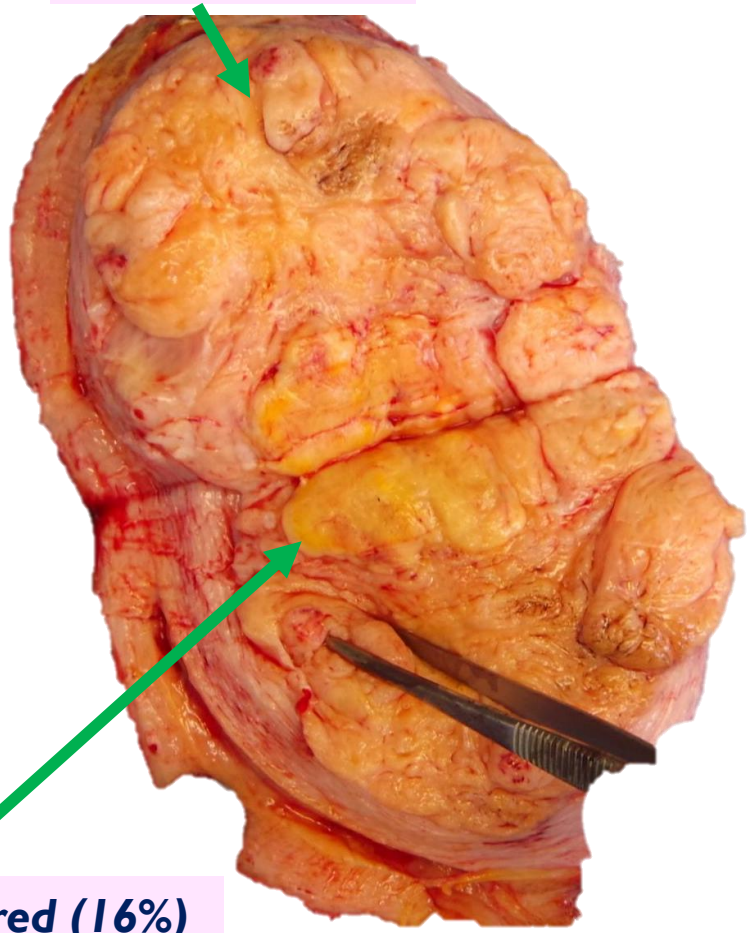

Mimickers of tumor cell necrosis in leiomyoma

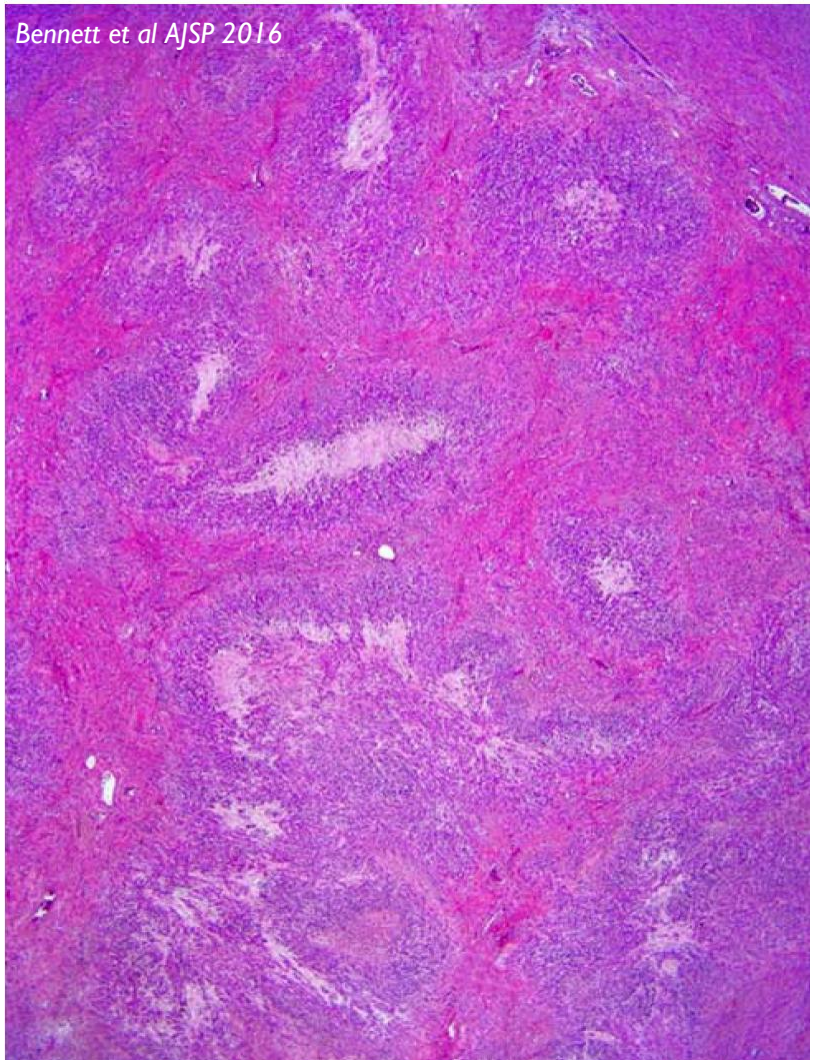

Multiple foci of necrosis

- Stellate central necrosis
- Hypercellular periphery
- Increased mitotic activity

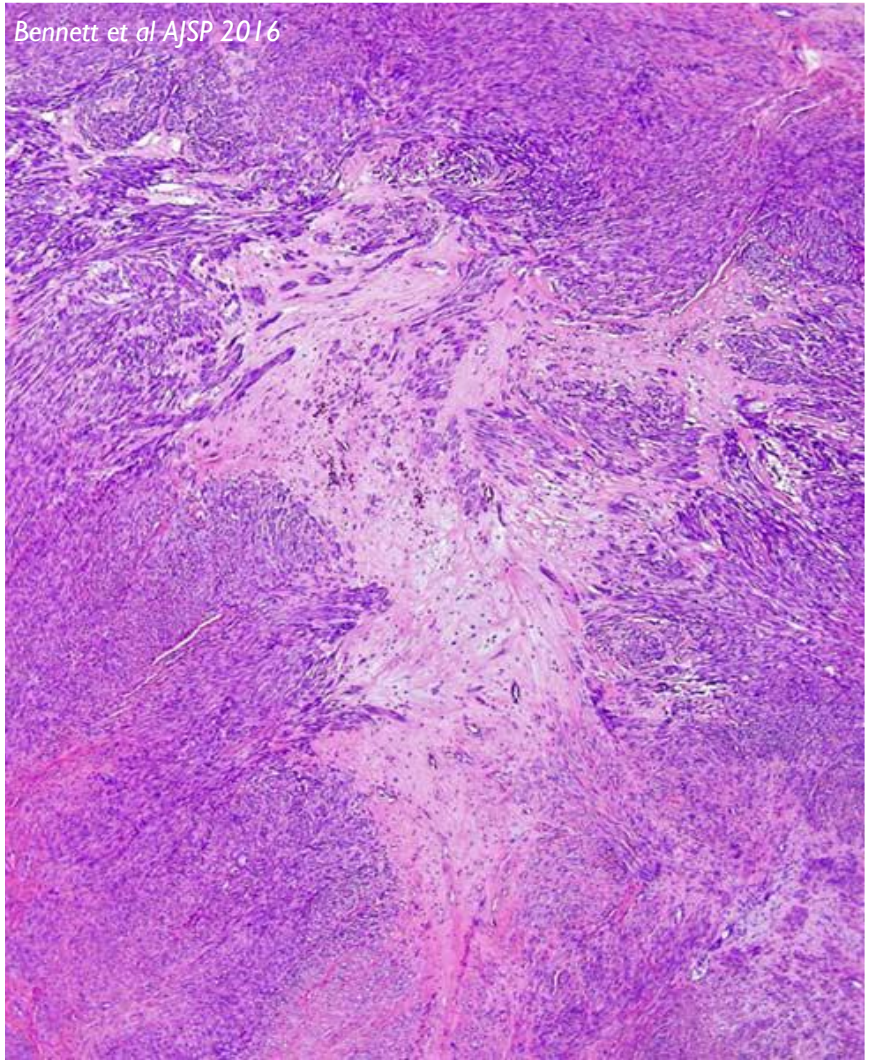

ORIGINAL ARTICLE

Apoplectic Leiomyomas

A Morphologic Analysis of 100 Cases Highlighting Unusual Features

Jennifer A. Bennett, MD,*† Colleen Lamb, MD,*† and Robert H. Young, MD*†

- Pyknosis and eosinophilia

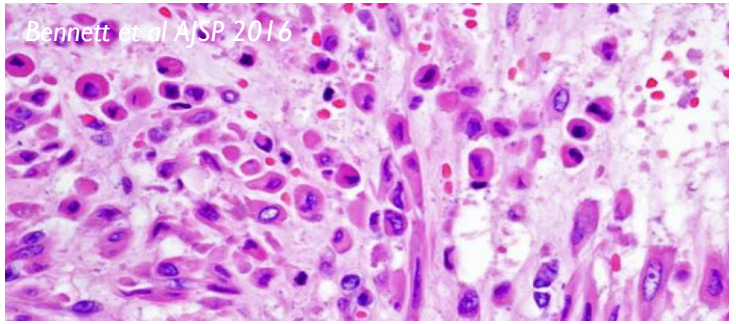

- Band of hyalinized collagen

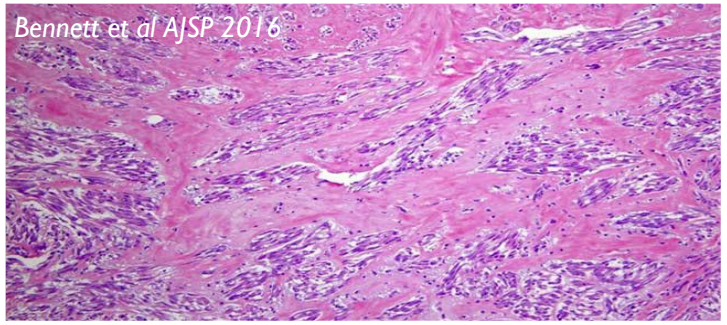

- Cyst-like appearance

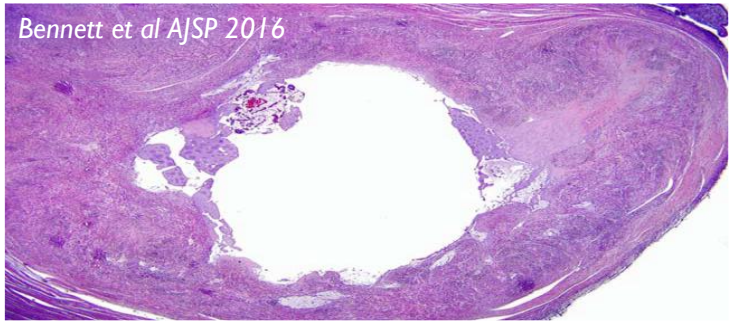

ORIGINAL ARTICLE

Interobserver Variability in the Interpretation of Tumor Cell Necrosis in Uterine Leiomyosarcoma

Diana Lim, MBBS, FRCPath, FRCPA,* Teresa Alvarez, MD,† Marisa R. Nucci, MD,‡ Blake Gilks, MD,§ Teri Longacre, MD,‖ Robert A. Soslow, MD,¶ and Esther Oliva, MD#

(Am J Surg Pathol 2013;37:650–658)

Necrosis: diagnostic issues

The discordant cases

Partial agreement

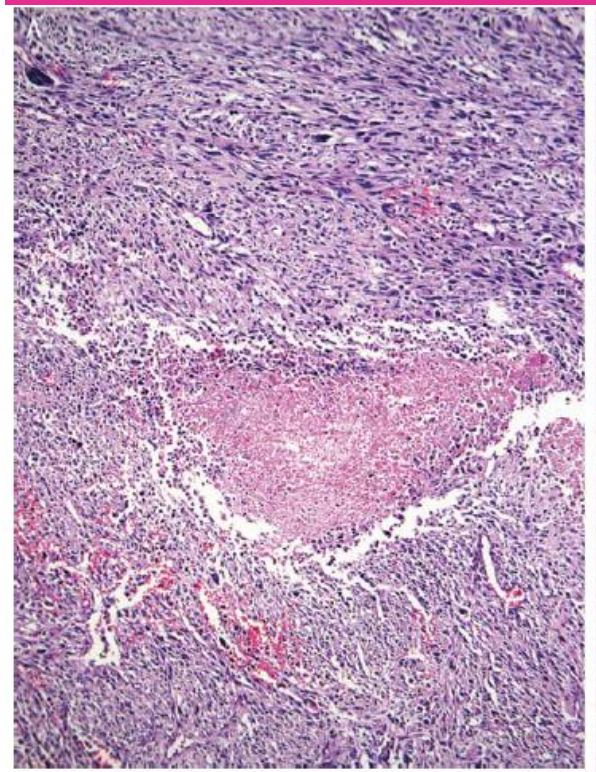

Abrupt transition BUT haemorrhage and inflammation

4/6 TCN;1/6 ischemic Necrosis; 1/6 indeterminate

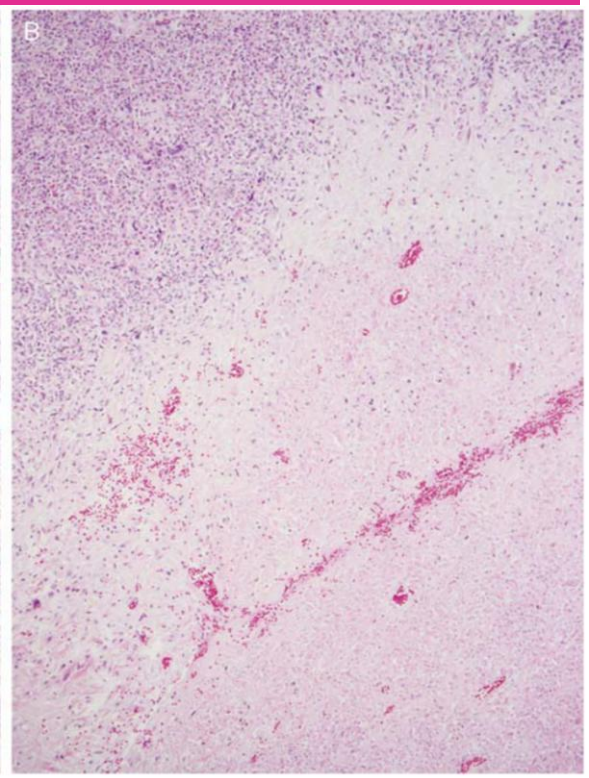

Fibrocollagen tissue with hemorrage BUT gost cells

4/6 ischemic Necrosis;1/6 TCN; 1/6 indeterminate

No Consensus

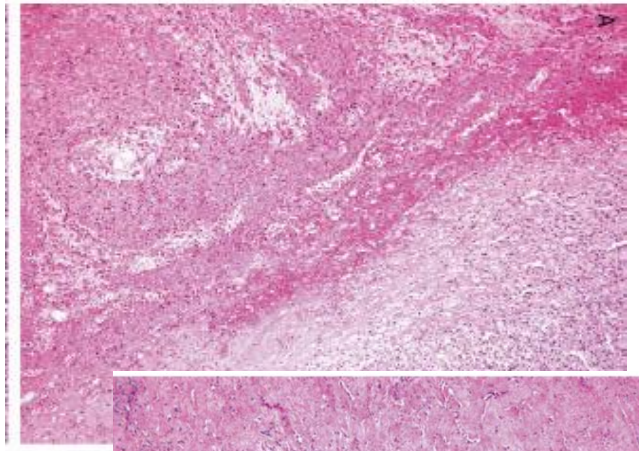

A. Gost cells BUT fibrin wall

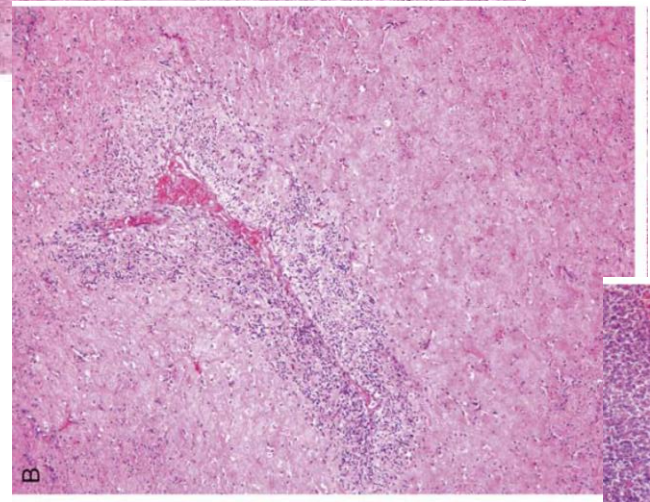

B. Perivascular rim of viable tumor cells with hyalinized stroma

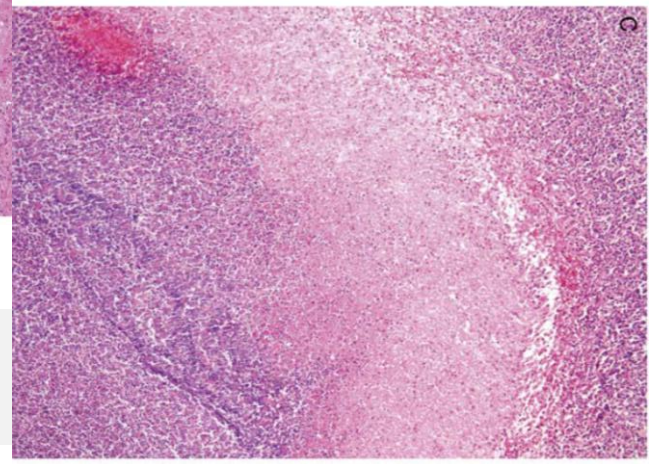

C. Abrupt transition BUT hemorrage and inflammation

Pitfalls in Assessing Necrosis

In pregnancy….

- **Hormonal status :**

Ischemic necrosis is more frequently associated with pregnancy and hormonal therapy

Study

97 LM during pregnancy (2015-2022)

Results

- **Geographic necrosis** 23%
- **Cell gost** outlines 51%
- **Perivascular preservation** 9%
- Moderate atypia 9%
- ER expression 65% negative (PR expressed in 61%)

No mitosis 74%
MSK algorithm *(p53, ATRX, MTAP, RB, PTEN)* **retained/wild type expression**
Follow up no recurrence (mean 19 months)

Conclusion

Ambigous necrosis is observed in pregnancy's LM.

ESP-Florence 2024-Oral presentation

OFP-02-008
Uterine leiomyomas during pregnancy: morphologic, immunohistochemical characteristics, and pitfalls in correlation with outcome

L. Mirkovic*, E. Olkhov-Mitsel, C. Parra-Herran
*Sunnybrook Health Sciences Centre, Canada

Background & objectives: Uterine leiomyomas during gestation often exhibit changes concerning for malignancy, such as increase in size and necrosis. We characterize the full spectrum of morphologic changes seen in uterine leiomyomas excised during pregnancy, focusing on changes attributed to malignant mesenchymal neoplasms.
Methods: Two expert pathologists reviewed 97 specimens (2015-2022) and recorded morphologic features. Immunohistochemistry for ER, Desmin, ALK, Caldesmon, CD10, CyclinD1, PR, p53, ATRX, MTAP, RB, PTEN, HMB45 and MelanA was performed on tissue microarrays (2 cores/tumour). Clinical data, including follow-up information, were obtained from electronic medical records.
Results: Mean age was 37 years (27-55). Mean leiomyoma size was 4.3 cm (0.7-16). With a mean follow-up of 19 months (0-80) none developed malignancy.
Ischemia often mimicked geographic necrosis with sharp border between viable and non-viable tumour (23%), cell ghost outlines (51%) and perivascular preservation (9%). Focal (<30%) myxoid change occurred in 42%, and moderate atypia in 9%. Most cases exhibited no mitoses (74%). Only one case reached 10 mitoses/10-HPF.
Desmin, caldesmon, PR were diffusely positive in 93%, 82% and 61%, while 65% were negative for ER. ALK was positive in 6%, always focal (up to 5% of tumour). p53, ATRX, MTAP, PTEN, RB showed retained/wild-type expression in all cases.
Conclusion: Uterine leiomyomas excised during pregnancy frequently exhibit changes that are attributed to malignant mesenchymal neoplasms (including necrosis that is difficult to subtype, myxoid change, focal expression of ALK, loss of ER staining). Despite this, clinical follow-up revealed no adverse outcomes in this cohort to-date. Pathologists should be aware of these potential pitfalls and avoid a diagnosis of malignancy or uncertain malignant potential (STUMP) in a smooth muscle tumour in the setting of pregnancy.

Diagnostic Pitfalls associated with ischemic necrosis

Histopathology

Histopathology 2017, **71**, 743–750. DOI: 10.1111/his.13282

Immunoexpression of p16 in uterine leiomyomas with infarct-type necrosis: an analysis of 35 cases*

Philip P Ip,[1] Diana Lim,[2] Annie N Y Cheung[1] & Esther Oliva[3]

Take home message :

1) **Sample away from necrosis**
2) **Do not use p16 positivity as marker of malignity**

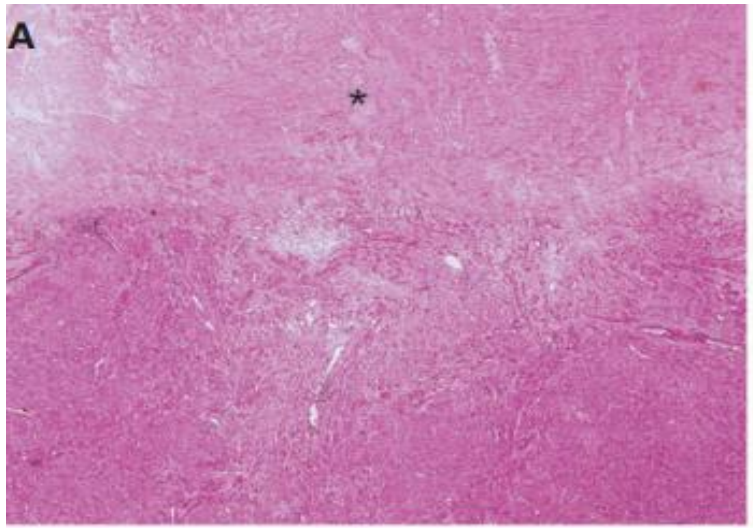

Ischemic necrosis with hypercellularity

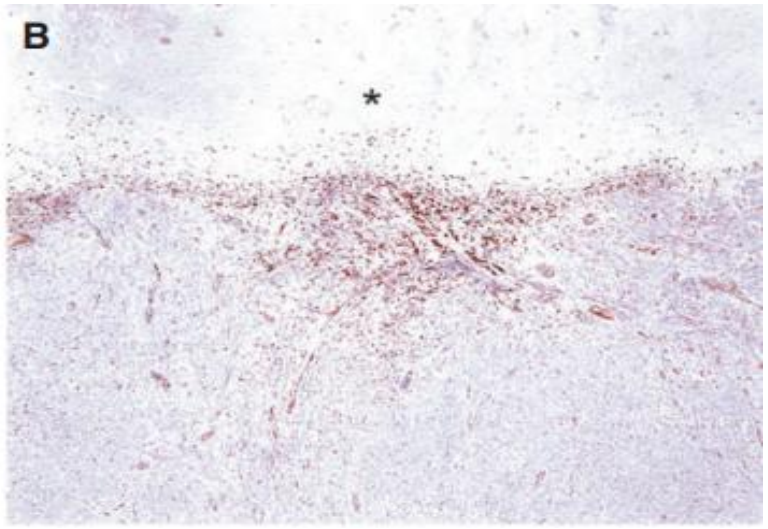

P16 positivity in the hypercellular areas near necrosis

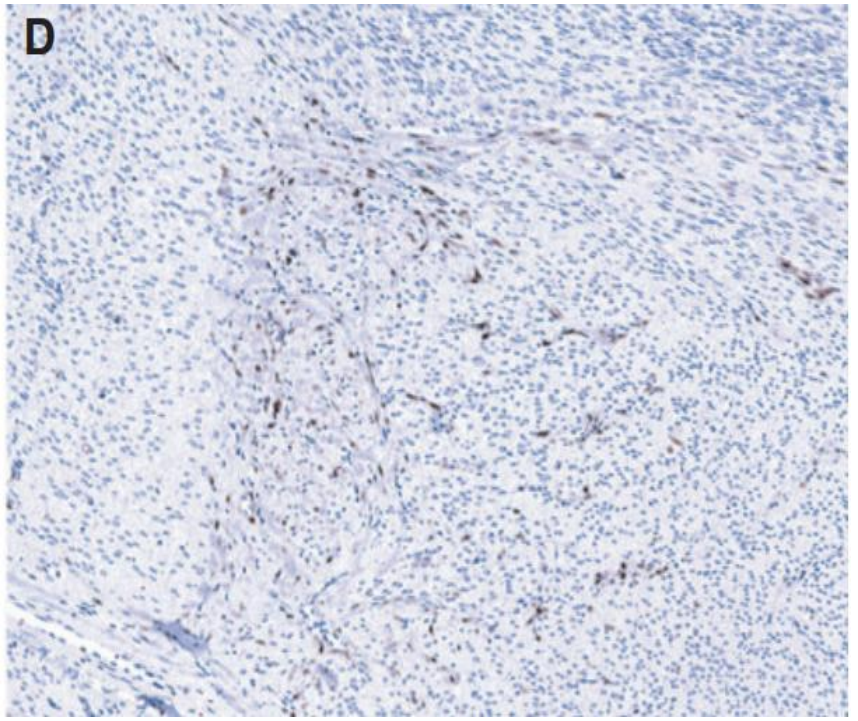

Away from necrosis p16 was negative!

Outline

1. Necrosis :
   - Morphologic criteria and issues in smooth muscle tumours of the uterus
     - **How to survive in the jungles 'necrosis**
   - Necrosis in endometrial stromal sarcomas
2. Mitoses
3. Prognostic value of necrosis and mitoses in smooth muscle tumours
4. Practical cases
5. Conclusions

How to survive in the necroses' jungle

- **Clinical data**
  - age, hormonal treatment
- **Macroscopy**
  - Macroscopic features
  - How to sample the macroscopy

How to survive in the necroses 'jungle

Clinical data

- **Age:**

The peak of incidence of LMS is in the 6th decade (>50 years)

  - LMS in young patient is possible but be careful!!

- **Pre-surgical treatment**
  - Embolisation: ischemic necrosis+++

Macroscopy

leiomyosarcoma

Soft, fleshy, beefy mass with necrosis



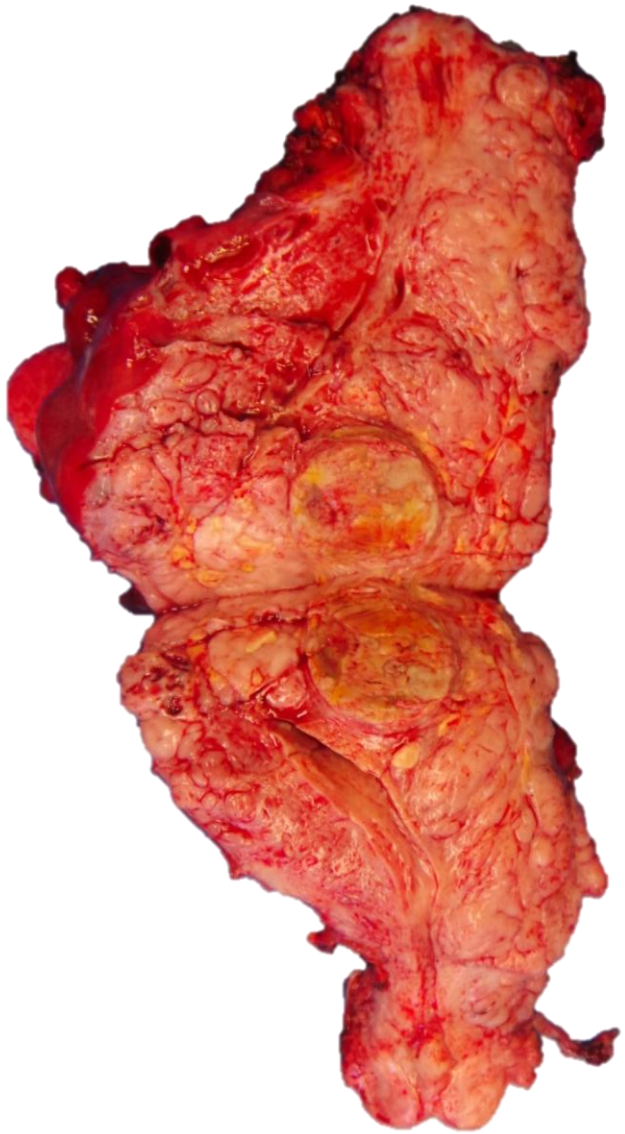



Courtesy of Dr Neumann F

size

LMS: mean size: 10 cm

But 25% of LMS are <5 cm!

Macroscopy

Leiomyosarcoma

- Fleshy
- necrotic

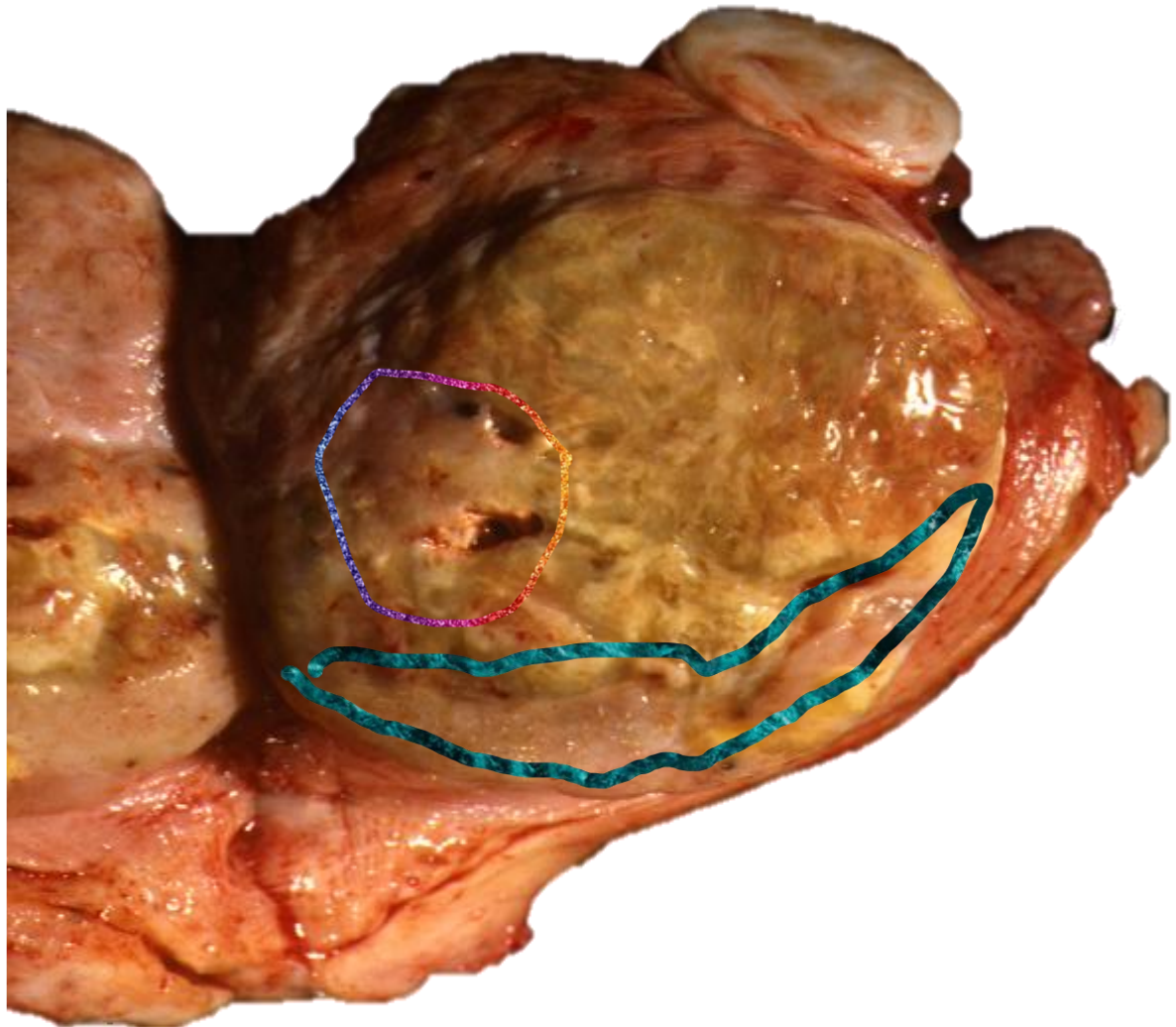

Leiomyoma

- dense
- Firm
- Rubbery
- whorled

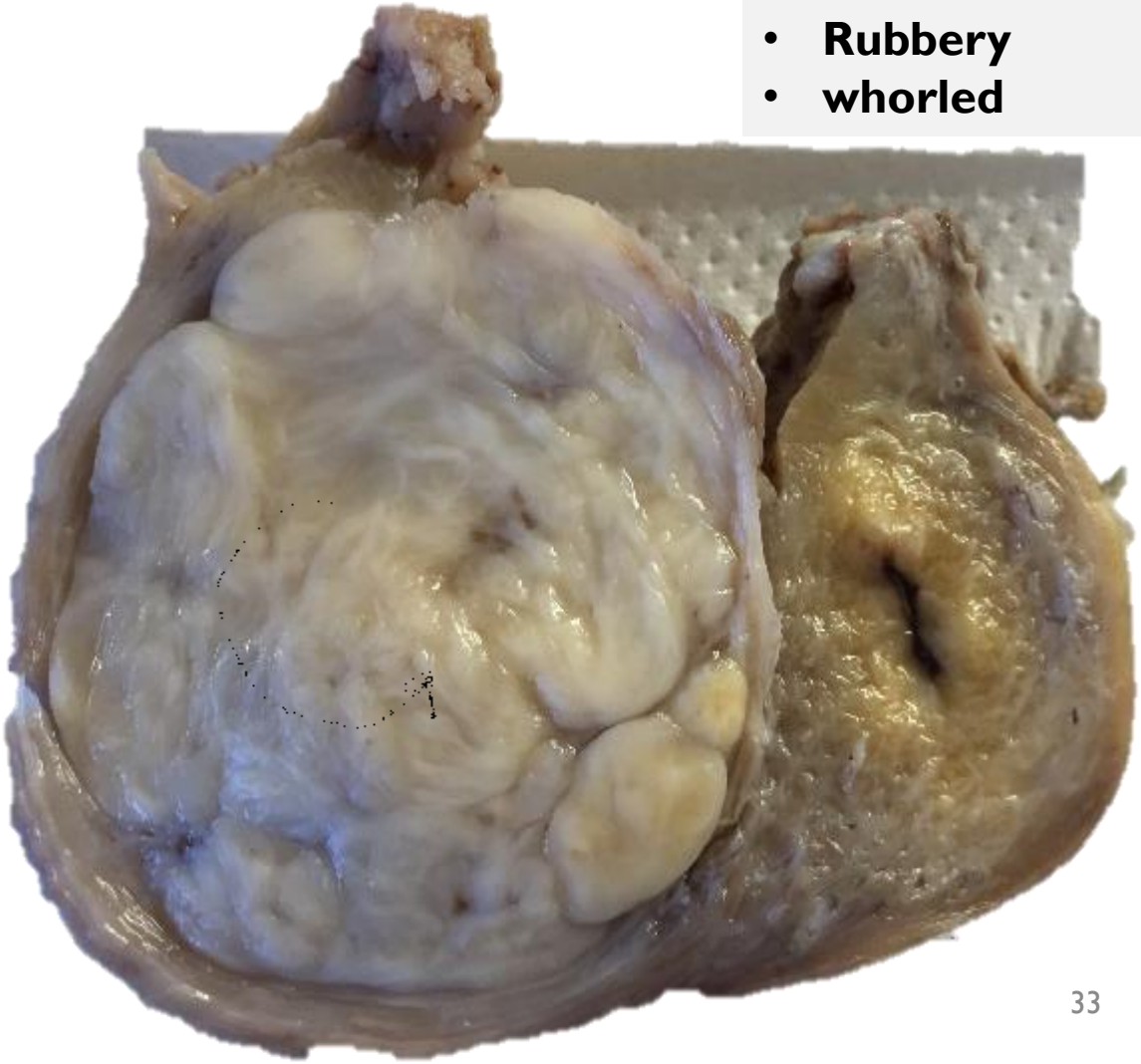

How to Sample Smooth Muscle Tumors with Necrosis

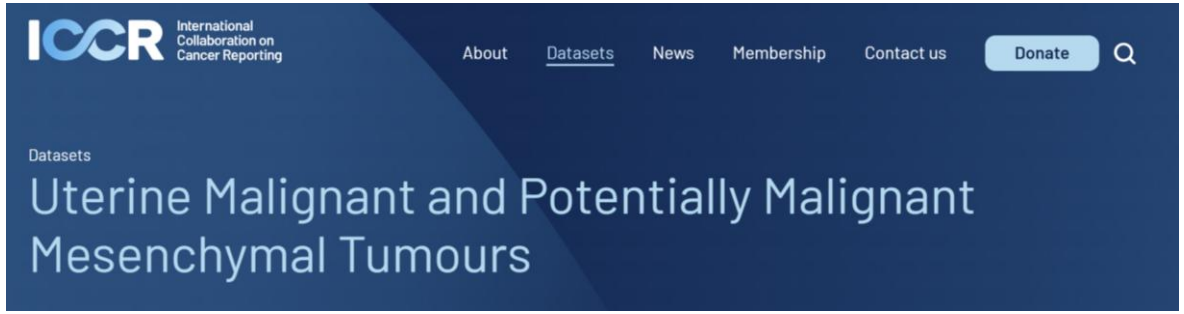

No minimal sampling

The Royal College of Pathologists
Pathology: the science behind the cure

1 block of the largest fibroid and 1 or 2 at random

rapid growth or abnormal radiological appearances, particularly in post menopausal status, haemorrhage, cystic degeneration or variation in colour should prompt more extensive sampling

COLLEGE of AMERICAN PATHOLOGISTS

Extensive sampling may be required to identify regions diagnostic of malignancy

How to Sample Smooth Muscle Tumors with Necrosis

- **Extensive sampling**
- **Between necrosis and viable tissue**
- **Far from necrosis**

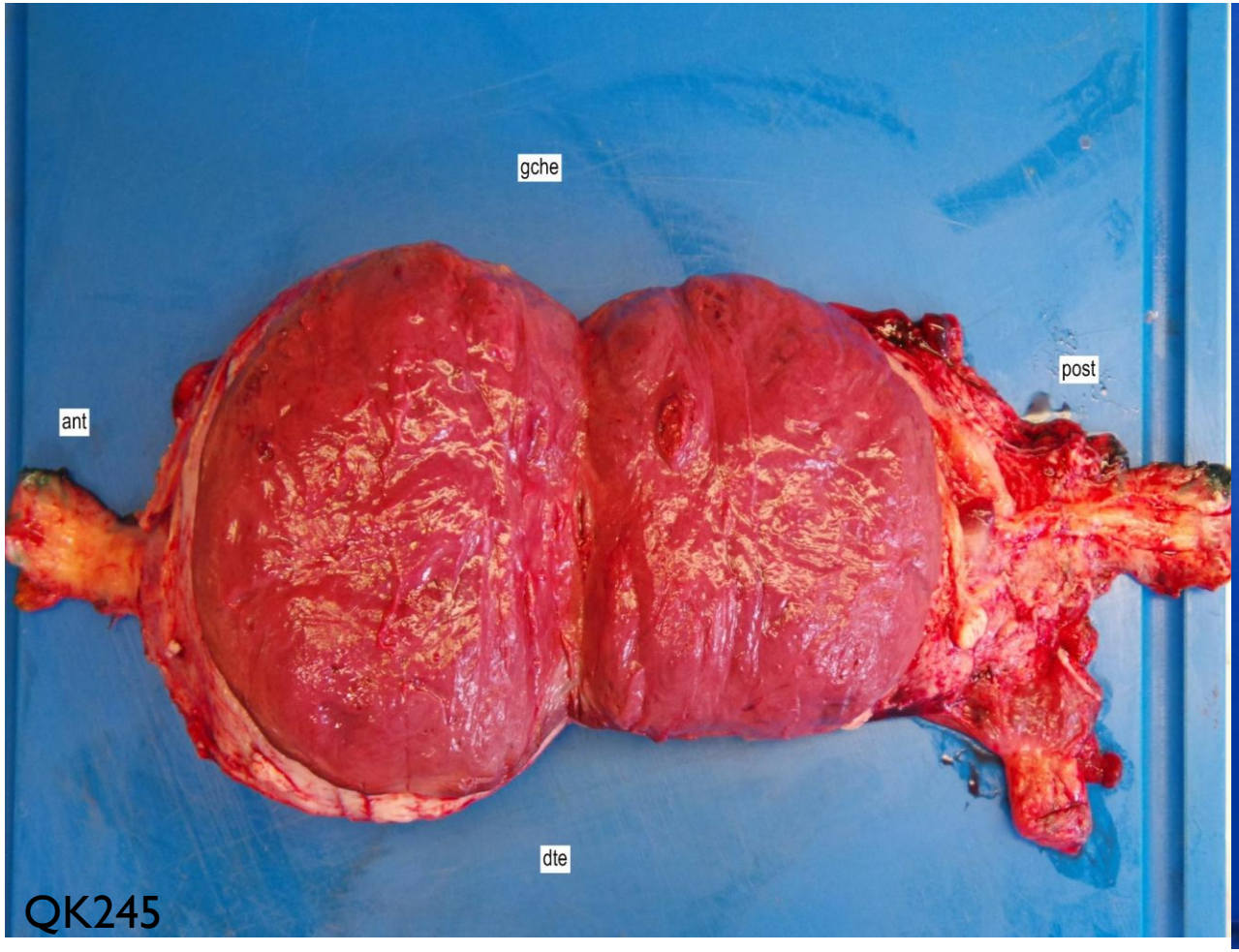

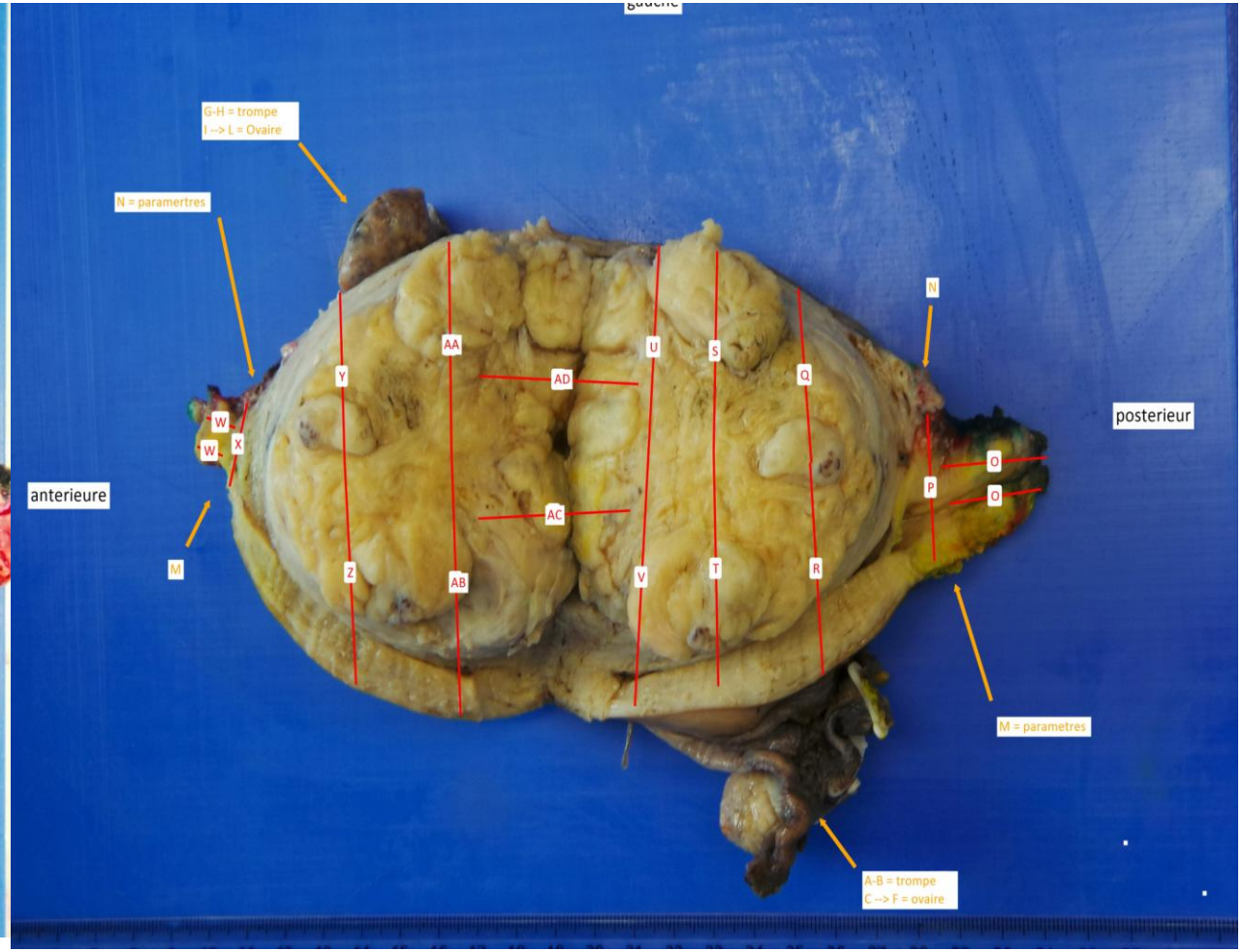

Histochemical Tools: Differentiating ischemic necrosis from tumor cell necrosis

Modern Pathology (2015) 28, 830–835
© 2015 USCAP, Inc All rights reserved 0893-3952/15 $32.00

Biomarker resolution of uterine smooth muscle tumor necrosis as benign *vs* malignant

Eric J Yang and George L Mutter

Department of Pathology, Division of Women's and Perinatal Pathology, Harvard Medical School, Brigham and Women's Hospital, Boston, MA, USA

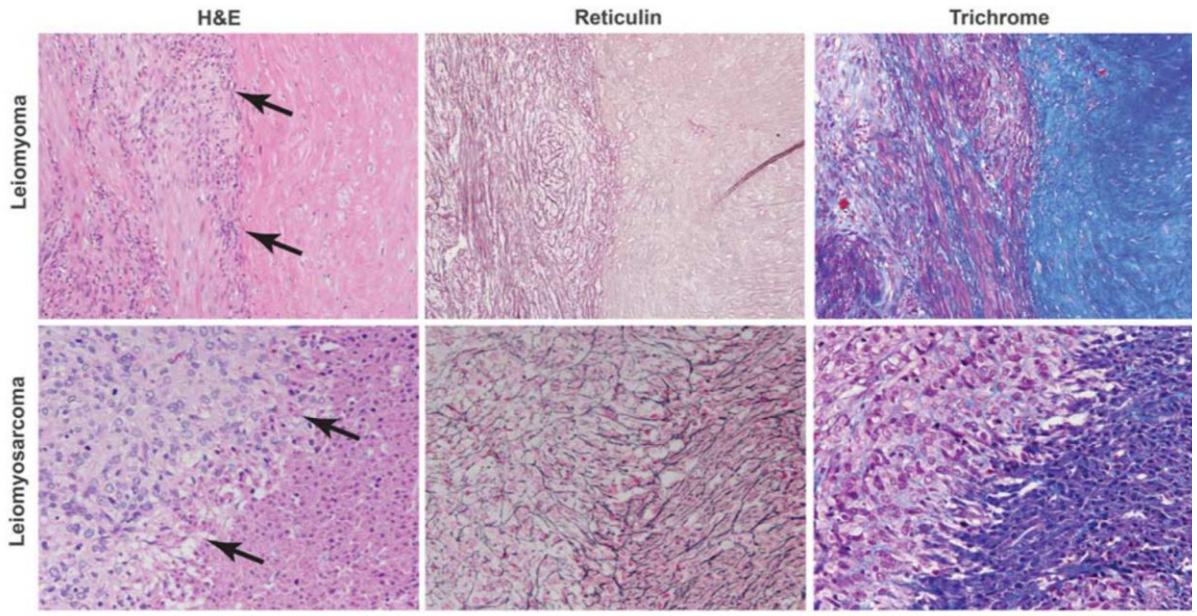

Table 1 Biomarker patterns by diagnosis (benign/malignant)

Marker	Area scored	Staining pattern	Benign (leiomyoma)	Malignant (leiomyosarcoma)	Significance
Reticulin	Nonviable	Absent	61.1%	4.5%	$P<0.001$ χ^2
		Present—honeycomb	33.3%	90.9%	
		Present—linear	5.6%	4.5%	
Collagen	Nonviable	Absent	0%	63.6%	$P<0.001$ Fisher exact
		Present	100%	36.4%	
Mitotic activity (MIB1)	Viable area, gradient toward interface	Absent	33.3%	13.6%	$P=0.009$ χ^2
		Even	44.4%	40.9%	
		Increase	22.2%	4.5%	
		Decrease	0%	40.9%	
		Total (100%)	18	22	

- **Reticulin absent**: 61% of **LM** (vs 4.5% of LMS) p< 0.001
- **Reticulin honeycomb** 91% of **LMS** (vs 33% of LM)
- **Collagen: absent** 64% of **LMS** p<0.001
- **Collagen: present 100%LM** (vs 36% of LMS)

I do not have personal experience

Outline

1. Necrosis :
   - Morphologic criteria and issues in smooth muscle tumours of the uterus
     - How to survive in the jungles 'necrosis
   - **Necrosis in endometrial stromal sarcomas**
2. Mitoses
3. Prognostic value of necrosis and mitoses in smooth muscle tumours
4. Practical cases
5. Conclusions

Necrosis in endometrial stromal sarcomas (ESS)…

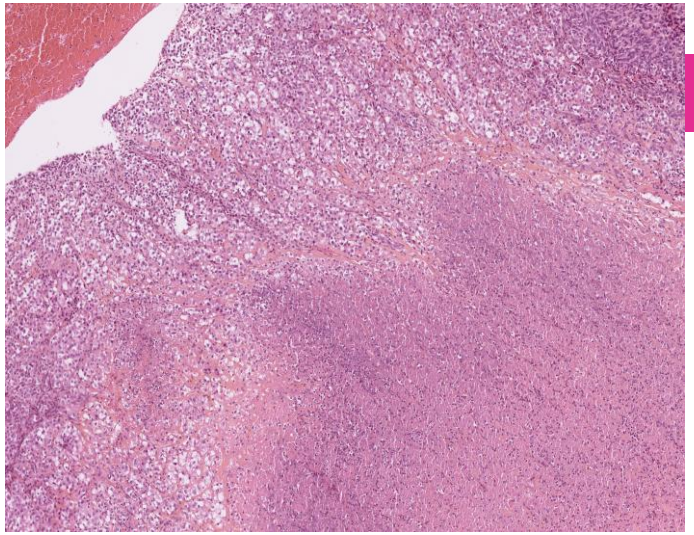

Necrosis in endometrial stromal sarcomas

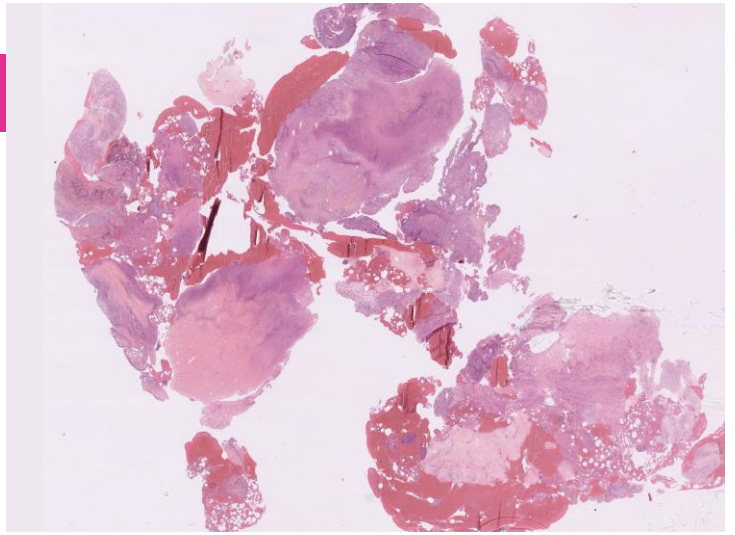

Worrisome feature

Exclude an high grade ESS

- Look for atypia, mitosis
- ER/PR negative or lower expression
- Cyclin D1 diffuse positivity

Exclude an high grade transformation of a low grade ESS

- Look for atypia, mitosis
- ER/PR lower expression
- Cyclin D1 diffuse positivity

RNAseq

YWHAE, BCOR fusions, BCOR ITD, BCORL1 etc

Sampling!!!!

Sampling!!!!

Outline

1. Necrosis :
   - Morphologic criteria and issues in smooth muscle tumours of the uterus
     - How to survive in the jungles 'necrosis
   - Necrosis in endometrial stromal sarcomas

2. **Mitoses**
3. Prognostic value of necrosis and mitoses in smooth muscle tumours
4. Practical cases
5. Conclusions

2020-WHO diagnostic criteria

Mitotic cut off varies according to the subtypes

Spindle LMS
At least 2/3 features

- **atypia**
- **Mitosis ≥4 mitoses/mm²** (≥10/10HPF)
- **Tumor cell necrosis**

Epithelioid LMS
at least 1/3 features

- **atypia**
- **Mitosis ≥1,6 mitoses/mm²** (≥4/10HPF)
- **Tumor cell necrosis**

Myxoïd LMS
at least 1/4 features

- **Infiltrative borders**
- **atypia**
- **Mitosis->0,4mitoses/mm²** (>1/10HPF)
- **Tumor cell necrosis**

Mitotit count: issues

Factors that can influence the mitotic count

Modern Pathology (2021) 34:1651–1657
https://doi.org/10.1038/s41379-021-00825-7

USCAP

REVIEW ARTICLE

Counting mitoses: SI(ze) matters!

Ian A. Cree[1] · Puay Hoon Tan[2] · William D. Travis[3] · Pieter Wesseling[4,5] · Yukako Yagi[3] · Valerie A. White[1] · Dilani Lokuhetty[1,6] · Richard A. Scolyer[7]

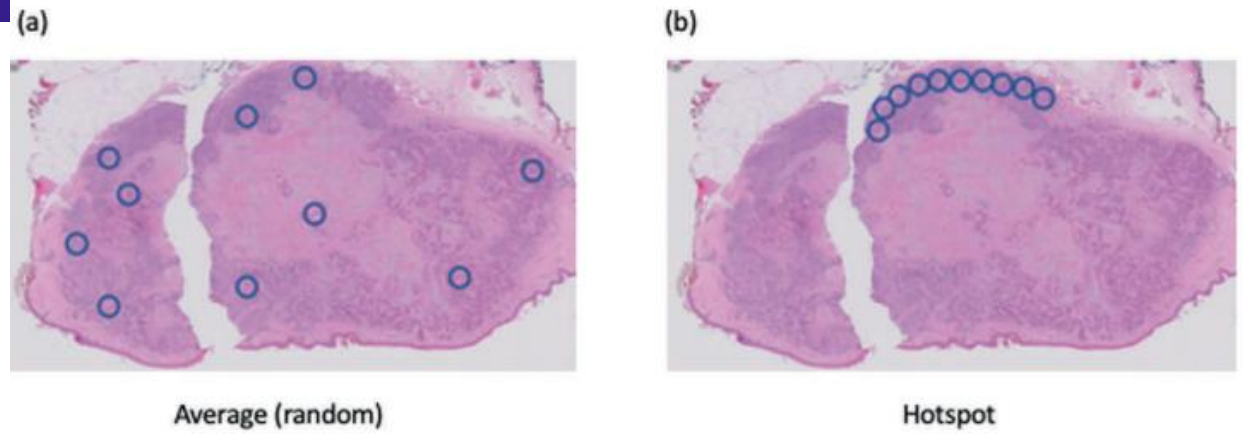

Counting methods:

"average": Mitoses are counted in randomly selected HPFs, and the average number per mm^2 is calculated

"hotspot": Start with low power to identify areas with high mitotic activity, then focus on adjacent regions for counting

Mitotic Count: Expressed in mitoses per mm^2, better suited for digital pathology

Software and Algorithms: Various software and algorithms have been proposed to automate mitotic counting

(Puri M at al J Pathol Informatic 2019; Stathonikos N et al J Pathol clinical research 2024)

How to recognize a mitosis

tips

Mitosis:

- absence of nuclear membrane
- cytoplasm still recognizable but pale
- chromatin with hairy extensions

(single in metaphase, double in telophase)

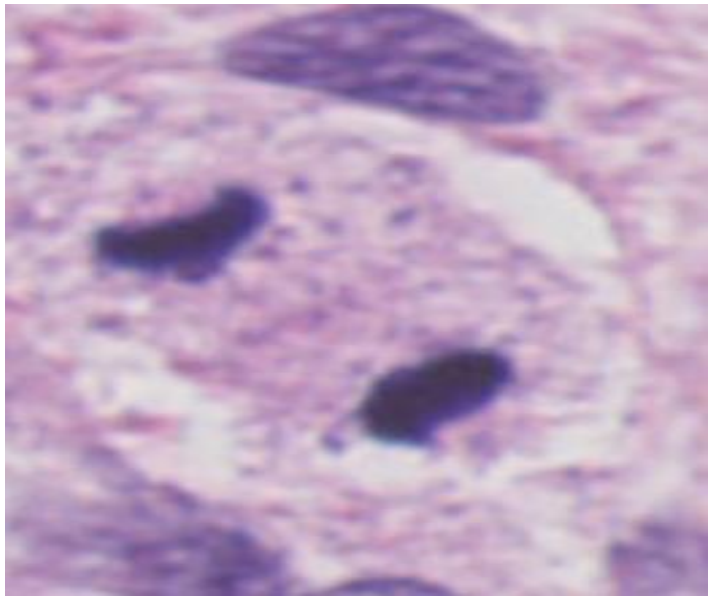

Apoptosis:

- pink retracted cytoplasm
- dense granular chromatin

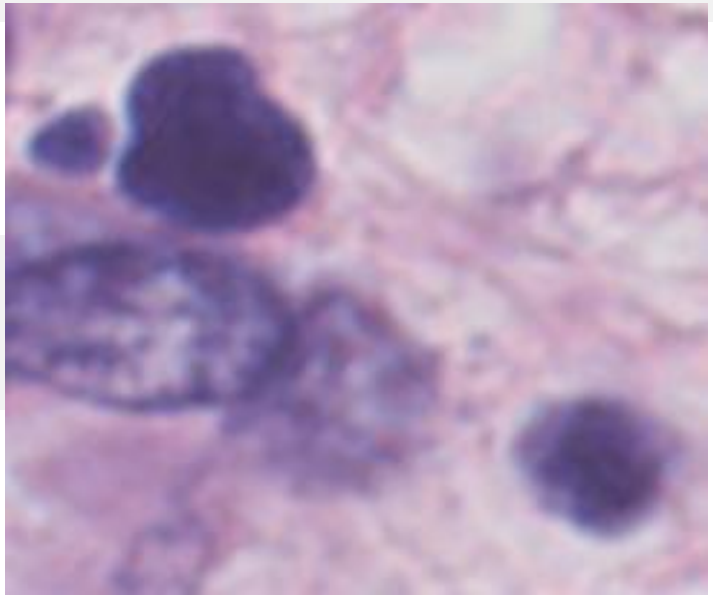

Karryorrhexis:

- Nuclear fragmentation

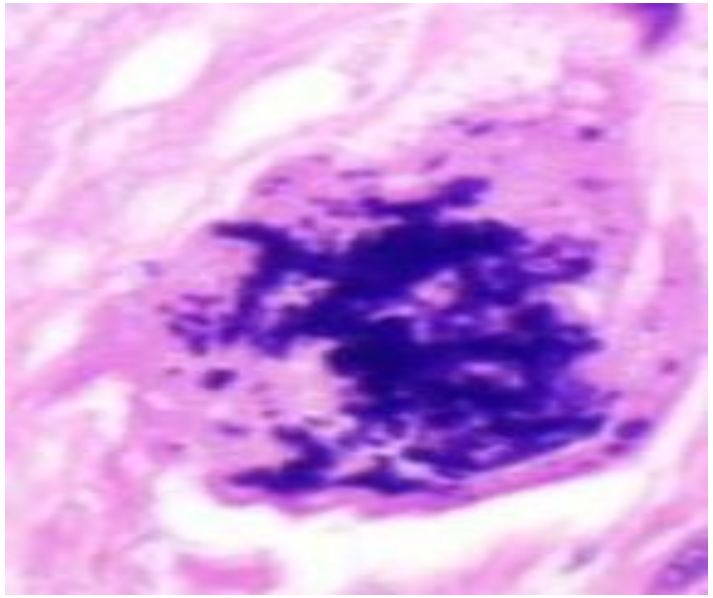

How to recognize an atypical mitosis

Atypical **mitosis**

tips

- **presence of more than one spindle axis (tripolar/tetrapolar)**

- **an offset of sister chromatids lacking of attachment to the spindle apparatus**

- **a single chromatid being tethered to both spindle poles obviously aneuploid metaphases**

Histopathology

Histopathology 2018, **73**, 284–298. DOI: 10.1111/his.13515

Predictors of adverse outcome in uterine smooth muscle tumours of uncertain malignant potential (STUMP): a clinicopathological analysis of 22 cases with a proposal for the inclusion of additional histological parameters

Mamta Gupta,[1,2] Anna L Laury,[3] Marisa R Nucci[2,4] & Bradley J Quade[2,4]

[1]*Department of Pathology, Beth Israel Deaconess Medical Center,* [2]*Harvard Medical School, Boston, MA,* [3]*Department of Pathology, Cedars-Sinai, Los Angeles, CA, and* [4]*Division of Women's and Perinatal Pathology, Department of Pathology, Brigham and Women's Hospital, Boston, MA, USA*

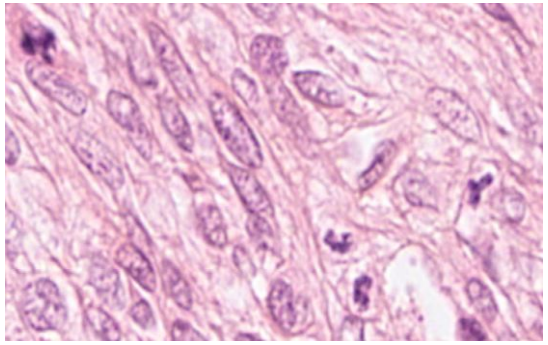

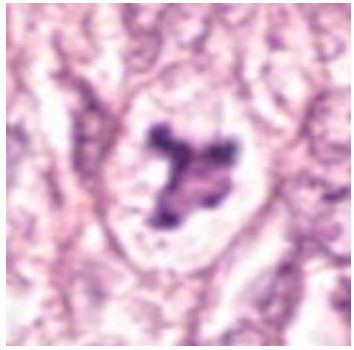

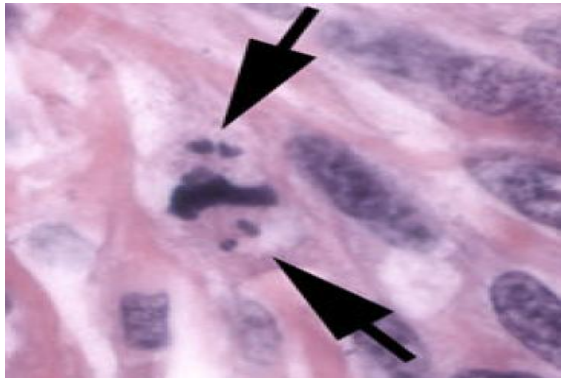

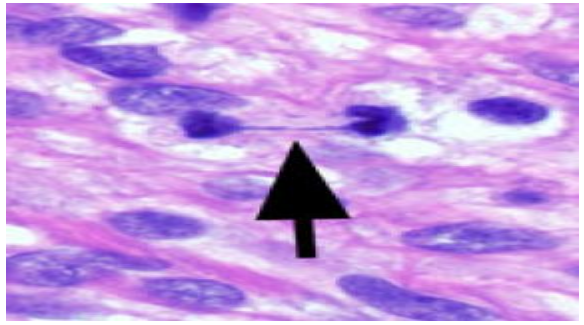

Prognostic value of tumor cell necrosis and mitoses

Prognostic value of tumor cell necrosis and mitoses in leiomyosarcoma

www.nature.com/modpathol

USCAP

ARTICLE

Check for updates

A novel morphology-based risk stratification model for stage I uterine leiomyosarcoma: an analysis of 203 cases

David B. Chapel[1,2✉], Aarti Sharma[1,3], Ricardo R. Lastra[3], Livia Maccio[4], Emma Bragantini[4], Gian Franco Zannoni[5], Suzanne George[6], Bradley J. Quade[1], Carlos Parra-Herran[1] and Marisa R. Nucci[1]

© The Author(s), under exclusive licence to United States & Canadian Academy of Pathology 2022

For stage I LMS

three-tiered risk model for 5-year disease-free and disease specific survival in women with stage I uterine leiomyosarcoma

Risk score= (T necrosis)(1)+(mitoses>25/10HPF(2.4mm²)(2)+(atypical mitoses)(2)+(LVI)(3)+(serosal abutment)(5)

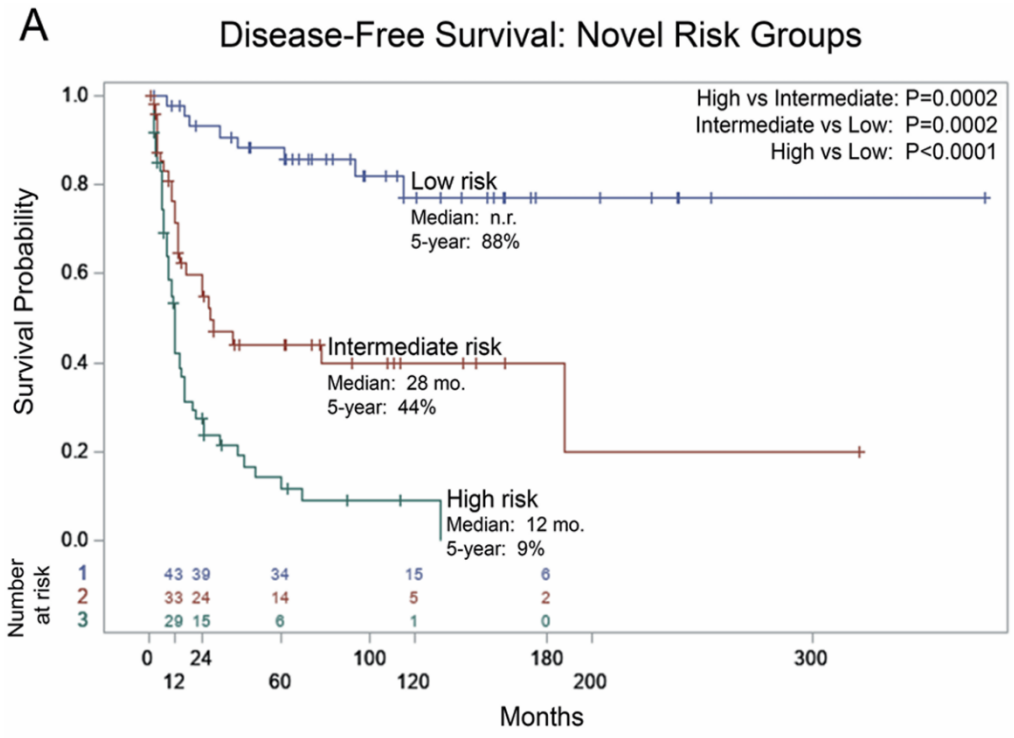

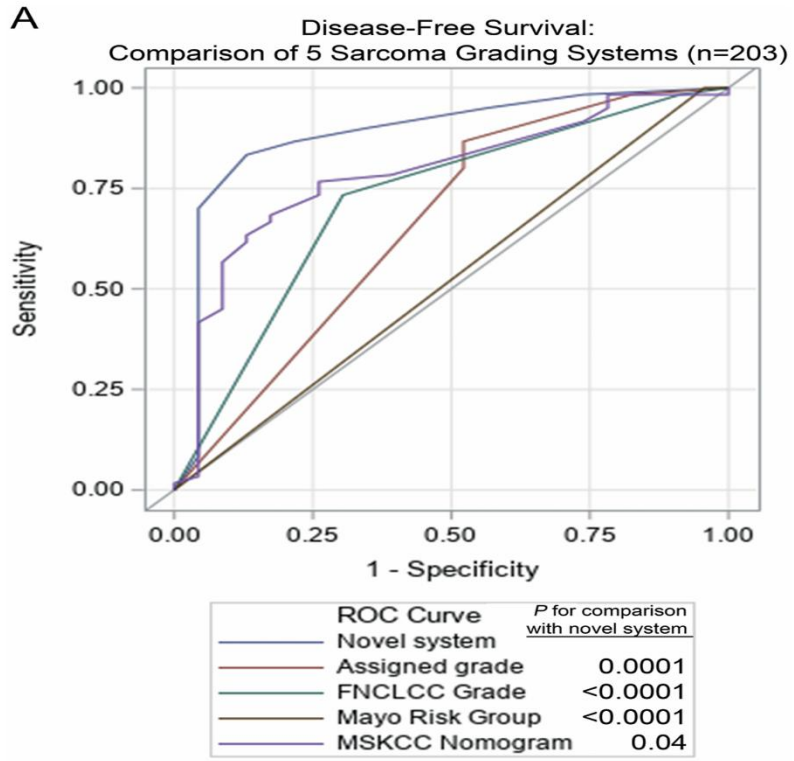

Low risk:0-2
Intermediate risk: 3-5
High risk: 6-13

AUC 0.9060 (0.8462–0.9659) for disease-free survival

Necrosis+mitoses=3/13 points

Prognostic value of tumor cell necrosis in STUMP

Tumor cell necrosis was the second Stanford item in STUMP (26%)

Tumor cell necrosis was the second Stanford item for risk recurrence (17,2 %)

PMID: 33786917

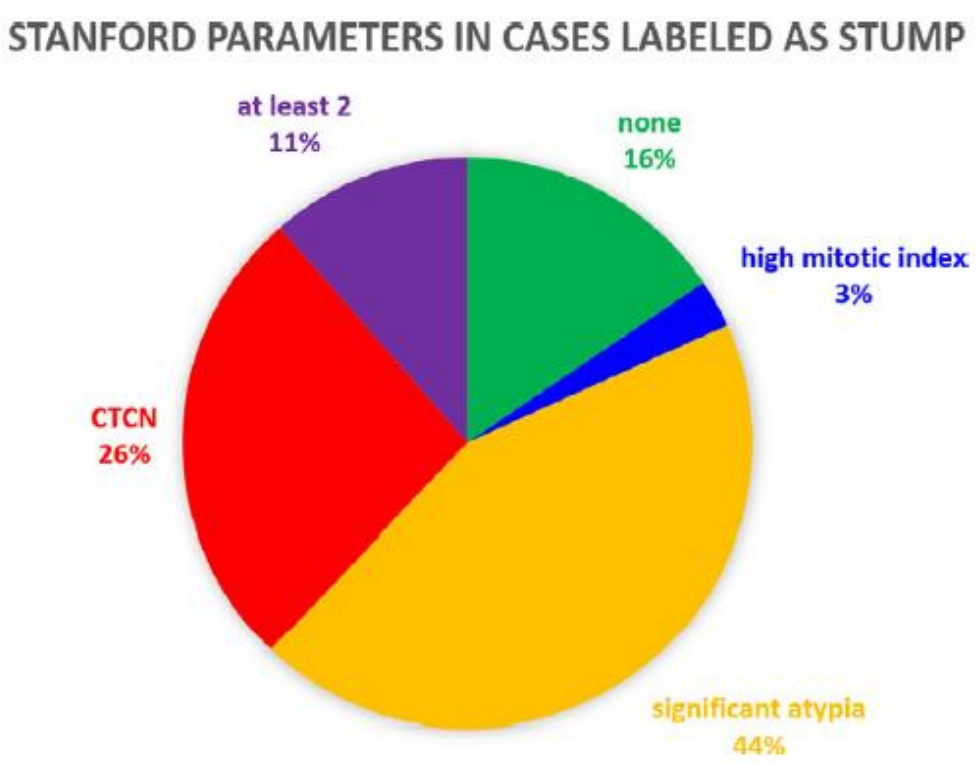

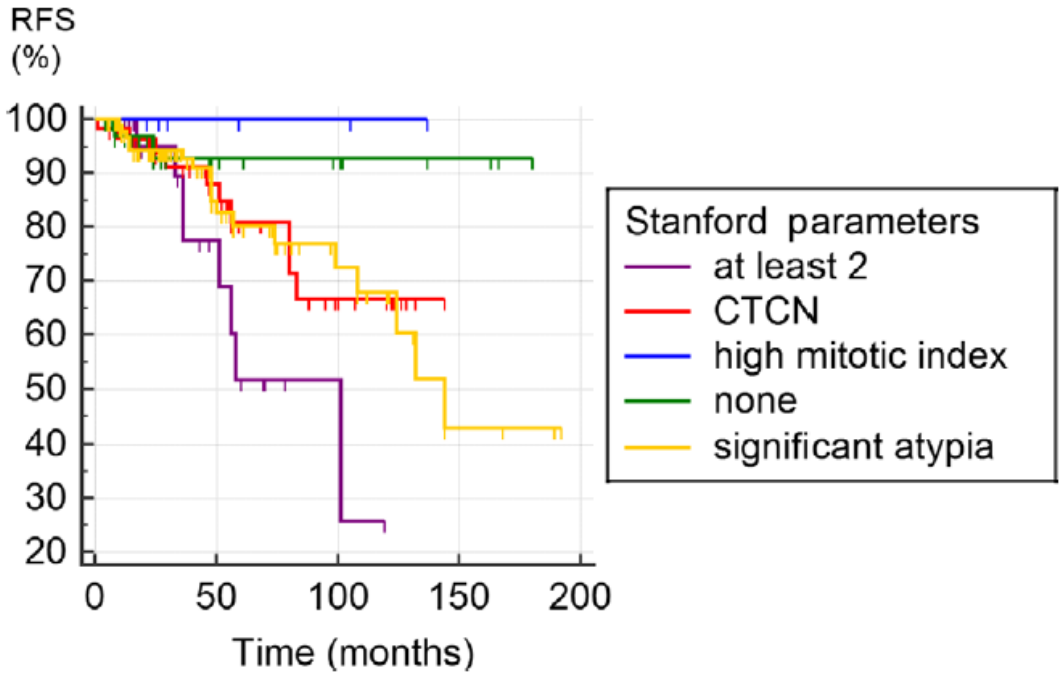

Some practical cases

Case 1

- **Clinical settings**…
  52-year-old patient
  Total hysterectomy for 5 leiomyomas
- the largest measuring 6 cm

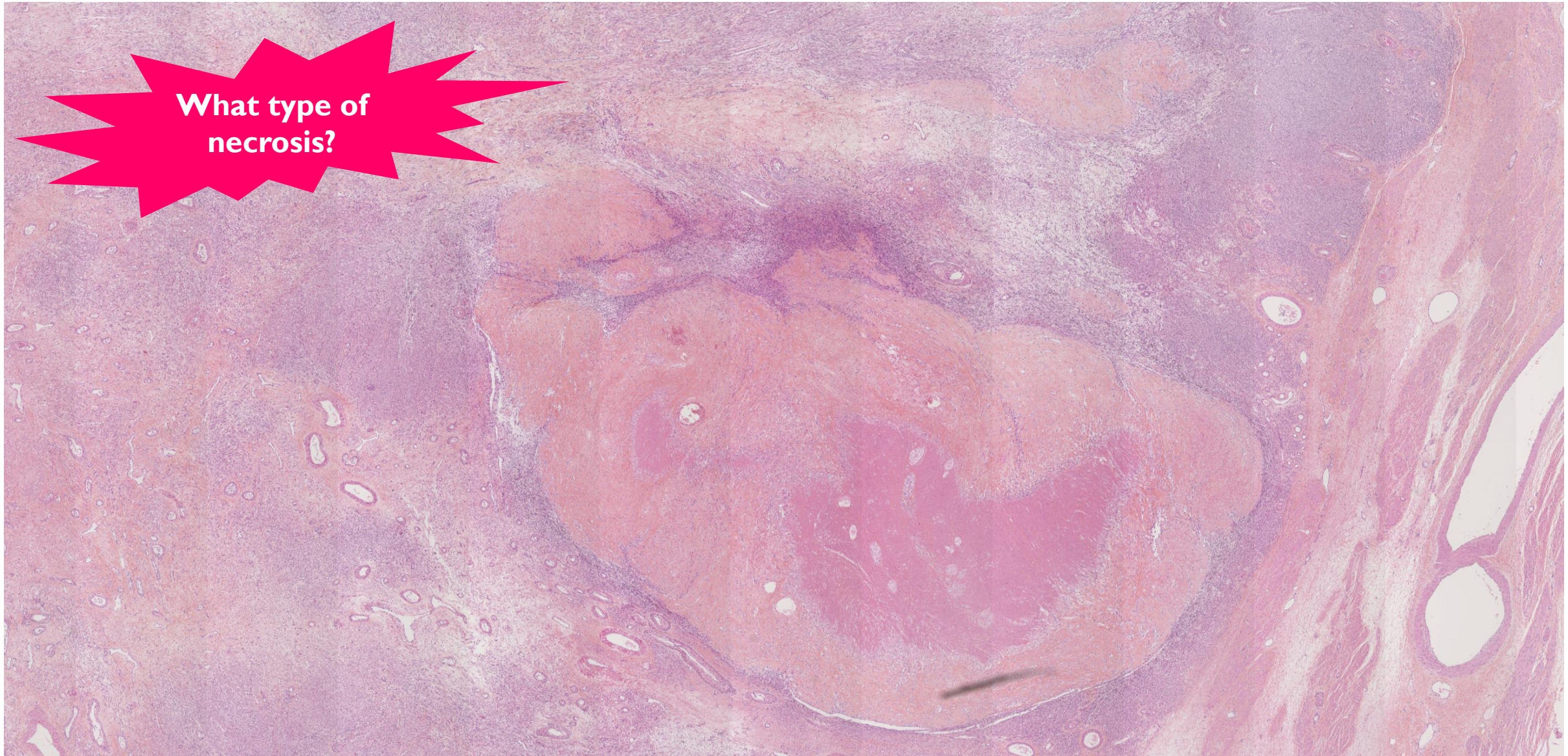

Case 1

What type of necrosis?

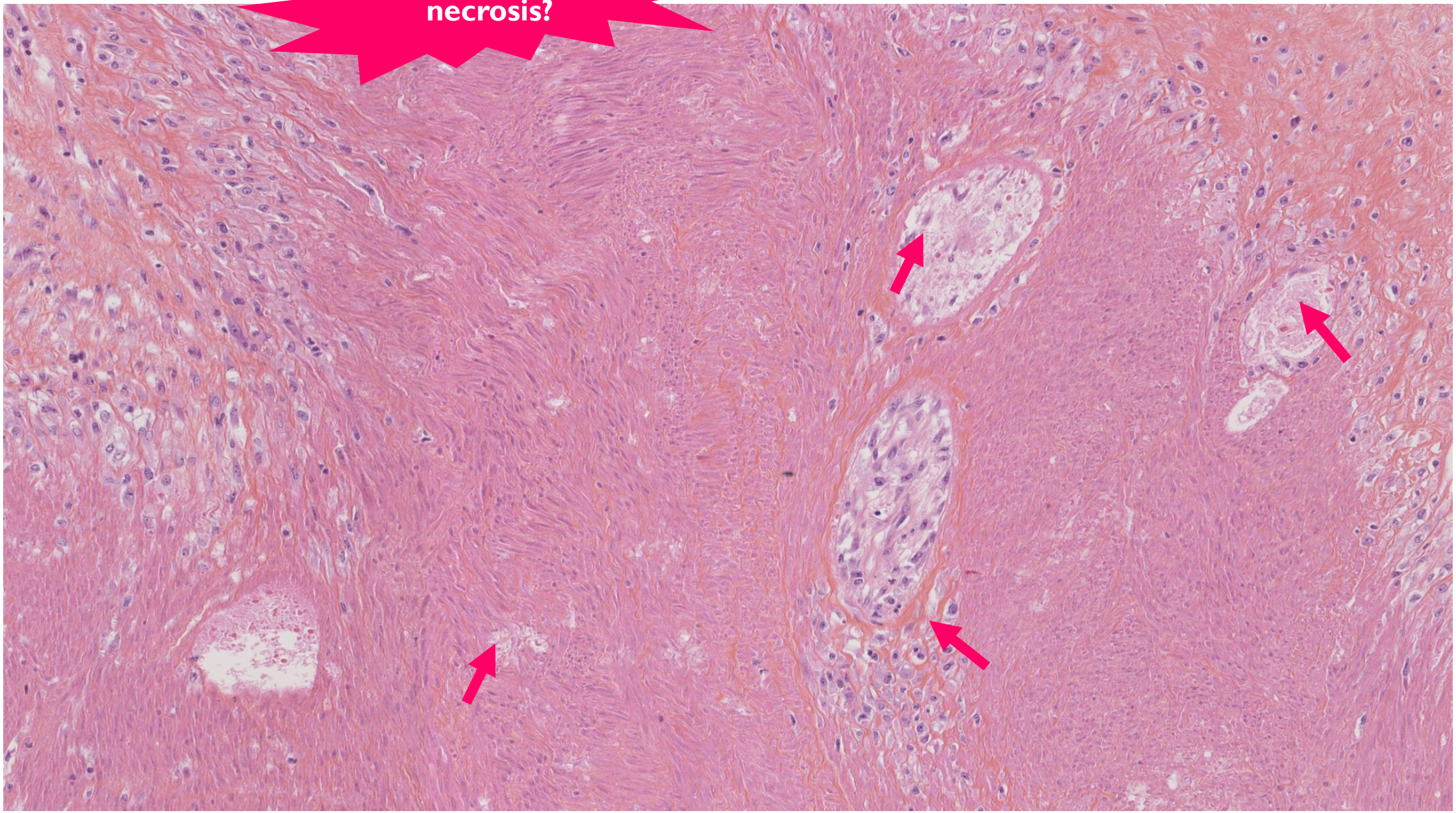

Case 1

- **Morphology:**
  No diffuse atypia
  'Reactive' changes around the necrosis
  KI-67: 20%

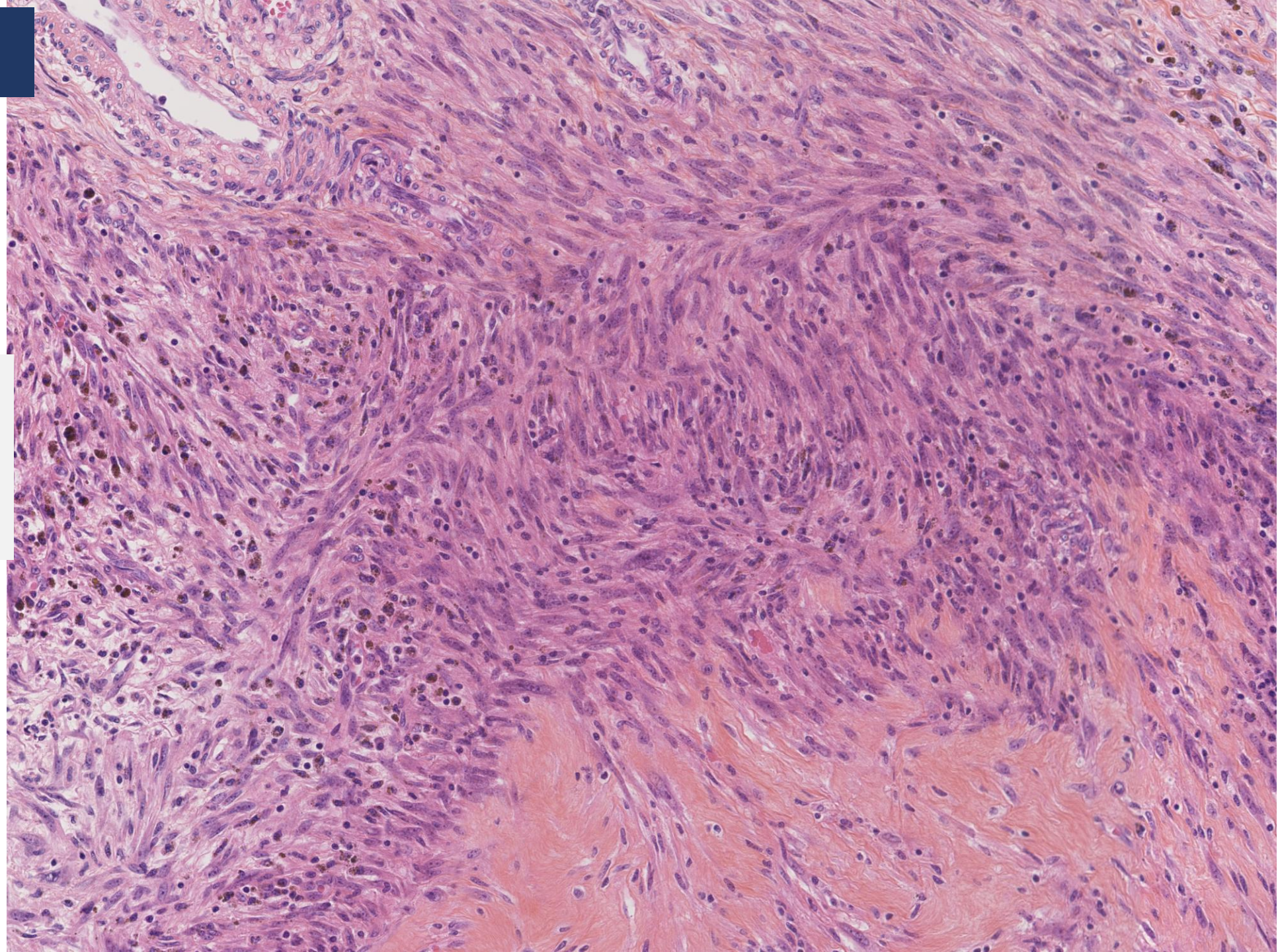

Case 1. Genomic Profile

: GI= $4^2/4=4$

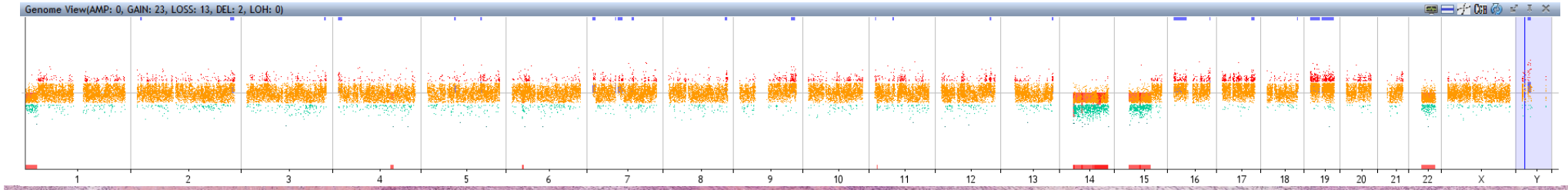

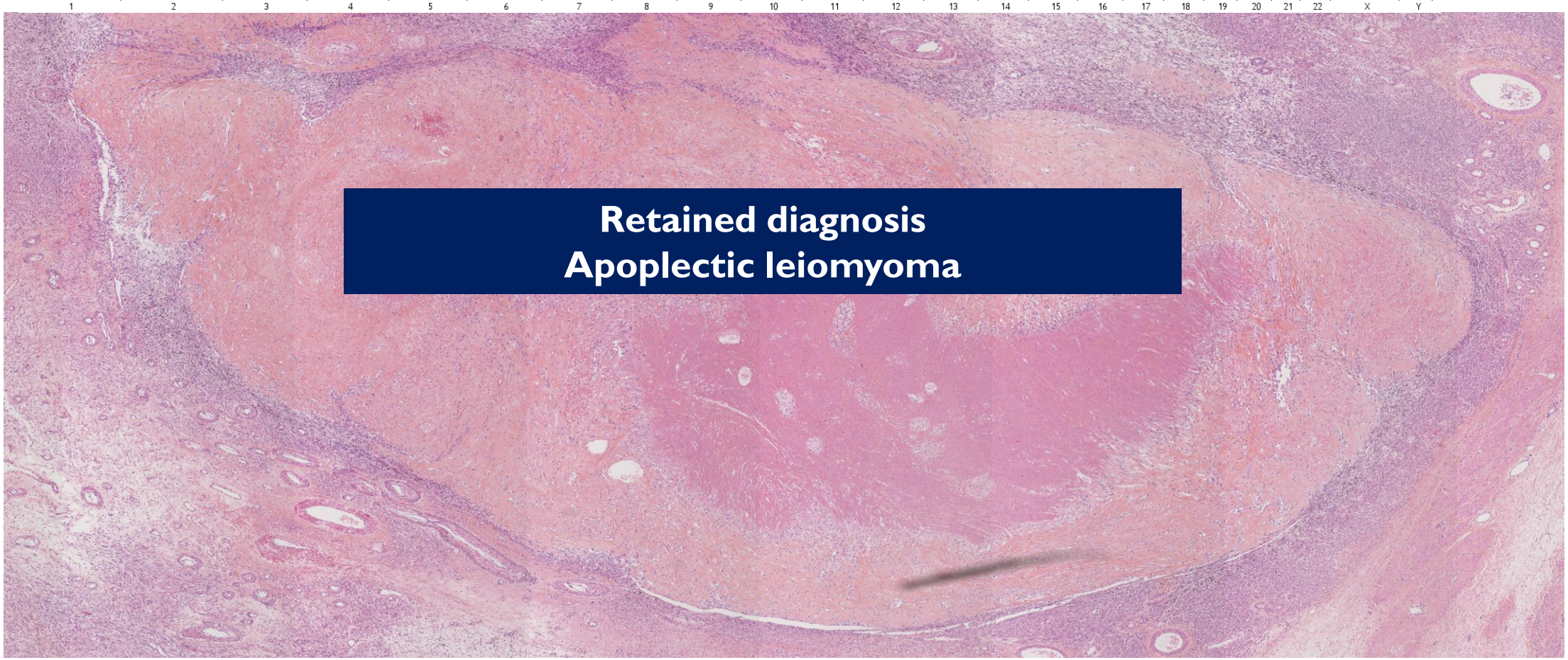

Retained diagnosis
Apoplectic leiomyoma

Case 2: IM537

Clinical History

- 2011: 43 years
- Large symptomatic uterine mass “fibroid”

Macroscopy

- Uterine mass 20 cm

Case 2: im537

Highly cellular smooth muscle tumour

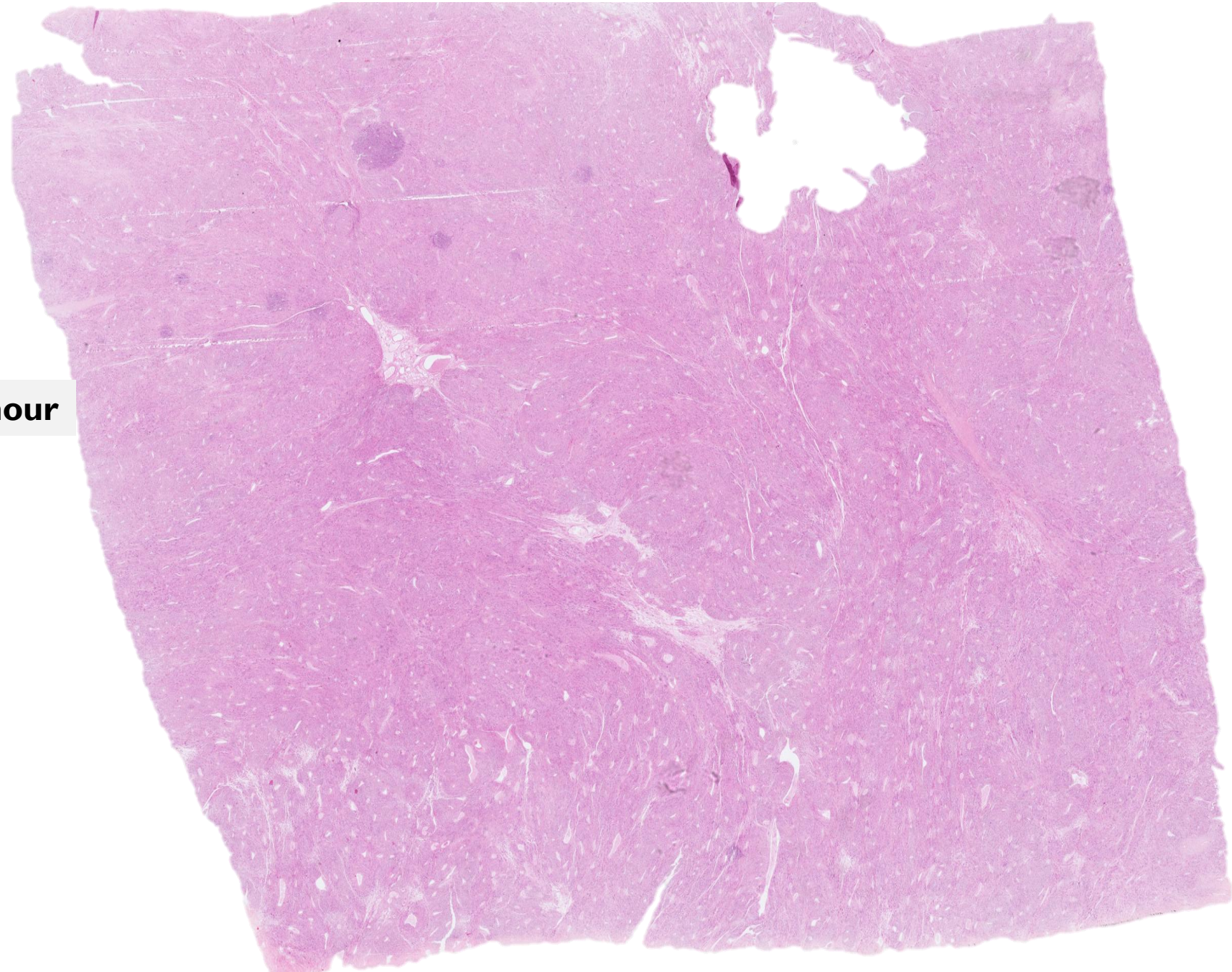

Case 2: IM537

- Highly cellular smooth muscle tumour
- Diffuse atypia
- 7 mitoses/10 HPF (2,9 mitoses/mm²)

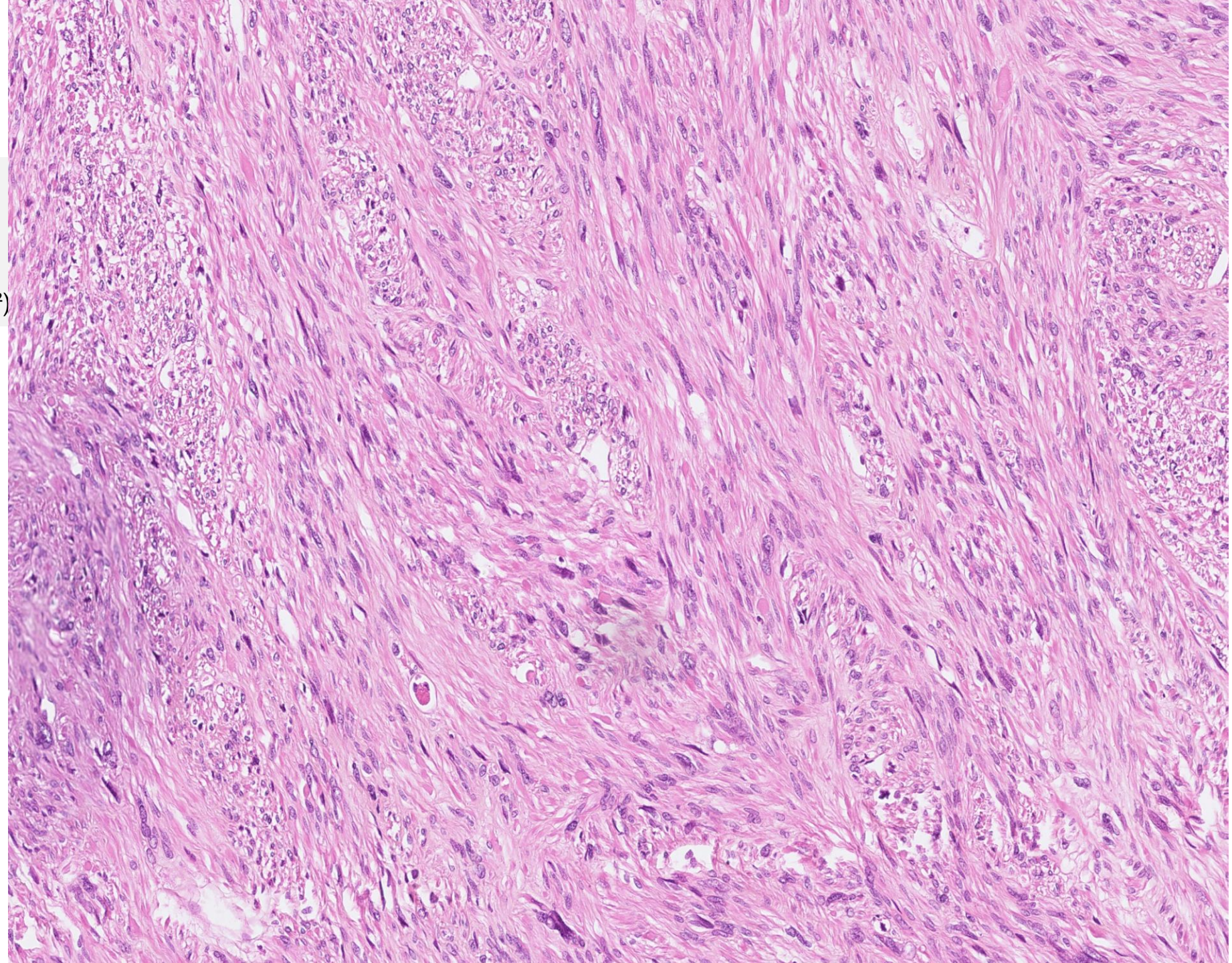

Case 2: IM537

What type of necrosis?

indeterminate

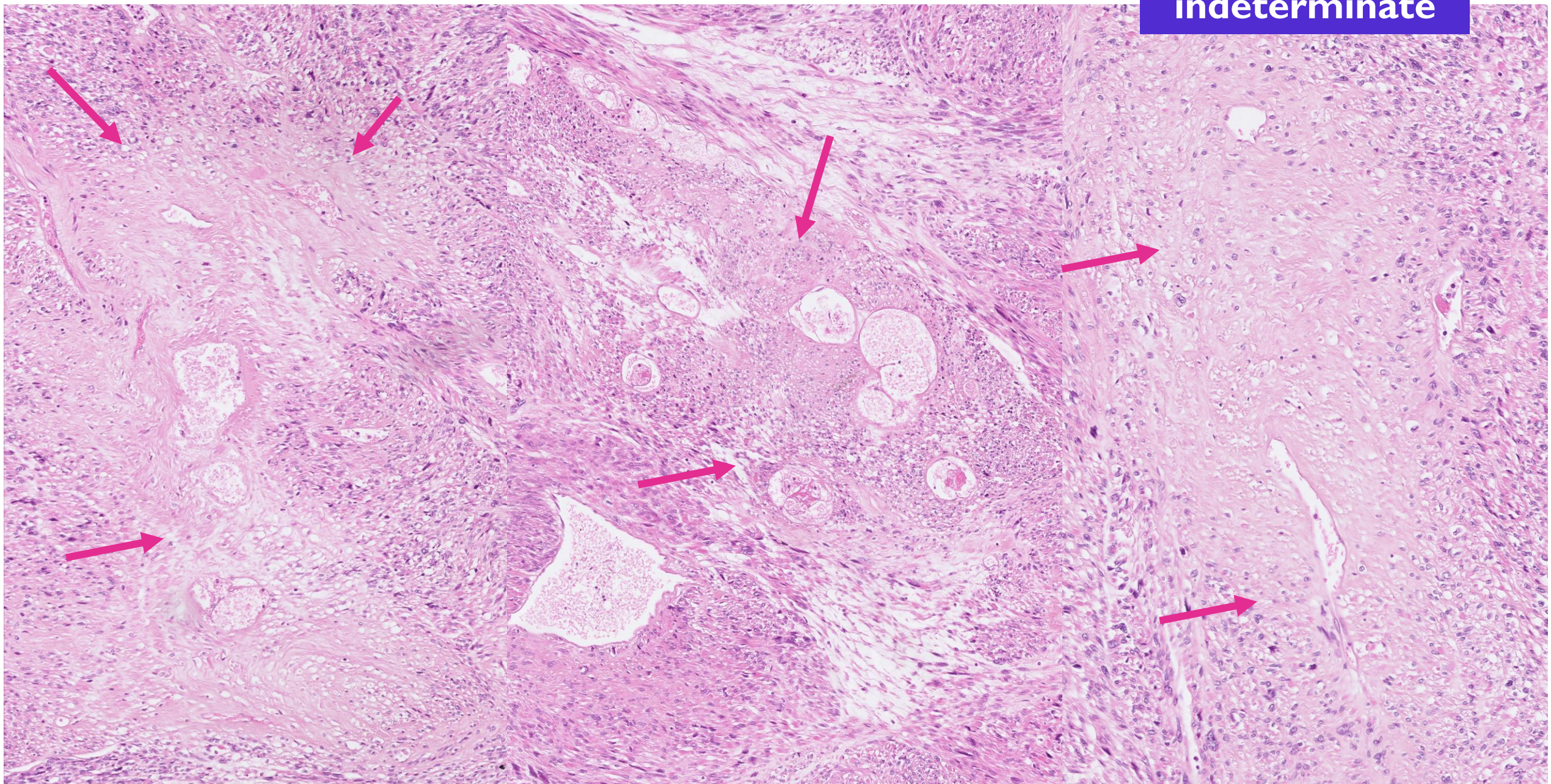

Case 2: IM537

Proposed diagnosis : STUMP
(diffuse moderate to marked atypia, <10 mitoses, indeterminate necrosis)

Array-CGH-Agilent 8x60k)

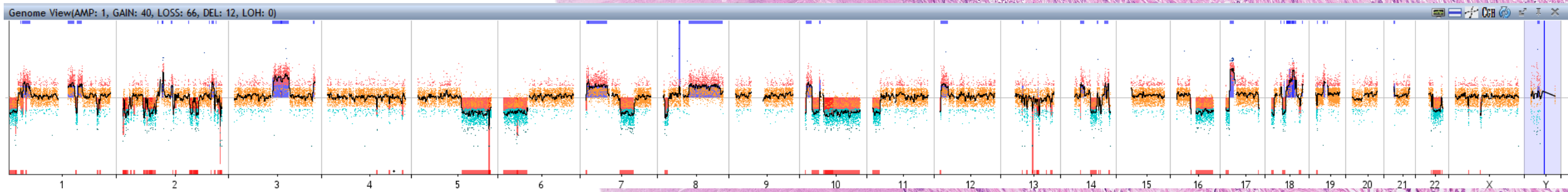

GI>100

Retained diagnosis : leiomyosarcoma

Follow up

- Local recurrence and bone metastasis 6 months later
- DOD 1 year later

Conclusions

Necrosis Assessment presents a significant challenge in diagnosing uterine smooth muscle tumors

Endometrial Stromal Sarcoma: The presence of necrosis is a red flag, raising suspicion of high-grade endometrial stromal sarcoma or high-grade transformation

Mitotic Count: Mitotic counting can be particularly challenging and requires standardization. Could digital pathology provide a solution?

Diagnostic Process of Smooth Muscle Tumors: It's crucial to consider

- clinical data (age, hormonal status)
- Macroscopy
- perform extensive sampling in the diagnostic algorithm
- Molecular tools can assist in challenging cases
- AI

Thanks for your attention

s.croce@bordeaux.unicancer.fr

