The British Association of Gynaecological Pathologists

21st Annual Meeting in Collaboration with ISGyP

5th and 6th June 2025

- A practical approach to mucin rich endometrial pathology
- Dr Richard Wong
- Department of Pathology, United Christian Hospital, Hong Kong
- 5th June 2025

The British Association of Gynaecological Pathologists

Speaker disclosures

- ❑ I have no financial conflicts of interest to disclose

Spectrum of mucin rich endometrial pathology

Source of diagnostic dilemma

Variety of pathological entities with overlapping features

Evolving concepts and criteria for emerging entities

Cervical pathology mimicking endometrial lesions

Pitfalls in IHC interpretation

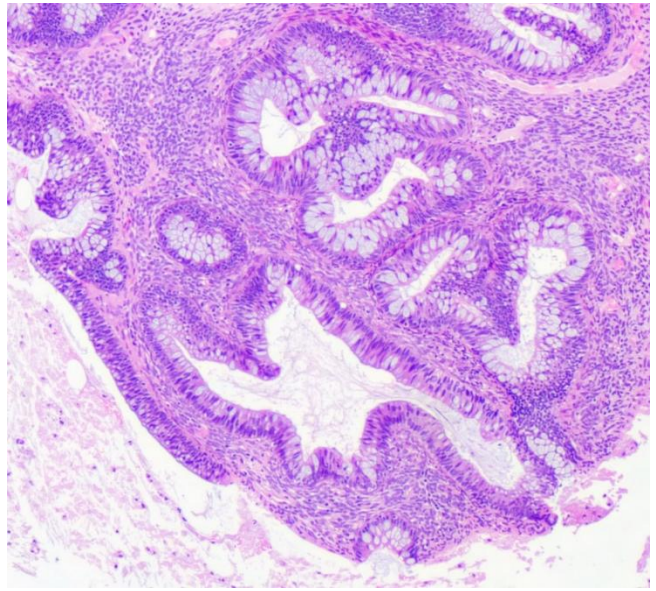

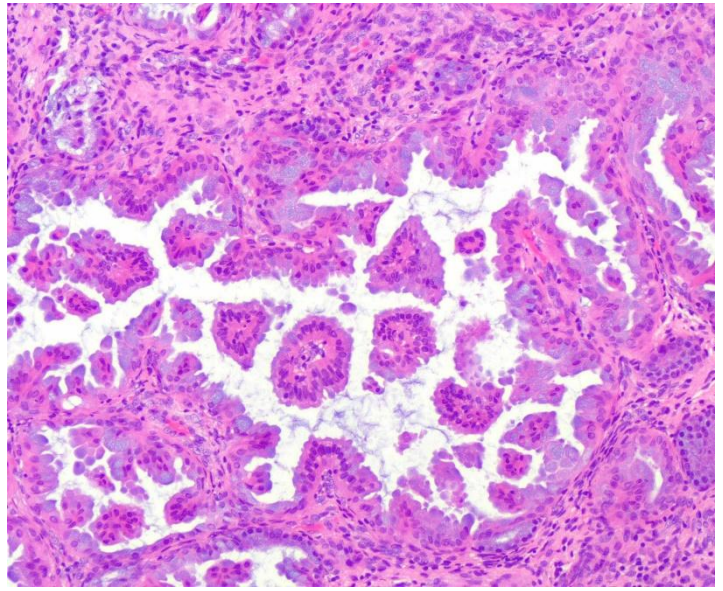

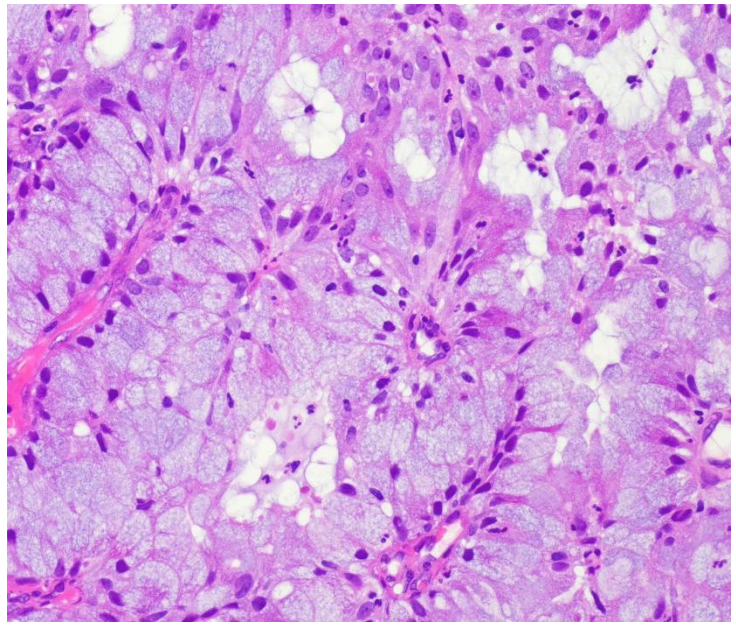

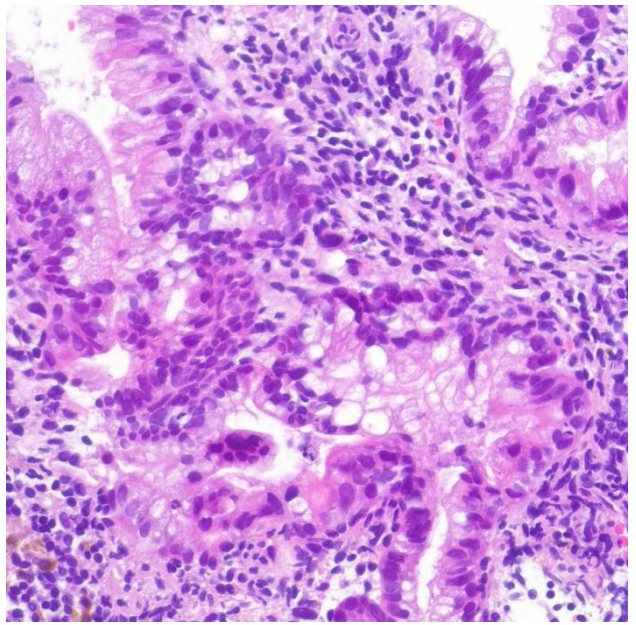

Mucinous lesions in endometrial specimens mostly fall within these three categories

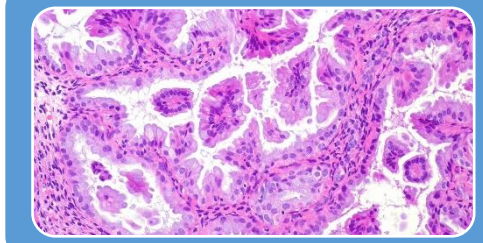

Müllerian-type mucinous lesions

- Mucinous metaplasia; papillary proliferation of endometrium with mucinous metaplasia
- Atypical mucinous glandular proliferation; endometrial hyperplasia with mucinous features
- Endometrioid carcinoma with mucinous differentiation

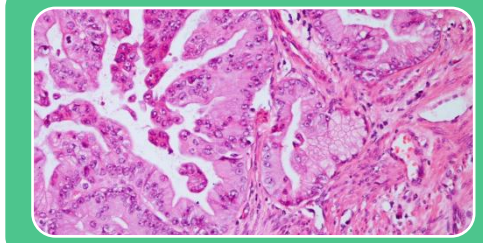

Gastric/gastrointestinal-type mucinous lesions (of the endometrium)

- Gastric-type mucinous metaplasia
- Atypical mucinous proliferation of gastric type
- Endometrial gastric (gastrointestinal)-type adenocarcinoma (EmGA)

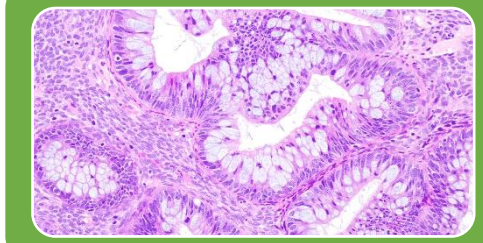

Cervical glandular lesions with mucinous features (involving the endometrium or inadvertently sampled in biopsies)

- HPV-associated adenocarcinoma and adenocarcinoma in situ (AIS or CGIN)
- Cervical gastric-type adenocarcinoma; gastric-type AIS; LEGH

Note: Metastasis from extrauterine sites may rarely present as mucinous lesions in the endometrium.

Evaluating lesions with mucinous features in endometrial specimens

- **Architecture:**
  - Glandular crowding/confluence
  - Papillary component (and its degree of complexity)
  - Infiltrative growth
- **Cytology:**
  - Cytoplasmic features (basophilic/eosinophilic/clear)
  - Nuclear atypia (and chromatin pattern)
  - Mitosis/apoptosis
  - Specific cell types (e.g. ciliated cells, goblet cells, Paneth-like neuroendocrine cells)

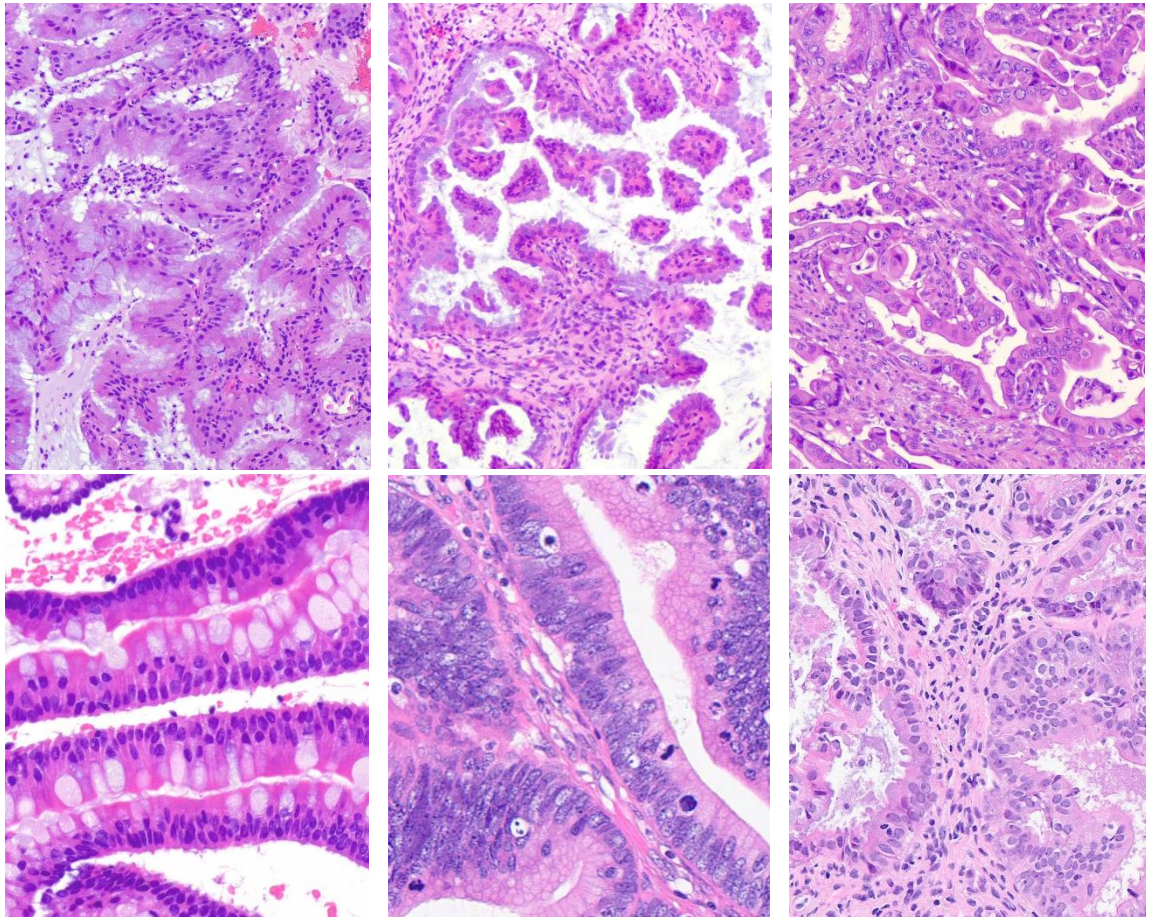

General considerations for lesions with mucinous features in endometrial specimens

- Variable extent of mucin-containing cells (may contain mucin poor areas)
- May have several acceptable alternative diagnoses (especially for Müllerian-type mucinous lesions)
  - e.g. PPE vs AMGP
- Not always possible to determine the exact location of the mucinous lesions in endometrial biopsies, e.g.
  - Detached strips without surrounding stroma
  - Difficulty distinguishing cervical stroma from the fibrous stroma of endometrial polyps

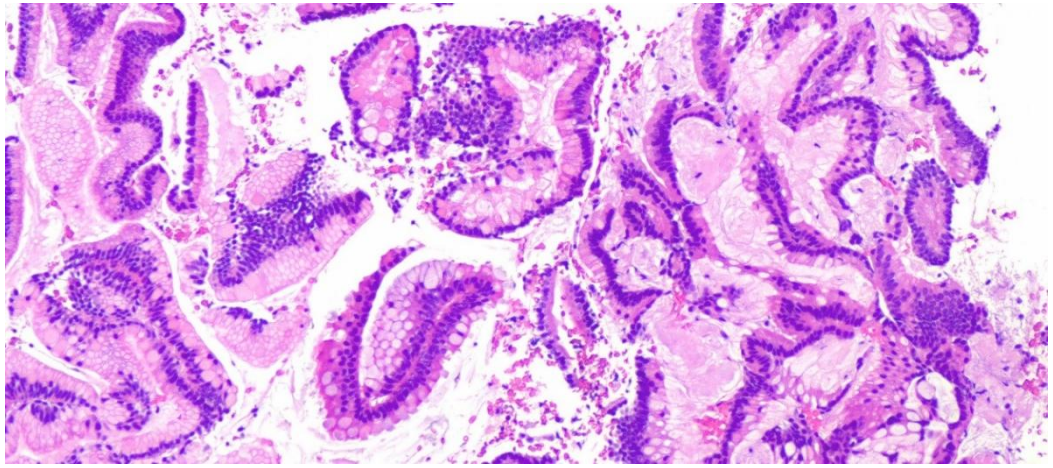

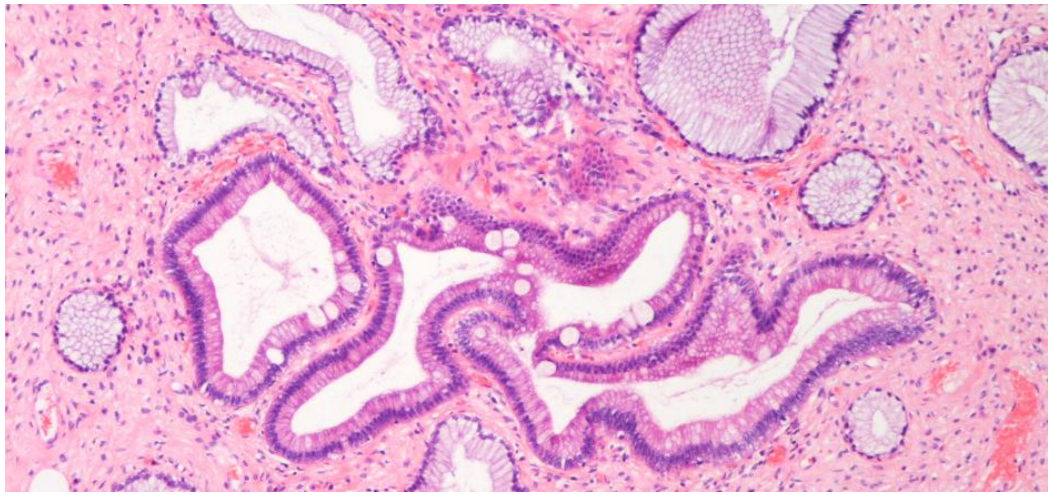

Müllerian-type mucinous lesions – Morphology

- Usually predominantly **pale basophilic** mucin
  - eosinophilic mucin possible
- Commonly admixed with various types of **metaplasia** and areas of **conventional endometrioid** features
  - e.g. tubal metaplasia, eosinophilic metaplasia, squamous metaplasia
- **Architecture** more important than cytology for distinction of benign, atypical and malignant lesions
  - often with subtle nuclear atypia even in malignancy

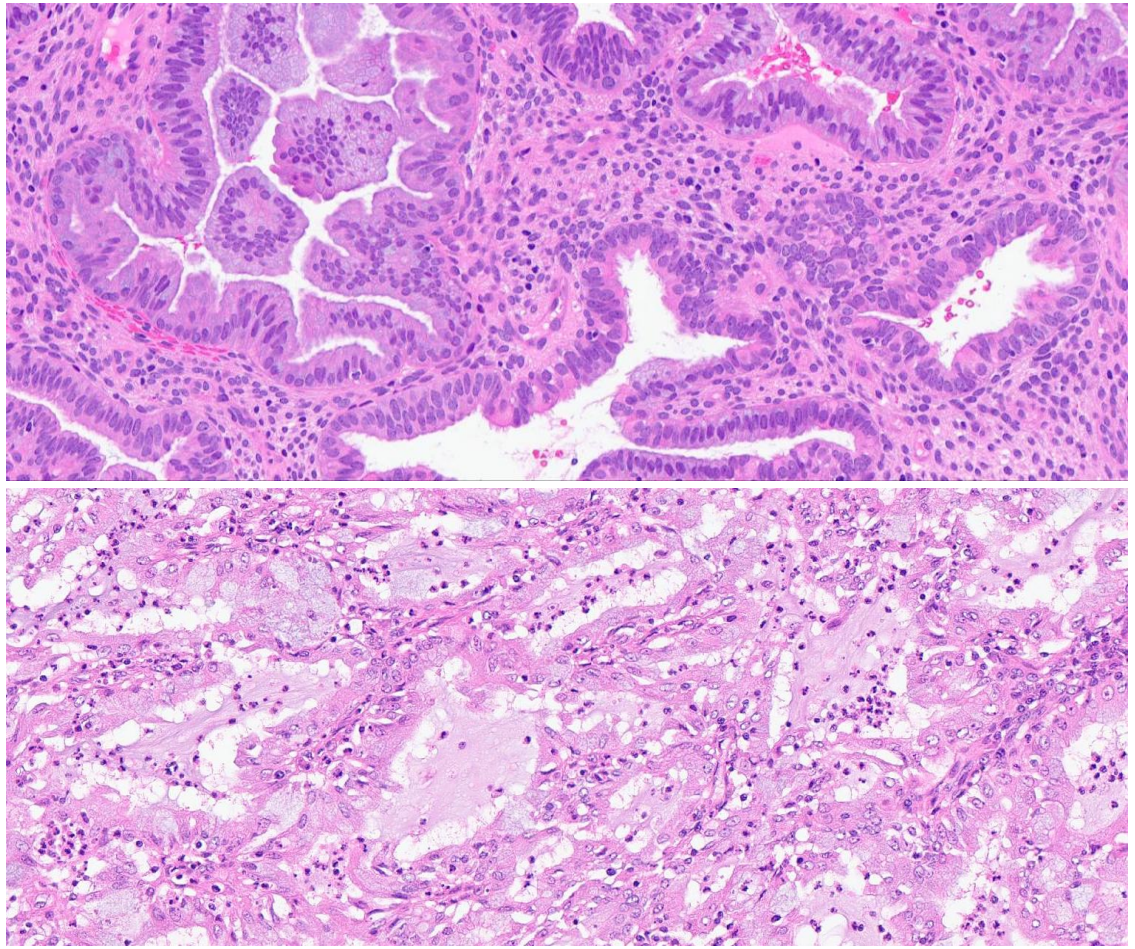

Müllerian-type mucinous lesions – Immunohistochemistry

- Typical IHC profile of mucinous areas in Müllerian-type lesions:
  - ER positive
  - **PR negative or focal weak**
  - **p16 diffusely positive**
  - p53 wild-type
  - CK7 diffusely positive
  - CK20 may be focally positive
- Loss of PR and increased p16 expression often delineate mucinous foci from non-mucinous areas of the same lesion

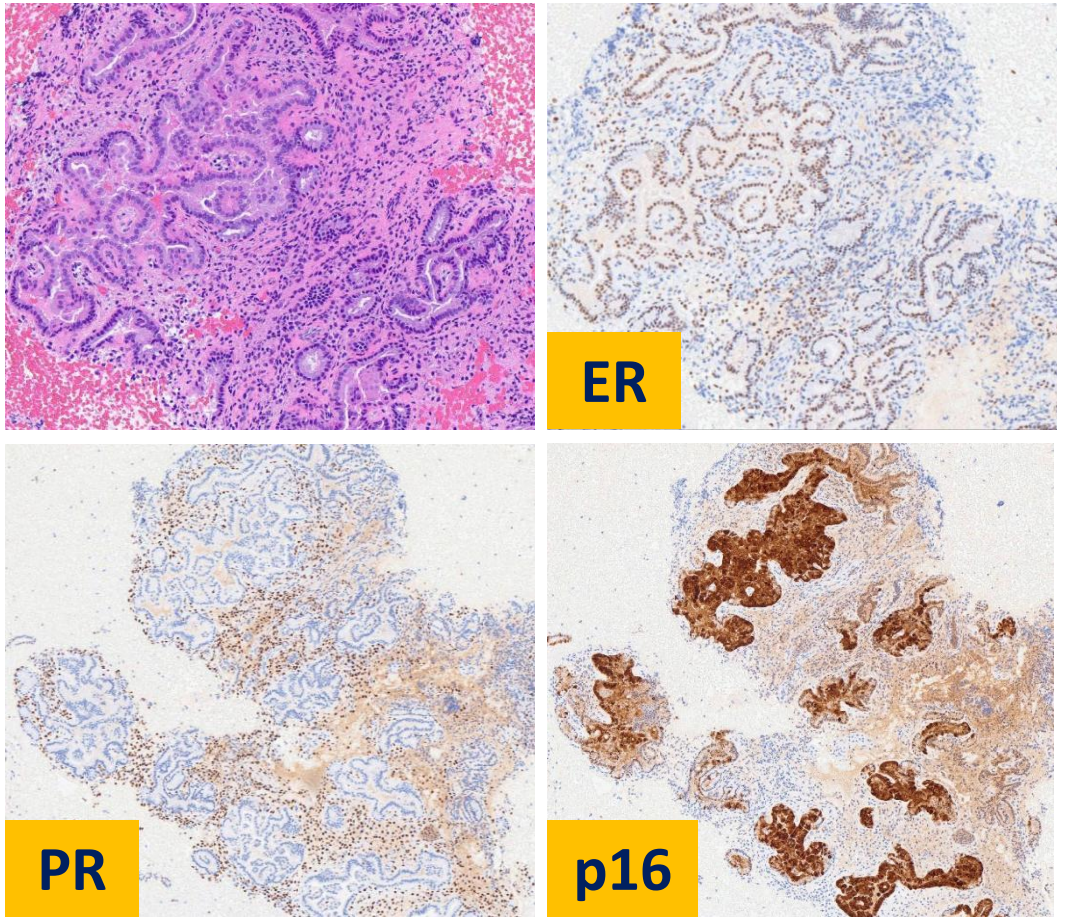

Müllerian-type mucinous lesions – Pathological entities

Mucinous metaplasia	• No architectural or cytological atypia
Papillary proliferation of endometrium (PPE) with mucinous metaplasia / Papillary mucinous metaplasia	• Papillary tufting with fibrovascular cores, intracytoplasmic mucin and no cytologic atypia • Typical IHC – loss of PR and PAX2, diffuse p16
Atypical mucinous glandular proliferation	• Mucinous proliferations with architectural complexity exceeding that of benign mucinous metaplasia but insufficient for a definitive diagnosis of carcinoma • Atypical features may include papillary architecture, microglandular pattern, extensive branching and budding, or cytologic atypia
Endometrioid carcinoma with mucinous differentiation	• Confluent glandular proliferation with focal or diffuse intracytoplasmic mucin, and variable cytologic atypia (usually minimal to mild)

Ip PP, Irving JA, McCluggage WG, et al. Am J Surg Pathol. 2013;37:167-77.
Rawish KR, Desouki MM, Fadare O. Hum Pathol. 2017;63:53-62.
Stewart CJR, Bigby S, Giardina T, et al. Pathology. 2018;50:286-292.
Fadare O. Adv Anat Pathol. 2022;29:275-296.

Gastric/gastrointestinal-type mucinous lesions of the endometrium

- Typically (at least focally) show **pale eosinophilic foamy cytoplasm** with distinct cell borders
  - Areas with basophilic mucin may be present
- Presence of **goblet cells** or **Paneth-like cells** in cases with intestinal differentiation
- Architecture resembling that of lobular endocervical glandular hyperplasia (LEGH) may be seen in gastric-type mucinous metaplasia
- Commonly associated with endometrial polyps

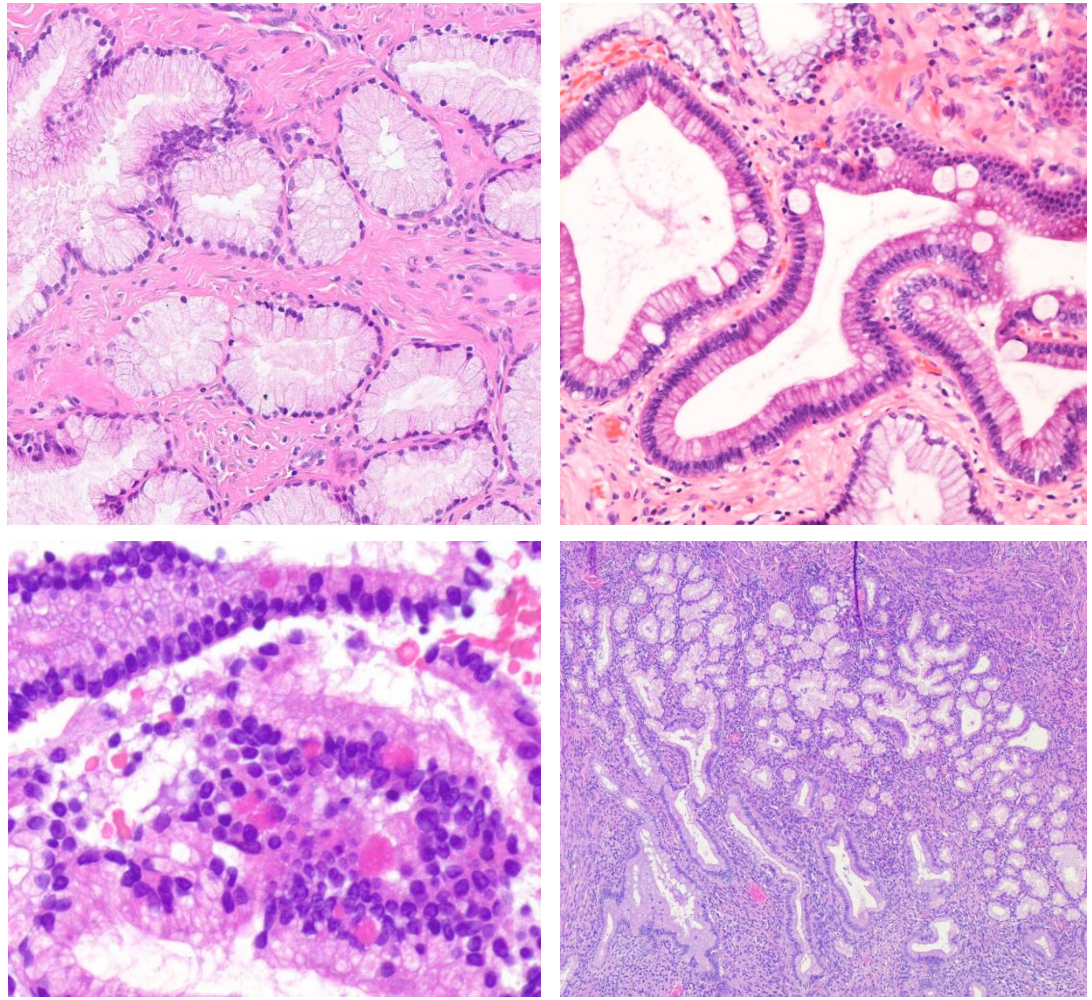

Gastric/gastrointestinal-type mucinous lesions of the endometrium

- Wide range of nuclear atypia in gastric-type lesions
  - Usually lacking the hyperchromatic nuclei, coarse chromatin and frequent mitosis/apoptosis that are typical of HPV-associated lesions
- Endometrial gastric-type carcinoma may have a variety of morphological patterns, some with mucin poor features

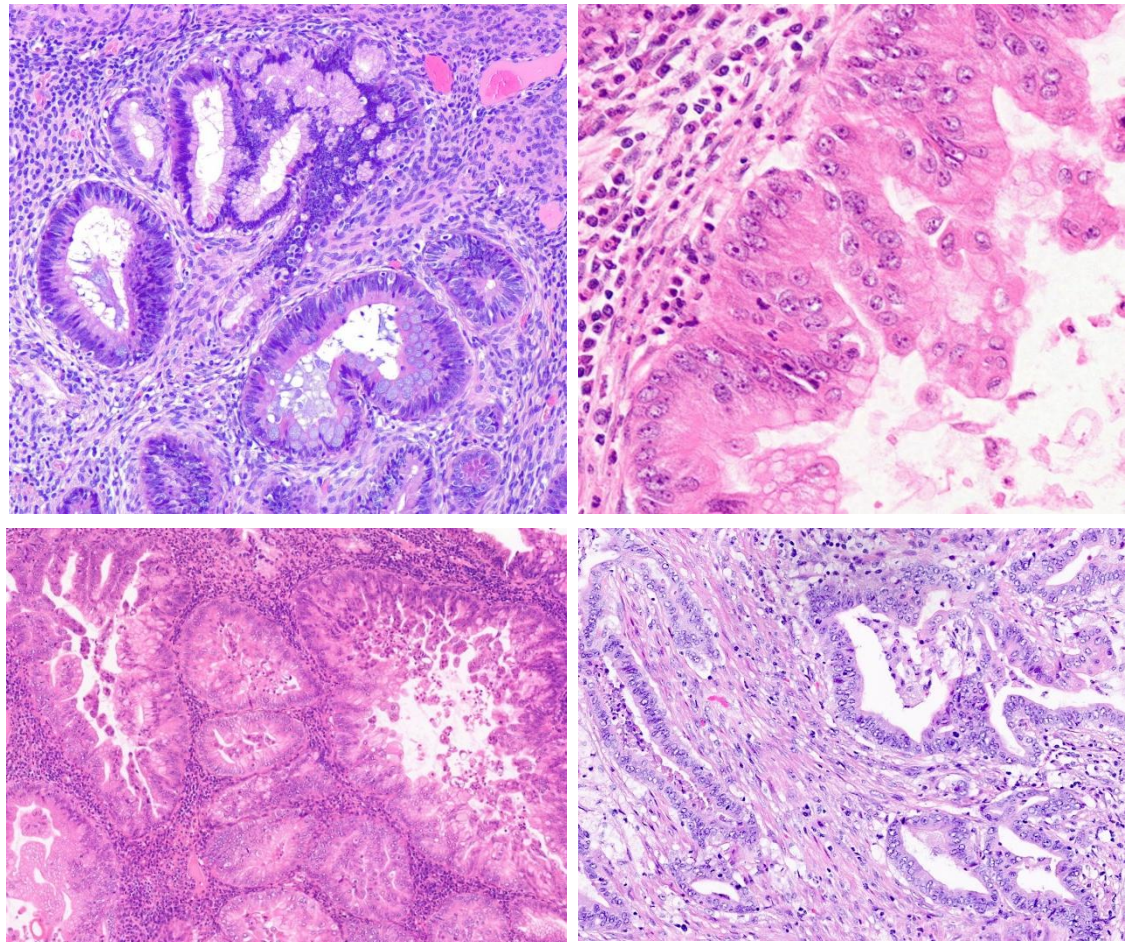

Courtesy of Dr Karen Talia

Gastric/gastrointestinal-type mucinous lesions of the endometrium

Gastric-type mucinous metaplasia	• Mucinous glands with gastric-type and/or intestinal-type features (+/- LEGH-like architecture), and with no cytological atypia or architectural complexity • IHC: at least focal expression of gastrointestinal markers (e.g. CDX2, CK20), +/- chromogranin-positive neuroendocrine cells
Atypical mucinous proliferation of gastric-type	• Gastric-type mucinous lesion with cytological atypia or significant architectural complexity falling short of adenocarcinoma
Endometrial gastric (gastrointestinal)-type carcinoma (EmGA)	• Endometrial glandular proliferation with gastric-type and/or intestinal-type features, together with significant cytological and/or architectural atypia, and the absence of typical endometrioid glandular elements • IHC: at least focal expression of GI markers (e.g. CDX2, CK20); absent or minimal (<5%) expression of ER

Note: Gastric-type features refer to voluminous, pale eosinophilic or clear cytoplasm with distinct cell borders. Intestinal-type features refer to goblet cells or Paneth-like cells.

Gastric-type mucinous metaplasia of the endometrium – typical IHC findings

- CK7 positive (usually diffuse)
- Gastrointestinal markers (e.g. CDX2, CK20) may be focal or diffuse
  - At least 1 marker should be focally positive
- Scattered chromogranin-positive neuroendocrine cells
- ER and PAX8 may be positive or negative
  - In positive cases, expression is often patchy and weaker than the surrounding normal endometrial glands
- p53 wild-type
- p16 negative (or non-block)

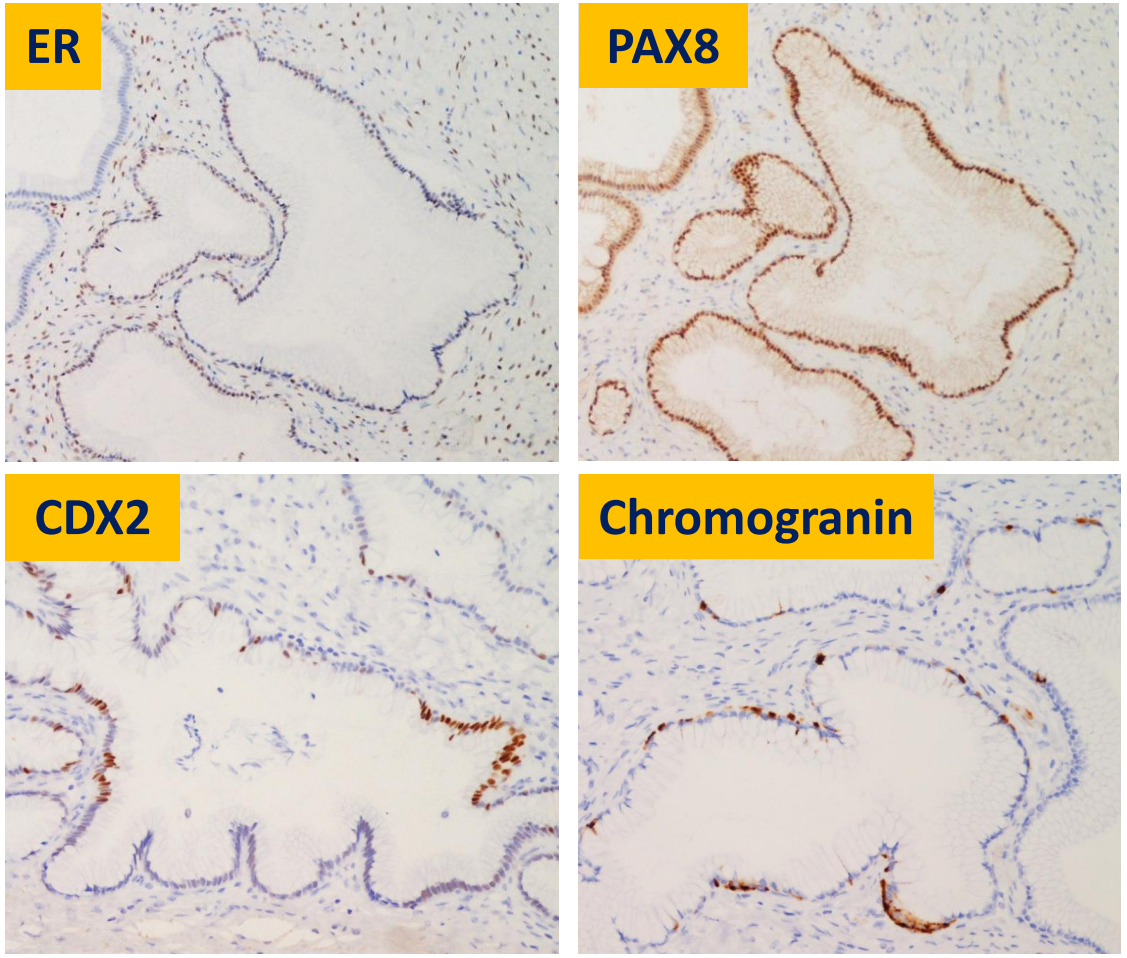

Wong RW, Ralte A, Grondin K, et al. Am J Surg Pathol. 2020;44:406-419.
Wong RW, Talia KL, McCluggage WG. Histopathology. 2024;85:20-39.

Endometrial gastric (gastrointestinal)-type adenocarcinoma – typical IHC findings

- CK7 usually positive
- Gastrointestinal markers (e.g. CDX2, CK20, HIK1083) may be positive or negative
  - At least 1 marker should be focally positive
  - CDX2 positive in 24/26 cases by Kaur et al. (largest series to date)
- By definition, ER negative or minimal (<5%)
- PAX8 may be positive or negative
  - 14/25 were PAX8 positive (Kaur et al.)
- p53 mutation-type or wild-type
  - 12/27 exhibited aberrant p53 (Kaur et al.)
- p16 usually negative or non-block, but occasionally diffuse

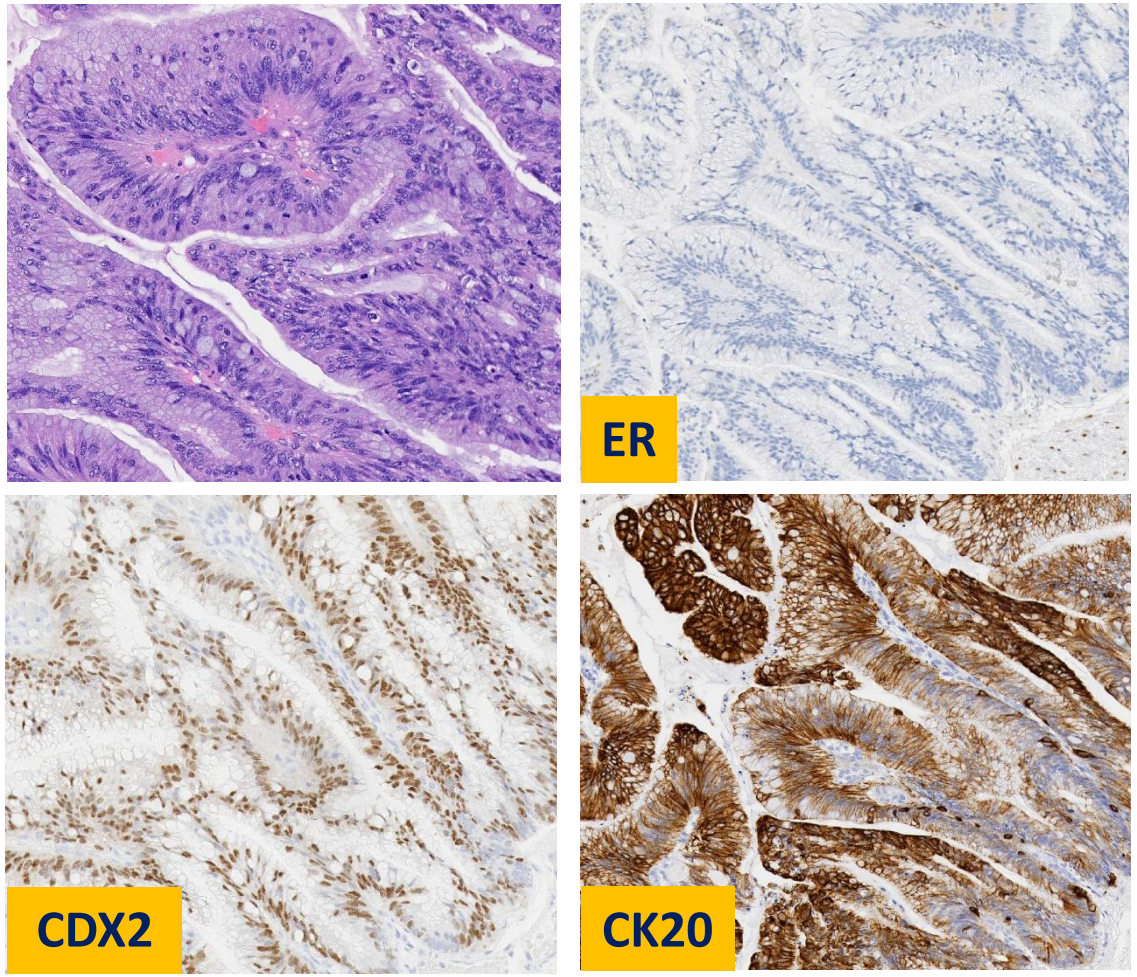

Wong RW, Ralte A, Grondin K, et al. Am J Surg Pathol. 2020;44:406-419.
Wong RW, Talia KL, McCluggage WG. Histopathology. 2024;85:20-39.
Kaur H, Lin LH, Kolin DL, et al. Am J Surg Pathol. 2025;49:564-577.

Cervical mucinous lesions in endometrial specimens – HPV-associated glandular lesions

- HPV-associated adenocarcinoma or AIS may have mucinous/intestinal features and involve the endometrium
  - May also be inadvertently sampled in an endometrial biopsy but not directly involving the endometrium
- May resemble endometrioid carcinoma when involving endometrial glands
  - Distinguished by morphology (nuclear hyperchromasia and apoptotic bodies) and IHC (p16 diffuse, p53 wild-type and ER negative)

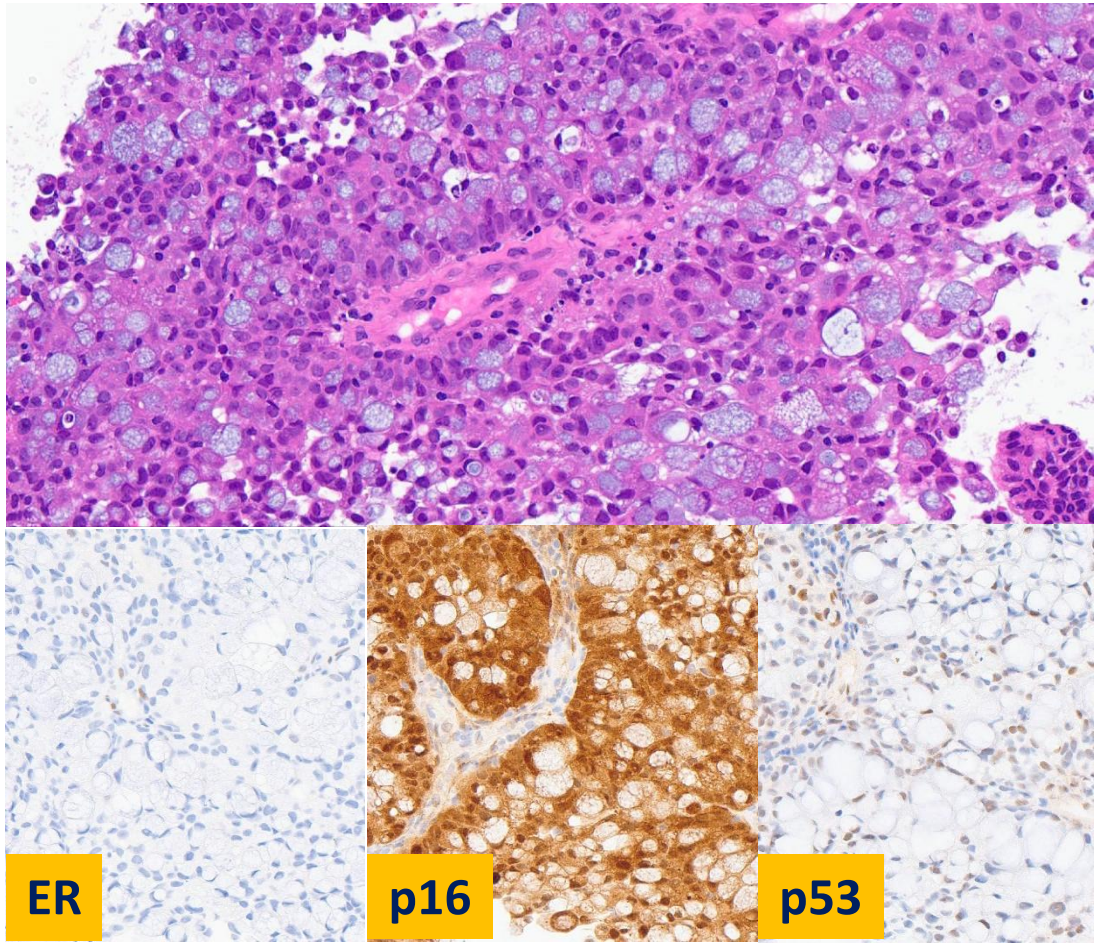

Yemelyanova A, Vang R, Seidman JD, et al. Am J Surg Pathol. 2009;33:914-24.
Reyes C, Murali R, Park KJ. Int J Gynecol Pathol. 2015;34:551-63.

Cervical mucinous lesions in endometrial specimens – Cervical gastric-type carcinoma

- Gastric-type adenocarcinomas of the cervix share similar morphological features and IHC profile with endometrial gastric-type adenocarcinomas
- If a gastric-type carcinoma involves both the endometrium and cervix, designation of the primary site should be based on evaluation of
  - Any (putative) precursor lesions?
  - Clinical and imaging?
  - Predominant site of involvement?

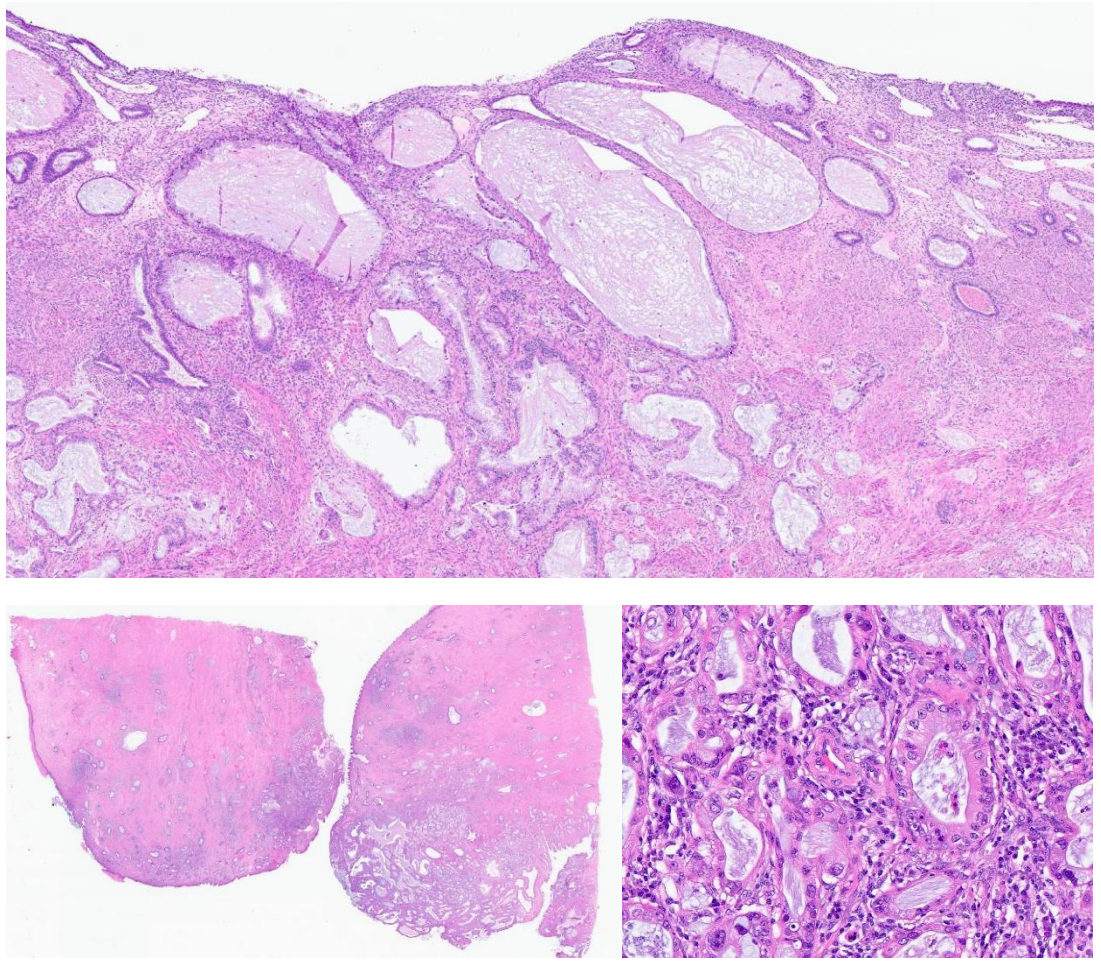

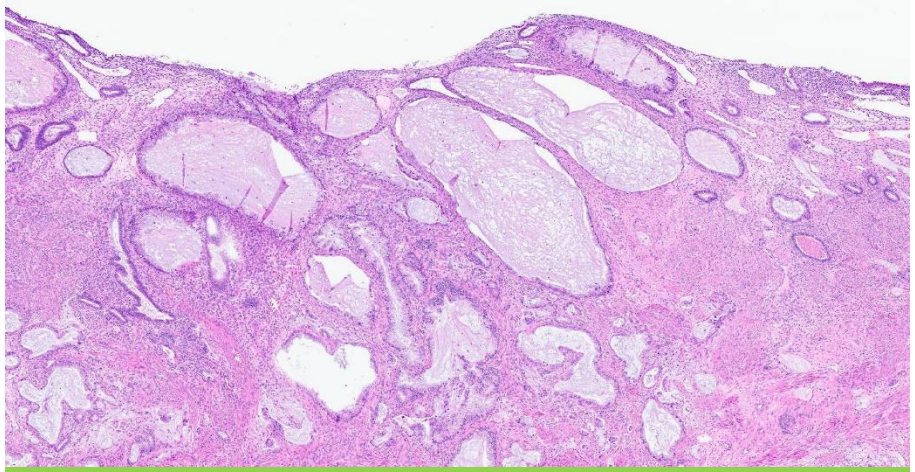

Endometrium

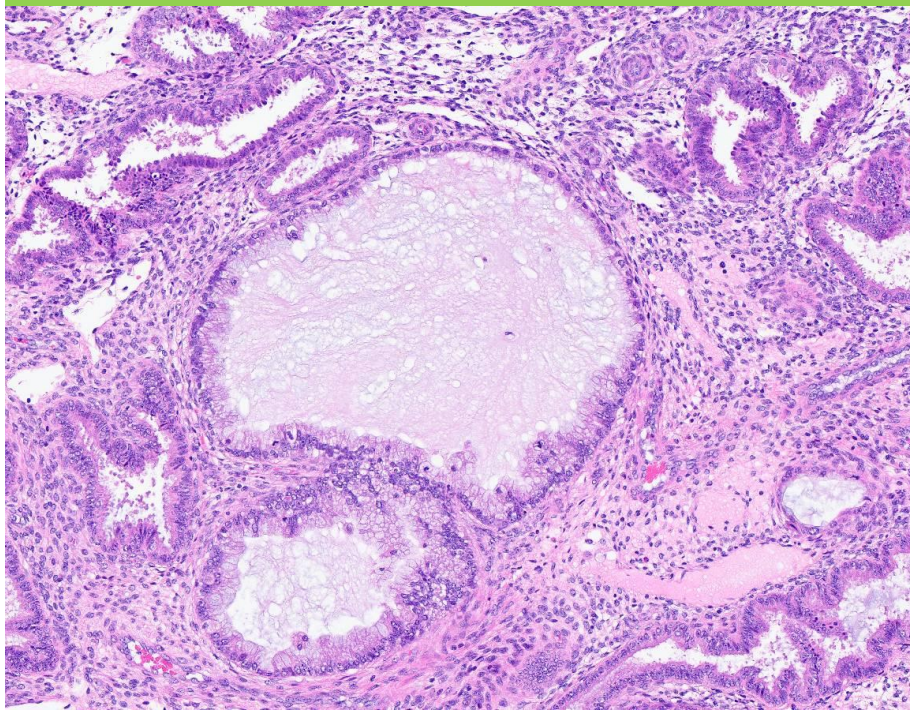

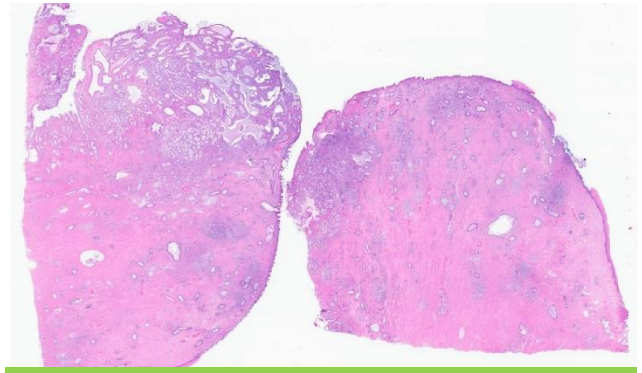

Cervix

The presence of LEGH (with gastric-type AIS) in the cervix supports a cervical origin

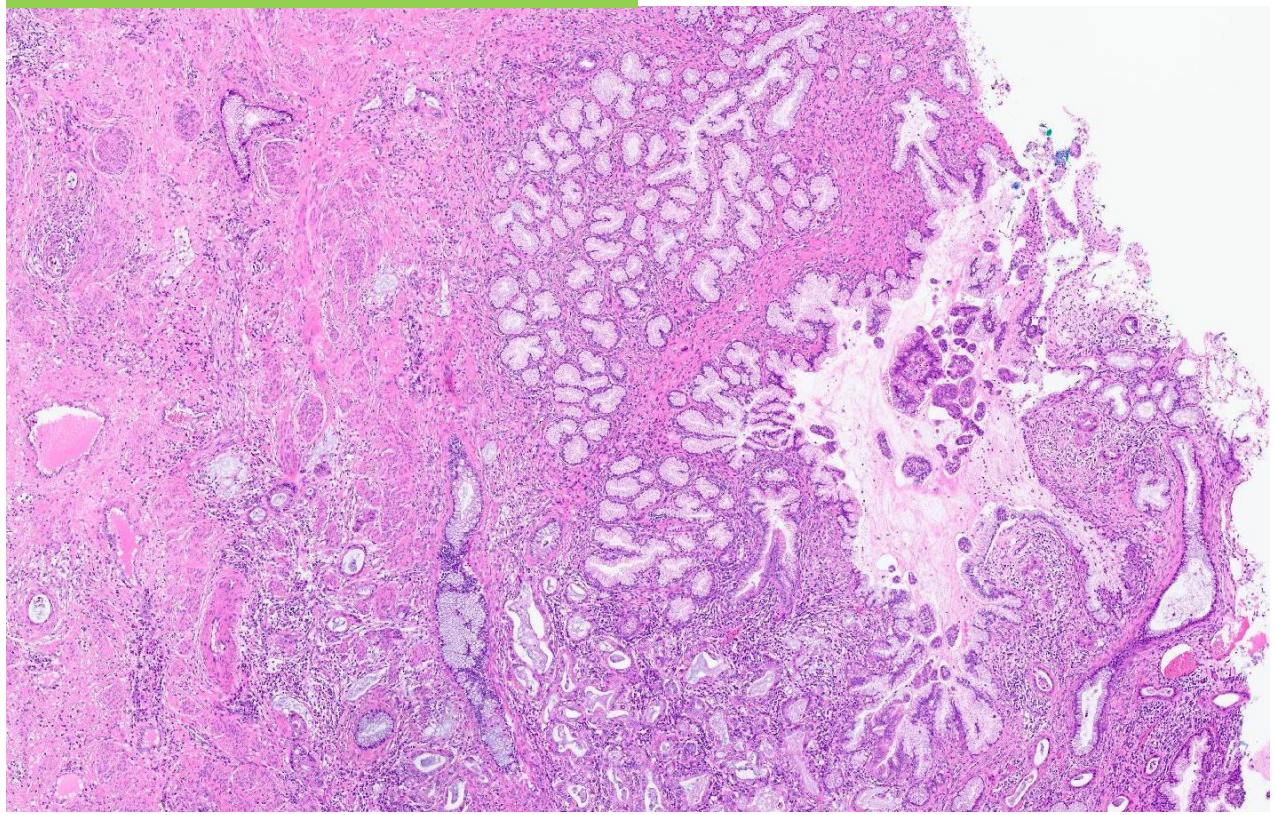

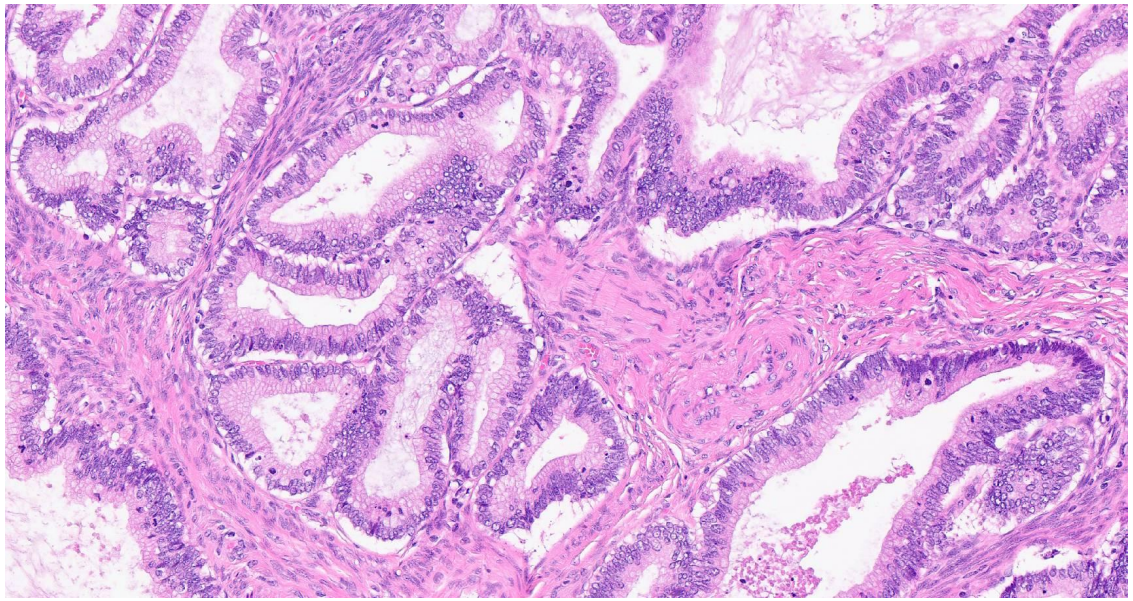

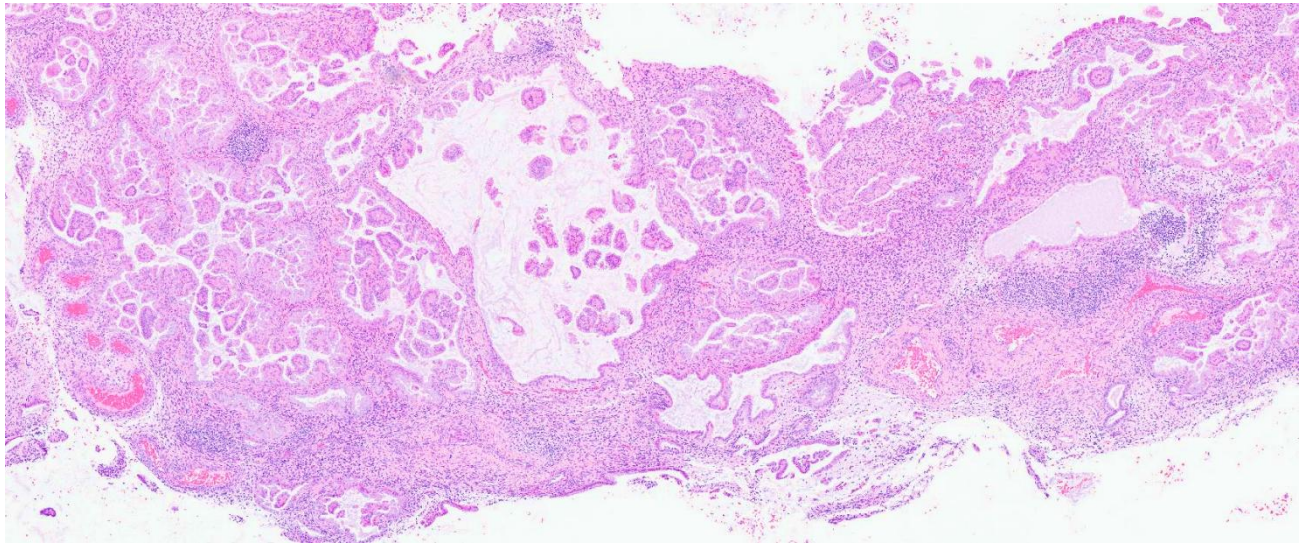

Let’s take a look at three mucin rich lesions …

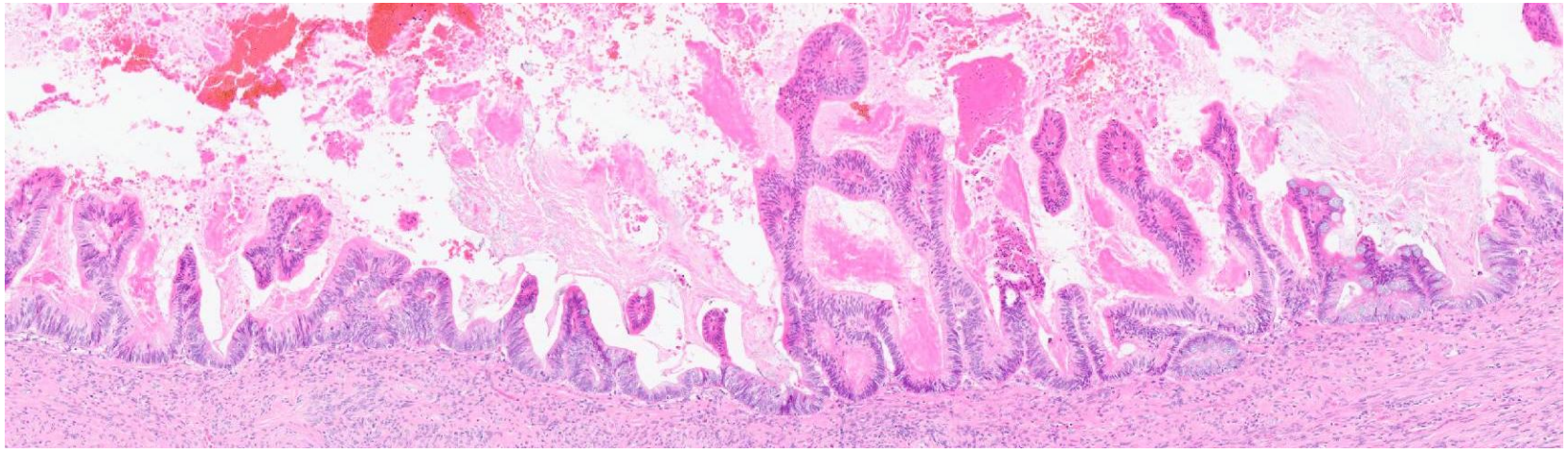

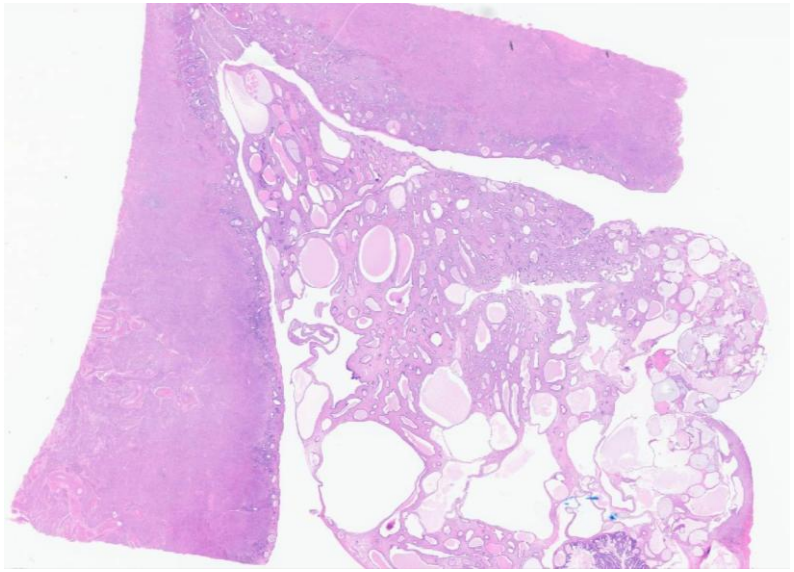

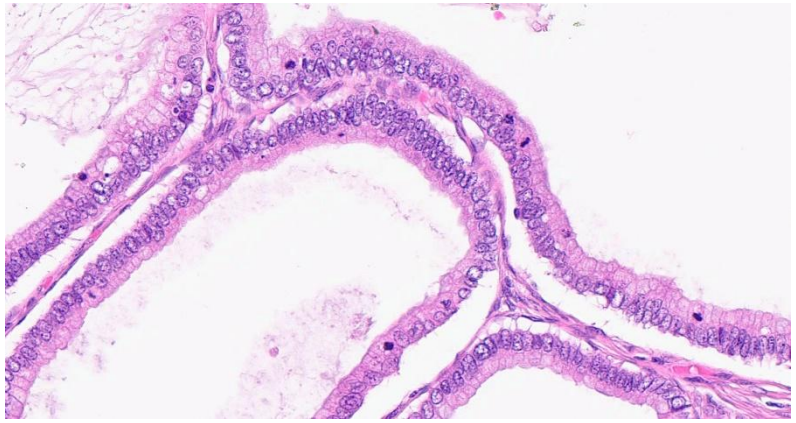

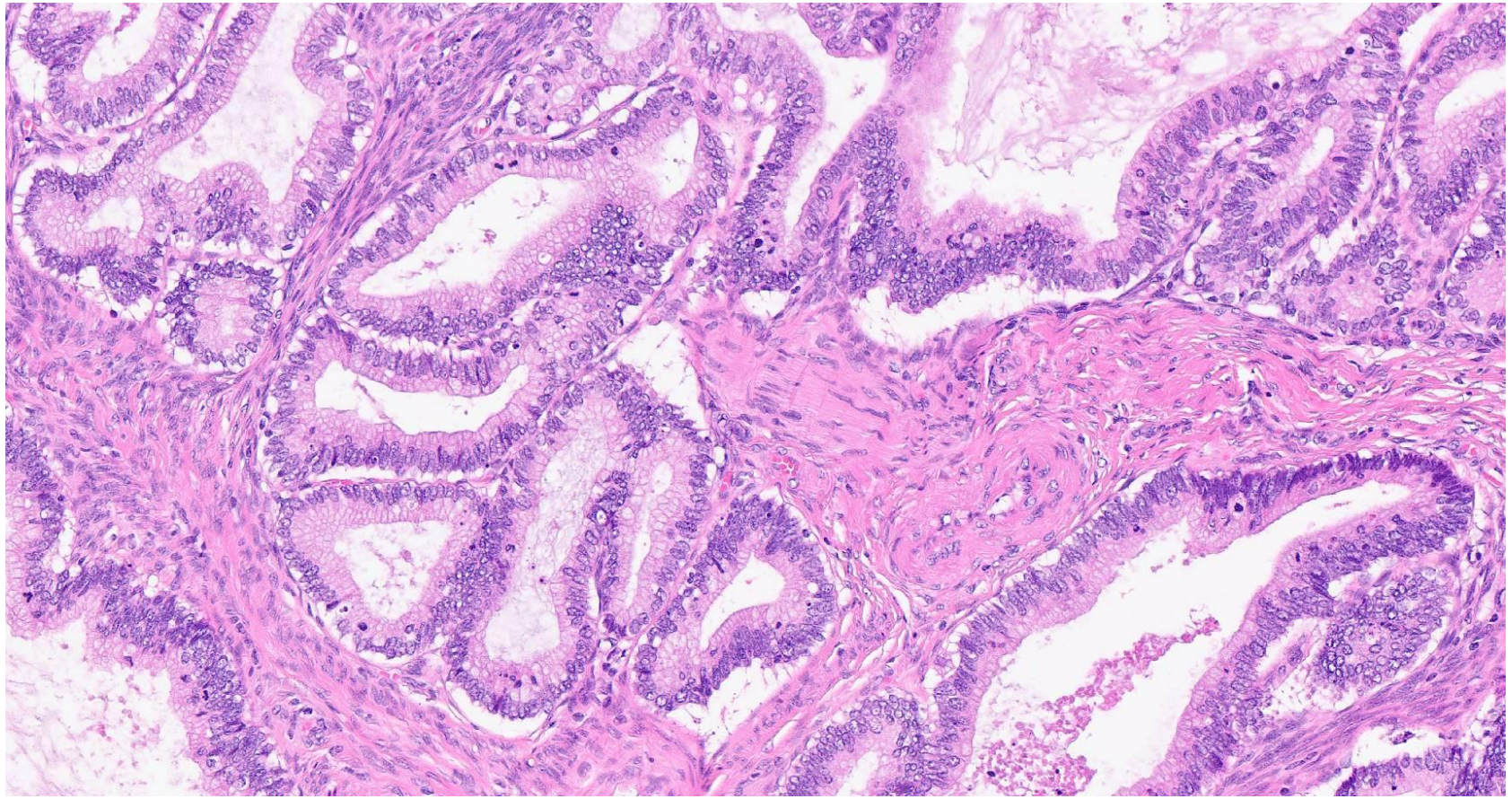

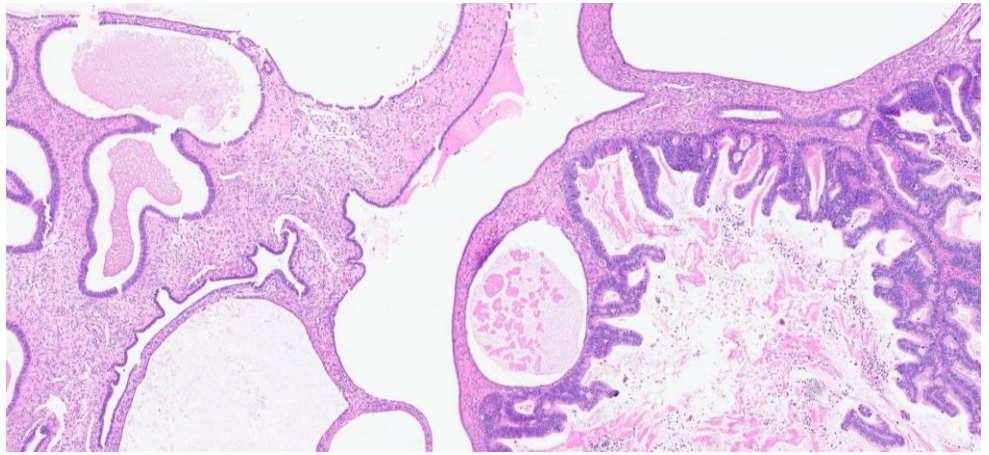

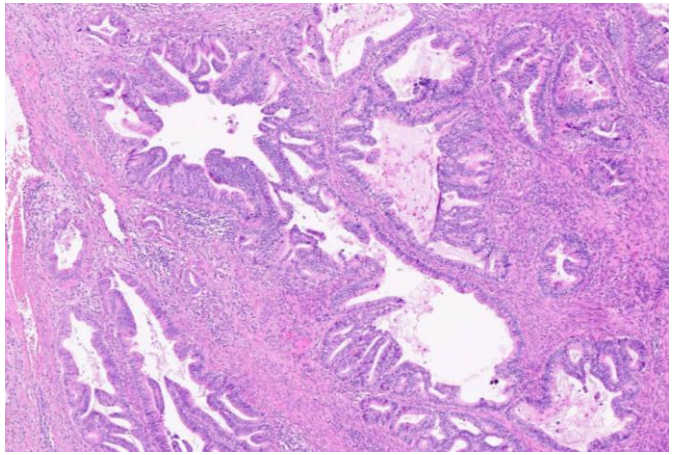

#1
Hysterectomy for uterine tumour

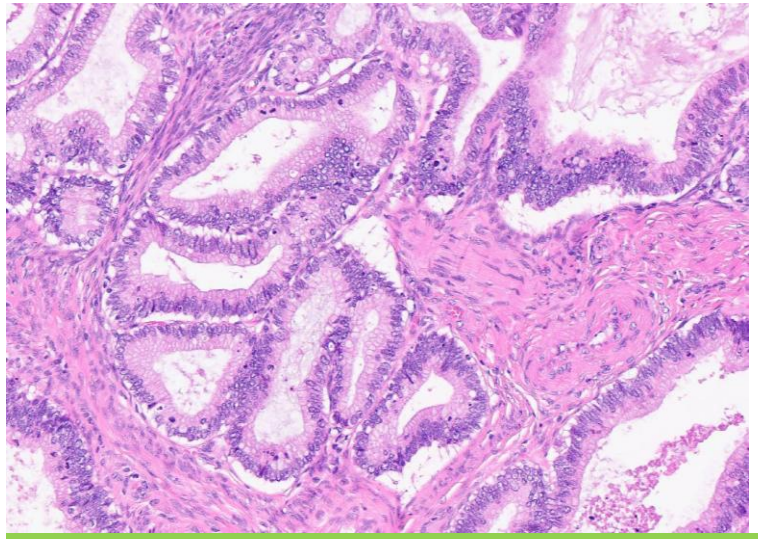

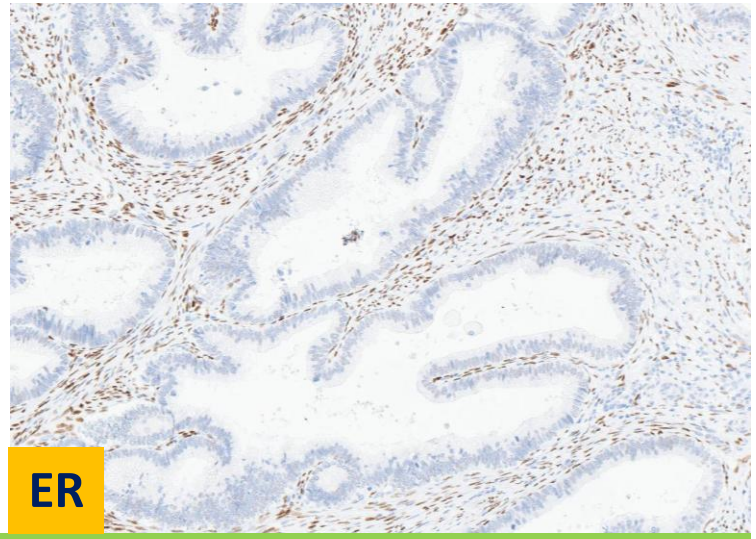

Endometrium



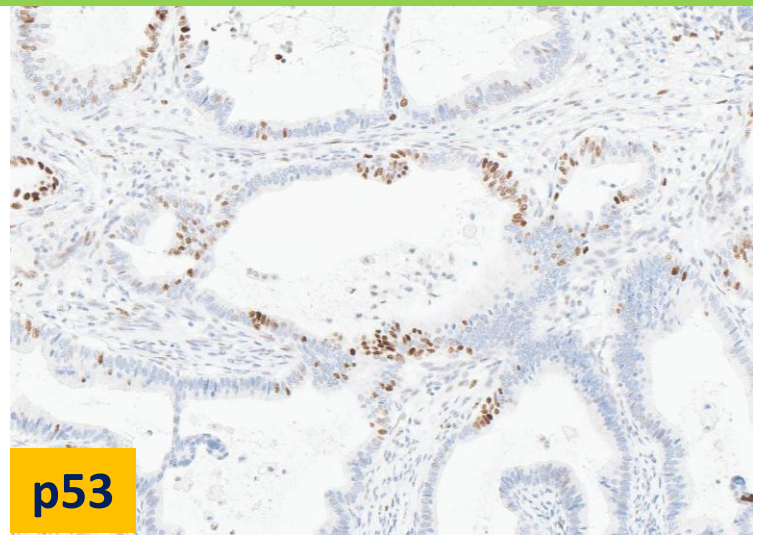

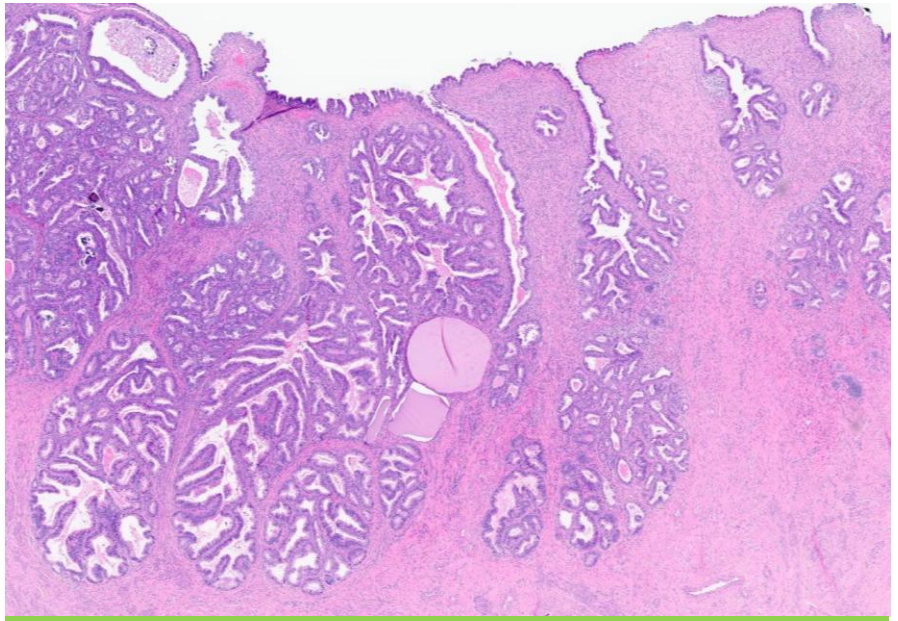

Cervix

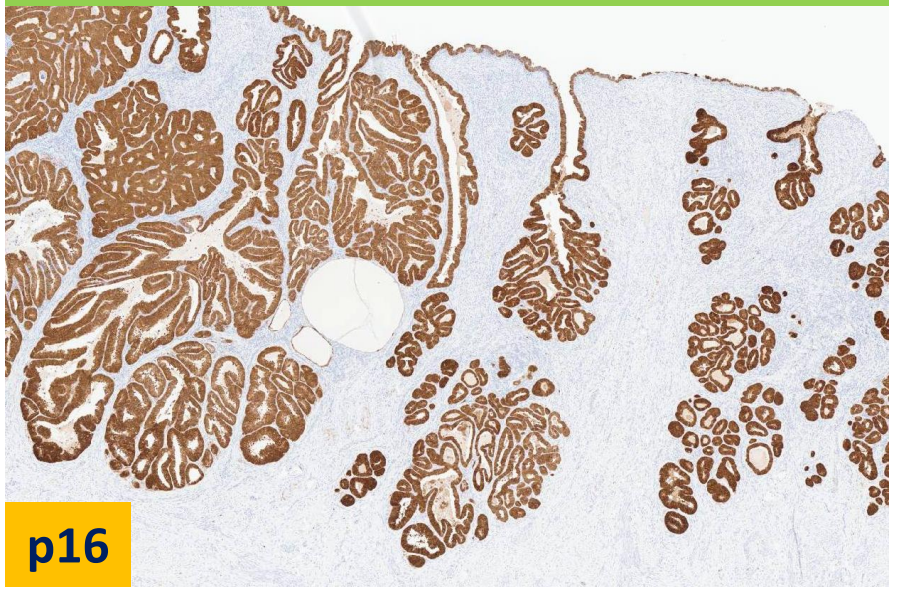

#1

HPV-associated adenocarcinoma involving endometrium

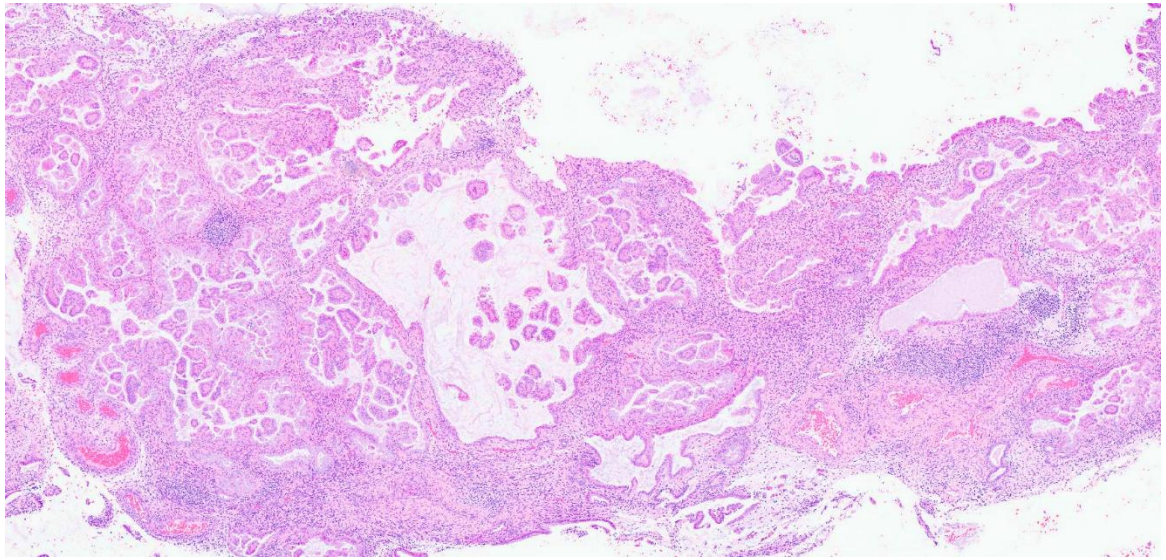

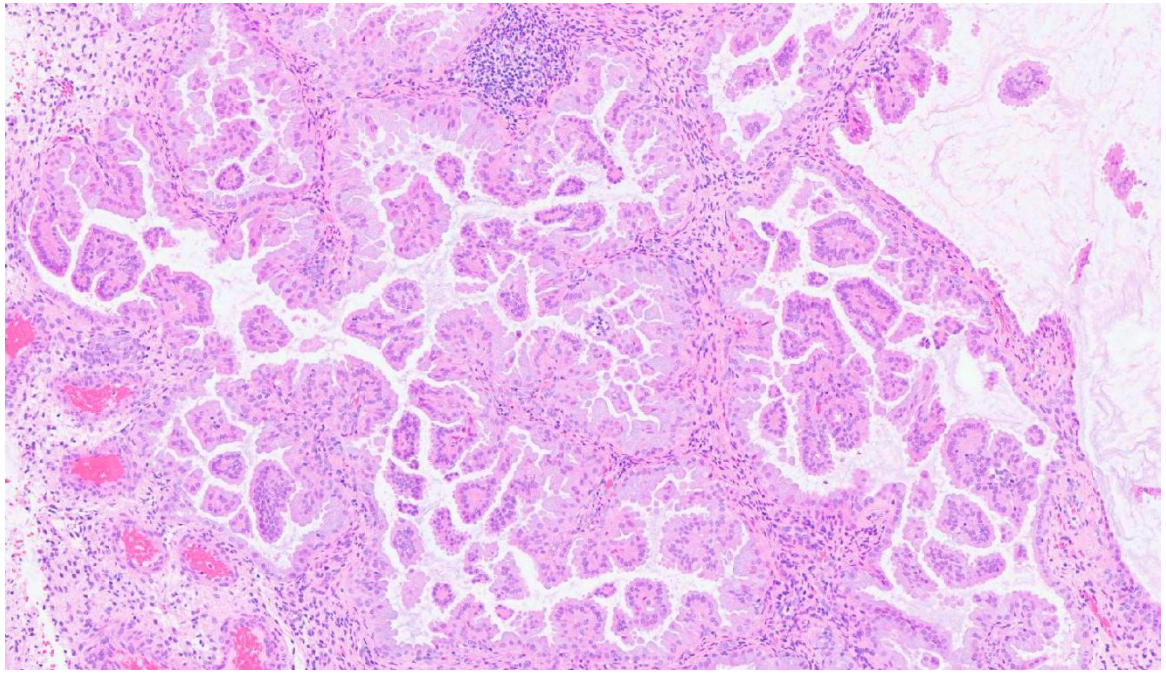

#2
Endometrial polyp biopsy

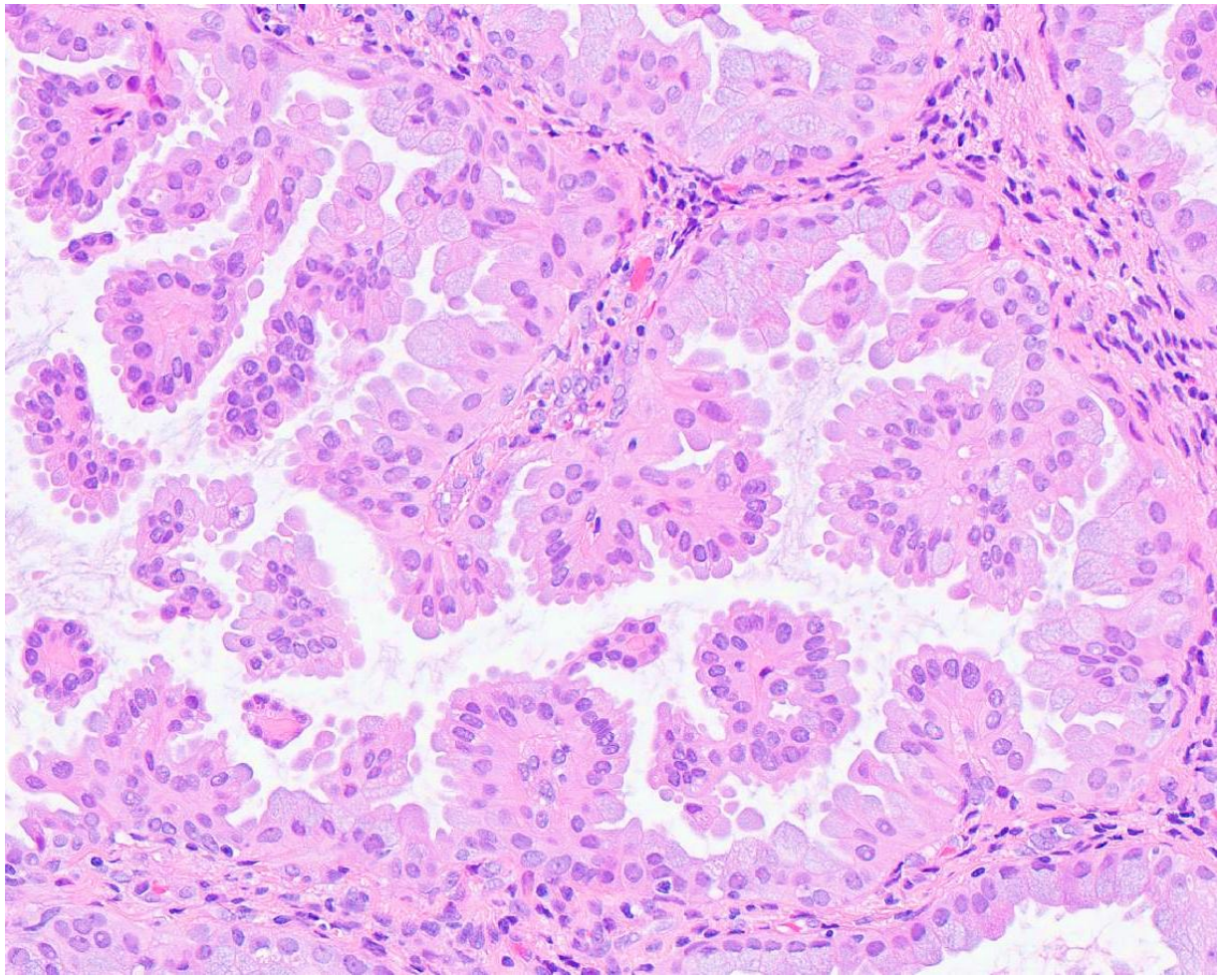

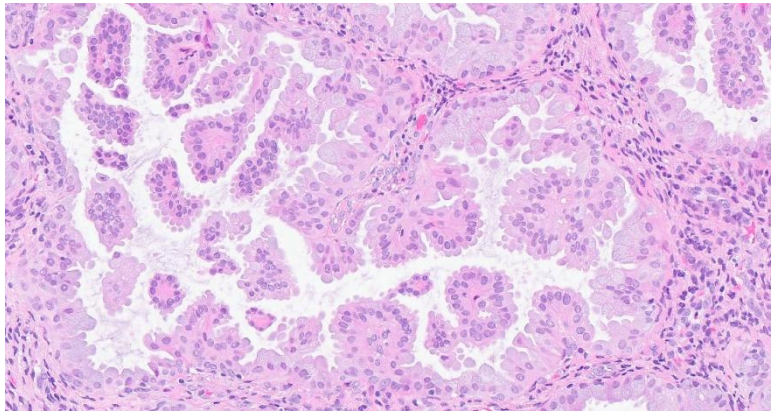

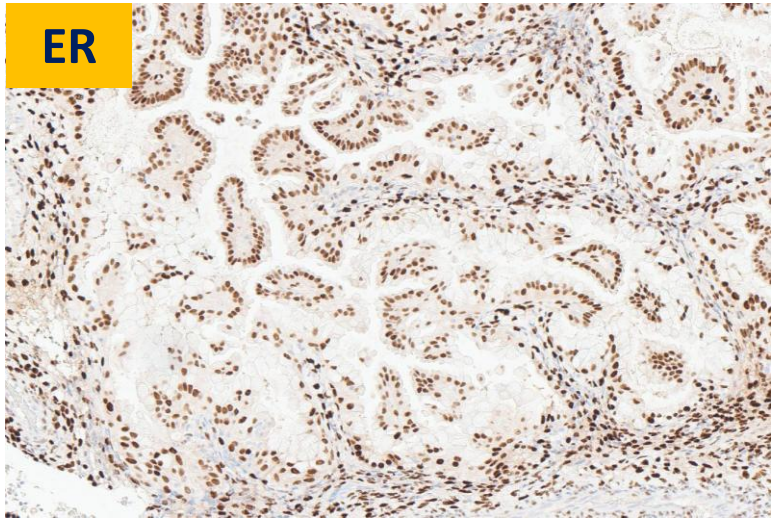

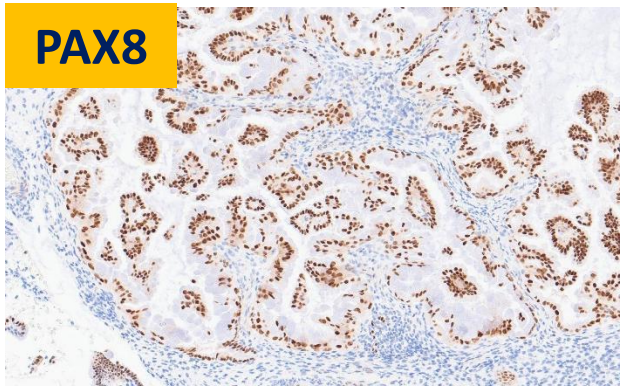

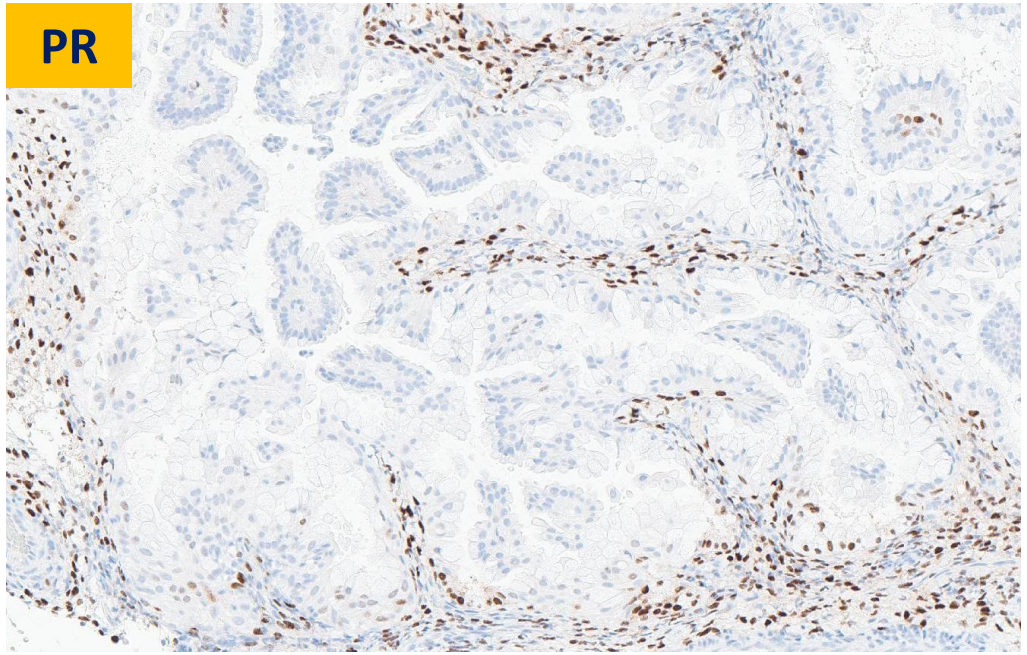

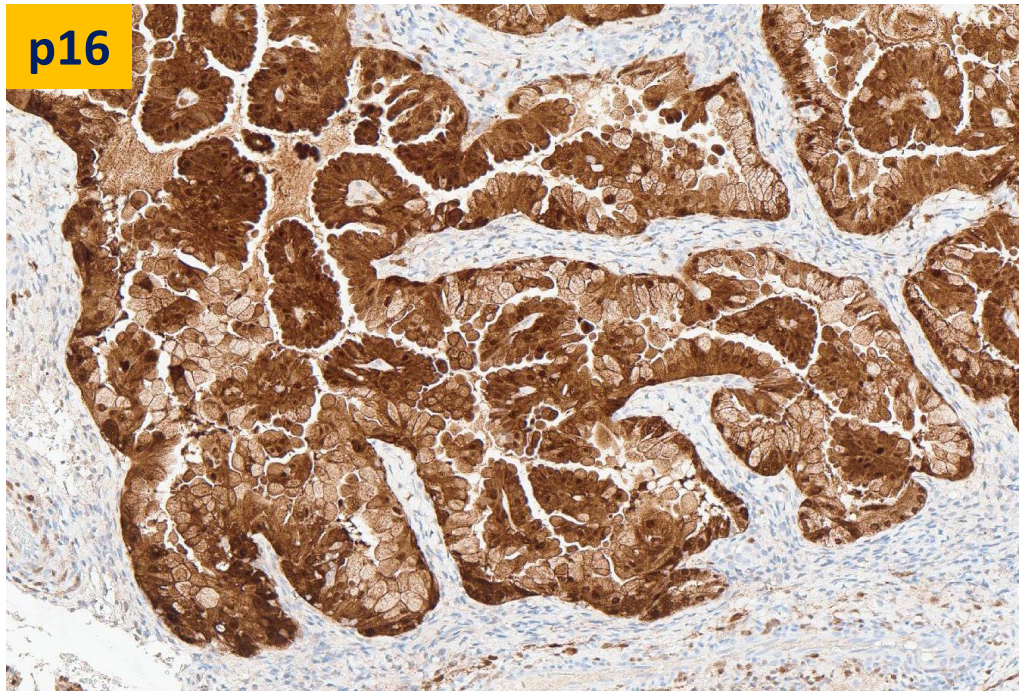

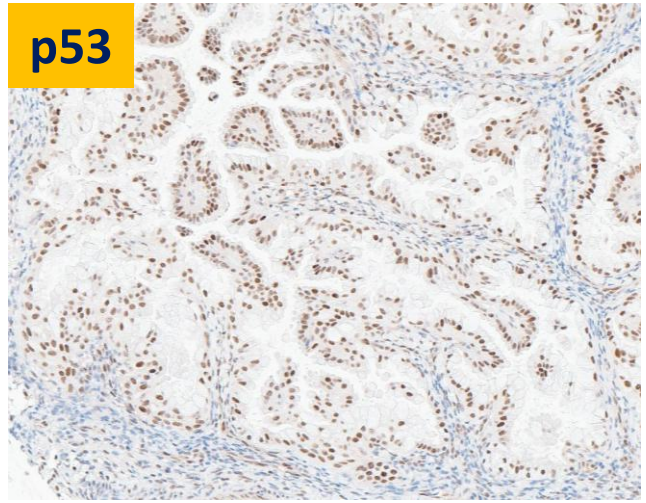

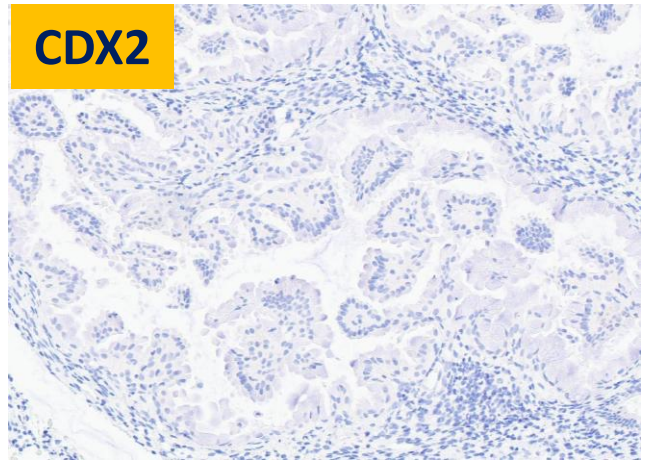

#2
Papillary proliferation of endometrium with mucinous metaplasia

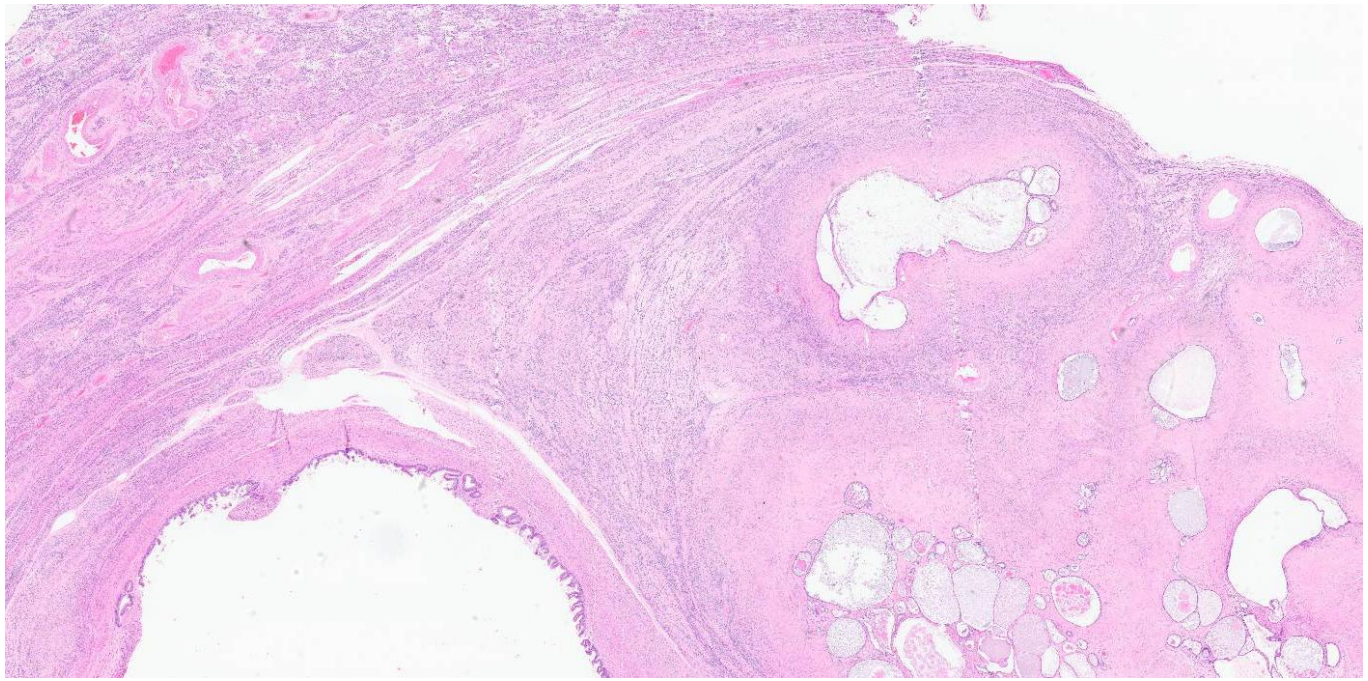

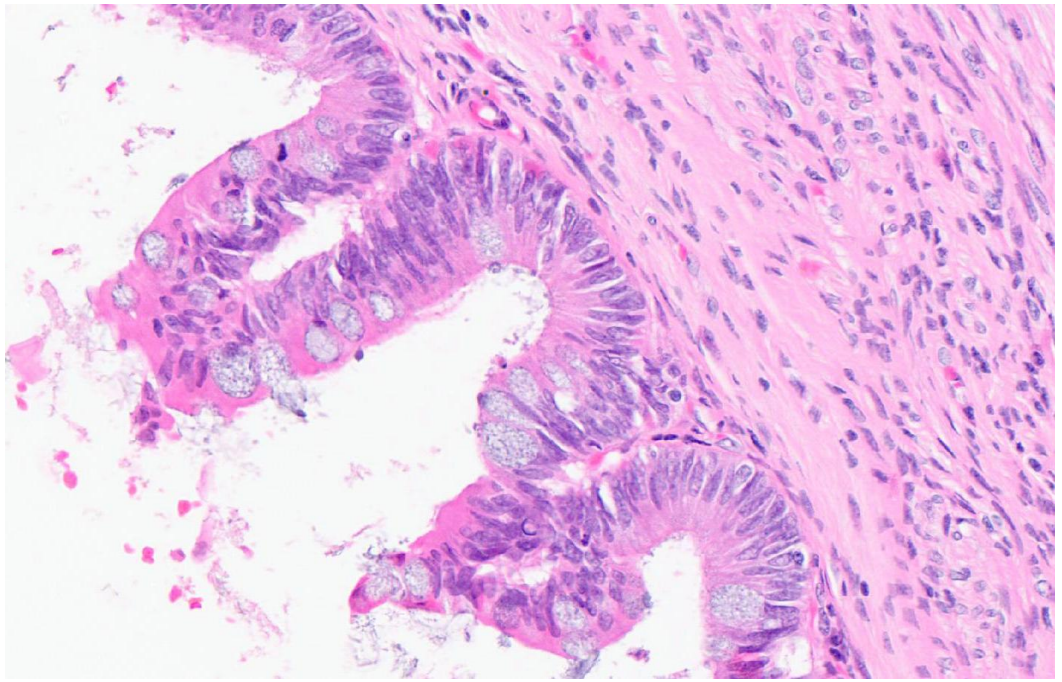

#3

Hysterectomy for uterine mass

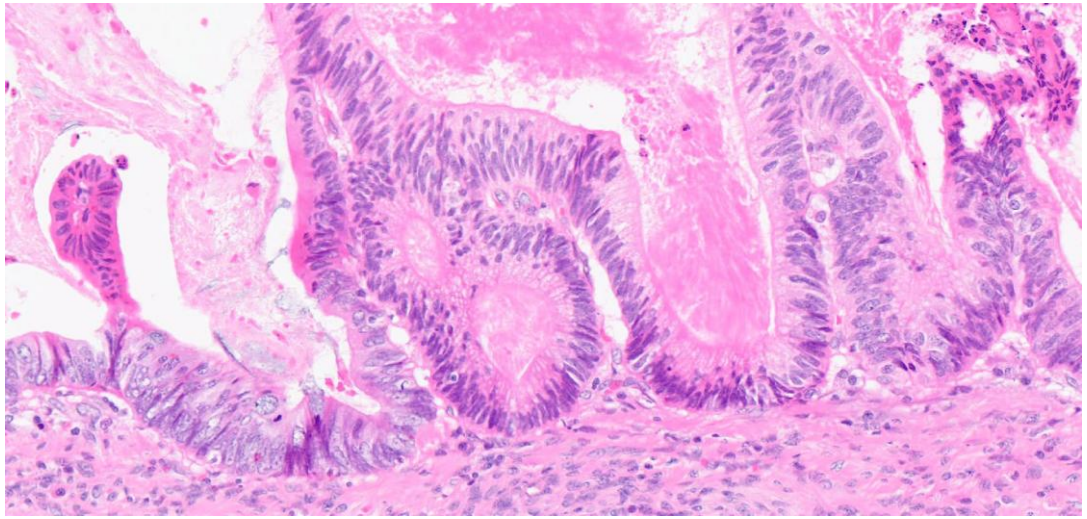

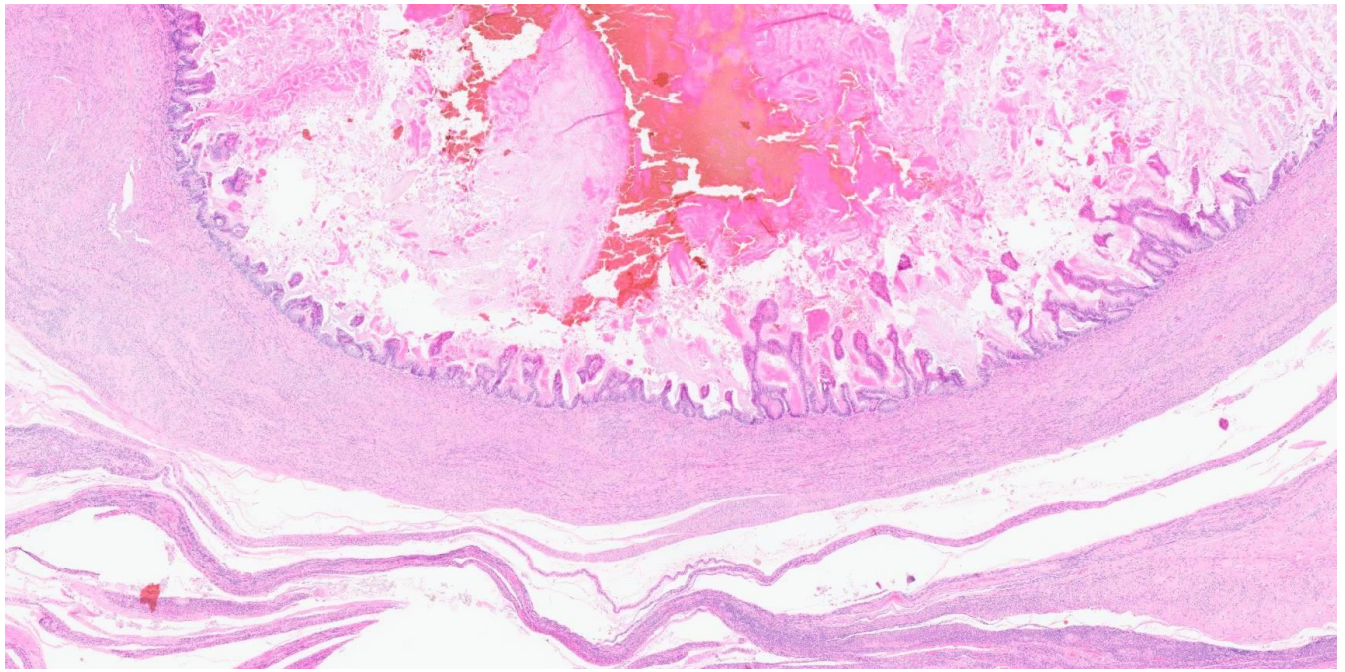

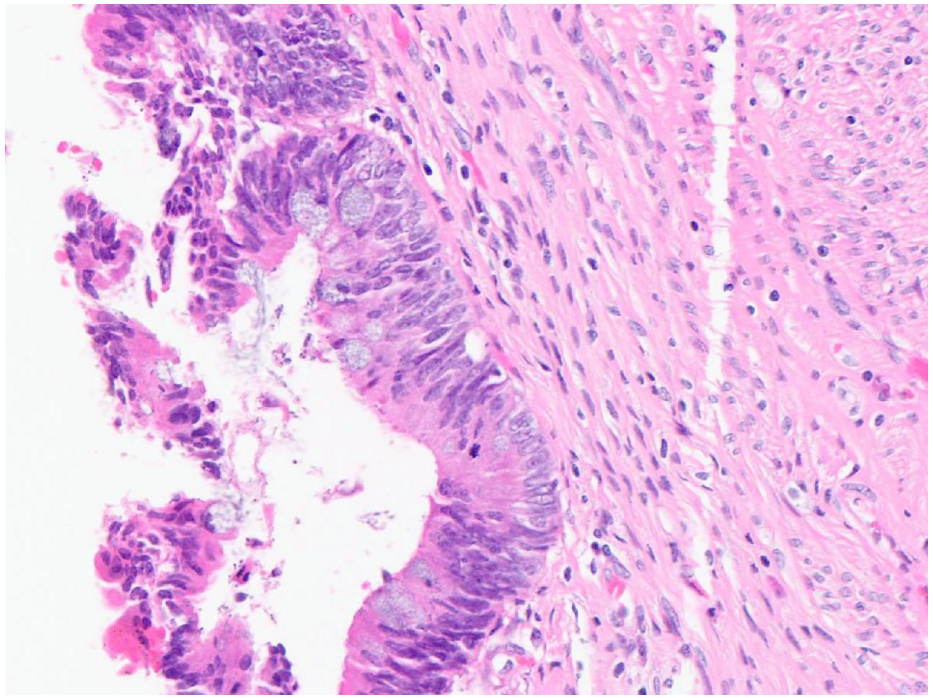

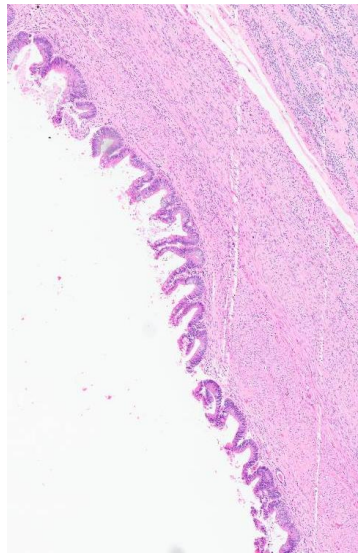

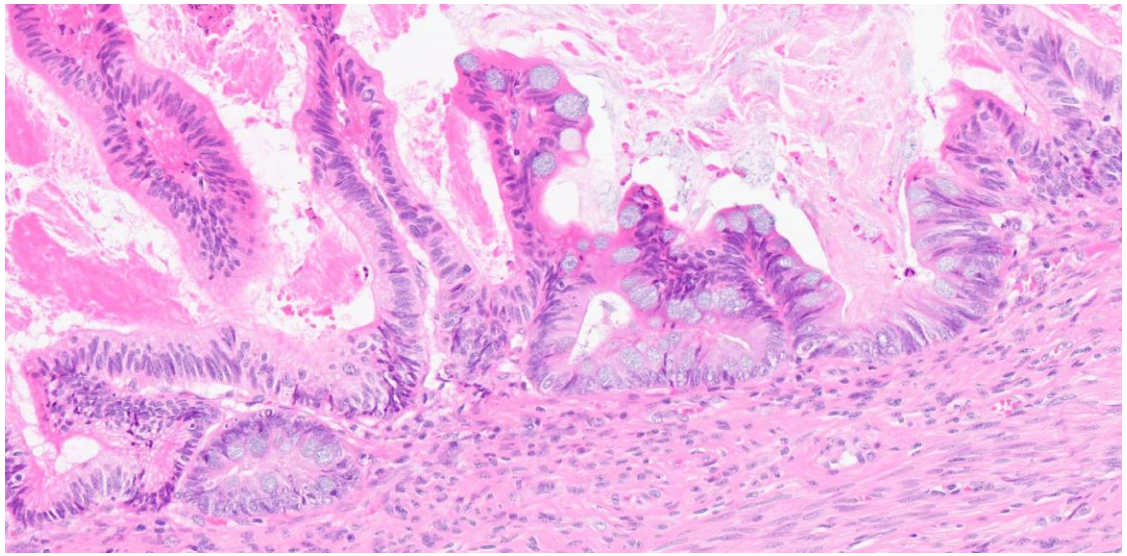

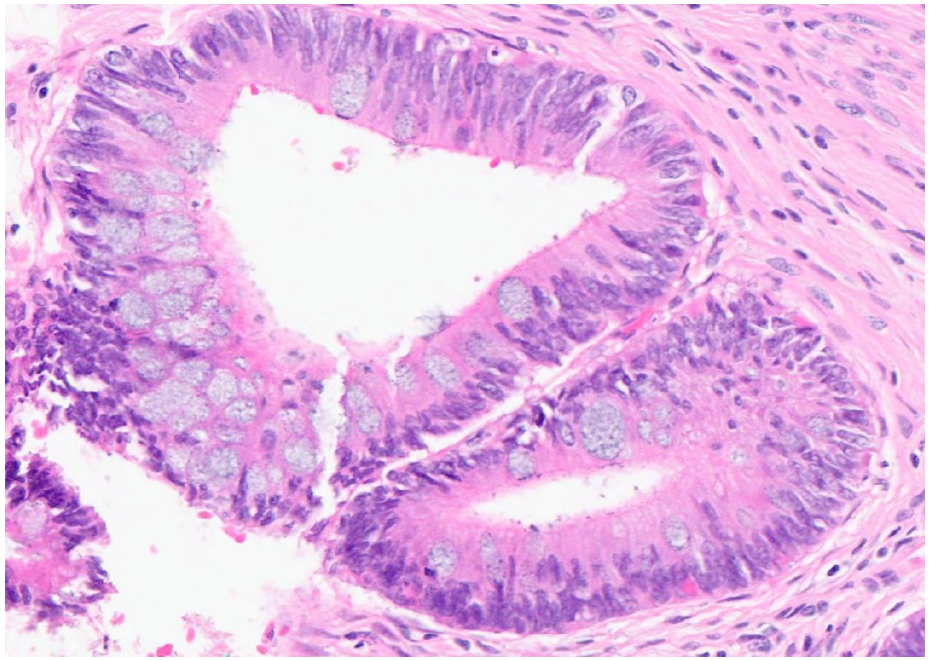

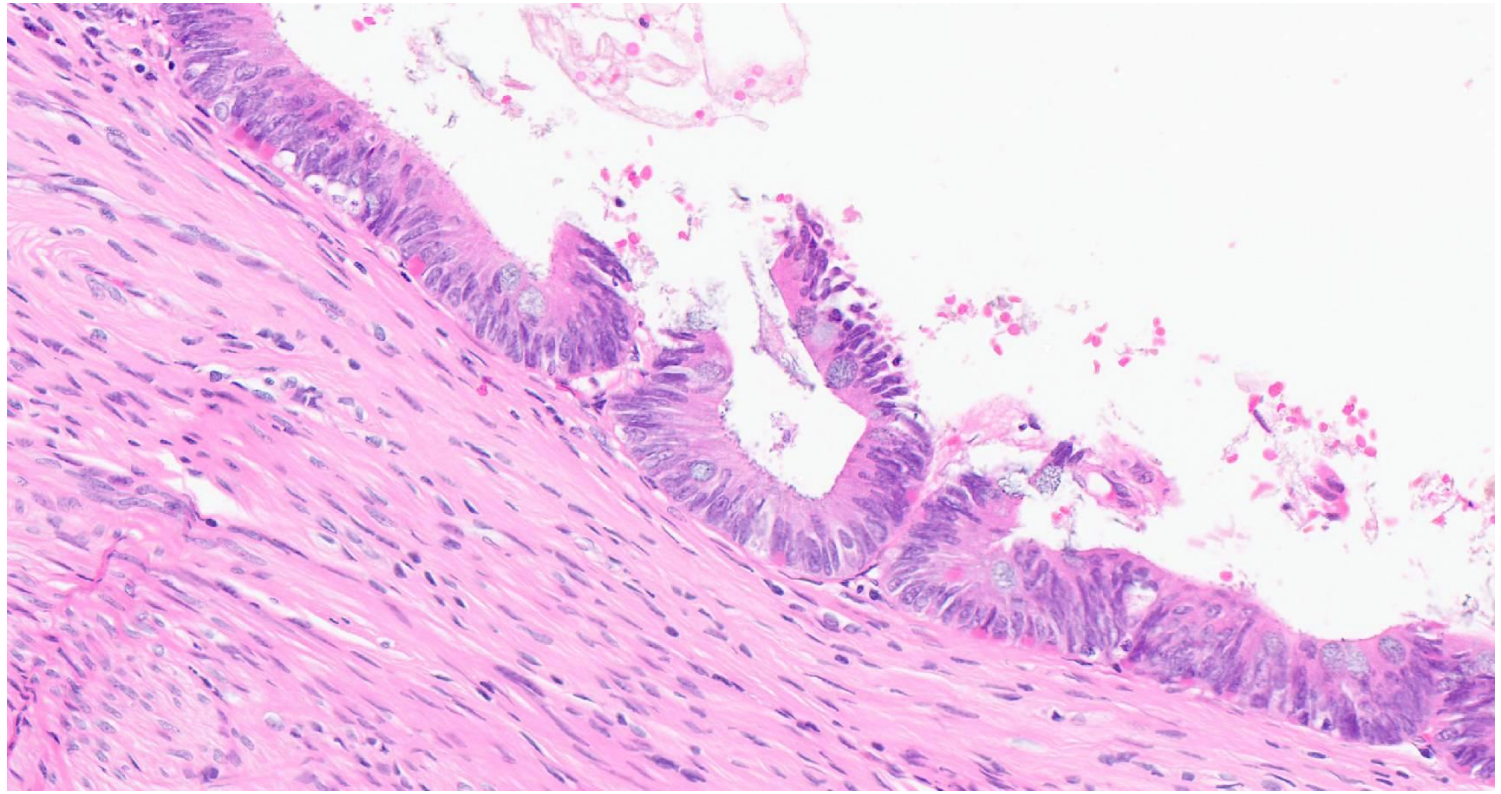

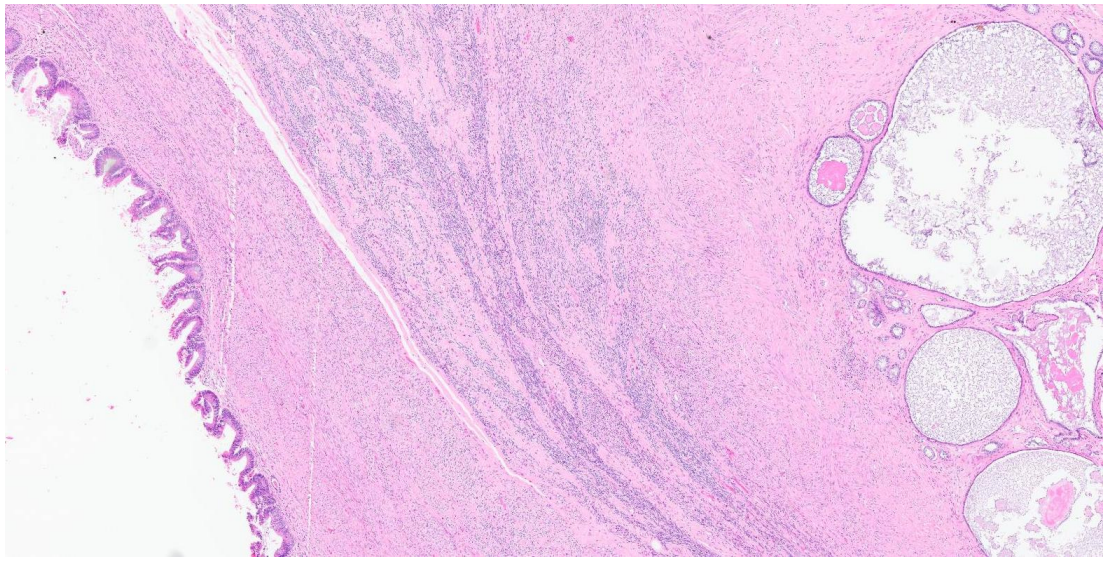



#3

Atypical mucinous proliferation of gastric-type



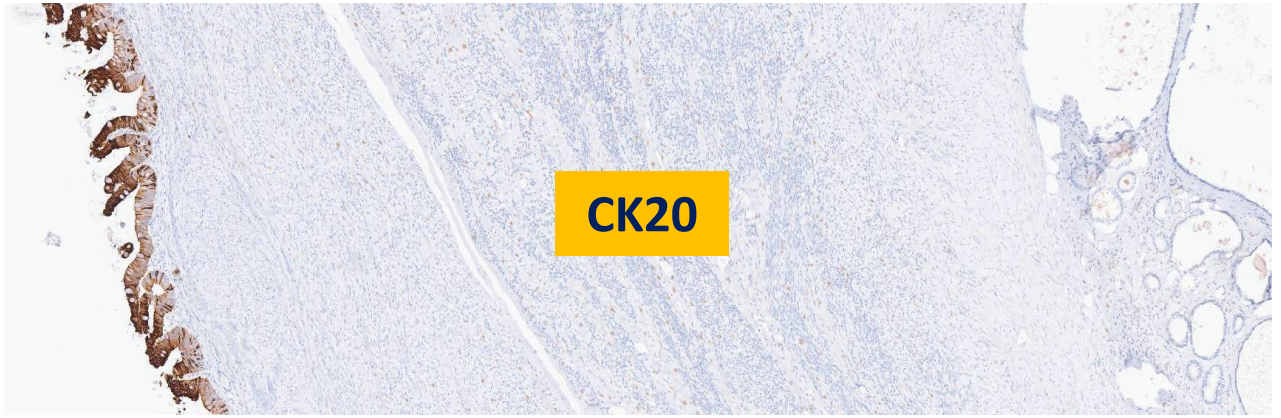

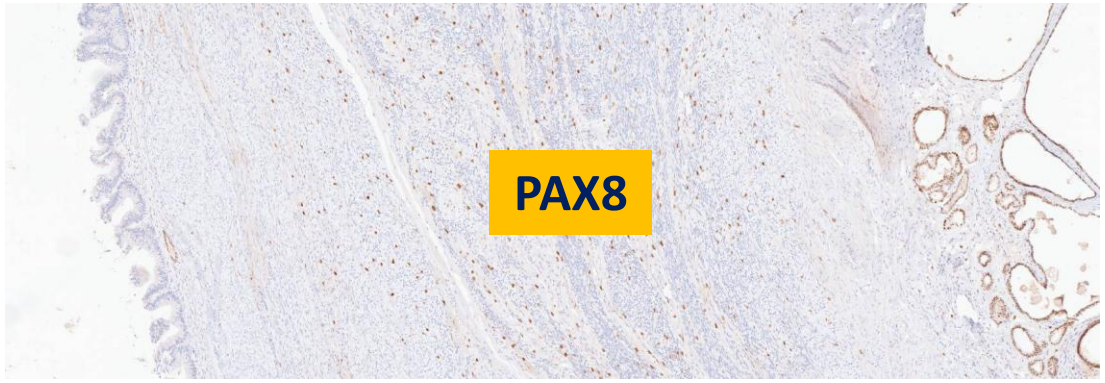



Practical approach to mucin rich endometrial pathology

- Consider the three major categories of mucinous lesions (or something else!)
  - Müllerian-type
  - Gastric/gastrointestinal-type
  - Cervical HPV-associated (or gastric-type)
- Give a comment based on the clinical context regarding the implications for the intermediate entities
  - Papillary proliferation of endometrium
  - Atypical mucinous glandular proliferation
  - Atypical mucinous proliferation of gastric-type
- Offer a comprehensive differential diagnosis when the exact location of the mucinous lesion is not entirely clear
  - Lack of surrounding stroma or indeterminate between endometrial vs cervical stroma
  - Clinical or imaging features suggestive of non-endometrial pathology

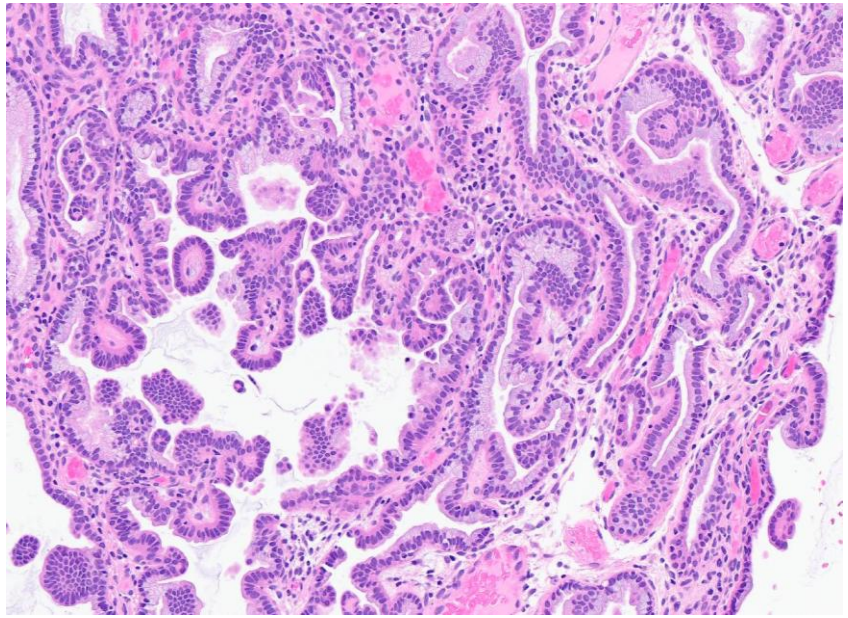
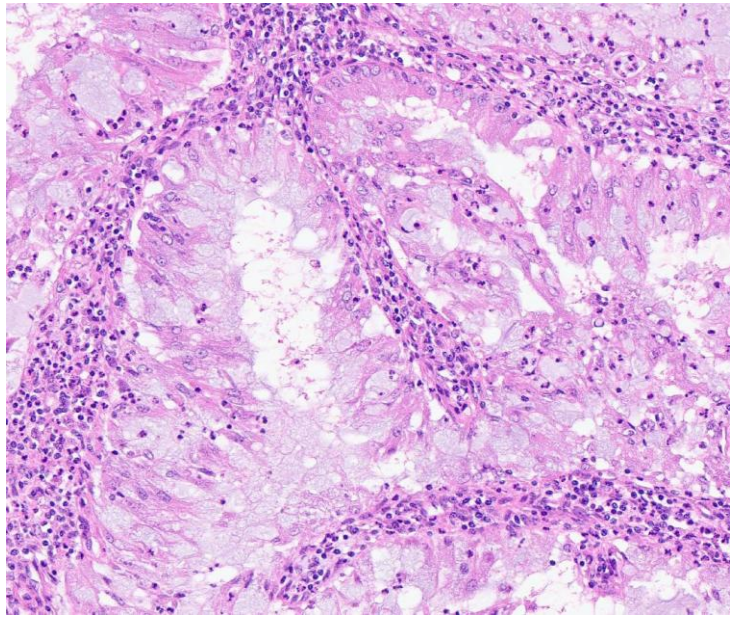
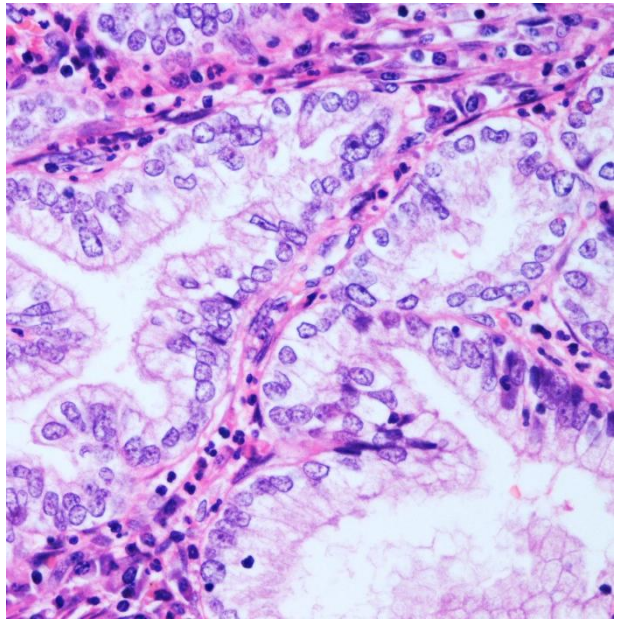

Thank you!

