The British Association of Gynaecological Pathologists

21st Annual Meeting in Collaboration with ISGyP

5th and 6th June 2025

- Practical Evaluation of Ovarian Mucinous Tumours
- Carlos Parra-Herran
- Brigham and Women's Hospital, Boston MA United States
- June 6, 2025

The British Association of Gynaecological Pathologists

Speaker disclosures

Choose one

- ❑ I have no financial conflicts of interest to disclose

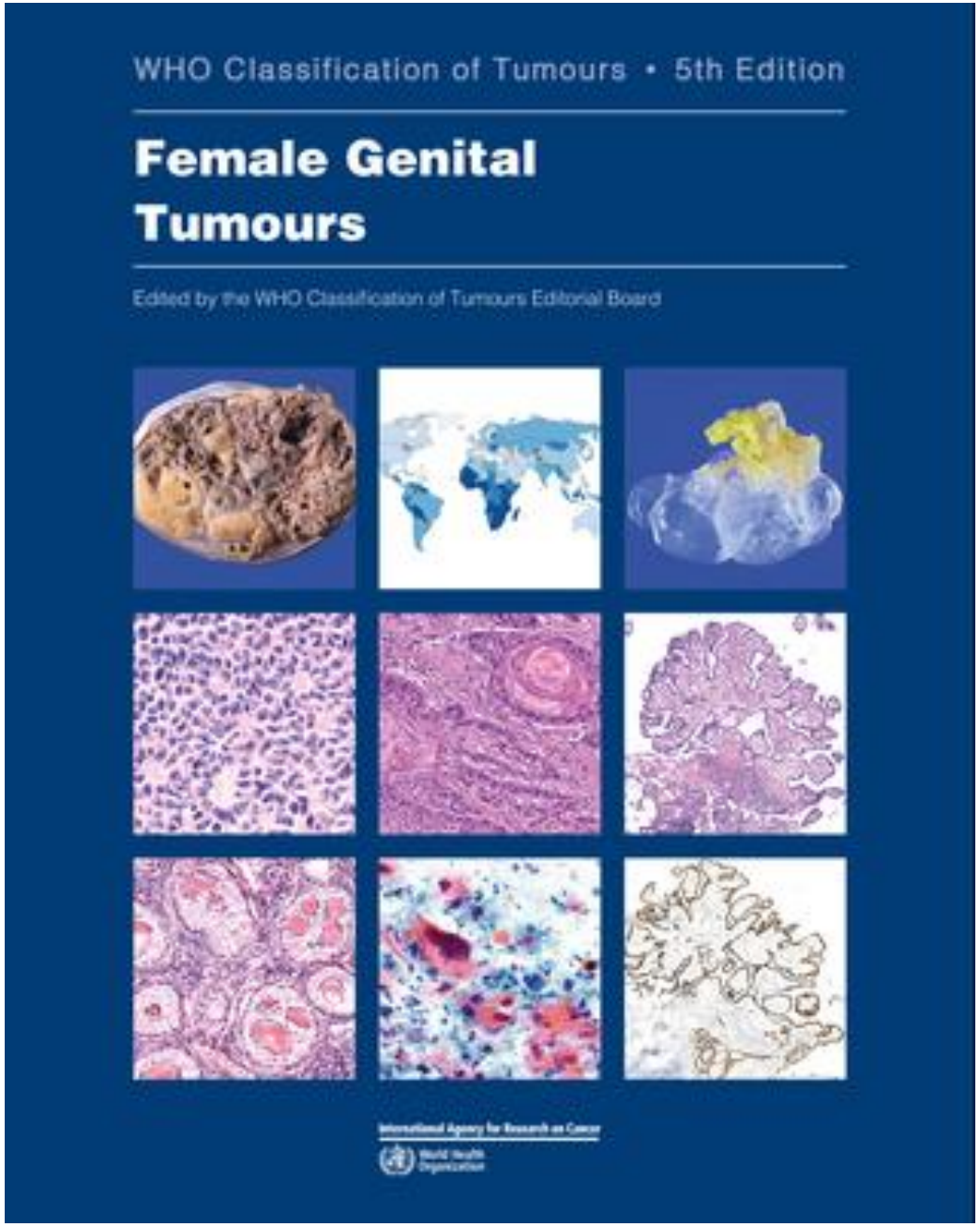

World Health Organization Classification of Female Genital Tumours. 5th Ed. 2020. International Agency for Research on Cancer.

REVIEW

Histopathology 2022;80: 255–278

Ovarian mucinous and seromucinous neoplasms: problematic aspects and modern diagnostic approach

Karen L Talia,[1,*] Carlos Parra-Herran[2,*] & W Glenn McCluggage[3,*]

[1]*Department of Pathology, Royal Women's Hospital and VCS Foundation, Melbourne, Australia,* [2]*Department of Pathology, Brigham and Women's Hospital, Boston, MA, USA, and* [3]*Department of Pathology, Belfast Health and Social Care Trust, Belfast, UK*

REVIEW ARTICLE

Adv Anat Pathol 2025;32:85–97

Diagnosis and Risk Stratification of Ovarian Mucinous Neoplasms: Pattern of Invasion, Immunohistochemistry, and Molecular Diagnostics

Martin Köbel, MD, Carlos Parra-Herran, MD,† and Kylie Gorringe, PhD‡§*

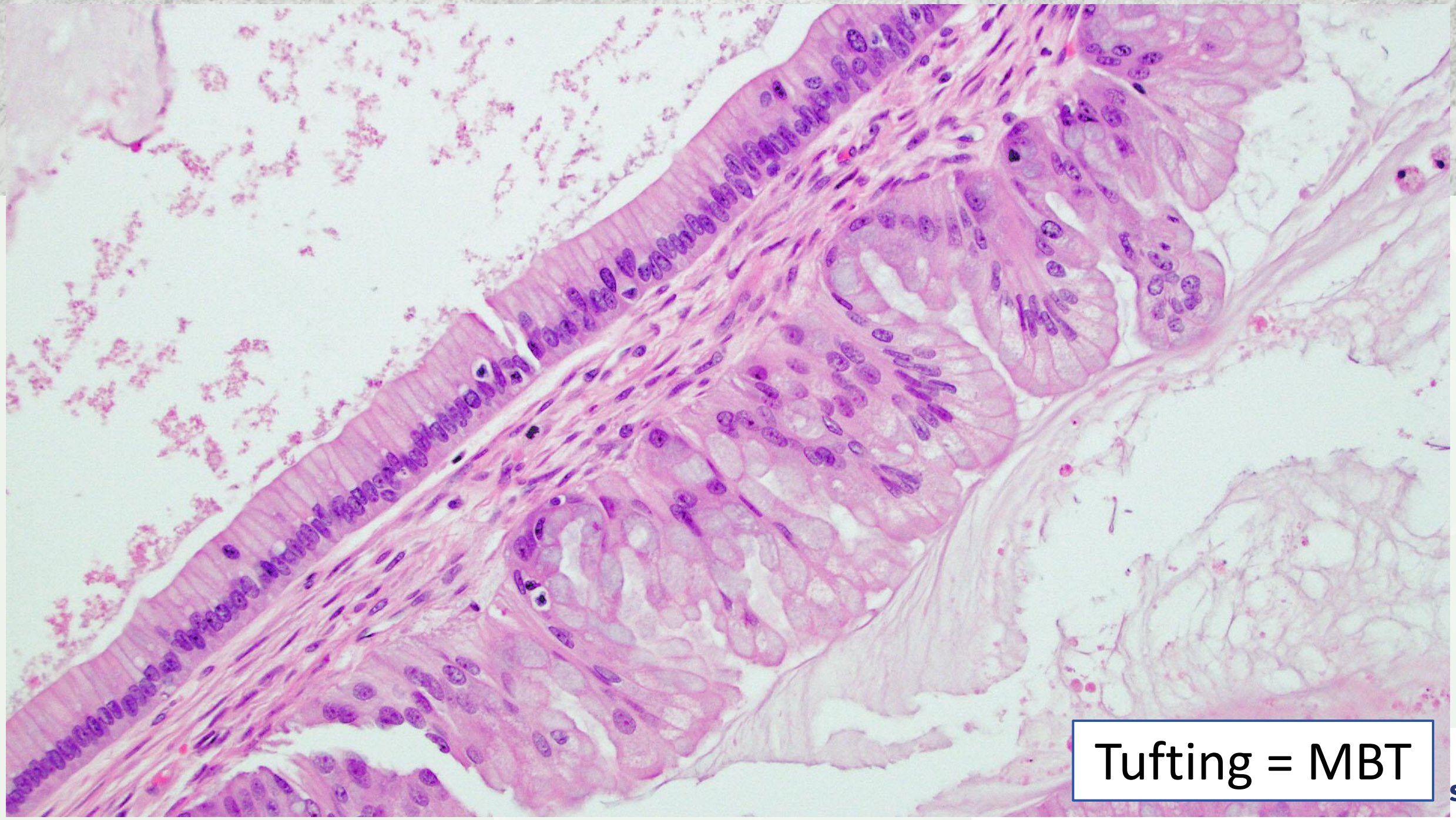
Tufting = MBT

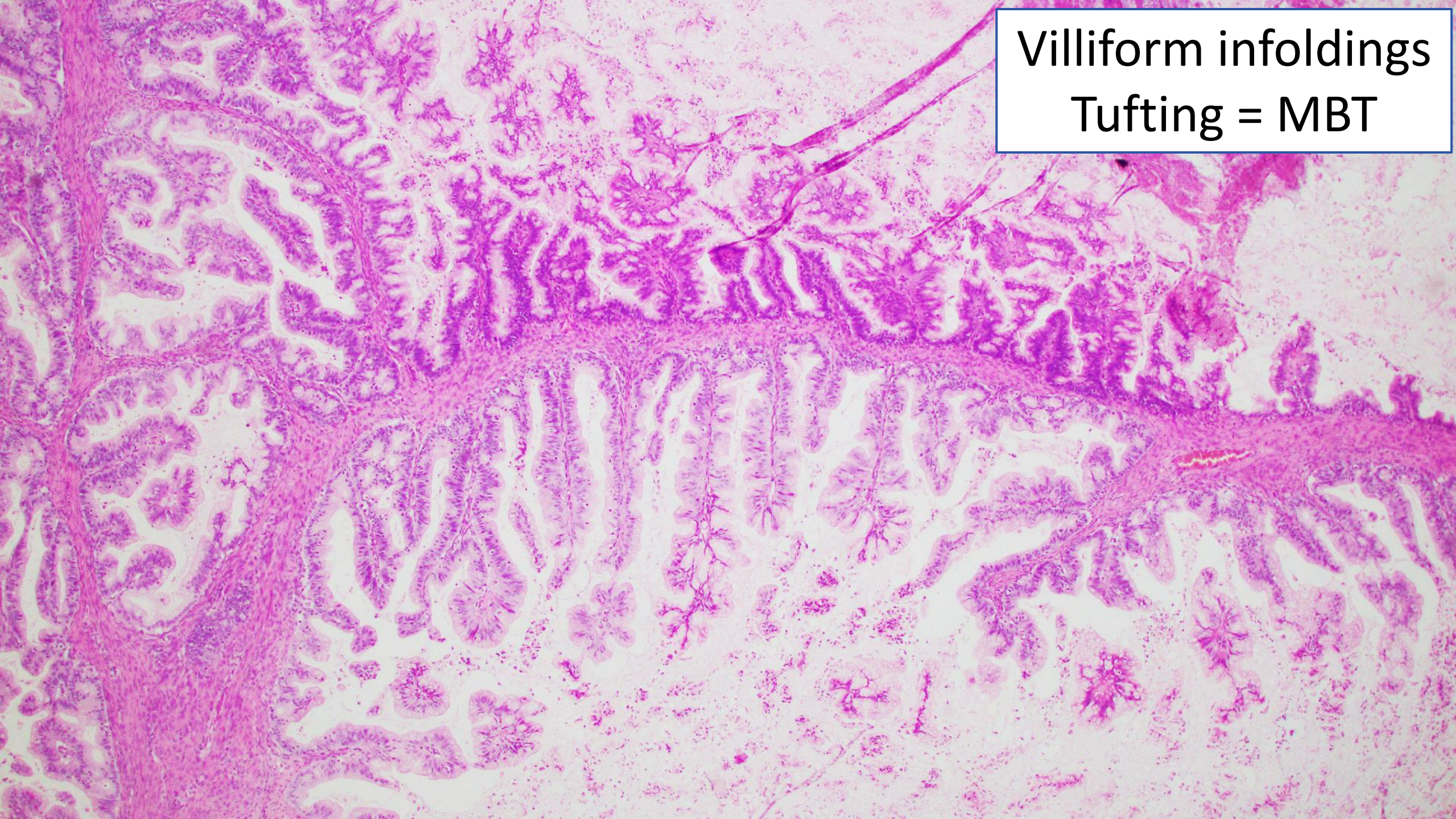
Villiform infoldings
Tufting = MBT

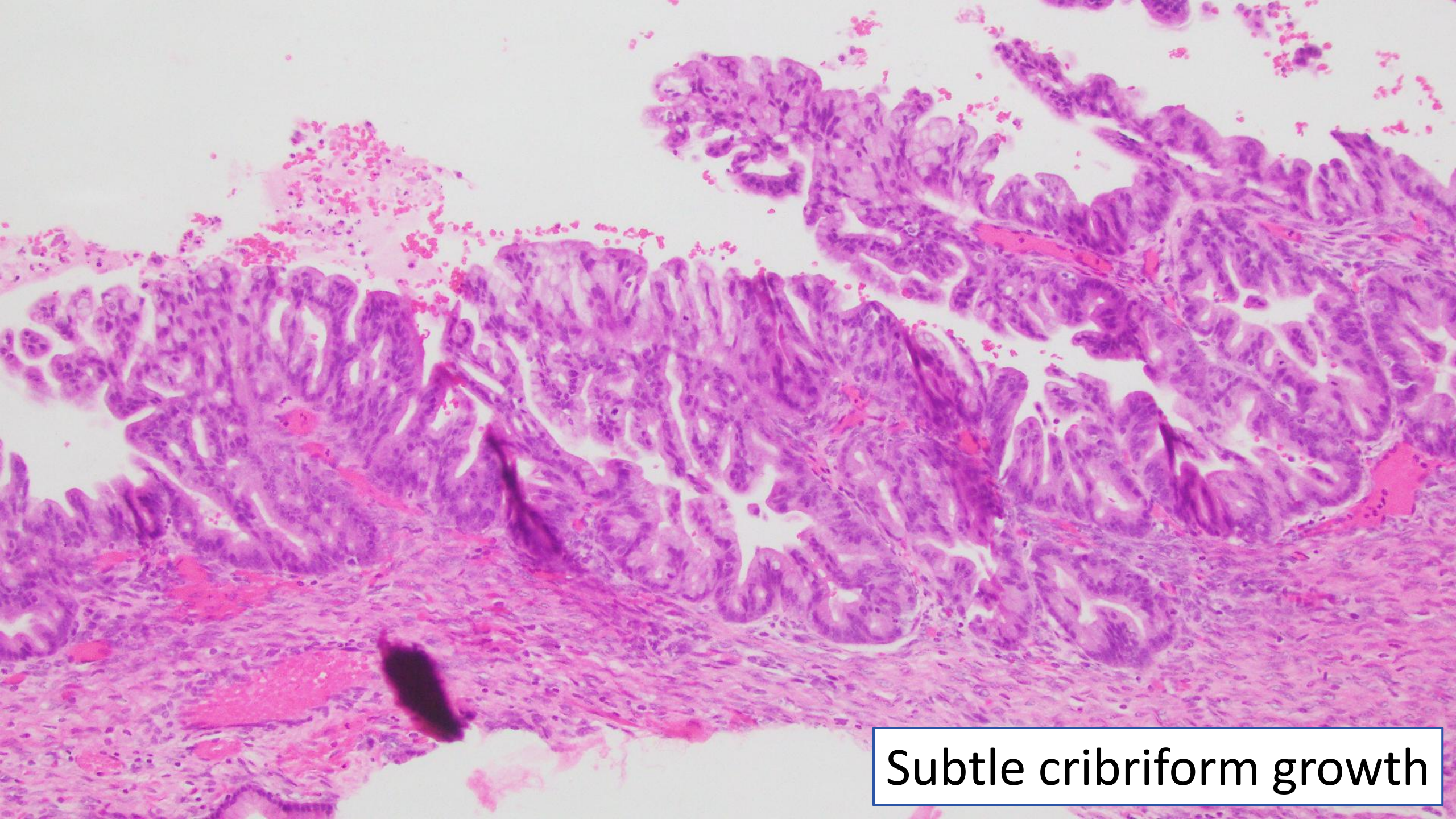
Subtle cribriform growth

MUCINOUS BORDERLINE TUMORS

- Largely indolent outcome
- Recurrence (?) after:
  - *Cystectomy*
  - *Incomplete removal*
  - *Intra-op spillage*

Pelvic – often with involvement of vagina and/or bowel

Residual ovarian parenchyma often identified in recurrence

Int J Gynecol Pathol 2010; 29:108–112
Int J Gynecol Pathol 2014; 33:156–165

The British Association of Gynaecological Pathologists

MUCINOUS BORDERLINE TUMORS

- Other features associated with recurrence
  - *Young age (<45 years)*
  - *Microinvasion and microinvasive carcinoma*
  - *Intraepithelial carcinoma*
  - *Stage IC or greater*
- 4.2% risk of malignant progression
  - *MBT vs undersampled malignancy*

Int J Gynecol Pathol 2010; 29:108–112
Int J Gynecol Pathol 2011;30: 218–230
Am J Surg Pathol 2011;35:1331–1336

The British Association of Gynaecological Pathologists

TABLE 1. Clinical and Pathologic Findings in Recurrent Cases

Case	Age at Diagnosis (y)	Maximum Tumor Dimension (cm)	Tumor Type	No. Sections Examined	Stage	Time to Recurrence (mo)	Site of Recurrence	Follow-Up
1	47	19	Borderline mucinous tumor	11	1A	8	Peritoneum and abdominal wall	Died of disease 1 mo after recurrence
2	46	17	Borderline mucinous tumor	19	1C	11	Peritoneum and abdominal wall	Died of disease 1 mo after recurrence
3	64	27	Borderline mucinous tumor	10	1C	35	Serosa of colon	Died of disease 35 mo after recurrence
4	43	28	Borderline mucinous tumor	11	1A	56	Omentum, liver and spleen	Died of disease 1 mo after recurrence
5	37	21	Borderline mucinous tumor (with microinvasion)	15	1A	23	Peritoneum and abdominal wall	Alive 9 mo after recurrence
6	28	16	Borderline mucinous tumor	13	1C	20	Peritoneum and abdominal wall	No follow-up
7	22	20	Borderline mucinous tumor	21	1C	4	Para-aortic lymph node	Alive and well 72 mo after recurrence
8	37	16	Mucinous carcinoma (grade 2) (expansile invasion)	11	2B	30	Peritoneum	Died of disease 18 mo after recurrence
9	78	20	Mucinous carcinoma (grade 1) (expansile invasion)	16	1A	45	Omentum	Died of disease 10 mo after recurrence
10	60	27	Mucinous carcinoma (grade 2) (expansile and infiltrative invasion)	11	1C	8	Pleura and peritoneum	Died of disease 10 mo after recurrence

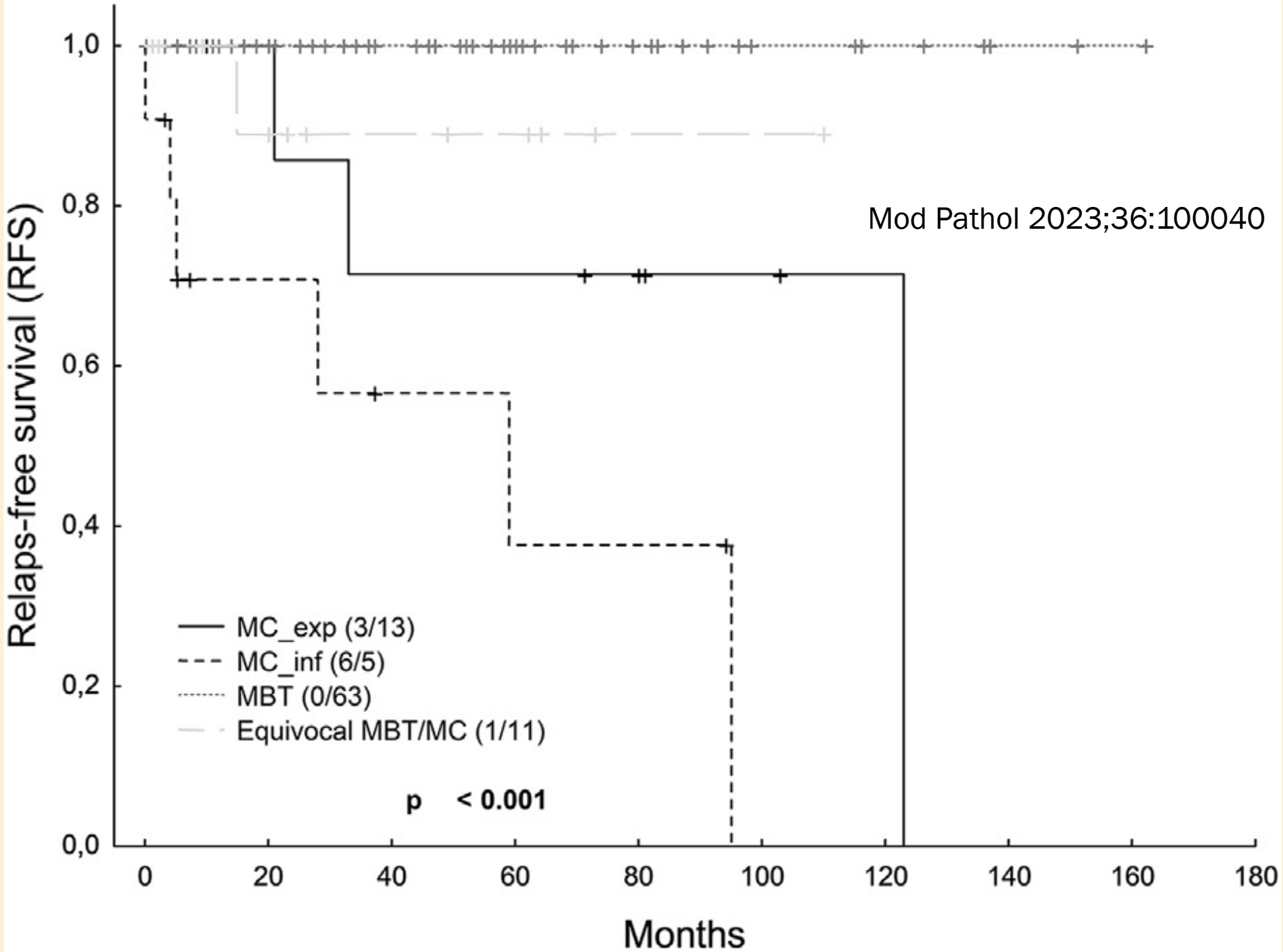

Mod Pathol 2023;36:100040

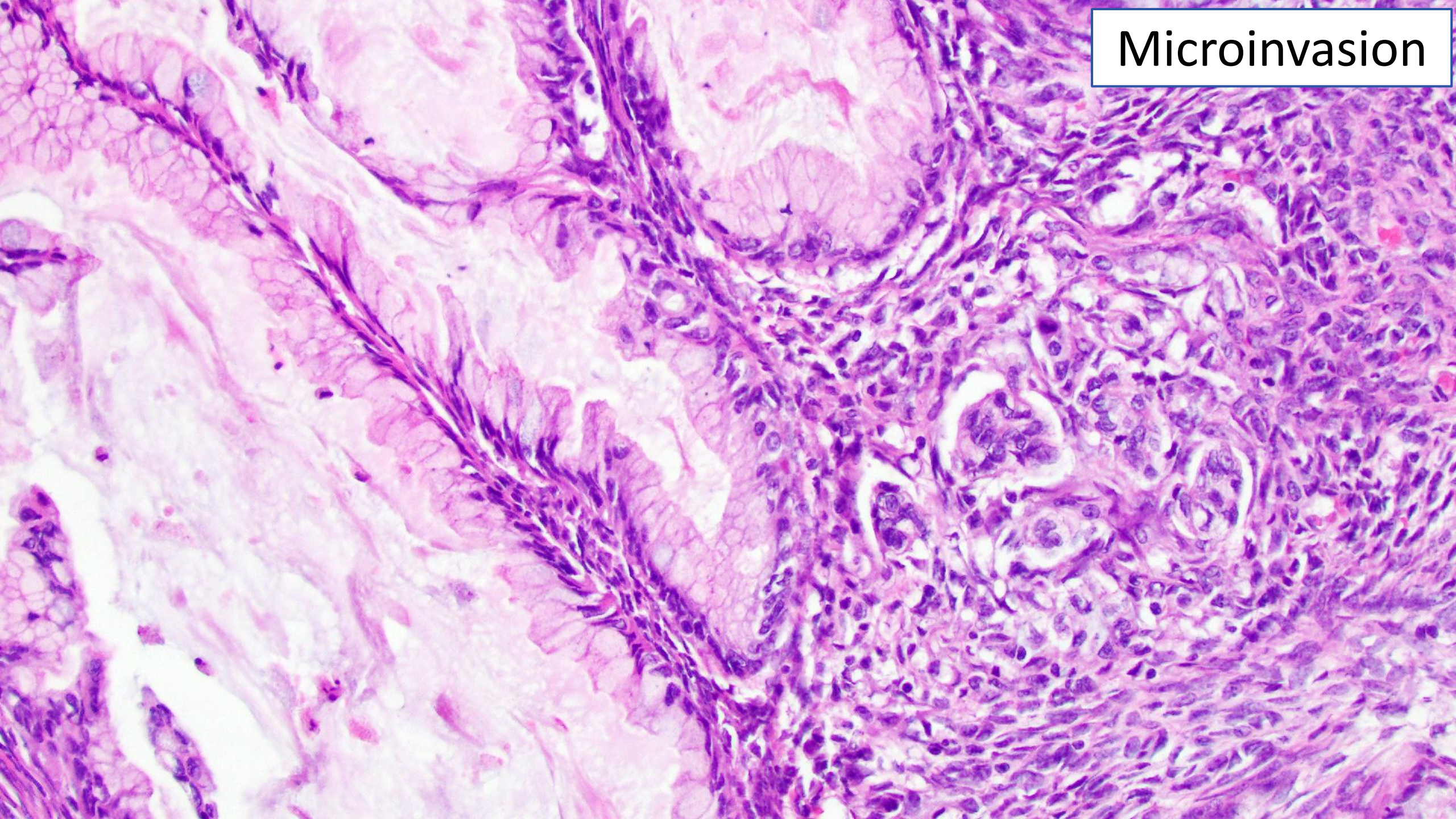
Microinvasion

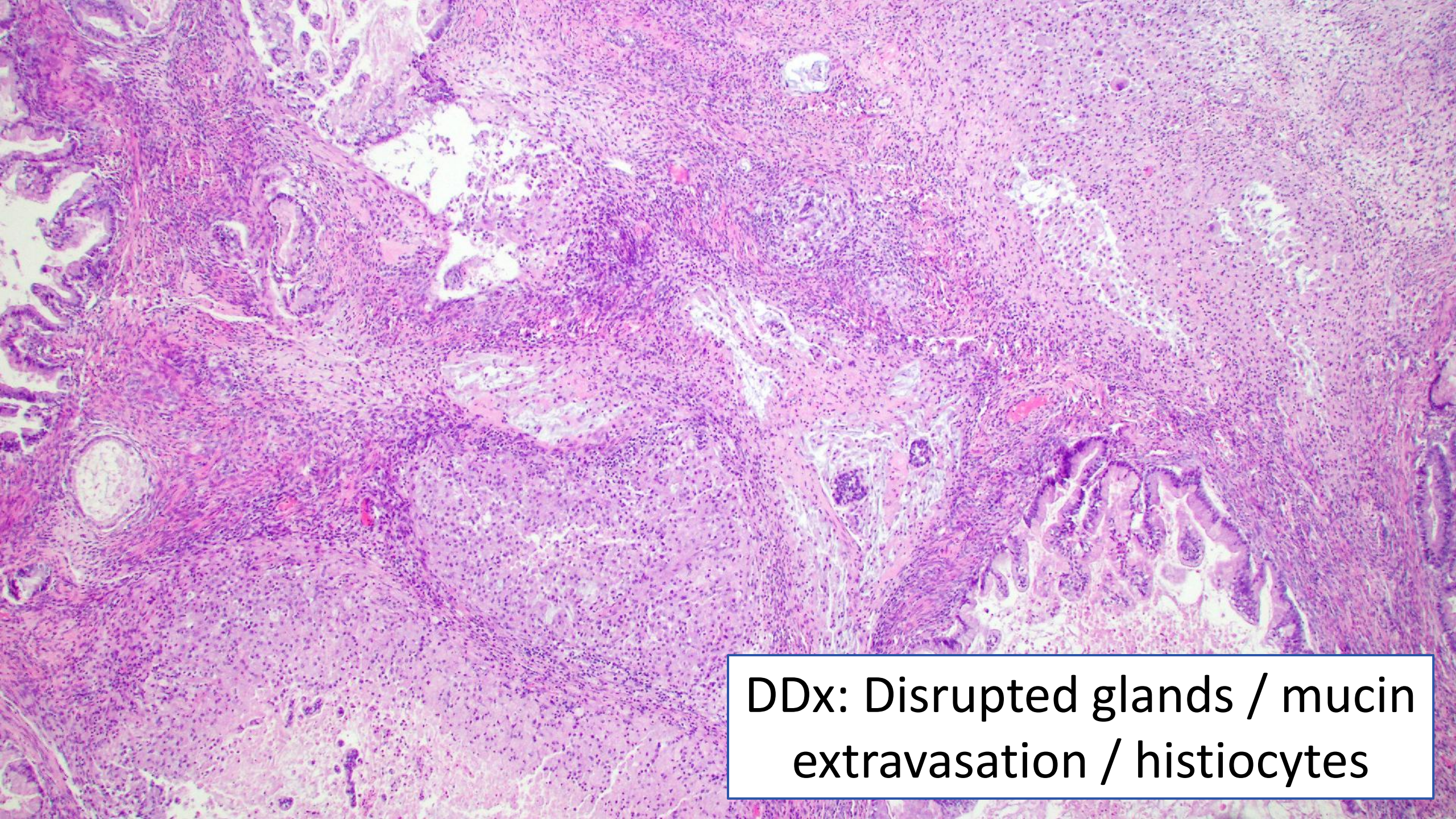
DDx: Disrupted glands / mucin extravasation / histiocytes

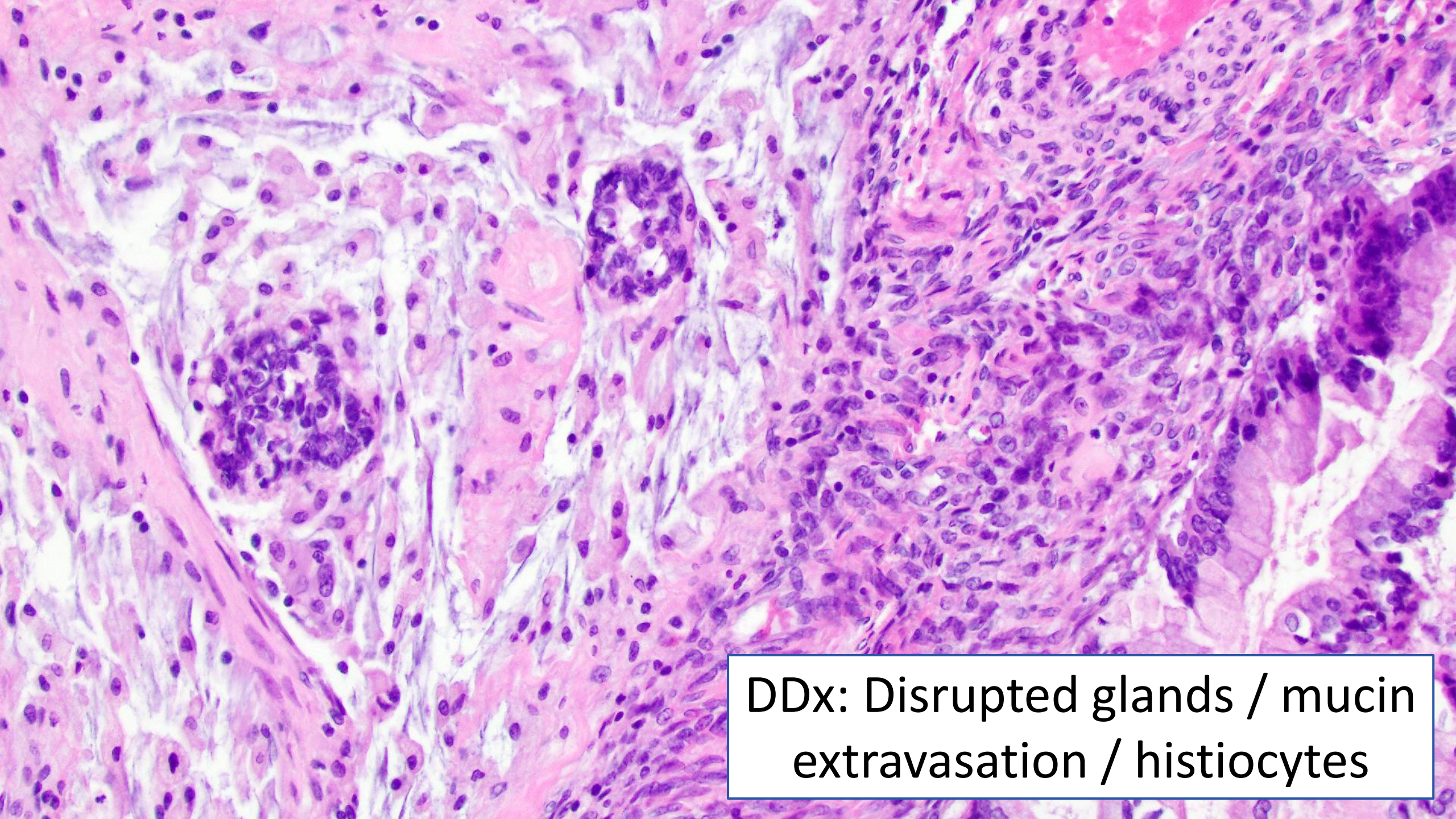
DDx: Disrupted glands / mucin extravasation / histiocytes

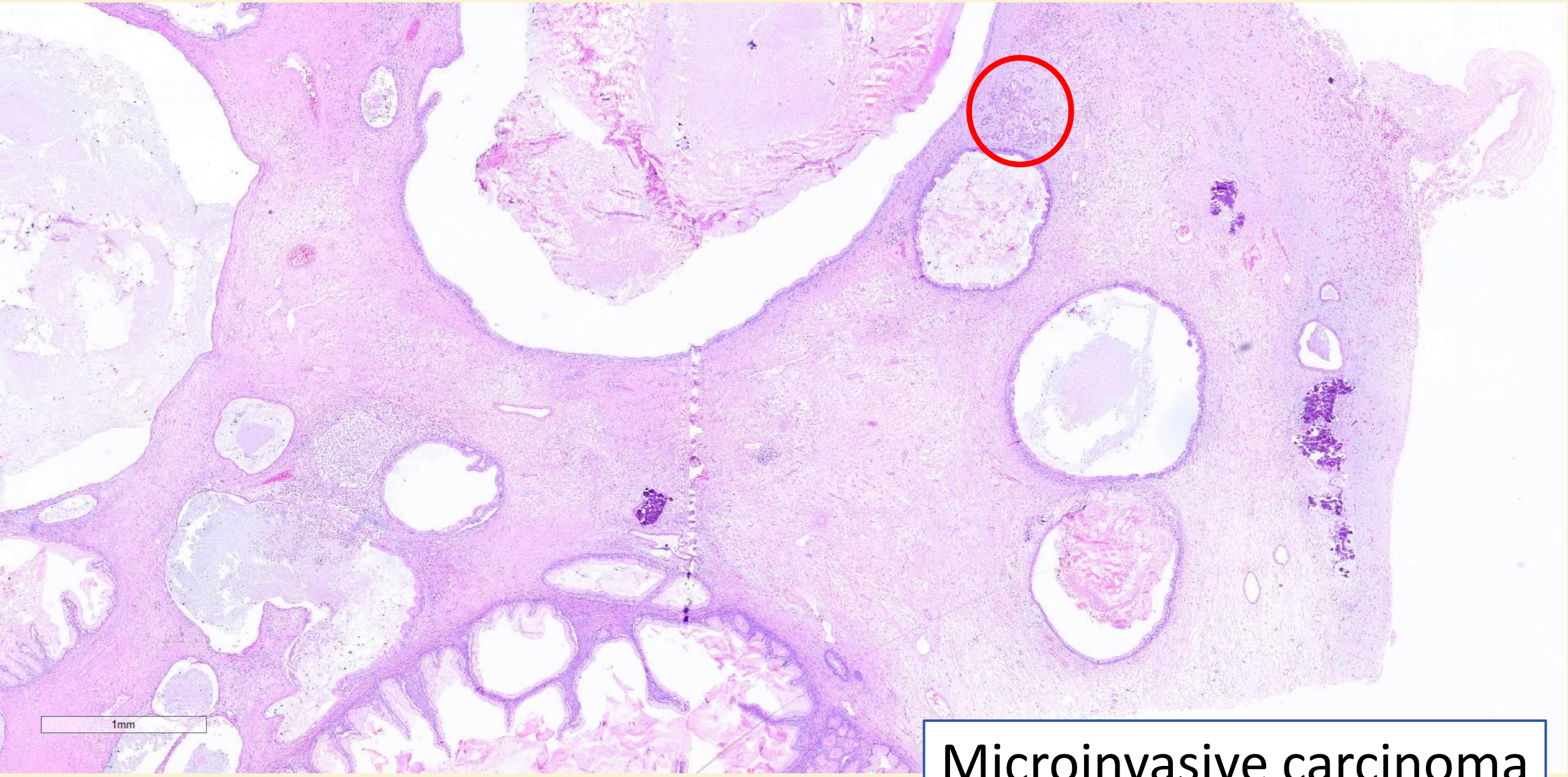

Microinvasive carcinoma

Microinvasion & Microinvasive CA in Mucinous tumors

- Microinvasion
  - *Should only consist of single / small clusters in a lacunae*
  - *Should not have desmoplasia*
- Microinvasive carcinoma
  - *The focus should measure less than 5mm*
  - *The invasive component should demonstrate nuclear atypia*
  - *Often with nested, papillary, glandular architecture*
  - *Often associated with nearby IEC*

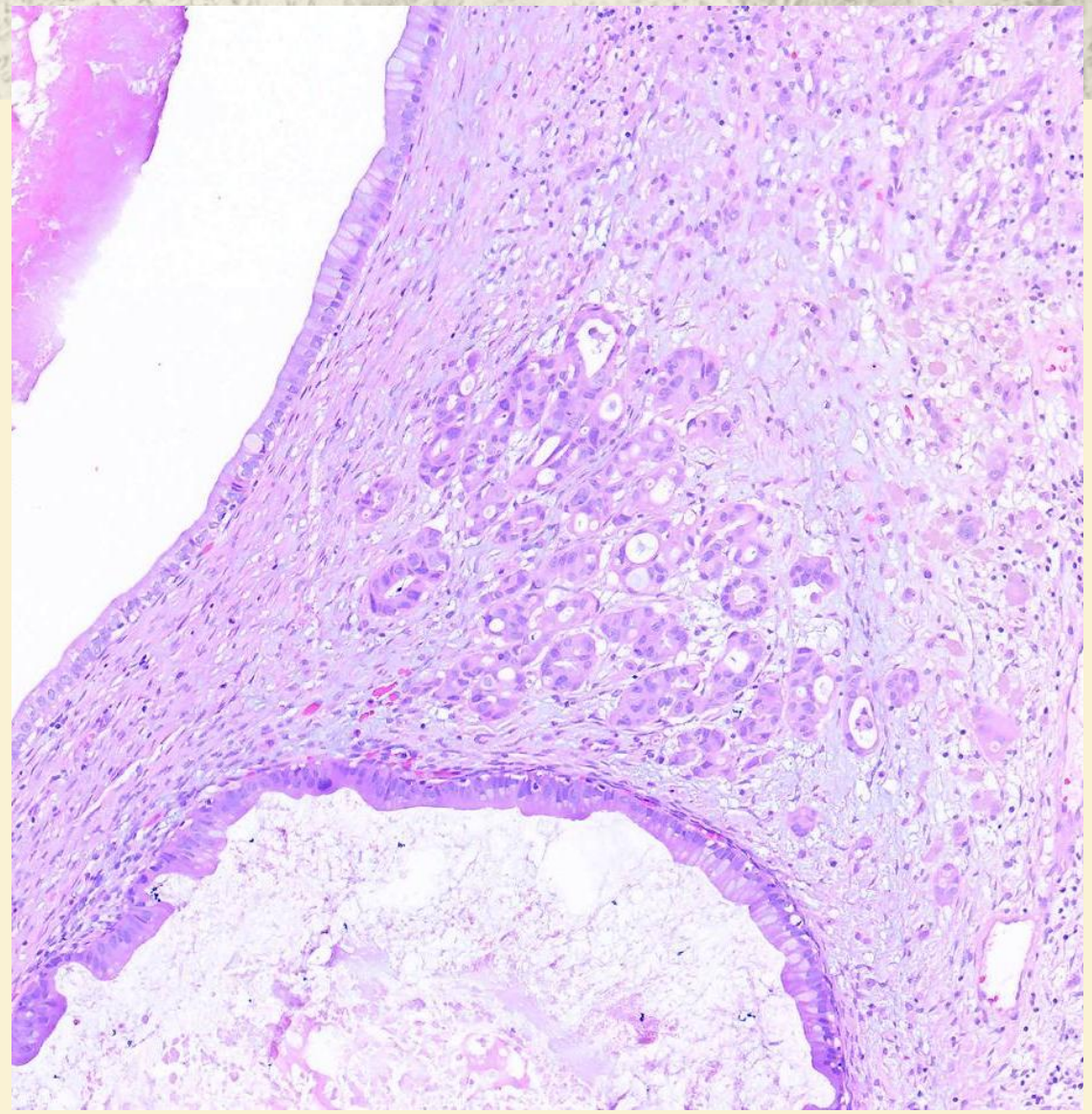

INTRAEPITHELIAL CA

- Mucinous borderline tumors show:
  - *Mild to moderate enlargement and hyperchromasia*
  - *Variable mitotic activity (bland to brisk)*
- Intraepithelial carcinoma:
  - *Severe nuclear atypia (noticeable at low power magnification)*
  - *Confined to the epithelium*
  - *Complex growth or mitotic activity are <u>not</u> a requirement*

J Gynecol Oncol 2013;24:44–51
Am J Surg Pathol 1999;23:617-35

The British Association of Gynaecological Pathologists

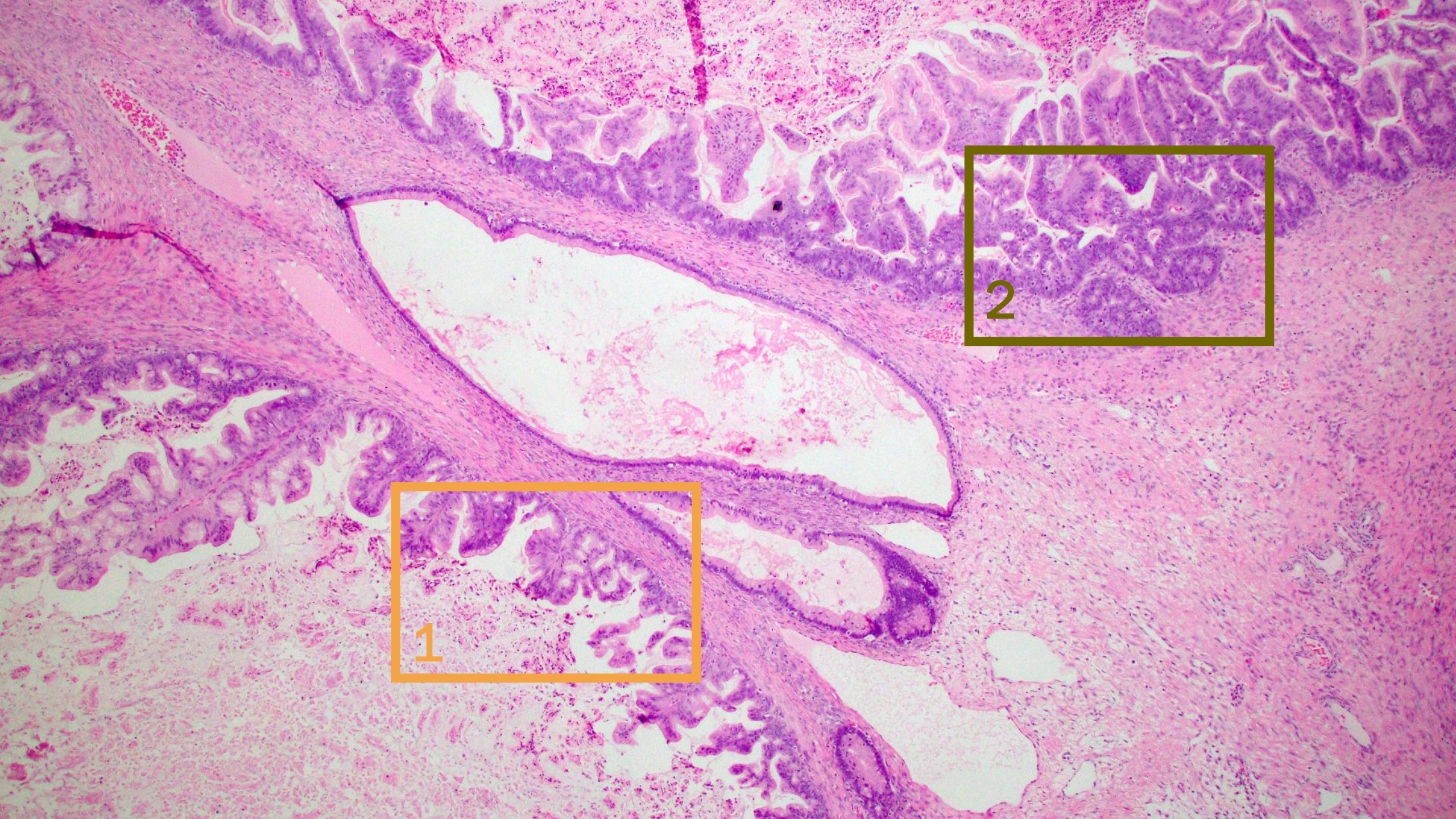
2
1

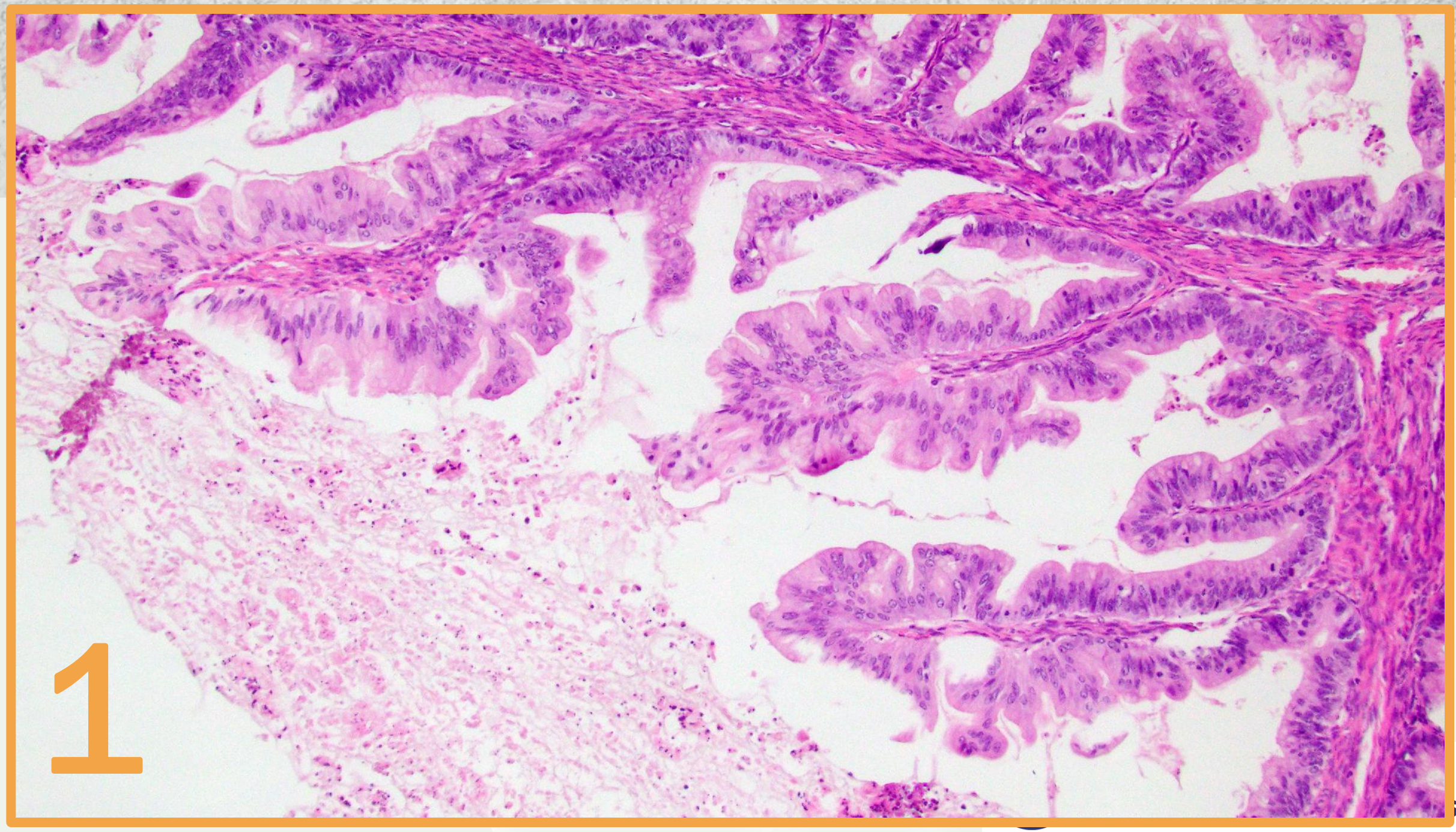
1

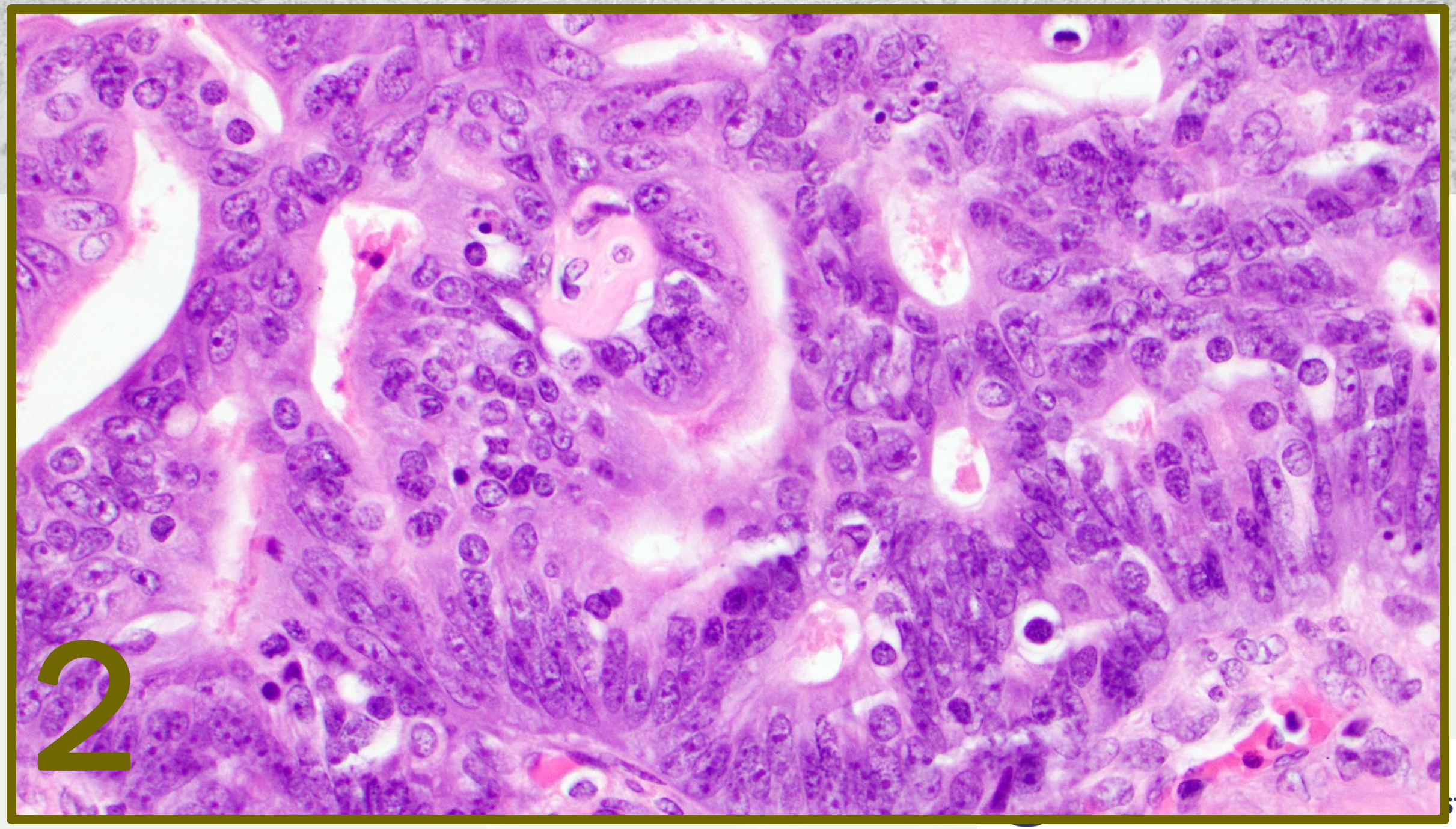
2

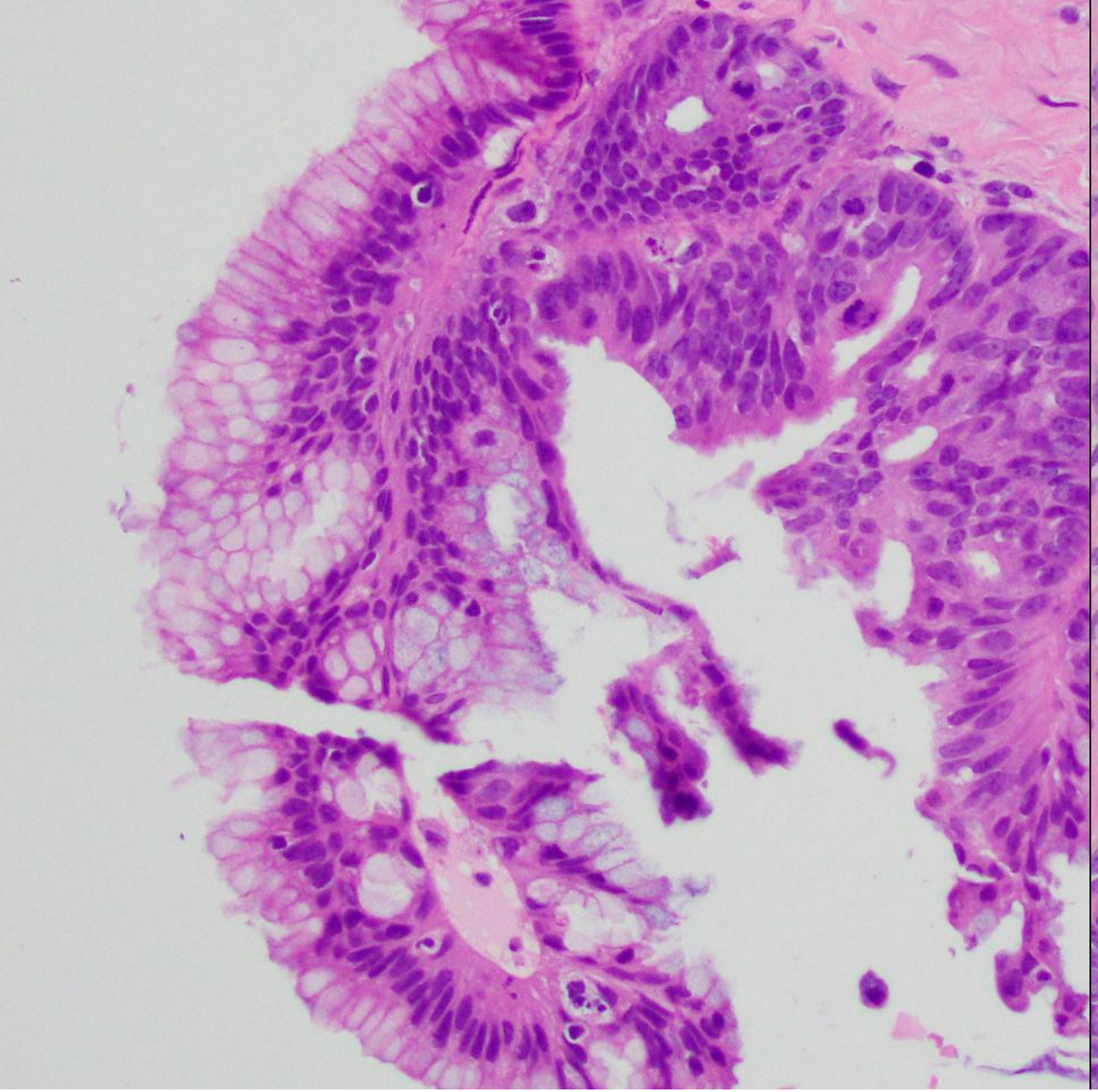

1+/2+ atypia = borderline

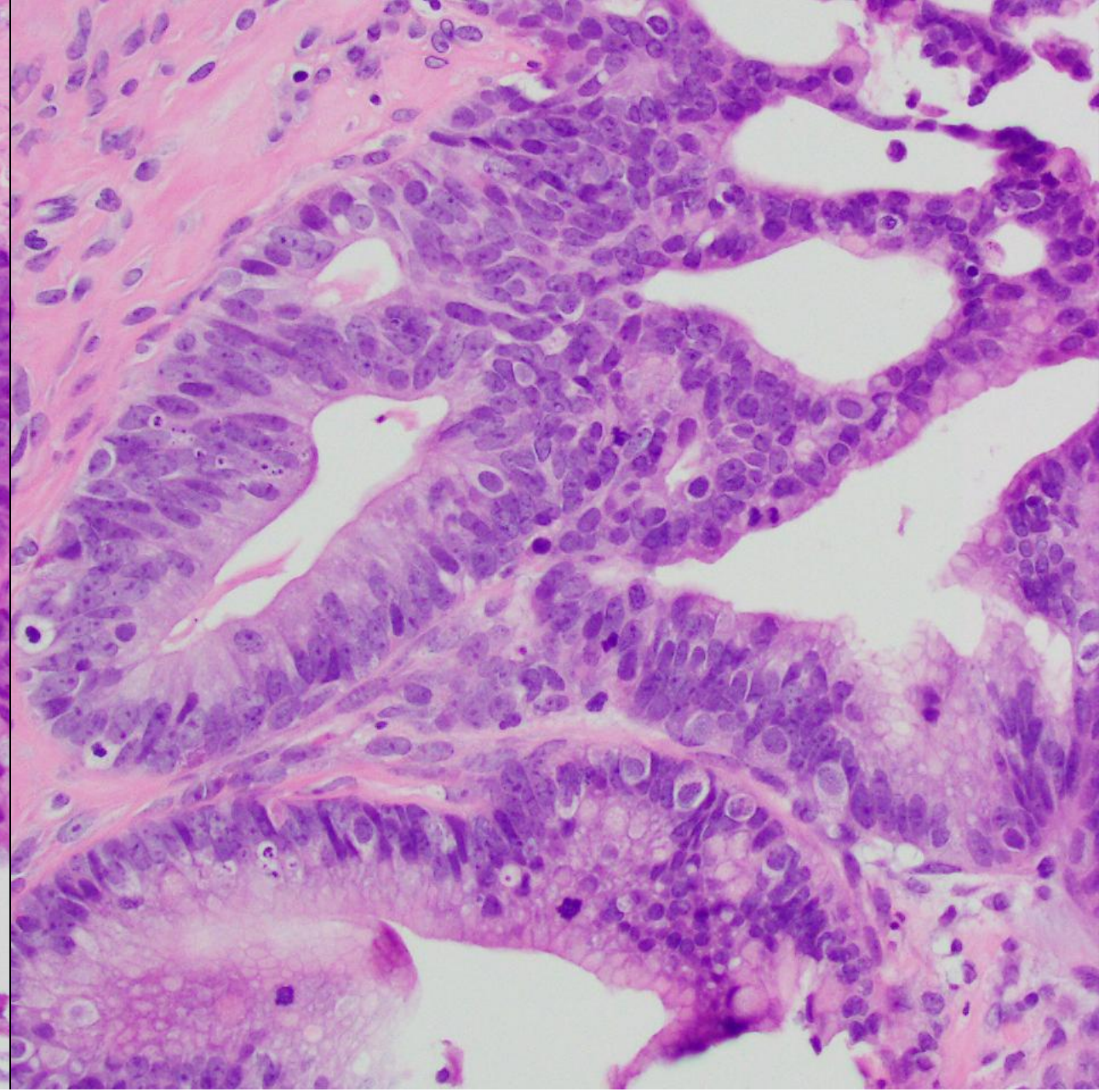

3+ atypia = intraepithelial CA

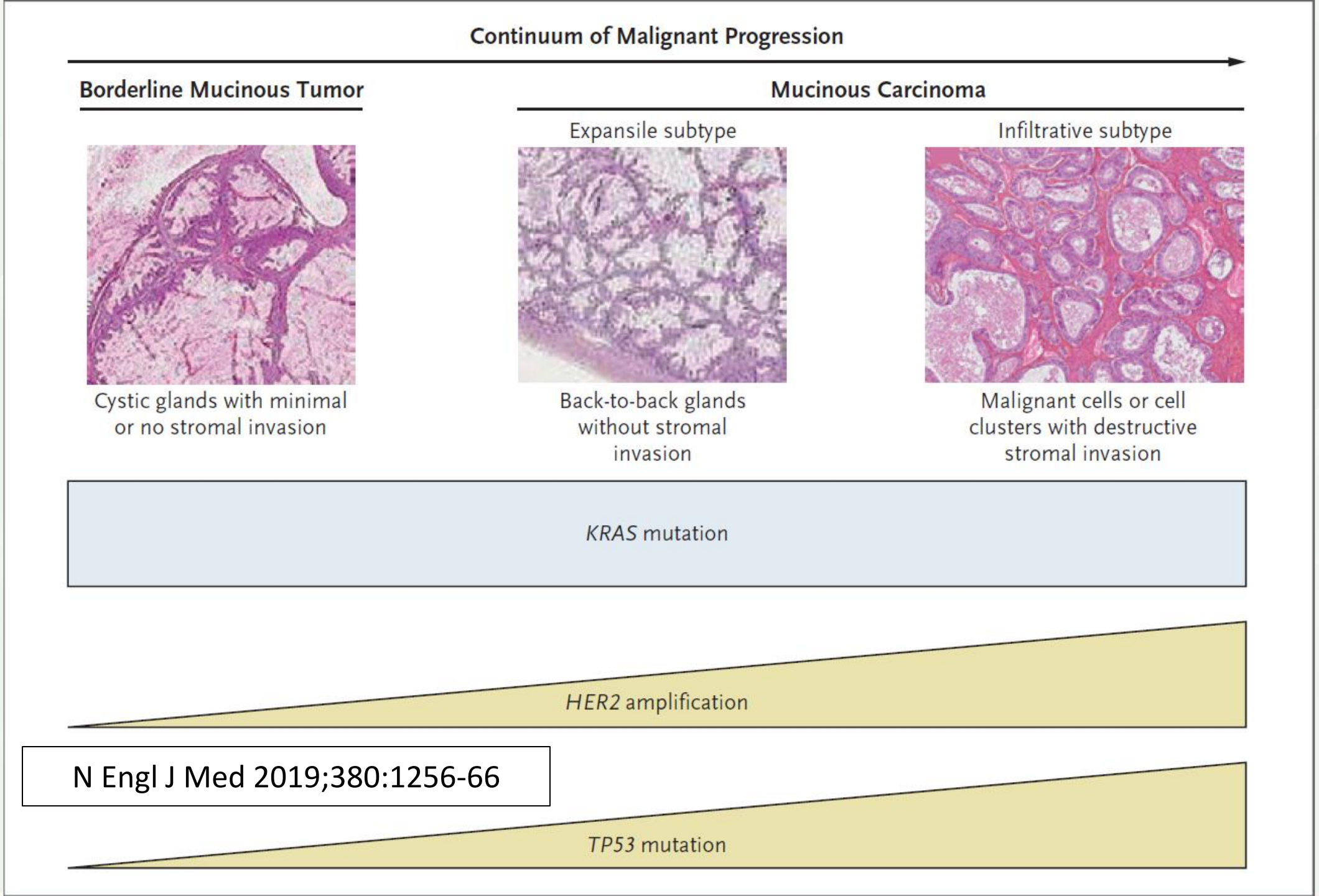

N Engl J Med 2019;380:1256-66

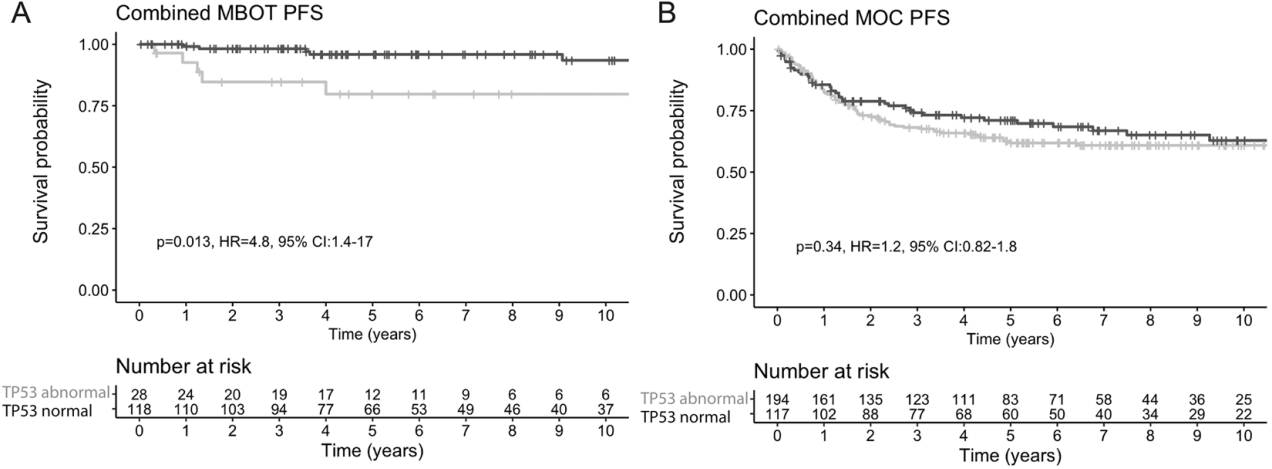

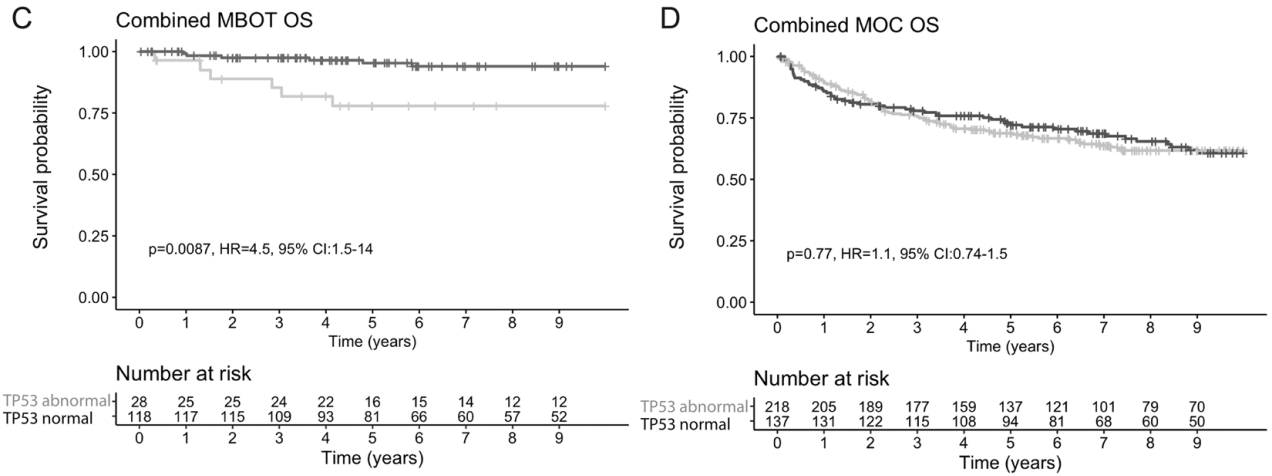

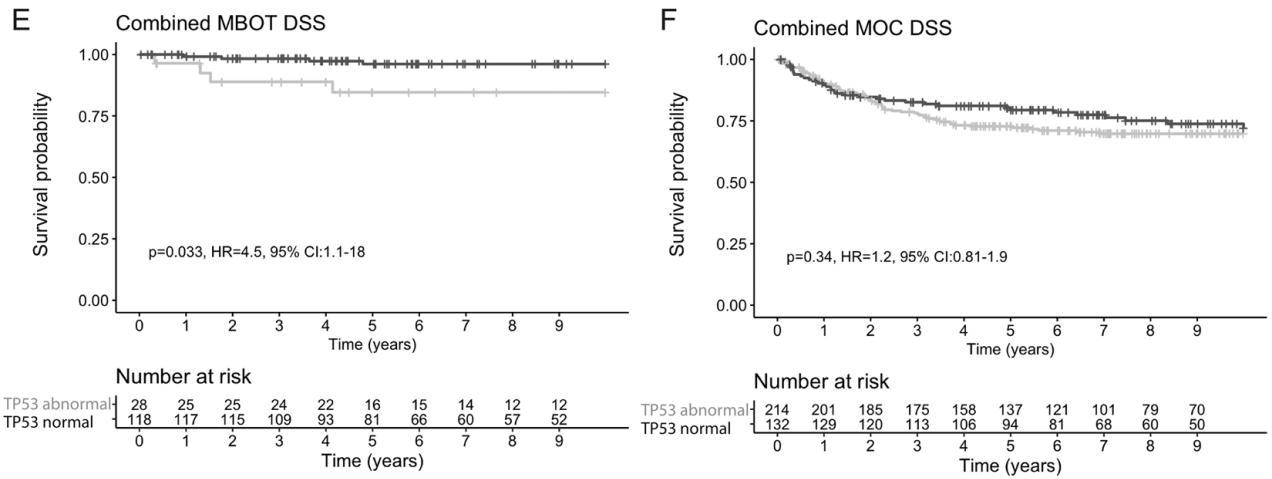

ANCILLARY TESTS

- At the moment, not validated for clinical use (MBT vs MCA, intraepithelial CA vs not)
- p53 IHC has high degree of correlation with *TP53* status
- p53mut in 20-33% MBT, 61-70% MCA
- p53 may have prognostic value in MBTs, but not in carcinomas

Int J Gynecol Pathol 2024;43:111-122
Mod Pathol 2021;34(1):194-206
Pathology 2023;55(6):785-791

The British Association of Gynaecological Pathologists

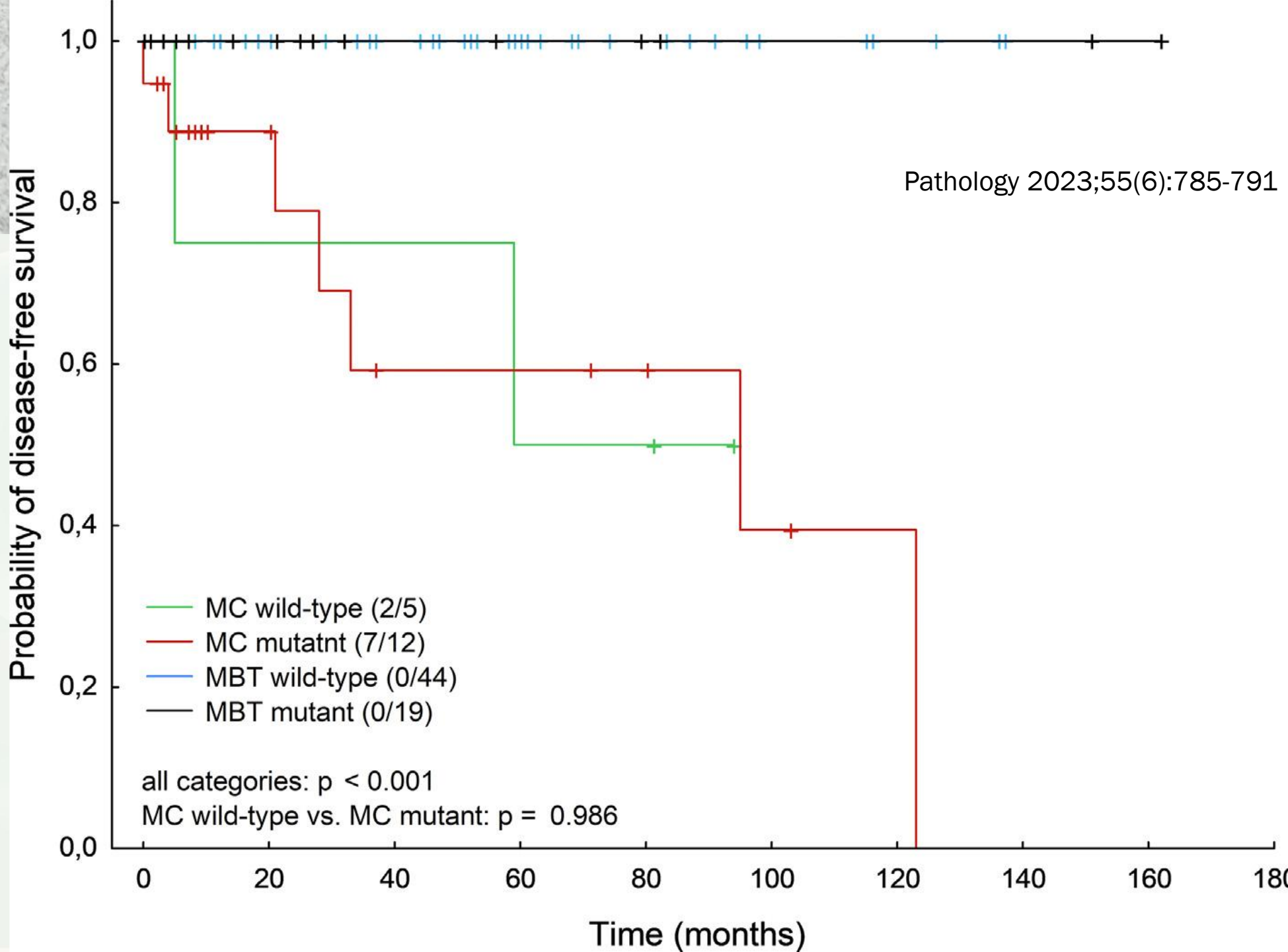

Pathology 2023;55(6):785-791

of Pathologists

Mod Pathol 2021;34(1):194-206

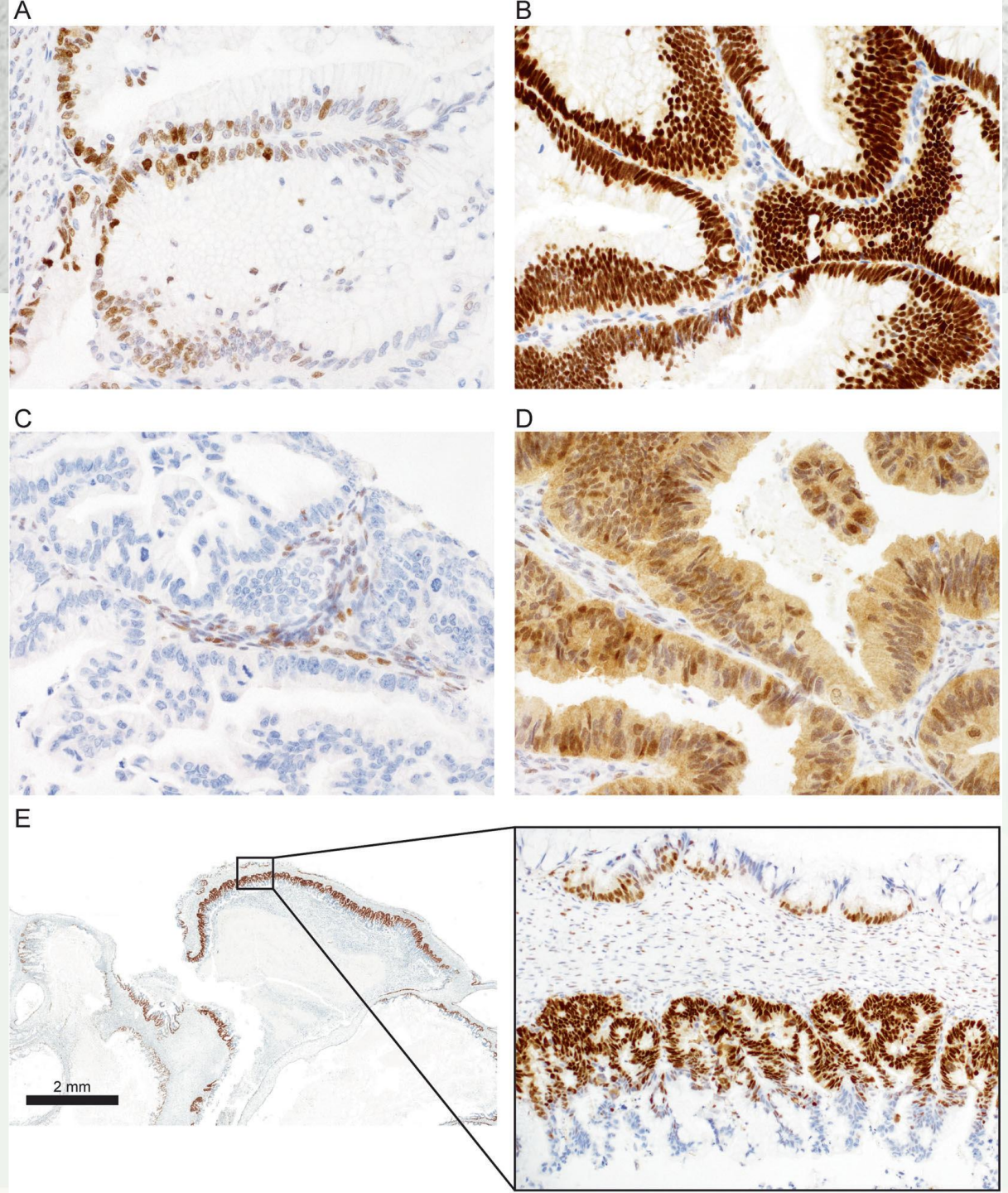

- p53 normal pattern
  - Wild type (heterogeneous)
- p53 abnormal patterns
  - Overexpression (strong nuclear positivity in at least 5% or 12 continuous tumor cells)
  - Null (absent expression)
  - Cytoplasmic
- Be aware of the “terminal differentiation” pattern (loss of staining in superficial layers)

The British Association of Gynaecological Pathologists

MODERN PATHOLOGY

USCAP UNITED STATES AND CANADIAN ACADEMY OF PATHOLOGY
Creating a Better Pathologist

Journal homepage: https://modernpathology.org/

Research Article

Primary Mucinous Tumors of the Ovary: An Interobserver Reproducibility and Detailed Molecular Study Reveals Significant Overlap Between Diagnostic Categories

Pavel Dundr[a,*], Michaela Bártů[a], Tjalling Bosse[b], Quang Hiep Bui[a], David Cibula[c], Jana Drozenová[d], Pavel Fabian[e], Oluwole Fadare[f], Jitka Hausnerová[g], Jan Hojný[a], Nikola Hájková[a], Radek Jakša[a], Jan Laco[h], Sigurd F. Lax[i,j], Radoslav Matěj[a,d,k], Gábor Méhes[l], Romana Michálková[a], Adam Šafanda[a], Kristýna Němejcová[a], Naveena Singh[m,n], Simona Stolnicu[o], Marián Švajdler[p], Tomáš Zima[q], Ivana Stružinská[a], W. Glenn McCluggage[r]

Mod Pathol 2023;36:100040

Table 1
Interobserver agreement of the diagnoses

Groups	Diagnosis	No. of cases	κ	SE	95% CI	*z*	*P* value	Result
Among all pathologists (14 observers)	All diagnoses: 2 categories[a]	124	0.445	0.008	0.416-0.448	52.1	<.001	Moderate agreement
	All diagnoses: 3 categories[b]	124	0.436	0.009	0.418-.0428	52.3	<.001	Moderate agreement
	MBT: 5 categories[c]	75	0.096	0.007	0.077-0.104	14.3	<.001	Slight agreement
	MBT: 2 categories[d]	75	0.075	0.006	0.072-0.101	8.1	<.001	Slight agreement
	MC: 5 categories[e]	34	0.287	0.012	0.321-0.368	30.4	<.001	Fair agreement
	MC: 3 categories[f]	34	0.330	0.017	0.358-0.426	26.2	<.001	Fair agreement
Among all pathologists, except for 1 (13 observers)[g]	All diagnoses: 2 categories[a]	124	0.534	0.016	0.420-.0435	58.2	<.001	Moderate agreement
	All diagnoses: 3 categories[b]	124	0.524	0.017	0.418-0.442	57.8	<.001	Moderate agreement
	MBT: 5 categories[c]	75	0.122	0.007	0.104-0.133	16.8	<.001	Slight agreement
	MBT: 2 categories[d]	75	0.109	0.007	0.102-0.125	10.8	<.001	Slight agreement
	MC: 5 categories[e]	34	0.330	0.013	0.368-0.420	32.4	<.001	Fair agreement
	MC: 3 categories[f]	34	0.387	0.019	0.417-0.493	27.9	<.001	Fair agreement

TP53 as a Diagnostic Aid in the Distinction of Ovarian Mucinous Borderline Tumors From Mucinous Carcinoma

Eun Young Kang, M.D., Tatjana Terzic, M.D., Prafull Ghatage, M.D., Lawrence Woo, M.D., Kylie L. Gorringe, Ph.D., Anthony N. Karnezis, M.D., Ph.D., Cheng H. Lee, M.D., Ph.D., and Martin Köbel, M.D.

Int J Gynecol Pathol 2024;43:111-122

TABLE 1. *Interobserver agreement among the 3 study pathologists on the diagnosis of ovarian mucinous neoplasms in the cohort as MBTs, borderline tumors with IEC, or ovarian MCs*

	Round 1		Round 2		
	κ coefficient	Agreement (%)	κ coefficient	Agreement (%)	P^*
Trinary					
SP 1 vs. 2	0.573	76.5	0.742	85.9	0.0042
SP 1 vs. 3	0.723	87.1	0.861	92.9	
SP 2 vs. 3	0.500	74.1	0.691	83.5	
Average	0.600	79.2	0.760	87.4	
Binary					
SP 1 vs. 2	0.677	87.1	0.808	91.8	0.0147
SP 1 vs. 3	0.822	92.9	0.892	95.3	
SP 2 vs. 3	0.658	87.1	0.758	89.4	
Average	0.720	89.0	0.820	92.2	

Trinary categorization was MBT versus MBT with IEC versus MC, and binary categorization was MBT versus MC. Round 1 involved only morphologic review, while round 2 was performed with integration of TP53 immunohistochemistry.
*t-test comparing κ coefficient.
IEC indicates intraepithelial carcinoma; MBT, mucinous borderline tumor; MC, mucinous carcinoma; SP, study pathologist.

TABLE 2. *Clinicopathologic characteristics of ovarian MBTs, ovarian MBTs with IEC, and ovarian MCs; majority diagnosis after TP53 IHC*

Int J Gynecol Pathol 2024;43:111-122

Parameters	MBT (N = 52)	MBT with IEC (N = 6)	MC (N = 27)	*P*
Age, mean (range) (yr)	52 (23–84)	60.5 (34–74)	51.3 (23–82)	0.4*
Tumor size, mean (range) (cm)	20.6 (6–41)	13.2 (6.5–26)	22.6 (12–42)	0.033*
LN dissection performed	24	3	14	
# of LNs dissected, mean (range)	8.7 (1–18)	7.3 (5–12)	9.6 (1–28)	0.74†
# of LNs positive, mean (range)	0	0	0	0.018†
Stage				
IA	42	5	15	
IC1	3	0	2	
IC2	7	0	5	
IC3	0	1	0	
IIA	0	0	1	
III	0	0	3	
IV	0	0	1	
Microinvasion (present)	3	2	NA	
Mural nodule (pseudosarcomatous)	0	1	1	
Teratoma-associated	2	0	1	
Pattern of invasion				
Confluent	NA	NA	23	
Destructive	NA	NA	5	
TP53 IHC				
Normal	42	0	4	<0.0001†
Abnormal	10	6	23	
Distribution of abnormal OE, mean (95% CI)	11.0 (0–29.6)	52 (28.5–75.5)	60 (47.6–72.4)	0.0004*
5-yr survival rate (% SE)	100	80	78.4	0.0046‡
Follow-up time for censored cases, median (95% CI) (mo)	47.9 (44.3–54.0)	49.1 (9.3–79.9)	53.7 (40.2–57.5)	

OVARIAN MUCINOUS CARCINOMA

- Stromal invasion ≥5 mm
  - *Expansile*
    - Glandular confluence (back-to-back glands)
    - Cribriform growth
    - I use the same I approach I would use for *EIN / atypical hyperplasia vs endometrioid carcinoma*

Am J Surg Pathol 2000;24:1447–1464
Mod Pathol 2005;18:903-11
Histopathology 2020;77:26–34

The British Association of Gynaecological Pathologists

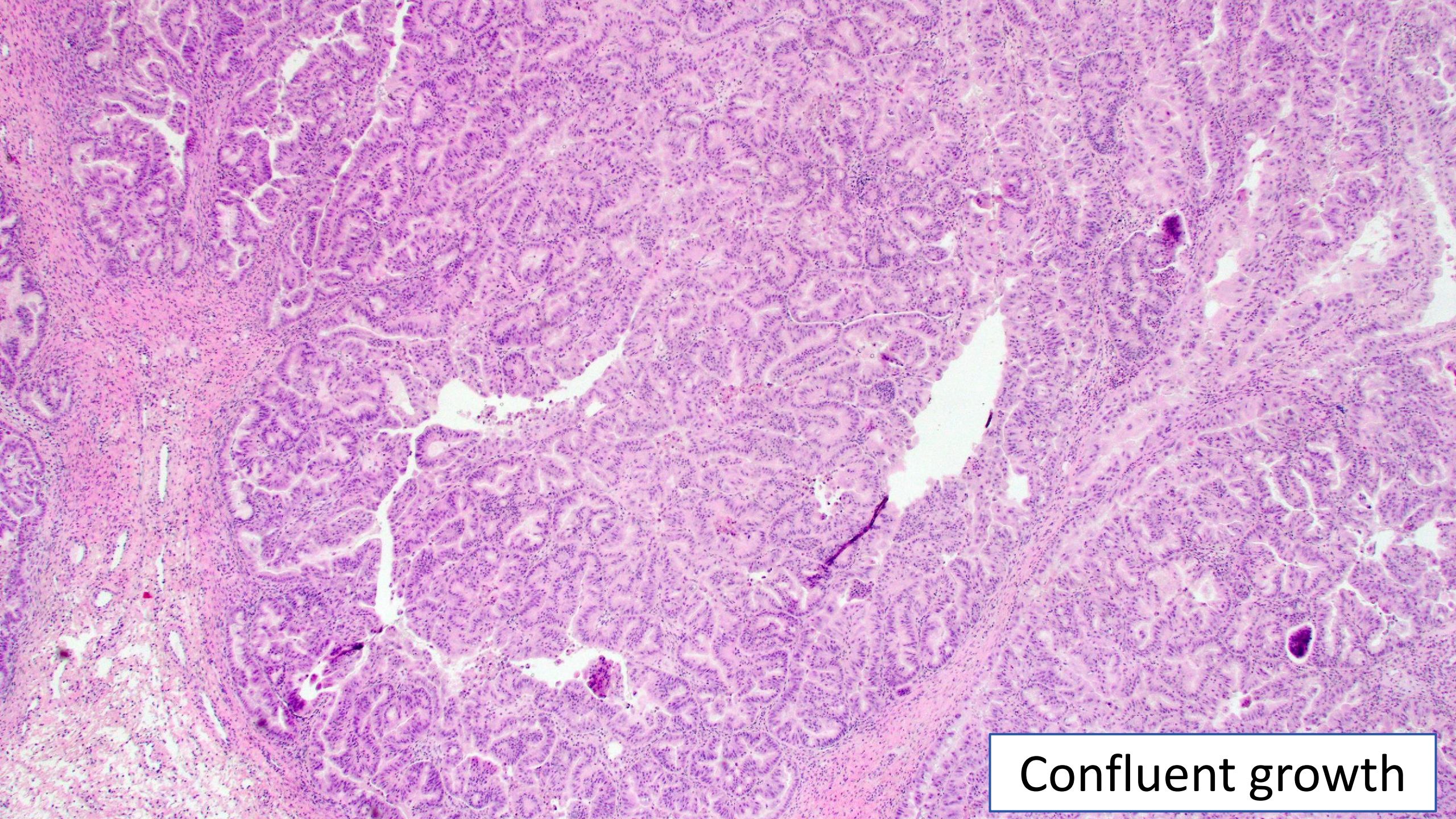
Confluent growth

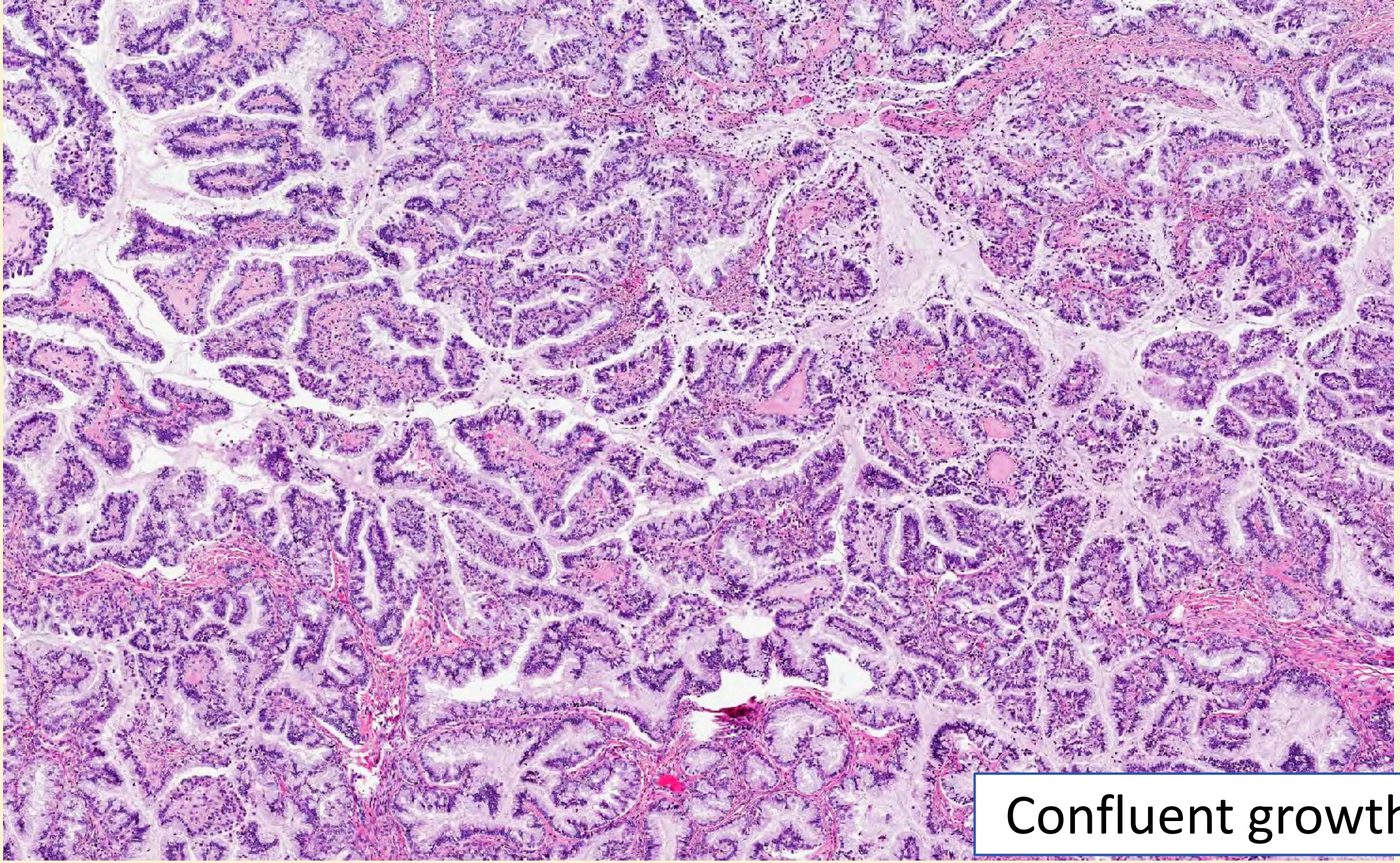
Confluent growth

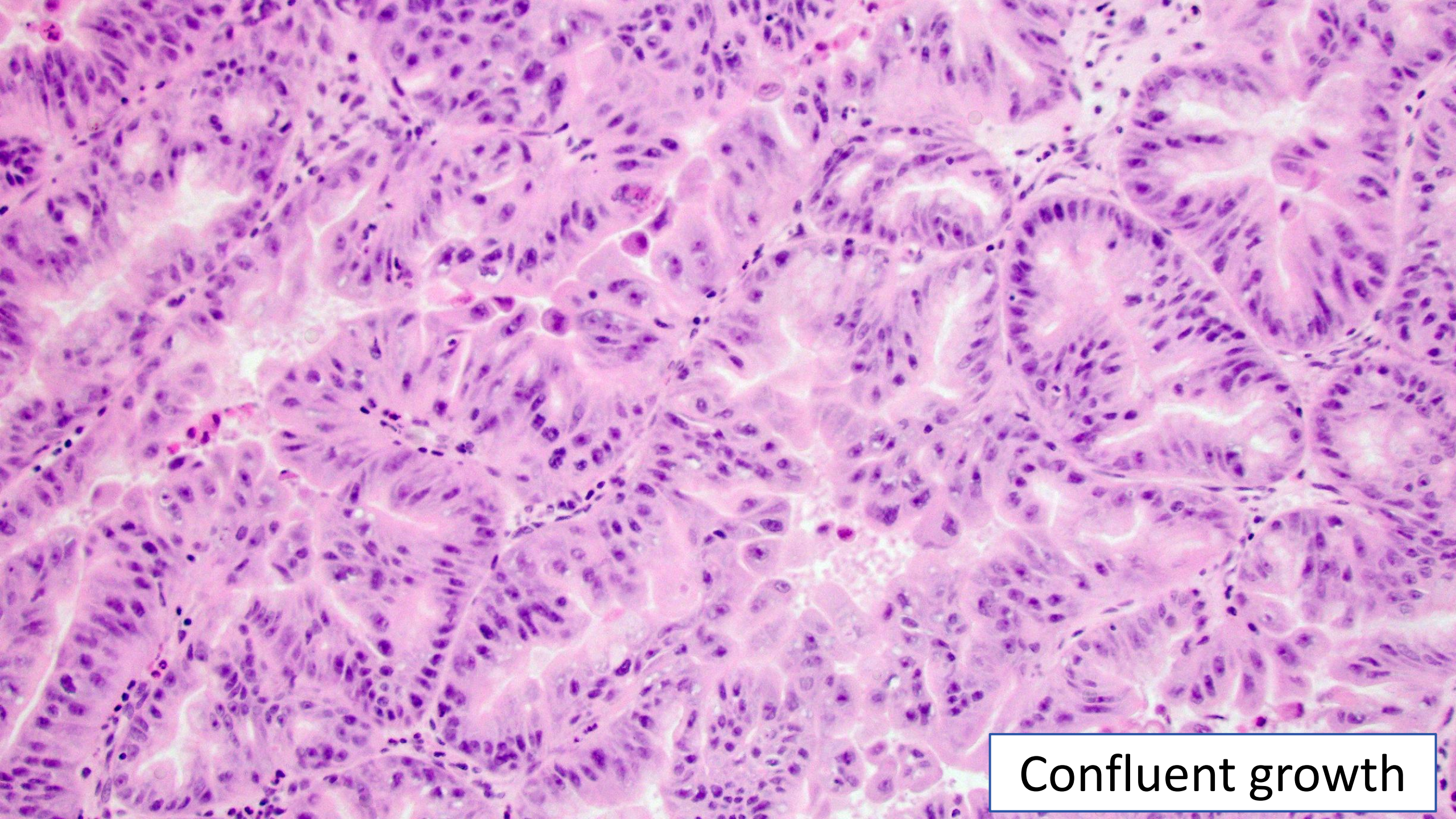
Confluent growth

OVARIAN MUCINOUS CARCINOMA

- Stromal invasion ≥5 mm
  - *Infiltrative*
    - Irregular / angulated glands
    - Desmoplastic stromal reaction
    - Single cells or cell clusters
    - Lymphovascular space invasion

Am J Surg Pathol 2000;24:1447–1464
Mod Pathol 2005;18:903-11
Histopathology 2020;77:26–34

The British Association of Gynaecological Pathologists

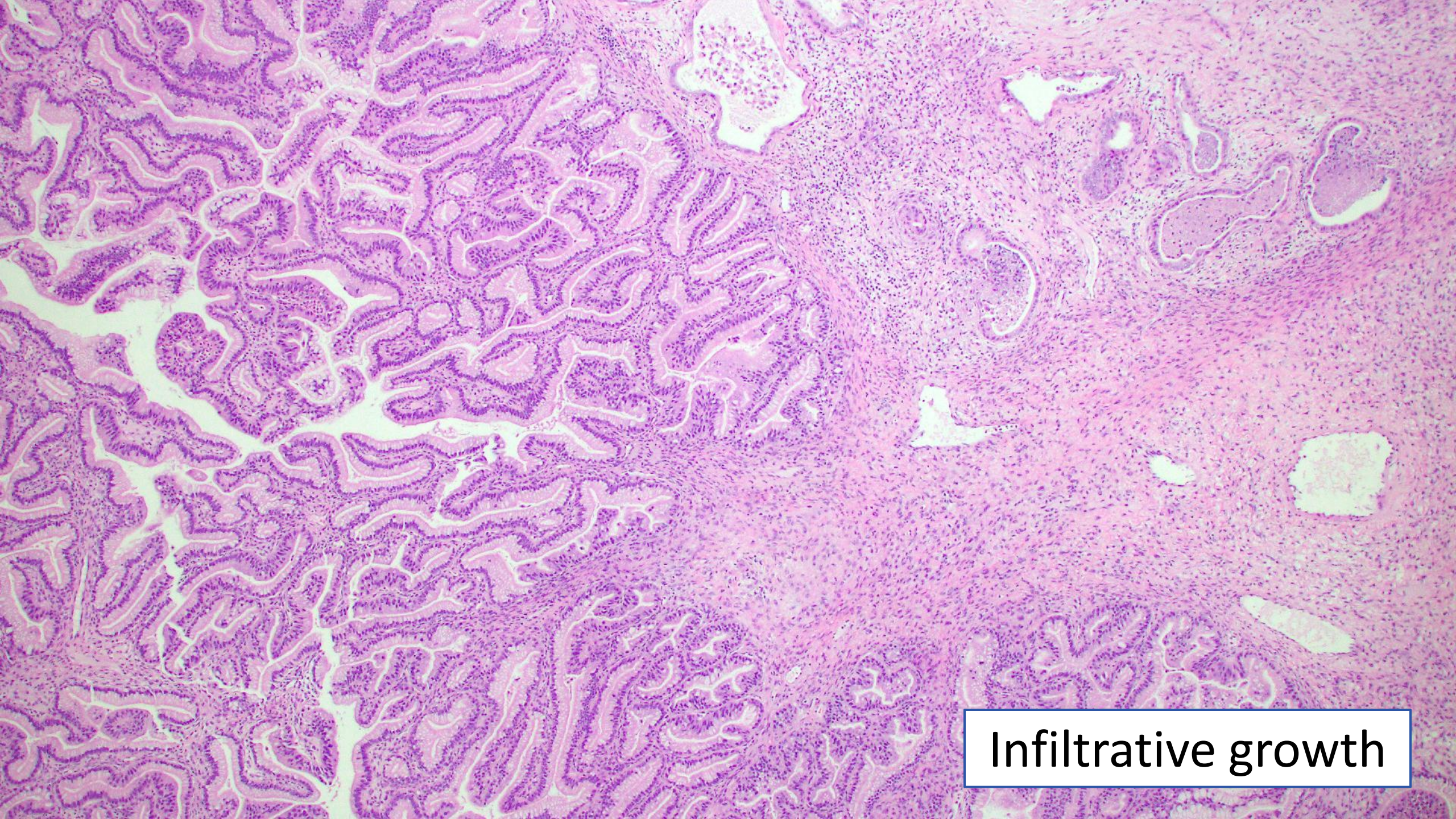
Infiltrative growth

Infiltrative growth

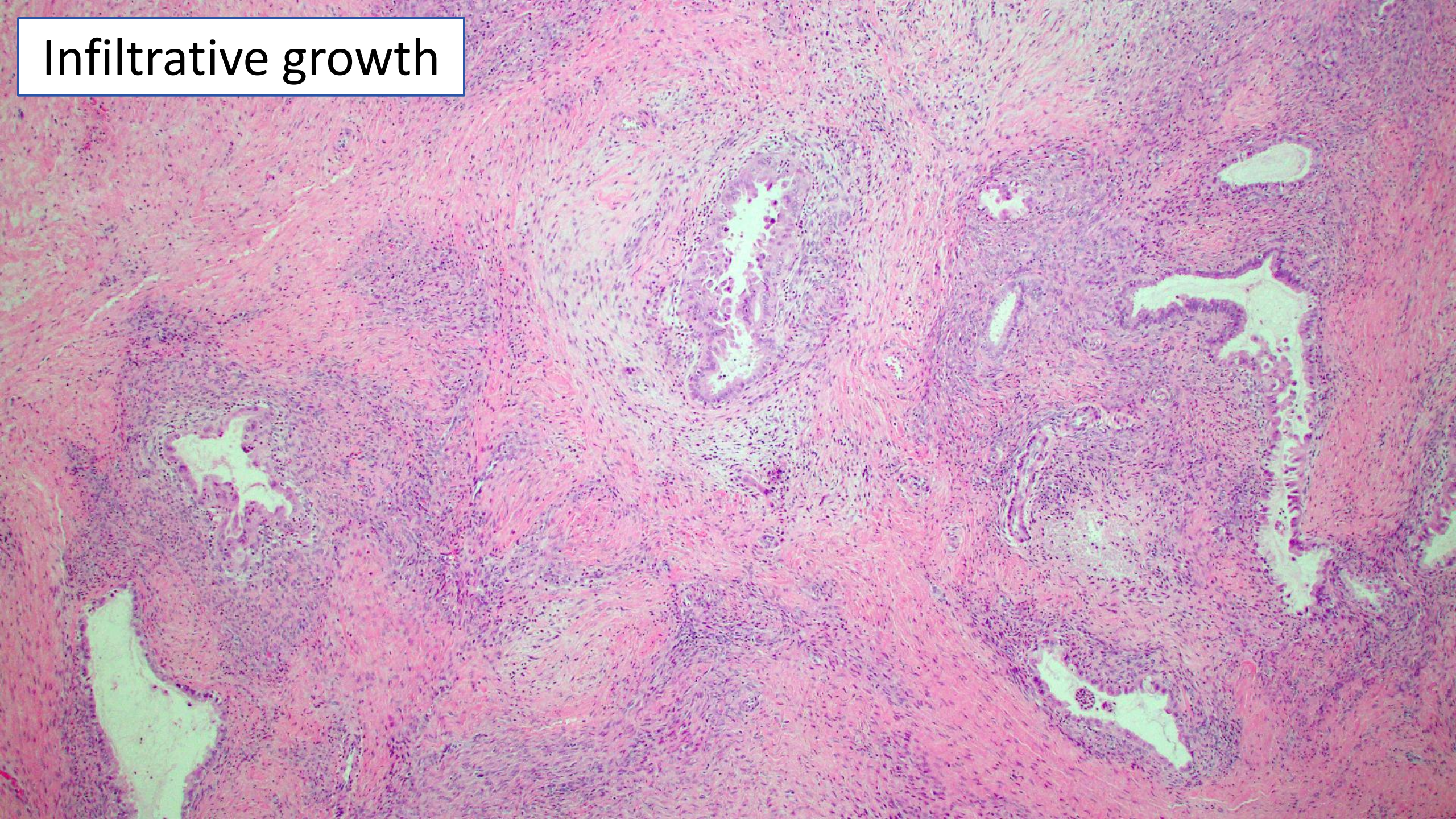

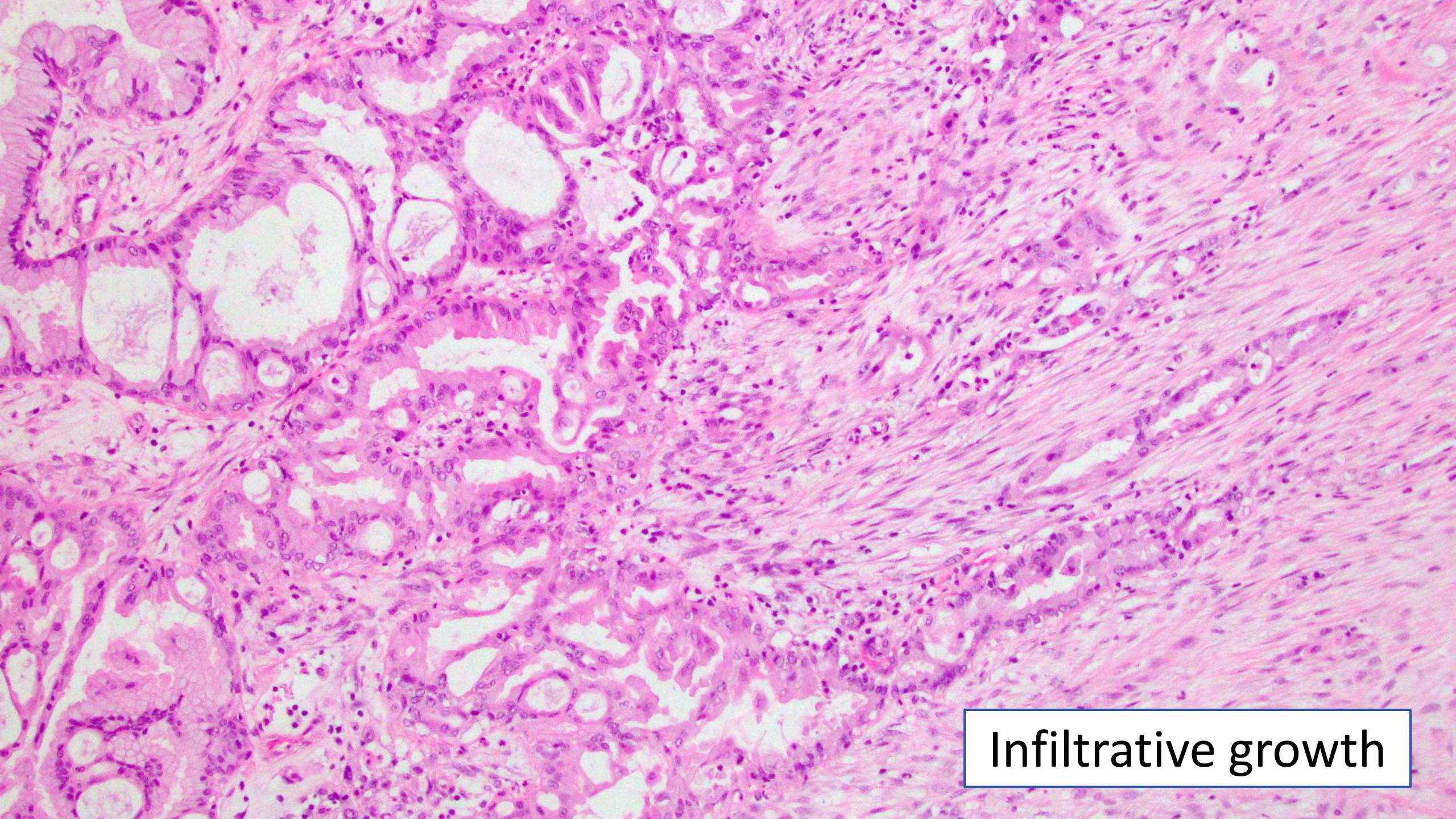
Infiltrative growth

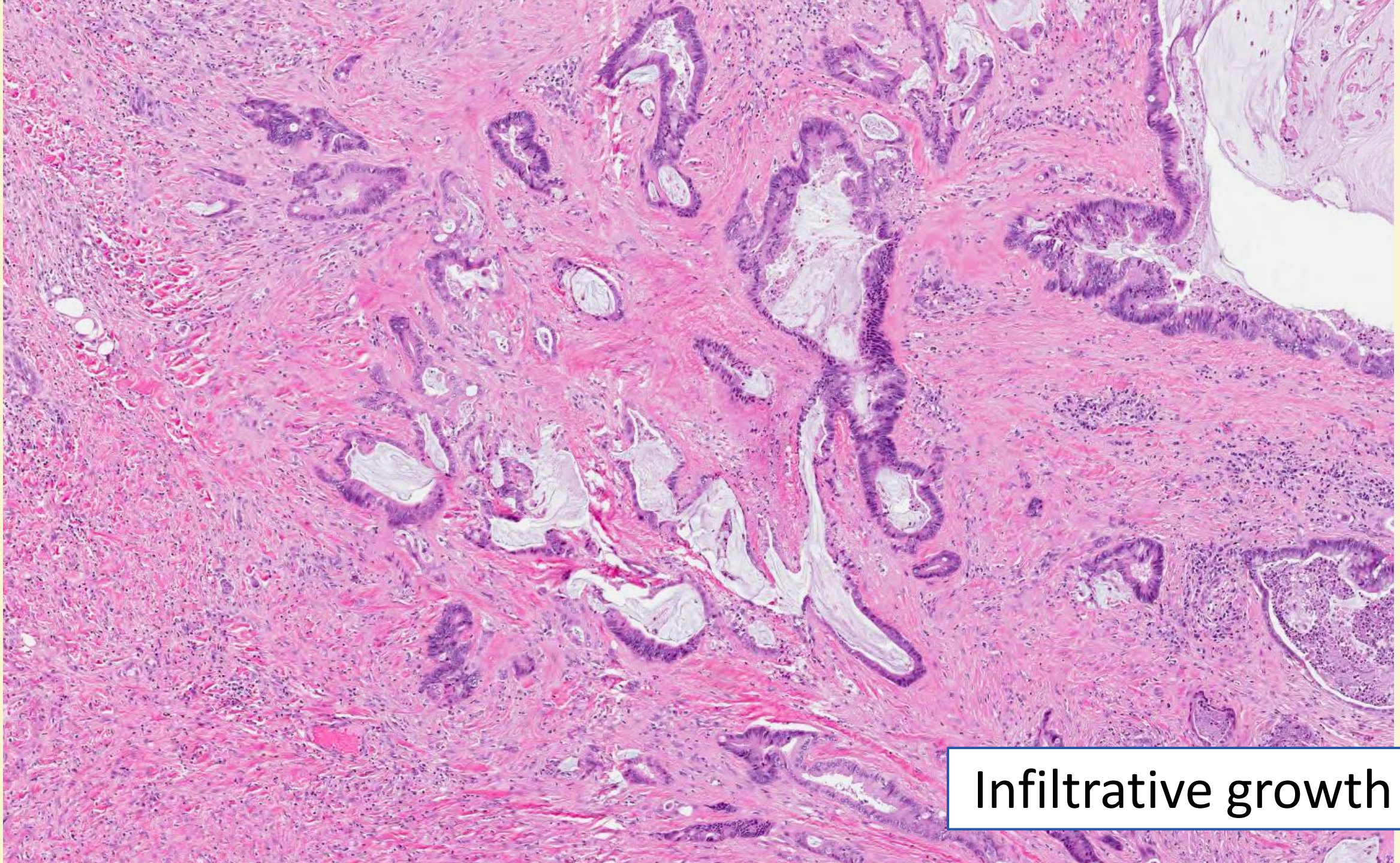
Infiltrative growth

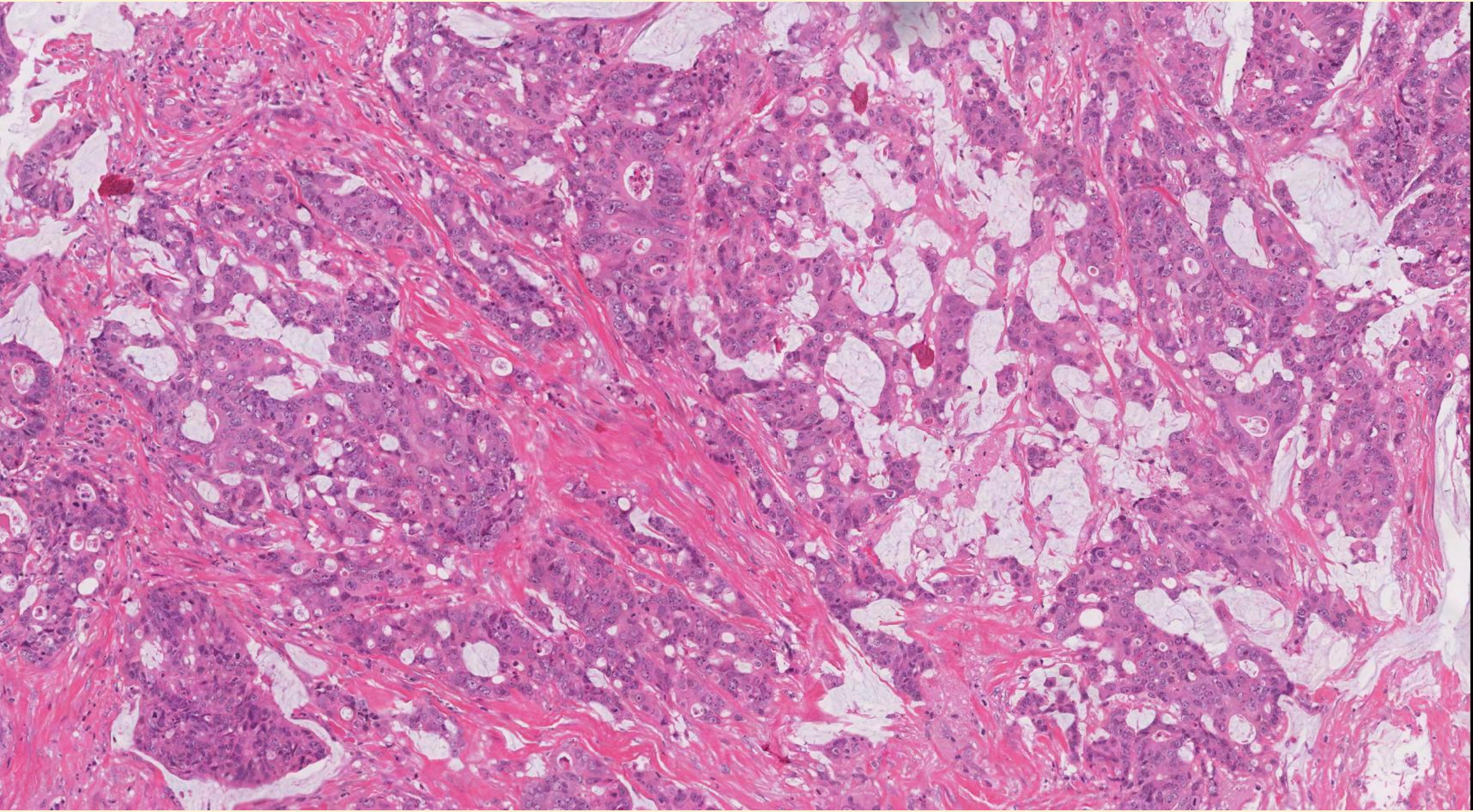

OVARIAN MUCINOUS CARCINOMA

- Infiltrative growth is associated with worse prognosis
  - *Lymph node metastases*
  - *Local recurrence & metastases*
  - *Disease-specific survival*
- Even in FIGO stage IA tumors

Mod Pathol 2005;18:903–911
Int J Gynecol Pathol 2005;24:205–217
Eur J Cancer 2013;49:1600–1608
Int J Gynecol Cancer 2018;28:493–499
Histopathology 2020;77:26–34

The British Association of Gynaecological Pathologists

Cancer-specific survival (A-D)

Histopathology 2024;84:1095–1110

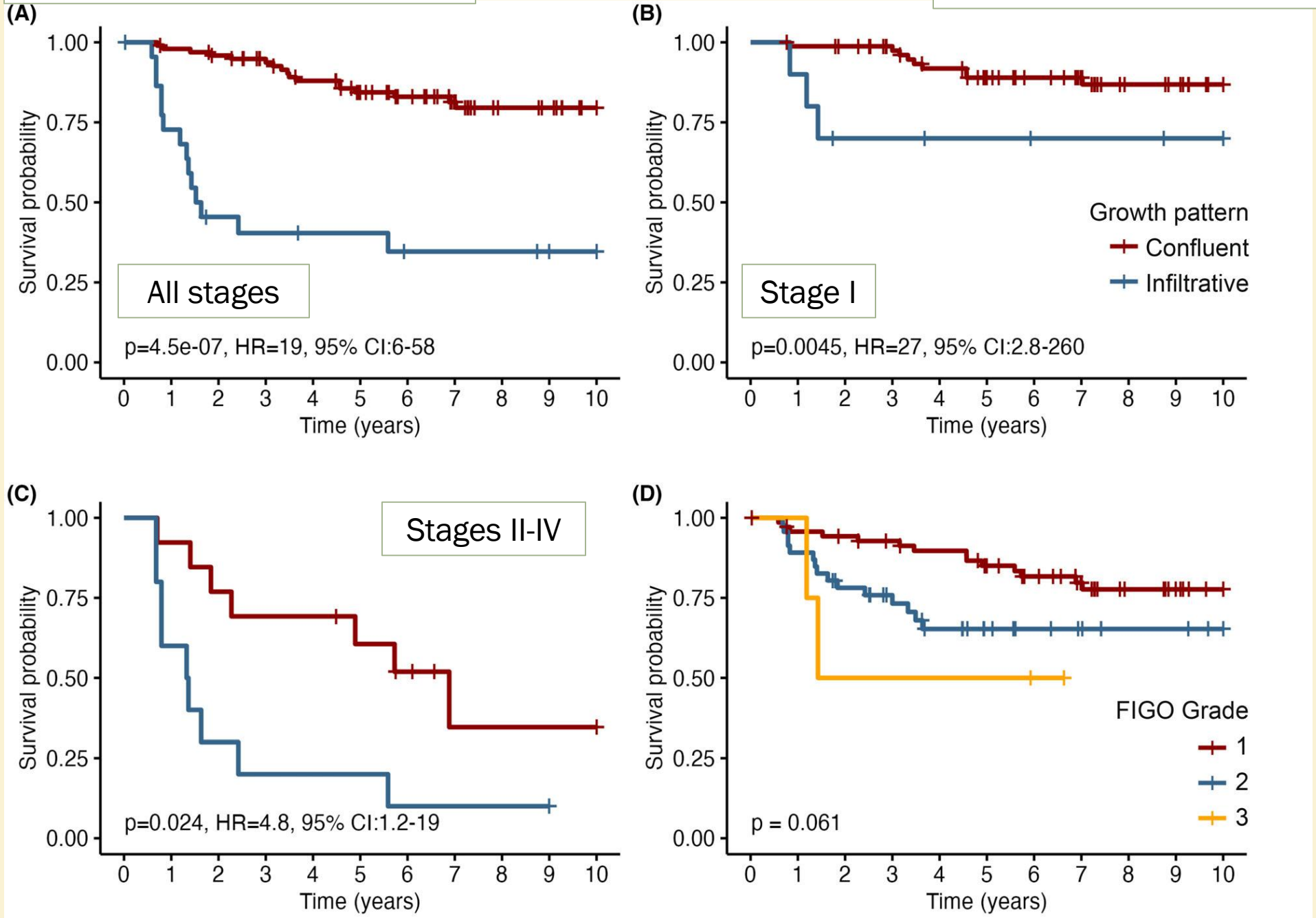

Grading based on the % of infiltrative / destructive growth pattern

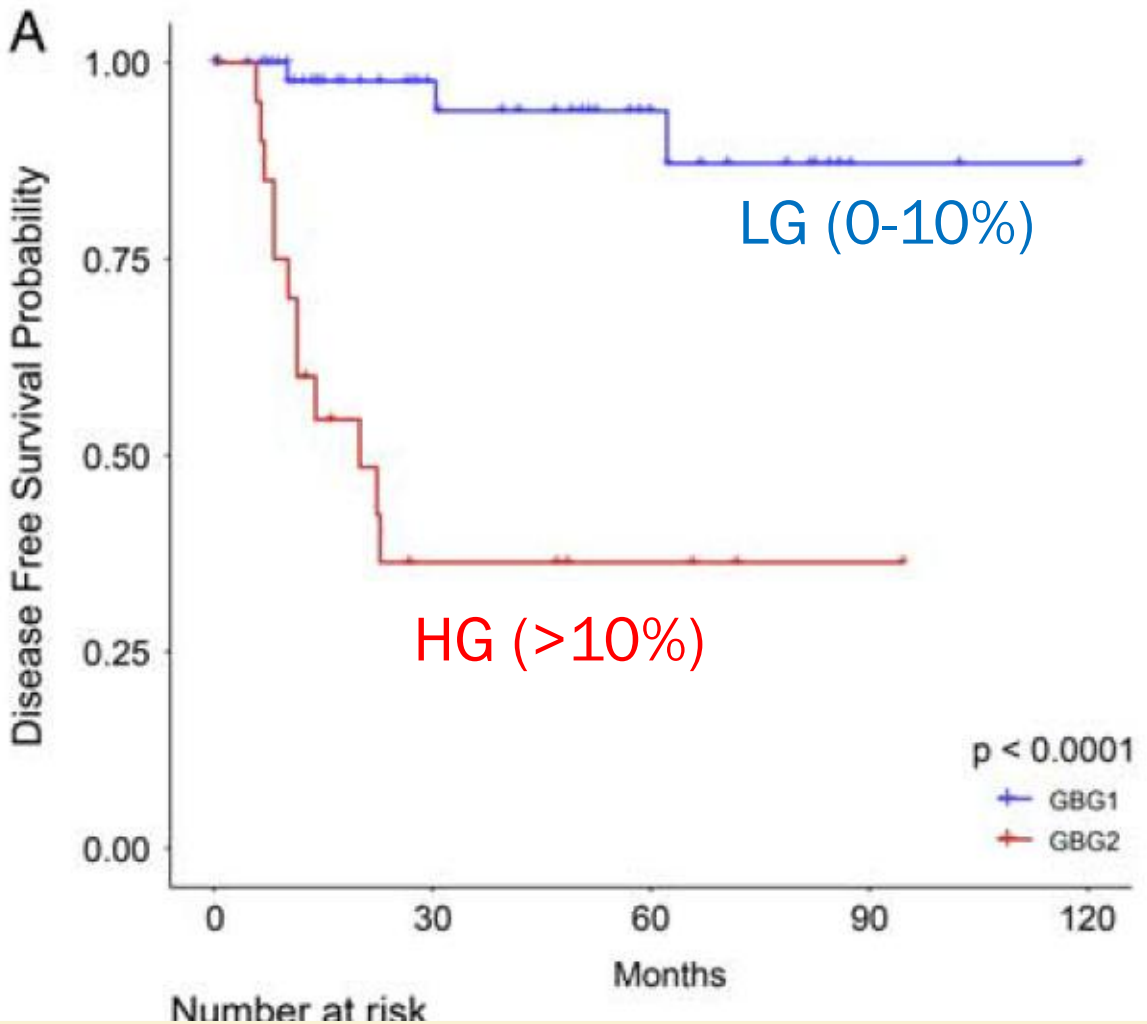

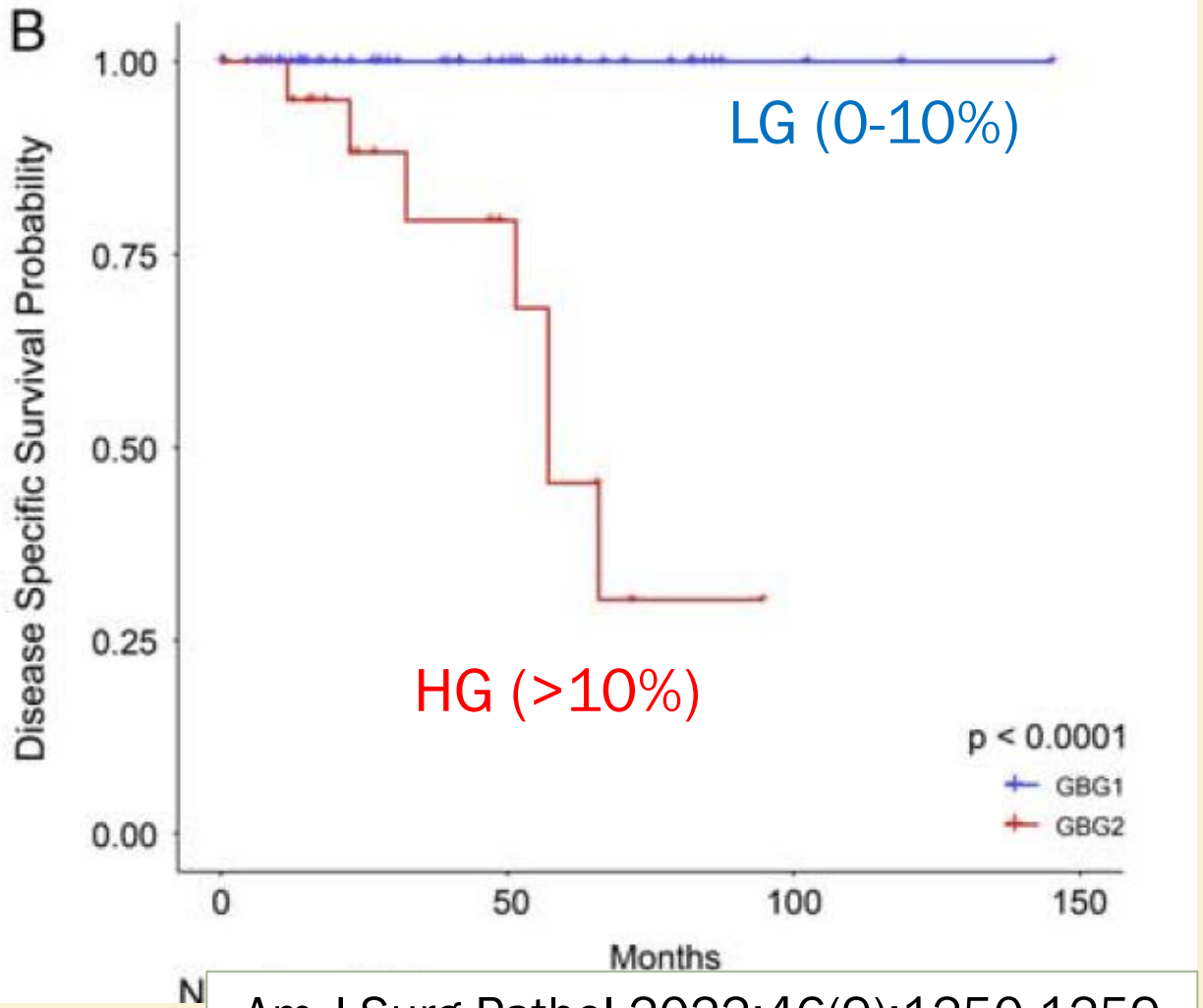

Am J Surg Pathol 2022;46(9):1250-1259

OVARIAN MUCINOUS CARCINOMA

- Growth pattern - **DEFINITIONS**
  - *Infiltrative: Destructive growth >1 mm or >10% of carcinoma volume*
  - *Confluent: Destructive growth ≤1 mm or ≤10% of carcinoma volume*

Adv Anat Pathol 2025;32:85–97
Histopathology 2024;84:1092–1094

The British Association of Gynaecological Pathologists

OVARIAN MUCINOUS CARCINOMA

- **GRADING** - Not reflected in NCCN guidelines for Tx of ovarian cancer (but sometimes requested by surgeon)
- International Collaboration on Cancer Reporting 2021
  - *Recommend Silverberg grading (non-core item)*
  - *Recommend including the % of infiltrative invasion*
  - *Don't use FIGO grading (it is not prognostic)*

International Collaboration on Cancer Reporting (ICCR). 2021.
http://www.iccrcancer.org/datasets/published-datasets/female-reproductive/ovary-ft-pp
Histopathology 2020;77:26–34

Histopathology 2020;77:26–34

Silverberg grading

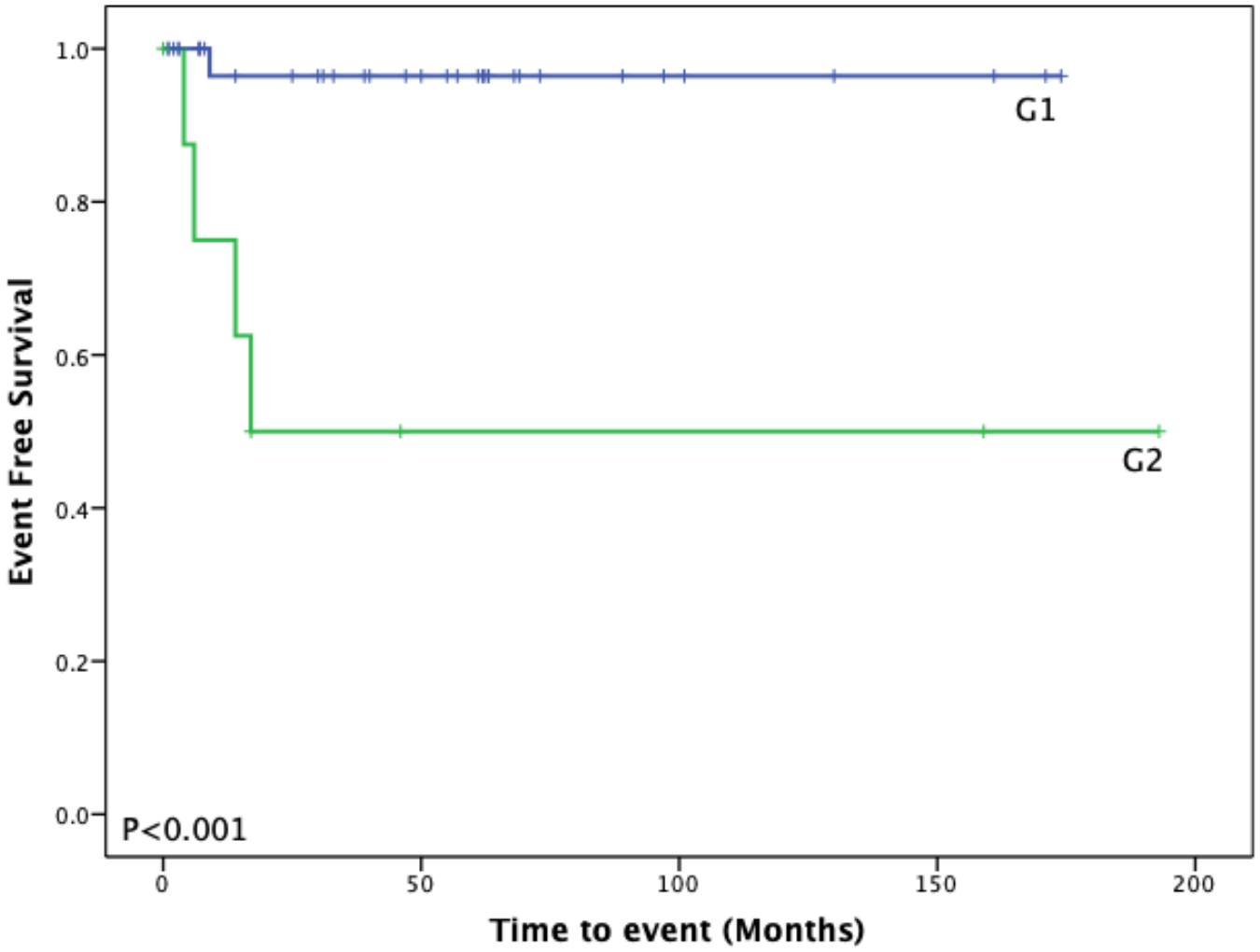

% infiltrative growth

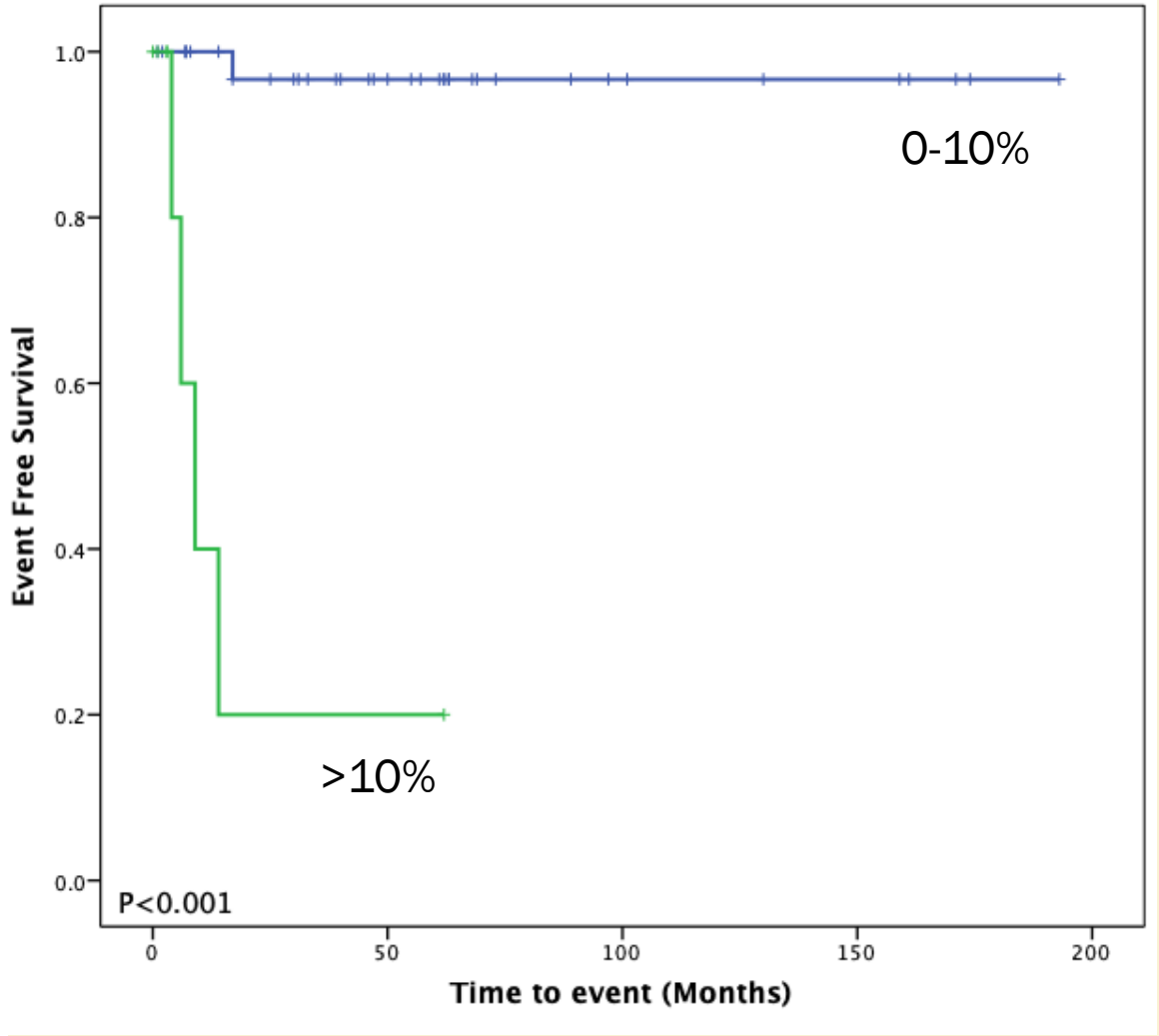

Cancer-specific survival (A-D)

Histopathology 2024;84:1095–1110

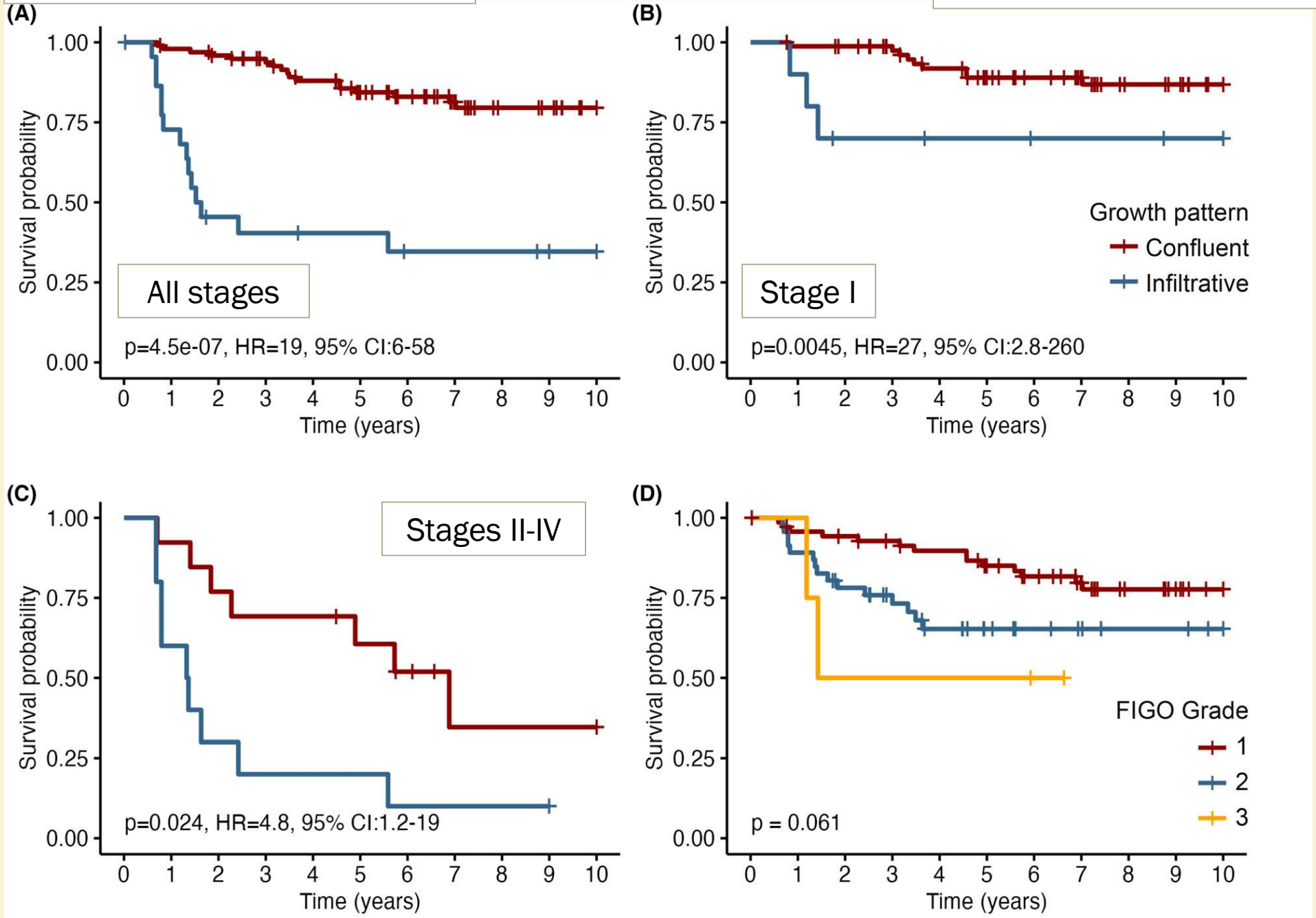

OVARIAN MUCINOUS CARCINOMA

- **GRADING** - Does the treating clinical team care?
- If they do:
  - *Don't use FIGO grading system (not proven value)*
  - *Use Silverberg (currently endorsed by ICCR)*
  - *Regardless, ALWAYS report the presence and % of infiltrative invasion*

International Collaboration on Cancer Reporting (ICCR). 2021.
http://www.iccrcancer.org/datasets/published-datasets/female-reproductive/ovary-ft-pp
Histopathology 2020;77:26–34, Am J Sug Pathol 2022 PMID 35363158

INTRAMURAL NODULES

- Clonal origin (regardless of type)
- Sarcomatoid (sarcoma-like)
  - *Indolent course*
  - *Well circumscribed*
  - *Heterogeneous population (atypical spindle cells, multinucleated giant cells, inflammatory cells)*
  - *Keratin positivity (weak, focal)*

Mod Pathol 2021;34:613–626
Am J Surg Pathol 1991;15:1055-62
Am J Surg Pathol 2002;26:1467-76

The British Association of Gynaecological Pathologists

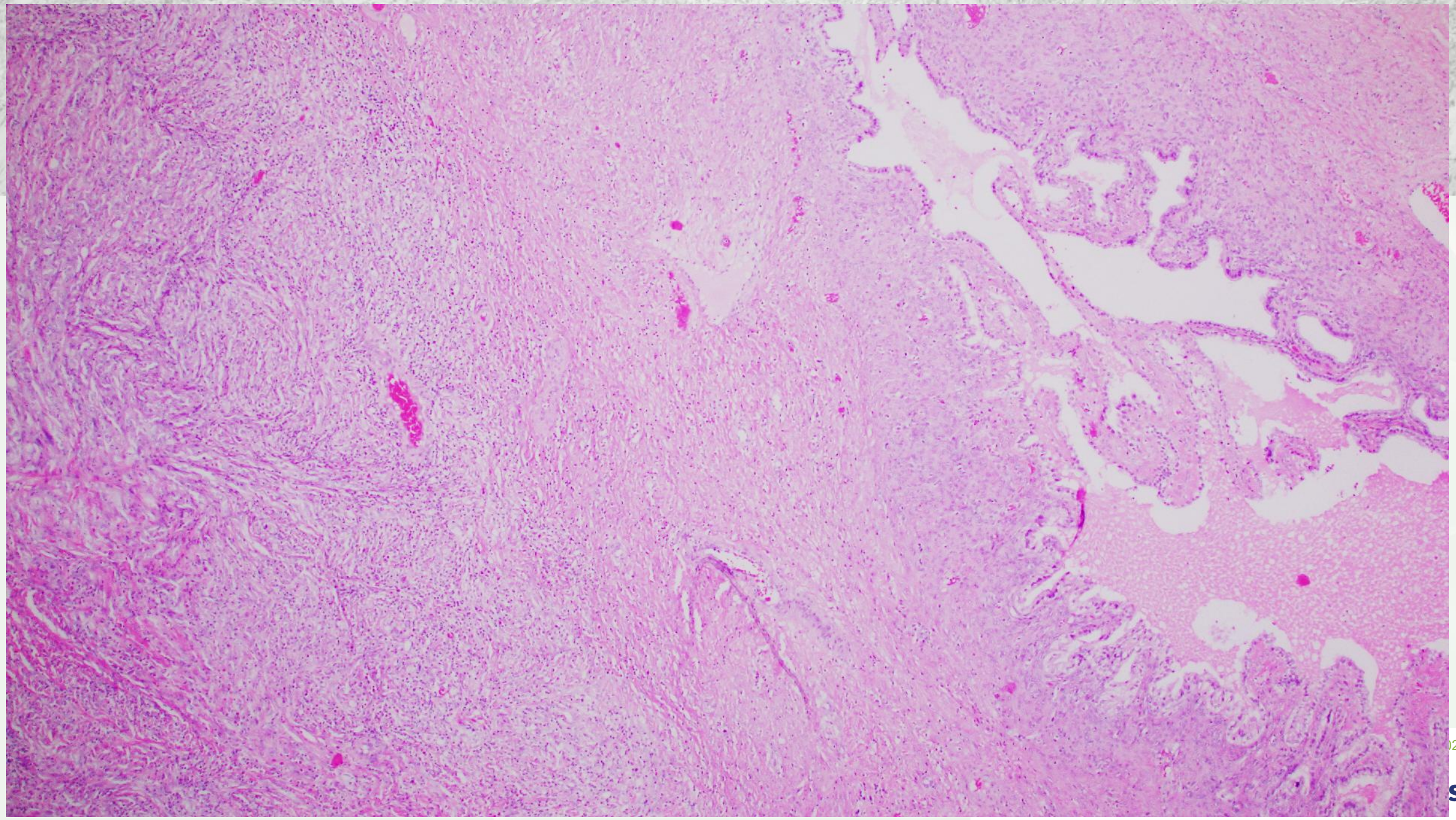

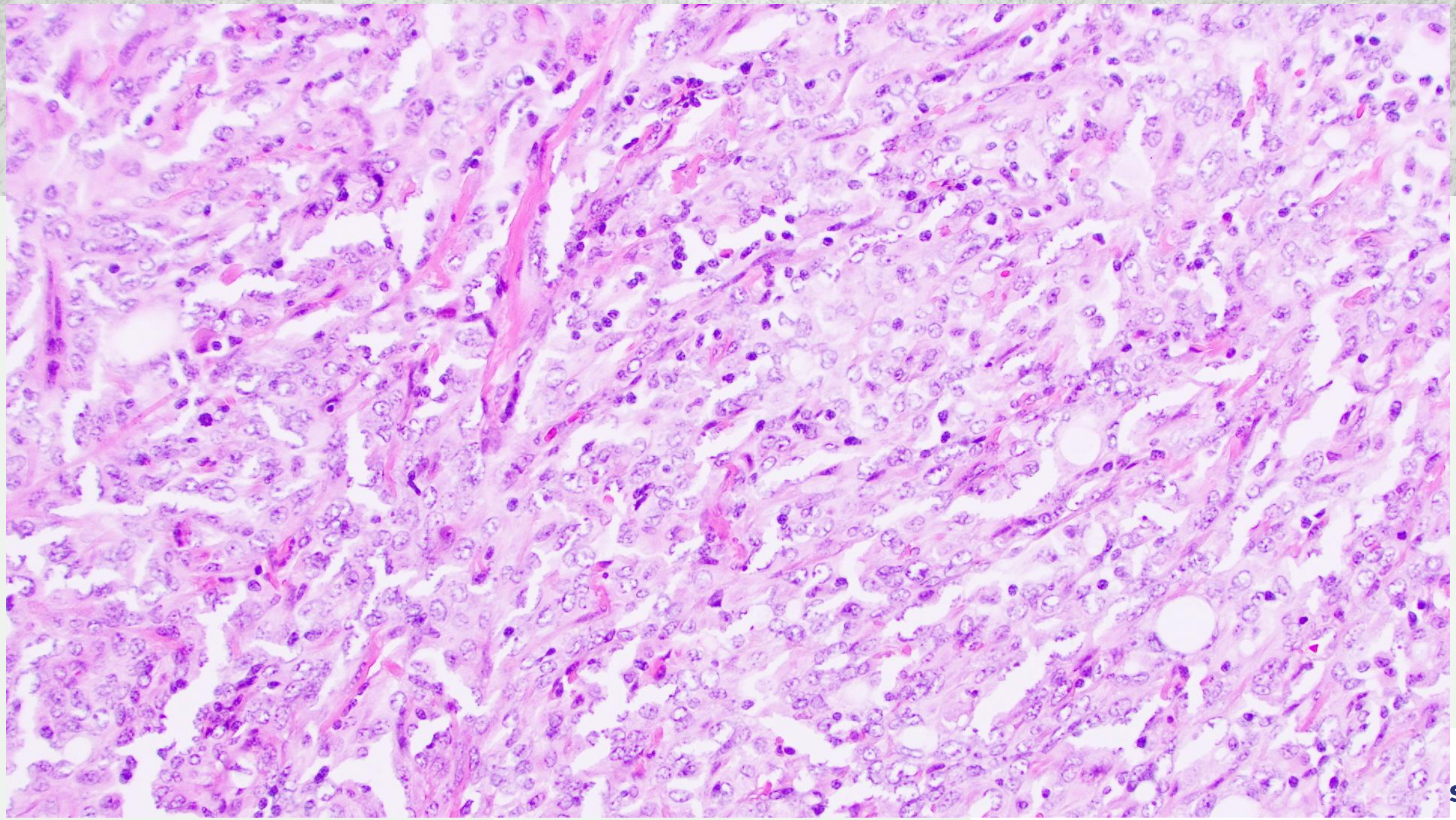

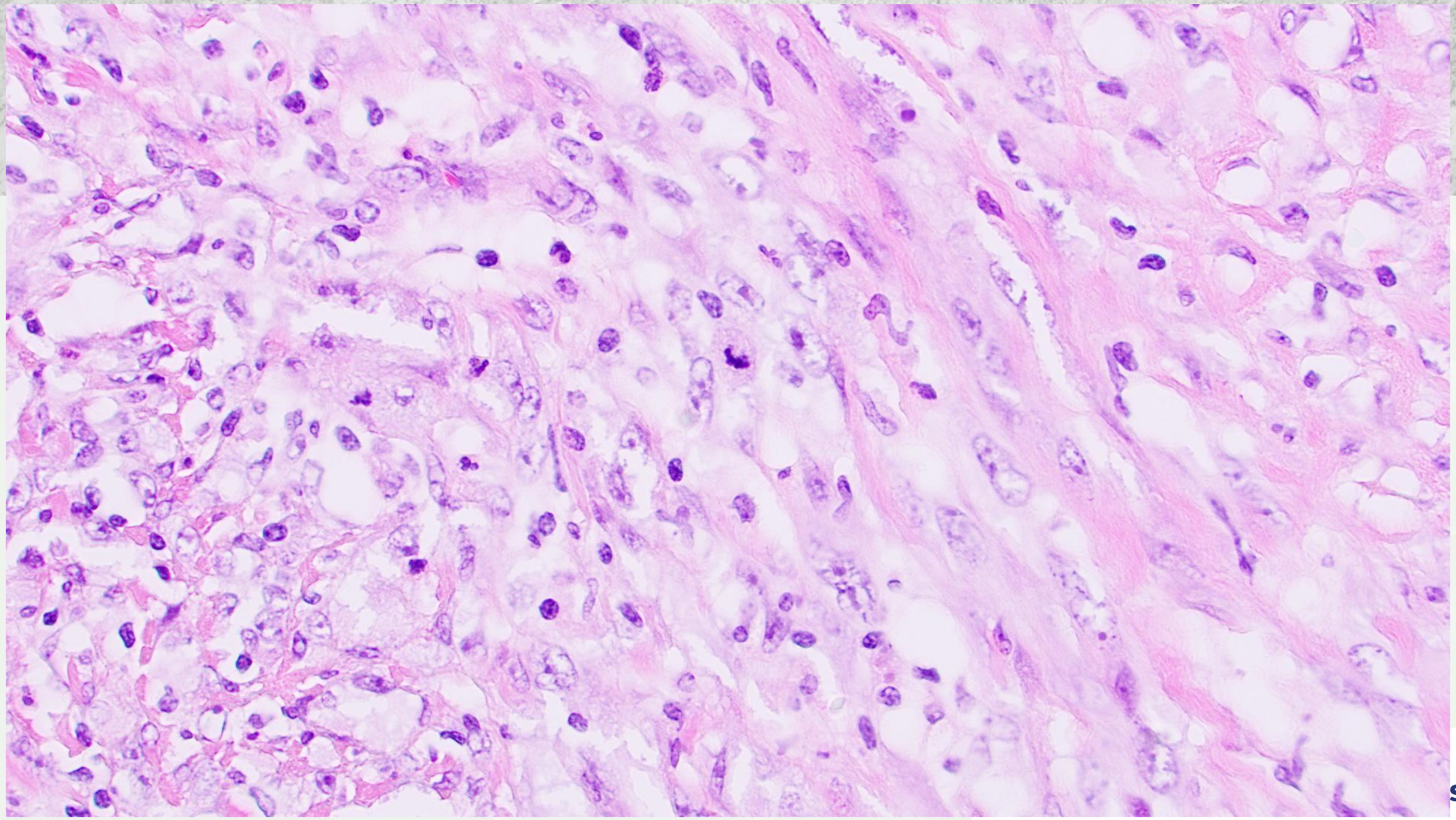

INTRAMURAL NODULES

- Sarcomatous
  - *Infiltrative edge*
  - *Less inflammation, marked nuclear pleomorphism and atypia*
- Anaplastic carcinoma
  - *Large cells with abundant eosinophilic cytoplasm and pleomorphism*
  - *Variable keratin positivity*

Am J Surg Pathol 1991;15:1055-62
Am J Surg Pathol 2008;32:383-89
Am J Surg Pathol 2017;41:1261-66

The British Association of Gynaecological Pathologists

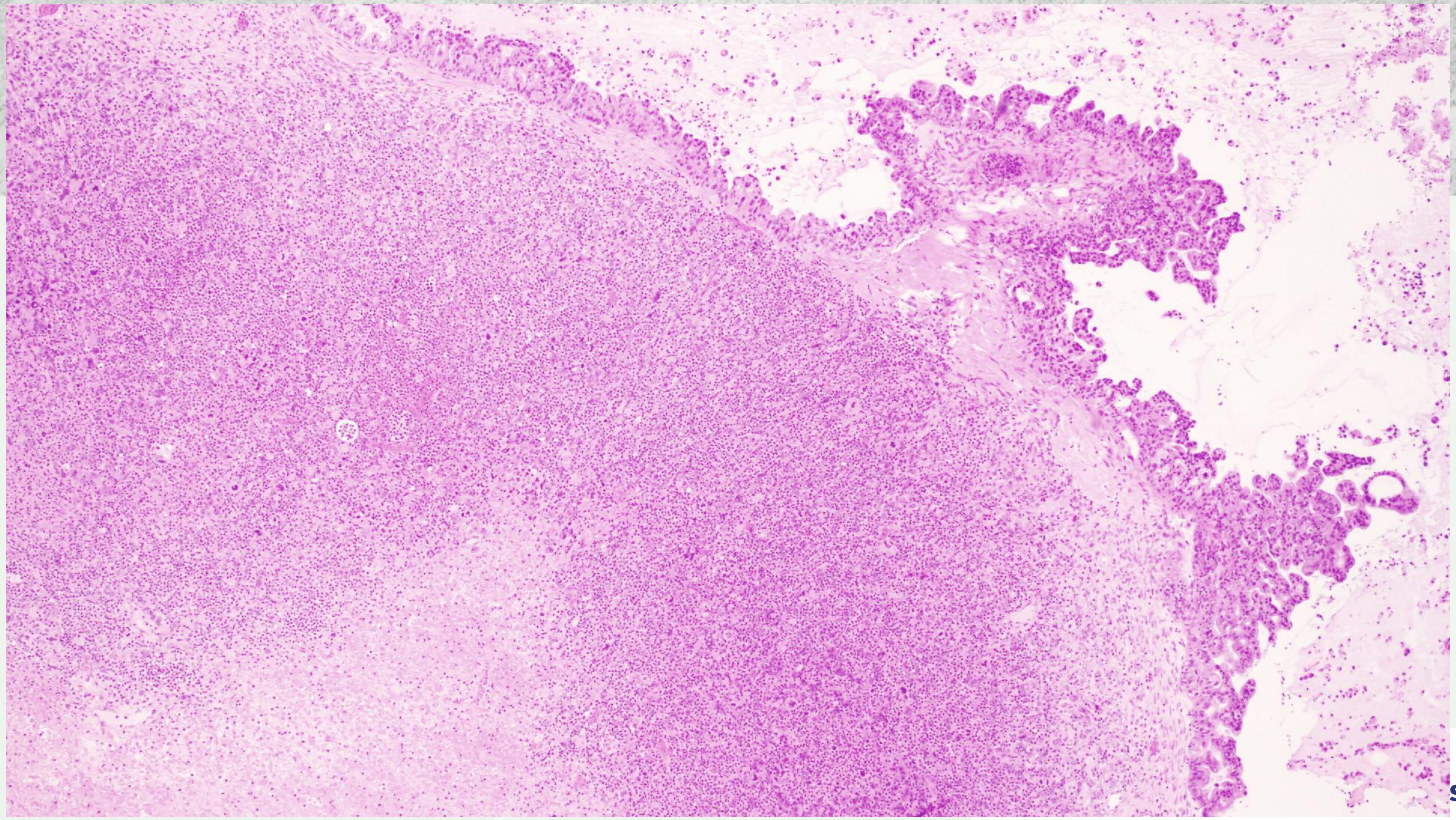

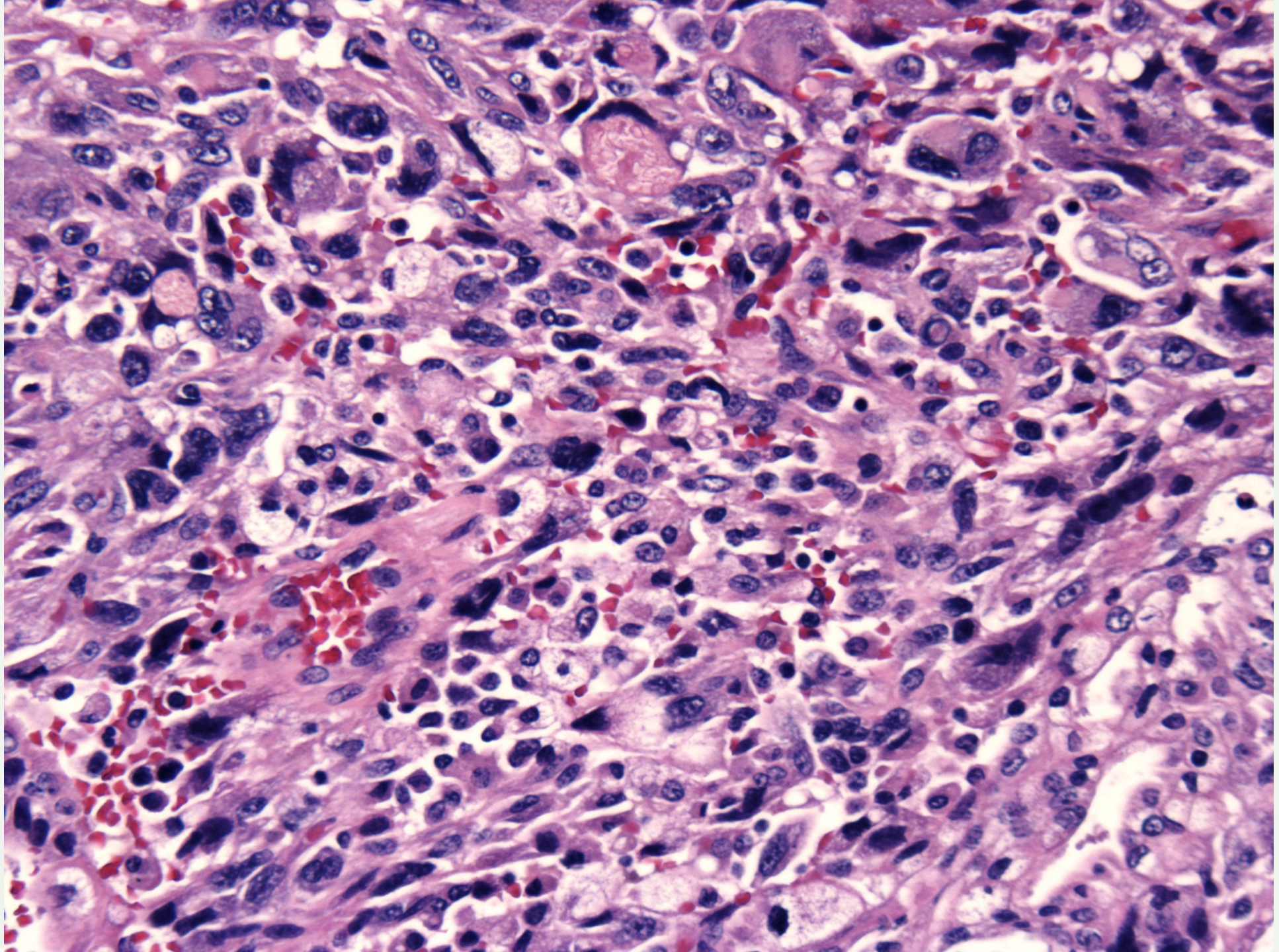

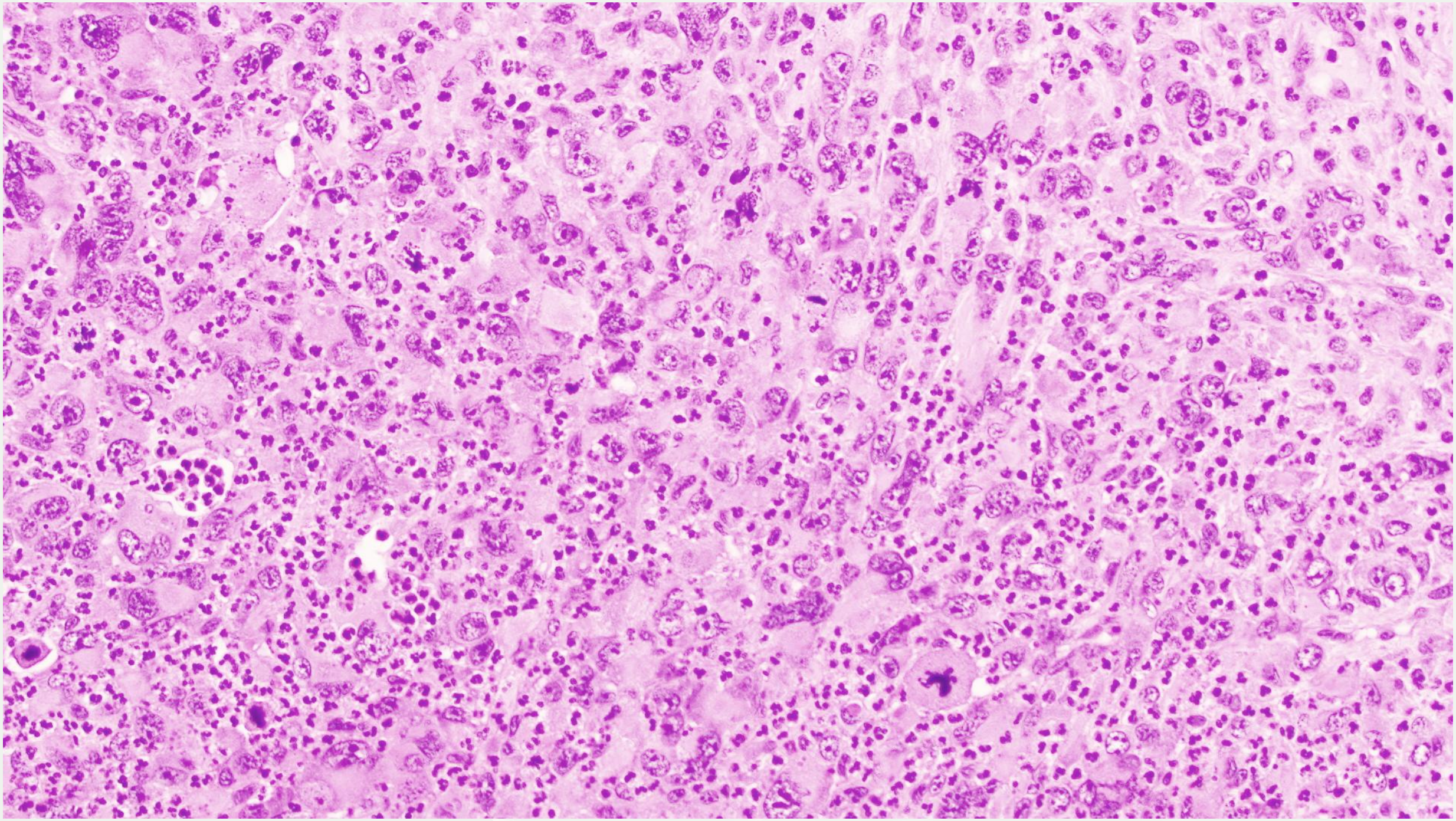

MURAL NODULES

Mod Pathol 2021;34:613–626
Am J Surg Pathol 1991;15:1055-62
Am J Surg Pathol 2002;26:1467-76

	SARCOMA-LIKE	SARCOMATOUS	ANAPLASTIC CA
Nodule borders	Well-circumscribed	Infiltrative	Infiltrative (can be smooth)
Cytologic atypia	Pleomorphic (epithelioid, spindle)	Pleomorphic (usually spindle homologous)	Pleomorphic (epithelioid, spindle, rhabdoid)
Inflammatory cells	Abundant (histocyte-rich)	Not prominent	Not prominent
Osteoclast-like giant cells	Abundant	None	None / occasional
Mitoses	Present (may be atypical)	Present (may be atypical)	Present (may be atypical)
Keratin	Variable (often weak)	Negative	Variable

KEEP IN MIND

- One mural nodule can show mixed morphology
- One tumor can have multiple nodules (of different kinds)

WHEN TO WORRY (about a malignant nodule)

- Infiltrative borders
- Lymphovascular space invasion
- Extrapelvic dissemination

THANK YOU!

cparra-herran@bwh.harvard.edu