The British Association of Gynaecological Pathologists

21st Annual Meeting in Collaboration with ISGyP

5th and 6th June 2025

Neuroendocrine Neoplasia in the Female Genital Tract

Dr Karen Talia
The Royal Women's and the Royal Children's Hospital
Melbourne
Australia

6th June 2025

The British Association of Gynaecological Pathologists

Speaker disclosures

- ❑ I have no financial conflicts of interest to disclose

Overview

Classification, terminology

Morphology, immunohistochemistry

Molecular findings

A focus on cervix and recent literature

Common classification

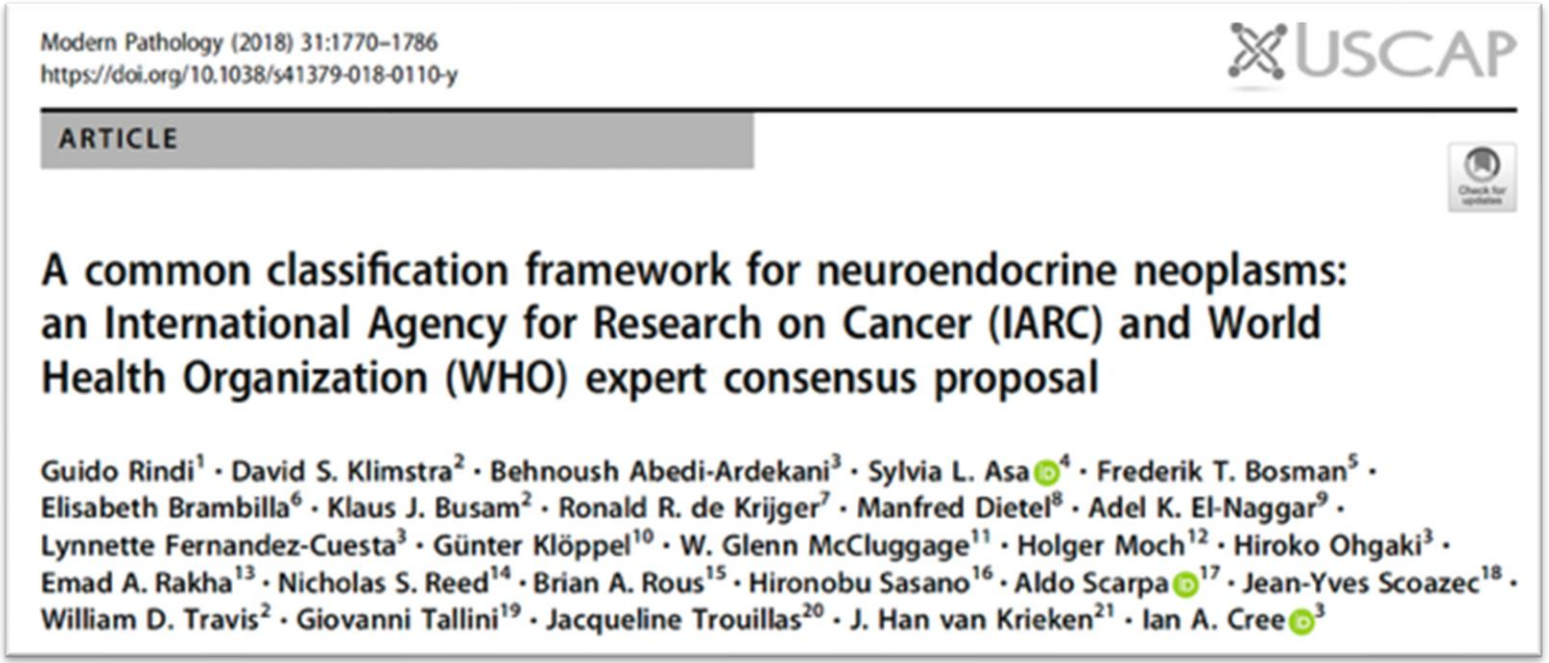

Modern Pathology (2018) 31:1770–1786
https://doi.org/10.1038/s41379-018-0110-y

USCAP

ARTICLE

A common classification framework for neuroendocrine neoplasms: an International Agency for Research on Cancer (IARC) and World Health Organization (WHO) expert consensus proposal

Guido Rindi[1] · David S. Klimstra[2] · Behnoush Abedi-Ardekani[3] · Sylvia L. Asa[4] · Frederik T. Bosman[5] · Elisabeth Brambilla[6] · Klaus J. Busam[2] · Ronald R. de Krijger[7] · Manfred Dietel[8] · Adel K. El-Naggar[9] · Lynnette Fernandez-Cuesta[3] · Günter Klöppel[10] · W. Glenn McCluggage[11] · Holger Moch[12] · Hiroko Ohgaki[3] · Emad A. Rakha[13] · Nicholas S. Reed[14] · Brian A. Rous[15] · Hironobu Sasano[16] · Aldo Scarpa[17] · Jean-Yves Scoazec[18] · William D. Travis[2] · Giovanni Tallini[19] · Jacqueline Trouillas[20] · J. Han van Krieken[21] · Ian A. Cree[3]

2017 IARC consensus conference - Common classification at all anatomical sites

Previously a range of site-specific terminologies and criteria

- Intended to reduce inconsistencies in terminology
- Allow consistent patient management, facilitate research

5th ed. WHO, all volumes

Neuroendocrine Neoplasm (NEN): All tumours

Neuroendocrine Tumour (NET): *Low-intermediate grade*

- NET G1, G2, G3 (NET G3 *not established in FGT*)
- Typical and atypical carcinoid retained in lung, H&N
- Carcinoid retained in ovary

Neuroendocrine Carcinoma (NEC): *High-grade by definition*

- Small cell NEC, Large cell NEC
- Carcinoma admixed with NEC / MiNEN

Rindi Mod Pathol 2018

Table 1.XX Classification and grading criteria for neuroendocrine neoplasms (NENs) of the GI tract and hepatopancreatobiliary organs

Terminology	Differentiation	Grade	Mitotic count[a] (mitoses/2 mm^2)	Ki-67 index[a]
NET, G1	Well differentiated	Low	< 2	< 3%
NET, G2		Intermediate	2–20	3–20%
NET, G3		High	> 20	> 20%
NEC, small cell type (SCNEC)	Poorly differentiated	High[b]	> 20	> 20%
NEC, large cell type (LCNEC)			> 20	> 20%
MiNEN	Well or poorly differentiated[c]	Variable[c]	Variable[c]	Variable[c]

NET G1, G2, G3 recognised in the GI tract and liver/pancreas/biliary tree
Well established diagnostic parameters with prognostic significance
In female genital tract, only G1 and G2 established

Neuroendocrine neoplasia in the FGT

Uncommon to rare; occur at any site

NET: Predominate in the ovary, “carcinoid tumour” is retained

Commonest neuroendocrine neoplasm in FGT

NETs extremely rare in other female genital sites

NEC: Most common in the **cervix**; less in endometrium, ovary, vulva

Cervix: **80% small cell NEC**, 12% large cell NEC; overlap may occur

Carcinoma admixed with NEC: Mostly cervix, HPVA adenocarcinoma/AIS

Also endometrium, ovary; vulval NEC usually pure

Papatsimpas Case Rep Oncol 2017, Chetty Virchows Arch 1993, Grondin IJGP 2019, Sulak Gynecol Oncol 1988, Chen AJSP 2021, Tempfer BMC Cancer 2018

Cell of origin

Native neuroendocrine cells (largely unappreciated)

- In cervical glandular or squamous epithelium
- NE marker +ve cells reported in AIS, Bartholin glands, F Tube

MiNEN - NEC derives **from carcinoma component**

Aetiology

HPV 16/18 Most *but not all* cervical NEC (**18>16** in SCNEC)
some NET, vulval non-Merkel NEC

Merkel cell polyomavirus, UV exposure Merkel cell ca

Grondin IJGP 2019, Chen AJSP 2021, Howitt AJSP 2020, Castle Gynecol Oncol 2018, Alejo Papillomavirus Res 2018, Sah IJGP 2022

Morphology

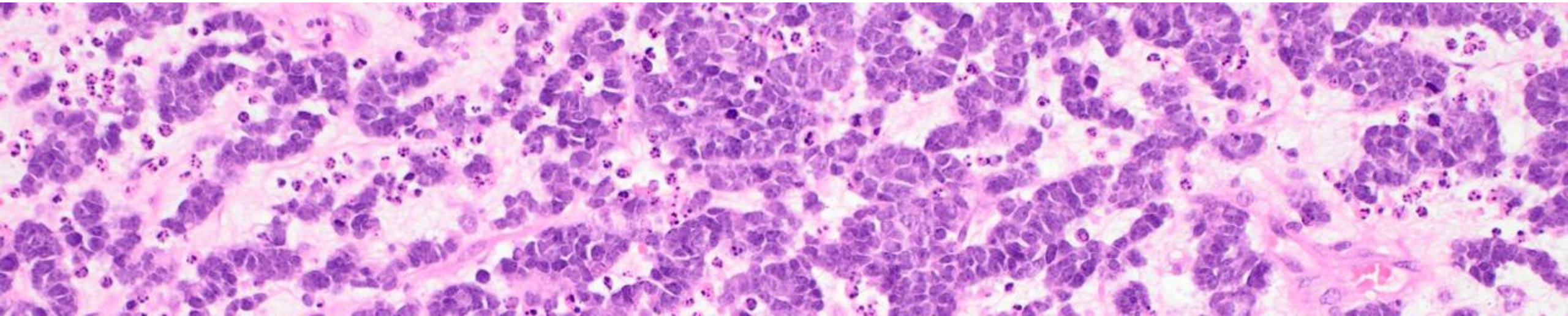

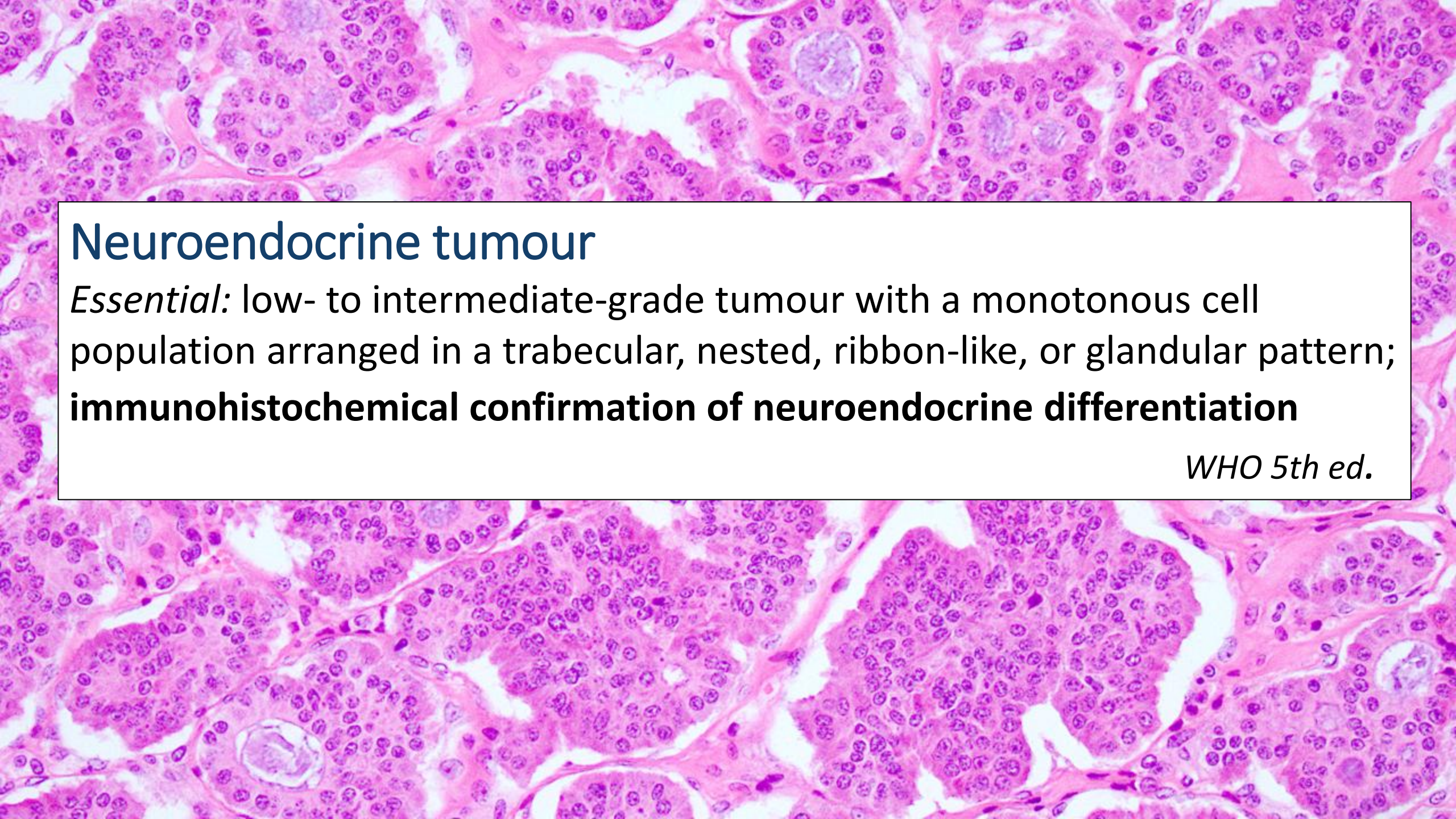

Neuroendocrine tumour

Essential: low- to intermediate-grade tumour with a monotonous cell population arranged in a trabecular, nested, ribbon-like, or glandular pattern; **immunohistochemical confirmation of neuroendocrine differentiation**

WHO 5th ed.

Neuroendocrine tumour

Nuclei: Round-oval, evenly spaced

Cytoplasm abundant, eosinophilic; ± reddish granules

Lacks atypia; mitotic activity low

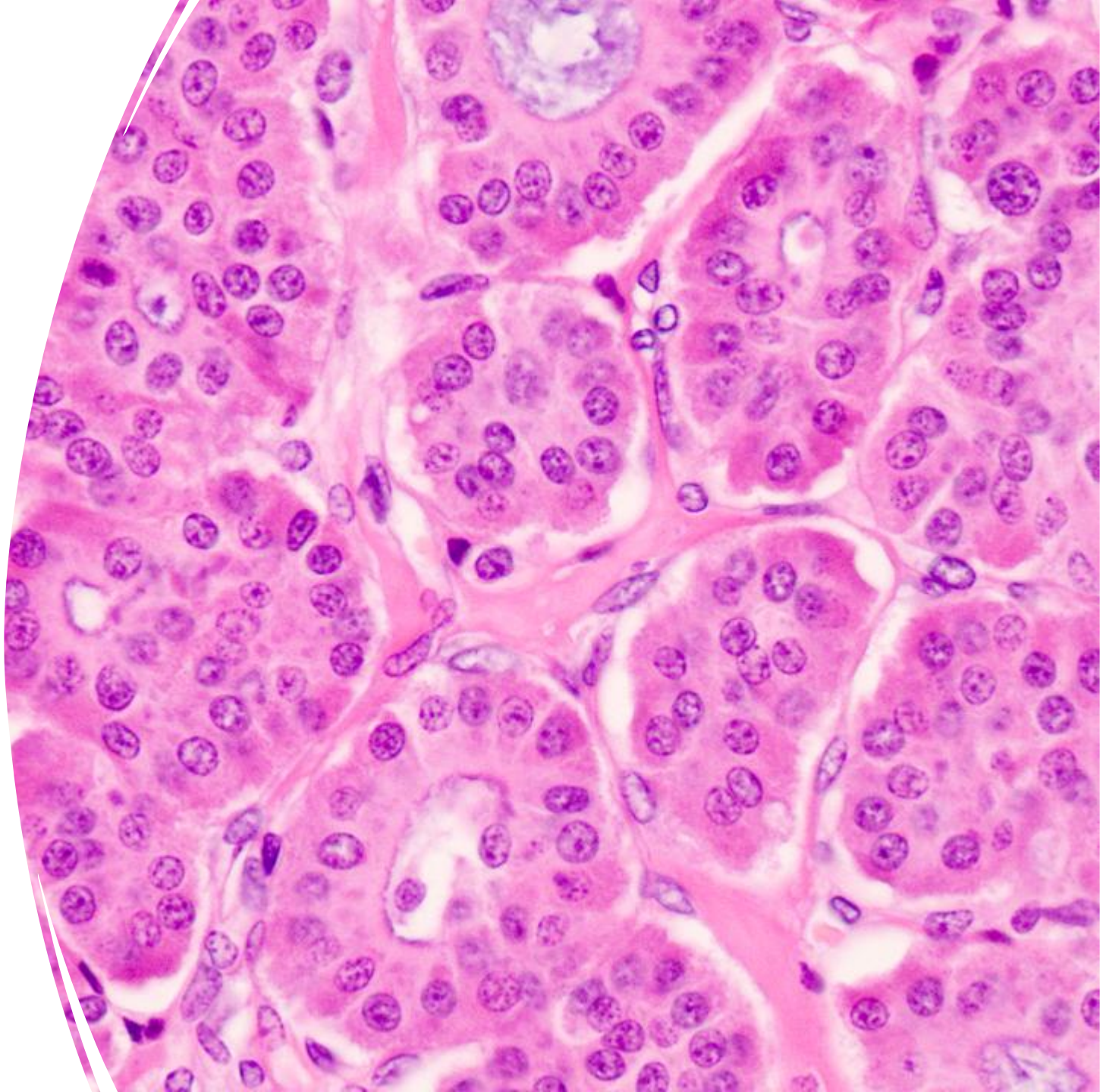

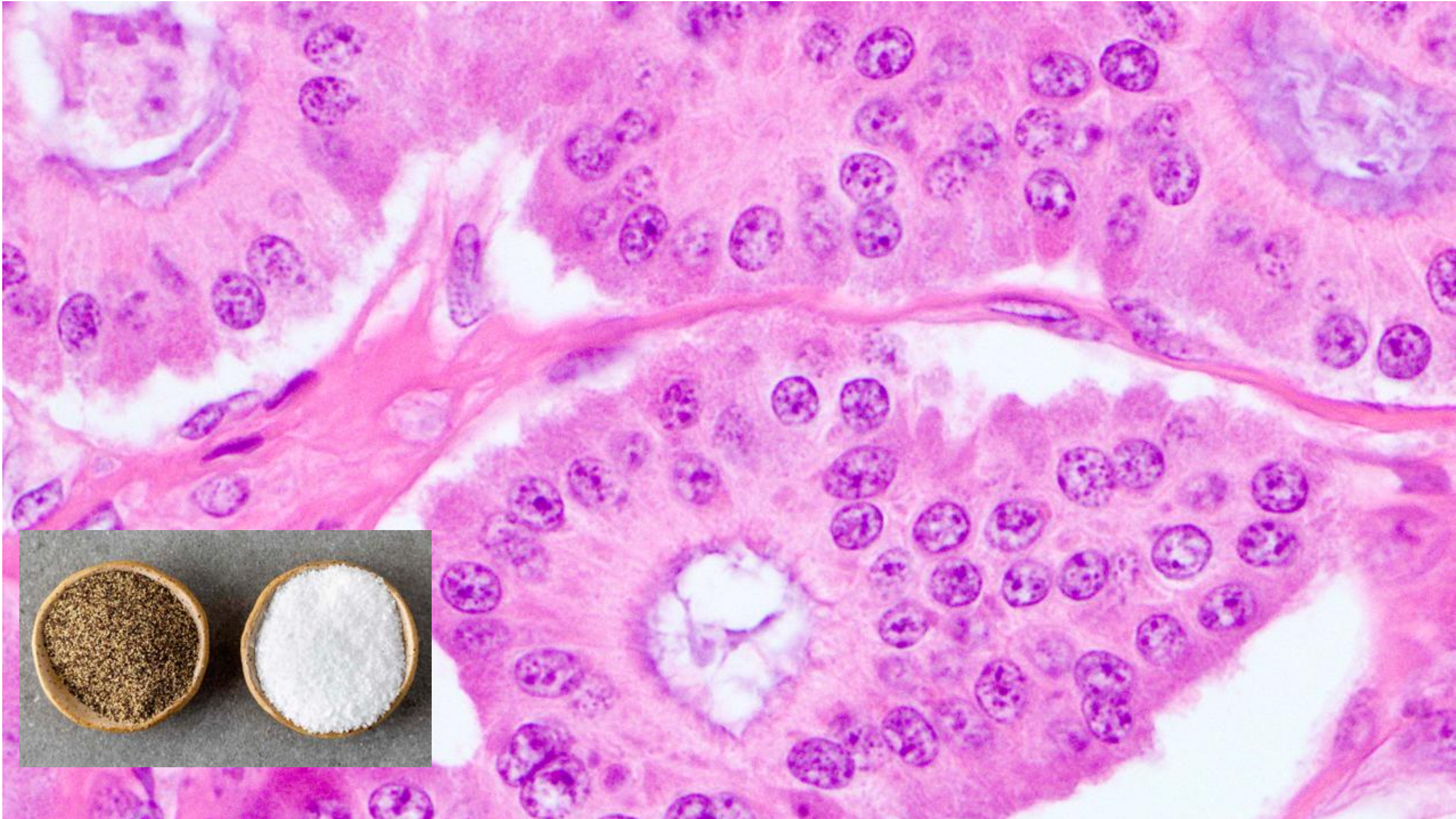

Grade 1	**Female genital tract**	Grade 2
Nuclei regular, uniform chromatin, small nucleoli		Nuclei **variable in size and shape, irregular chromatin**
Rare/no mitotic figures		**5-10 mitotic figures/10 HPF** 0.5mm diam (5-10 mitotic figures/2mm^2)
No necrosis		Focal necrosis acceptable

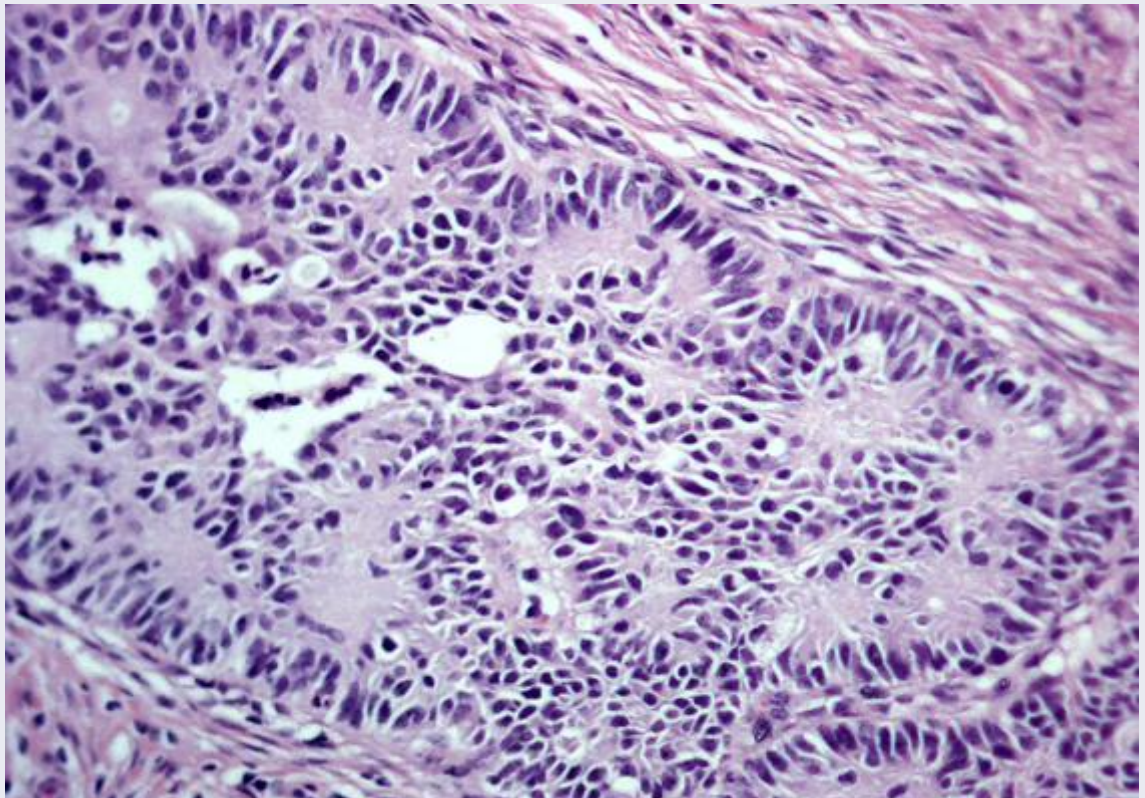

WHO 5th Ed

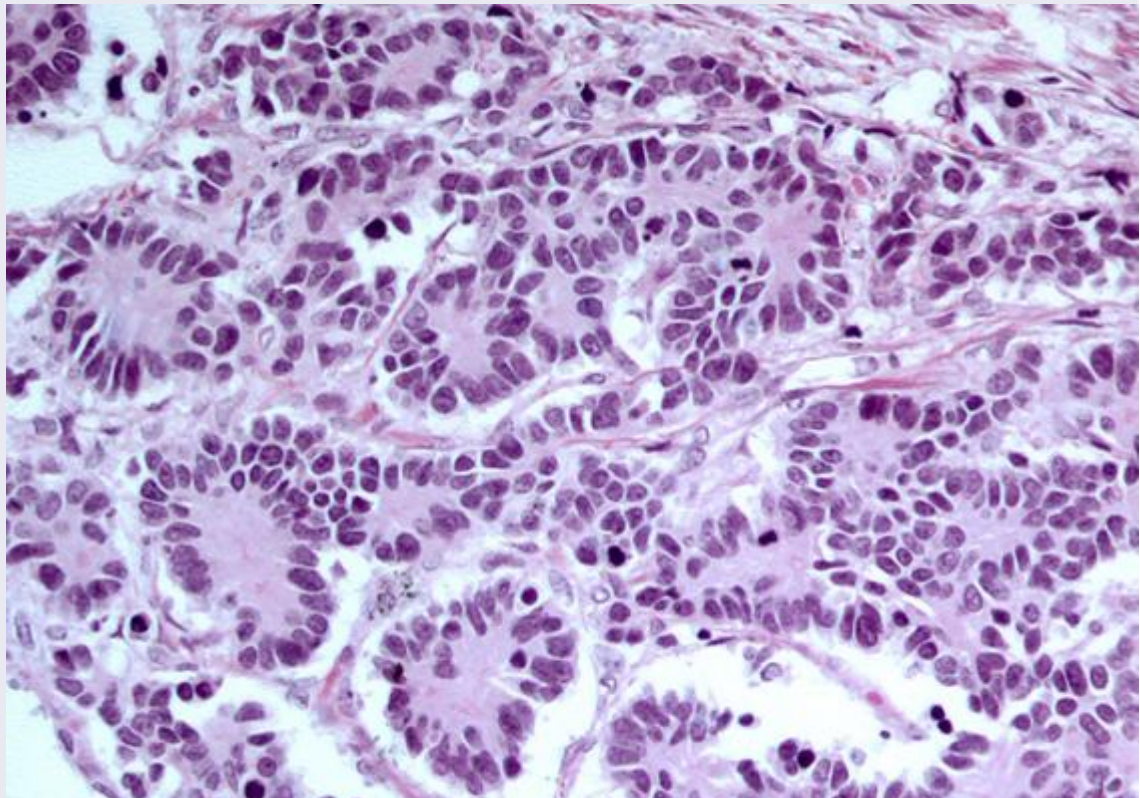

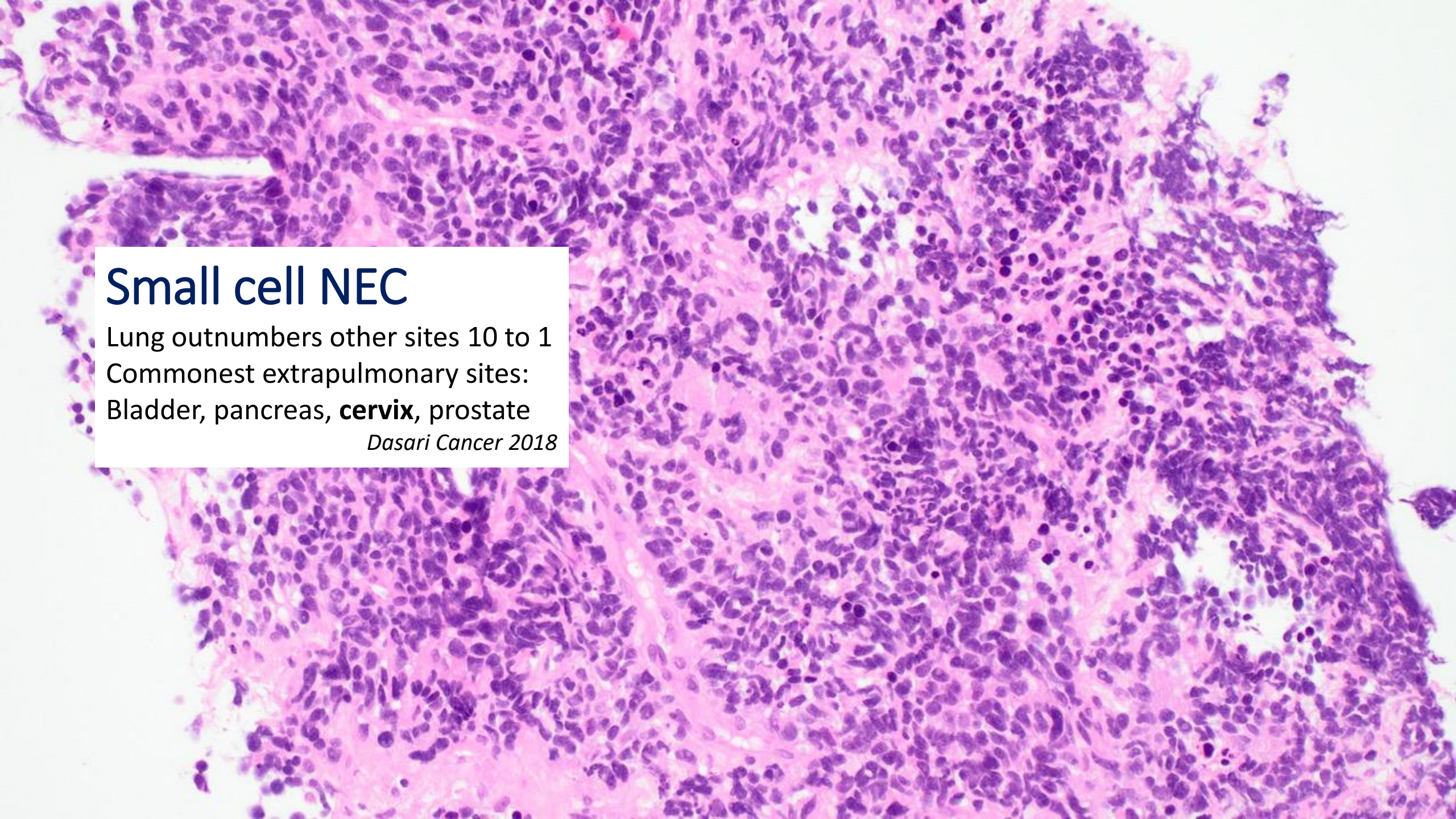

Small cell NEC

Lung outnumbers other sites 10 to 1

Commonest extrapulmonary sites:

Bladder, pancreas, **cervix**, prostate

Dasari Cancer 2018

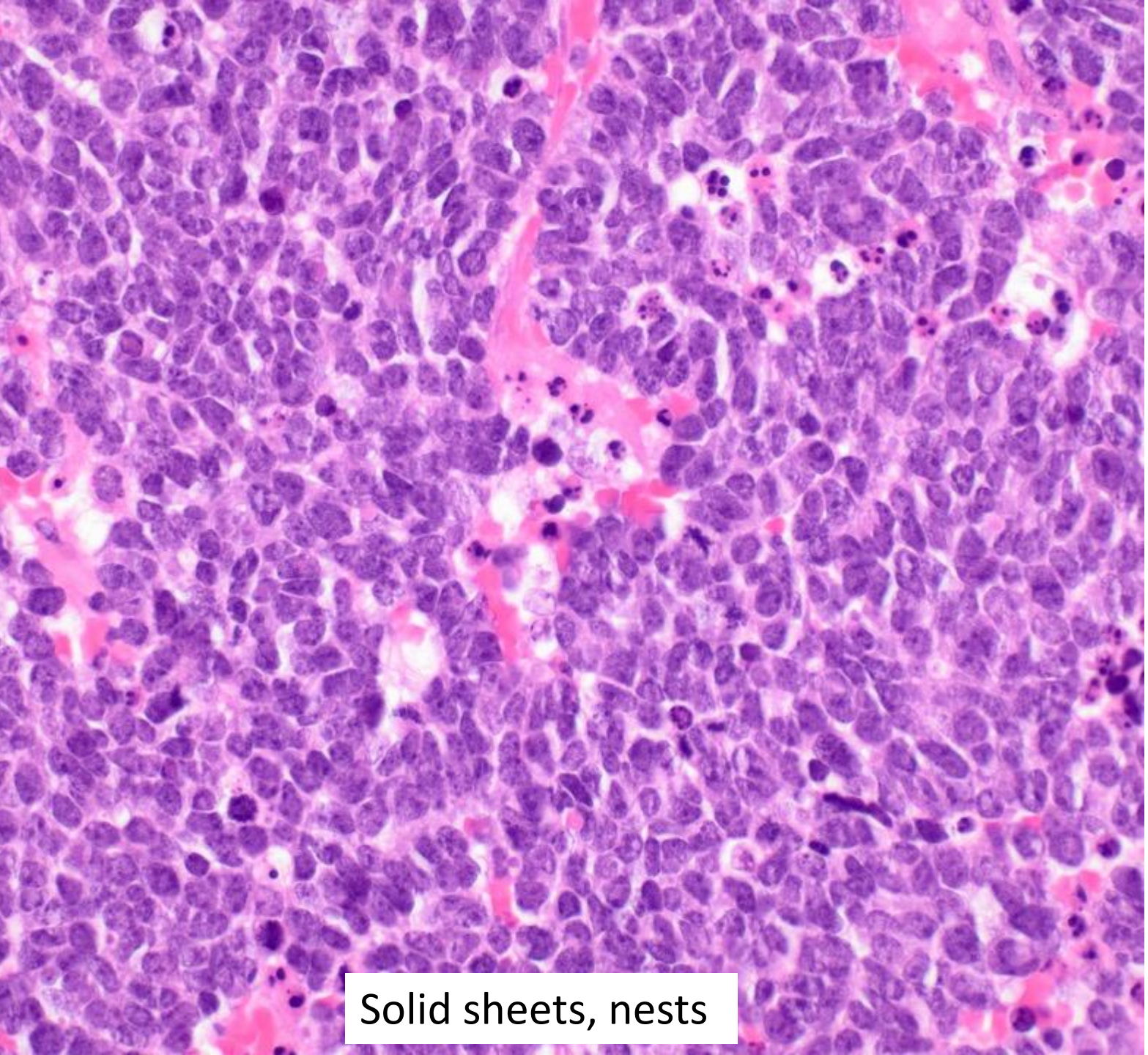
Solid sheets, nests

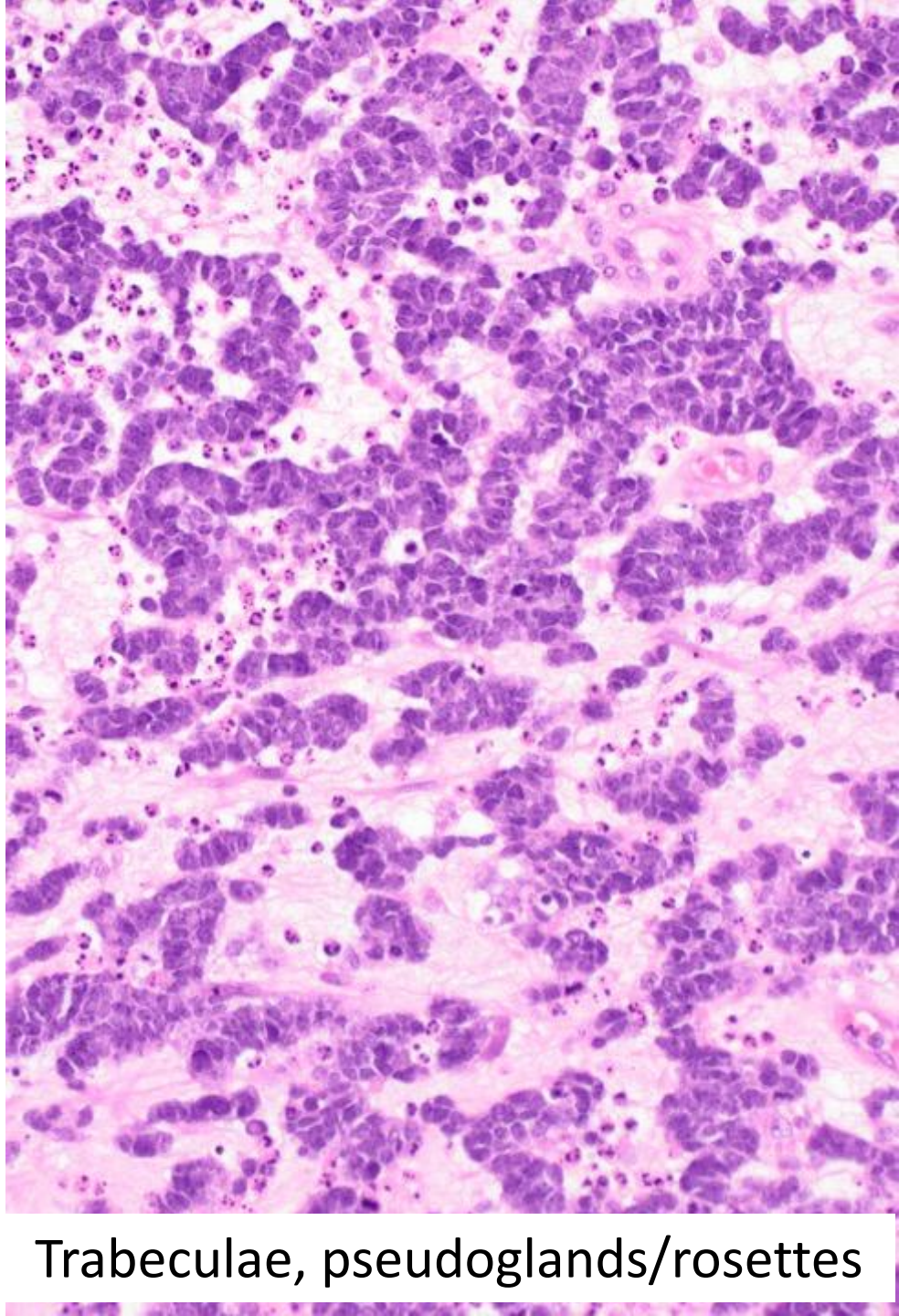
Trabeculae, pseudoglands/rosettes

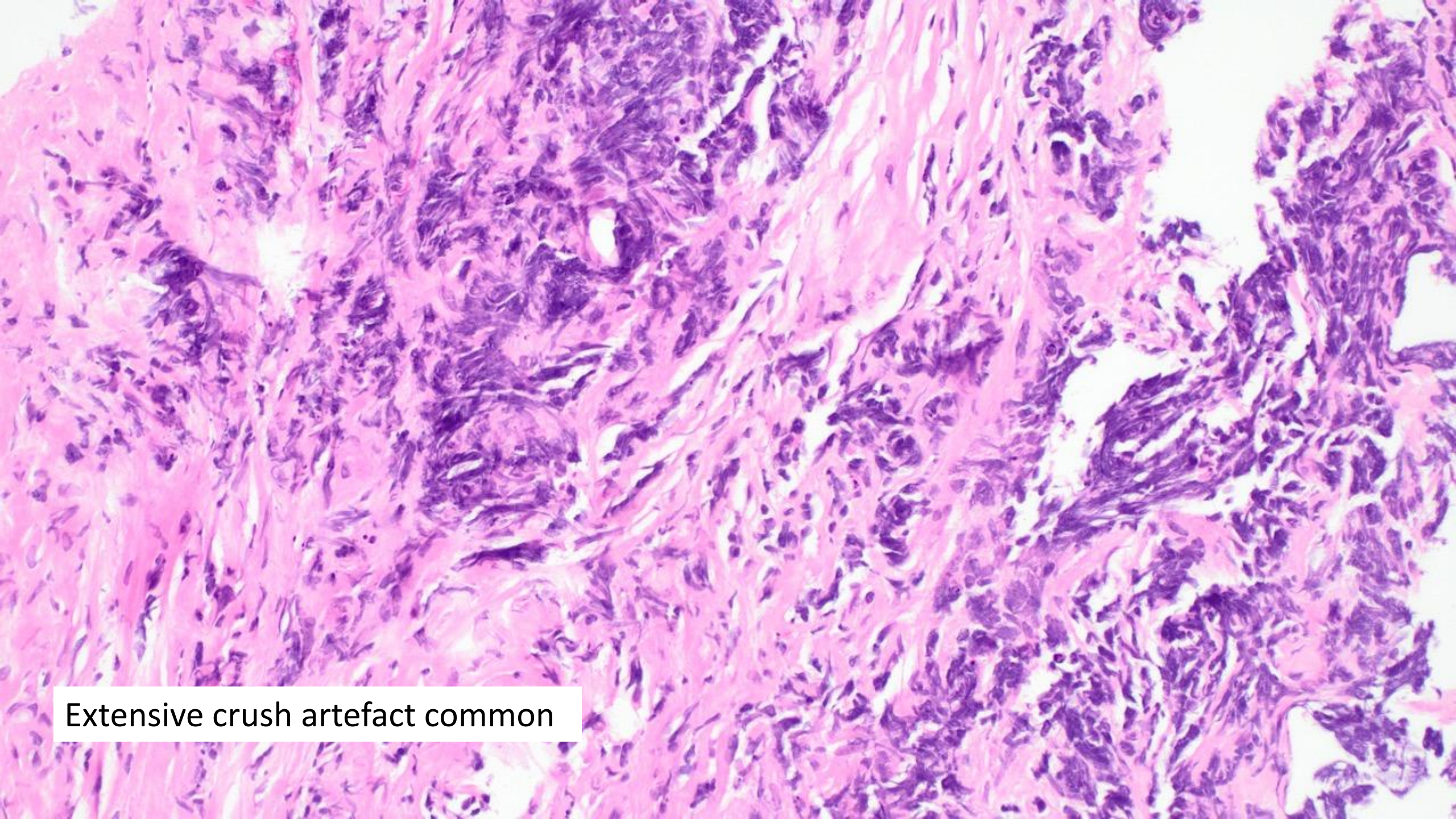
Extensive crush artefact common

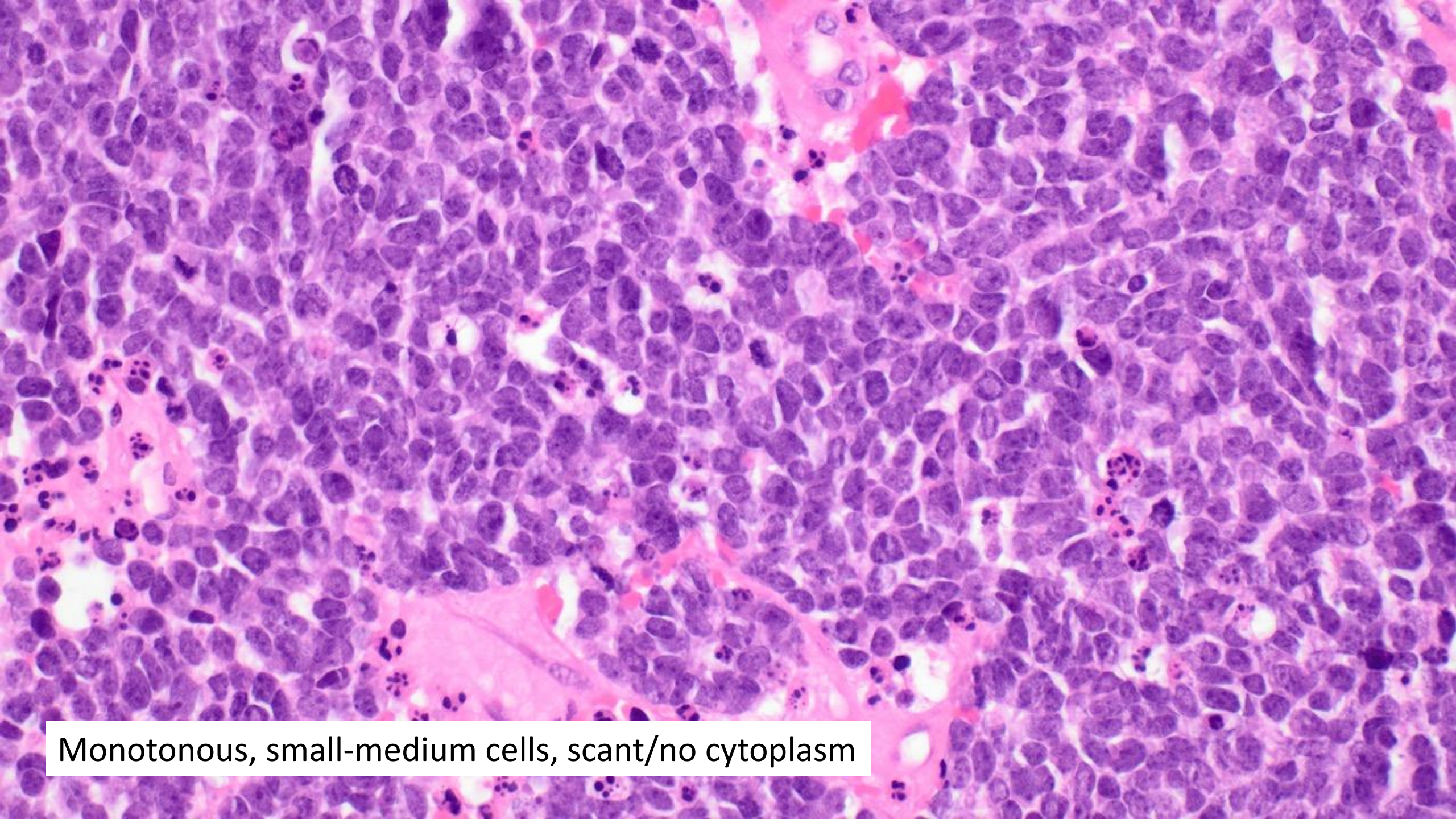
Monotonous, small-medium cells, scant/no cytoplasm

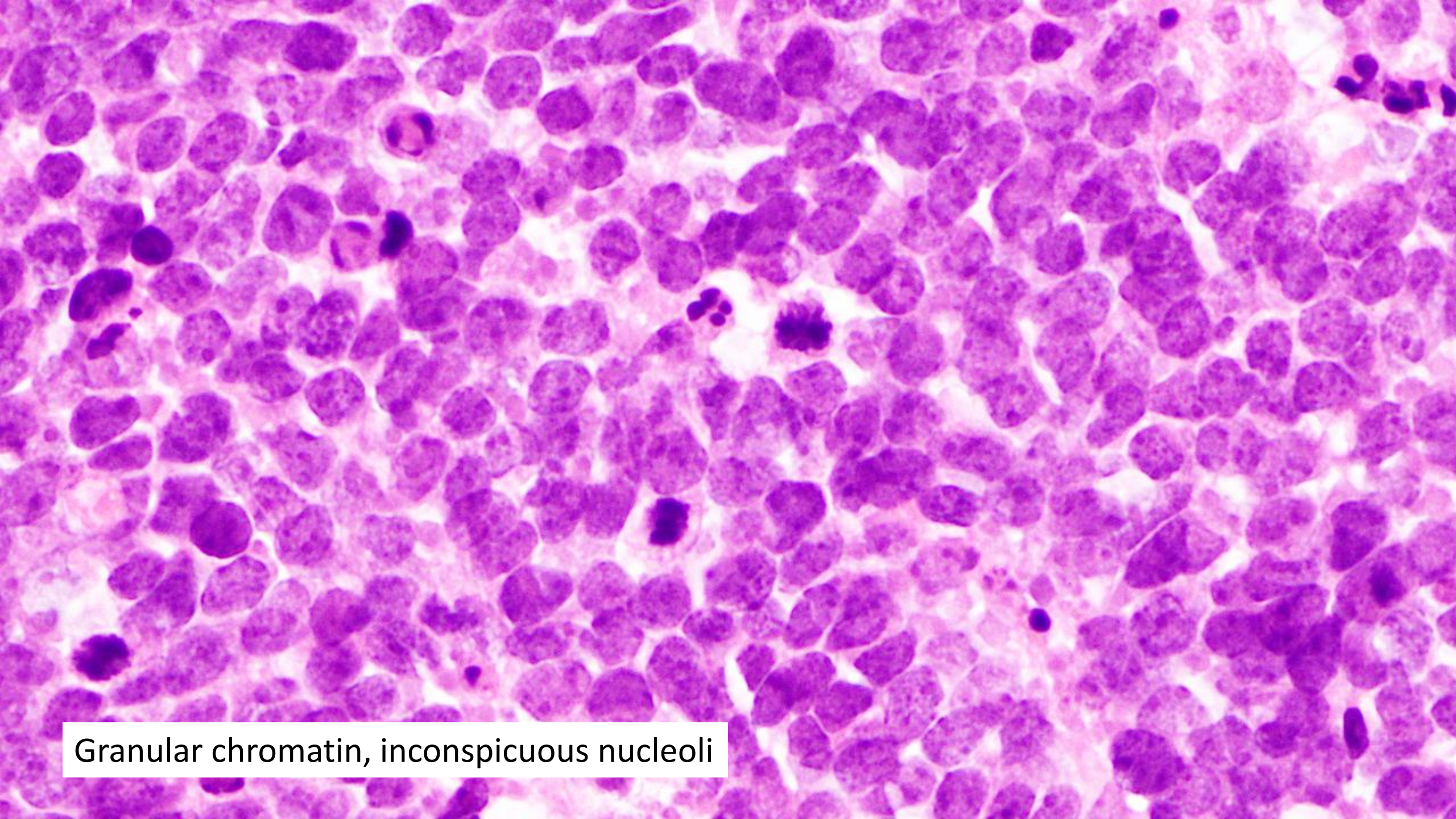
Granular chromatin, inconspicuous nucleoli

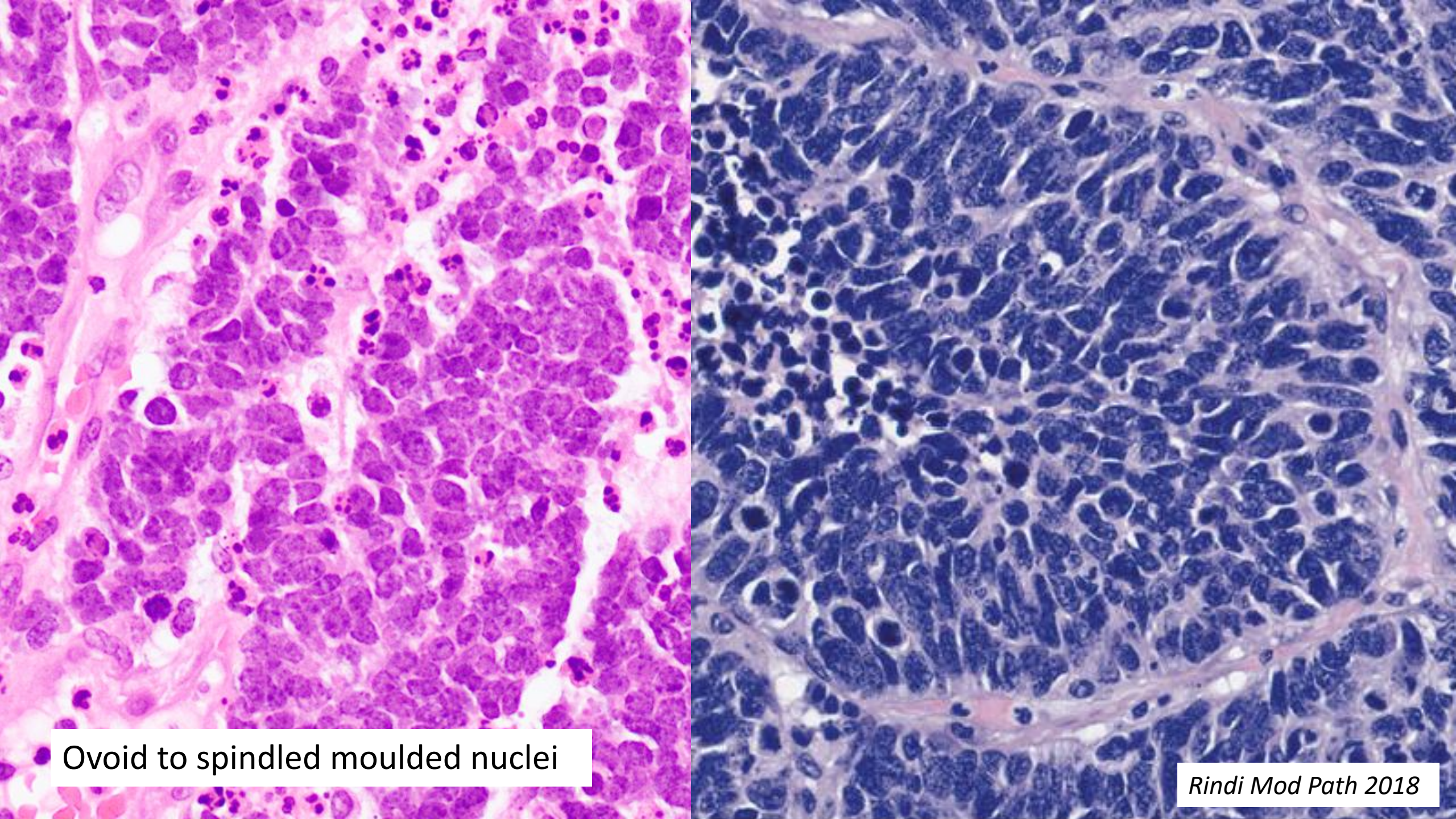
Ovoid to spindled moulded nuclei
Rindi Mod Path 2018

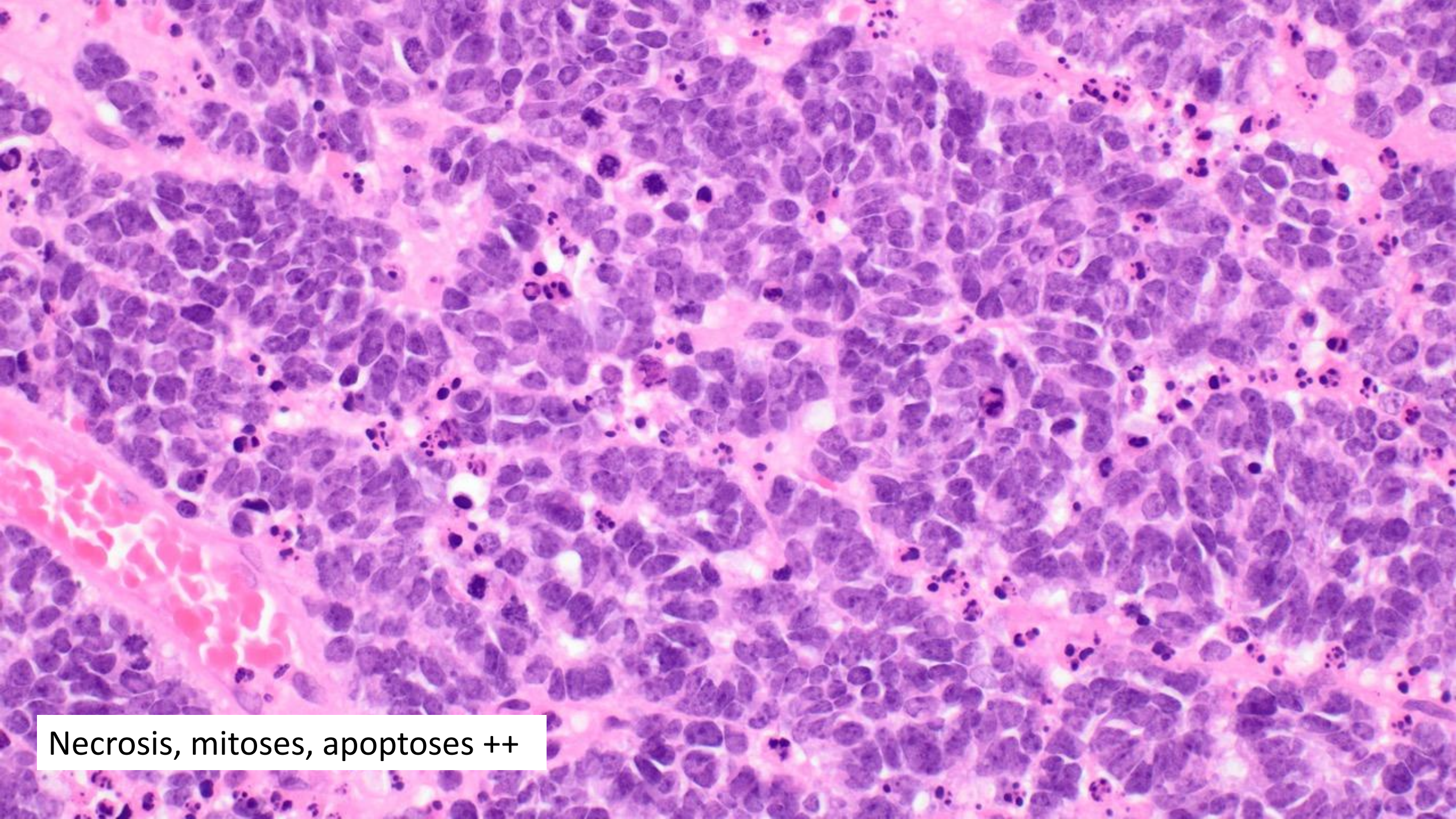
Necrosis, mitoses, apoptoses ++

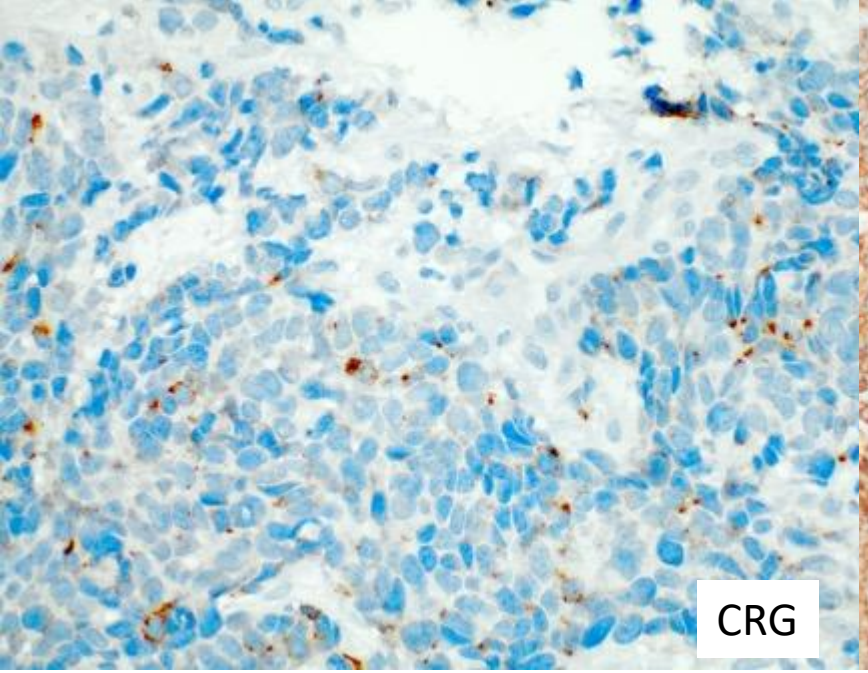

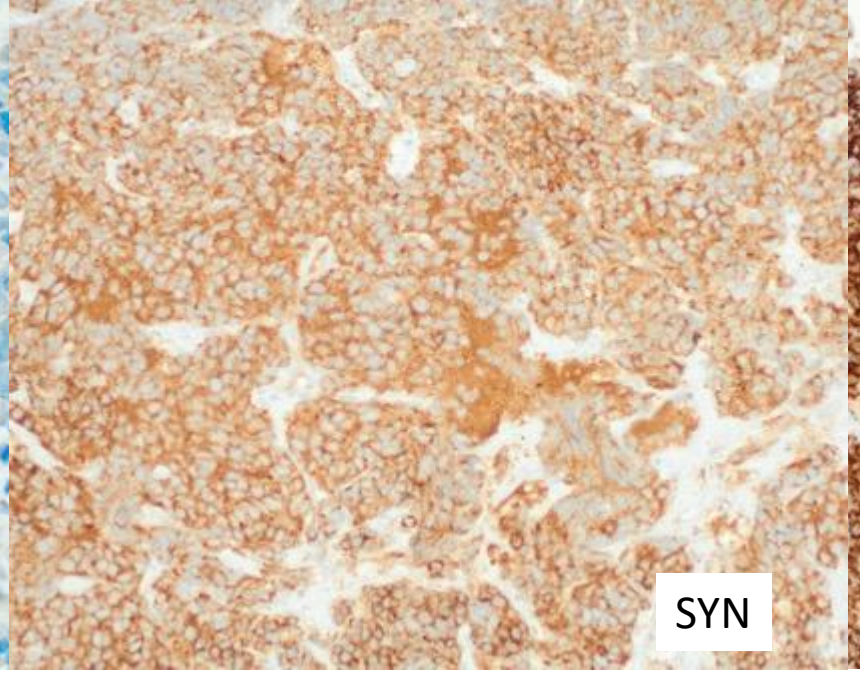

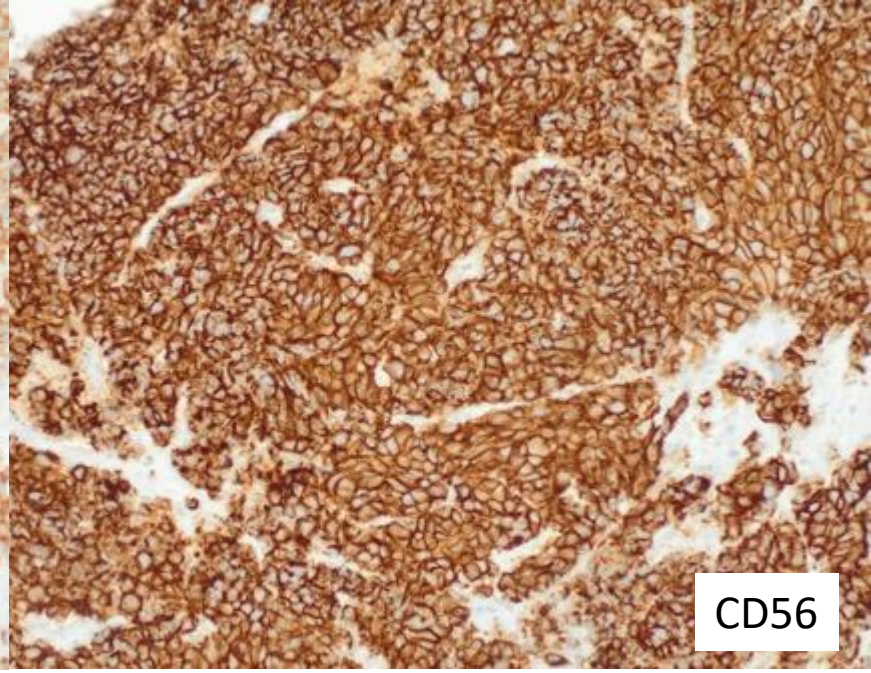

Small cell NEC

Usually positive with one or more neuroendocrine marker and cytokeratin

Expression may be focal, punctate or even absent

Diagnosis can be made in the absence of neuroendocrine marker positivity if the morphology is typical

WHO 5th ed., Bellizzi Hum Pathol 2020, McCluggage AJSP 2010

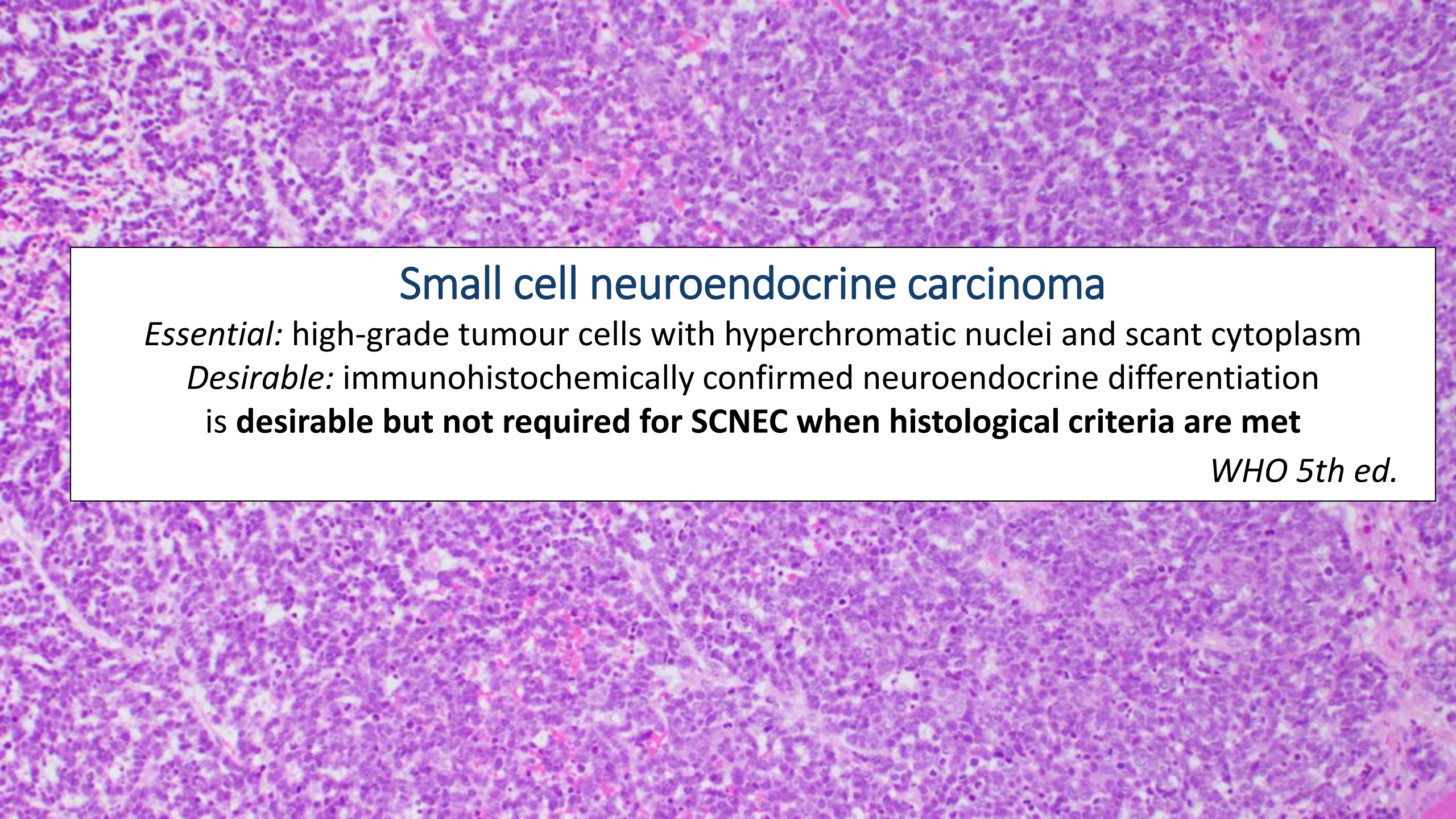

Small cell neuroendocrine carcinoma

Essential: high-grade tumour cells with hyperchromatic nuclei and scant cytoplasm

Desirable: immunohistochemically confirmed neuroendocrine differentiation

is **desirable but not required for SCNEC when histological criteria are met**

WHO 5th ed.

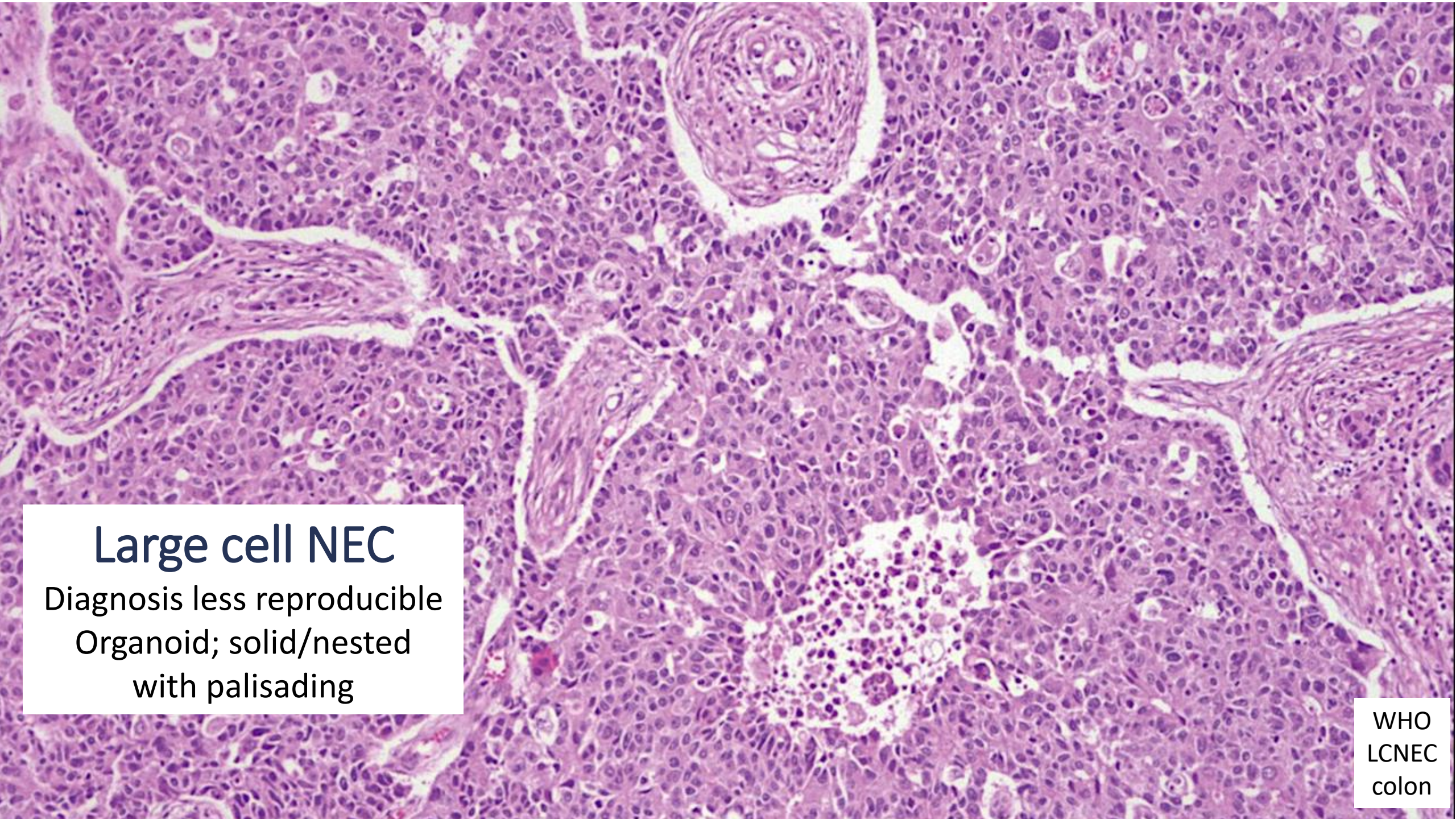
Large cell NEC
Diagnosis less reproducible
Organoid; solid/nested
with palisading
WHO
LCNEC
colon

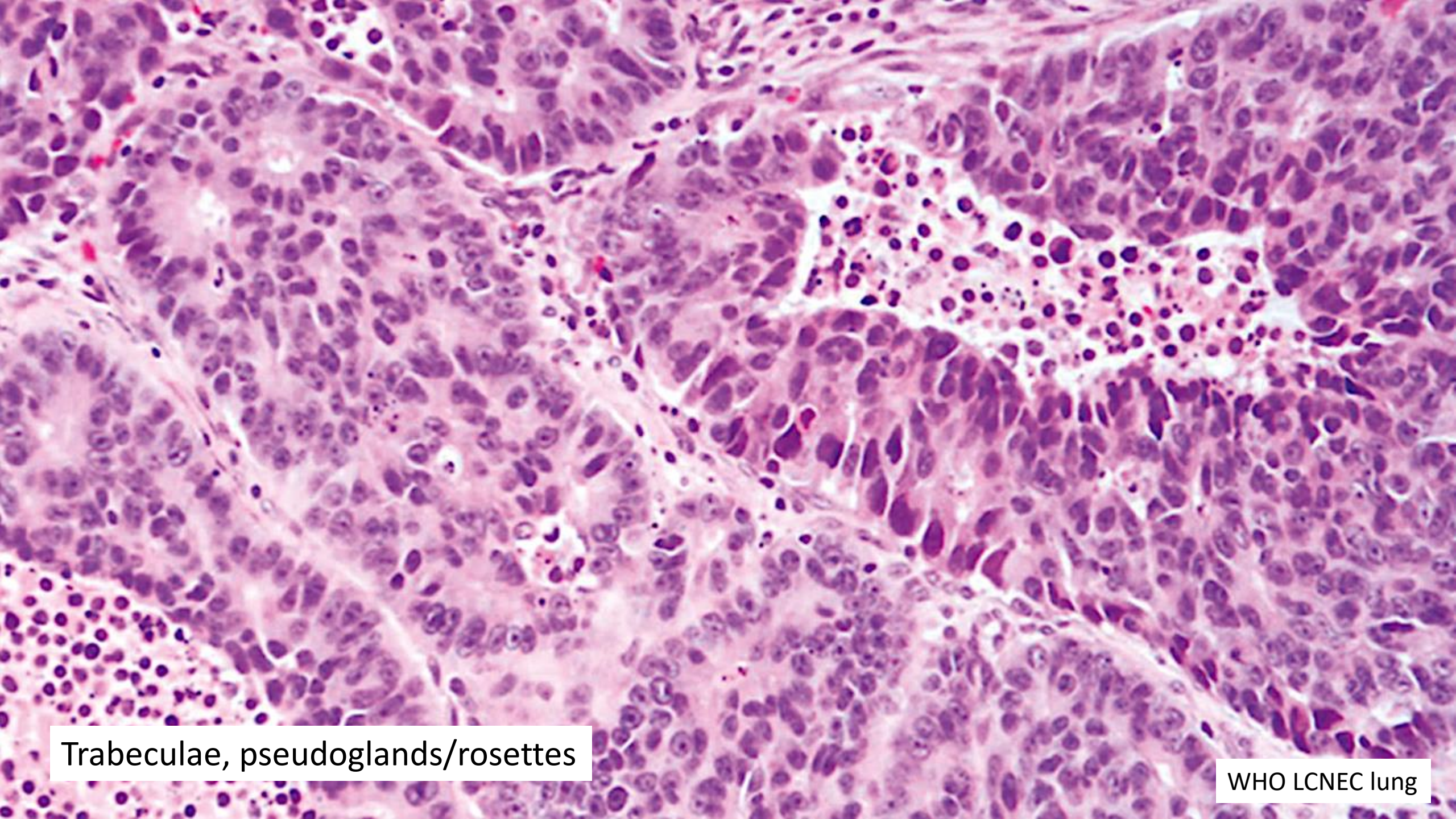
Trabeculae, pseudoglands/rosettes
WHO LCNEC lung

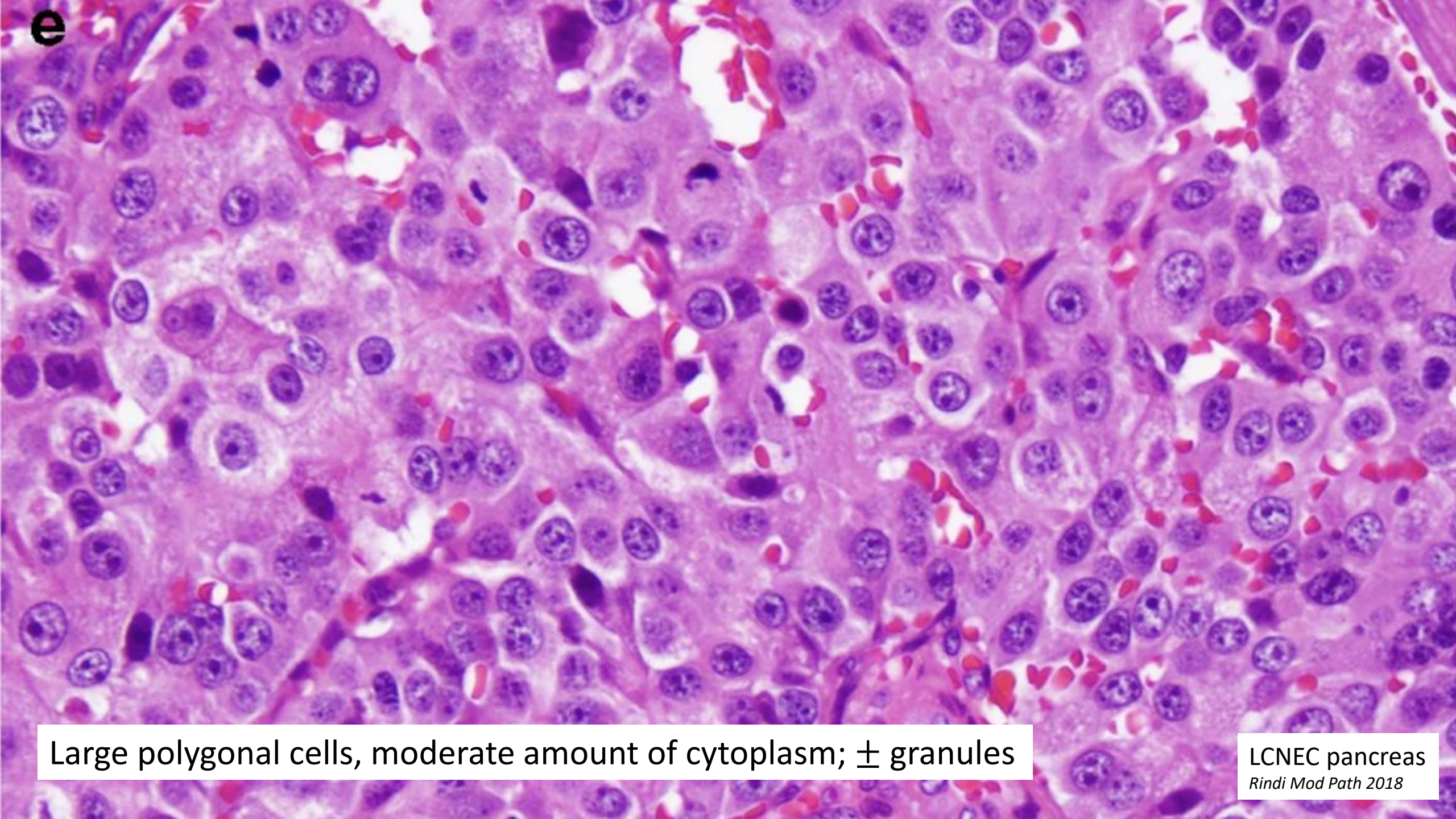

Large polygonal cells, moderate amount of cytoplasm; ± granules

LCNEC pancreas

Rindi Mod Path 2018

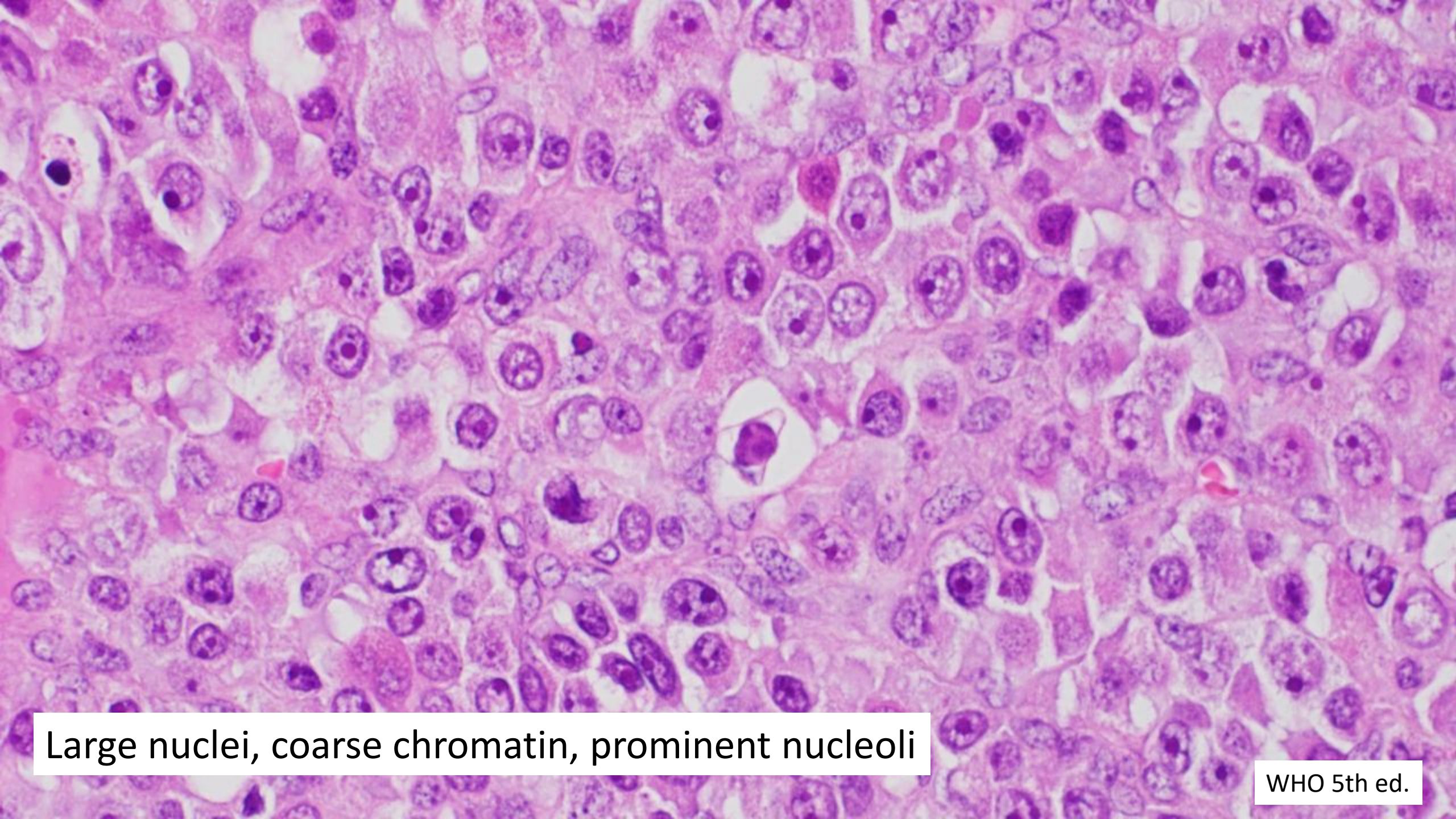
Large nuclei, coarse chromatin, prominent nucleoli
WHO 5th ed.

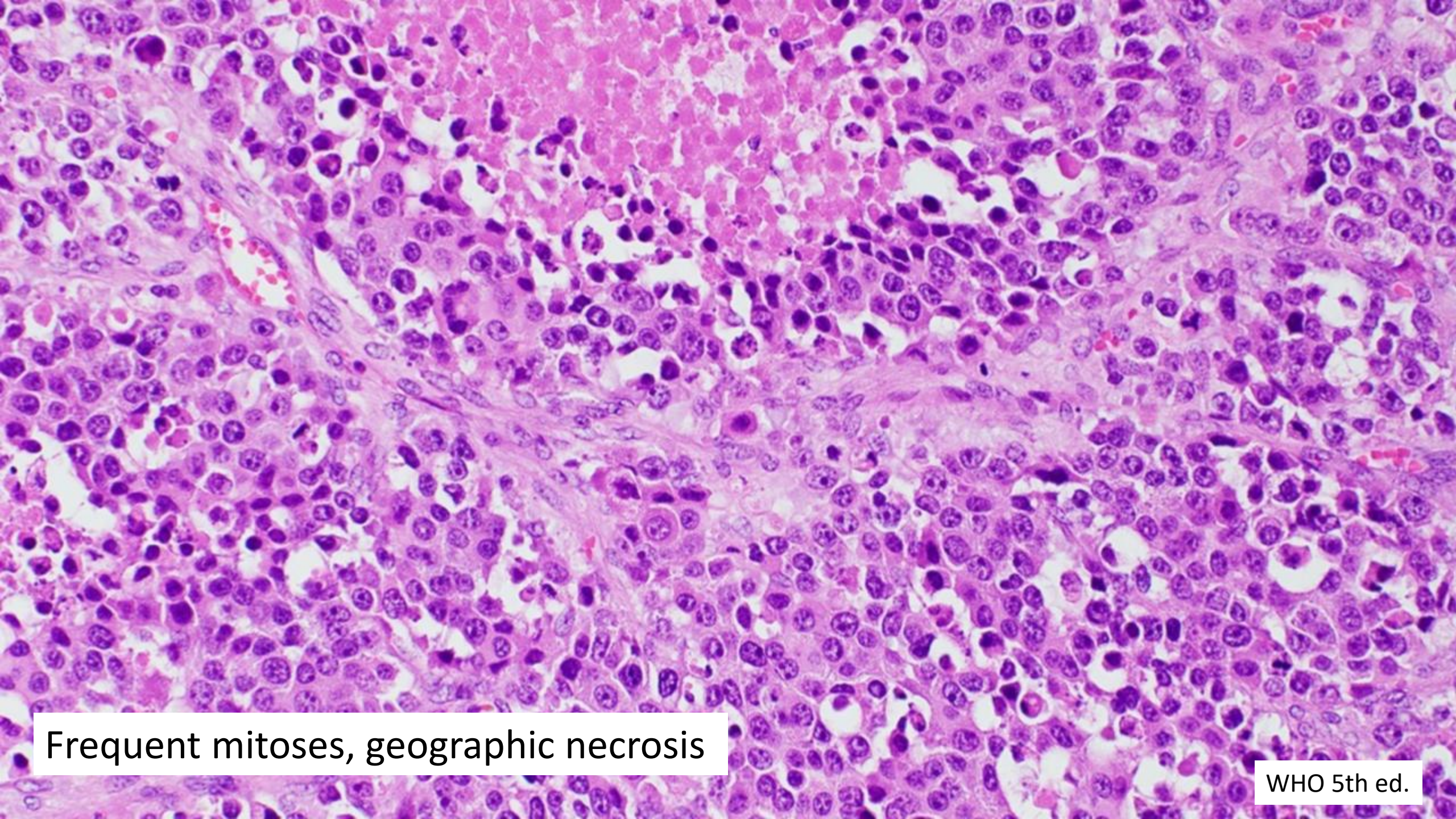
Frequent mitoses, geographic necrosis
WHO 5th ed.

Large cell neuroendocrine carcinoma

Essential: high-grade neuroendocrine histomorphology with **expression of at least one neuroendocrine marker** *WHO 5th ed.*

If **CD56** is the only marker expressed, typical LCNEC histology required

Most LCNECs **diffusely positive** with broad spectrum cytokeratins

NE marker expression occurs in poorly differentiated carcinomas, often focal

Without appropriate morphology - NOT diagnostic of NEC

- Does not indicate NE differentiation

Mixed carcinoma and NEC / MiNEN

Cervix:

HPVA endocervical adenocarcinoma is most common; usual or intestinal type

HPVA SCC less common

Rare: HPVI gastric type adenocarcinoma, HPVI mesonephric, adenoid basal

Endometrium:

Endometrioid followed by serous carcinoma

Ovary:

Any ovarian epithelial tumour type

Even a small NEC component conveys an adverse outcome
Document the individual tumour types and their approximate percentages

Horn Ann Diagn Pathol 2006, Wei Diagn Pathol 2024

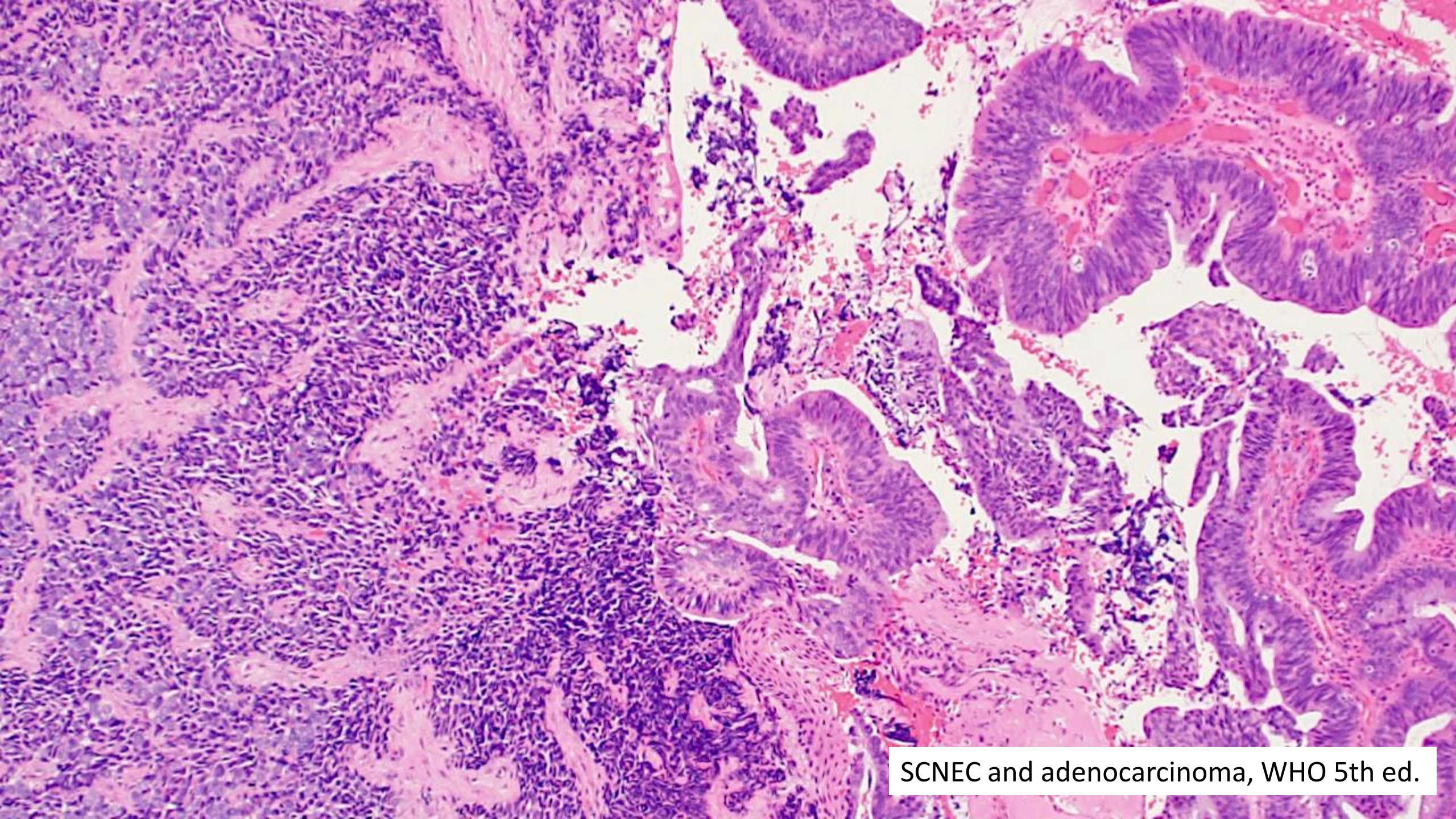
SCNEC and adenocarcinoma, WHO 5th ed.

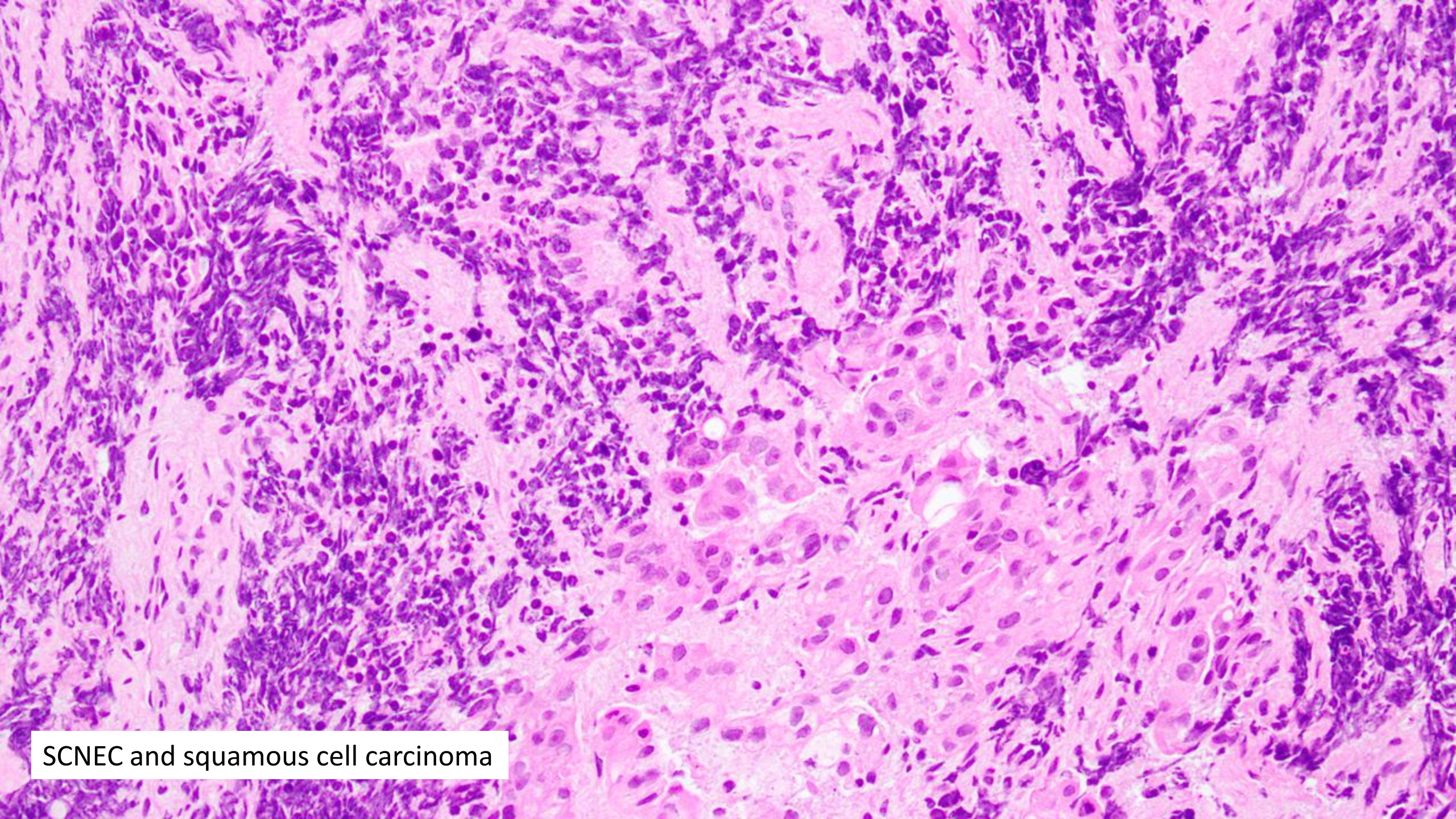
SCNEC and squamous cell carcinoma

Immunohistochemistry

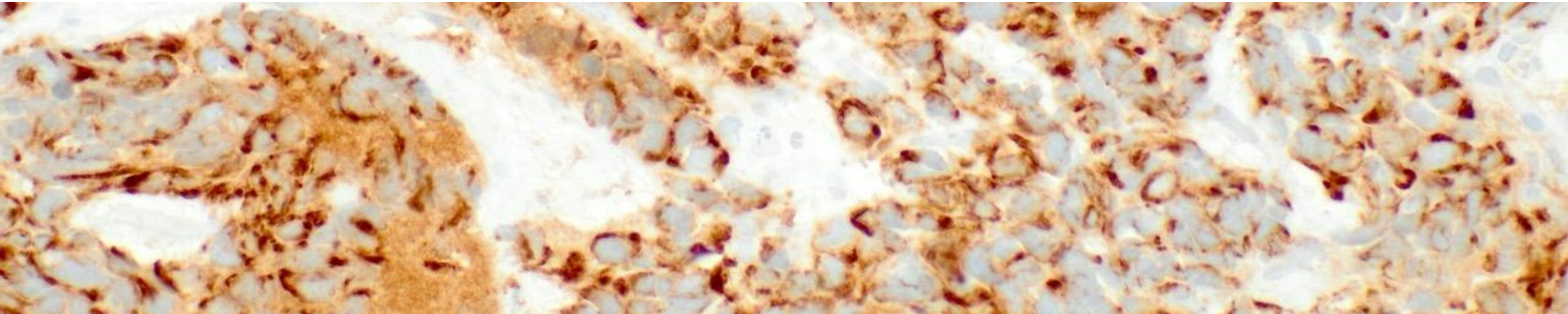

Traditional neuroendocrine markers

Chromogranin A (CRG): MORE SPECIFIC

Synaptophysin (SYN): MORE SENSITIVE

NET: Expect diffuse strong CRG and/or SYN; if not question the Dx
NEC: Significant subset are CRG/SYN negative (~¼)

CD56 (NCAM): Sensitive but LACKS SPECIFICITY

Only considered evidence of NE differentiation if appropriate histology, especially if the only marker staining

All sub-optimally sensitive and specific - combined use recommended

Combined data, sensitivity in cervix: SCNEC 66%, **79%**, 61%+ (CRG, SYN, CD56)
LCNEC 66%, 82%, **88%**+

McCluggage AJSP 2010 and AJSP 2020, Bellizzi Hum Pathol 2020, Zou AJSP 2021

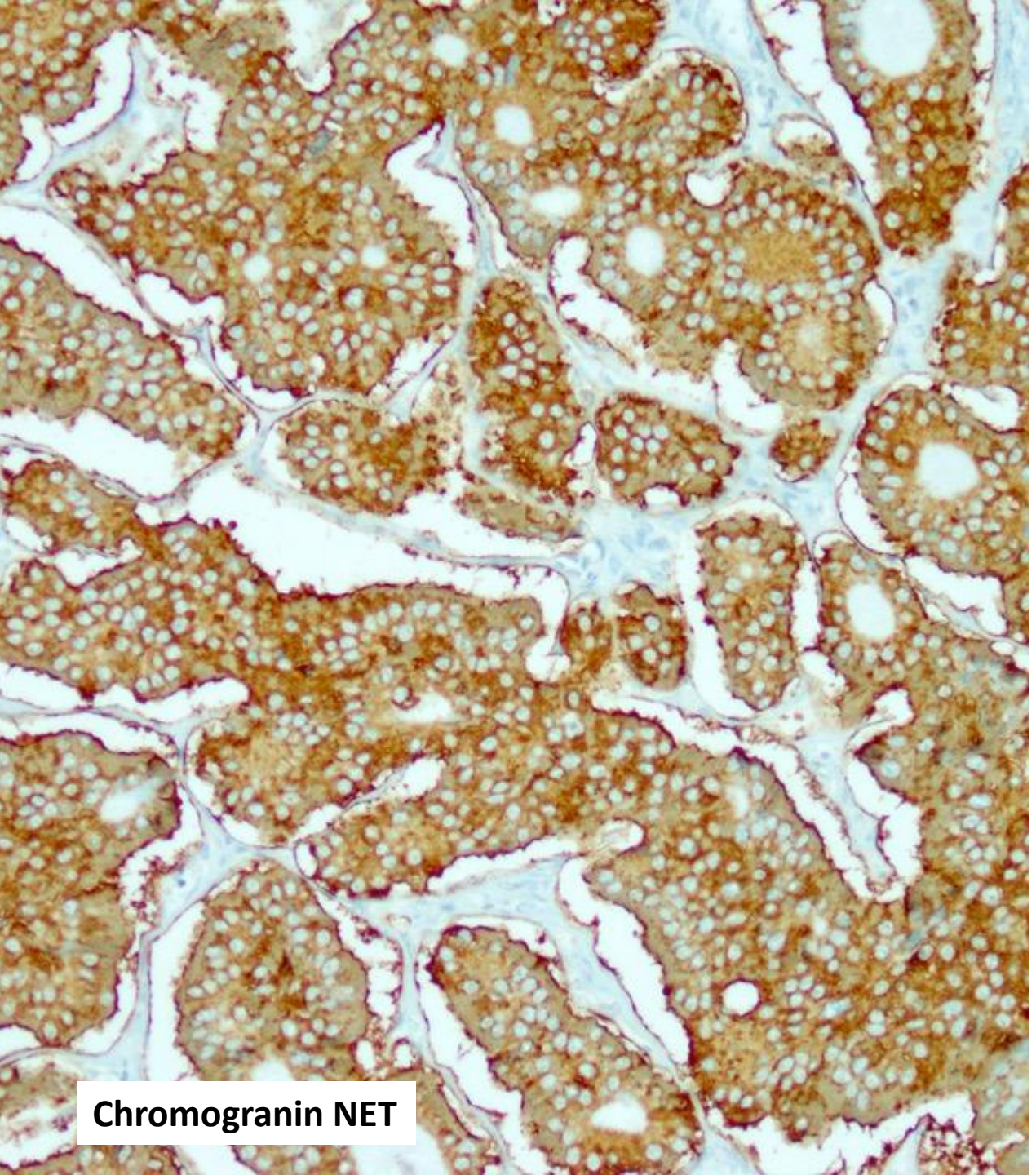

Chromogranin NET

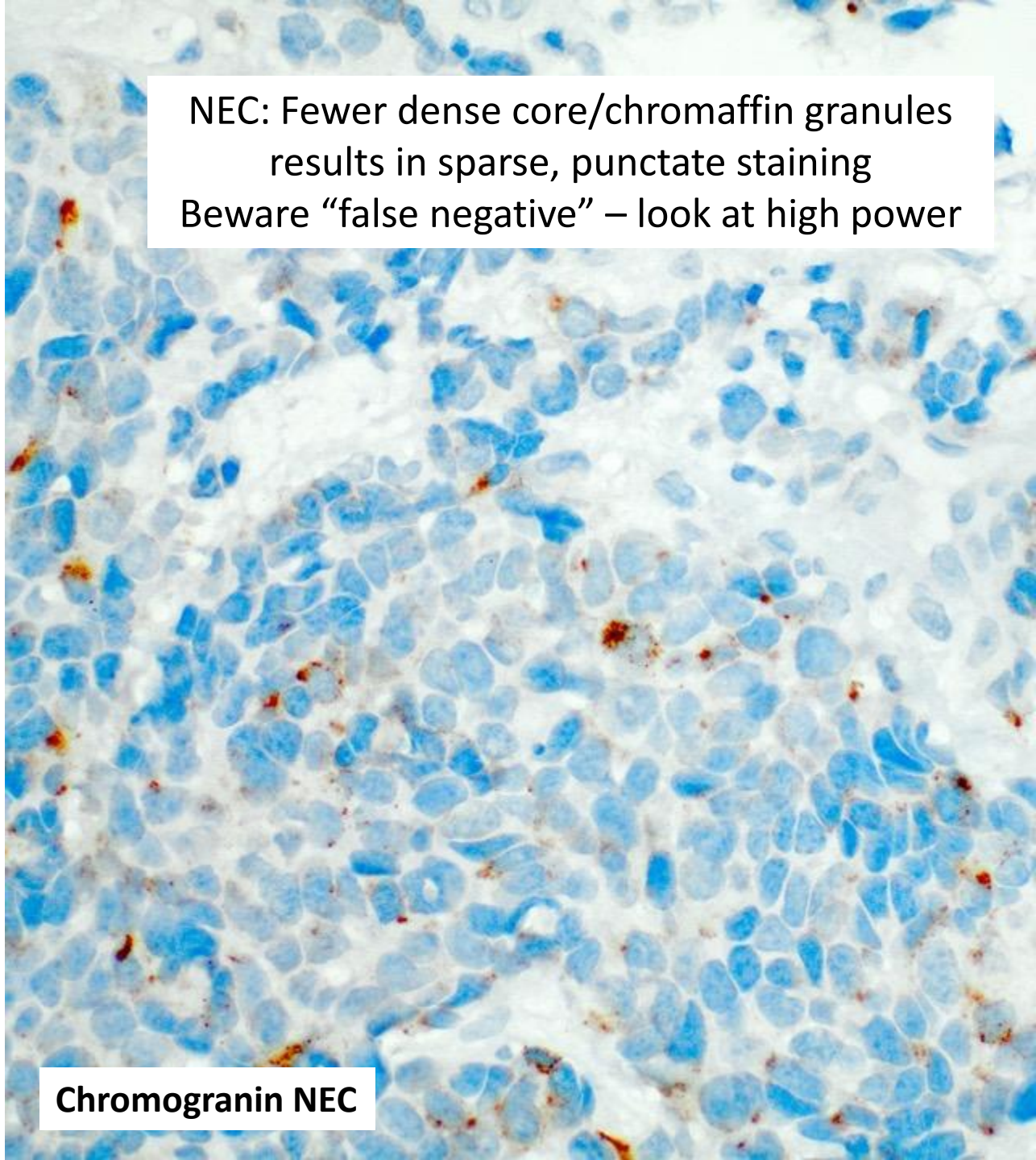

NEC: Fewer dense core/chromaffin granules results in sparse, punctate staining
Beware “false negative” – look at high power

Chromogranin NEC

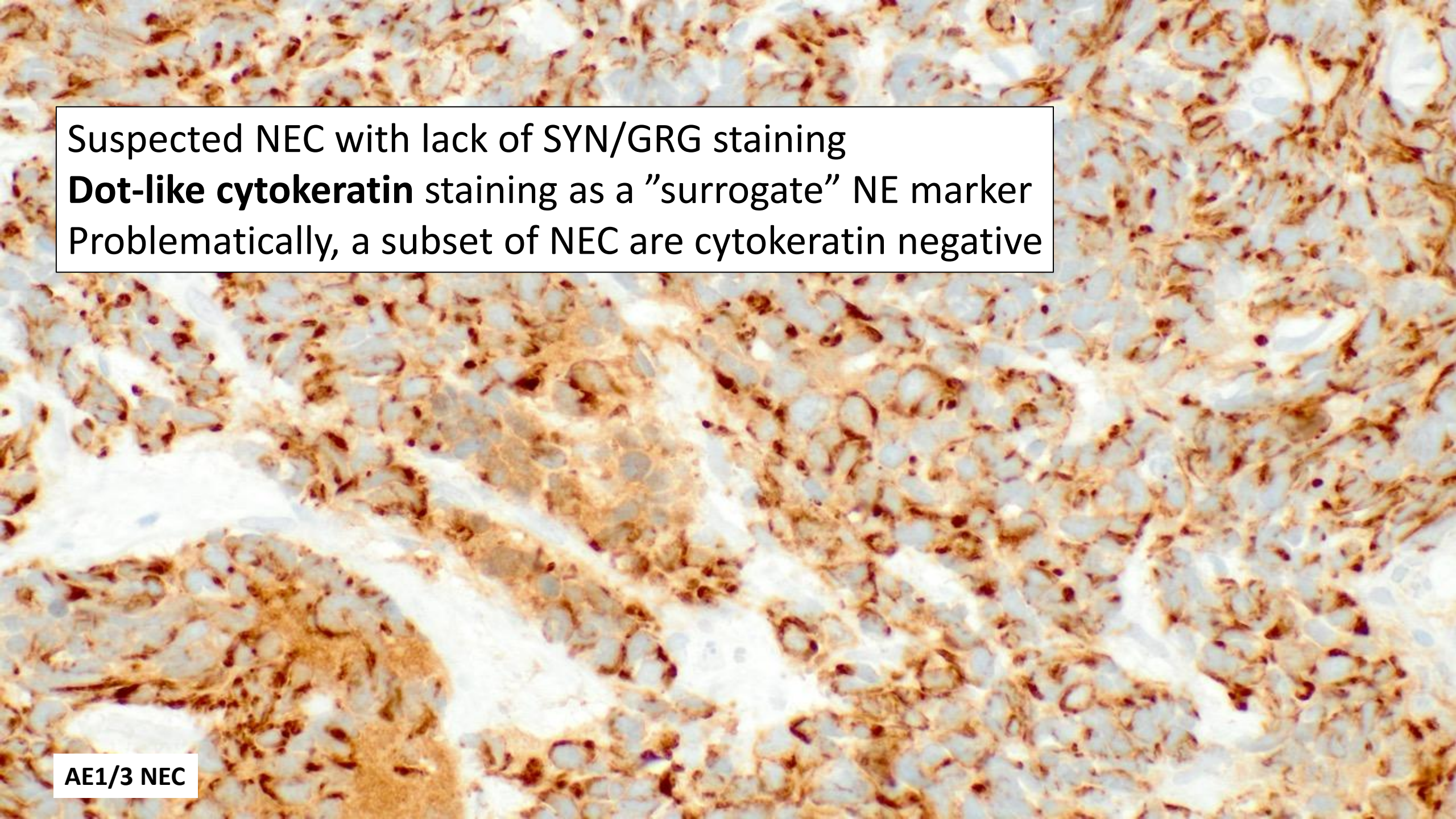
Suspected NEC with lack of SYN/GRG staining
Dot-like cytokeratin staining as a ”surrogate” NE marker
Problematically, a subset of NEC are cytokeratin negative
AE1/3 NEC

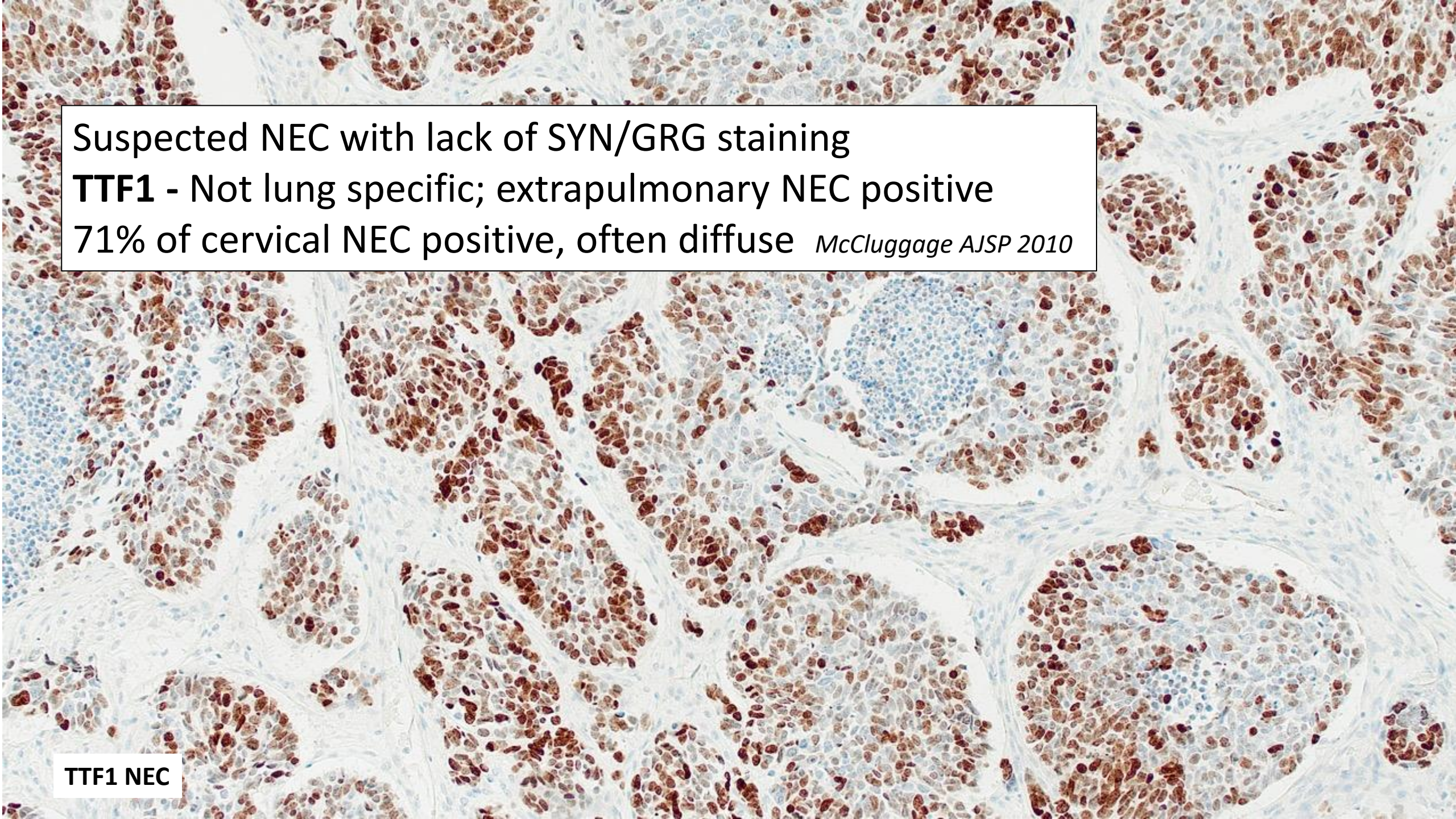
Suspected NEC with lack of SYN/GRG staining
TTF1 - Not lung specific; extrapulmonary NEC positive
71% of cervical NEC positive, often diffuse *McCluggage AJSP 2010*
TTF1 NEC

New markers

INSM1: Transcription factor associated with NE differentiation; nuclear stain

Reported excellent sensitivity and specificity for NEN in many sites

More sensitive than traditional NE markers in NEC

Rb: Rb inactivation is a hallmark of SCNEC lung and a sensitive NEC marker

Others: CXCR4 (overexpressed in >80% of NEC), clusterin, SSTR2a

Don't forget MMR: Subset of endometrial and cervical NEC are MMRd

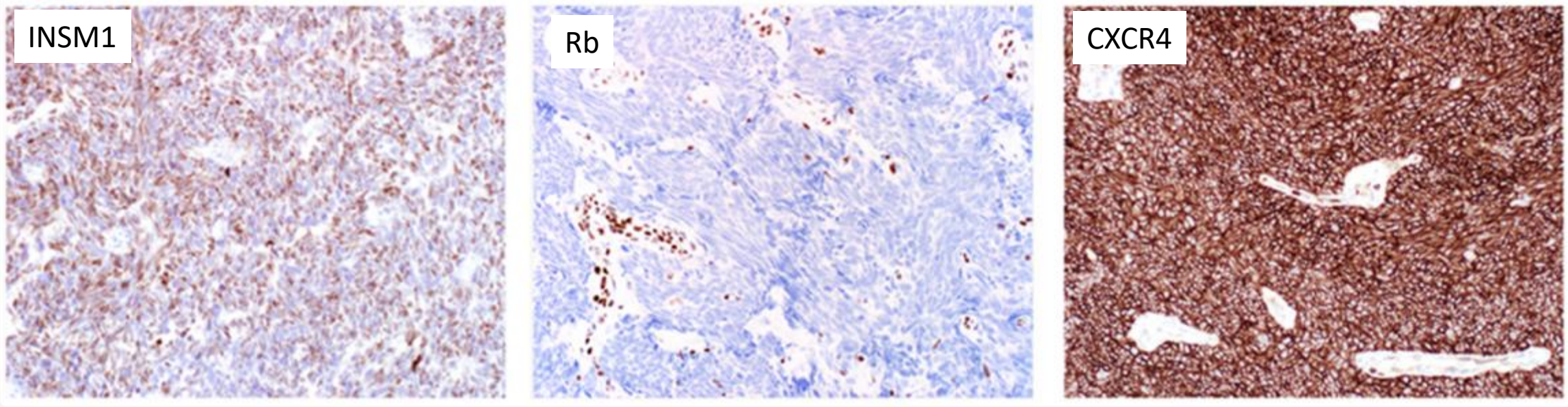

Bellizzi Hum Pathol 2020

Insulinoma-associated Protein 1 Expression and Its Diagnostic Significance in Female Genital Tract Neuroendocrine Carcinomas

IJGP 2021

Ching-Heng Ting, M.D., M.S., Tao-Yeuan Wang, M.D., and Pao-Shu Wu, M.D., Ph.D.

49 NEC – 39 cervix, 5 endometrium, 4 vagina, 1 ovary
Whole tissue sections - INSM1, CRG, SYN, CD56, TTF1

Cervix, small cell NEC: **INSM1 97% positive**; highest sensitivity, intensity/H score

cf. CD56 55%+, SYN 73%+, CRG 82%+, TTF1 77%+

Cervix, large cell NEC: **INSM1 67% positive** (only 6 cases), less than CD56, SYN

Endometrial NEC: INSM1 only focal/weak staining, less than CD56, SYN

Conclusions: INSM1 a useful first line stain in suspected SCNEC cervix

Negative INSM1 does not exclude NEC, especially LCNEC

INSM1 has **no diagnostic value** in the endometrium

INSM1 Is Less Sensitive But More Specific Than Synaptophysin in Gynecologic High-grade Neuroendocrine Carcinomas

An Immunohistochemical Study of 75 Cases With Specificity Test and Literature Review

AJSP 2021

Qiong Zou, MD, Lily Zhang, MD,† Zhiqiang Cheng, MD,‡ Xiaojing Guo, MD,‡ and Dengfeng Cao, MD, PhD†*

Also analysed specificity: Compared 75 NEC to 422 non-NE gyn tumours

75 NEC; 41 cervix, 24 endometrium, 5 ovary

Whole sections and TMAs for most non-NE

INSM1 positive in 92% of NEC; only synaptophysin scored higher at 96%

(and stained more cells); CRG 81%, CD56 69%

Of 422 non-NE tumours (most TMAs): **5% positive for INSM1**

CRG 18%, SYN 19%, CD56 25%

→**Synaptophysin more sensitive than INSM1**

→**INSM1 is more specific** than all traditional markers – 95% specificity

→Again, **more sensitive in cervix vs. other gyn sites** 100% vs. 82%

INSM1 Is Less Sensitive But More Specific Than Synaptophysin in Gynecologic High-grade Neuroendocrine Carcinomas

An Immunohistochemical Study of 75 Cases With Specificity Test and Literature Review

AJSP 2021

Qiong Zou, MD, Lily Zhang, MD,† Zhiqiang Cheng, MD,‡ Xiaojing Guo, MD,‡ and Dengfeng Cao, MD, PhD†*

Also analysed specificity: Compared 75 NEC to 422 non-NE gyn tumours

75 NEC; 41 cervix, 24 endometrium, 5 ovary

Whole sections and TMAs for most non-NE

Which non-neuroendocrine tumours were positive?

INSM1: Undifferentiated endometrial carcinoma - 40%

Ovarian mucinous borderline/carcinoma – 18%

Immature teratoma (neuroepithelium) – 79%

Usually focal staining (except immat. teratoma)

CRG: Mostly endometrial carcinomas, ovarian epithelial tumours – especially uterine endometrioid, sometimes extensive

Less non-specific NE staining in cervix than endometrium/ovary

Expression of neuroendocrine markers in non-neuroendocrine endometrial carcinomas

August W. Moritz[1], Matthew P. Schlumbrecht[2], Mehrdad Nadji[1], Andre Pinto[1]

Pathology 2019

[1]*Department of Pathology, University of Miami Miller School of Medicine, Miami, FL, United States;* [2]*Department of Obstetrics and Gynecology, Division of Gynecological Oncology, University of Miami Miller School of Medicine, Miami, FL, United States*

Endometrium

71 endometrial carcinomas; Endometrioid 26, CCC 12, serous 20, un/dediff 3, CS 10
Whole sections SYN, CRG, CD56, TTF1

Expression relatively common in non-NE endometrial carcinomas

66% of cases; most often **focal** staining for a **single marker** (<25% of cells)

Most often CD56: 58% of tumours vs. 7% for SYN, 28% CRG, 24% TTF1

Most likely to express NE markers: Carcinosarc 100%, Serous 80%

Least likely: Clear cell carcinoma

Recommend use of >1 NE marker; **CRG and SYN co-expression rarely seen**

Original Article *IJGP 2023*

Neuroendocrine Marker Expression in Primary Non-neuroendocrine Epithelial Tumors of the Ovary: A Study of 551 Cases

Michaela Kendall Bártů, M.D., Ph.D., Kristýna Němejcová, M.D. Ph.D., Romana Michálková, Ph.D., Quang Hiep Bui, M.D., Jana Drozenová, M.D., Pavel Fabian, M.D., Ph.D., Oluwole Fadare, M.D., Jitka Hausnerová, M.D., Jan Laco, M.D., Ph.D., Radoslav Matěj, M.D., Ph.D., Gábor Méhes, M.D., Ph.D., Adam Šafanda, M.D., Naveena Singh, M.D., Petr Škapa, M.D., Ph.D., Zuzana Špůrková, M.D., Simona Stolnicu, M.D., Ph.D., Marián Švajdler, M.D., Ph.D., Sigurd F. Lax, M.D., Ph.D., W. Glenn McCluggage, M.D., and Pavel Dundr, M.D., Ph.D.

Ovary

551 ovarian epithelial neoplasms
INSM1, SYN, CRG, CD56 on TMA

Generally limited, focal staining, rarely diffuse

Most frequent positive:

- **Mucinous tumours, especially MBT**
- GI phenotype, expect NE elements
- Scattered along base of glands

CD56+: 26% of high-grade serous carcinoma

Mucinous carcinoma (A) and MBT (B-D)

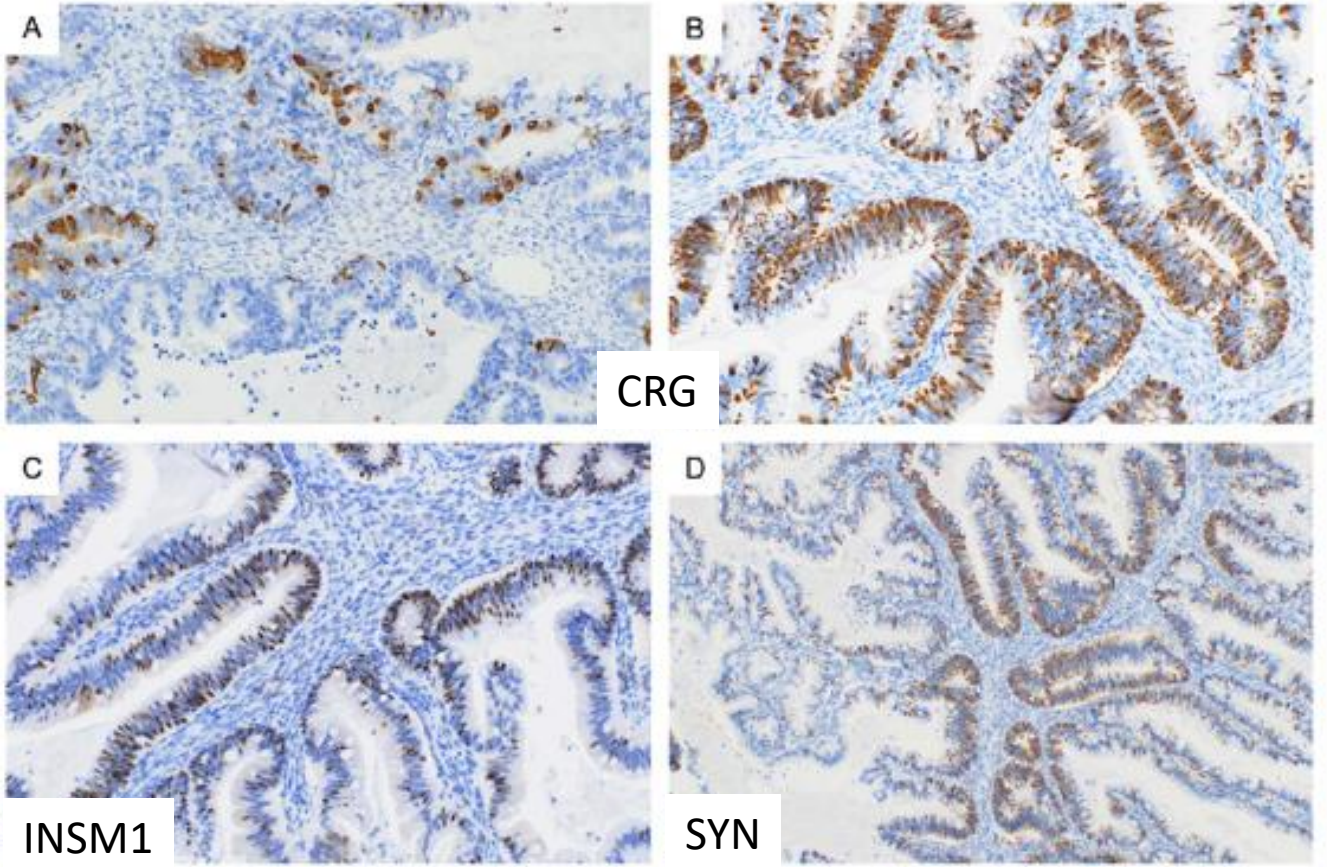

Immunohistochemistry - pitfalls

p16: Block-type/diffuse expression in cervical NEC, reflecting HRHPV

Also see p16 block-type in HPV-independent NEC *not due to HPV*

HPV molecular testing to resolve

NEC cervix may show SATB2+ CK20+, CDX2+, p63+ and CK7- PAX8-

PAX 8 (poly): Expression in GI, pancreatic, lung NETs

PR: Expression in pancreatic and lung NET (58%, 7%)

CK20, neurofilament, CD99 membranous: May be positive in cervical NEC

Pocrnich AJSP 2016, Howitt AJSP 2020, Bellizzi Hum Pathol 2020, Katafuchi IJGP 2021, McCluggage 2010, Inzani Virchow Arch 2022

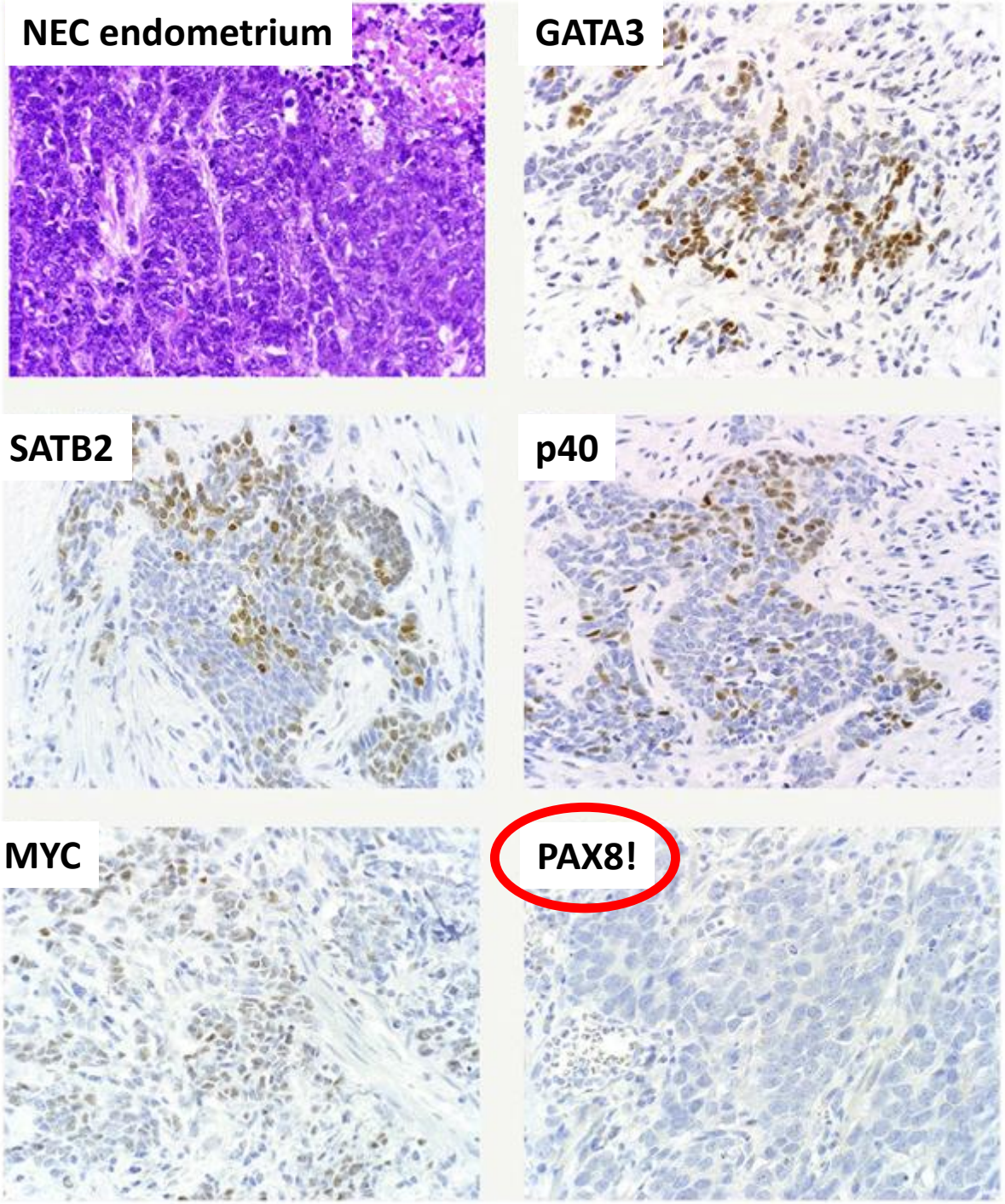

Hans popper society current topic

Immunohistochemistry in the diagnosis and classification of neuroendocrine neoplasms: what can brown do for you? ☆

Andrew M Bellizzi MD

Hum Pathol 2020

NECs tend to express multiple transcription factors e.g. PAX 8, TTF-1, SATB2, p40 independent of site

Staining typically patchy but can be diffuse

Transcription factors should not be used to assign site of origin in metastatic NEC of unknown primary

Genomic features

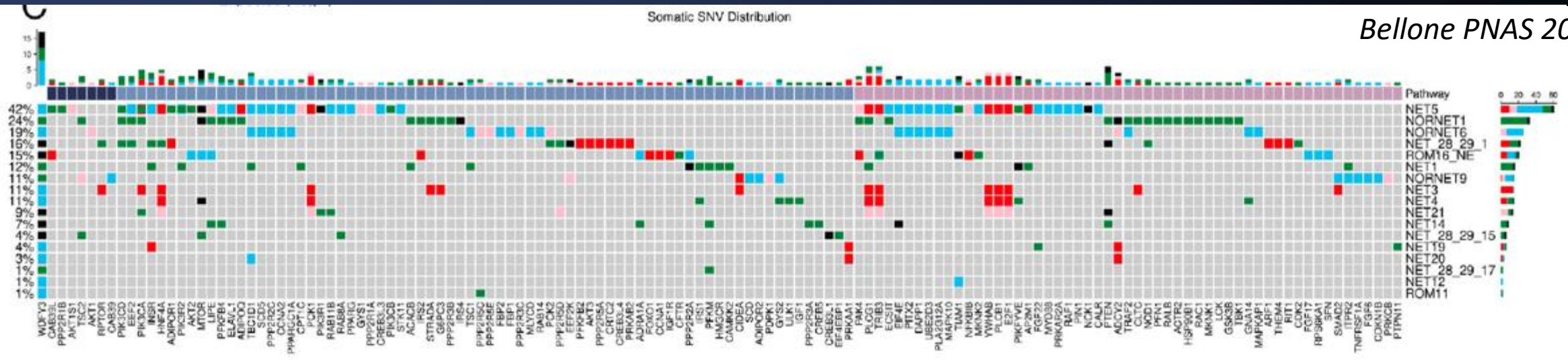

Bellone PNAS 2024

SCNEC and LCNEC are molecularly distinct

Molecular hallmark of SCNEC is co-mutation of *TP53* and *RB1*
seen in lung, GI, pancreas

Large cell NEC has 2 molecular groups:

small cell like (*TP53 & Rb* loss) ~ 40%
or non-small cell cancer like (*STK11, KRAS, KEAP1 etc*)

Genomic data on LCNEC outside the lung is scant although similar trends emerging in GI/pancreas. May have treatment implications for LCNEC

Bellizzi Hum Pathol 2020. Ordulu AJSP 2022, Rekhtman Clin Cancer Res 2016, Esfahani Front Oncol 2021

Morphologic and Molecular Heterogeneity of Cervical Neuroendocrine Neoplasia

A Report of 14 Cases

Zehra Ordulu, MD, Mari Mino-Kenudson, MD,* Robert H. Young, MD, FRCPath,* Koen Van de Vijver, MD, PhD,†‡ Gian Franco Zannoni, MD,§ Ana Félix, MD, PhD,‖ Eike Burandt, MD,¶ Adele Wong, MB, BCh, BAO,# Valentina Nardi, MD,* and Esther Oliva, MD**

AJSP 2022

14 cases; IHC, HRHPV ISH, targeted sequencing
6 SCNEC, 6 LCNEC, 2 NET, 5 NEC admixed with HPVA adenoca; 2 sequenced
Most HPV 16/18+, 3 HPV neg, all were SCNEC

Molecular pathways in female genital tract NEC differ to NEC in other sites and are closer to usual cervical cancers

– yet treated largely according to SCNEC lung

Most NECs: Molecular alterations overlapping with cervical carcinoma - PI3K/MAPK

A subset, 3/6 SCNEC: Co-mutation *TP53 & Rb1* (molecular signature SCNEC lung/GI/panc)

Enriched in HPV-negative SCNEC

NEC admixed with carcinoma: Shared alterations, supports clonality (as in endometrium, lung, GI)

NETs lacked any significant alterations; genomically silent

PNAS RESEARCH ARTICLE | MEDICAL SCIENCES

2024

Integrated mutational landscape analysis of poorly differentiated high-grade neuroendocrine carcinoma of the uterine cervix

Stefania Bellone[a,1], Kyungjo Jeong[b,1], Mari Kyllesø Halle[c,d], Camilla Krakstad[c,d], Blair McNamara[a], Michelle Greenman[a], Levent Mutlu[a], Cem Demirkiran[a], Tobias Max Philipp Hartwich[a], Yang Yang-Hartwich[a], Margherita Zipponi[a], Natalia Buza[e], Pei Hui[e], Francesco Raspagliesi[f], Salvatore Lopez[f,2], Biagio Paolini[f], Massimo Milione[f], Emanuele Perrone[g], Giovanni Scambia[g], Gary Altwerger[a], Antonella Ravaggi[h], Eliana Bignotti[h], Gloria S. Huang[a], Vaagn Andikyan[a], Mitchell Clark[a], Elena Ratner[a], Masoud Azodi[a], Peter E. Schwartz[a], Charles M. Quick[i], Roberto Angioli[j], Corrado Terranova[j], Samir Zaidi[k], Shuvro Nandi[l], Ludmil B. Alexandrov[l], Eric R. Siegel[m], Jungmin Choi[b,3], Joseph Schlessinger[n,3], and Alessandro D. Santin[a,3]

Largest cohort studied; 64 cervical NEC, whole exome and RNA sequencing

66% HPVA – **one third are HPV-independent**

In mixed tumours, adenocarcinoma and NEC derive from a common precursor with mutations typical of adenocarcinoma

Actionable treatment pathways identified; promising response to combination targeted therapy (pan-HERi, PIK3CAi, ATRi) in patient-derived xenografts

Cervical neuroendocrine neoplasia

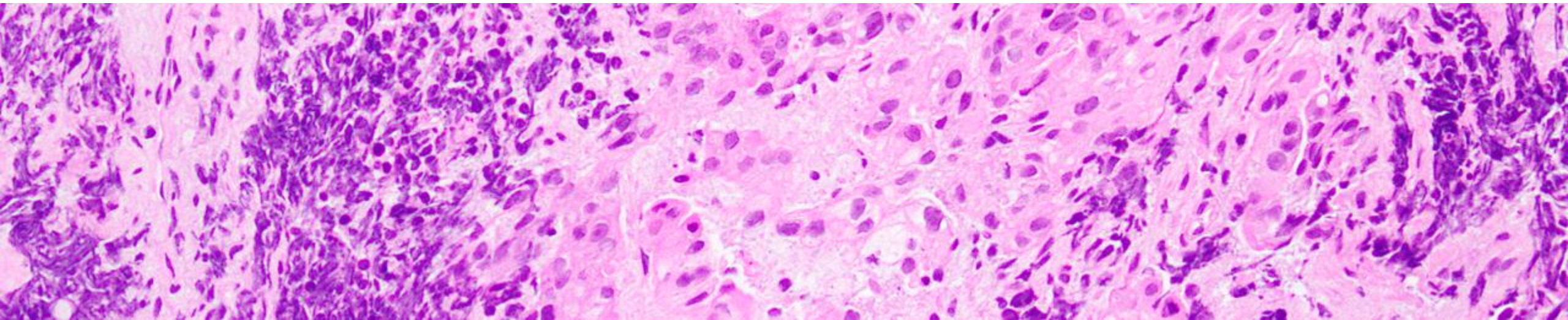

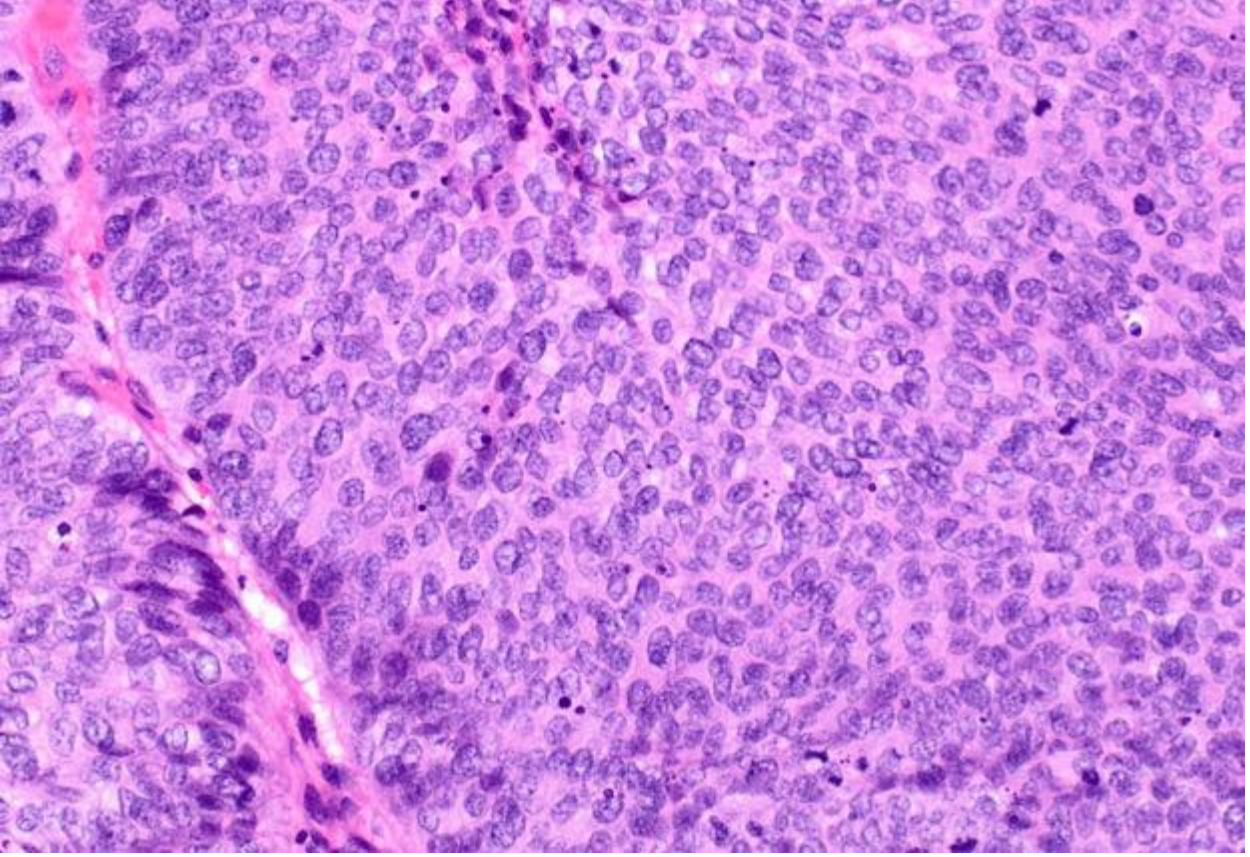

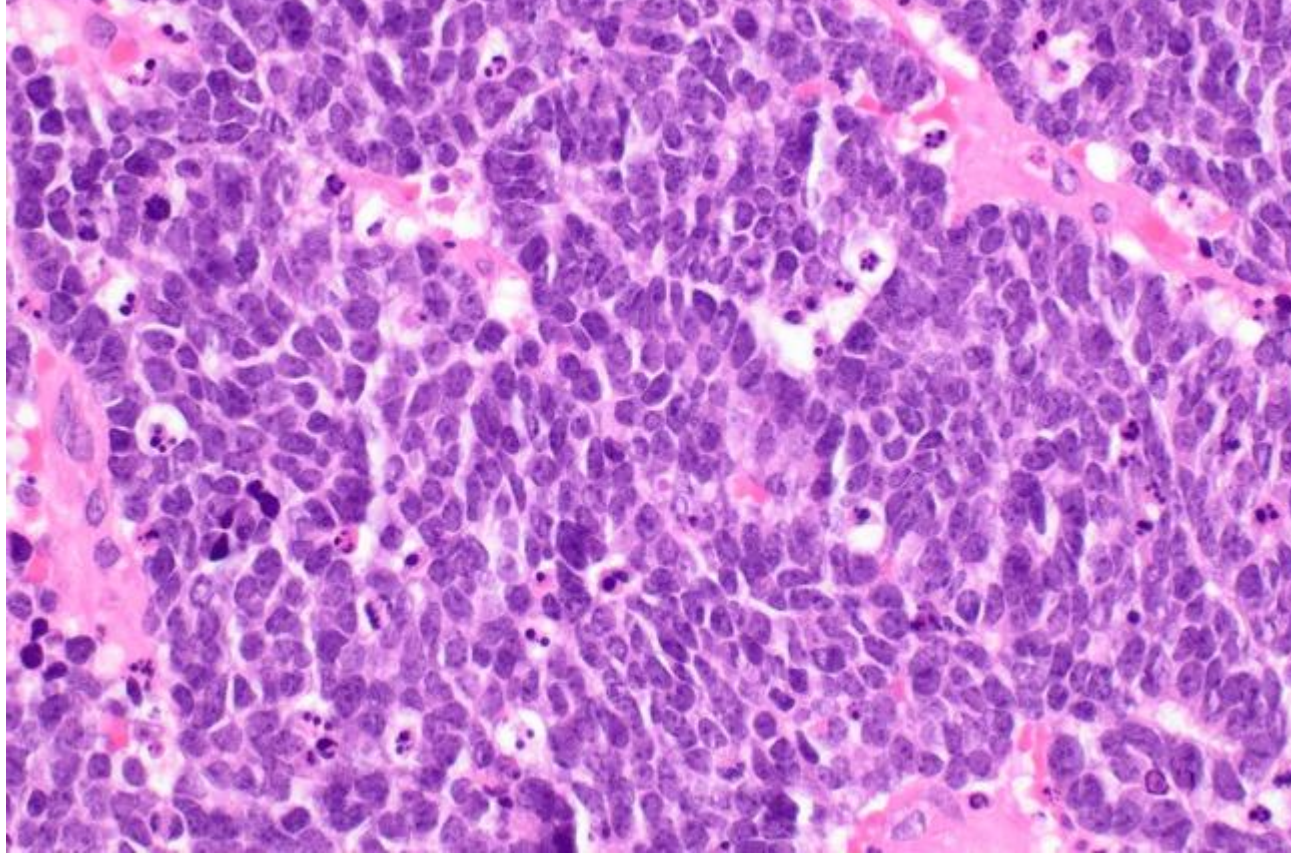

Small cell NEC vs. squamous cell carcinoma cervix

HPVA, non-keratinising/basaloid sq cell ca

- Both HPVA (mostly), p16 diffuse positive

- p40, p63 may both be positive in NEC and **sometimes p63 is diffuse** - *McCluggage AJSP 2010*

- Squamous cell carcinoma negative with NE markers

Small versus large cell NEC

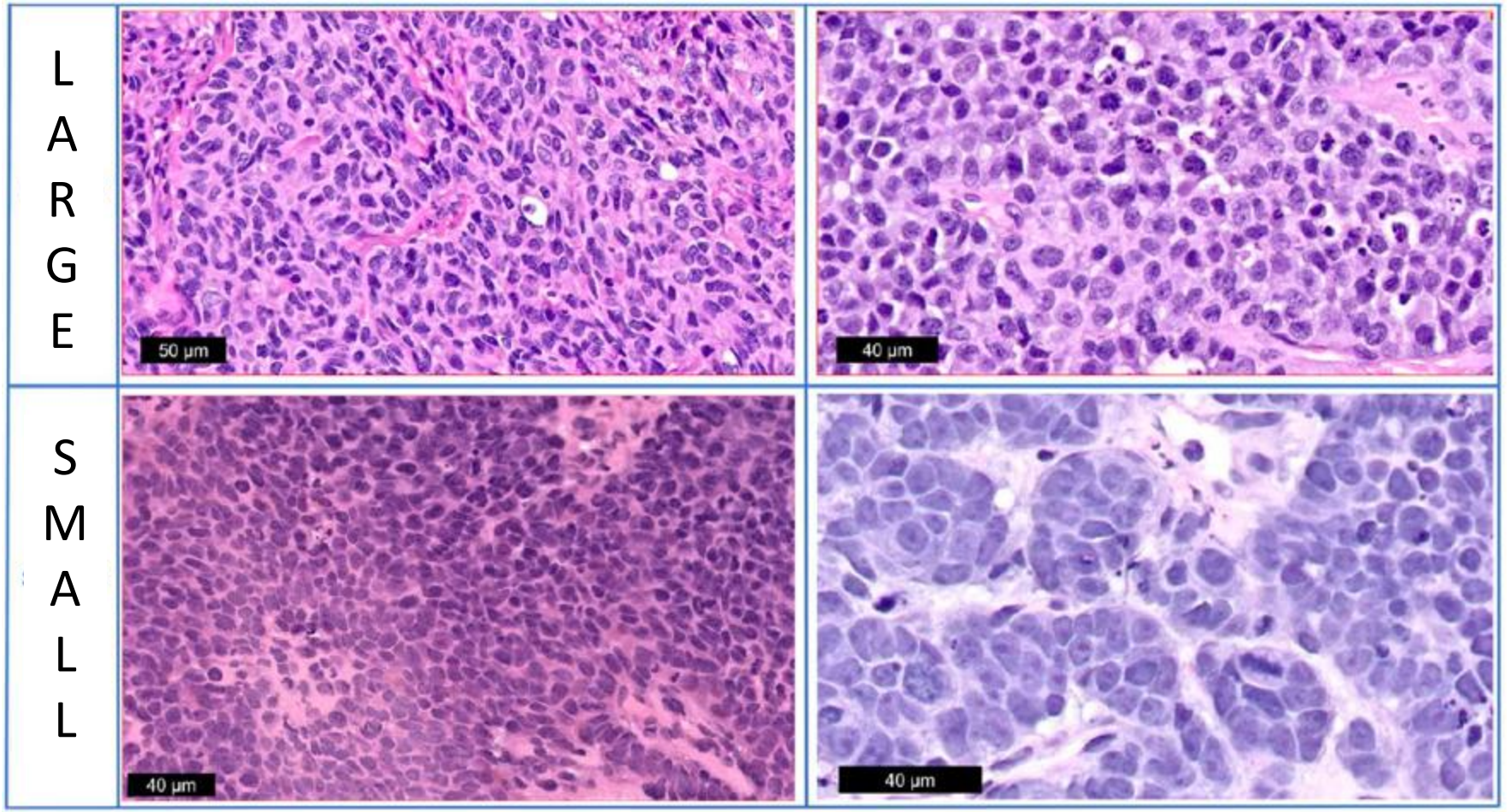

More cytoplasm
More pleomorphism
Nucleoli
Vesicular chromatin
Geographic necrosis

Moulding
Different nuclear features (classically)

Suggest diagnose as “neuroendocrine carcinoma”

Lamiman IJGP 2024, Ordulu AJSP 2022

Poorly differentiated carcinoma cervix, ambiguous NE features

Large cell neuroendocrine carcinoma?

or

Poorly differentiated squamous or adenoca?

or

Mixed LCNEC-non-NEC cervix?

p16: Does not distinguish NEC from HPVA carcinoma

p63, p40: Expression occurs in NEC
p63 may be diffuse

High-grade tumour, lineage uncertain – some advocate a low threshold for NE marker staining

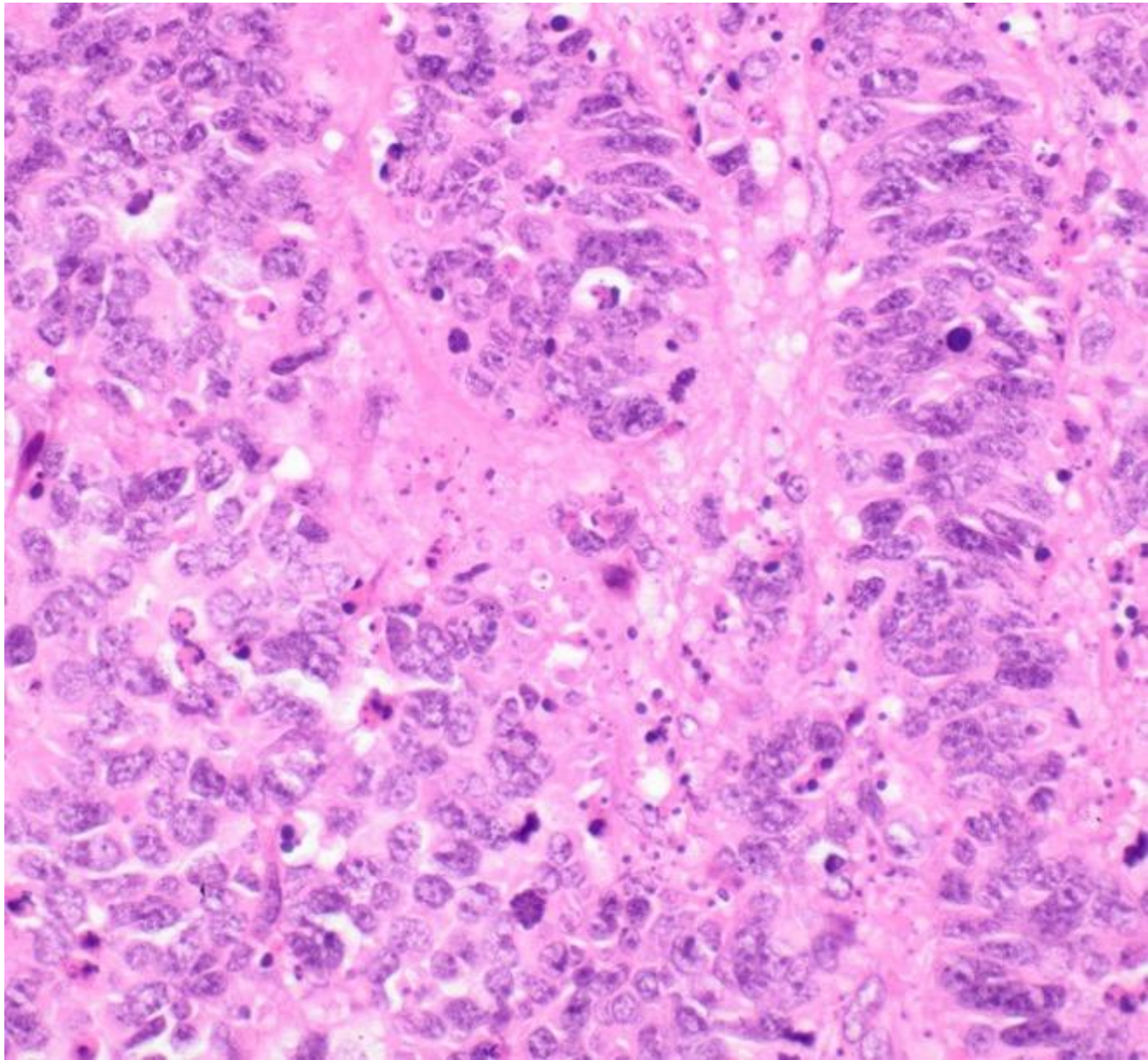

Lamiman IJGP 2024, Bellizzi Hum Pathol 2020

Poorly differentiated carcinoma *with neuroendocrine marker expression*

Neuroendocrine marker expression occurs in this context

- Best described in lung and colon cancer, rates of 10—20%
- Adenocarcinoma > squamous

Scattered positive cells is not proof of diagnosis of neuroendocrine carcinoma. *Significant* marker positivity is required for diagnosis of LCNEC

Bellizzi Hum Pathol 2020

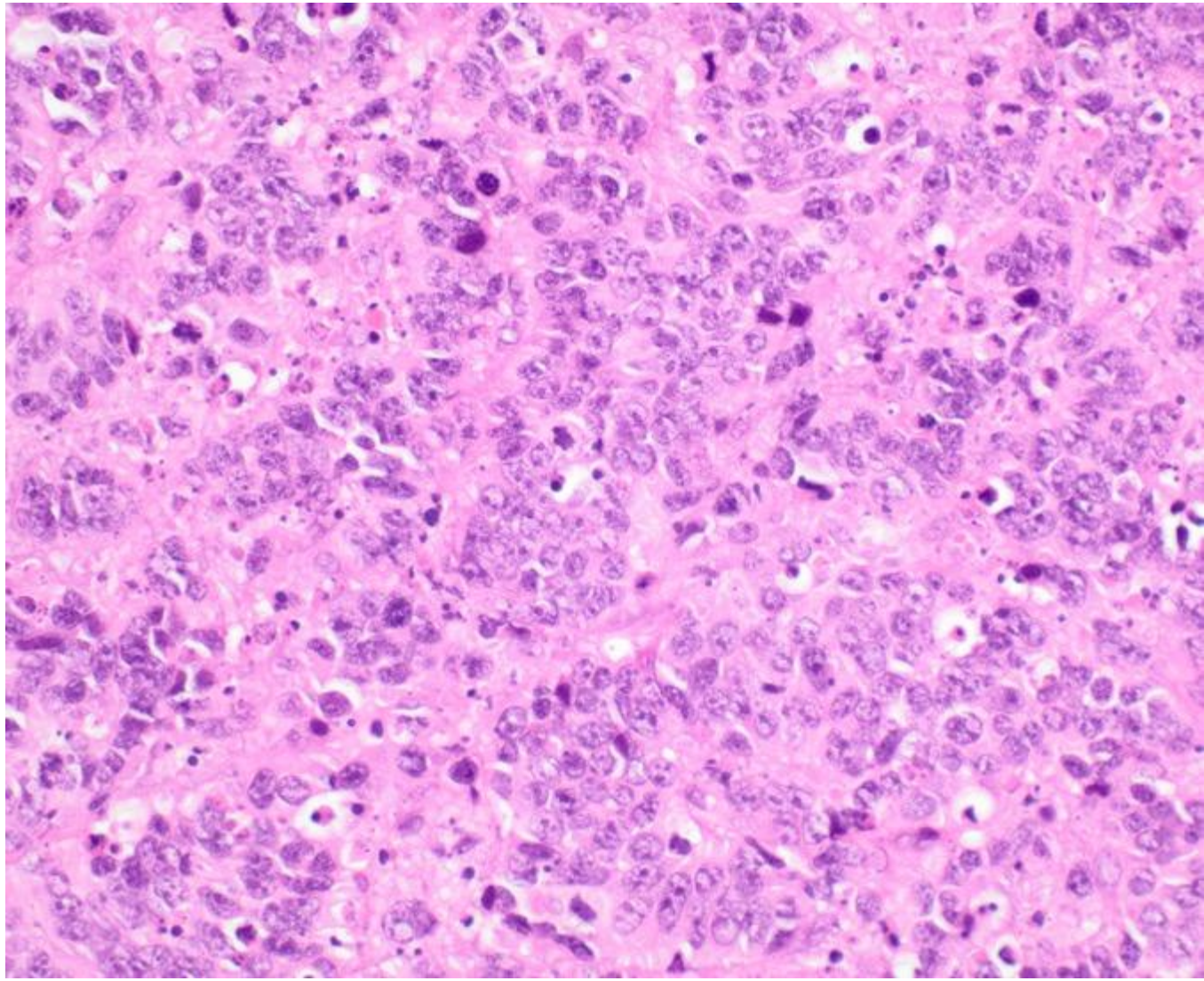

Strategies, approach

Diagnosis of NEC should be based on morphology, not NE IHC alone, *noting:*

- Spectrum of appearance of small cell NEC probably broader than textbooks
- Large cell NEC does overlap with ”poorly differentiated carcinoma”

Suggested strategies:

- Arbitrary threshold: > 30% of cells with moderate staining before seriously consider NEC *(advocated by Bellizzi)* … WHO 4th > 10% of cells *(endometrium)*
- Use “corroborative neuroendocrine stains“: Dot-like keratin positivity, TTF1
- Add on p40 for squamous cell carcinoma or site-specific stains for adenocarcinoma – with caveats
- Send out for INSM1

Bellizzi Hum Pathol 2020

“Poorly differentiated carcinoma with neuroendocrine differentiation” is problematic for clinicians – try to avoid

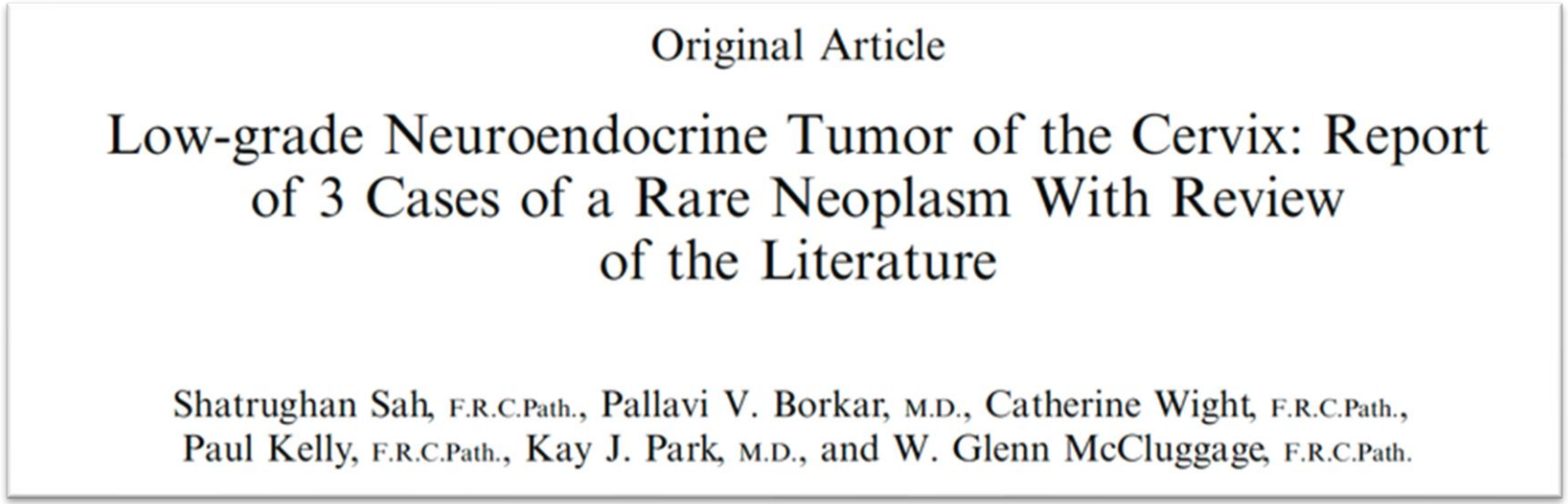

Original Article

Low-grade Neuroendocrine Tumor of the Cervix: Report of 3 Cases of a Rare Neoplasm With Review of the Literature

Shatrughan Sah, F.R.C.Path., Pallavi V. Borkar, M.D., Catherine Wight, F.R.C.Path., Paul Kelly, F.R.C.Path., Kay J. Park, M.D., and W. Glenn McCluggage, F.R.C.Path.

Cervical NET

3 cervical NETs

Extremely rare; report of 3 cases

One case **initially diagnosed as HG NEC cervix** (**HPVA**) on biopsy

After chemoradiation, hysterectomy - **NET morphology**

? Maturation phenomenon, induced by treatment

Challenges the current understanding of NET and NEC being fundamentally different tumours



Thank you!

Acknowledgements:
Raji Ganesan
Carlos Parra-Herran
Kate Strachan

Neuroendocrine Neoplasia of the Female Genital Tract

Surg Pathol Clinics 2022

Karen L. Talia, MBBS(Hons), FRCPA[a,*], Raji Ganesan, FRCPath[b]