The British Association of Gynaecological Pathologists



Lecturer – Oluwole Fadare

Bio – Professor Fadare is a Professor of Pathology and Chief of Anatomic Pathology at University of California San Diego. He is a gynecologic pathologist whose research is focused on various aspects of diagnostic pathology of the female genital tract

The British Association of Gynaecological Pathologists

Everyday Dilemmas in Gynaecological Pathology

- **Title:** Reporting residual hyperplasia after progestin treatment of atypical endometrial hyperplasia
- **Speaker:** Oluwole Fadare, MD
- **Affiliation:** University of California San Diego, San Diego, CA, USA
- **Date:** March 7th 2025.

The British Association of Gynaecological Pathologists

Speaker disclosures

- ❑ I have no financial conflicts of interest to disclose

Progestins

- A progestogen (a.k.a progestagen, gestagen, or gestogen) is a molecule that simulates the effects of progesterone, binds to the progesterone receptor, and functions as an agonist. It can be either natural or synthetic
- A progestins is a synthetic progestogen.

Michael Edwards; Ahmet S. Can Progestins. Treasure Island (FL): StatPearls Publishing; 2025.
Bookshelf ID: NBK563211PMID: 33085358

Progestins: many options

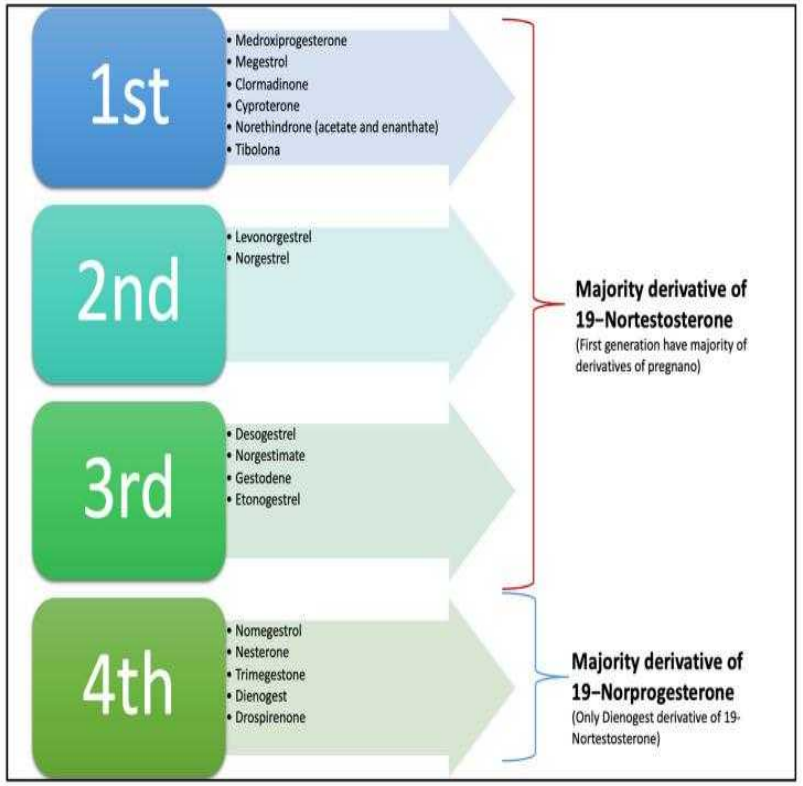

Hormonal Agent	Dosage and Length
Medroxyprogesterone acetate	10–20 mg/d (preferred) or cyclic 12–14 d/mo
Depot medroxyprogesterone	150 mg intramuscularly every 3 mo
Micronized vaginal progesterone	100–200 mg/d (preferred) or cyclic 12–14 d/mo
Megestrol acetate	80 mg twice/d (standard dose), range 40–200 mg/d
Levonorgestrel intrauterine system	52 mg in steroid reservoir over 5 y

Modified from Trimble CL, Method M, Leitao M, Lu K, Ioffe O, Hampton M, et al. Management of endometrial precancers. Obstet Gynecol 2012;120:1160–75. doi: 10.1097/aog.0b013e31826bb121

Ring et al. Obstet Gynecol. 2022 Dec 1;140(6):1061-1075.
Manuel García-Sáenz et al. J Clin Med. 2023 May 10;12(10):3388.

Side effect profiles

Oral progestins

- weight gain, nausea, mood changes, risk of venous thromboembolism, and irregular vaginal bleeding

Levonorgestrel-releasing intrauterine system

- pelvic pain, breast tenderness, ovarian cysts, weight gain, and acne, early phase bleeding
- displacement, embedment, perforation, falling out

Abu Hashim H. et al. Am. J. Obstet. Gynecol. 2015;213:469–478.
Lethaby et al. Cochrane Database Syst. Rev. 2015;30:CD002126

Mechanisms of progestin action in the endometrium

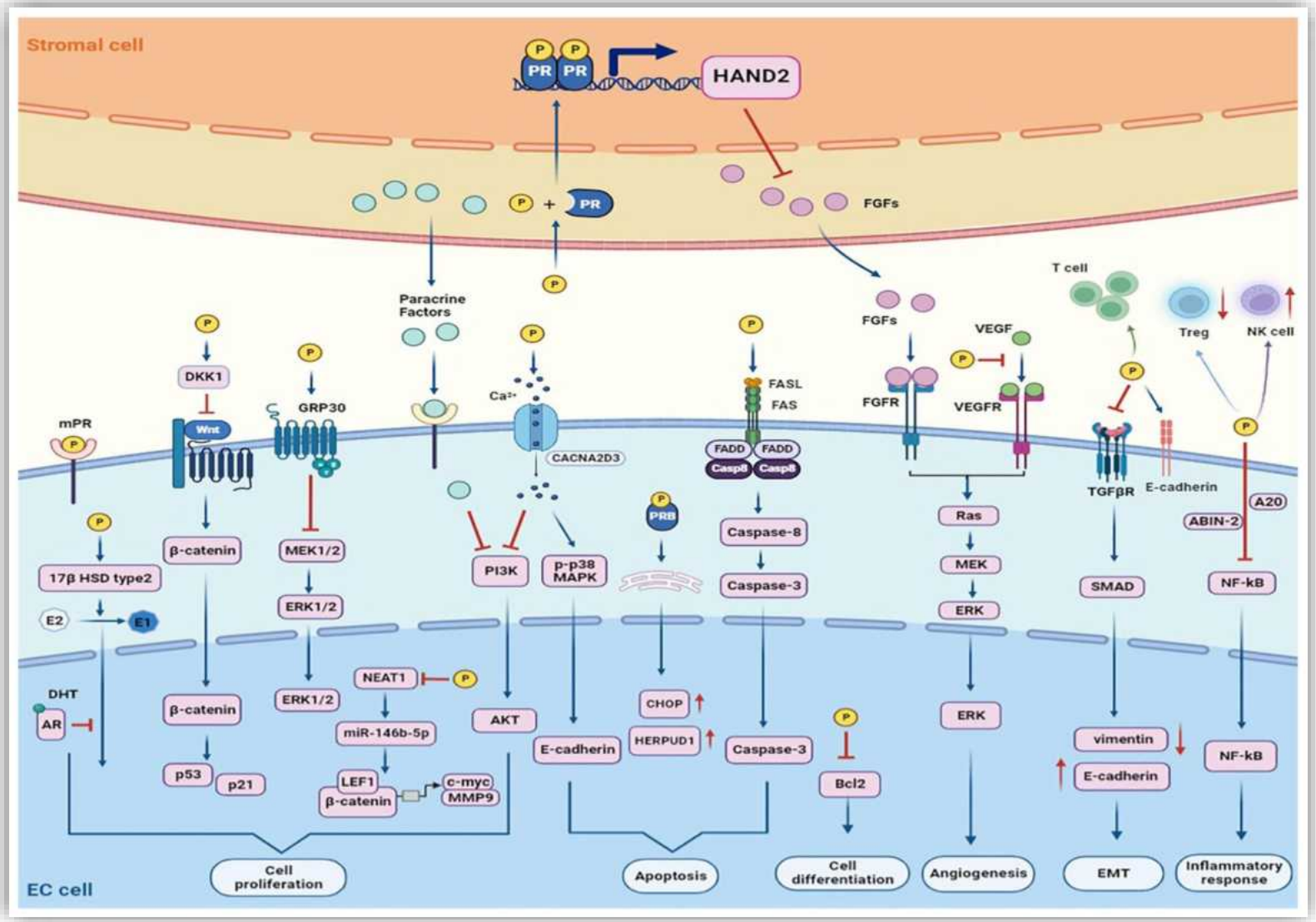

Lv et al. Cancers (Basel). 2022;14(24):6210

Mechanisms of progestin action in the endometrium

Cell cycle arrest

Antiangiogenic effects

Inflammatory response

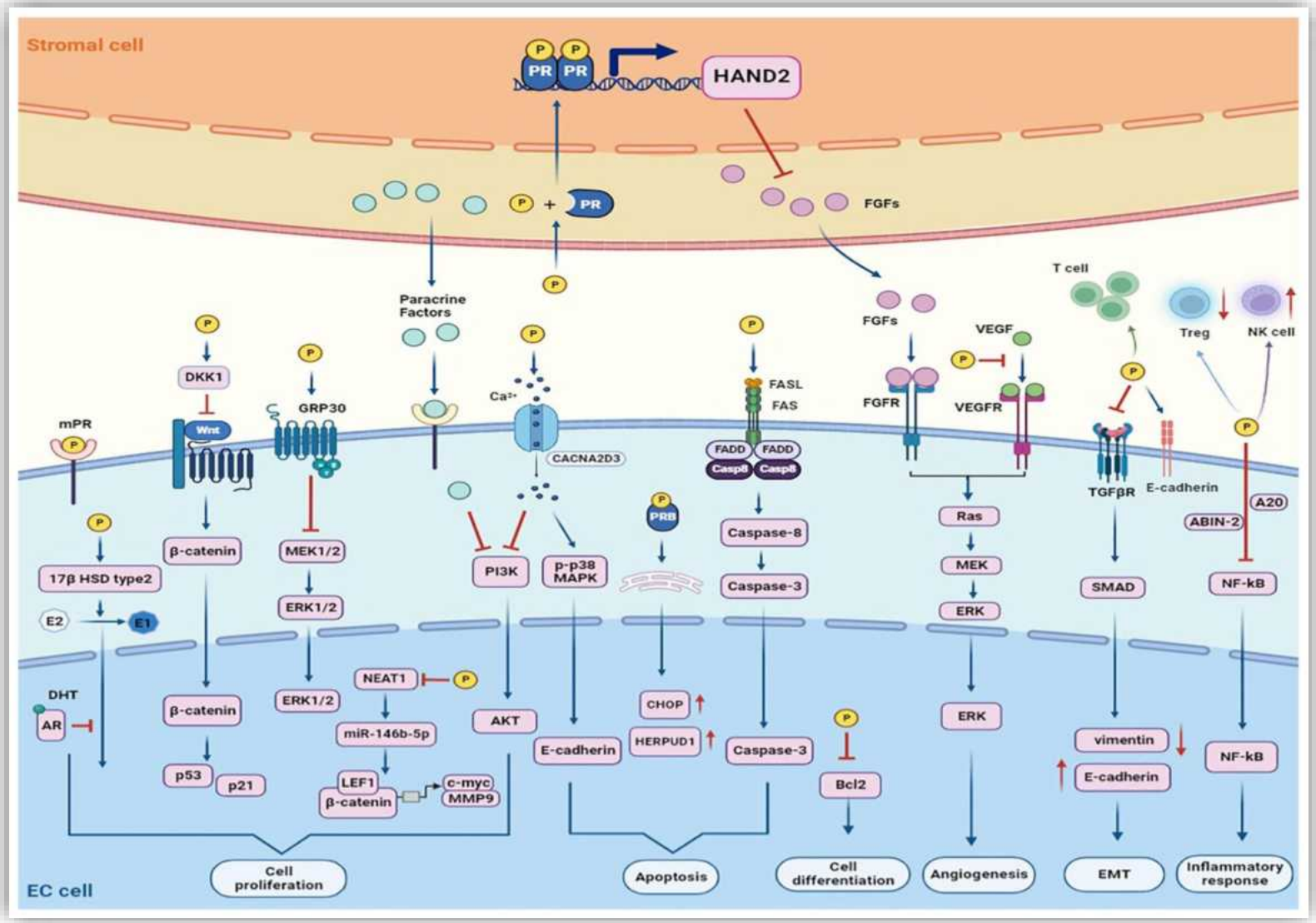

Anti-apoptotic effects

Induction of cell differentiation

Regulation of ER and PR

Lv et al. Cancers (Basel). 2022;14(24):6210

Histologic Effects of Progestins on Non-Hyperplastic Endometrium

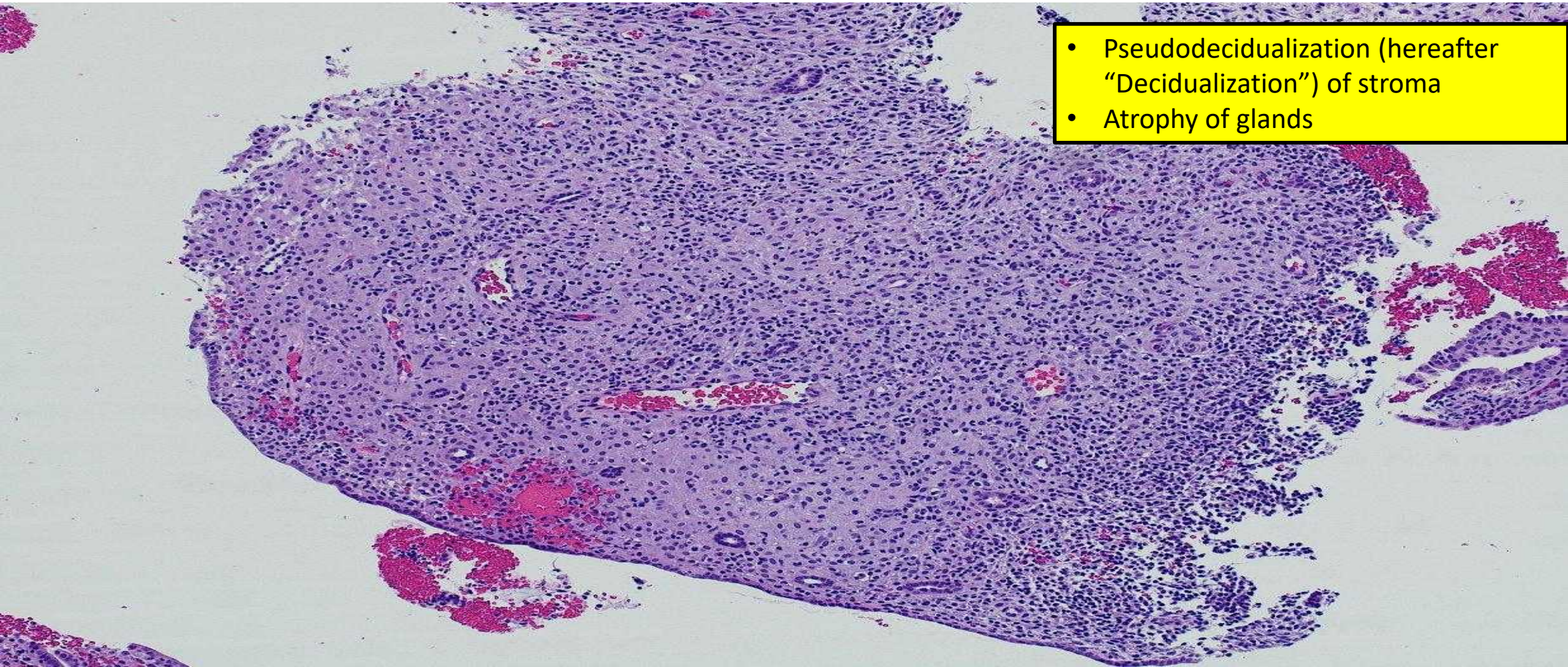

- Pseudodecidualization (hereafter “Decidualization”) of stroma
- Atrophy of glands

Histologic Effects of Progestins on Non-Hyperplastic Endometrium

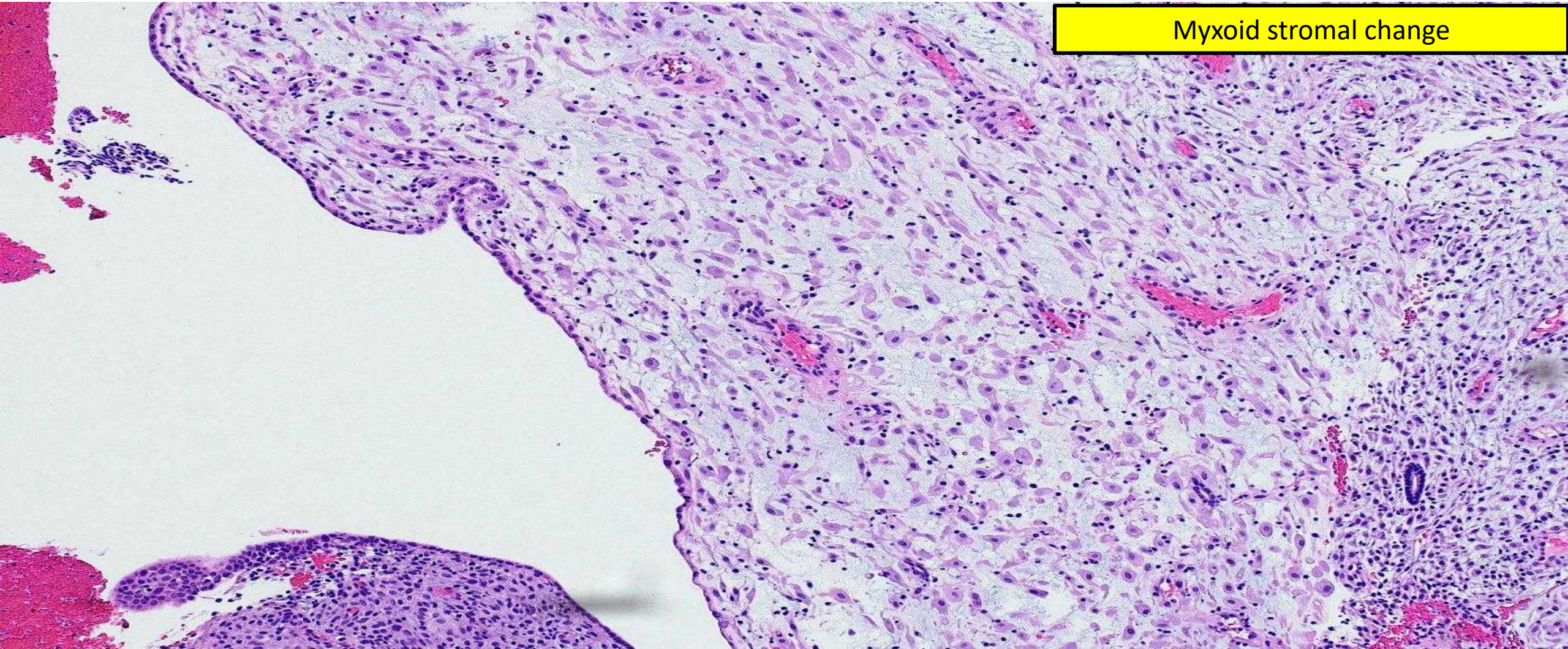

Histologic Effects of Progestins on Non-Hyperplastic Endometrium

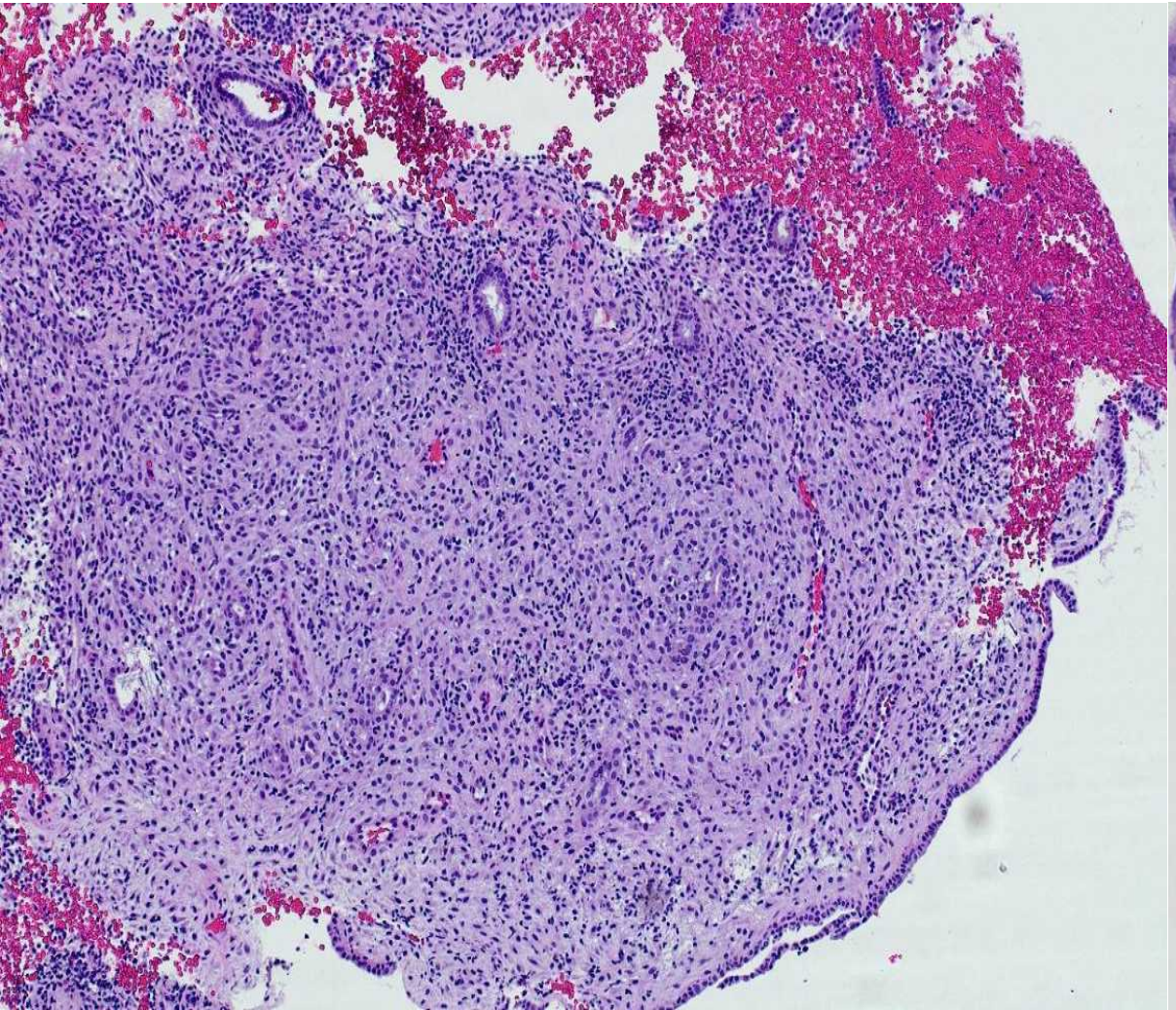

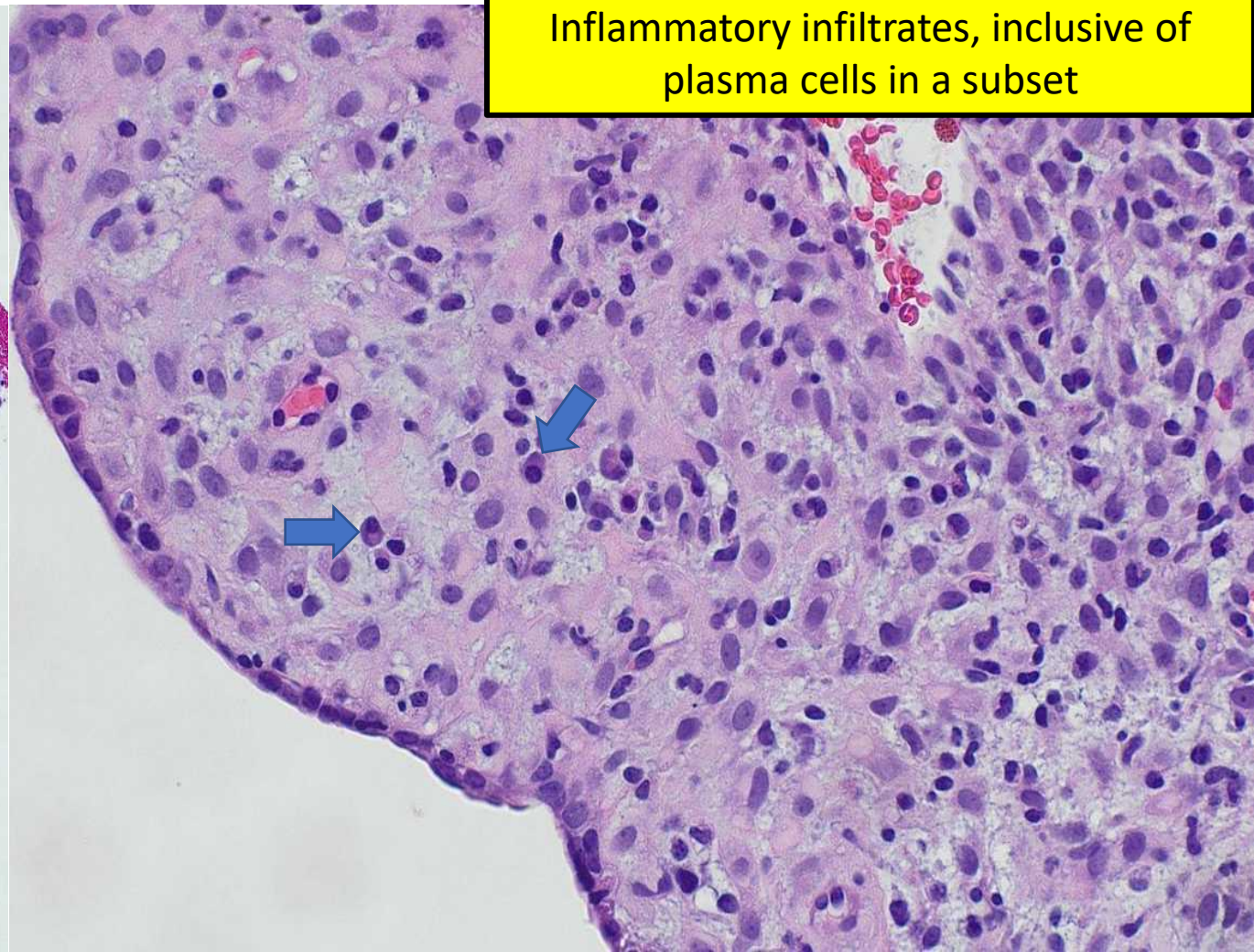

Inflammatory infiltrates, inclusive of plasma cells in a subset

Histologic Effects of Progestins on Non-Hyperplastic Endometrium

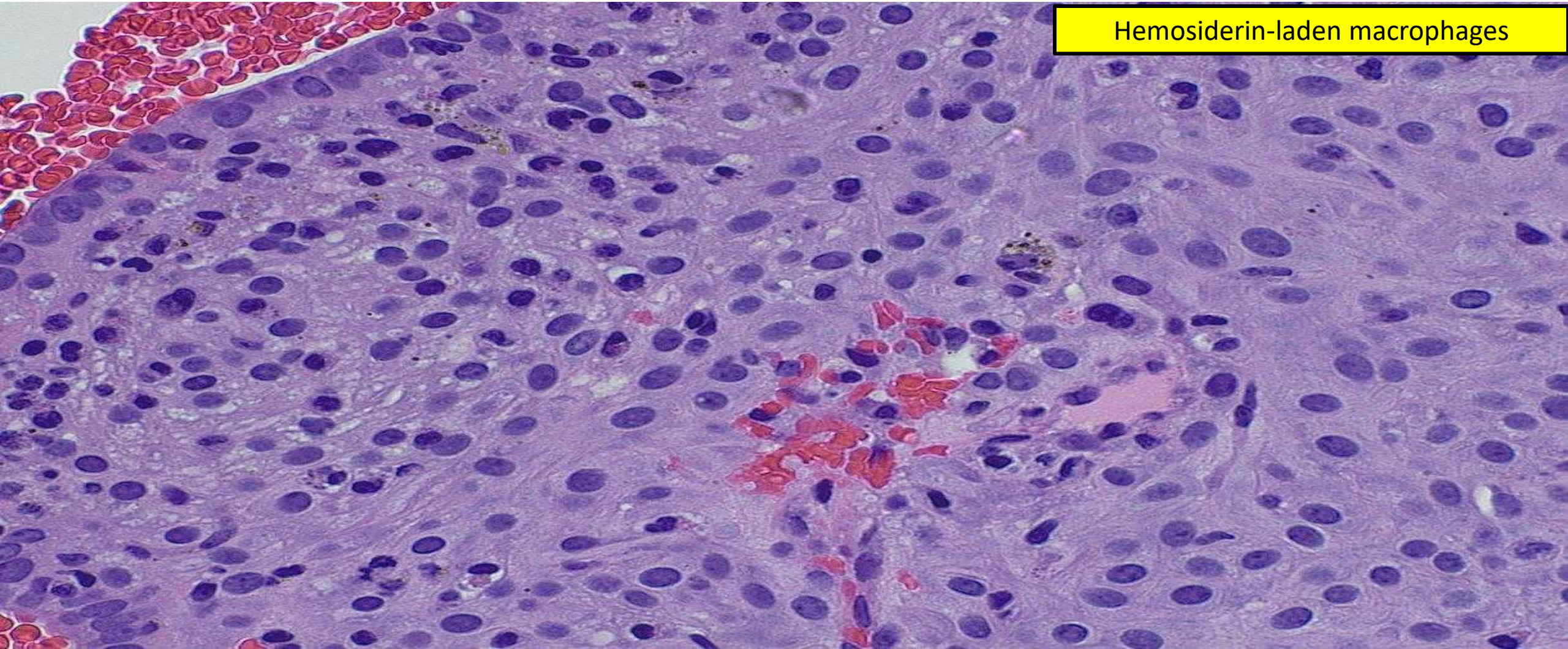

Histologic Effects of Progestins on Non-Hyperplastic Endometrium

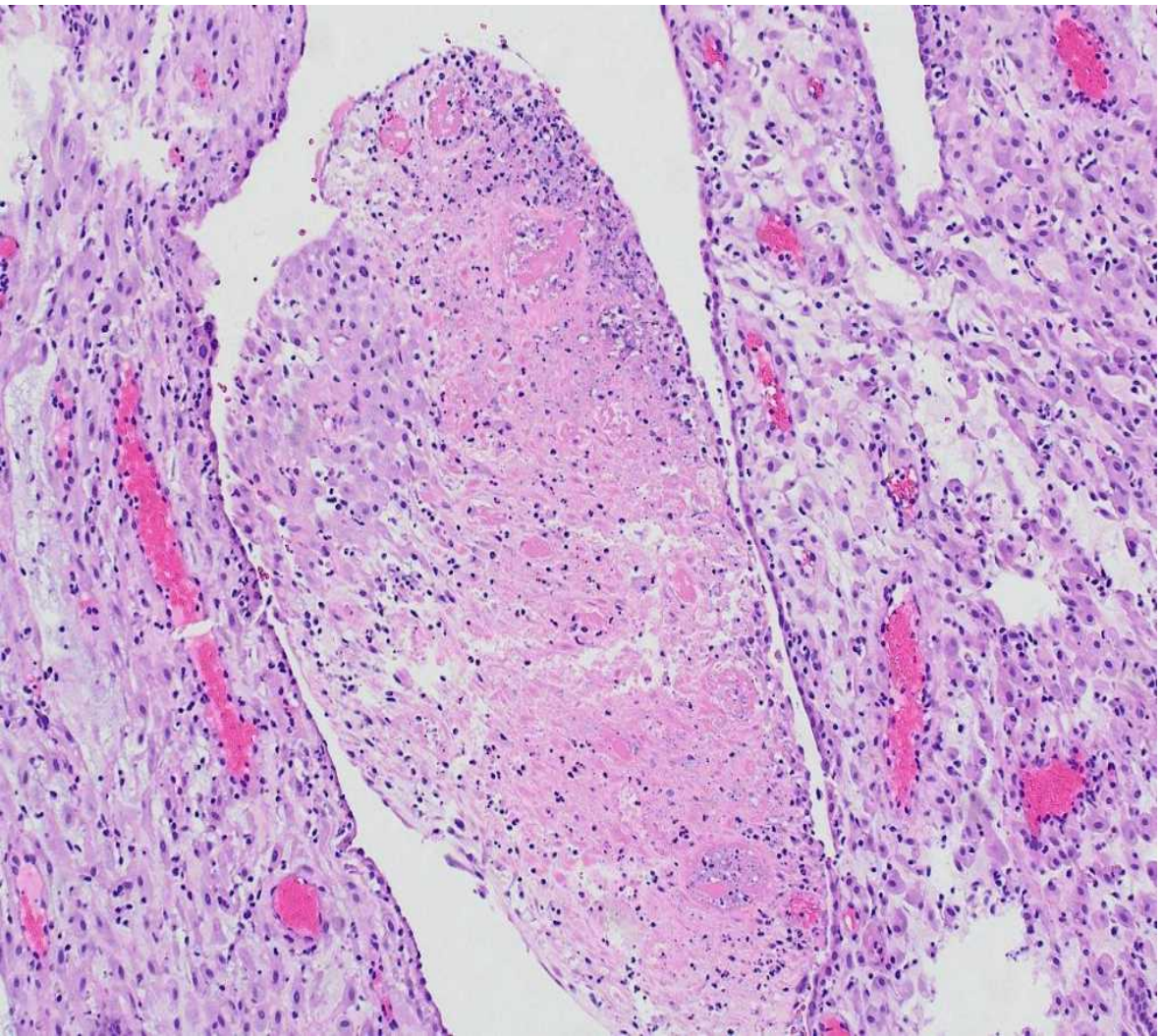

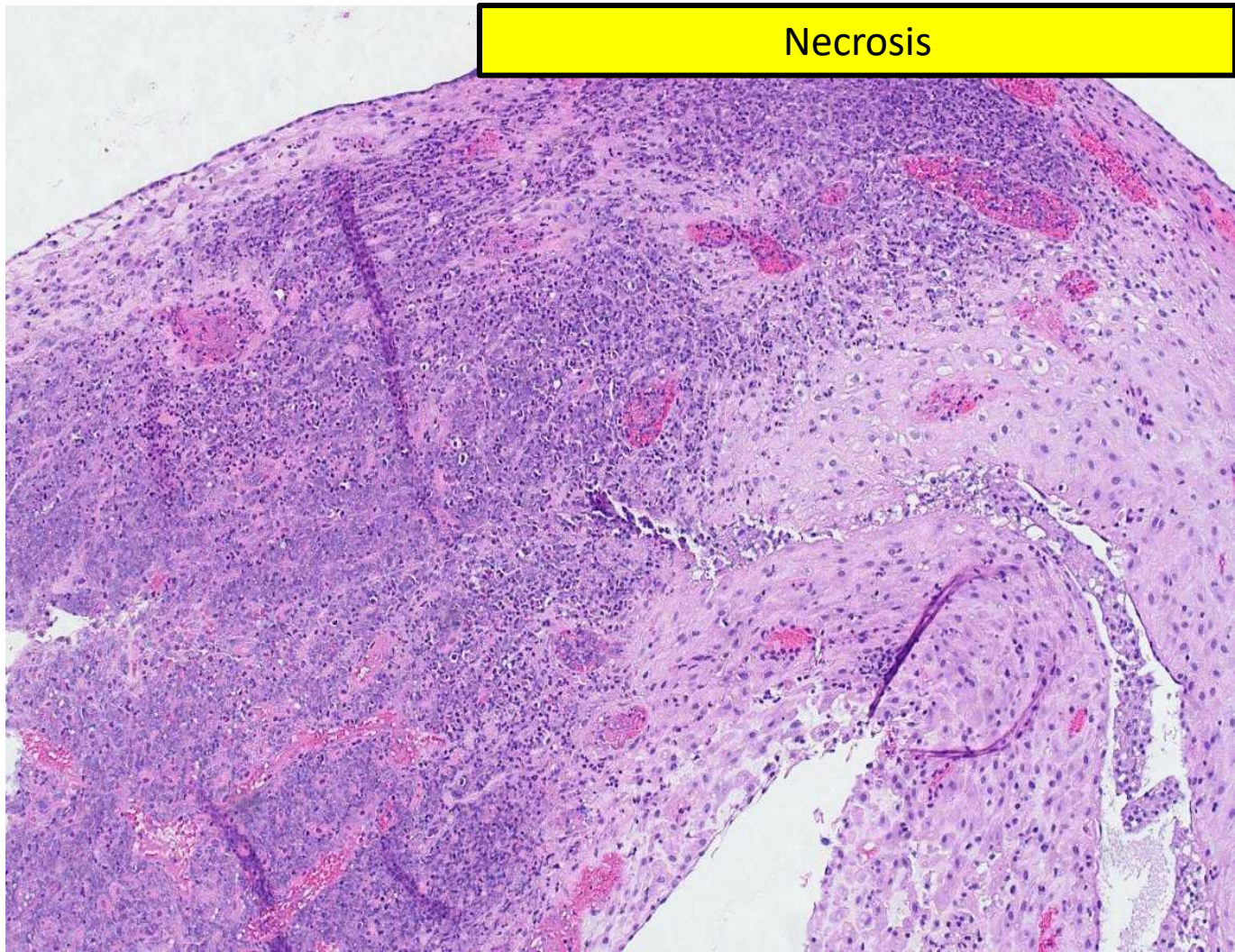

Histologic Effects of Progestins on Non-Hyperplastic Endometrium

Calcifications

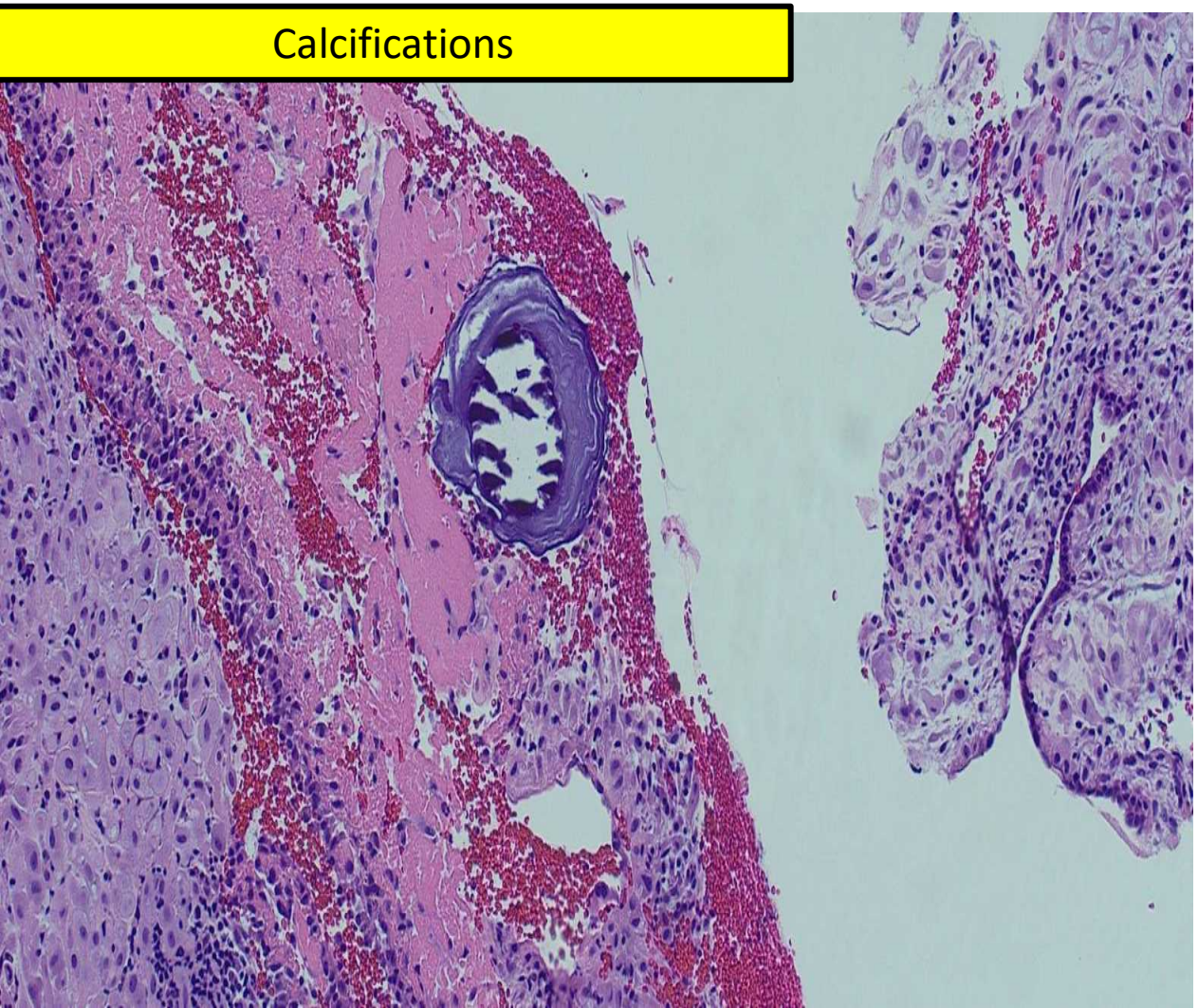

Surface Papillary formations

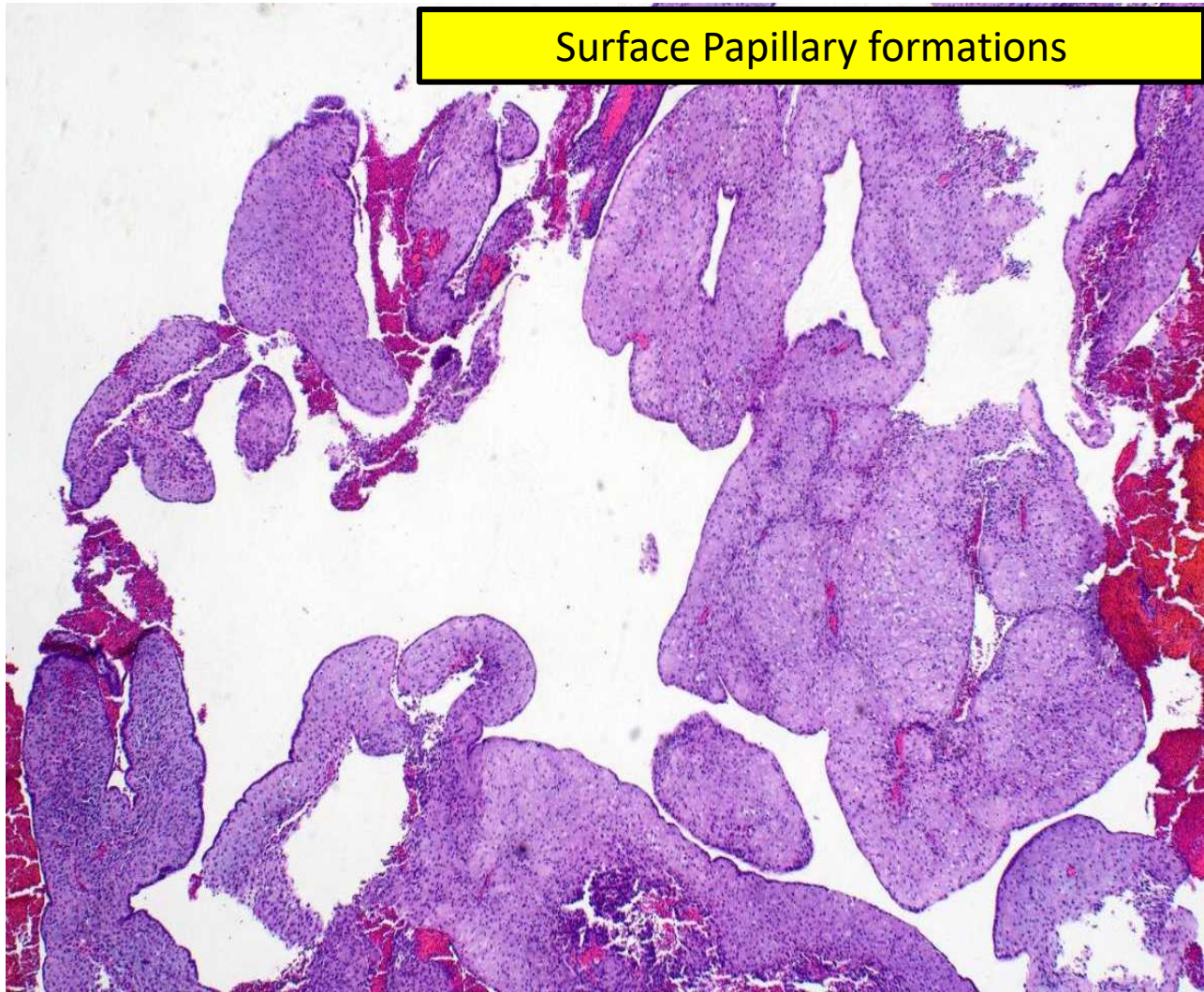

Histologic Effects of Progestins on Non-Hyperplastic Endometrium

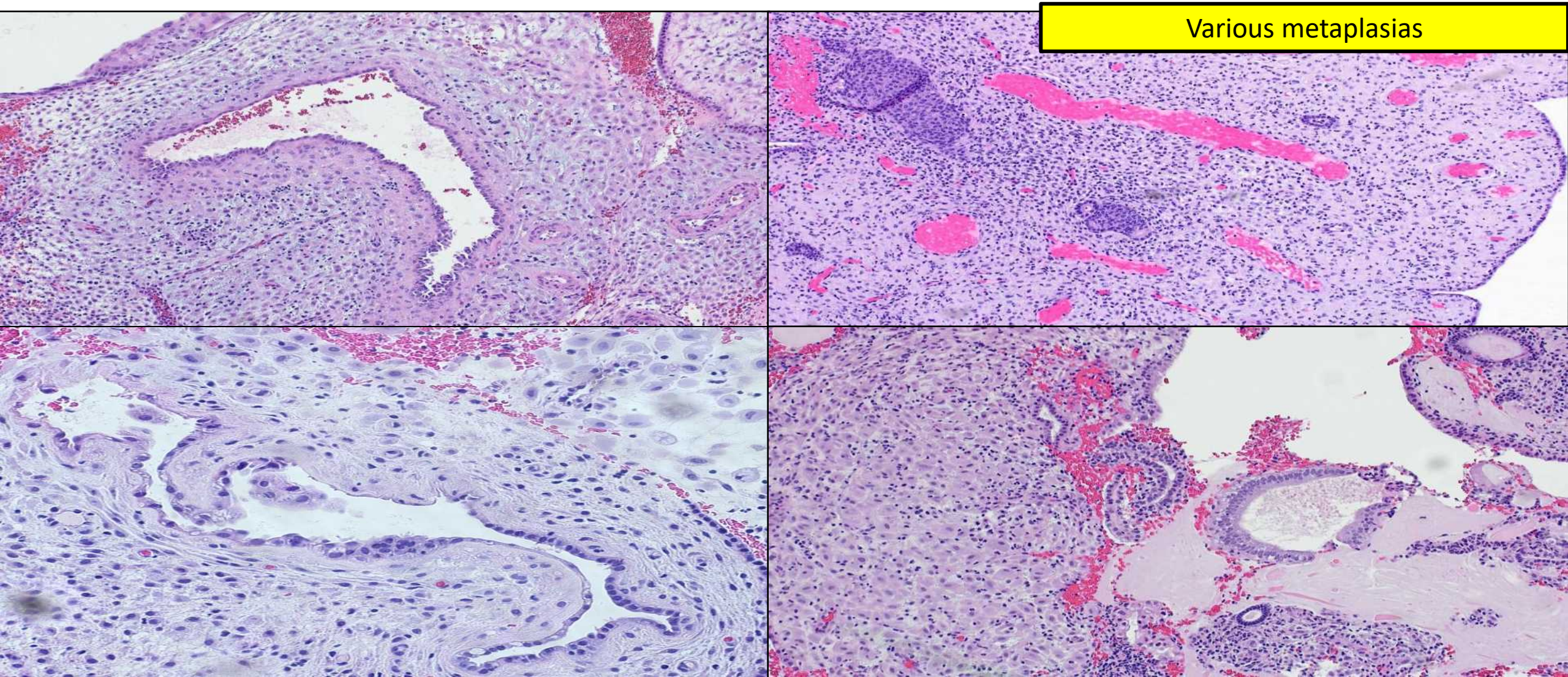

The effects of the levonorgestrel intrauterine system (Mirena coil) on endometrial morphology

V Phillips, C T Graham, S Manek, W G McCluggage

J Clin Pathol 2003;56:305–307

International Journal of Surgical Pathology
Volume 15 Number 2
April 2007 148-154
© 2007 Sage Publications
10.1177/1066896906299120
http://ijsp.sagepub.com
hosted at
http://online.sagepub.com

Morphologic Changes in the Endometrium Associated With the Use of the Mirena Coil: A Retrospective Study of 106 Cases

Rahul K. Hejmadi, MD, DNB, FEBP, MRCPath,
Shalini Chaudhri, MD, MRCPath, Raji Ganesan, MD, FRCPath,
and Terence P. Rollason, FRCPath

	Hejmadi et al [n=106]	Philips et al [n=76]
Pseudodecidualization	104 (98)	72 (96)
Glandular atrophy	82 (81.2)	65 (86.7)
Plasma cells	95 (89.6)	20 (26.7)
Myxoid stroma	59 (55.7)	29 (38.7)
Hemosiderophages	5 (4.7)	24 (32)
Calcification	11 (10.4)	1 (1.33)
Nuclear atypia	9 (18.6)	3 (4)
Focal glandular metaplasia	55 (53.9)	7 (9.3)
Microglandular hyperplasia	14 (13.2)	1 (1.3)
With pseudodecidualization	3 (2.8)	—

Endometrial atypical hyperplasia/ endometrioid intraepithelial neoplasia [AEH]

"***..simultaneous change of epithelial cytology and an increased number of endometrial glands in comparison with the stroma (crowded gland architecture) within a morphologically defined region, distinct from the surrounding endometrium or from entrapped normal glands***"

WHO Classification of Tumours Editorial Board. Female Genital Tumours. Lyon (France): IARC 2020. 5th Ed. Vol 4.

Endometrial atypical hyperplasia/ endometrioid intraepithelial neoplasia [AEH]

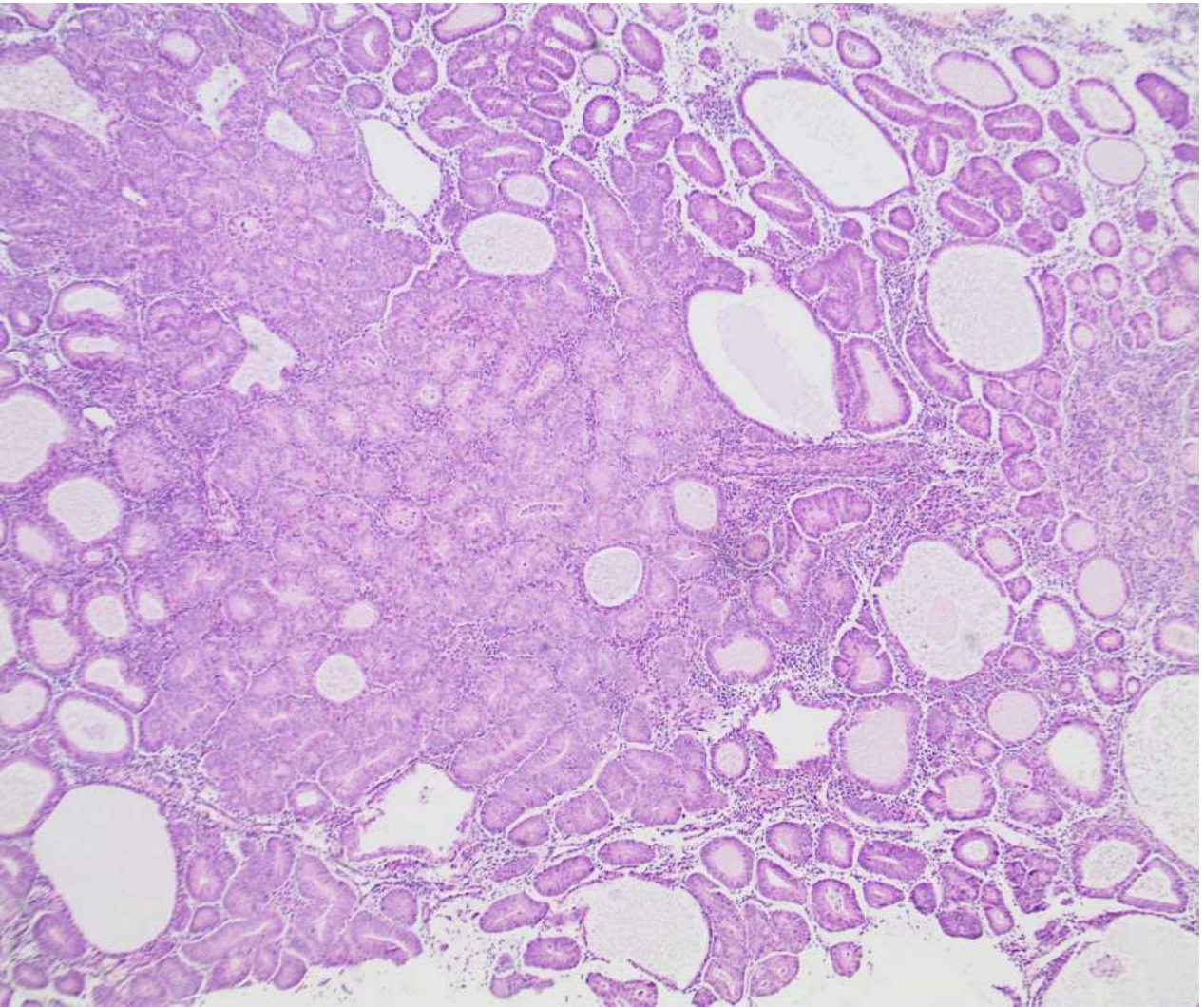

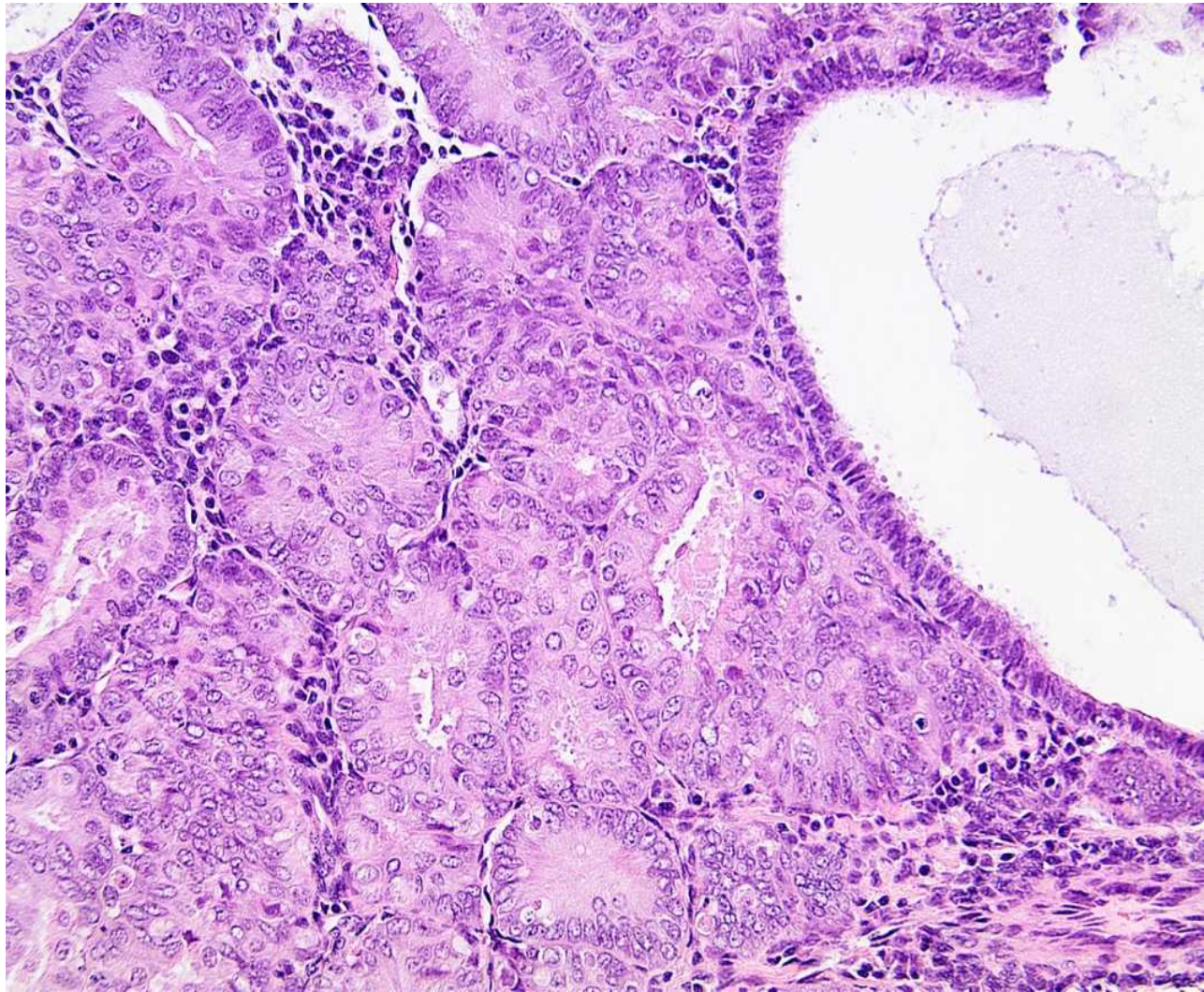

AEH: Outcomes, Based on Meta-Analyses

- Doherty et al. [PMID: 32343732]:
  - "the pooled prevalence of **concurrent** endometrial cancer was **32.6%** (95% CI: 24.1%-42.4%)" [concurrent: within 3 months]
  - The risk of **progression** to cancer, (n = 5 studies), annual incidence rate = **8.2%**, 95% CI 3.9%-17.3%).

- Rakha et al. [PMID: 23073327]:
  - "positive predictive value (PPV) of AEH in detecting endometrial cancer (6% to 63%) with an overall PPV of **37%**"

Doherty et al. PLoS One. 2020 Apr 28;15(4):e0232231.
Rakha et al. Am J Surg Pathol. 2012 Nov;36(11):1683-90

UCSD Experience after diagnosis of AEH in a Sampling Specimen: Hormones versus Surgery

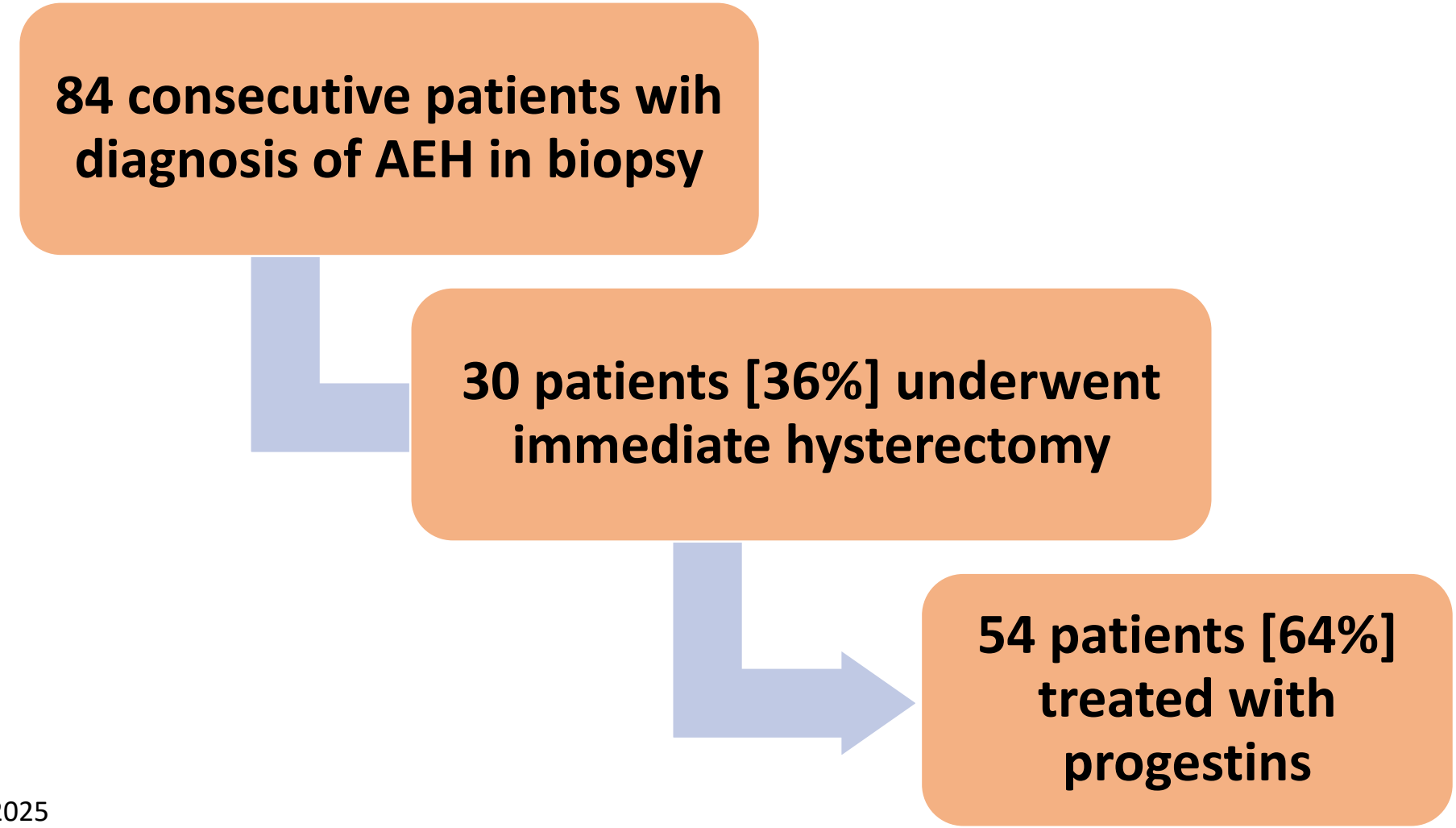

WangPan Shi et al, USCAP 2025

Sampling Surveillance During Progestin Therapy for AEH

- No standardized approaches to follow-up
- Follow-up biopsies are commonly performed **every 3 months**, resulting in multiple endometrial samples from each patient over the course of progestin therapy.
- ACOG: "*If there is no response or some regression during the initial 3–6 months of therapy, an additional 3–6 months of therapy may be considered after discussion with the patient. If there is no response after 9–12 total months of therapy, other management options, including definitive surgery, should be discussed*" [Clinical Consensus Statement, Number 5, Sept 2023]

Data from two systematic reviews/meta-analyses on progestin treatment of AEH

	Pathological complete response	Disease progression while on oral treatment	Median time to complete response	Disease persistence/ non-responders	Pathological complete response followed by relapse
Baker et al. PMID: 22196499	74%	2.7%	5.9 months	16%	20.1%
Gunderson et al. PMID: 22245711	66%		6 months (range, 1-18 months)	14%	

AEH: When progestins do not work, or only partially work after a reasonable duration

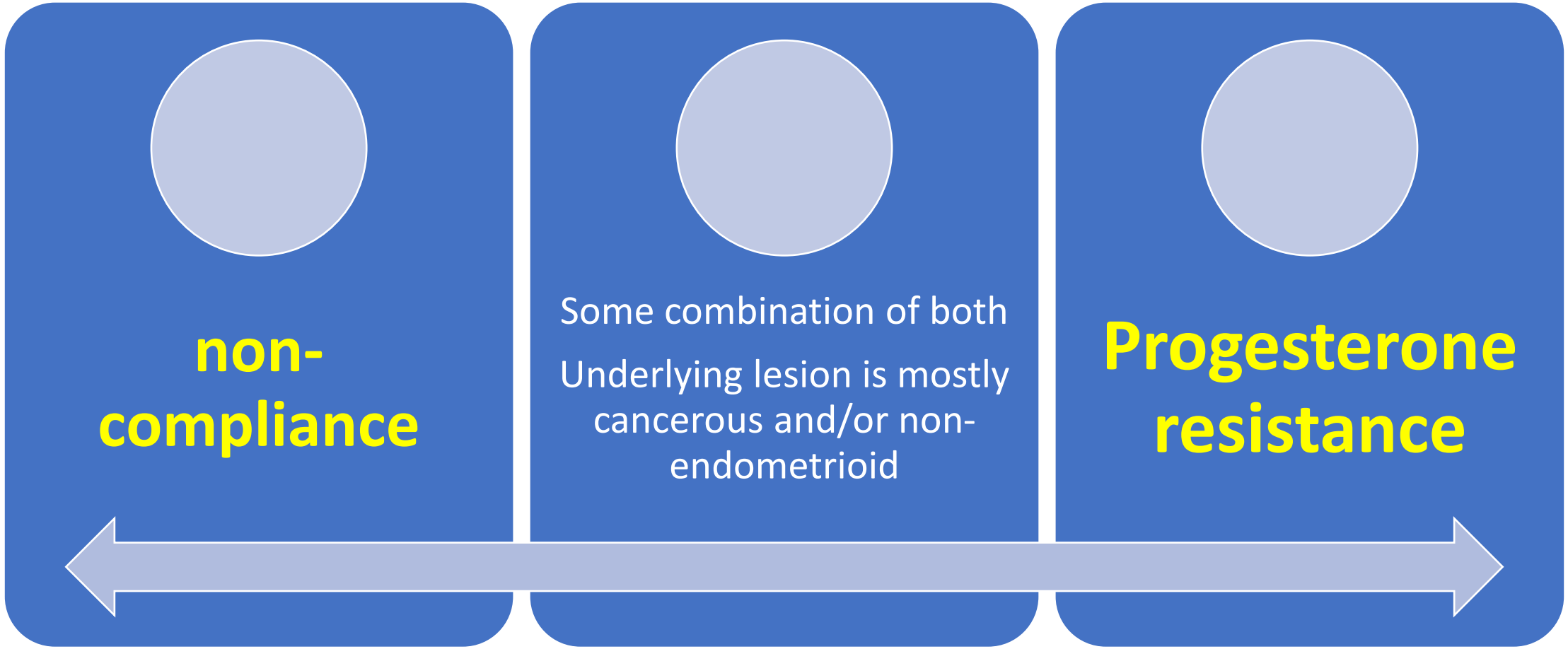

Follow-up Biopsies on an AEH patient who is being treated with Progestins

Key Questions for the Pathologist

(1) Is residual hyperplasia present? *YES or NO?*

(2) If residual hyperplasia is present, any insights, qualitative or quantitative, about the hyperplasia?

(3) Is Cancer present? *YES or NO?*



Ross University School of Medicine
https://medical.rossu.edu/about/blog/what-does-a-pathologist-do-and-how-to-become-one

Assessing Endometrial Hyperplasia and Carcinoma Treated With Progestin Therapy

Am J Clin Pathol 2012;138:524-534
DOI: 10.1309/AJCPM2TSDDF1MHBZ

Mark J. Mentrikoski, MD,[1] Akeesha A. Shah, MD,[1] Krisztina Z. Hanley, MD,[2] and Kristen A. Atkins, MD[1]

Histologic Alterations in Endometrial Hyperplasia and Well-differentiated Carcinoma Treated With Progestins

(*Am J Surg Pathol* 2007;31:988–998)

Darren T. Wheeler, MD, Robert E. Bristow, MD,† and Robert J. Kurman, MD‡*

Histologic Alterations in Endometrial Hyperplasia and Well-differentiated Carcinoma Treated With Progestins

(*Am J Surg Pathol* 2007;31:988–998)

Darren T. Wheeler, MD, Robert E. Bristow, MD,† and Robert J. Kurman, MD‡*

Post-treatment samples (compared to pre-treatment samples)

- Fewer number of involved fragments
- Stromal cells: spindled or decidualized
- Decrease in glandular crowding/complexity/glands-to-stroma ratio
- New cribriform pattern: 33% of cases
- Decreased glandular cellularity, decreased mitotic index, decreased N:C ratio
- Foci of inactive or secretory endometrium: 67% of cases
- Conspicuous cystic dilatation: 17% of cases
- Metaplasia: 89% of cases [eosinophilic 89%, squamous 39%, mucinous 32%)

POST-PROGESTIN TREATED ENDOMETRIAL HYPERPLASIA

Foci of Residual Hyperplasia/Cancer:

Back-to-back (confluent) or crowded glands;

cribriform patterns; extensive papillary architecture; solid architecture;

Confluent/crowded cysts may be present (cysts lined by columnar, non-atrophic epithelium);

Unequivocal atypia or cytologic demarcation may be present.

Foci of Response:

Absence of aforementioned cytoarchitectures

Foci of Ambiguity:

Insufficient abnormalities to classify as residual hyperplasia, but possibly abnormal; may represent foci of "partial response"

GLANDULAR CROWDING/CONFLUENCE/COMPLEXITY

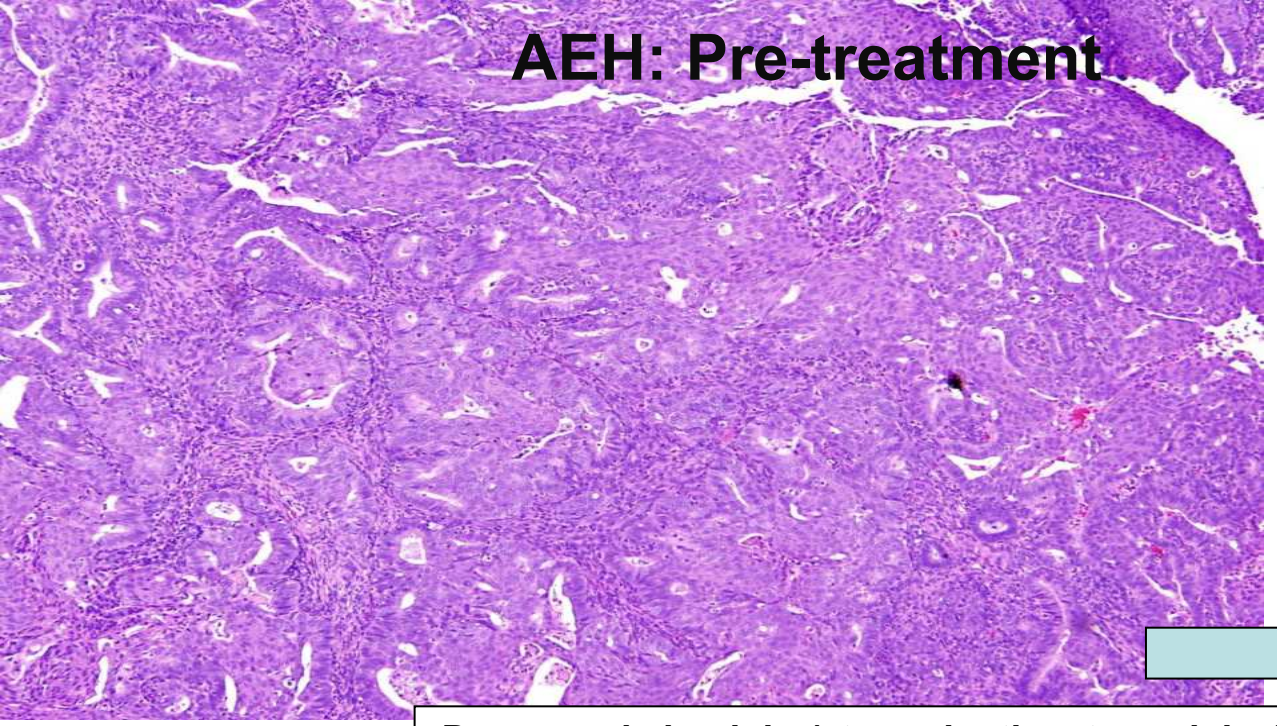

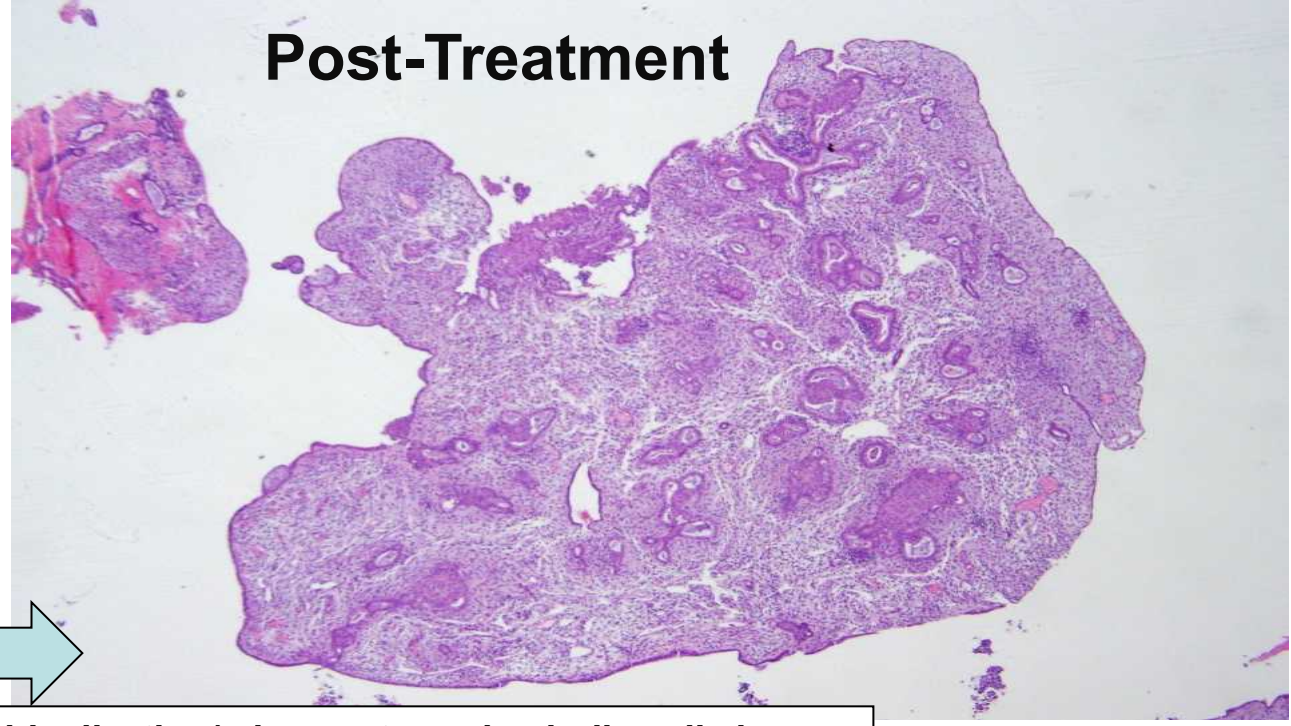

Decreased glandular/stromal ratio, stromal decidualization/edema, stromal spindle cell change

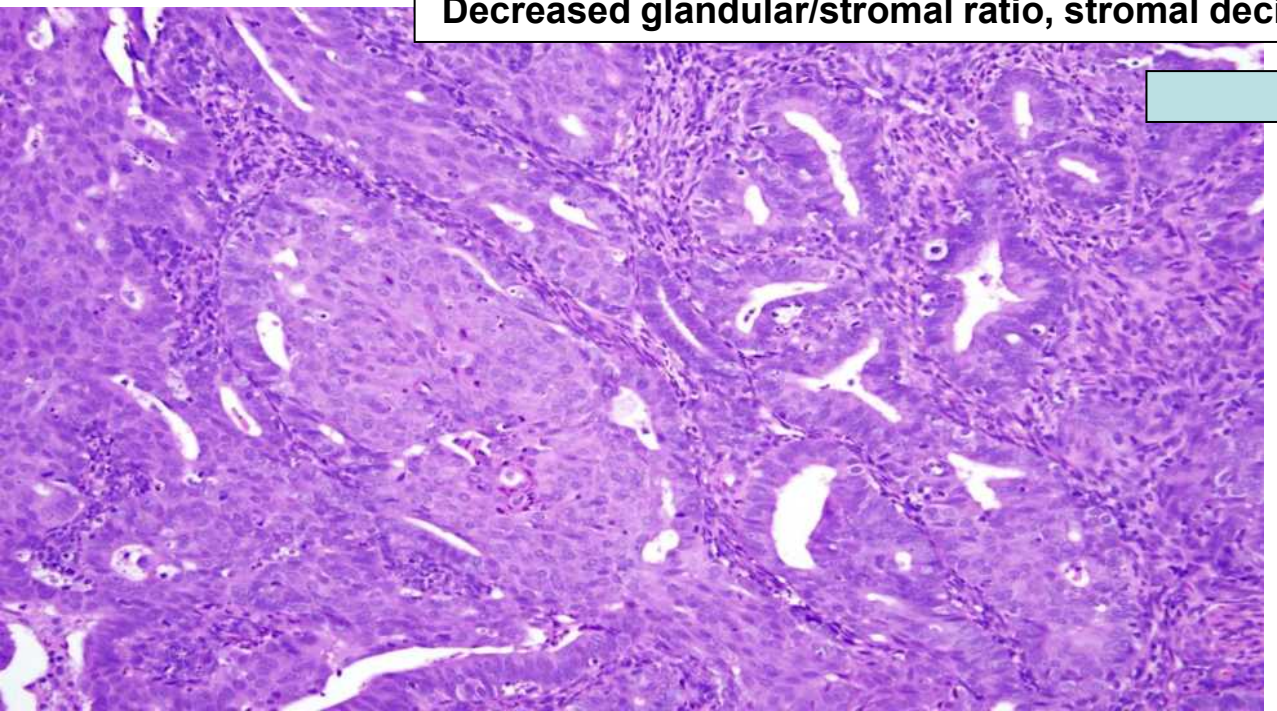

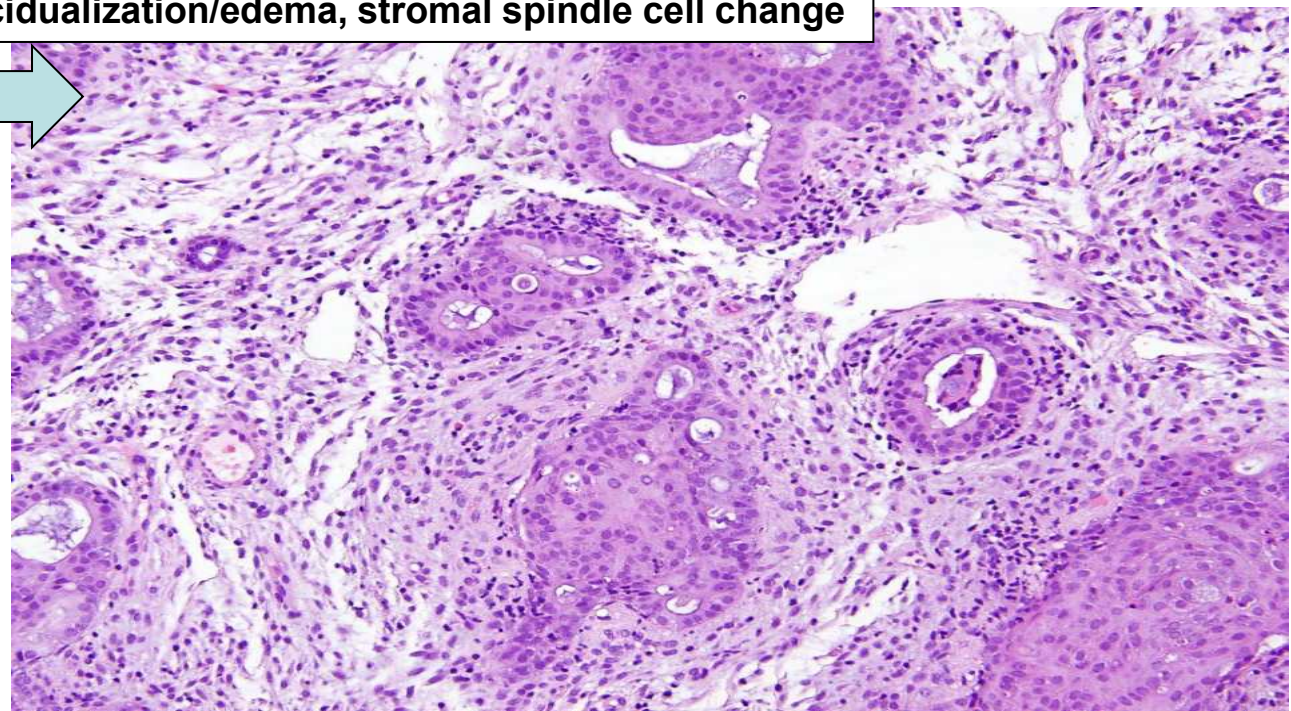

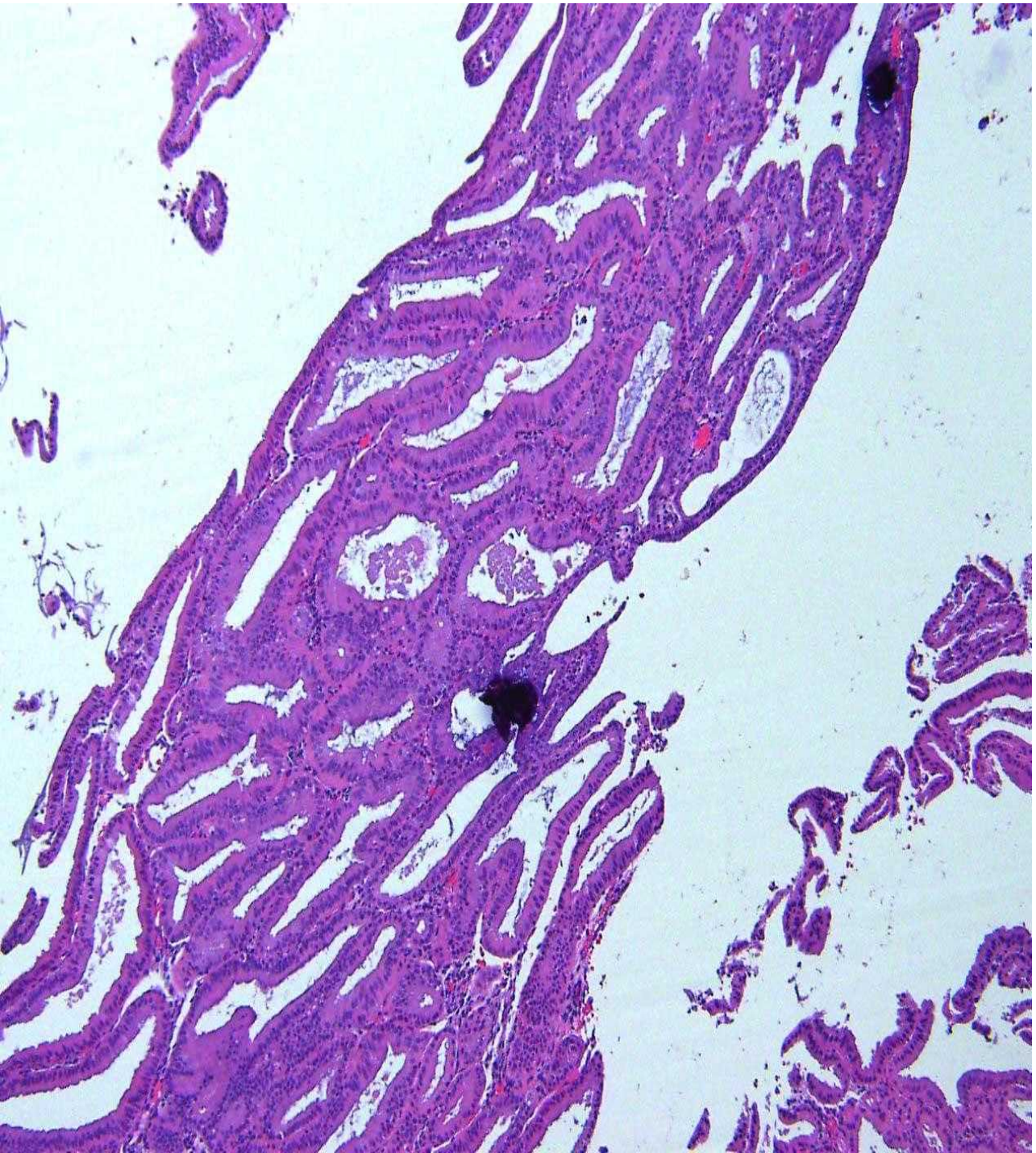

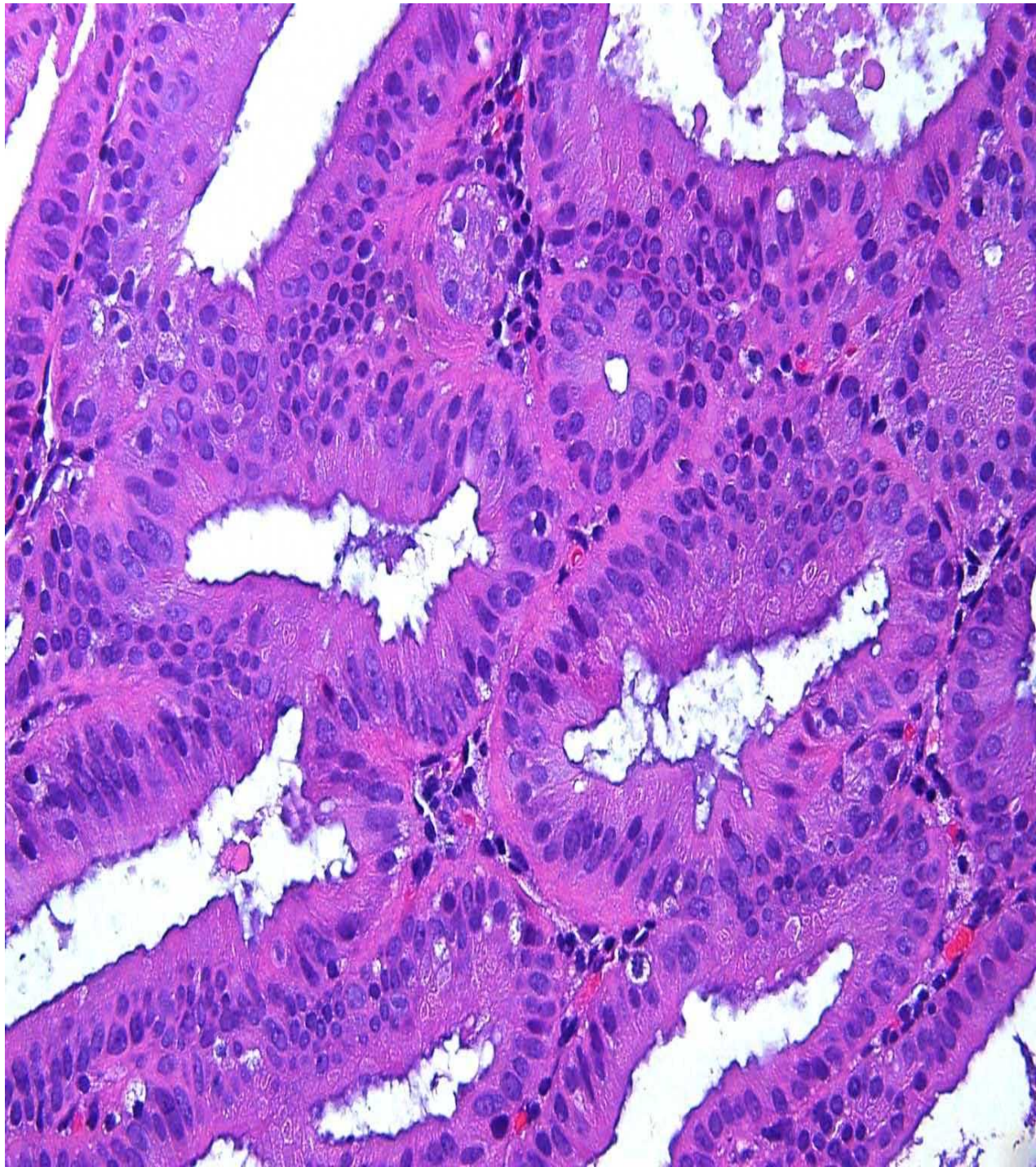

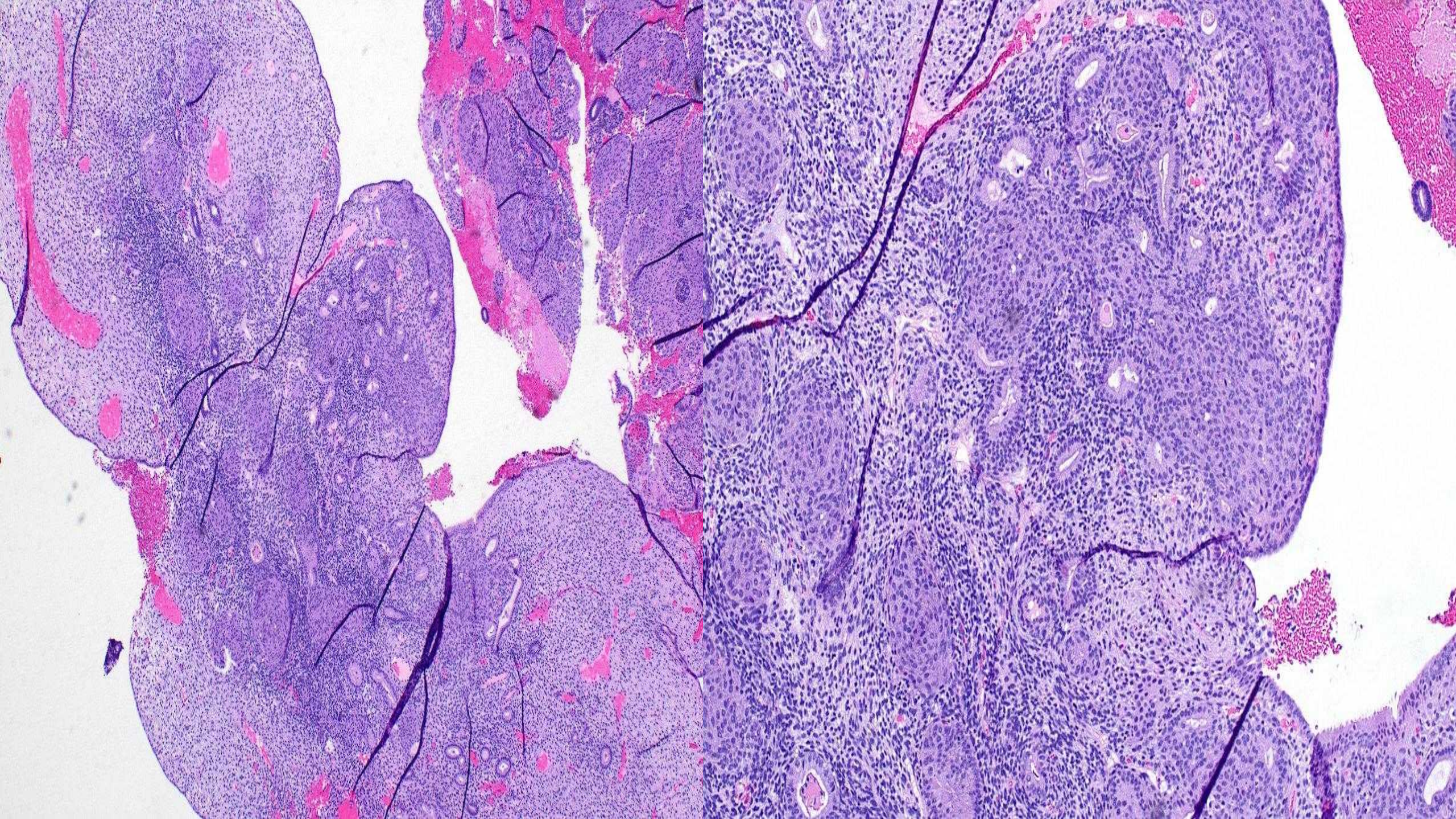

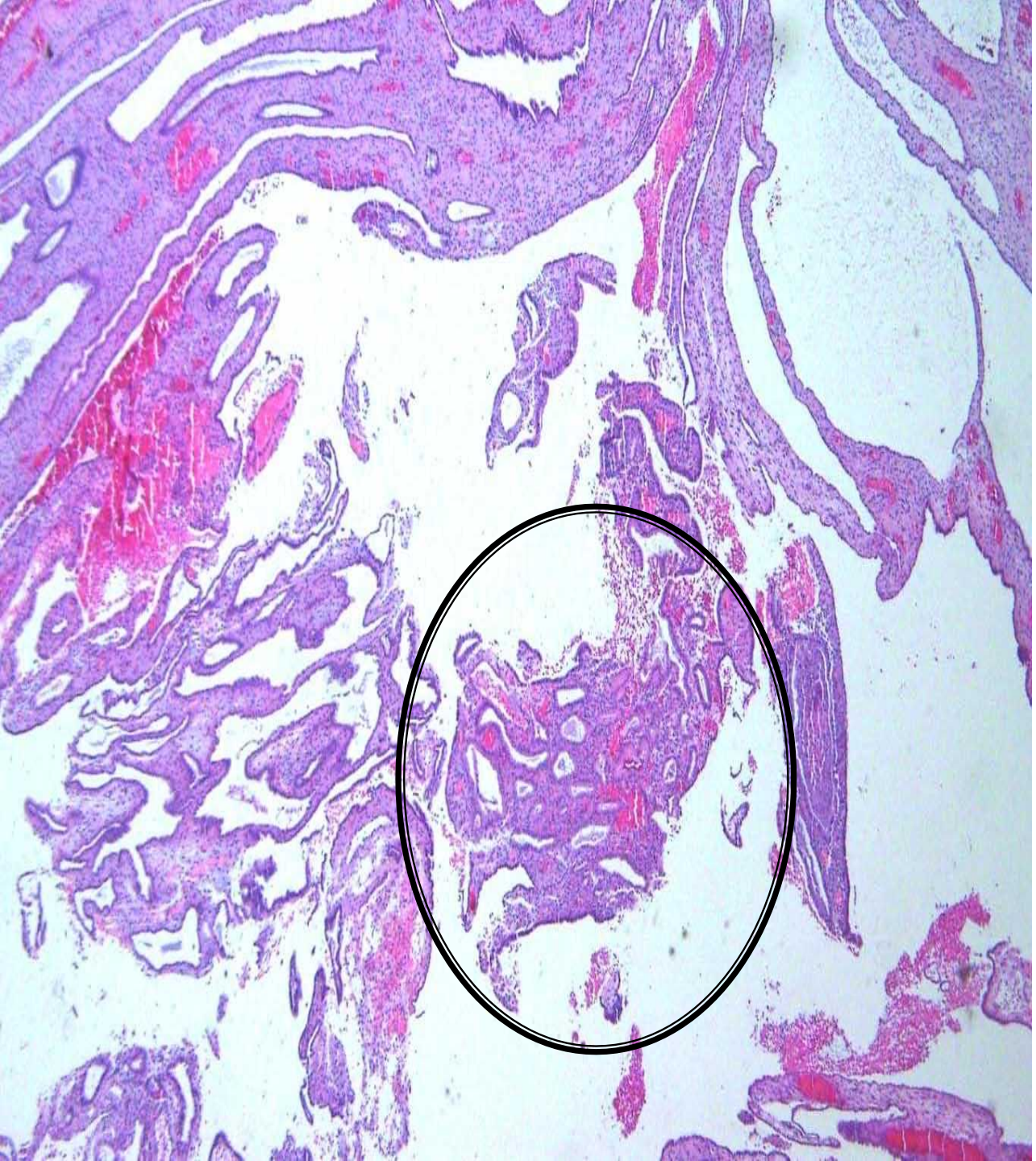

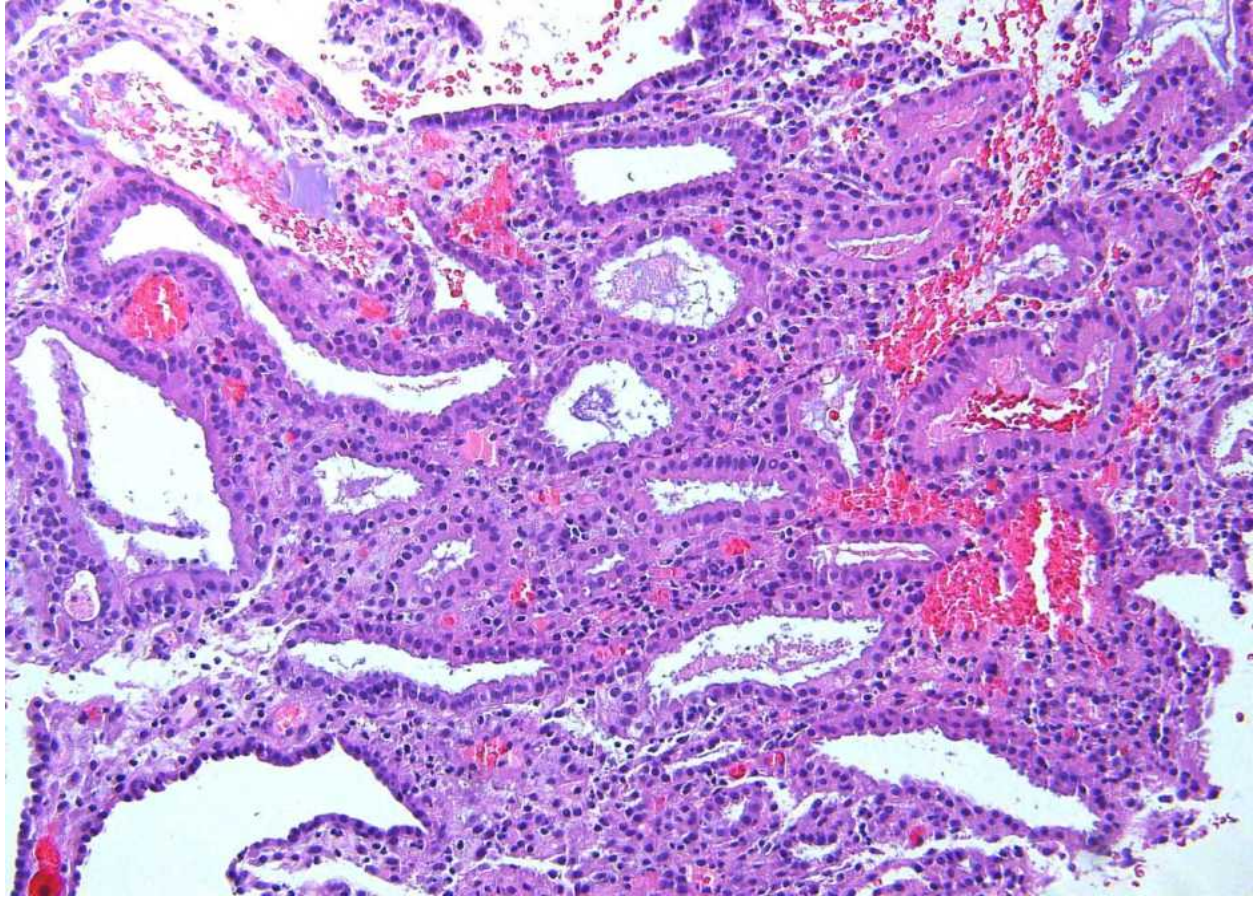

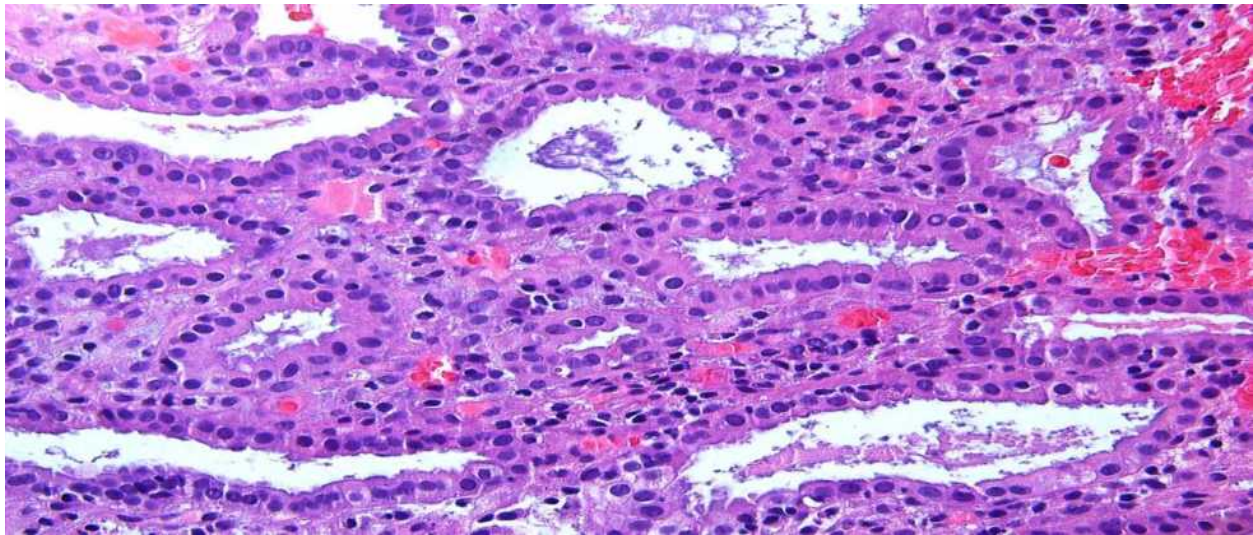

Histologic Alterations in Endometrial Hyperplasia and Well-differentiated Carcinoma Treated With Progestins

(*Am J Surg Pathol* 2007;31:988–998)

Darren T. Wheeler, MD, Robert E. Bristow, MD,† and Robert J. Kurman, MD‡*

- **Glandular crowding and/or back-to-back glands present at 1-3 mo biopsy**
  - 51% showed resolution/regression in final specimen
- **Glandular crowding and/or back-to-back glands present at 4-6 mo biopsy**
  - 34% showed resolution/regression in final specimen
- **Glandular crowding and/or back-to-back glands present at 7-9 mo biopsy**
  - 14% showed resolution/regression in final specimen

CRIBRIFORM FORMATIONS

Disease revealed or progression?

- 22-33% of cases may show increased architectural complexity in the follow-up biopsy/final specimen relative to the index biopsy

(Mentrikoski et al AJCP. 2012, and Wheeler et al. AJSP 2007;31:988-98)

Disease revealed or progression?

- 22-33% of cases may show increased architectural complexity in the follow-up biopsy/final specimen relative to the index biopsy

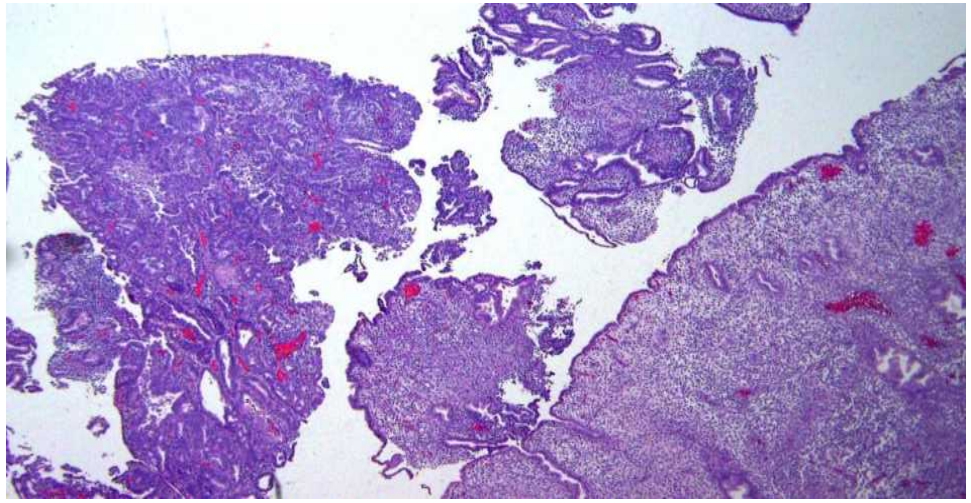

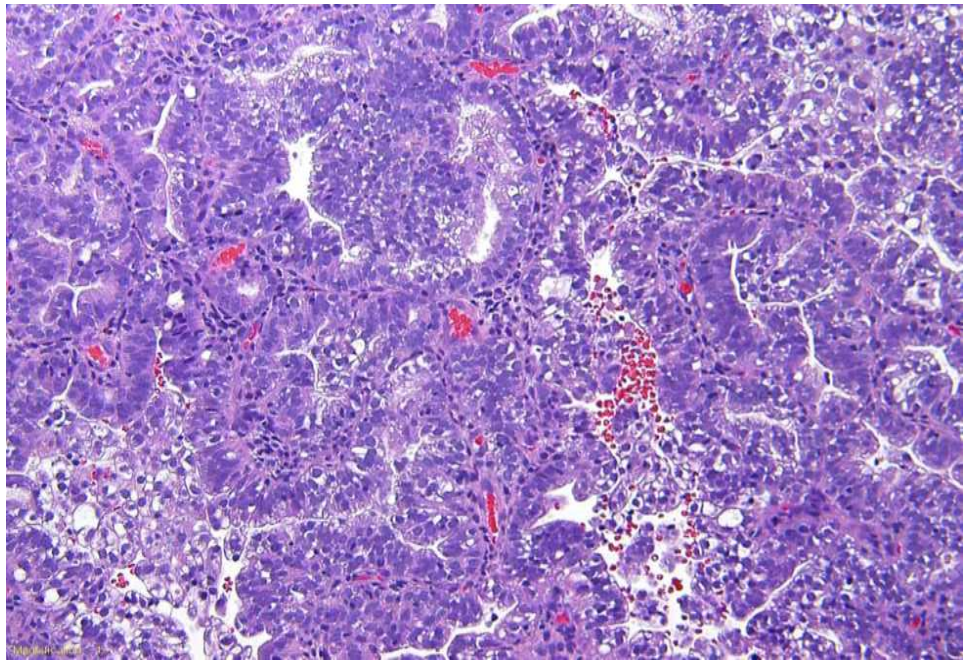

(Mentrikoski et al AJCP. 2012, and Wheeler et al. AJSP 2007;31:988-98)

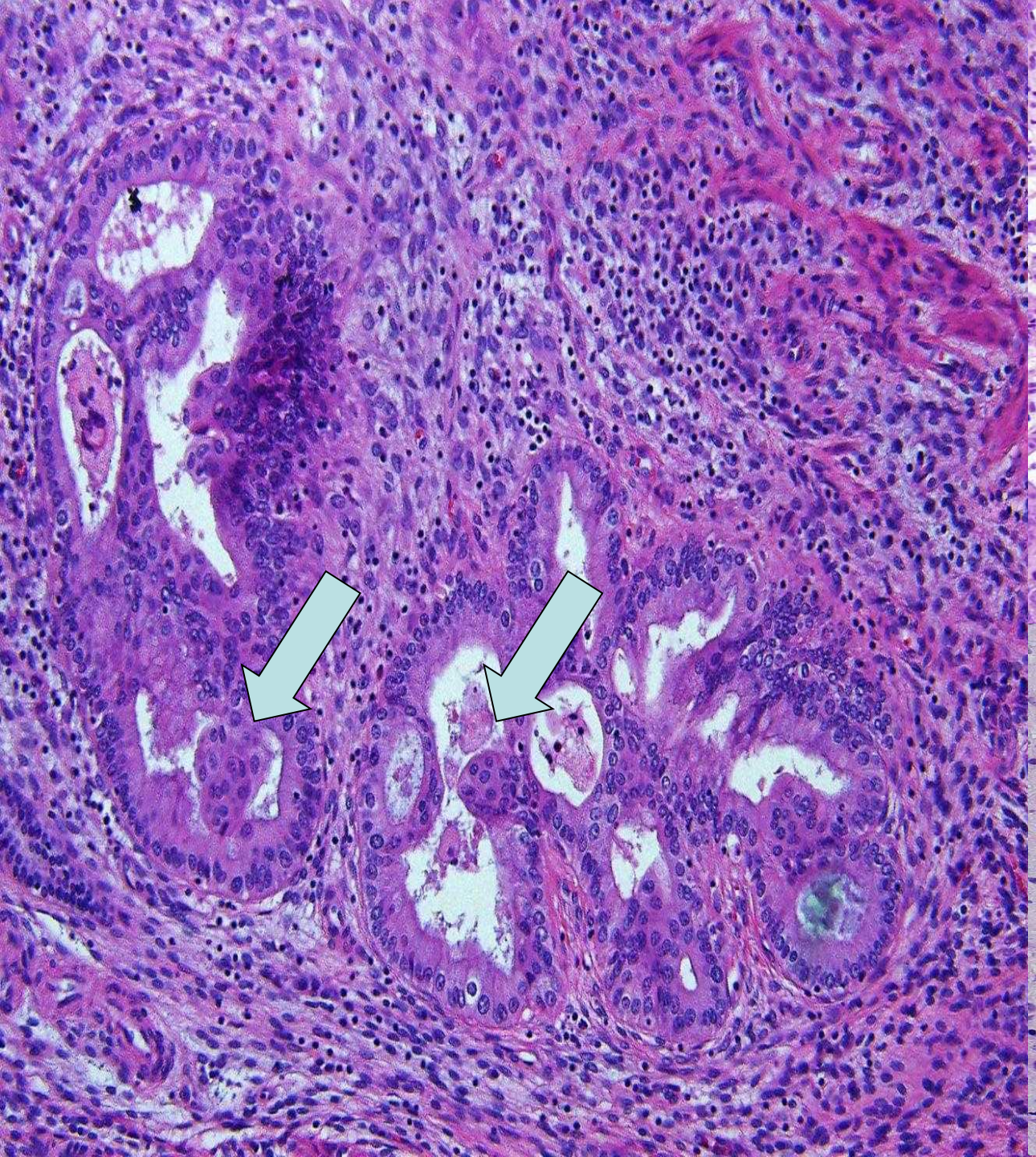

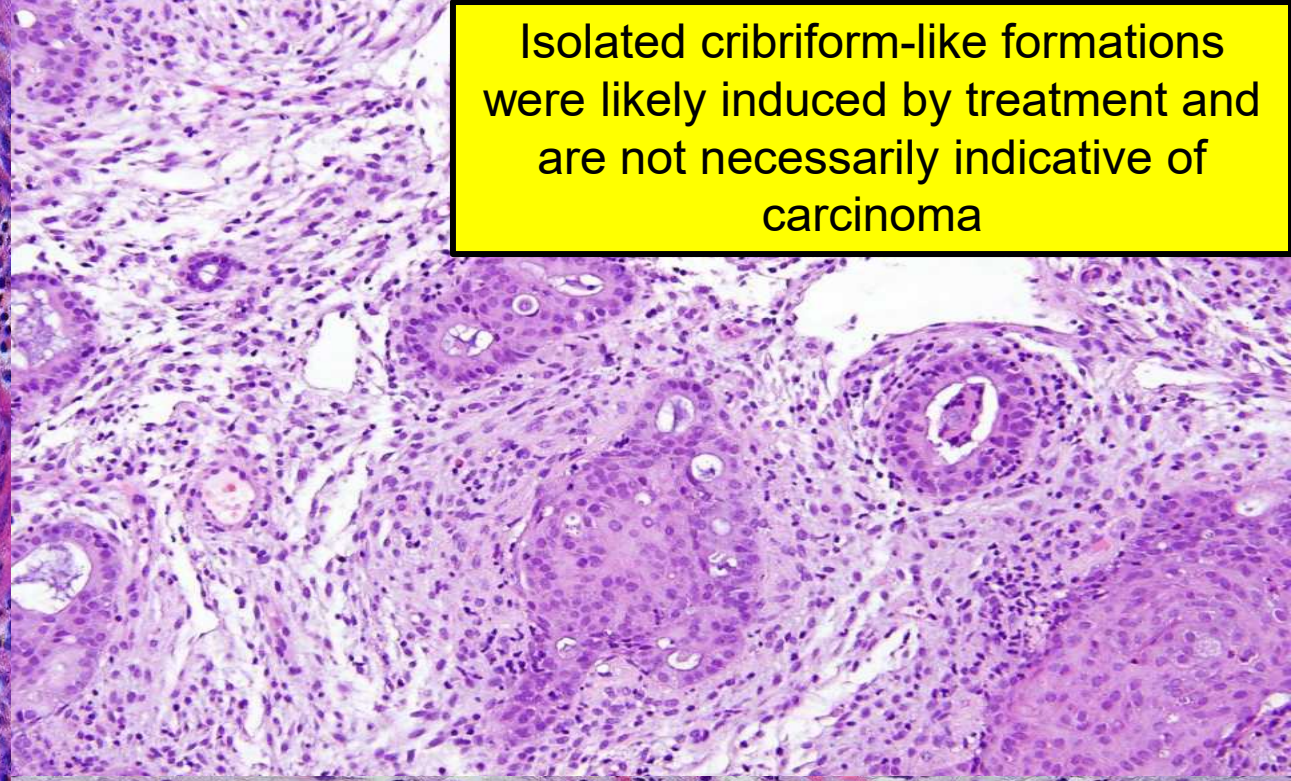

Isolated cribriform-like formations were likely induced by treatment and are not necessarily indicative of carcinoma

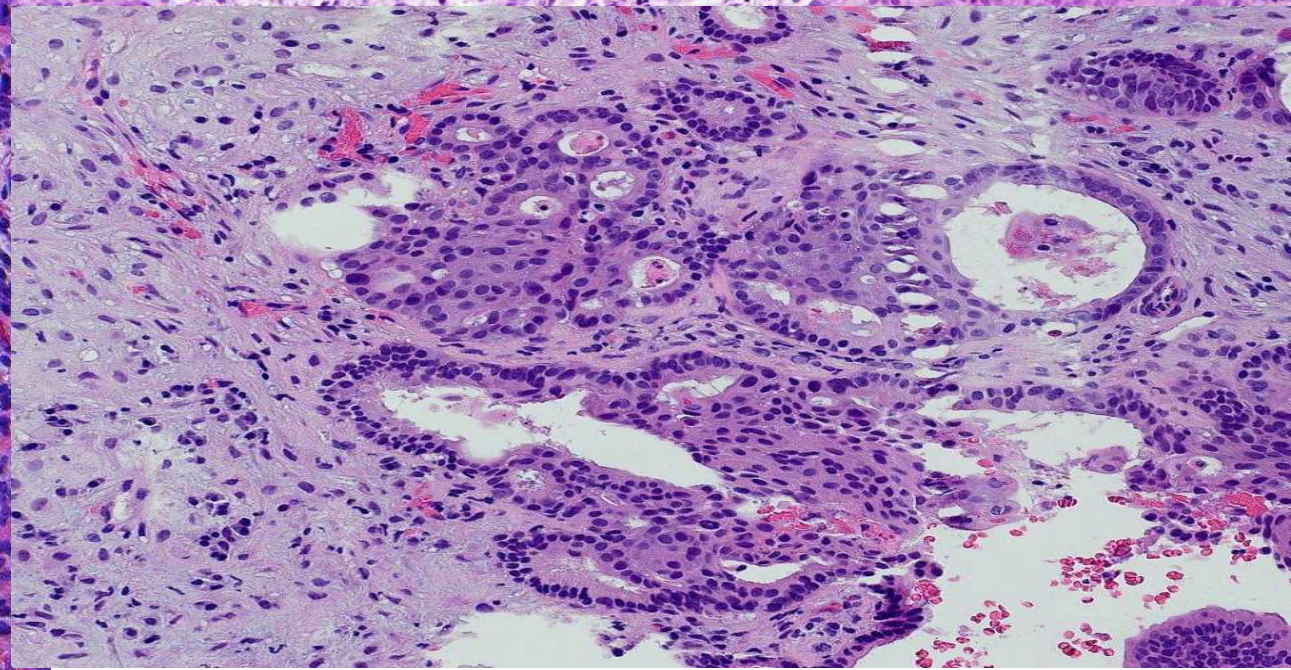

The presence of glands that are abridged by squamous morules, especially when extensive or crowded, is evidence of architectural complexity

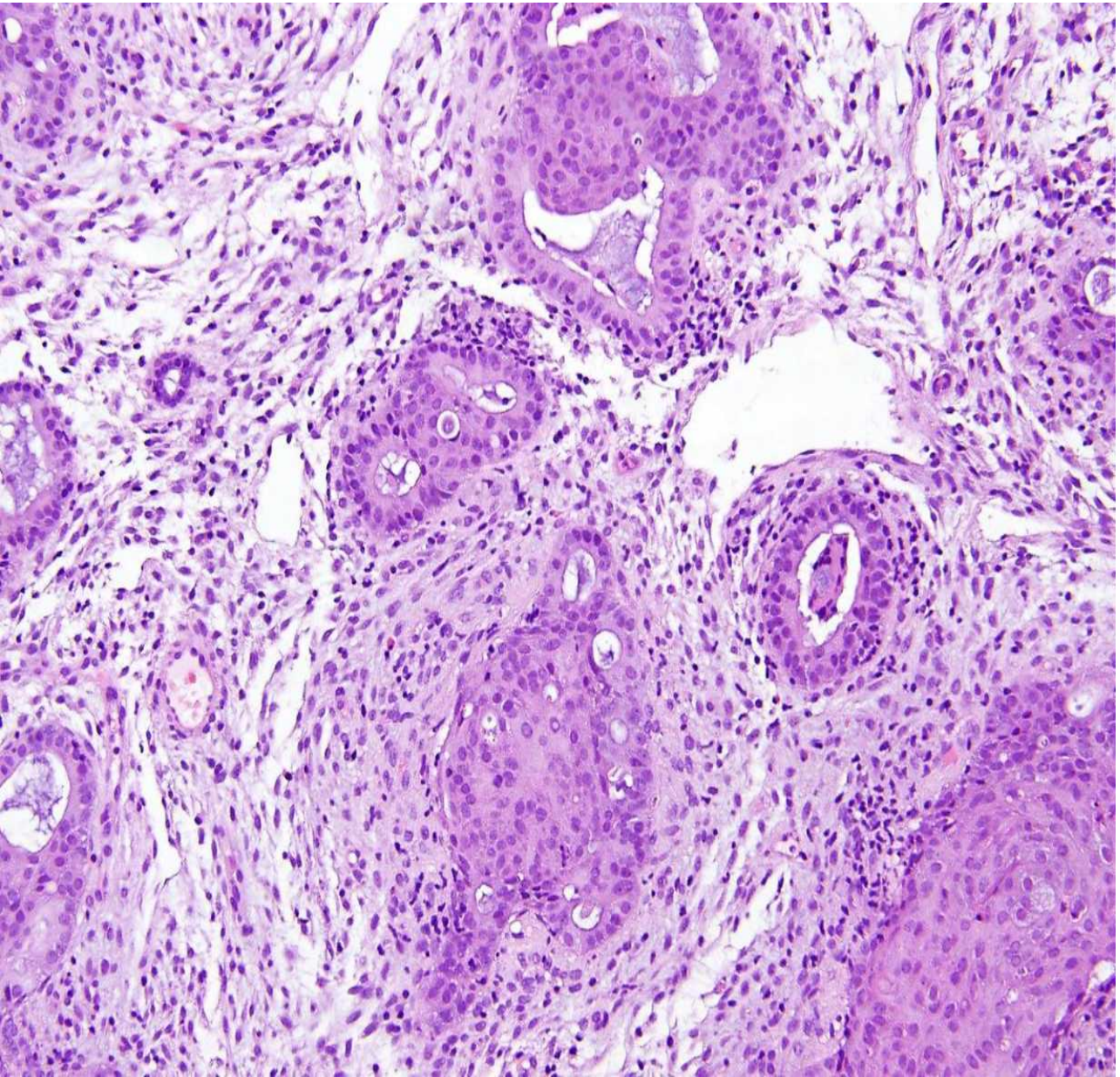

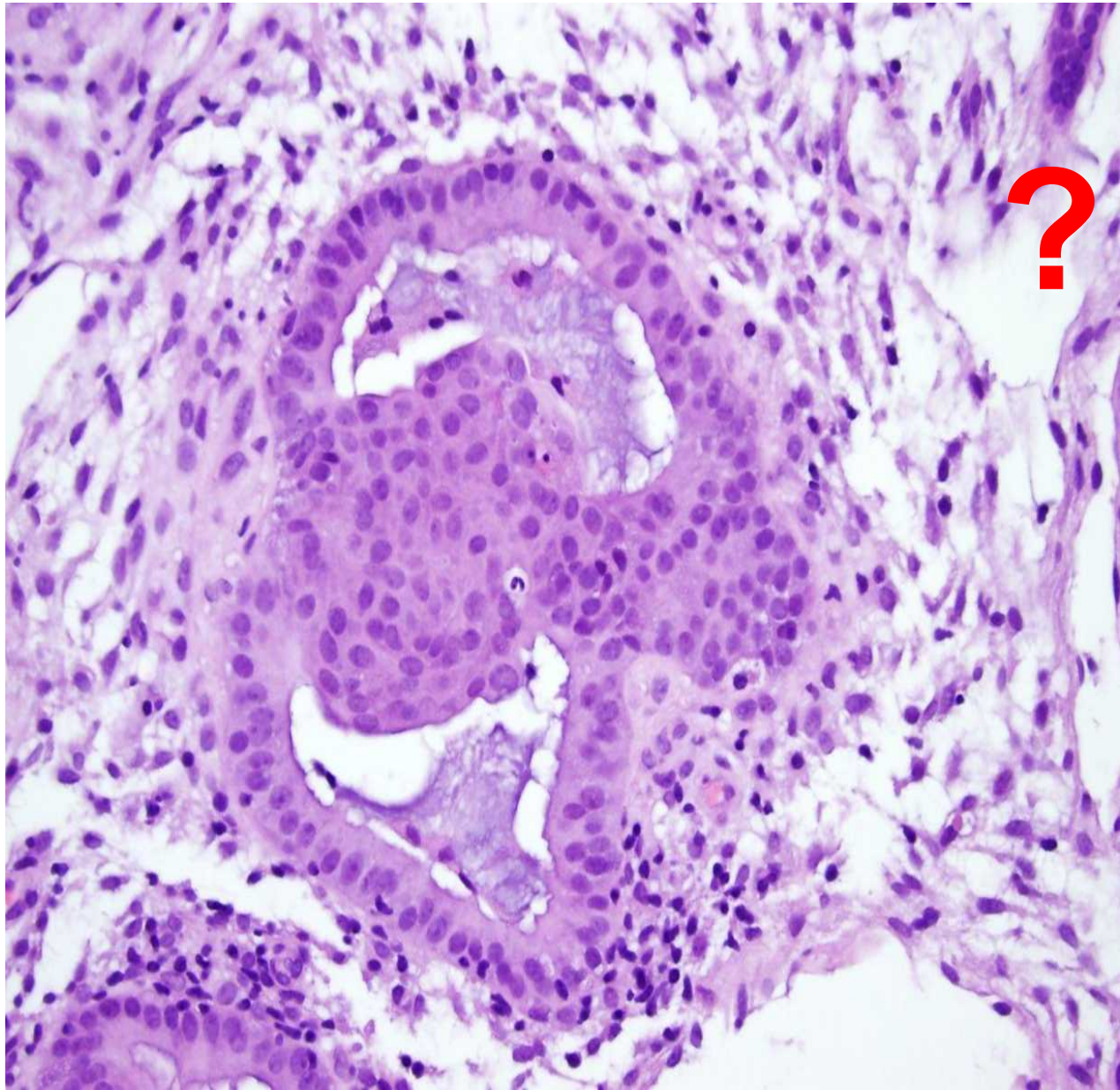

PAPILLARY FORMATIONS

“Broad papillae” are almost certainly induced by progestins [not seen prior to treatment]

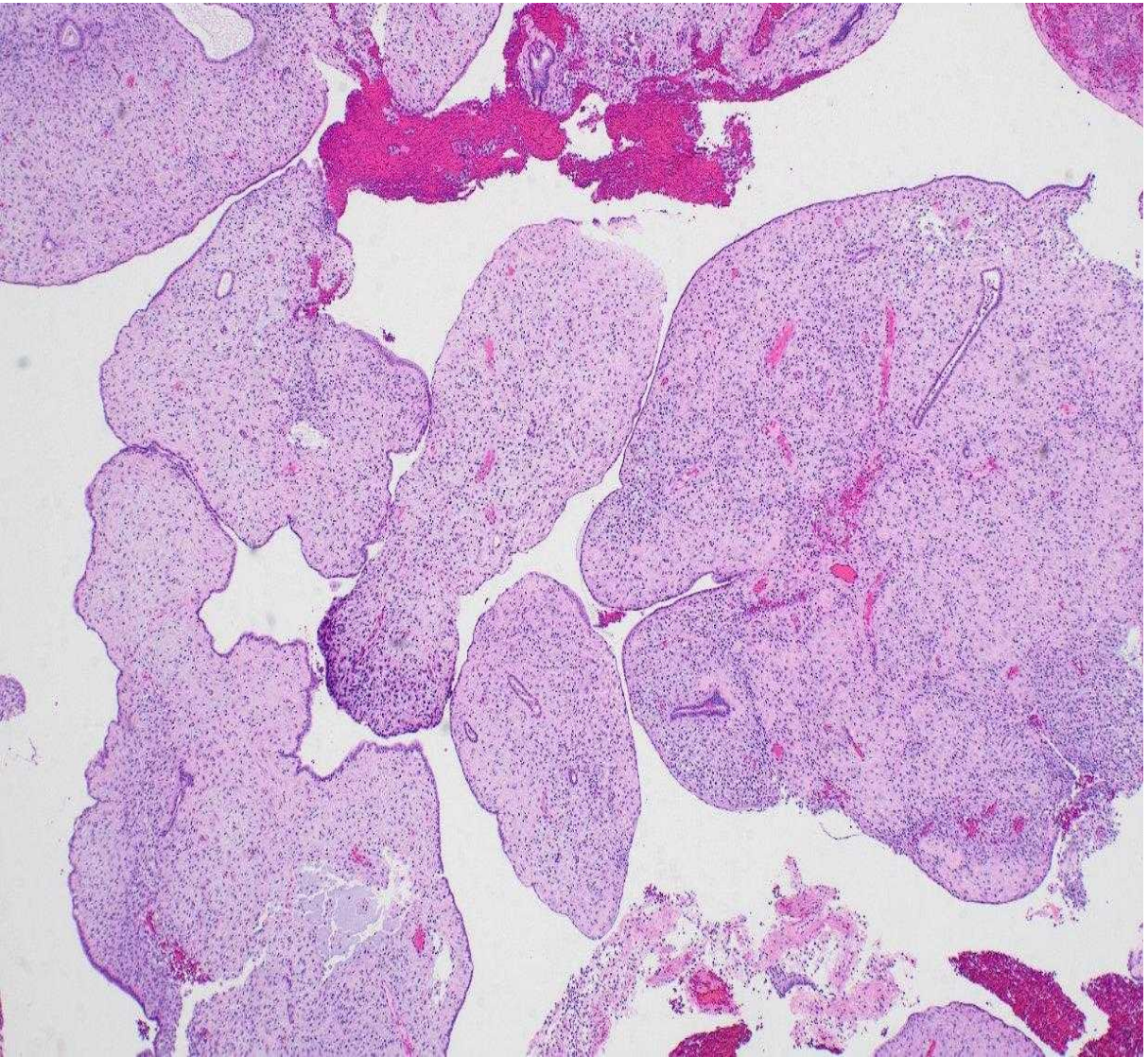

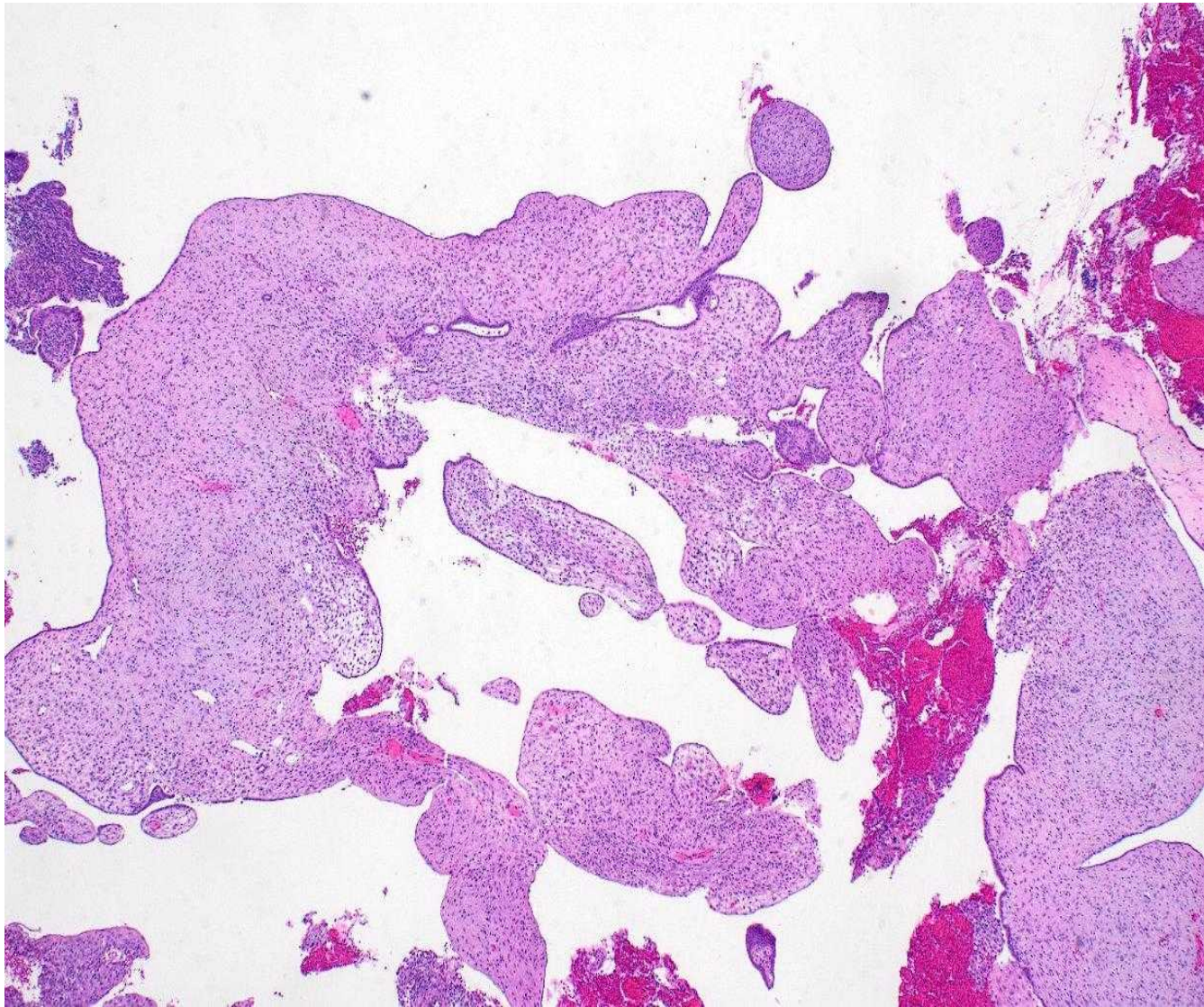

Other papillae forms may also be induced by treatment but can be seen in index samples

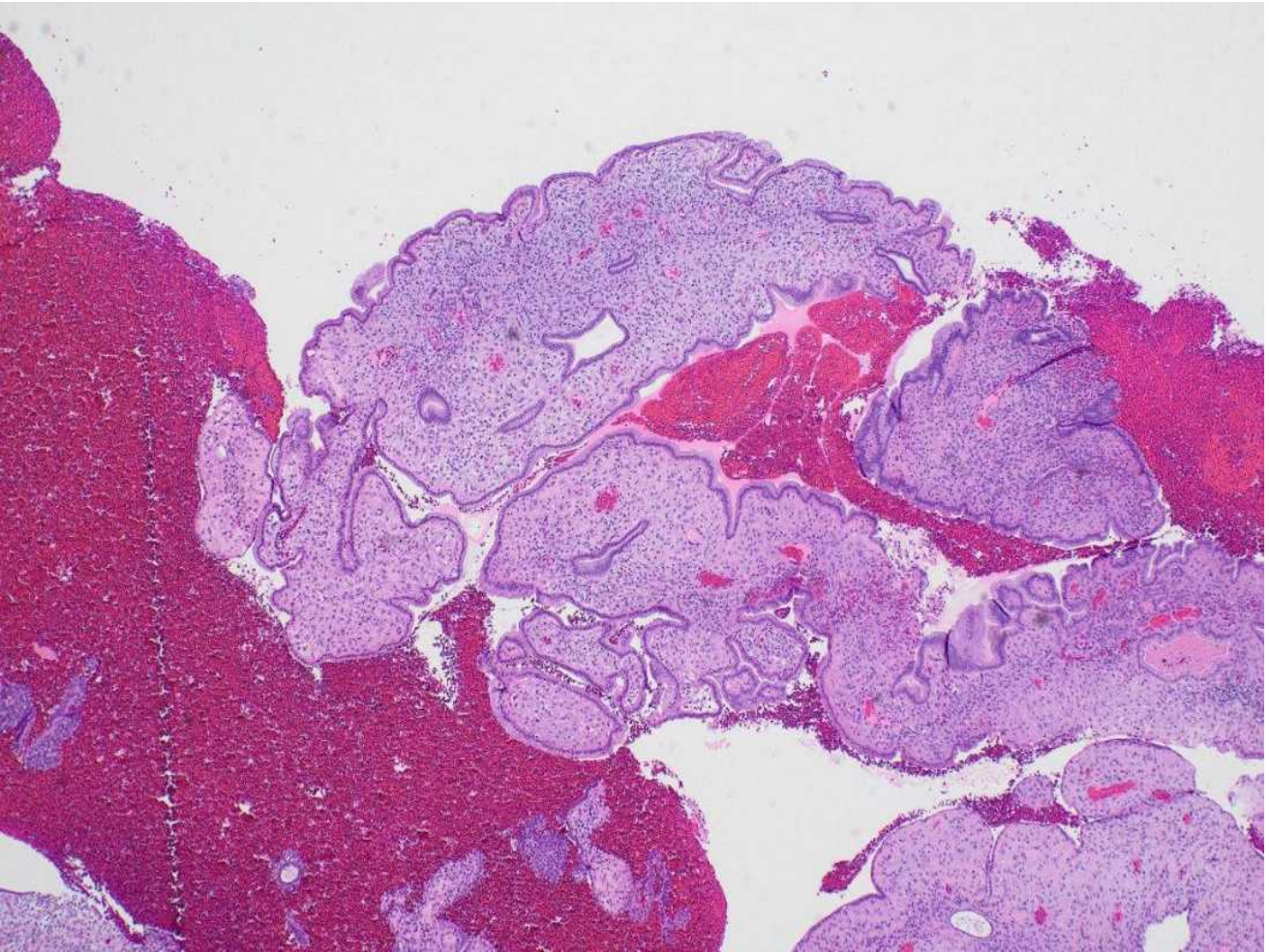

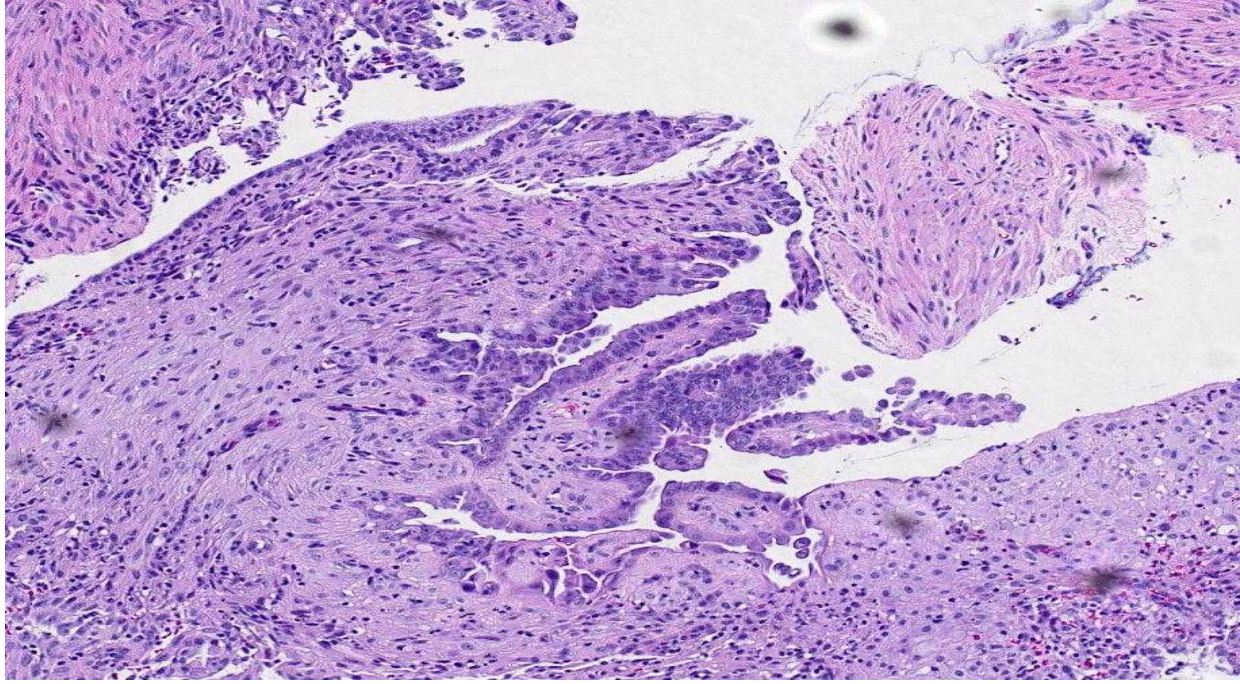

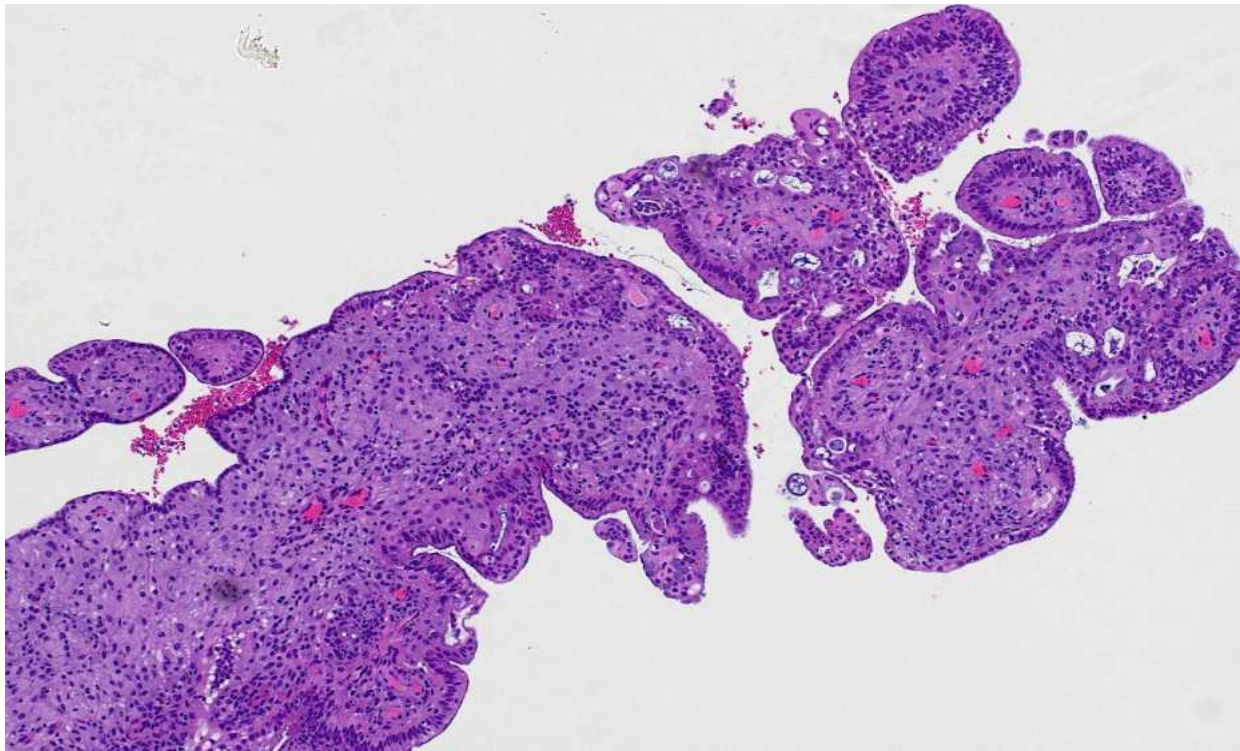

Extensive and architecturally complex papillae are significant, and are diagnostic of at least AEH

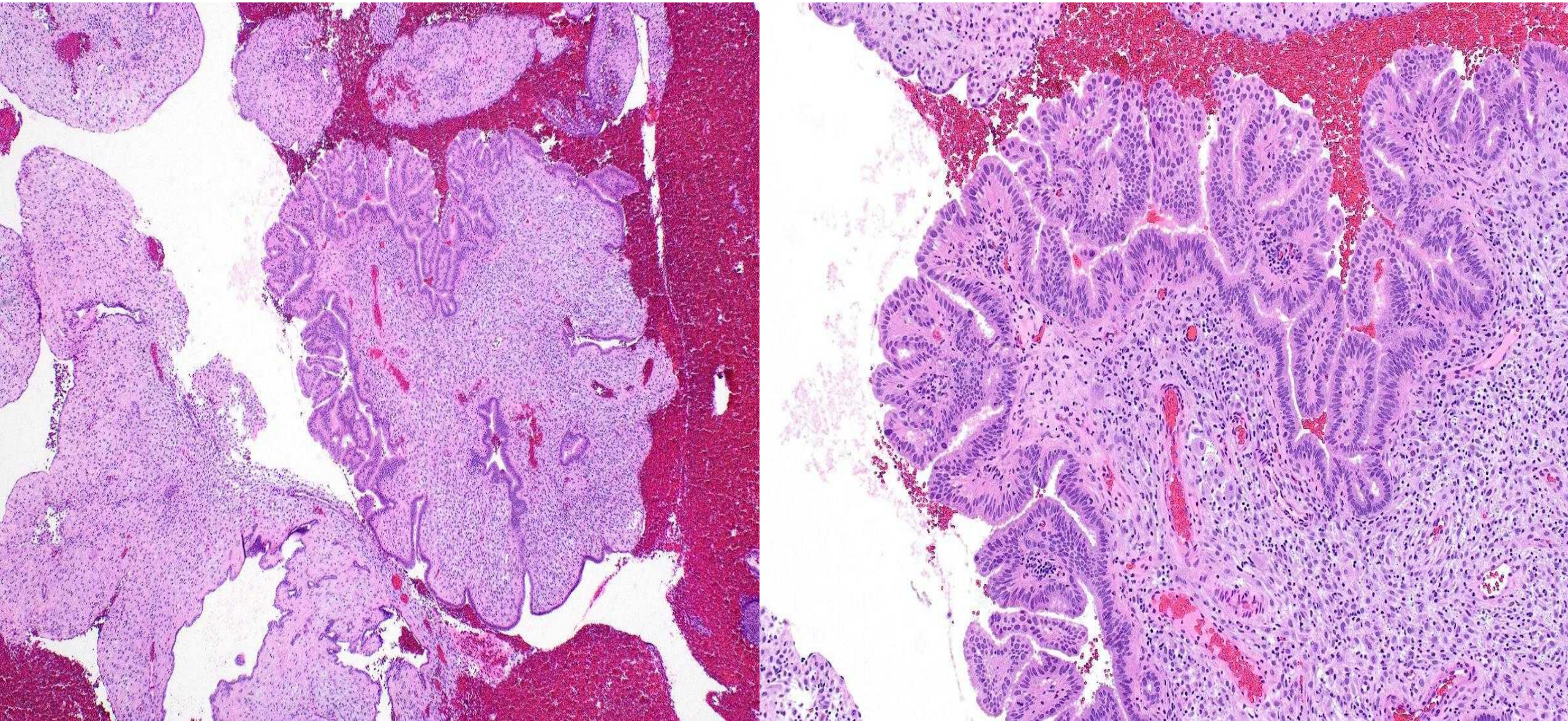

Extensive and architecturally complex papillae are significant, and are diagnostic of at least AEH

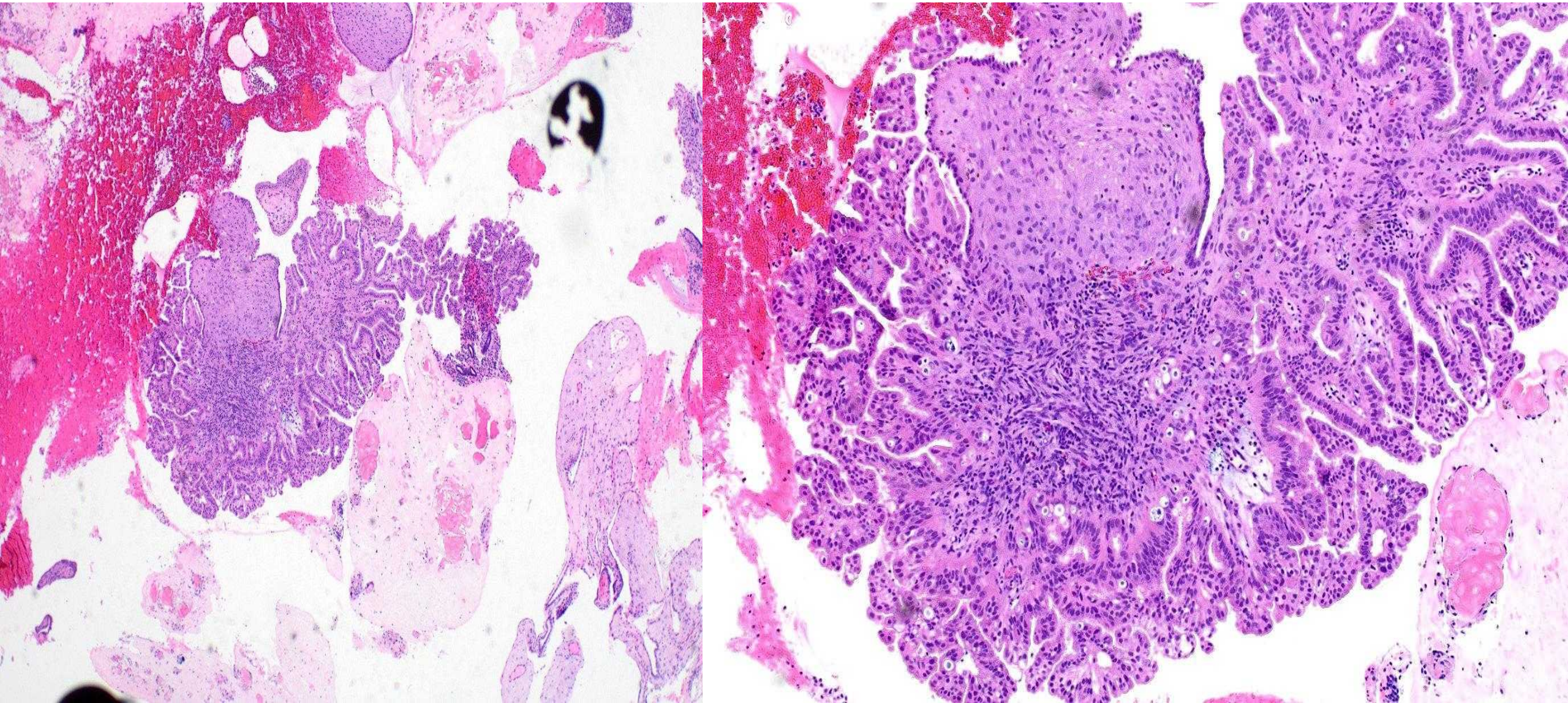

Extensive and complicated papillae are indicative of at least AEH

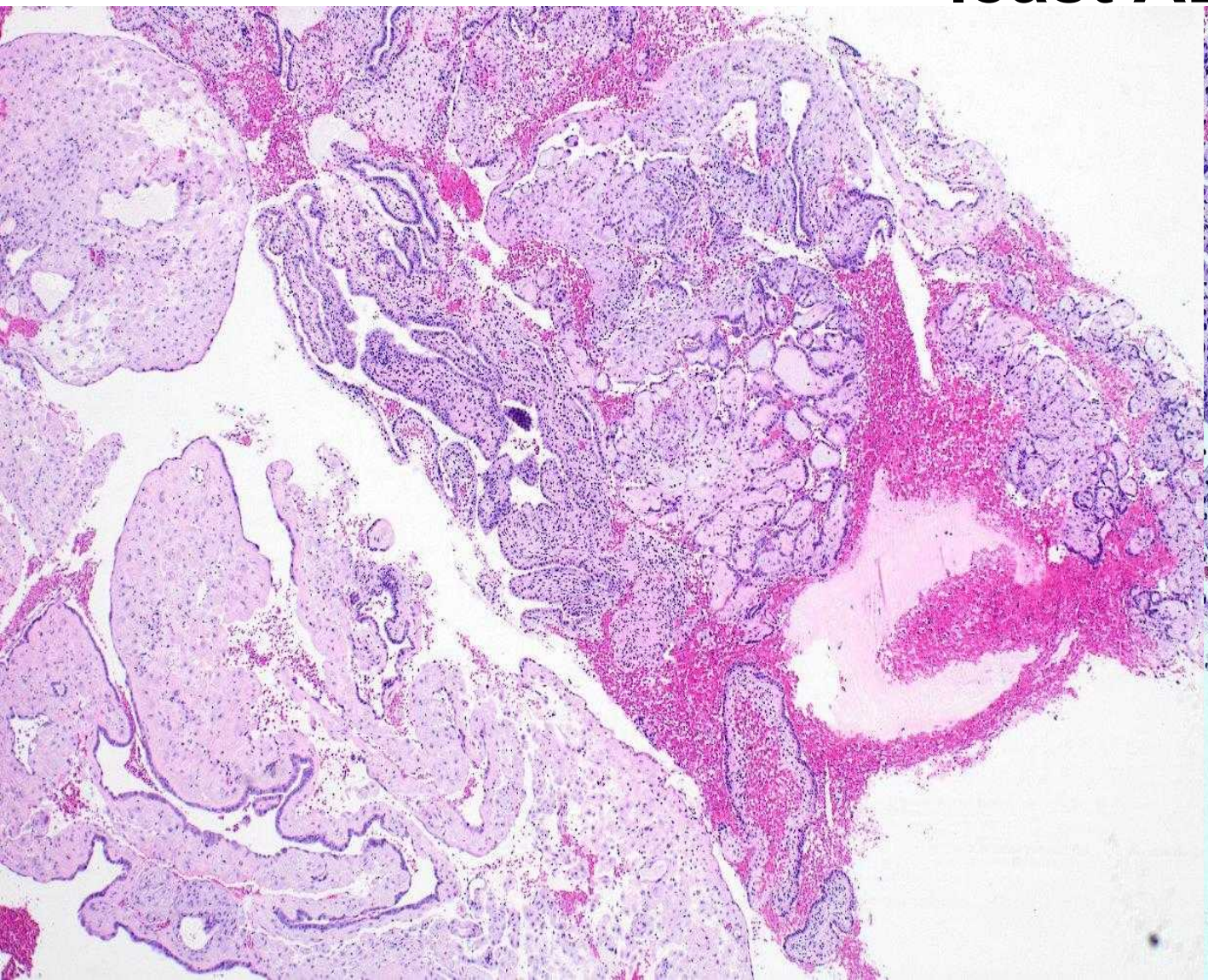

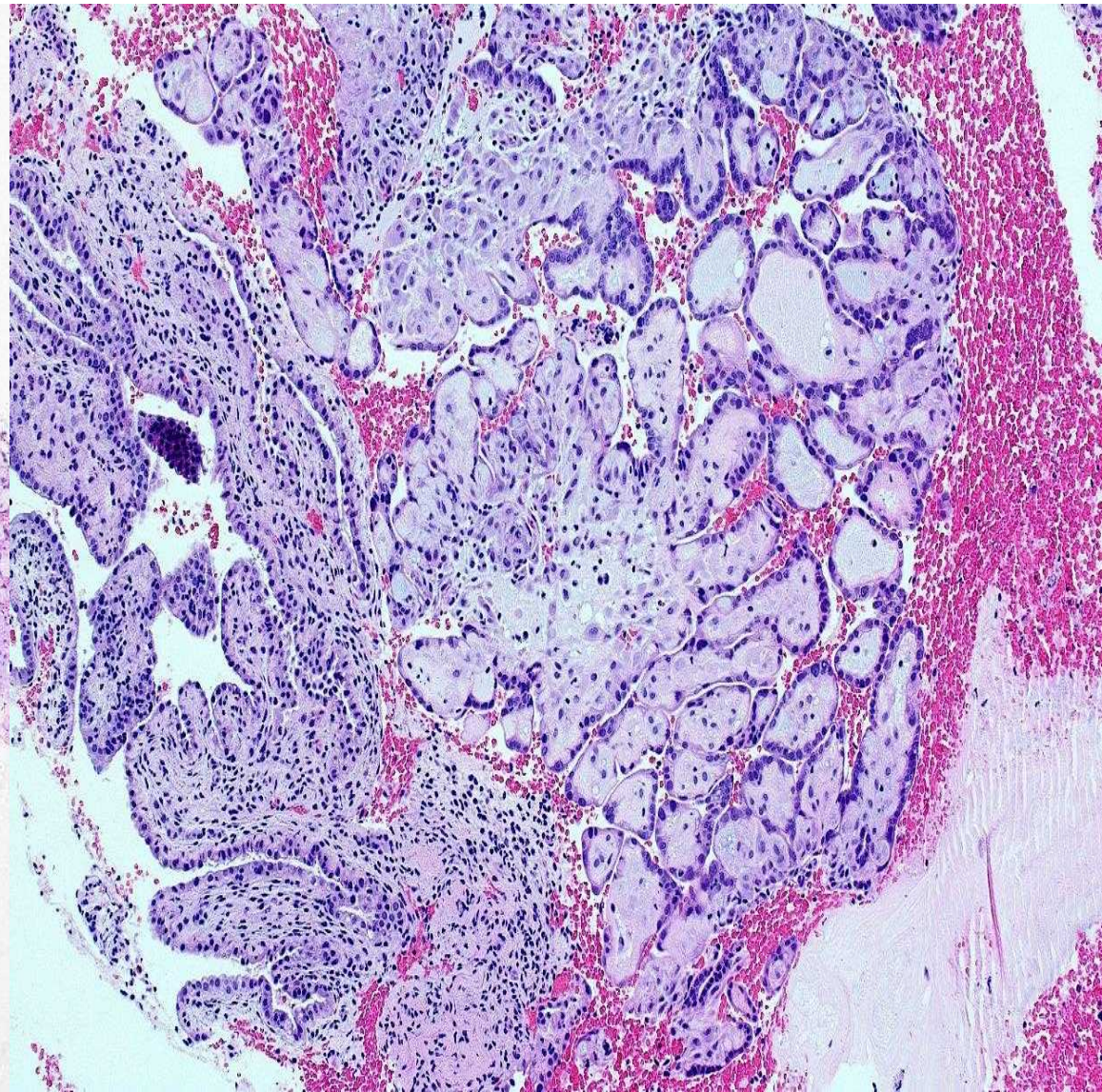

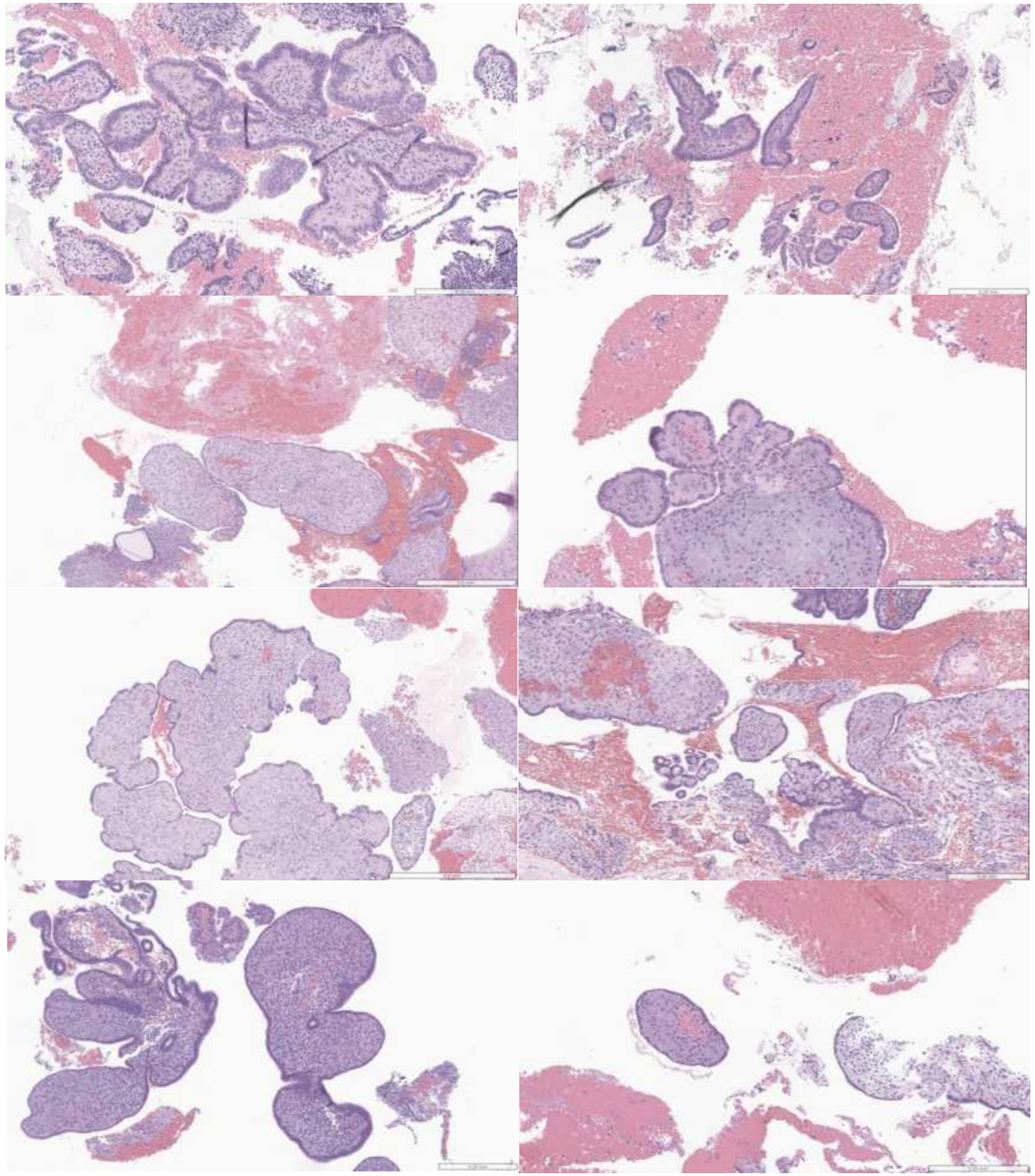

?

“Broad papillae” that are branching are of uncertain significance

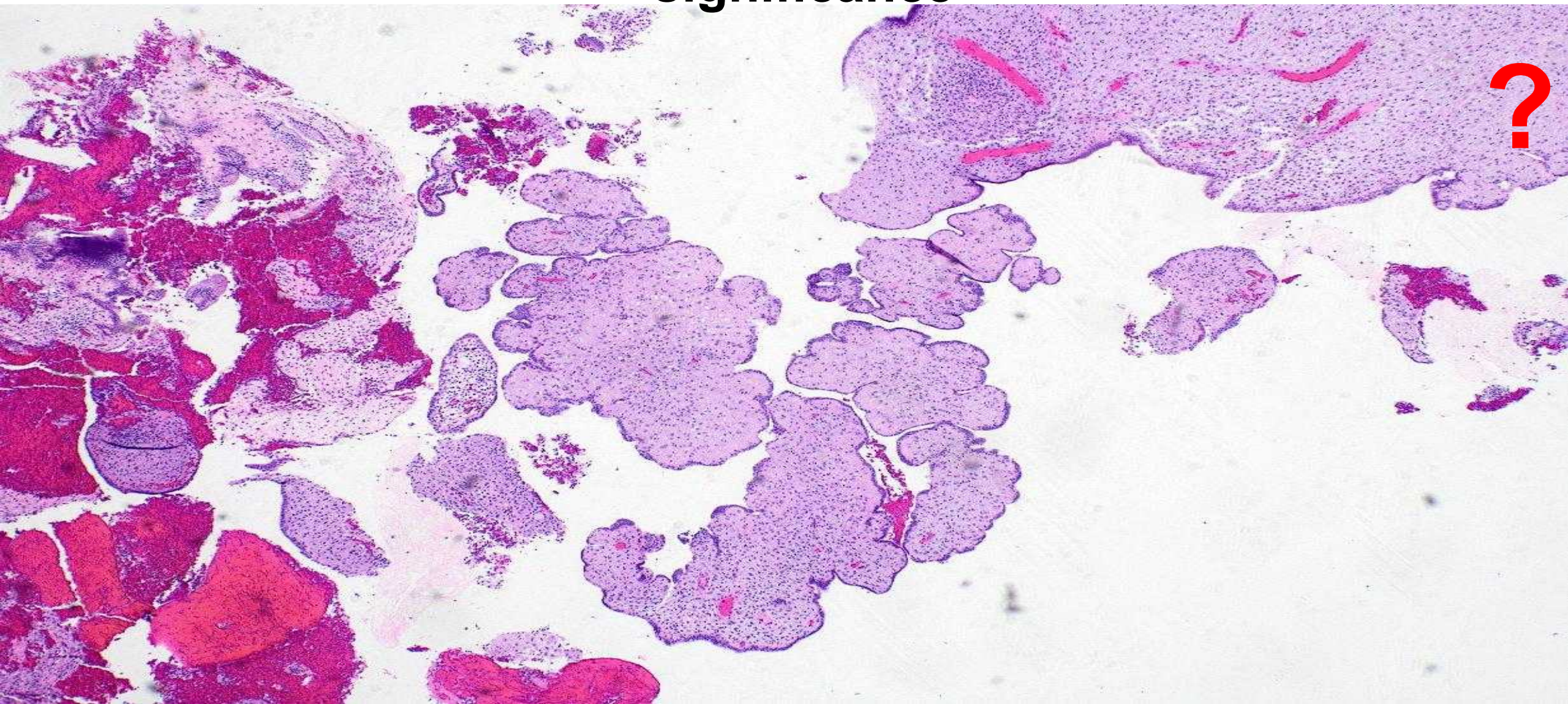

Histologic Alterations in Endometrial Hyperplasia and Well-differentiated Carcinoma Treated With Progestins

(*Am J Surg Pathol* 2007;31:988–998)

Darren T. Wheeler, MD, Robert E. Bristow, MD,† and Robert J. Kurman, MD‡*

- **Cribriform and/or papillary pattern present at 1-3 mo biopsy**
  - 35% showed resolution/regression in final specimen
- **Cribriform and/or papillary pattern present at 4-6 mo biopsy**
  - 33% showed resolution/regression in final specimen
- **Cribriform and/or papillary pattern present at 7-9 mo biopsy**
  - 0% showed resolution/regression in final specimen

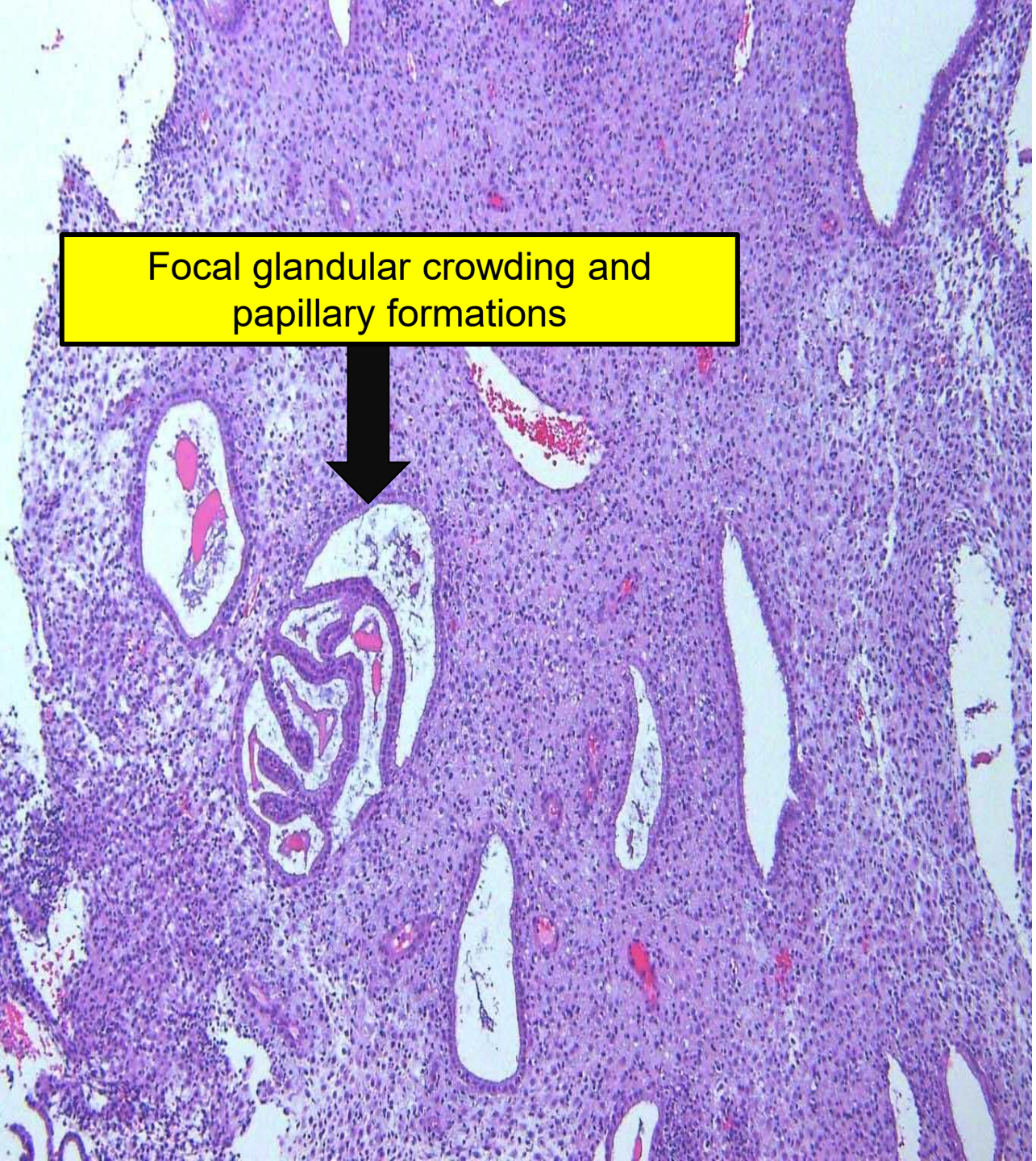
Focal glandular crowding and
papillary formations

CYSTIC GLANDS

17% of cases show conspicuous glandular cystic dilation in a follow-up sample.

-Wheeler et al. Am J Surg Pathol 2007;31:988–998

Histologic Alterations in Endometrial Hyperplasia and Well-differentiated Carcinoma Treated With Progestins

(*Am J Surg Pathol* 2007;31:988–998)

Darren T. Wheeler, MD, Robert E. Bristow, MD,† and Robert J. Kurman, MD‡*

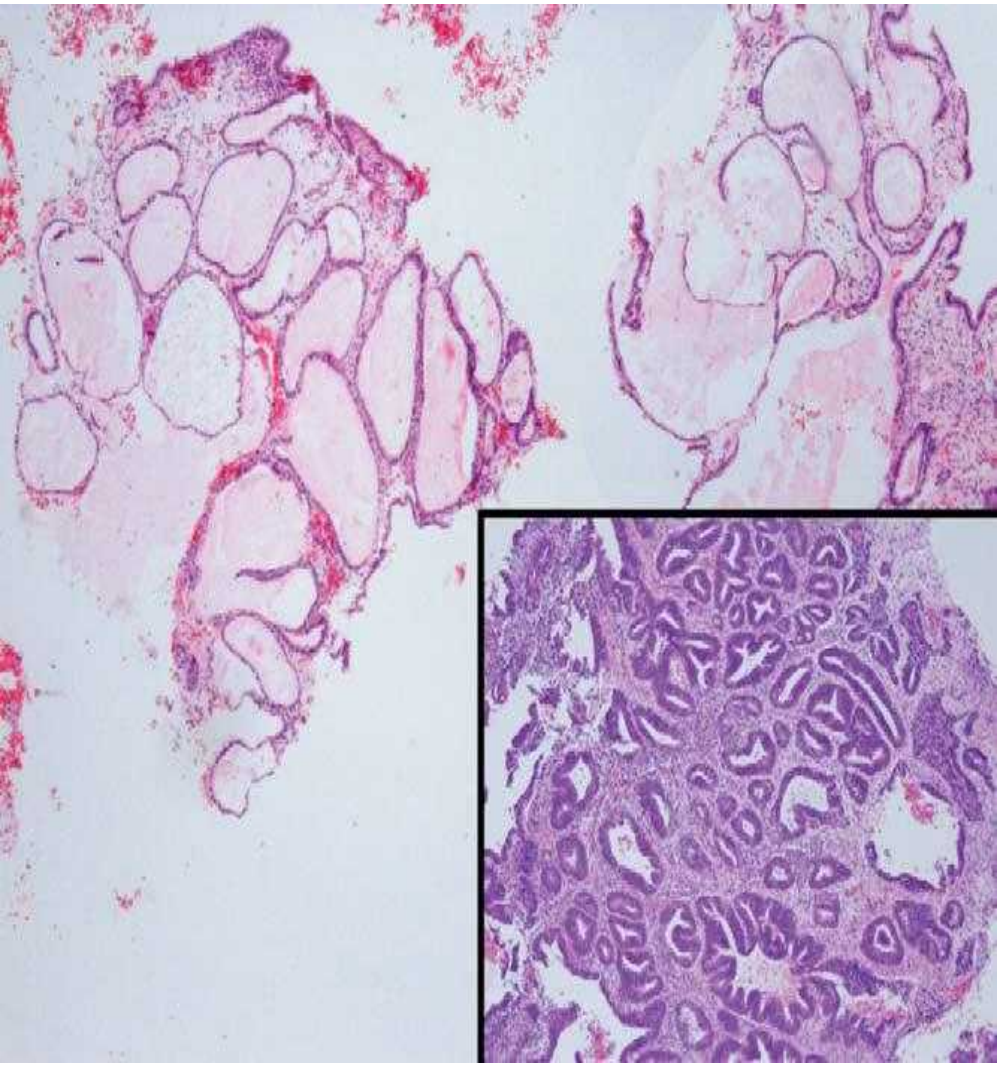

- **“crowded, cystically dilated glands lined by flattened inactive epithelium resembling cystic atrophy”.**

AEH after 3 months of progestin treatments:

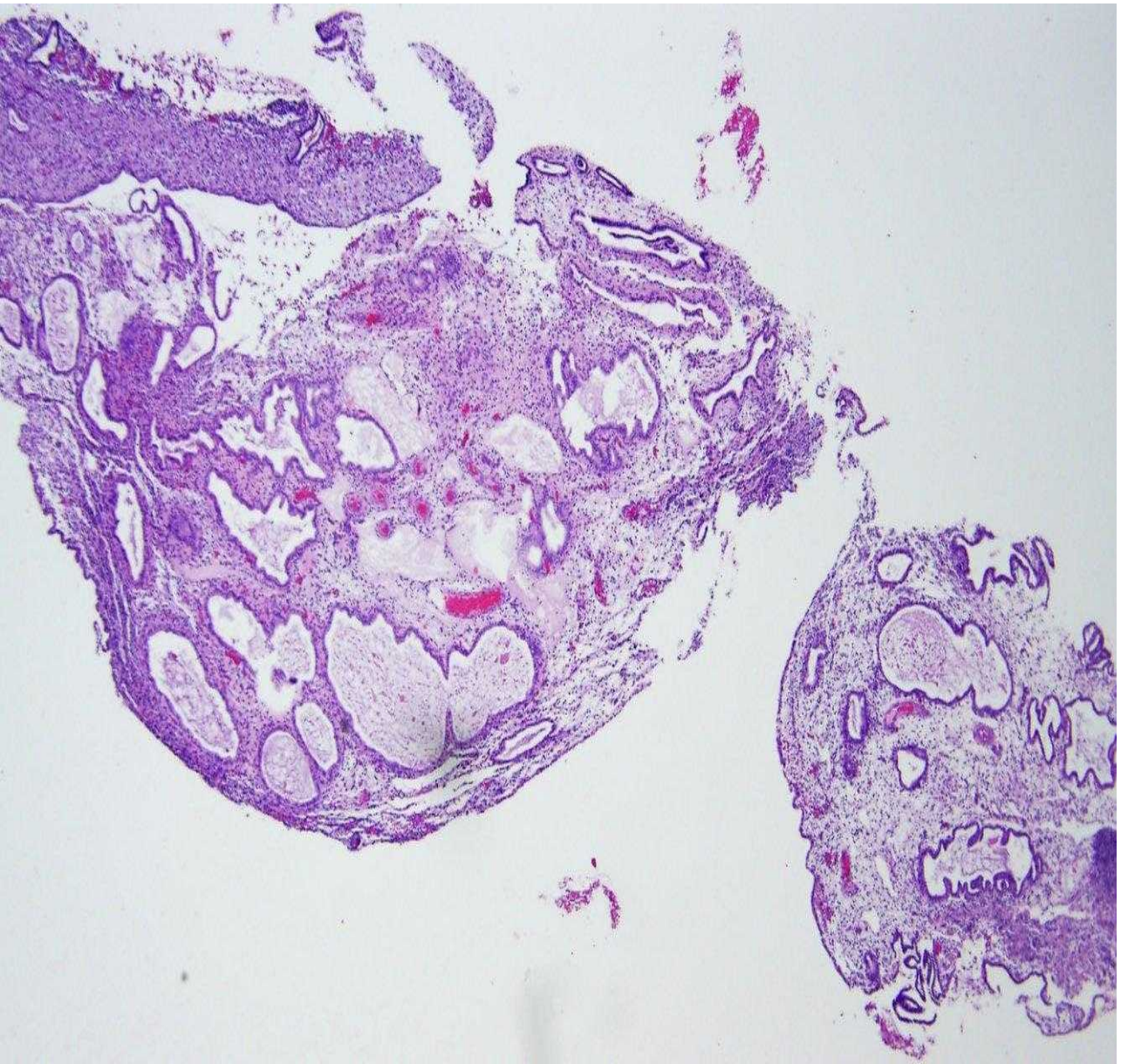

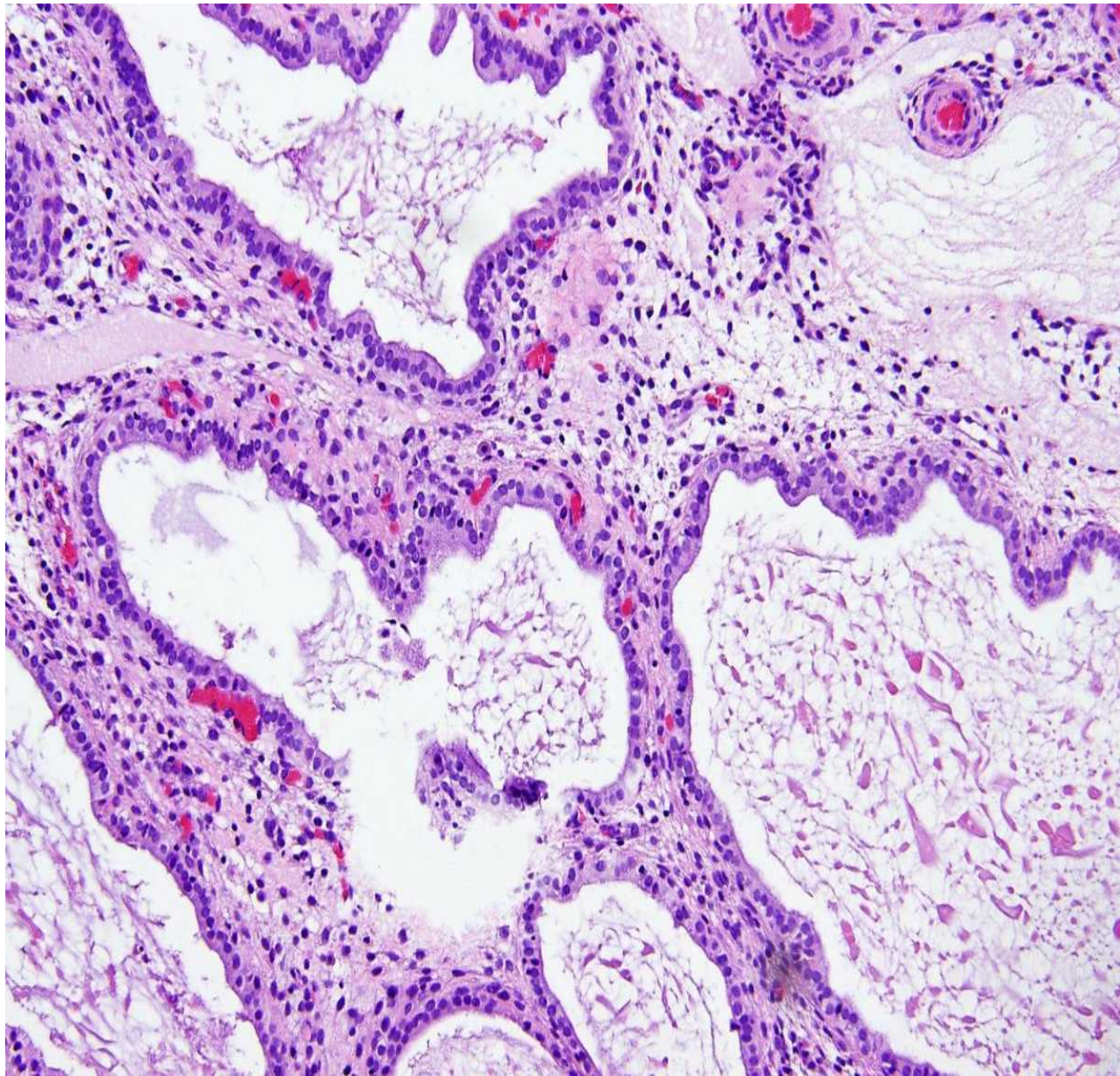

BAGP/ISGyP Survey of 95 Pathologists

- 52.6% of respondents regarded this as negative for hyperplasia and 16.8% categorised this as residual atypical hyperplasia

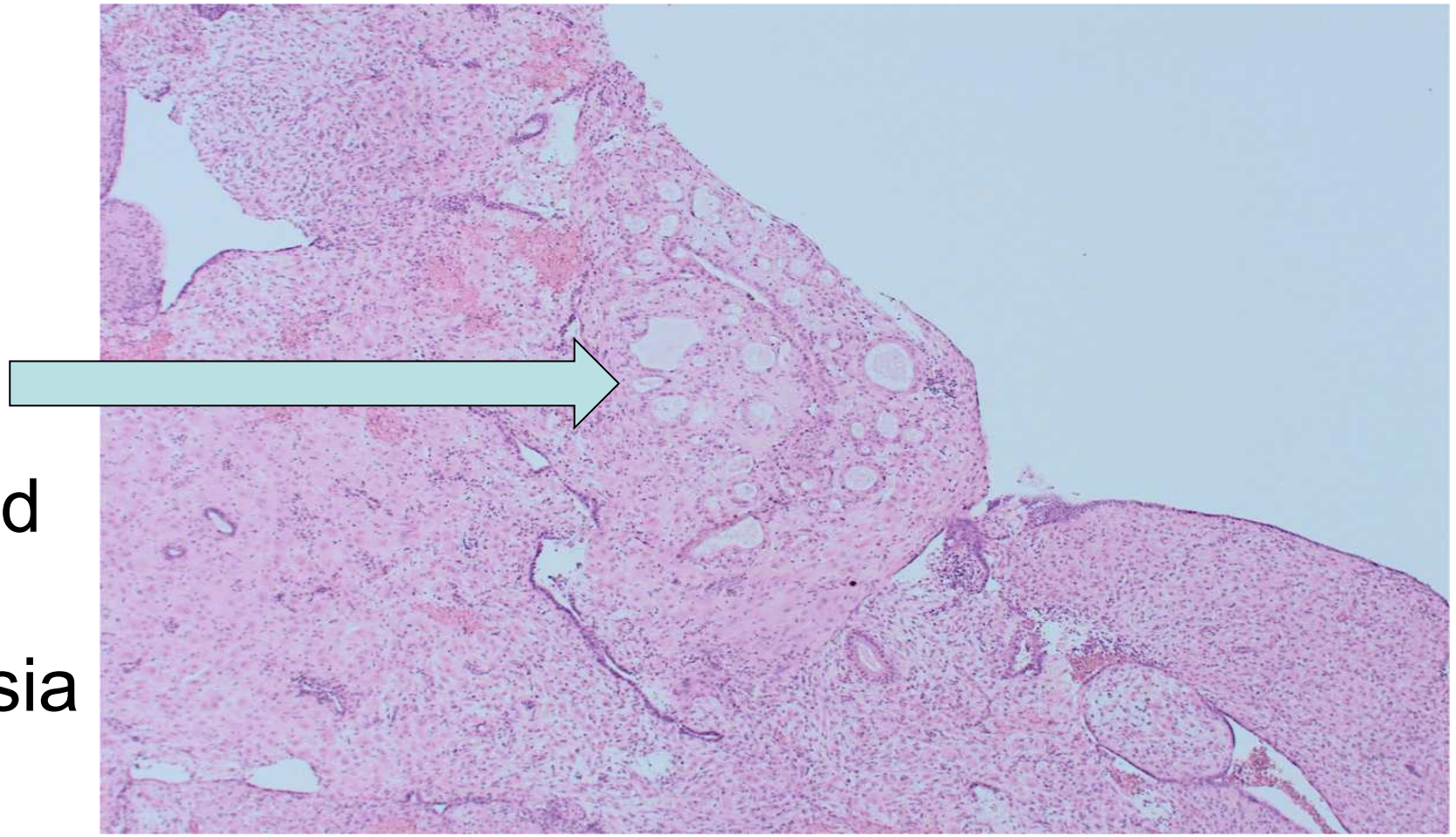

Ganesan R, et al. Int J Gynecol Pathol. 2022 Mar 1;41(2):142-150

ATROPHIC CYSTS:
POSSIBLY WORRISOME WHEN CROWDED OR EXTENSIVE

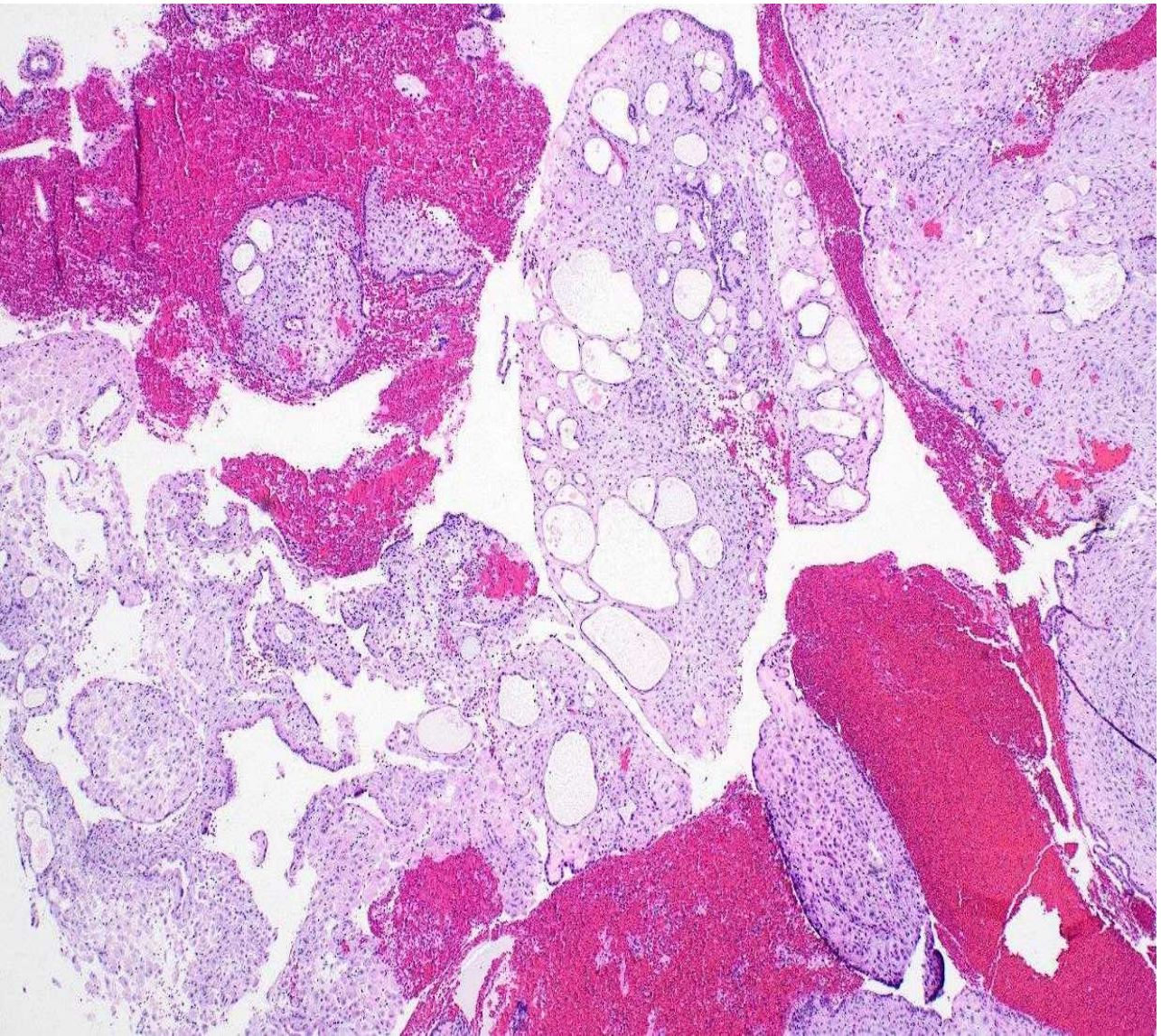

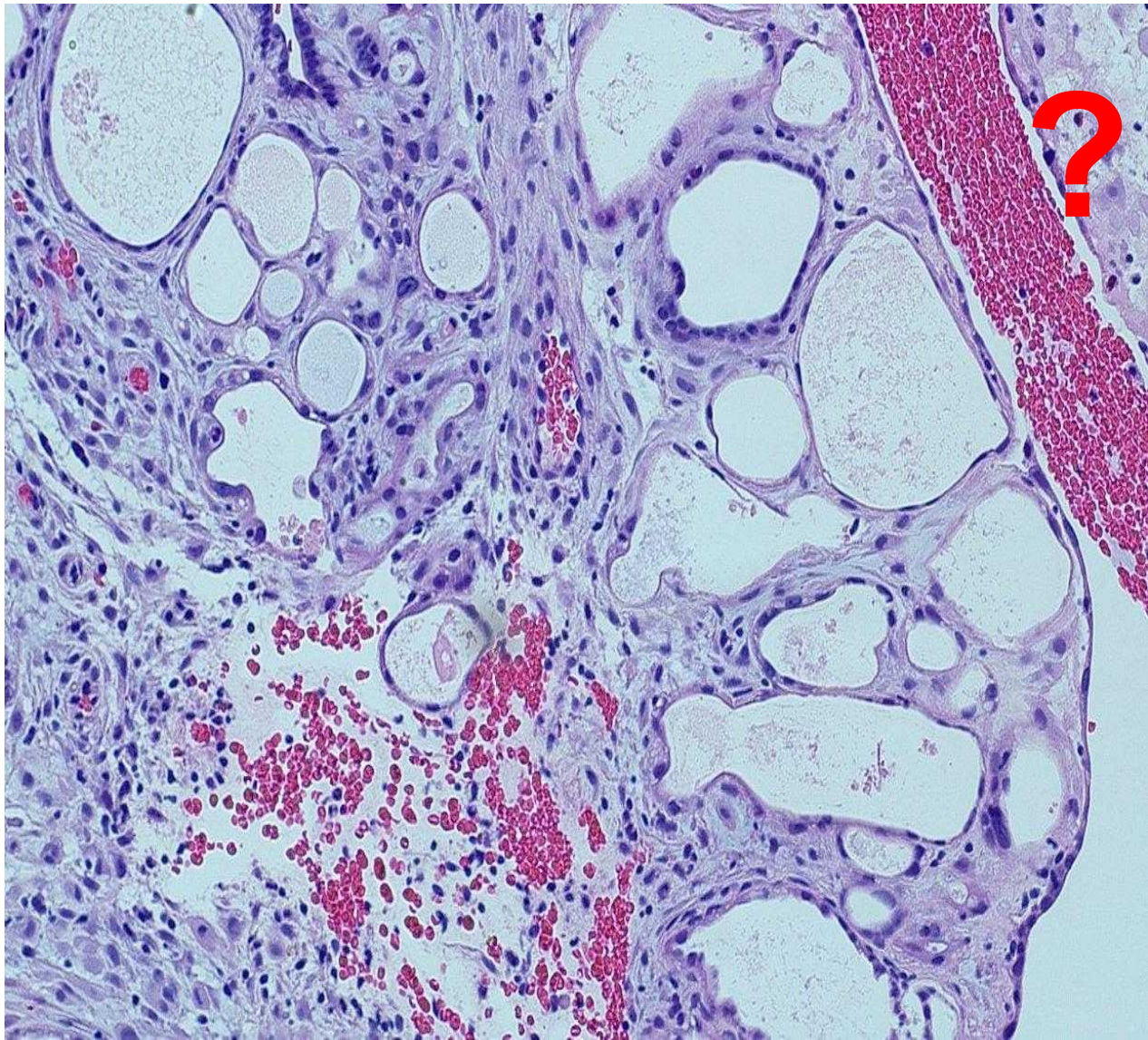

AEH AFTER 6 MONTHS OF THERAPY:

PARTIALLY CONFLUENT, CYSTIC GLANDS, AND MORULE-ABRIDGED GLANDS, LINED BY NON-ATROPHIC, NON-ATYPICAL EPITHELIUM

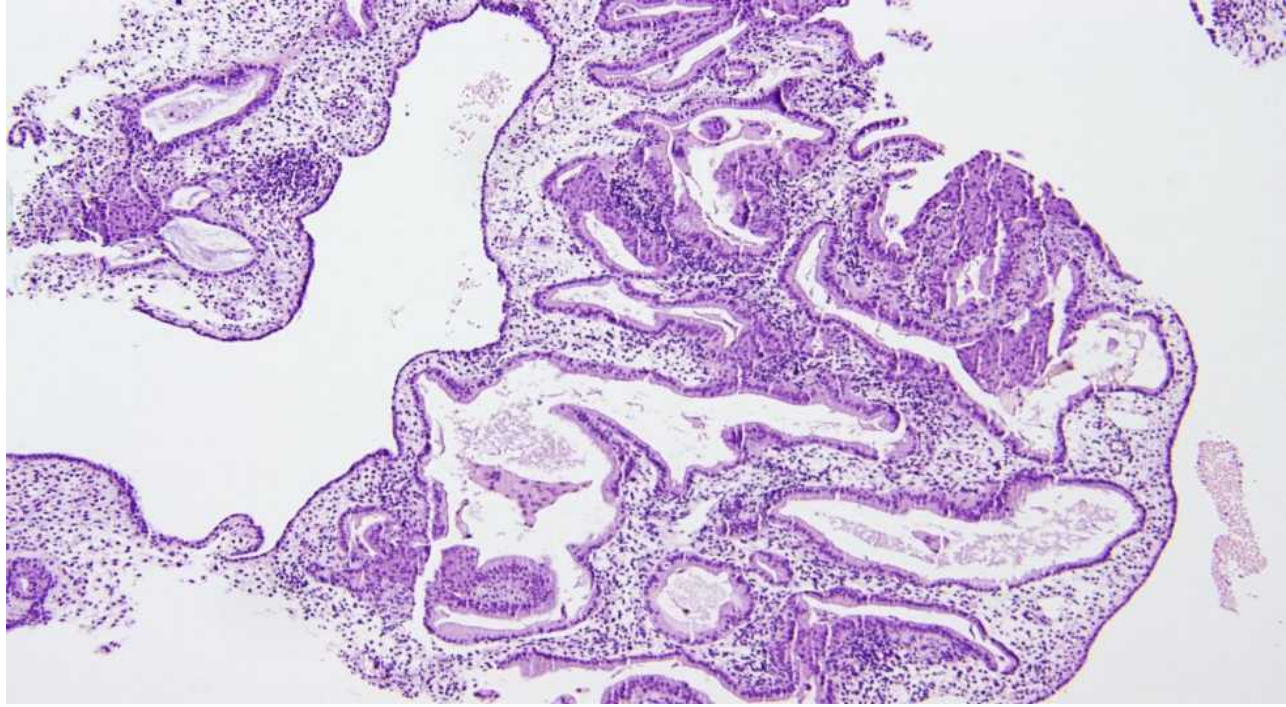

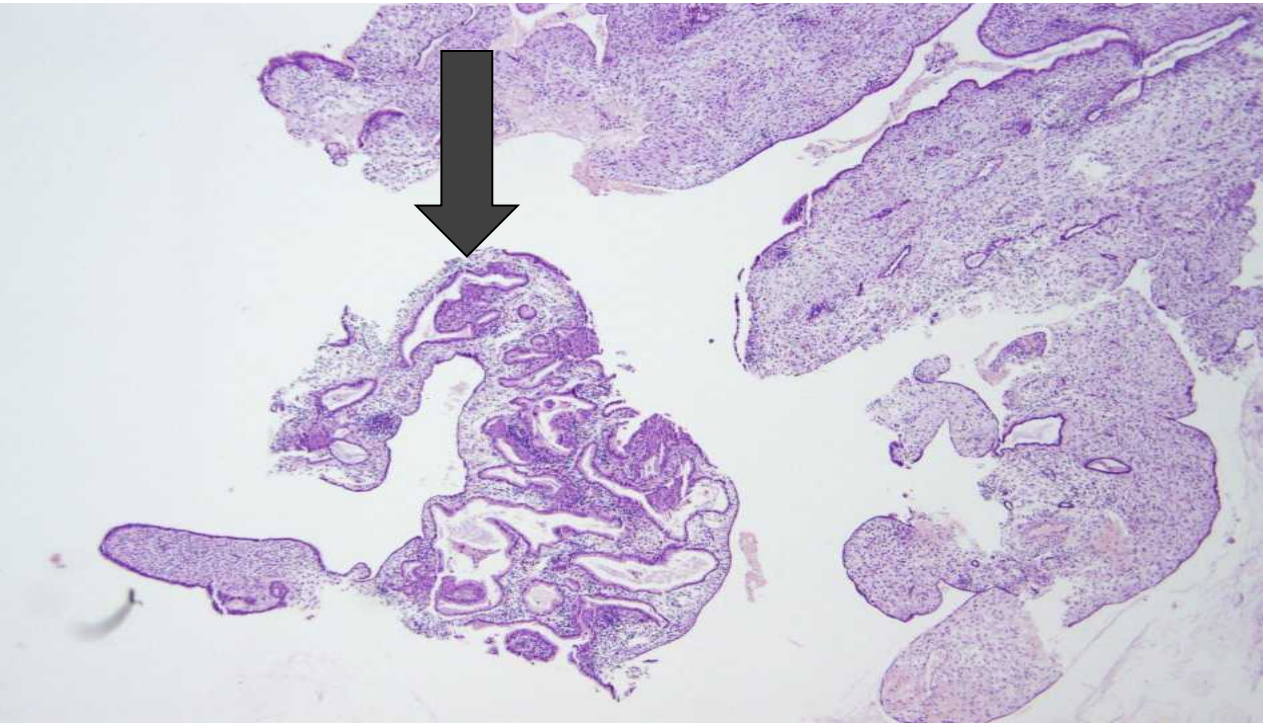

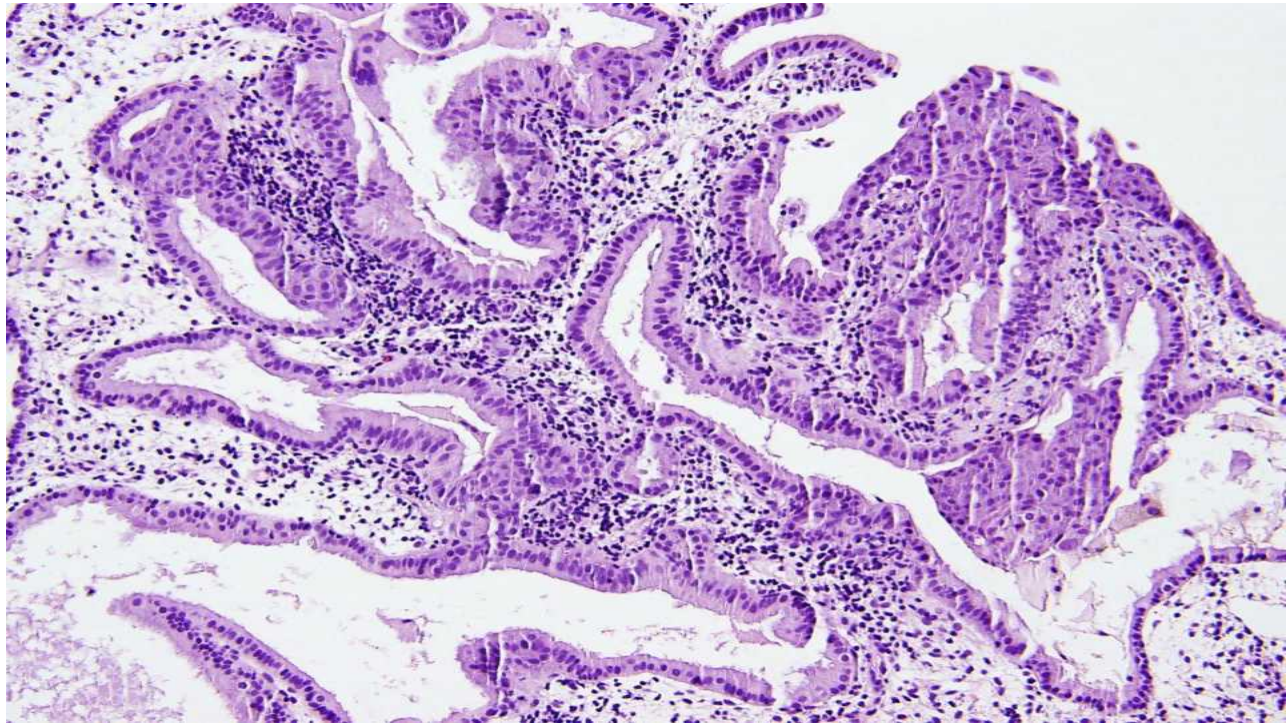

Scattered Atrophic Cysts

Non-diagnostic of residual hyperplasia

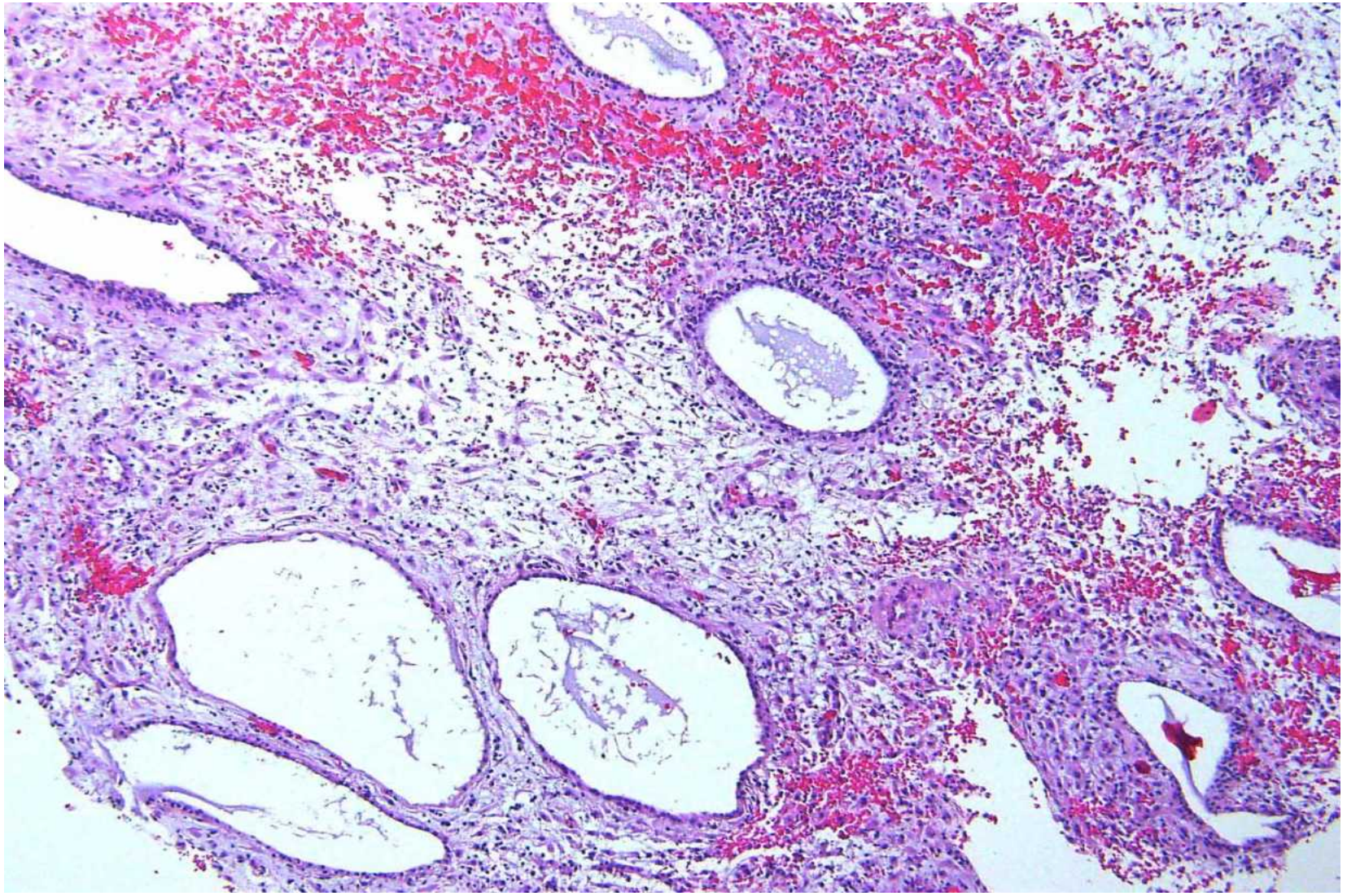

Basalis glands in progestin-treated patients tend to be cystically dilated

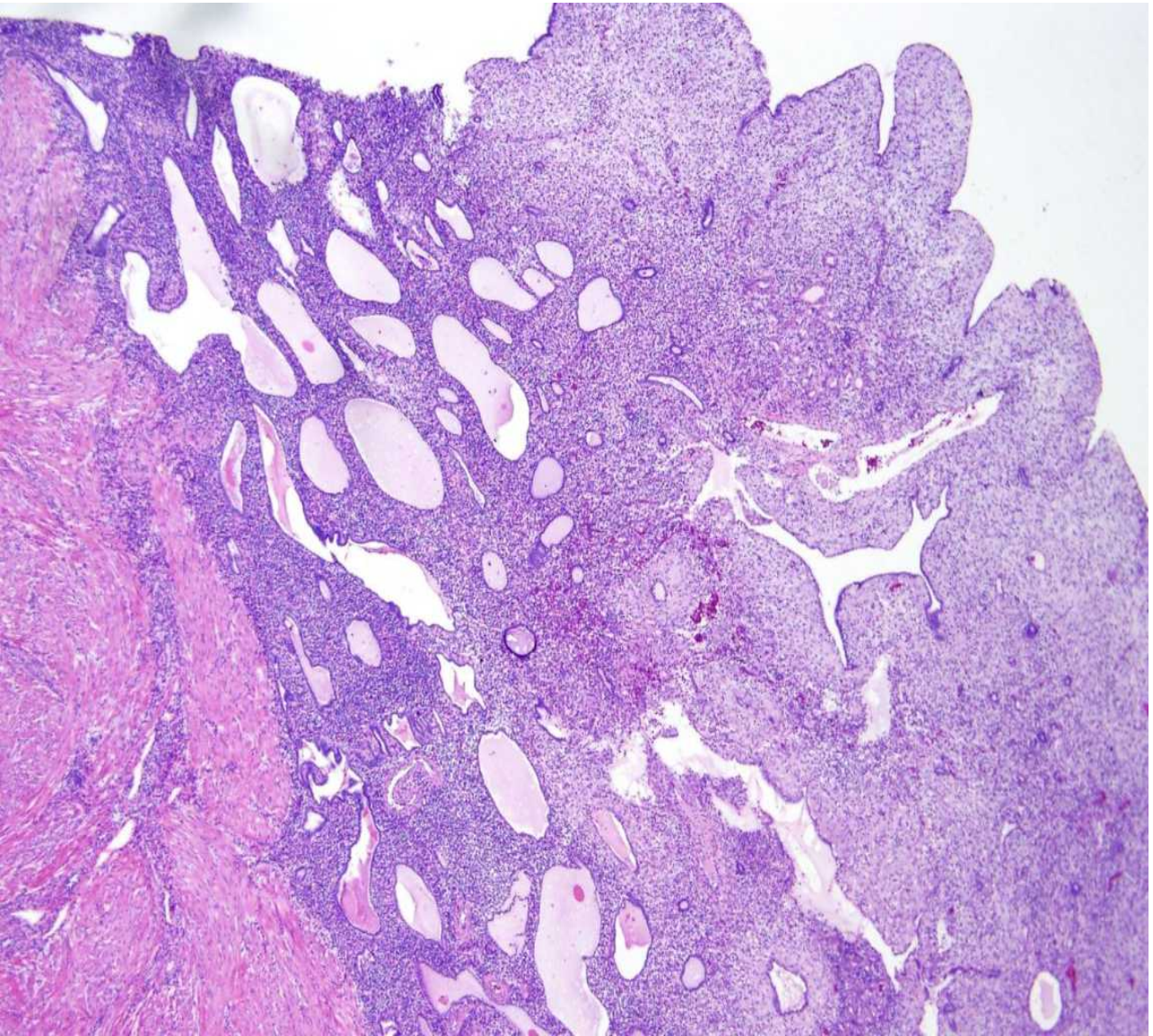

In this scenario, glands are inactive, and are surrounded by cellular basalis stroma, rather than decidualized stroma

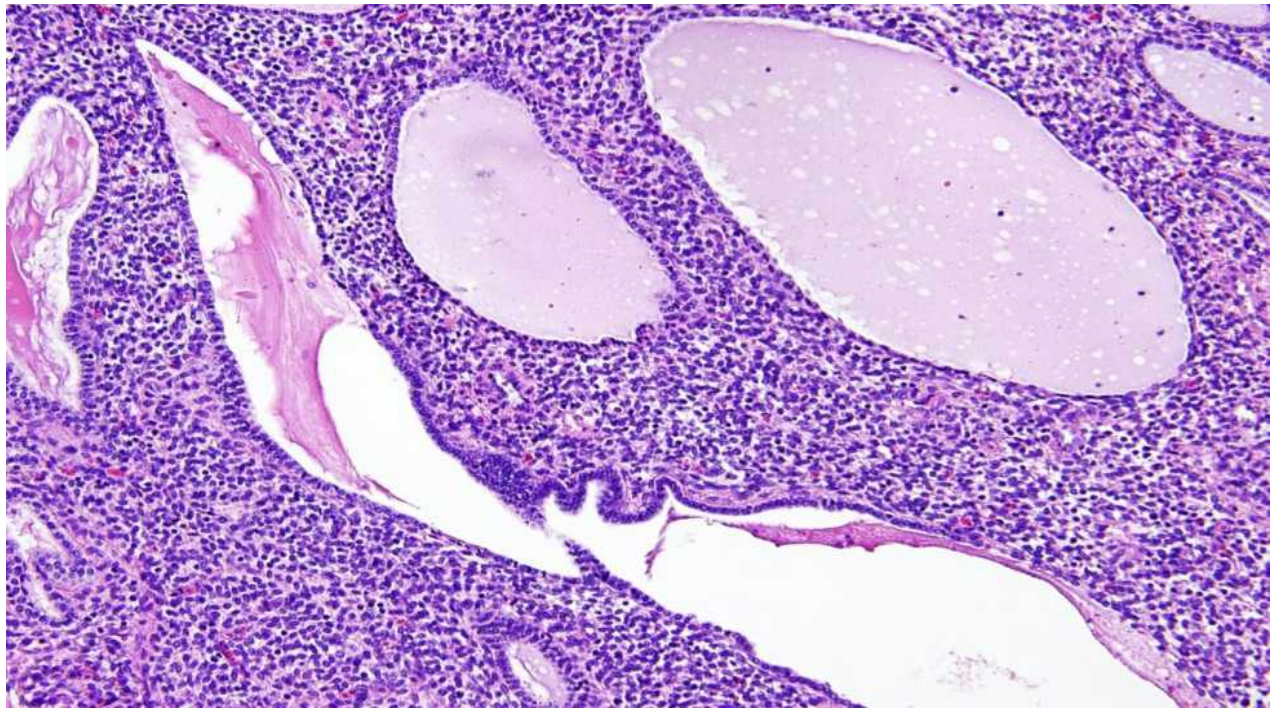

Reporting:

- When lined by non-atrophic-appearing epithelium, cysts are indicative of residual hyperplasia if crowded and/or extensive.
- When crowded glands are lined by atrophic epithelium, significance is not completely clear; perform IHC if feasible.

STROMA

Prospective phase II trial of levonorgestrel intrauterine device: nonsurgical approach for complex atypical hyperplasia and early-stage endometrial cancer

Check for updates

Shannon N. Westin, MD, MPH; Bryan Fellman, MS; Charlotte C. Sun, PhD; Russell R. Broaddus, MD, PhD; Misty L. Woodall, ADN; Navdeep Pal, MBBS, MPH; Diana L. Urbauer, MS; Lois M. Ramondetta, MD; Kathleen M. Schmeler, MD; Pamela T. Soliman, MD; Nicole D. Fleming, MD; Jennifer K. Burzawa, MD; Alpa M. Nick, MD; Andrea M. Milbourne, MD; Ying Yuan, PhD; Karen H. Lu, MD; Diane C. Bodurka, MD; Robert L. Coleman, MD; Melinda S. Yates, PhD

- Phase II trial, Cancer/AEH; End-point pathologic response at 12 months
- **96.9% of ultimate (i.e. at 12 mo) responders (31 of 32) had pathologic evidence of exogenous progesterone effect at 3 months compared with 25% of non-responders (2 of 8) (P=0.001).**

Am J Obstet Gynecol 2021;224:191.e1-15

Lack of stromal response in foci of residual hyperplasia

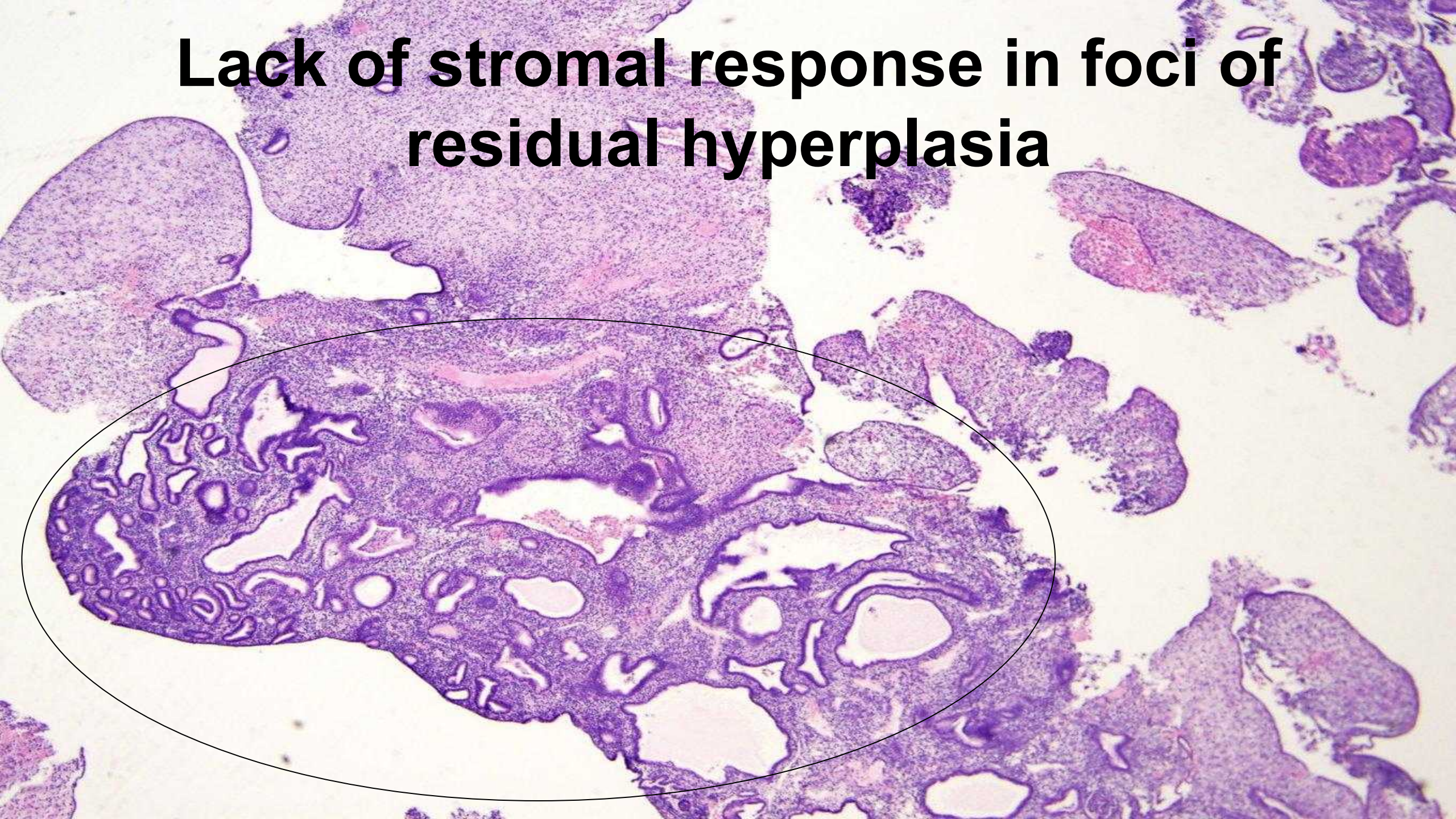

Lack of stromal response in foci of residual hyperplasia

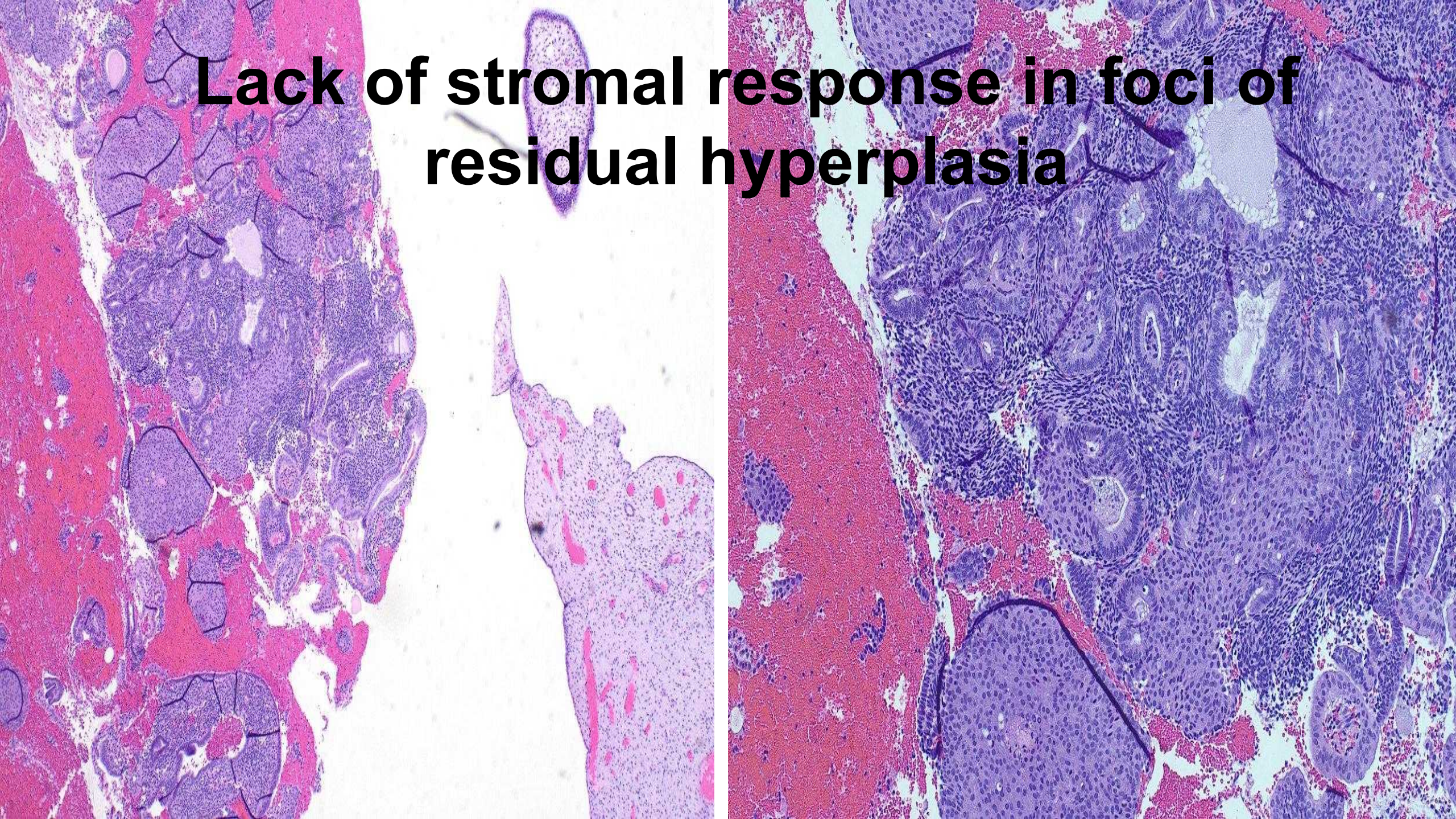

Reporting:

Lack of stromal decidual response in foci of glandular crowding is suggestive of at least partial progesterone resistance, and is accordingly worth mentioning, especially if the same phenomenon was seen in prior follow-up samples.

CYTOLOGIC ATYPIA

Assessing Endometrial Hyperplasia and Carcinoma Treated With Progestin Therapy

Am J Clin Pathol 2012;138:524-534
DOI: 10.1309/AJCPM2TSDDF1MHBZ

Mark J. Mentrikoski, MD,[1] Akeesha A. Shah, MD,[1] Krisztina Z. Hanley, MD,[2] and Kristen A. Atkins, MD[1]

Persistent cytologic atypia and/or architectural abnormalities after the first 6 months is the most significant predictor of treatment failure.

Histologic Alterations in Endometrial Hyperplasia and Well-differentiated Carcinoma Treated With Progestins

(*Am J Surg Pathol* 2007;31:988–998)

Darren T. Wheeler, MD, Robert E. Bristow, MD,† and Robert J. Kurman, MD‡*

The “cytologic atypia” problem

- Progestin may cause cytologic atypia to be decreased or inapparent, however,
  - –Cytologic atypia may be difficult to assess in this setting, and there are a lot of equivocal cases
  - –Metaplasias are common in this setting and may further complicate the determination of atypia.

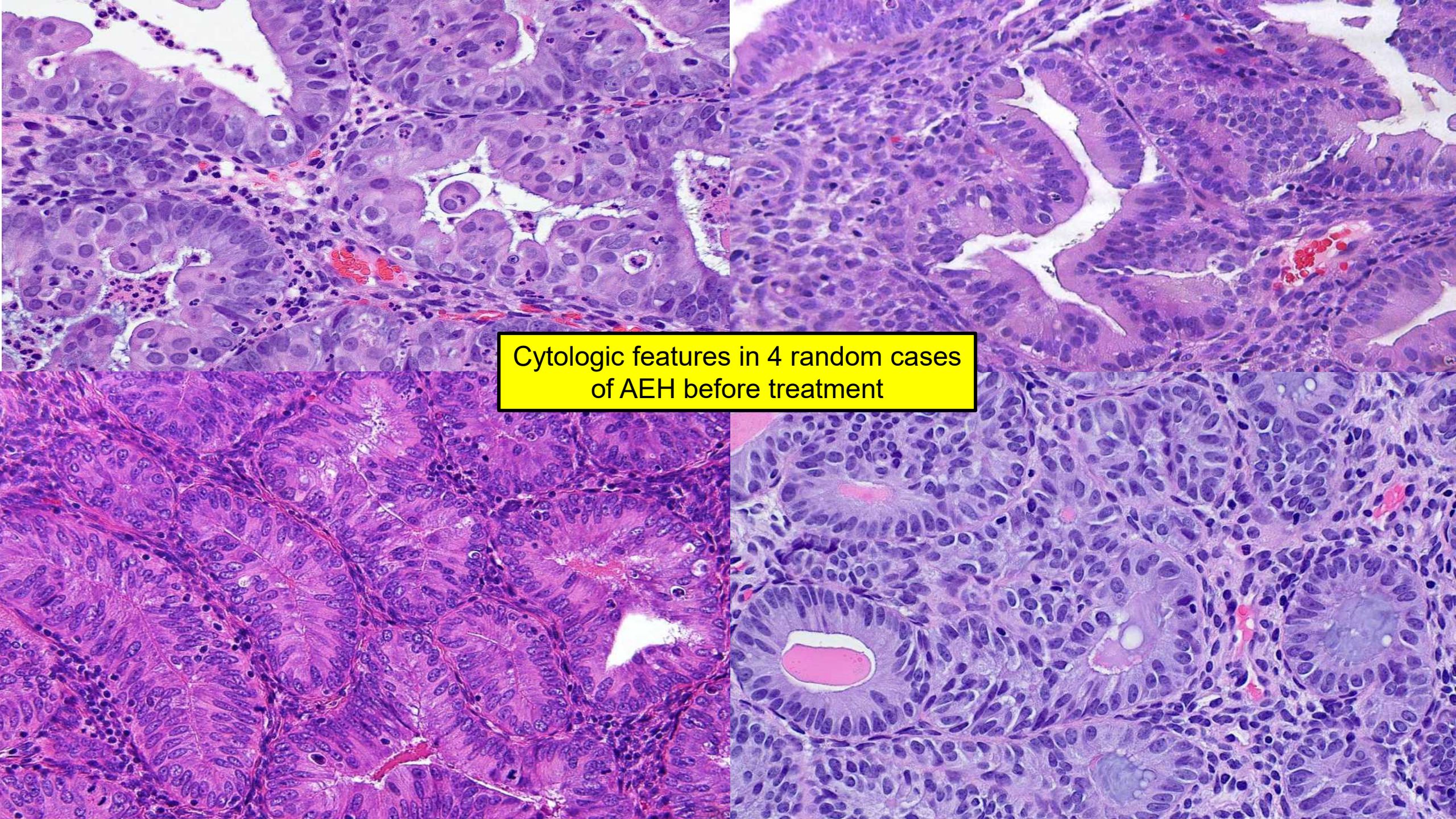
Cytologic features in 4 random cases
of AEH before treatment

Post-treatment samples with unequivocal atypia almost invariably have concurrent architectural complexity

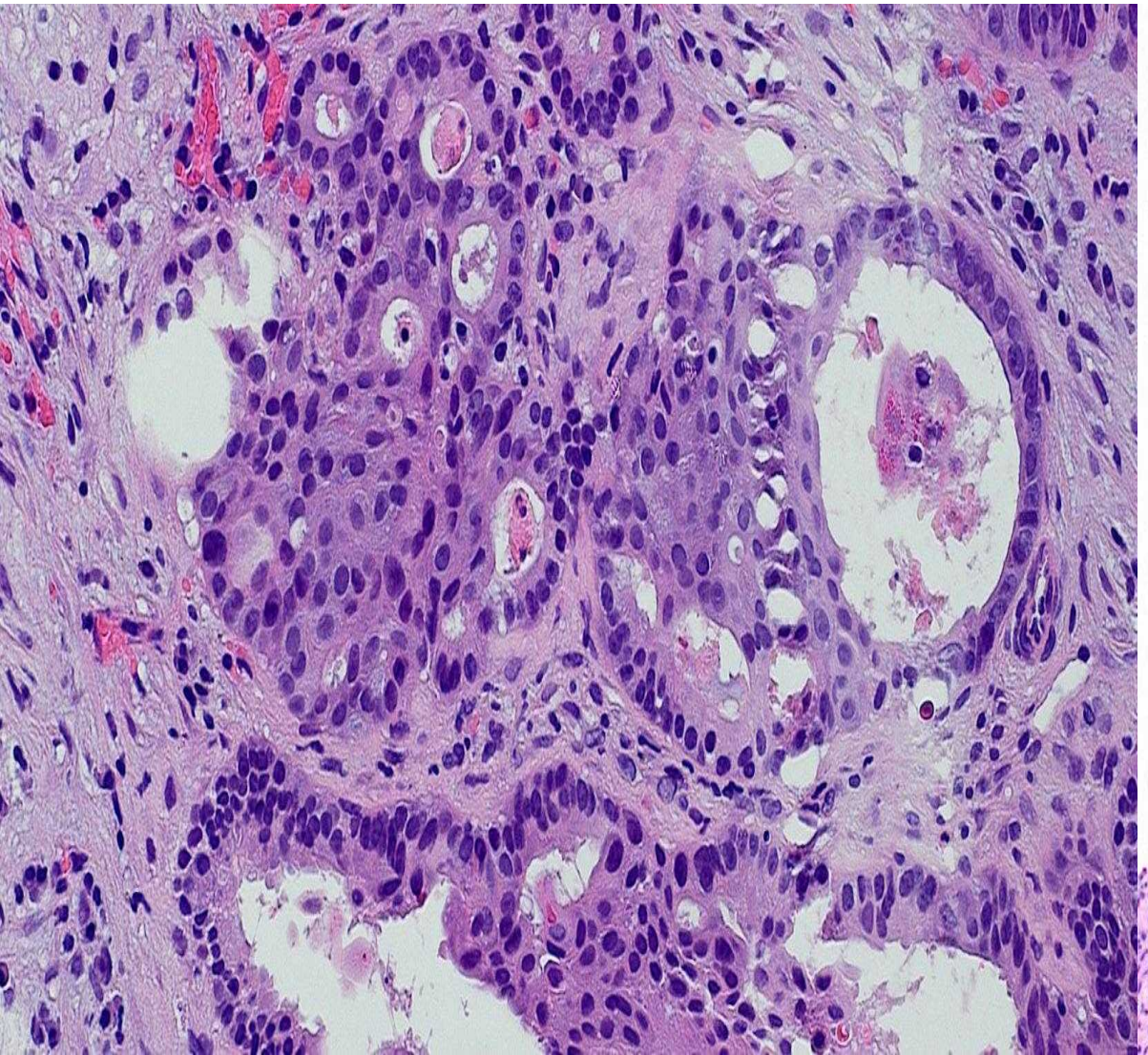

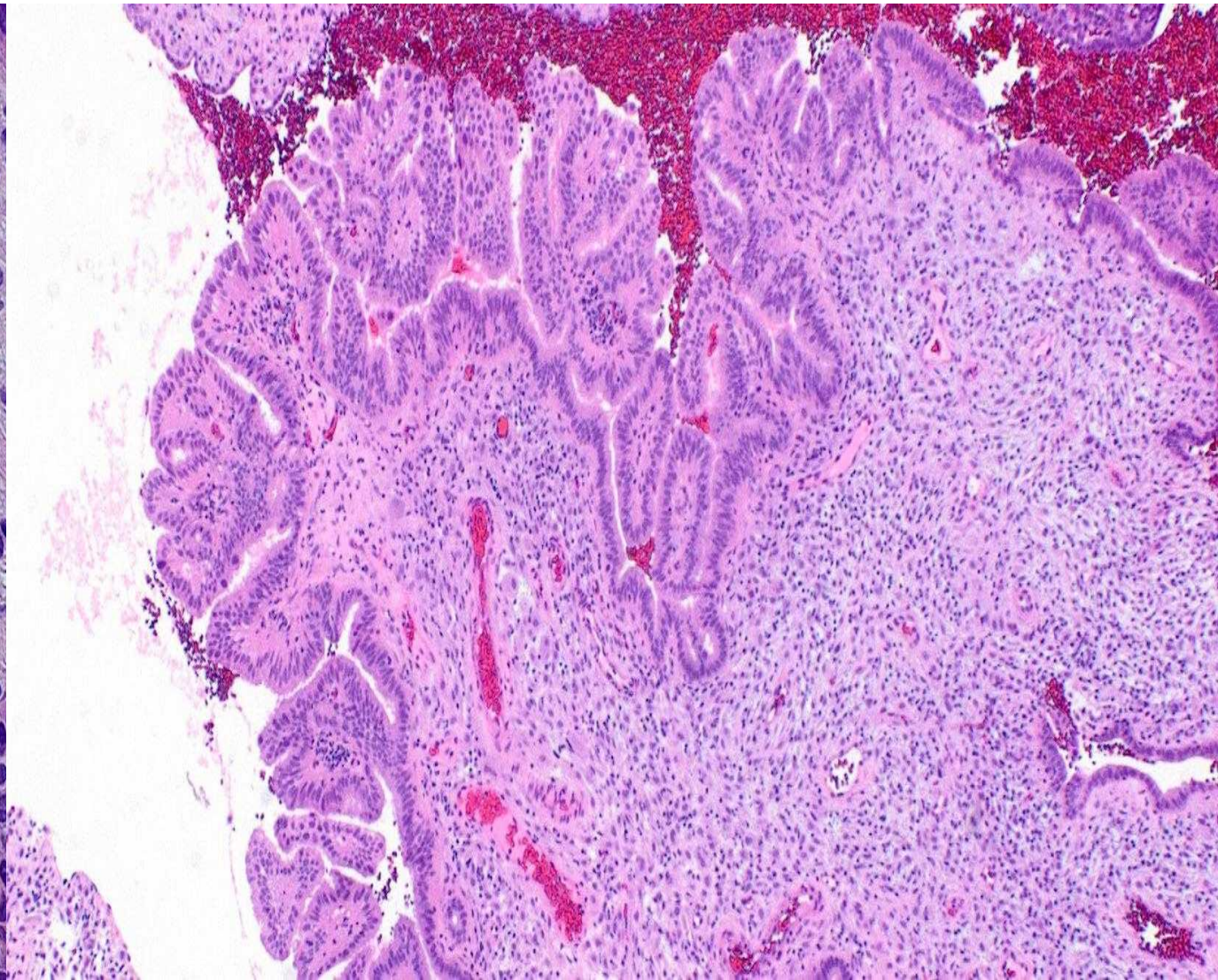

Architecture is ultimately more important….



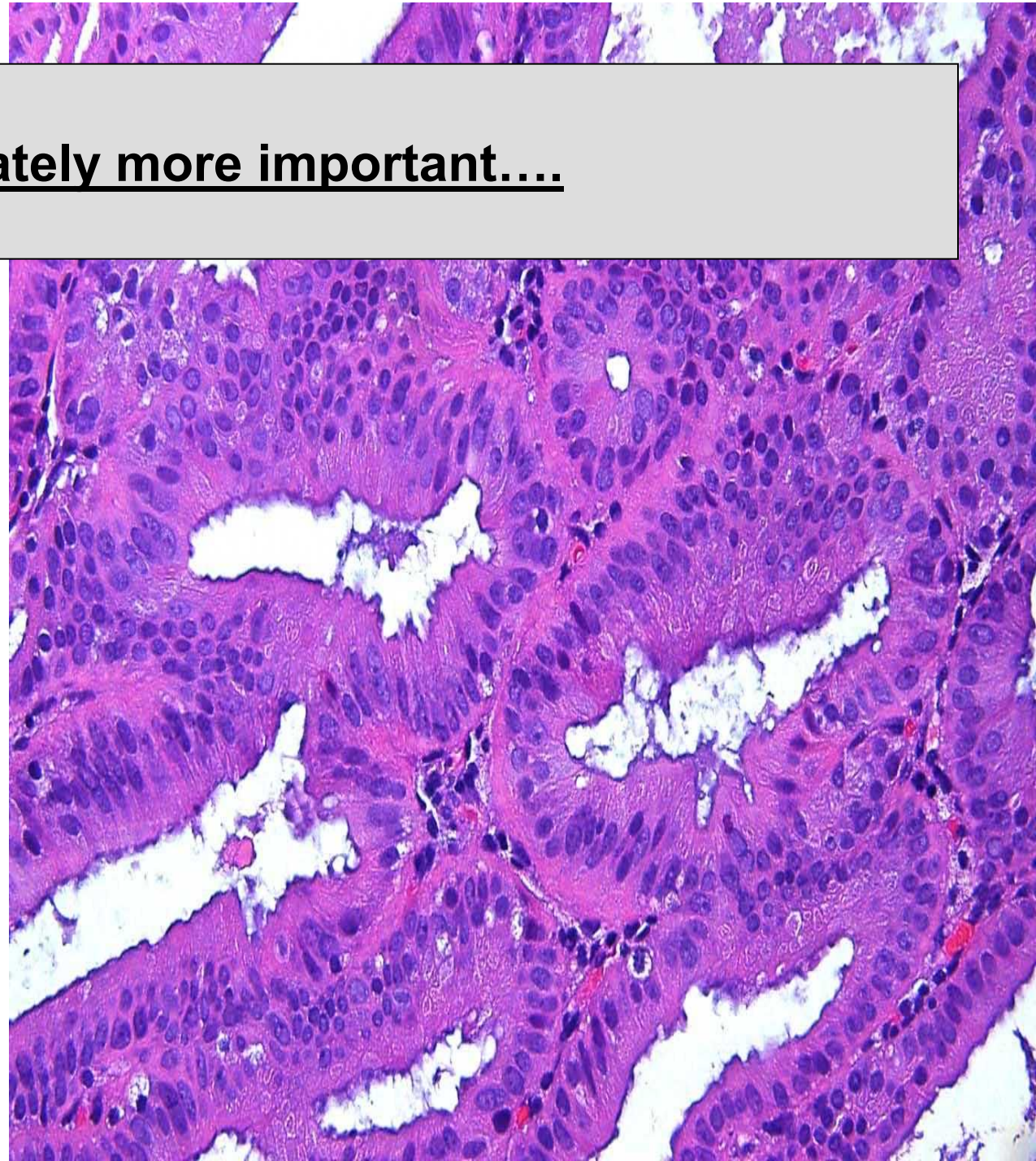

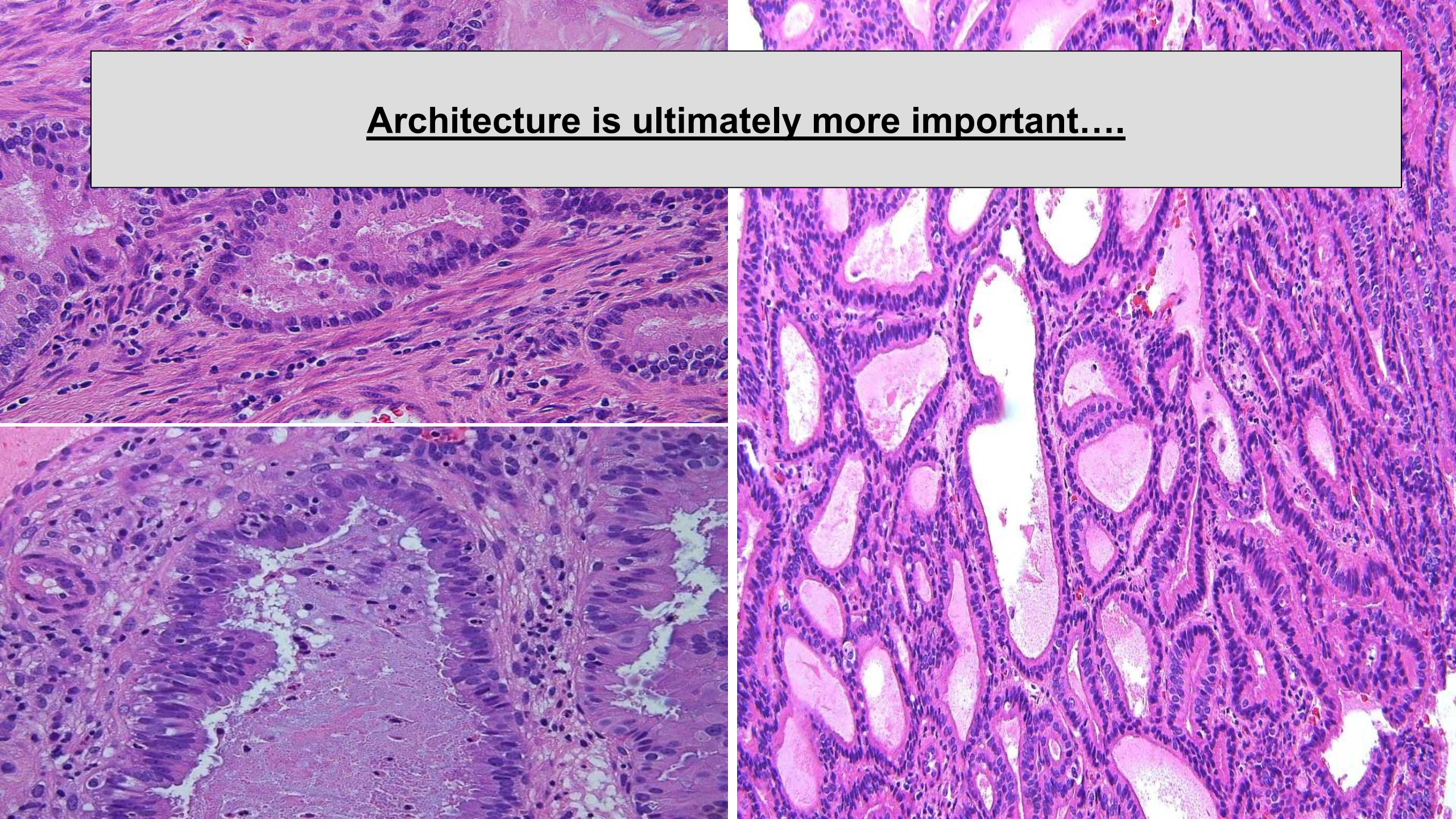

Architecture is ultimately more important….

The “cytologic atypia” problem

- Progestin may cause cytologic atypia to be decreased or inapparent, however,
  - Cytologic atypia may be difficult to assess in this setting, and there are a lot of equivocal cases
  - Specifically reporting on the “**absence**” of atypia subsequent to an AEH biopsy may create a false narrative over time, i.e. that there is progressive improvement even when florid architectural derangements may be present.

Reporting:

Recommendation on reporting follow-up samples for AEH: residual hyperplasia present or absent, based on architecture [i.e. “residual hyperplasia” is equivalent to “residual atypical hyperplasia” in this context].

When unequivocal atypia/cytologic demarcation is present, mention this in commentary.

MICROGLANDULAR PROLIFERATIONS

A Mirena IUD [for non-hyperplastic indications] is associated with microglandular hyperplasia of the cervix in 13.2% of cases, and endocervical pseudodecidualization in 2.8% of cases
-Hejmadi et al. Int J Surg Pathol 148-154

Microglandular Hyperplasia of the Cervix

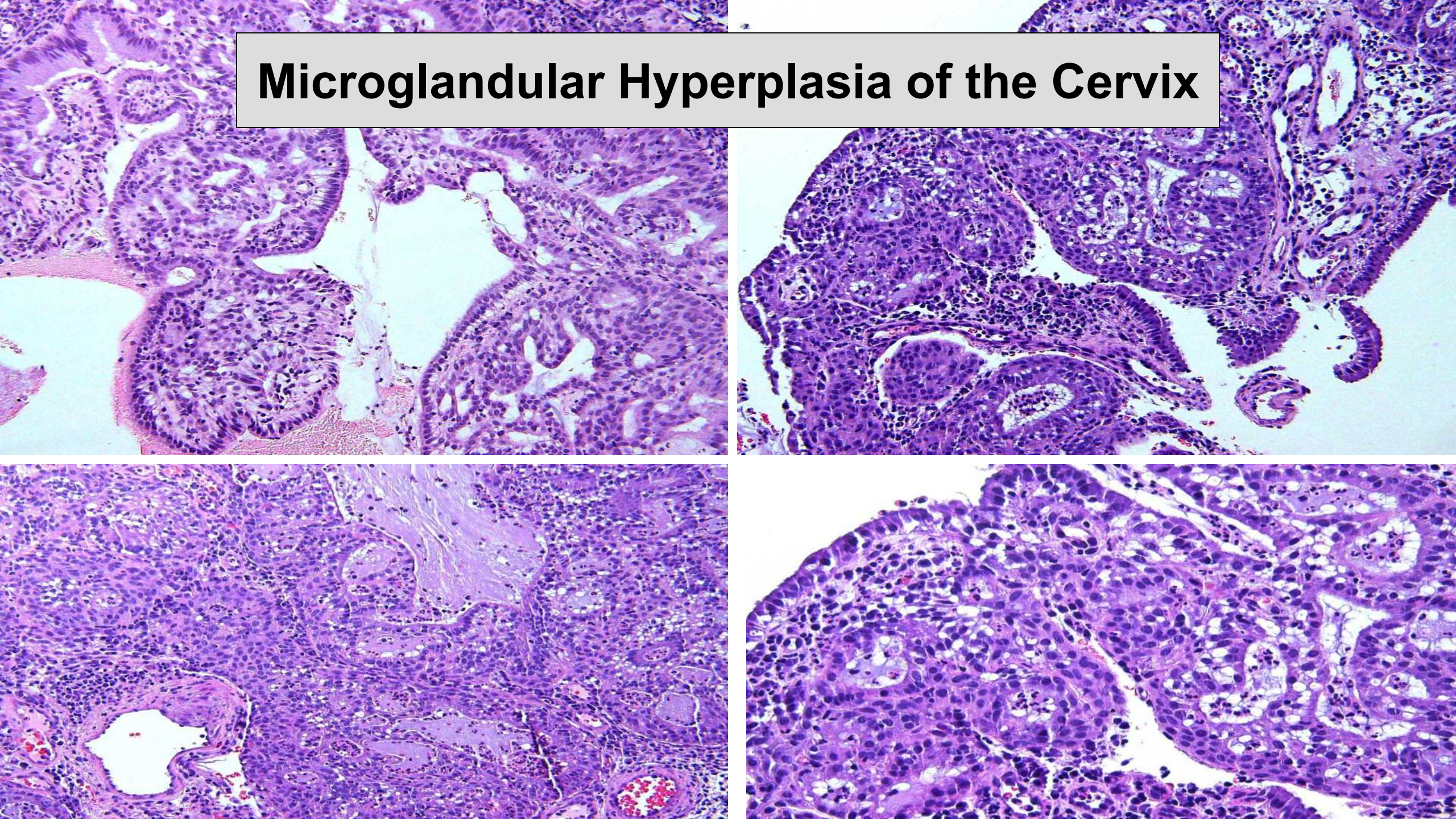

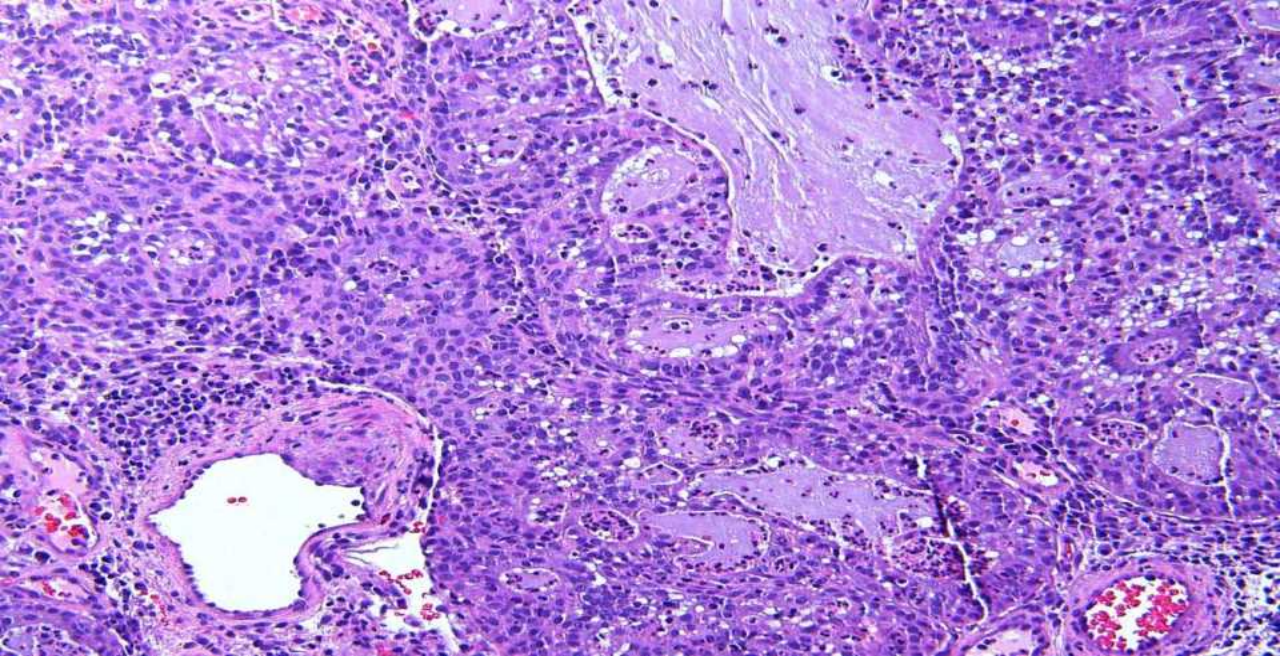

Microglandular Hyperplasia

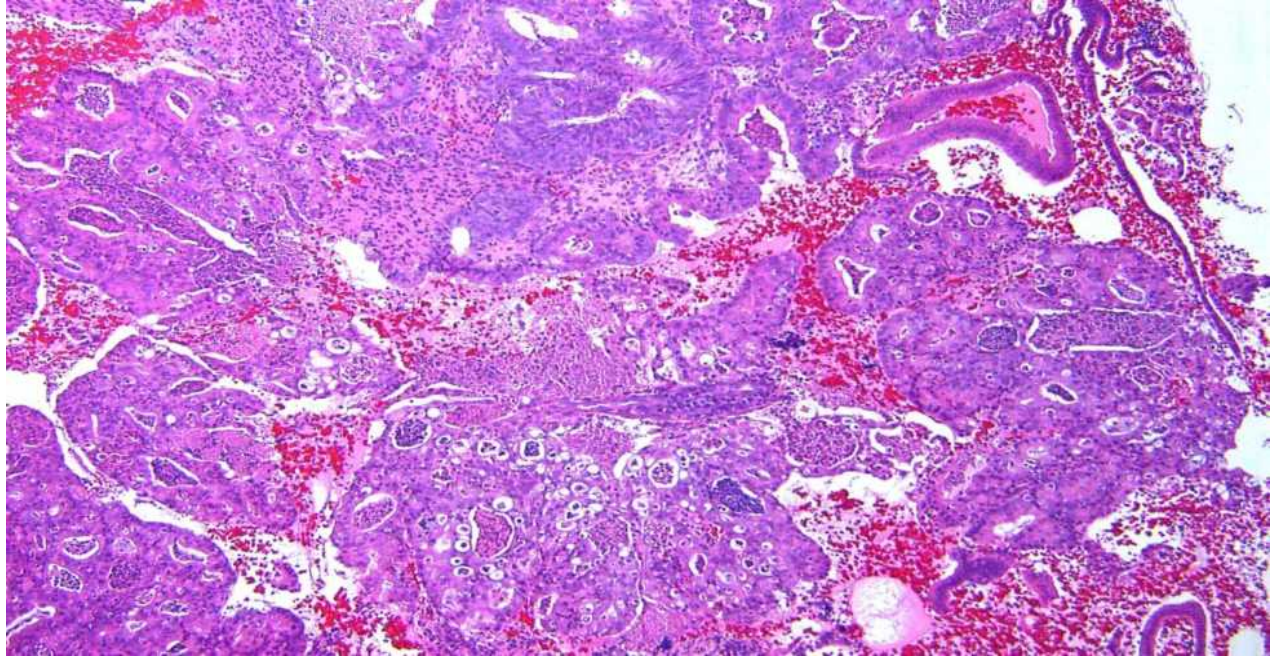

Endometrial Adenocarcinoma with Microglandular Hyperplasia-like Patterns

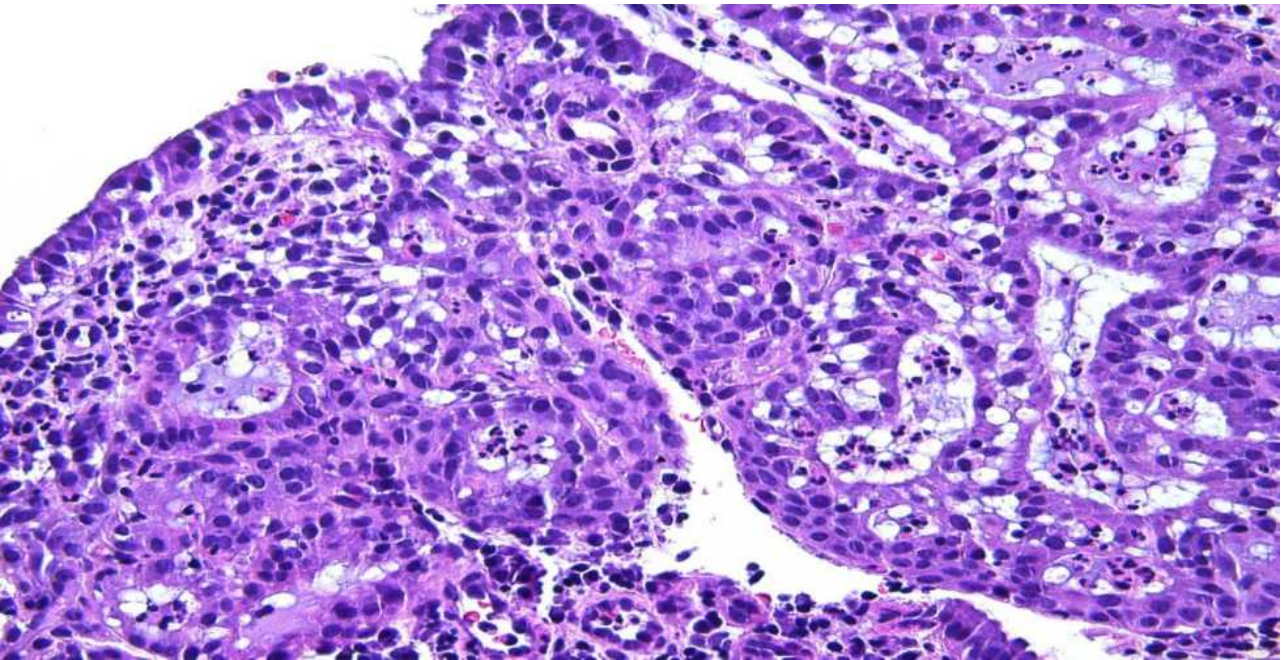

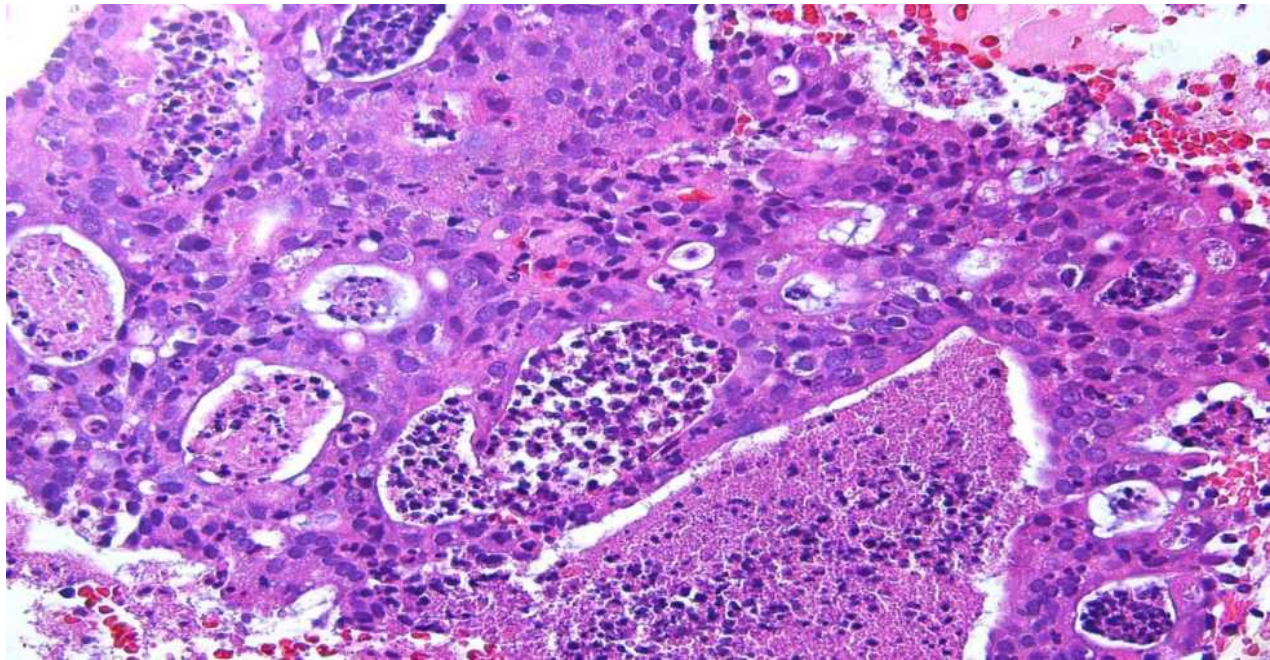


Architectural complexity associated with microglandular change: diagnostic of residual hyperplasia.

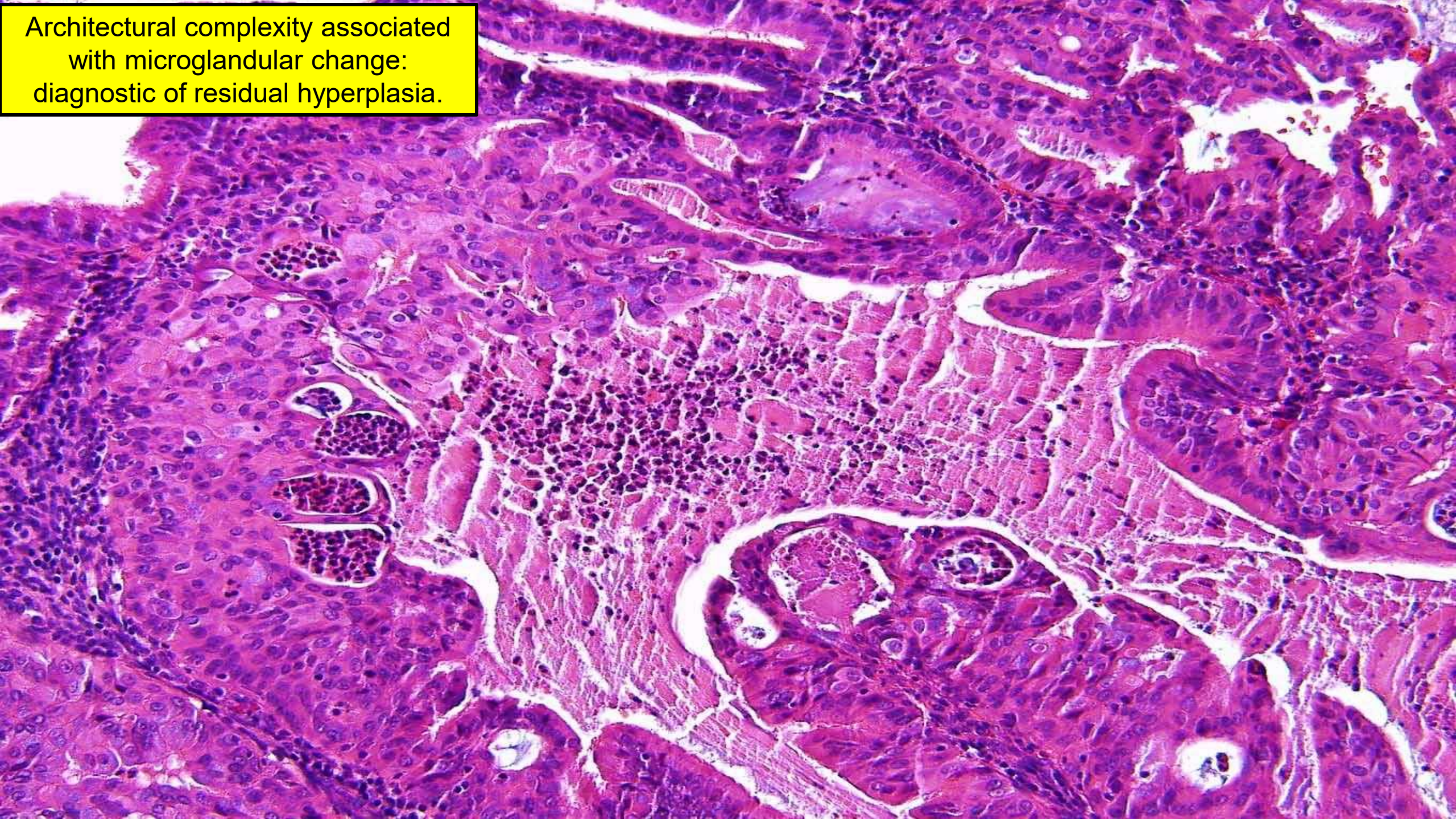
Architectural complexity associated with microglandular change: diagnostic of residual hyperplasia.


Architectural complexity associated with microglandular change: diagnostic of residual hyperplasia.

Architectural complexity associated with microglandular change: diagnostic of residual hyperplasia.

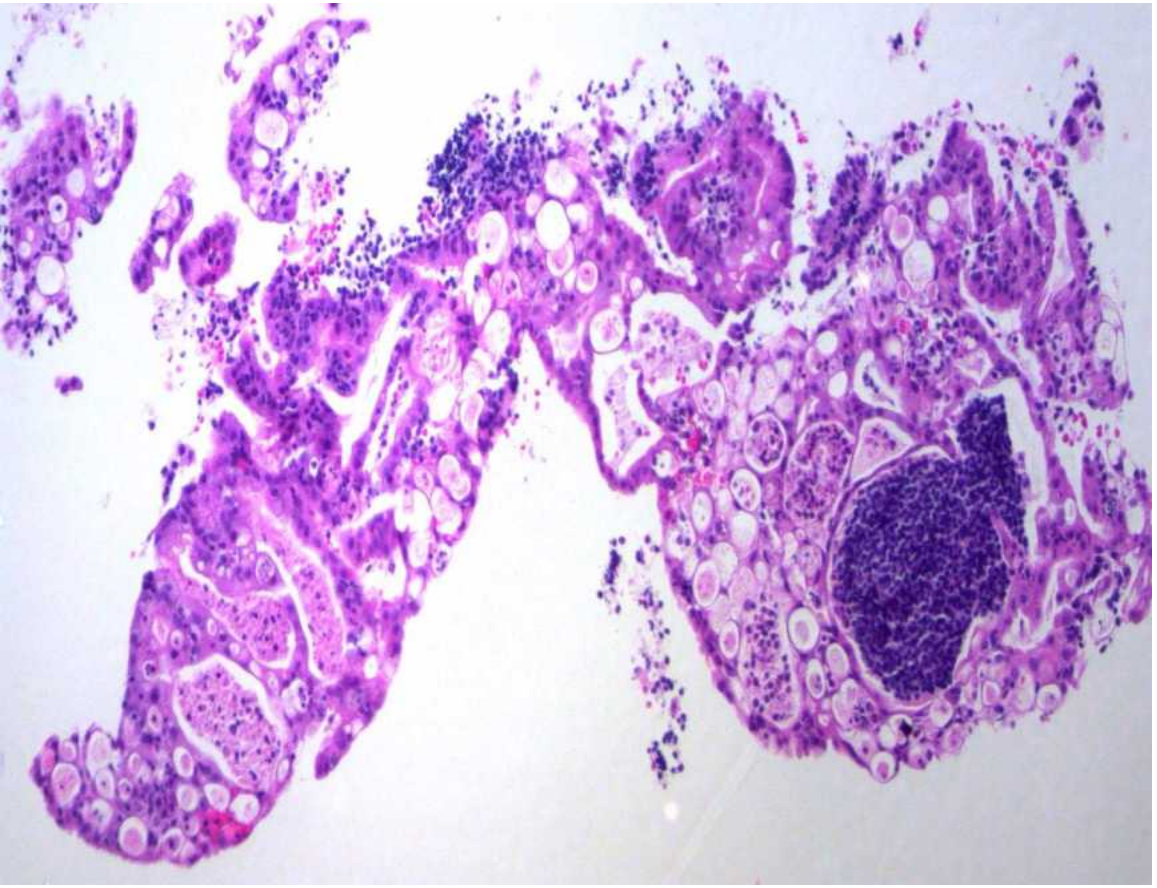

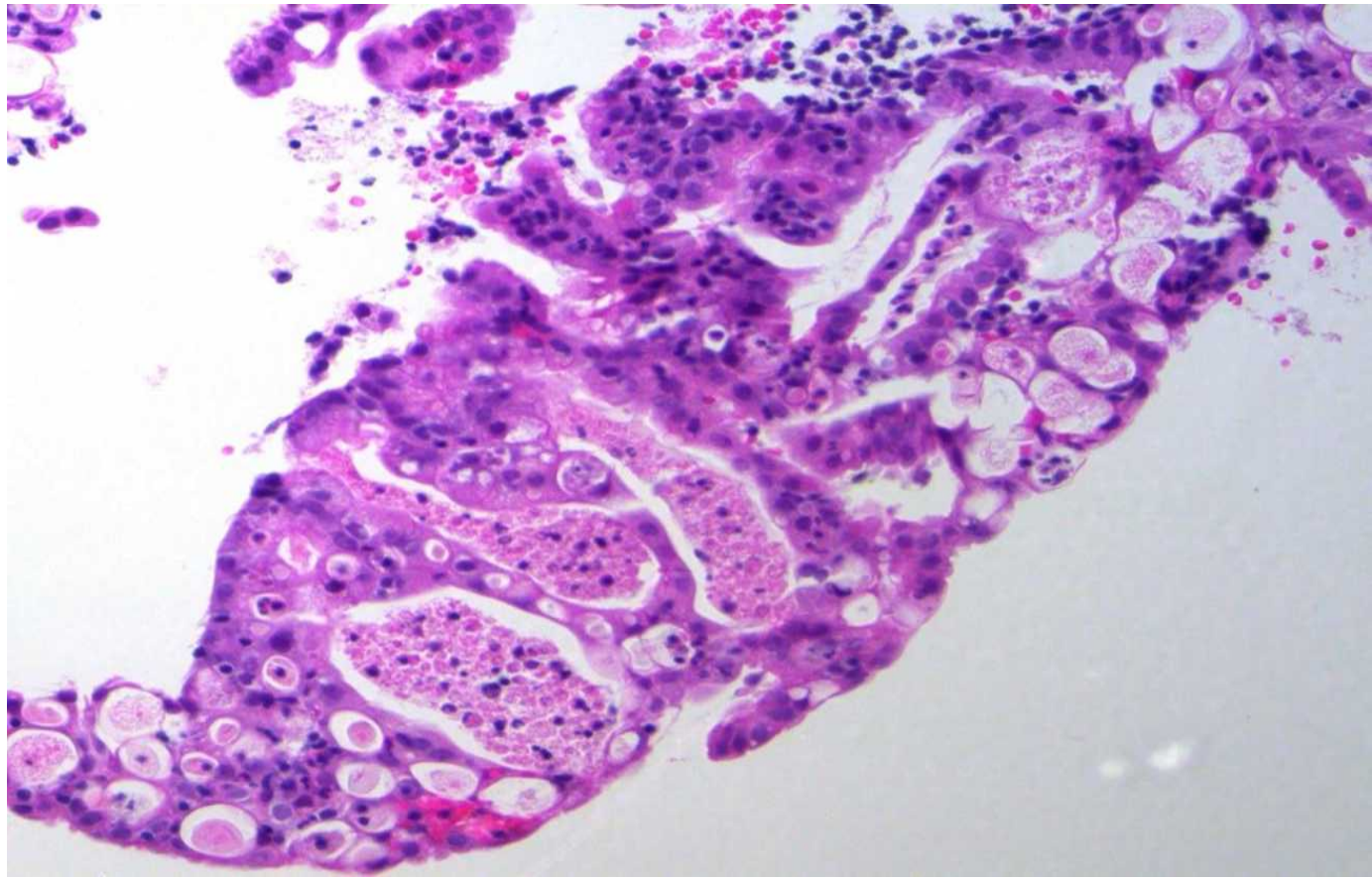

Some microglandular proliferations are mostly surface processes, and it is unclear whether they represent residual hyperplasia if concurrent architectural abnormality is absent

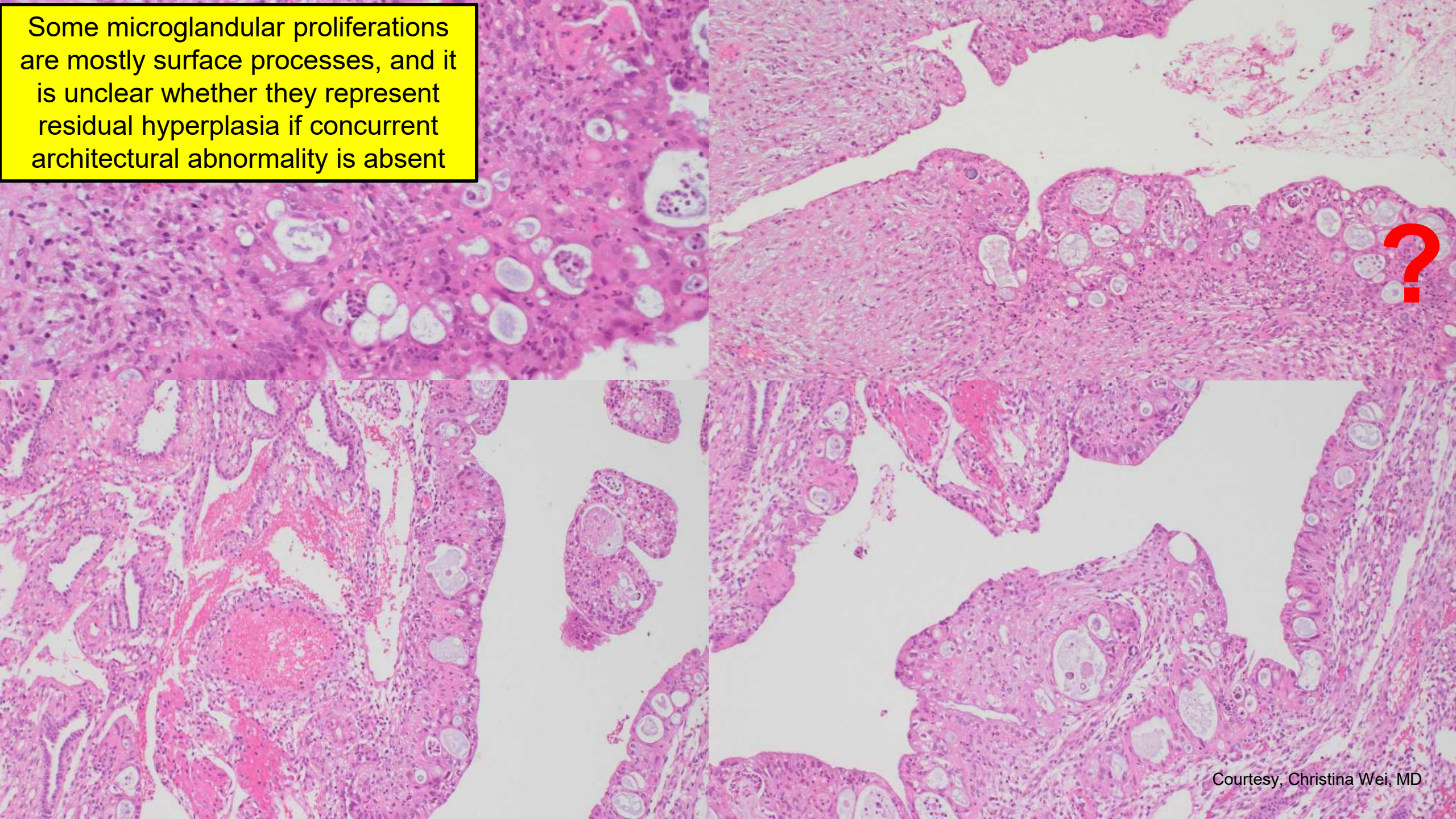

Courtesy, Christina Wei, MD

When extensive and more than a surface process, I classify as residual hyperplasia.



Courtesy, Christina Wei, MD

When extensive and more than a surface process, I classify as residual hyperplasia.

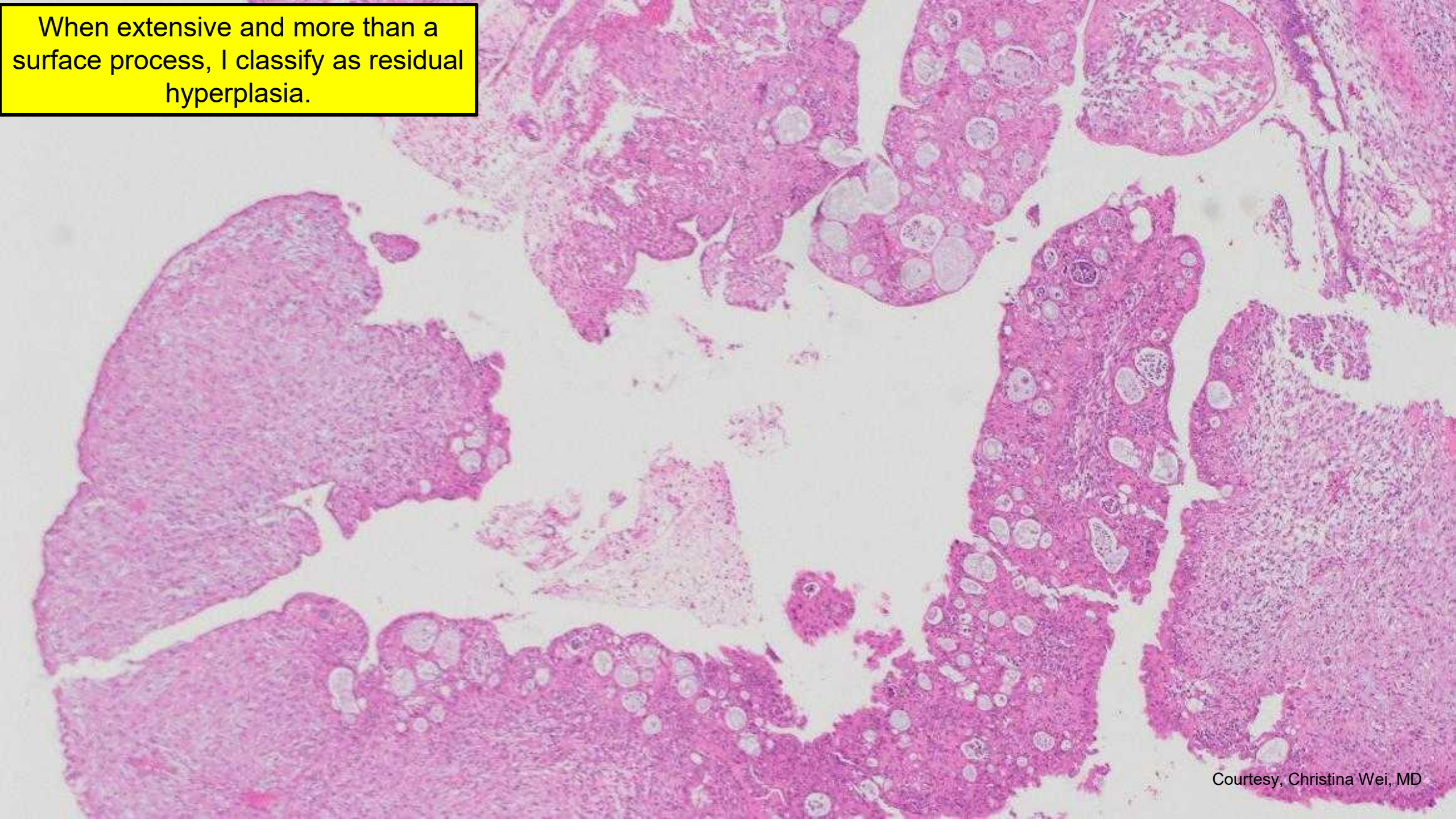

Courtesy, Christina Wei, MD

When extensive and more than a surface process, I classify as residual hyperplasia.

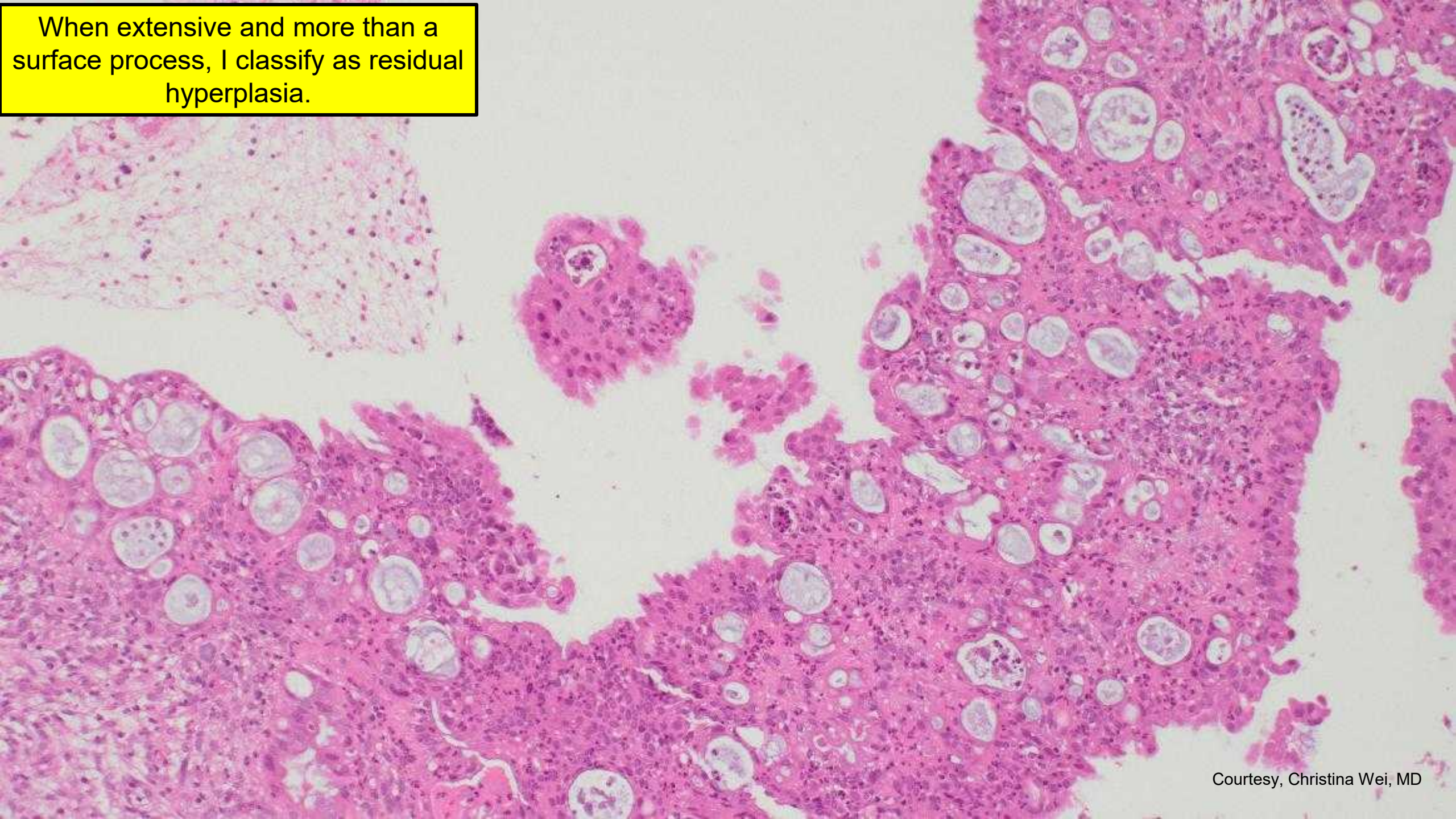

Courtesy, Christina Wei, MD

BIOMARKER ABERRANCY AS A DETERMINANT OF RESIDUAL HYPERPLASIA.

The AEH Triad: β-Catenin, PTEN and PAX2

Marker	NORMAL	ABERRANT	POTENTIAL PITFALLS THAT SHOULD NOT BE INTERPRETED AS ABERRANT
β-Catenin	Membranous, cytoplasmic staining in columnar cells	Strong, unequivocal nuclear expression in any proportion of columnar cells in focus of interest	Nuclear staining in squamous morules.
PTEN	Cytoplasmic expression	Complete absence of staining in glands of interest; compare with internal controls	-Diminished staining -Isolated glandular loss of staining (require loss in at least 5% of glands of interest). -Loss of staining in normal glands
PAX2	Nuclear expression	Complete absence of staining in glands of interest; compare with internal controls	-Isolated glandular loss of staining (require loss in at least 5% of glands of interest). -Loss of staining in normal glands

β-Catenin

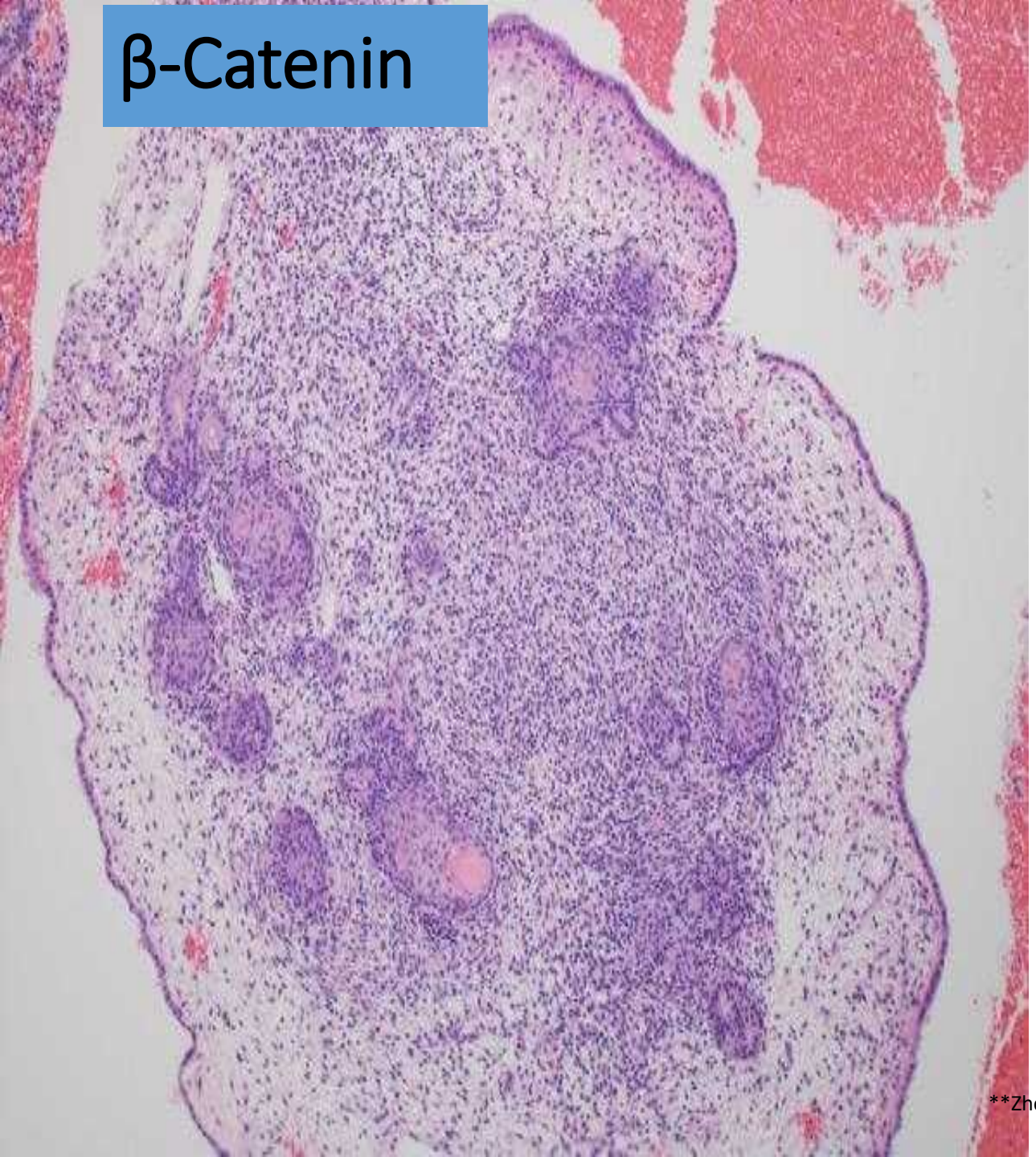

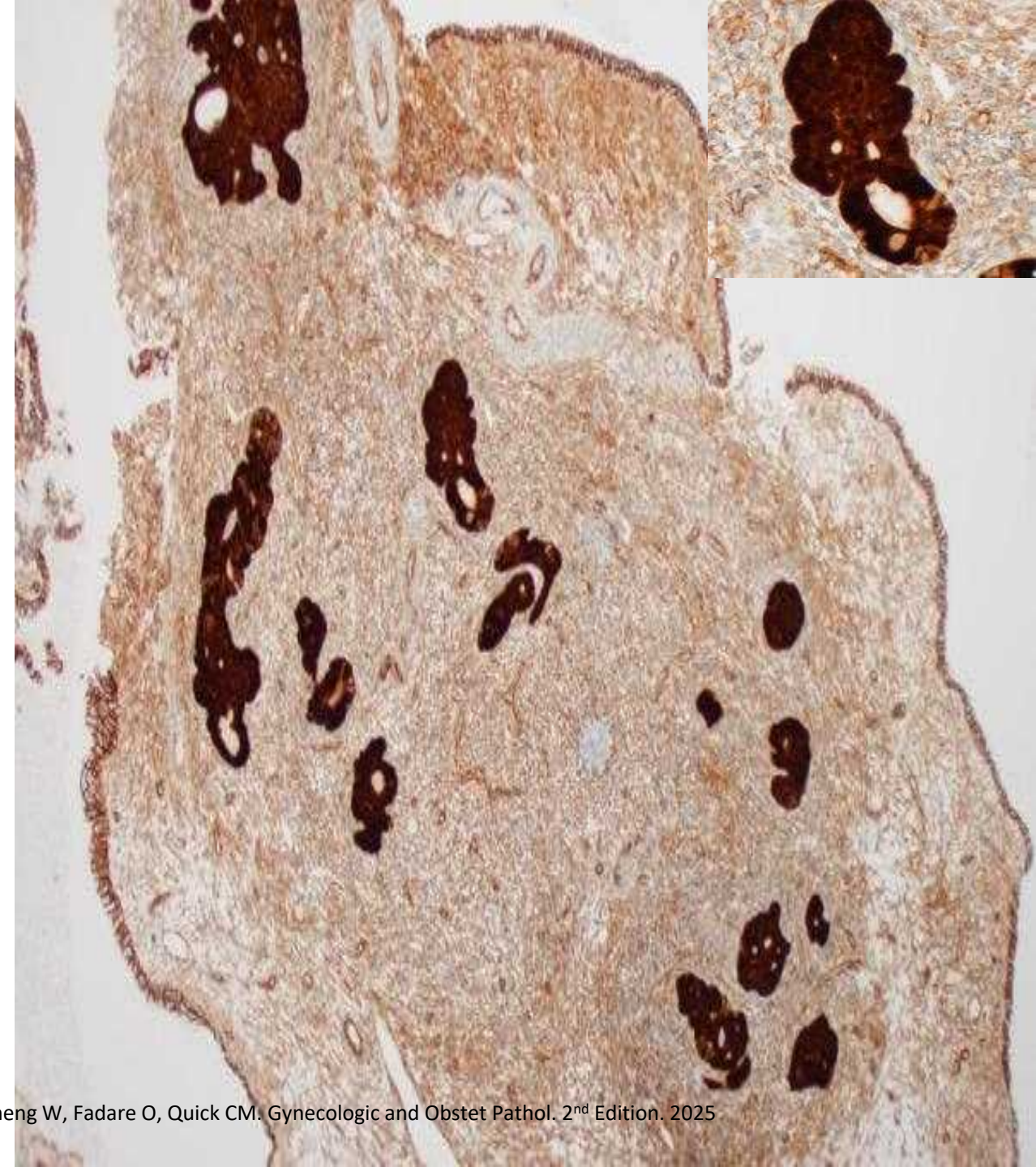

**Zheng W, Fadare O, Quick CM. Gynecologic and Obstet Pathol. 2nd Edition. 2025

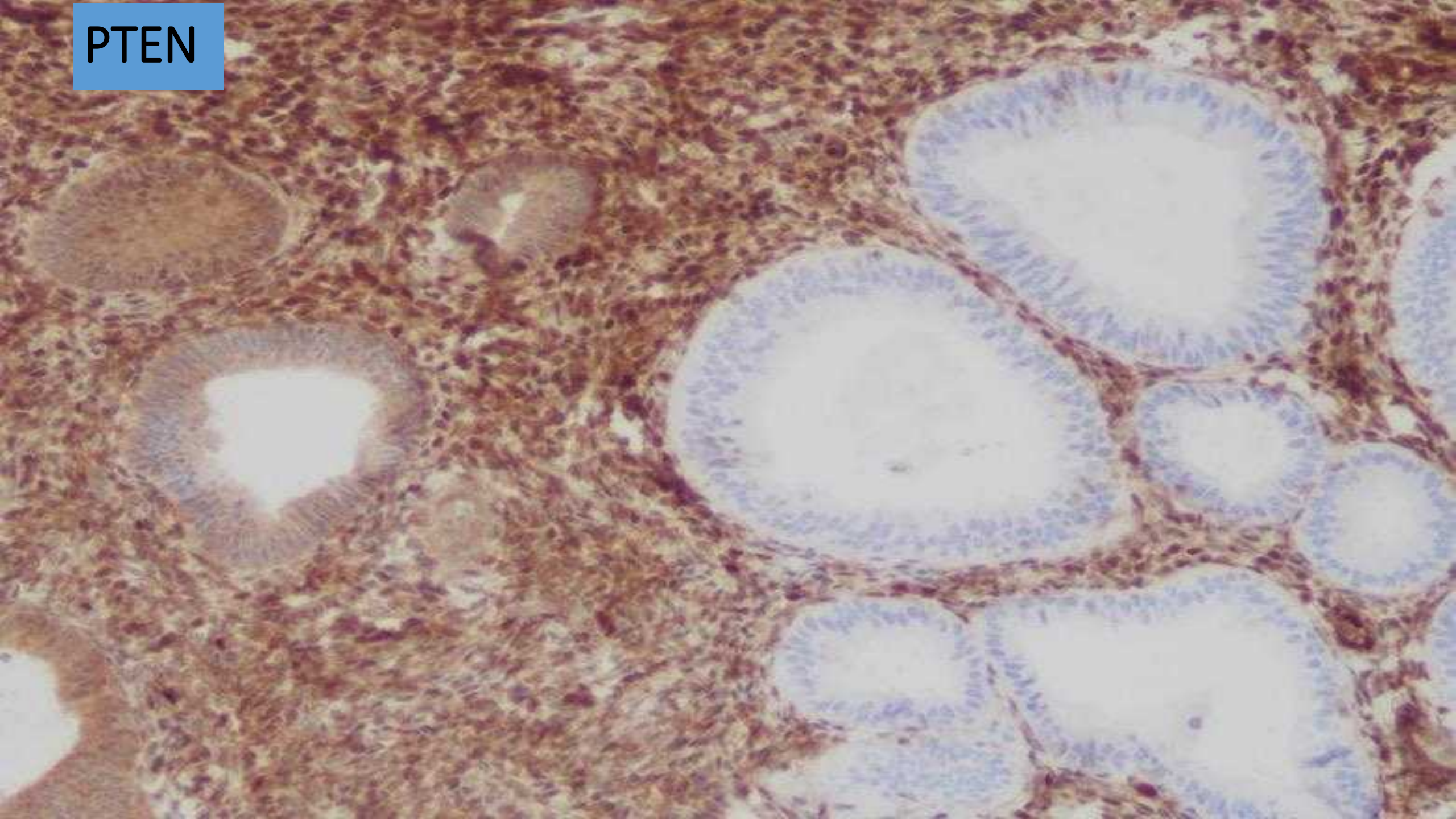
PTEN

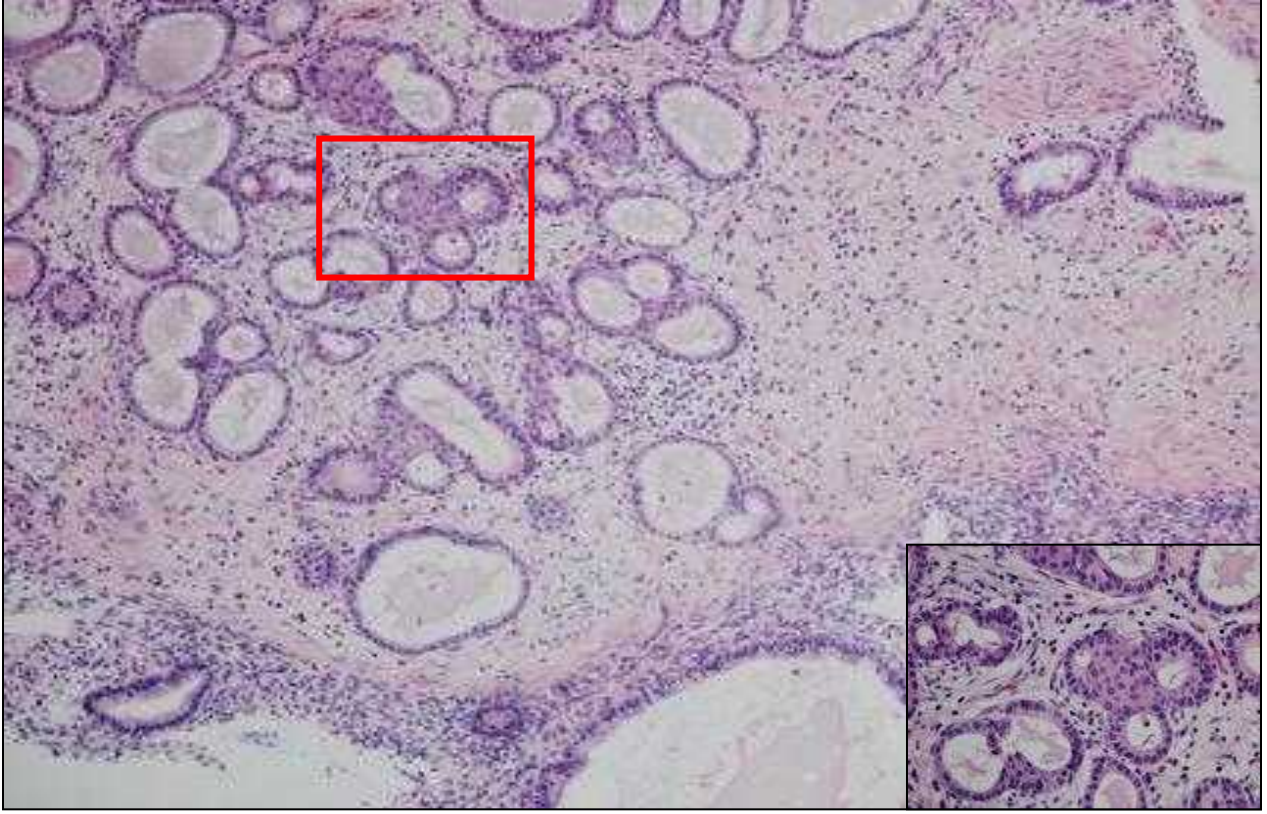

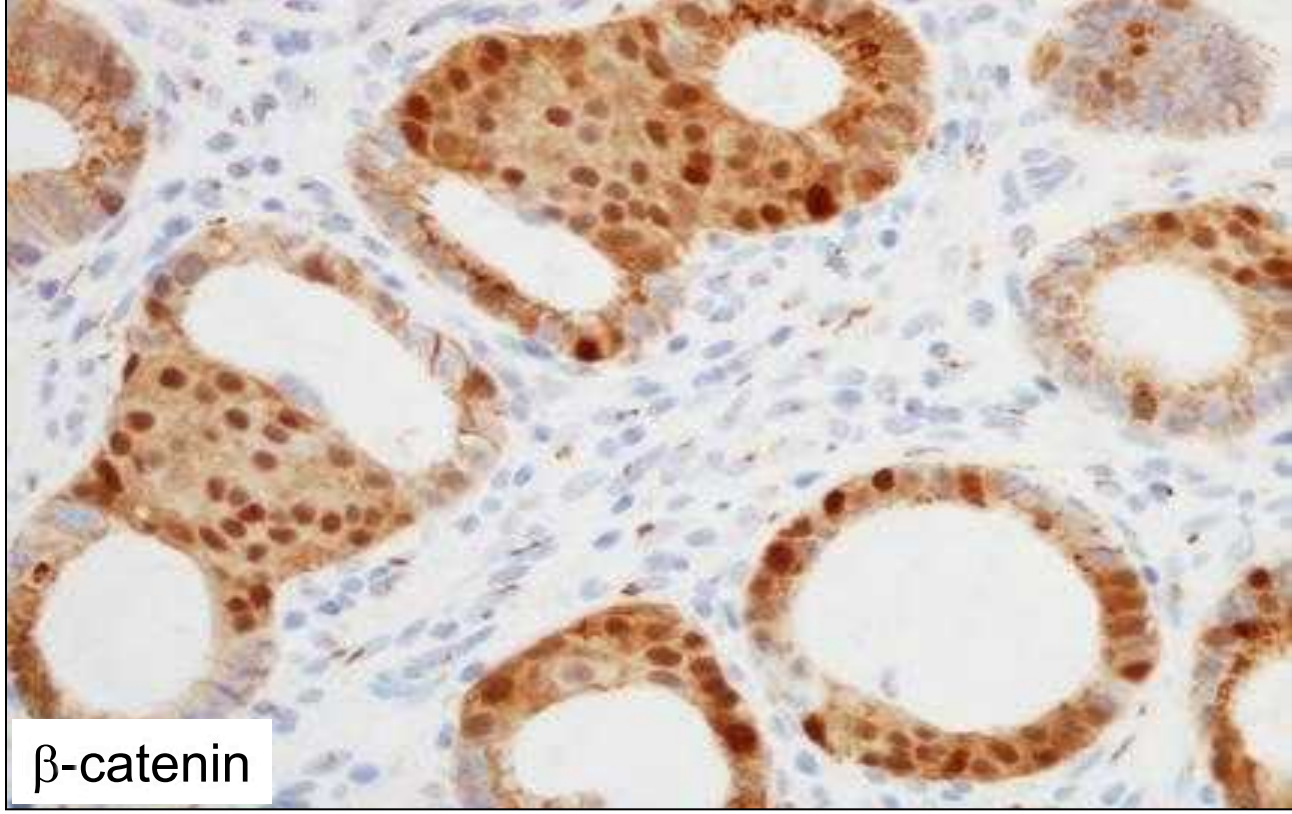

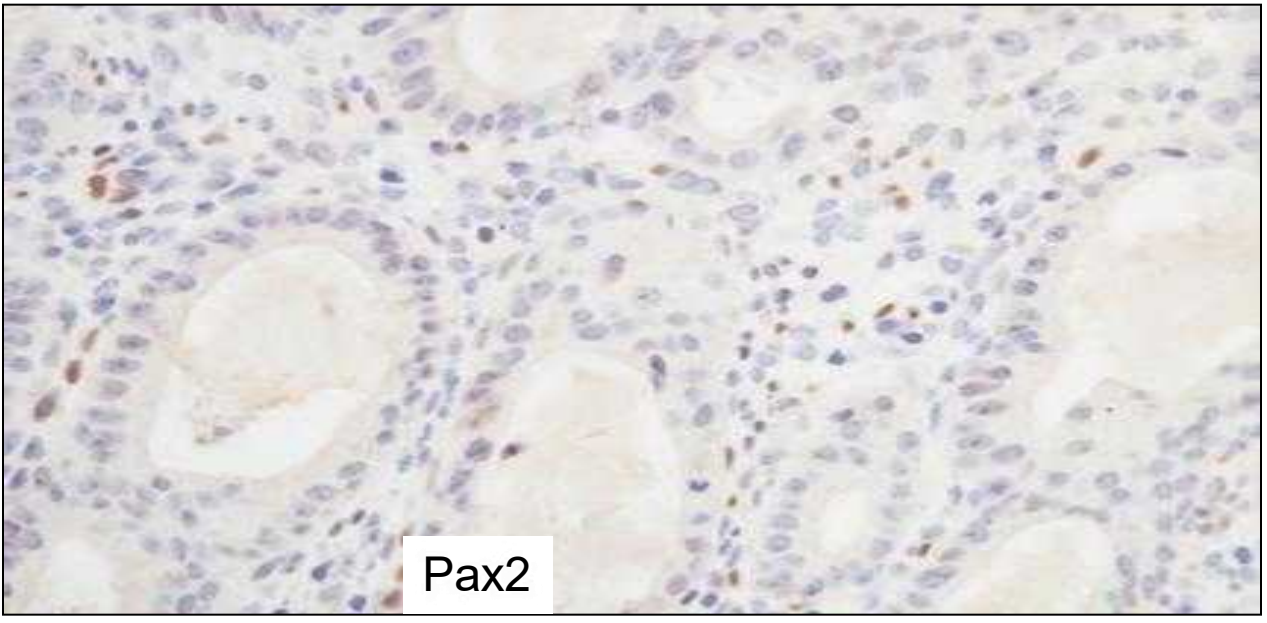

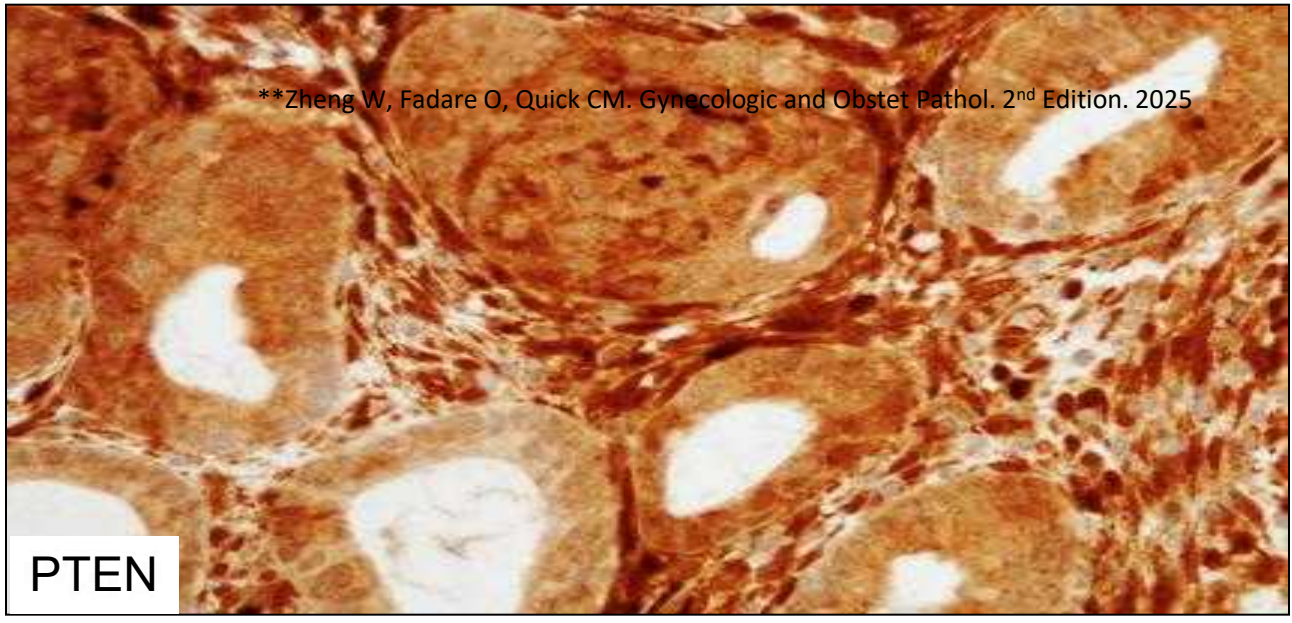

**Zheng W, Fadare O, Quick CM. Gynecologic and Obstet Pathol. 2nd Edition. 2025

Reliable Identification of Endometrial Precancers Through Combined Pax2, β-Catenin, and Pten Immunohistochemistry

Mitzi Aguilar, BS, Hao Chen, MD, PhD,* Glorimar Rivera-Colon, MD,* Shuang Niu, MD,* Kelley Carrick, MD,* Katja Gwin, MD,* Ileana C. Cuevas, PhD,* Subhransu S. Sahoo, PhD,* Hao-Dong Li, PhD,* Song Zhang, PhD,†‡ Wenxin Zheng, MD,*‡ Elena Lucas, MD,*‡ and Diego H. Castrillon, MD, PhD*‡*

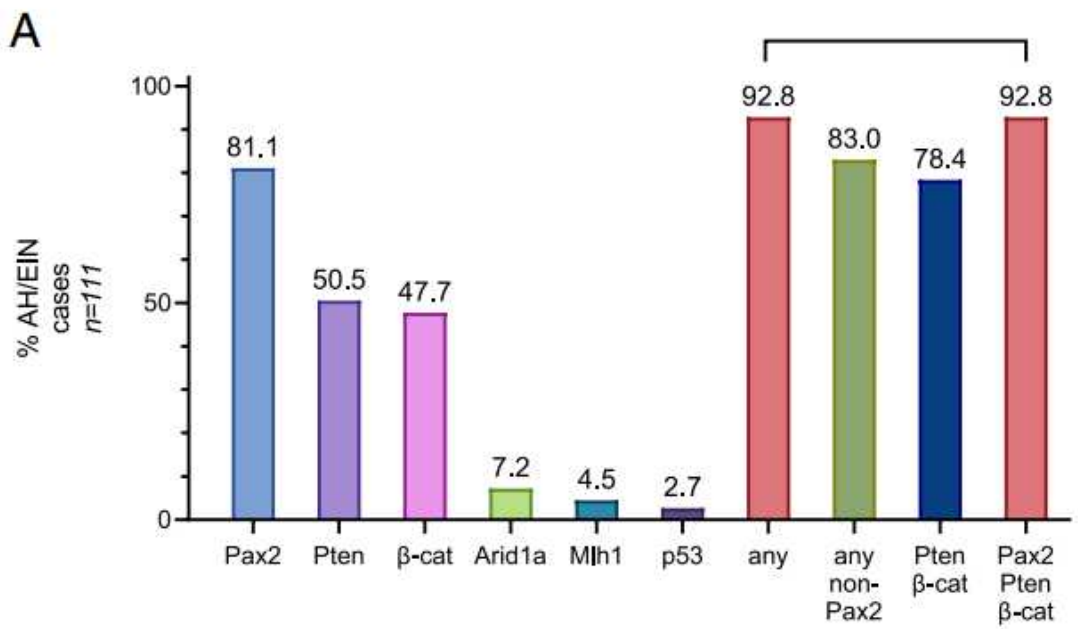

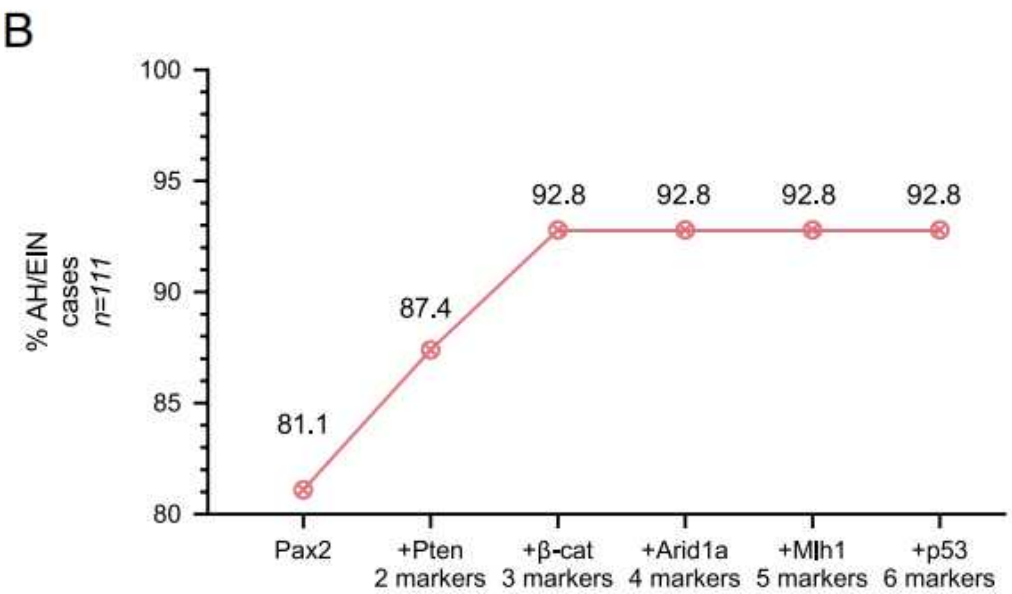

β-catenin, Pax2, and Pten Panel Identifies Precancers Among Histologically Subdiagnostic Endometrial Lesions

Mitzi Aguilar, BS, Hao Chen, MD, PhD,* Subhransu S. Sahoo, PhD,* Wenxin Zheng, MD,*†‡ Jessica Grubman, MD, MAS,† Jeffrey A. SoRelle, MD,*§ Elena Lucas, MD,*‡ and Diego H. Castrillon, MD, PhD*†‡*

"Marker-aberrant cases were more likely to progress to endometrioid precancer or cancer (P=0.0002)"

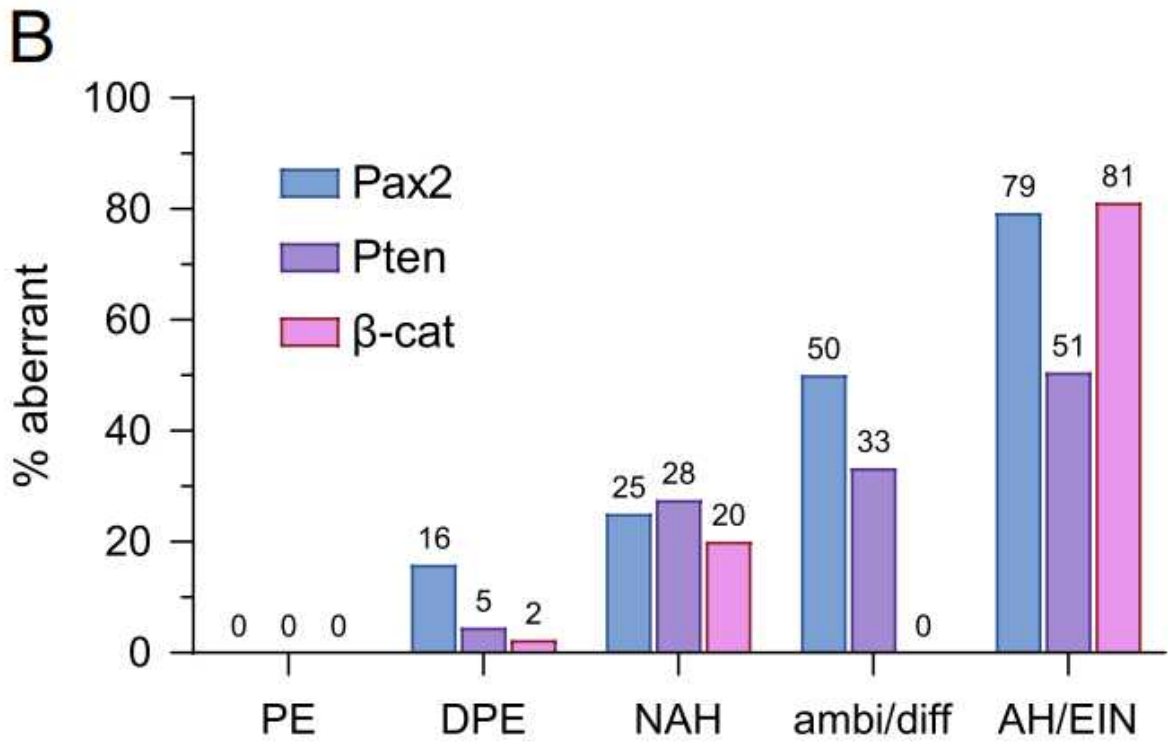

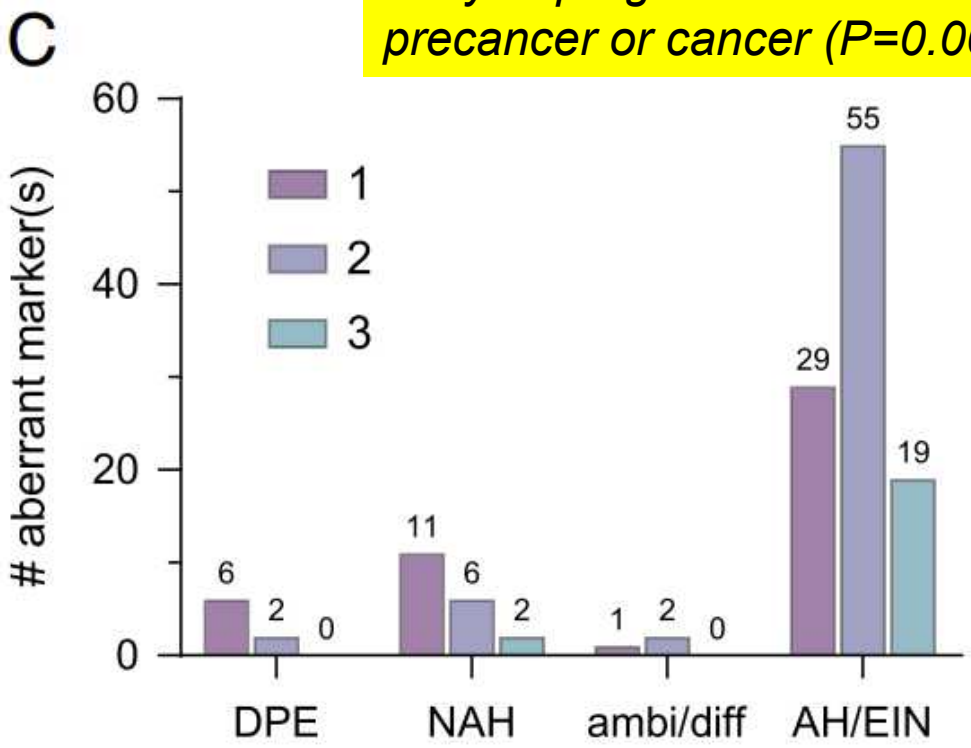

(*Am J Surg Pathol* 2023;47:618–629)

Histopathology

Histopathology 2024, **85**, 579–589. DOI: 10.1111/his.15215

Lesions sub-diagnostic of endometrioid intra-epithelial neoplasia/atypical hyperplasia: value of morphology and immunohistochemistry in predicting neoplastic outcome

Nicolas Wyvekens, George L Mutter, Marisa R Nucci, David L Kolin & Carlos Parra-Herran

Division of Women's and Perinatal Pathology, Department of Pathology, Brigham and Women's Hospital, Harvard Medical School, Boston, MA, USA

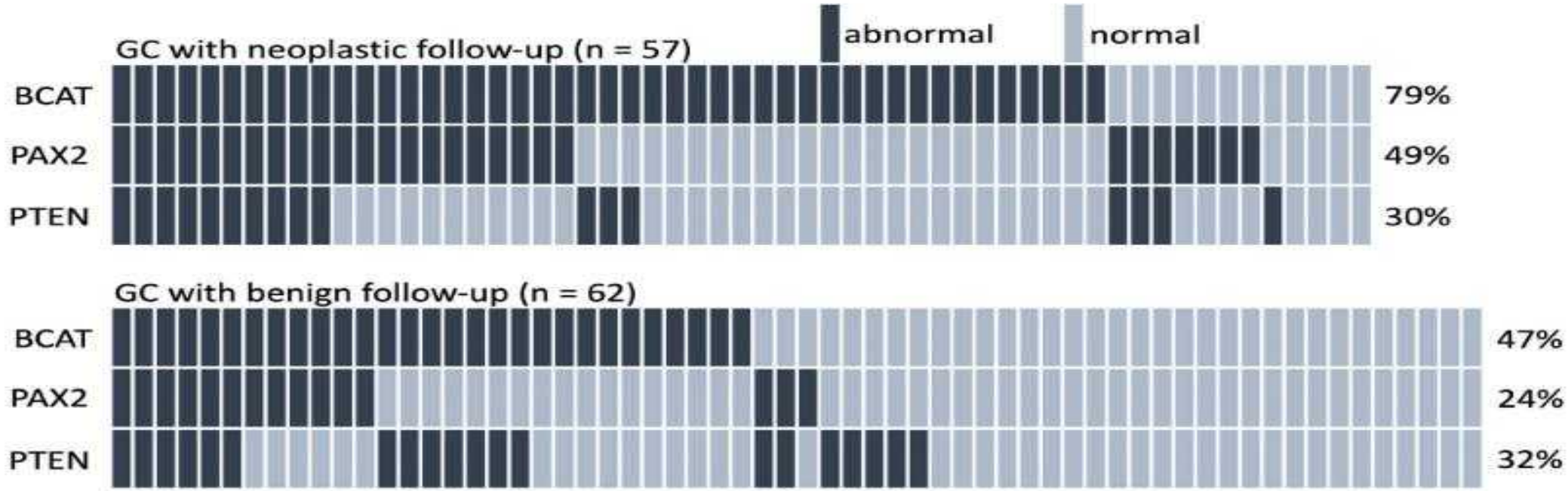

Specific Biomarker Expression Patterns in the Diagnosis of Residual and Recurrent Endometrial Precancers After Progestin Treatment

A Longitudinal Study

Hao Chen, MD, PhD, Elena Lucas, MD,* Amanda L. Strickland, MD,* Kelley Carrick, MD,* Katja Gwin, MD, PhD,* Diego H. Castrillon, MD, PhD,*†‡ Glorimar Rivera-Colon, MD,* Shuang Niu, MD,* Kyle H. Molberg, MD,* and Wenxin Zheng, MD*†‡*

- Aberrant expression patterns of PTEN and/or PAX2 in primary biopsies persisted in persistent/recurrent AH across serial endometrial biopsies
- For follow-up biopsies that showed uncertain residual hyperplasia status, PTEN/PAX2 expression pattern identical to the initial biopsy were significantly correlated with persistent or recurrent disease

(*Am J Surg Pathol* 2020;44:1429–1439)

International Journal of Gynecological Pathology
43:494–505, Lippincott Williams & Wilkins, Baltimore
Copyright © 2024 by the International Society of Gynecological Pathologists

Original Article

Predicting Progestin Therapy Response With PTEN, PAX2, and β-Catenin in Patients With Endometrioid Precancer

Naijia Liu, M.D., Ph.D., Wanrun Lin, M.D., Ph.D., Yan Wang, M.D., Zhigang Yao, M.D., Ph.D., Glorimar Rivera-Colon, M.D., Yan Li, M.D., Ph.D., Kelley S. Carrick, M.D., Hao Chen, M.D., Ph.D., Elena Lucas, M.D., and Wenxin Zheng, M.D.

- Comparing ultimate responders and non-responders, non-responders are more likely to show PTEN loss (but not PAX2, beta-catenin aberrancy) in their initial samples.
- Follow-up samples for ultimate non-responders are more likely to show PTEN loss, PAX2 loss, and β-catenin nuclear staining

Reporting

- Recommendation: PAX2, β-catenin and PTEN IHC on all initial diagnoses of AEH in a sampling specimen**
- Patterns of expression may help to resolve ambiguous cases in follow-up samples.

**Zheng W, Fadare O, Quick CM. Gynecologic and Obstet Pathol. 2nd Edition. 2025

Follow-up Biopsies on an AEH patient who is being treated with Progestins

Key Questions for the Pathologist

(1) Is residual hyperplasia present? *YES or NO?*

(2) If residual hyperplasia is present, any insights, qualitative or quantitative, about the hyperplasia?

(3) Is Cancer present? *YES or NO?*



Ross University School of Medicine
https://medical.rossu.edu/about/blog/what-does-a-pathologist-do-and-how-to-become-one

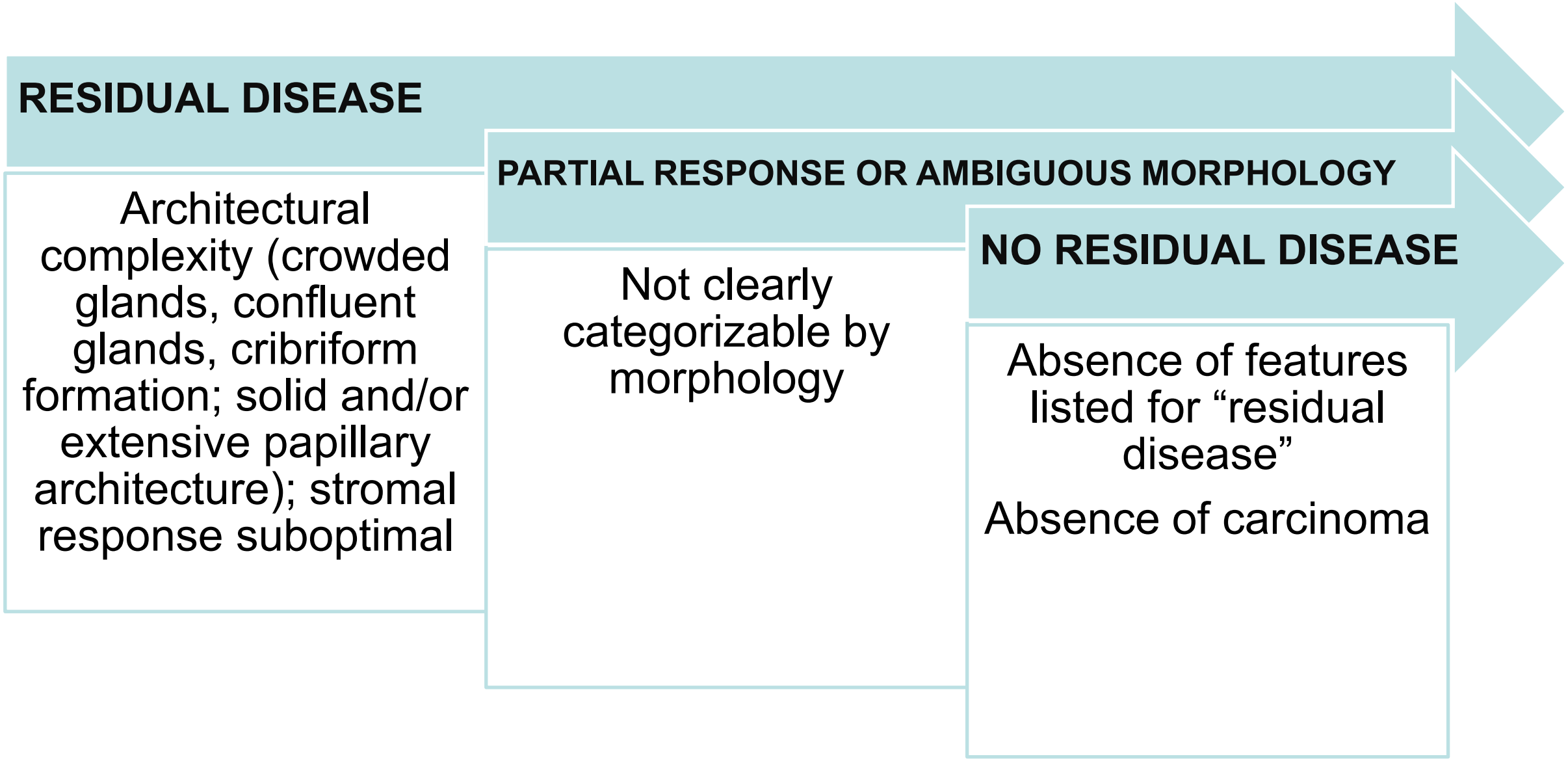
RESIDUAL DISEASE
Architectural complexity (crowded glands, confluent glands, cribriform formation; solid and/or extensive papillary architecture); stromal response suboptimal
PARTIAL RESPONSE OR AMBIGUOUS MORPHOLOGY
Not clearly categorizable by morphology
NO RESIDUAL DISEASE
Absence of features listed for “residual disease”
Absence of carcinoma

RESIDUAL DISEASE

Architectural complexity (crowded glands, confluent glands, cribriform formation; solid and/or extensive papillary architecture); stromal response suboptimal

PARTIAL RESPONSE OR AMBIGUOUS MORPHOLOGY

Not clearly categorizable by morphology

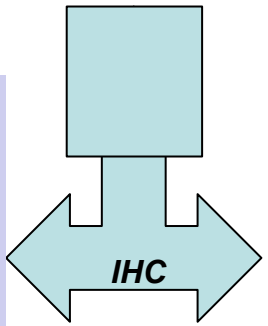

Aberrant IHC: **Residual disease**

Normal IHC: **No Residual disease**

Normal IHC: **ambiguous report**

NO RESIDUAL DISEASE

Absence of features listed for “residual disease”

Absence of carcinoma

Ambiguous morphology

- **Insufficient abnormalities to classify as residual hyperplasia by morphology**, but possibly abnormal; may represent foci of “partial response”
- Examples: equivocal crowding; microglandular architecture in a purely surface pattern; somewhat crowded atrophic cysts; some papillary patterns; single glands abridged by squamous morules; isolated morules as the only abnormal feature; others
- IHC may resolve

Follow-up Biopsies on an AEH patient who is being treated with Progestins

Key Questions for the Pathologist

(1) Is residual hyperplasia present? *YES or NO?*

(2) **If residual hyperplasia is present, any insights, qualitative or quantitative, about the hyperplasia?**

(3) Is Cancer present? *YES or NO?*

- **<u>Recommendation:</u>**
  - Report percent of sample involved by residual hyperplasia.
  - Comparison to previous sample to assess for trends
  - If there are any areas of architectural complexity associated with lack of stromal decidual response, note this and quantify to the extent possible.
  - This approach ultimately tells a story over time

Follow-up Biopsies on an AEH patient who is being treated with Progestins

Key Questions for the Pathologist

(1) Is residual hyperplasia present? *YES or NO?*

(2) If residual hyperplasia is present, any insights, qualitative or quantitative, about the hyperplasia?

(3) Is Cancer present? *YES or NO?*



Ross University School of Medicine
https://medical.rossu.edu/about/blog/what-does-a-pathologist-do-and-how-to-become-one

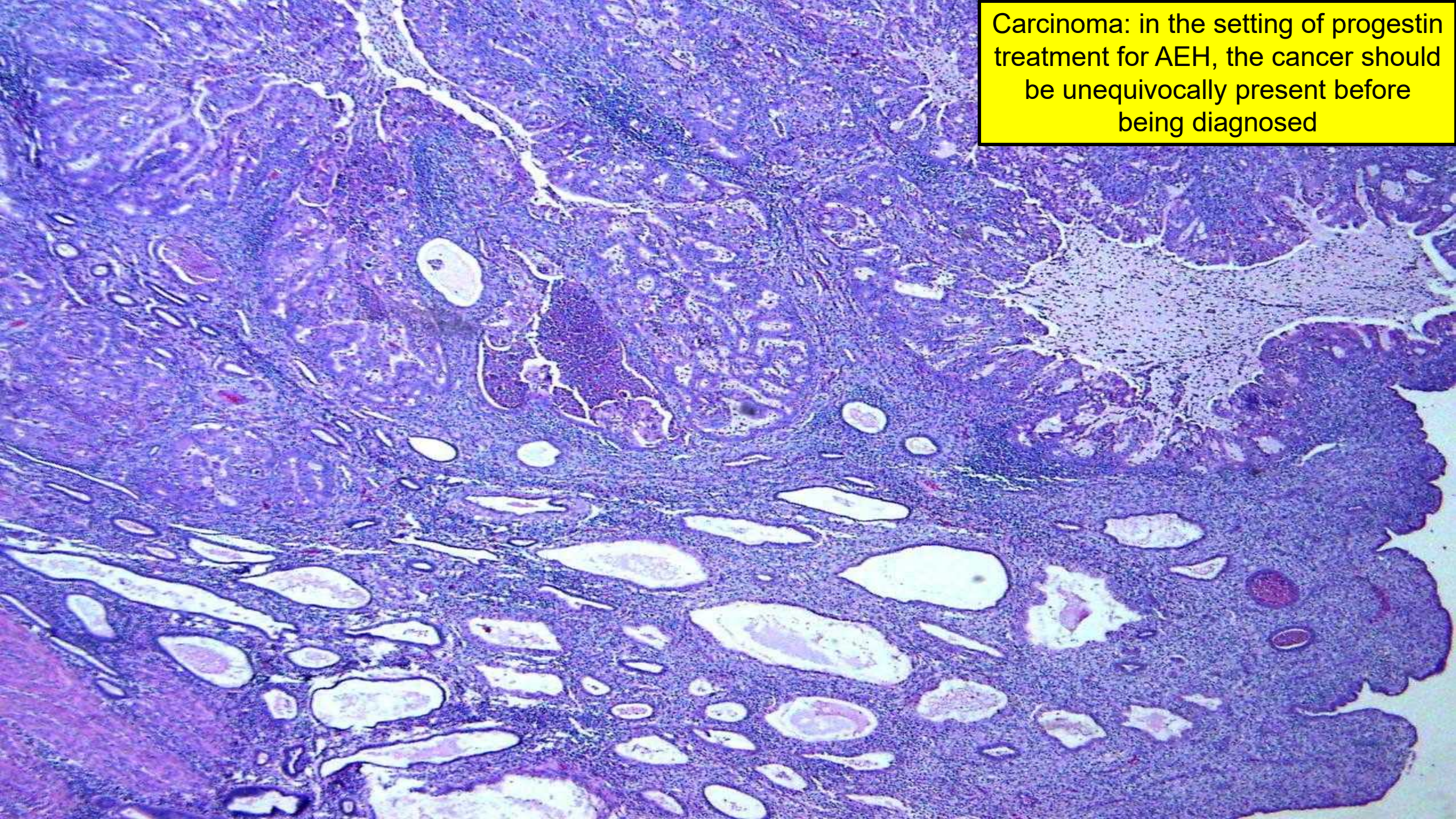
Carcinoma: in the setting of progestin treatment for AEH, the cancer should be unequivocally present before being diagnosed

Progestin Therapy Score (PTS): USCAP 2025

- PTS of zero indicating no residual disease (RD) and a PTS of 7 or higher signifying RD presence
- PTS not only correlates with RD presence but also strongly reflects the amount of RD in progestin-treated endometrial samples

PTS	0	1	2	3	4	5	6	7	8
# Cases	31	28	52	37	34	22	17	19	9
# RD (%)	0 (0)	1 (4)	4 (8)	4 (11)	12 (35)	17 (77)	15 (88)	18 (95)	9 (100)

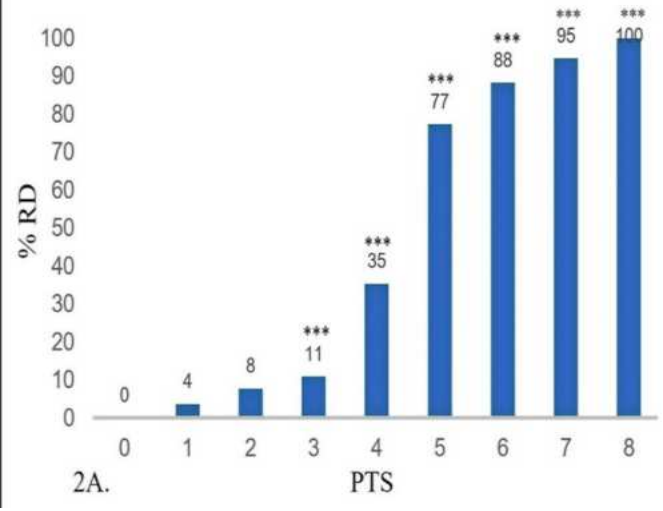

2A.

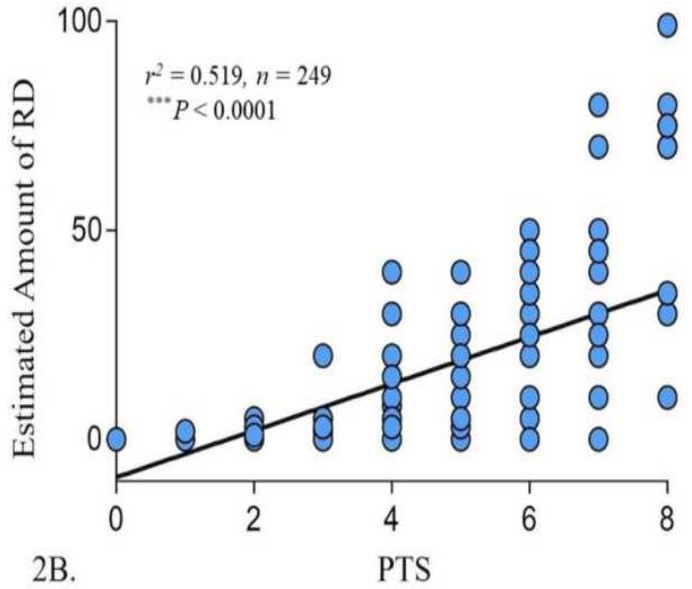

2B.

Parameter	Morphological features	Score
Endometrial epithelia	Completely attenuated (flat or cuboidal)	0
	Partially attenuated (low columnar)	1
	Non attenuated (Columnar, like regular proliferative endometrial glandular cells or higher)	2
Endometrial stromal cells	Completely decidualized	0
	Less or partially decidualized	1
	Non-decidualized	2
Glandular crowding	No crowding	0
	Focally crowded	1
	Apparently crowded	2
Glandular complexity	No complexity	0
	Focal complexity (any irregular, papillary, cribriform and morule or in combination)	1
	Extensive complexity	2

Ling Chen; Wanrun Lin; Elena Lucas; Glorimar Rivera Colon; Shuang Niu; Kelley Carrick; Katja Gwin; Wenxin Zheng
Progestin Therapy Score: A Predictor of Residual Disease in Endometrial Precancers and Cancers. USCAP 2025

Summary

- A spectrum of changes may be seen in the follow-up samples of AEH patients on progestin treatment
- The specific changes are related to appearances of the index lesion, duration of treatment, responsiveness of lesion, and unknown factors.
- Pathologists should strive to provide meaningful information regarding the efficacy of ongoing treatments
- More consensus within the field is needed, but for now pathologists within a single practice group should use similar diagnostic terminology