The British Association of Gynaecological Pathologists

bsccp | The British Society for Colposcopy and Cervical Pathology

Lecturer – Dr Pinias Mukonoweshuro

I am a Consultant Histopathologist with a specialist interest in Gynaecological pathology including Cervical screening histology. I am based at the Royal United Hospital Bath NHS Foundation Trust. I am the current BAGP secretary and have previously held roles as host for ISGYP LiVE webinar series, BAGP council and National Gynaecological EQA.



The British Association of Gynaecological Pathologists

bsccp | The British Society for Colposcopy and Cervical Pathology

Basic Cervical Histopathology Course

- Squamous non-invasive histology including mimics
- Dr Pinias Mukonoweshuro
- Royal United Hospital Bath NHS Foundation Trust
- 26 February 2025

The British Association of Gynaecological Pathologists

bsccp | The British Society for Colposcopy and Cervical Pathology

Speaker disclosures

I have no financial conflicts of interest to disclose

Outline

- Normal cervix
- HPV infection
- Squamous intraepithelial neoplasia
- Biomarkers
- Mimics
- Histology reporting of squamous lesions in small biopsies

Anatomy

- At puberty & pregnancy the endocervical cells are pushed out to lie on the ectocervix



Normal **Ectropion**

Metaplasia

- The endocervical cells are transformed into squamous cells through the process of **squamous metaplasia**

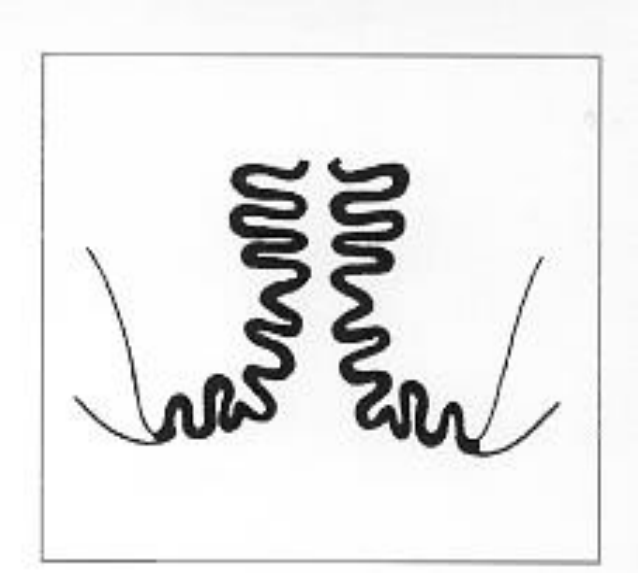

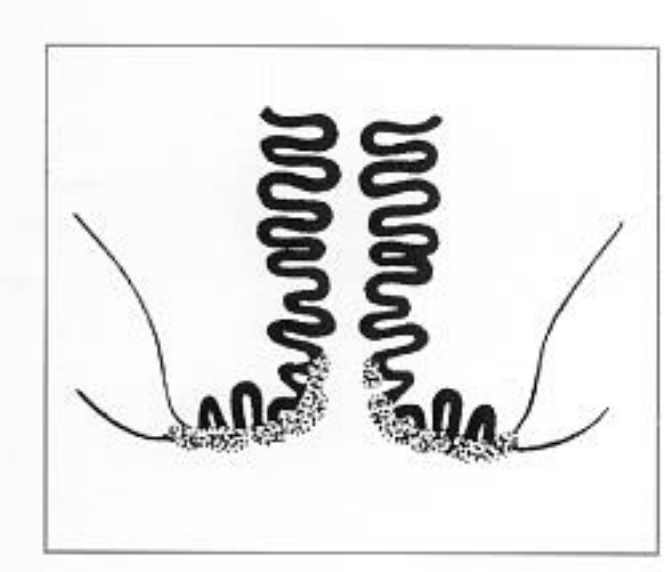

Transformation Zone

- The area where metaplasia occurs is called the TRANSFORMATION ZONE (TZ)
- This is the area where CERVICAL INTRAEPITHELIAL NEOPLASIA may arise
- The transformation lies between the original squamo-columnar junction (SCJ) and the new squamo-columnar junction
- The SCJ and TZ are dynamic and change in response to puberty, pregnancy, menopause and hormonal stimulation
- TZ is classified into TZ1, TZ2 and TZ3 depending on location of new SCJ

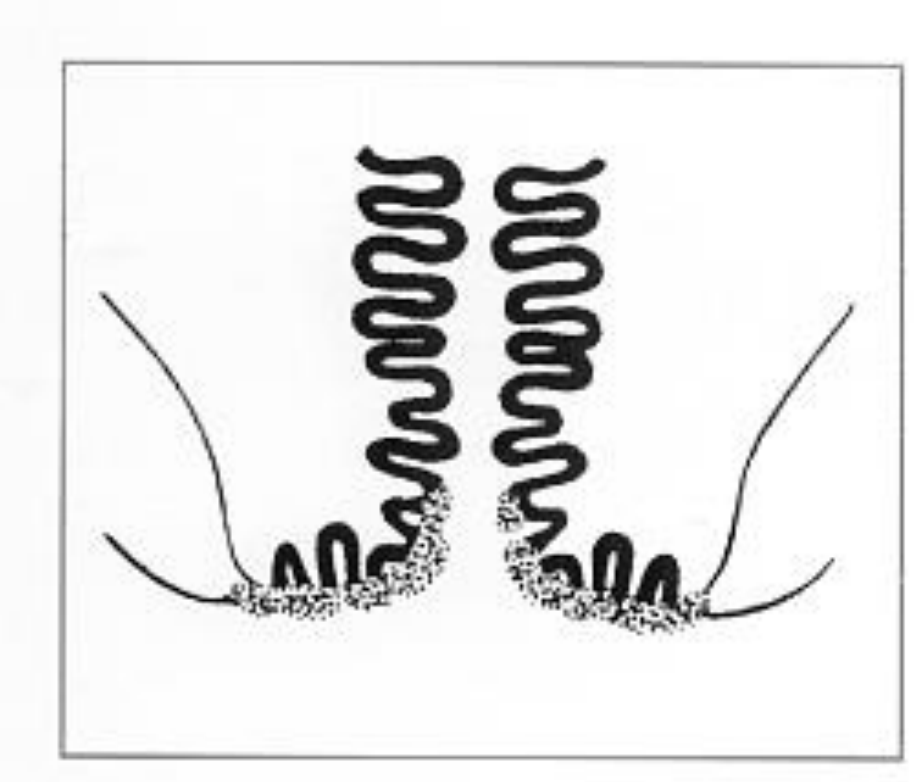

Transformation zone (TZ) types

- TZ 1 – Ectocervical, fully visible. (7-10mm depth of excision)
- TZ2 – part of TZ located in endocervix, fully visible. (10-15mm depth of excision)
- TZ3 – TZ has endocervical component , **not fully visible. (**15-25mm depth of excision)

Histology of transformation zone

- “TZ tissue will have surface squamous epithelium with either surface columnar tissue or stromal gland crypt, or both”



- We would cautiously recommend that the transformation zone should be defined by the presence of squamous and columnar epithelium in continuity and/or the presence of squamous epithelium with underlying glands. J Clin Pathol. 2005 Jun; 58(6): 671.

Transformation zone tissue with squamous metaplasia

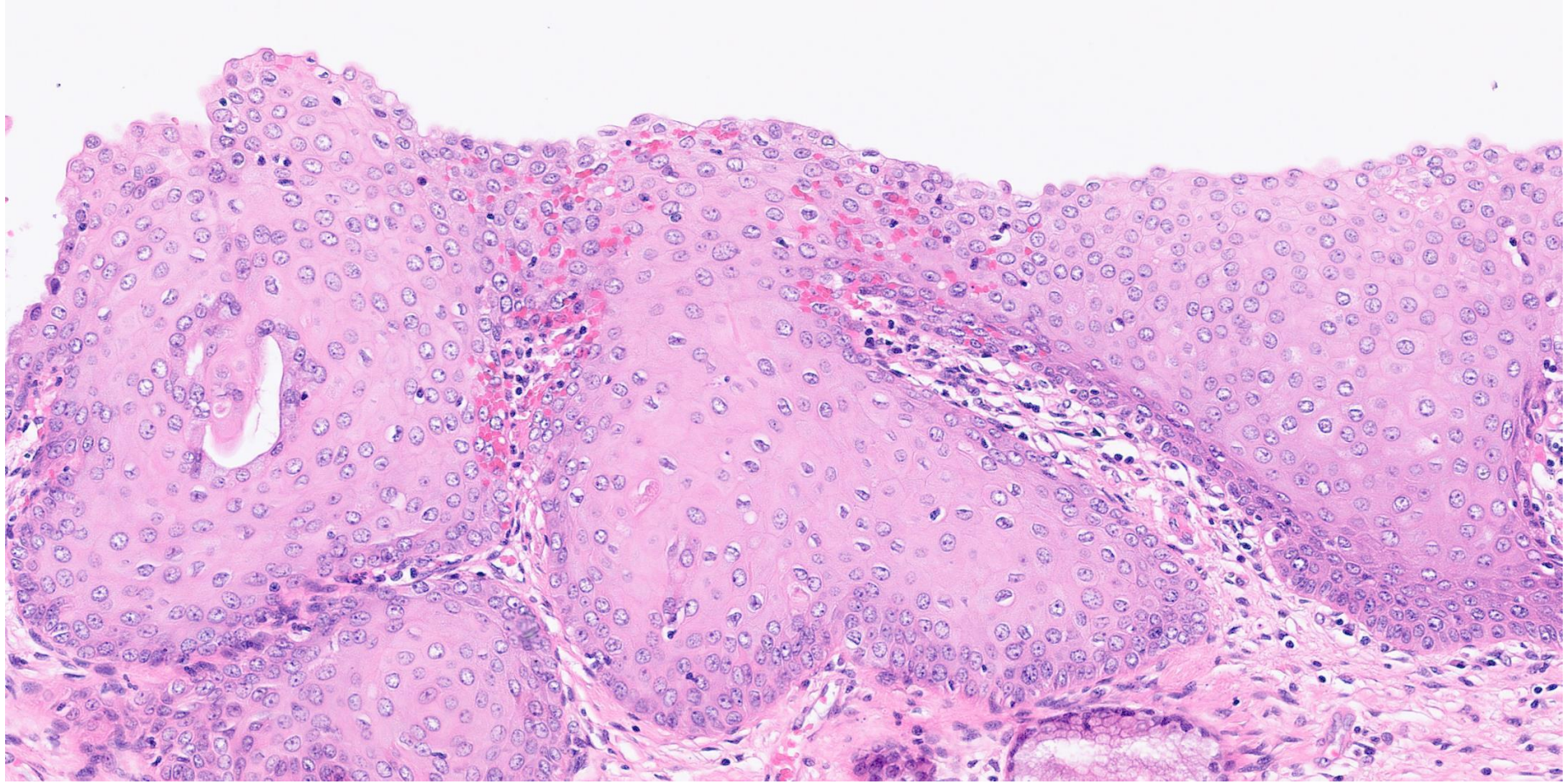

Role of HPV in cervical neoplasia

- HPV DNA carries oncogenes that specify proteins which inactivate tumour suppressors which allows the infected cells to keep proliferating

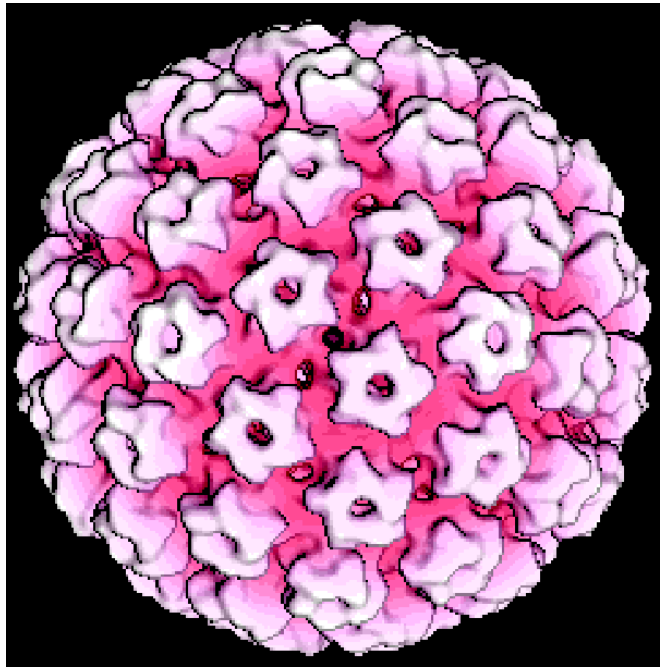

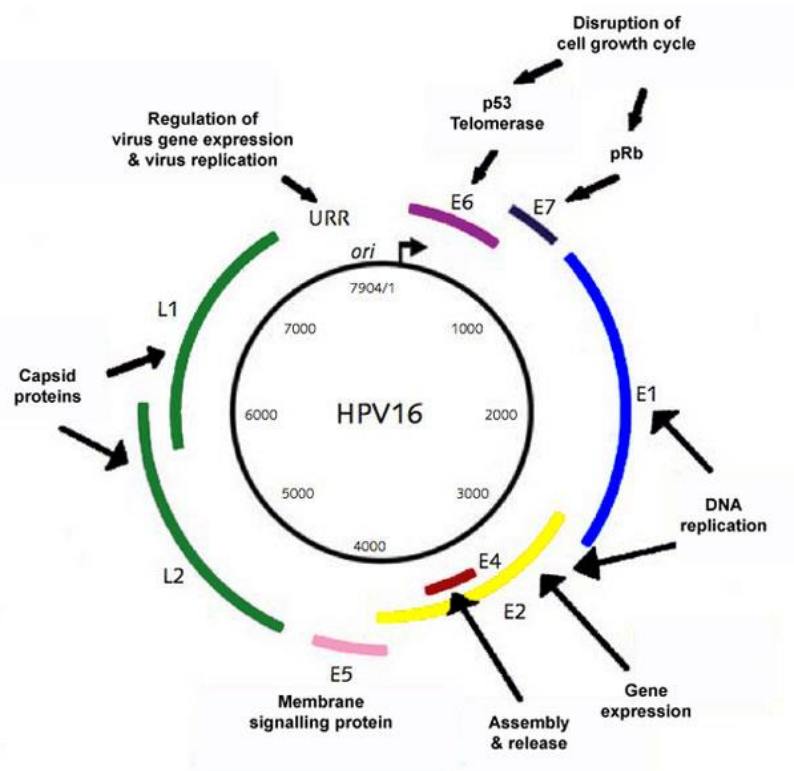

Role of HPV in cervical neoplasia

- HPV infection established in basal layers
- HPV genes classified as “early (E)” or “late (L)” depending on the timing of their expression in the epithelium
- E6 and and E7 play the most significant role in cervical neoplasia
- E6 binds to p53 – blocks cell apoptosis
- E7 binds to retinoblastoma (RB) tumour suppressor protein - abolishes cell cycle arrest and leads to unscheduled cellular proliferation.

HPV

- >200 serotypes of HPV
- Infection transient in most cases
- 20-30% of women do not clear HPV. Most women clear HPV within 24 months
- High risk HPV (e.g. 16, 18, 31, 33) – associated with cervical intraepithelial neoplasia (CIN), cervical glandular intraepithelial neoplasia (CGIN), stratified mucin-producing intraepithelial lesion (SMILE) and cancer.
- Low risk (6 and 11) – warts

Squamous Epithelium

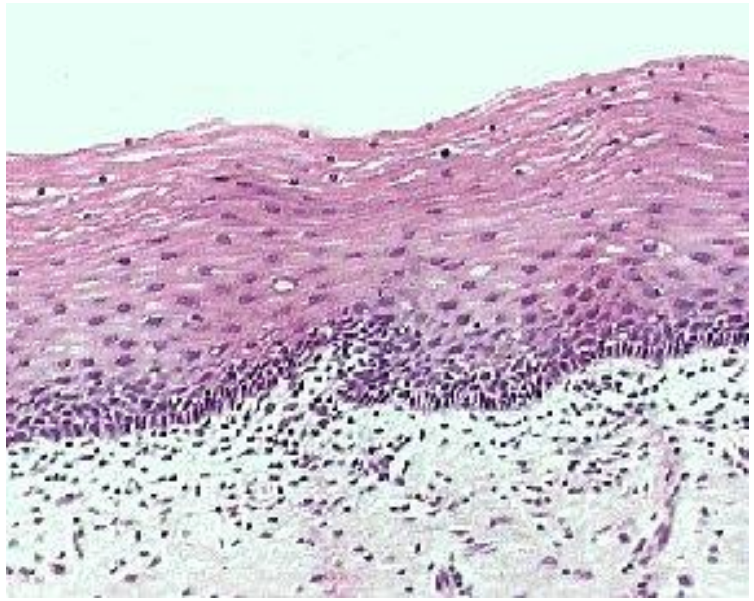

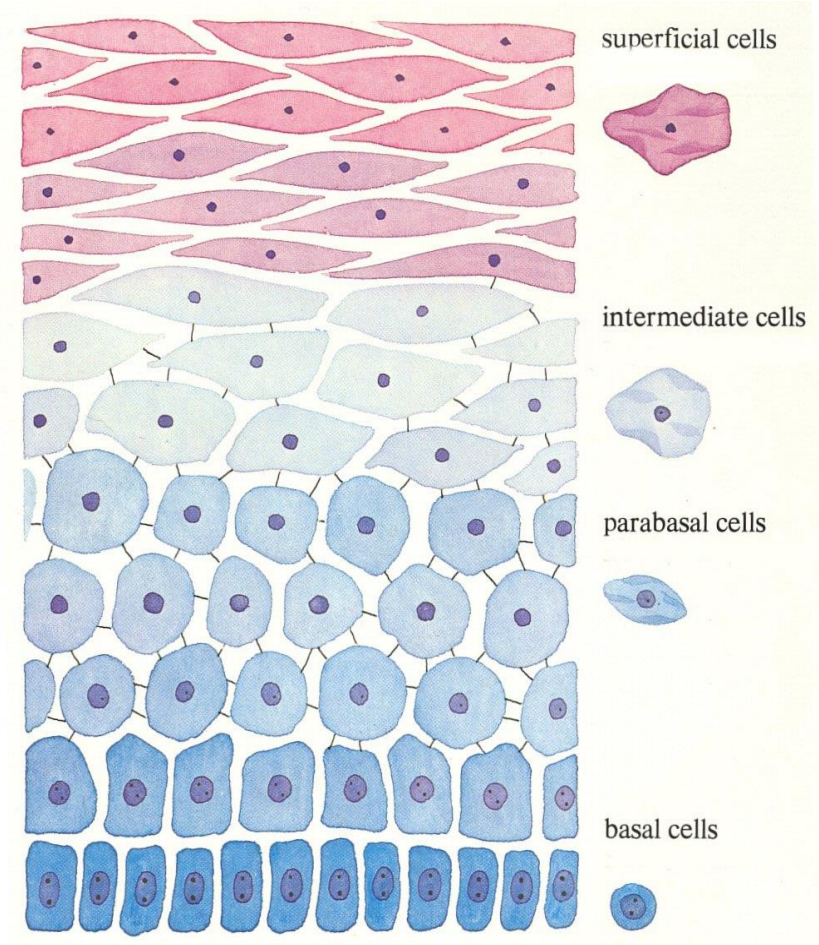

Normal v. koilocytosis

- Normal

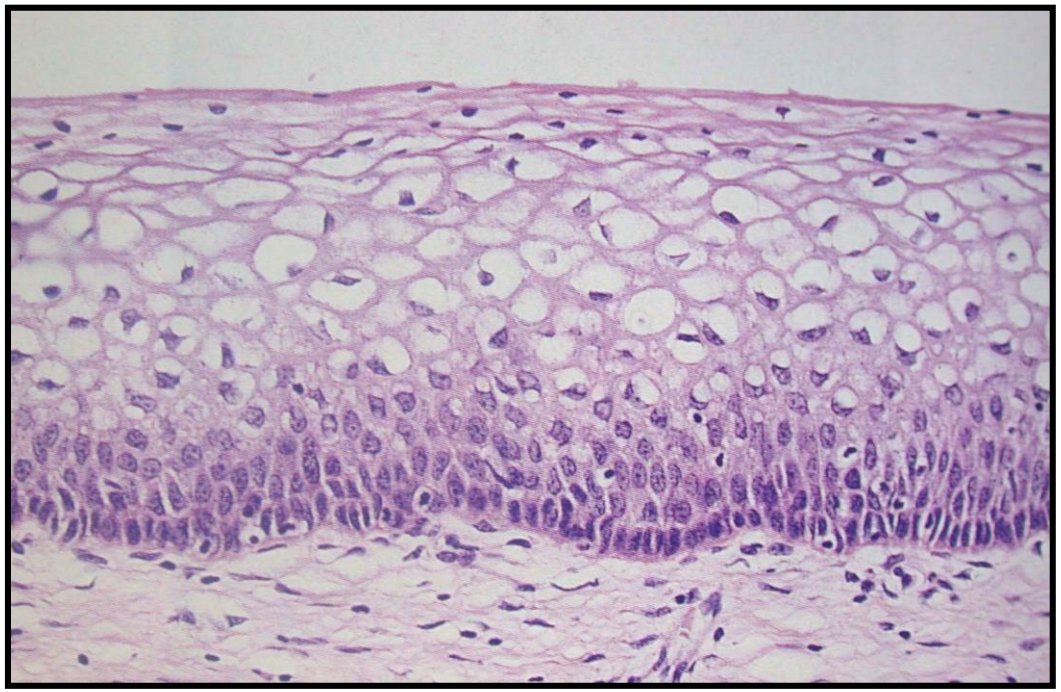

- Koilocytosis

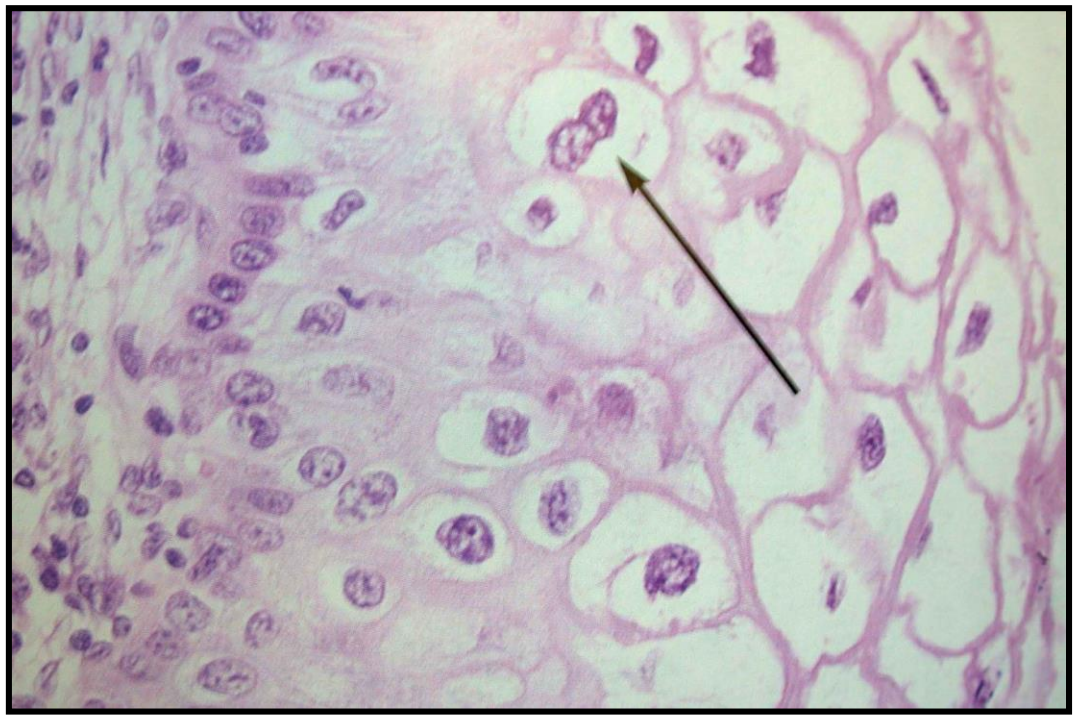

Koilocyte

- Mature squamous cell with recognisable nuclear and cytoplasmic alterations due to HPV infection
- Sharply defined perinuclear clearing/halo
- Nuclear enlargement (2 - 3 x normal)
- Nuclear membrane irregularity – wrinkled/raisinoid appearance
- Nuclear hyperchromasia
- Binucleation

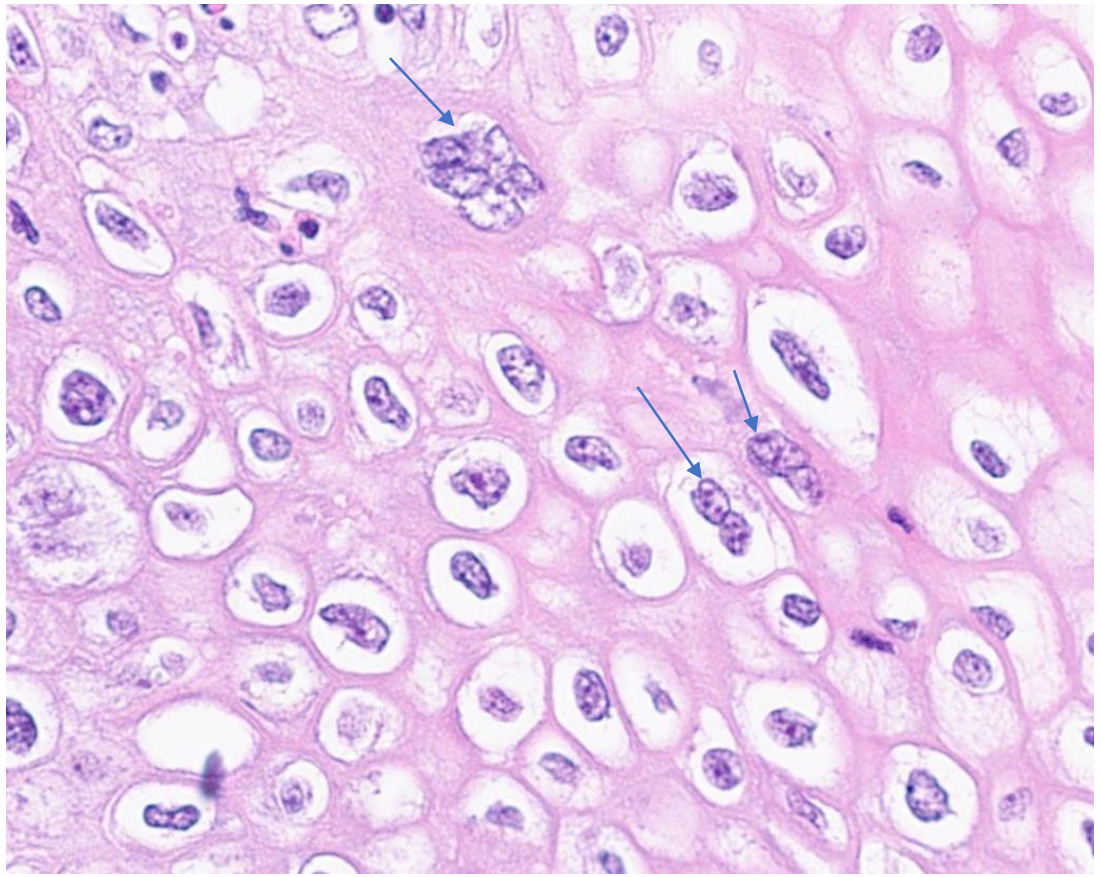

Squamous intraepithelial lesions (SILs)/Cervical intraepithelial neoplasia (CIN)

- Proliferations of squamous cells driven by HPV infection not extending beyond the basement membrane
- Show maturation abnormalities and or viral cytopathic changes
- Divided into:

  LSIL (condyloma/CIN1)

  HSIL (CIN2)

  HSIL (CIN3)

Diagnostic criteria (WHO) – LSIL (CIN1)

- Full thickness atypia with moderate to abundant cytoplasm in cells within the upper two thirds of the epithelium
- Basaloid morphology and significant mitotic activity restricted to **lower epithelial third** of epithelium
- Koilocytic atypia present

CIN1 with koilocytosis

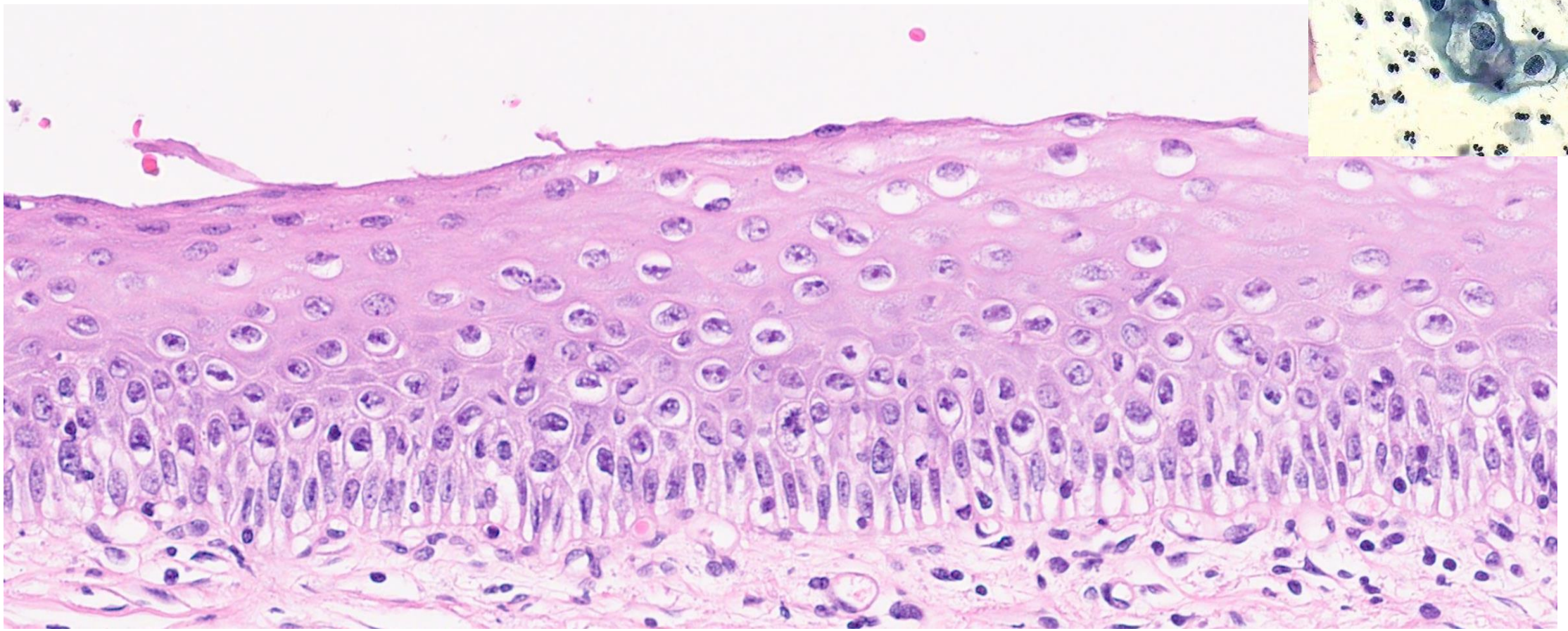

HSIL (CIN2)

- Full thickness atypia
- Basaloid cells mitotic activity extending into the **upper half to two thirds** of the epithelium
- Retained koilocytic change on the surface
- Difficult diagnosis, best reviewed at MDT if conservative treatment is considered

CIN2

- Classified as HSIL together with CIN3
- Significant rates of regression in young women <30yrs
- Conservative management appropriate in correct clinical context
- Accurate histological diagnosis important
- Histological diagnosis prone to underdiagnosis or overdiagnosis
- MDT review with careful use of p16 useful in diagnosis

CIN2 with koilocytosis

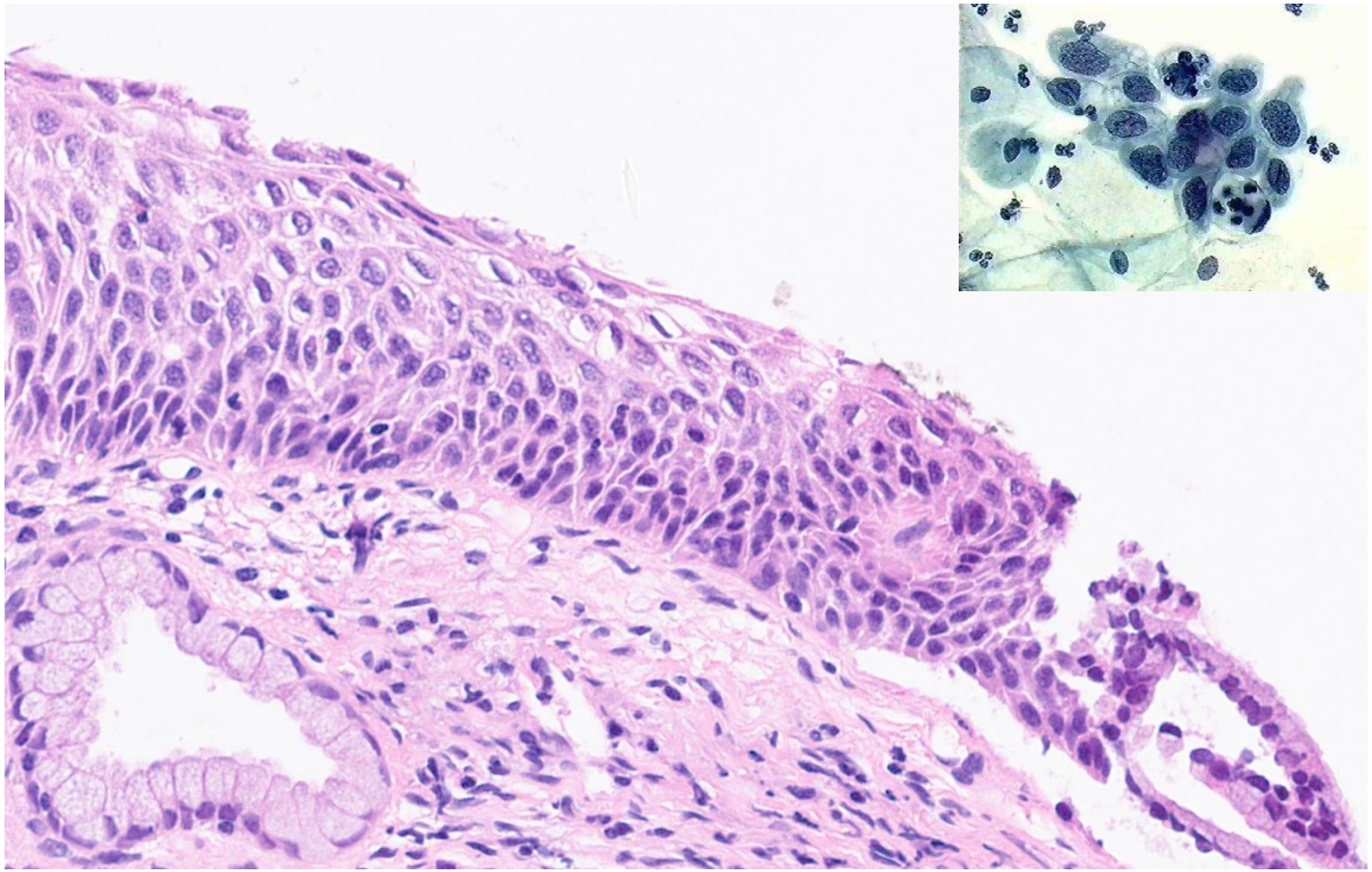

HSIL (CIN3)

- Full thickness atypia with similar cells base to surface
- Mitotic activity identified throughout the epithelium
- Upper portions of epithelium show a significantly higher N:C ratio than in LSIL and HSIL

CIN3

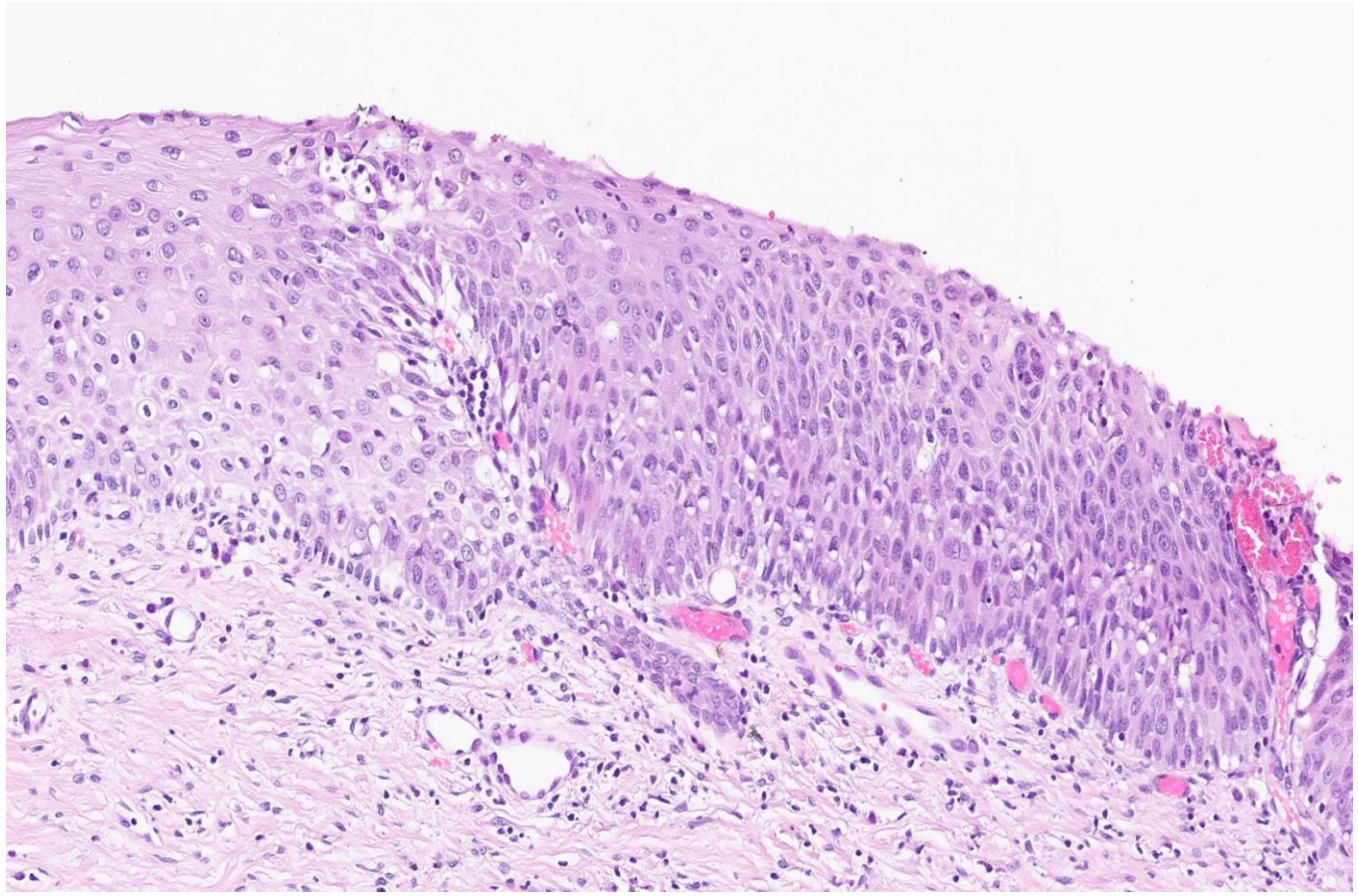

CIN3

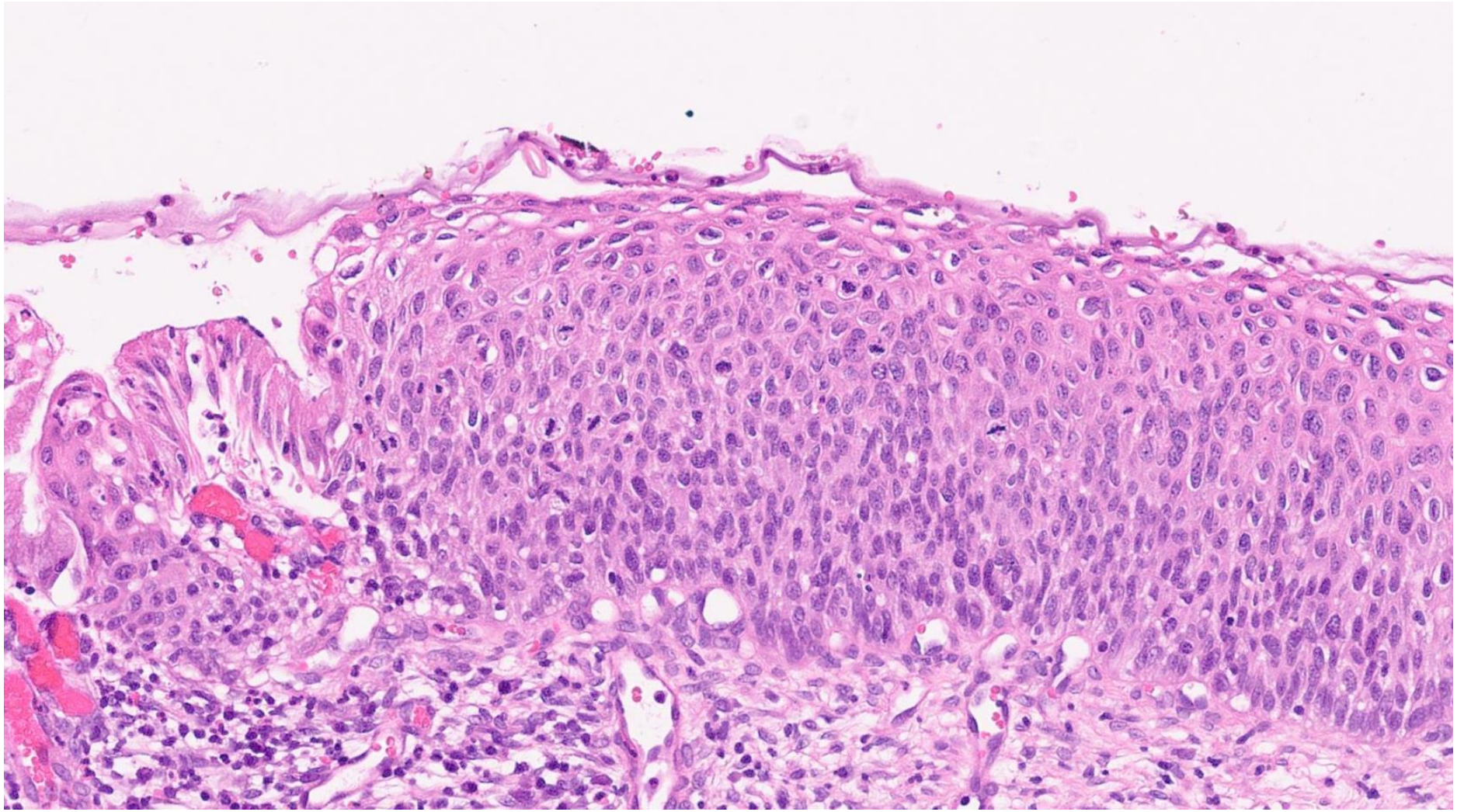

CIN3

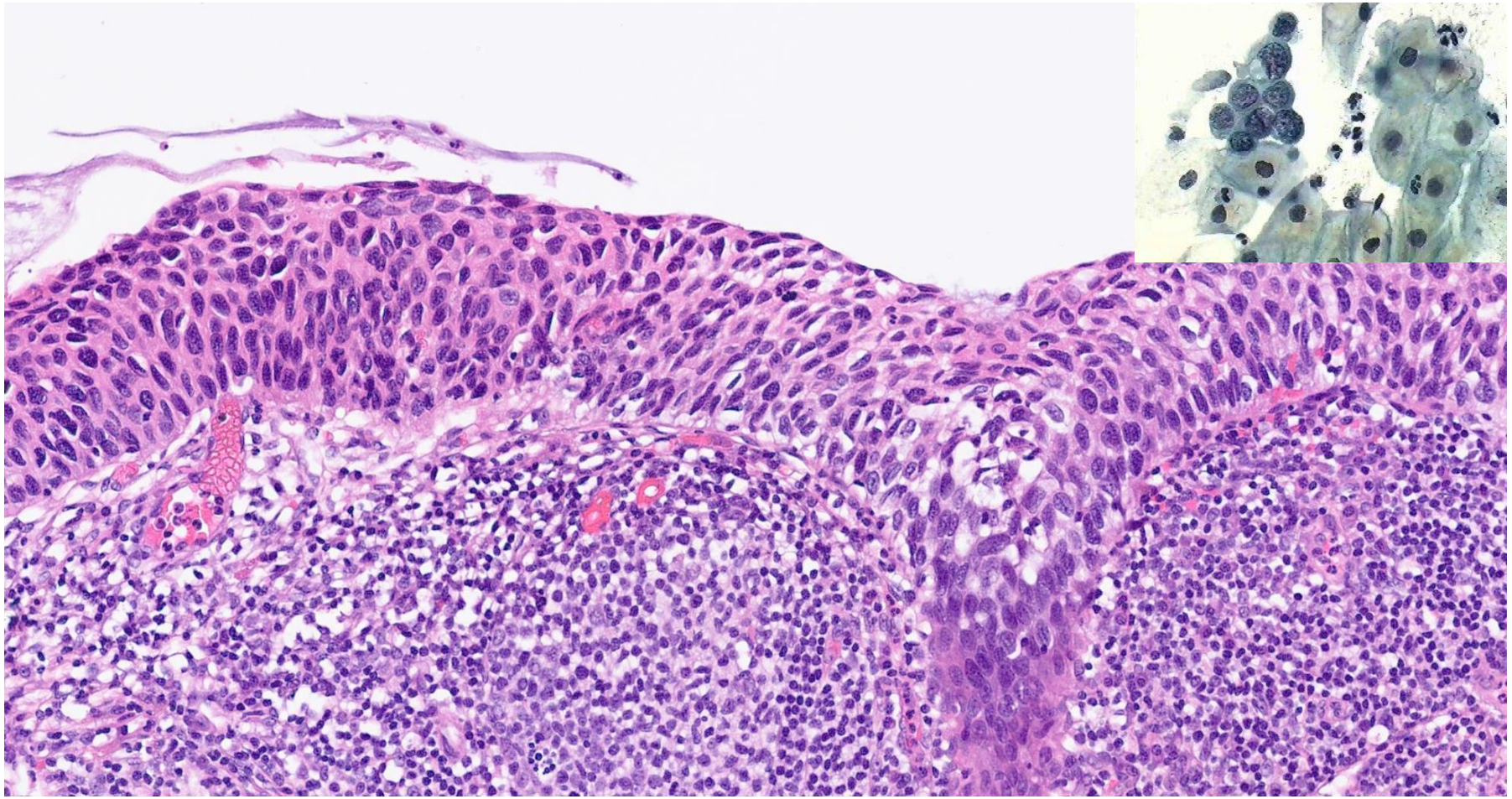

CIN3 with crypt involvement

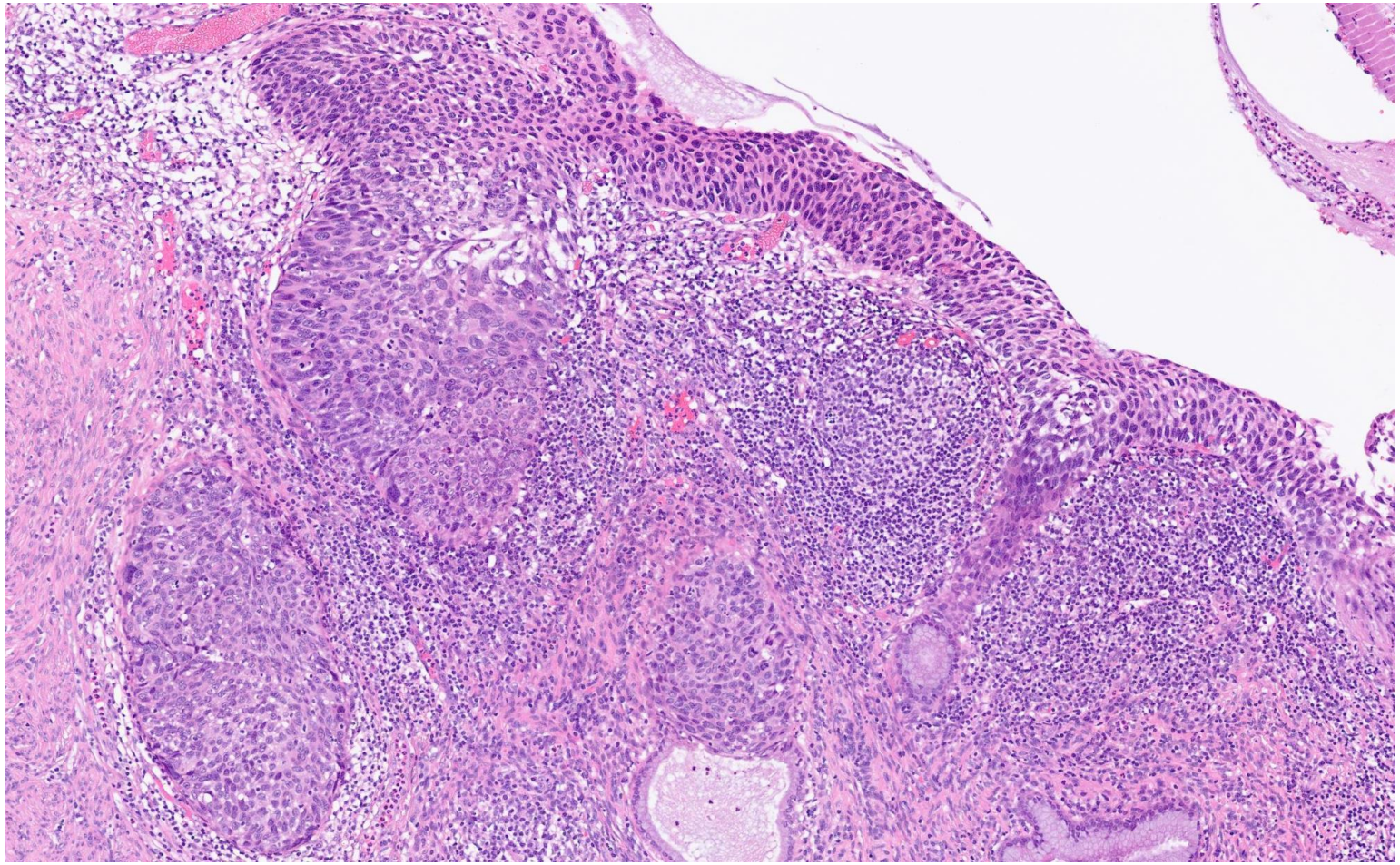

Crypt involvement

- NHS CSP recommends histological reporting of crypt involvement
- Crypt involvement is a risk factor for disease recurrence especially after ablative procedures
- In general crypt involvement precludes ablative procedures – however no definition of crypt depth involvement so regarded as any crypt involvement in a biopsy

Expansile CIN3. PMID 7962647

A I al-Nafussi, DE Hughes. J Clin Pathol. 1994 Sep:47(9):7990804

- CIN3 that extensively involves endocervical crypts
- Crypt involvement leads to expansion of the crypts beyond their normal outline
- Shows central necrosis and intraepithelial squamous maturation
- Increased risk of invasion and recurrence

Expansile CIN3 + FIGO 1a1 HPVA SCC

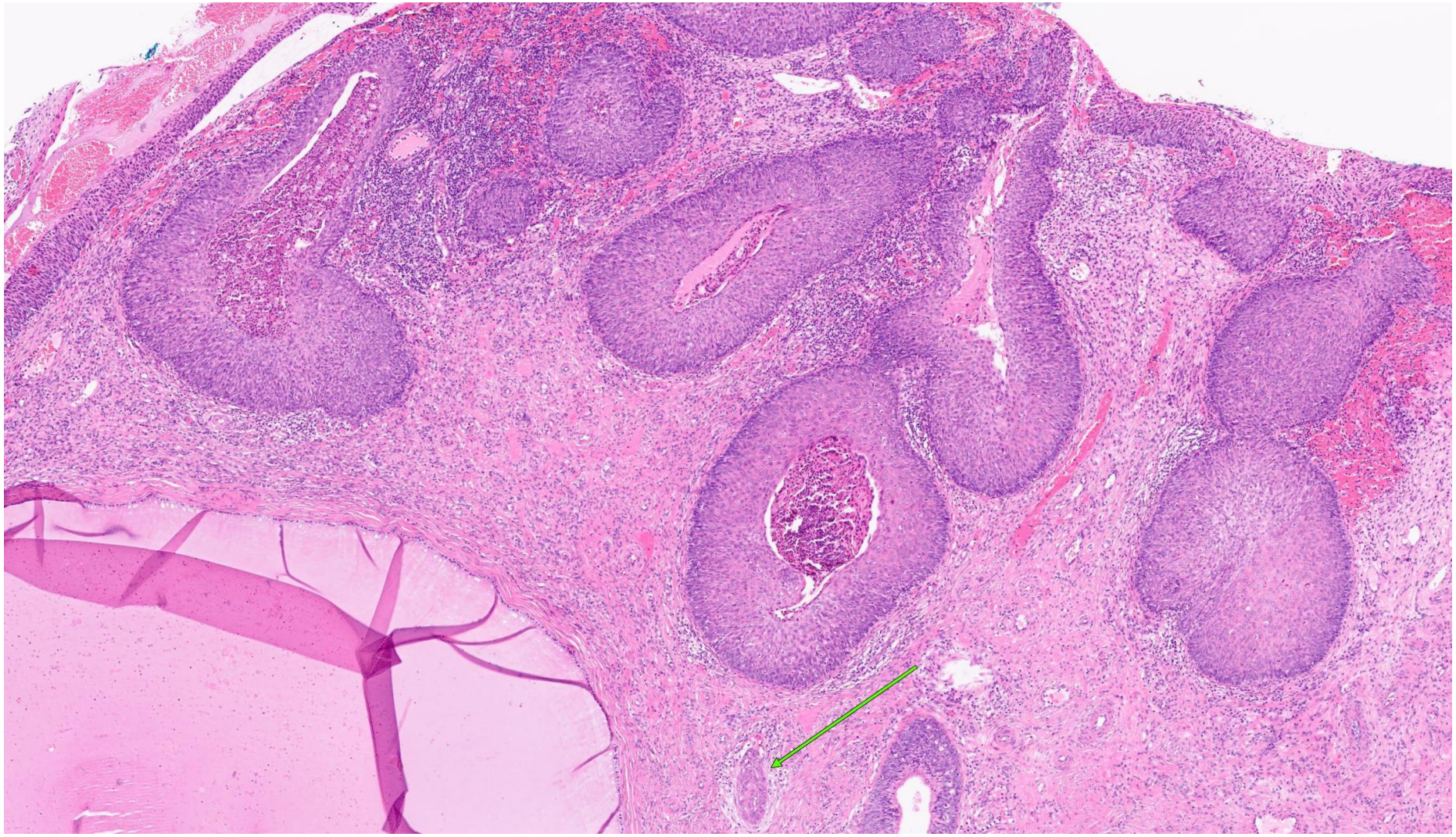

Poll Q1. What is the diagnosis?

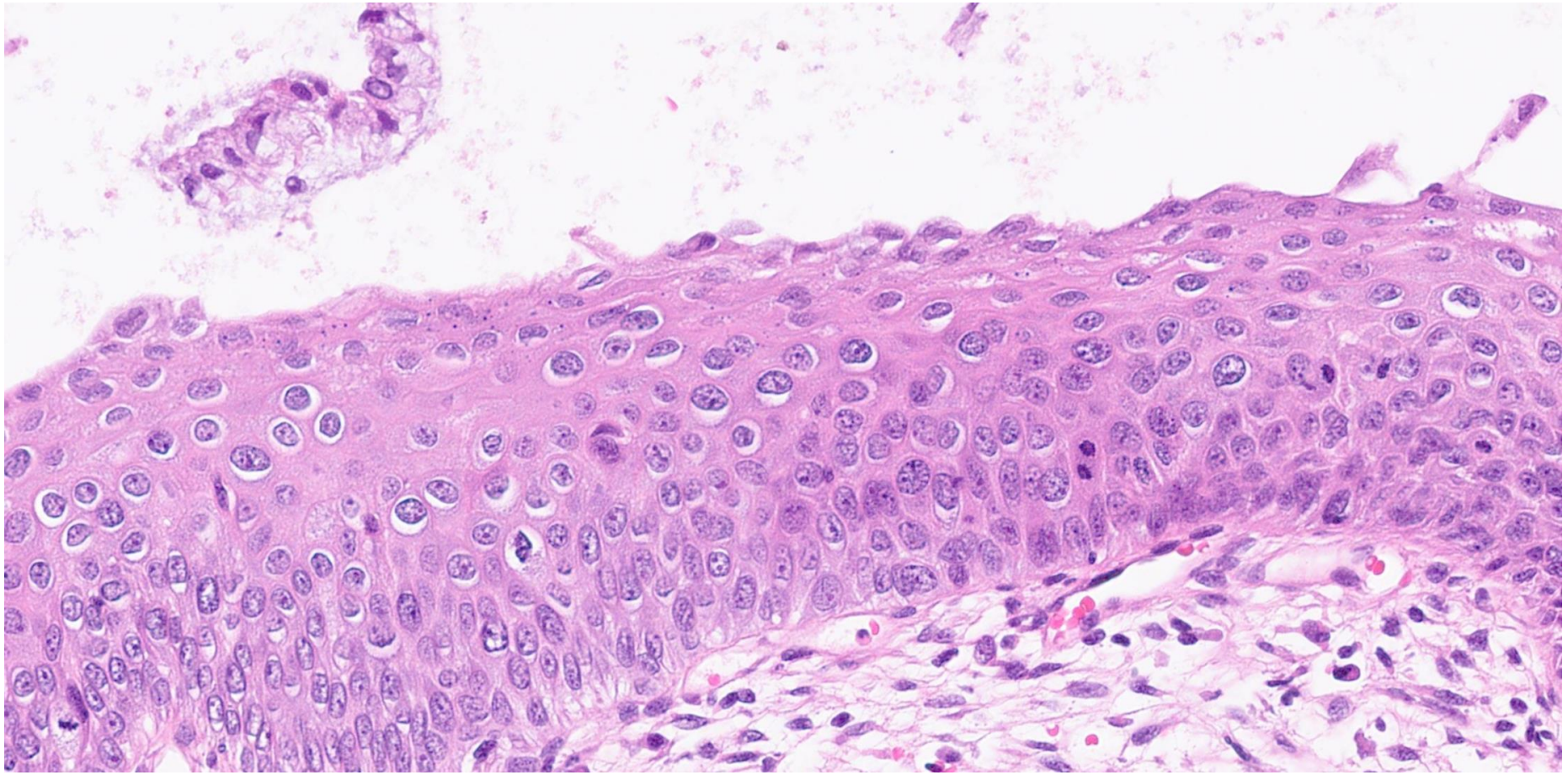

Poll Q2. Is p16 immunohistochemistry useful for grading this lesion?

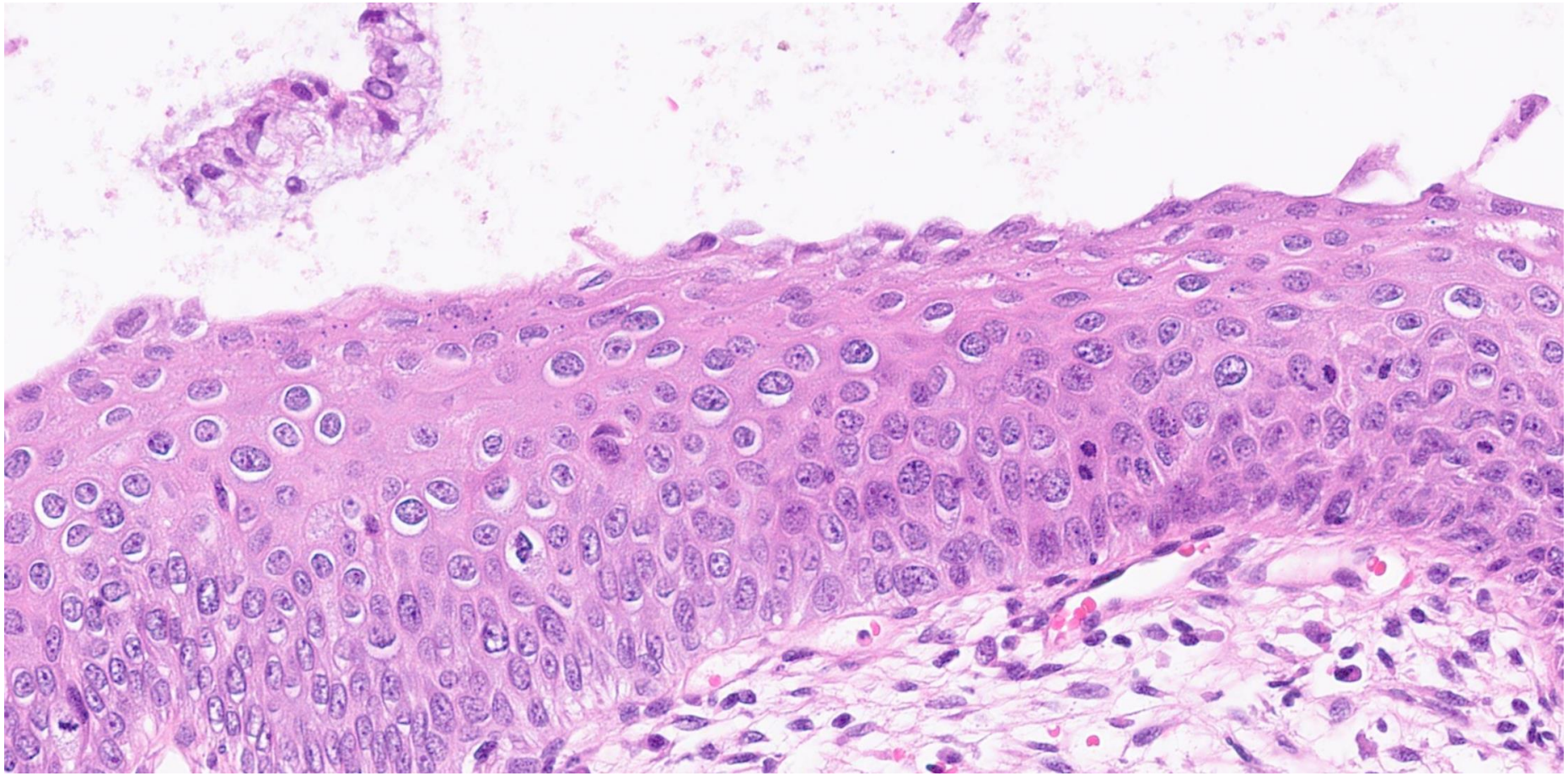

Poll Q3. What is the diagnosis?

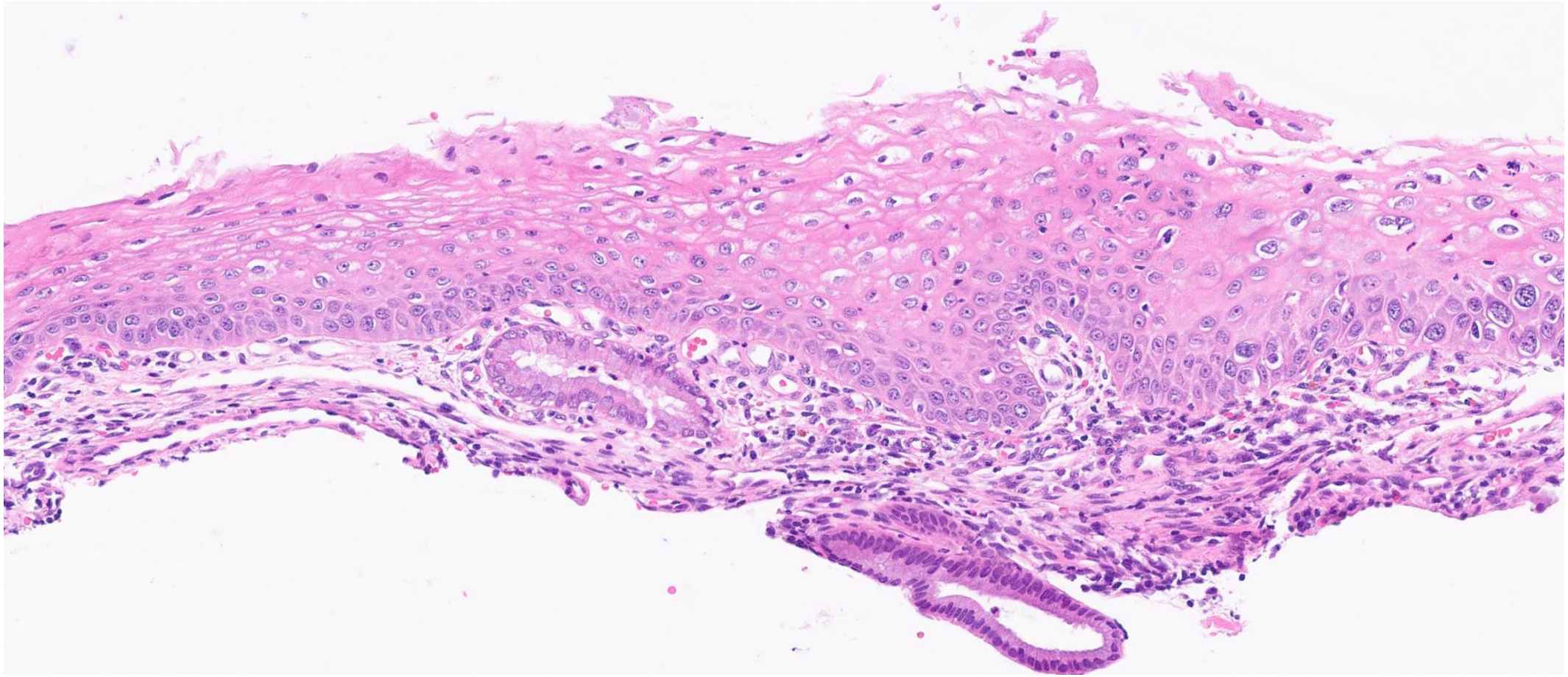

Poll Q4. Does this p16 stain change your diagnosis?

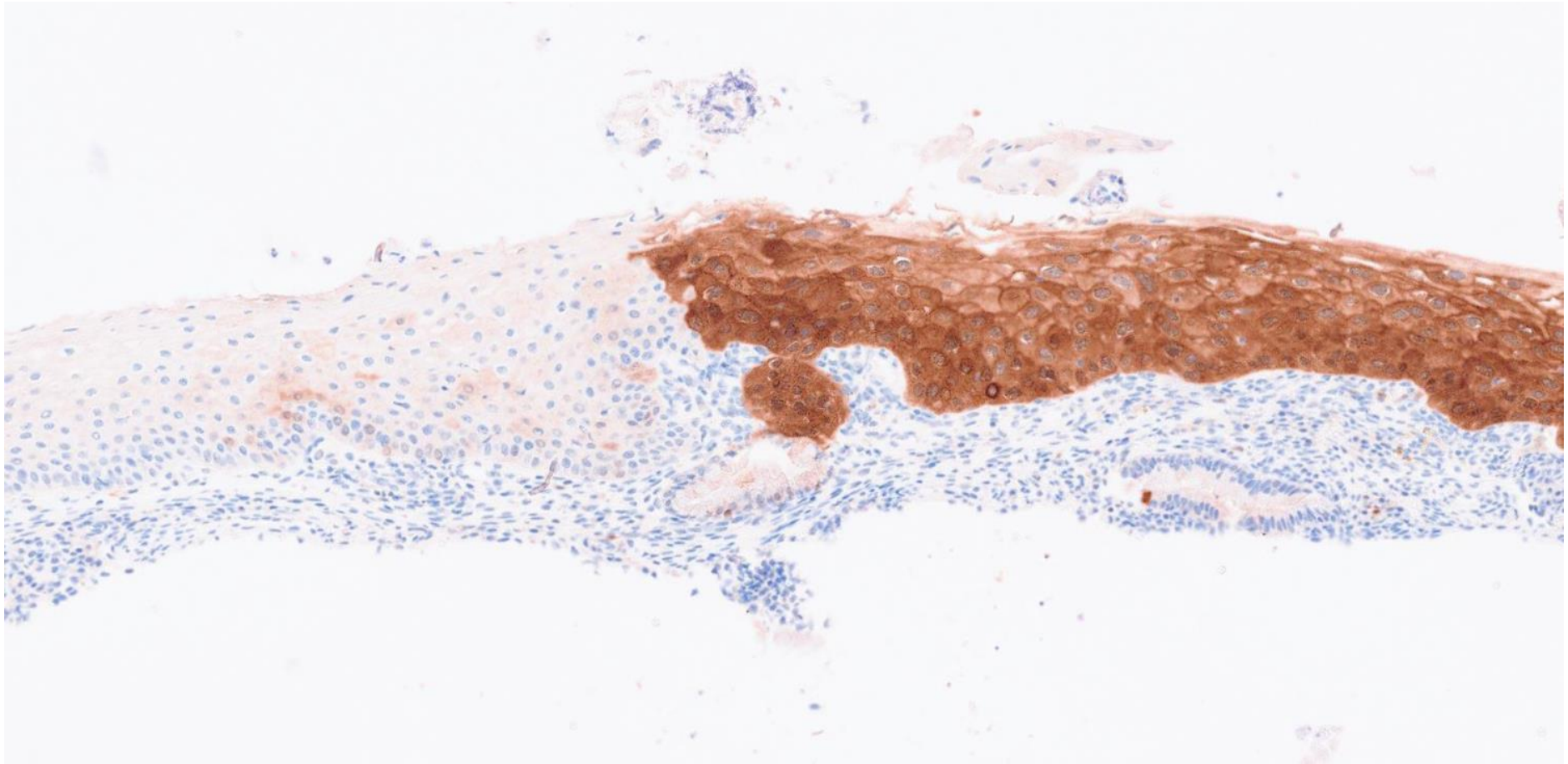

Biomarkers in cervical intraepithelial neoplasia

- P16
- CK7
- Ki-67

p16



Interpretation of p16 Immunohistochemistry In Lower Anogenital Tract Neoplasia

Authors: Naveena Singh[1], C Blake Gilks[2], Richard Wing-Cheuk Wong[3], W Glenn McCluggage[4], C Simon Herrington[5]

[1]Barts Health NHS Trust, London, UK; [2]Vancouver General Hospital [3]Pamela Youde Nethersole Eastern Hospital, Hong Kong, [4]Belfast Health and Social Care Trust, Belfast, UK; [5]University of Edinburgh

The Lower Anogenital Squamous Terminology Standardization Project for HPV-Associated Lesions: background and consensus recommendations from the College of American Pathologists and the American Society for Colposcopy and Cervical Pathology

Teresa M Darragh [1], Terence J Colgan, J Thomas Cox, Debra S Heller, Michael R Henry, Ronald D Luff, Timothy McCalmont, Ritu Nayar, Joel M Palefsky, Mark H Stoler, Edward J Wilkinson, Richard J Zaino, David C Wilbur; Members of LAST Project Work Groups. PMID: 22742517

p16

- Good surrogate test for the PRESENCE of a potentially transforming HPV infection
- Immunohistochemistry (IHC) readily available
- Overexpression on IHC is a marker of a potentially transforming infection
- Reported as block or non block staining
- Careful use improves diagnostic agreement in cervical biopsy interpretation
- Overuse will result in overcall of HSIL

p16 overexpression.
WHO Classification of Tumours . 5th edition

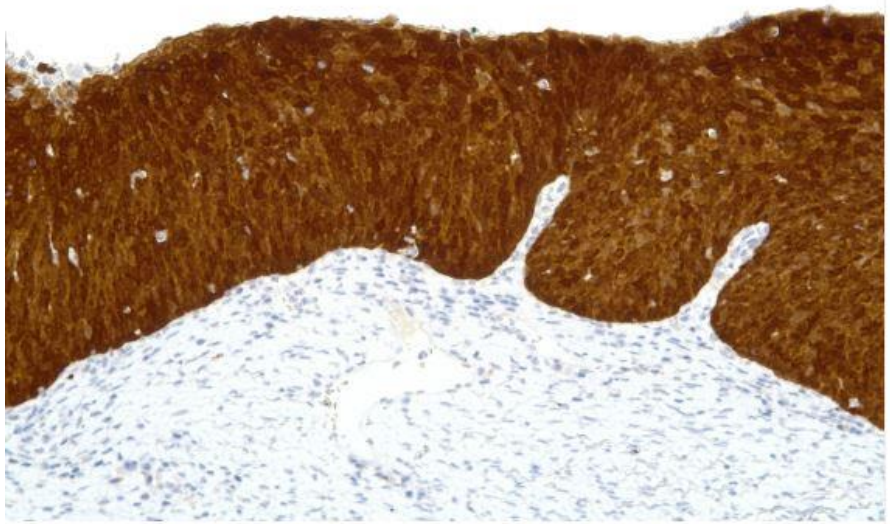

#13822

View Original

Diagnosis:
High-grade squamous intraepithelial lesion (CIN 3)
Legend:
Abnormal cells with a high N:C ratio involve more than two thirds of the mucosal thickness (see <<#16771>>Fig. #16771) and exhibit block-positive p16 reactivity (shown here).

Indication for p16 in cervical squamous lesions

- Differential diagnosis is between high grade intraepithelial neoplasia (IN2/IN3) and a mimic (atrophy, squamous metaplasia, repair, inflammation etc.)

- If H&E diagnosis is IN2+, abnormal p16 helps with clarifying diagnosis

- Can be used an adjunct where there is concern for missed high grade IN (e.g. fragmented biopsies)

p16 should not be used

- For grading intraepithelial neoplasia. Up to 50% of low grade squamous intraepithelial neoplasia in cervix can show abnormal staining

- Grading of all intraepithelial neoplasia should be based on H&E morphology

- Predict biological behaviour/progression of intraepithelial lesion – Colposcopy treatment should be guided by grade of lesion not p16 result (>90% of CIN1 and up to 2/3rds of CIN2 in young women will regress regardless of p16 result)

P16 use - take home message

- Any identified p16 block positive tissue must meet H&E morphological criteria for a high grade lesion to be reported as high grade squamous intraepithelial lesion.

Case

- 25 year old P0
- Cytology low grade squamous dyskaryosis
- Colposcopy - moderate acetowhite

Histology – 25 year old P0
CIN1 with florid koilocytosis or CIN2?

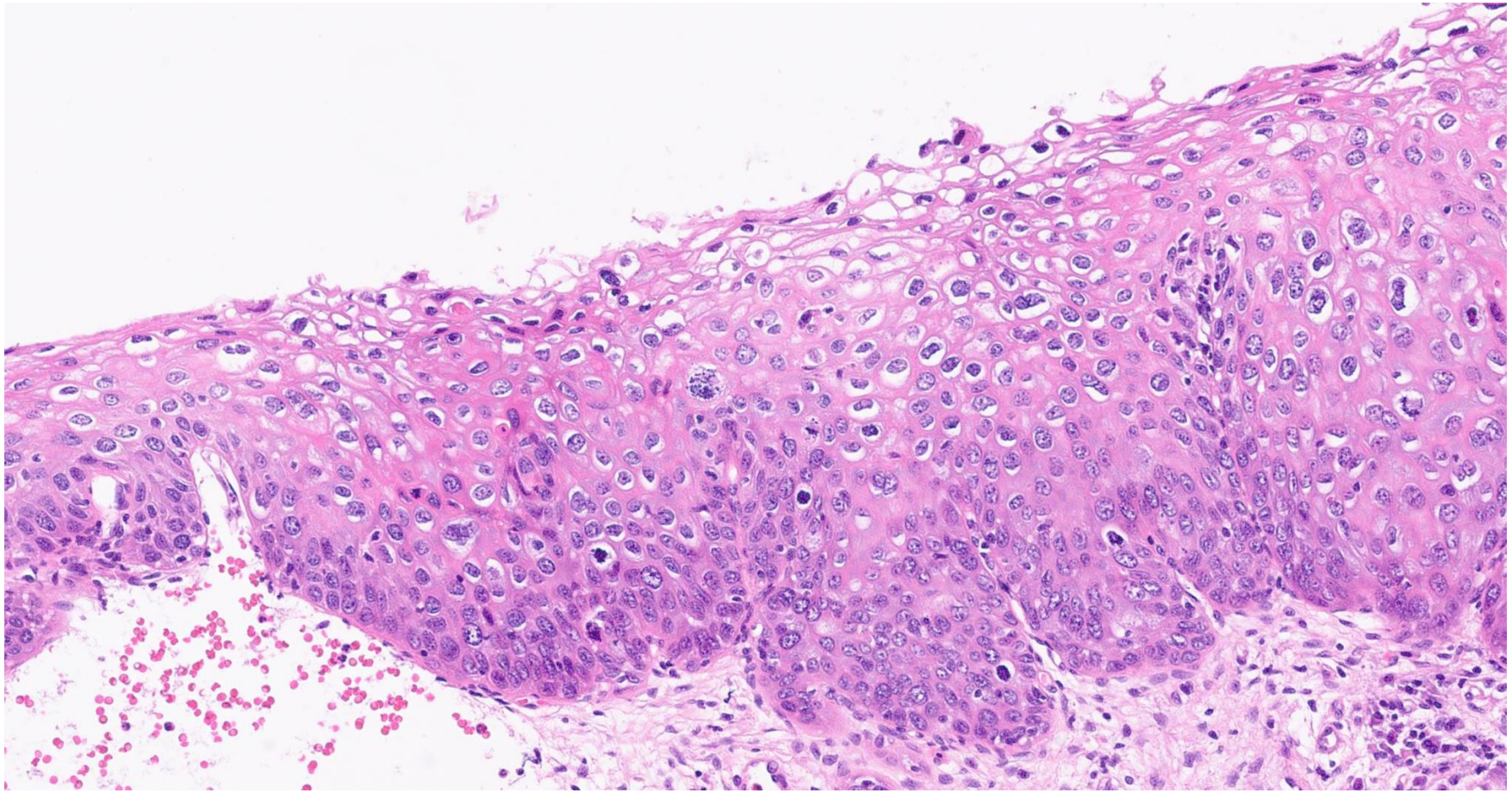

P16 immunohistochemistry – negative/normal

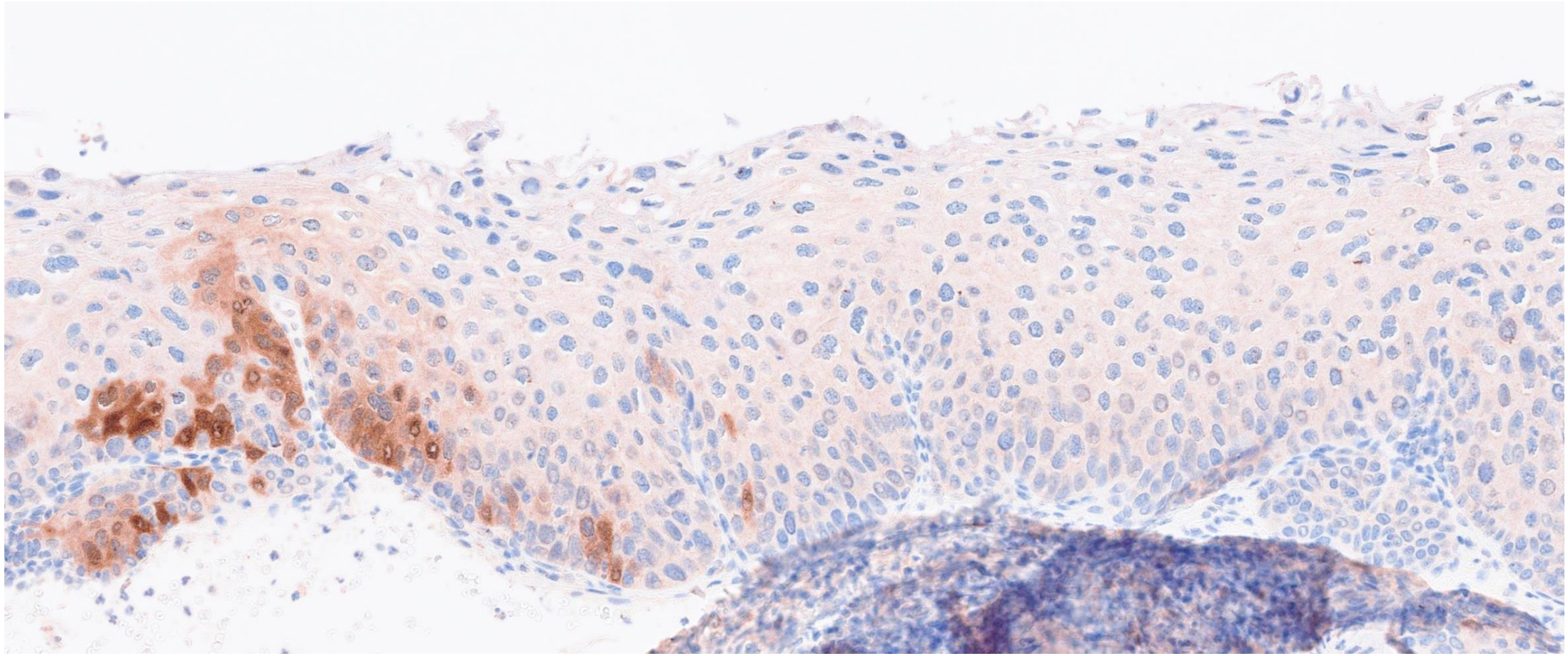

Diagnosis: CIN1 with florid koilocytosis, p16 normal/negative.

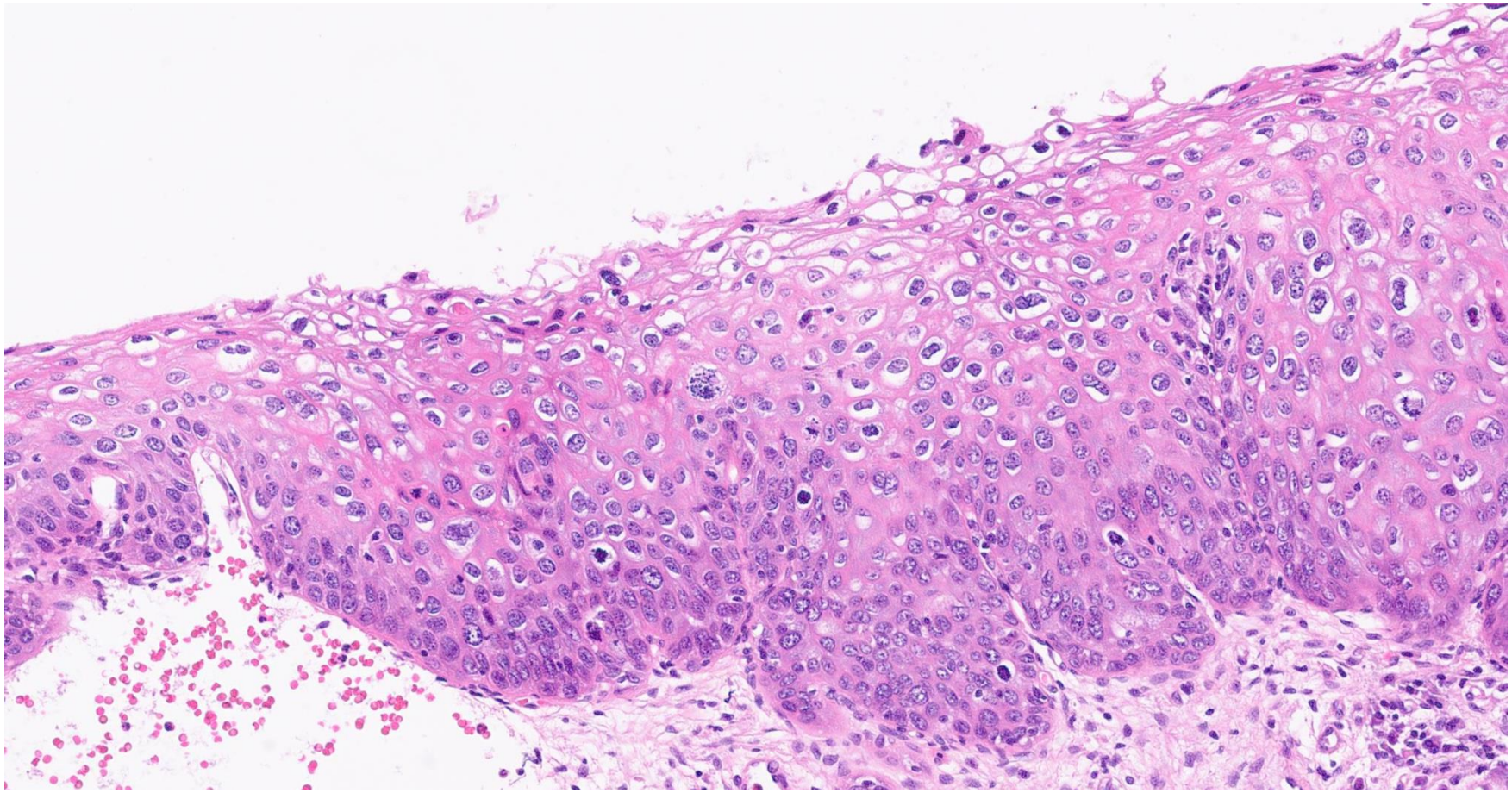

Utility of p16 in equivocal CIN1/?CIN2 lesions

- If pathologists is considering a diagnosis of CIN2 in an equivocal lesion

  p16 immunohistochemistry is useful and recommended to refine diagnosis in combination with H&E morphology.

- Negative p16 immunohistochemistry favours CIN1/LSIL

Poll questions

- Answers

Poll Q1&2. CIN2, p16 not useful for grading

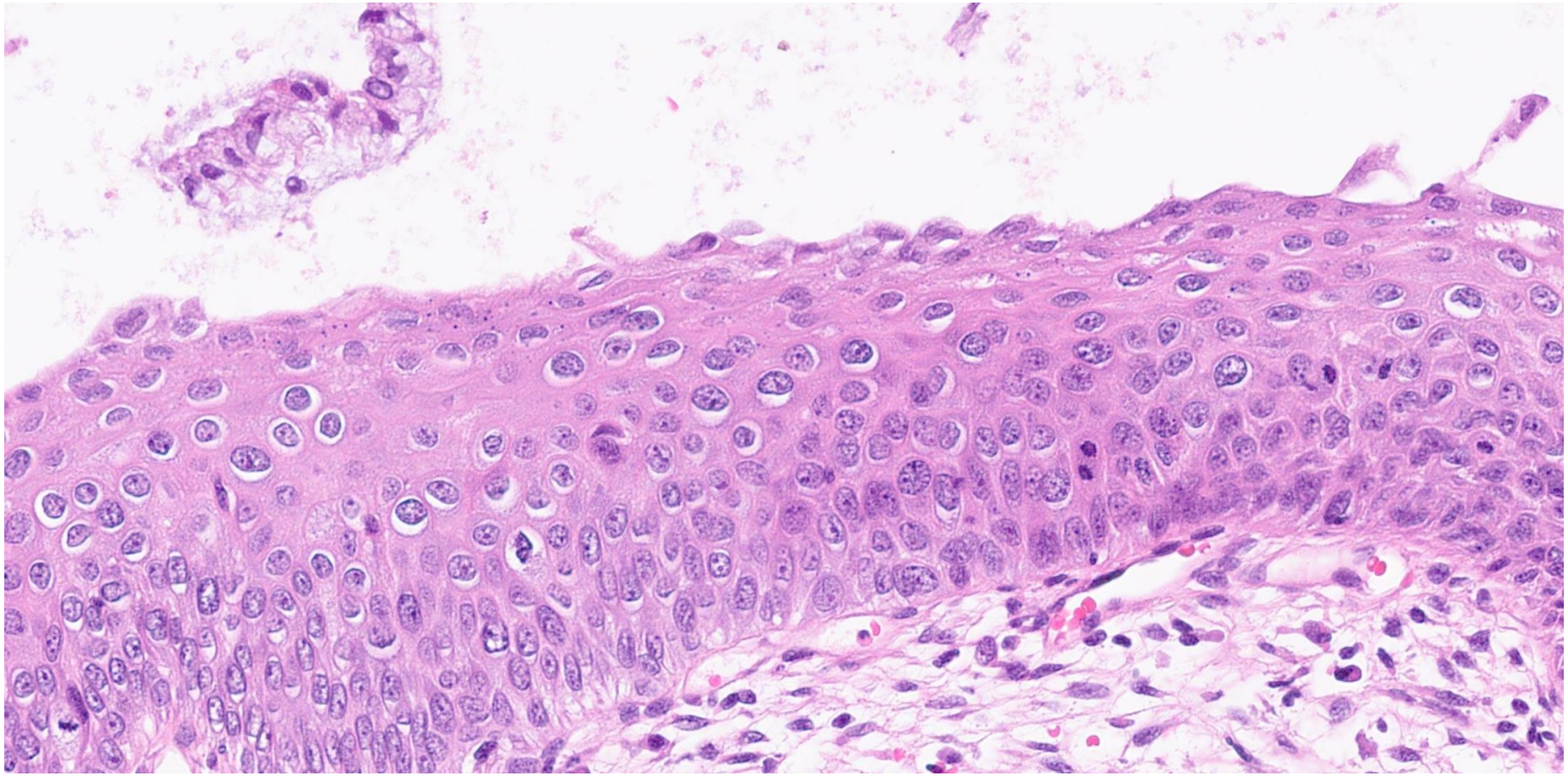

Poll Q3&4. CIN1 with florid koilocytosis, p16 block positive. H&E morphology consistent with CIN1

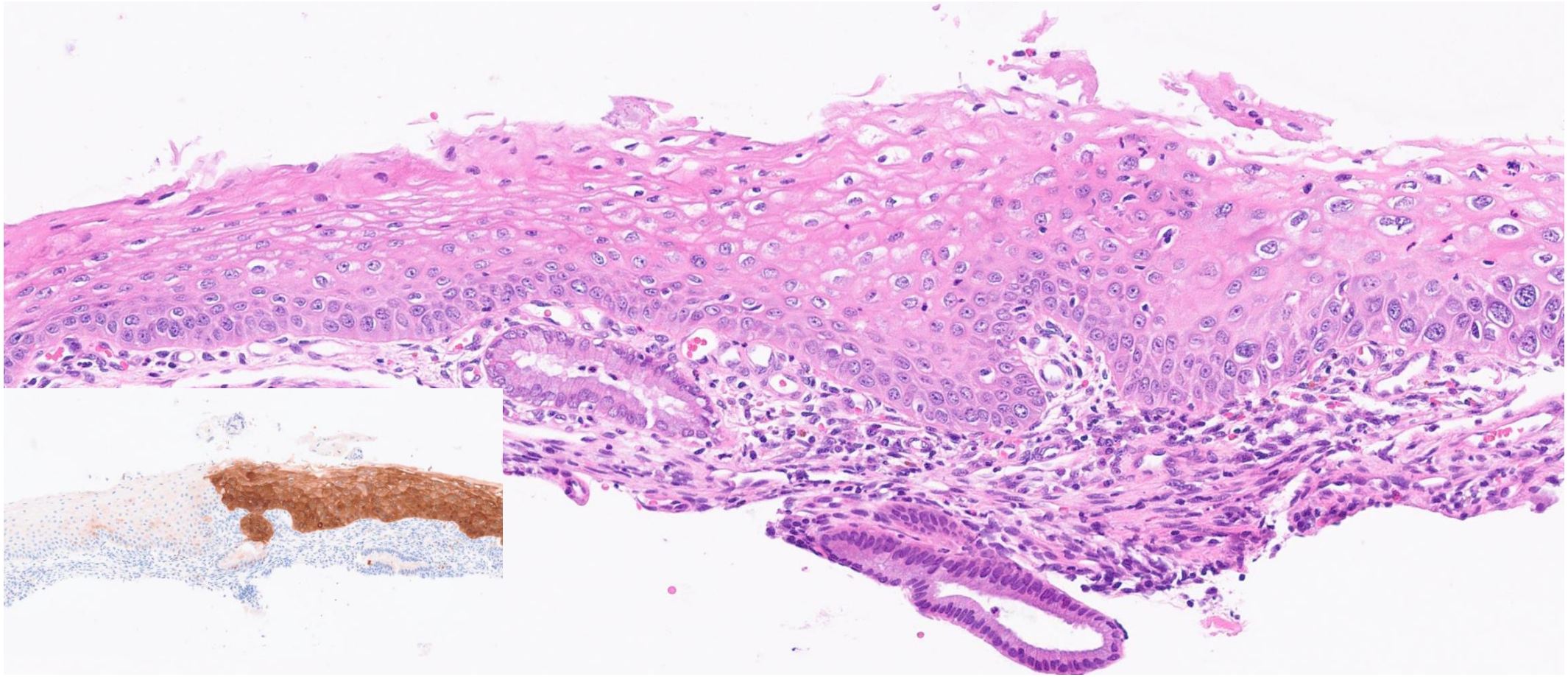

Take home message

- Negative p16 immunohistochemistry (IHC) is useful in excluding high grade squamous intraepithelial lesion
- P16 is over expressed in up to 50% of CIN1 (LSIL)
- Grading of CIN is based on morphology not p16 stain
- No need for p16 IHC if obvious negative, CIN1 or CIN3

Fragmented biopsies. P16 block positive in fragmented tissue

Intact TZ biopsy + fragments of HSIL

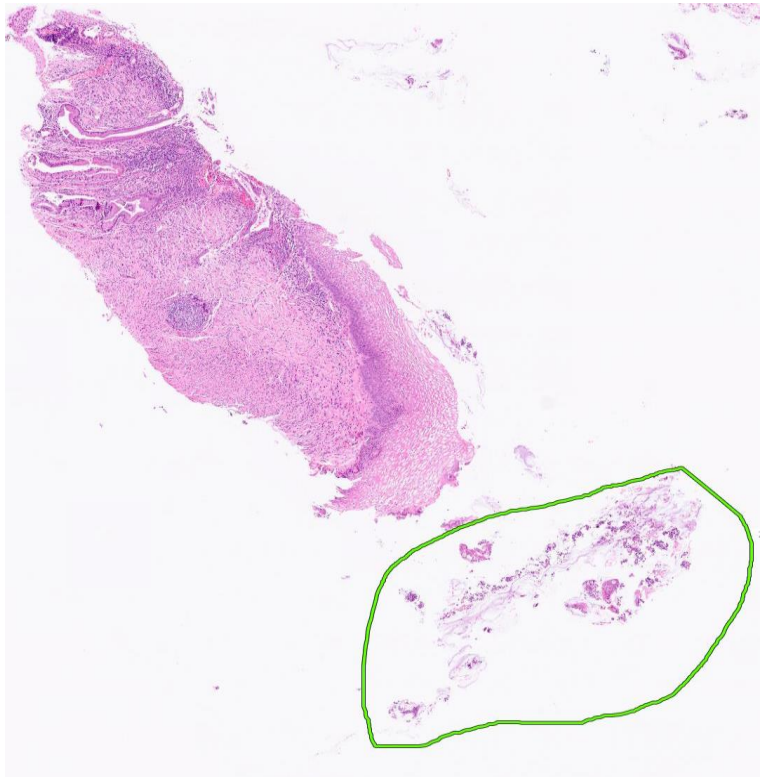

Fragments of HSIL

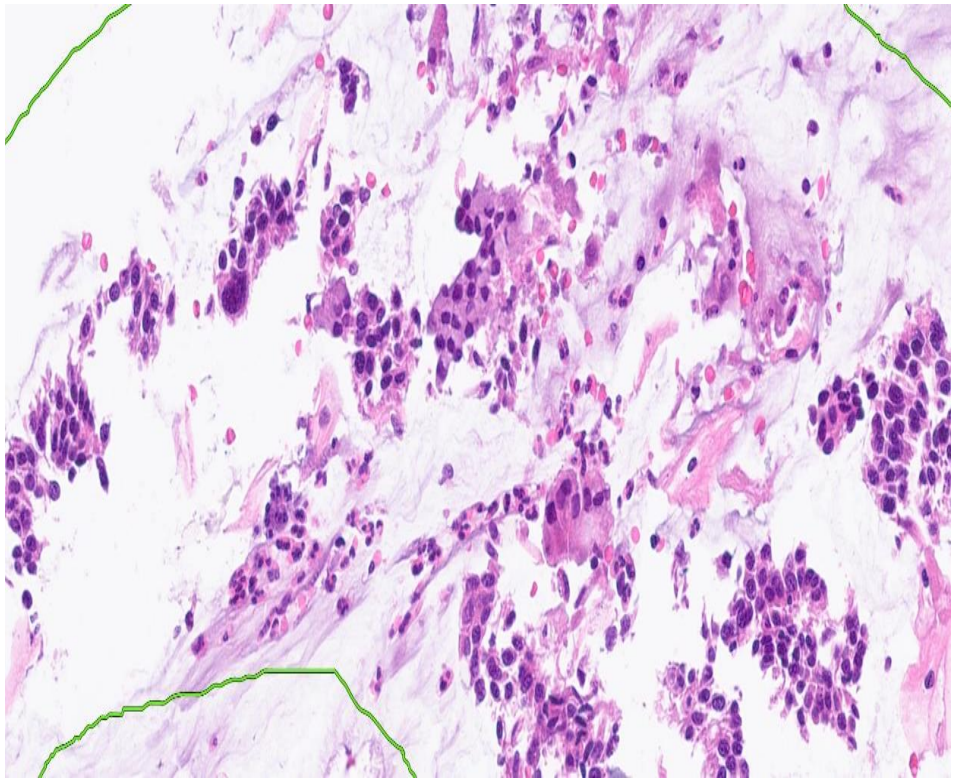

Difficult areas in reporting squamous intraepithelial neoplasia

- Florid koilocytosis v. CIN1
- CIN1 v. CIN2
- CIN2 v. CIN3
- CIN in thin epithelium (<10 cells thick)
- Negative p16 useful to exclude a high grade lesion with appropriate morphology (negative p16 can occur due technical reasons or inactivation of p16 gene)
- MDT discussion is advised for select difficult cases to guide management

Mimics of squamous intraepithelial lesion

- Immature squamous metaplasia
- Reactive/reparative epithelial changes
- Decidua
- Radiation effect
- Inflammation

Mimics of squamous intraepithelial lesion

- Transitional metaplasia
- Atrophy

p16 negative/normal

Mimics of squamous intraepithelial lesion

- Glandular lesions e.g. SMILE

34 year old, cytology severe dyskaryosis. Histology - CIN3 + SMILE

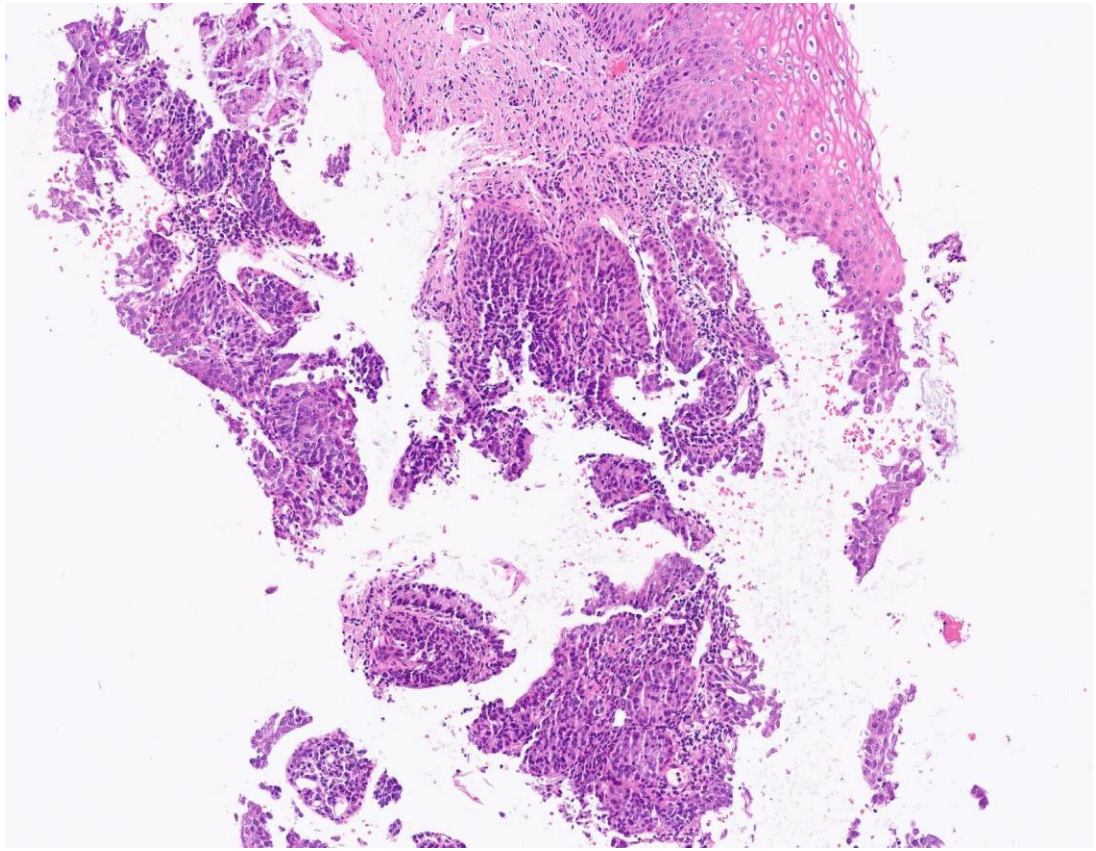

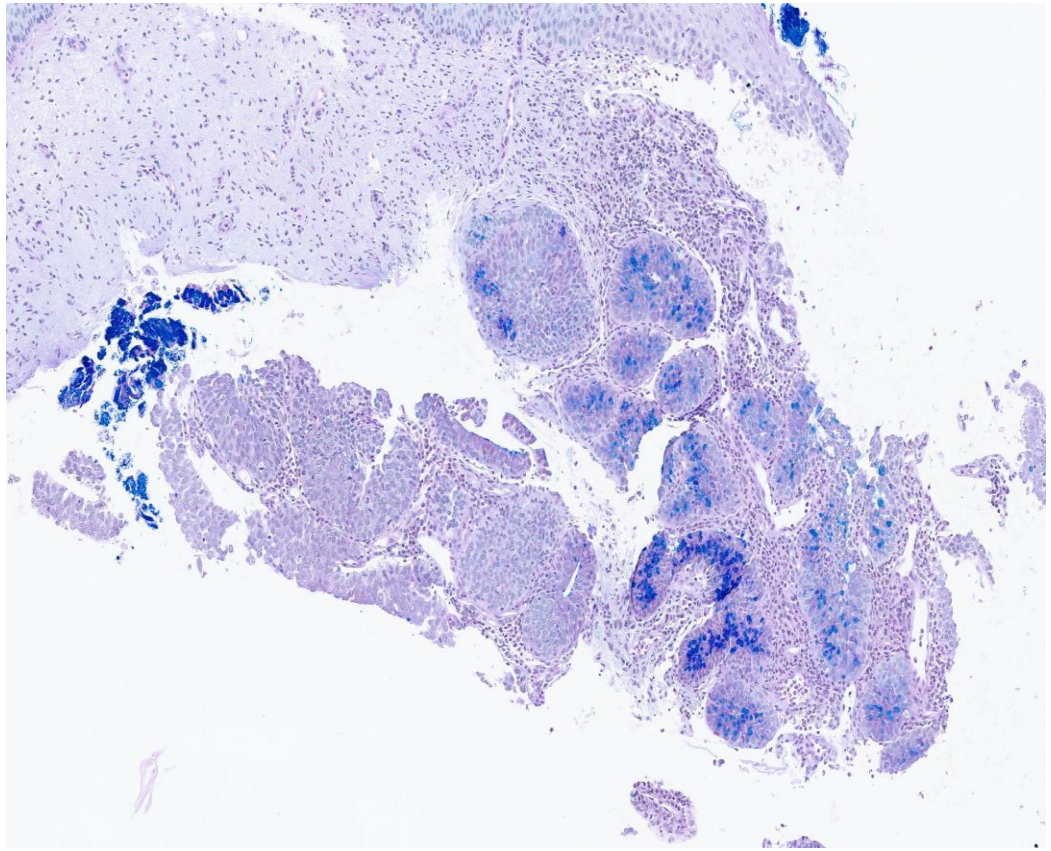

CIN3 + SMILE p16 block positive

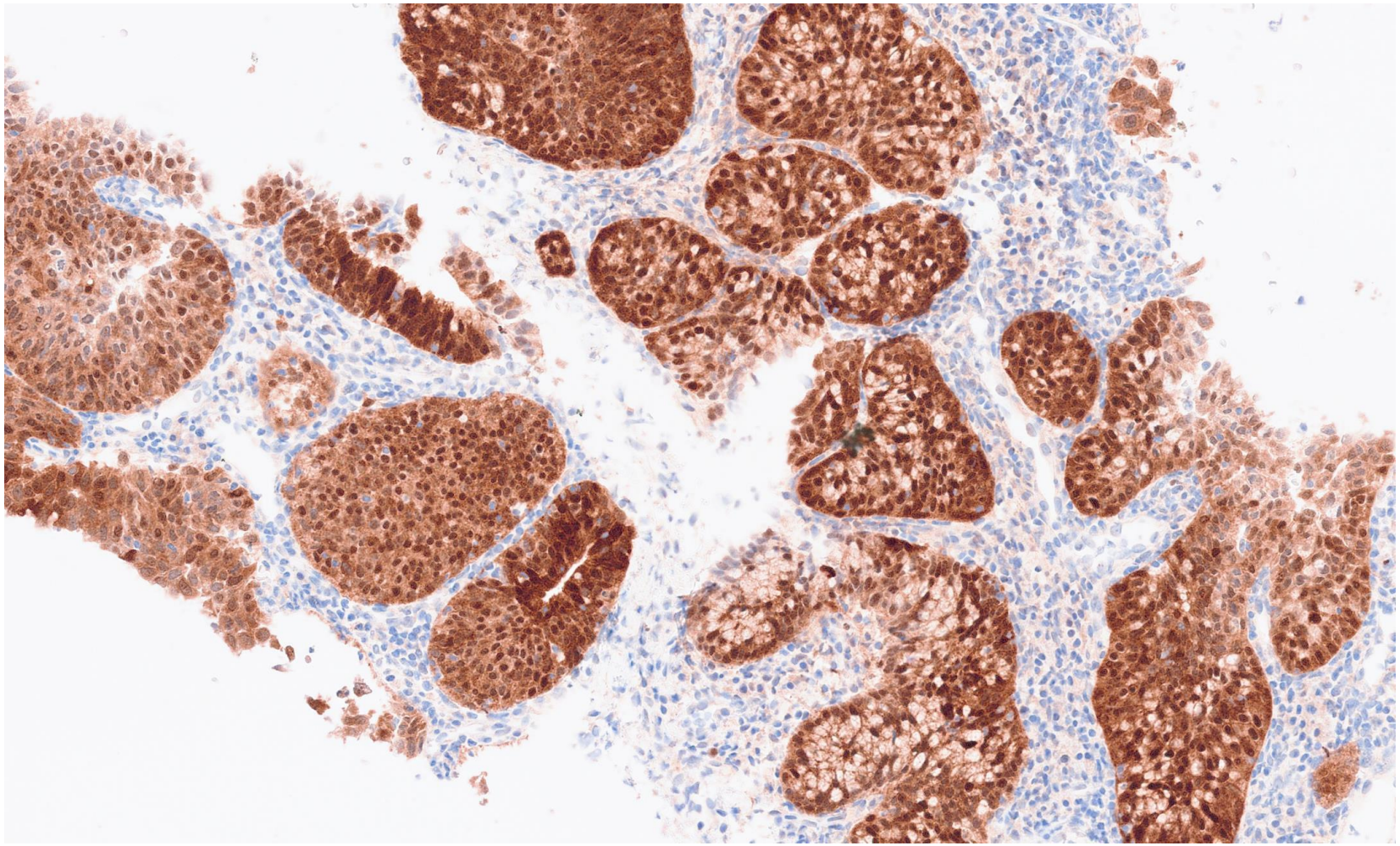

Histology of squamous metaplasia

- Uniform nuclei with fine chromatin
- Columnar cells may be seen on surface
- No nuclear contour irregularities
- No abnormal mitoses
- Nuclear enlargement and increased nuclear:cytoplasmic ratio present
- No nuclear hyperchromasia
- No loss of polarity or organization.

- <u>No p16 overexpression</u>

Squamous metaplasia (p16 normal/negative)

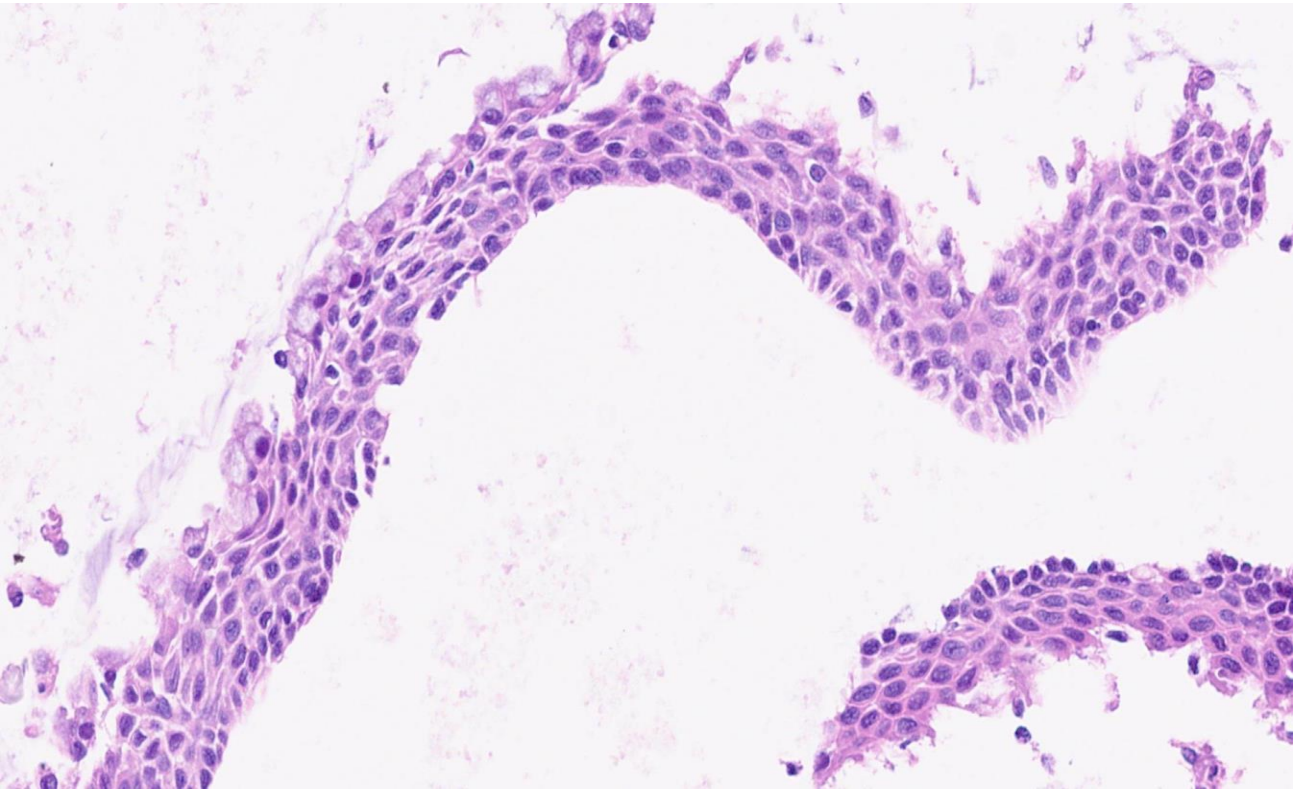

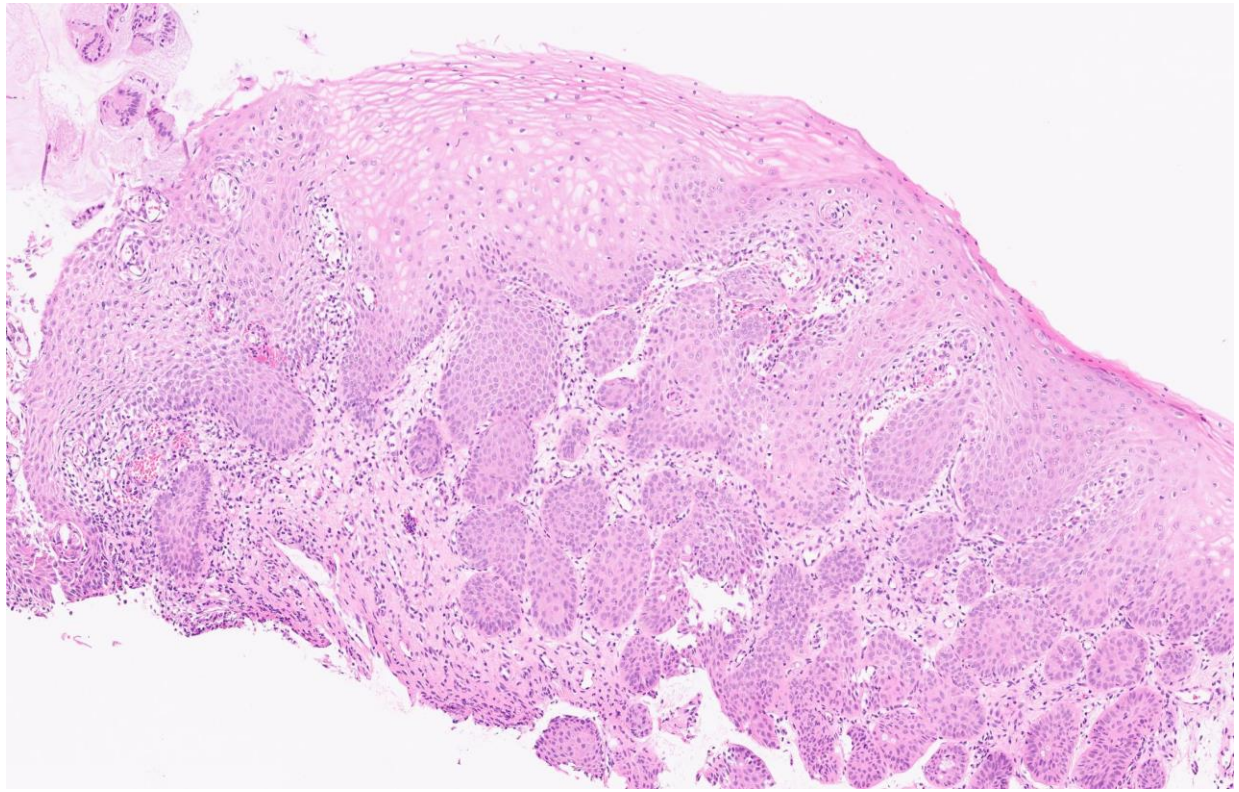

Squamous metaplasia v. HSIL in metaplastic squamous epithelium

Immature metaplasia (p16 negative)

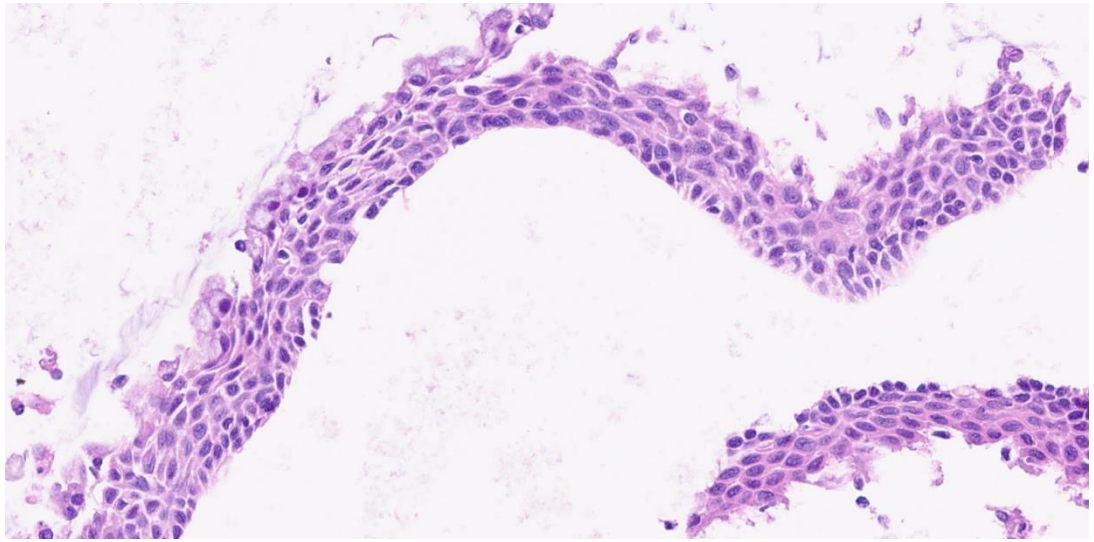

HSIL in metaplastic squamous epithelium (p16 block positive)

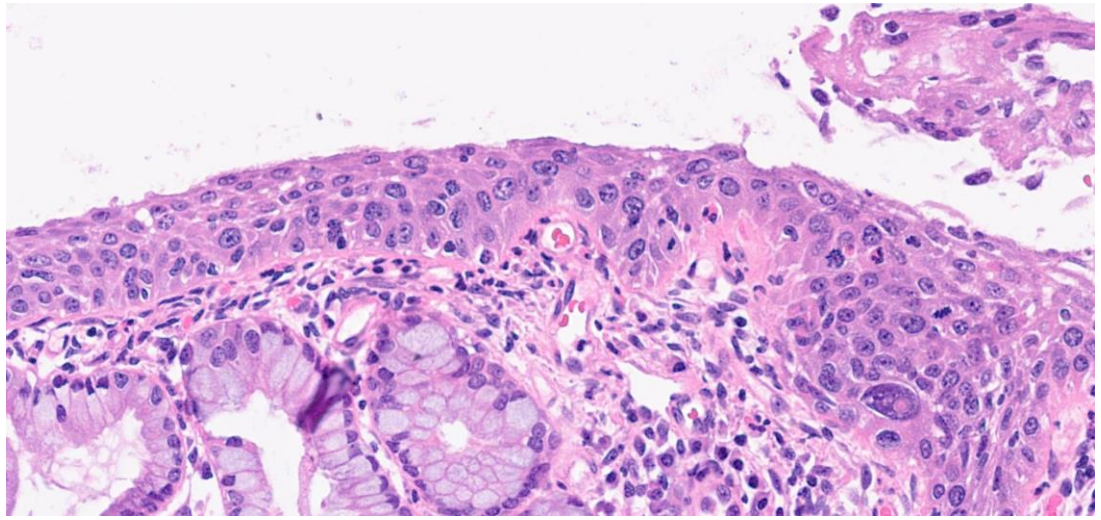

Atrophy

- Epithelium is thin and consists of parabasal cell
- Minor variation in cell size and orientation
- Mitoses absent
- No maturation to superficial cells
- Can be inflamed

- P16 negative + low Ki-67 proliferation index

Transitional metaplasia

- Post menopausal
- Vertical orientation of cells in lower layers
- Horizontal orientation in upper layers
- Perinuclear halos
- Uniform nuclear contours and nuclear grooves

P16 negative

Inflammation, koilocytosis and candida

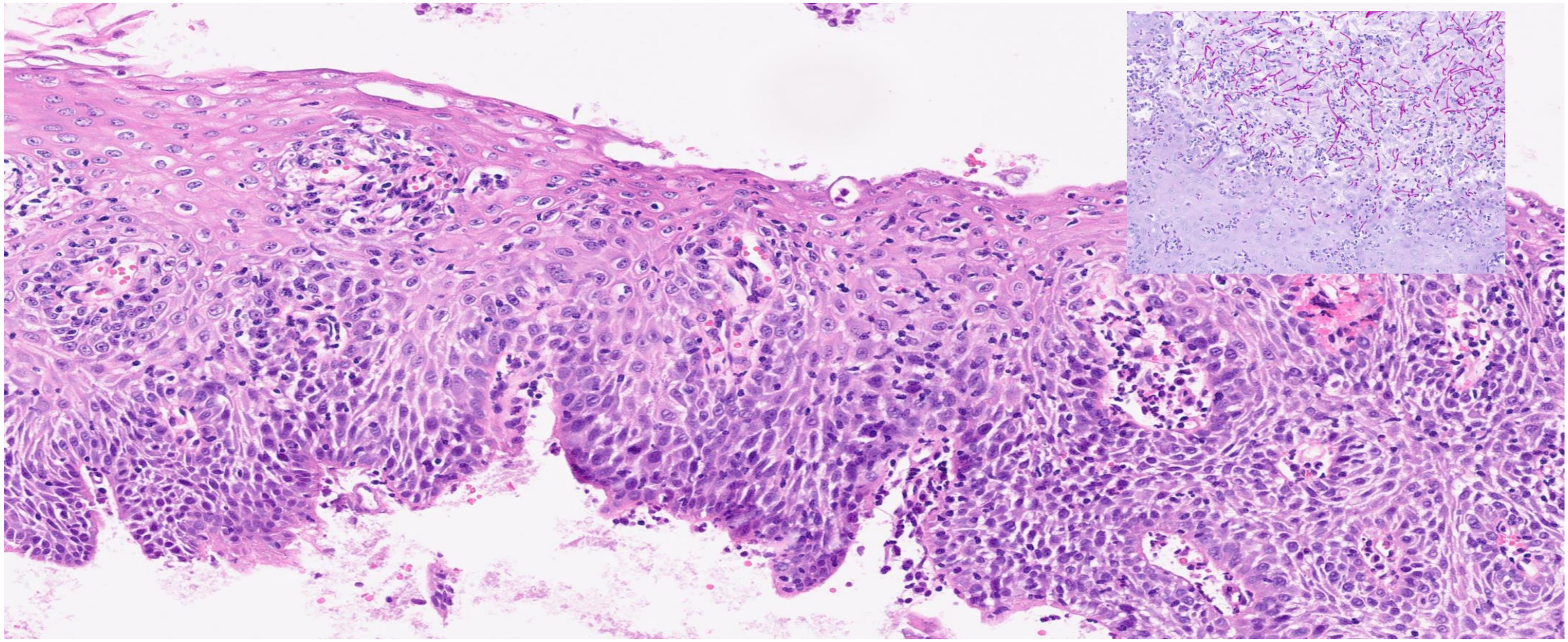

Inflammation, p16 negative

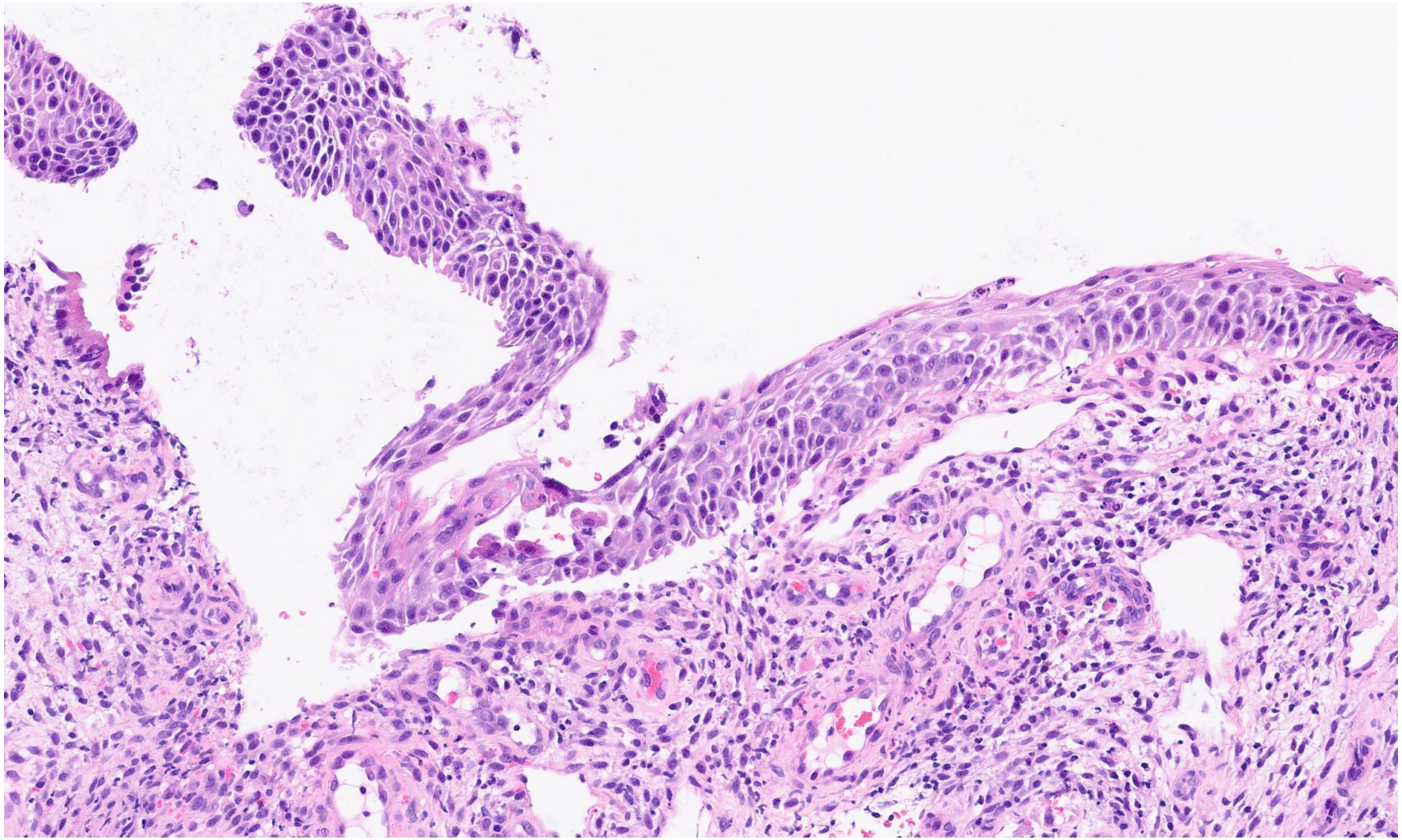

Histology reporting issues (NHS CSP)

- Biopsy size for adequate sample (at least 2mm)
- Limitations – fragmentation, inflammation ,crosscut, loss of epithelium, distortion
- Presence or absence of transformation zone
- If Colposcopic directed biopsy – absence of TZ implies biopsy may not be representative but is not inadequate
- Biopsy <2mm with abnormality - not inadequate
- Biopsy <2mm, no abnormality /TZ - inadequate

Histology reporting issues (NHS CSP)

- Cytology squamous abnormality, biopsy no squamous epithelium = inadequate biopsy

- Cytology glandular abnormality, biopsy no glandular epithelium = inadequate biopsy

Summary

- Cervical intraepithelial neoplasia grading is based on H&E morphology
- Biomarkers (p16) can assist to refine morphological diagnosis
- Representative biopsies from the cervical transformation enable accurate diagnosis
- Examination of additional levels in select cases can be useful
- MDT discussion of difficult cases is advised
- Scope for AI to aid diagnosis in future

Thank you

Questions?