THE BRITISH ASSOCIATION of GYNECOLOGICAL PATHOLOGISTS
17th ANNUAL MEETING, JUNE 10-11, 2021

RECENTLY DESCRIBED UTERINE MESENCHYMAL TUMORS

Esther Oliva
Massachusetts General Hospital/Harvard Medical School
eoliva@mgh.harvard.edu

OUTLINE

- **Tumors with epithelioid morphology**
  - **PEComa**
  - **SMARCA-4 deficient uterine sarcoma**

- **Tumors with spindled morphology +/- myxoid background**
  - **Inflammatory myofibroblastic tumor**
  - **BCOR-High-Grade Endometrial Stromal Sarcoma**
  - **Sarcomas Resembling Fibrosarcoma (NTRK/COL1A1-PDGFB/other)**
  - **Solitary Fibrous Tumor**

PERIVASCULAR EPITHELIOID CELL TUMOR (PEComa)

- Mesenchymal tumor composed of perivascular epithelioid cells (PECs) that express melanocytic and smooth muscle markers
- Uterine corpus > cervix > vagina > ovary > broad ligament
- Wide age range and clinical presentation non-specific
- Most sporadic but ~10% associated with tuberous sclerosis
- Potential treatment with mTOR inhibitors

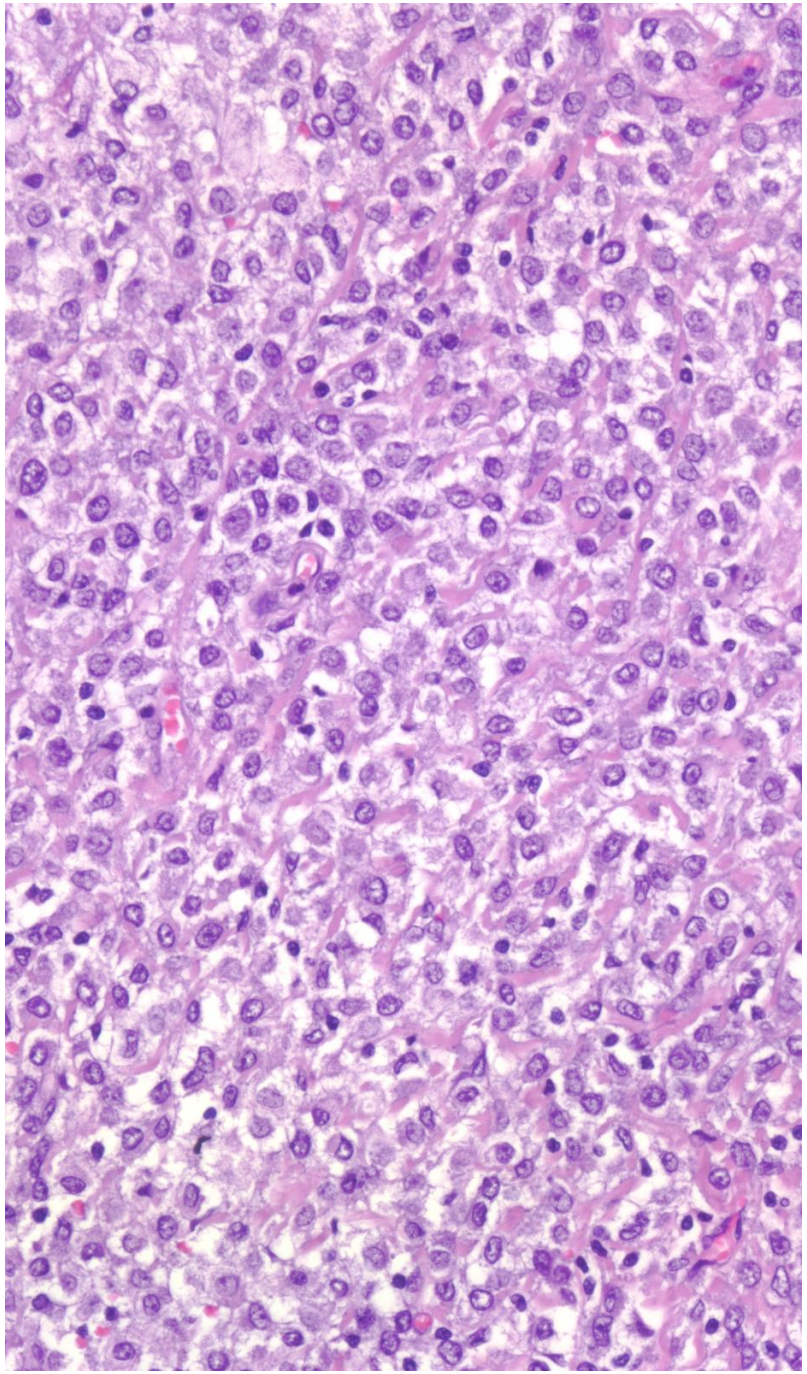
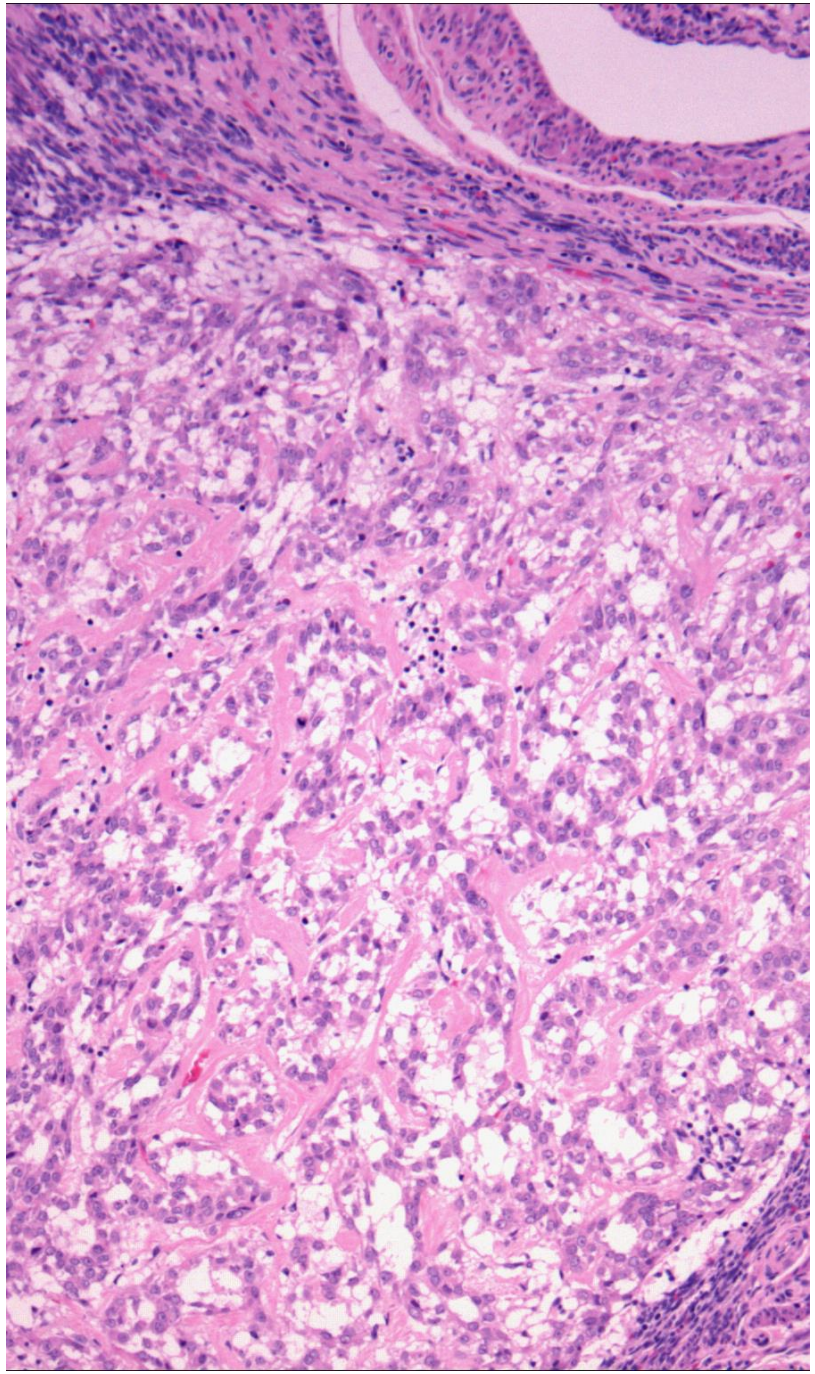
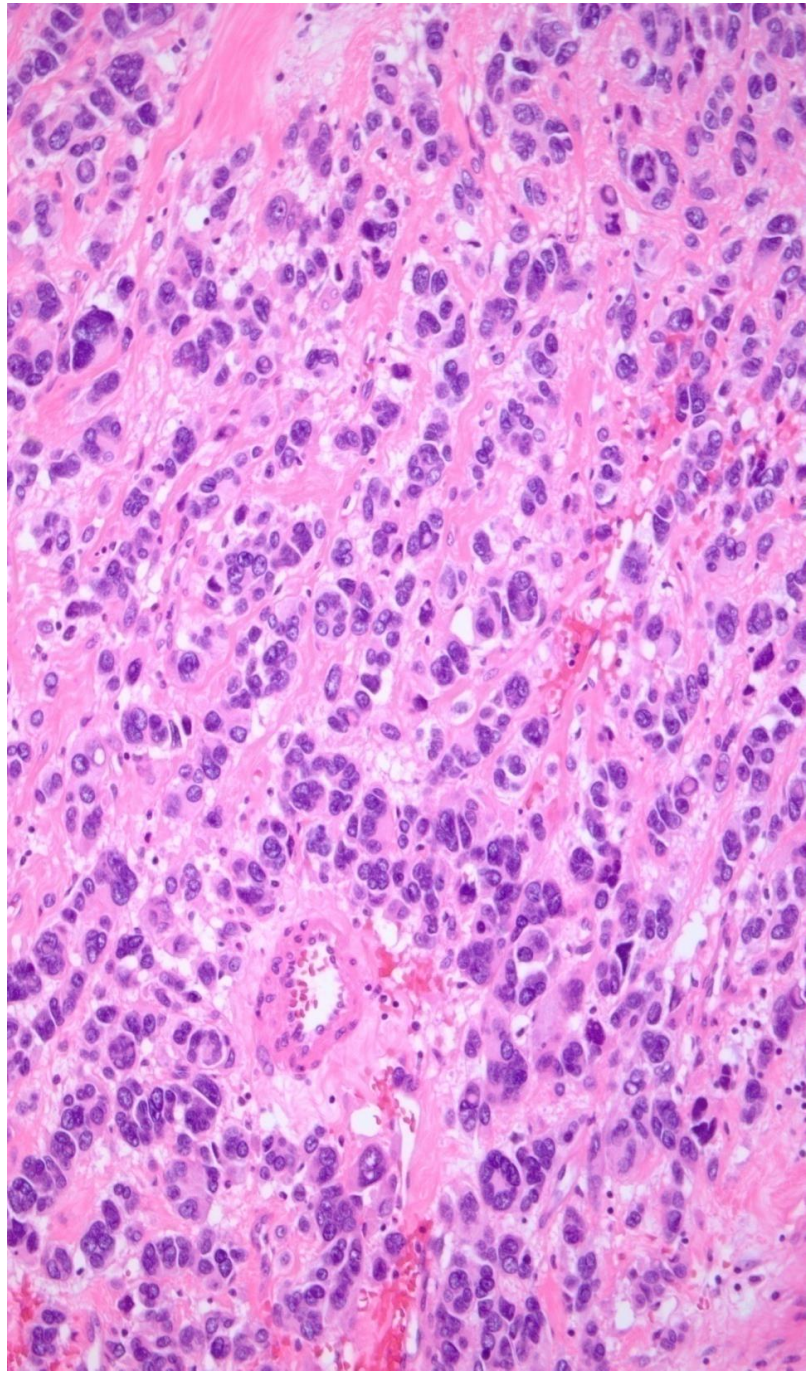

PECOMA

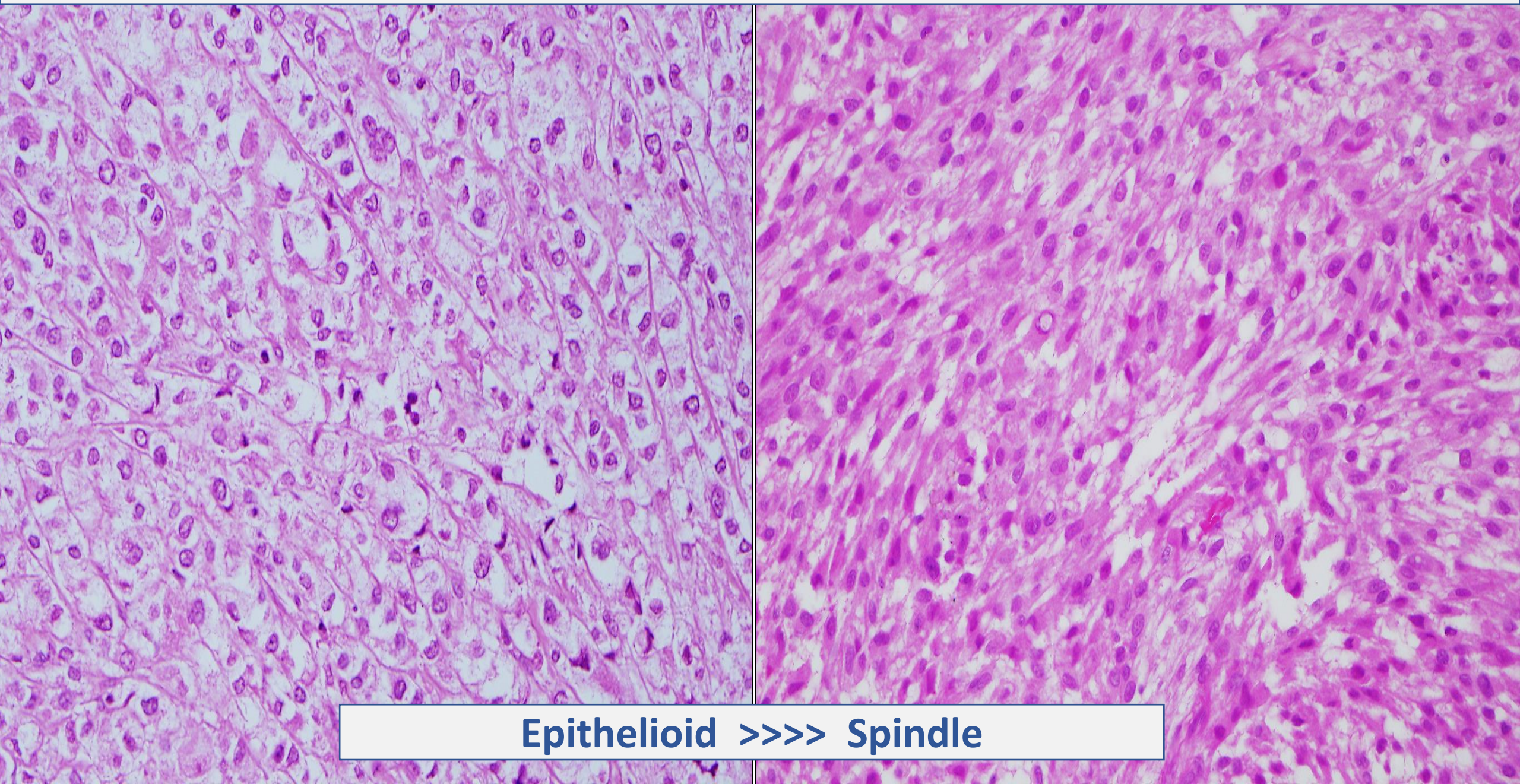

Epithelioid >>>> Spindle

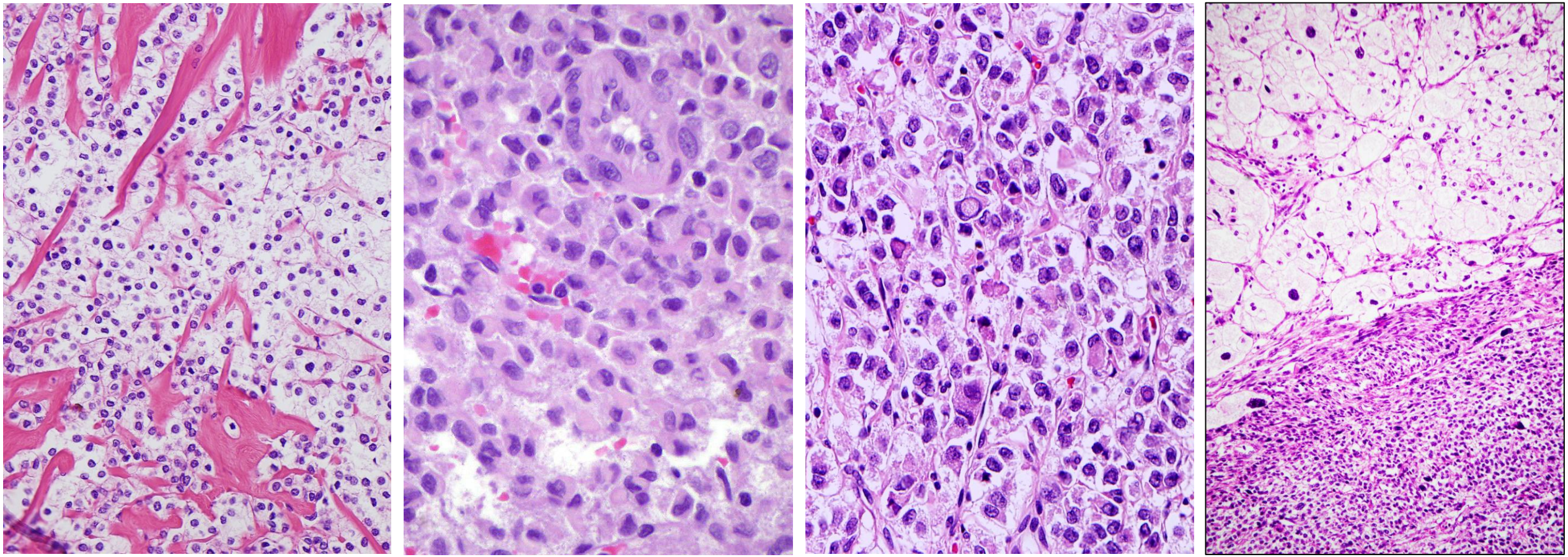

PEComa: CYTOLOGY

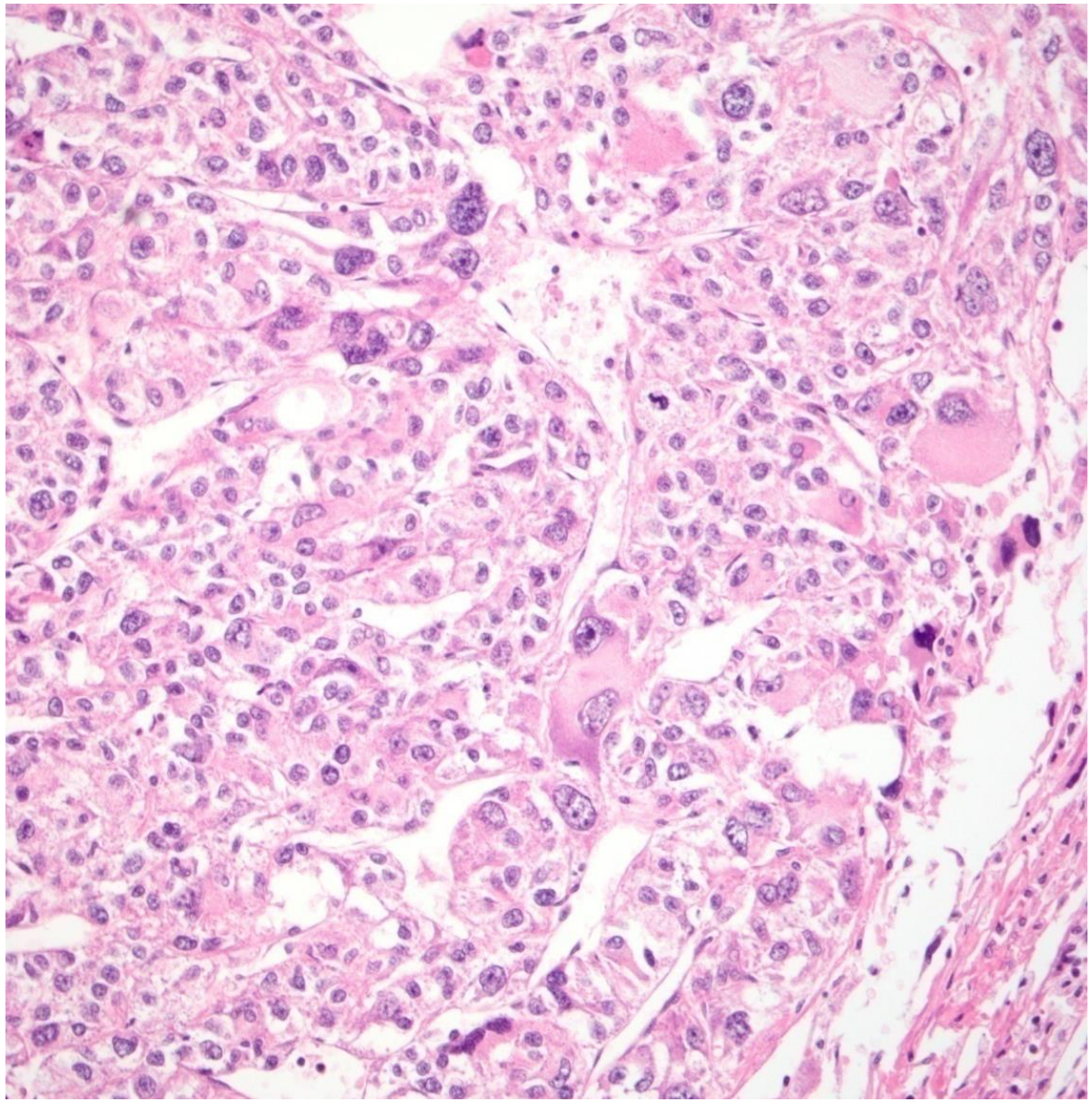

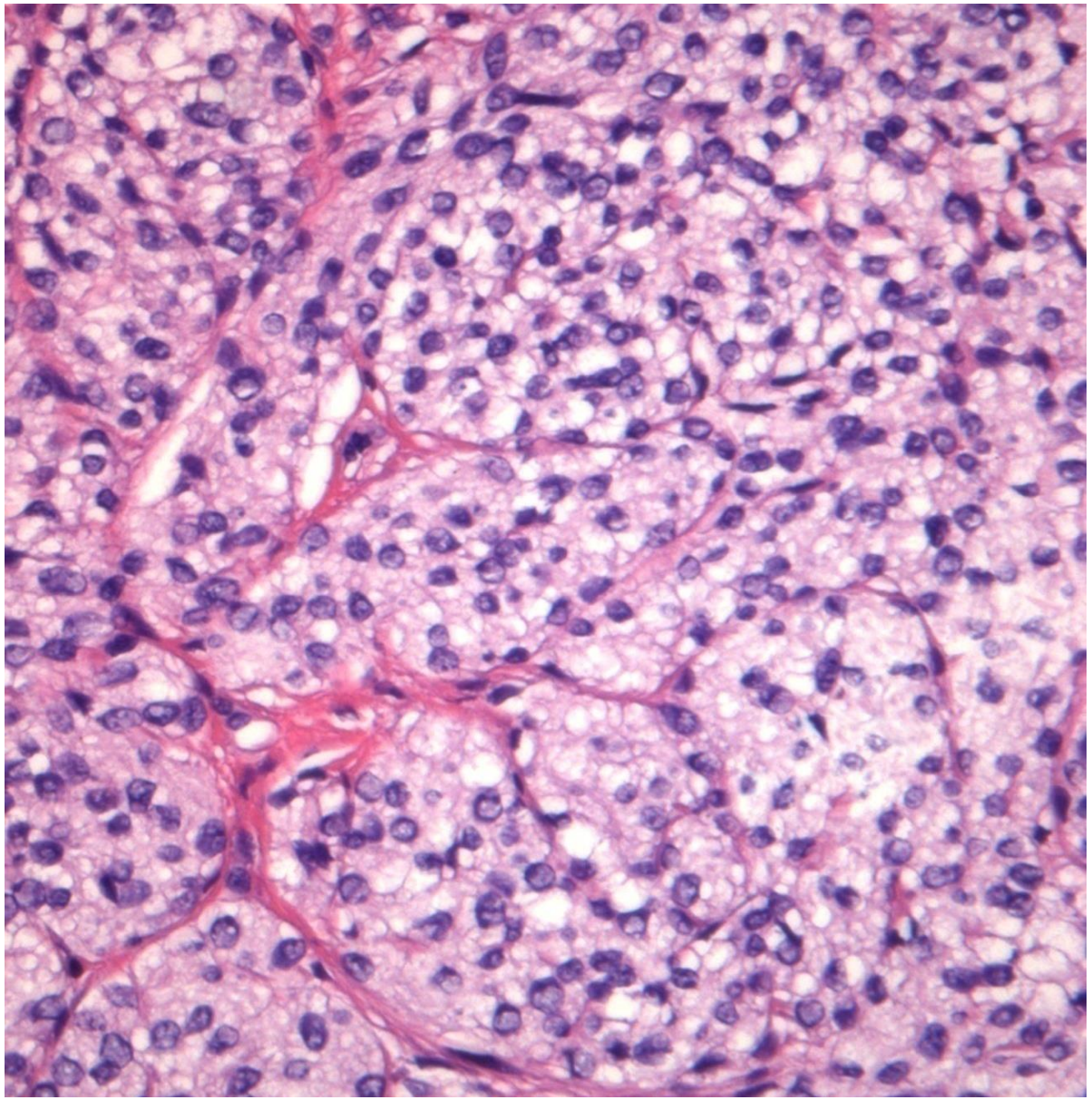

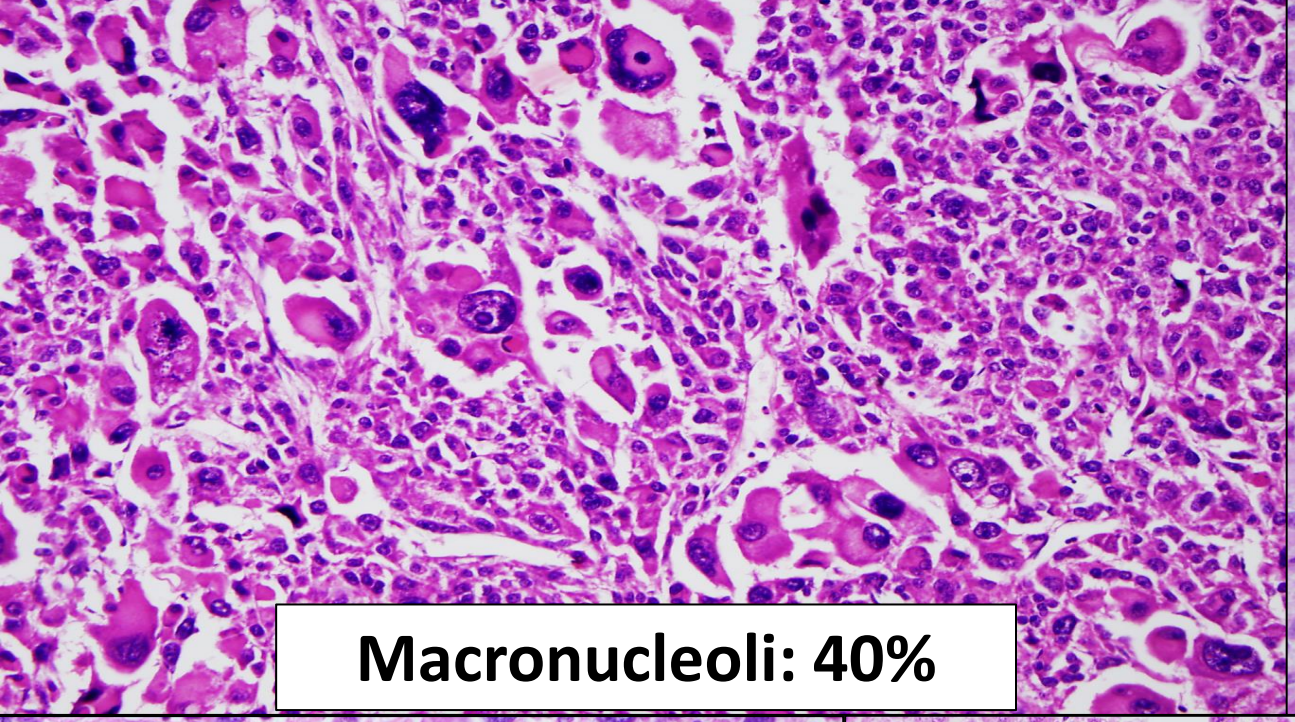
Macronucleoli: 40%

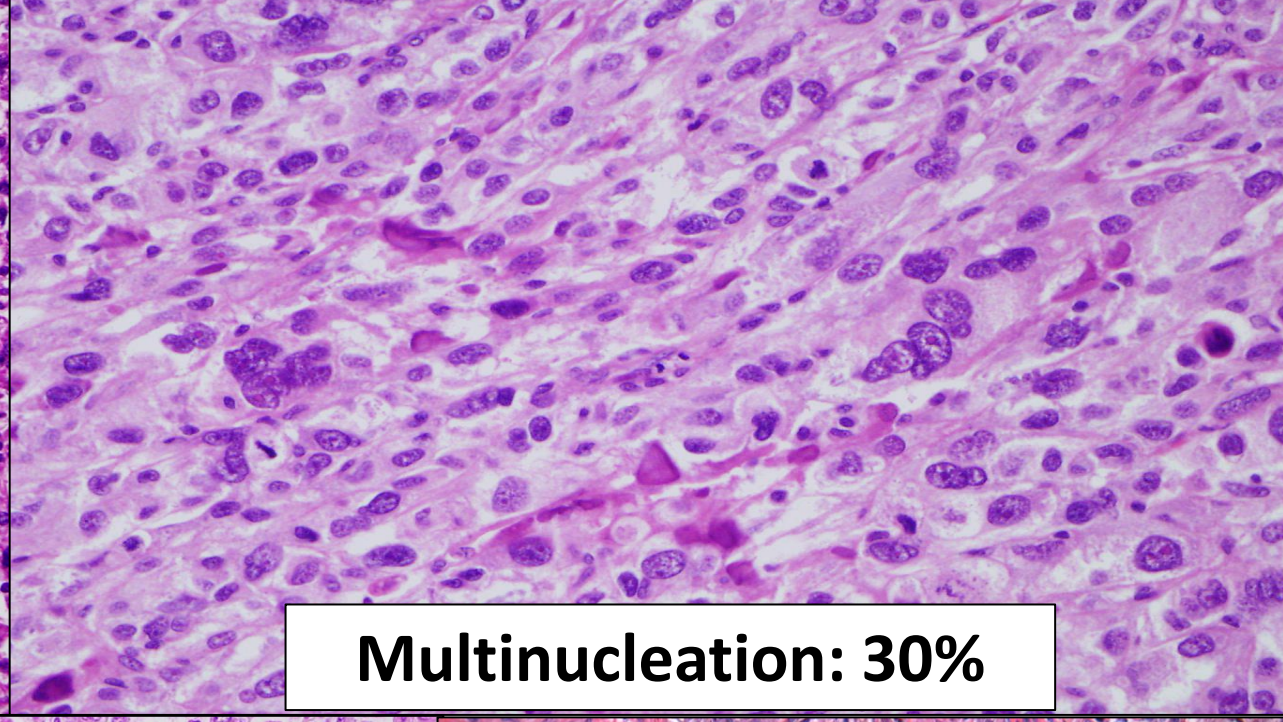
Multinucleation: 30%

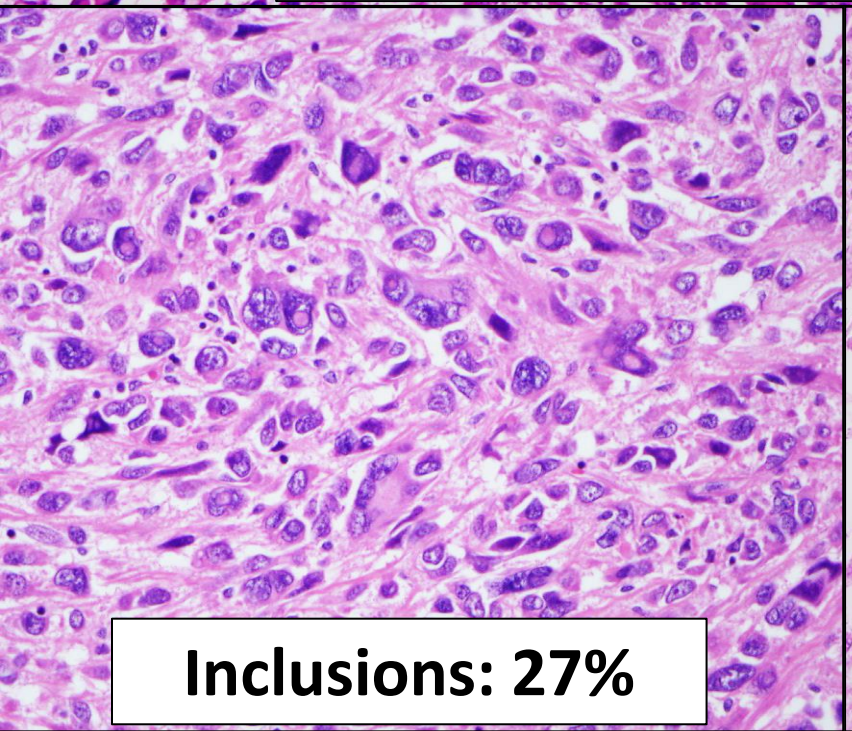
Inclusions: 27%

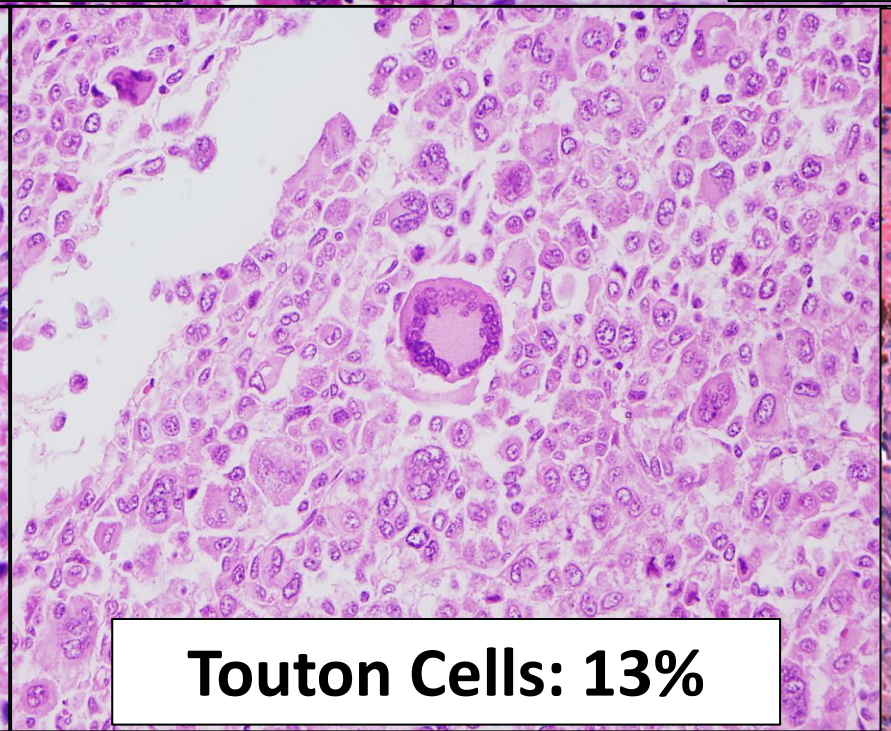
Touton Cells: 13%

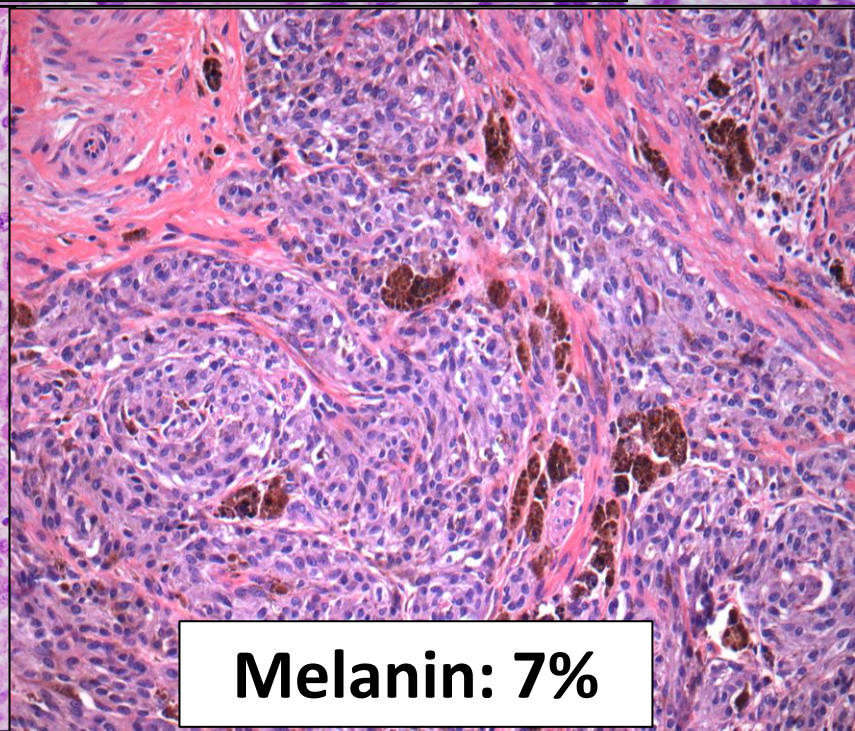
Melanin: 7%

IMMUNOHISTOCHEMISTRY

- HMB45: Expressed in 99% of PEComas; variable expression
- Melan-A: Often focal and less extensive than HMB45
- MiTF: Not very reliable marker and non-specific
- Smooth muscle markers: Always positive at least for one marker
    - Smooth muscle actin (~90%) > desmin > caldesmon
    - More often positive in spindle areas
- Cathepsin K: Often strongly and diffusely positive
- PNL2: Variable cytoplasmic positivity
- TFE3: Positive in only those with fusion
- ER/PR: May be positive
- AE1/3, s100, and CD10: Rarely positive
- PAX8: Negative

TSC Alterations are Common in PEComas

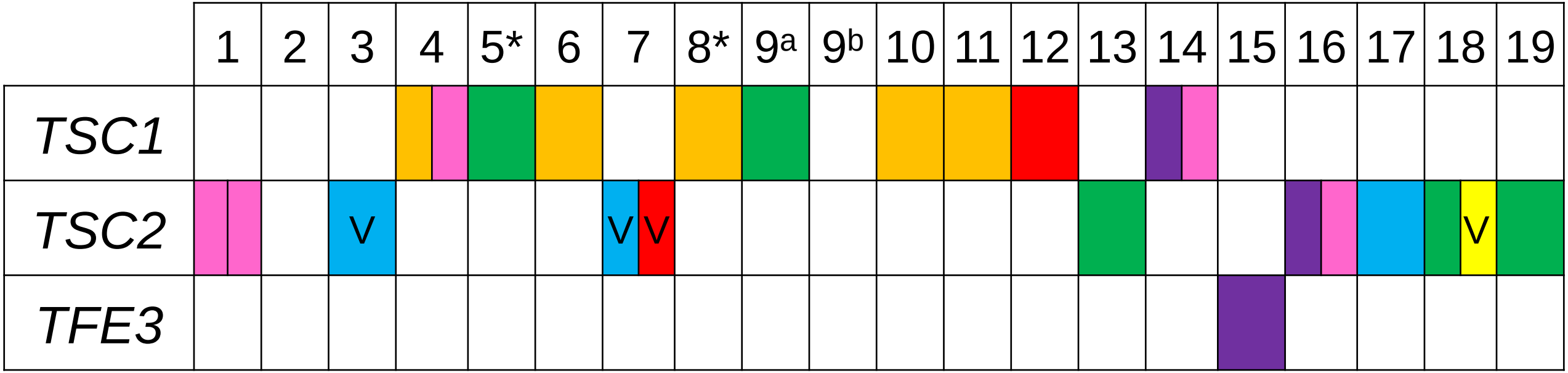

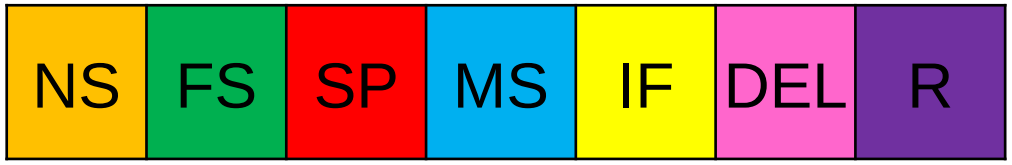

*=tuberous sclerosis, V=VUS

TSC1: 9/19 (47%)
TSC2: 8/19 (42%)

Bennett J et al, Modern Pathol 2021

PEComa with TFE3 fusions

NOT ASSOCIATED WITH *TSC* GENE MUTATIONS

Absent or minimal Melan-A and absent myogenic expression

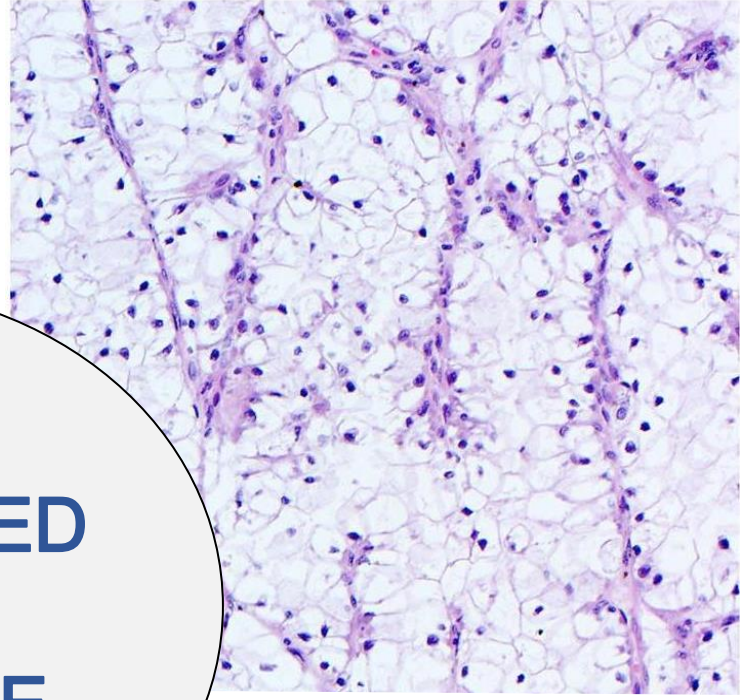

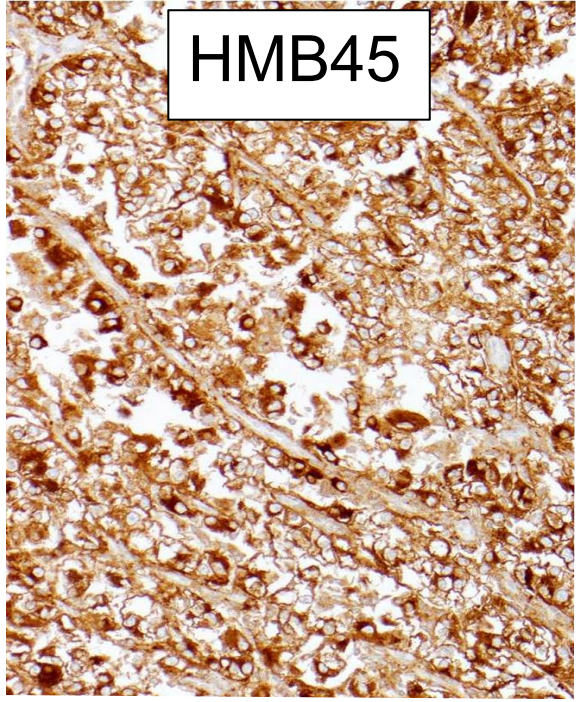

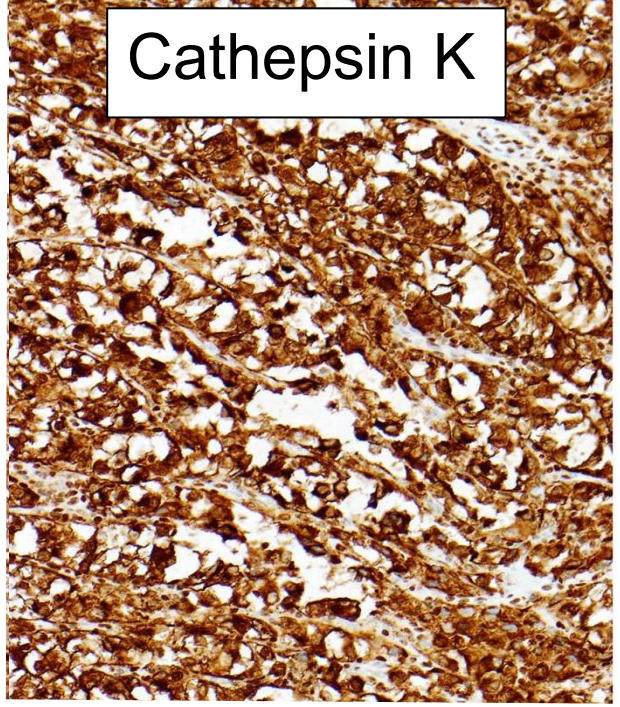

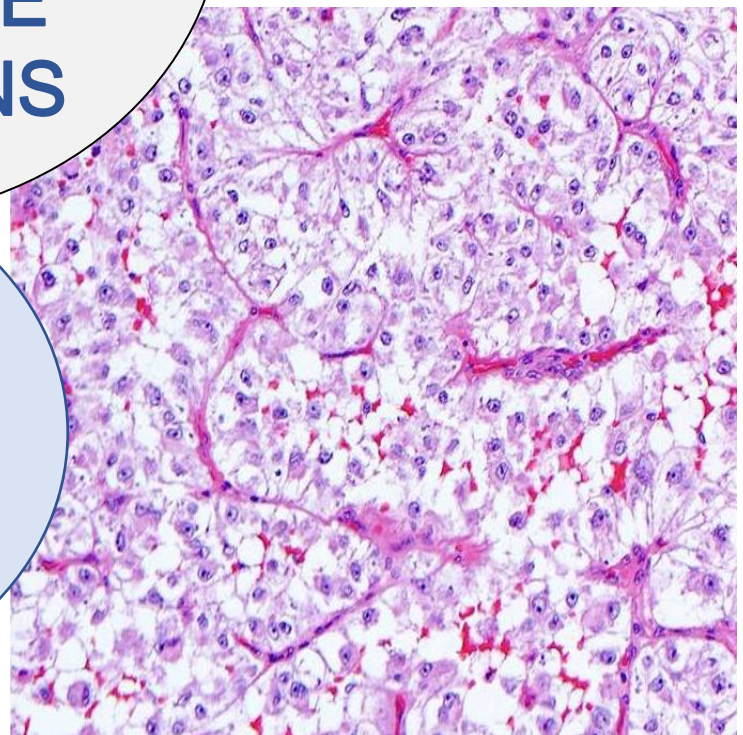

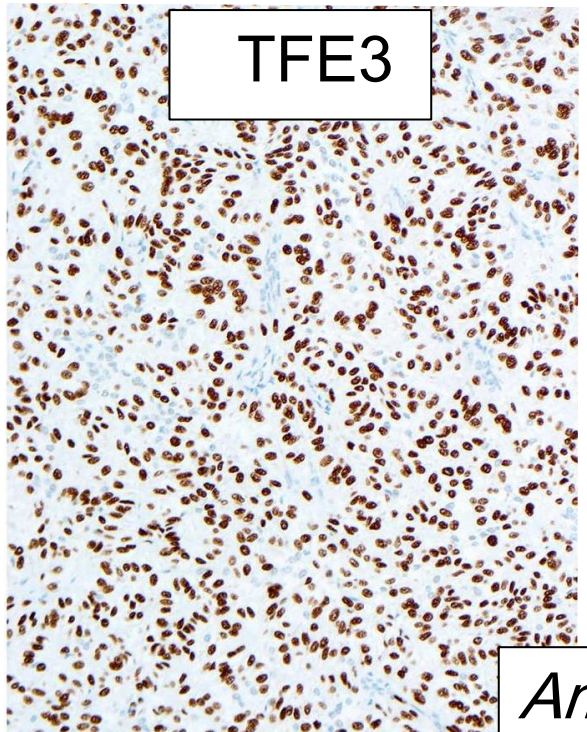

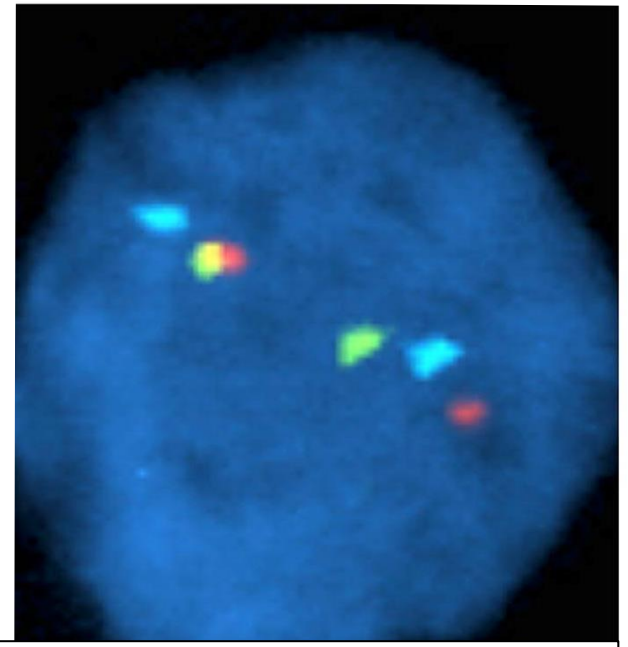

Am J Surg Pathol 2015

PEComa

Differential Diagnosis:

- Epithelioid smooth muscle tumor
- UTROSCT
- Epithelioid endometrial stromal sarcoma
- Intermediate-type trophoblastic tumors
- Melanoma
- Alveolar soft part sarcoma
- Secondary involvement by gastrointestinal stromal tumor
- Metastases

EPITHELIOID LEIOMYOSARCOMA (*PGR fusion* subset), with *t*(9,11)

Chiang S et al, Am J Surg Pathol 2019

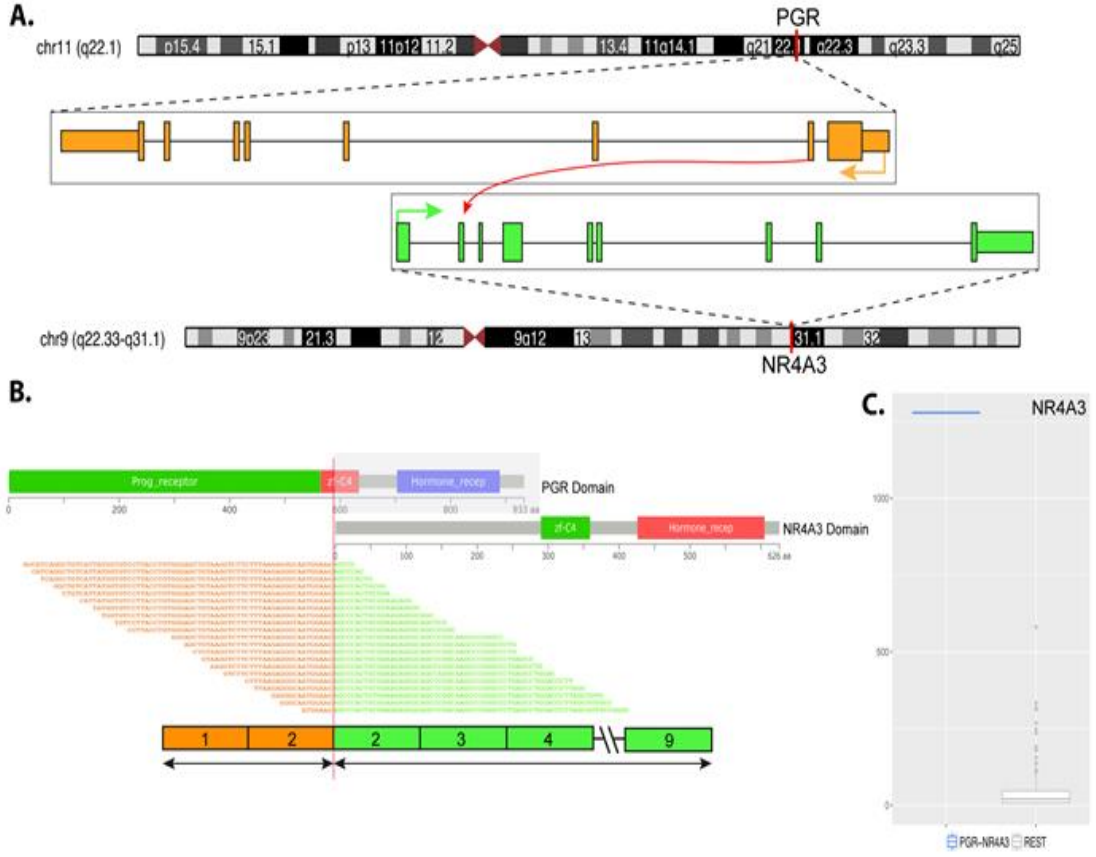

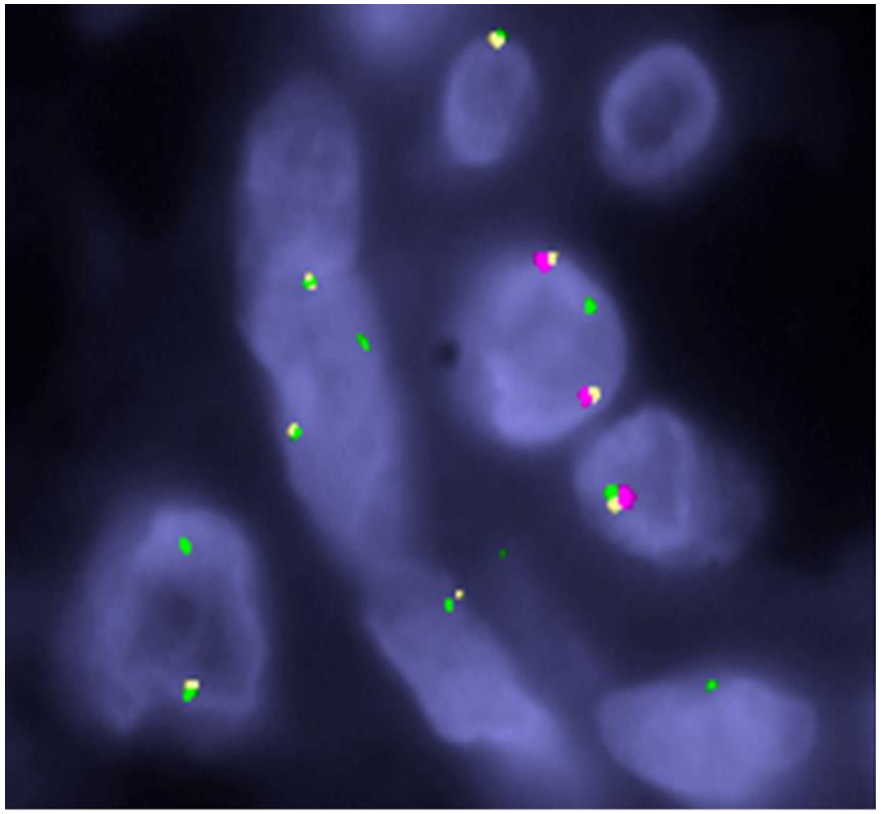

PGR-NR4A3 fusion ----projected fusion protein including the progesterone receptor domain of PGR

PGR mutations rare; seen in 2% of EC and 0.2% of high-grade serous carcinomas

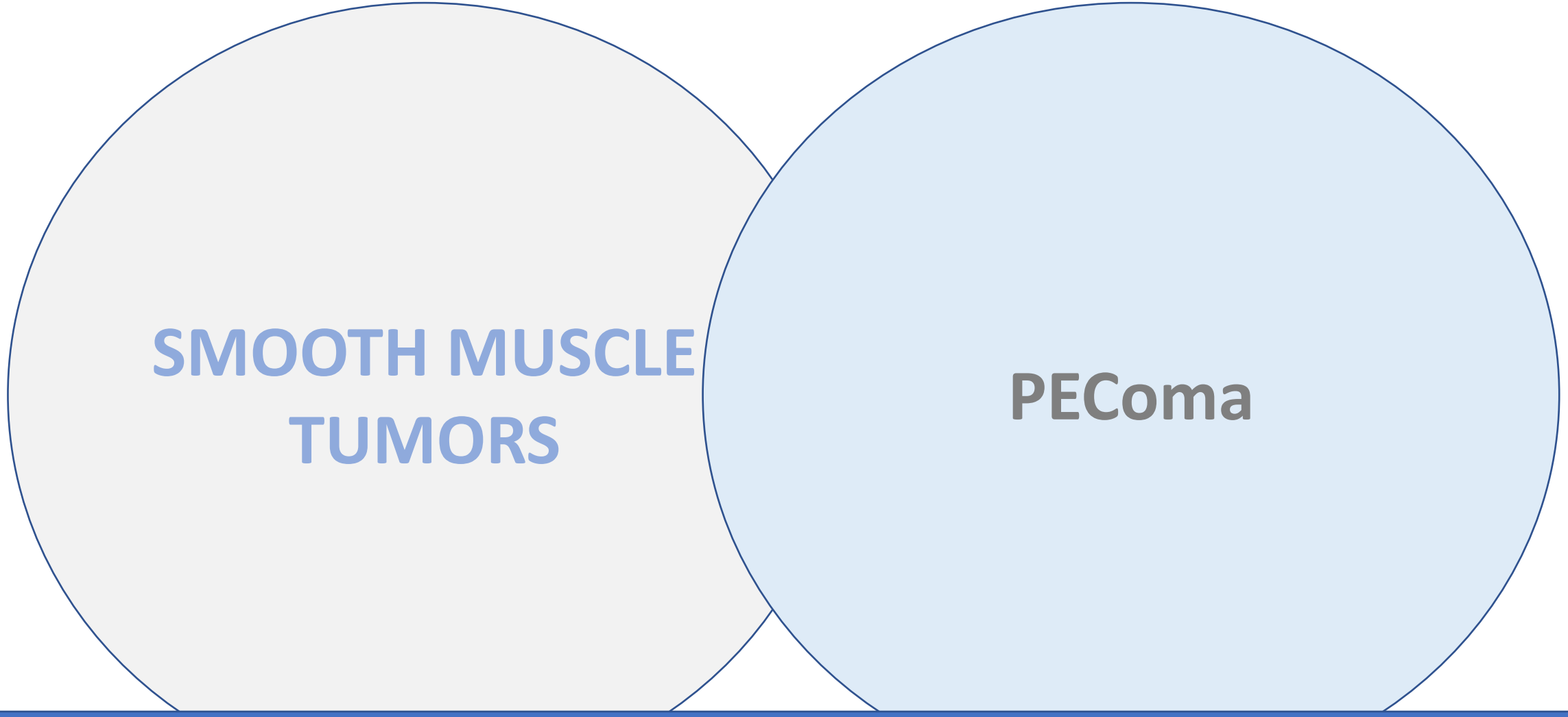

It was established that in the correct setting, at least focal expression of 2 melanocytic markers was sufficient for a diagnosis of PEComa

Malignant PEComas Often Harbor *TP53* and/or *ATRX* Mutations

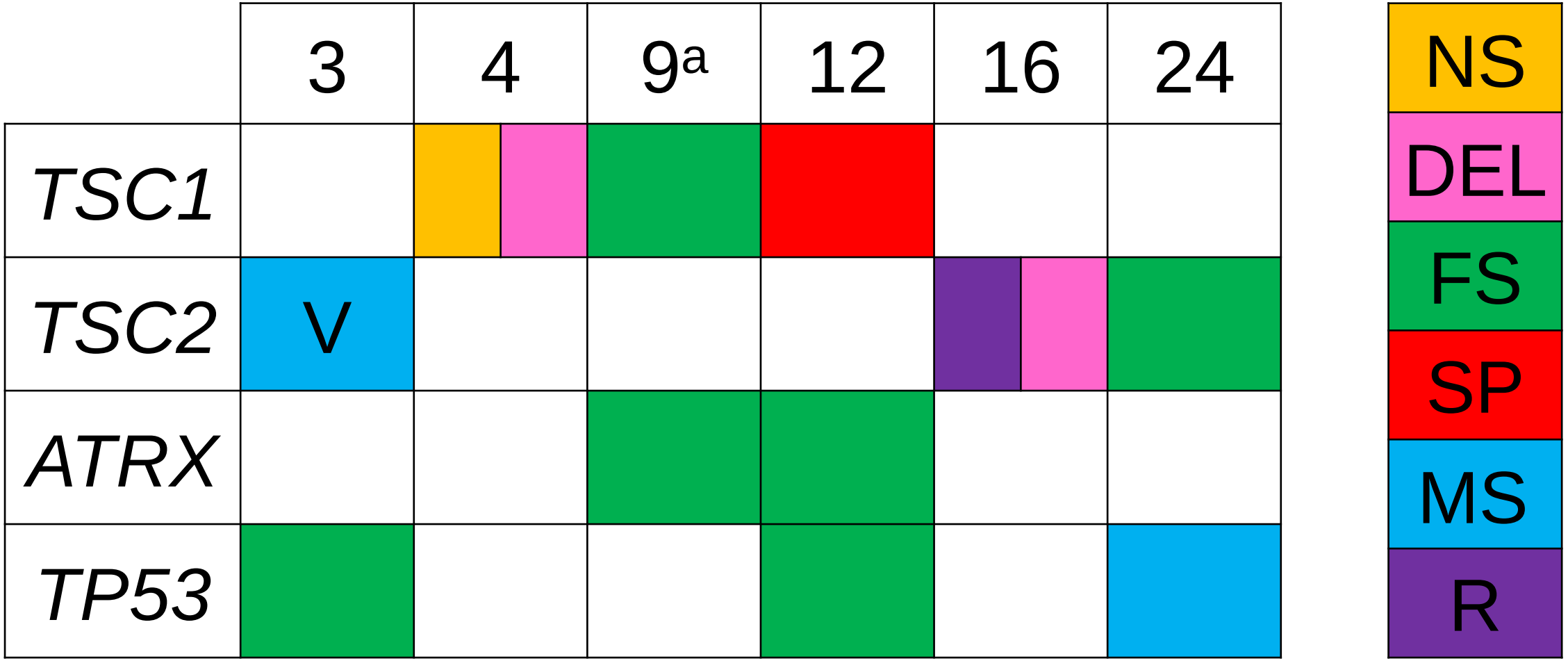

GENOMIC PROFILING AIDS CLASSIFICATION OF DIAGNOSTICALLY CHALLENGING UTERINE MESENCHYMAL TUMORS WITH MYOMELANOCYTIC DIFFERENTIATION

Malignant PEComa	• HMB-45: 15%, 70%, 100%, “Positive” • *TFE3* fusion, *TSC2* mutation, *TSC2* homozygous deletion
PEComa-Like	• HMB-45: 5%, “Focal”, “Positive” • *TSC2* mutation (n=2), *TSC2* mutation only in recurrence
Myogenic	• HMB-45: 0%, 1%, 5%, 5%, 50%, “Focal” • No *TSC* alterations or *TFE3* fusions
Sarcoma NOS	• HMB-45: 15%, “Focal” • No *TSC* alterations or *TFE3* fusions

Am J Surg Pathol, 2021

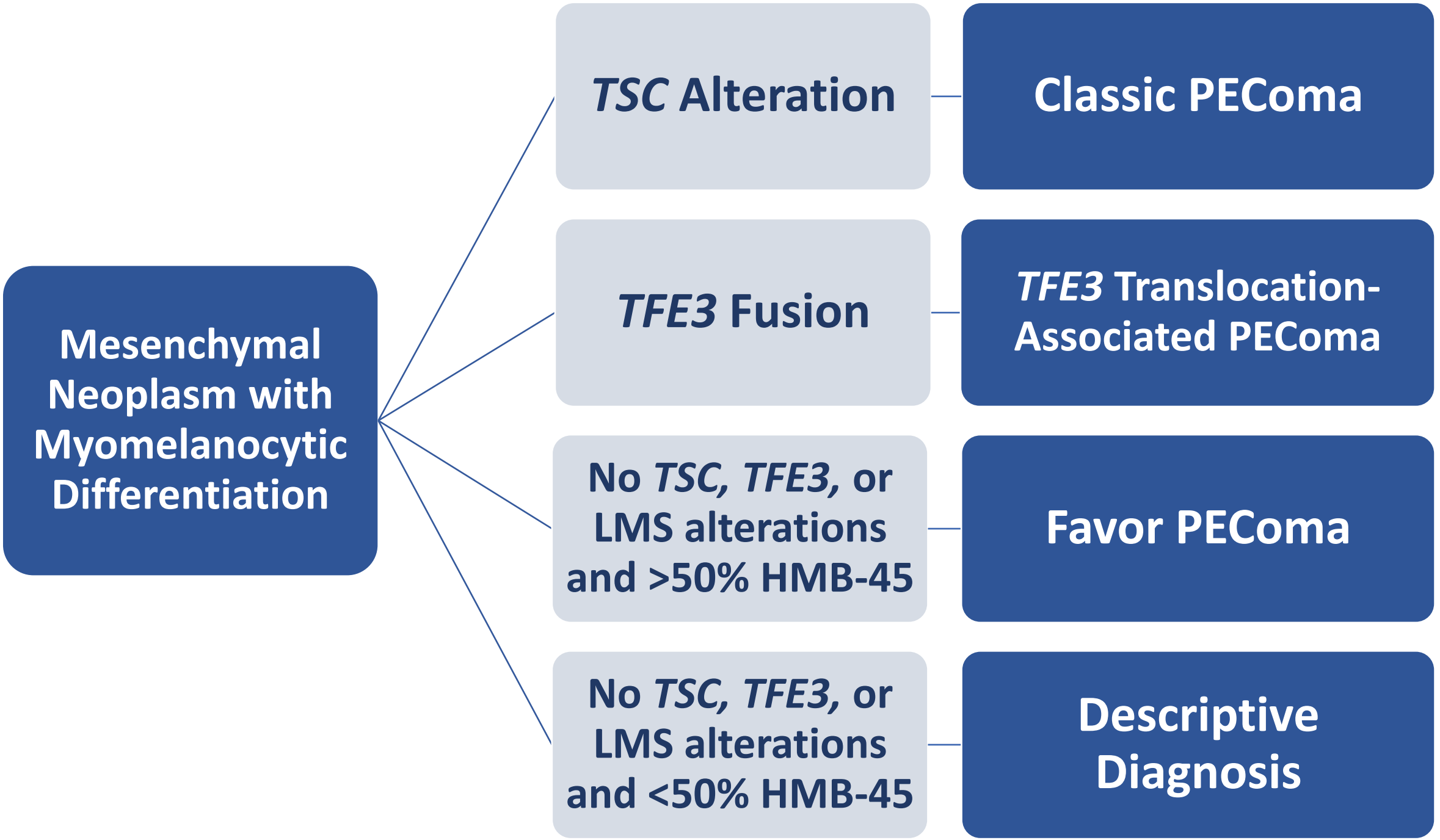
Mesenchymal Neoplasm with Myomelanocytic Differentiation
TSC Alteration
Classic PEComa
TFE3 Fusion
TFE3 Translocation-Associated PEComa
No *TSC*, *TFE3*, or LMS alterations and >50% HMB-45
Favor PEComa
No *TSC*, *TFE3*, or LMS alterations and <50% HMB-45
Descriptive Diagnosis

	WHO 2013	WHO 2020
Benign		< 3 features: ≥ 5 cm, high-grade atypia, >1 mitoses/50 HPFs, necrosis, LVI
Uncertain malignant behavior	Nuclear pleomorphism /multinucleated giant cells or >5 cm	
Malignant	≥ 2 features: >5 cm, infiltration, high-grade atypia, >1 mitoses/50 HPFs, necrosis, vascular invasion	≥ 3 features

SMARC DEFICIENT UTERINE SARCOMA

- Likely diagnosed in past as uterine malignant rhabdoid tumor or undifferentiated endometrial carcinoma
- Typically, high stage at presentation (III-IV)
- Sporadic>>>>> Germ-line mutations (often truncated mutations)
- Bi-allelic SMARCA-4 inactivation, with low tumor mutational burden and no significant copy number alterations
- Large tumor, generally centered in corpus with deep myometrial invasion, cervical involvement and 25% with ovarian extension
- Aggressive behavior; median survival <1 year

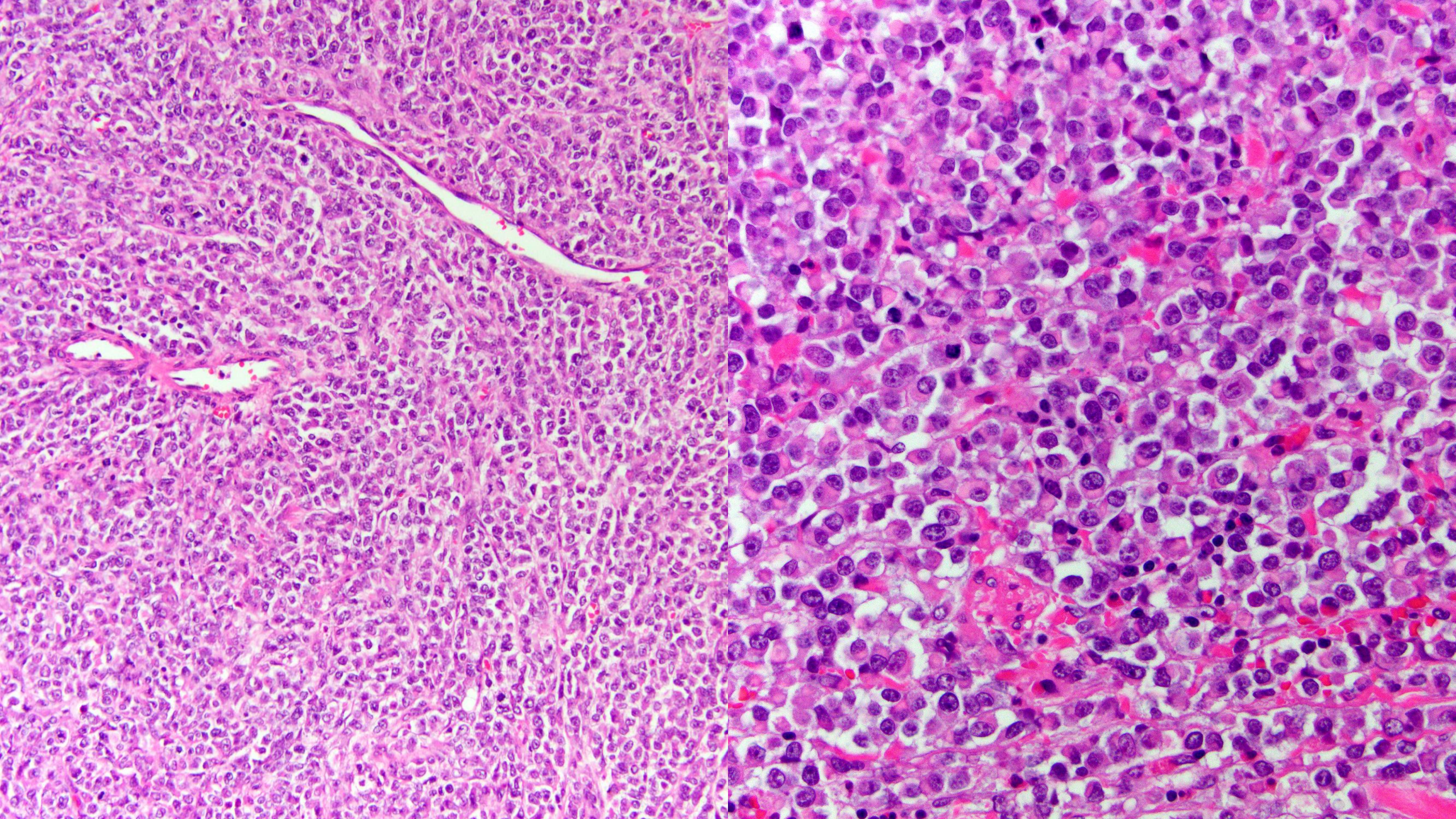

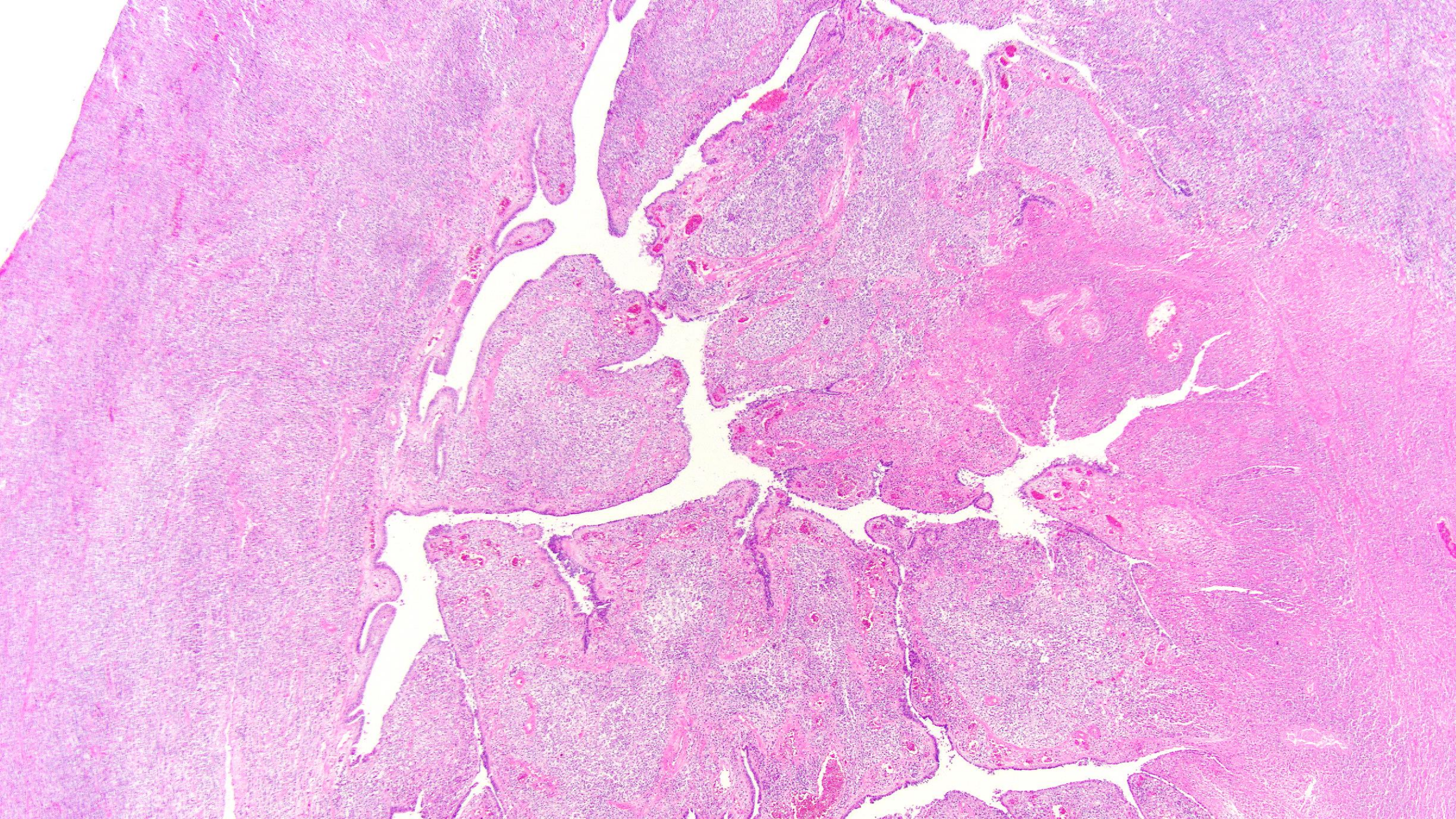

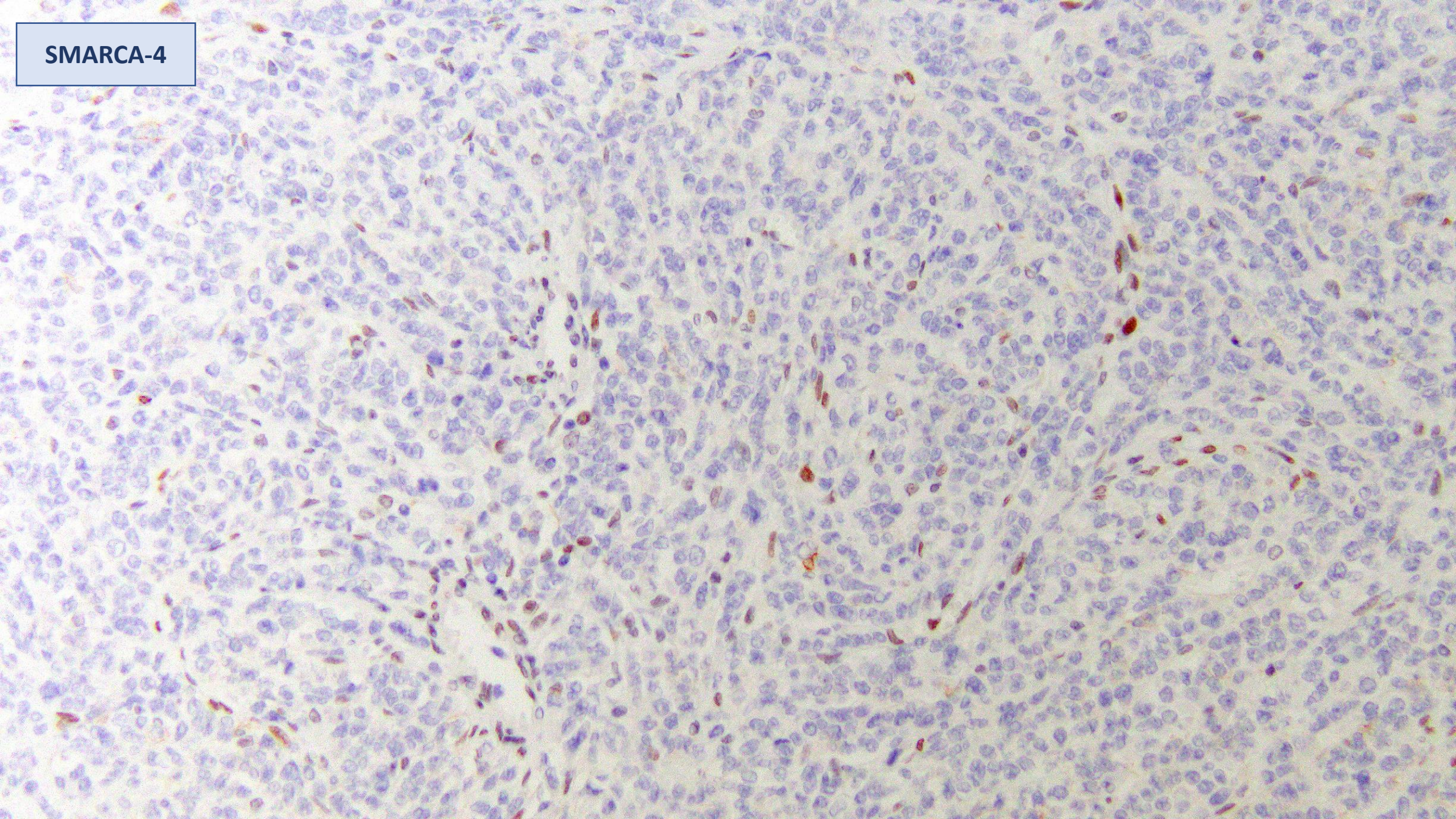
SMARCA-4

	SDUS	UD-EC
Epithelioid cells	Present	Present
Rhabdoid morphology	Diffuse	Typically focal
Pleomorphic cells	Absent	May be seen
Well-differentiated carcinoma	Absent	Present (sampling may be helpful)
Phyllodiform-like growth	May be present (mimics adenosarcoma at low power)	Absent
MMR	Intact	Deficient ~50%
Keratins/EMA/Claudin-4	Negative (or only rare + cells)	Often focal but may be -
p53	Wild-type	Mutant ~30%
SMARCA4	Loss of expression	Loss of expression in ~25%
WT1	May be +	-
Tumor mutational burden	Very low	Moderate to high
Copy number alterations	Very low	Moderate to high

INFLAMMATORY MYOFIBROBLASTIC TUMOR

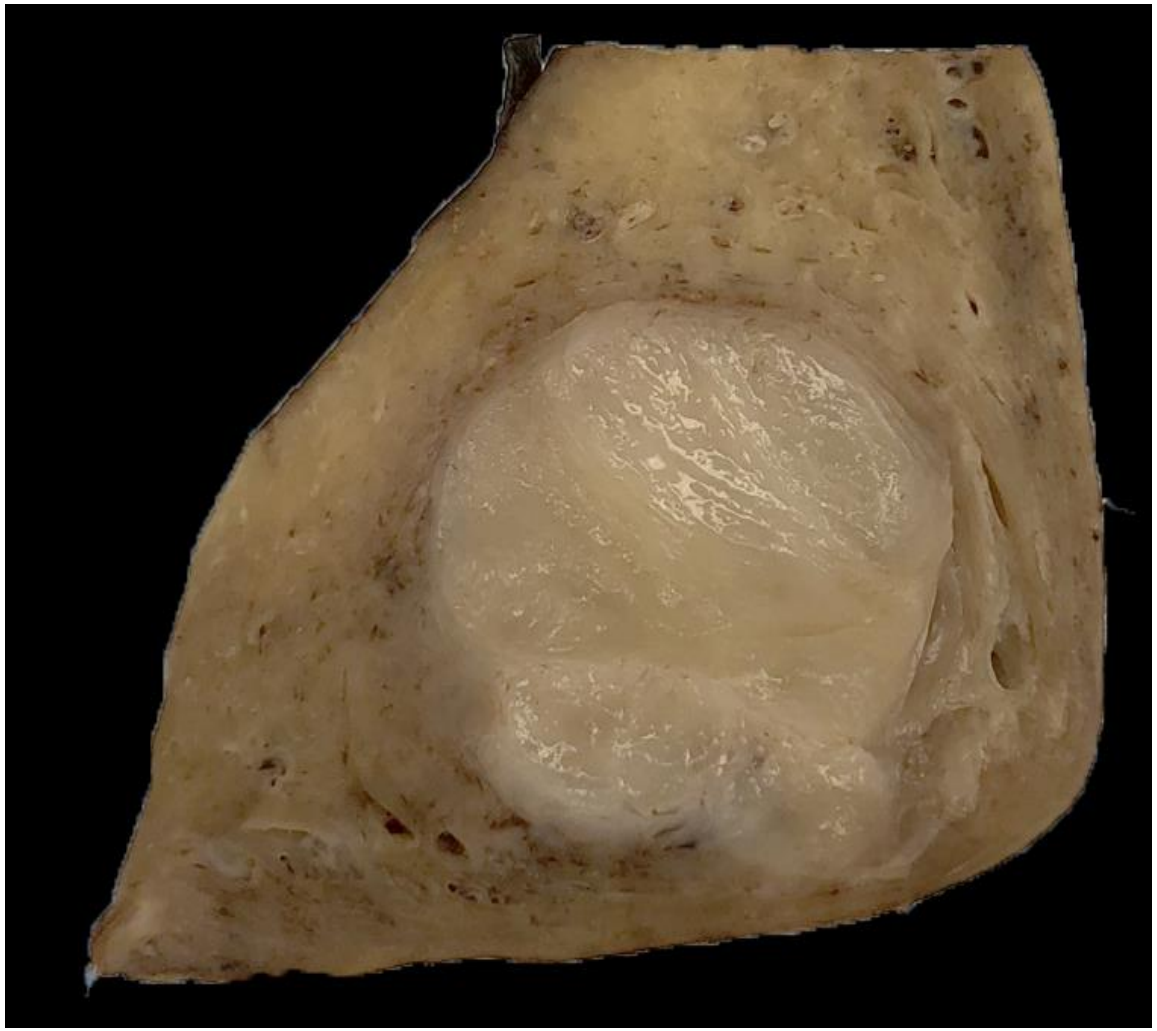



May be strikingly myxoid

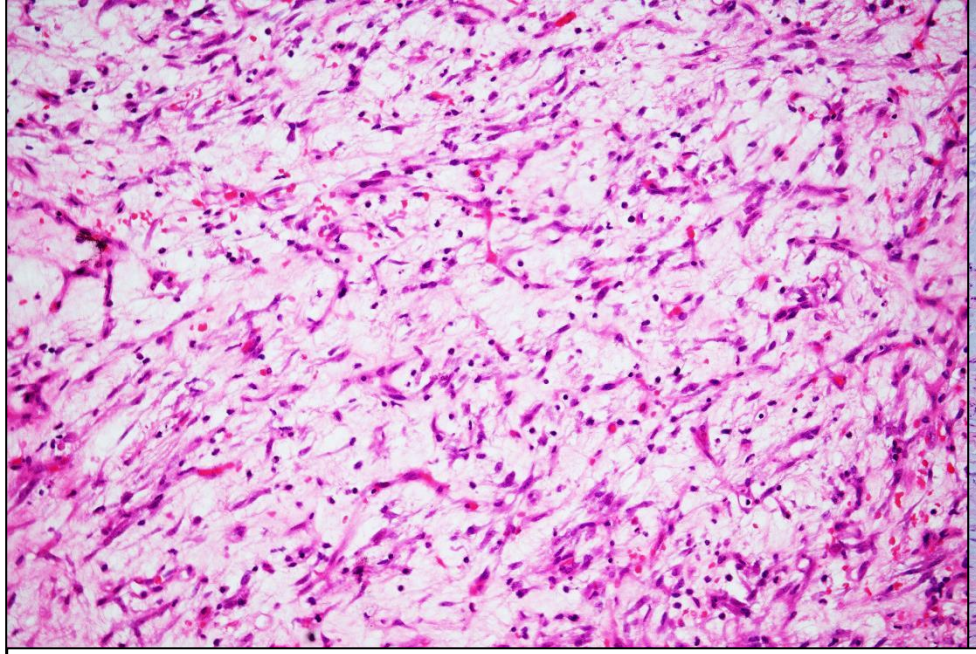

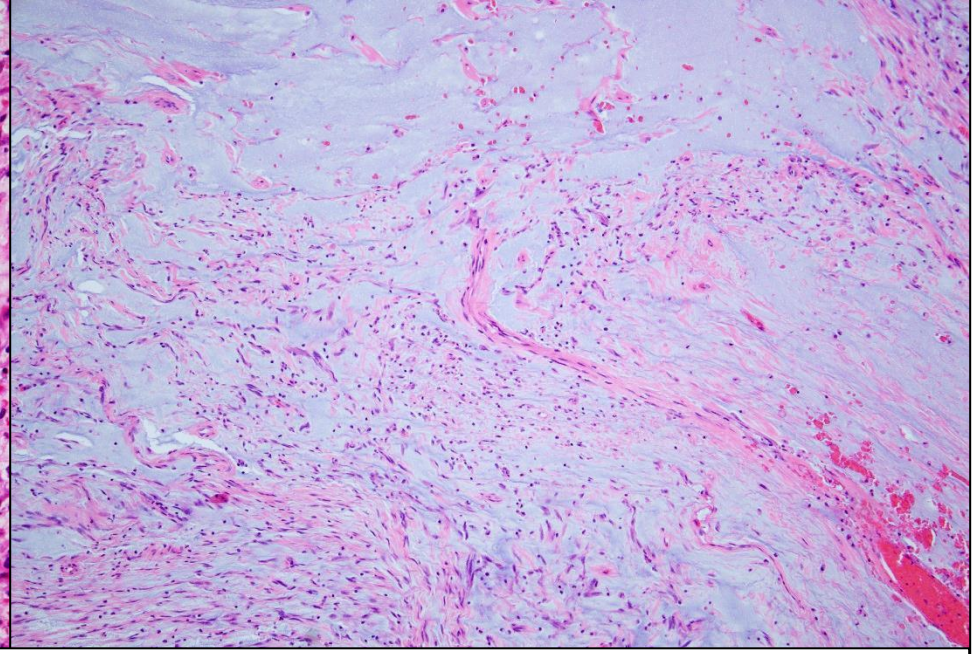

Myxoid appearances

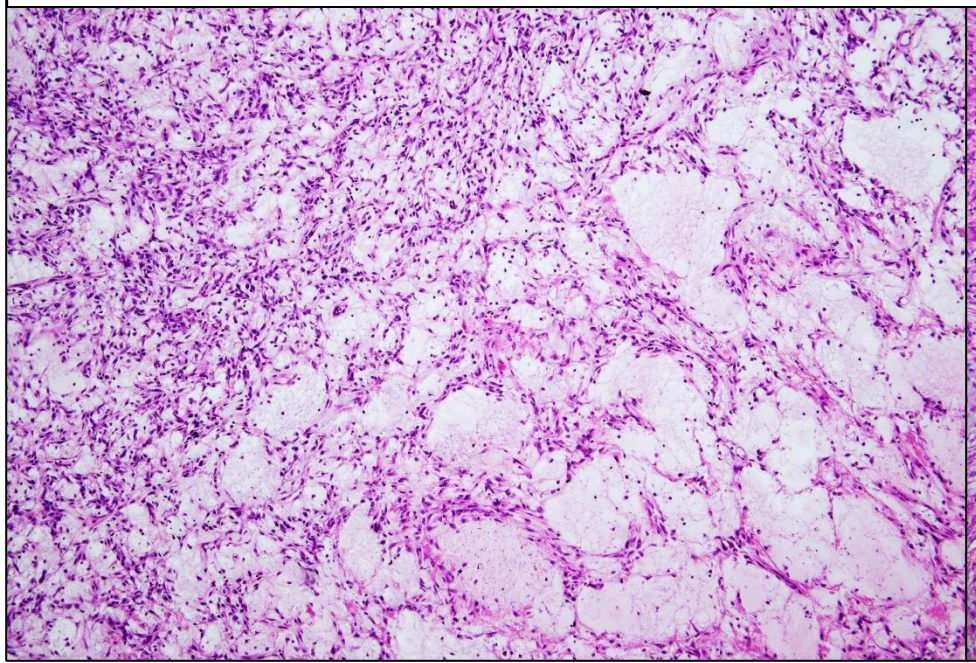

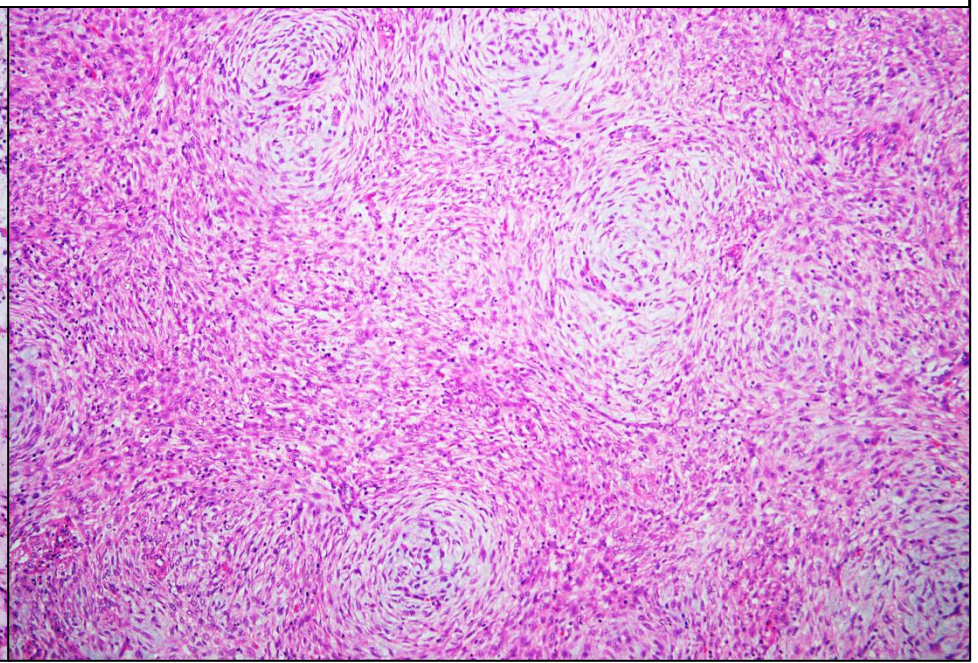

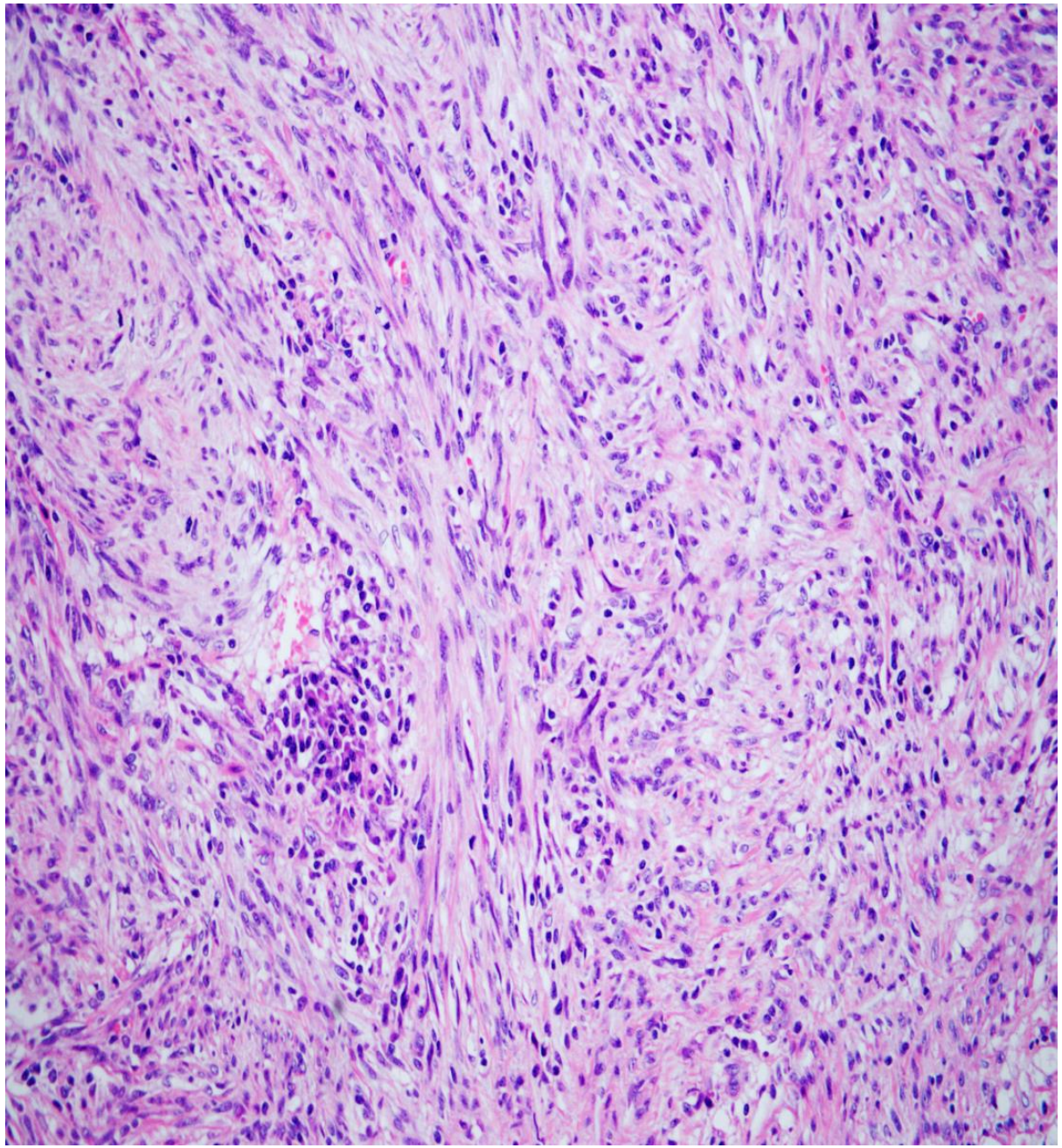

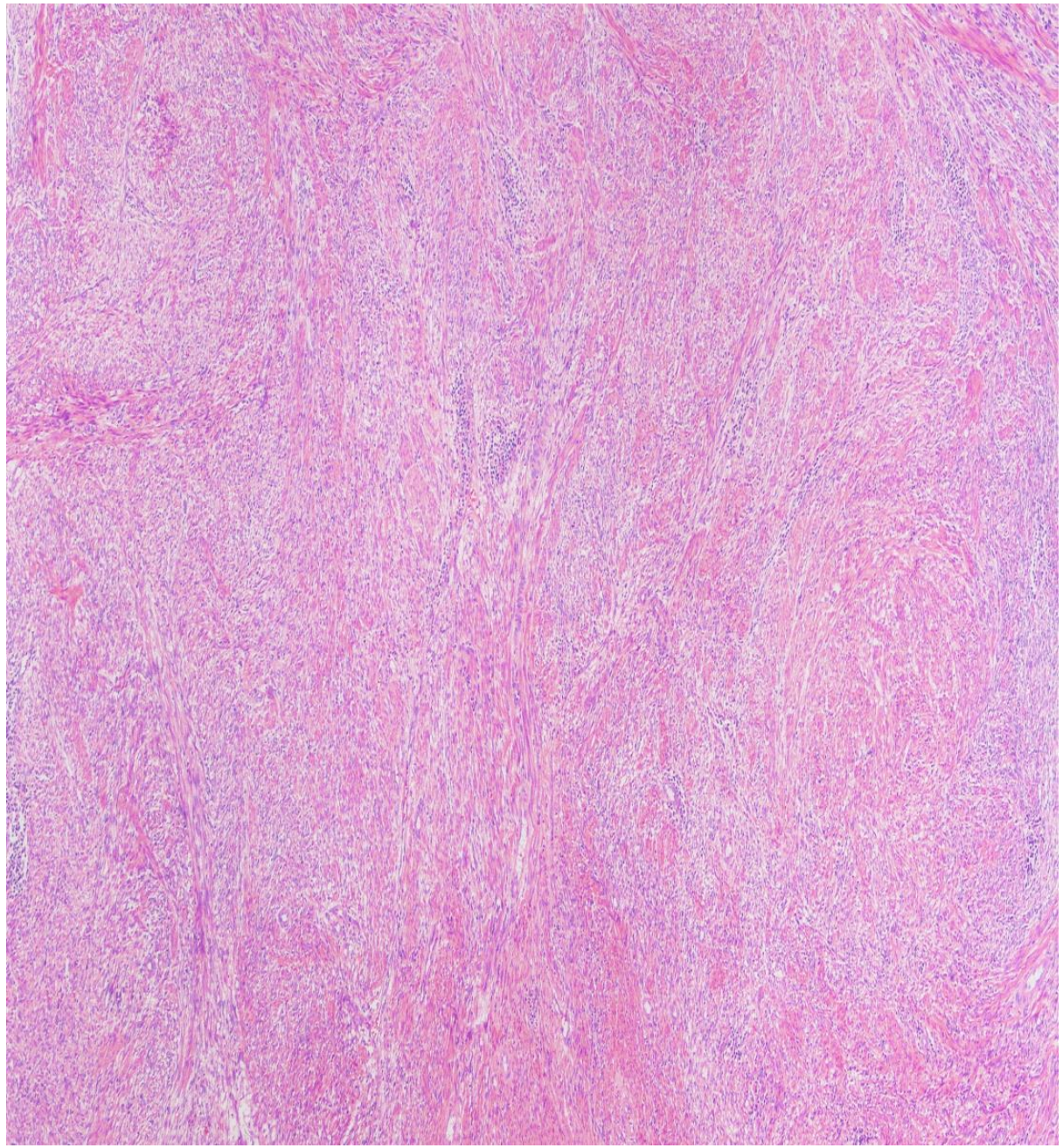

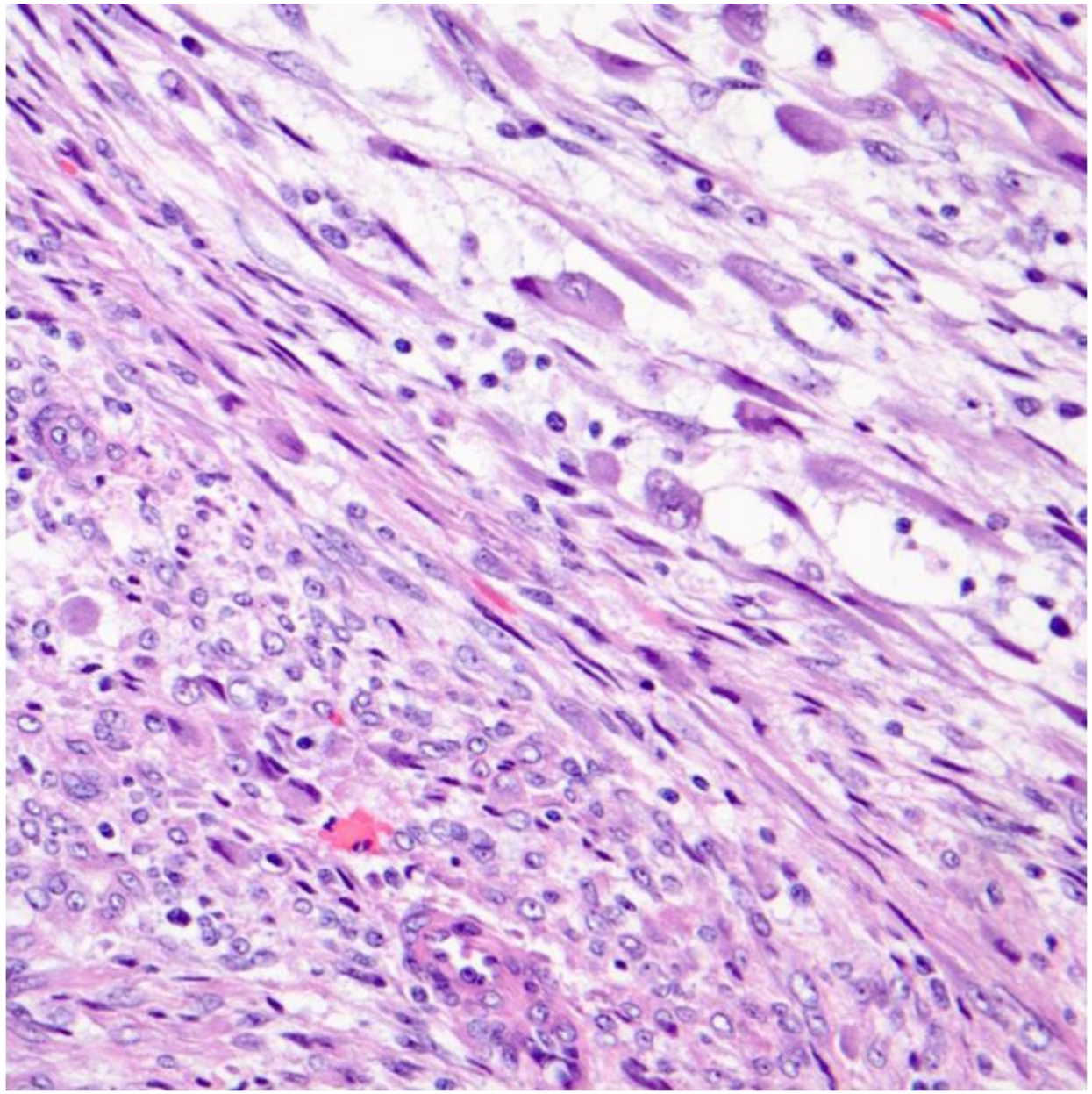

Ganglion cells

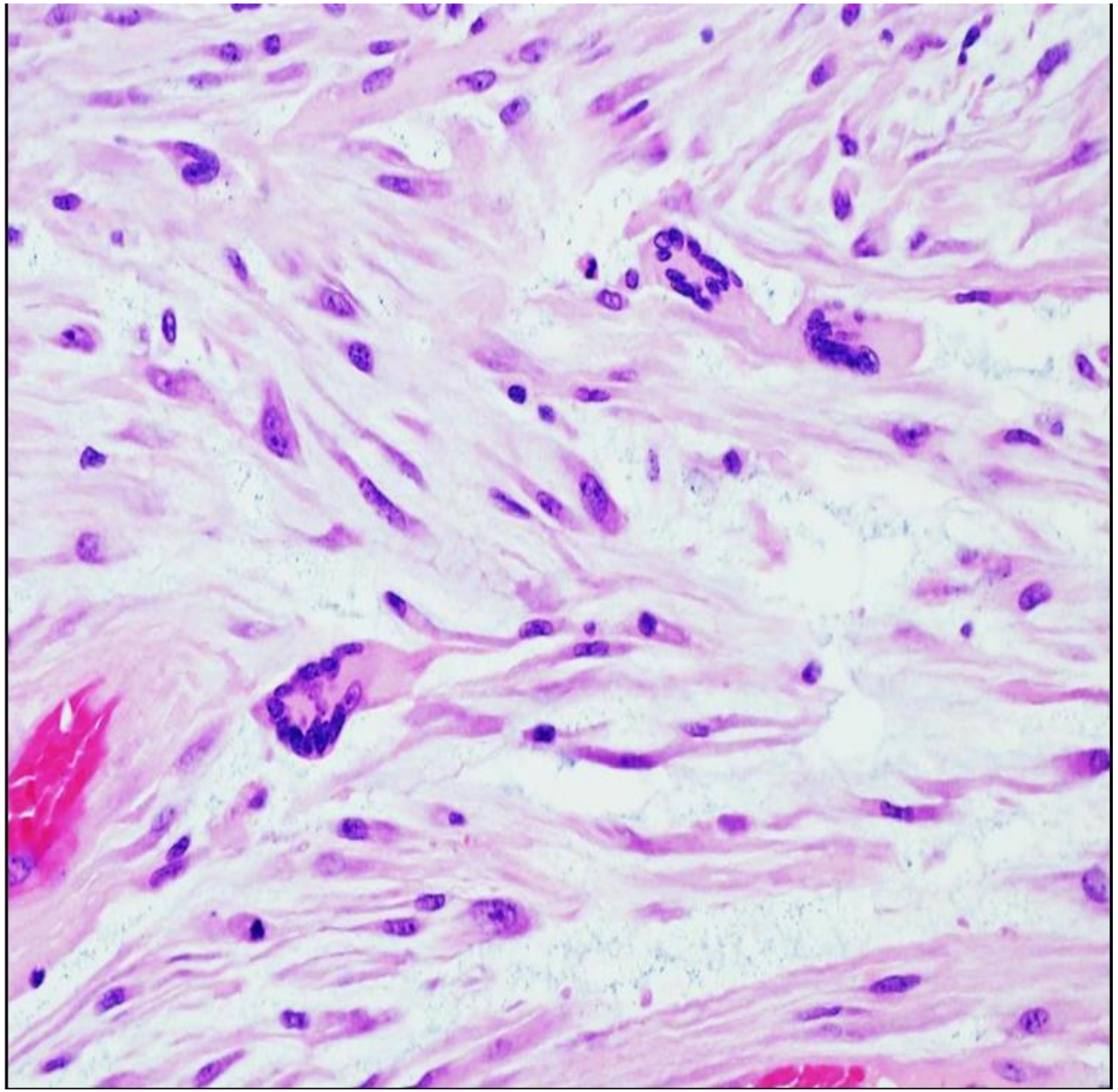

Touton cells

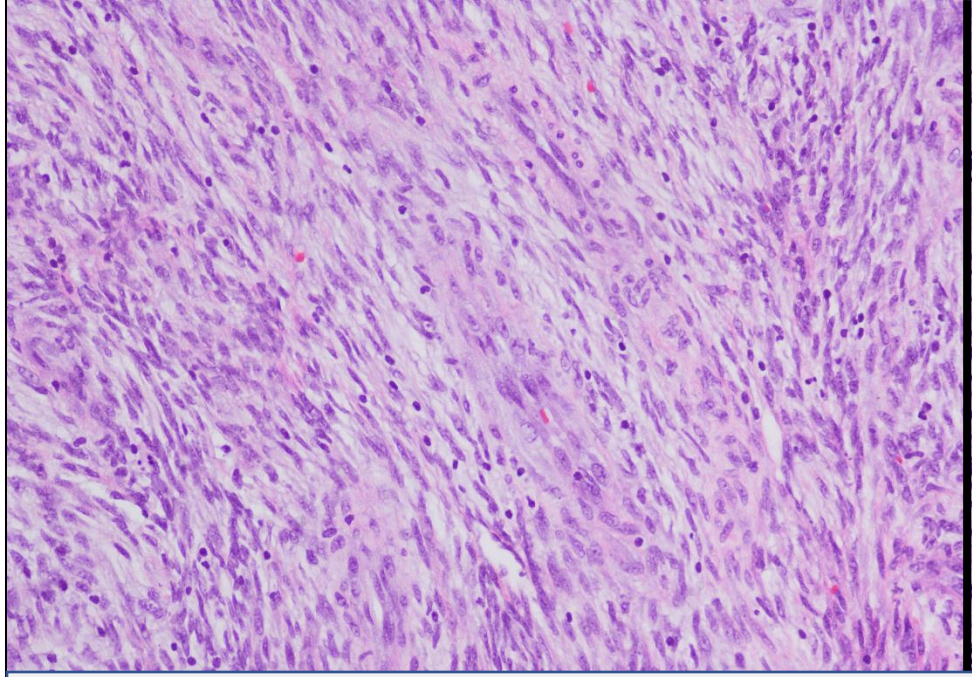

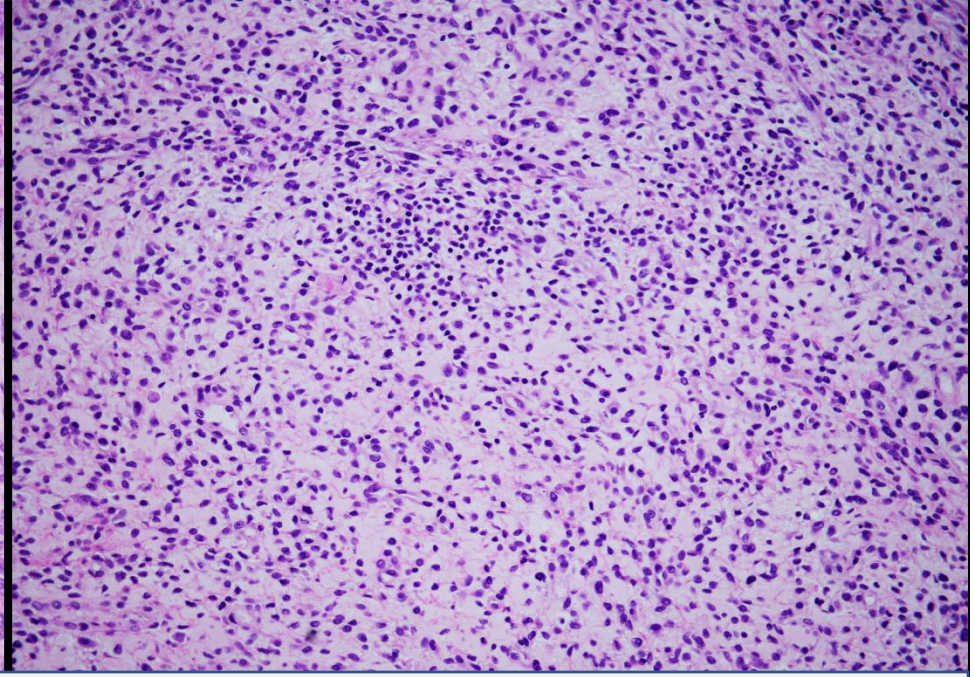

INFLAMMATORY INFILTRATE

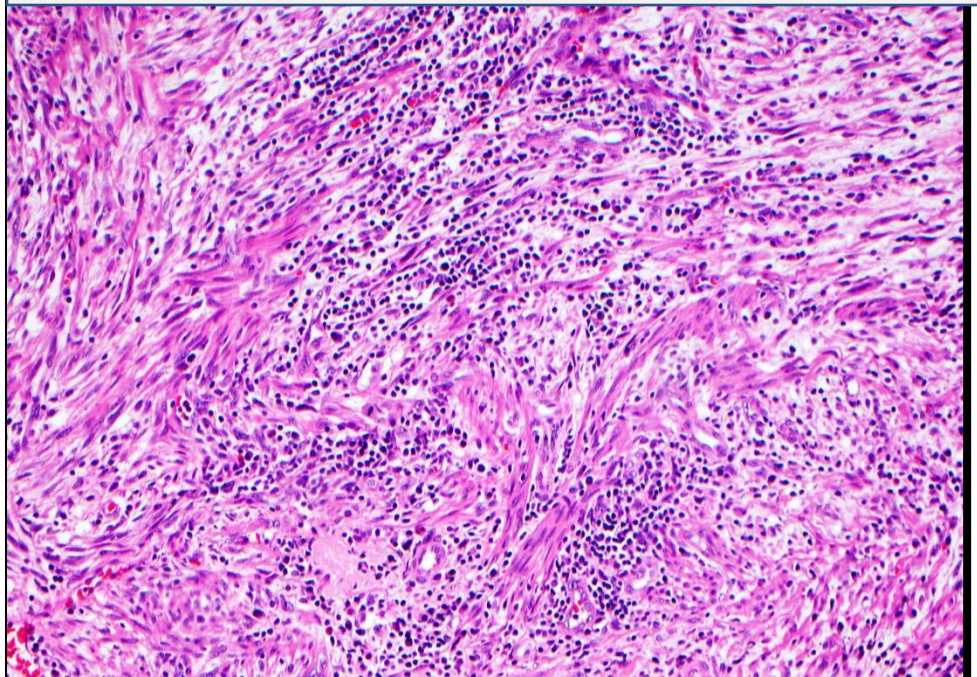

Location

- **Compact-Predominant: 46%**
- **Equally Distributed: 31%**
- **Myxoid-Predominant: 23%**

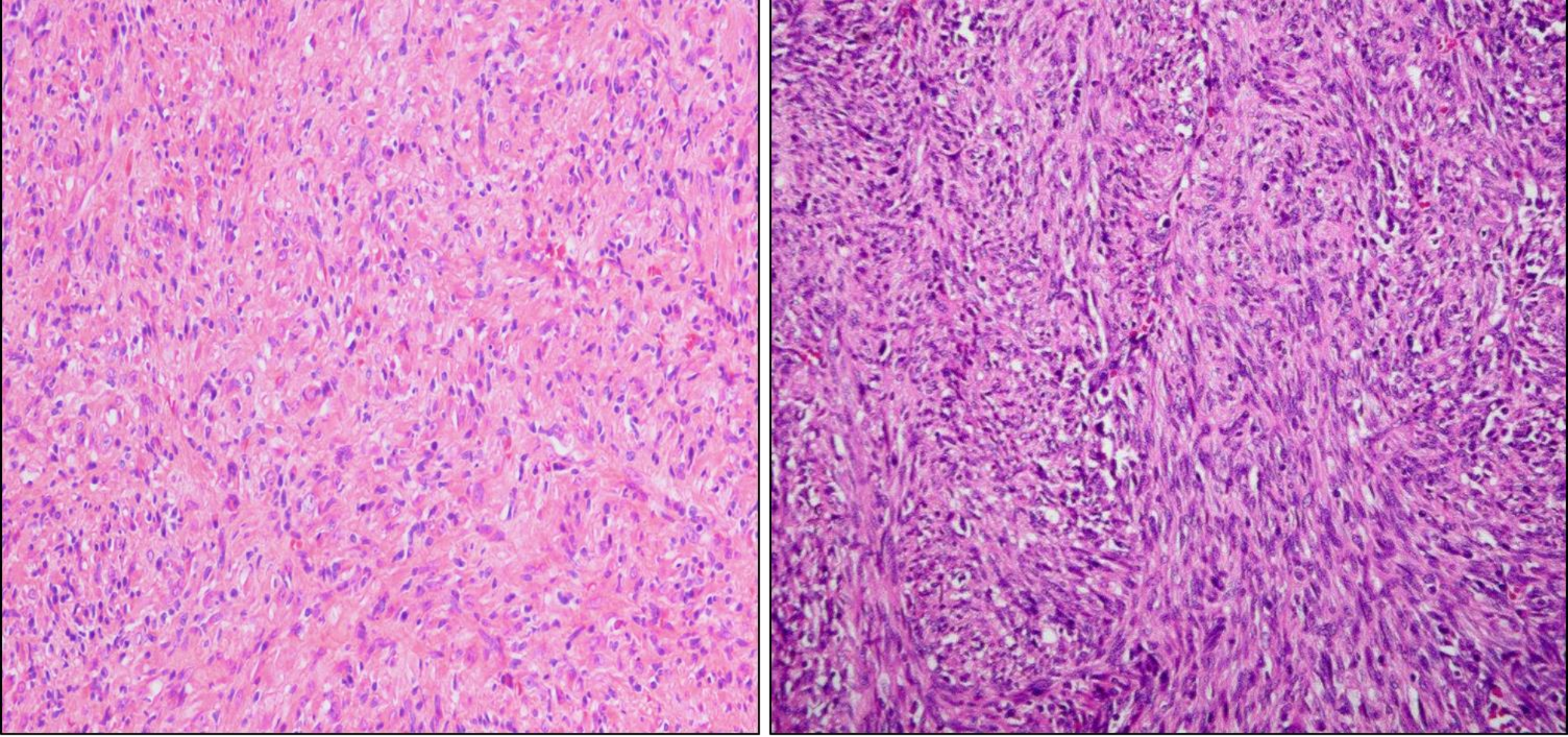

Be aware of smooth muscle-like appearance!

INFLAMMATORY MYOFIBROBLASTIC TUMOR

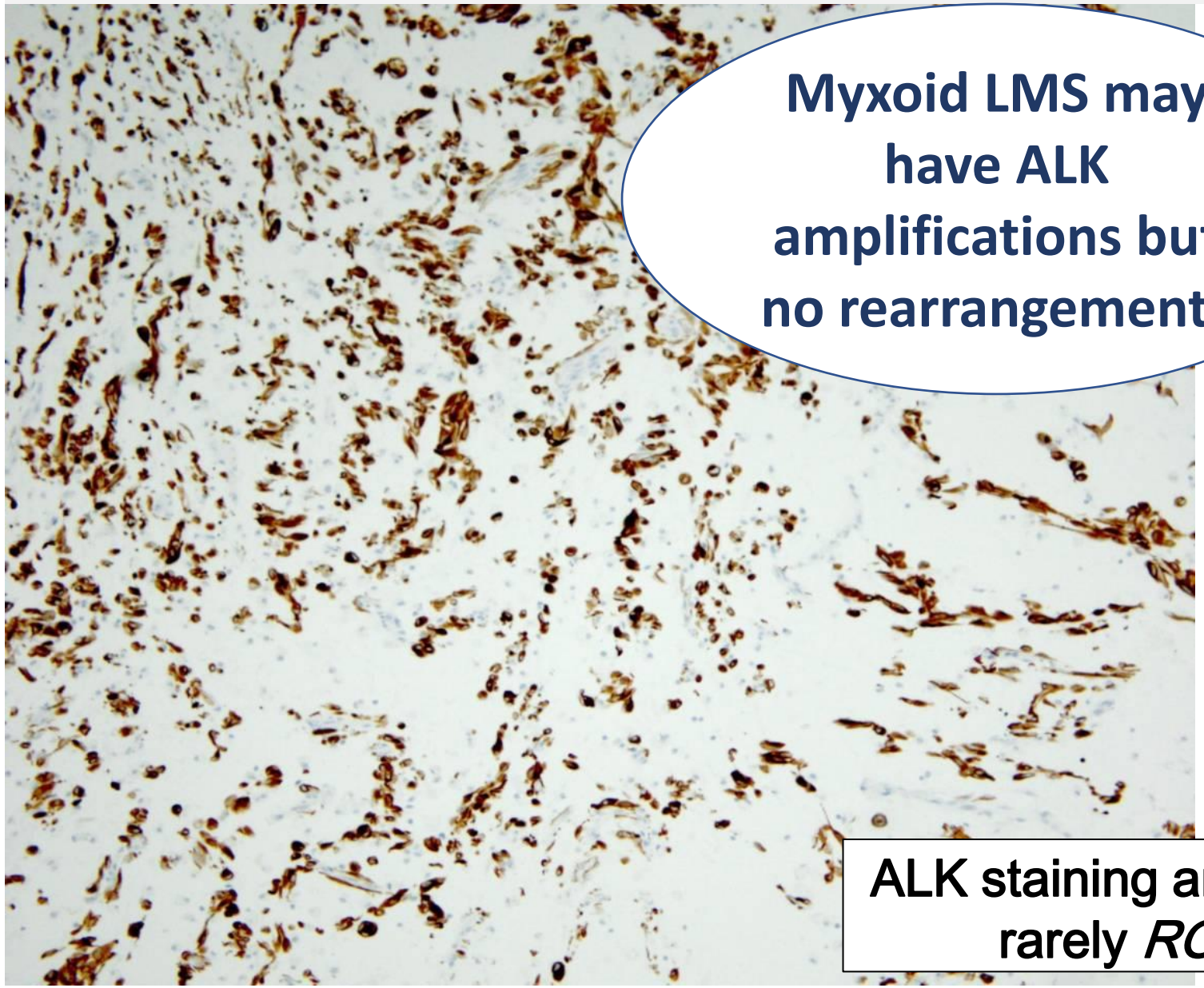

Myxoid LMS may have ALK amplifications but no rearrangements

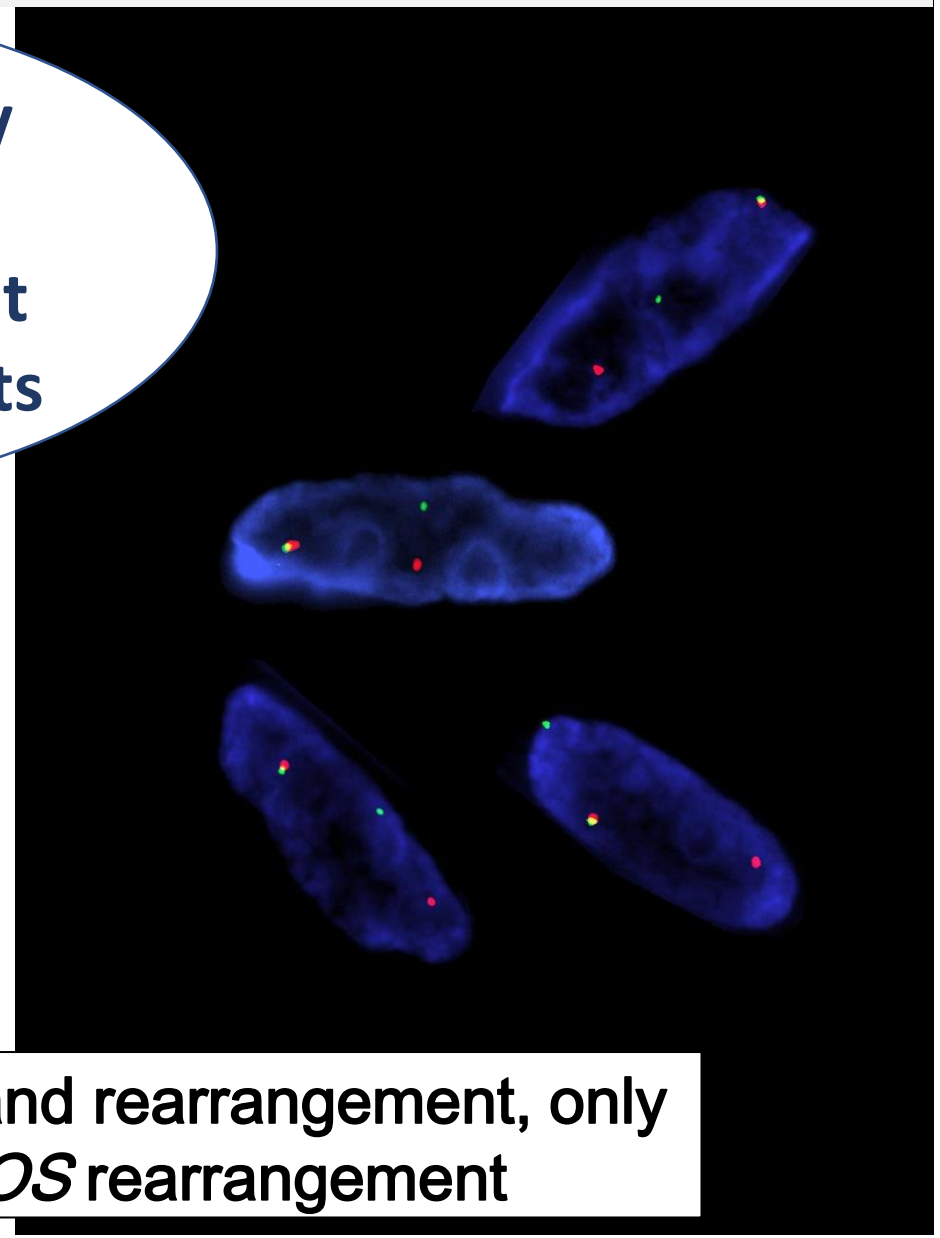

ALK staining and rearrangement, only rarely *ROS* rearrangement

INFLAMMATORY MYOFIBROBLASTIC TUMOR



Smooth muscle markers may be positive!!!

Desmin

Inflammatory Myofibroblastic Tumor of the Uterus: An immunohistochemical Study of 23 Cases

Bennett J, et al, Am J Surg Pathol 2020

IFITM1 **19/23** **(83%)**

(more specific than CD10 in dx of ESTs)

BCOR **8/20** **(40%)**

Transgelin **22/23** **(96%)**

(more sensitive than other smooth muscle markers in ddx)

P53 wild type **23/23** **(100%)**

p16 lost **5/23** **(22%)**

(2 associated with CDKN2A deletions; both malignant)

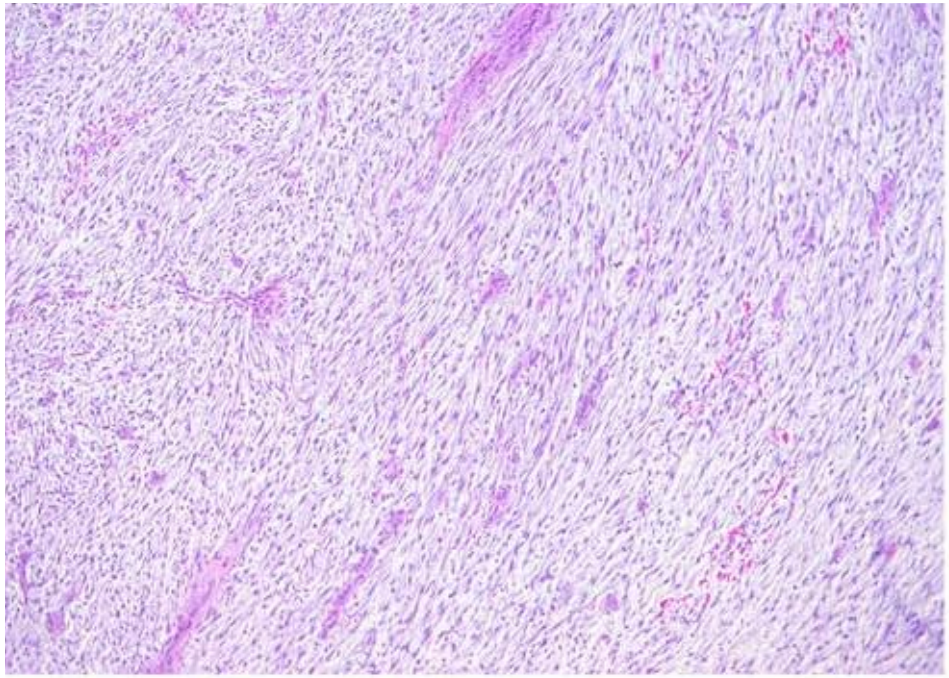

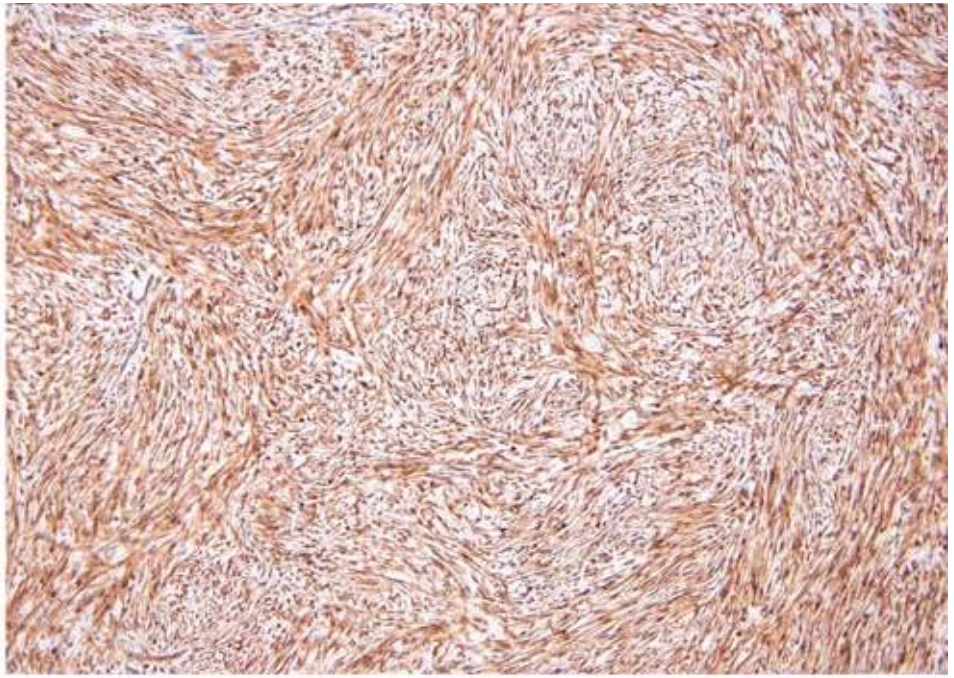

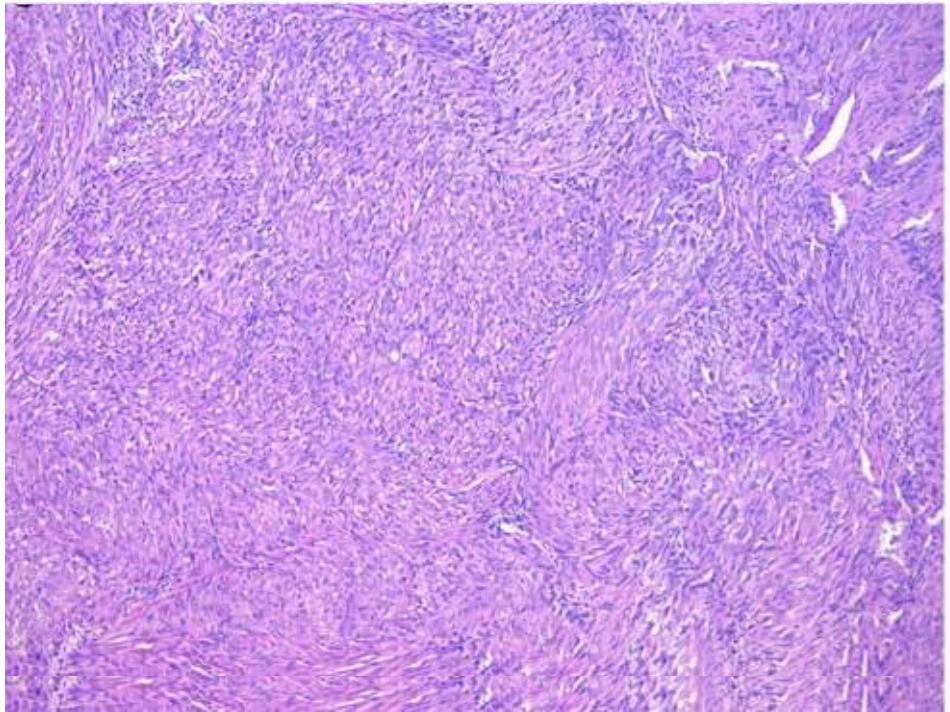

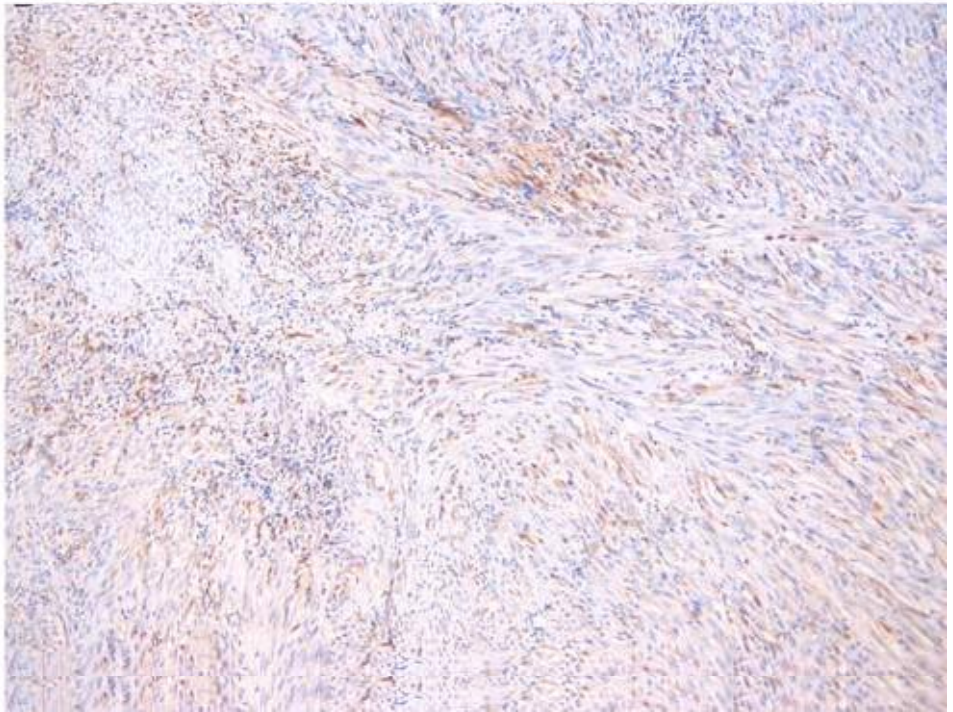

IFITM1
more often, extensively, and strongly expressed in myxoid areas

Transgelin often show opposite profile

INFLAMMATORY MYOFIBROBLASTIC TUMOR

Features associated with aggressive behavior:

- Large size (>7 cm)
- Necrosis
- Moderate to severe cytologic atypia
- High mitotic activity
- Lymphovascular invasion

Parra-Herran C et al, Am J Surg Pathol 2015;39:157-68

Bennett J et al , Modern Pathol 2017; 30:1489-1503

NOVEL HIGH-GRADE ENDOMETRIAL STROMAL SARCOMA: A MORPHOLOGIC MIMICKER OF MYXOID LEIOMYOSARCOMA

Hoang LN et al, Am J Surg Pathol 2016



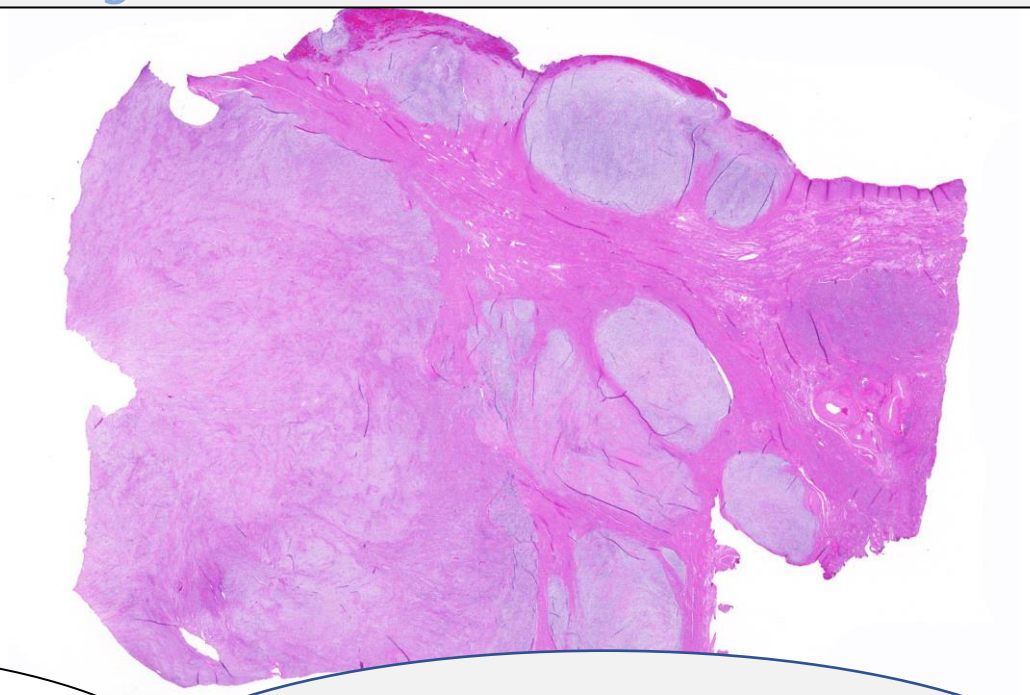

Tongue-like, broad front, or destructive

More aggressive behavior compared to low-grade tumors

BCOR-ZC3H7B HIGH-GRADE ENDOMETRIAL STROMAL SARCOMA

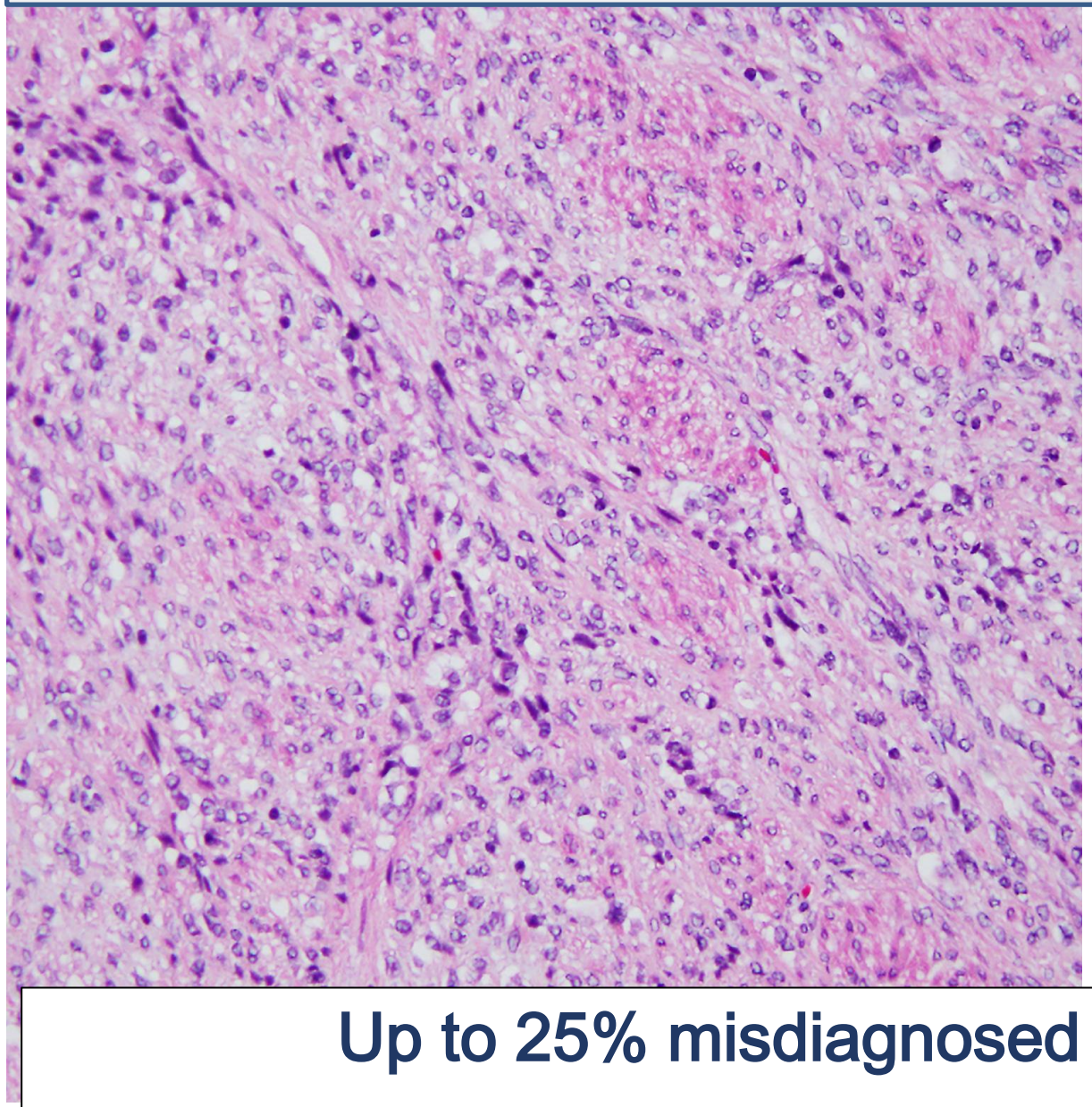

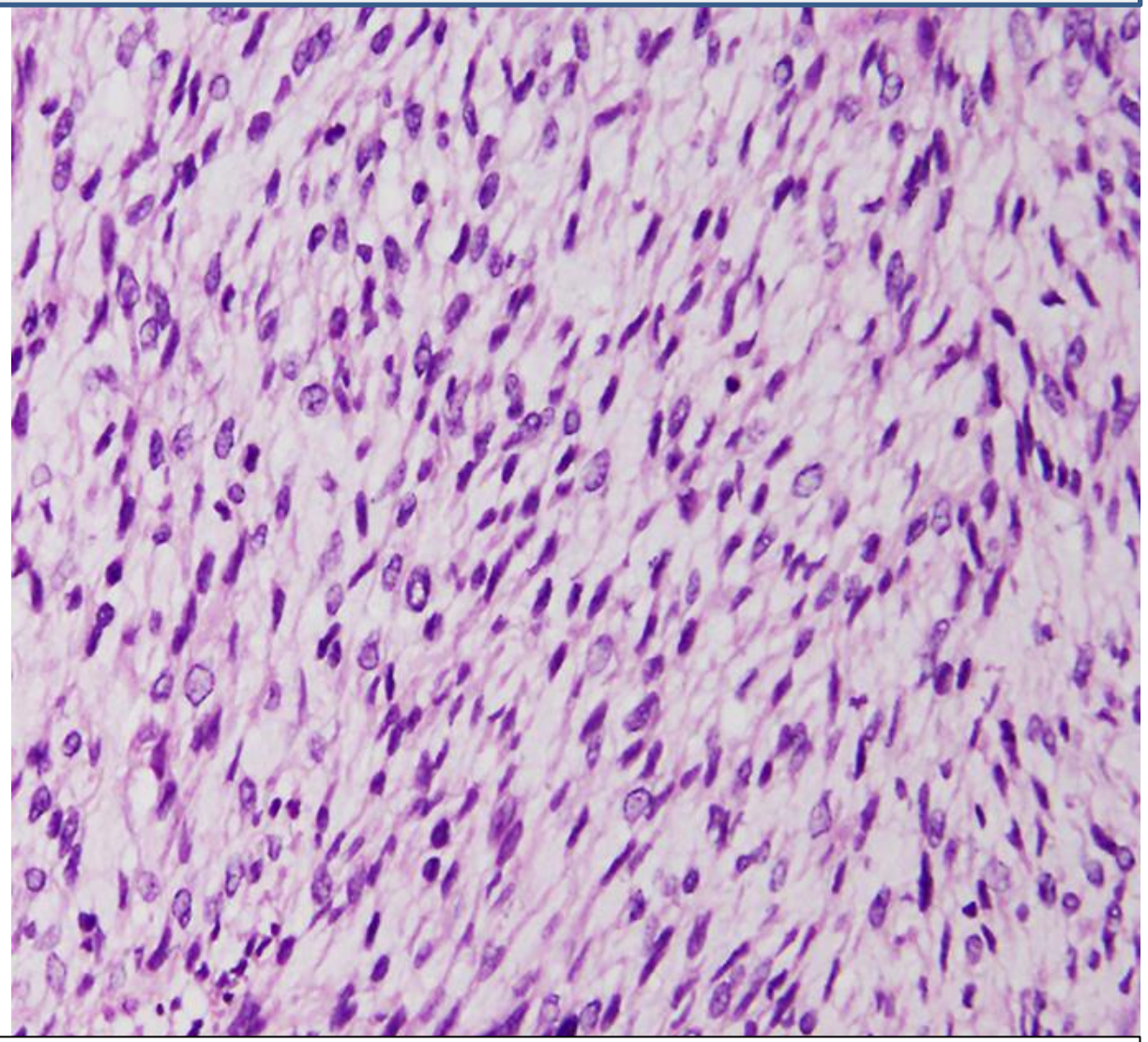

Up to 25% misdiagnosed as such in different series

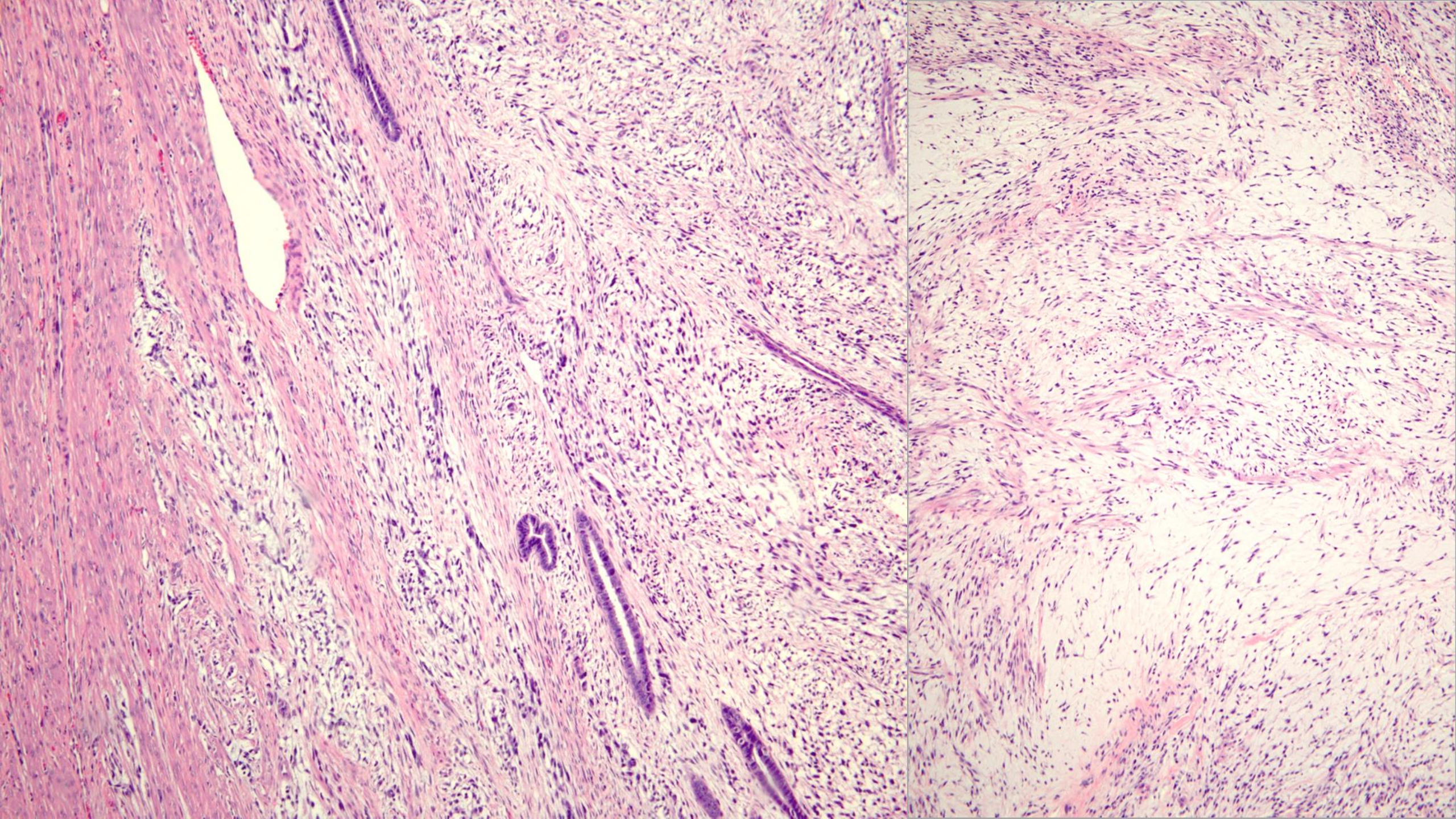

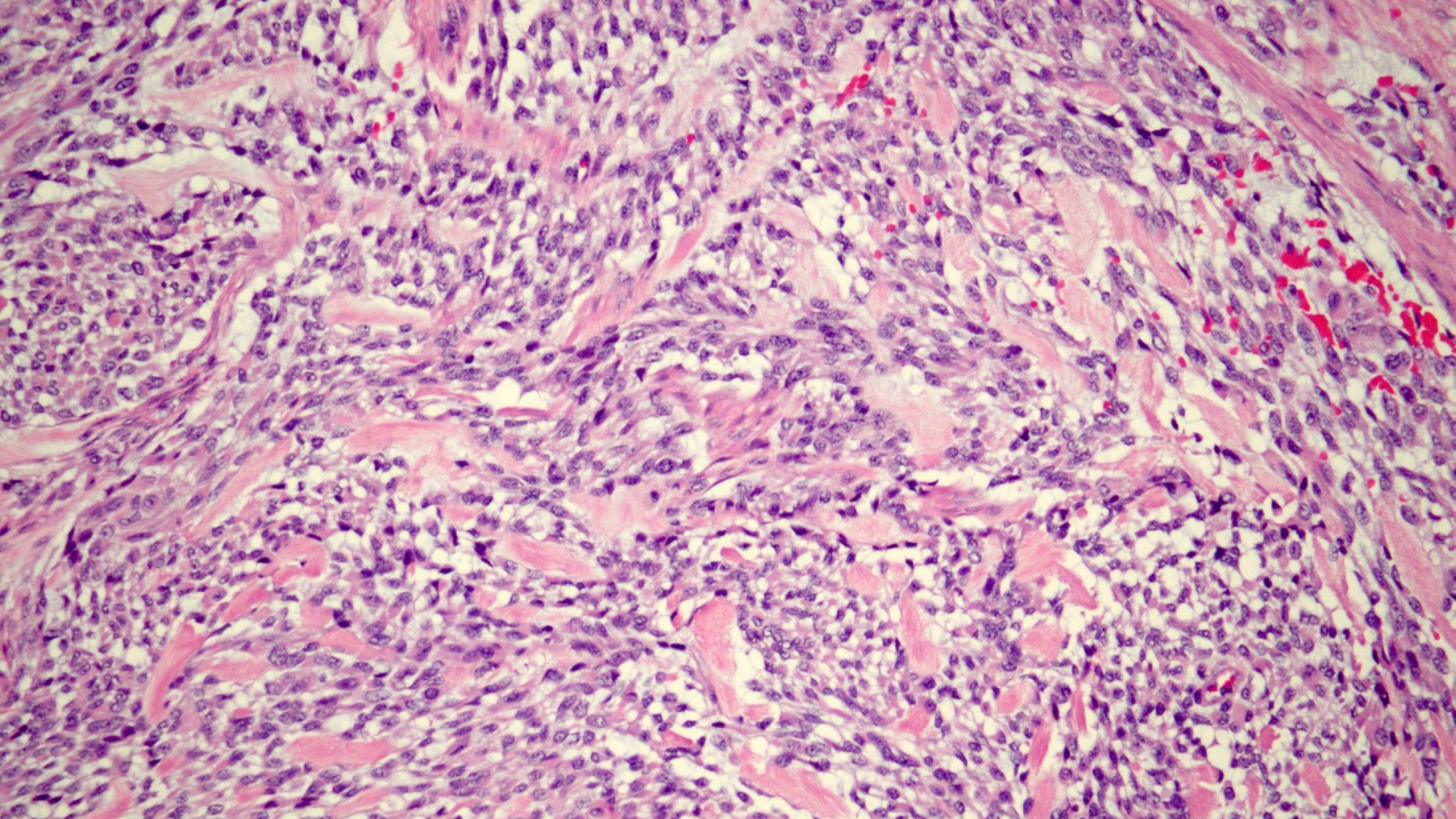

BCOR ITD (INTERNAL TANDEM DUPLICATION) HIGH-GRADE SARCOMAS

Lewis N et al, Mod Pathol 2018; Mariño-Enriquez A et al, Am J Surg Pathol 2018

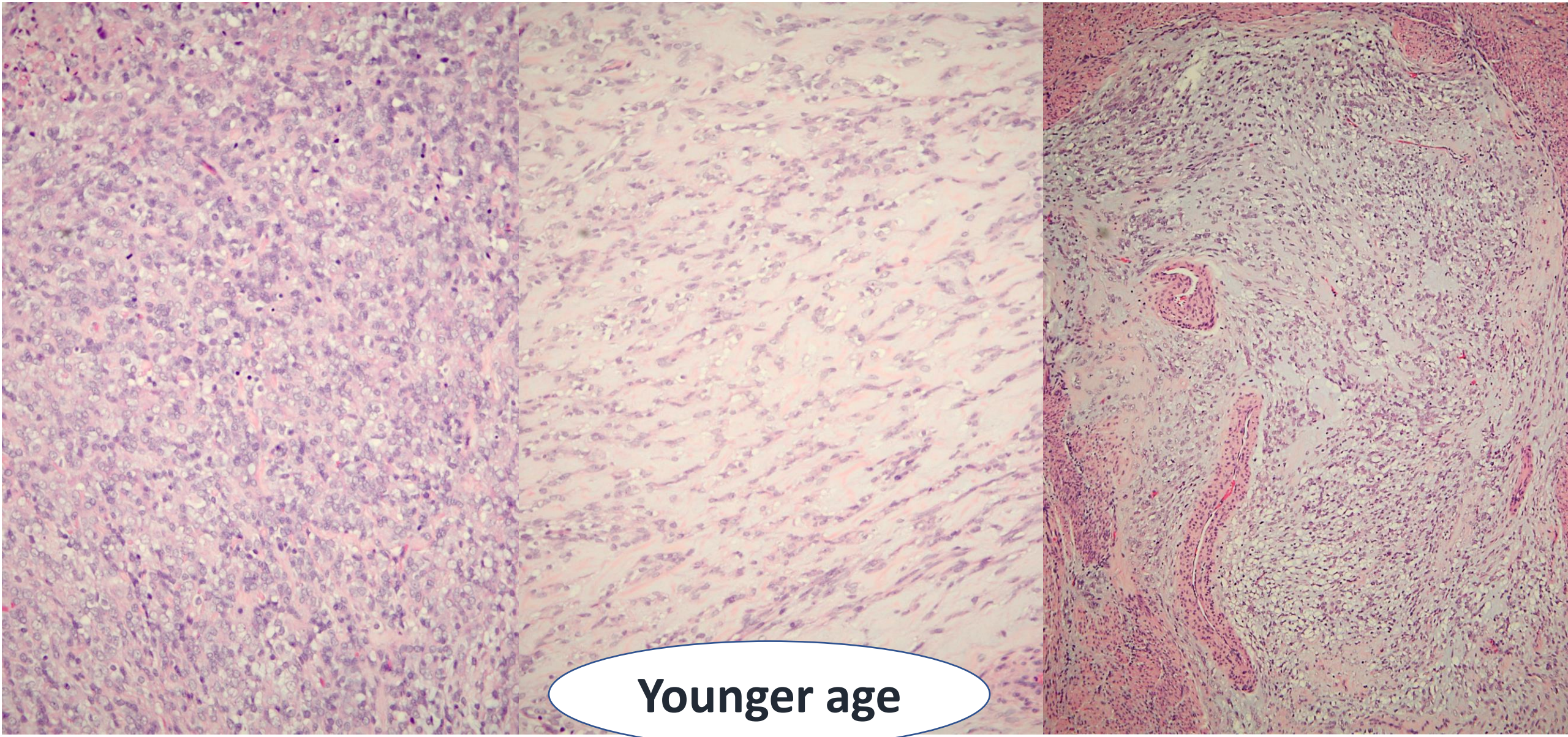

	CD10	ER	PR	CyclinD1	BCOR	Desmin	SMA	Caldesmon
ESN	+ D	+ D	+ D	-/+ F	-/+ F	-/+ F/D	+ D	+ F/D
LG-ESS	+ D	+ D	+ D	-/+ F	-/+ F	-/+ F/D	+ D	+ F/D
YWHAE-NUT2A/B HG-ESS Low-grade areas	+ D	+ D	+ D	-/+ F	-/+ F	-	-	-
YWHAE-NUT2A/B HG-ESS High-grade areas	-	-	-	+ D	+ D	-	-	-
ZC3H7B-BCOR HG-ESS	+ D	-/+ F	-/+ F	+ D	-/+ F/D	-	-/+ F	-/+ F
BCOR ITD HG-ESS	+ F/D	-	-	+ D	+ F/D	-/+ F	-	-

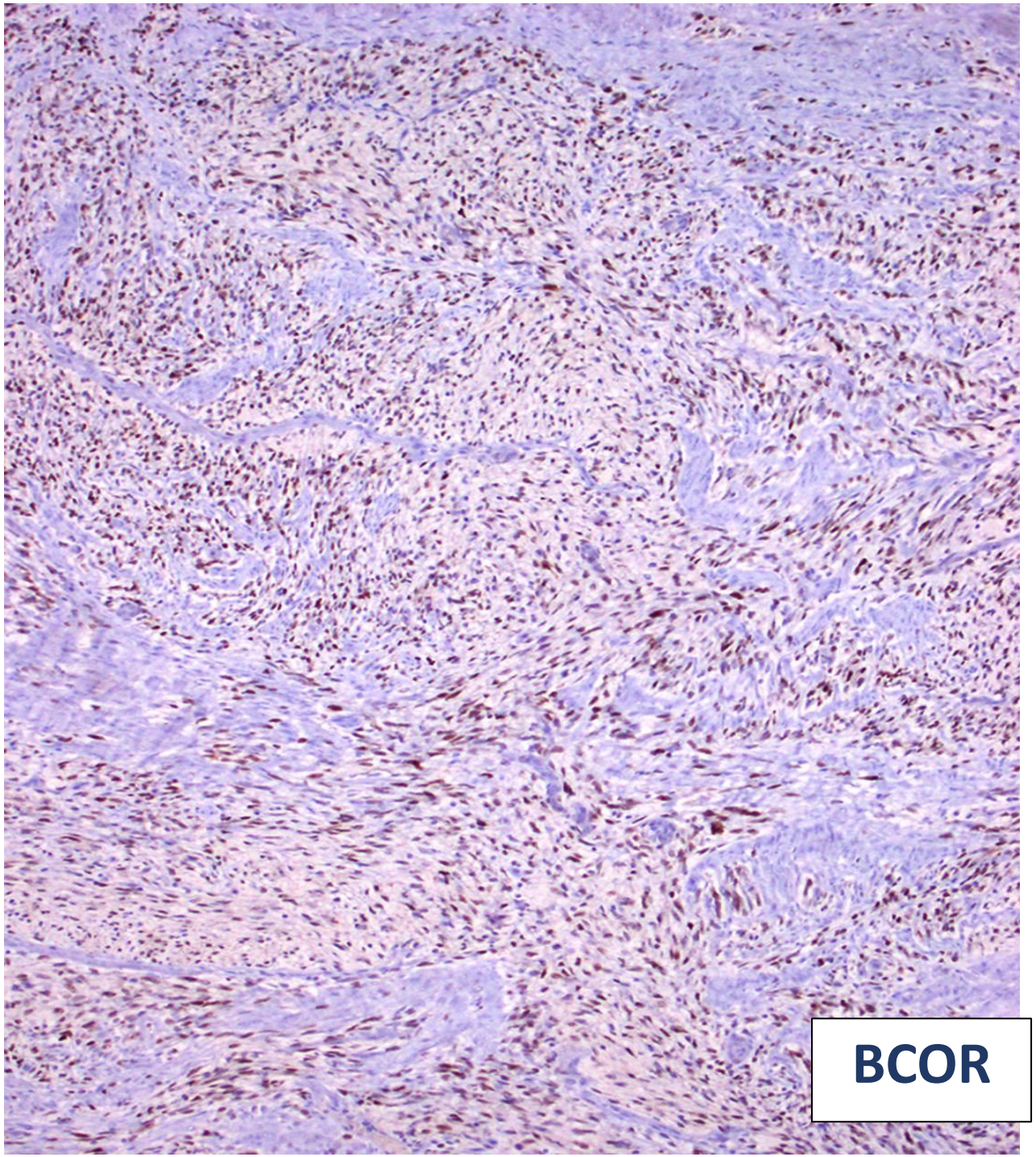

In a malignant myxoid spindle cell tumor negative for BCOR and muscle markers showing diffuse cyclinD1 expression perform MOLECULAR STUDIES

BCOR- Partner fusion gene in a variety of mesenchymal neoplasms

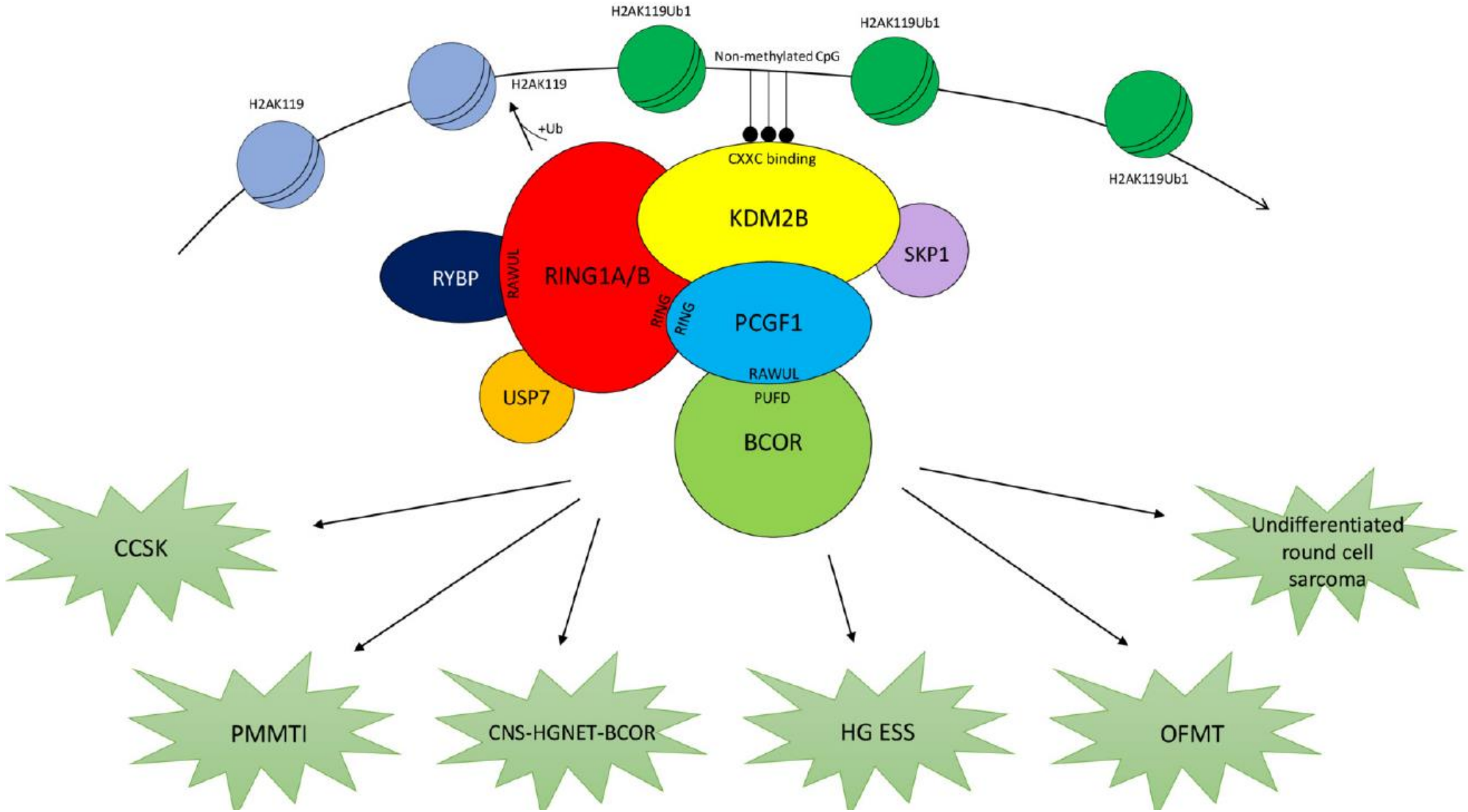

Aldera AP, Govender D. J Clin Pathol 2020;73:314–317

Genomic profiling of *BCOR*-rearranged uterine sarcomas reveals novel gene fusion partners, frequent *CDK4* amplification and *CDKN2A* loss

Gynecol Oncol 2020

….and broader morphologic spectrum, including admixture of spindle, epithelioid or small round cells and severe cytologic atypia

Endometrial stromal sarcomas with *BCOR*–rearrangement harbor *MDM2* amplifications

J Pathol 2020

……Also high frequency of CDK4 amplification combined with cyclinD1 protein overexpression

Potential therapeutic targets

UTERINE AND VAGINAL SARCOMAS RESEMBLING FIBROSARCOMA: A clinicopathologic study and molecular analysis of 13 cases showing common NTRK-rearrangements and the description of a COL1A1-PDGFB fusion novel to uterine neoplasms

Croce S, et al, Modern Pathol 2019;32:1008-1022

- **NTRK-rearranged sarcomas (7)**

Mean 31 years, centered in cervix, and early stage at dx
Patternless, herringbone or fascicular architecture, spindle cells with mild to moderate atypia. Often prominent lymphocytic infiltrate
Trk diffuse cytoplasmic staining; CD34 and S100 positive; desmin, BCOR, ER and PR negative

- **COL1A1-PDGFB rearranged sarcomas (3)**

Uterine corpus and cervix, stage I to III
Storiform and herringbone architecture, spindle cells with mild to moderate atypia
CD34 positive; ER, PR, S100, Trk negative

- **Fibroblastic sarcoma with features of malignant nerve sheath tumor (3)**

Uterine corpus, cervix and vagina
S100 (diffuse or focal) positive and H3K27 loss (the latter in two of three tumors)
Trk negative and variable expression of CD34

NTRK-REARRANGED CERVICAL SPINDLE CELL NEOPLASM

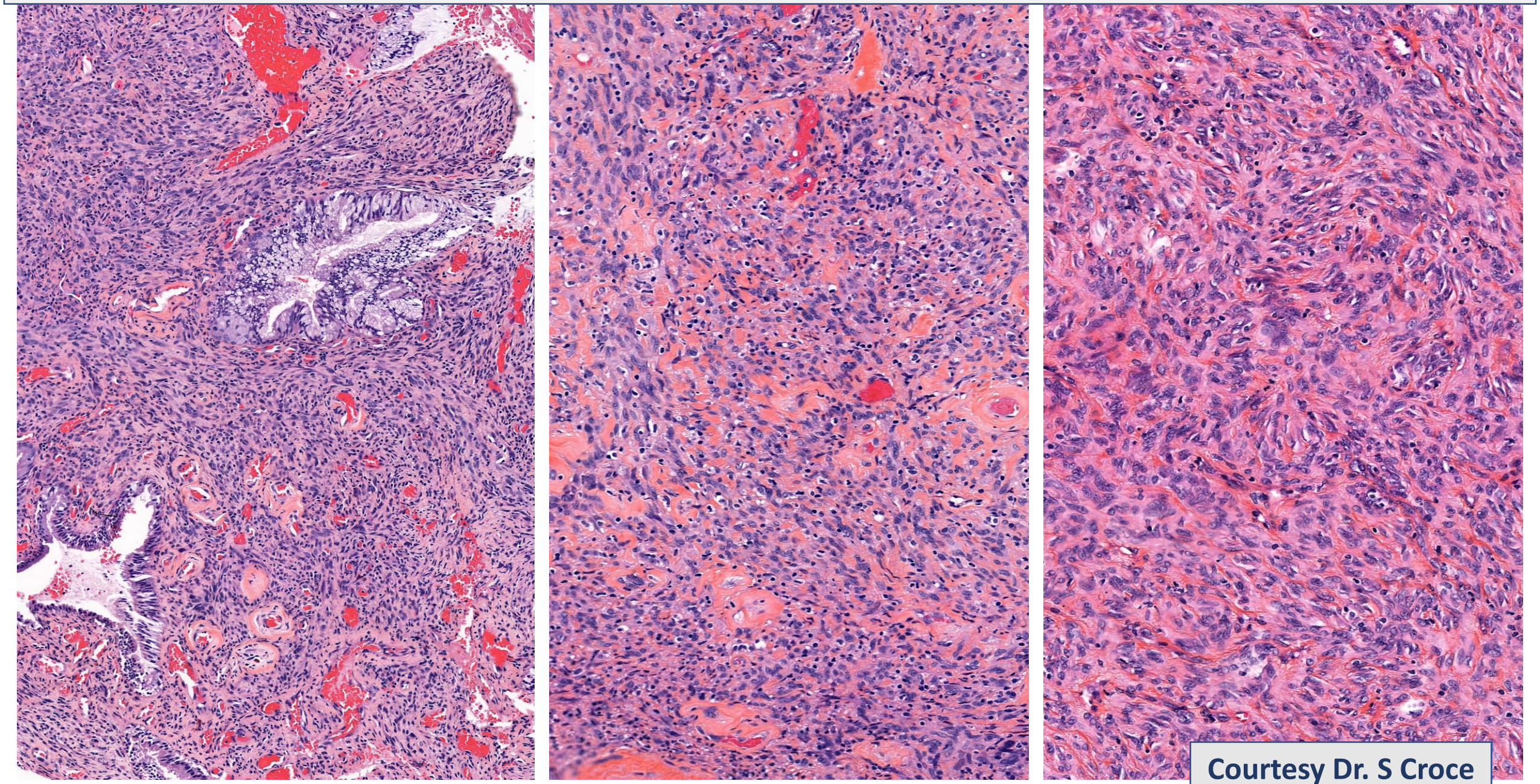

Courtesy Dr. S Croce

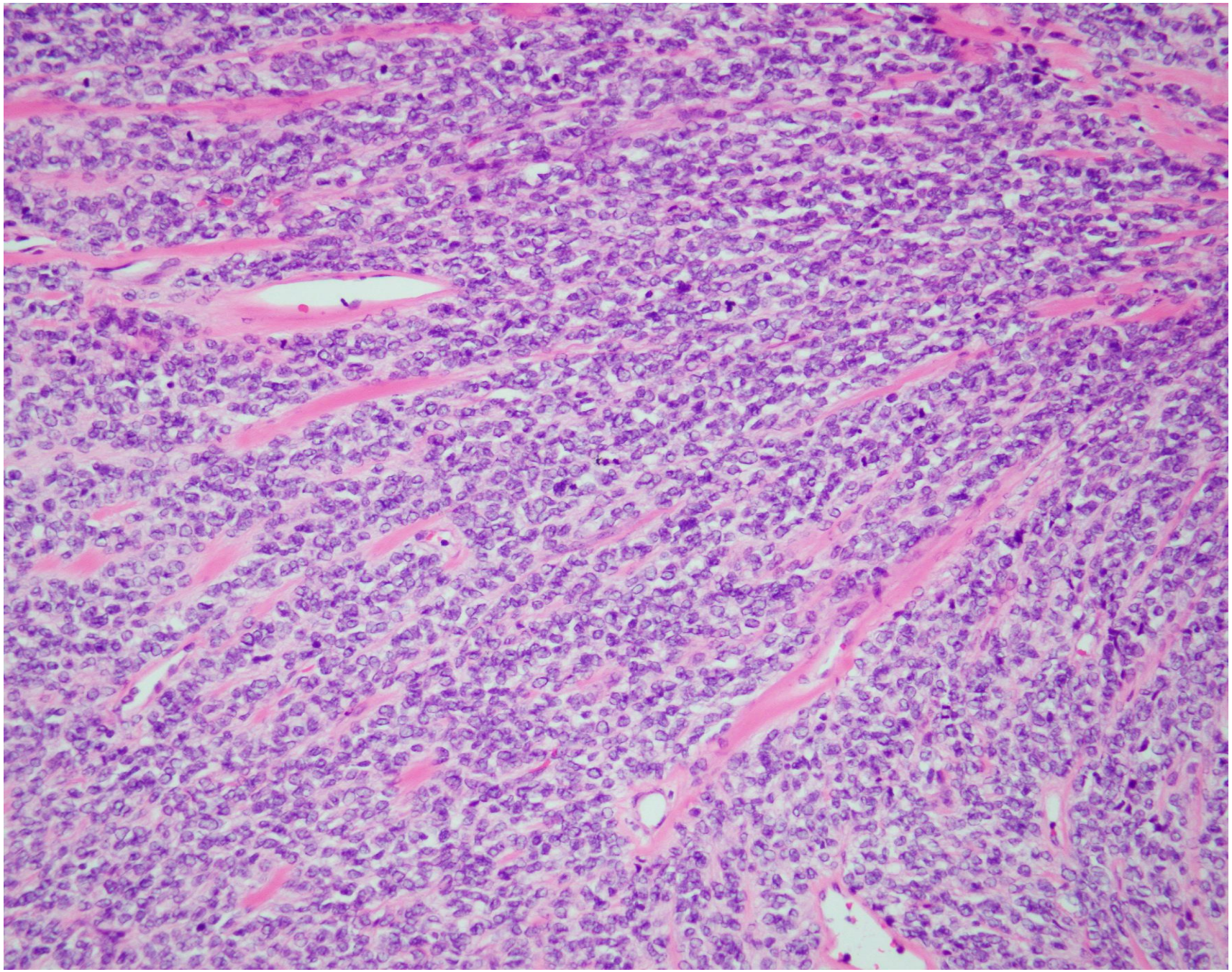

NTRK CERVICAL SARCOMA (Fusion positive)

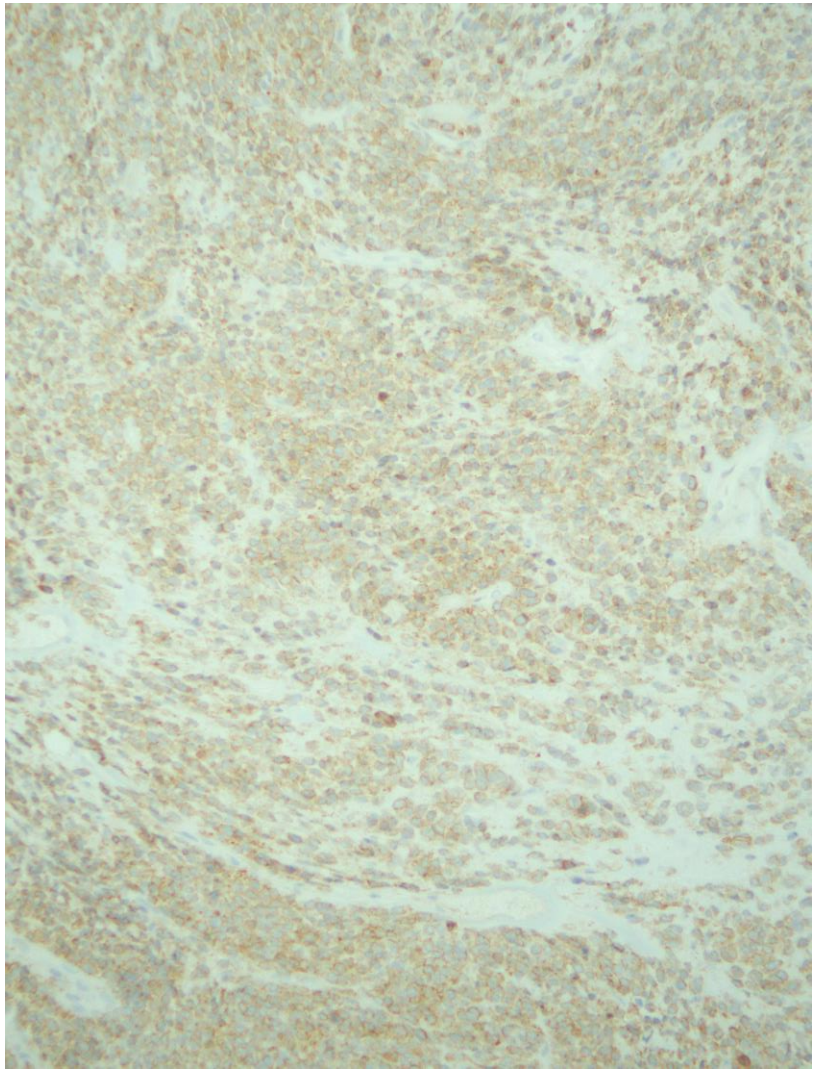

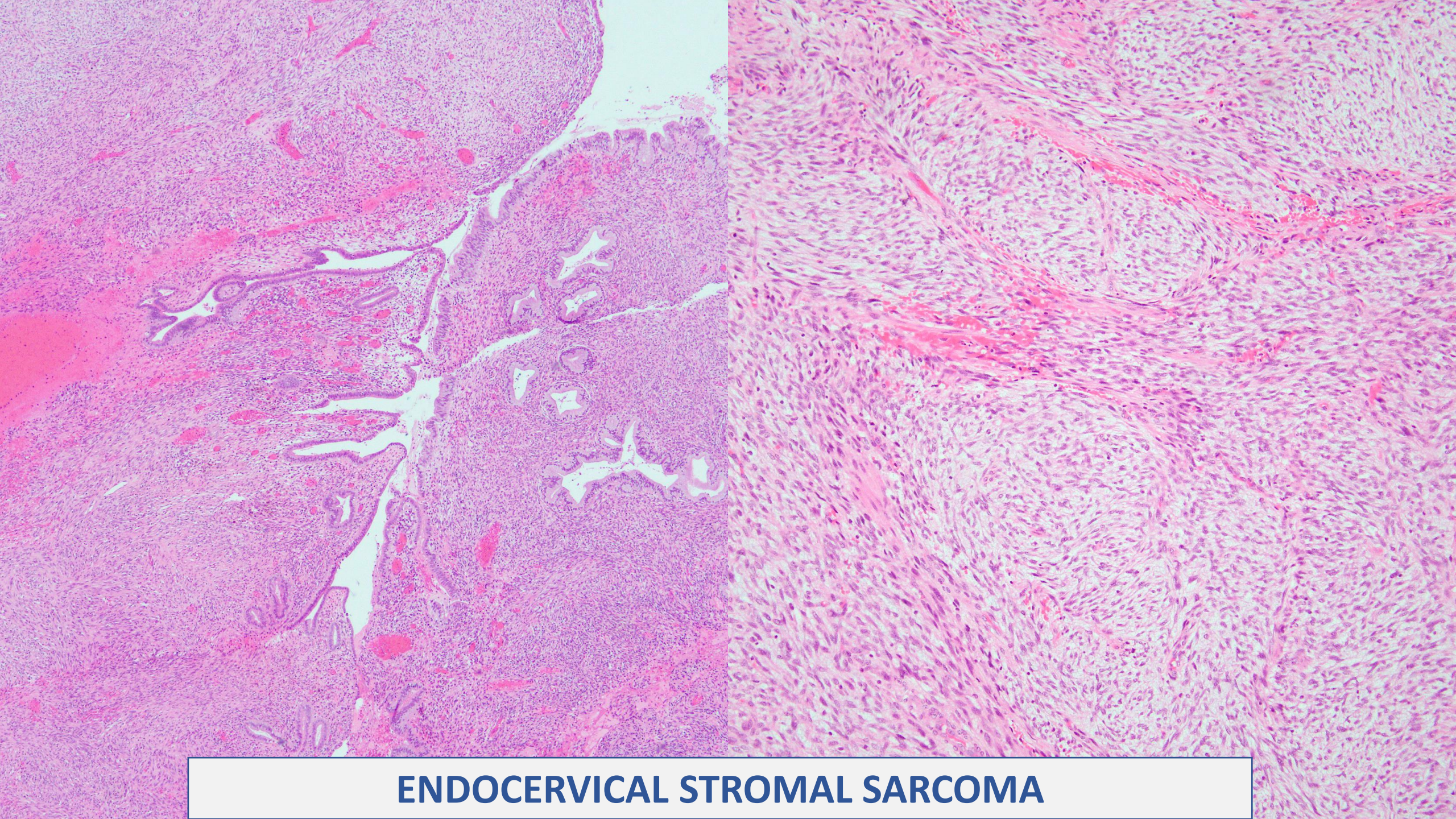

ENDOCERVICAL STROMAL SARCOMA

Likely fibroblastic sarcoma with features of malignant nerve sheath tumor

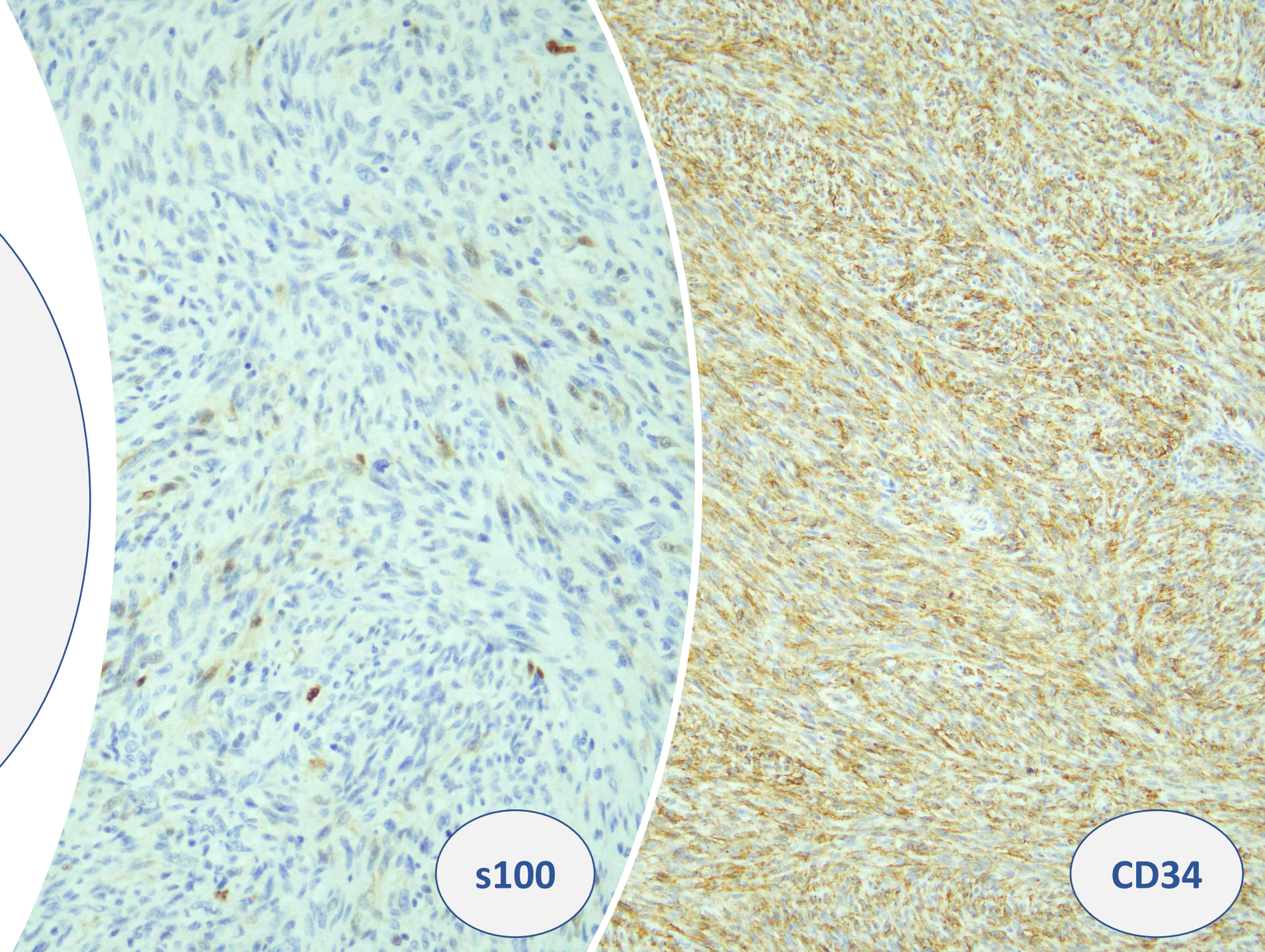

Targeted RNA expression profiling identifies high-grade endometrial stromal sarcoma as a clinically relevant molecular subtype of uterine sarcoma

Momeni-Boroujeni A, et al, Modern Pathol 2020

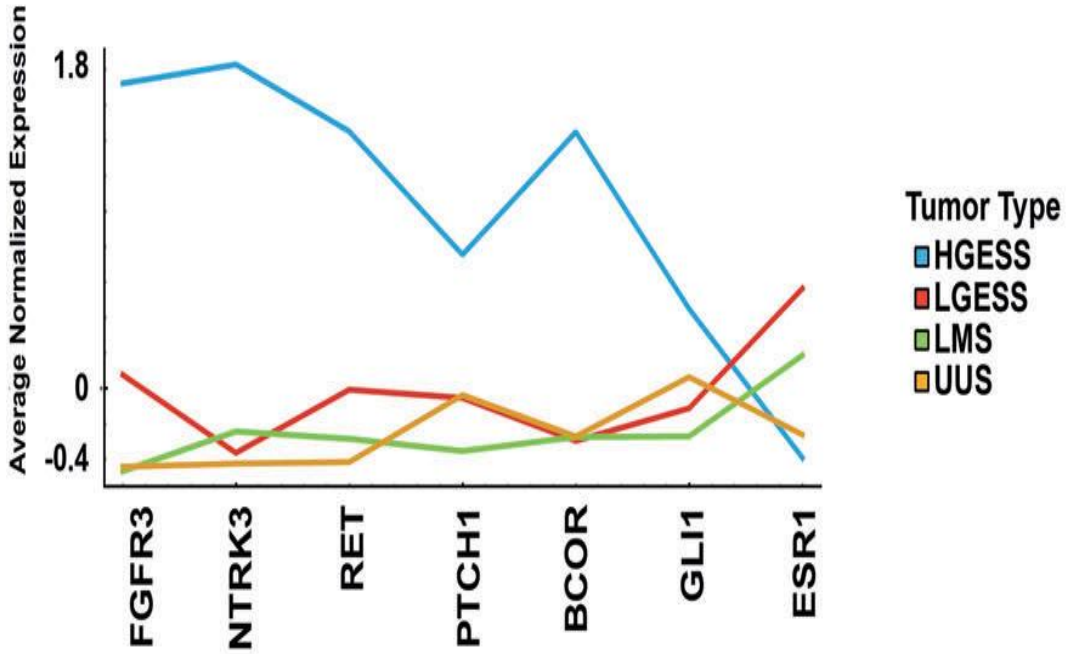

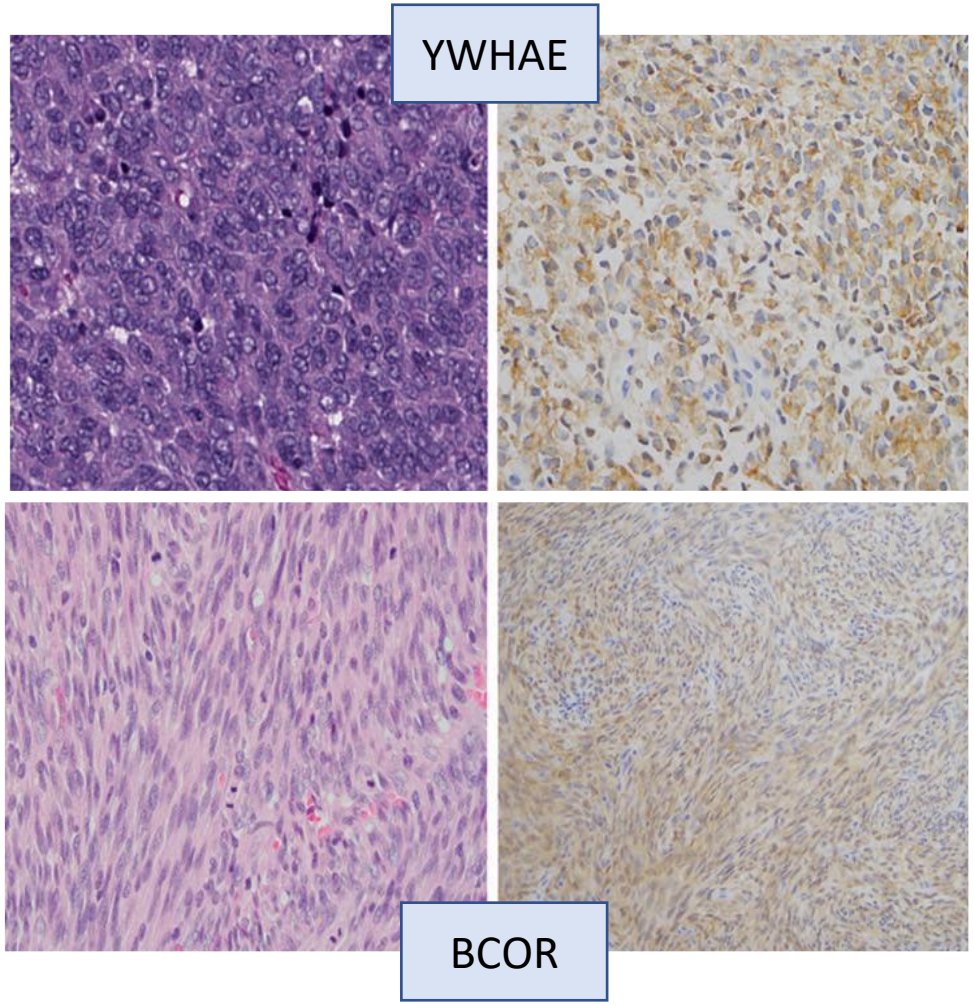

Cytoplasmic and/or nuclear pan-Trk staining of variable extent and intensity was seen in 91% of HGESS regardless of cyclin D1 and/or BCOR positivity

UTERINE SOLITARY FIBROUS TUMOR

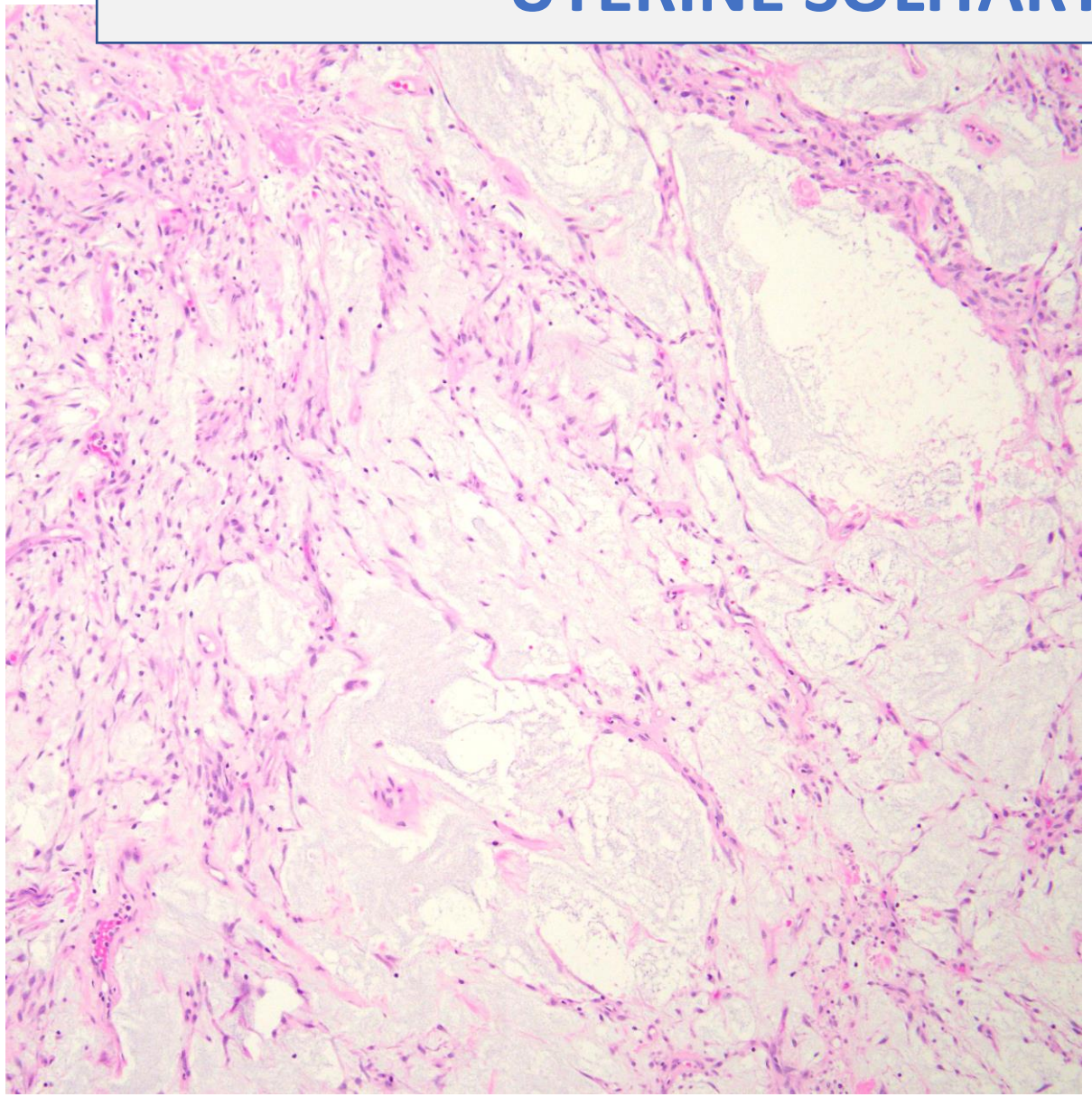

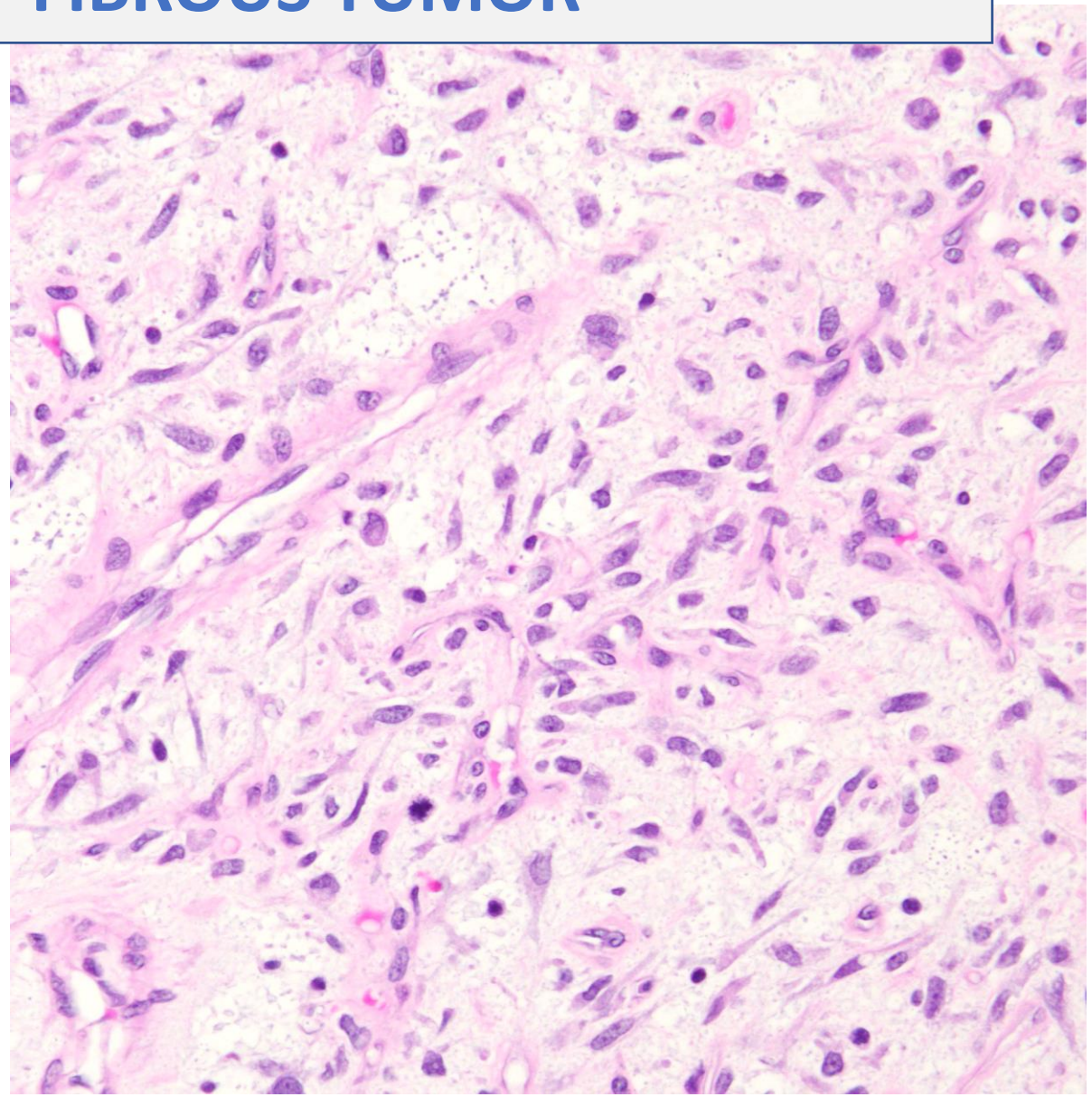

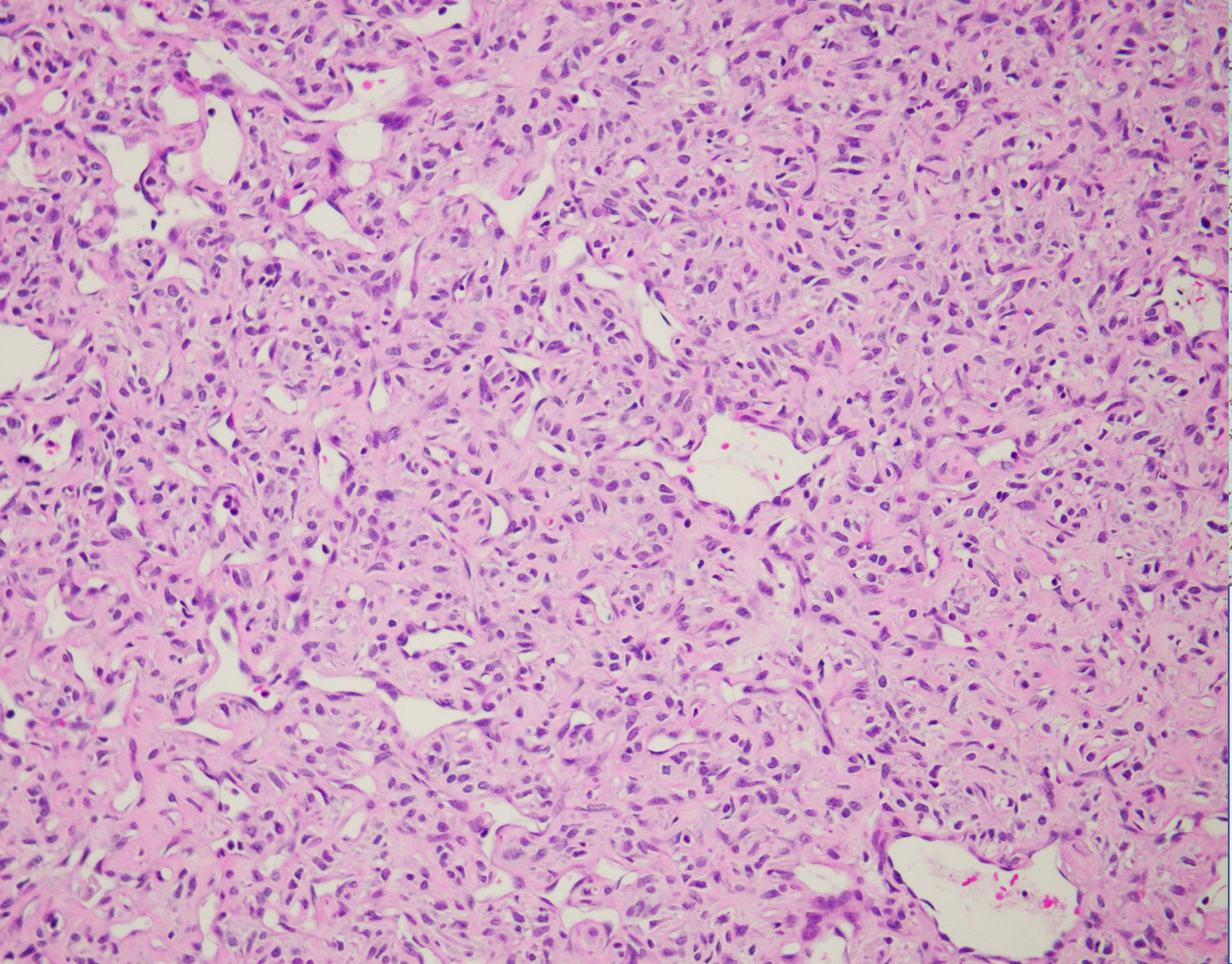

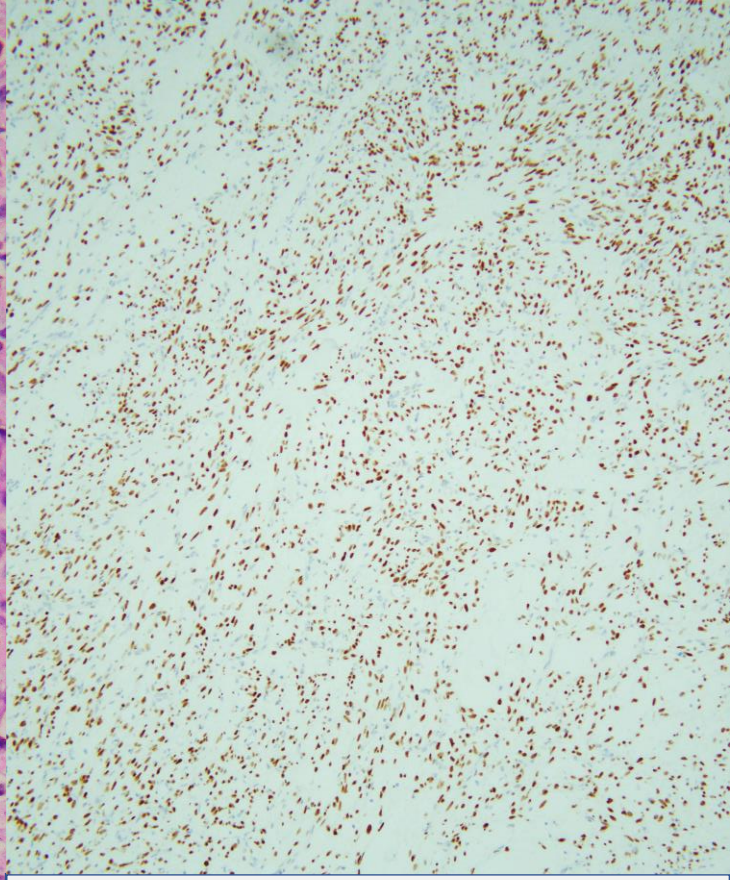

TYPICAL MORPHOLOGY AND STAT6 POSITIVE

…..reported to be BCOR positive if malignant at least in kidney

HOSPITAL DE LA SANTA CREU I SANT PAU



MASSACHUSETTS GENERAL HOSPITAL



THANK YOU!

MYXOID MESENCHYMAL TUMORS

ALK, BCOR, CyclinD1, PLAG1, p16, p53 immunohistochemistry

TP53, ATRX, MED12 mutations

PLAG1, HMGA2, BCOR, BCORL1, ALK rearrangements

LMS	IMT	BCOR HG-ESS
PLAG1 and/or p53 positive, 20% BCOR; rarely CyclinD1 +	ALK positive	CyclinD1> BCOR positive
TP53 (32%), (*ATRX)* (26%), *MED12* (21%); BRCA2 (rare) mutations	ALK rearrangement	BCOR,BCORL1 rearrangements
PLAG1 and/or HMGA2 rearrangements		

Novel PLAG1 Gene Rearrangement Distinguishes a Subset of Uterine Myxoid Leiomyosarcomas From Other Uterine Myxoid Mesenchymal Tumors

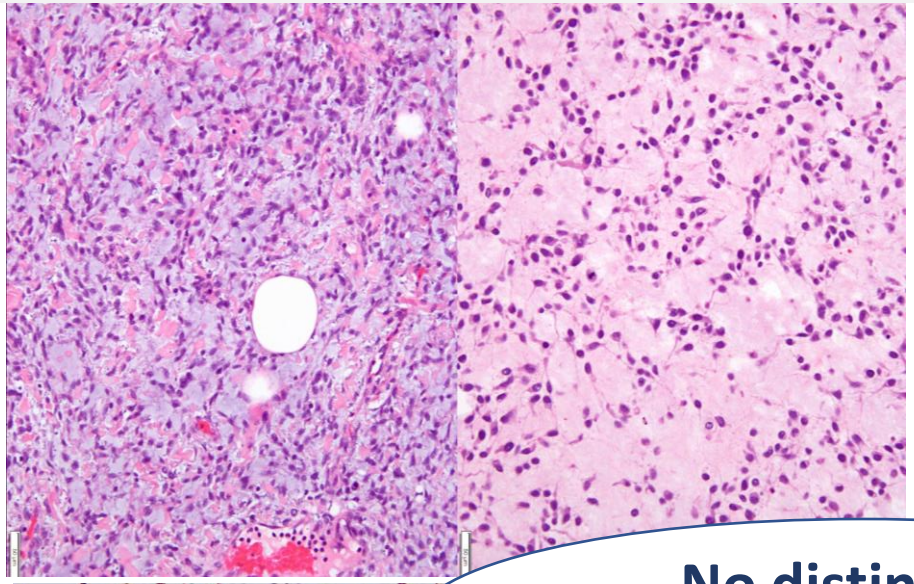

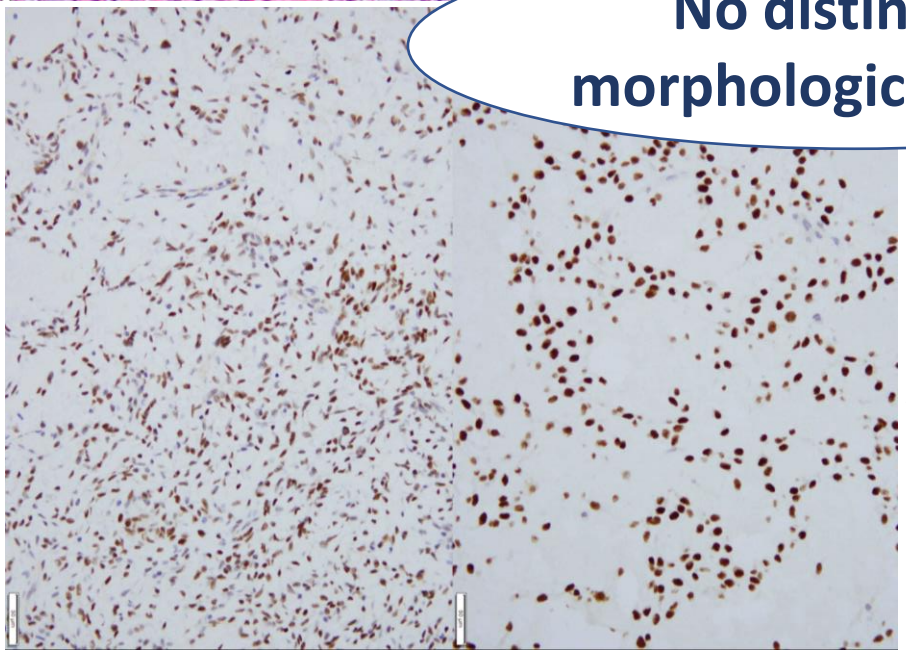

No distinctive morphologic features

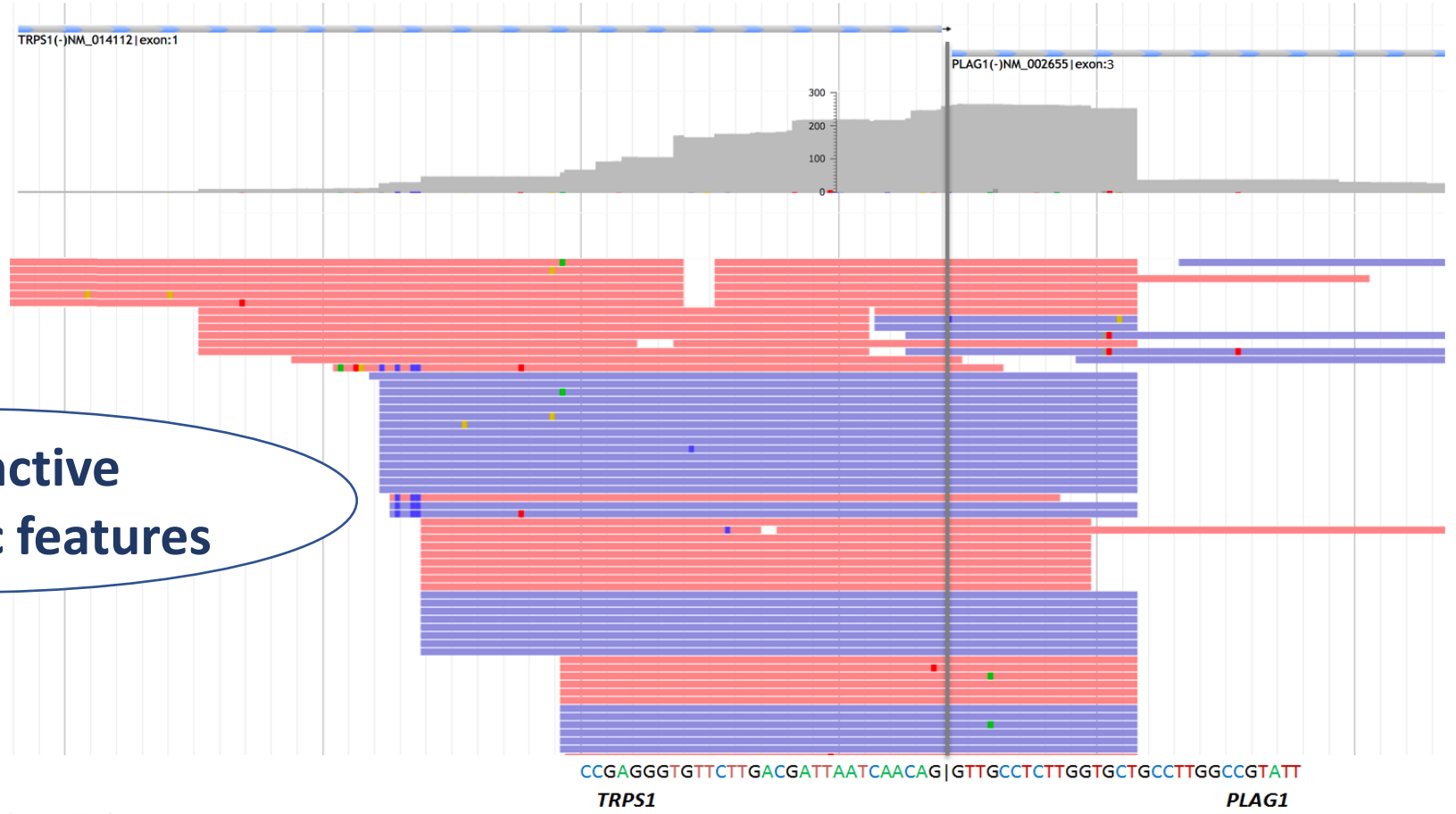

TRPS1-PLAG1 fusion>RAD51B-PLAG1 fusion (NGS/FISH)

Arias Stella JA et al, Am J Surg Pathol 2019; 43:382-388

Pregnancy-associated Inflammatory Myofibroblastic Tumors of the Uterus Are Clinically Distinct and Highly Enriched for *TIMP3-ALK* and *THBS1-ALK* Fusions

Kelly A. Devereaux, MD, PhD, Megan B. Fitzpatrick, MD, Sara Hartinger, BS, MS, Carol Jones, BS, Christian A. Kunder, MD, PhD, and Teri A. Longacre, MD

(*Am J Surg Pathol* 2020;44:970–981)

- If pregnancy-associated, usually incidentally found at time of delivery, adherent to the placenta or as a detached mass
- Typically well-circumscribed and small (0.5 to 6.8 cm)
- May display decidual-like appearance
- In contrast to non-pregnancy associated IMTs that ALK gene rearrangements with several different fusion partners, including THBS1, TIMP3, IGFB5, FN1, TNS1, DES, SEC. 31, TPM3, and DCTN1, those pregnancy related are enriched for TIMP3 and THBS1, and we recently encountered a novel *SYN3-ALK* fusion
- Always benign

Uterine Epithelioid Leiomyosarcomas With Clear Cells

Reactivity With HMB-45 and the Concept of PEComa

Elvio G. Silva, MD, Michael T. Deavers, MD,* Diane C. Bodurka, MD,† and Anais Malpica, MD**

Am J Surg Pathol 2004;28:244

ELSEVIER

Available online at www.sciencedirect.com

SCIENCE DIRECT®

Annals of Diagnostic Pathology 9 (2005) 43–45

Annals of DIAGNOSTIC PATHOLOGY

A uterine leiomyosarcoma that became positive for HMB_{45} in the metastasis

Elvio G. Silva[a,*], Diane C. Bodurka[b], Maria A. Scouros[c], Alberto Ayala[a]

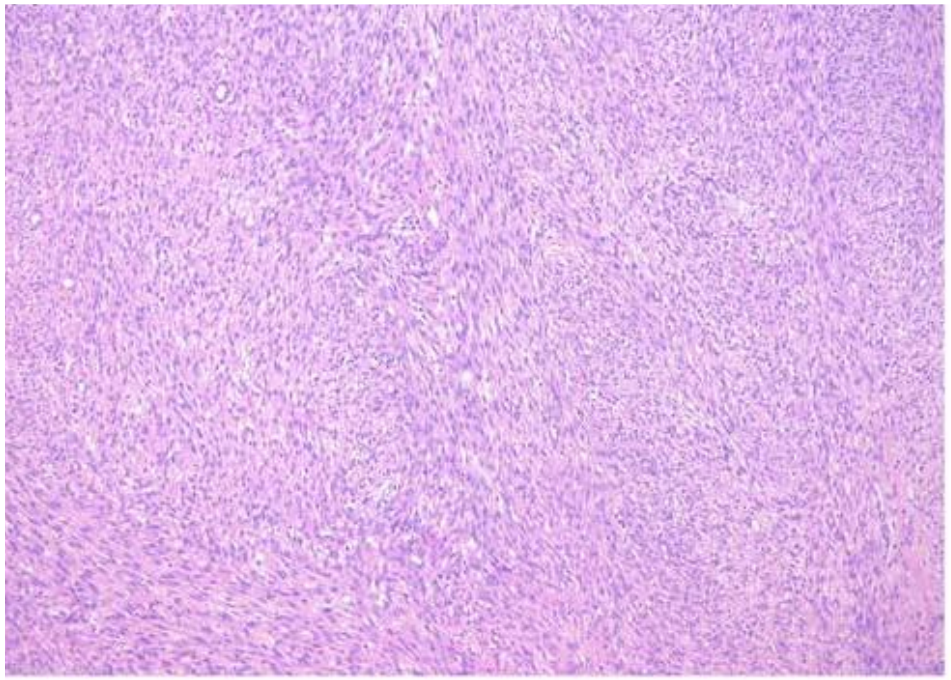

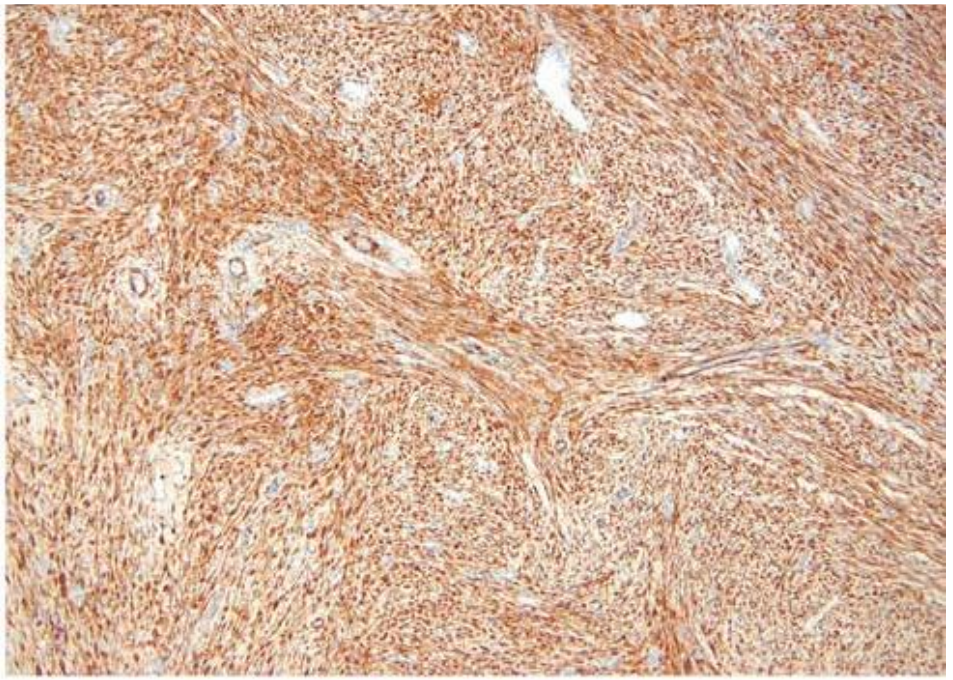

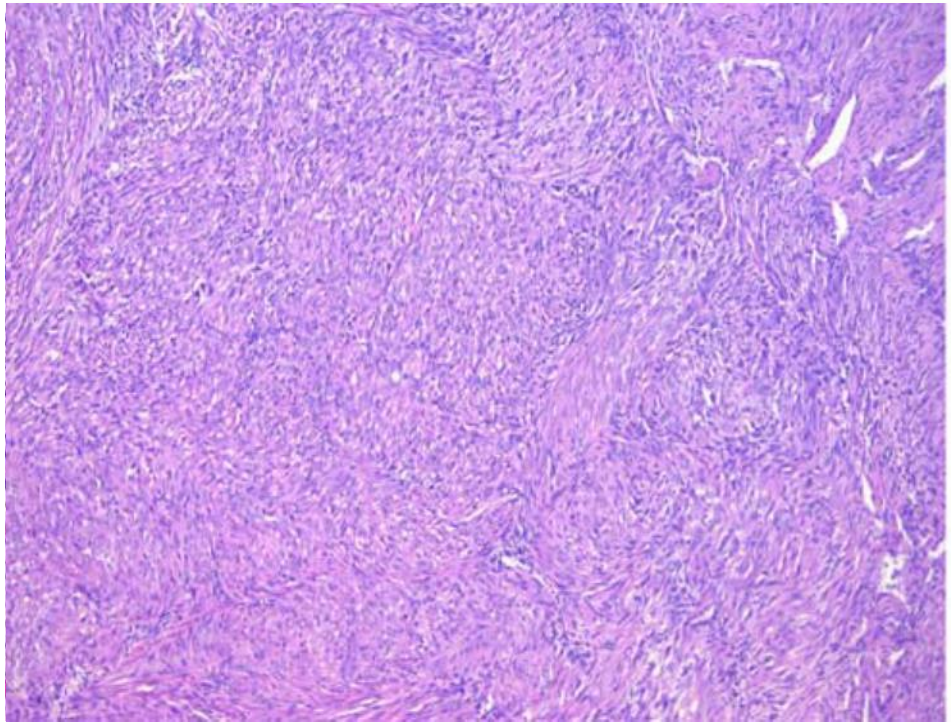

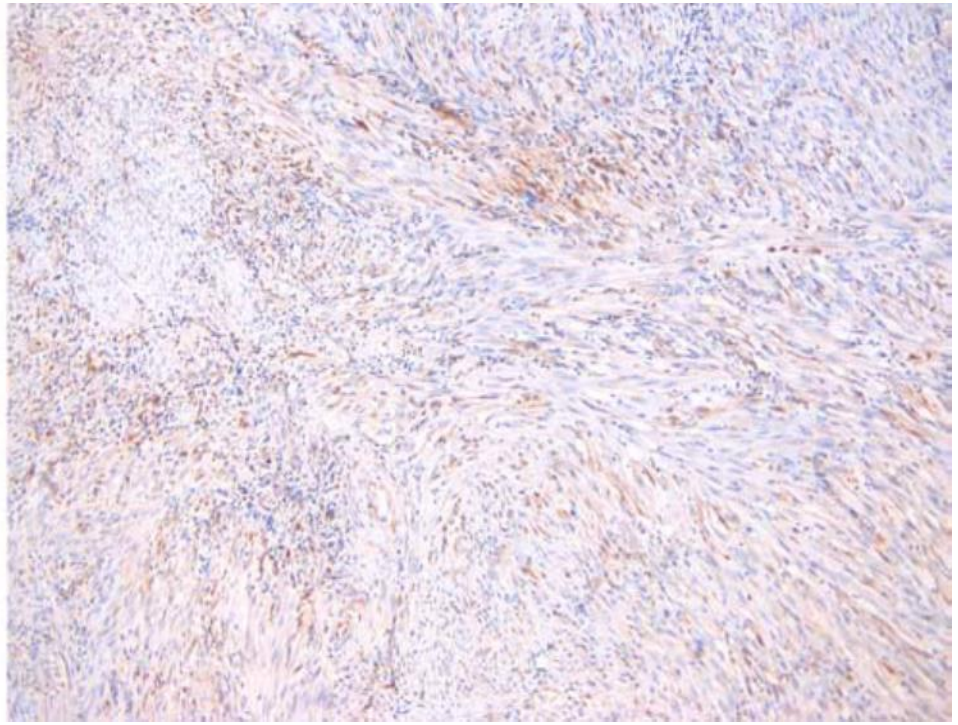

Transgelin more commonly, extensively, and strongly expressed in compacted areas

Solitary Fibrous Tumors of the Female Genital Tract: A Detailed Morphologic Study of 27 cases

K Devins, S Croce, E Burandt, J Bennett, A Pesci, GF Zannoni, PP Ip, GP Nielsen, R Young, E Oliva

- **Age 25 – 78 (mean: 55) years**

- **Sites:**
  - **Vulva = 7**
  - **Vagina = 2**
  - **Uterine cervix = 2**
  - **Uterine corpus = 6**
  - **Fallopian tube/broad ligament = 5**
  - **Ovary = 5**

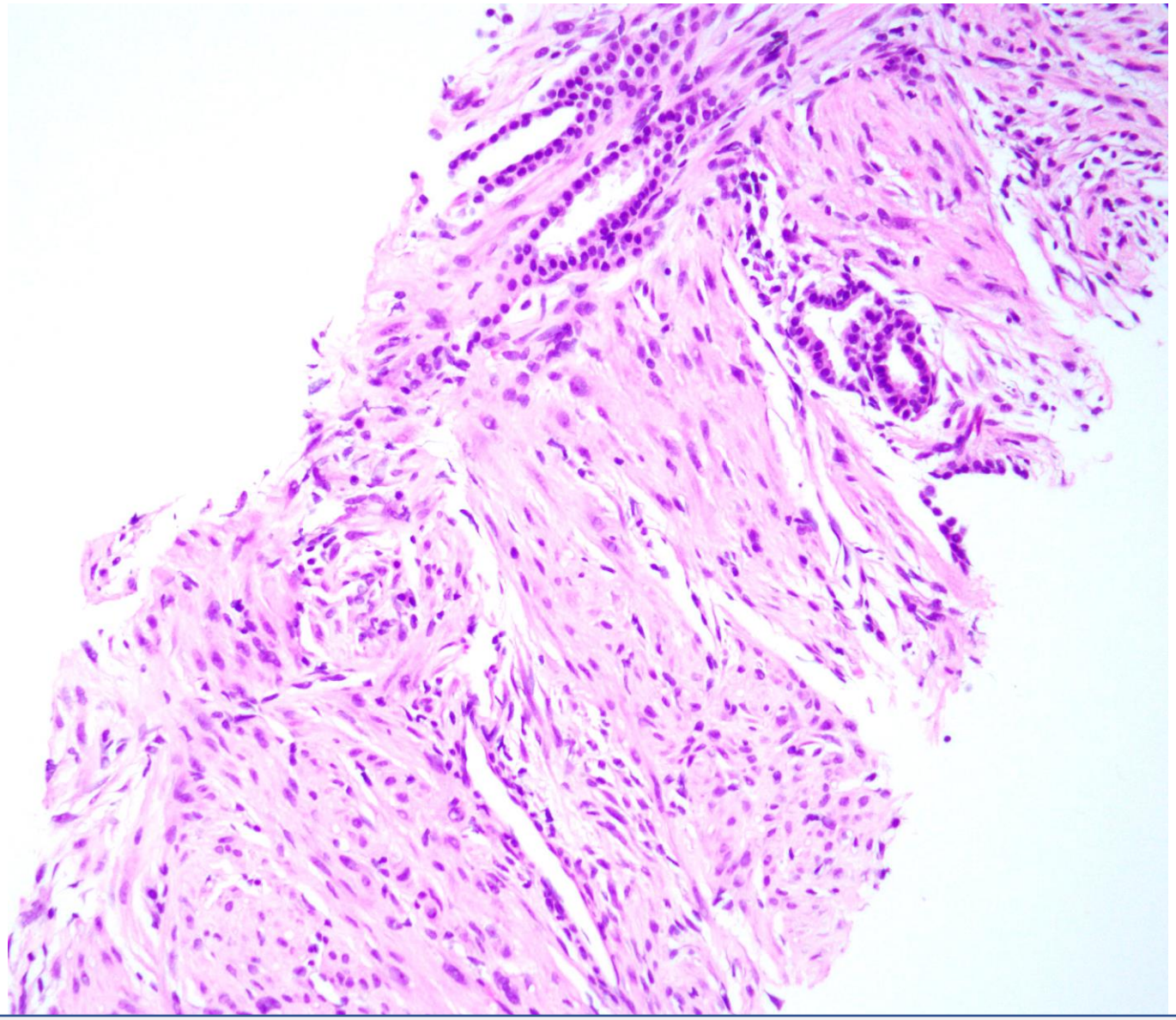

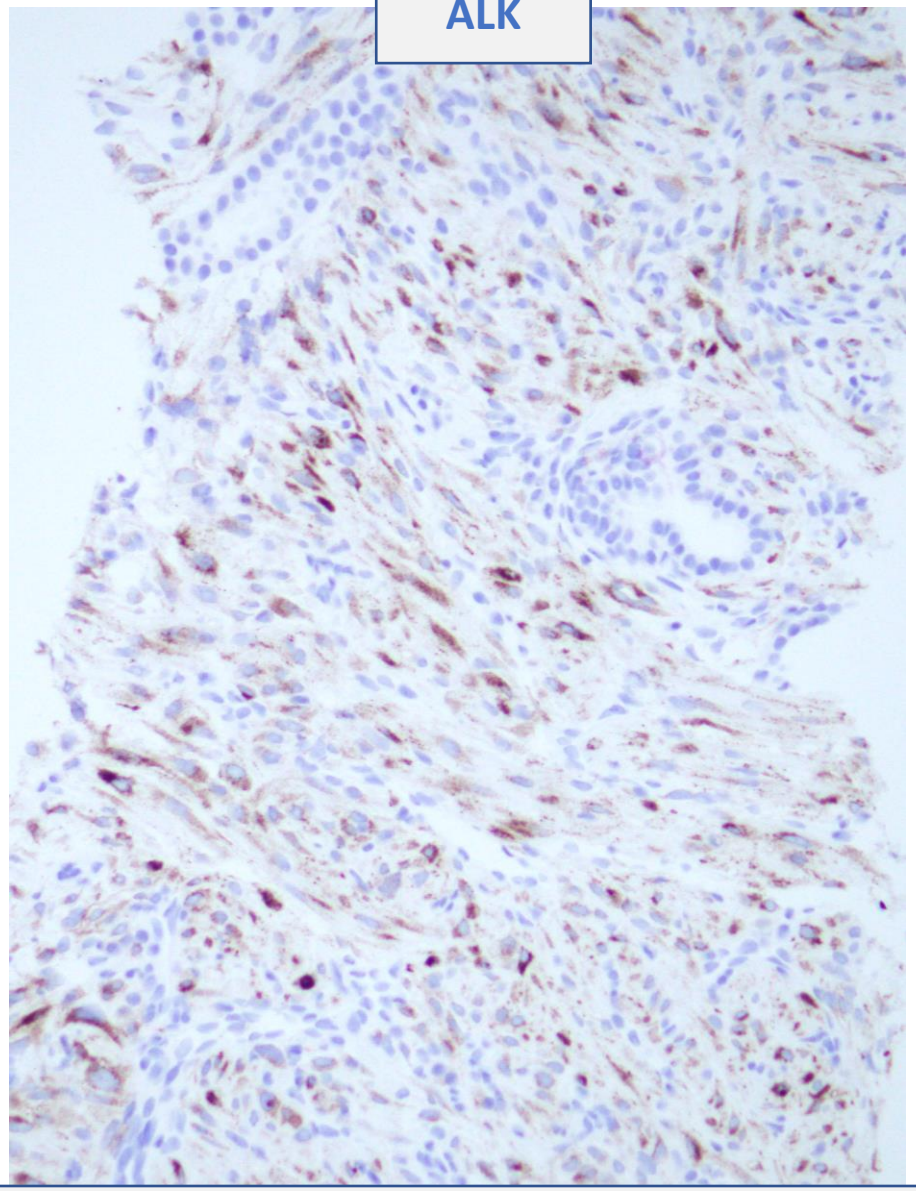

INFLAMMATORY MYOFIBROBLASTIC TUMOR METASTATIC TO LUNG: IDENTICAL APPEARANCE TO SMOOTH MUSCLE TUMOR